

Biology Charts

For use with any course book

The Axis (C2)

Odontoid Process

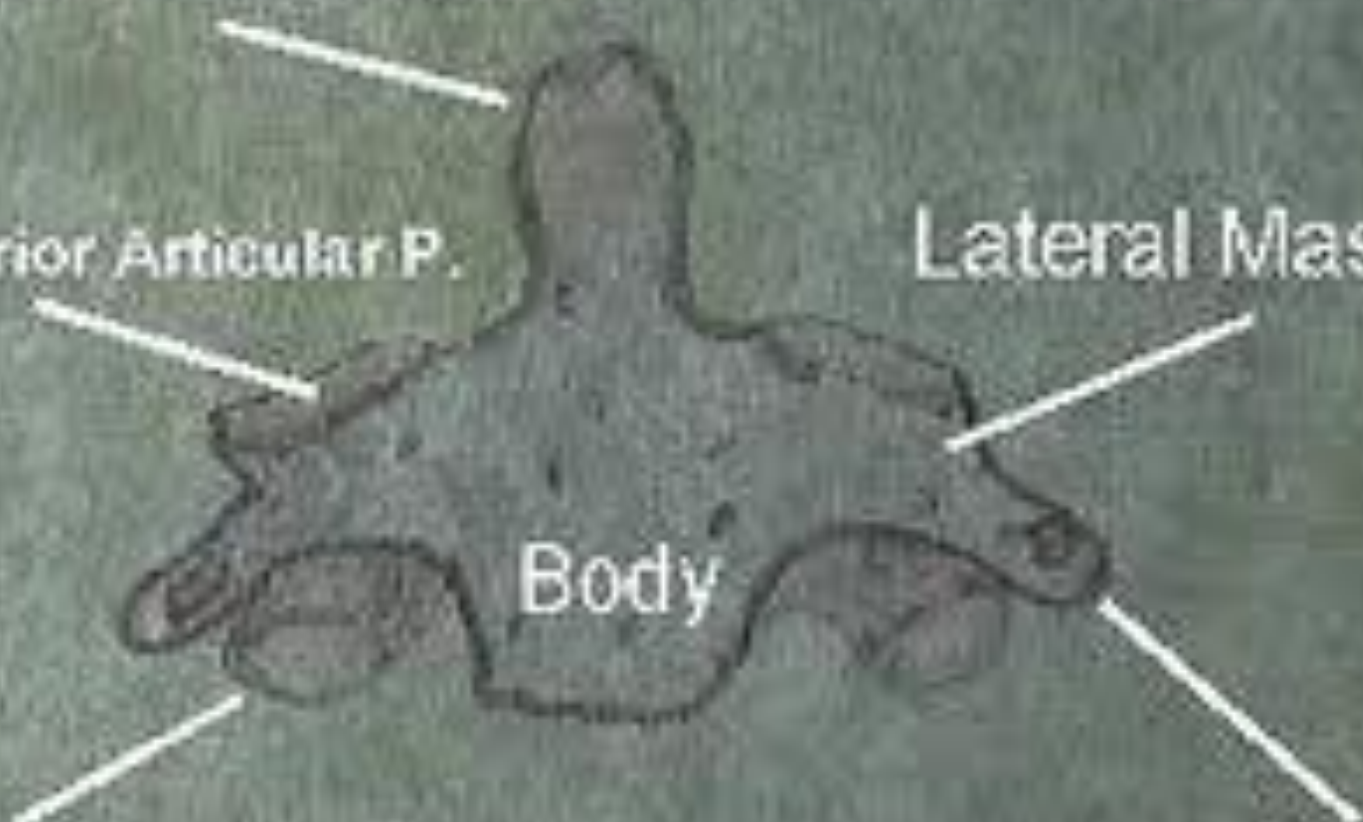
Superior Articular P.

Lateral Mass

Body

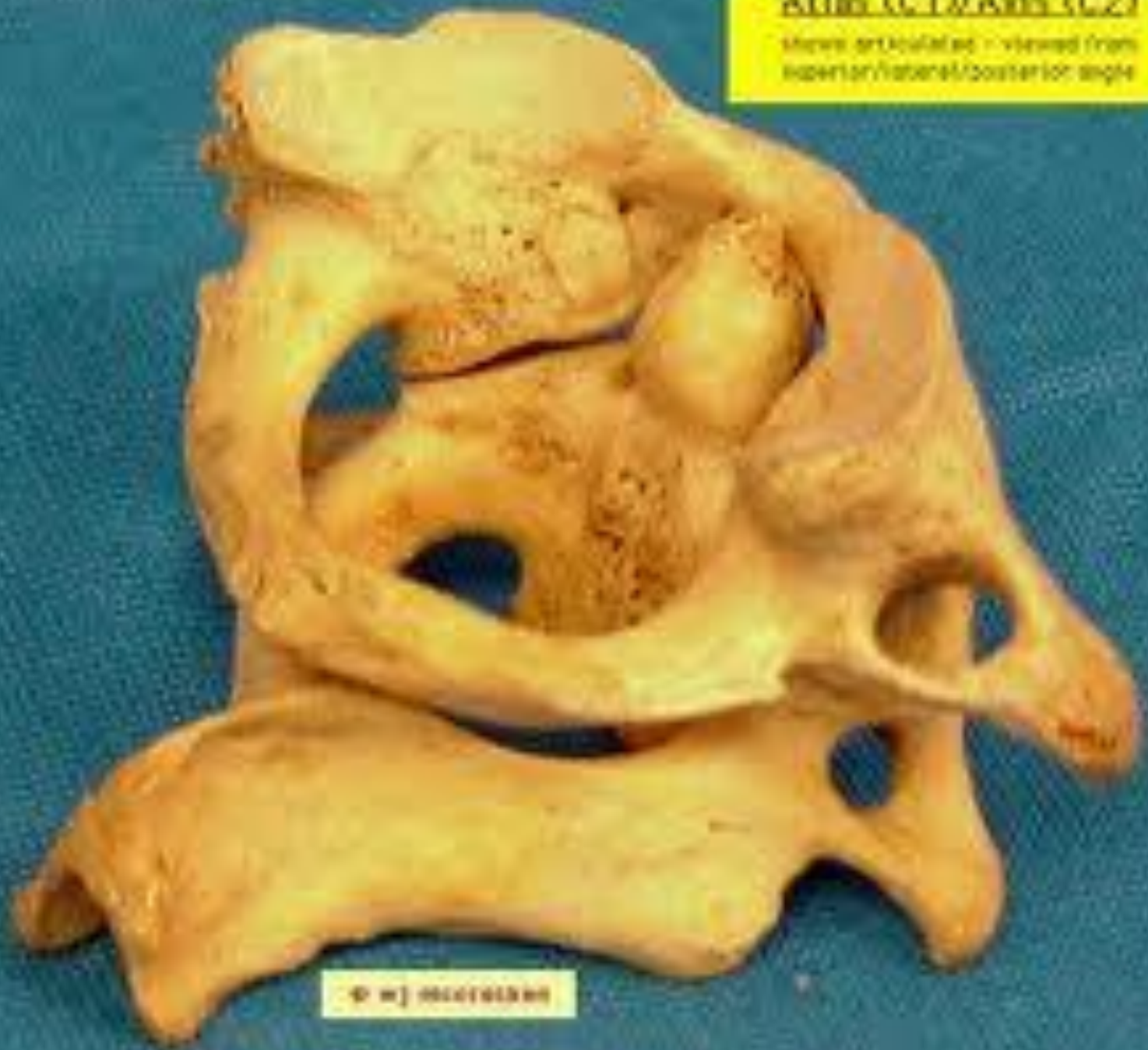Inferior Articular P.

Transverse Process



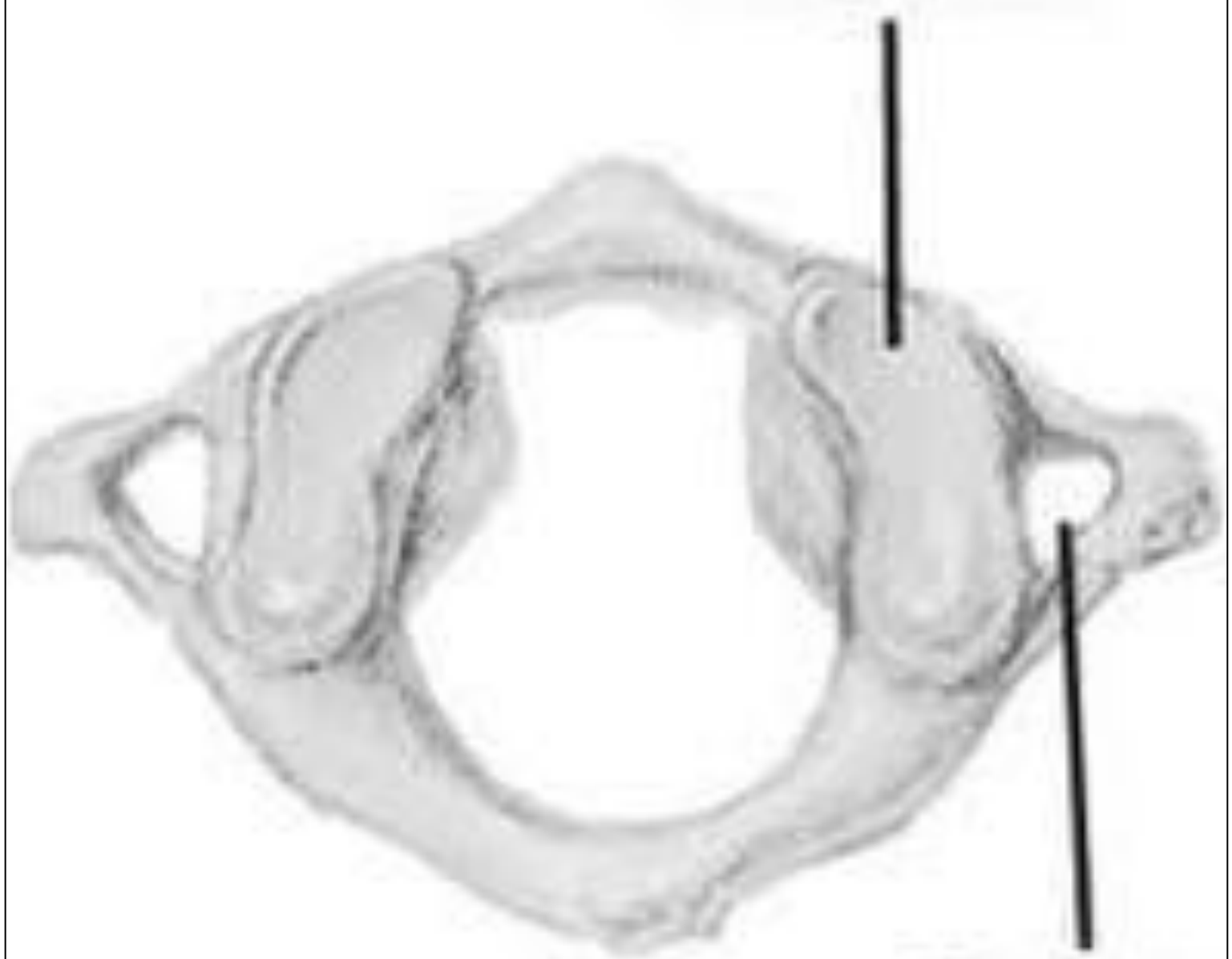
Atlas (C1)/Axis (C2)

shown articulated - viewed from
superior/lateral/posterior angle

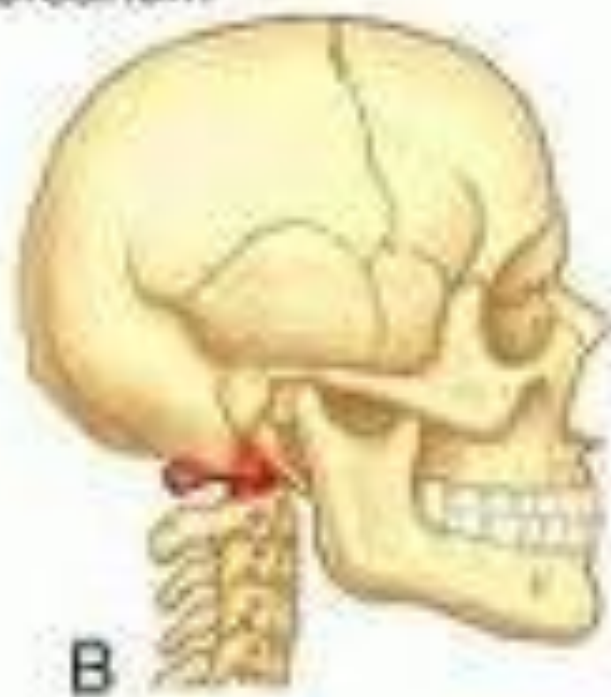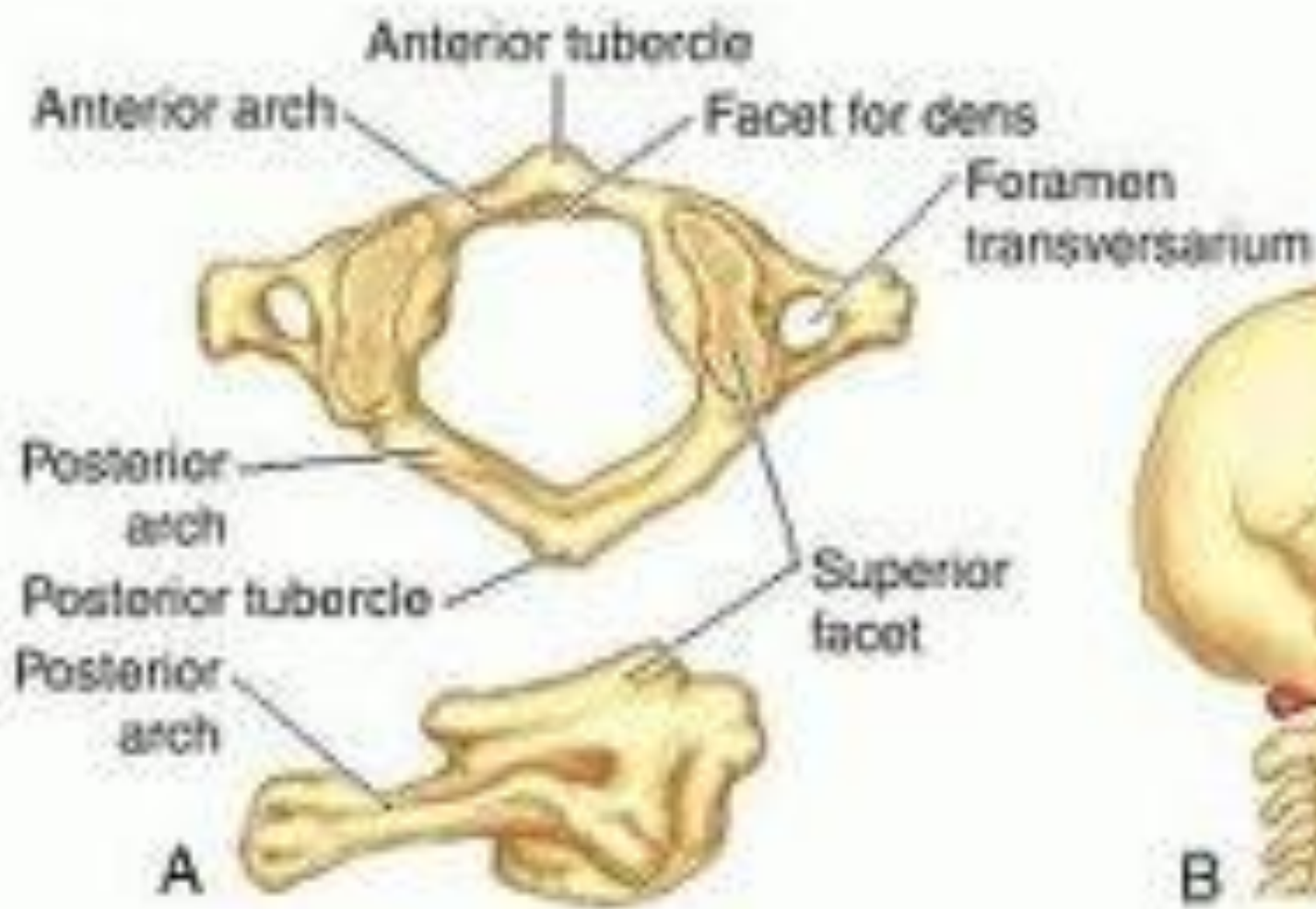


© WJ Associates Inc.

Articular facet



Transverse foramen



DIFFERENT LAND ANIMALS (1 of 3)



hare



zebra



tiger



rhinoceros



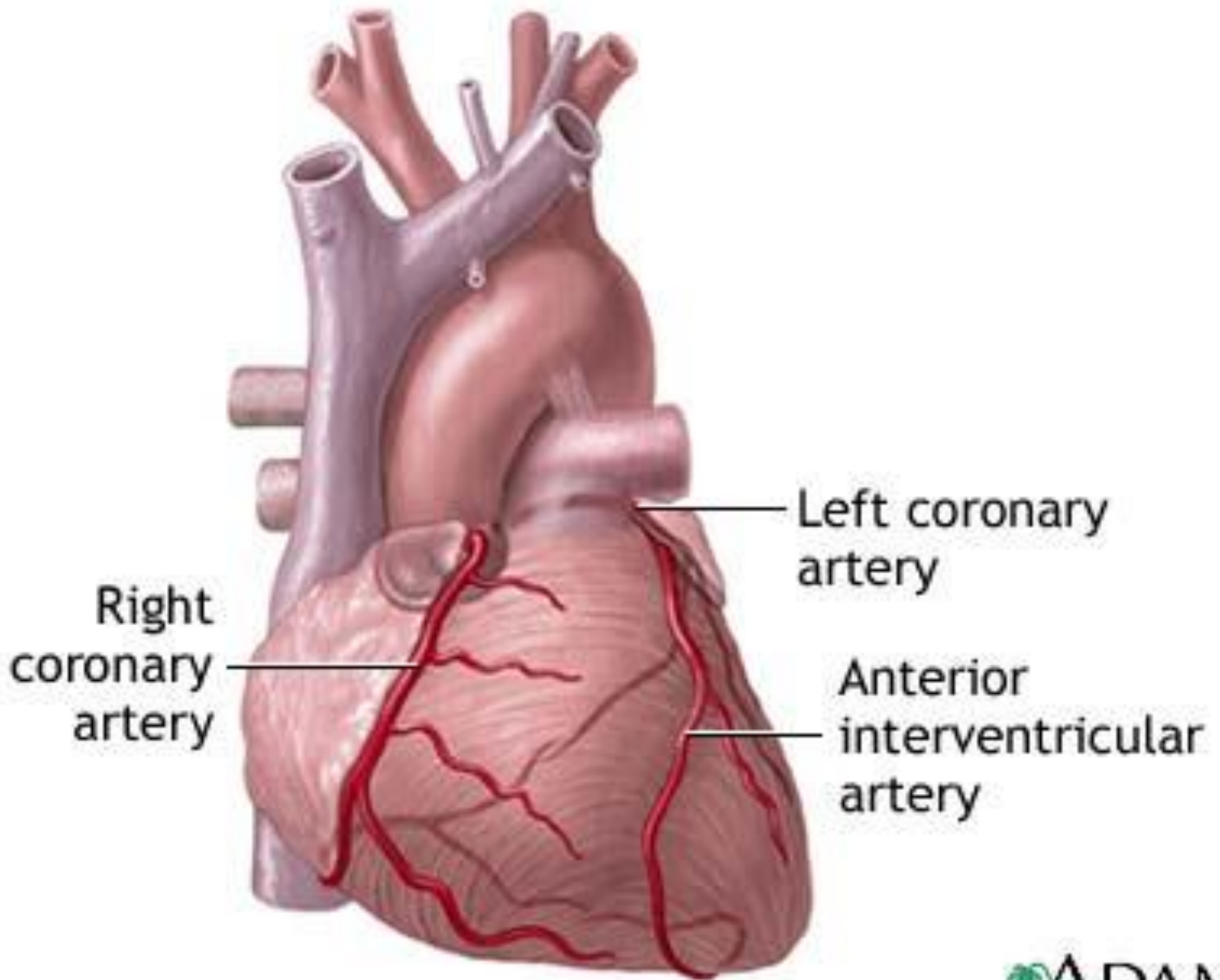
raccoon



bear

LES ANIMAUX DE LA FERME / FARM ANIMALS





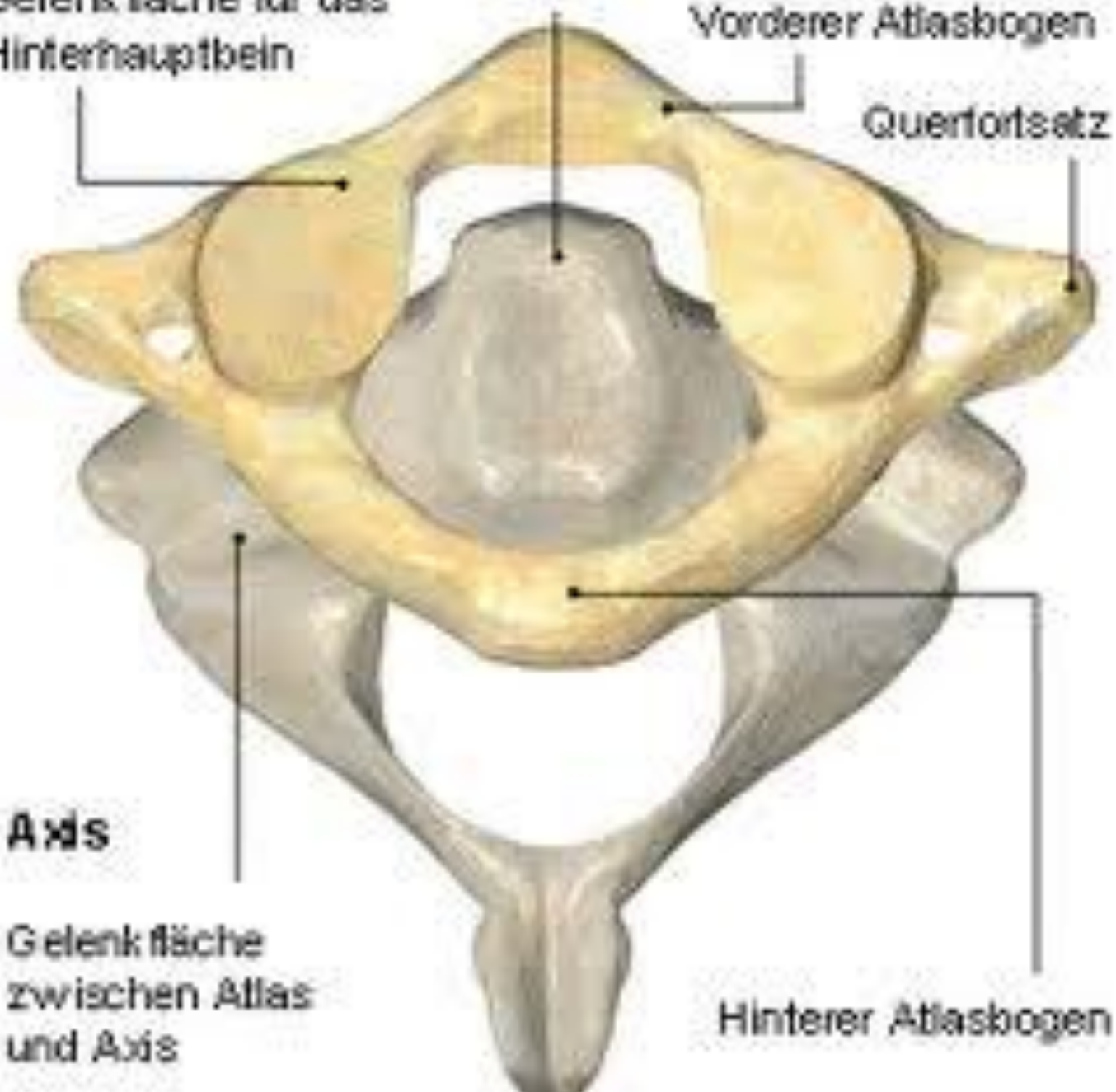
Atlas

Gelenkfläche für das Hinterhauptbein

Dens Axis

Vorderer Atlasbogen

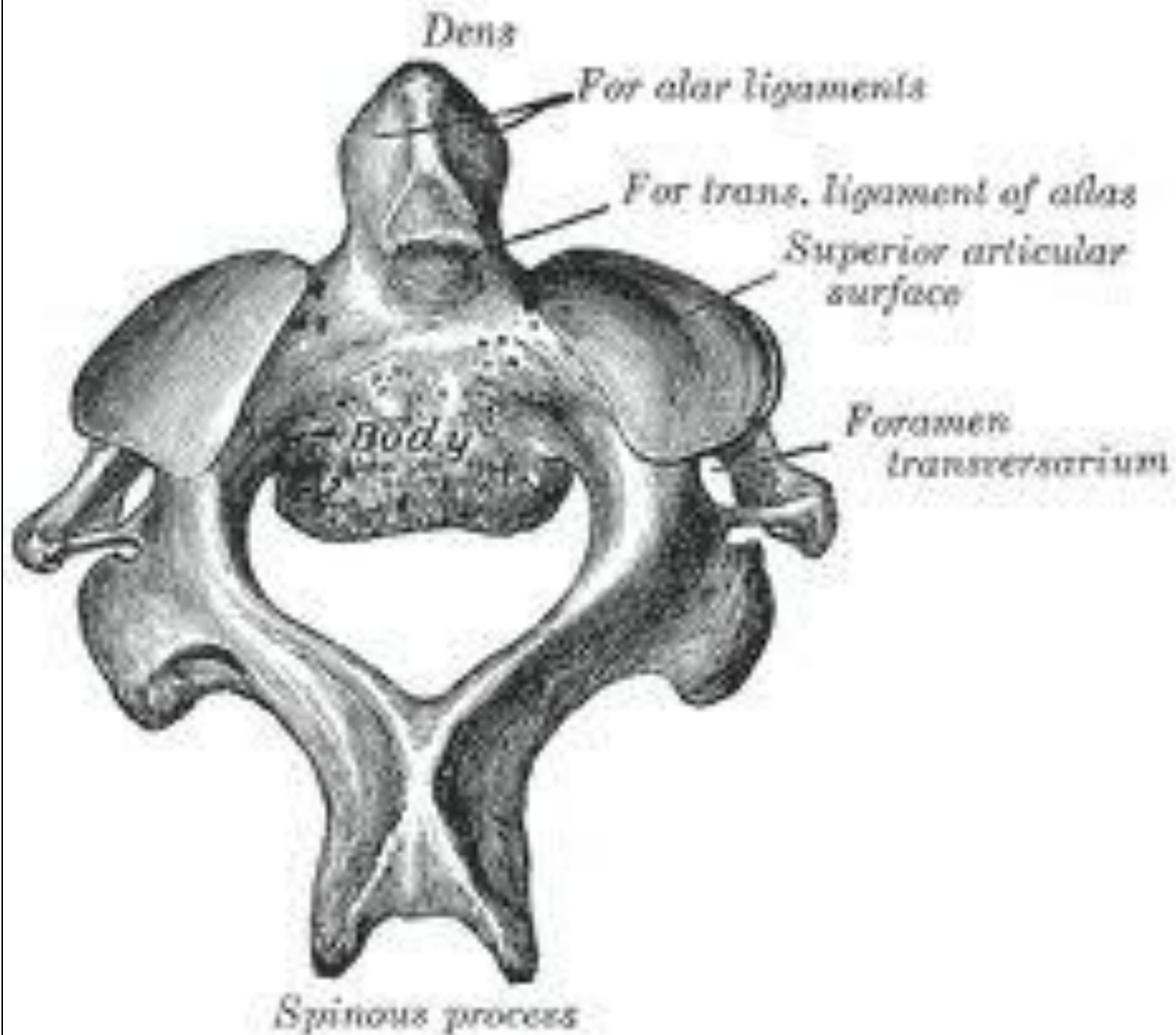
Querfortsatz



Axis

Gelenkfläche zwischen Atlas und Axis

Hinterer Atlasbogen



Nerve Cell (Neuron)

Dendrites

Nucleus

Cell Body

Schwann
Cells

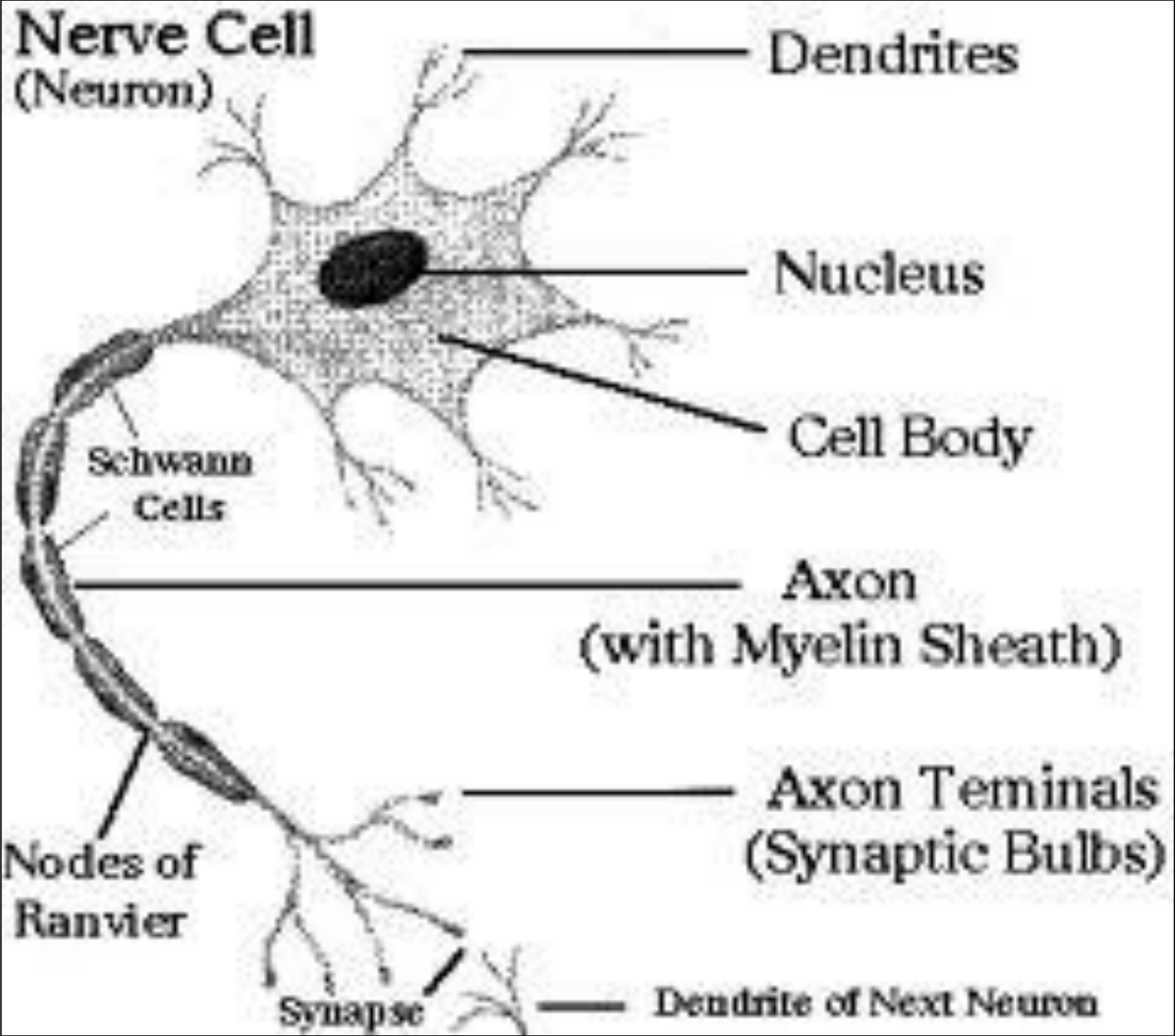
Axon
(with Myelin Sheath)

Axon Terminals
(Synaptic Bulbs)

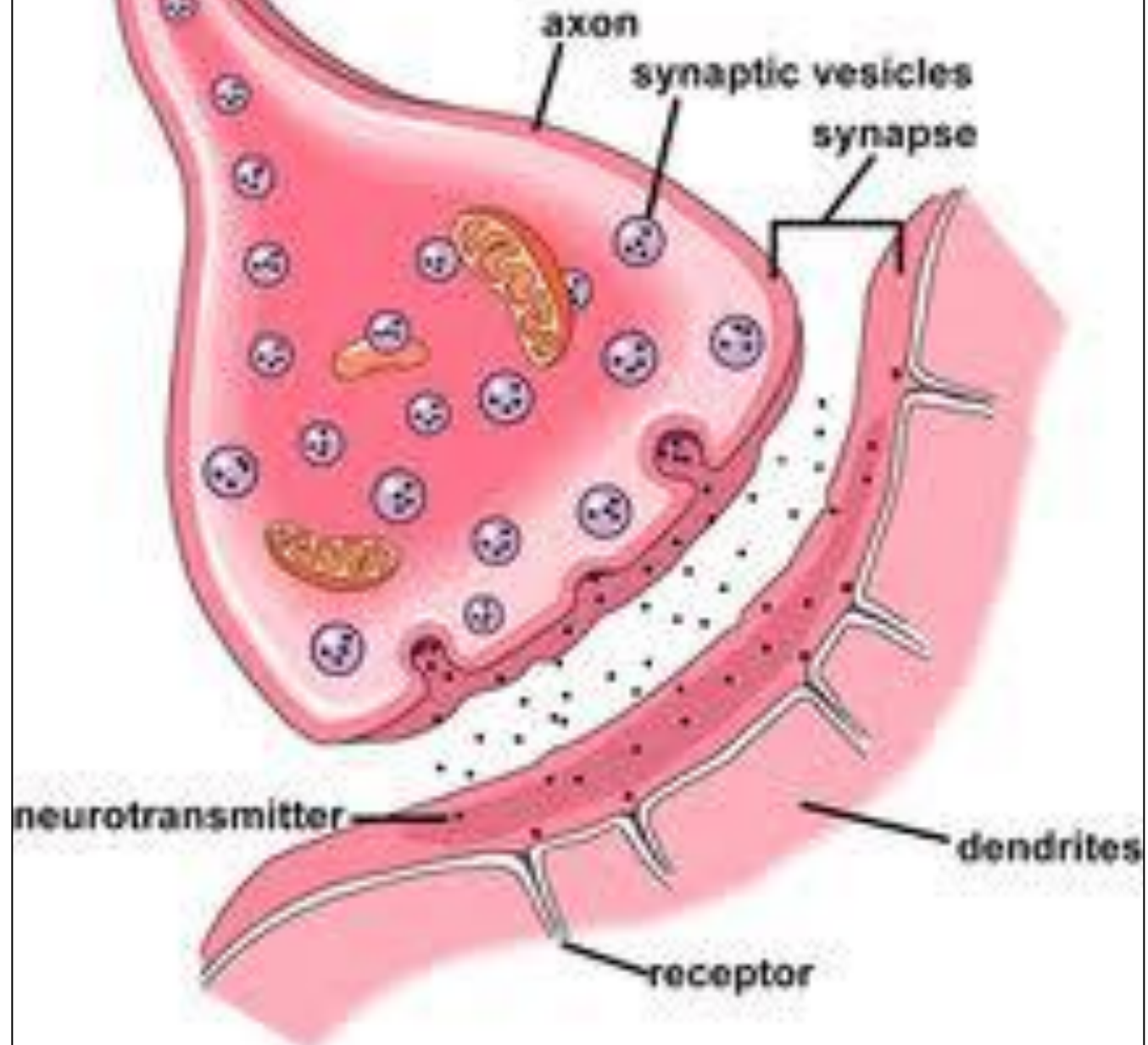
Nodes of
Ranvier

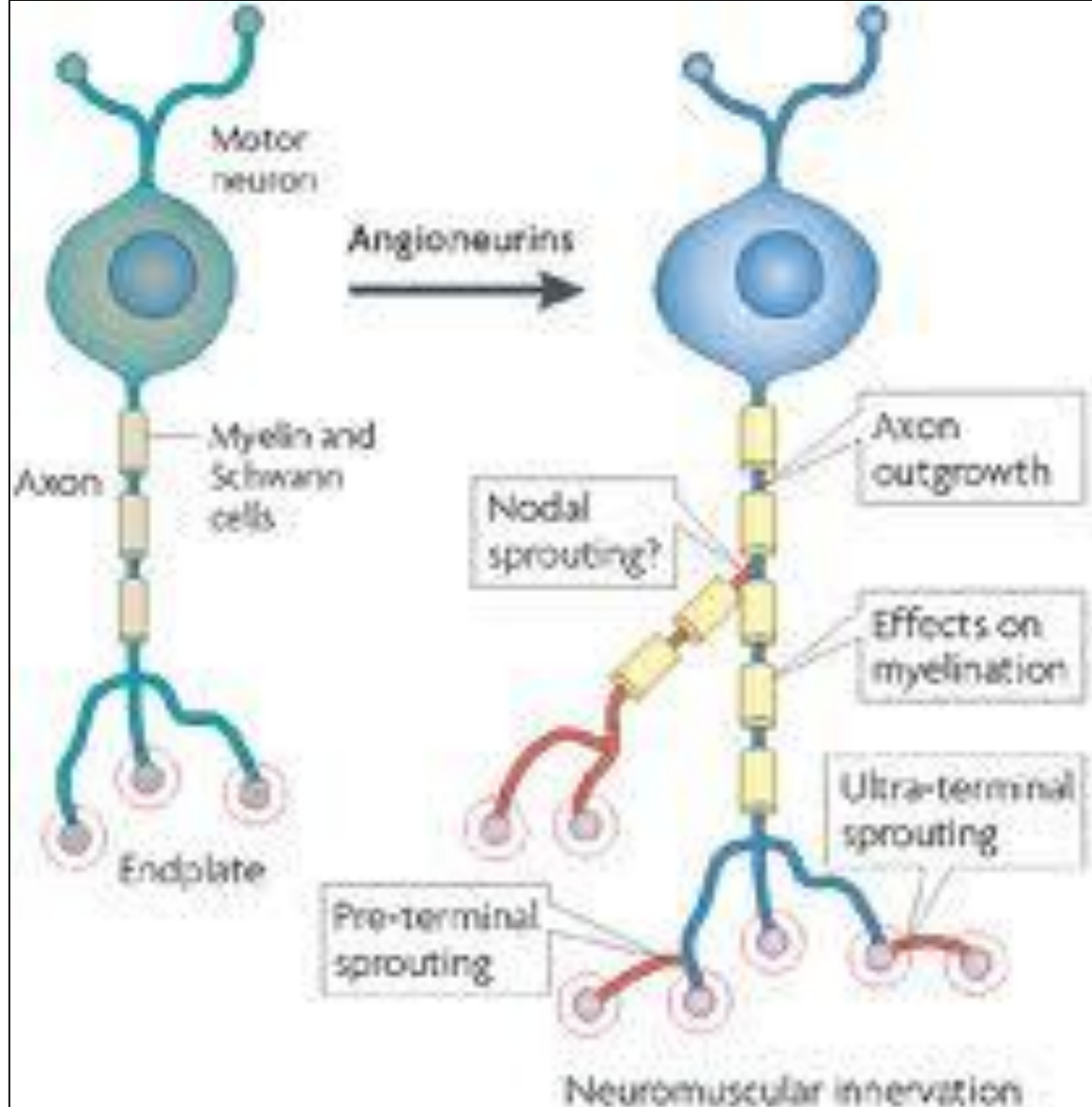
Synapse

Dendrite of Next Neuron

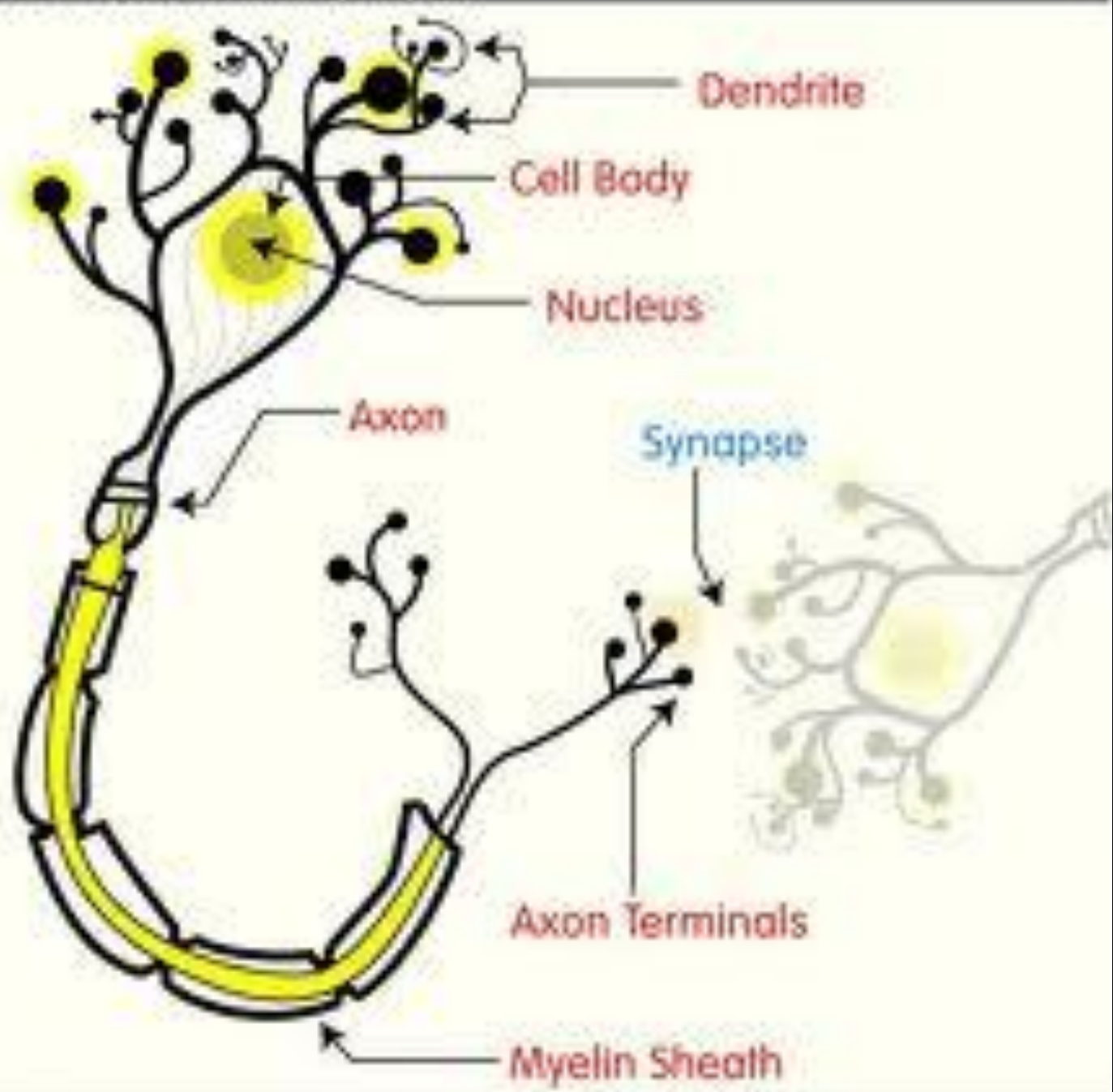


Synapse

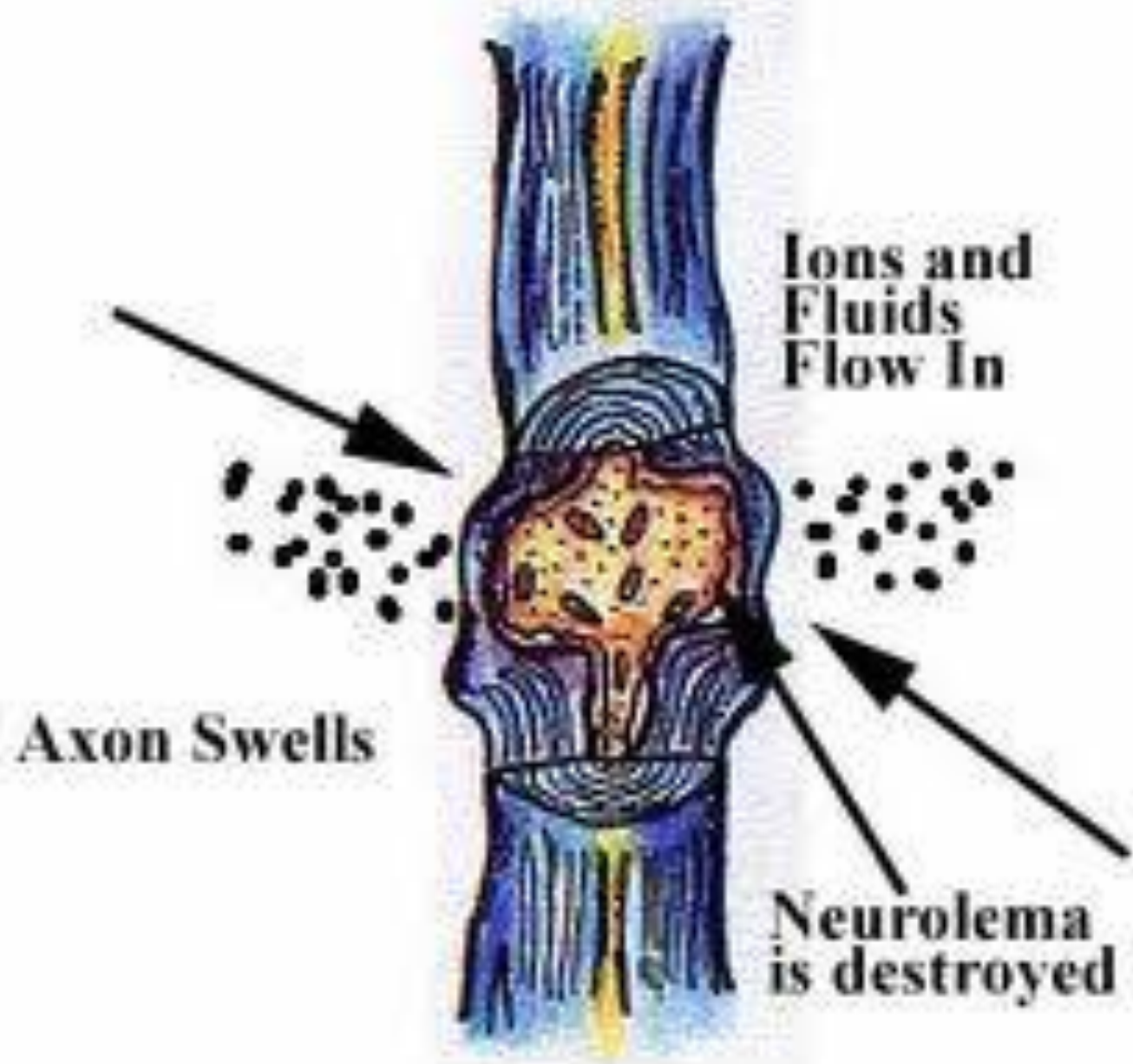




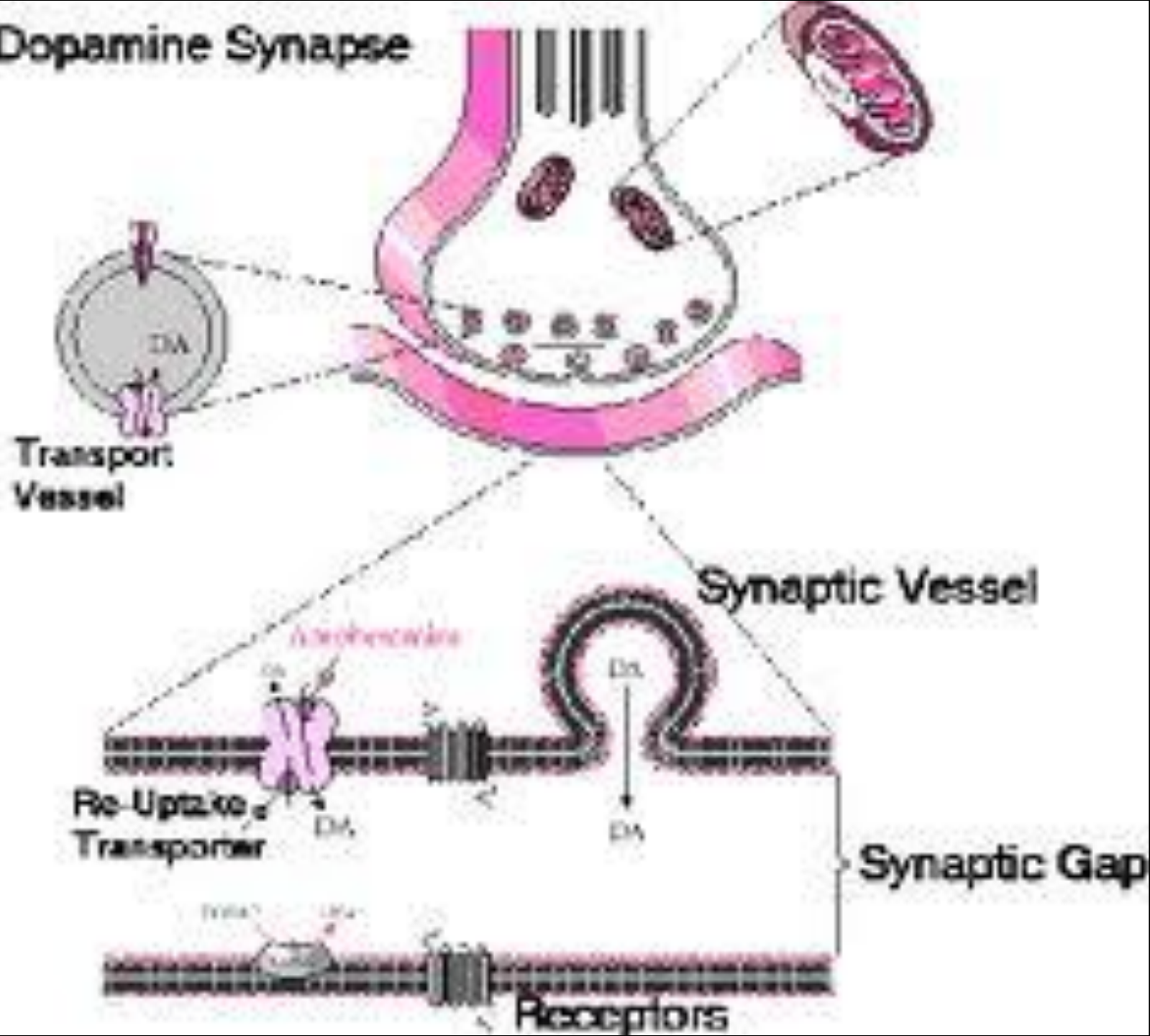
THE NEURON and synapse

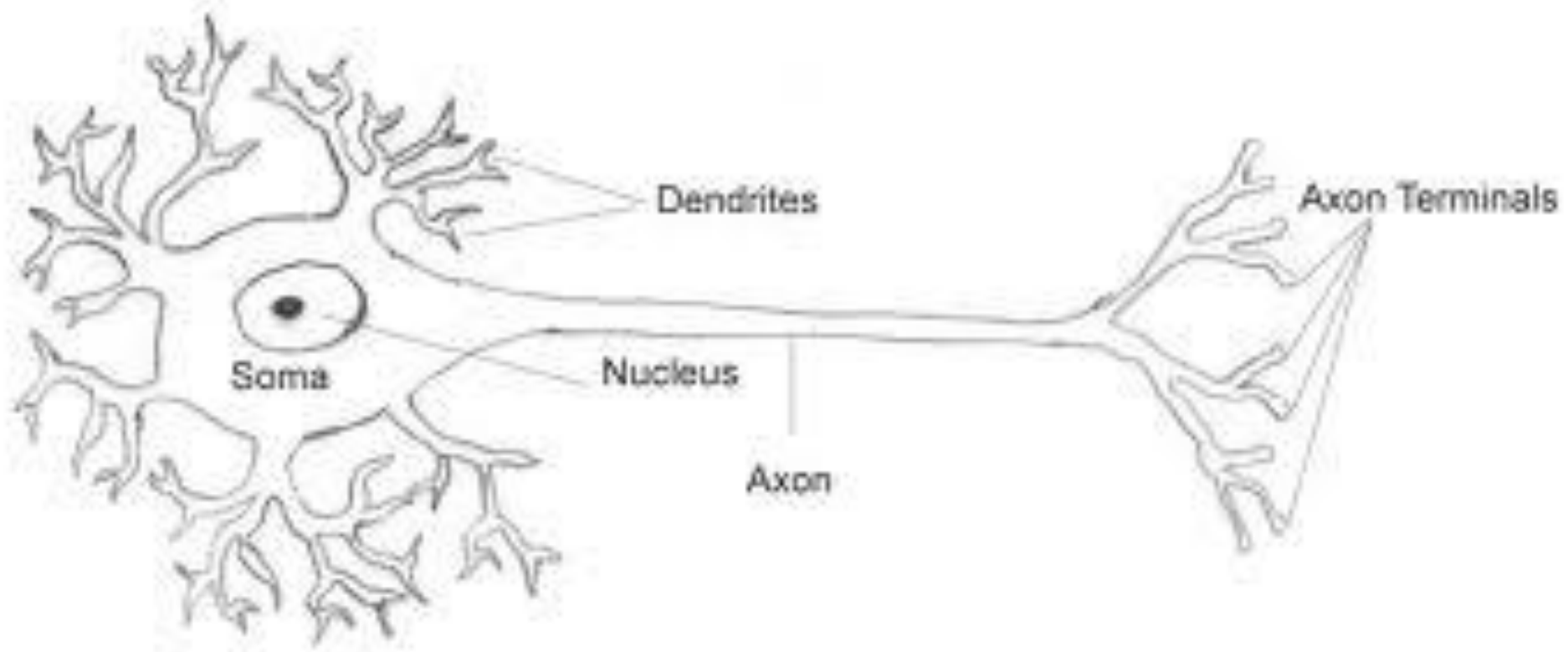


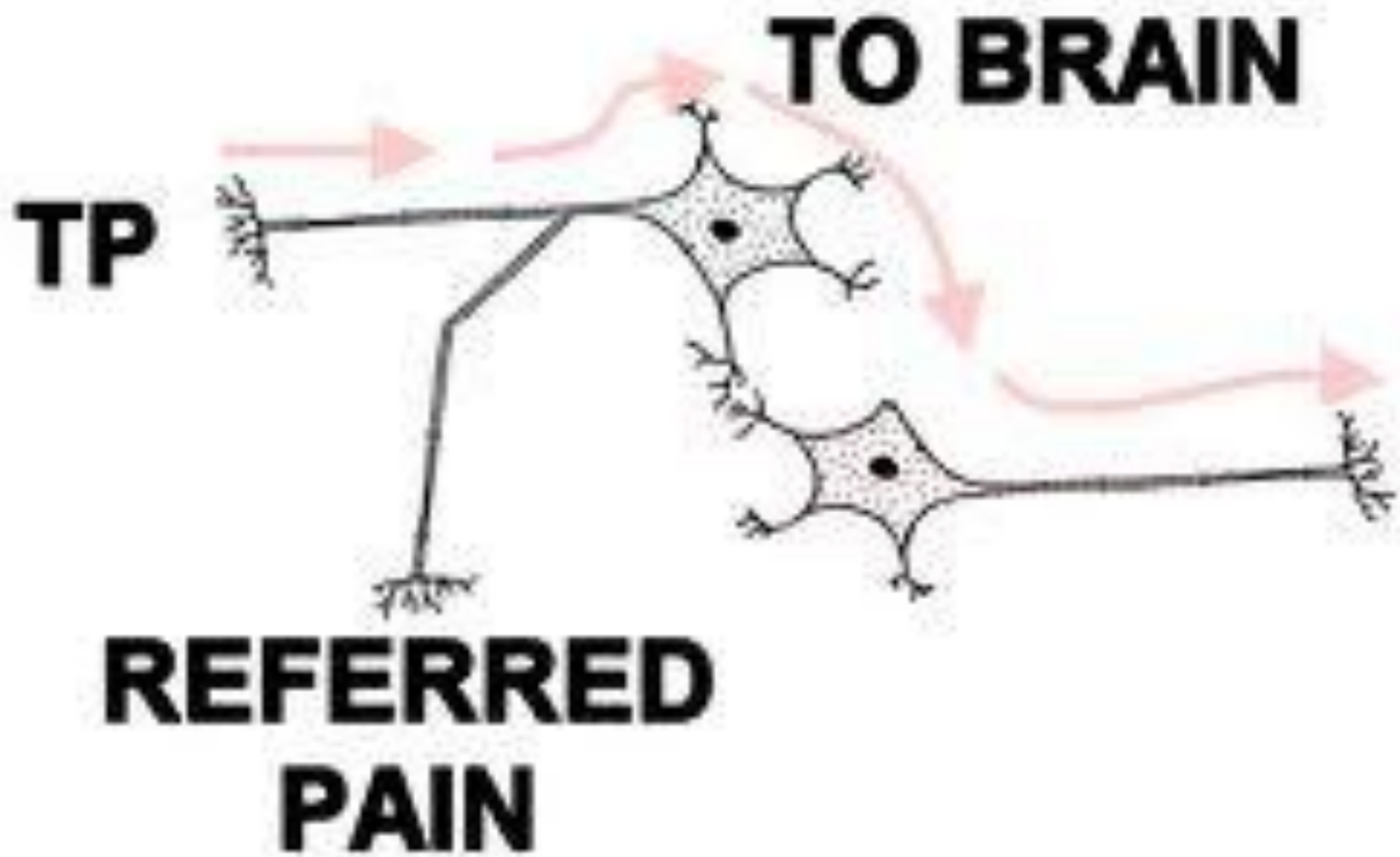
Reaction of Axon to Damage

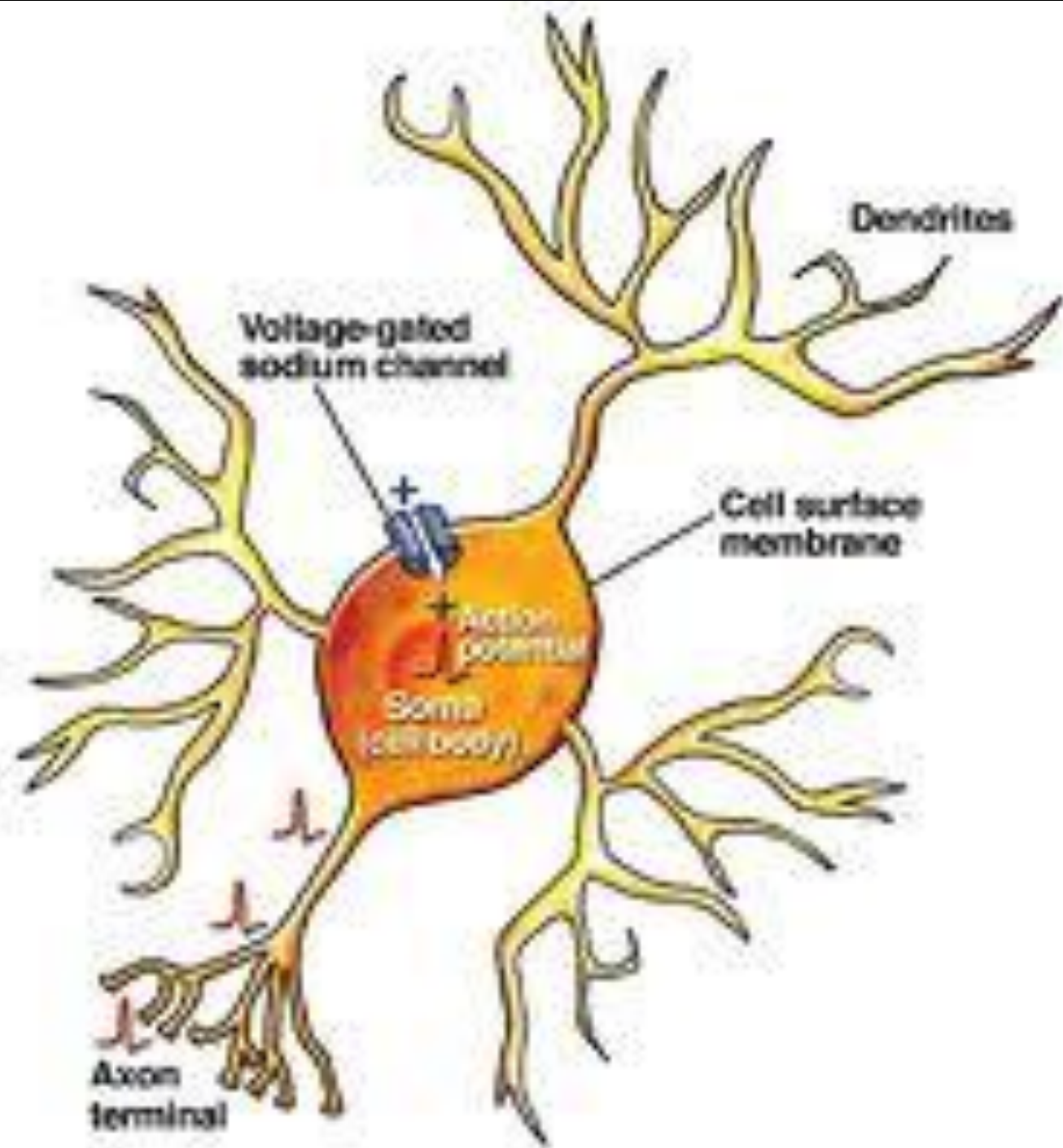


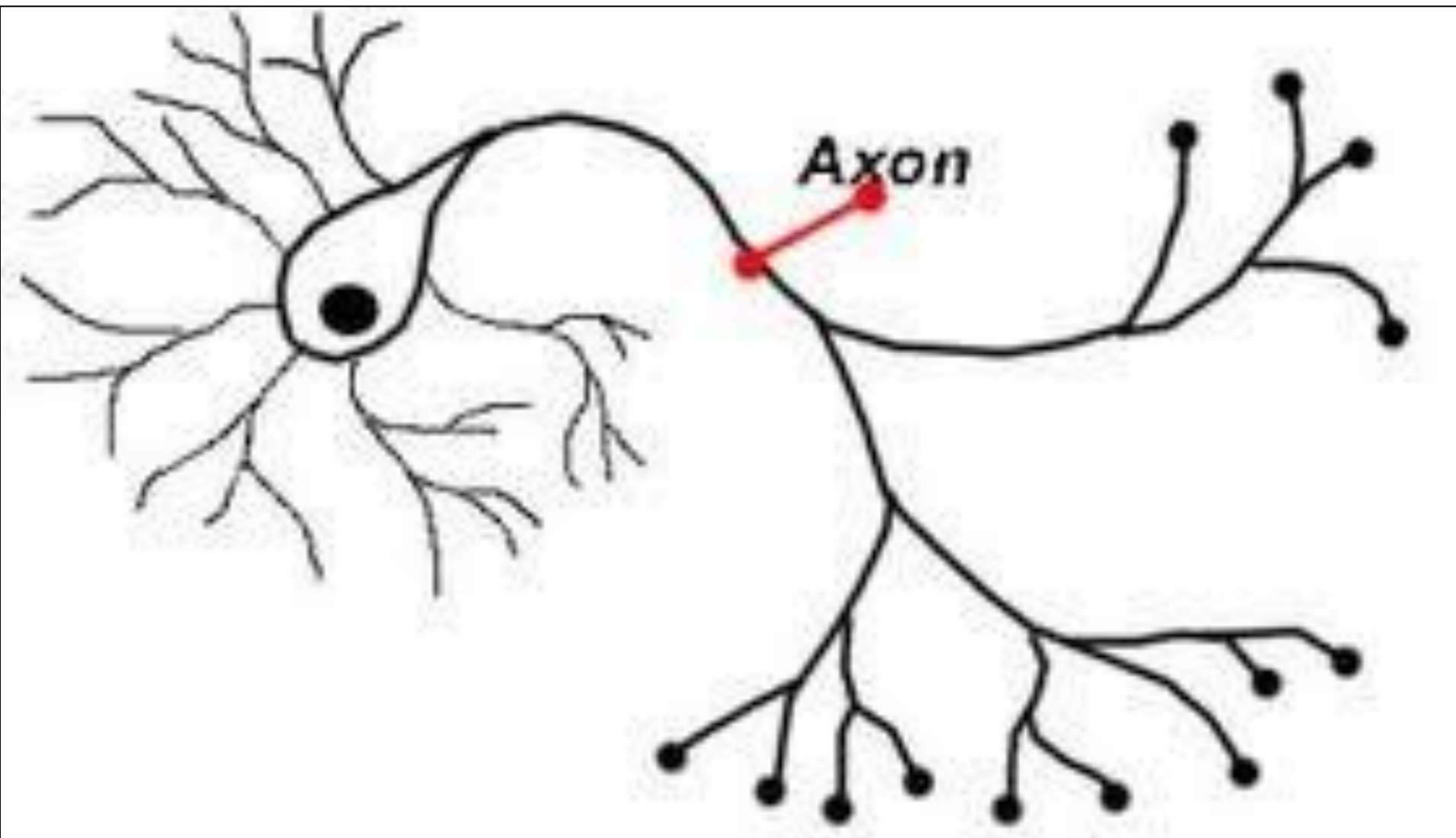
Dopamine Synapse

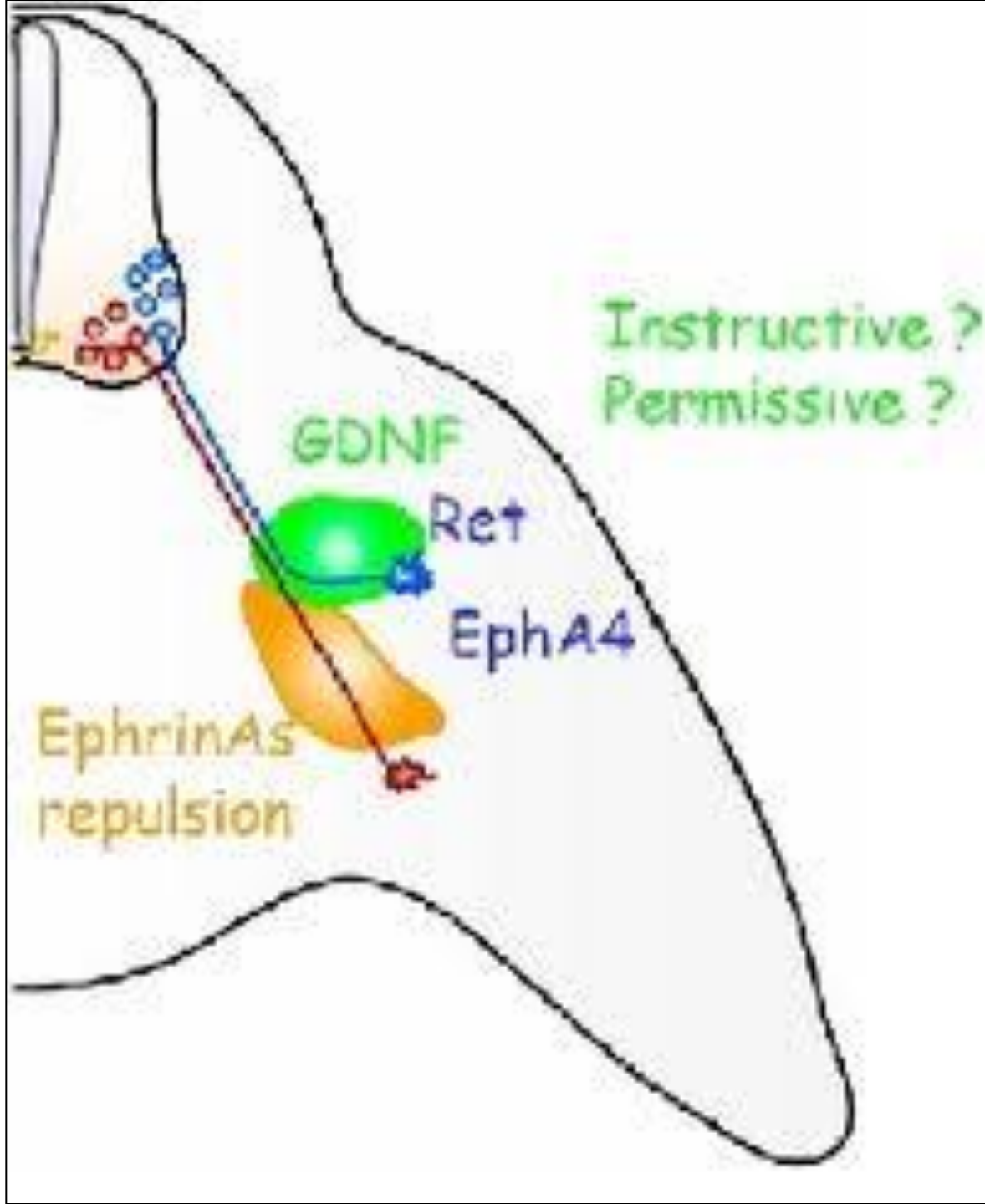




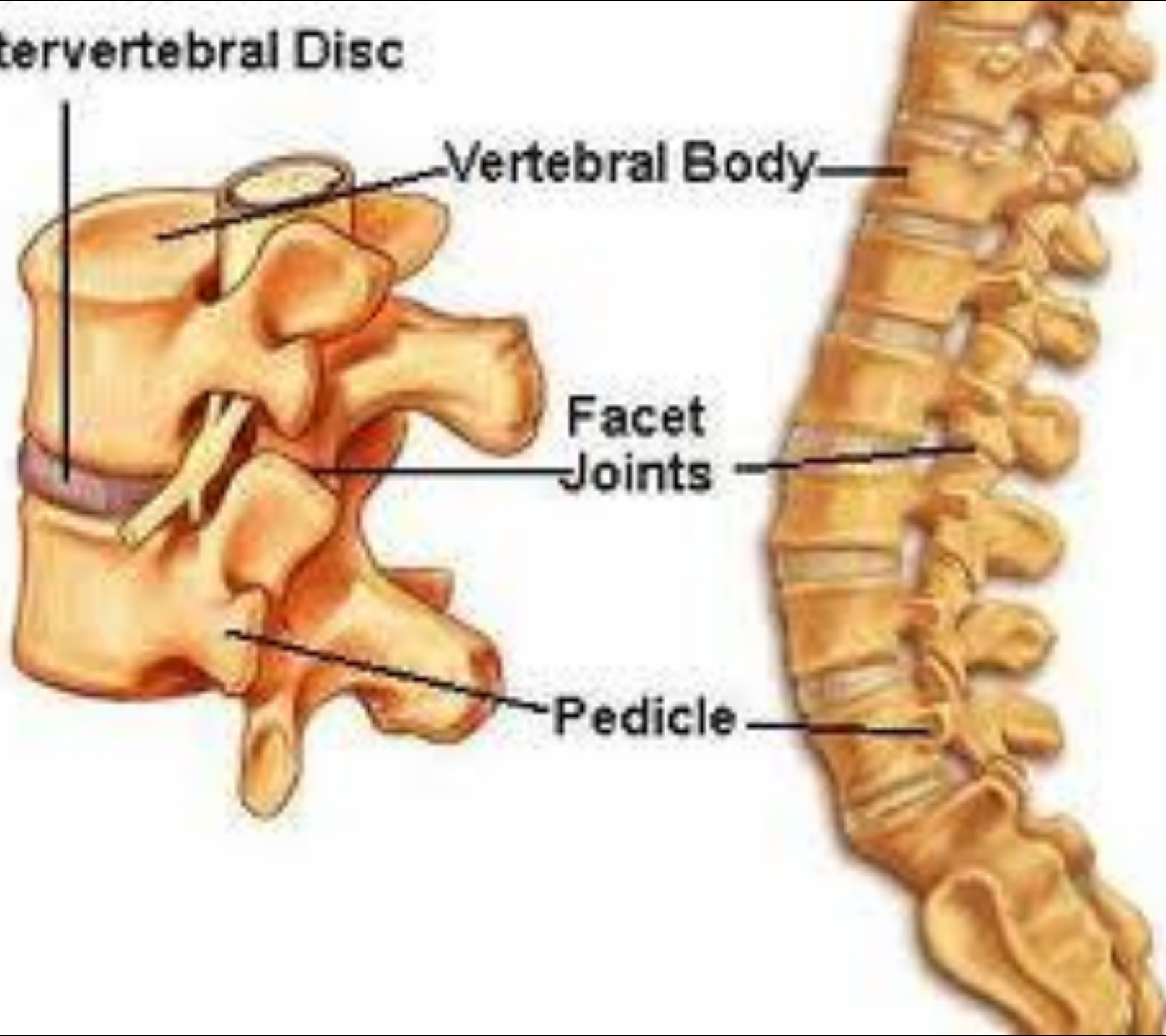


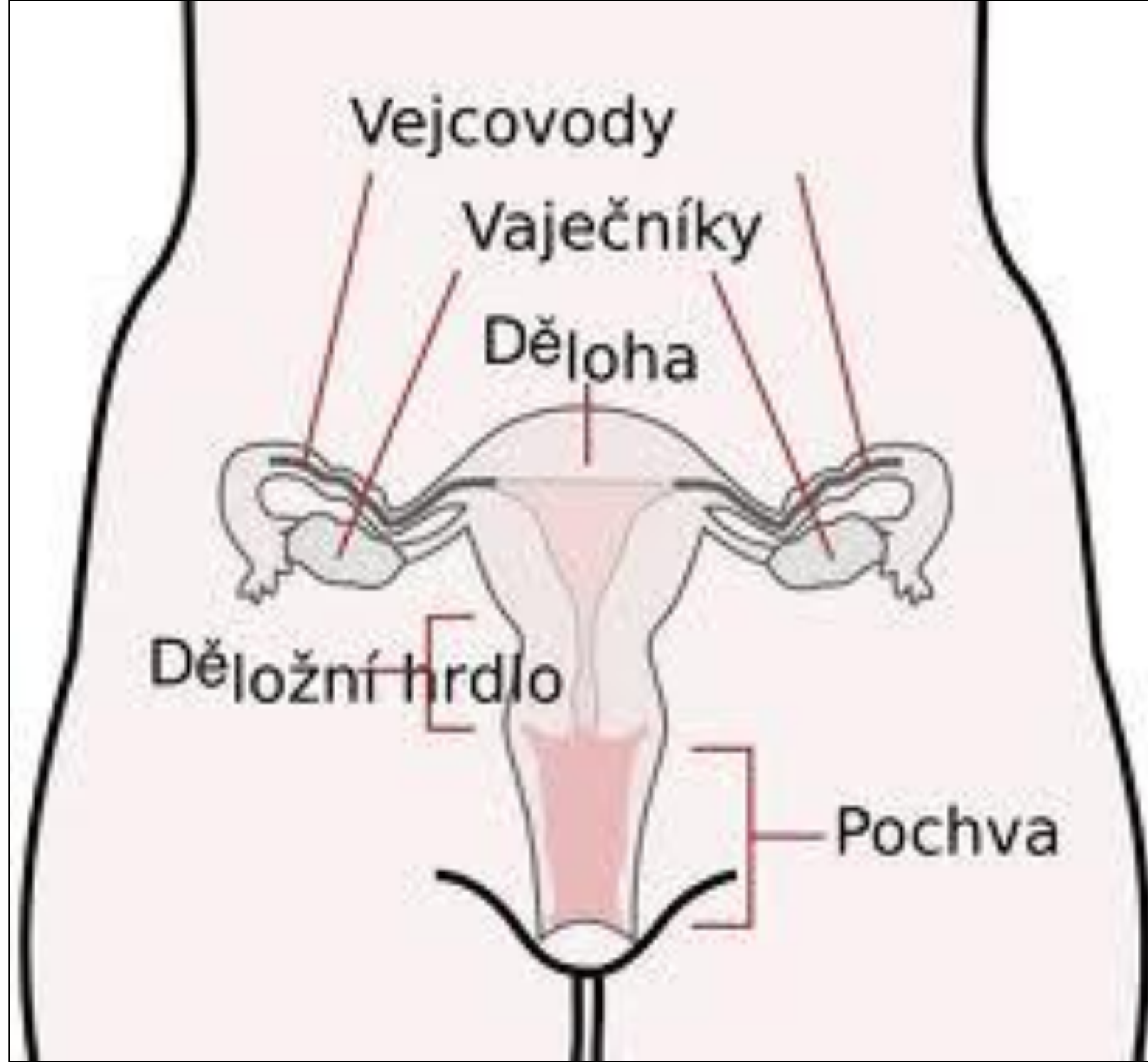




Intervertebral Disc





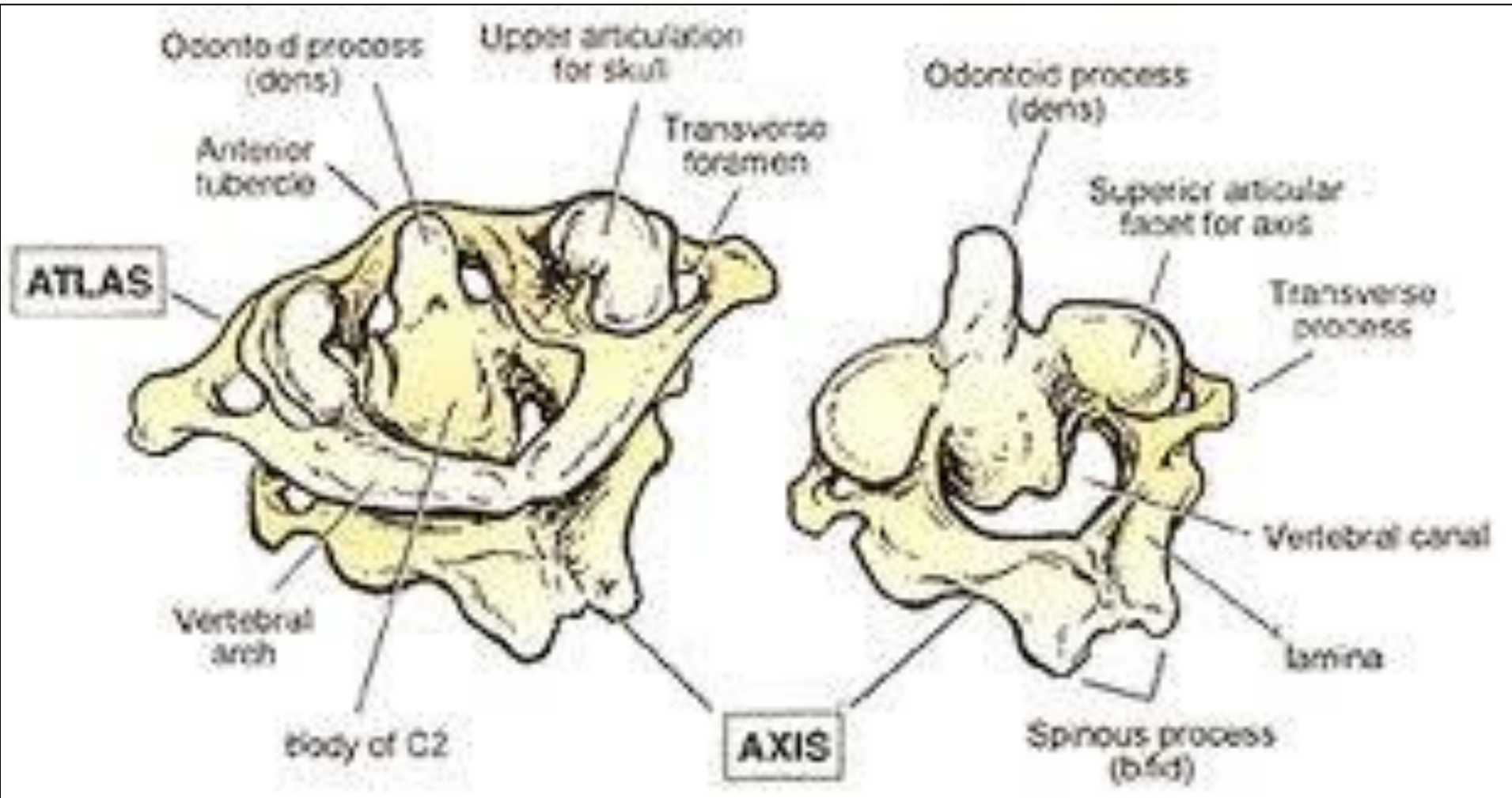
Vejcovody

Vaječníky

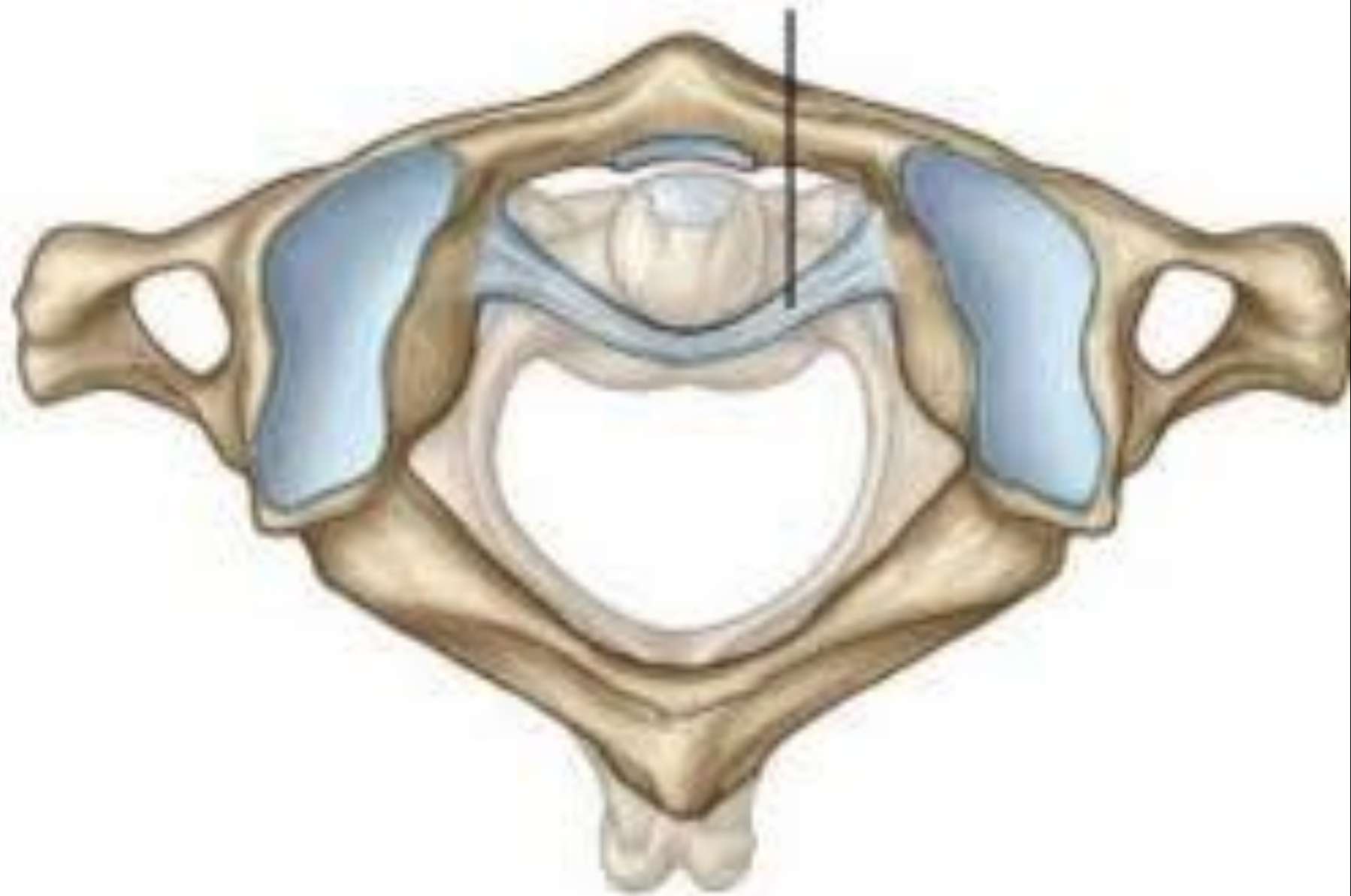
Děloha

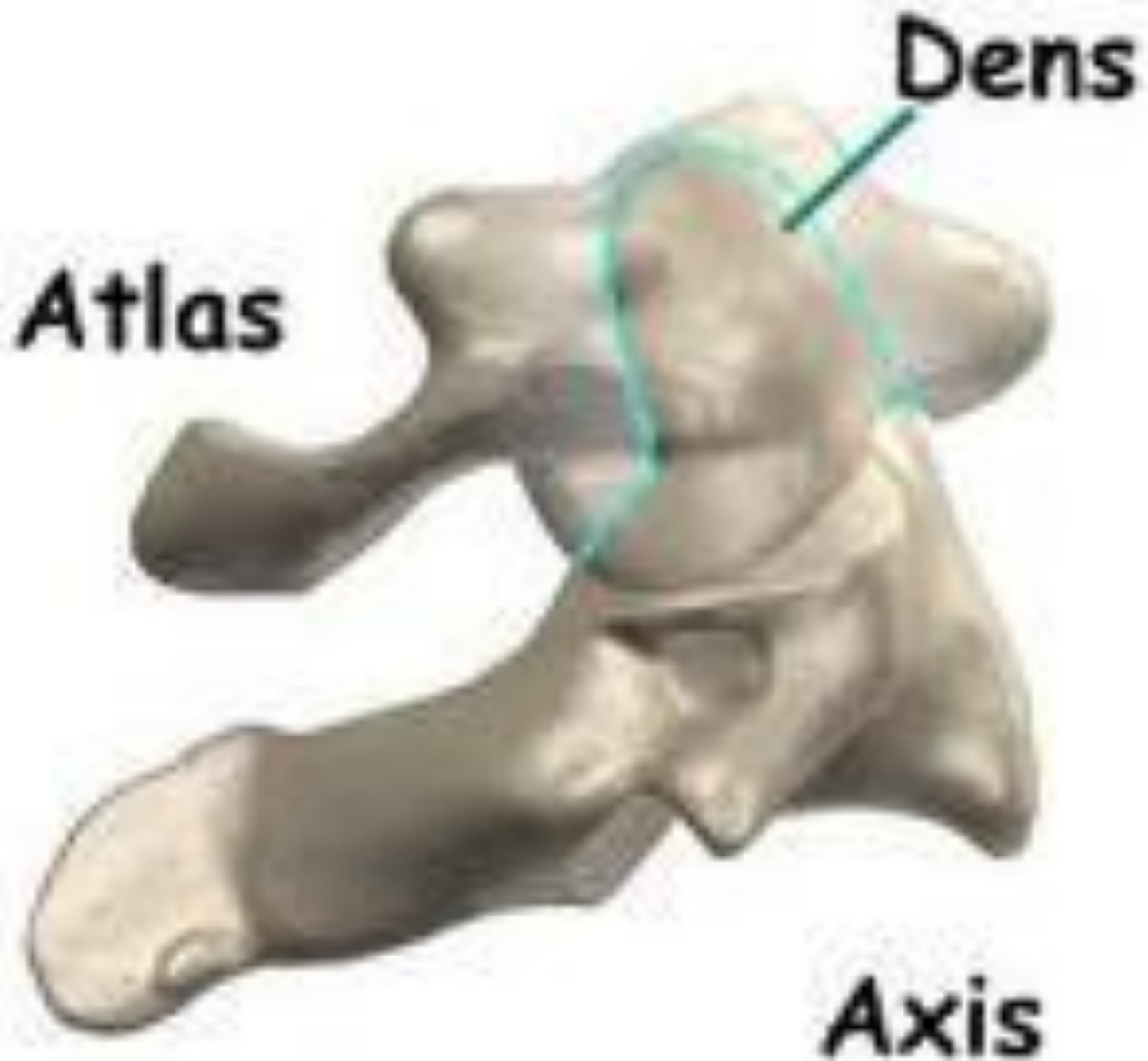Děložní hrdlo

Pochva

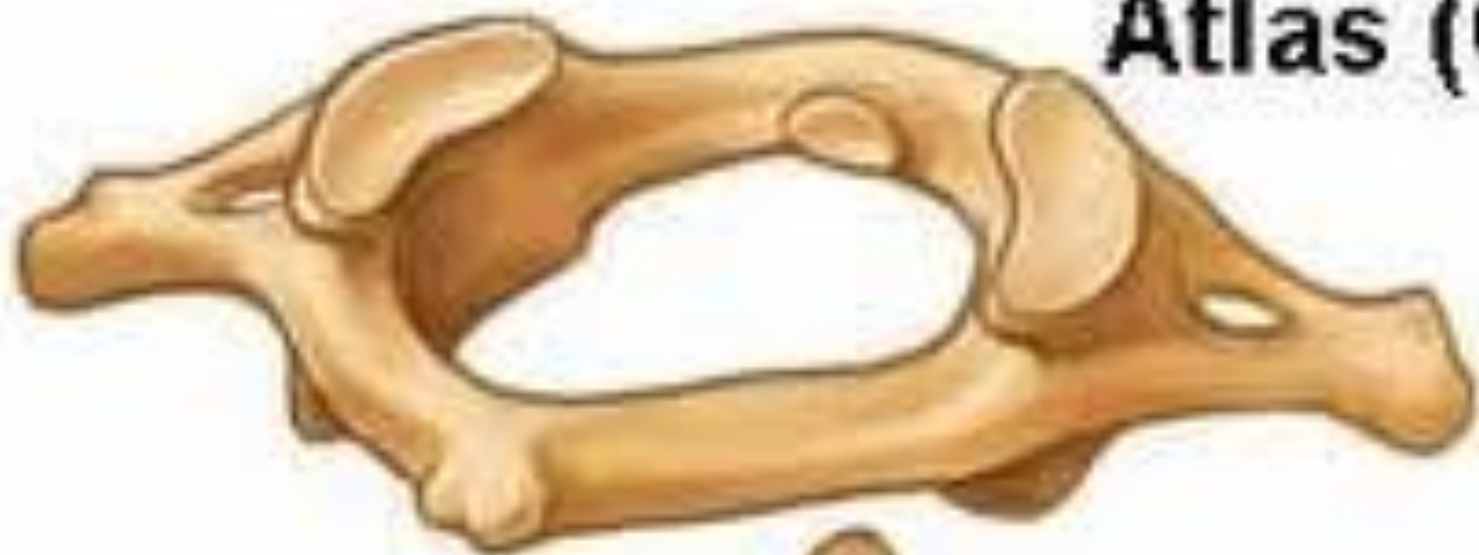

ligament of atlas






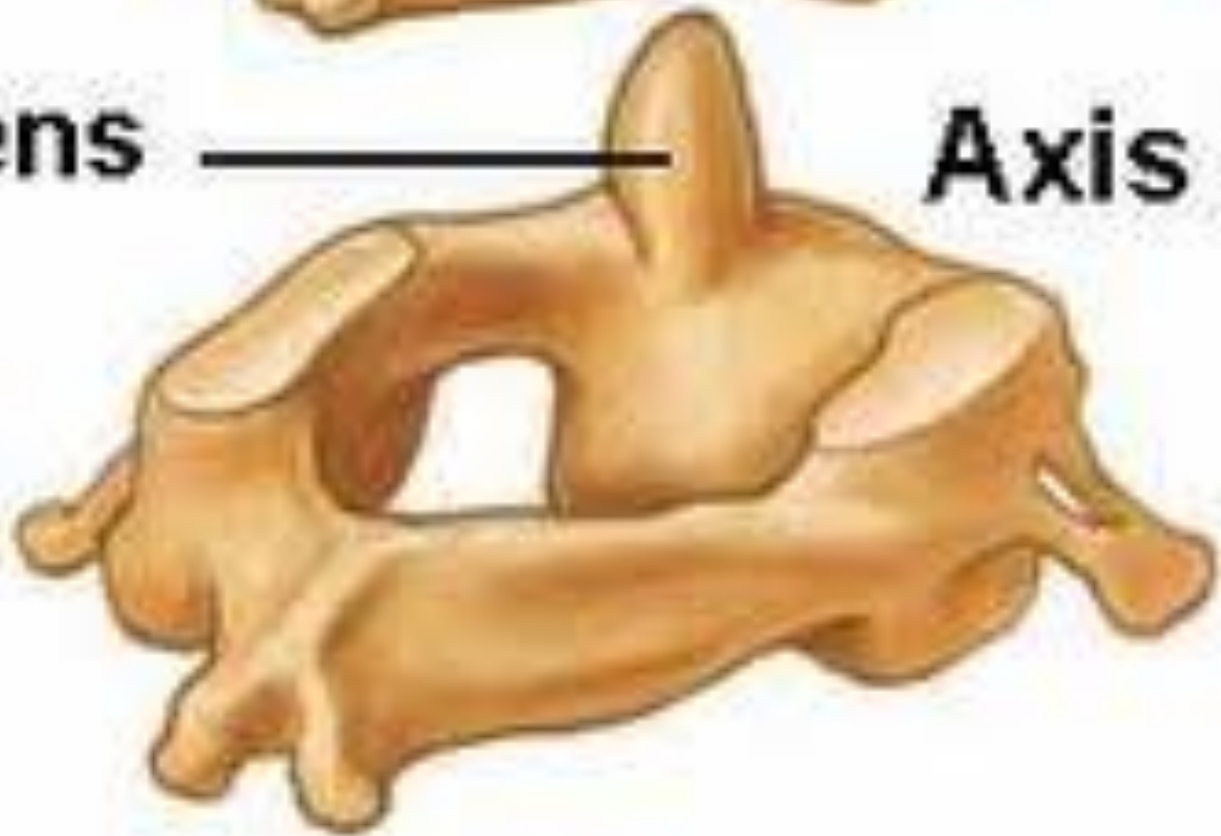
Atlas (C1)



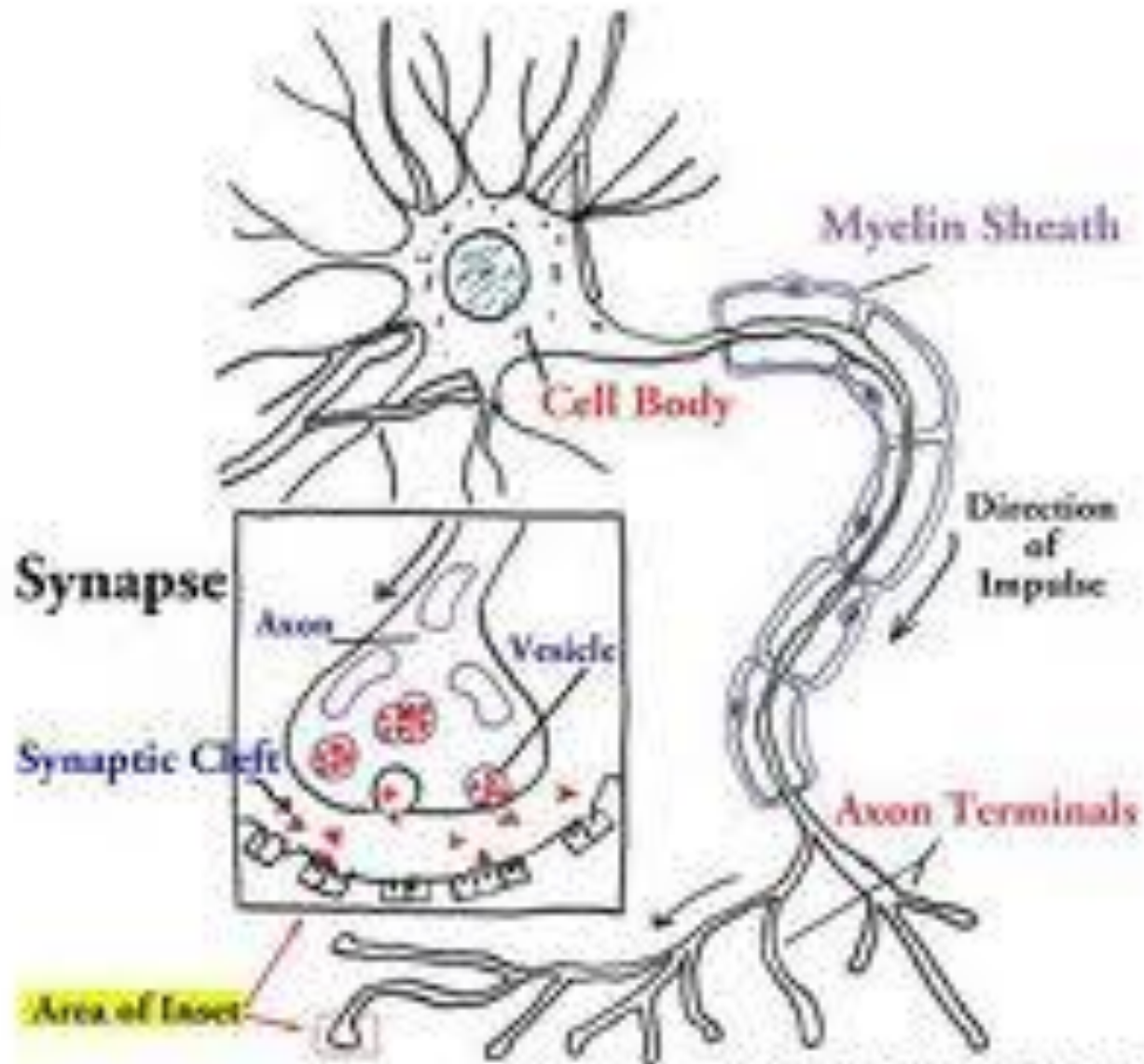
Dens



Axis (C2)

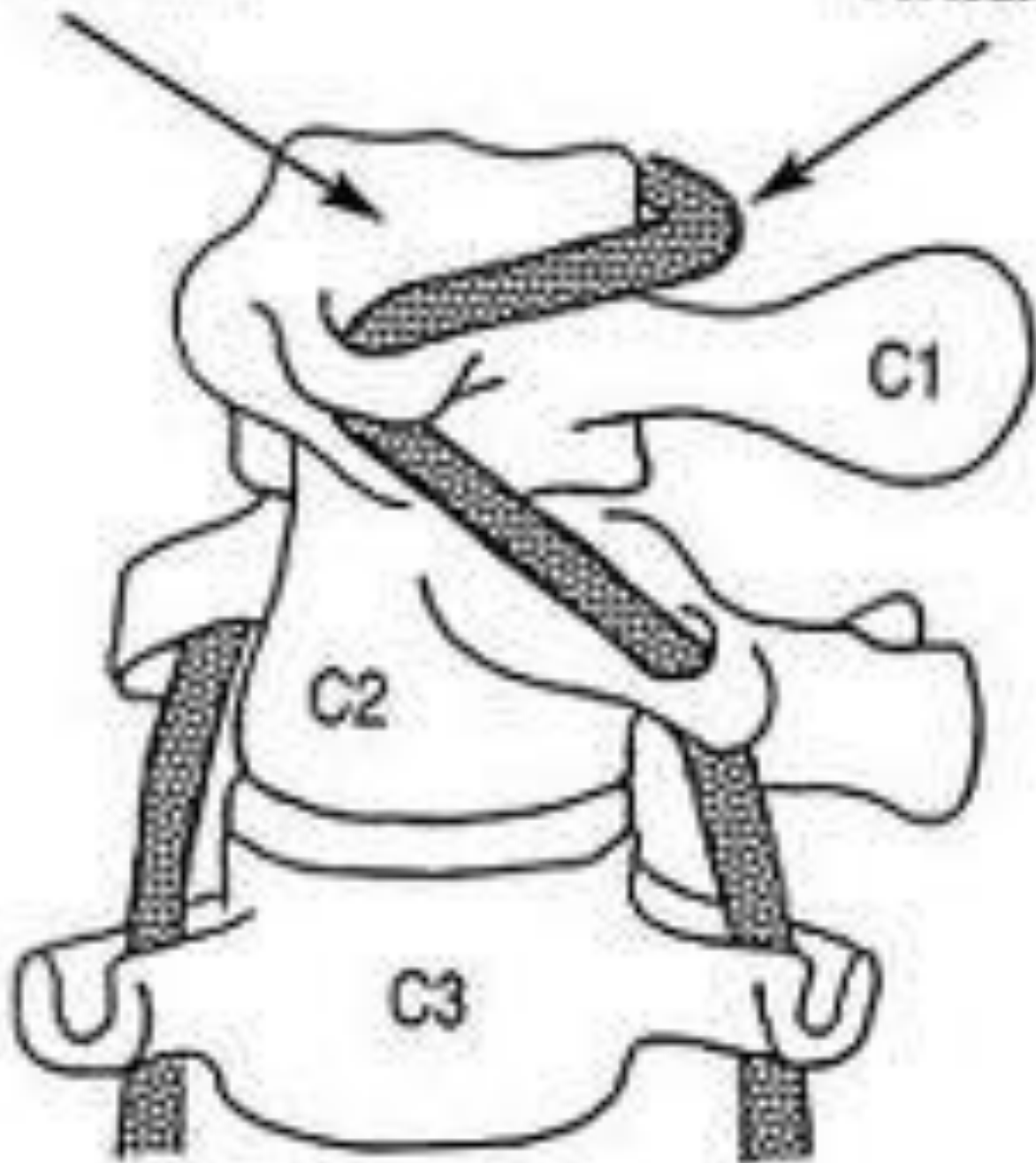


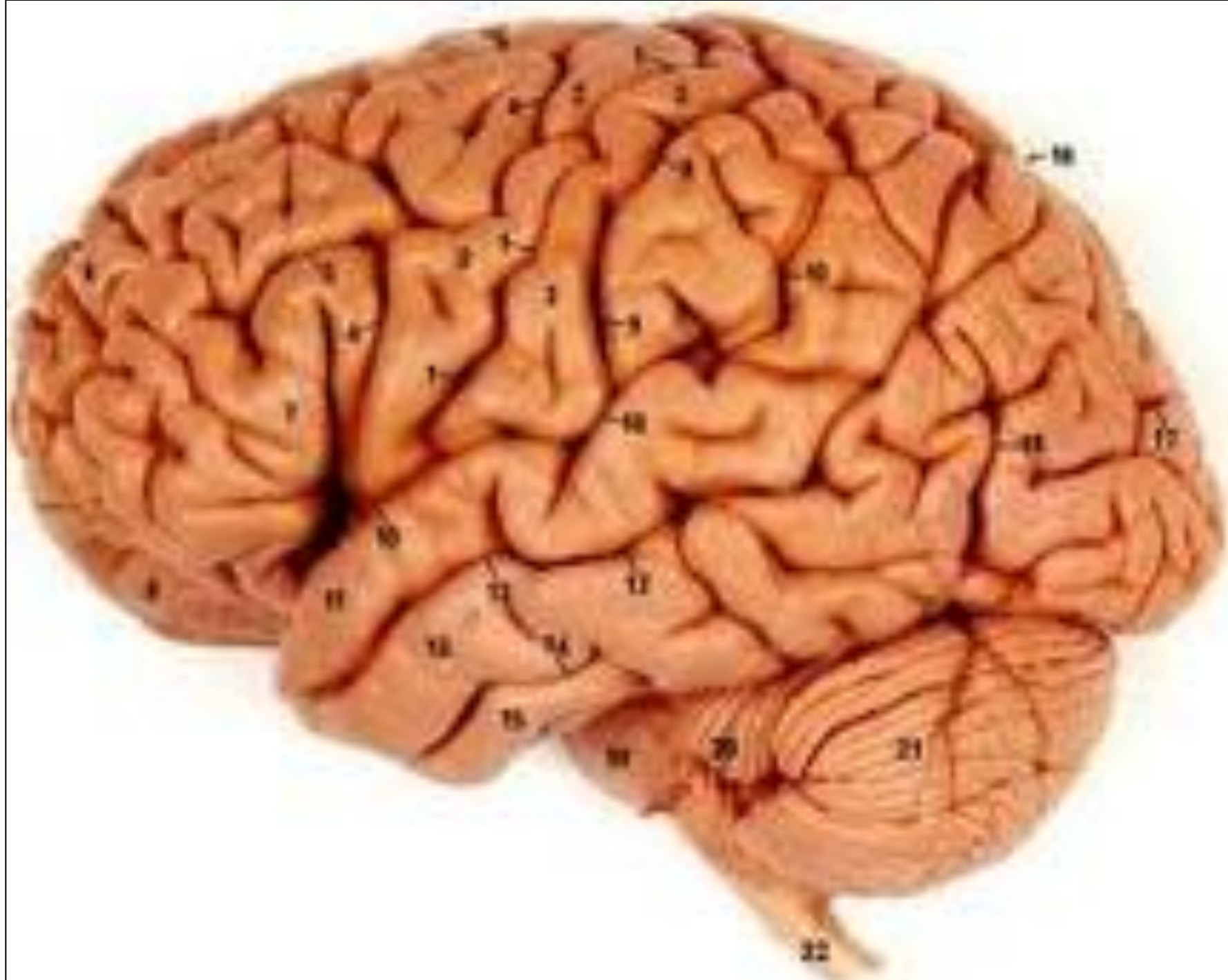
NERVE AXON

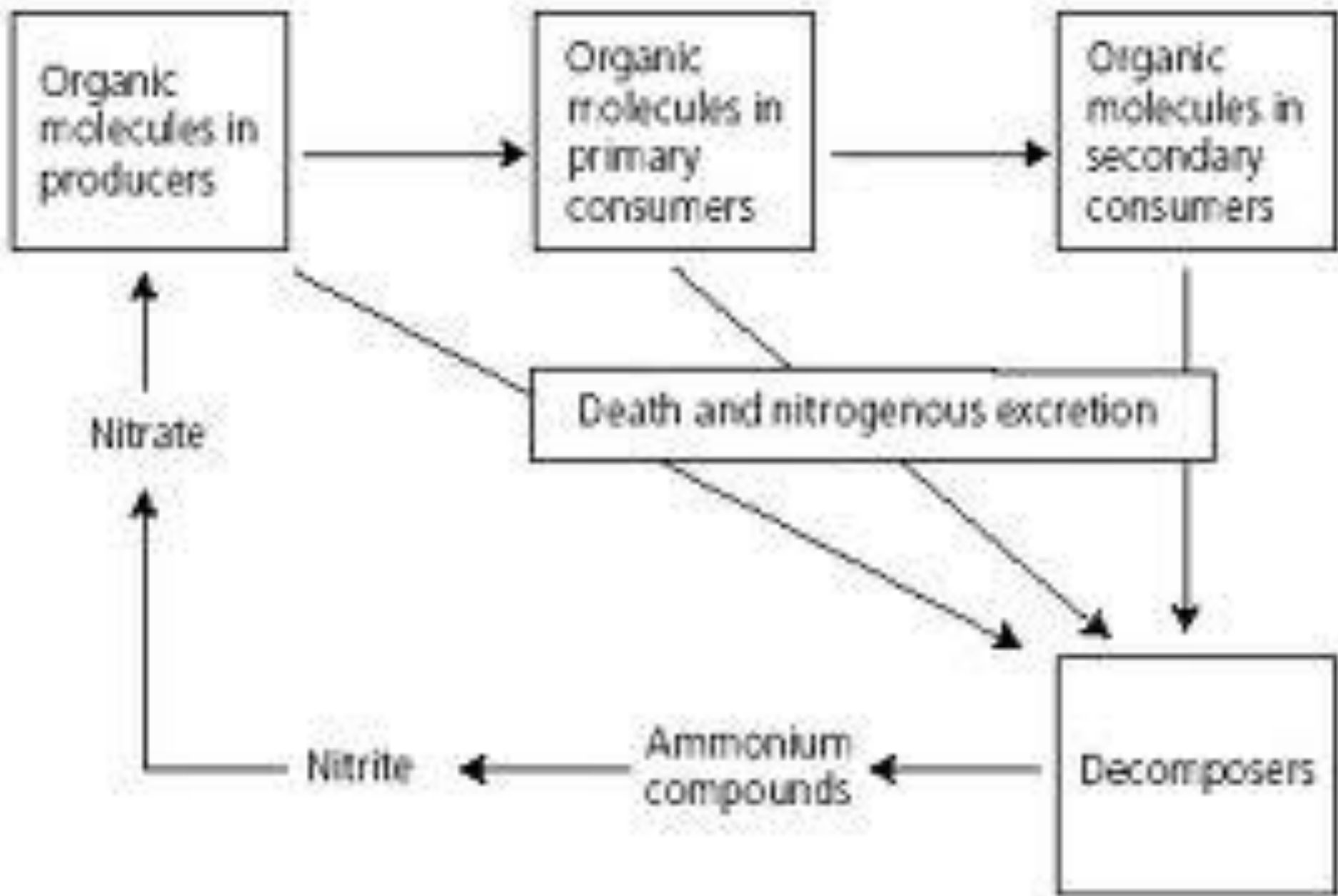


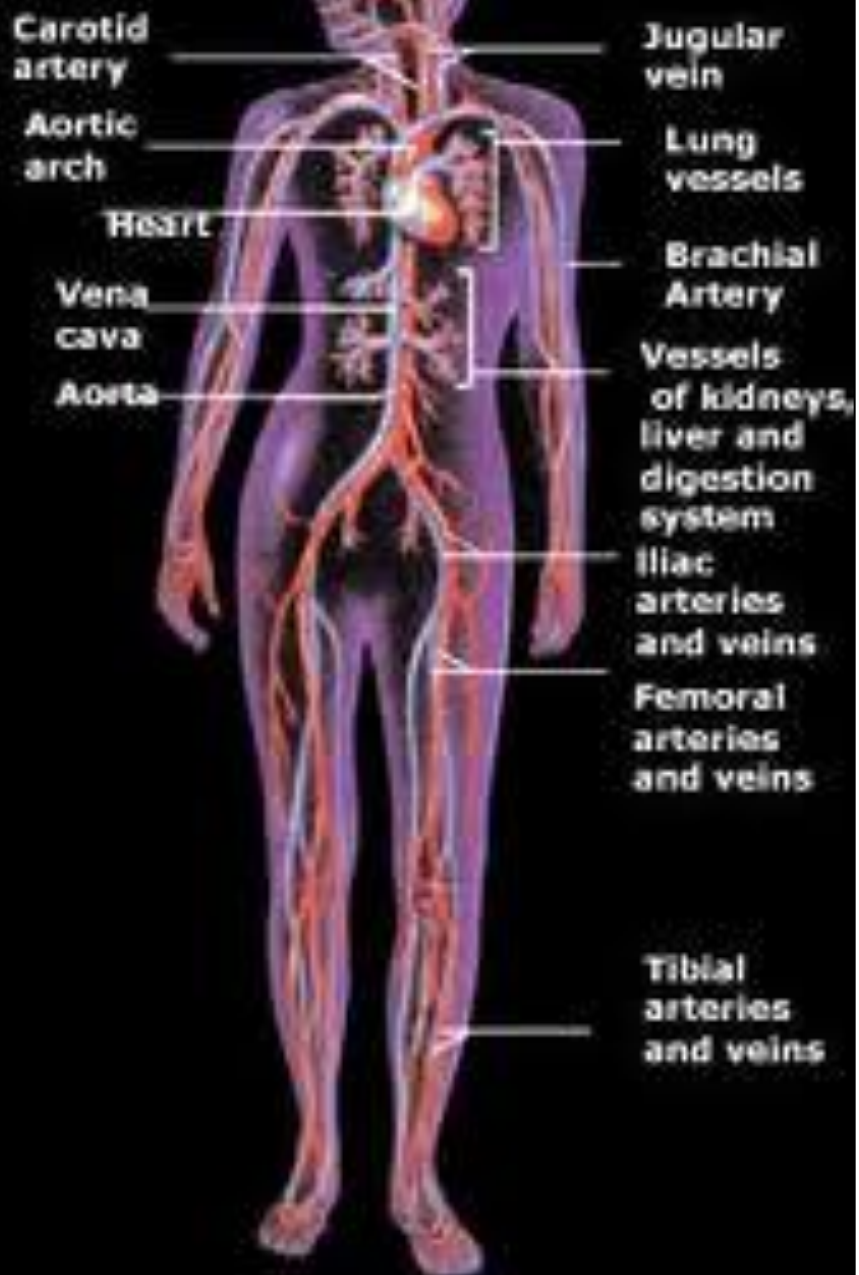
Atlas vertebra

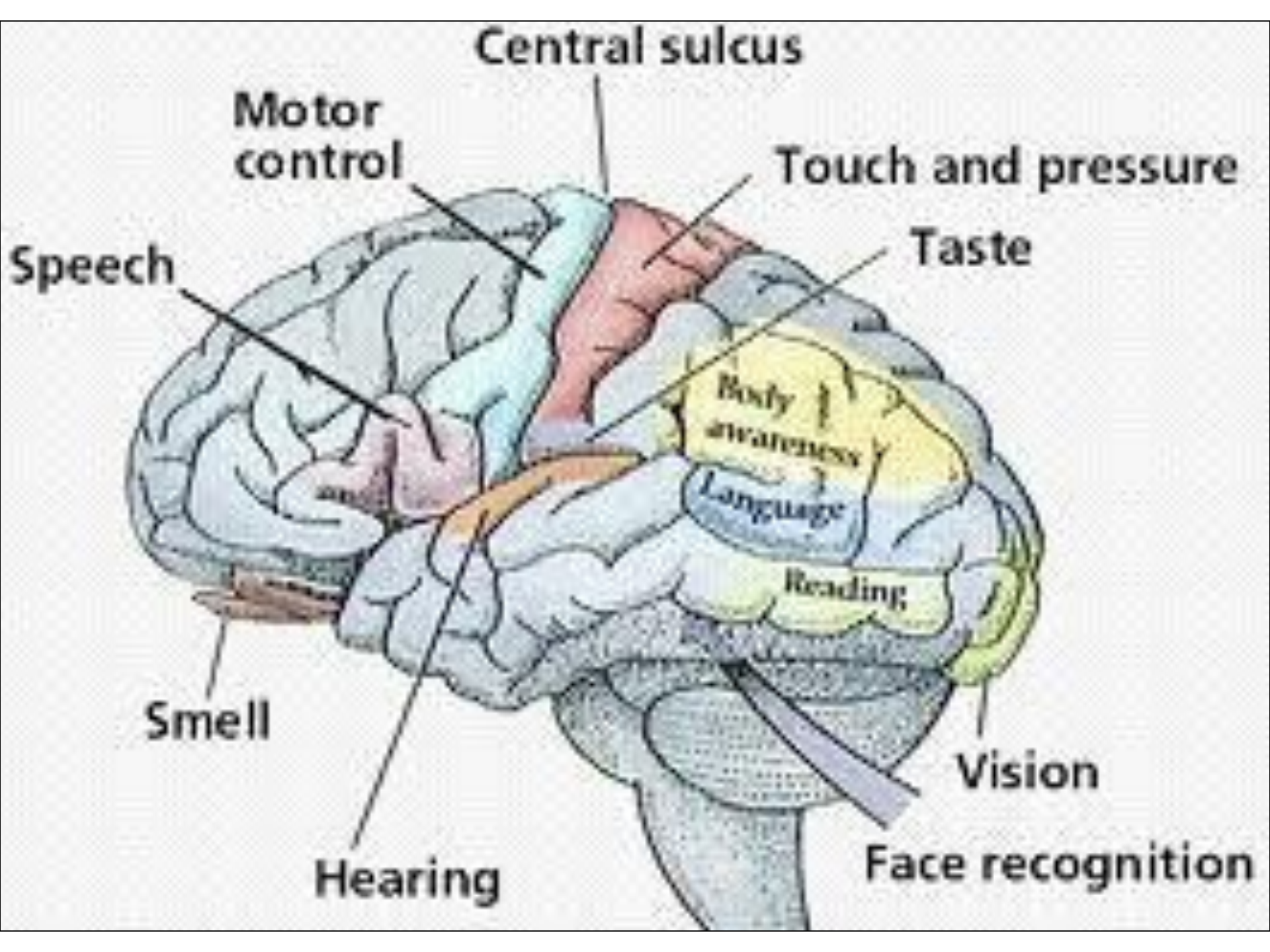
Vertebral artery

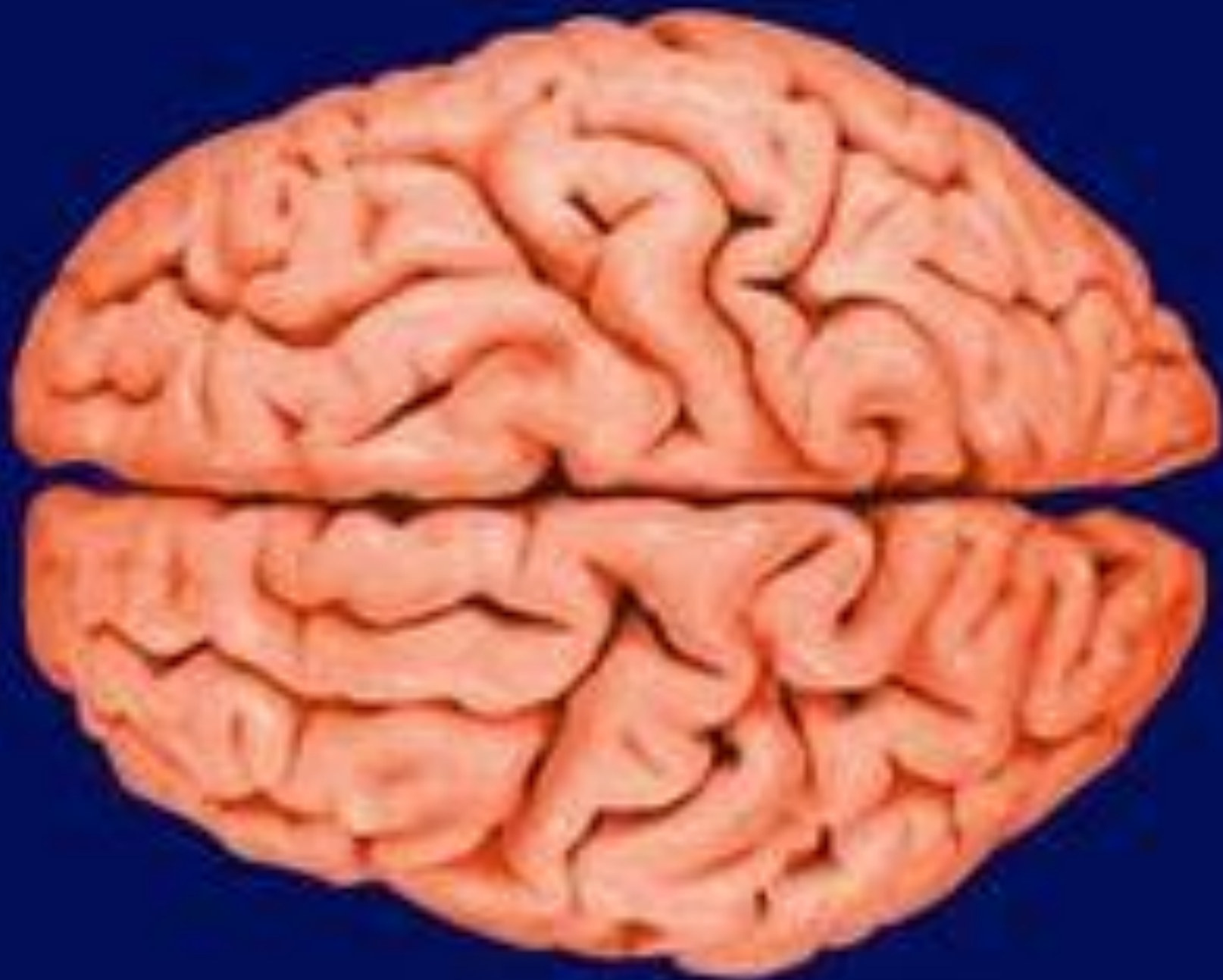

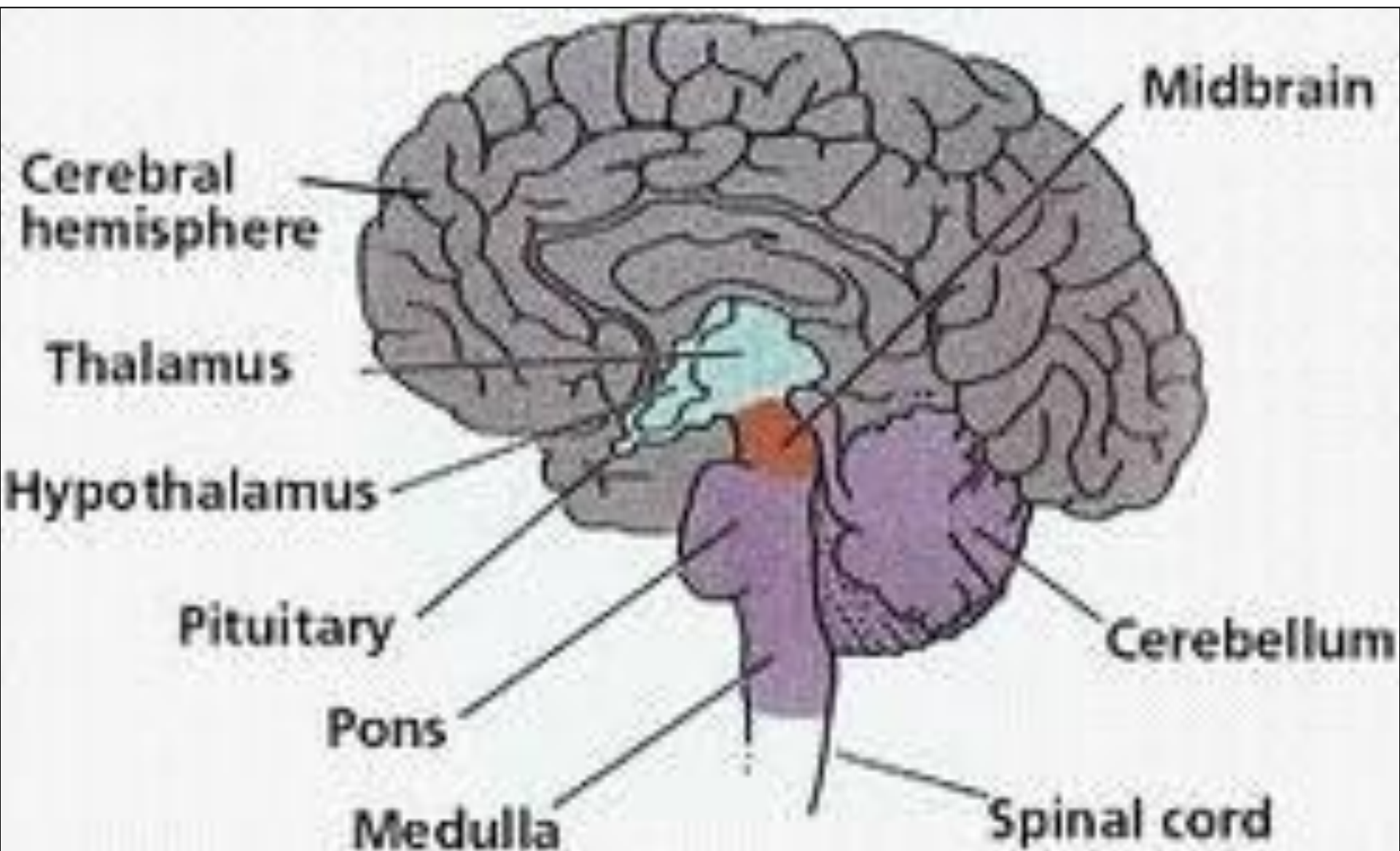




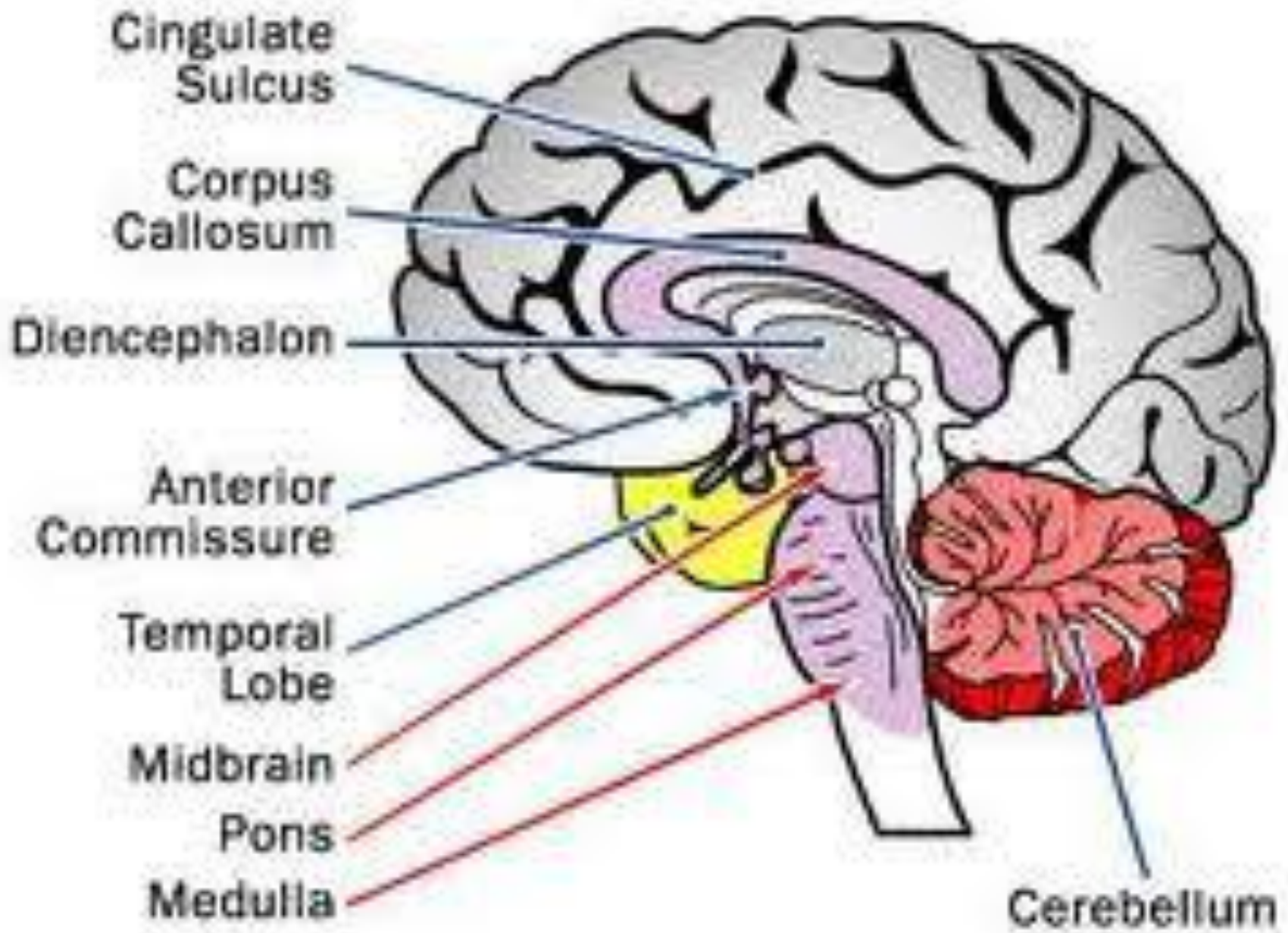



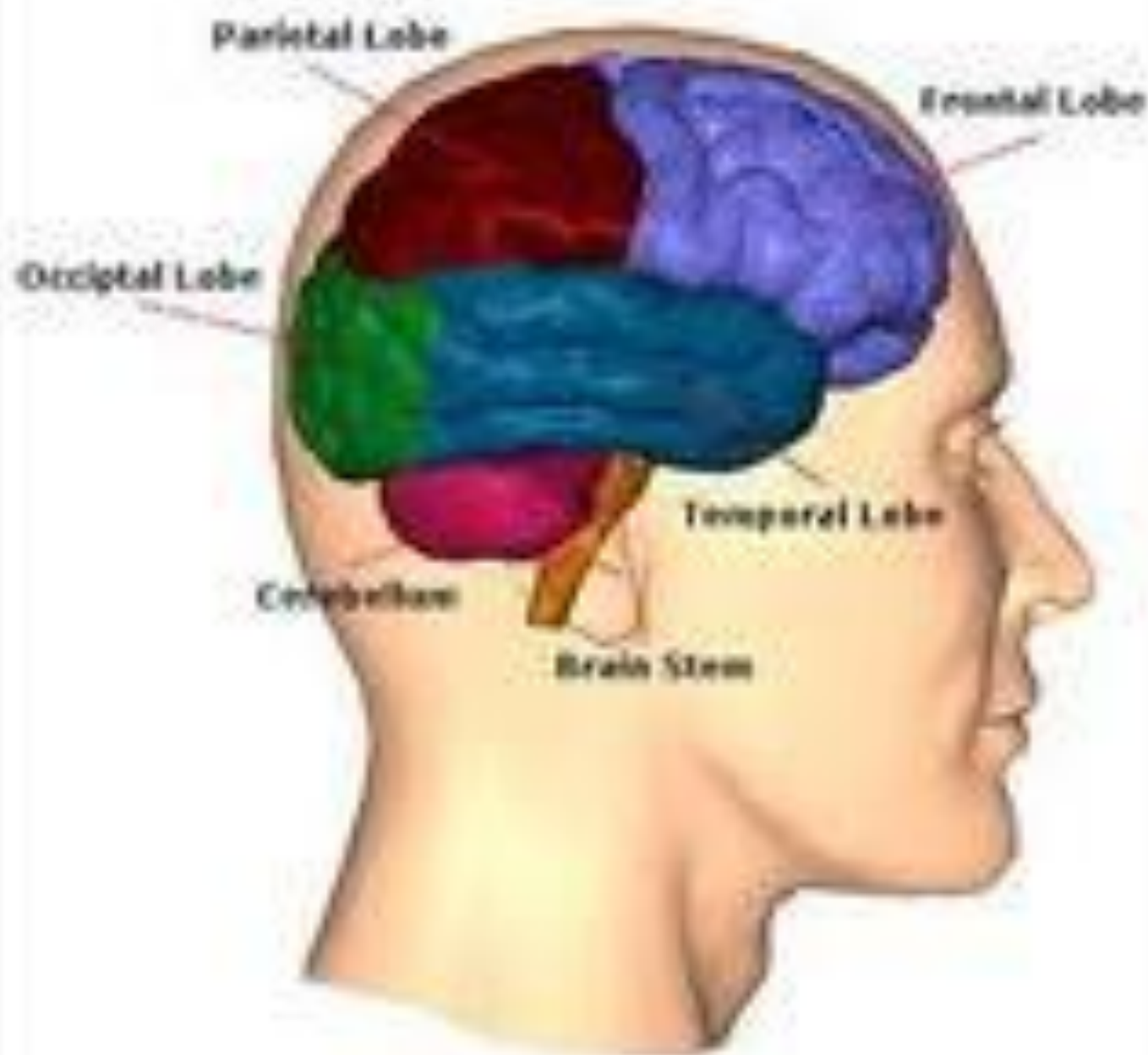


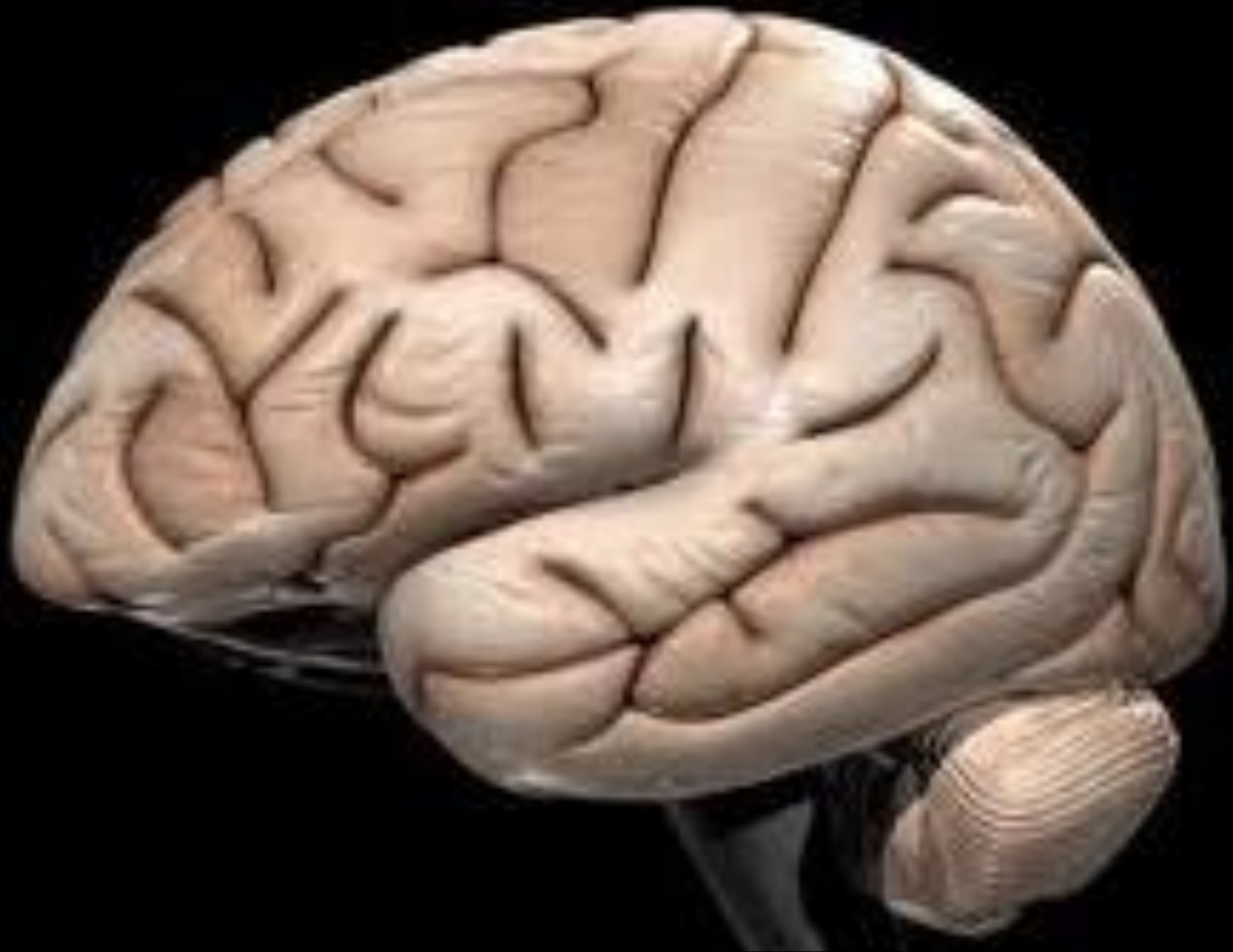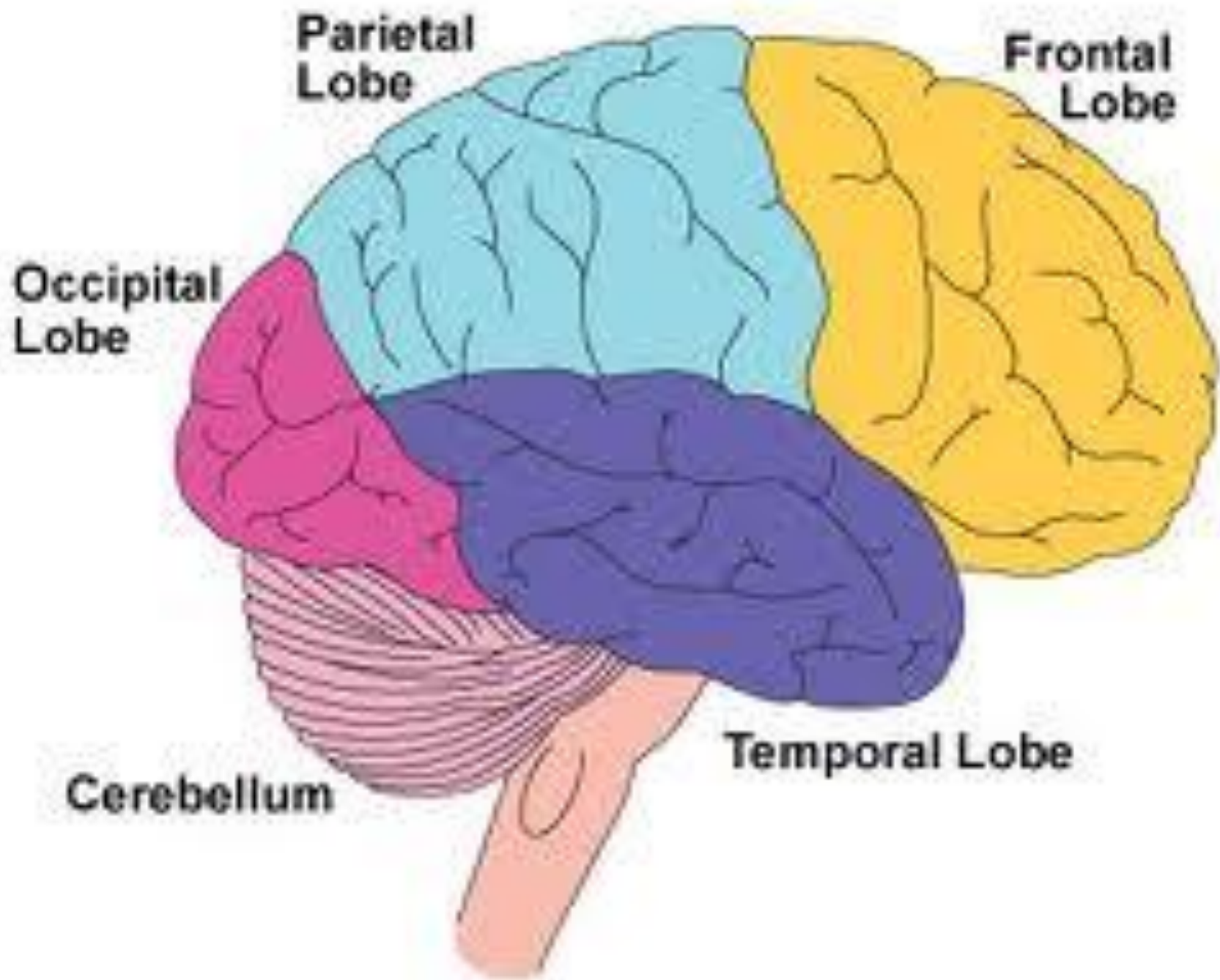


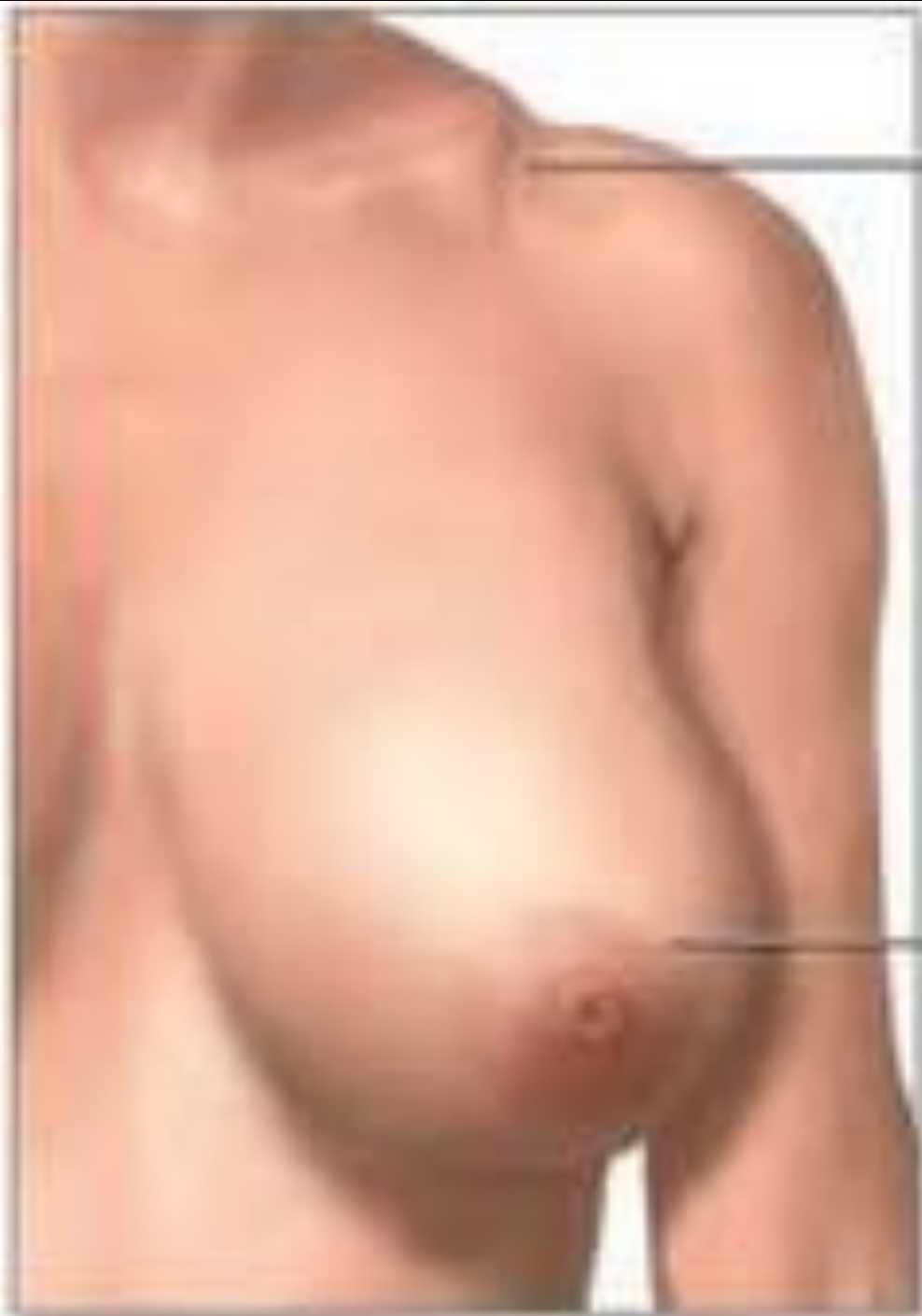Major Internal Parts of the Human Brain





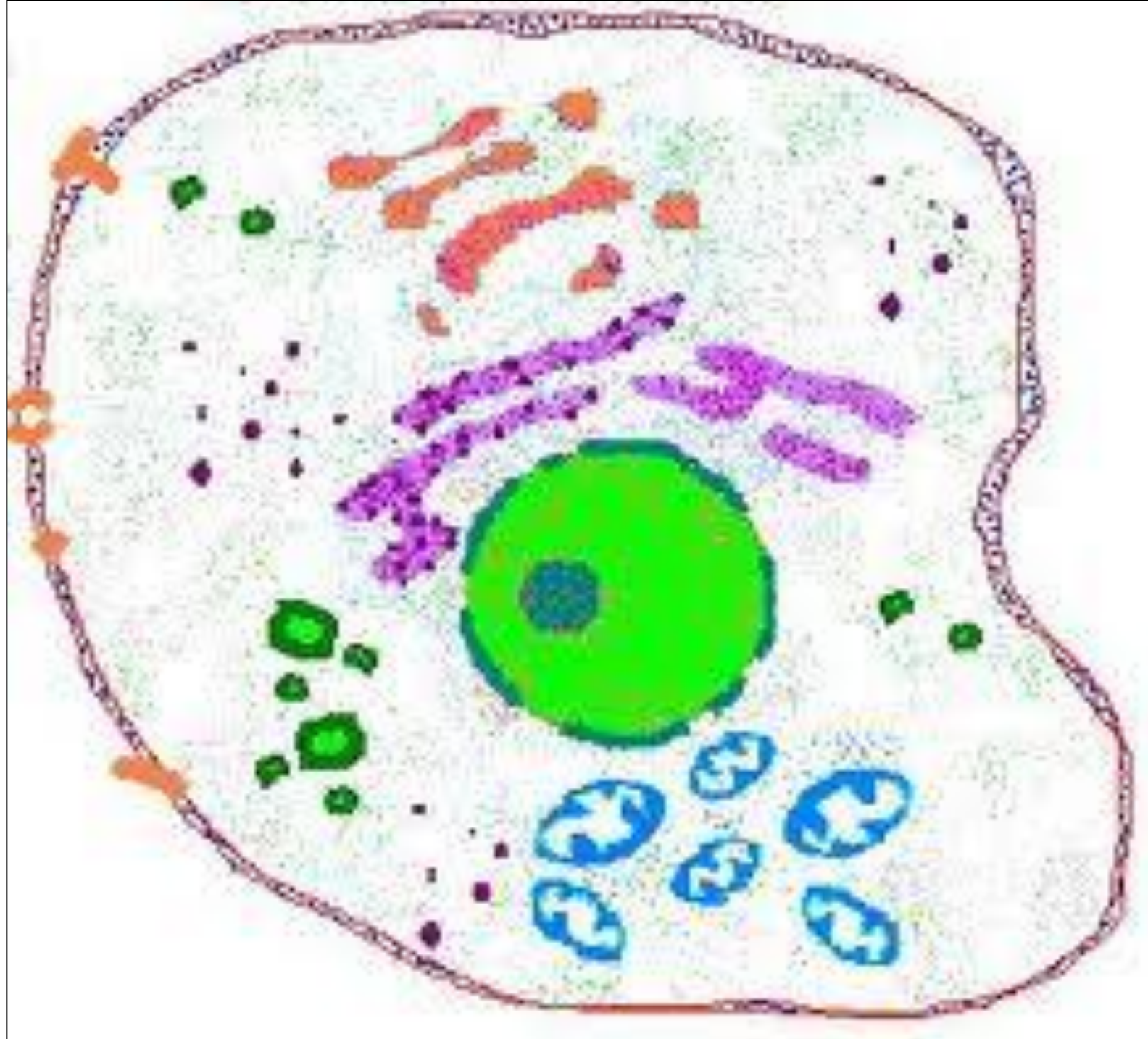






Groove from
bra strap

Disproportionately
large breast



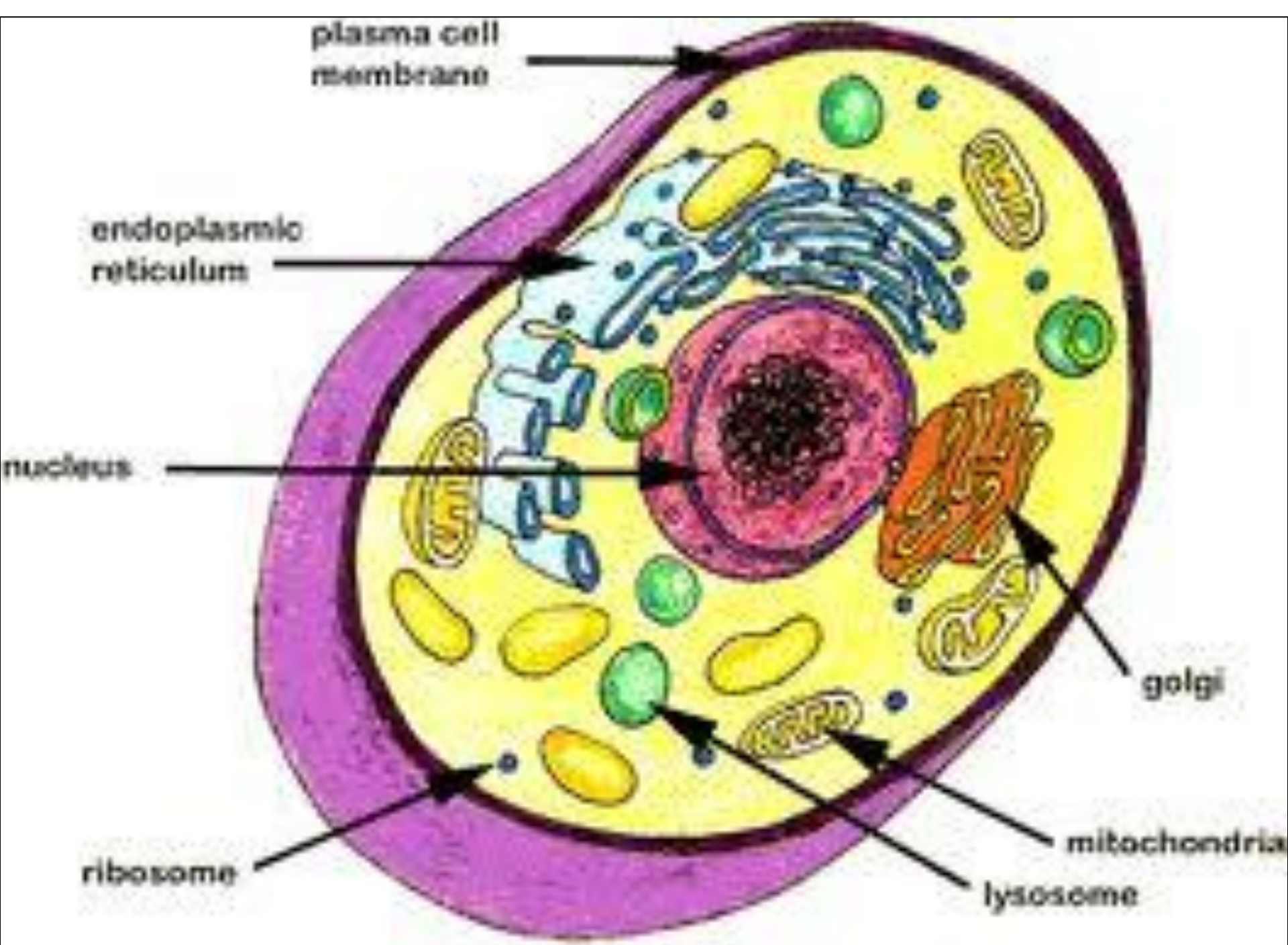


Table 2 : Percentages of required elements supplied to a corn crop by various processes (mass flow, diffusion and root interception)

Nutrient	Amount Needed for 9500 kg Grain ha ⁻¹	Approximate Amount (%) Supplied by:		
		Mass Flow	Diffusion	Root Interception
Nitrogen	190	79	20	1
Phosphorous	40	5	93	2
Potassium	195	18	80	2
Calcium	40	375	0	150
Magnesium	45	222	0	33
Sulfur	22	295	0	5

Source: Barber, 1984

Total Competitive Response (TCR)

$$= \ln\left(\frac{T_{AN}}{T_{NN}}\right) \quad (1)$$

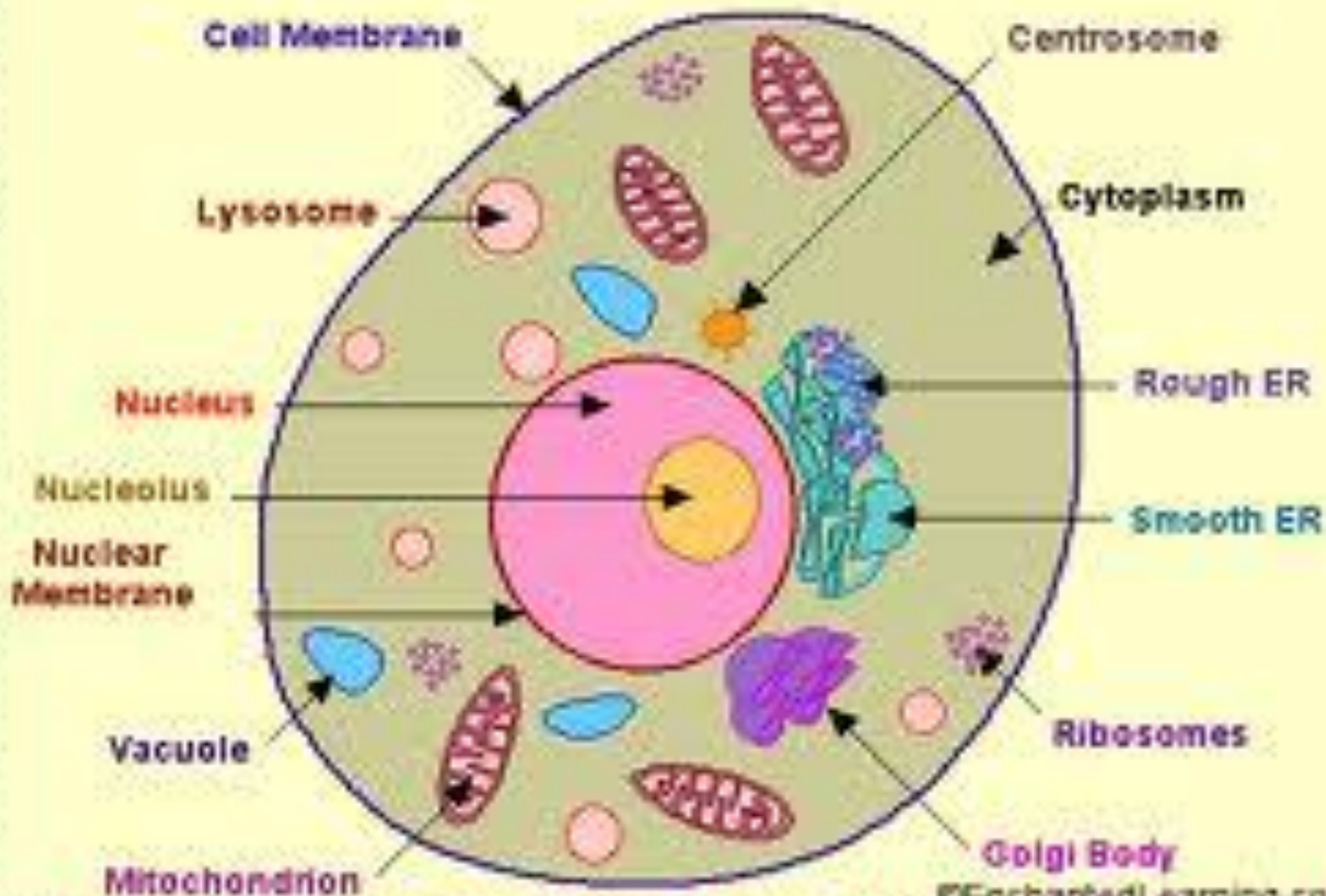
Aboveground Competitive Response (ACR)

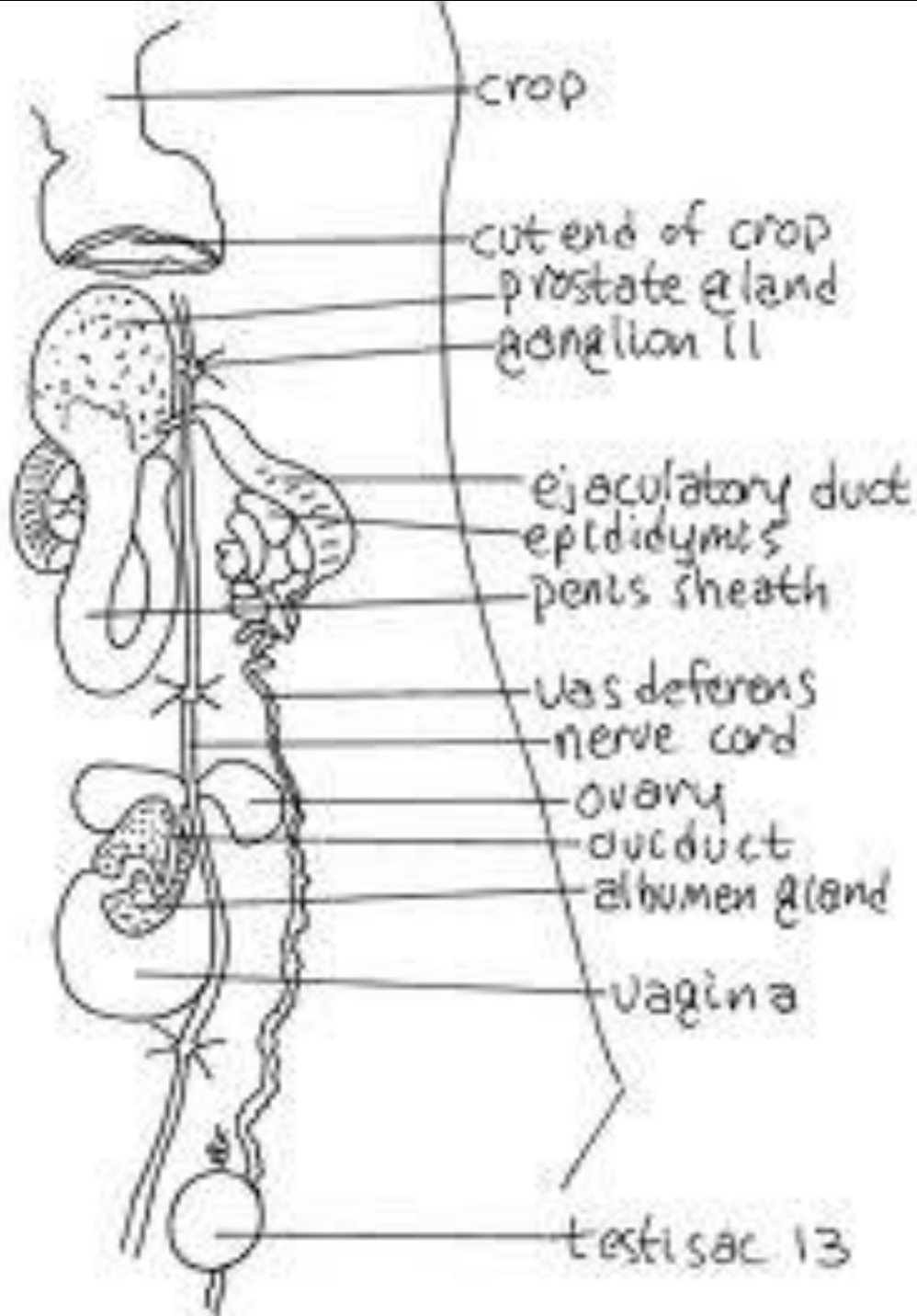
$$= \ln\left(\frac{T_{SN}}{T_{NN}}\right) \quad (2)$$

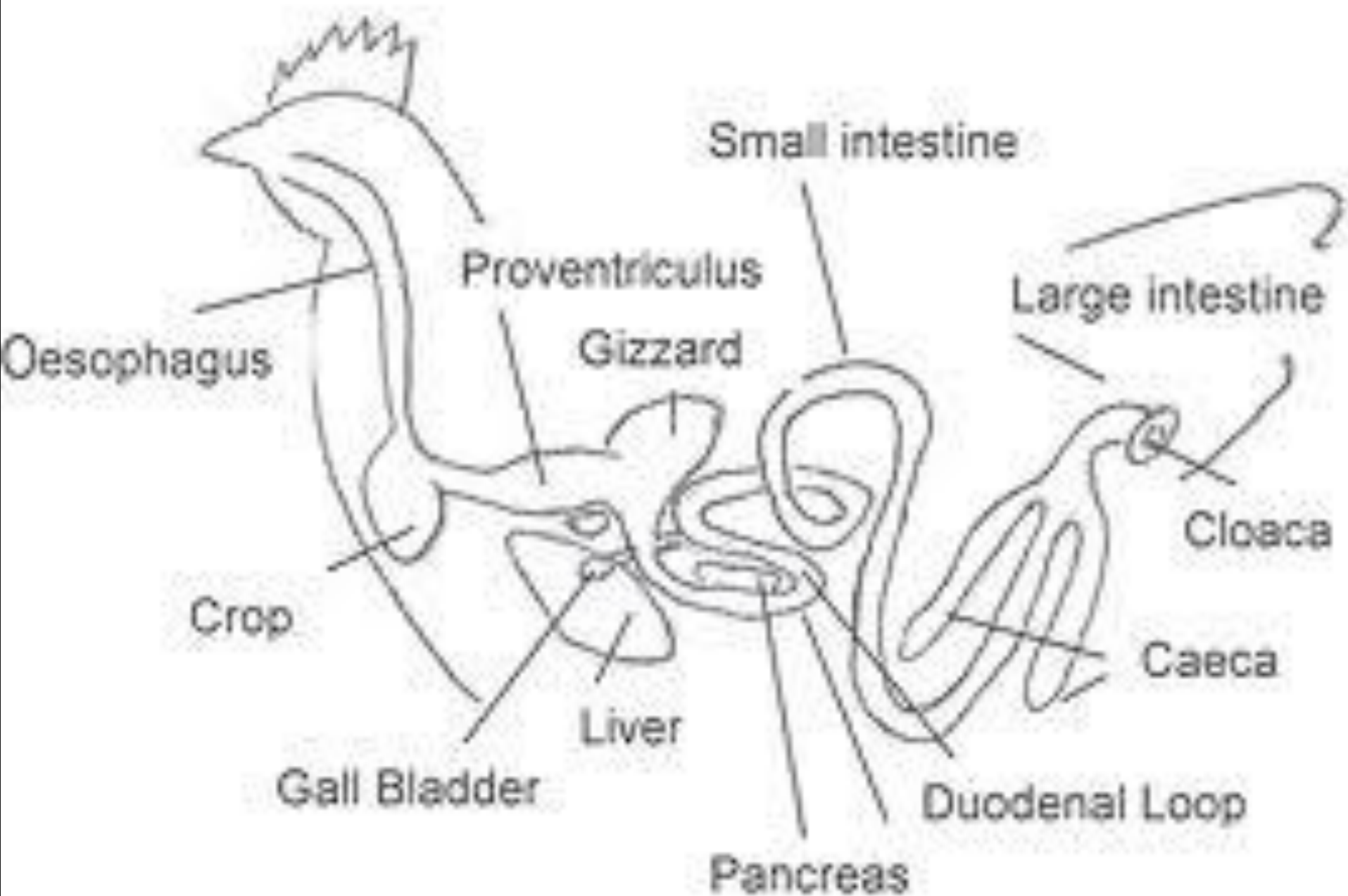
Belowground Competitive Response (BCR)

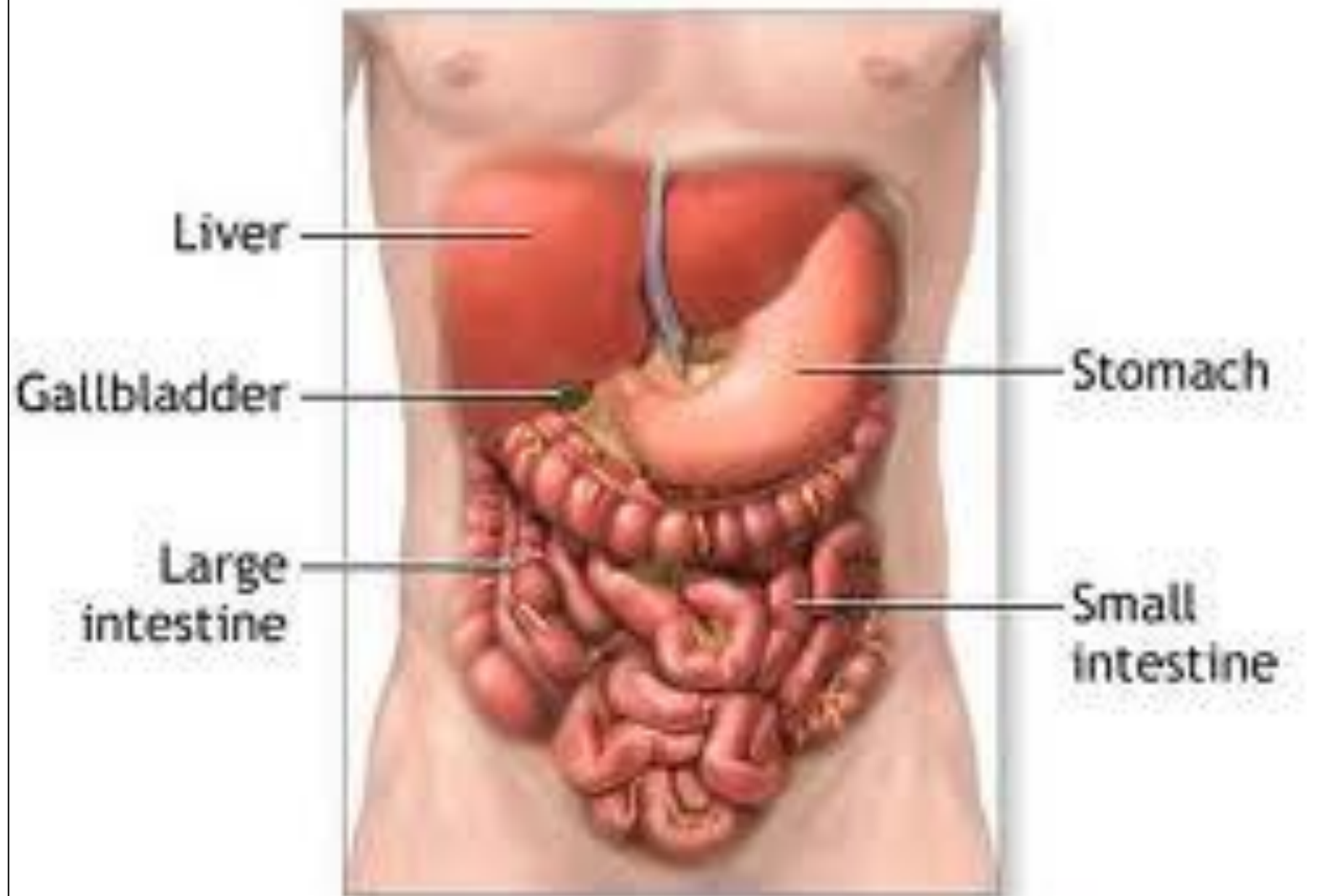
$$= \ln\left(\frac{T_{RN}}{T_{NN}}\right) \quad (3)$$

Cross-Section of an Animal Cell

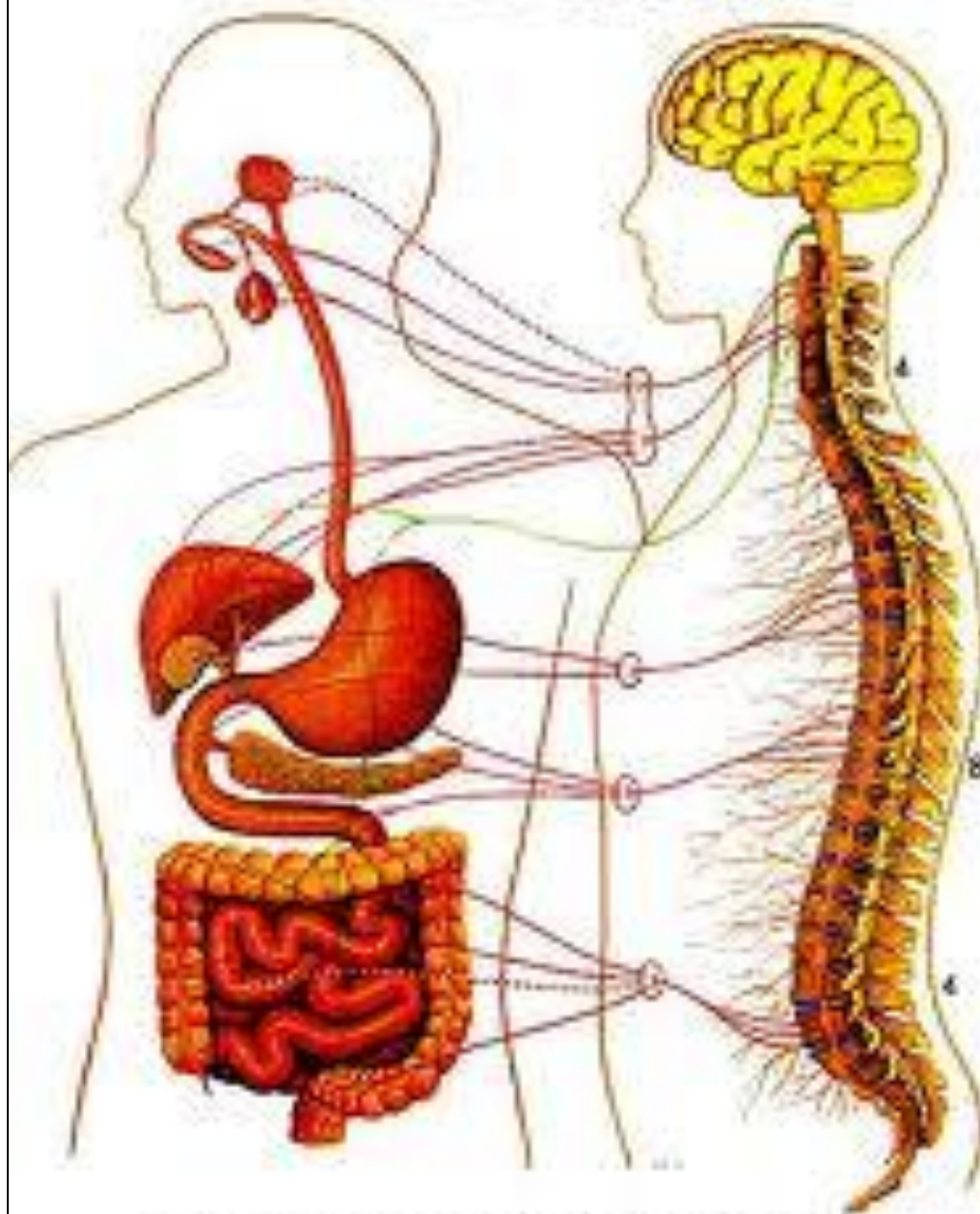


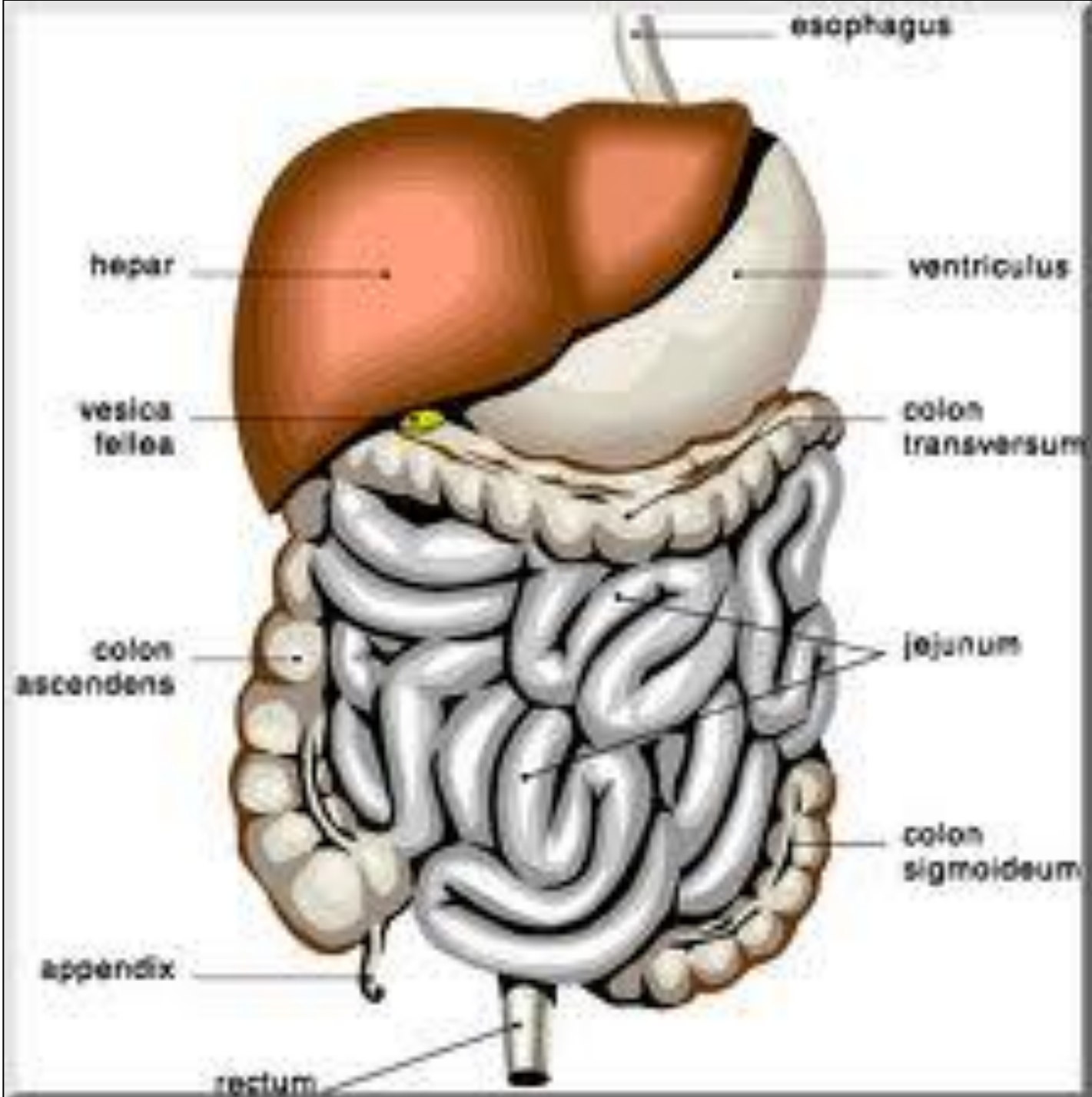


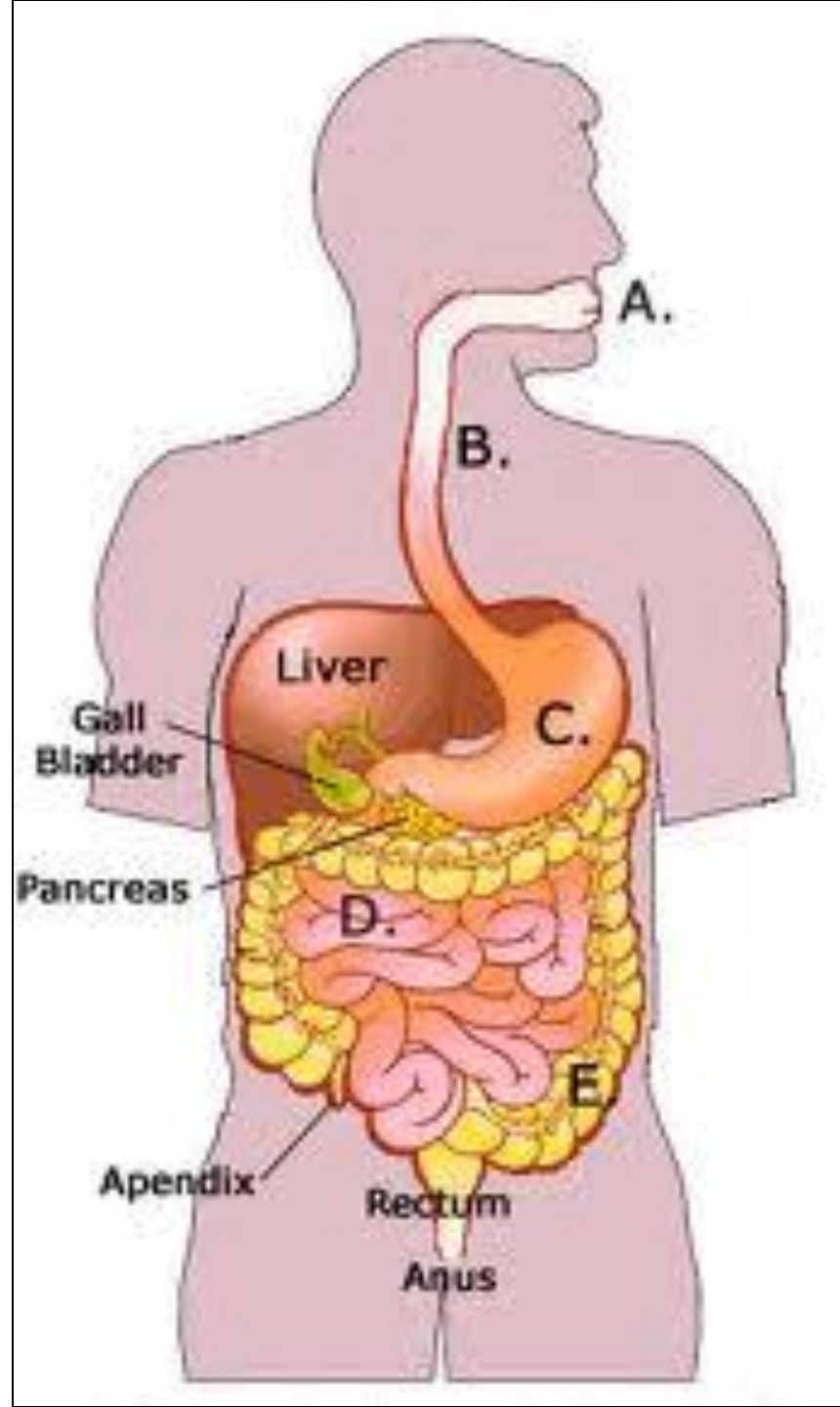


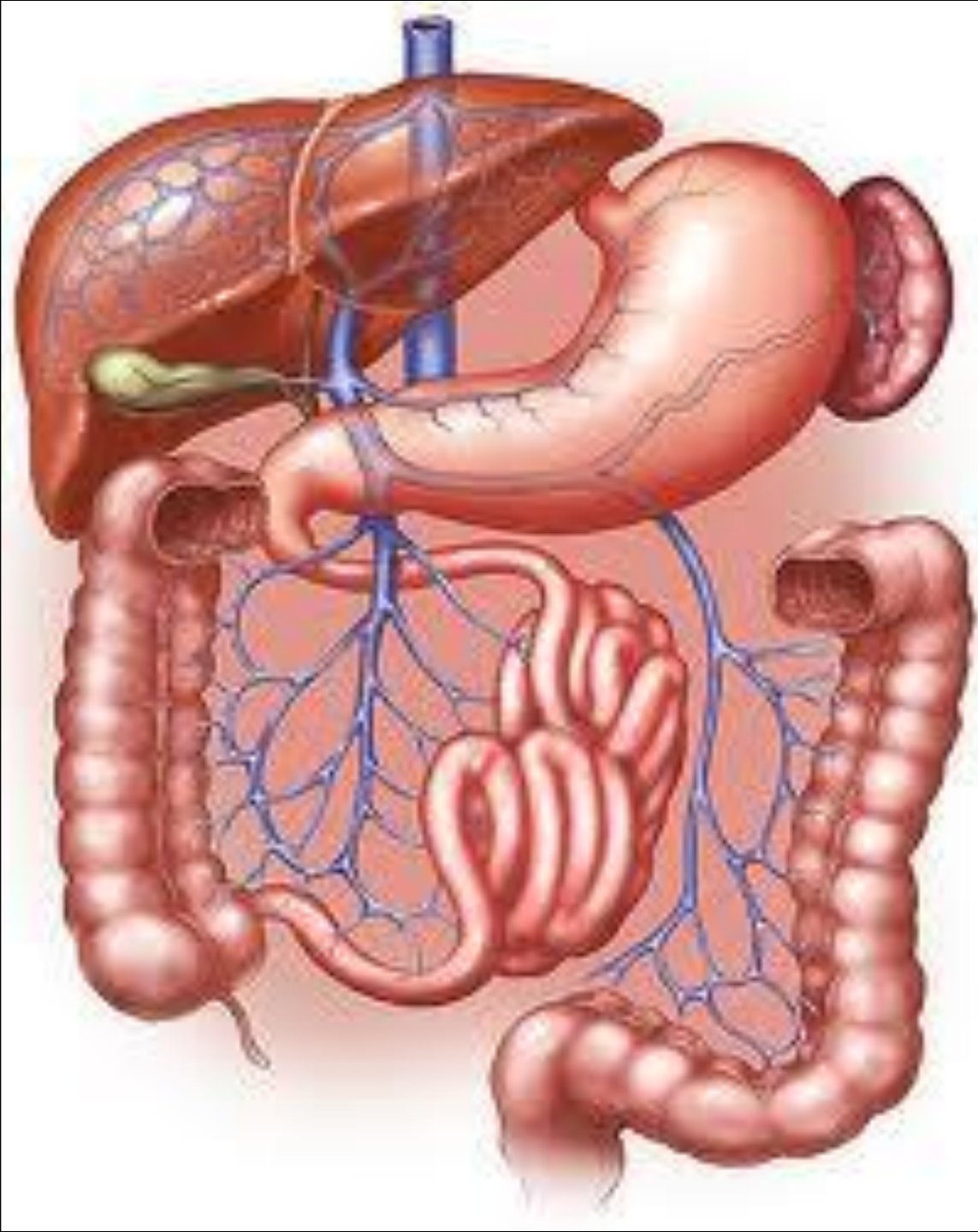


DIGESTIVE SYSTEM

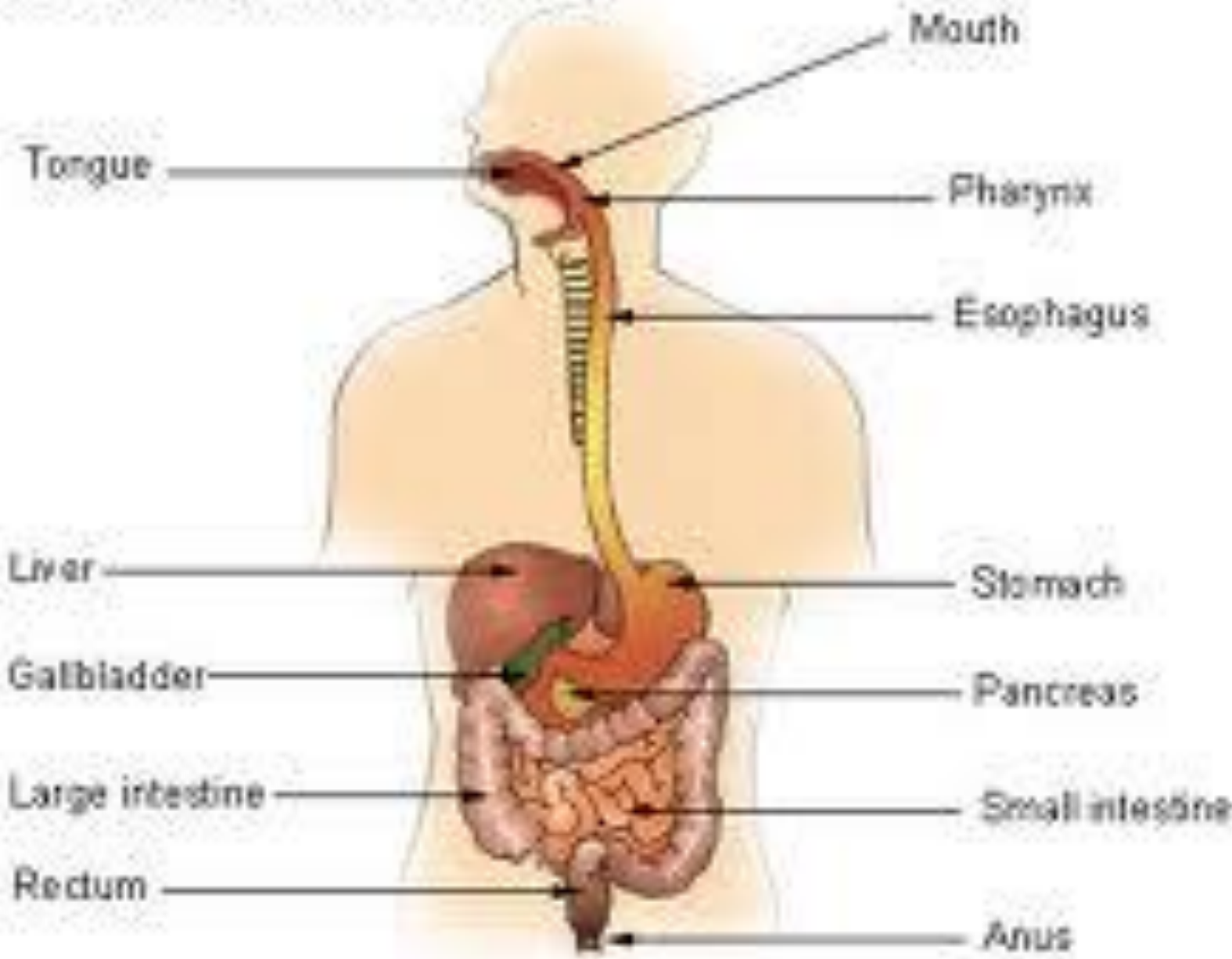


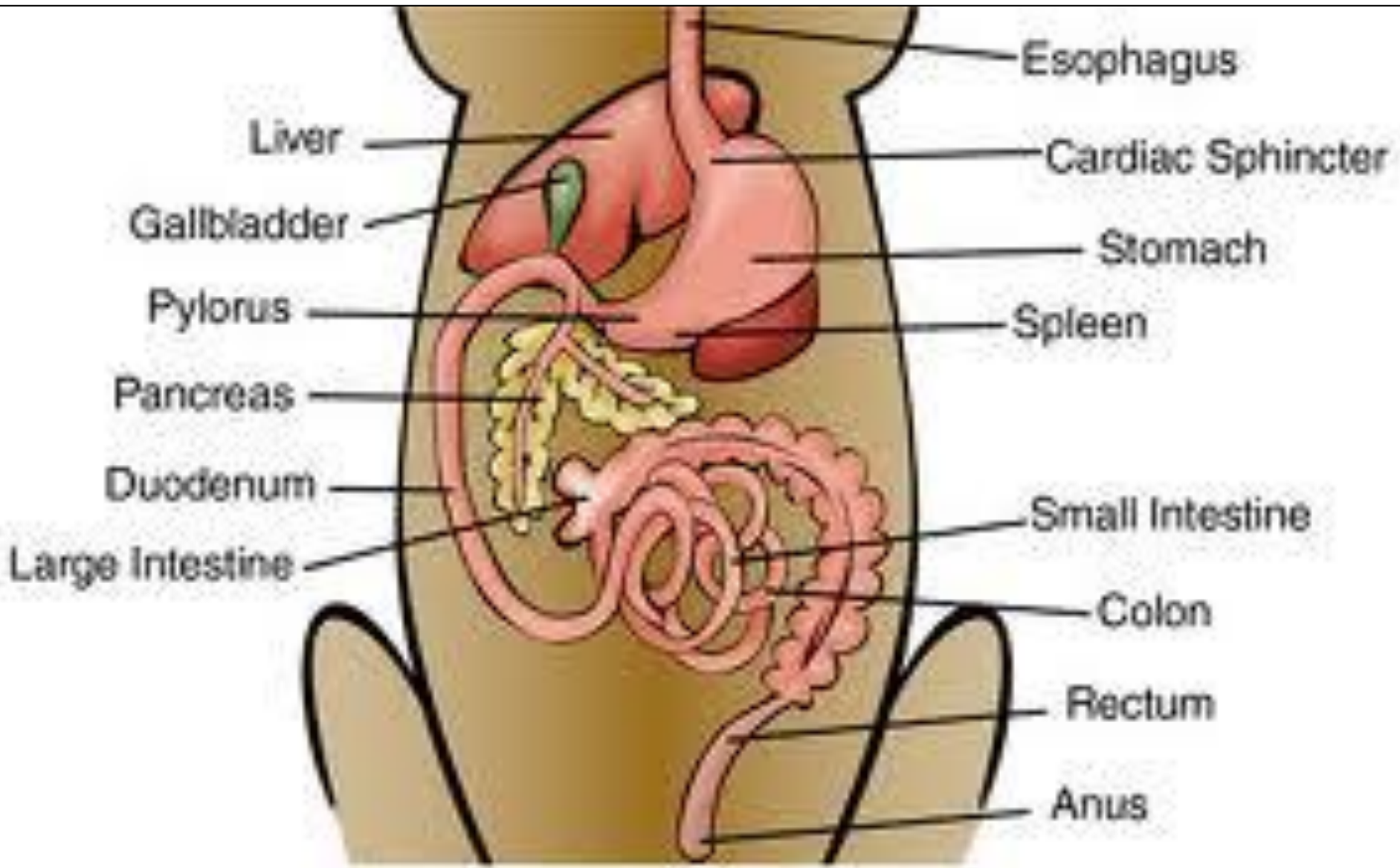






Organs of the Digestive System







Salivary glands

Esophagus

Stomach

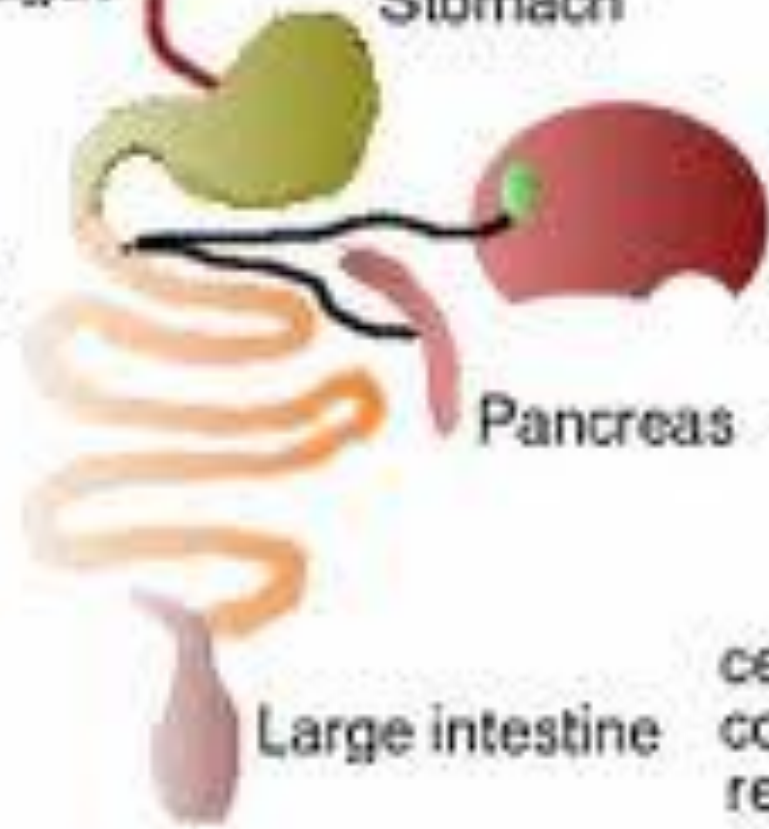
Liver and
gallbladder

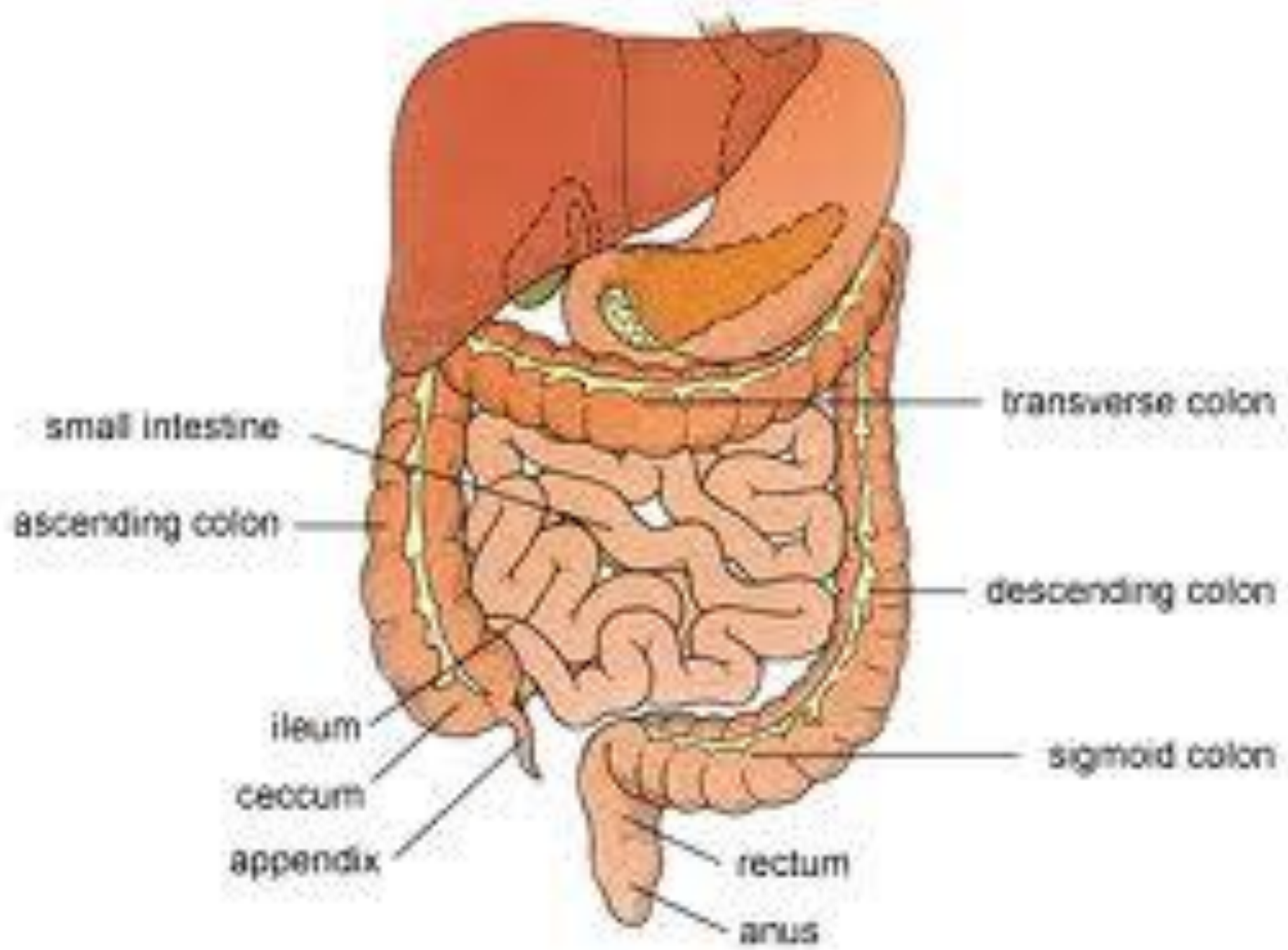
Small intestine
duodenum
jejunum
ileum

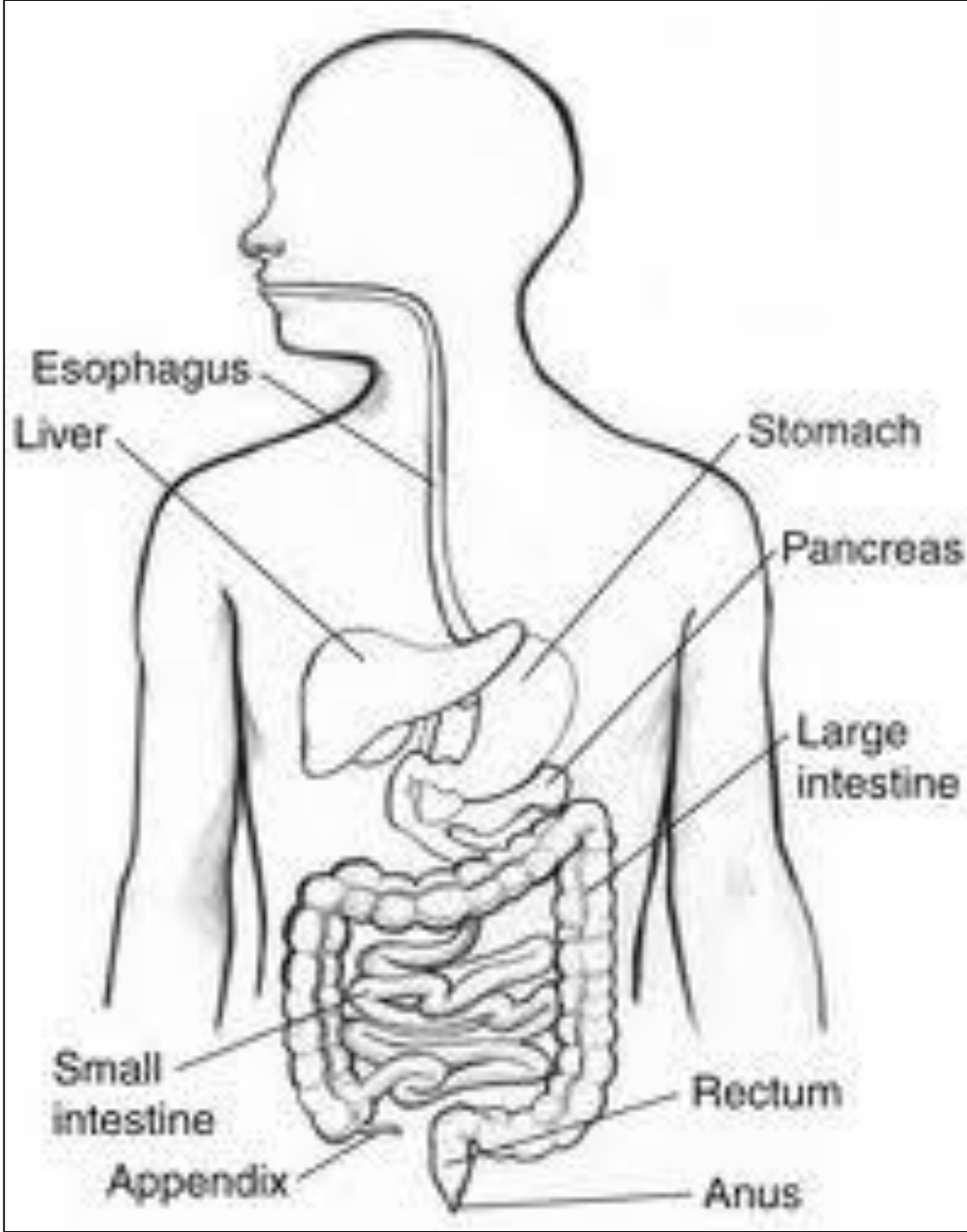
Pancreas

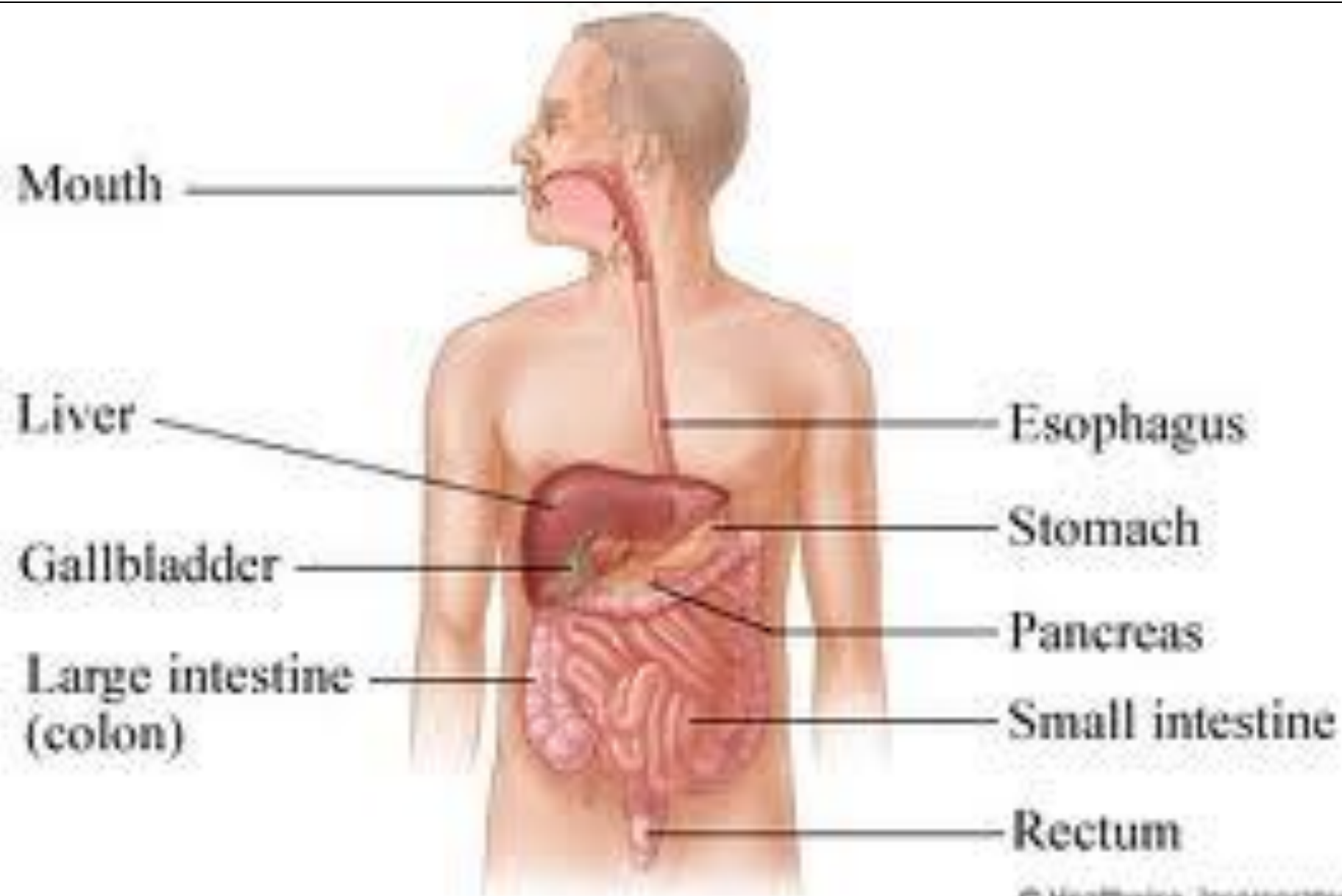
Large intestine

cecum
colon
rectum









Mouth

Liver

Gallbladder

Large intestine
(colon)

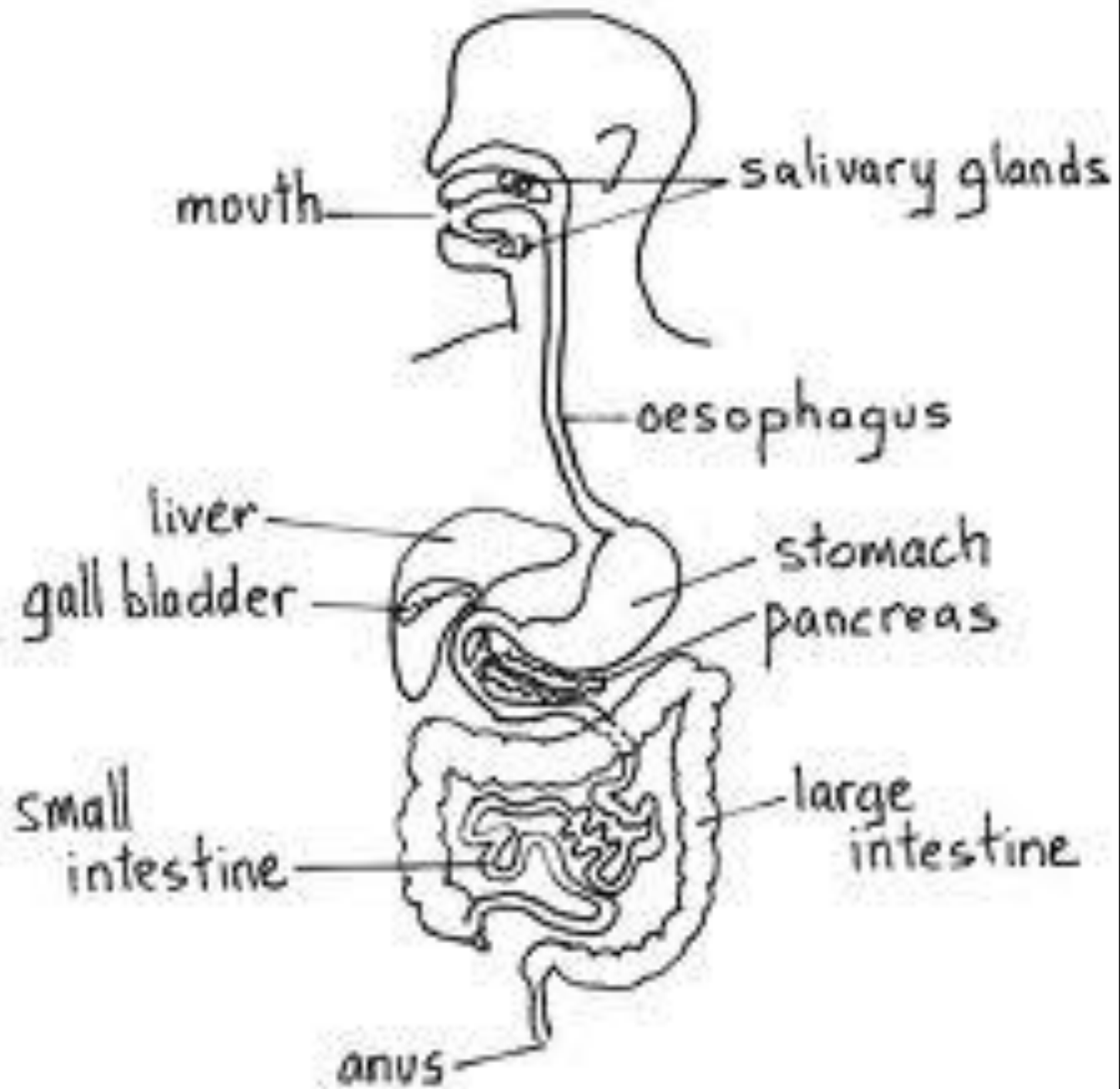
Esophagus

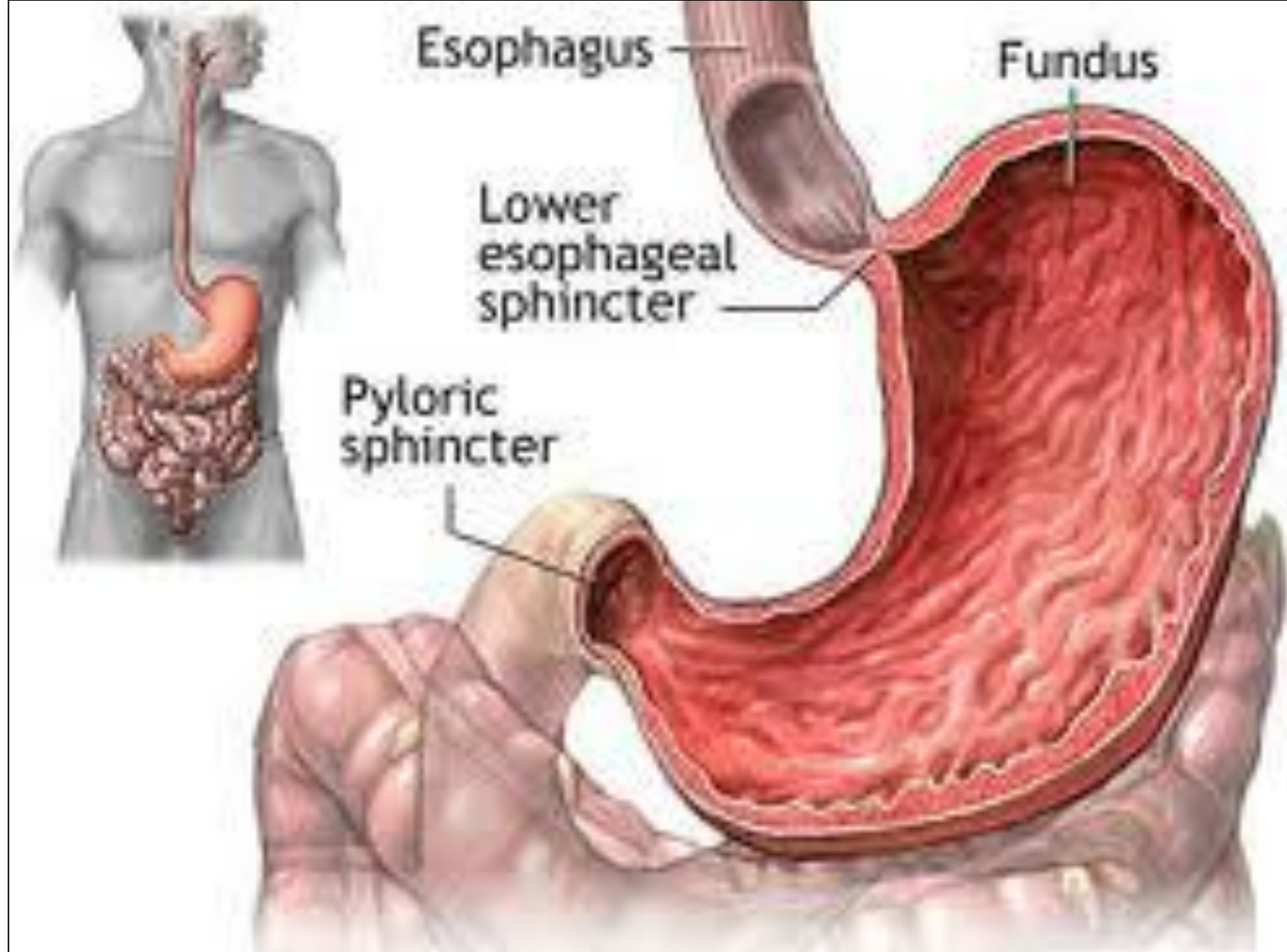
Stomach

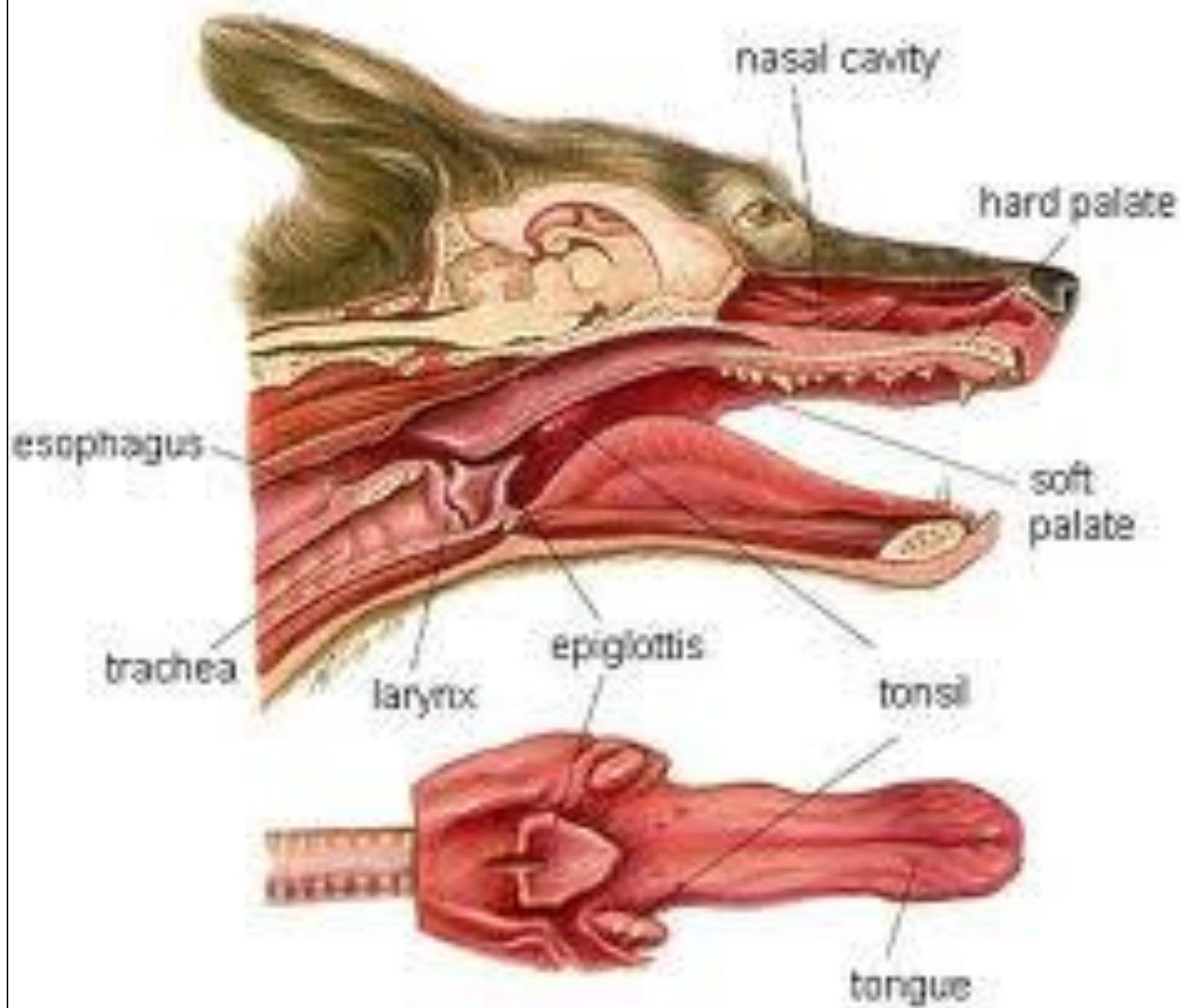
Pancreas

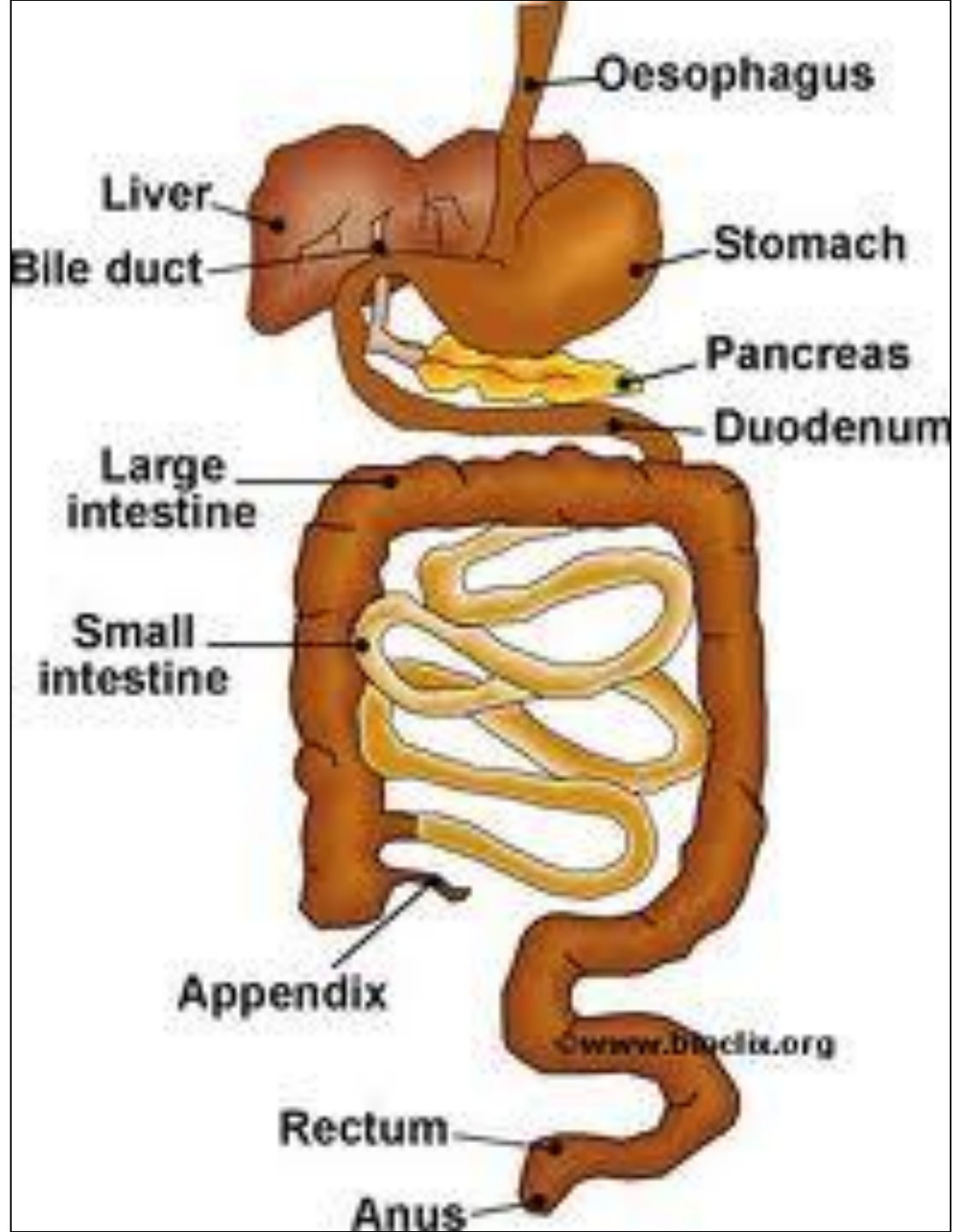
Small intestine

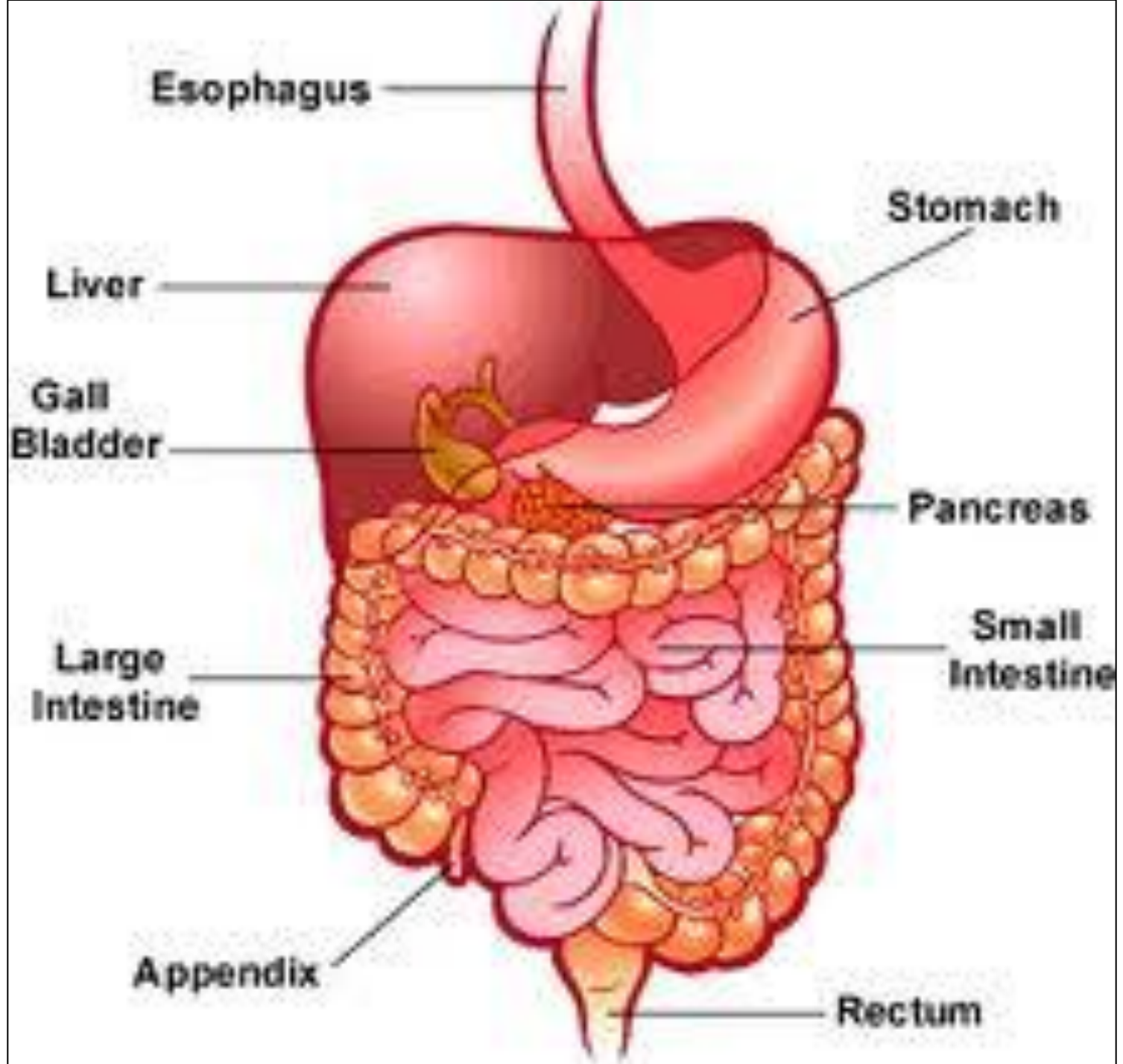
Rectum

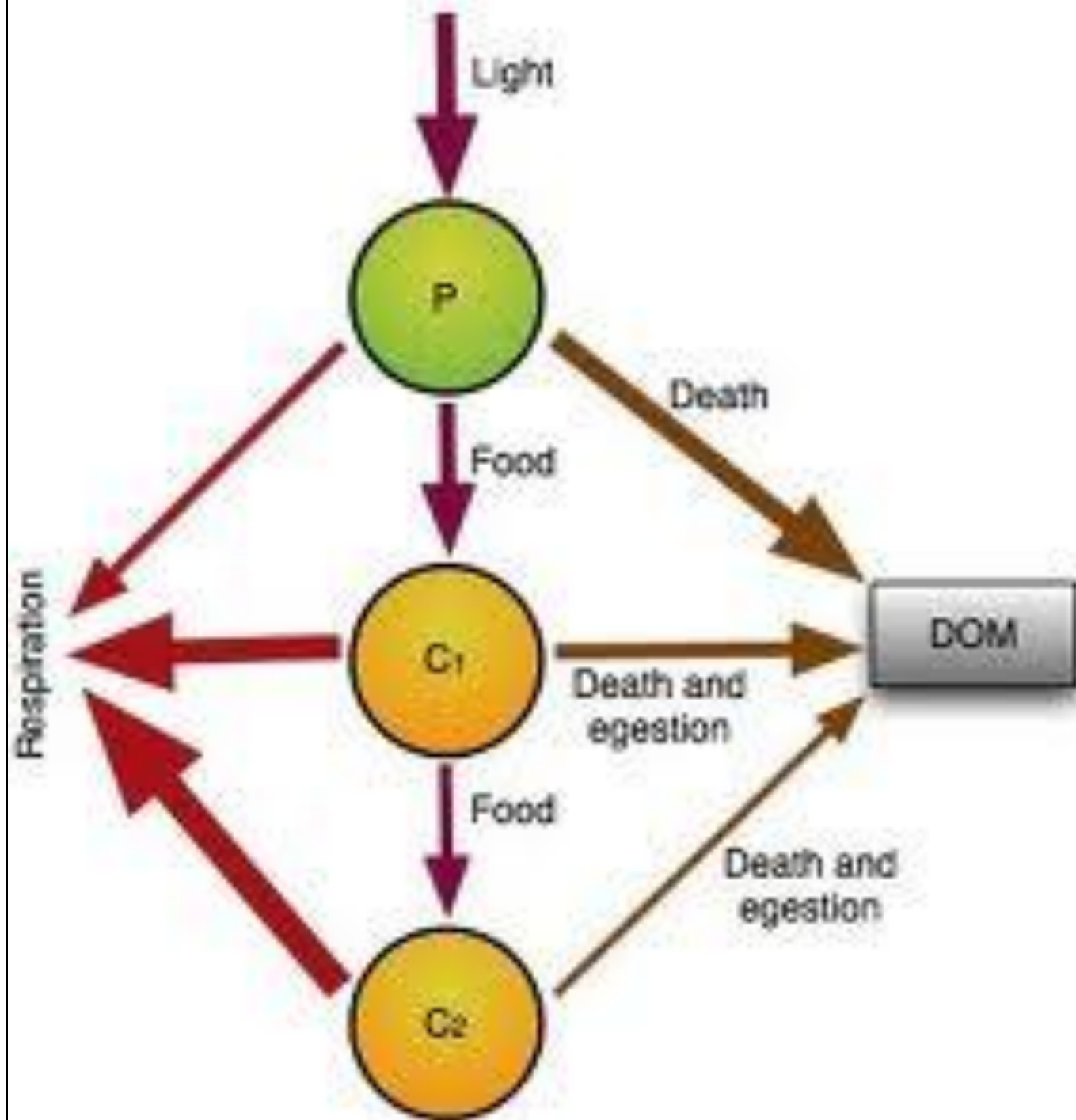




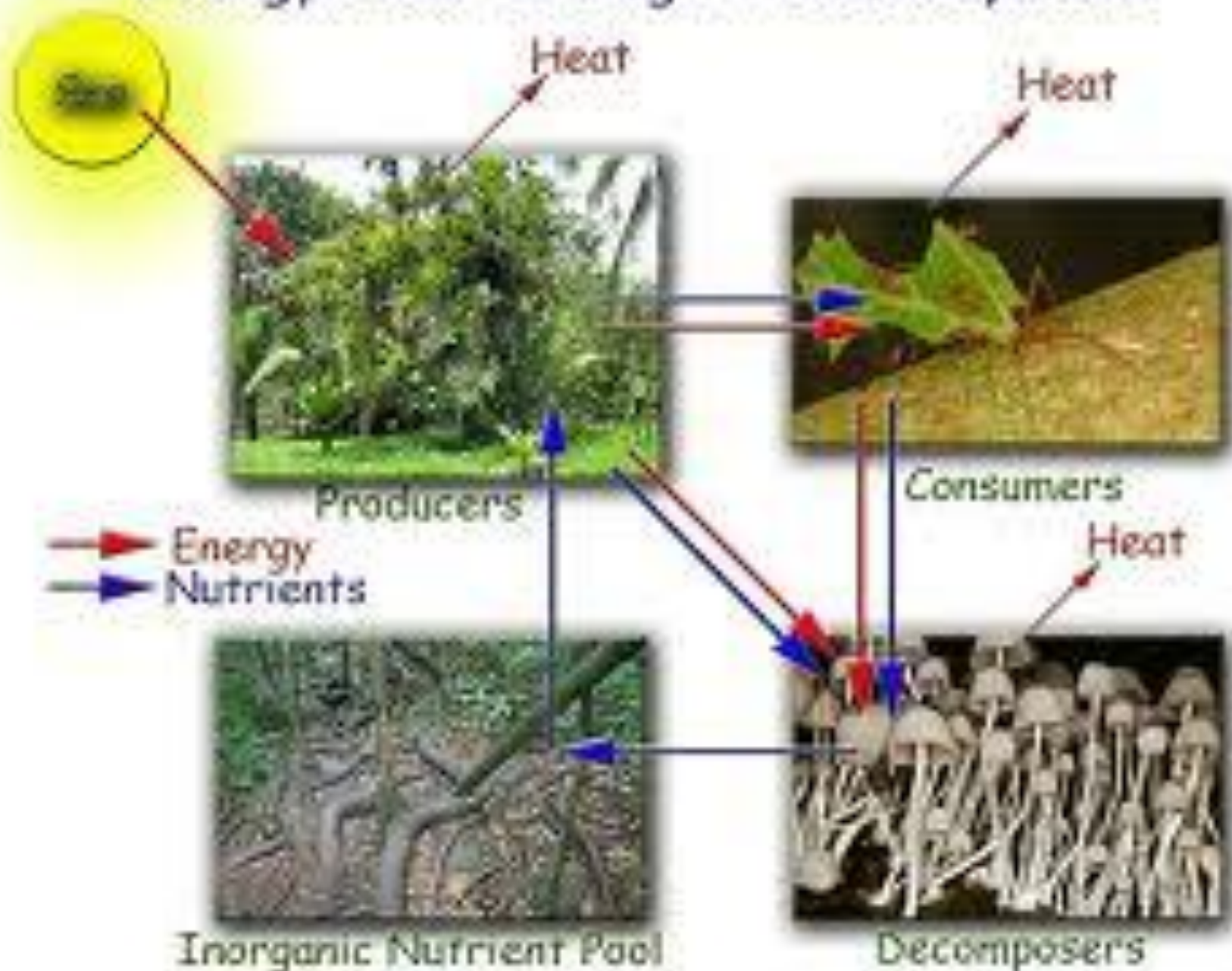


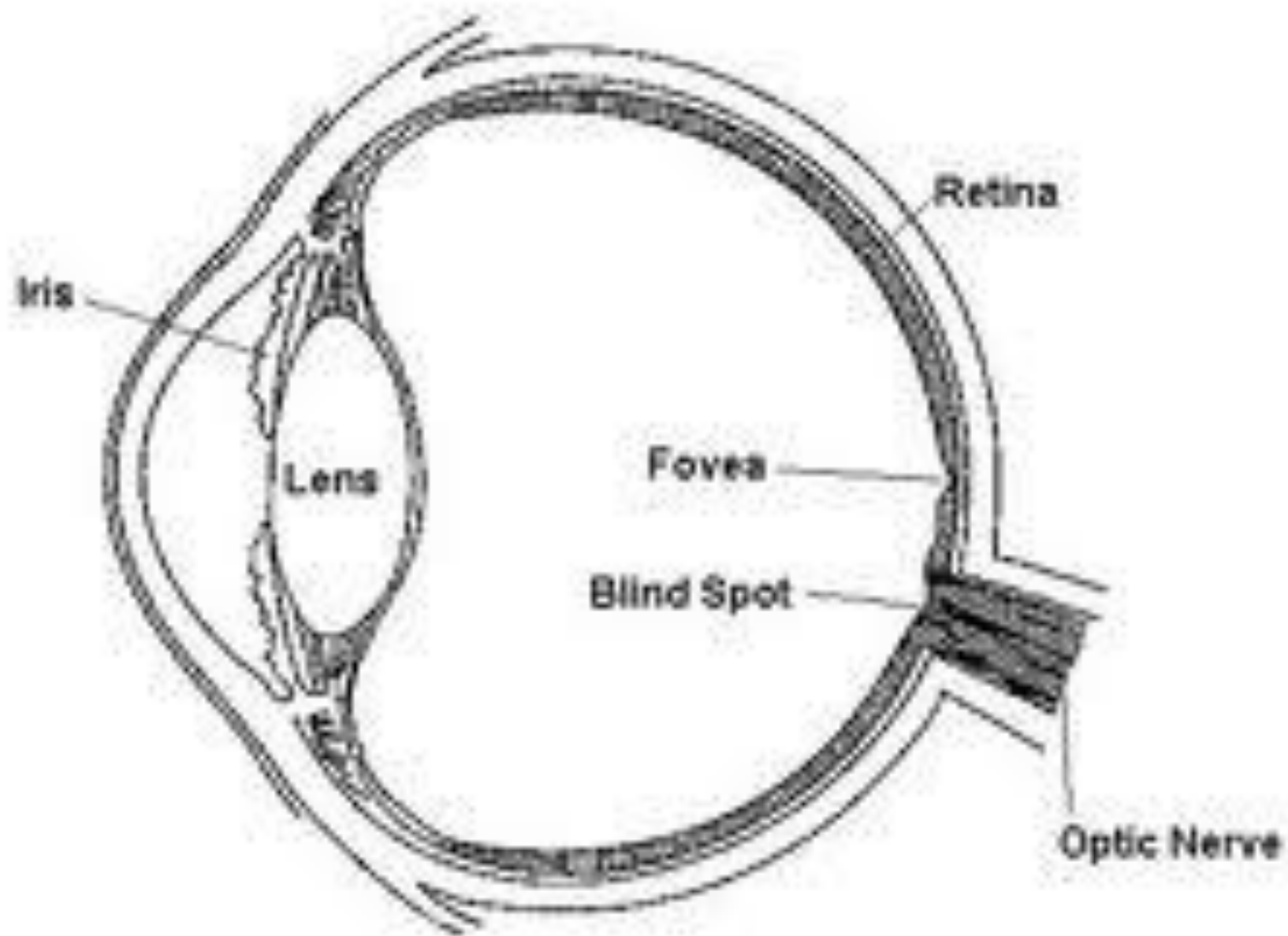




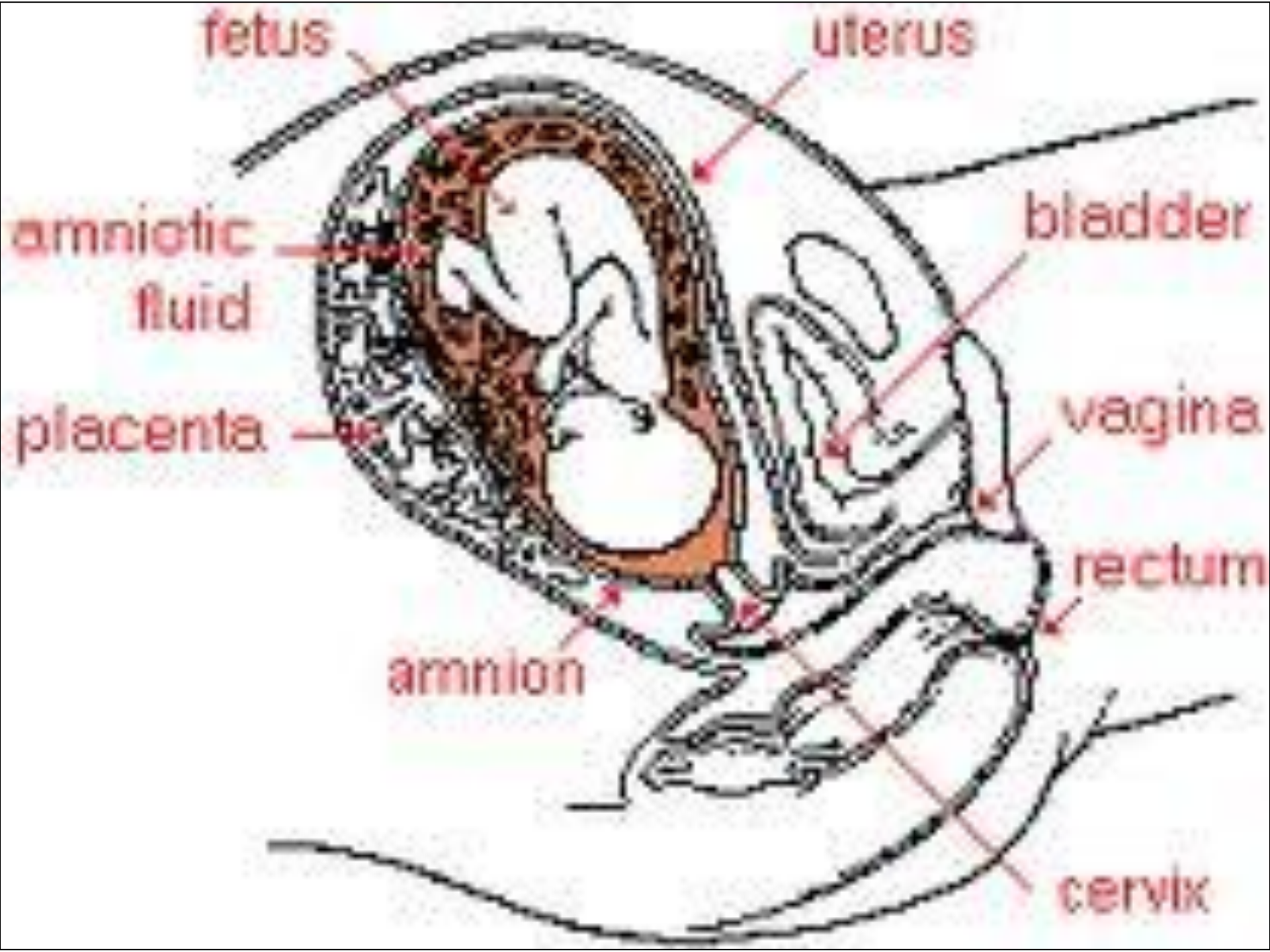


Energy Flow Through The Ecosystem

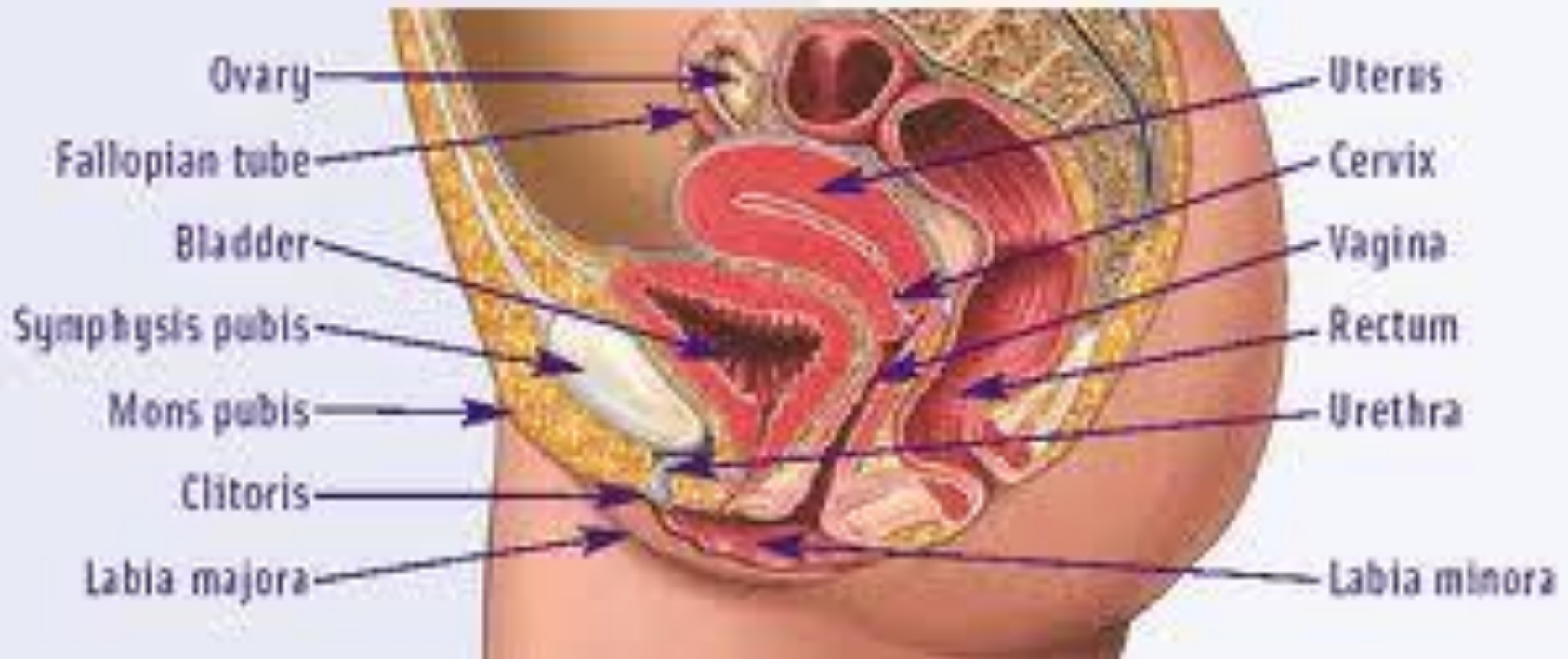


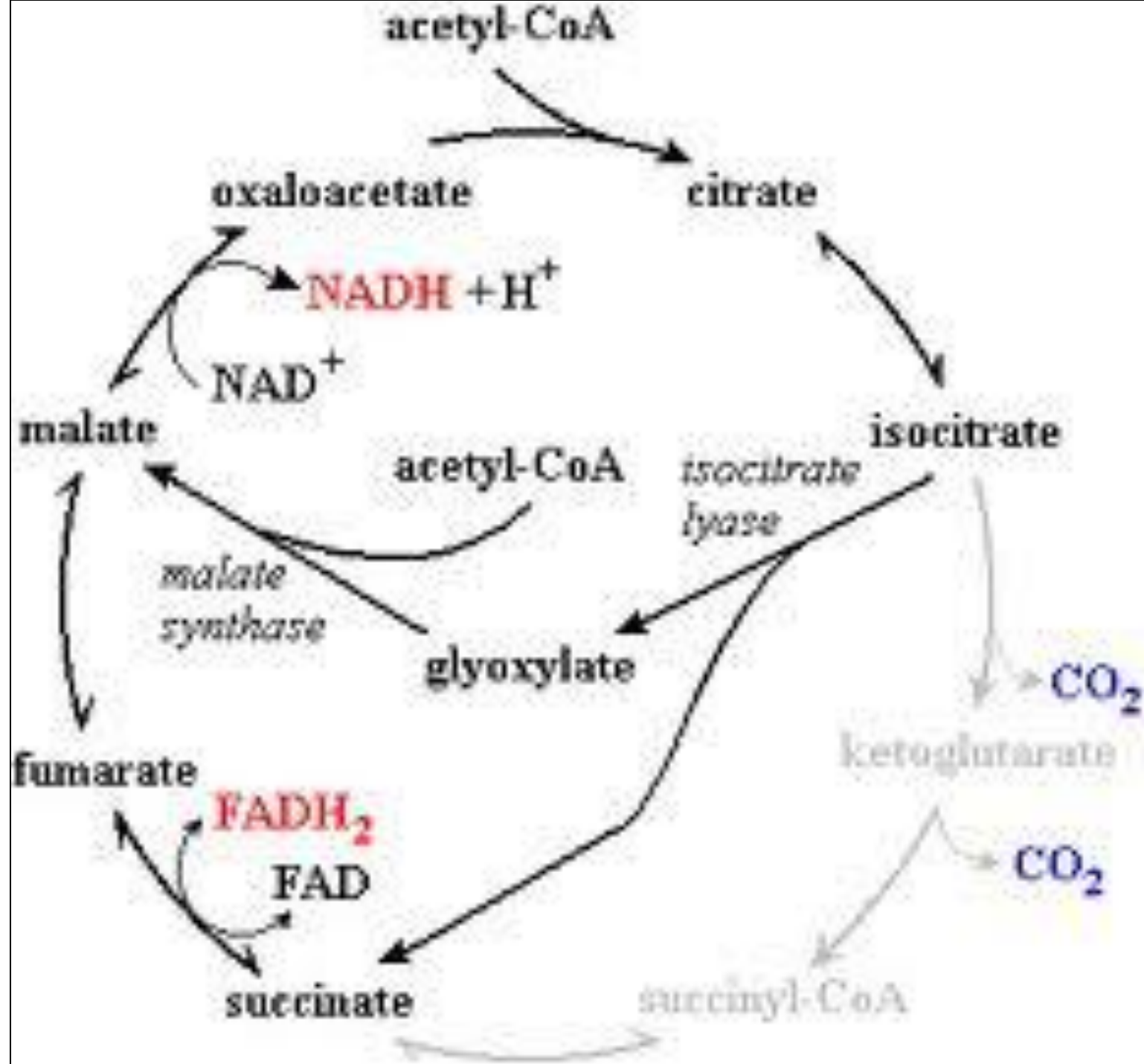


The Eye



The Female Reproductive System







duck



pheasant



pigeon

www.visualdictionaryonline.com



goose

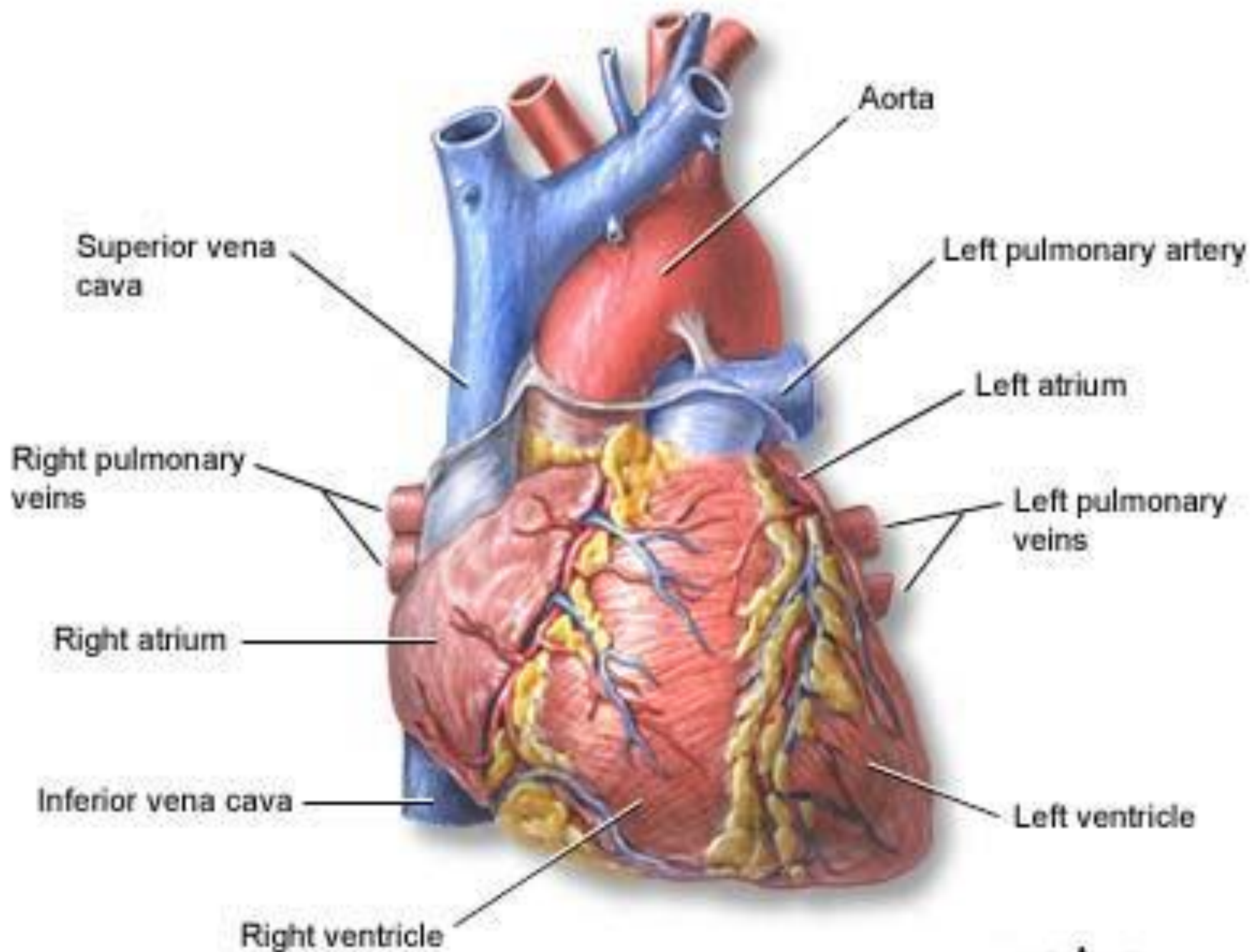


guinea fowl



turkey





Inside the Heart

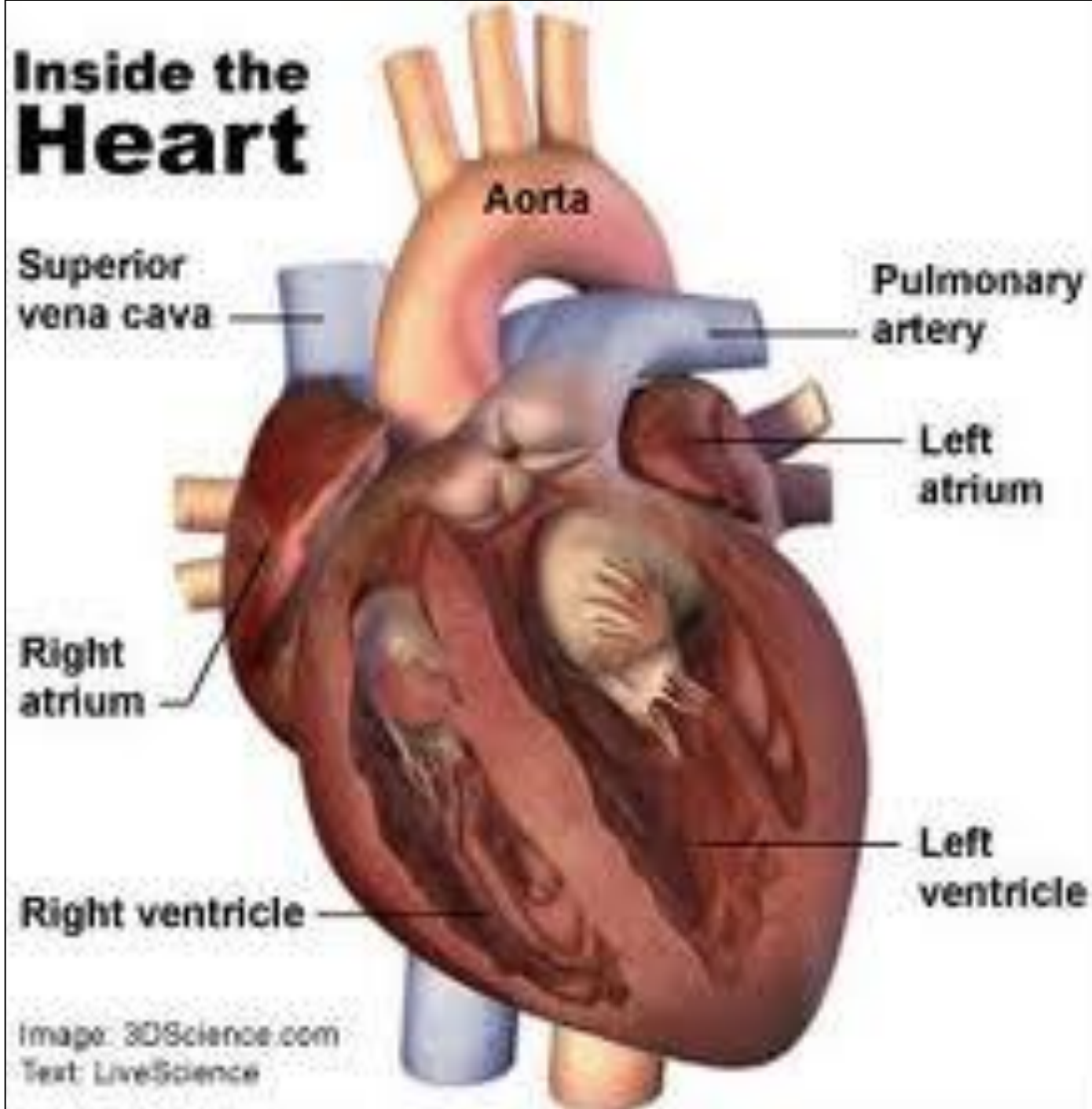
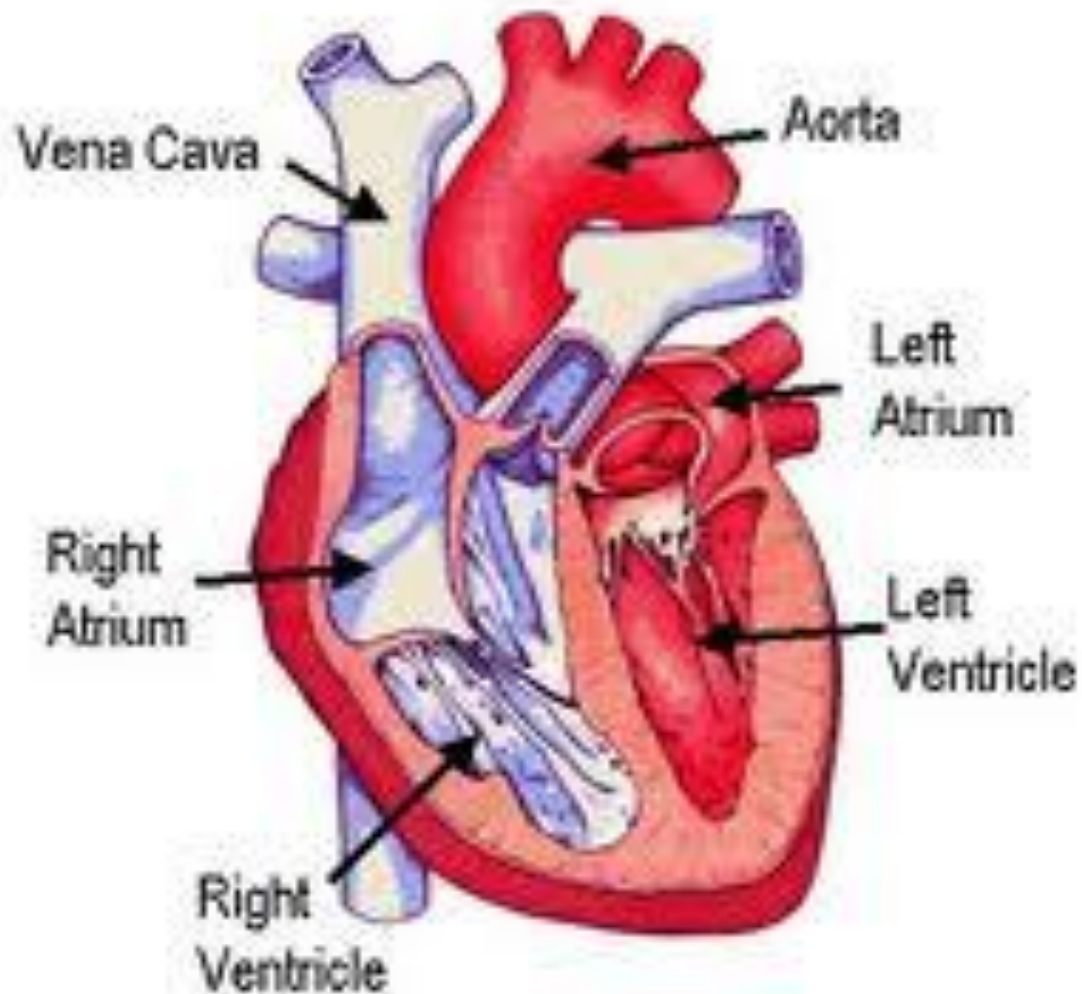



Image: 3DScience.com
Text: LiveScience

The Human Heart

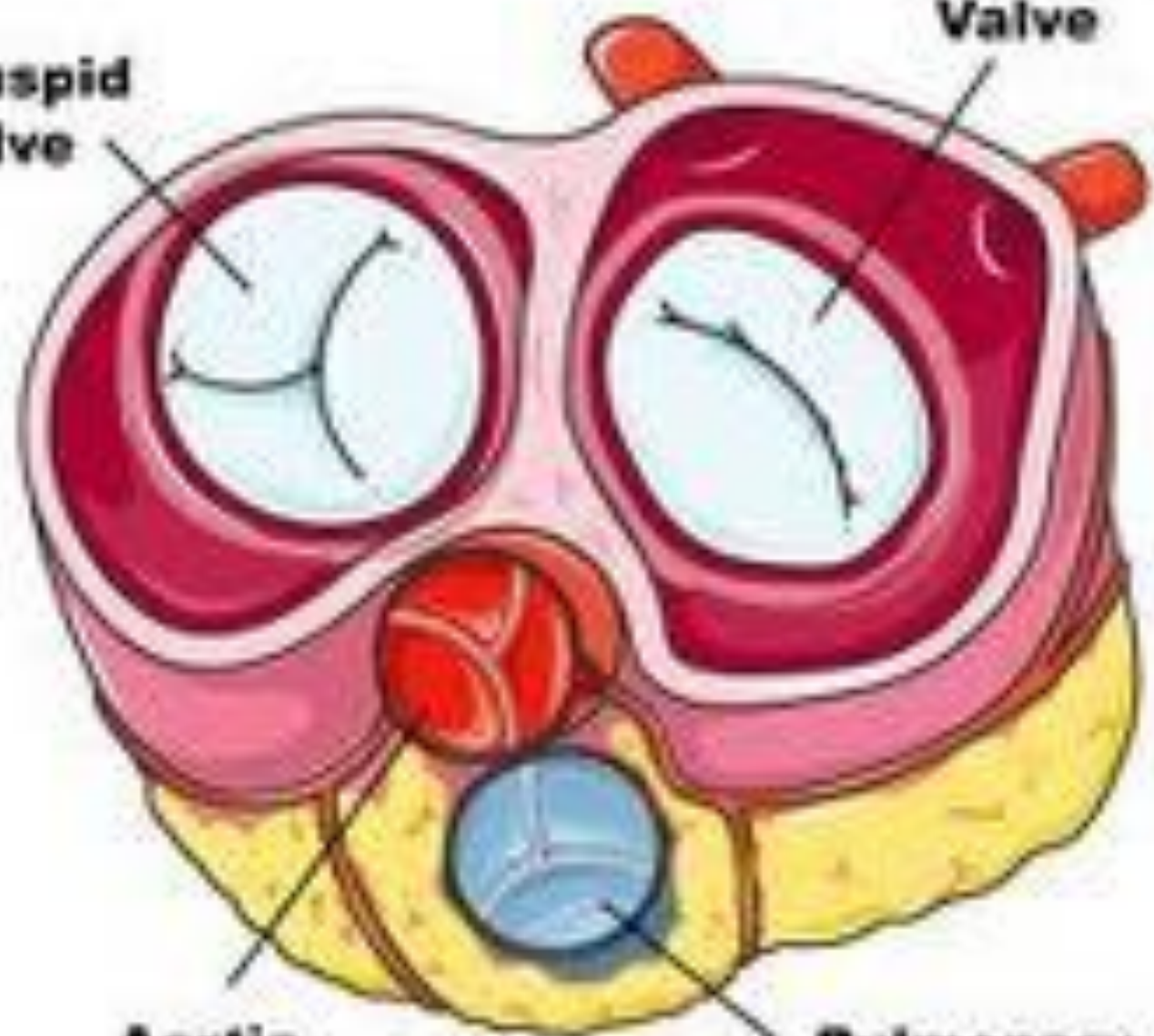


 Oxygenated Blood

 De-Oxygenated Blood

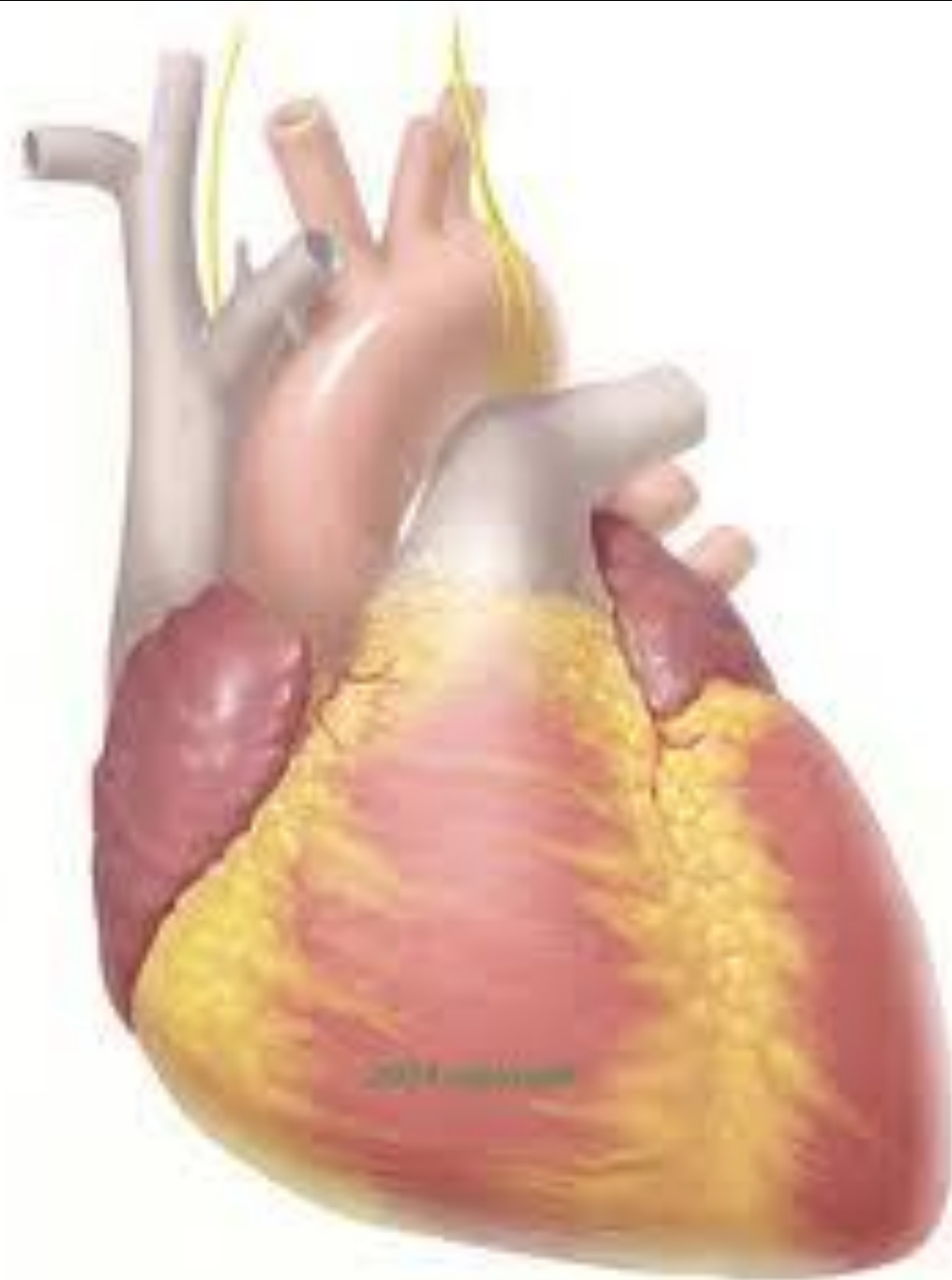
Tricuspid Valve

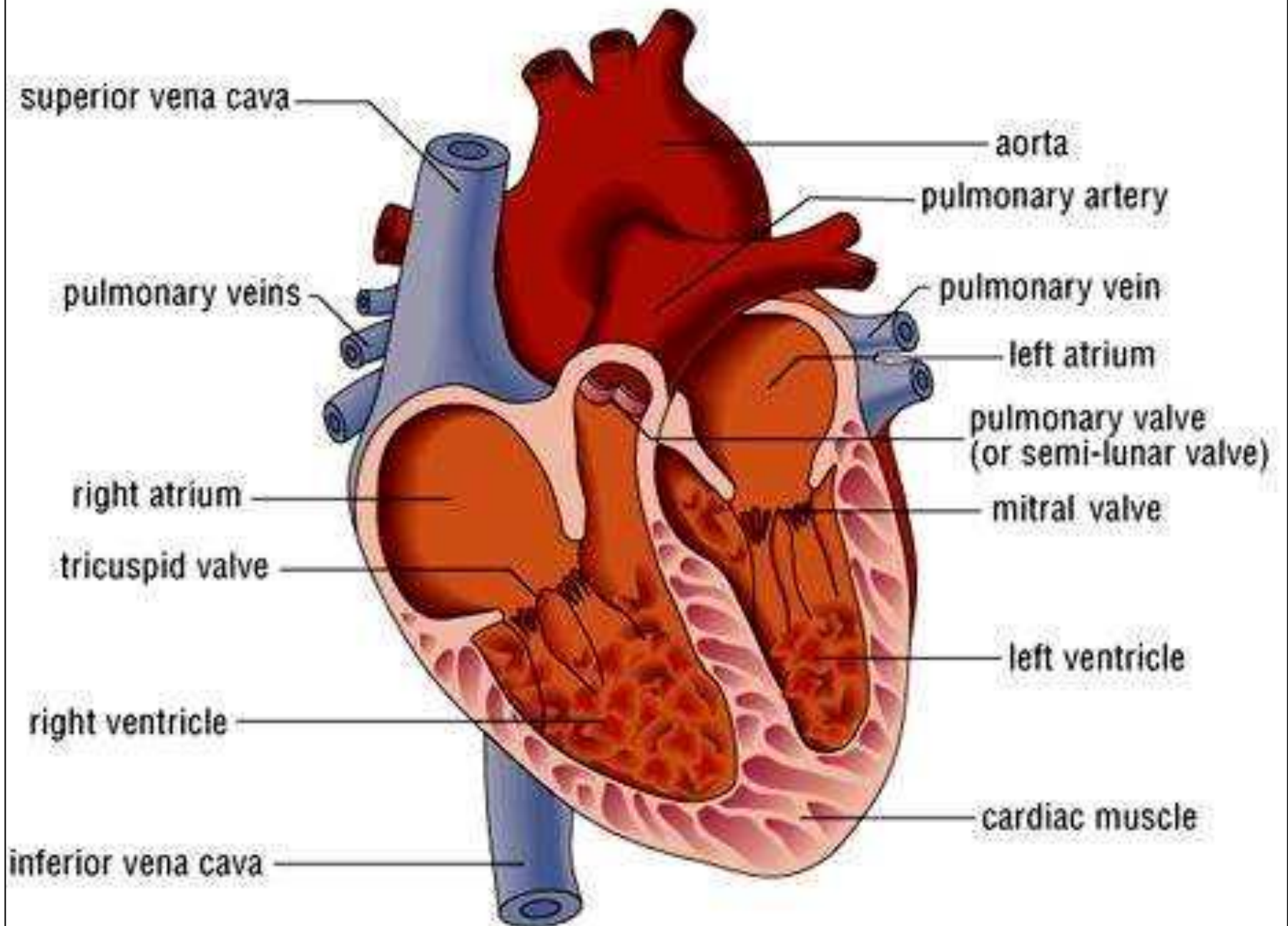
Mitral Valve

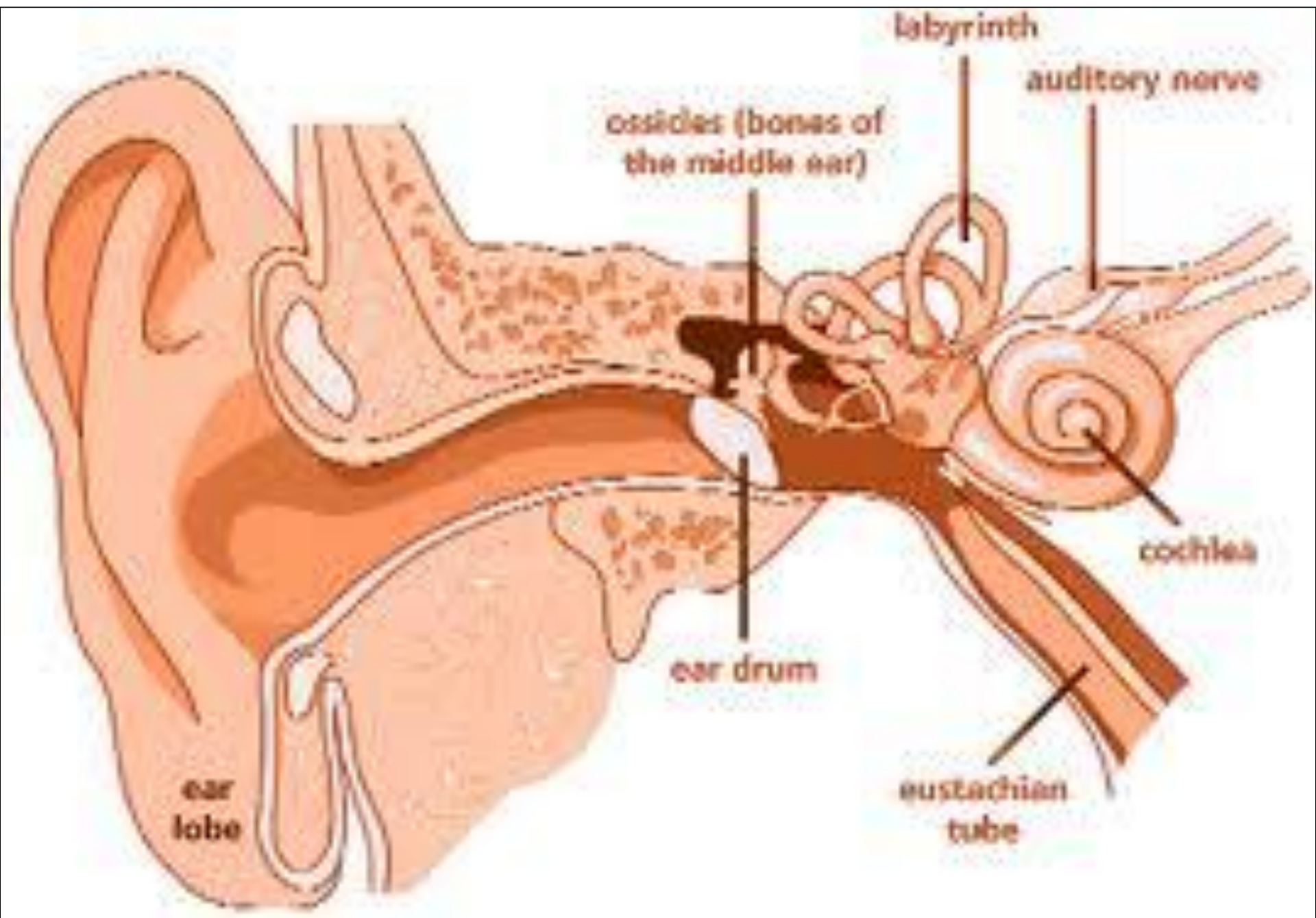


Aortic Valve

Pulmonary Valve







labyrinth

auditory nerve

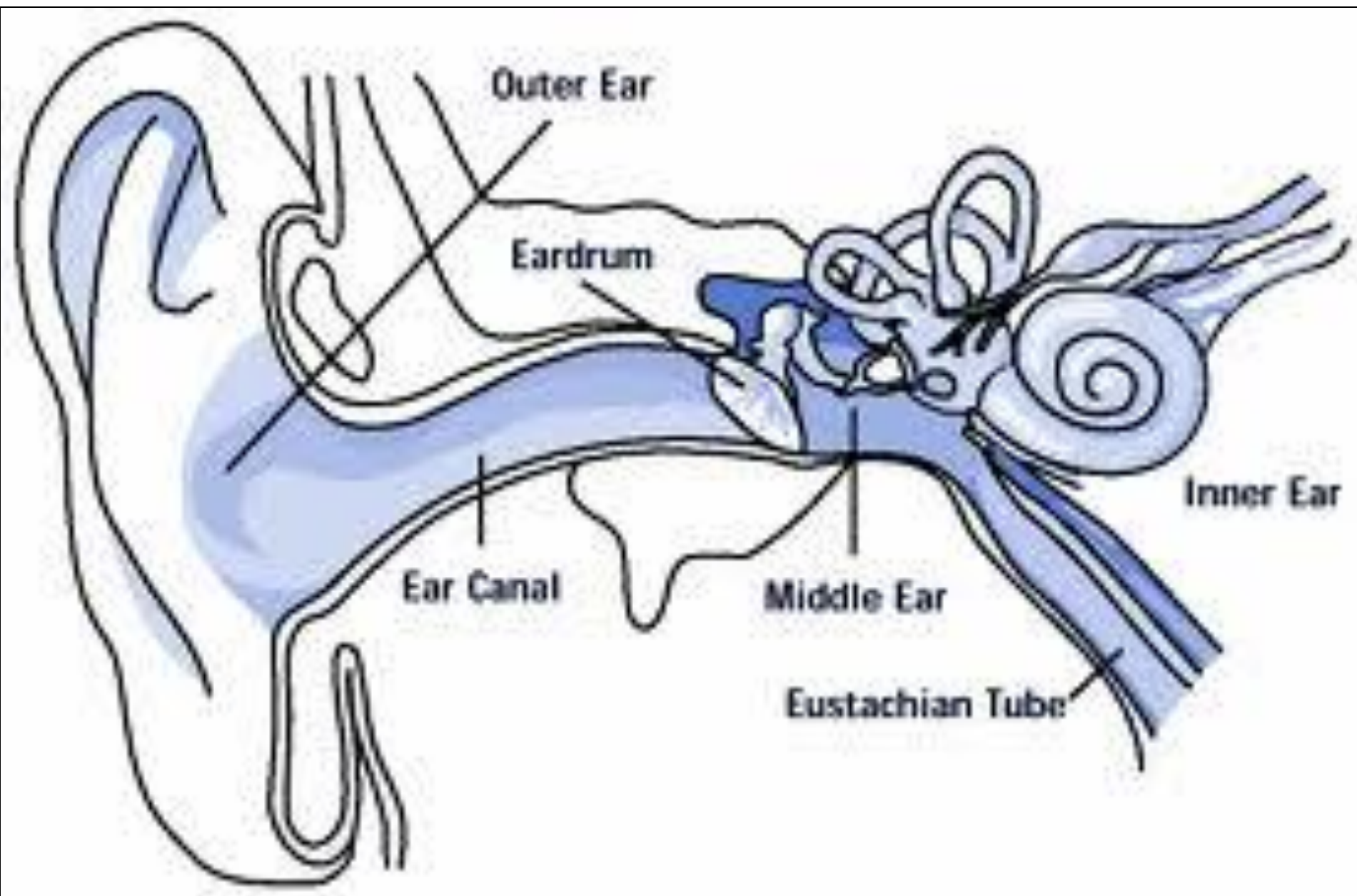
ossicles (bones of the middle ear)

cochlea

ear drum

eustachian tube

ear lobe



Outer Ear

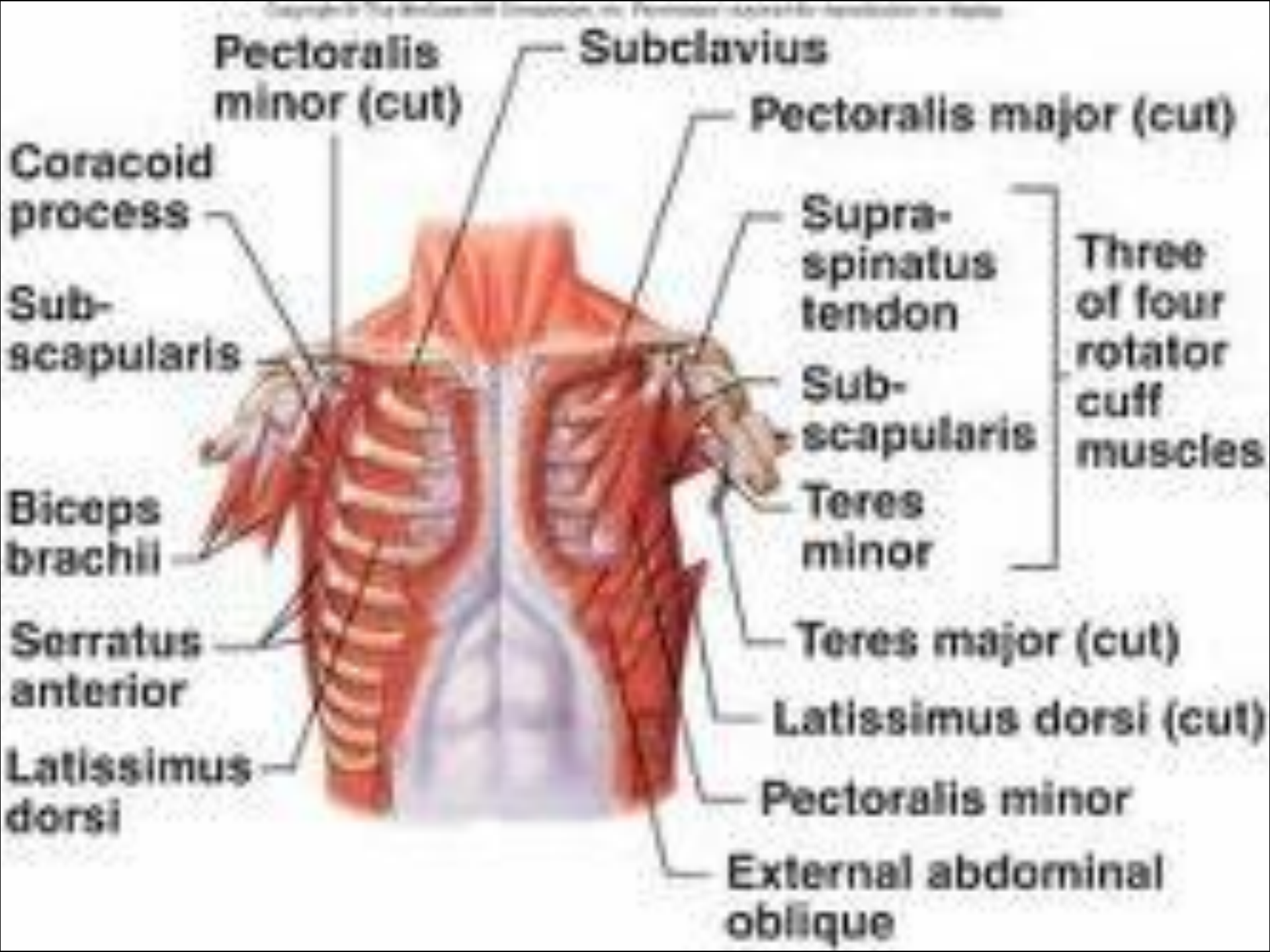
Eardrum

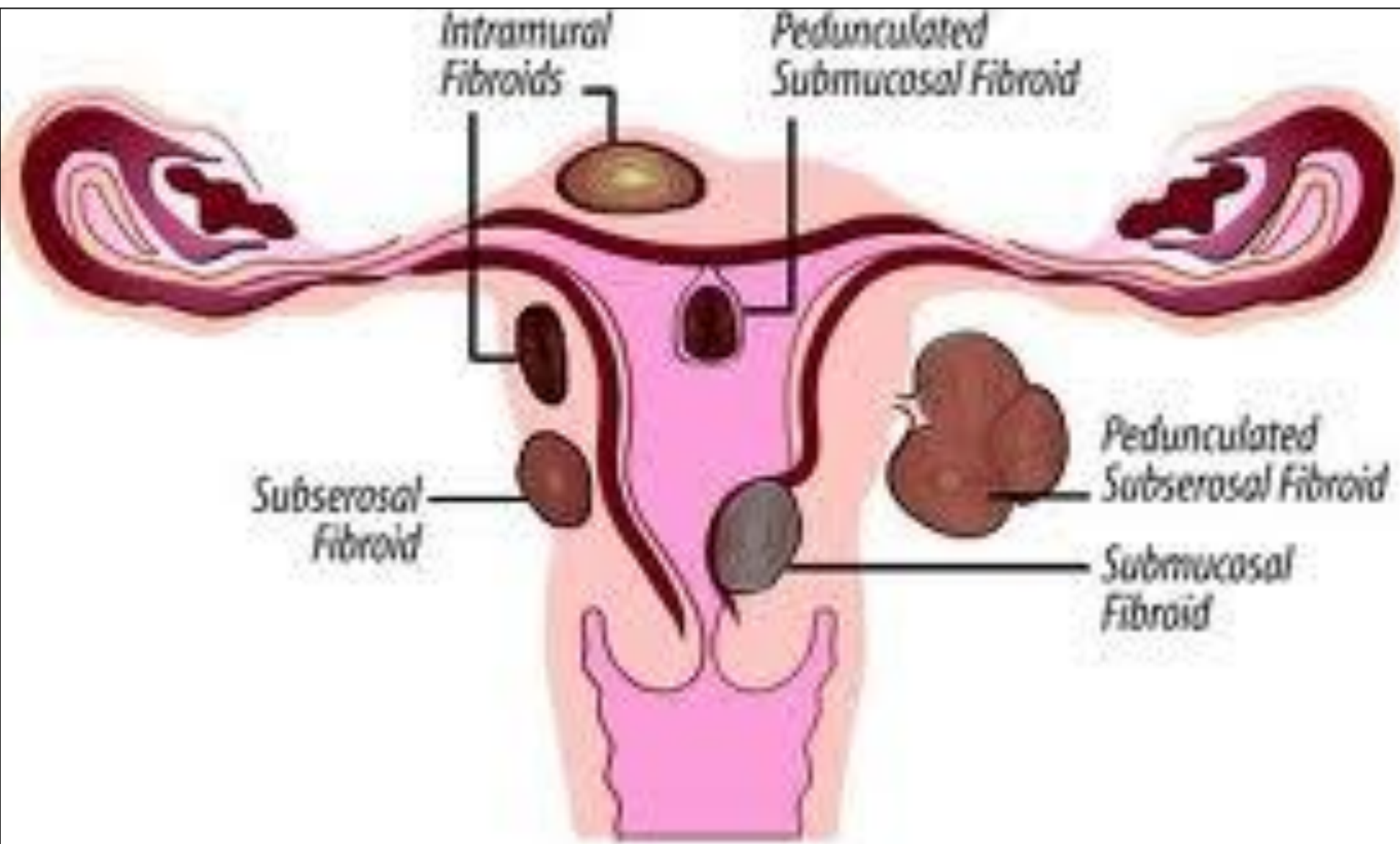
Ear Canal

Middle Ear

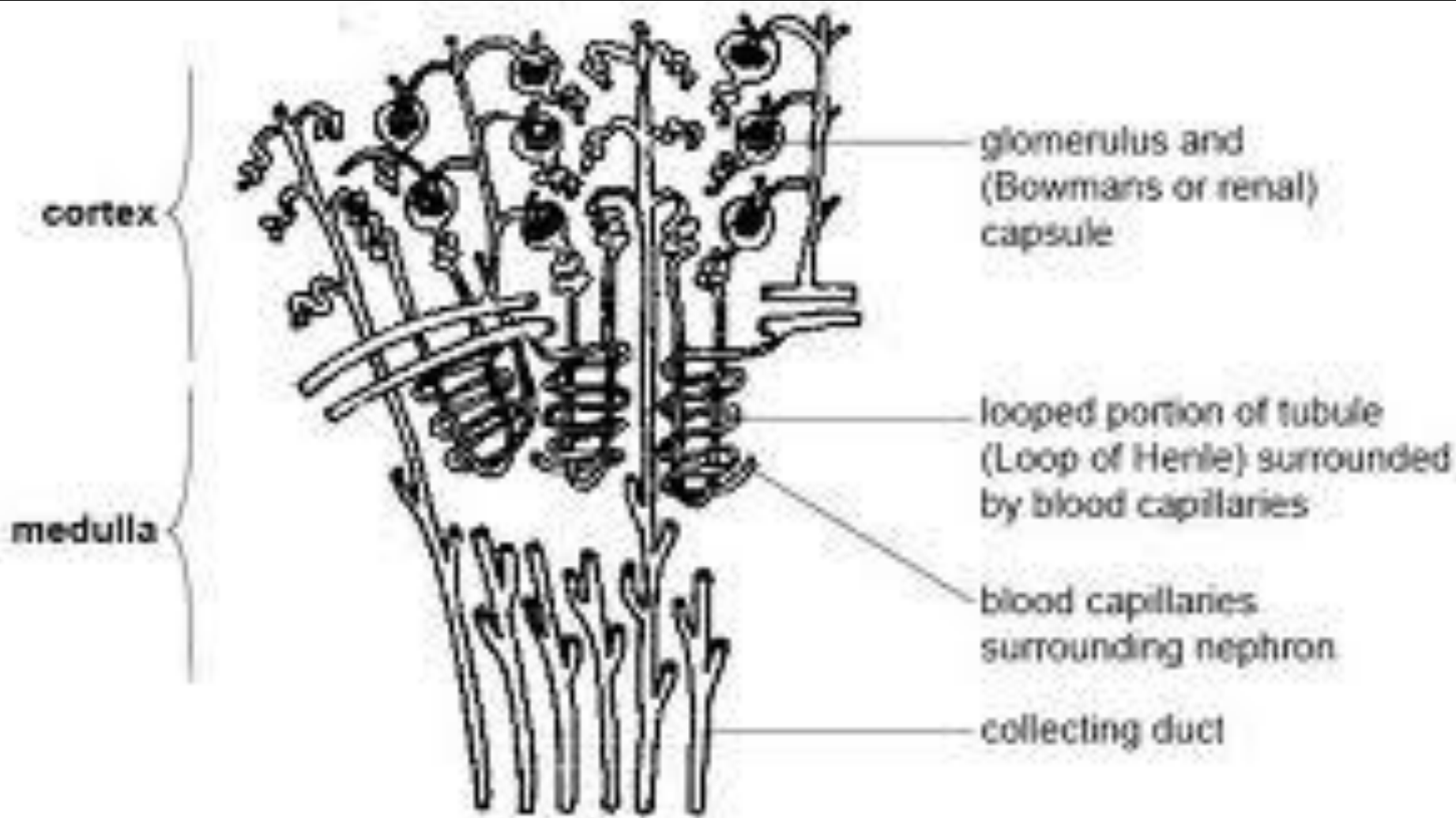
Eustachian Tube

Inner Ear





Fibroid Uterus



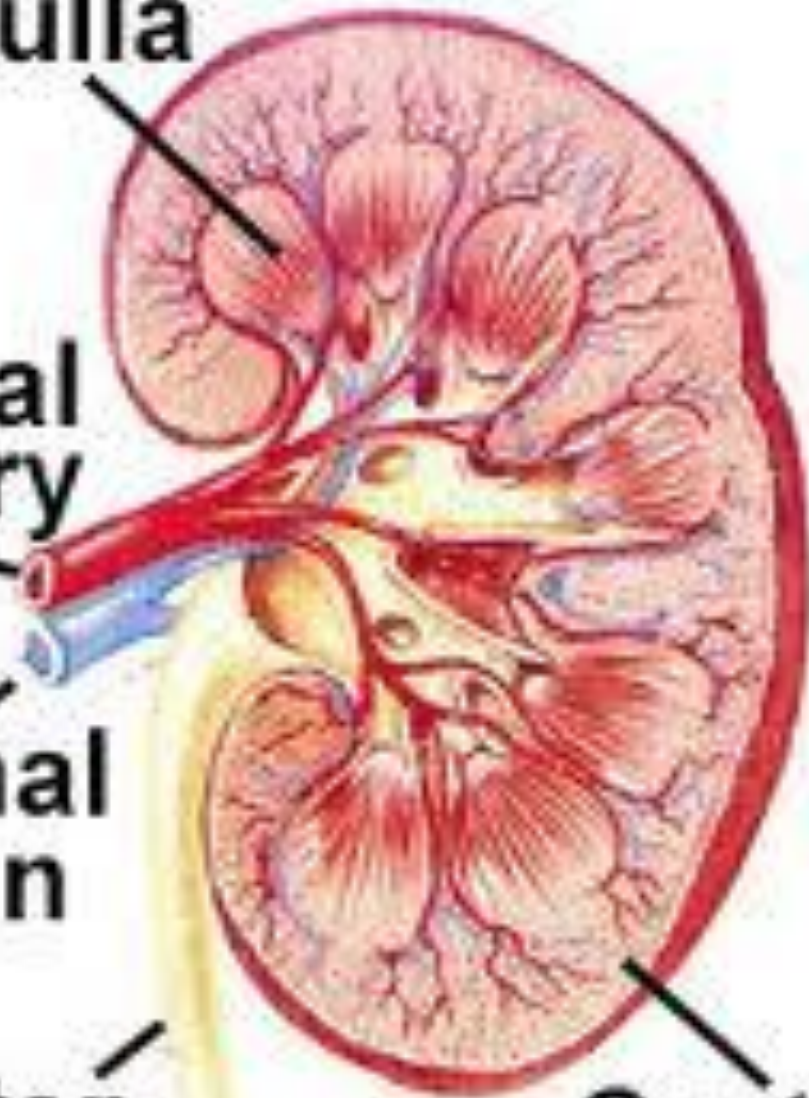
Medulla

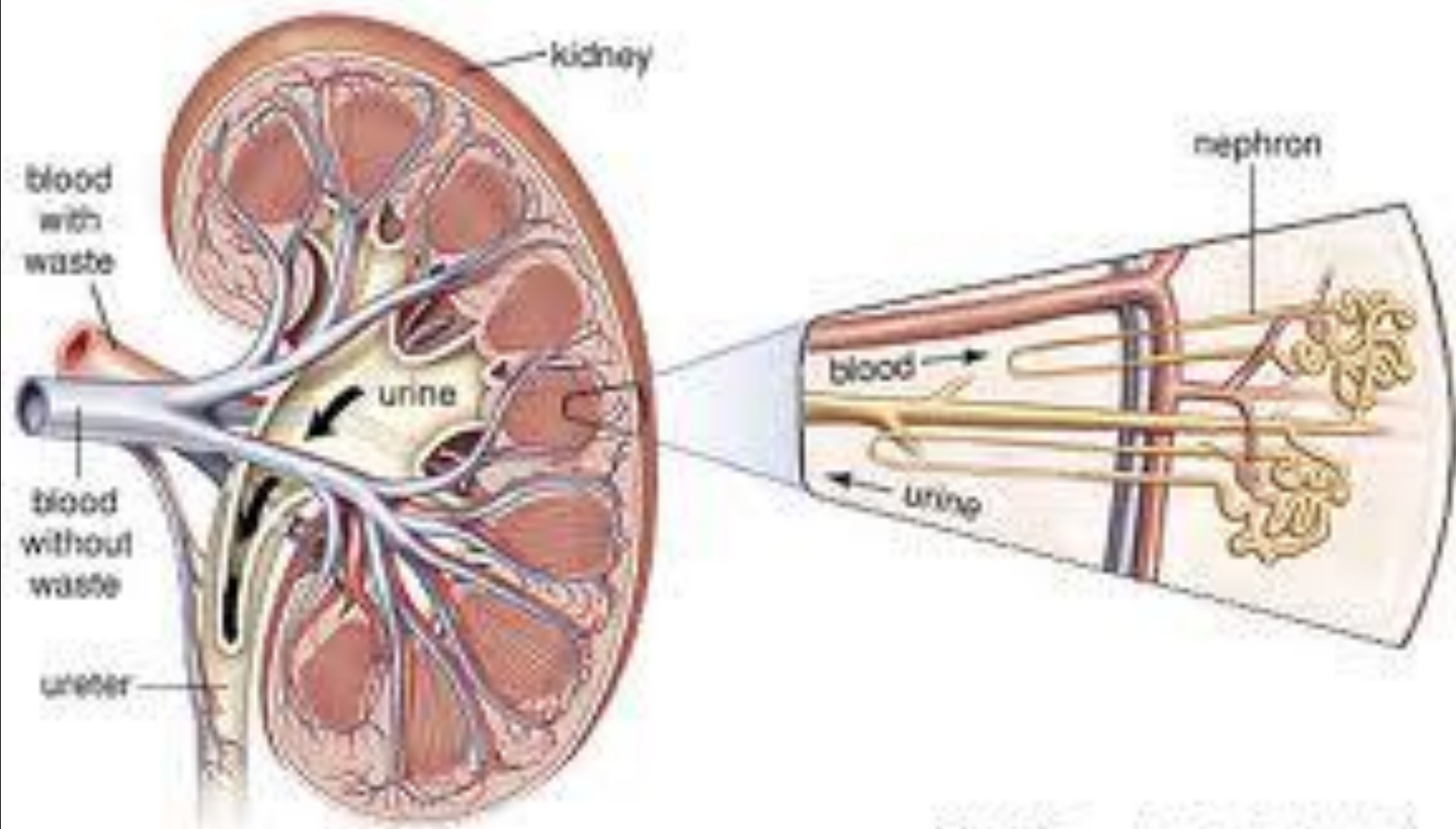
**Renal
Artery**

**Renal
Vein**

Ureter

Cortex

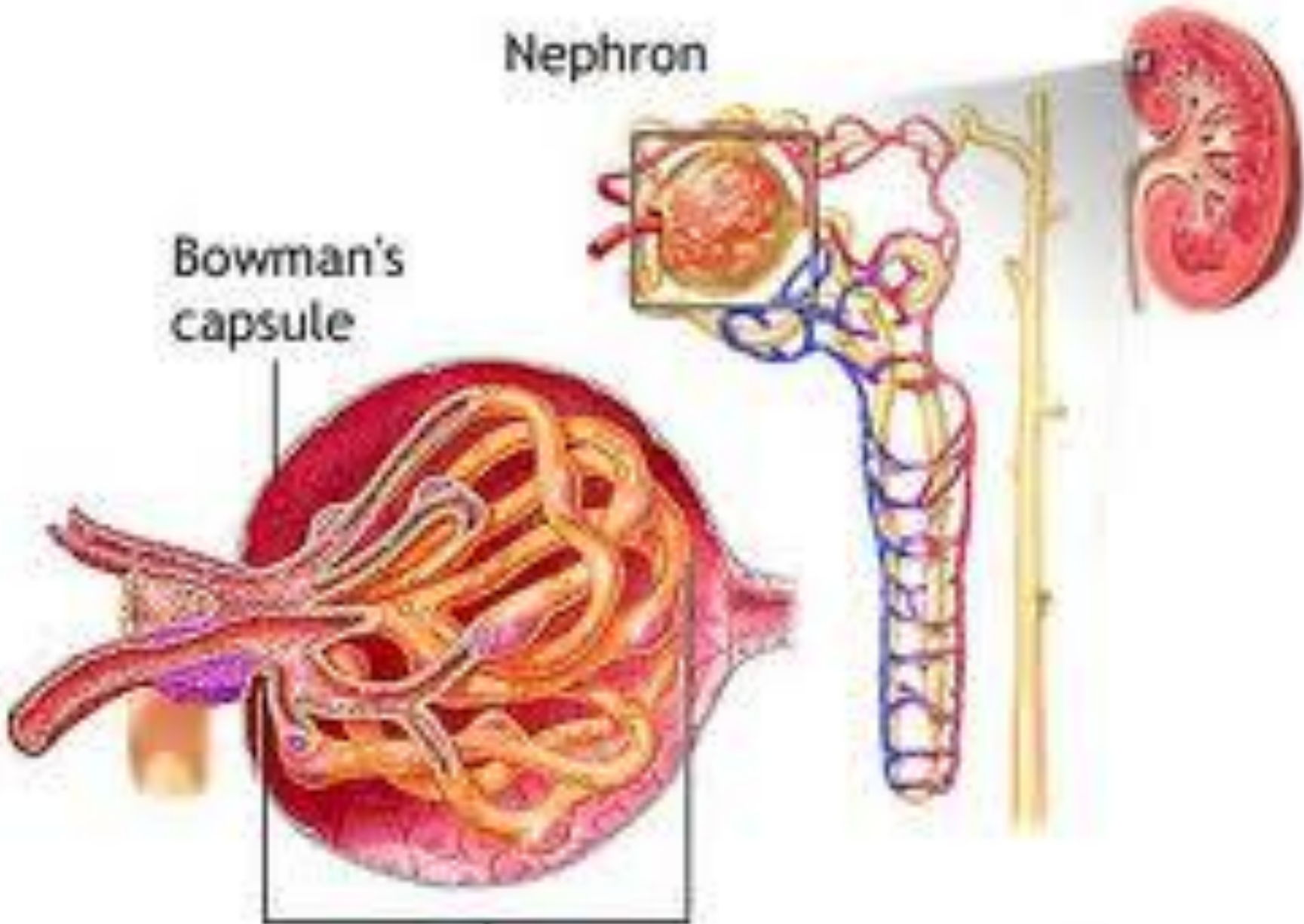




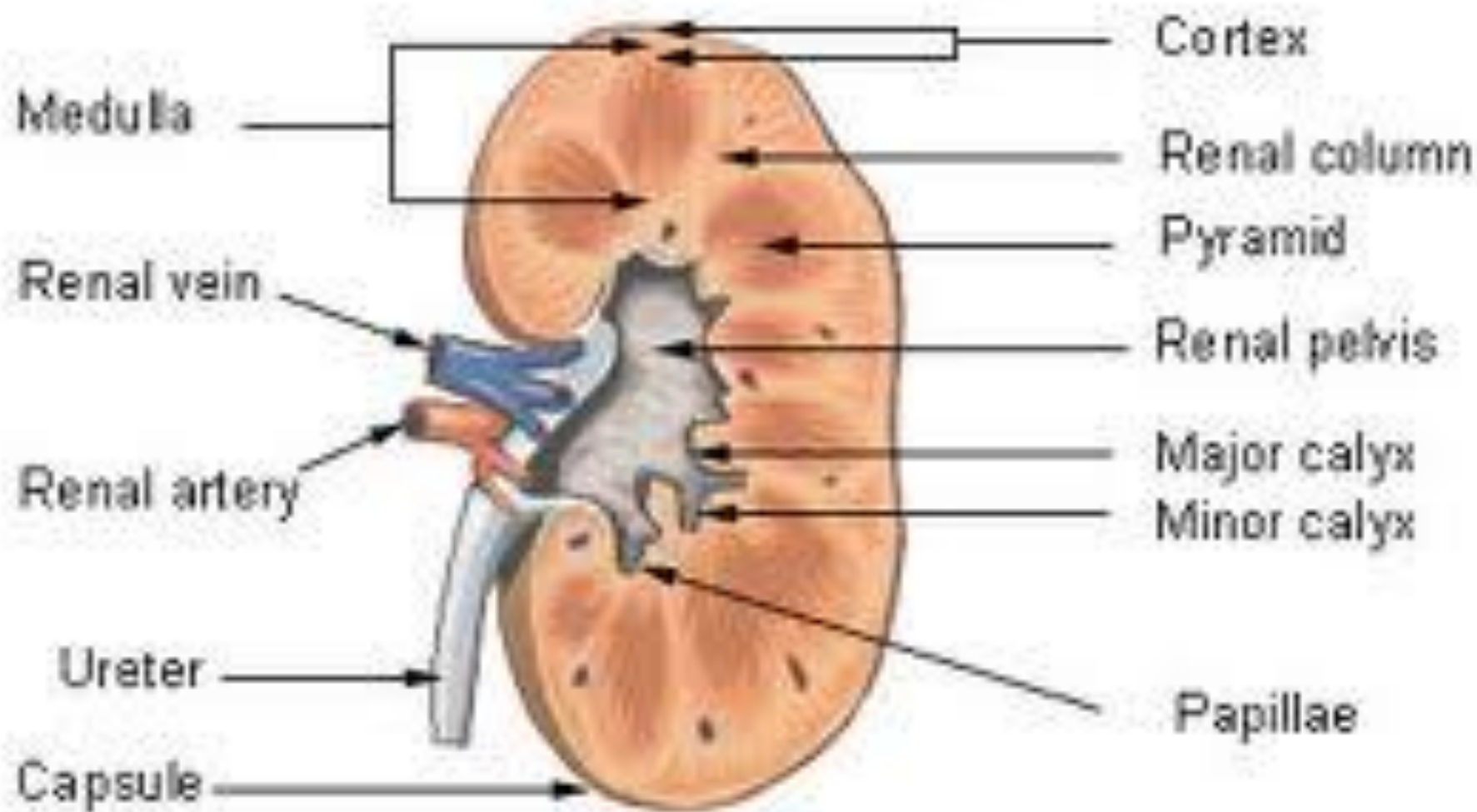
Nephron

Bowman's capsule

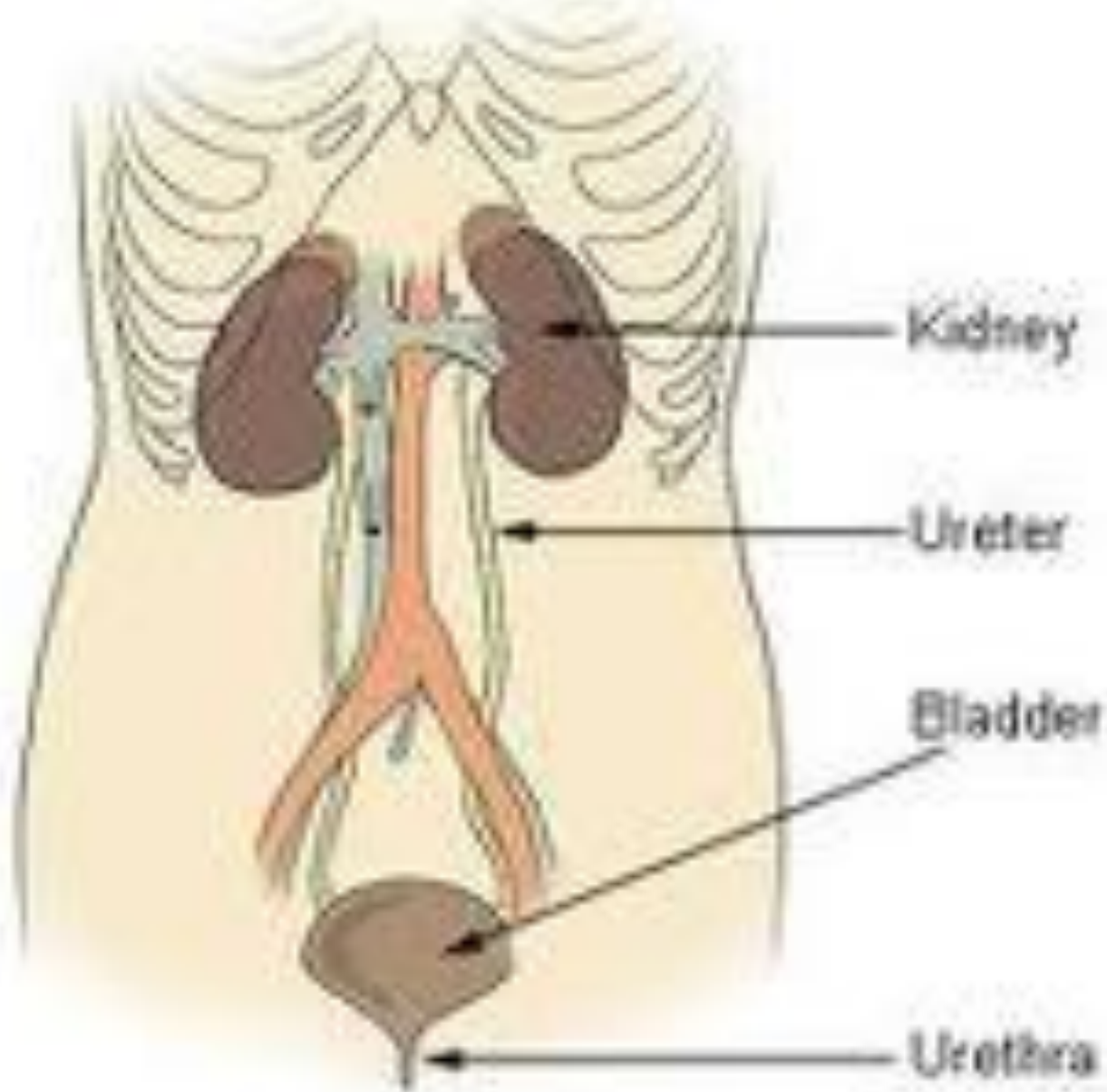
Glomerulus

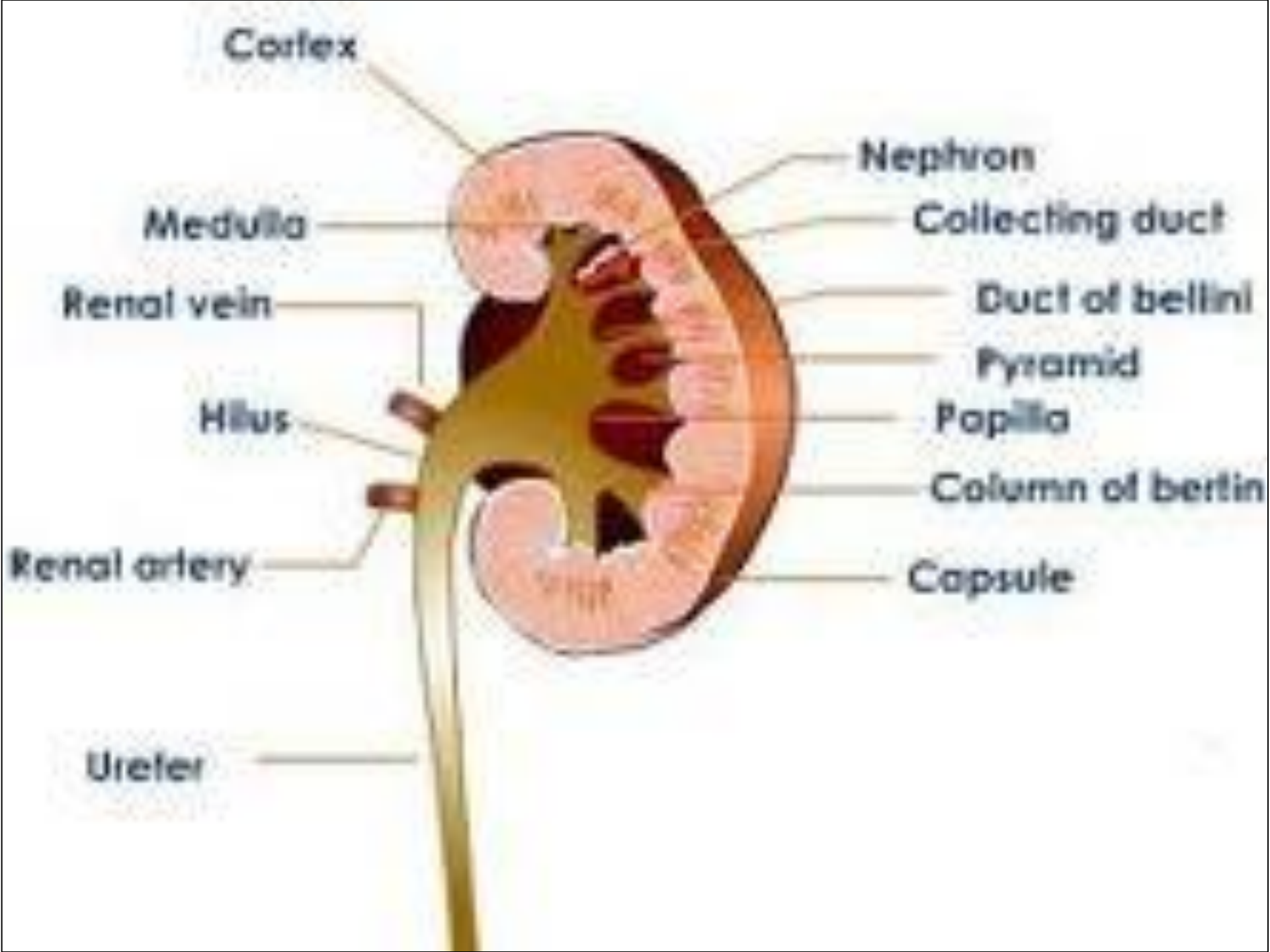


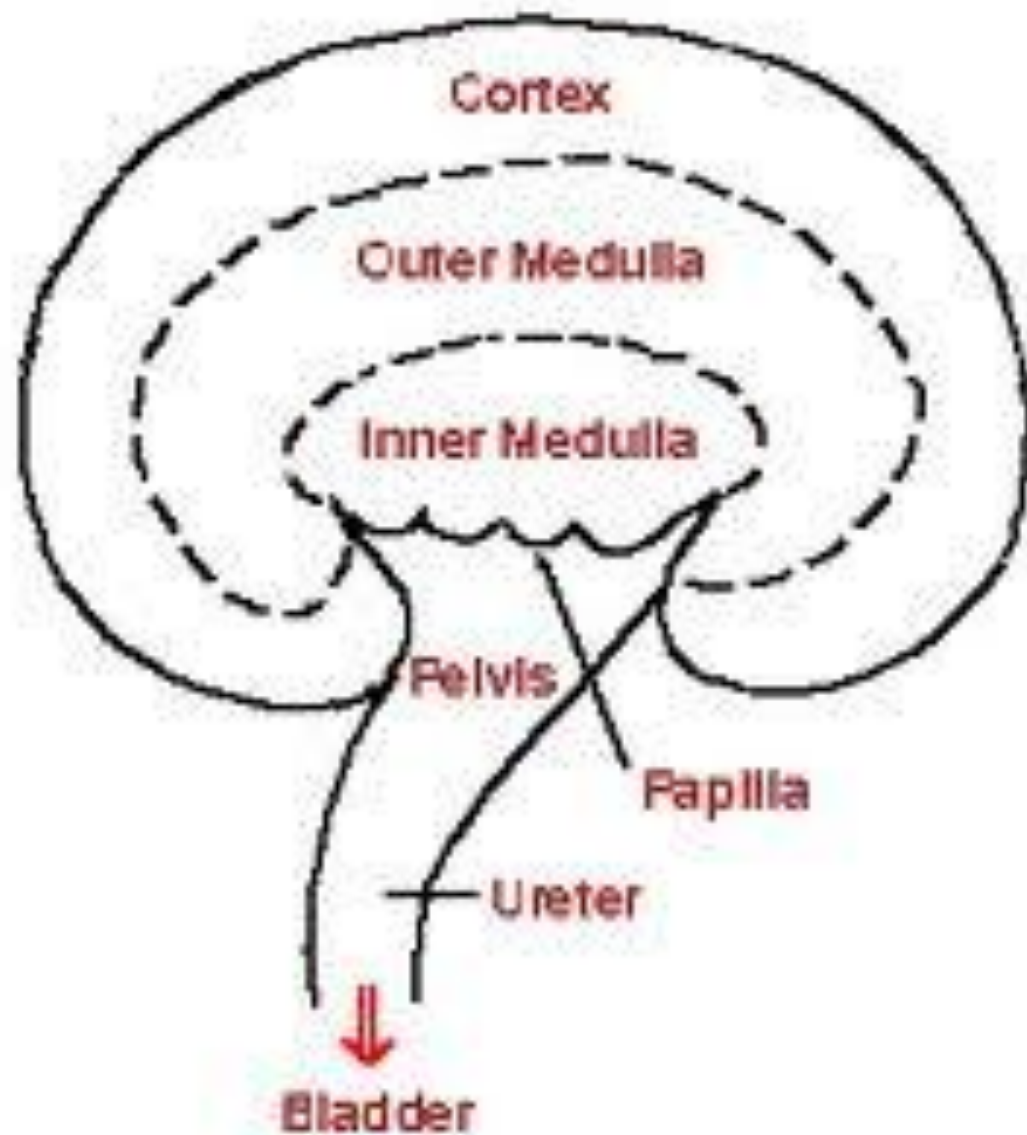
Frontal section through the Kidney

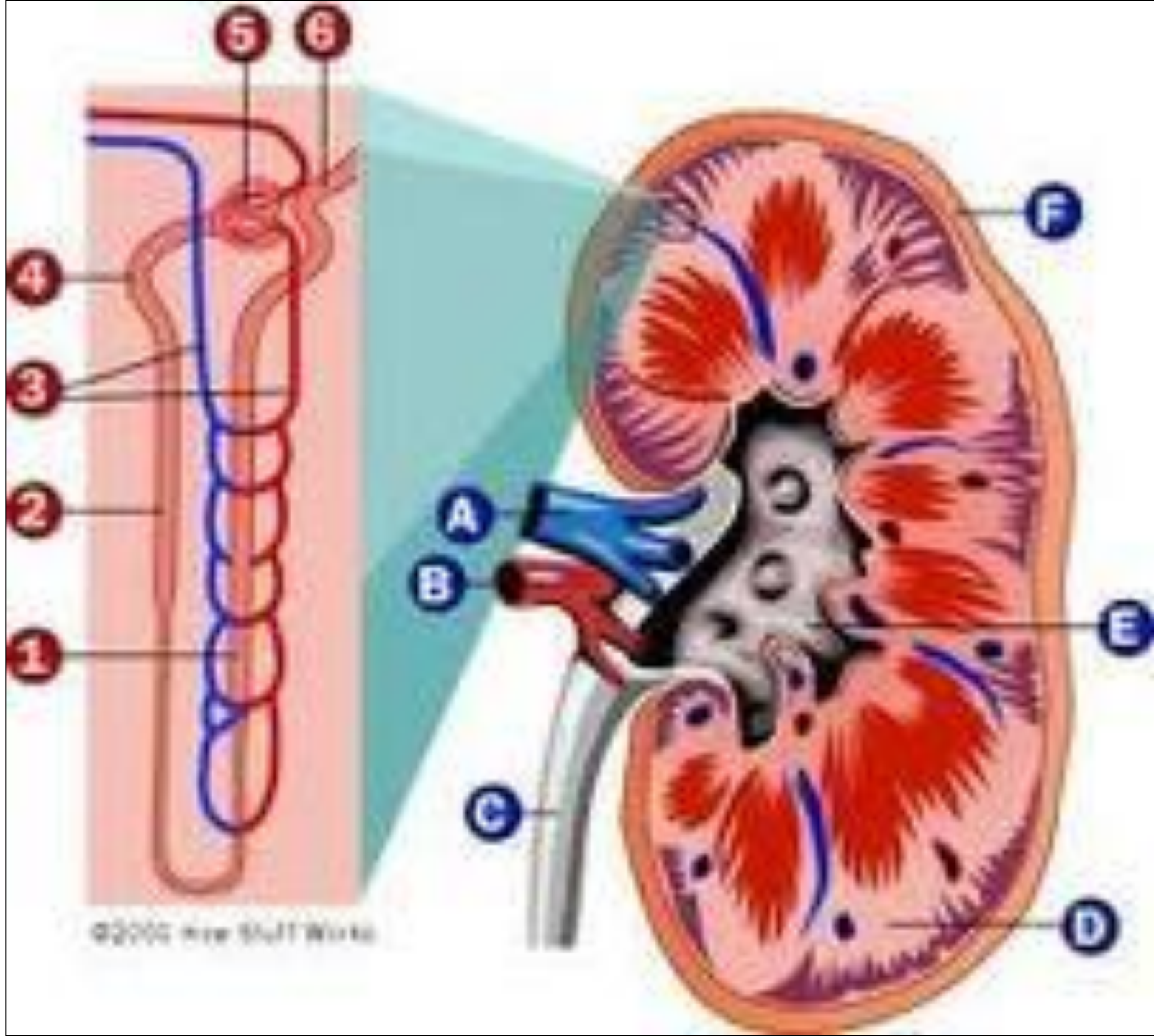


Components of the Urinary System

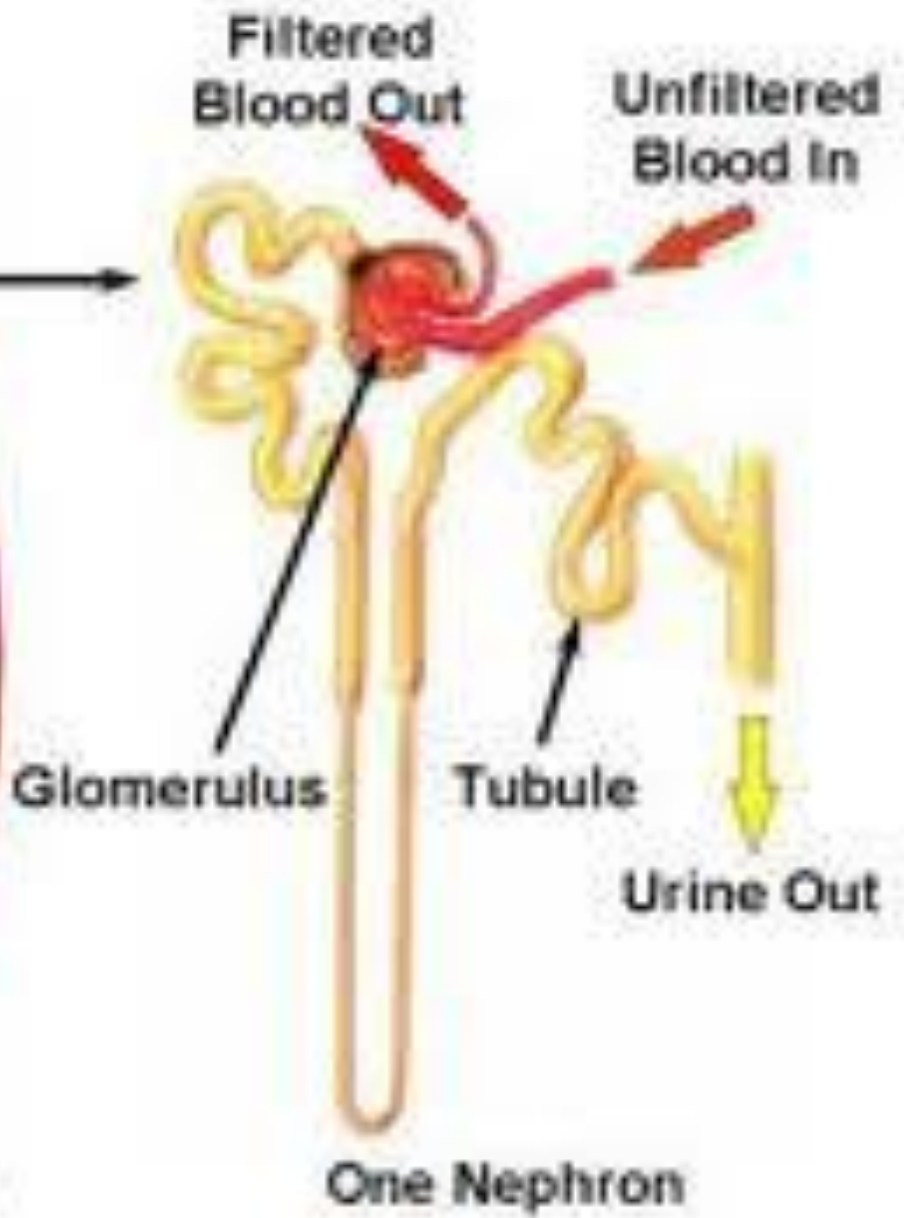
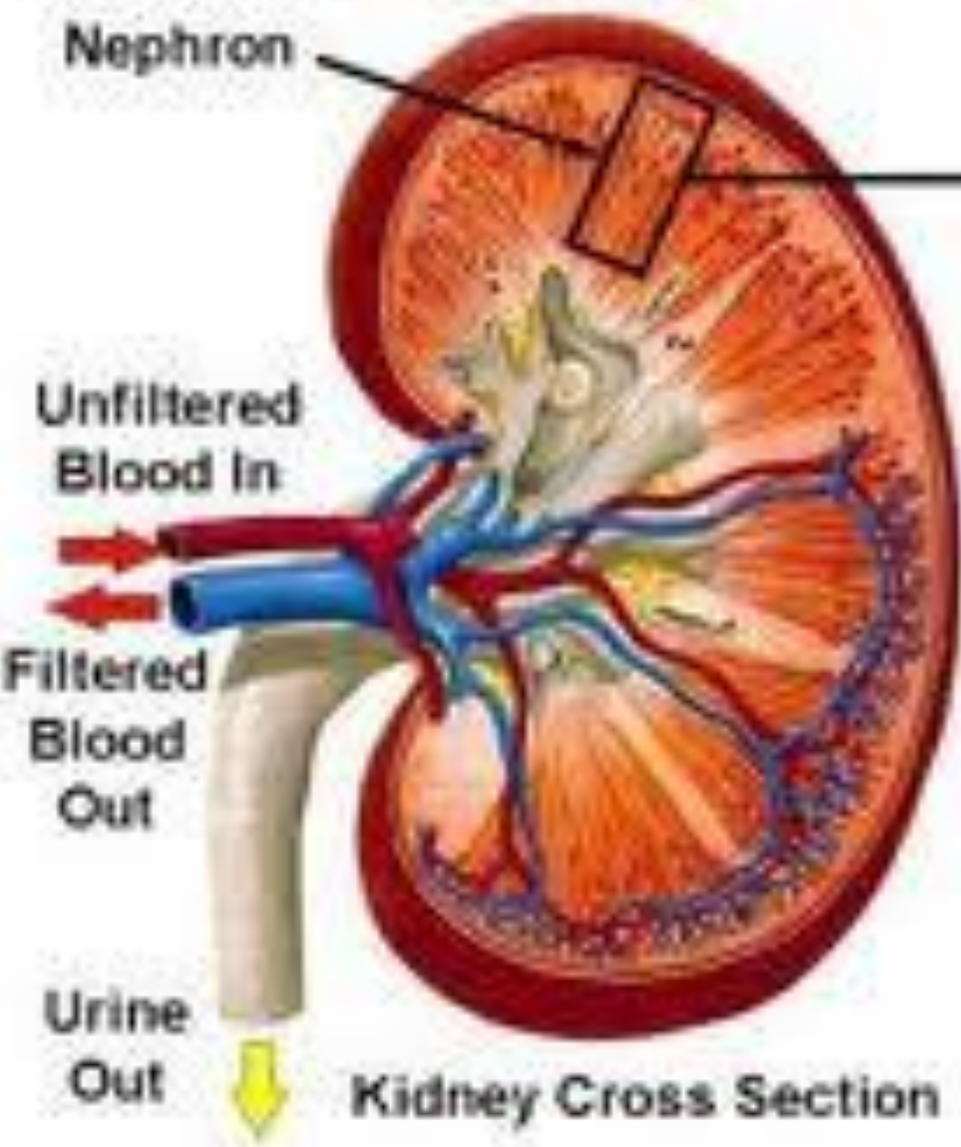

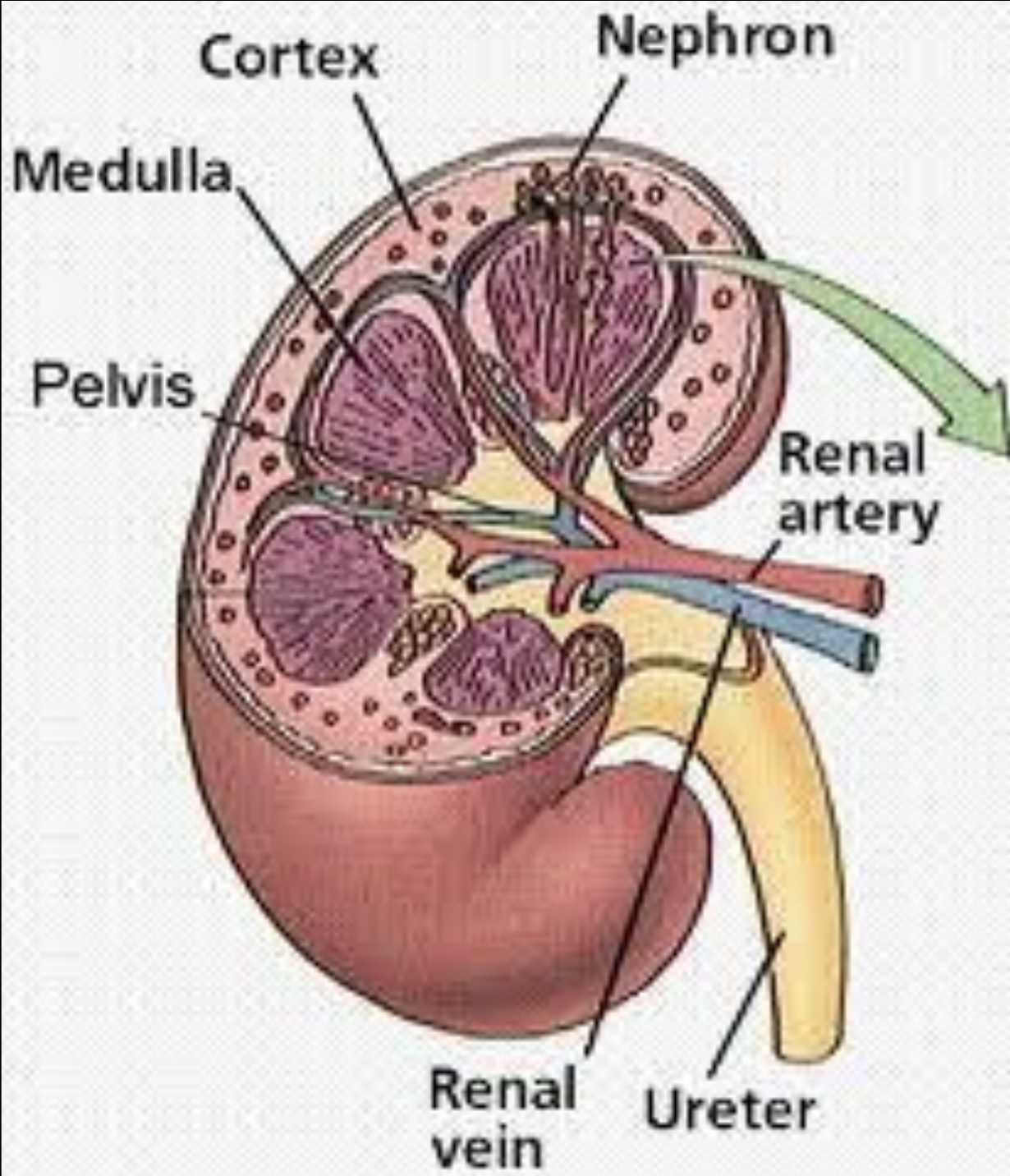


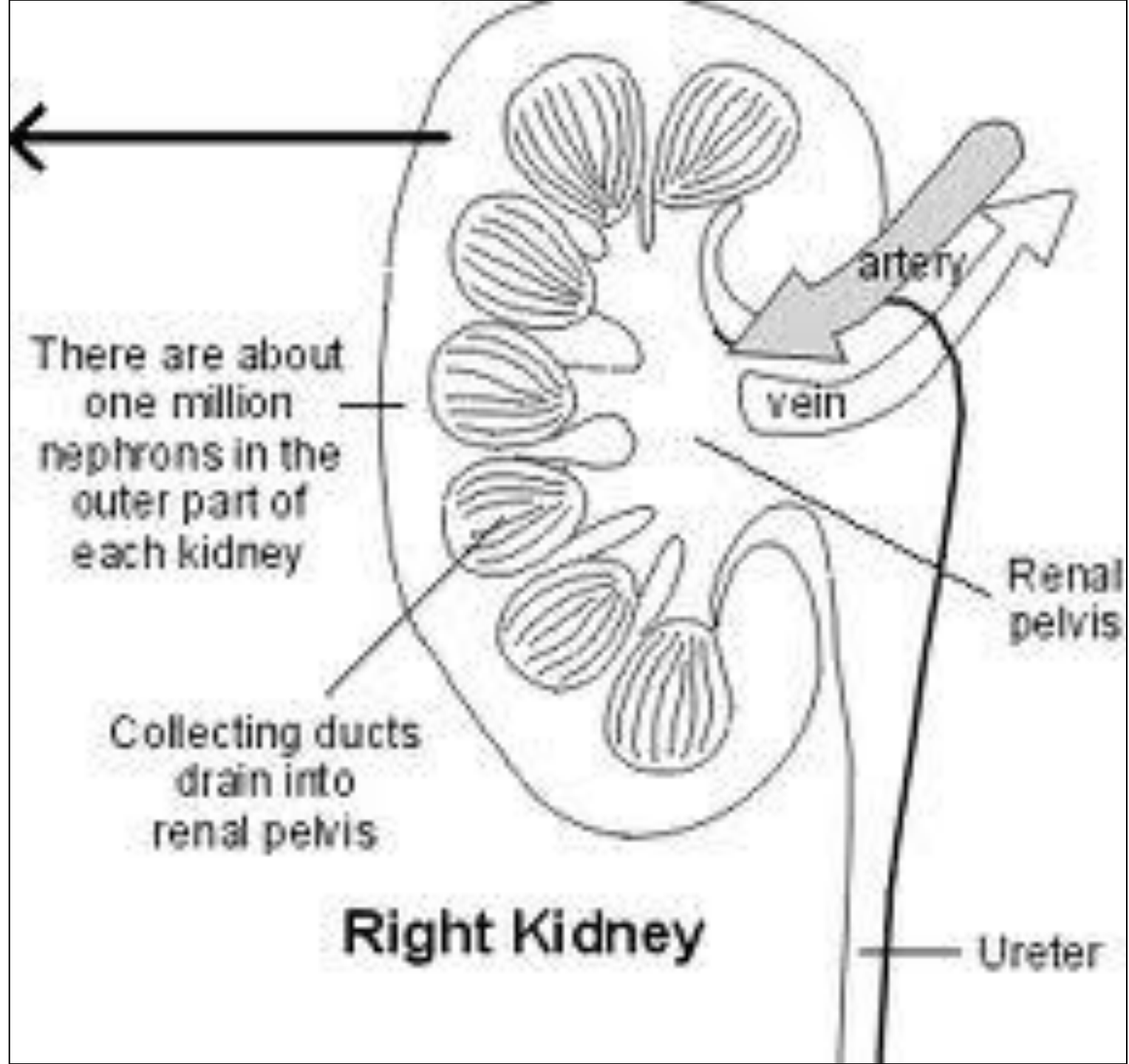


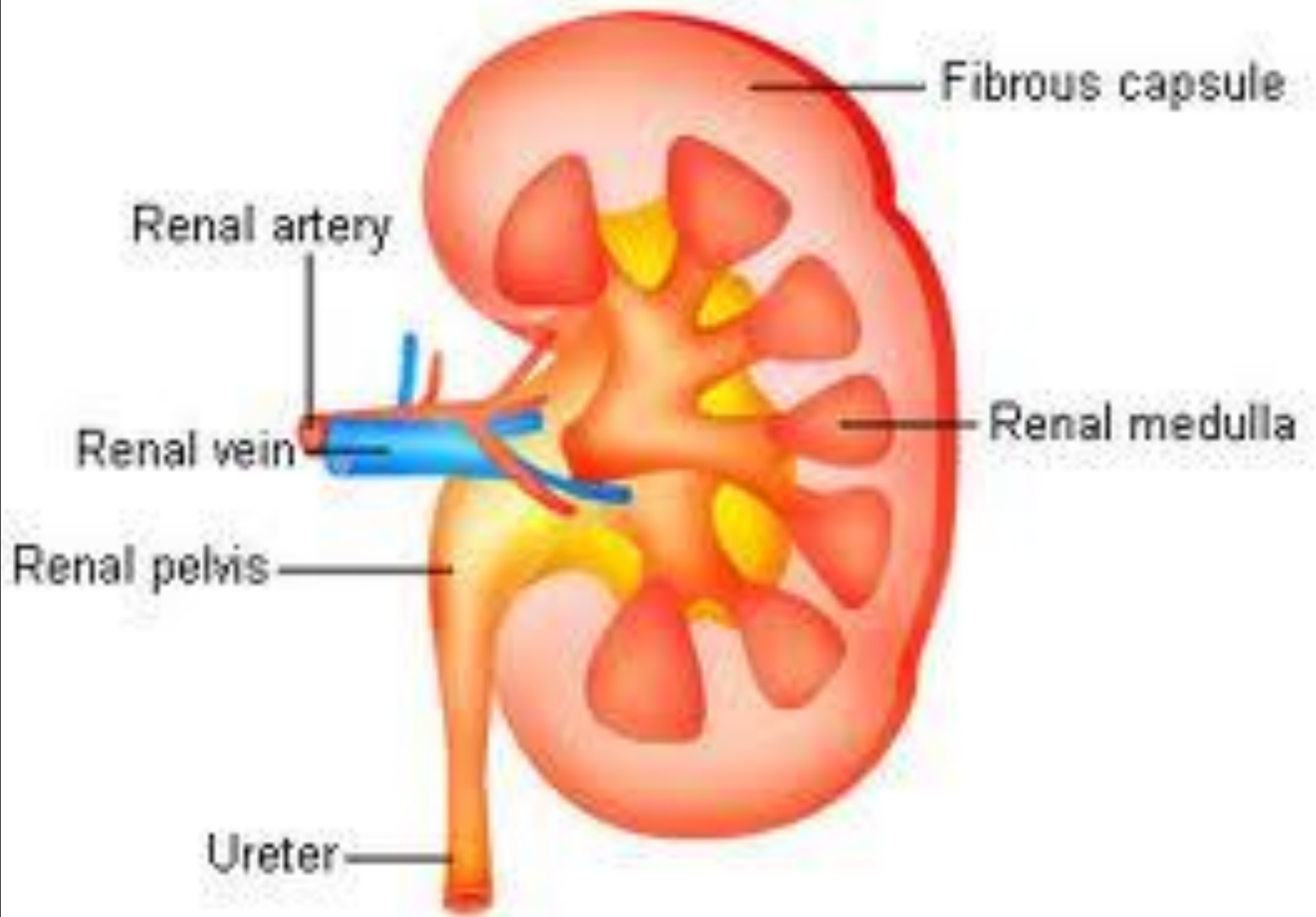


Parts of the Nephron

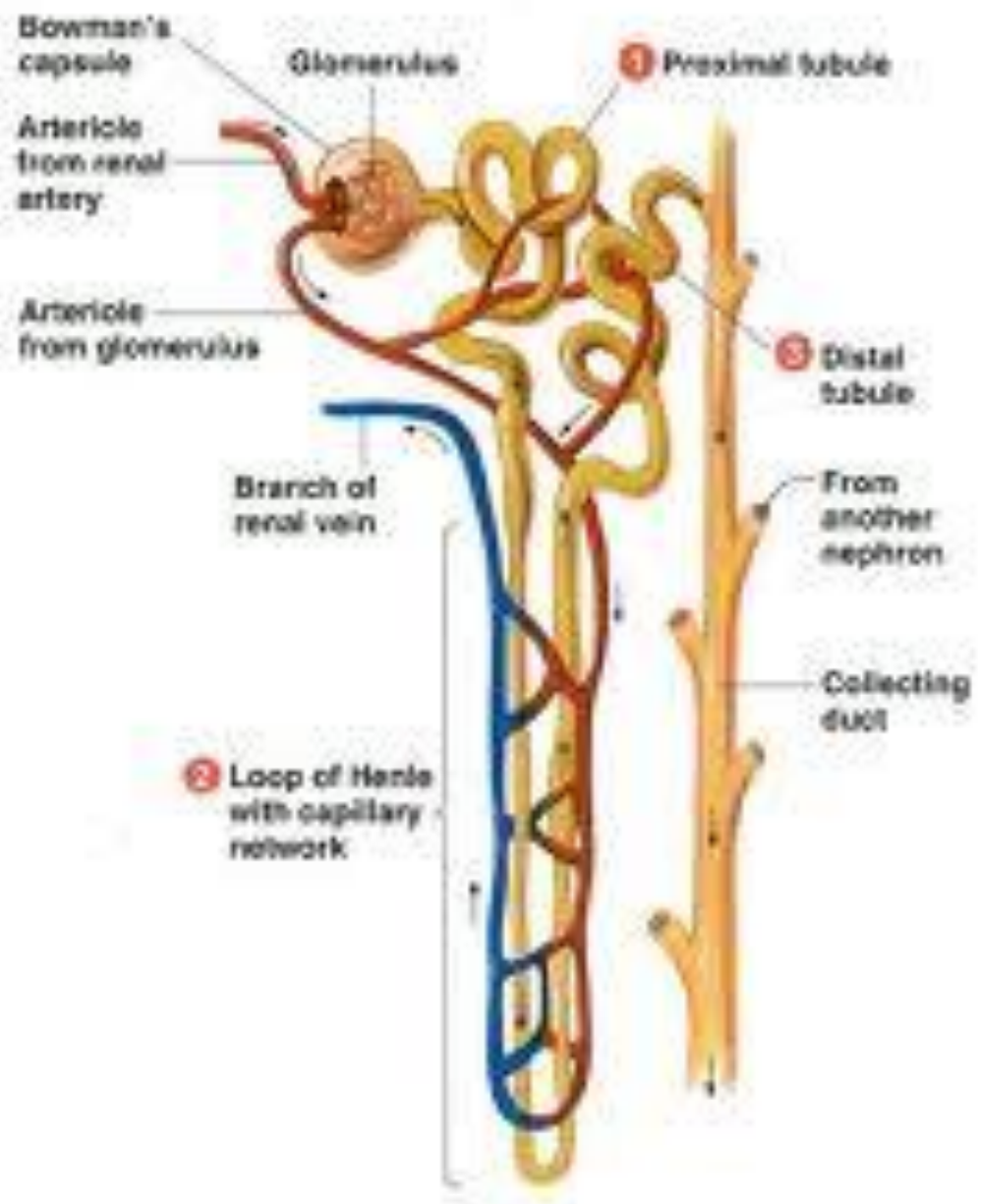


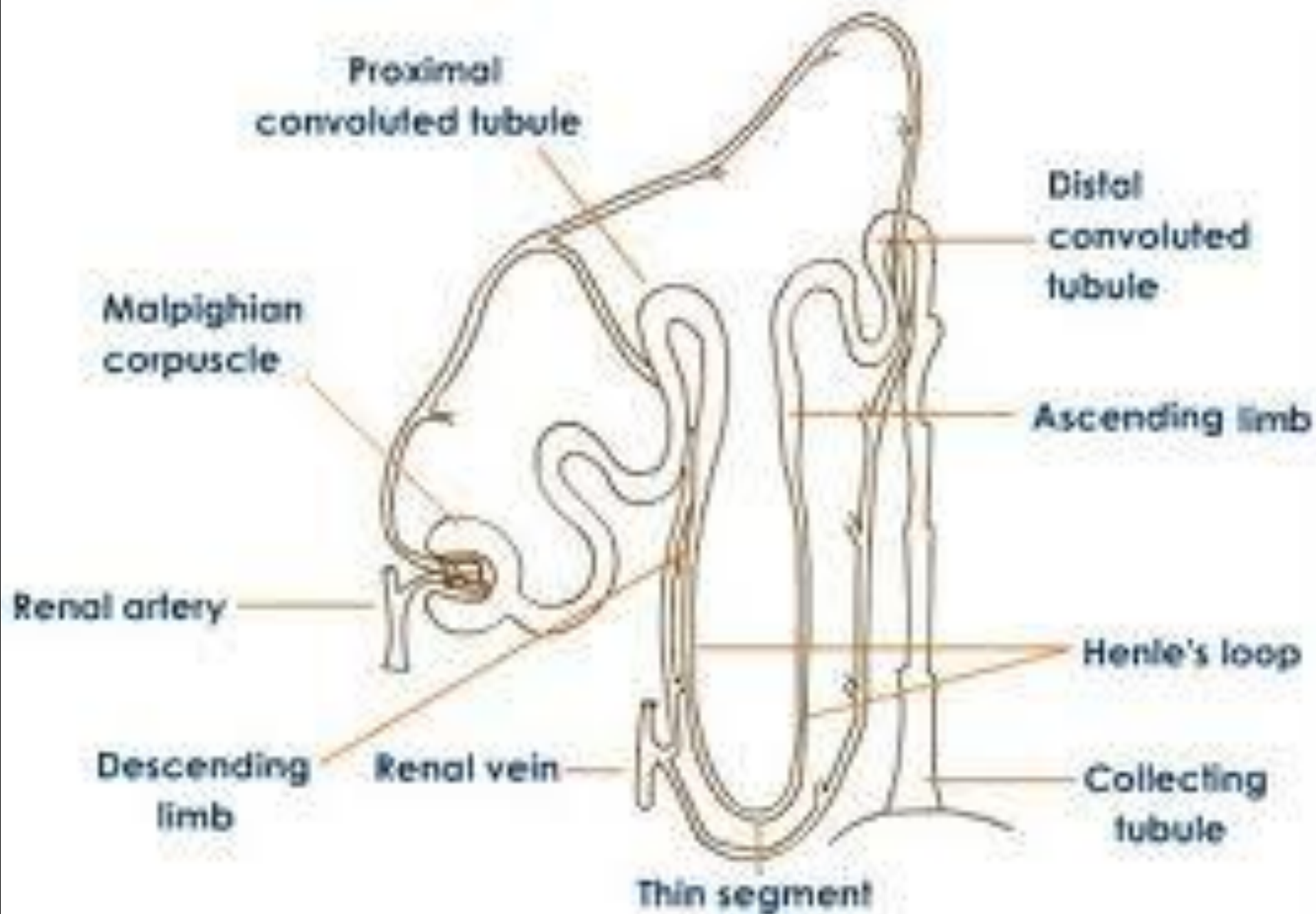




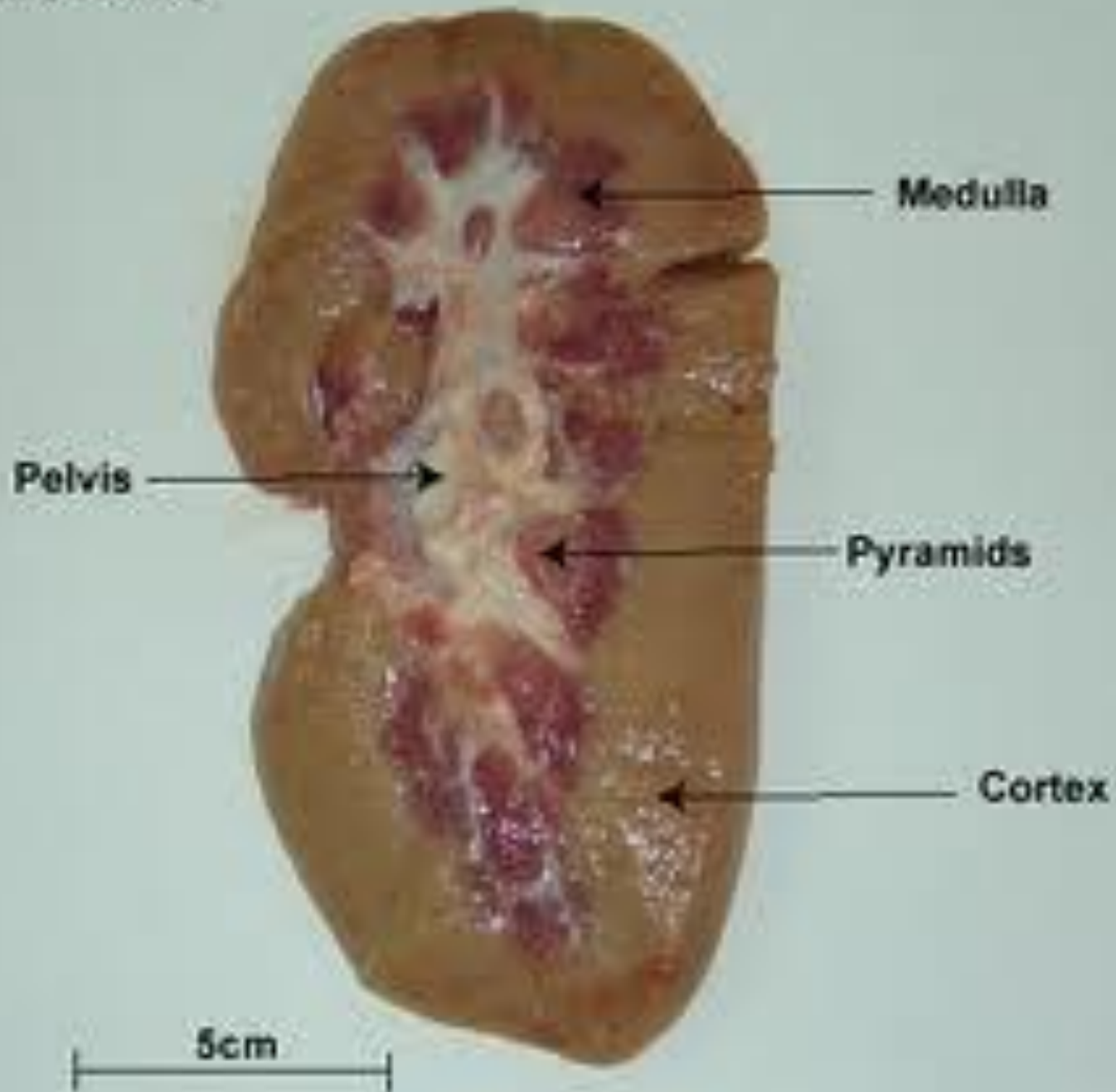


Detailed structure of a nephron



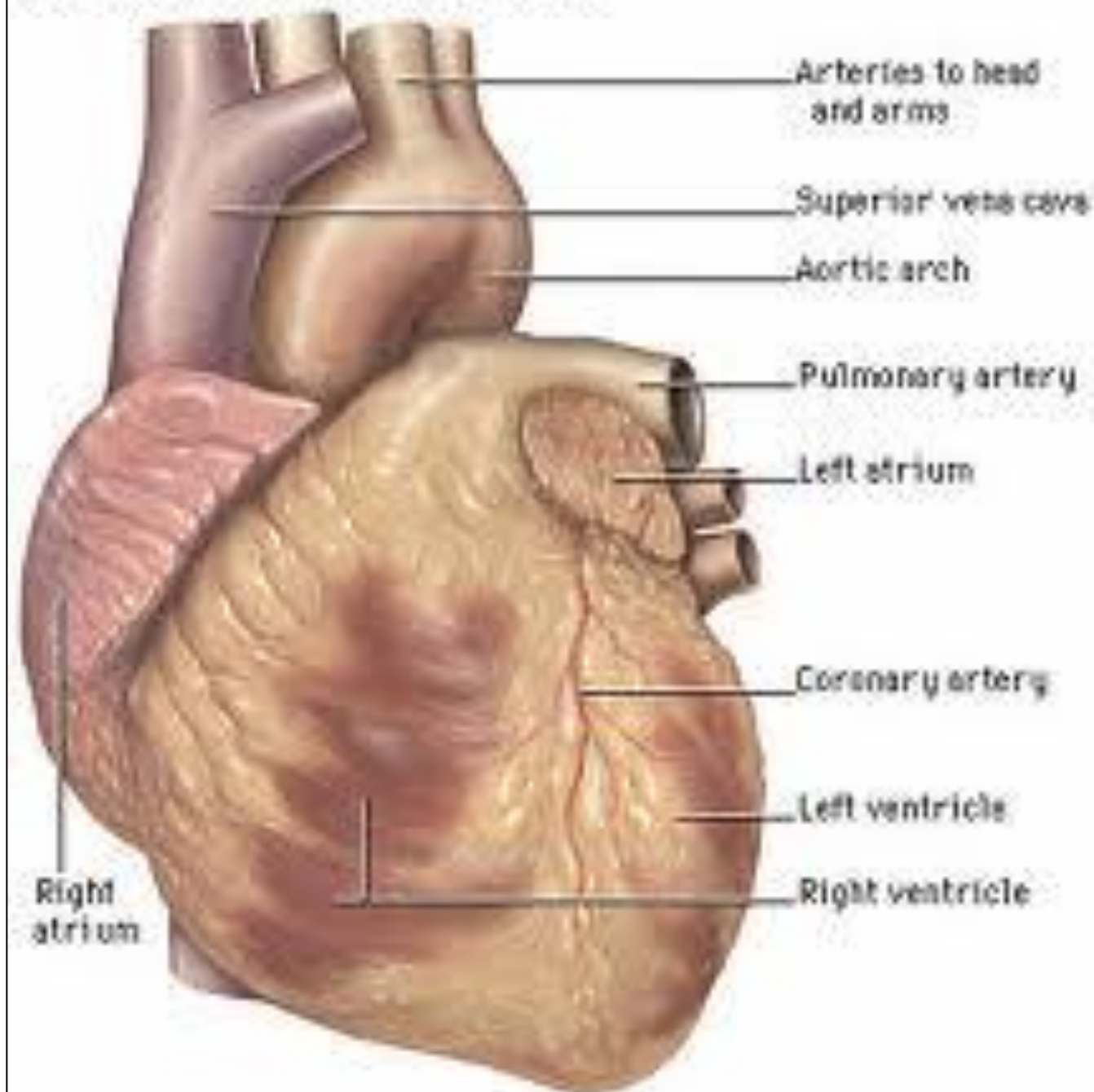


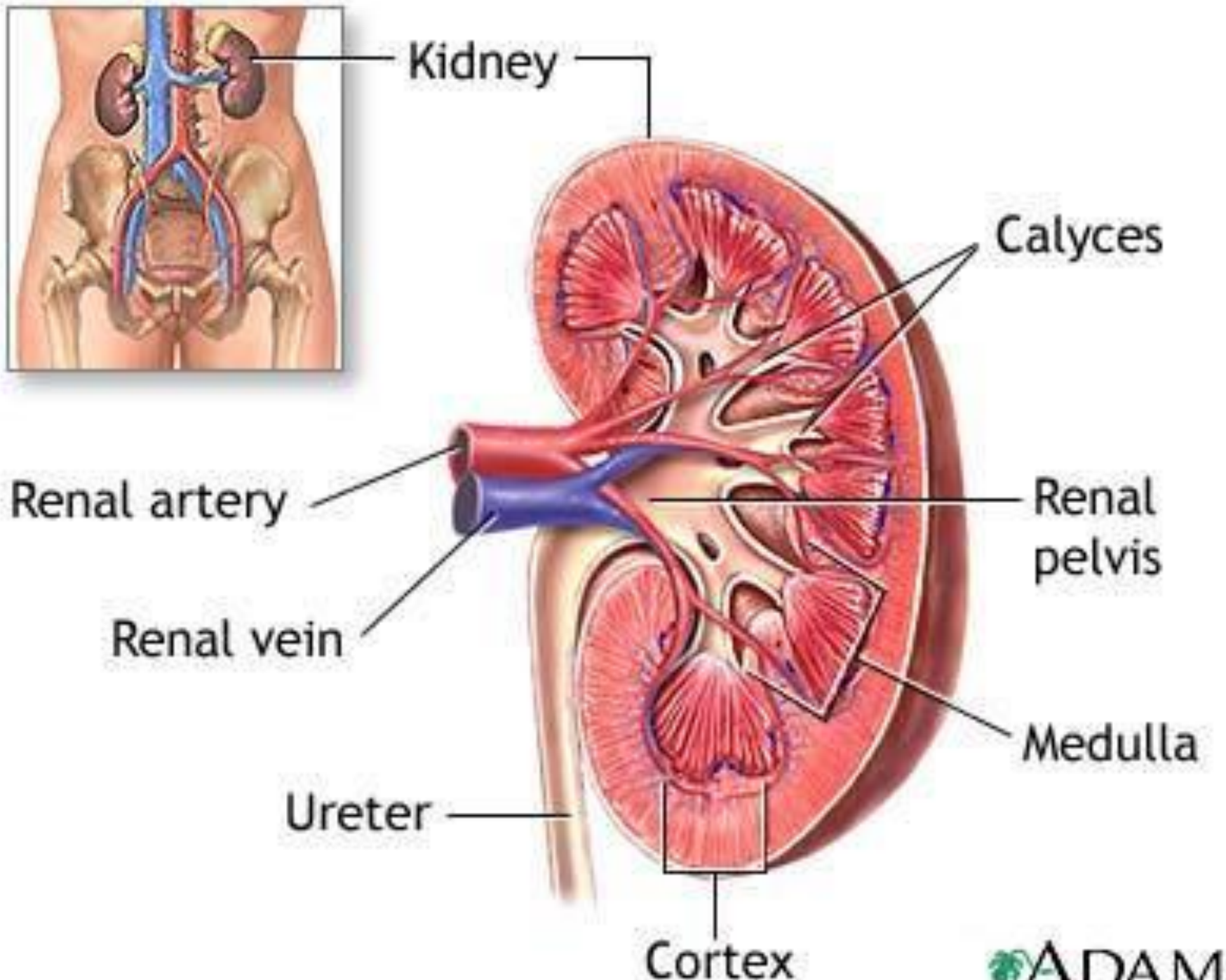
Pig Kidney

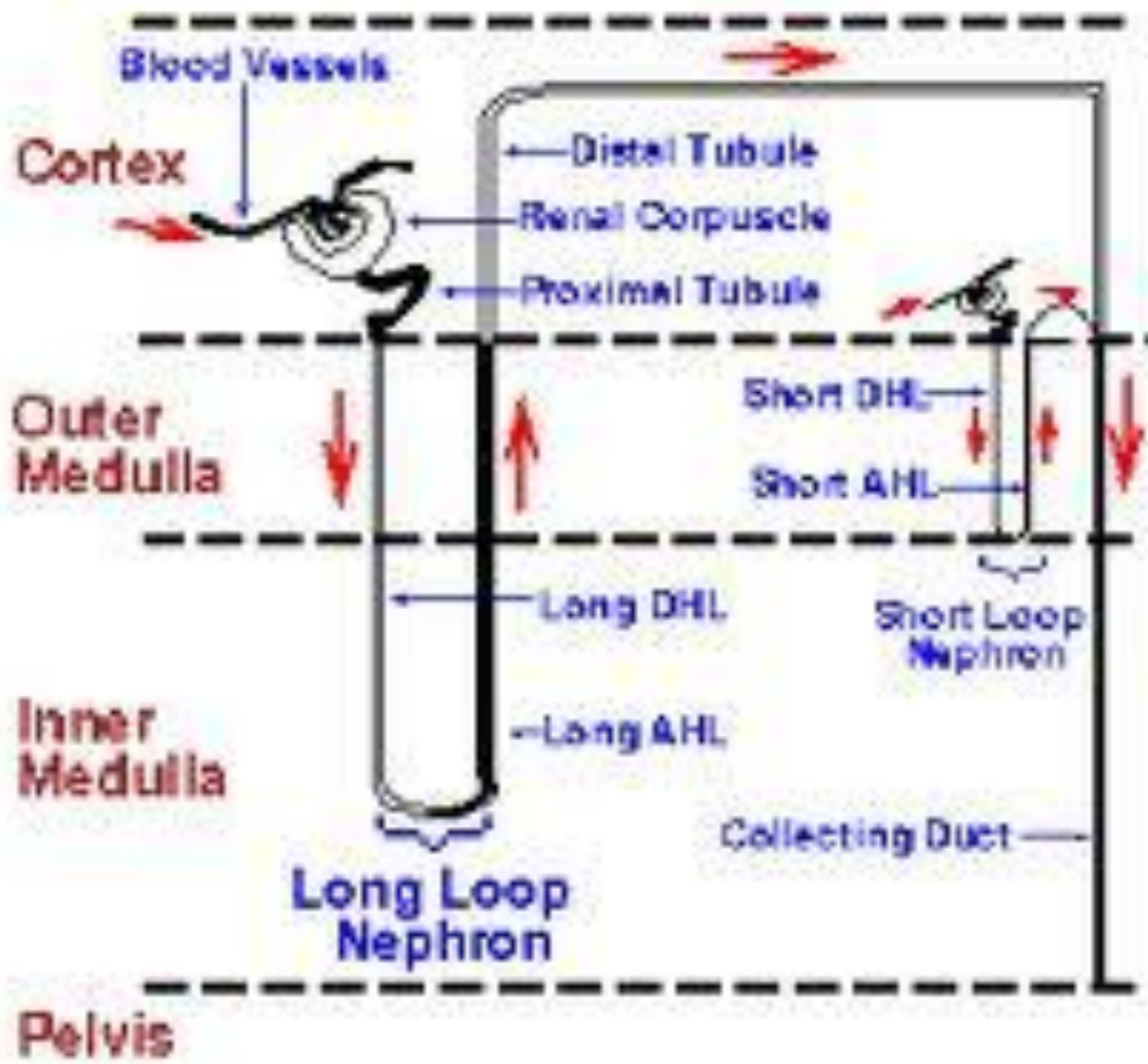




Exterior structures of the heart







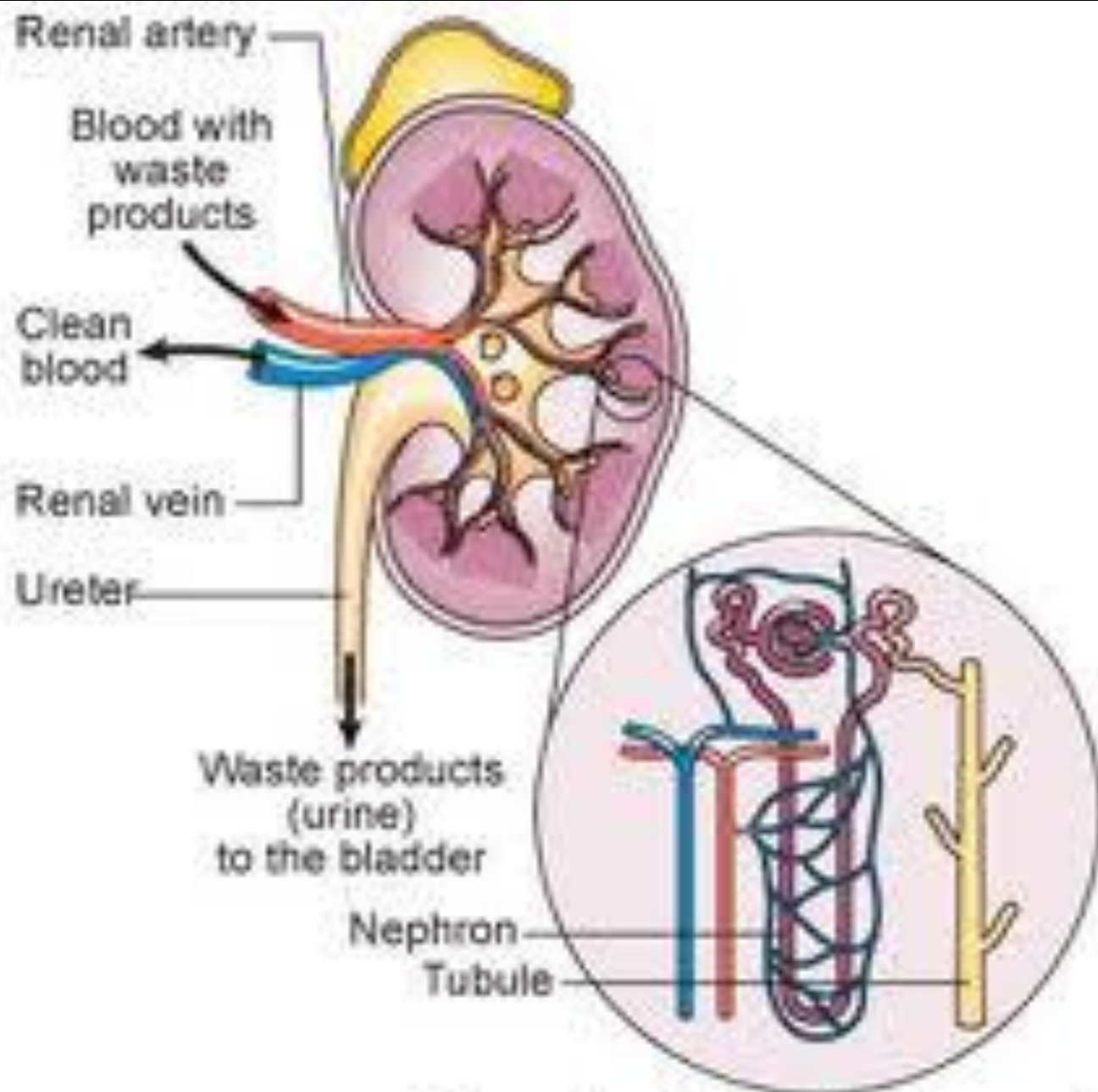
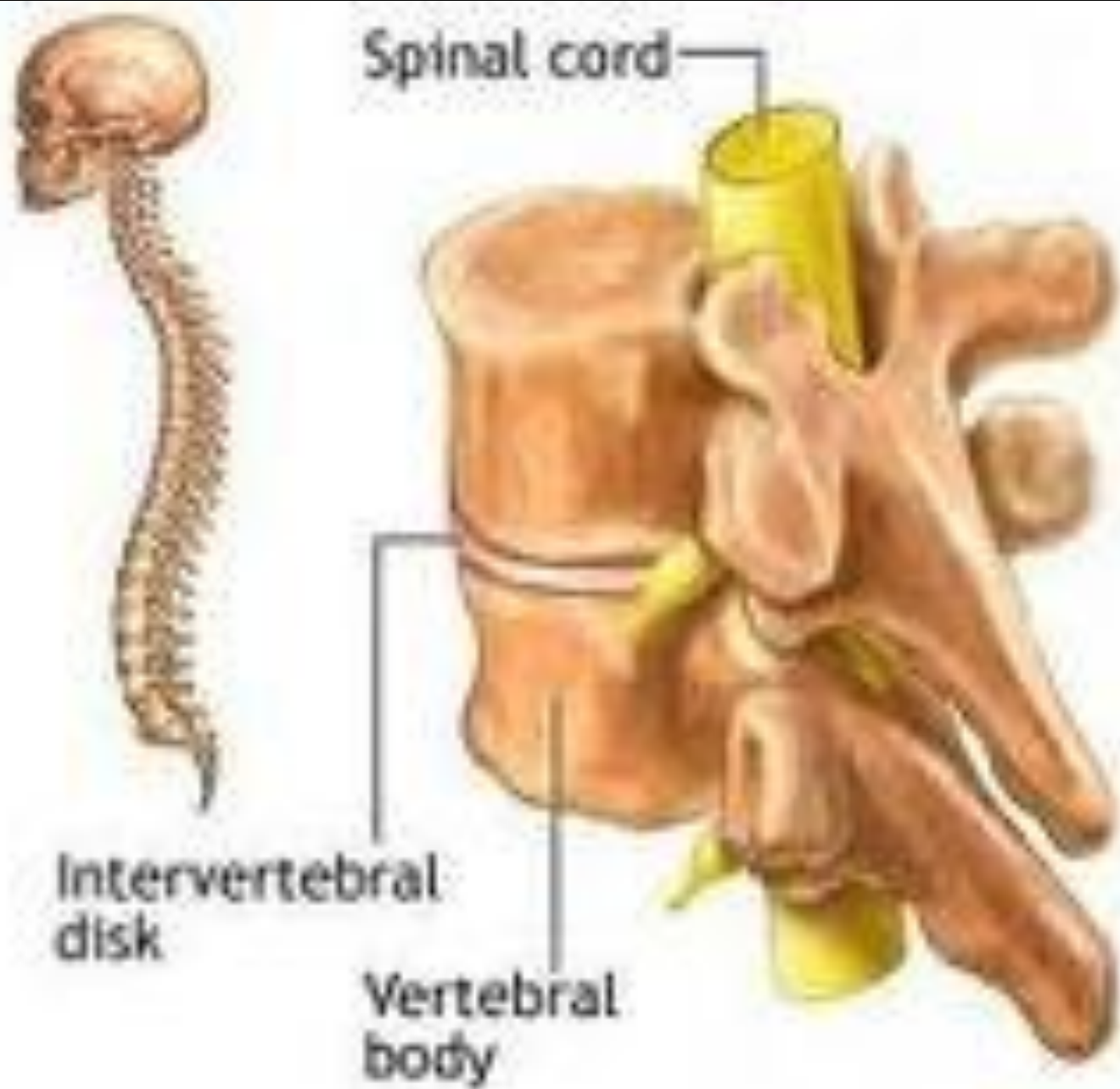
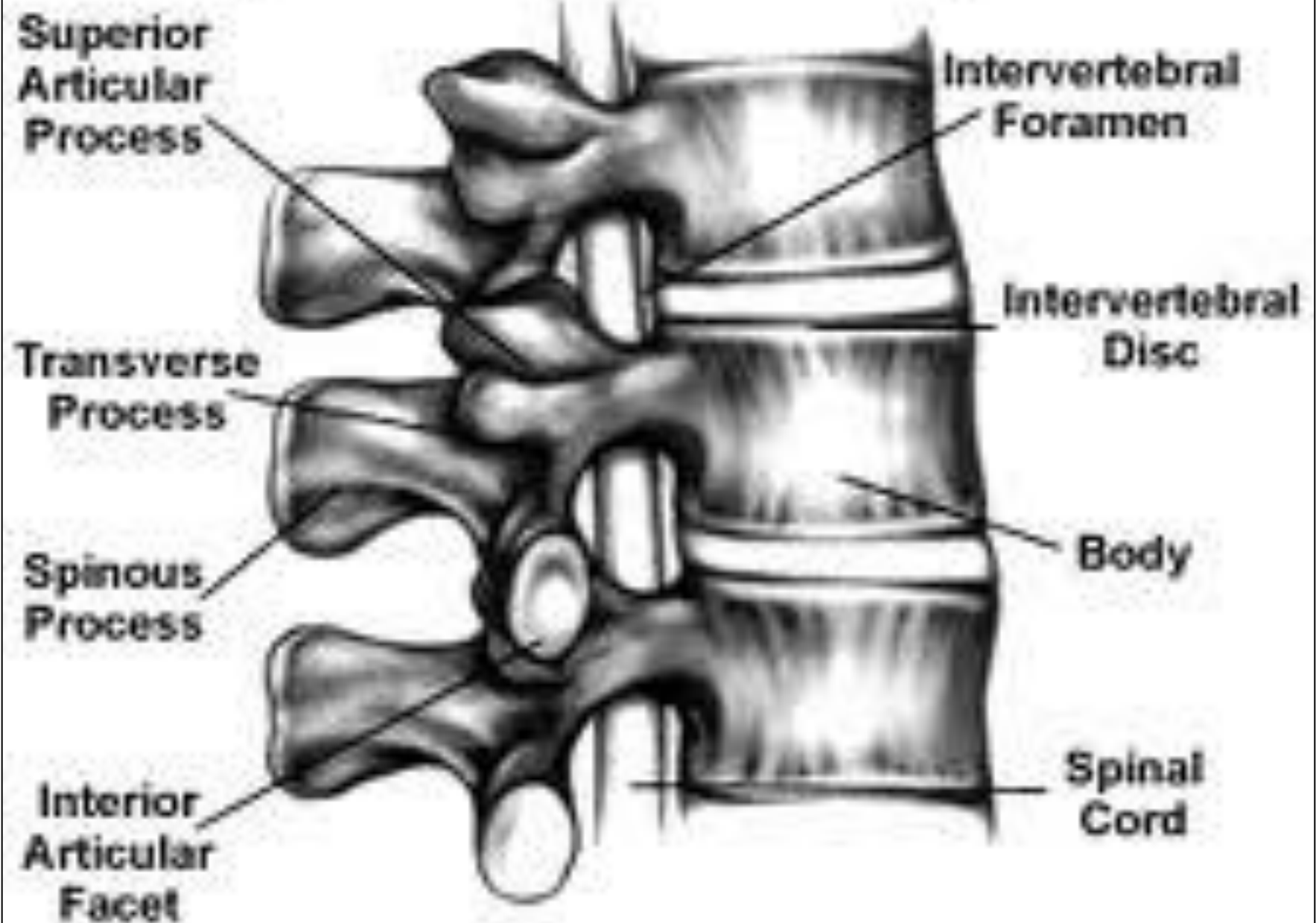


Diagram showing how the kidneys work
©CancerHelp UK



← POSTERIOR ANTERIOR →

















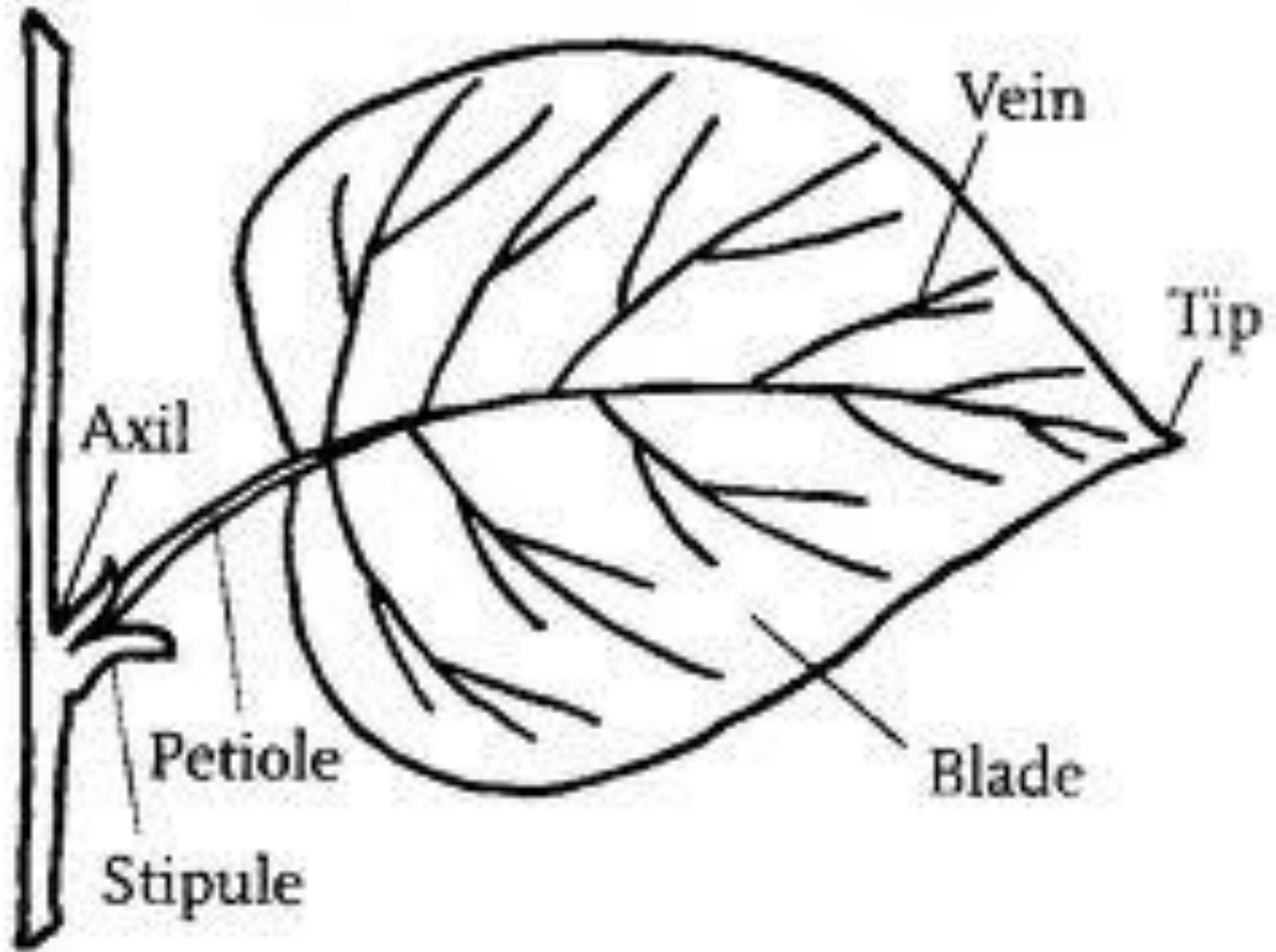








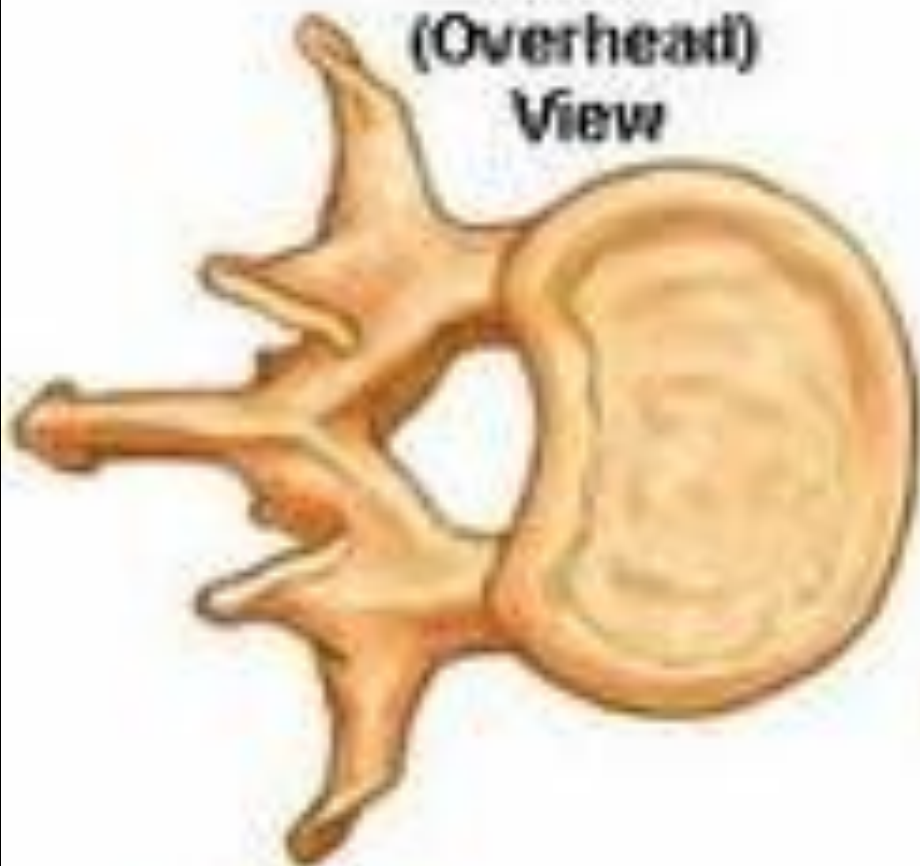LEAF PART NAMES



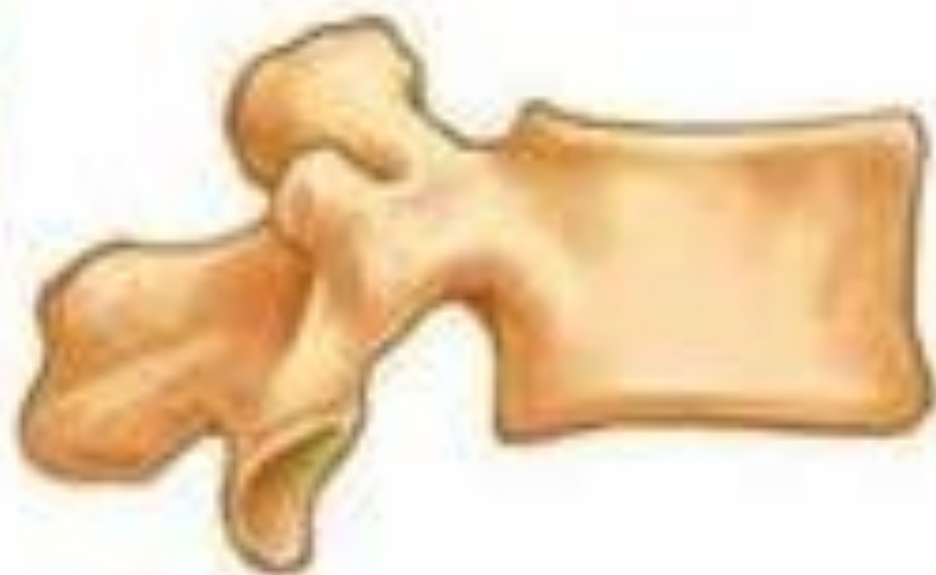

Lumbar Vertebrae

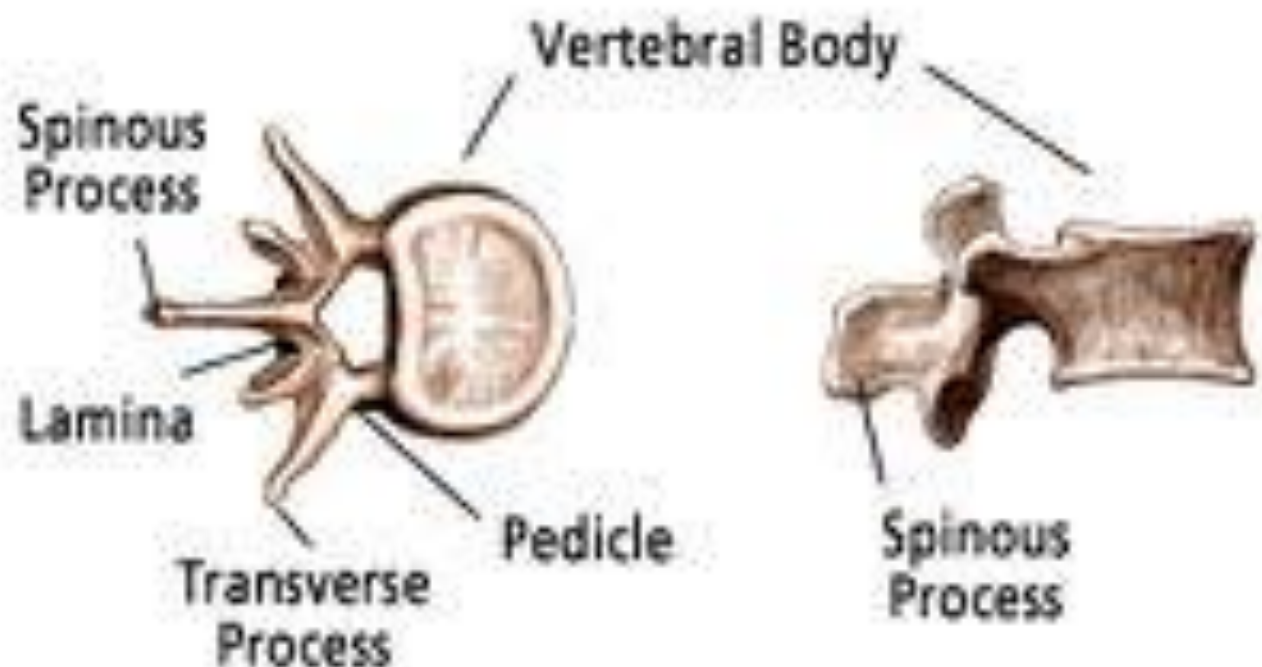
**Axial
(Overhead)
View**



**Lateral
(Side)
View**

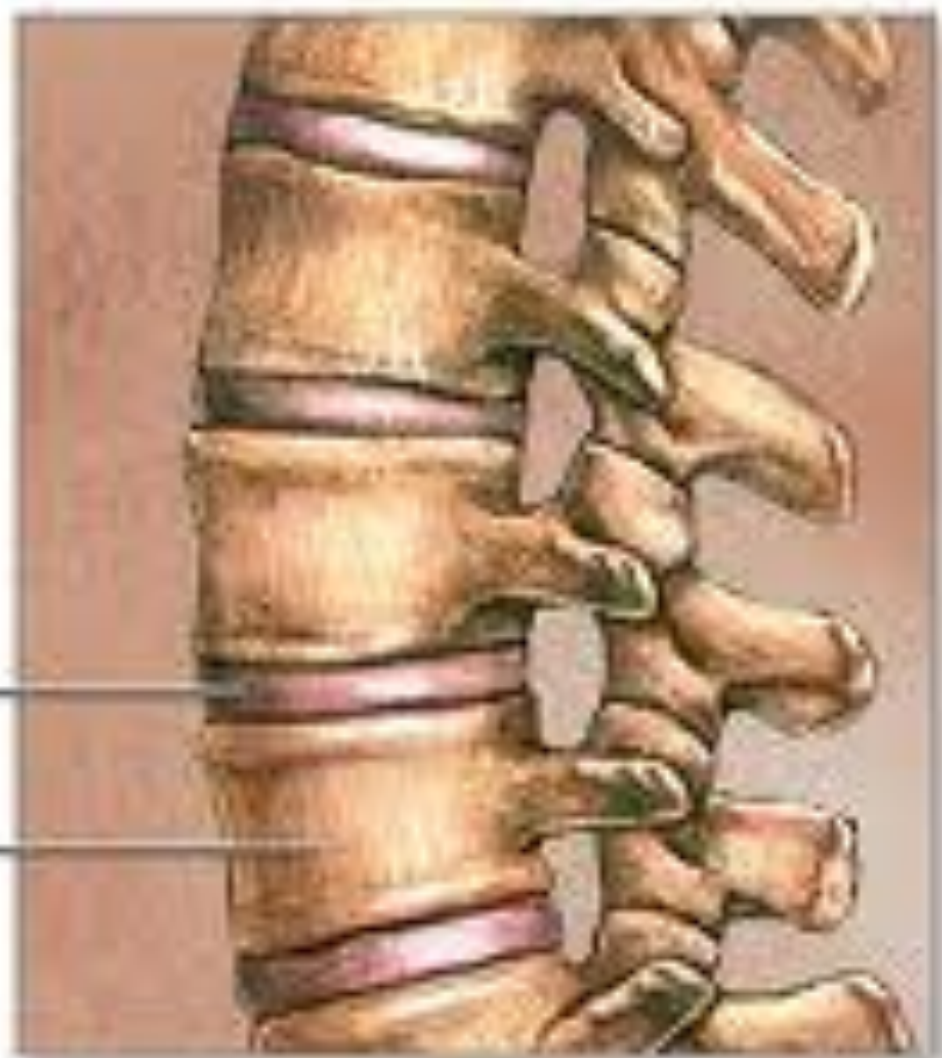
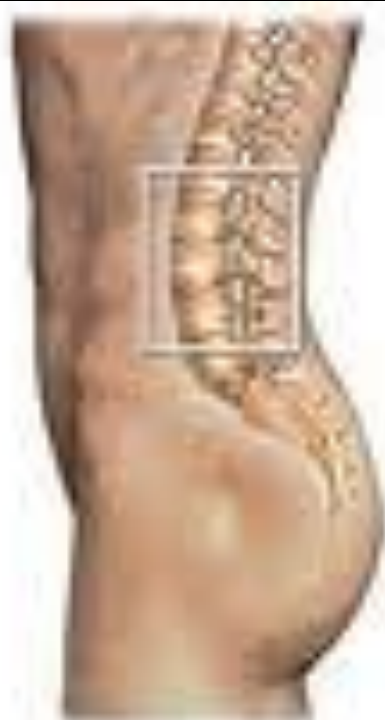
Lumbar Vertebrae



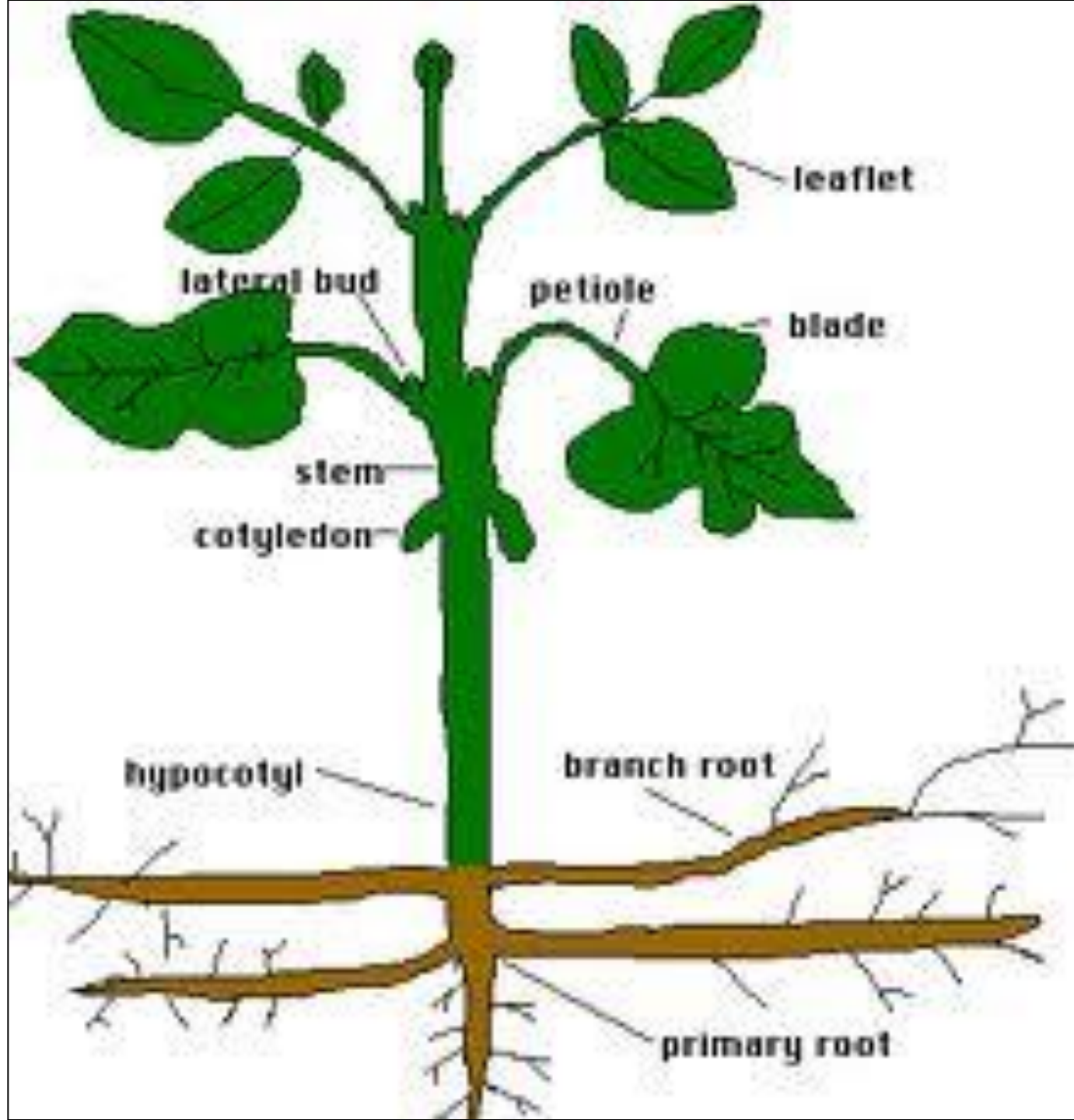
**Axial
(Overhead View)**

**Lateral
(Side View)**

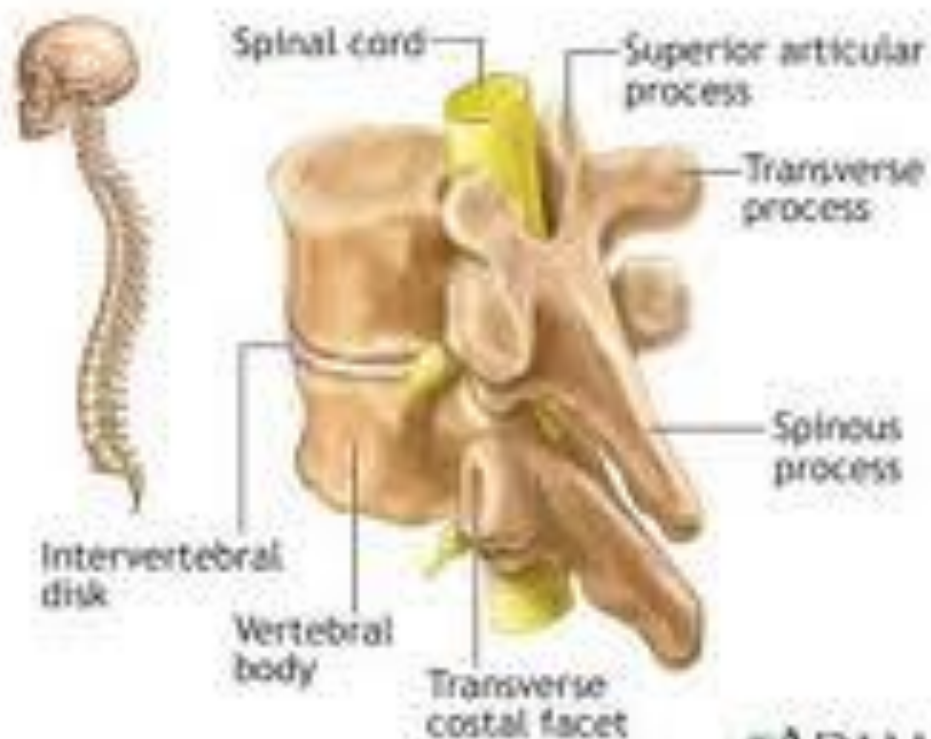
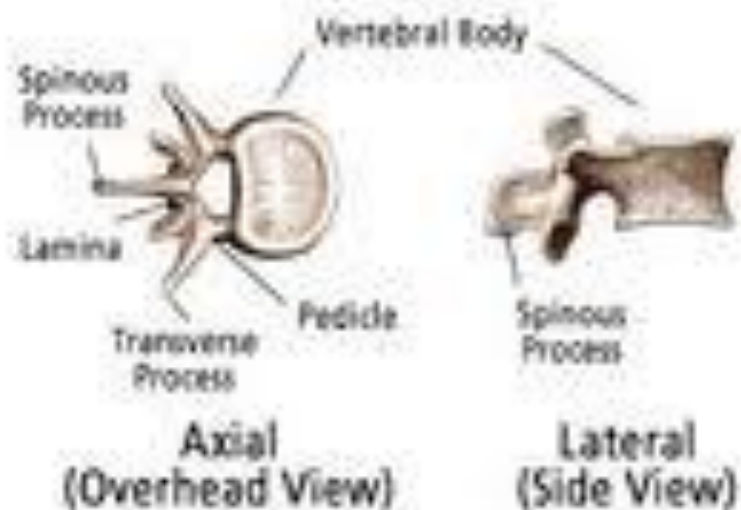


Intervertebral disk

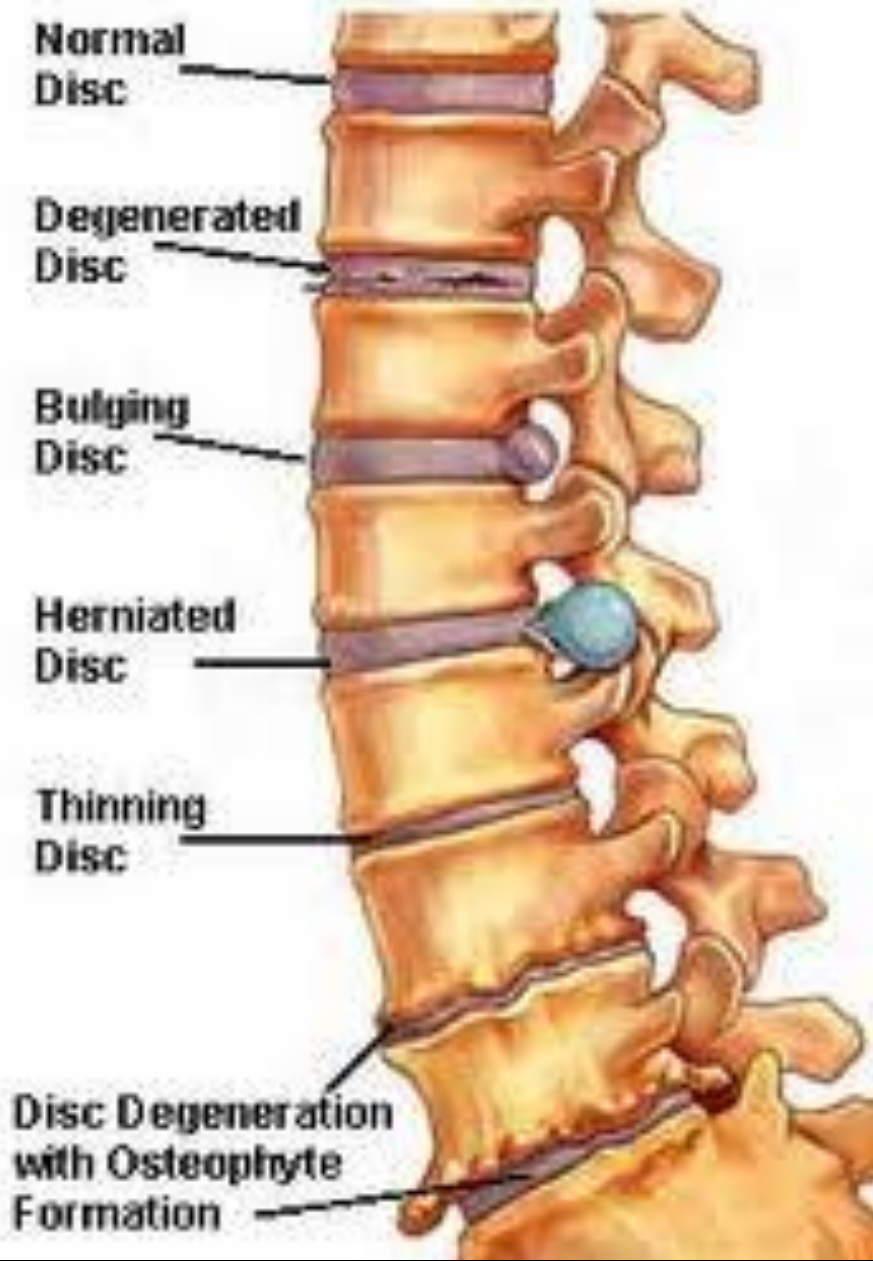
Lumbar vertebra

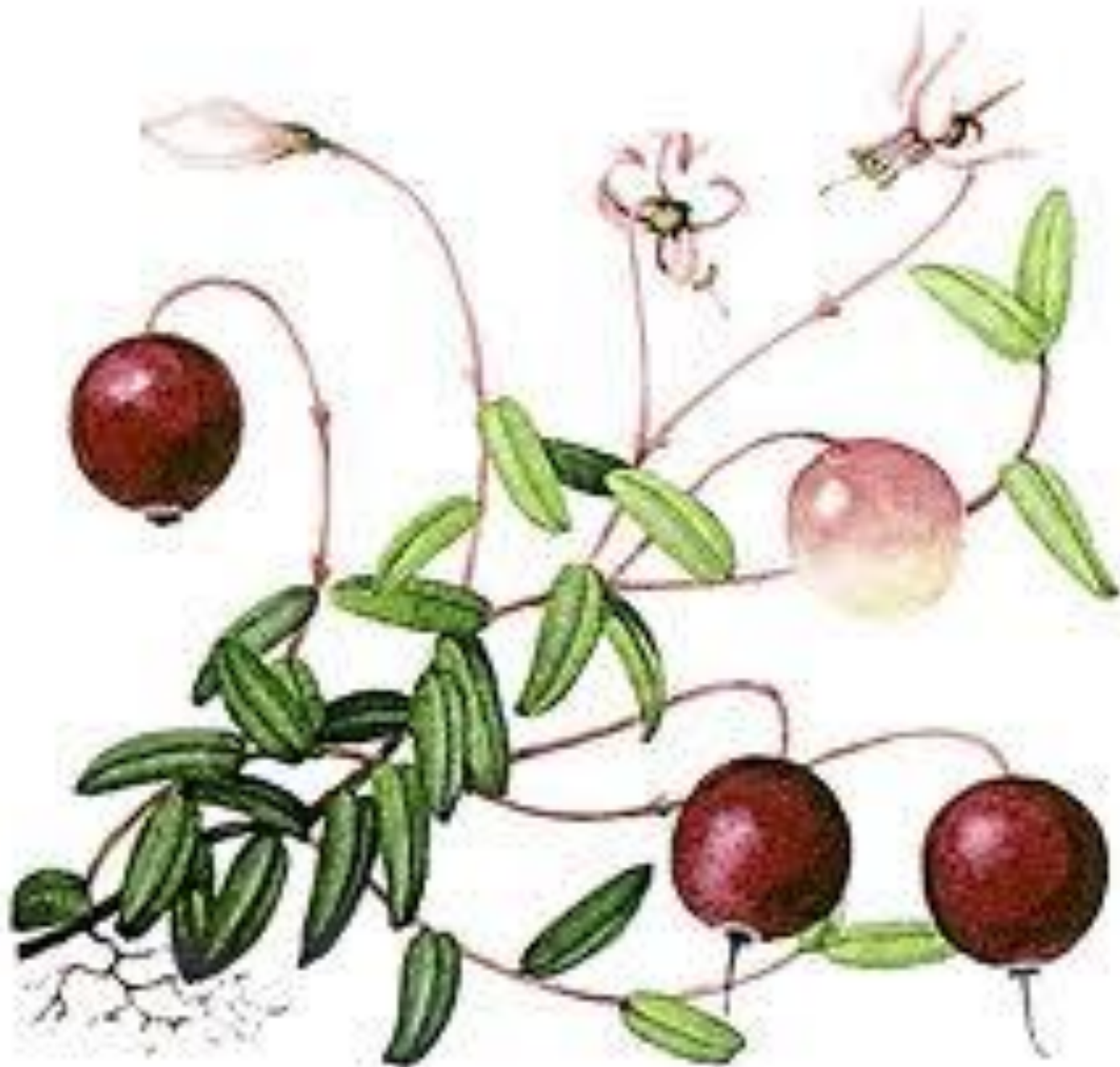

Lumbar Vertebrae



Examples of Disc Problems





Vertebral Column

Cervical vertebrae

Thoracic vertebrae

Lumbar vertebrae

Sacrum

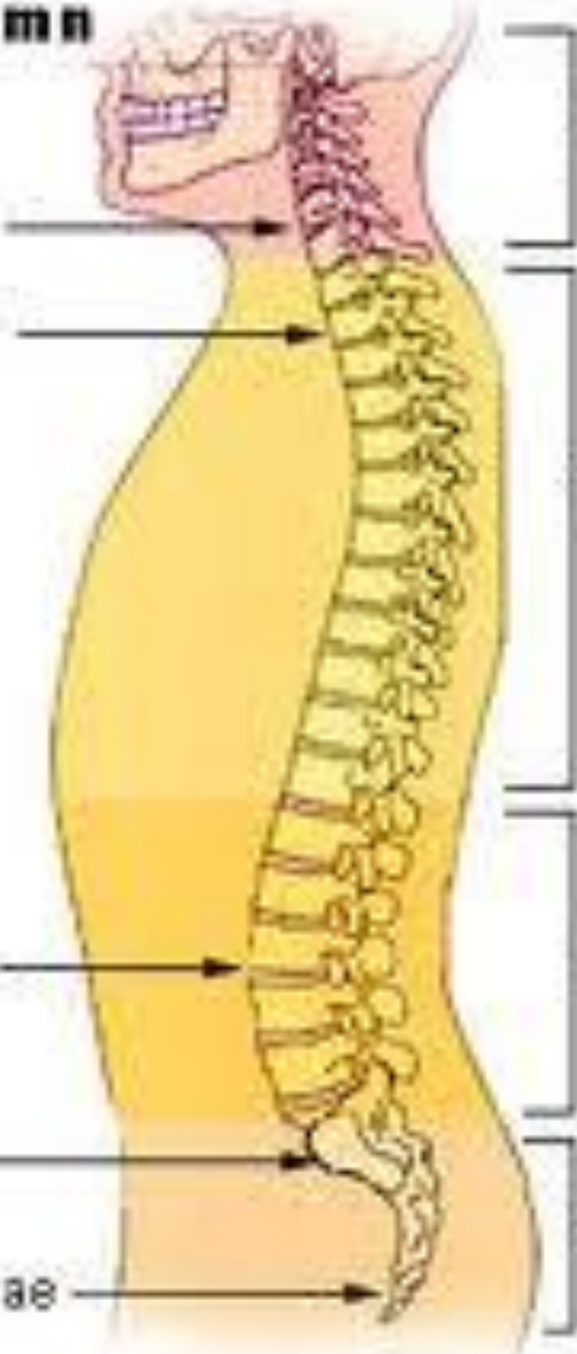
Coccygeal vertebrae

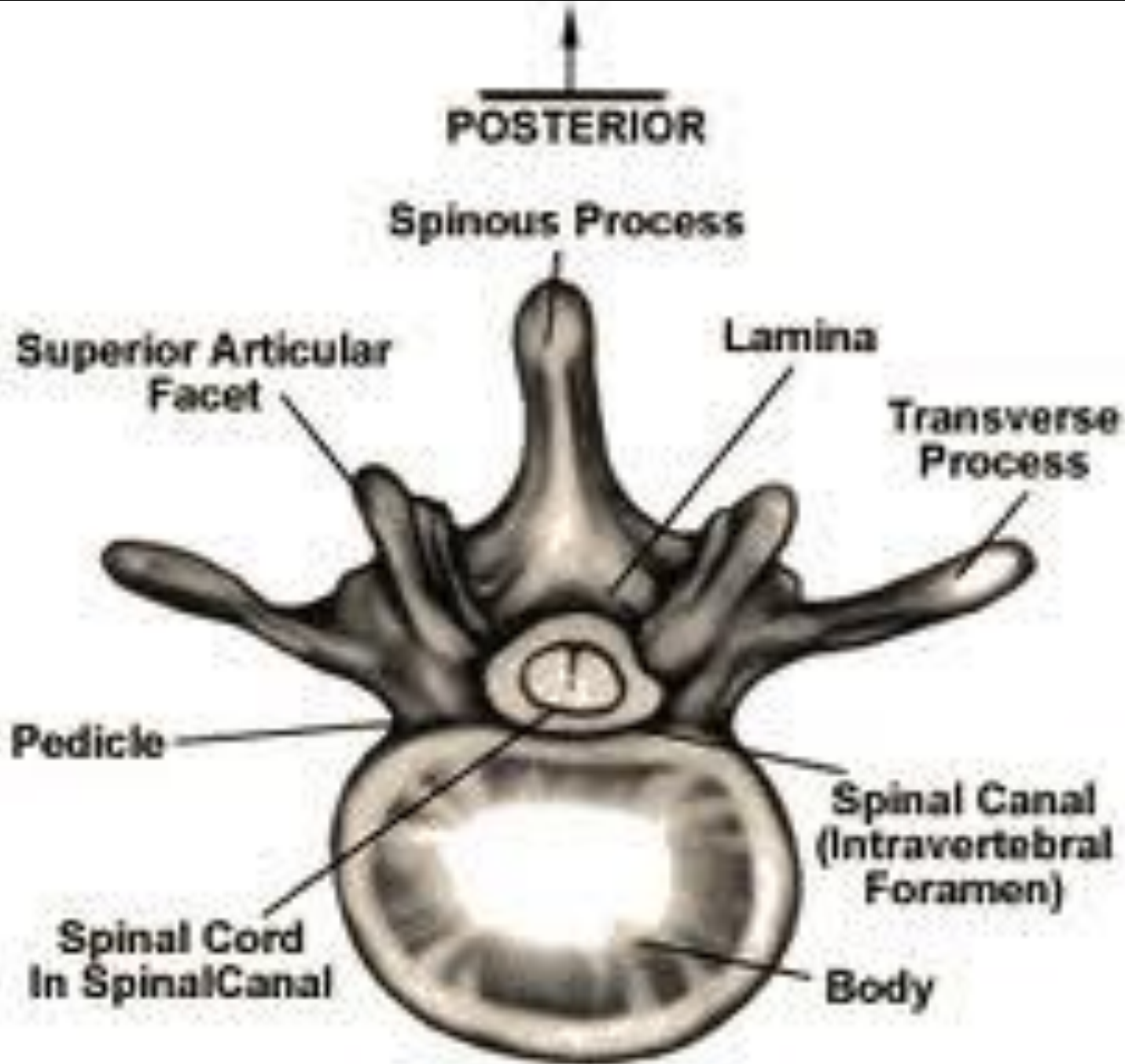
Cervical curve

Thoracic curve

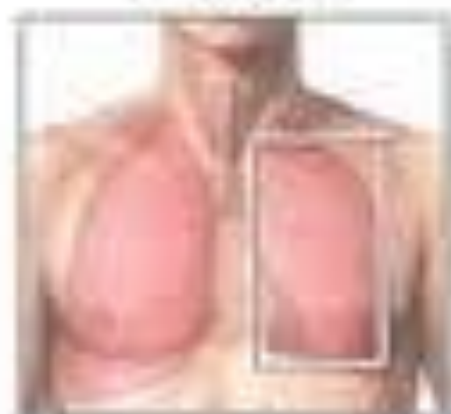Lumbar curve

Sacral curve





Lungs



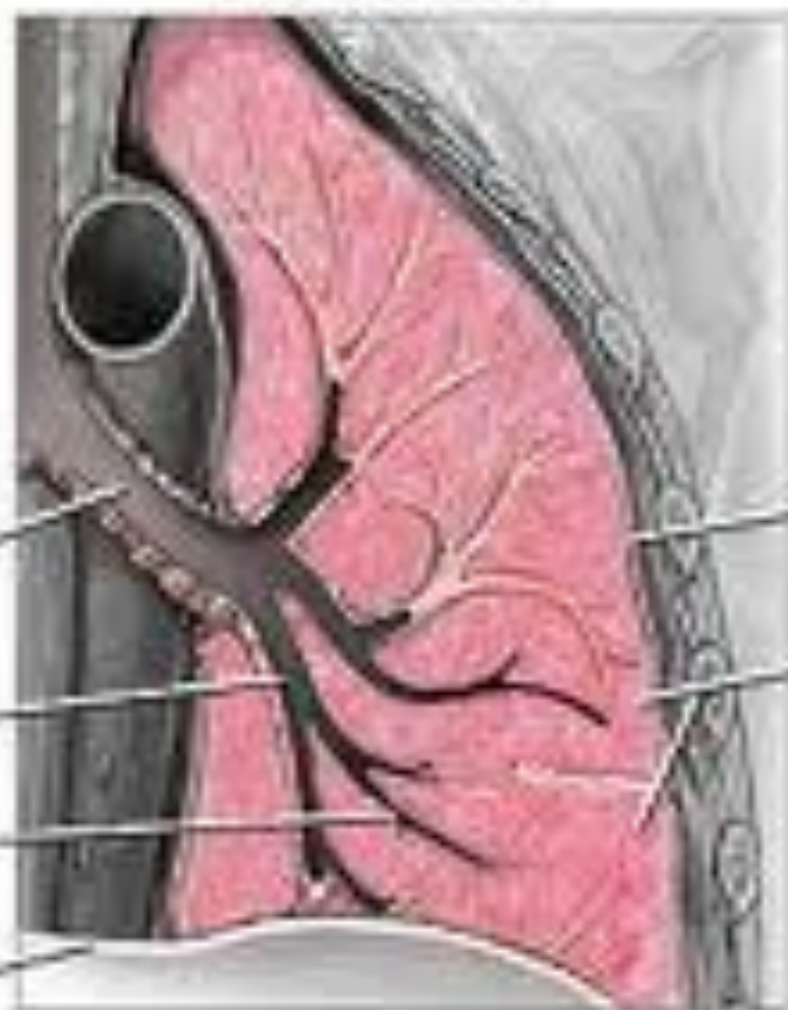
Left lung

Left main
stem bronchus

Bronchi

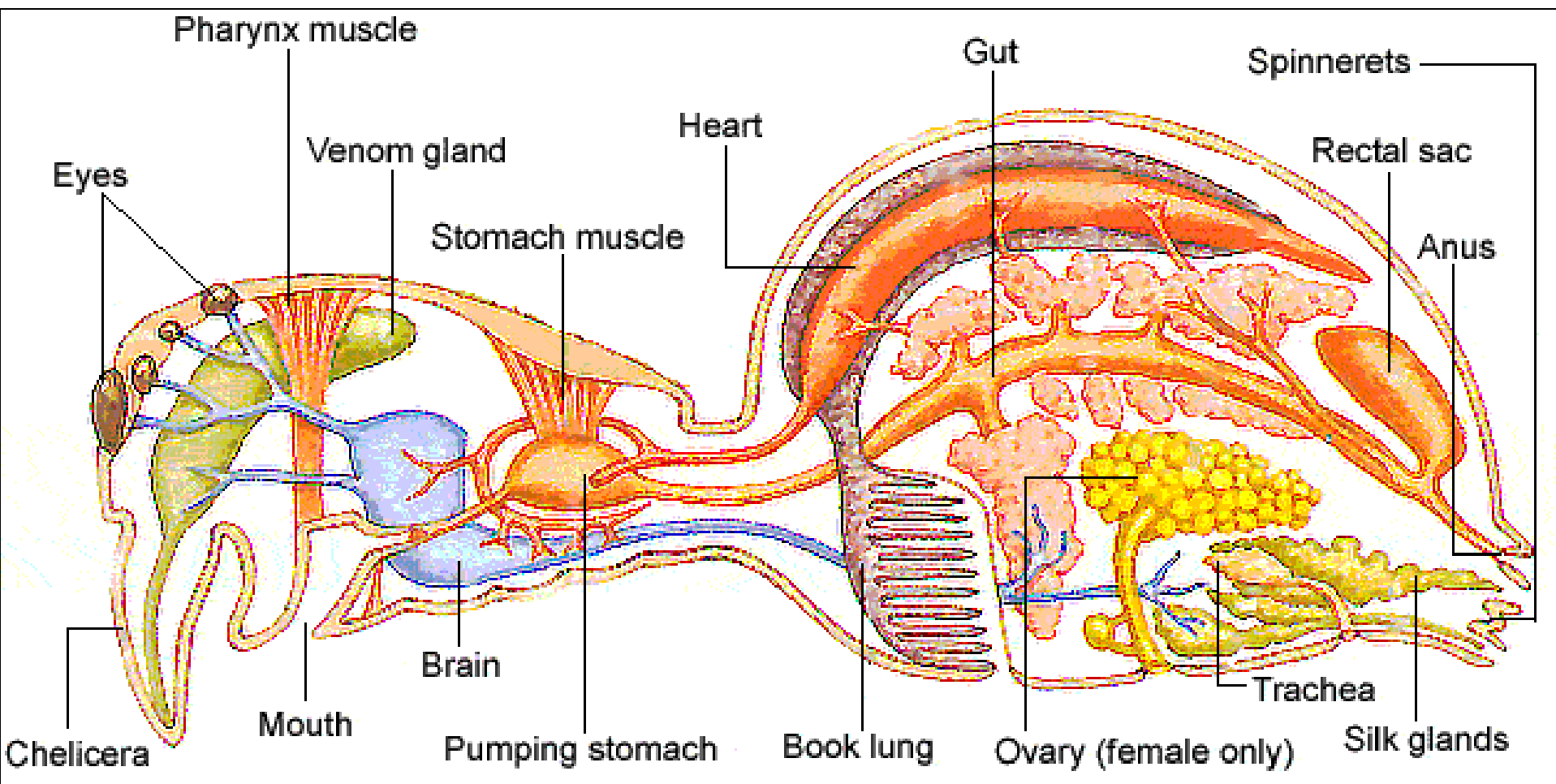
Bronchioles

Diaphragm

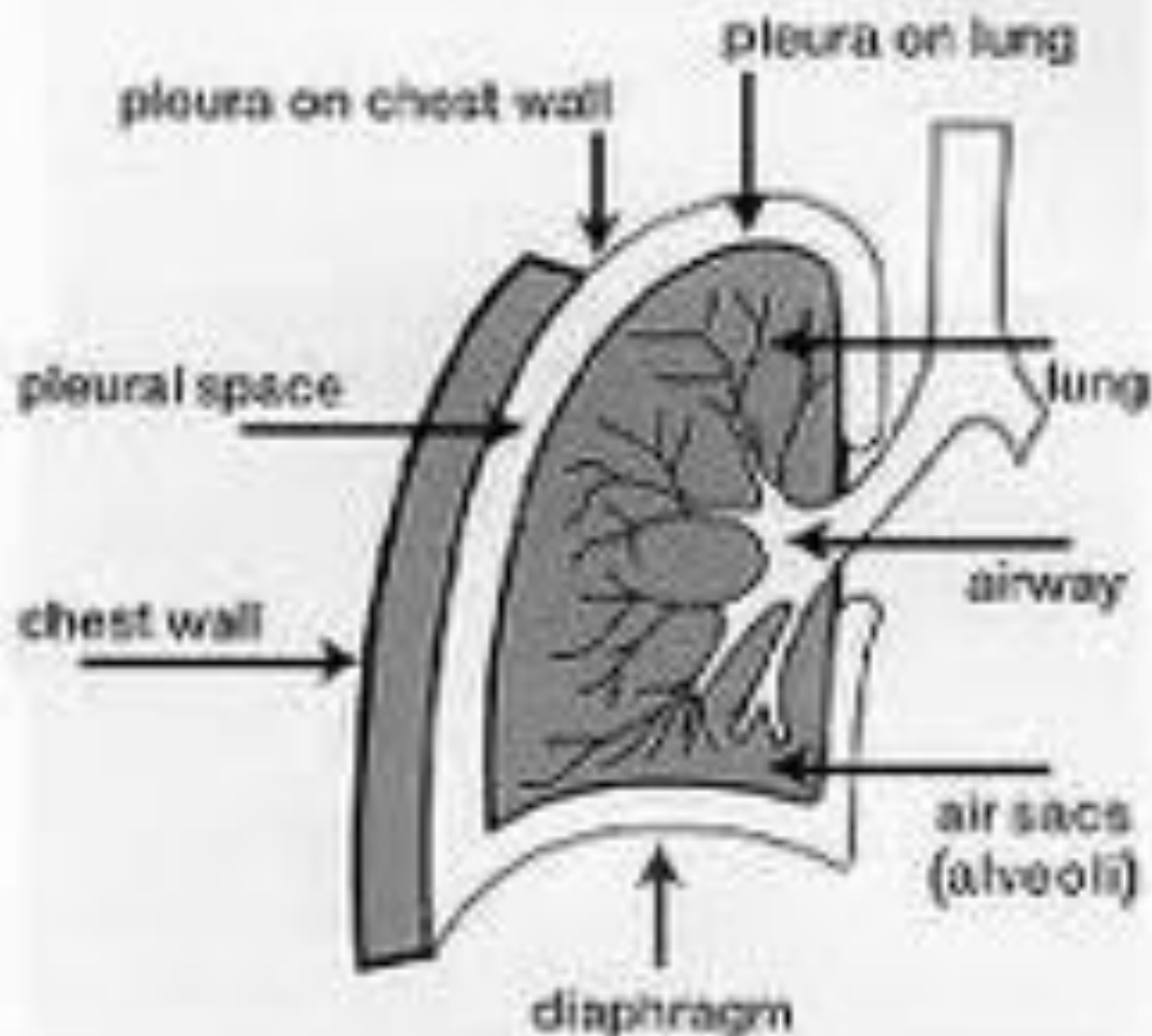


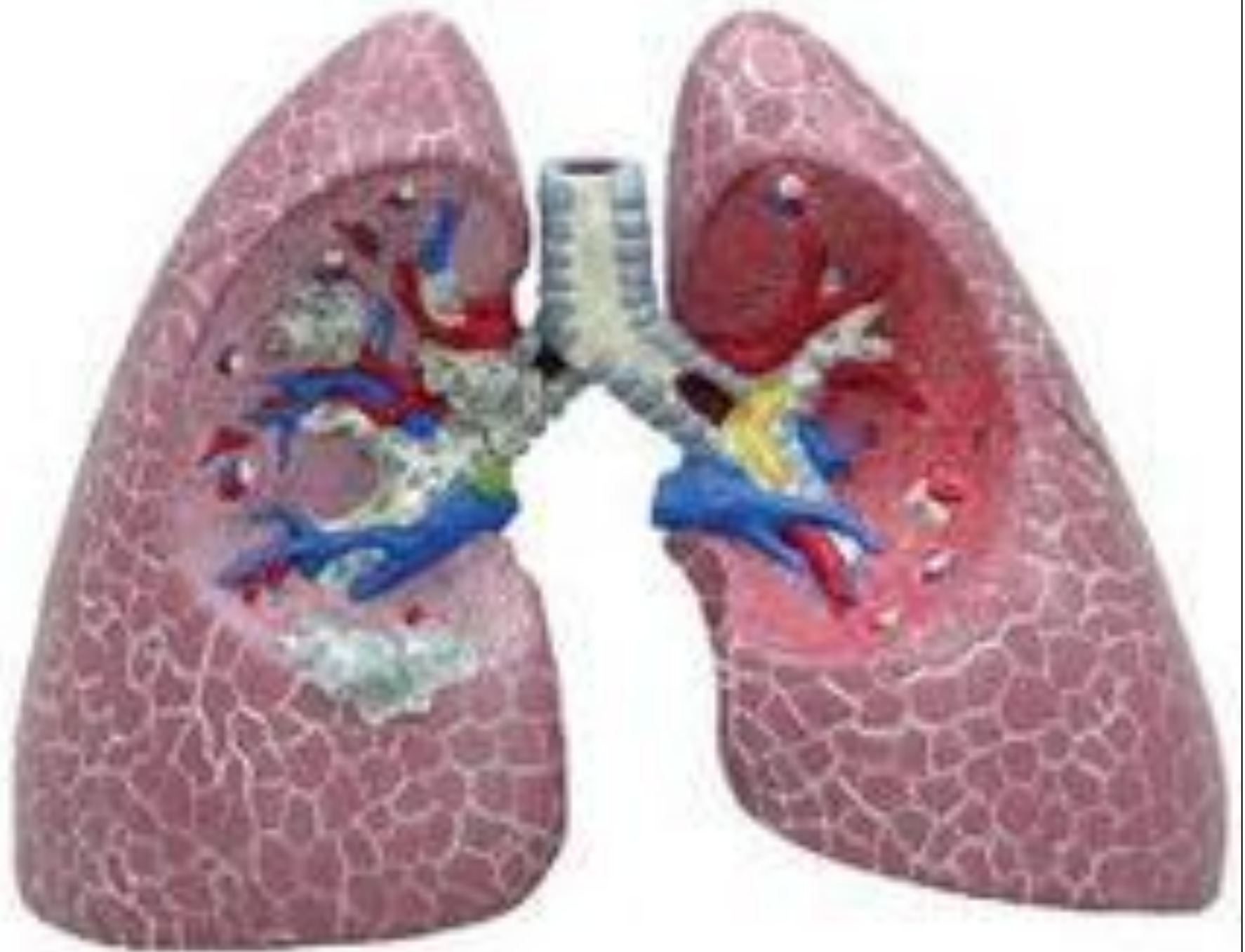Pleura

Left
lobes



Normal lung anatomy





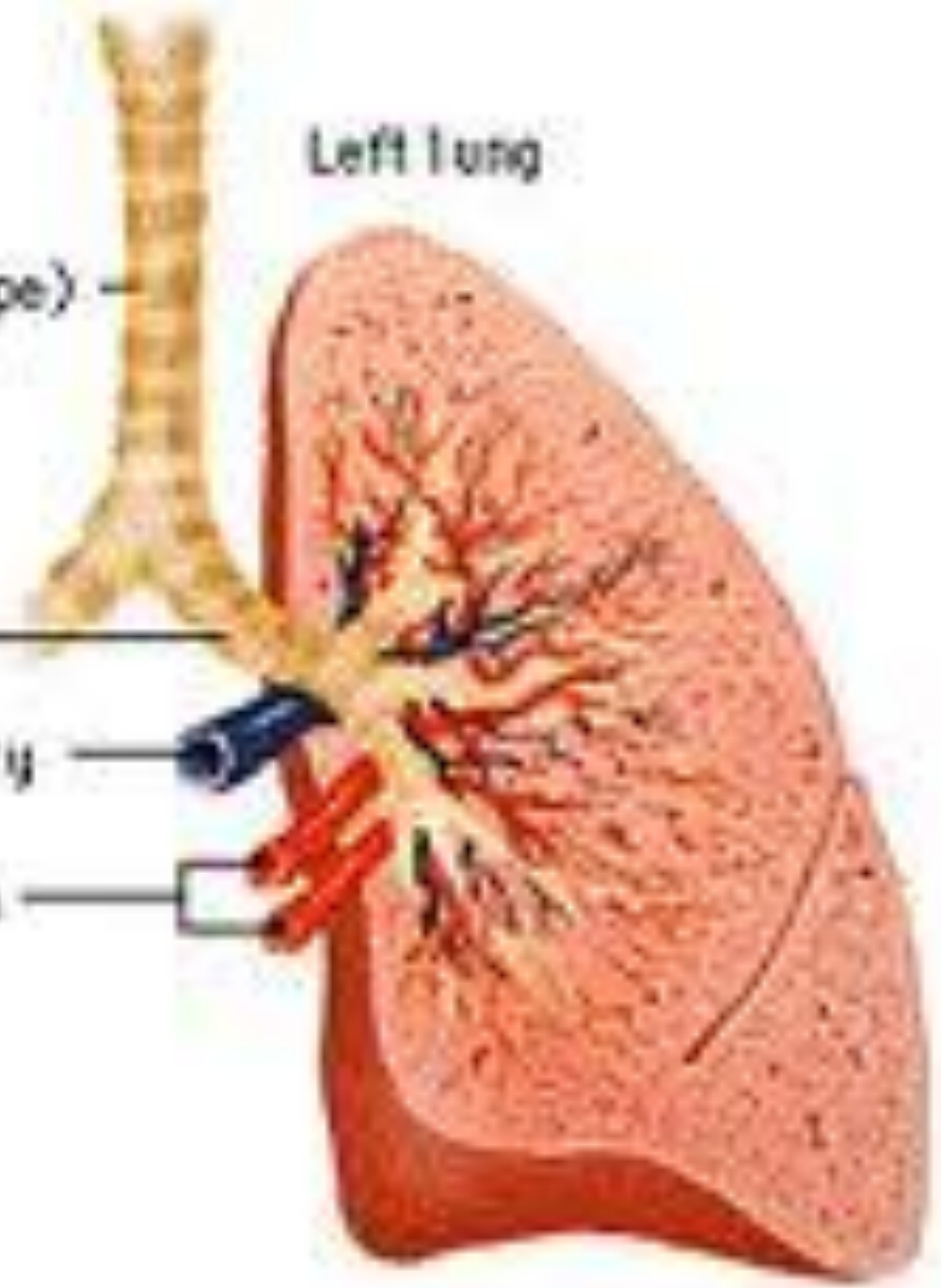
Left lung

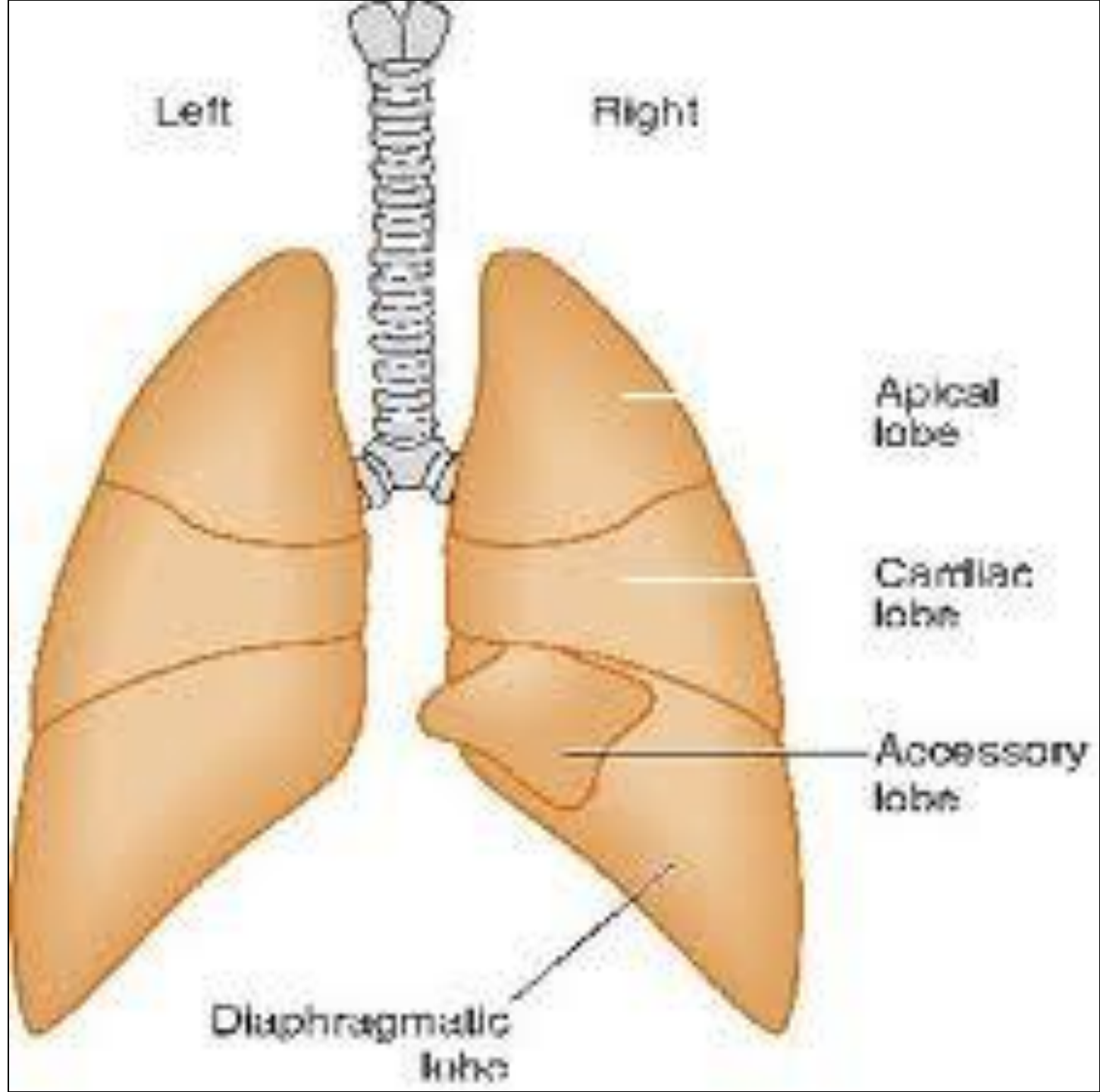
Trachea (windpipe)

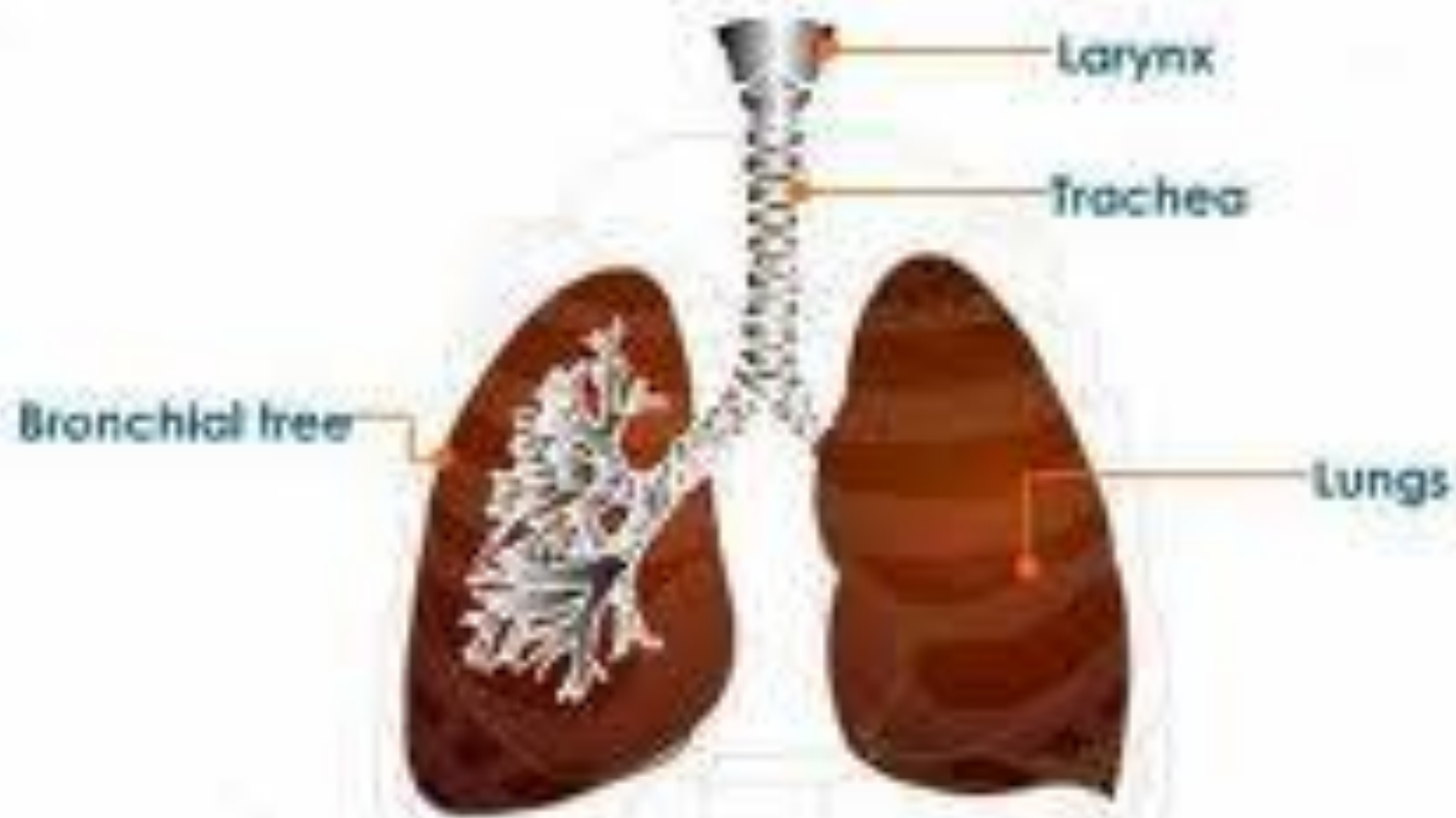
Bronchus

Pulmonary artery

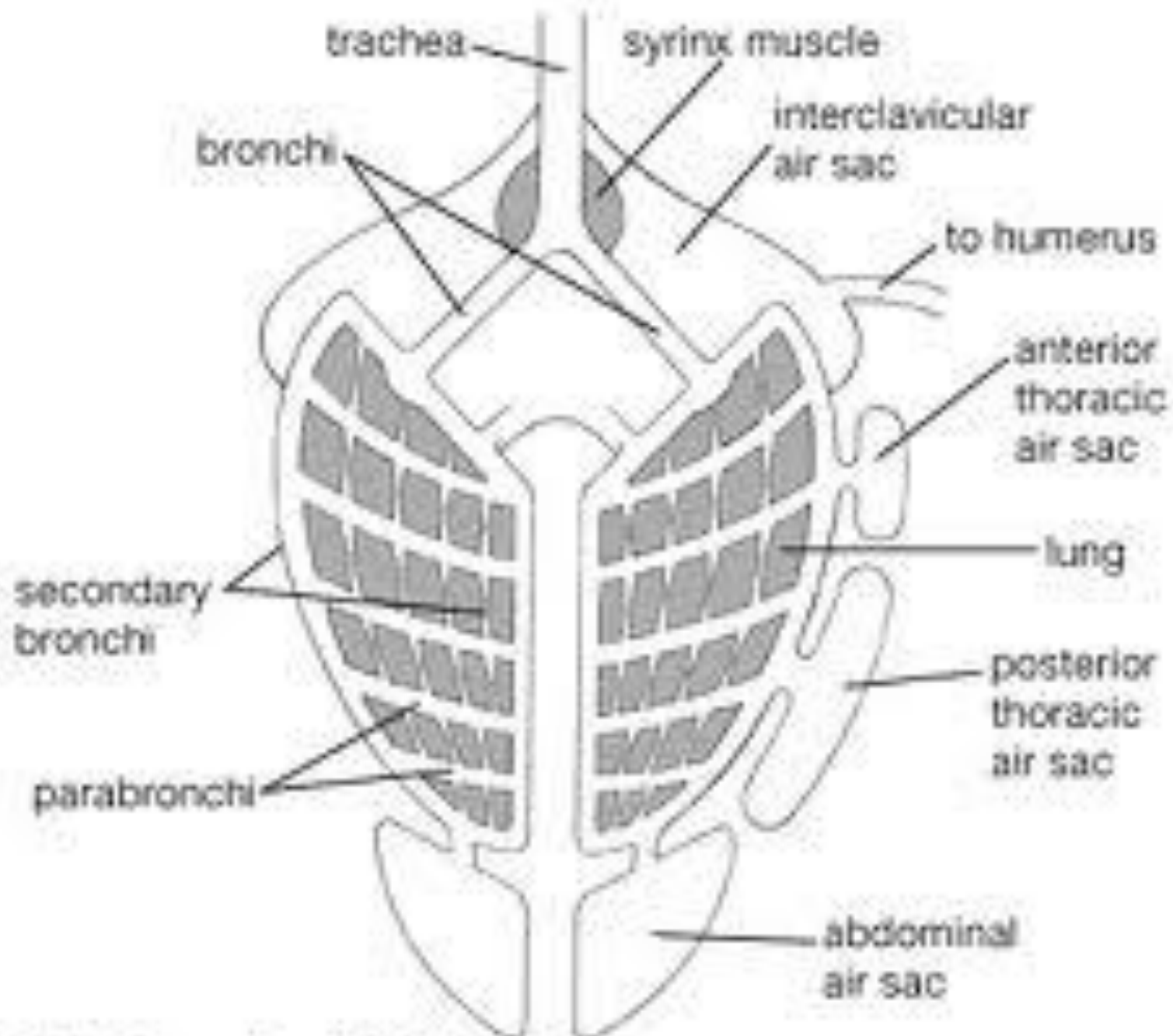
Pulmonary veins

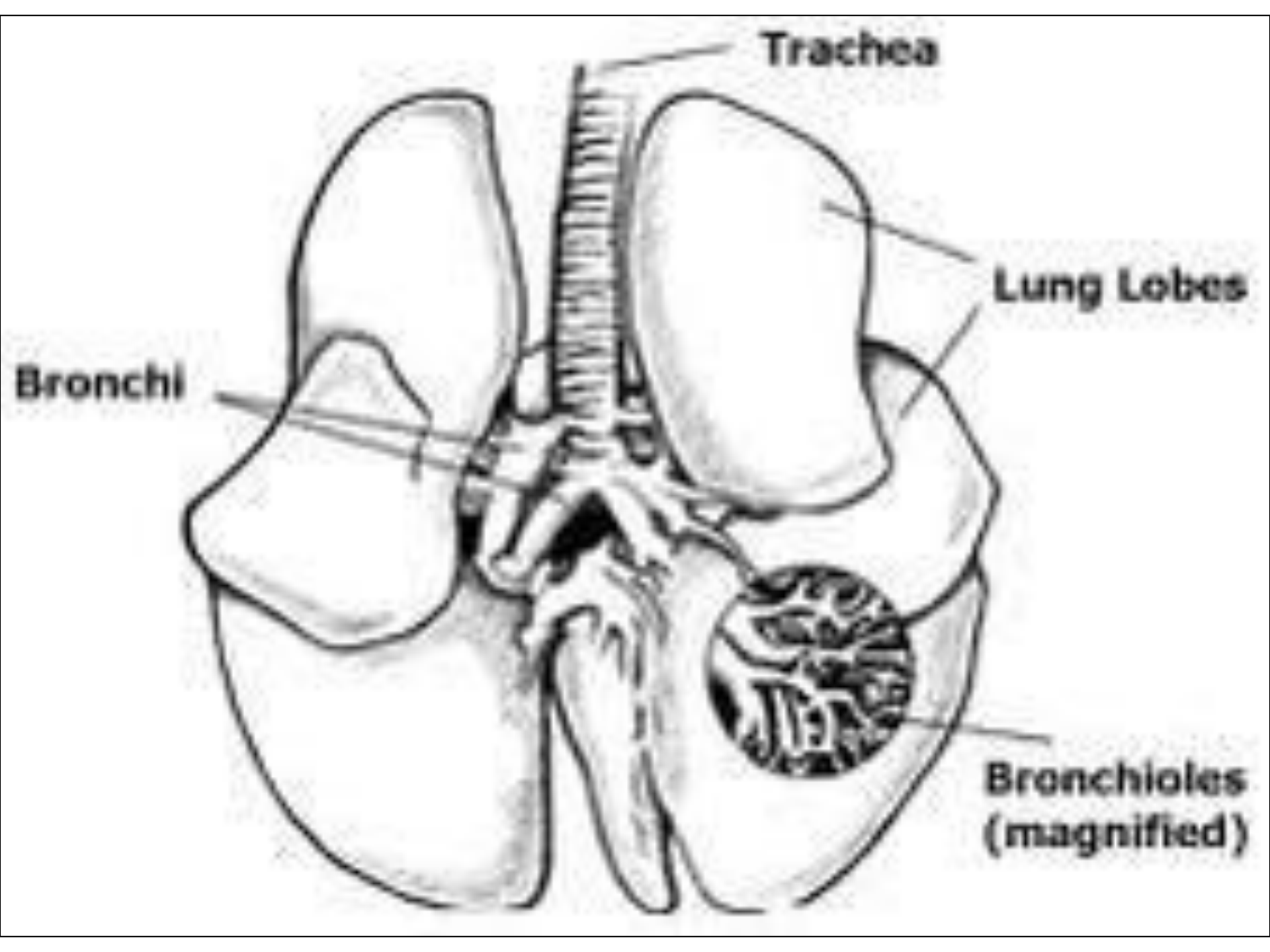


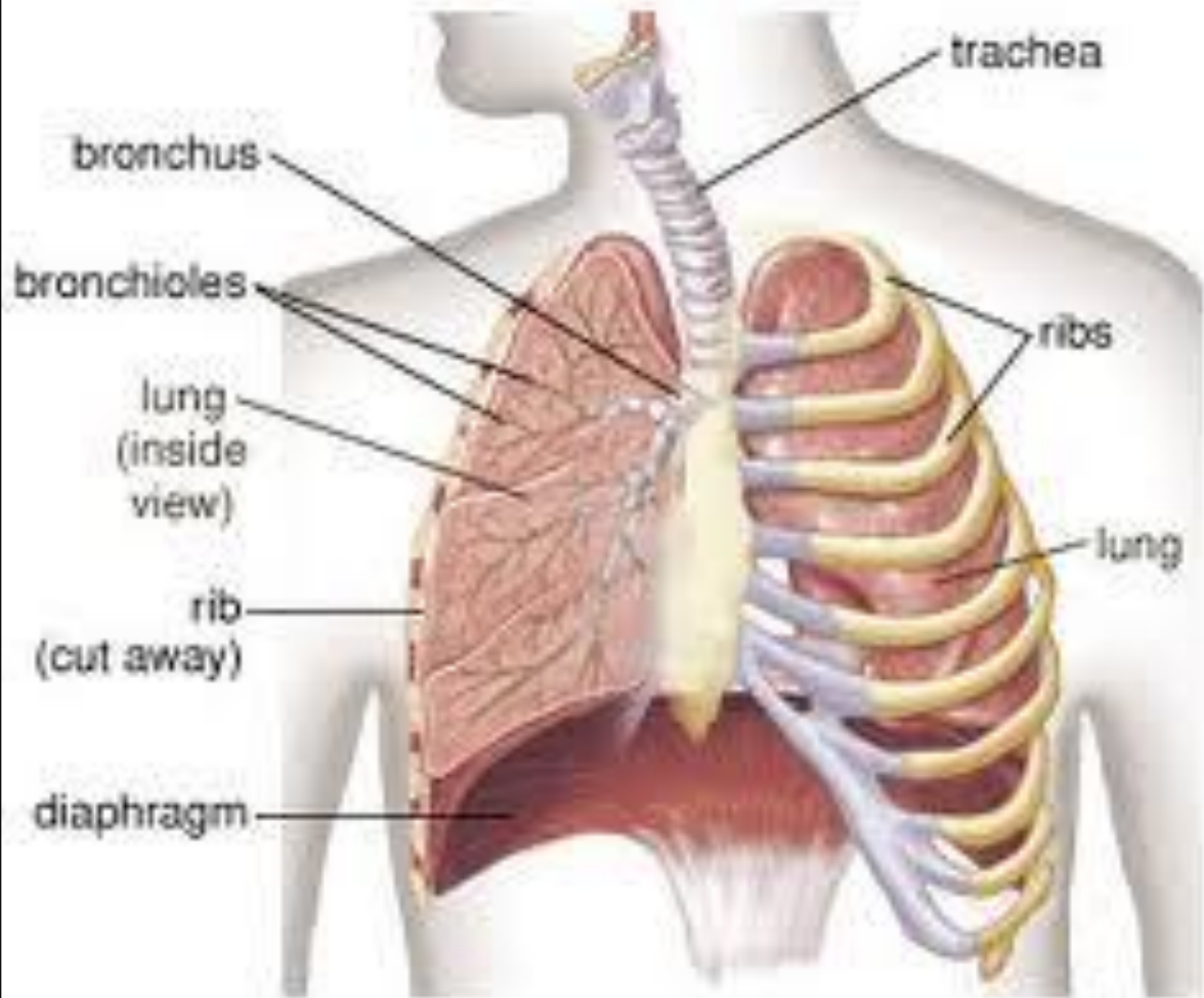


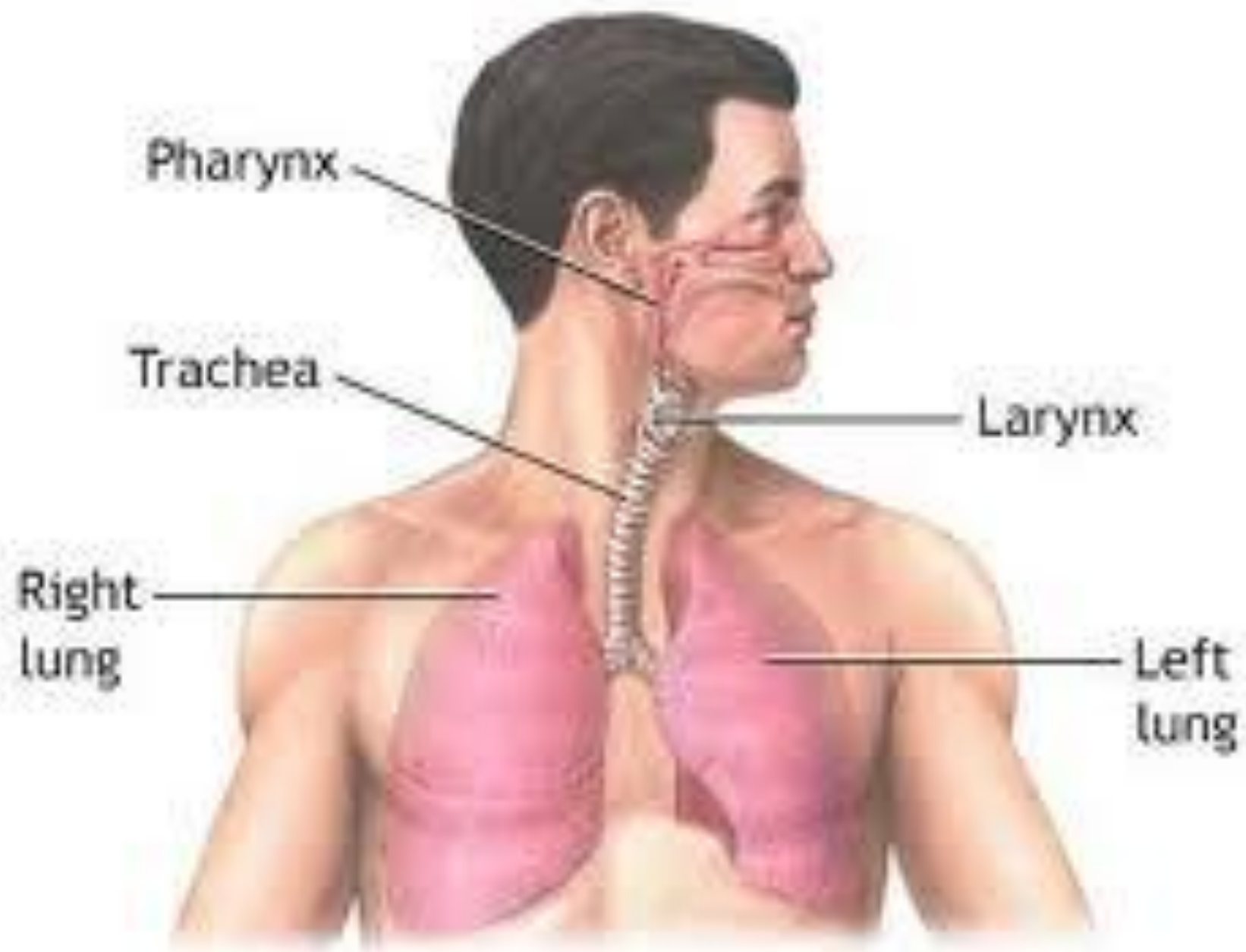


Respiratory Organs as Contained Inside the Rib Cage

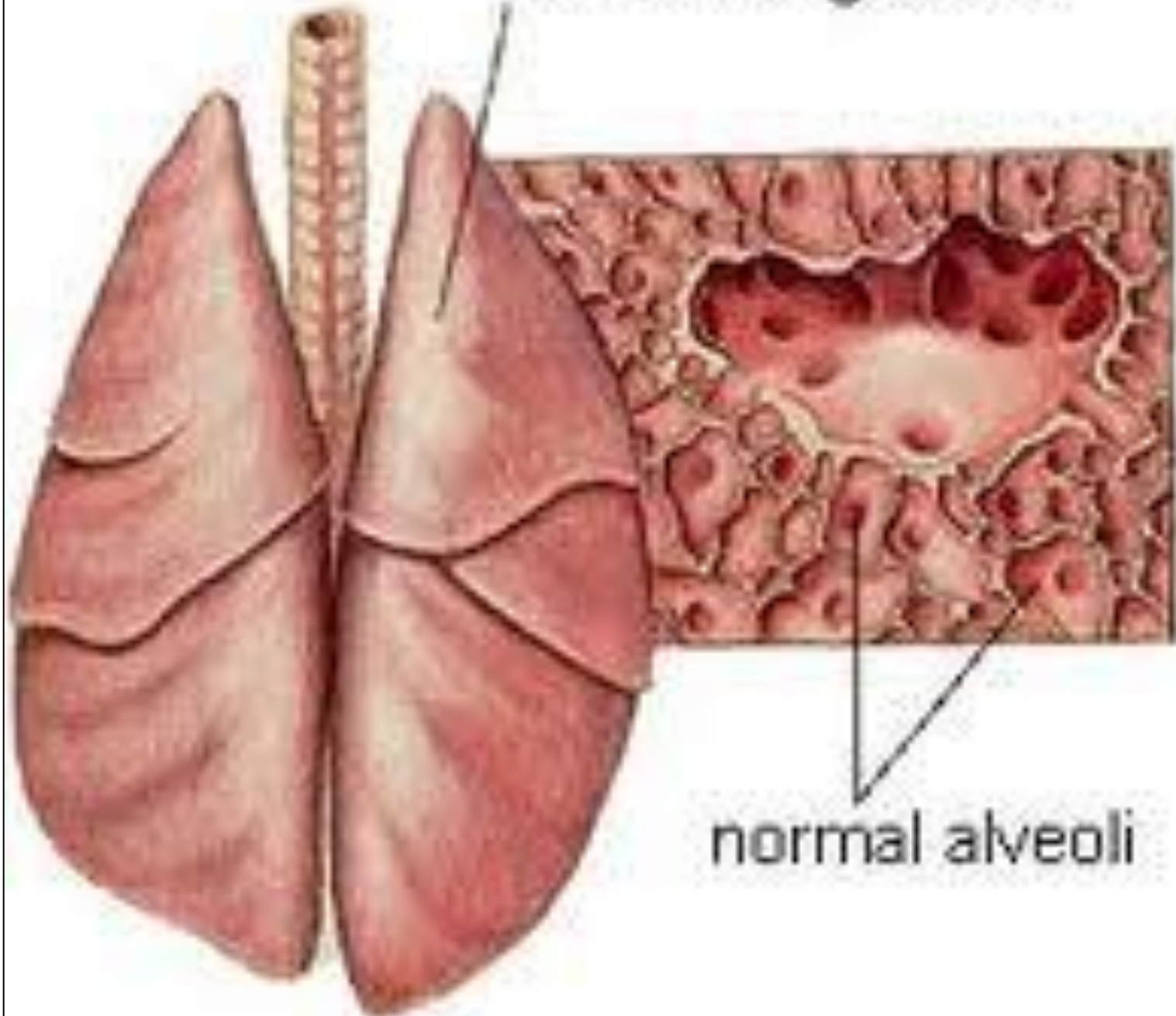








normal lung tissue



normal alveoli

Windpipe (trachea)

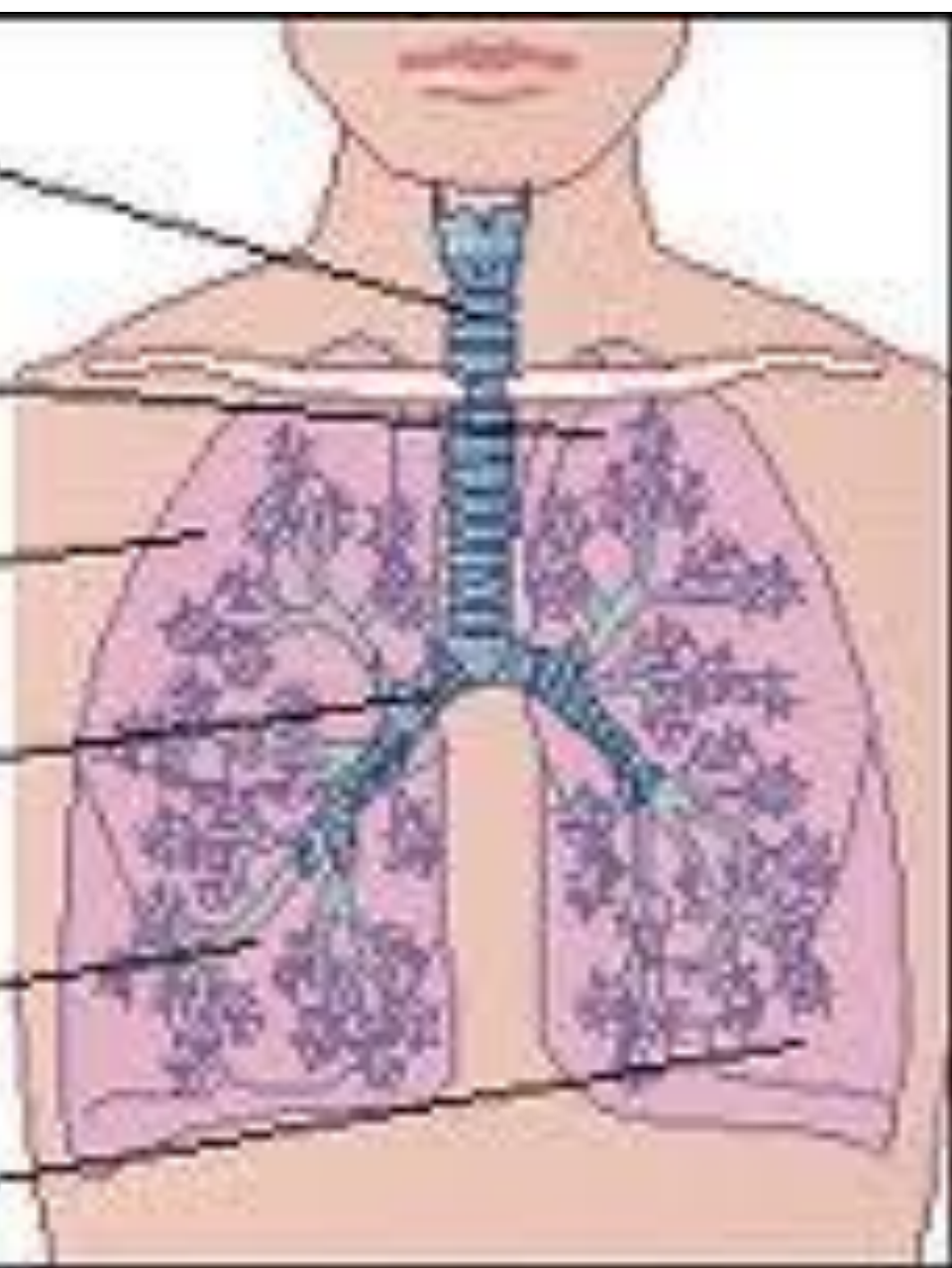
Left upper lobe

Right upper lobe

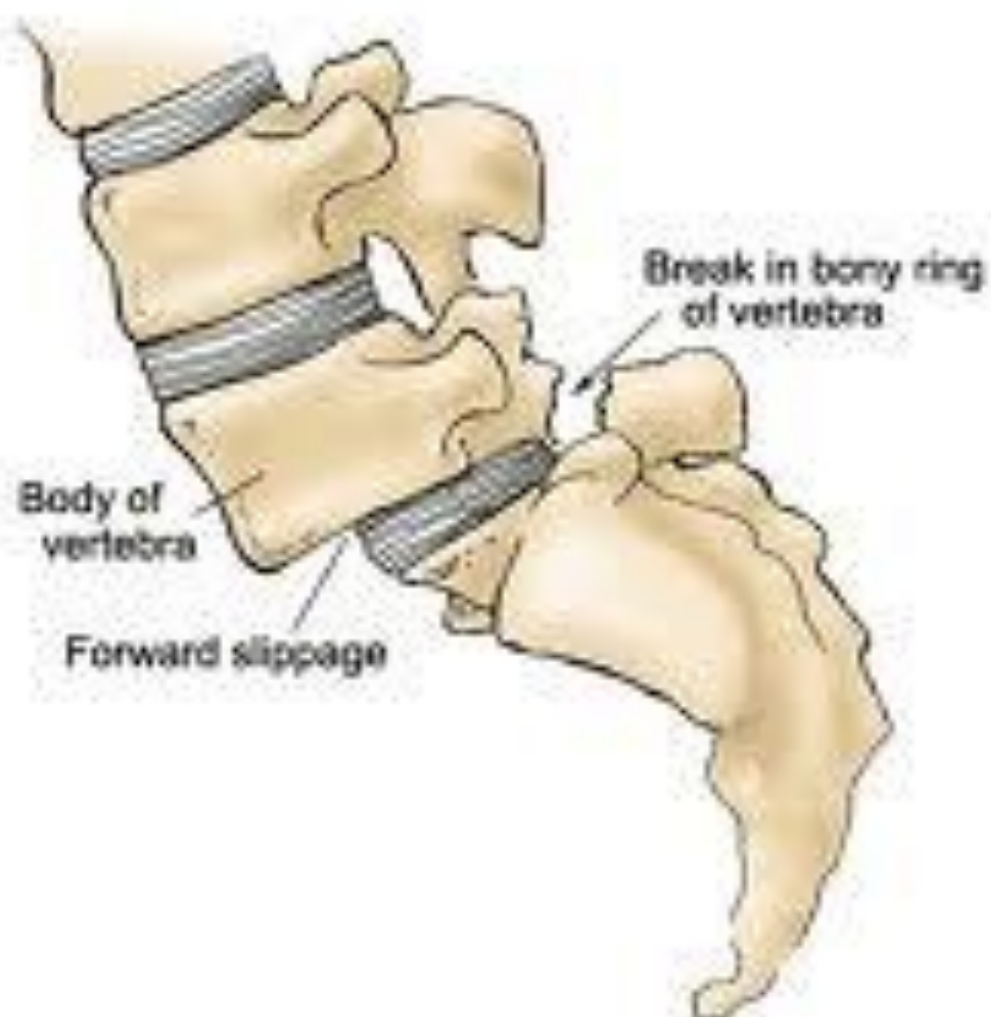
Right bronchus

Right middle lobe

Left lower lobe



Spondylolisthesis



Side View of Low Backbone

Superior articular
facet

Sacral canal

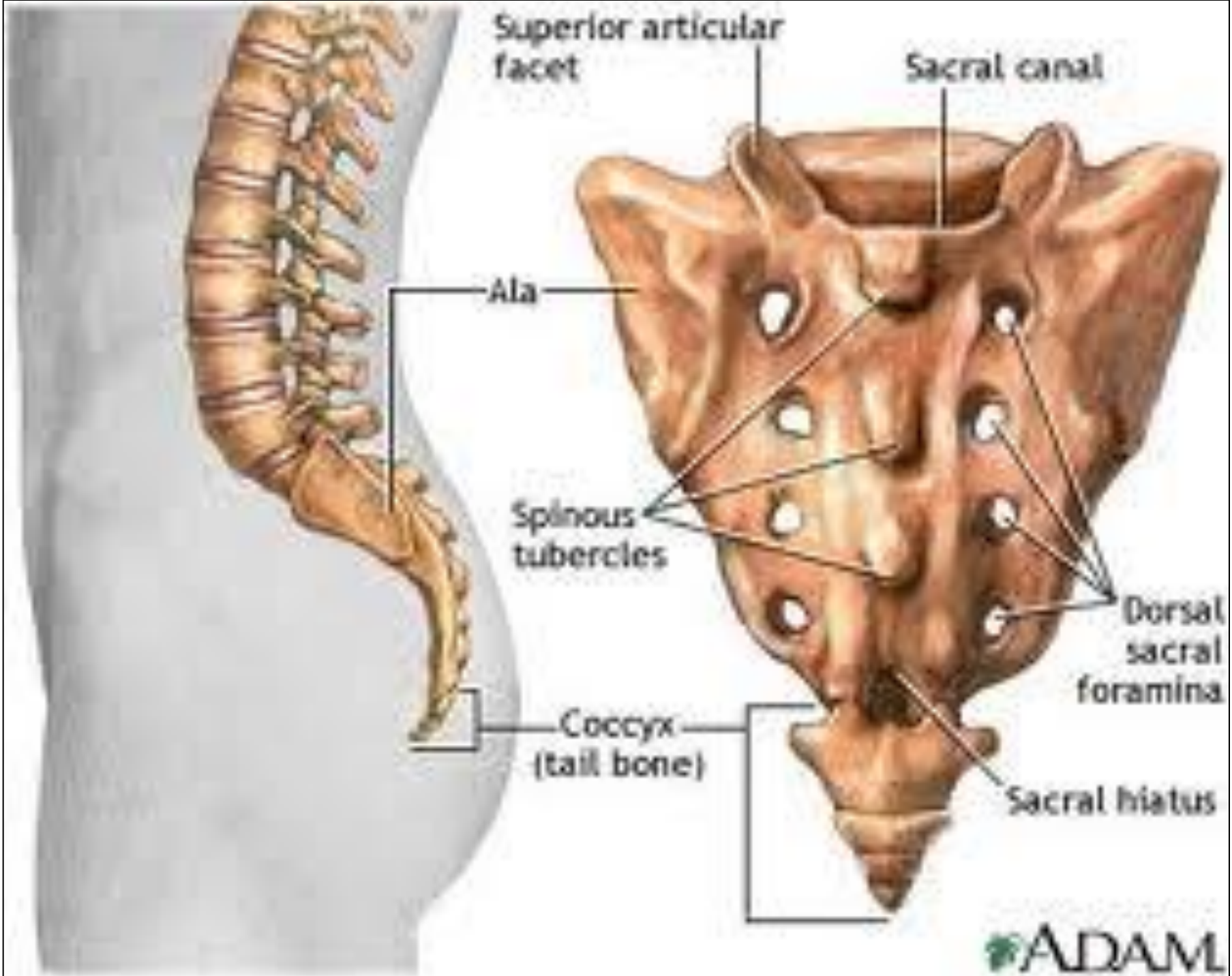
Ala

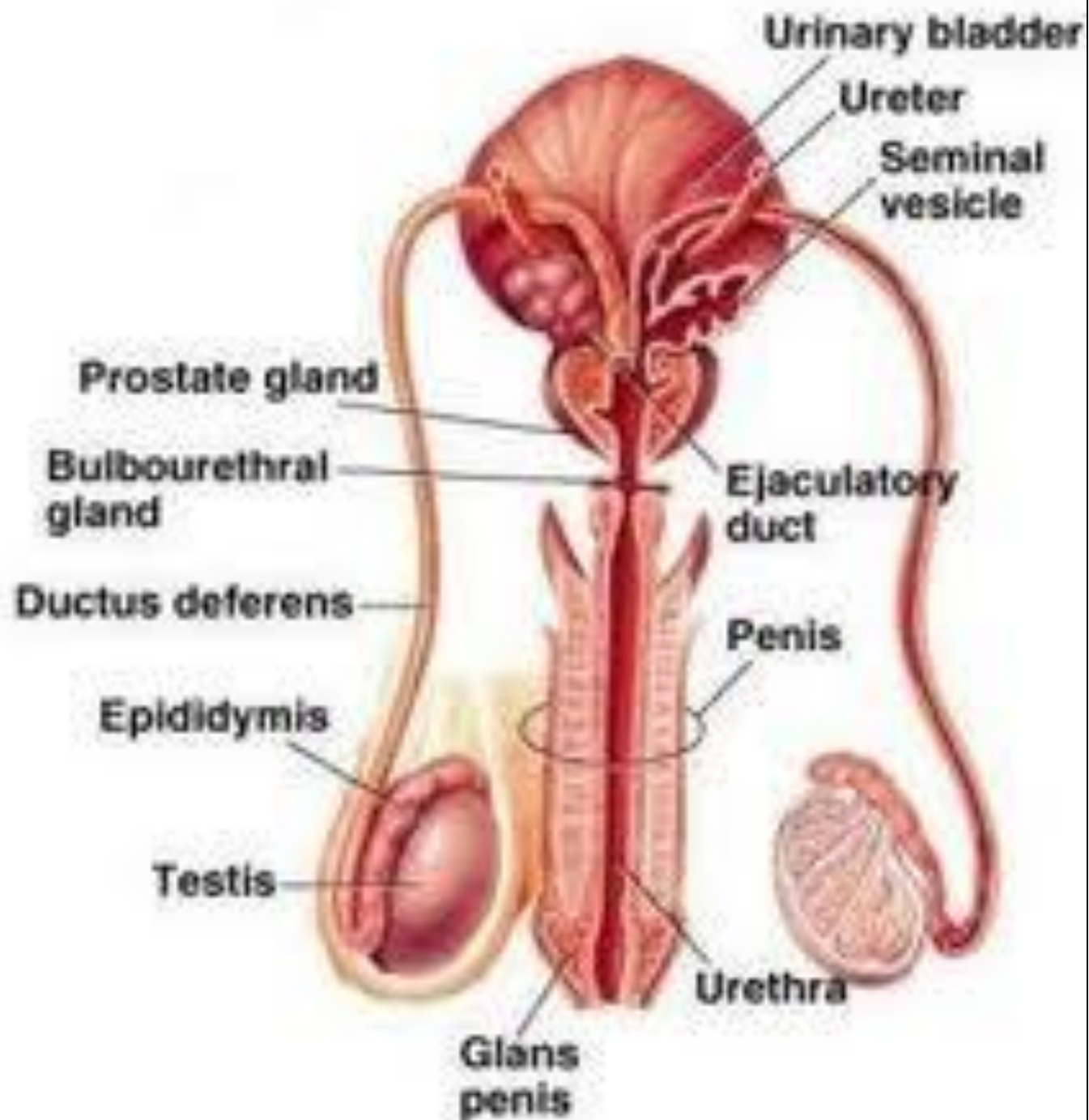
Spinous
tubercles

Dorsal
sacral
foramina

Coccyx
(tail bone)

Sacral hiatus







Poison oak



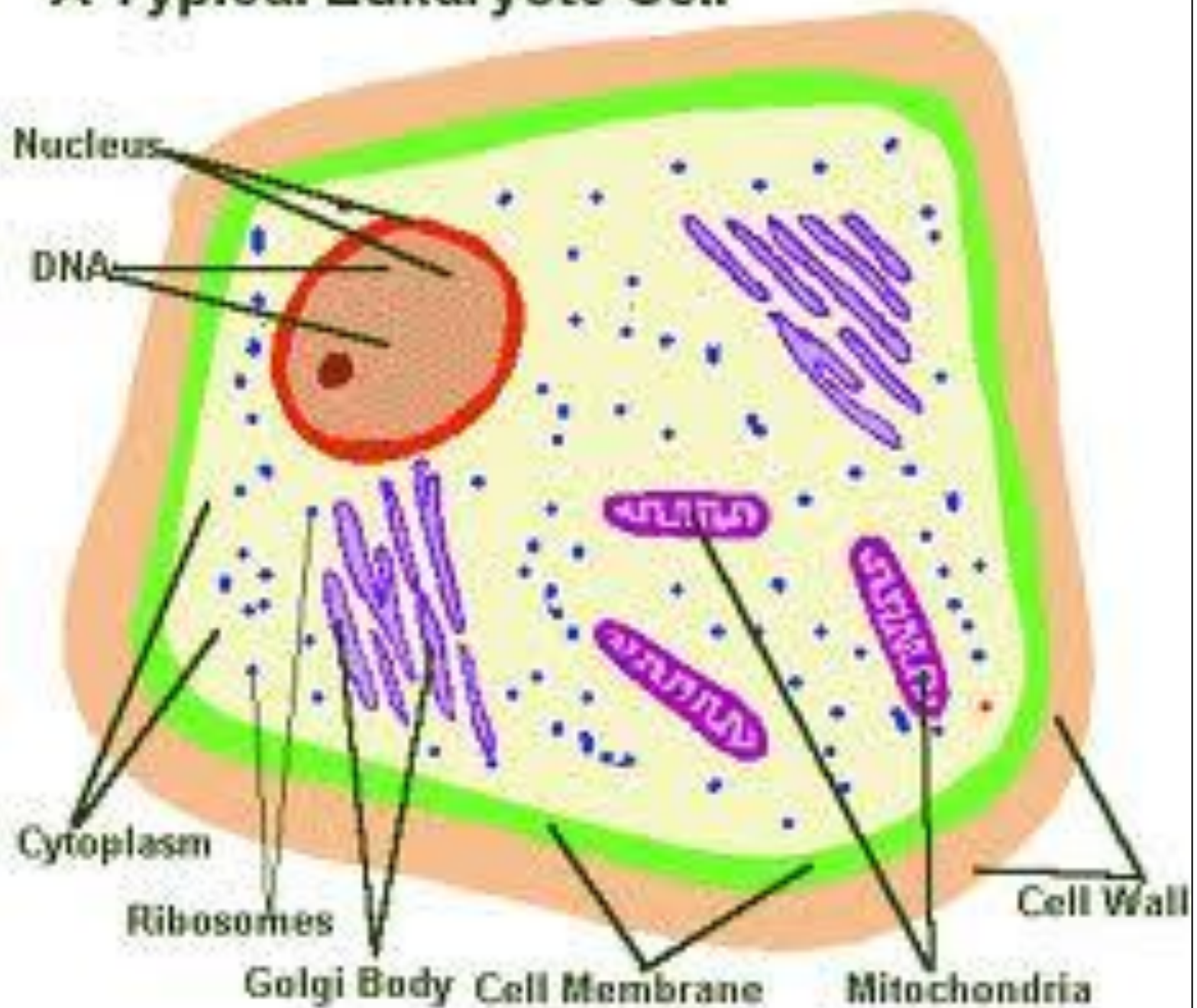
Poison sumac

Poison ivy

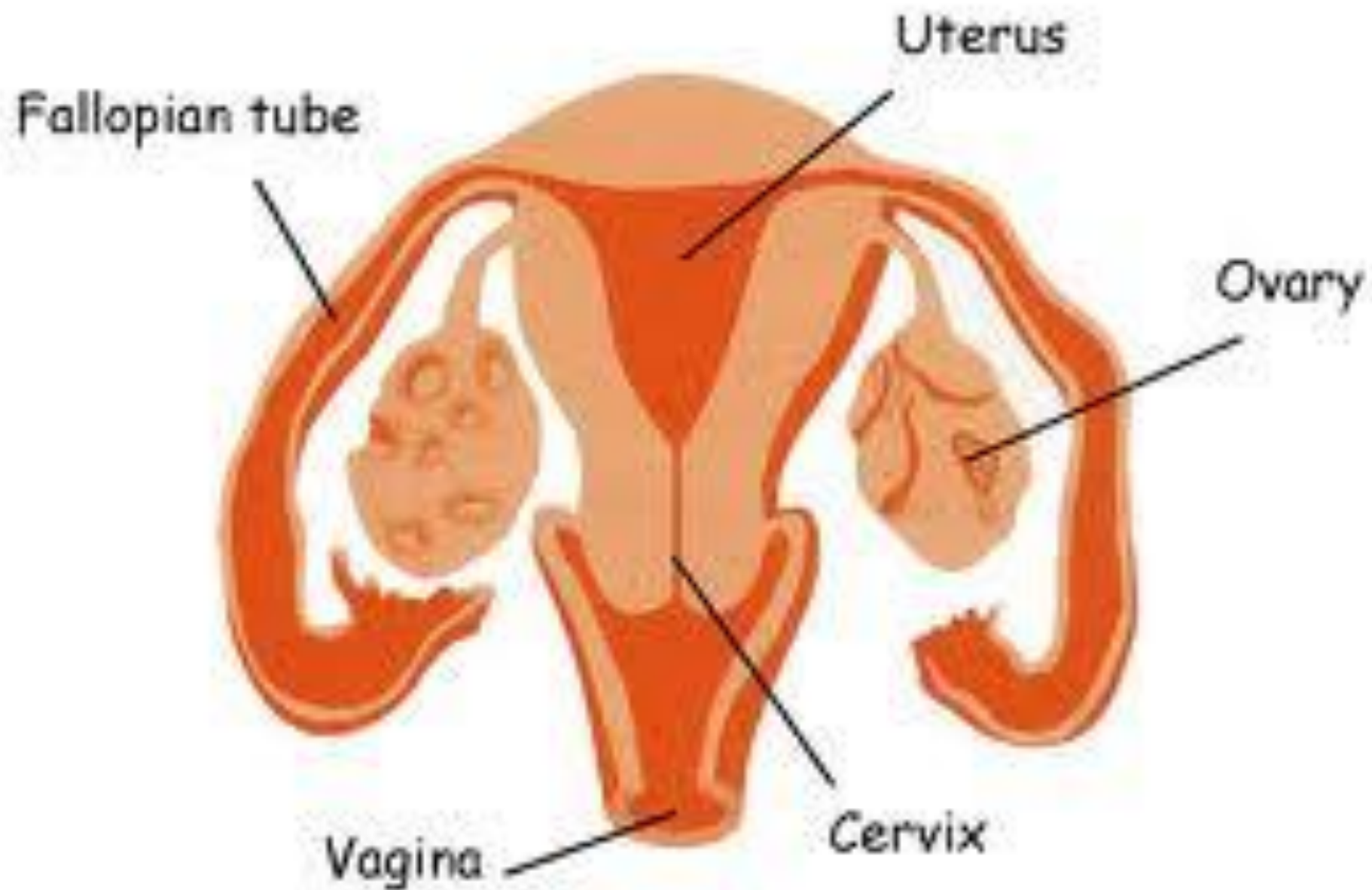




A Typical Eukaryote Cell

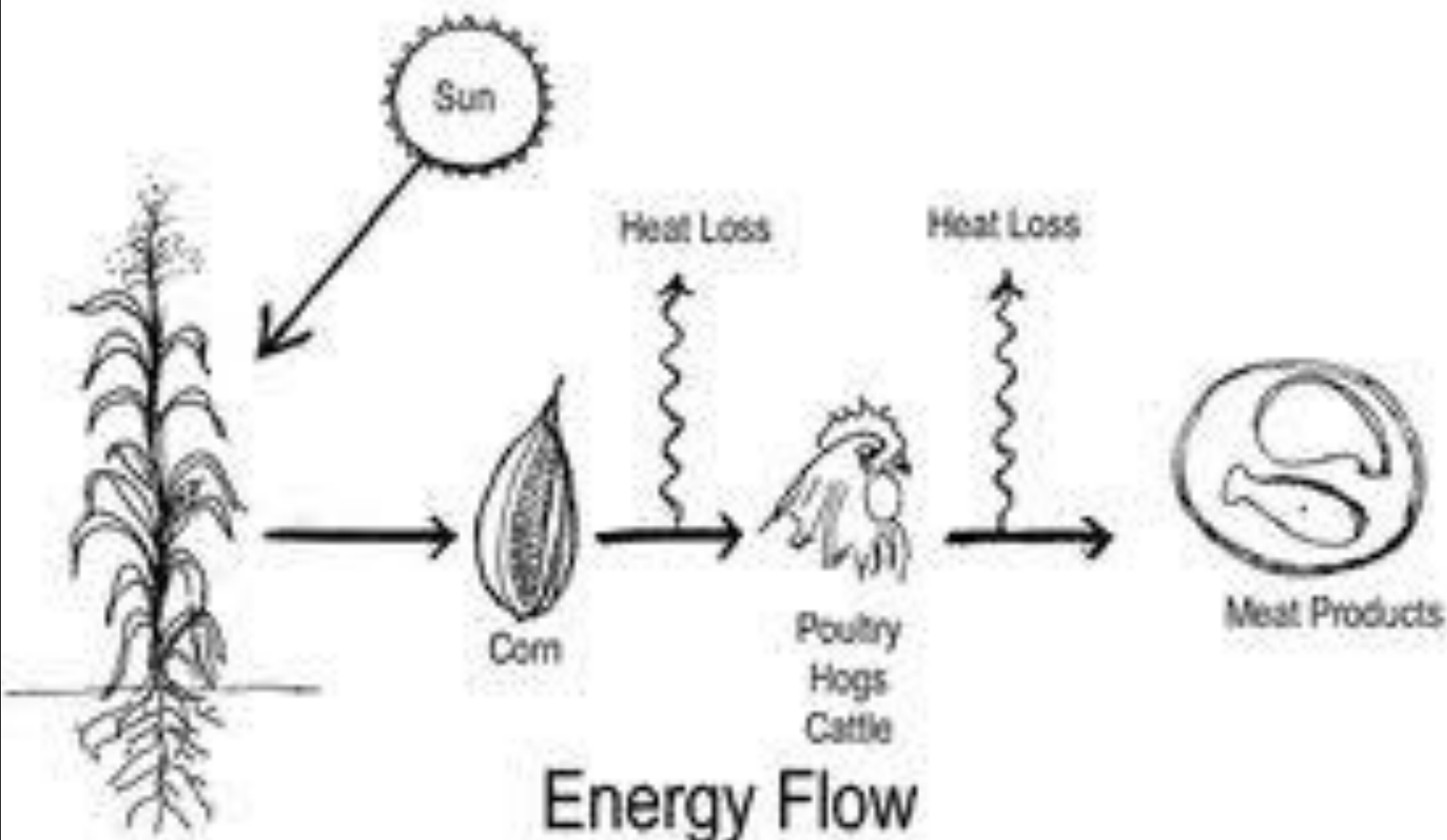


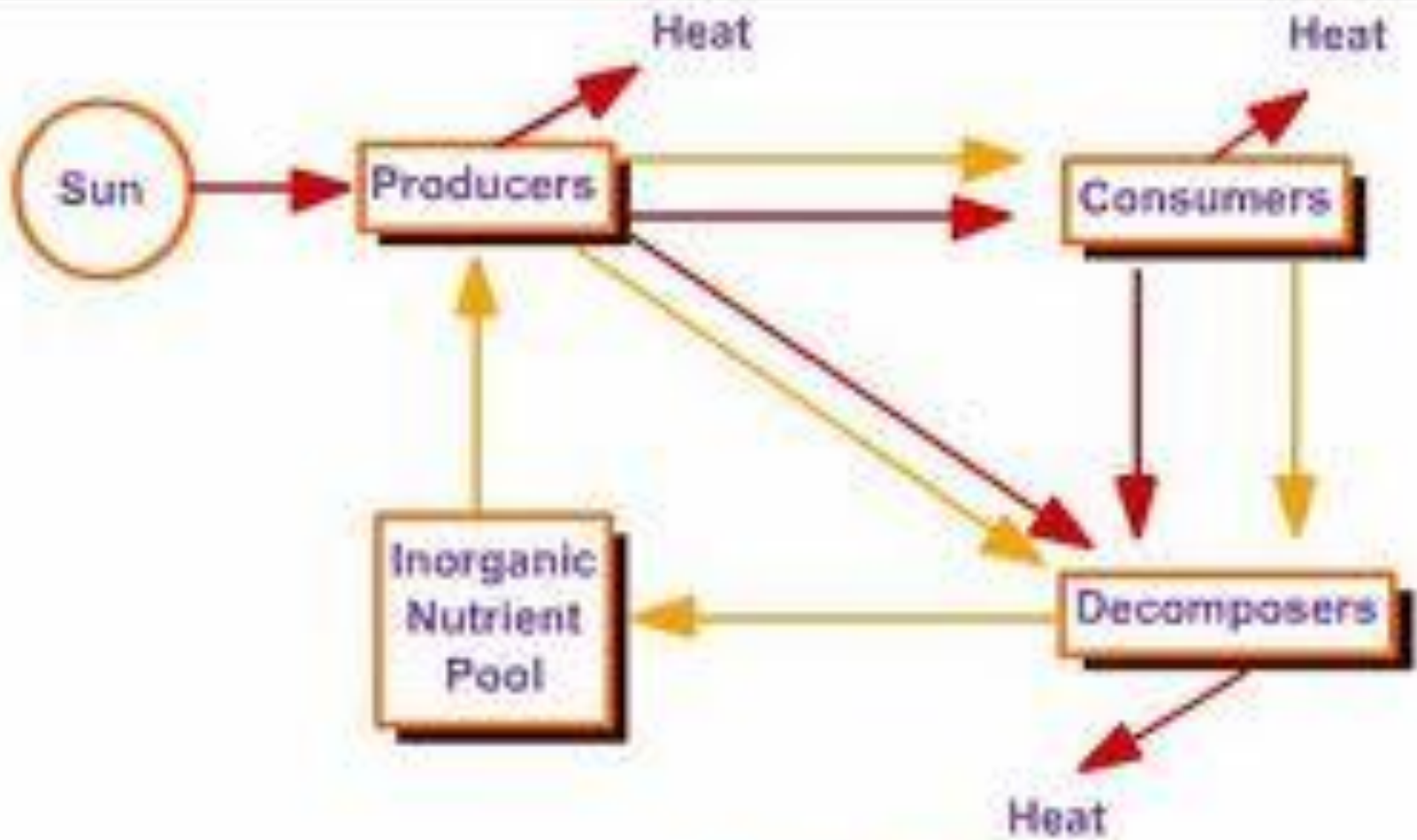




Medicinal Plants

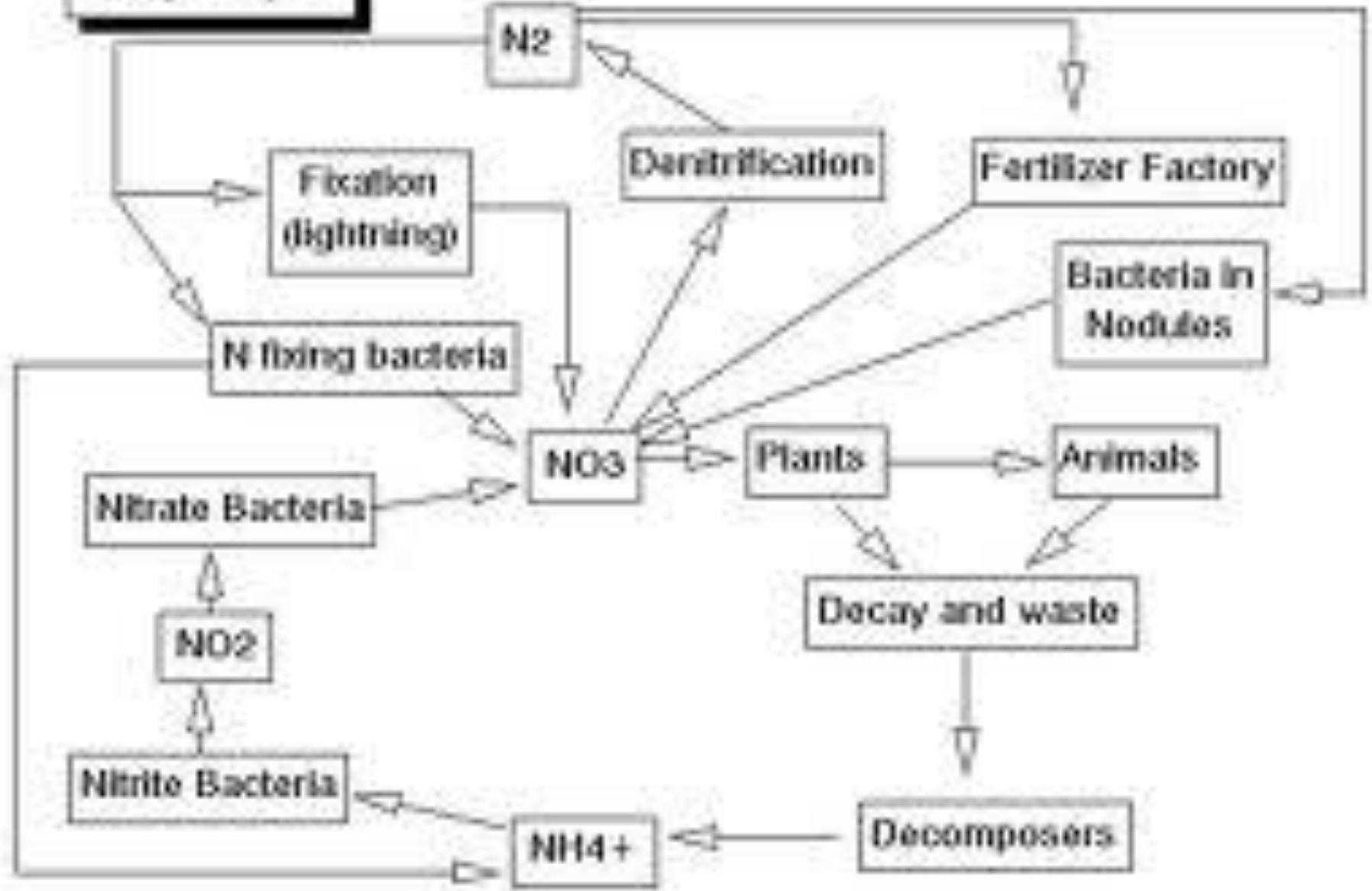






Energy Flow

Nitrogen Cycle



THE NITROGEN CYCLE

Fish waste

Nitrate Buildup

NO_2
Nitrite

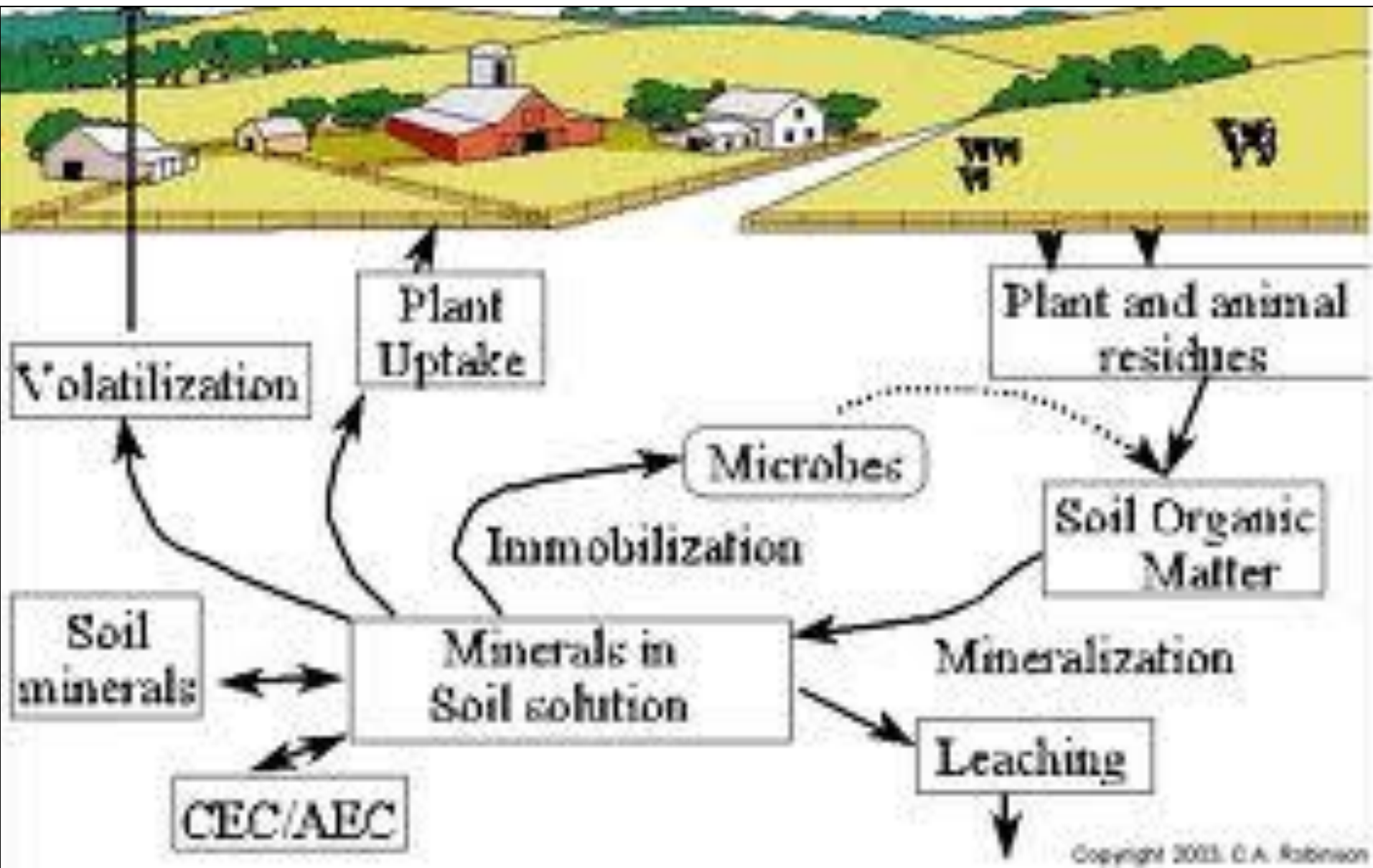
NO_3
Nitrate

NH_3
Ammonia

Plant waste

Plant fertilizer





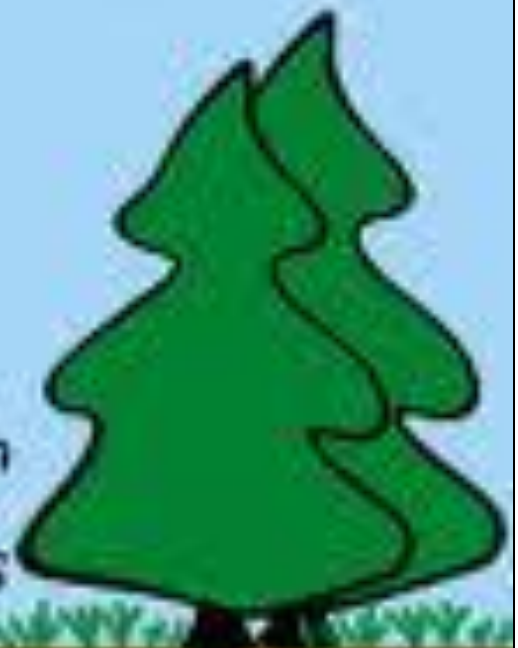

nitrogen in the atmosphere

nitrogen in animal proteins



nitrogen in plant proteins

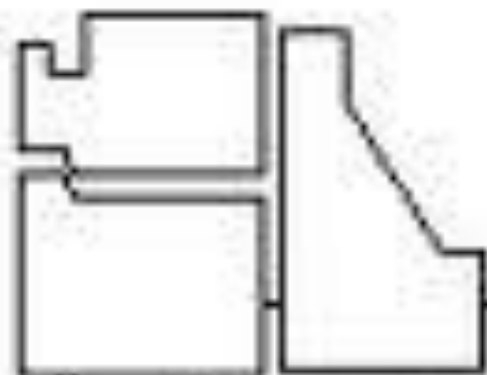


nitrogen in decaying matter and waste




bacteria "fix" nitrogen for use by plants





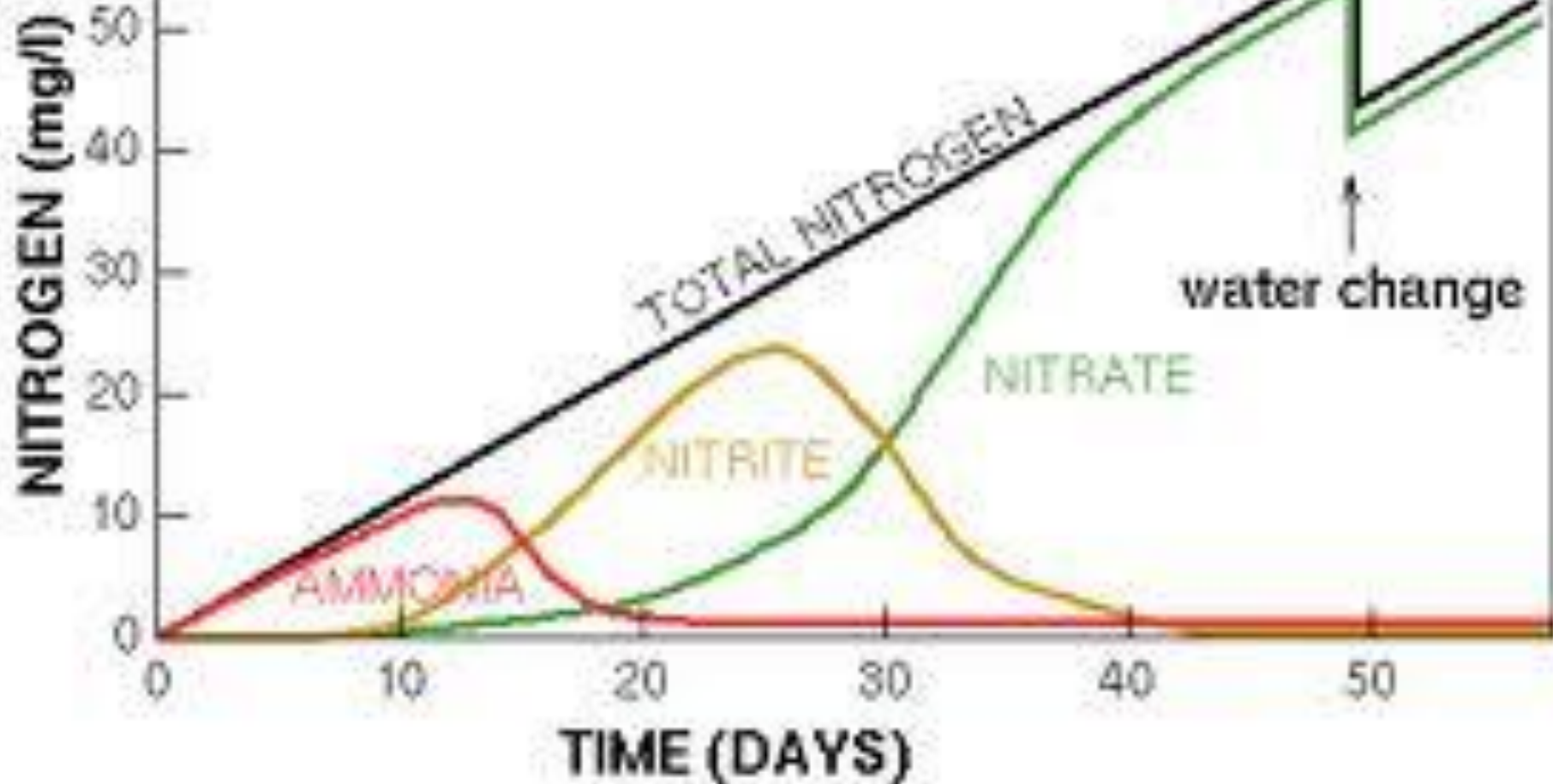
THE NITROGEN CYCLE

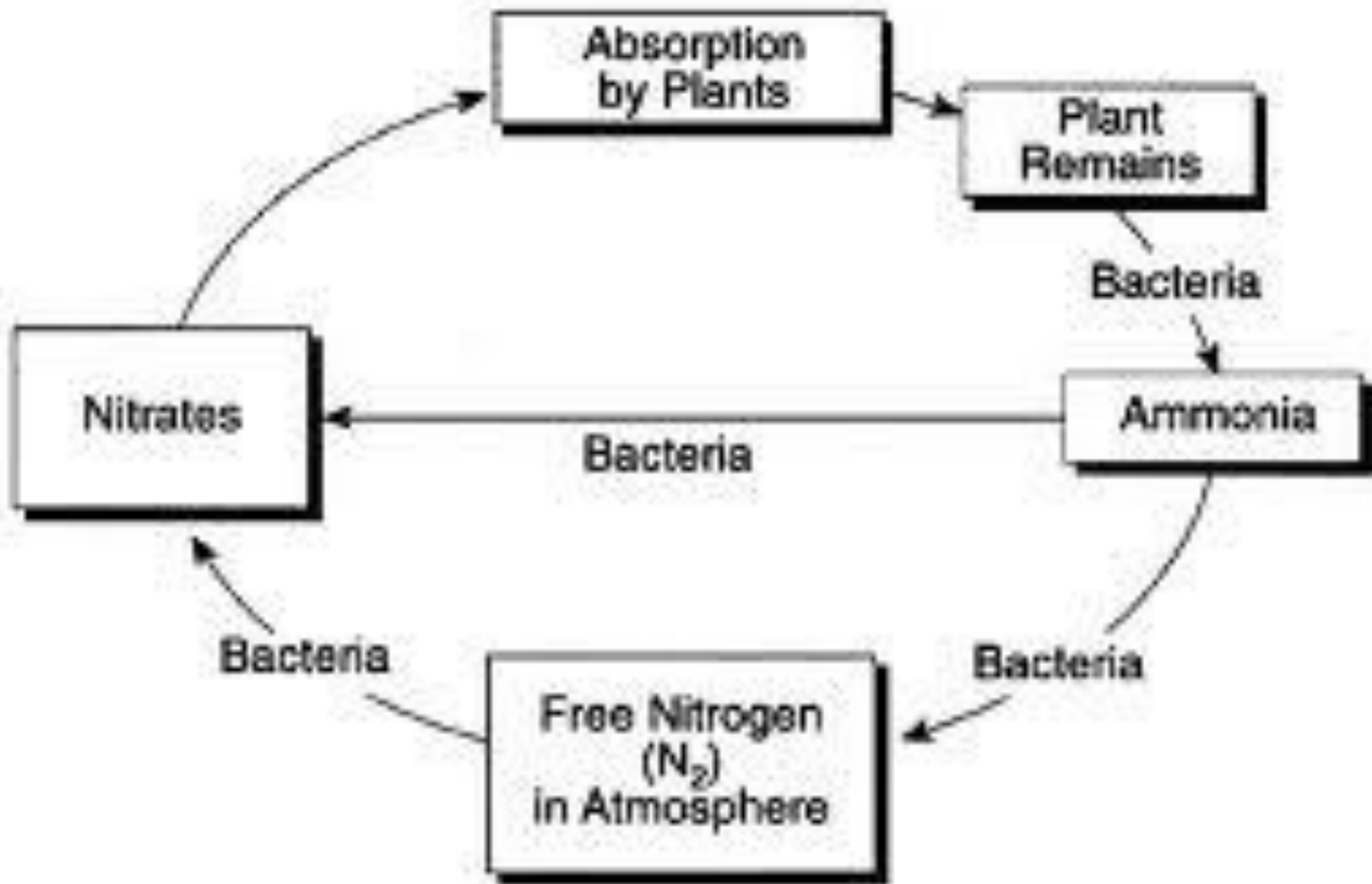
- ▶ Complex cycle of chemical pathways that trace N transformations and movement in an ecosystem
- ▶ Problems occur when some forms of N leak from the system

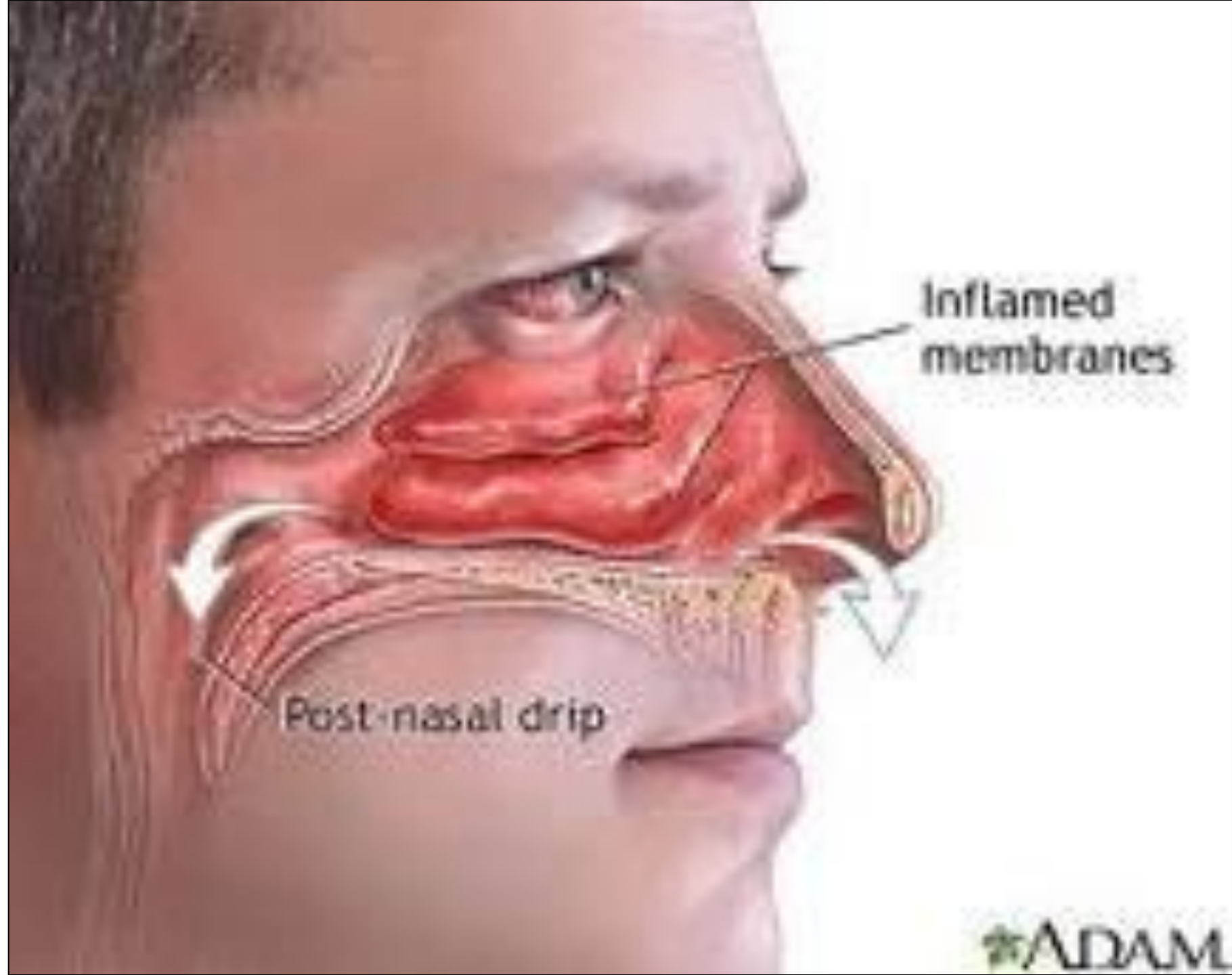

Cycling of a New Tank (after Spotte)

(numbers are for illustration; your mileage will vary!)

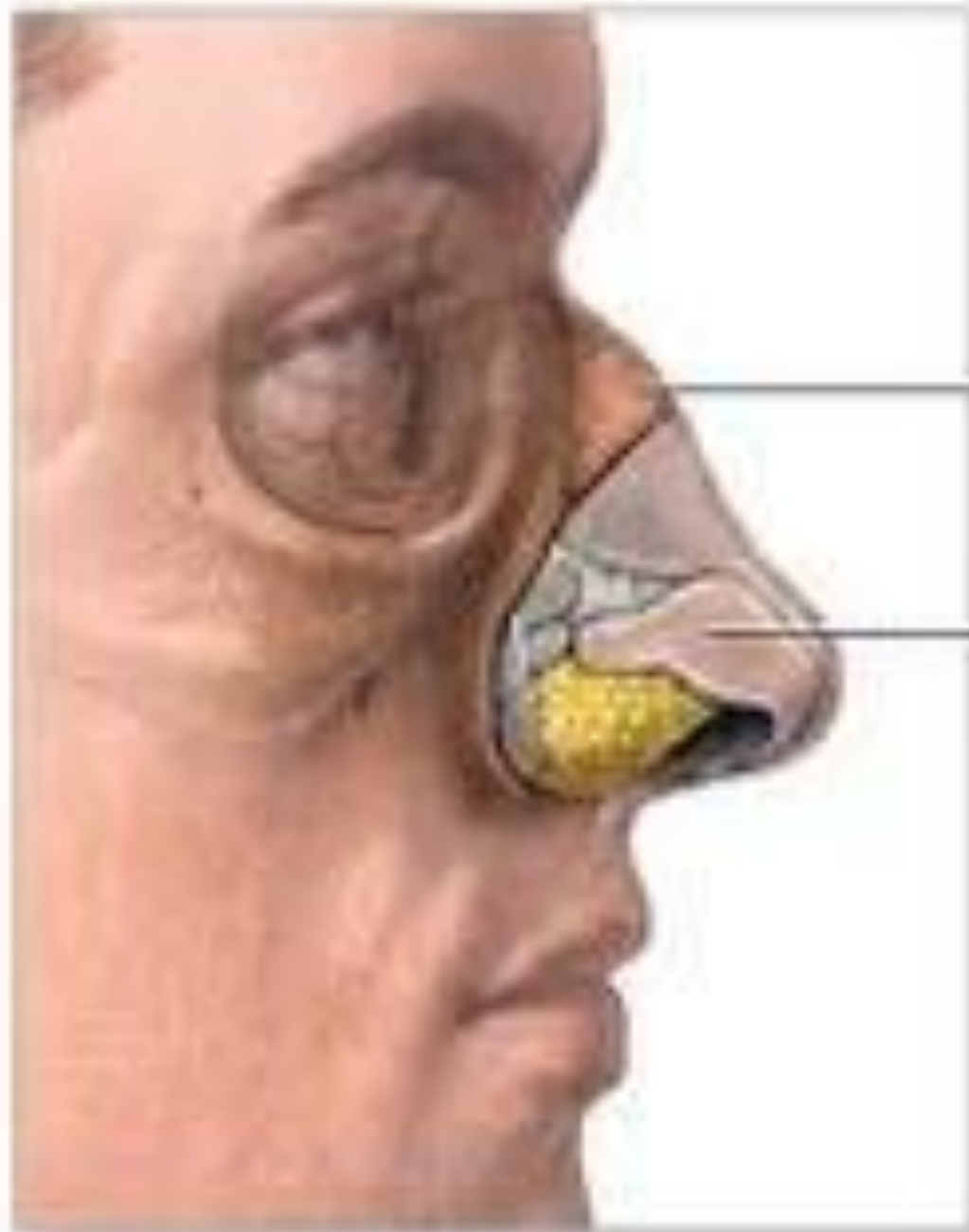






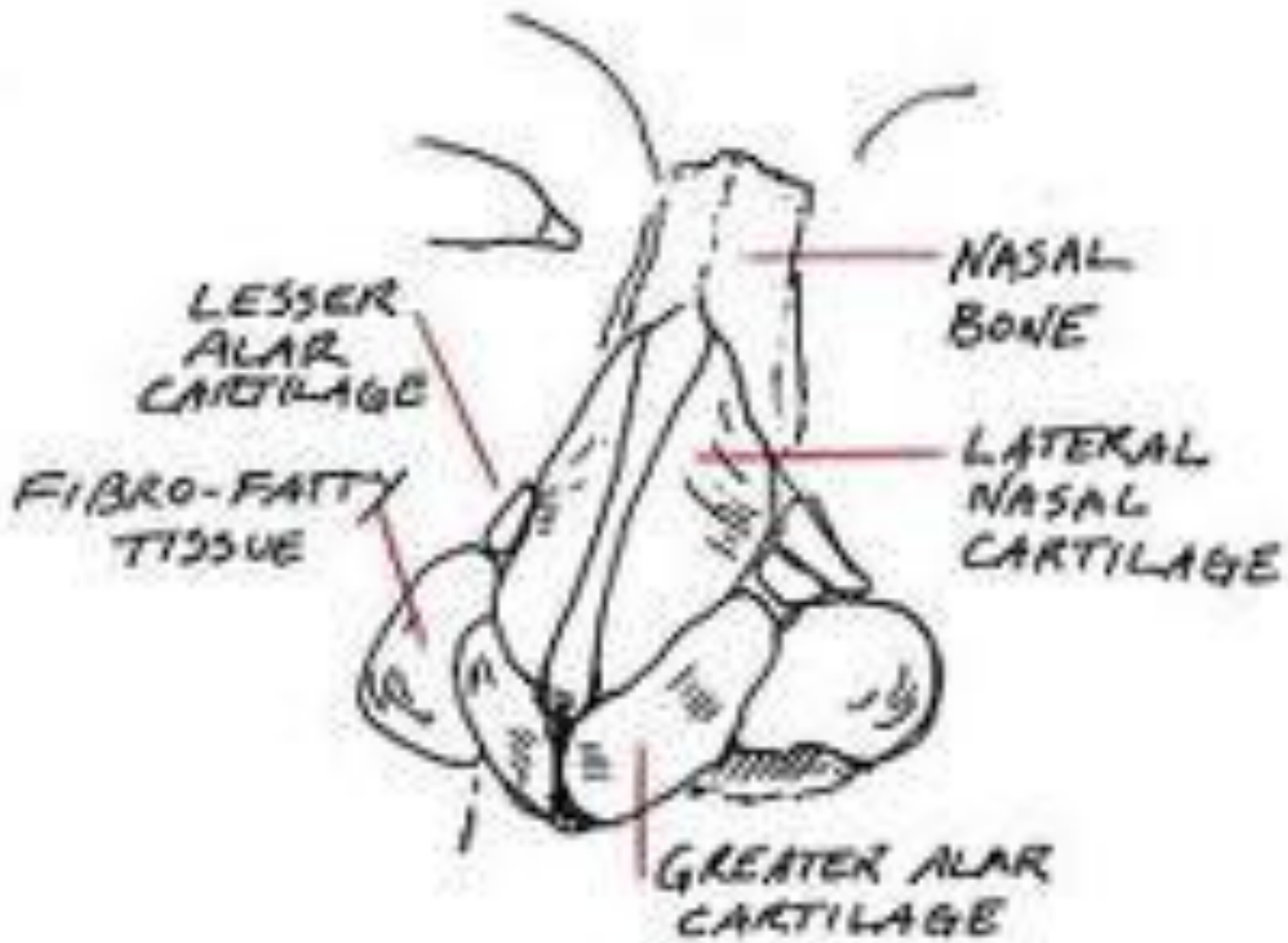
Inflamed membranes

Post-nasal drip



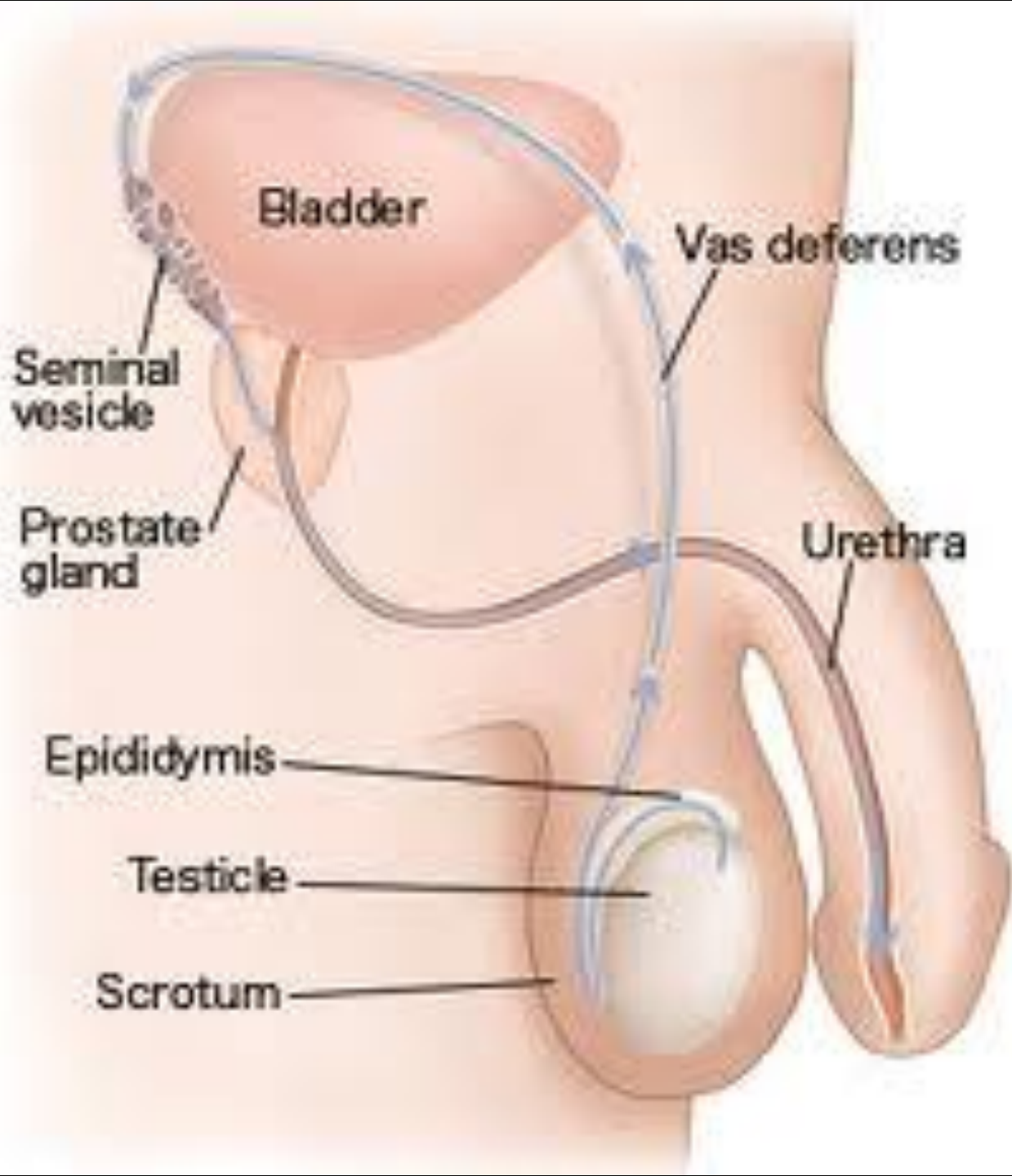Dorsal hump

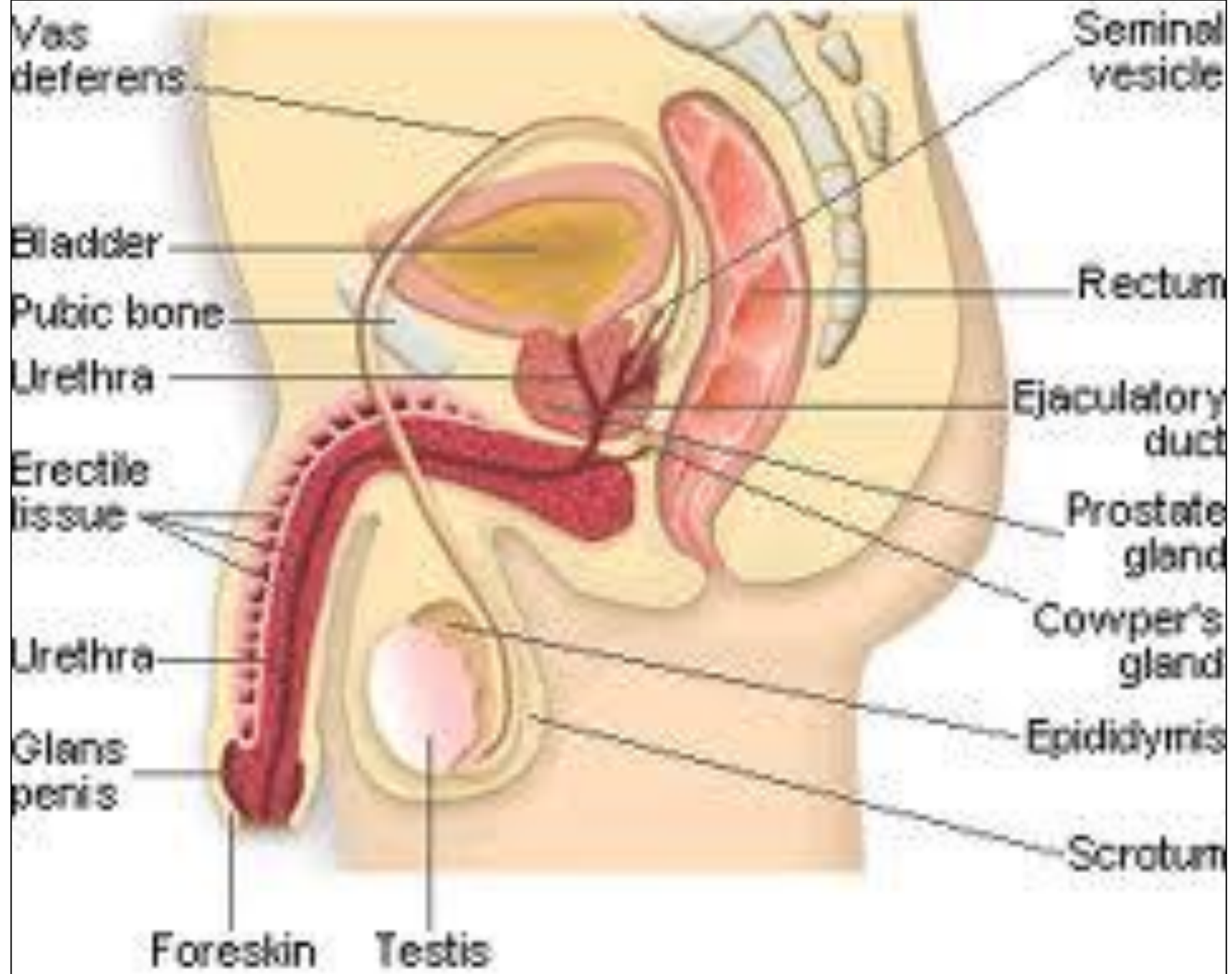
Cartilage

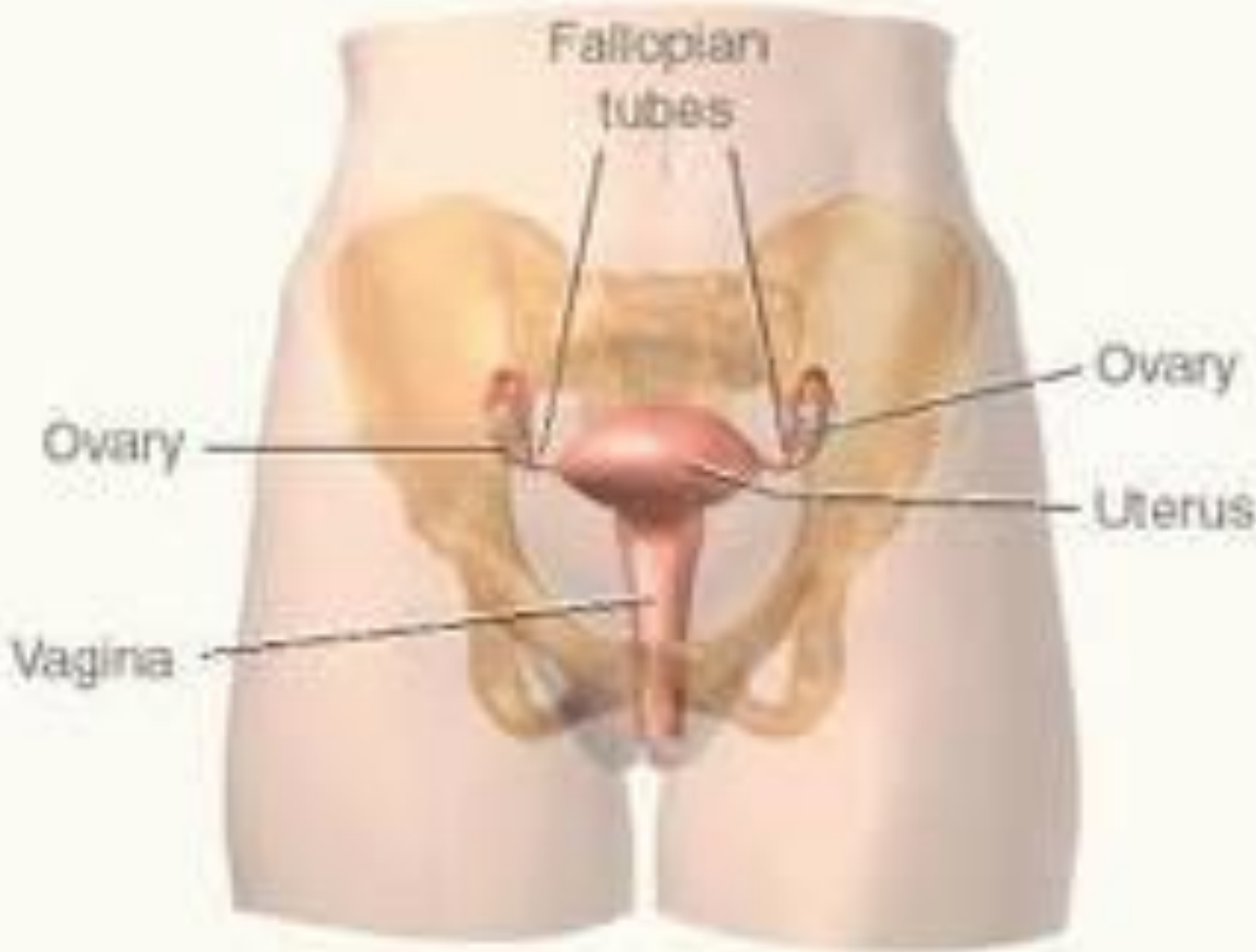











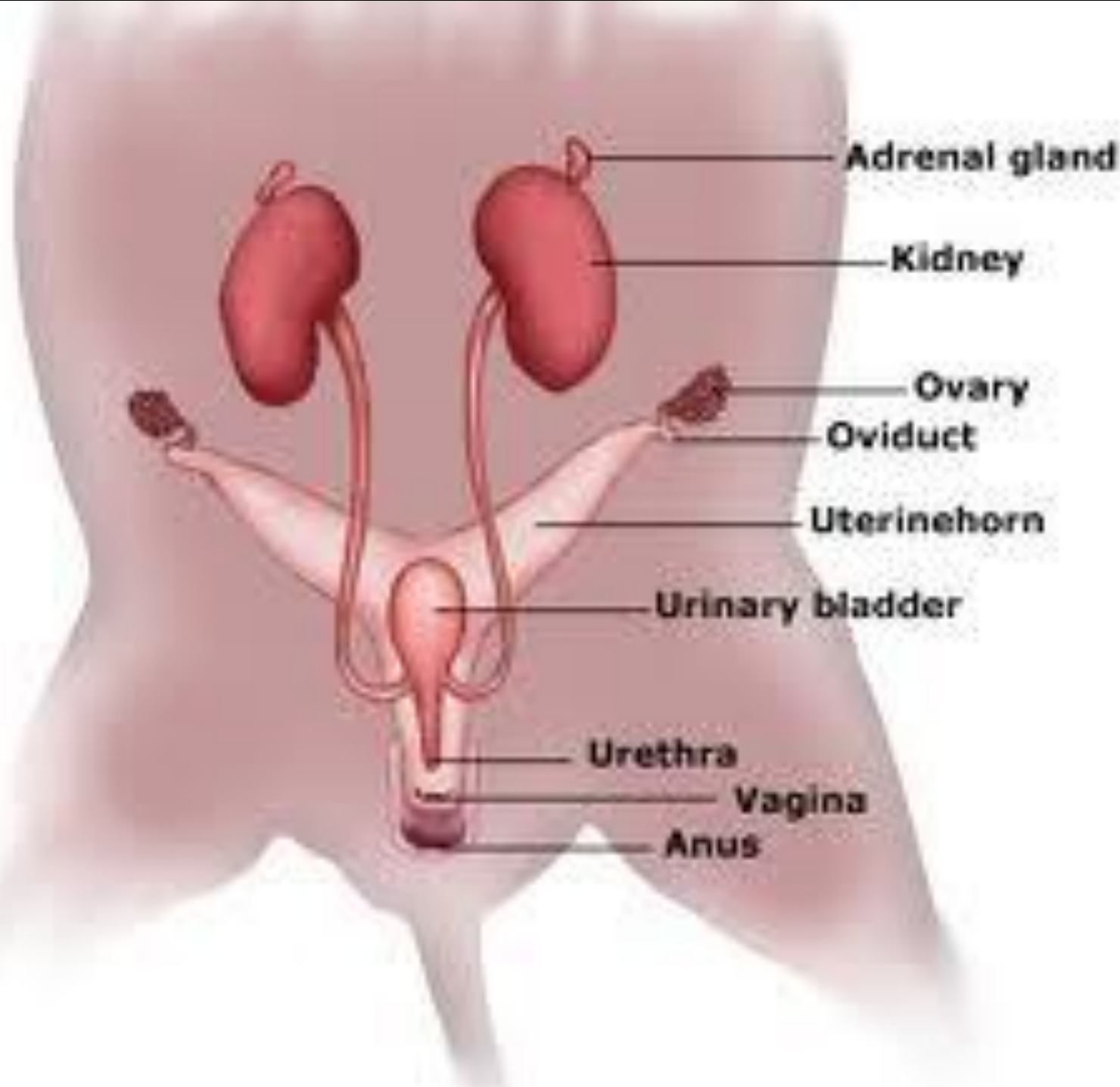
Fallopian
tubes

Ovary

Ovary

Uterus

Vagina



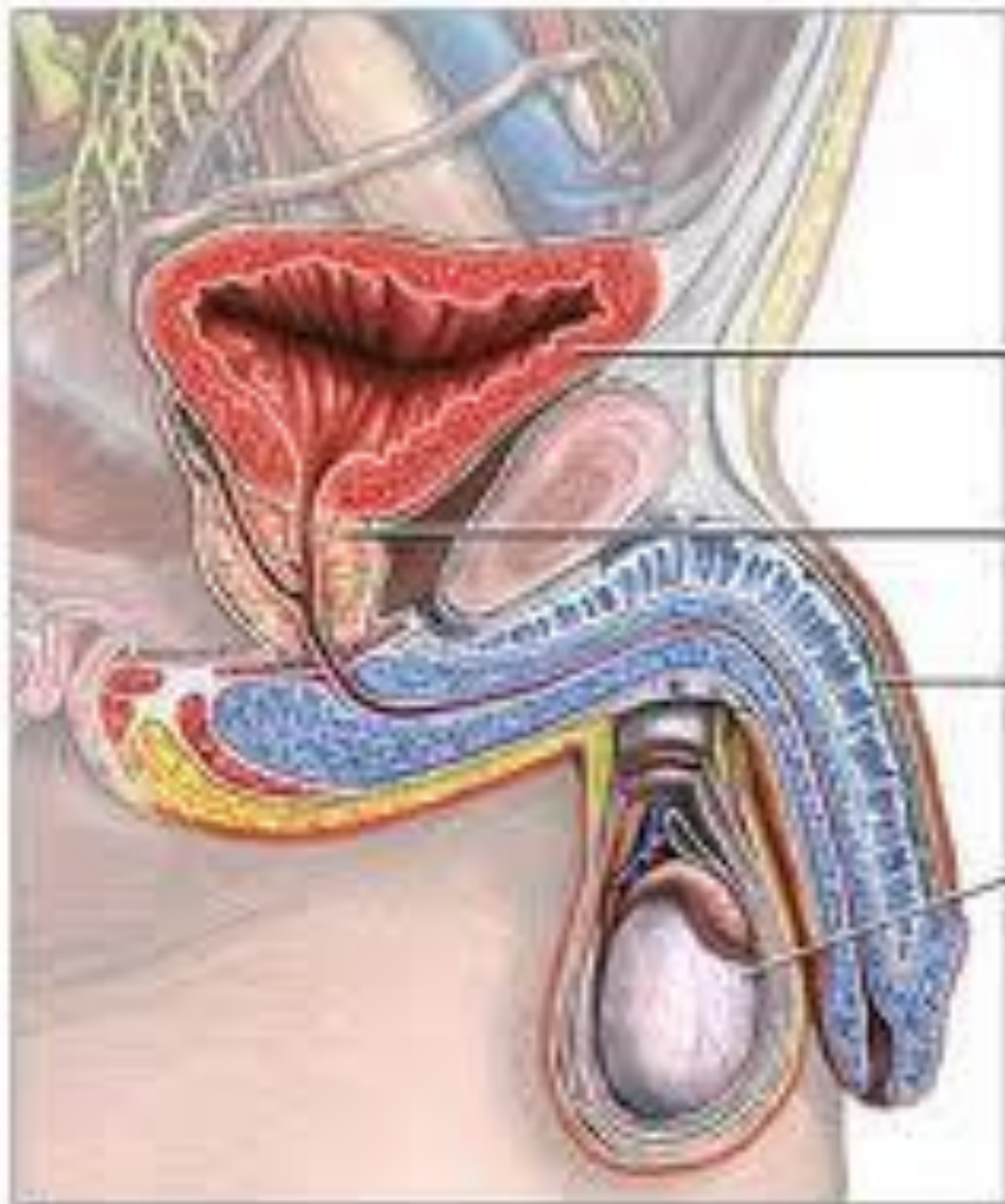
Young male reproductive system

Bladder

Prostate

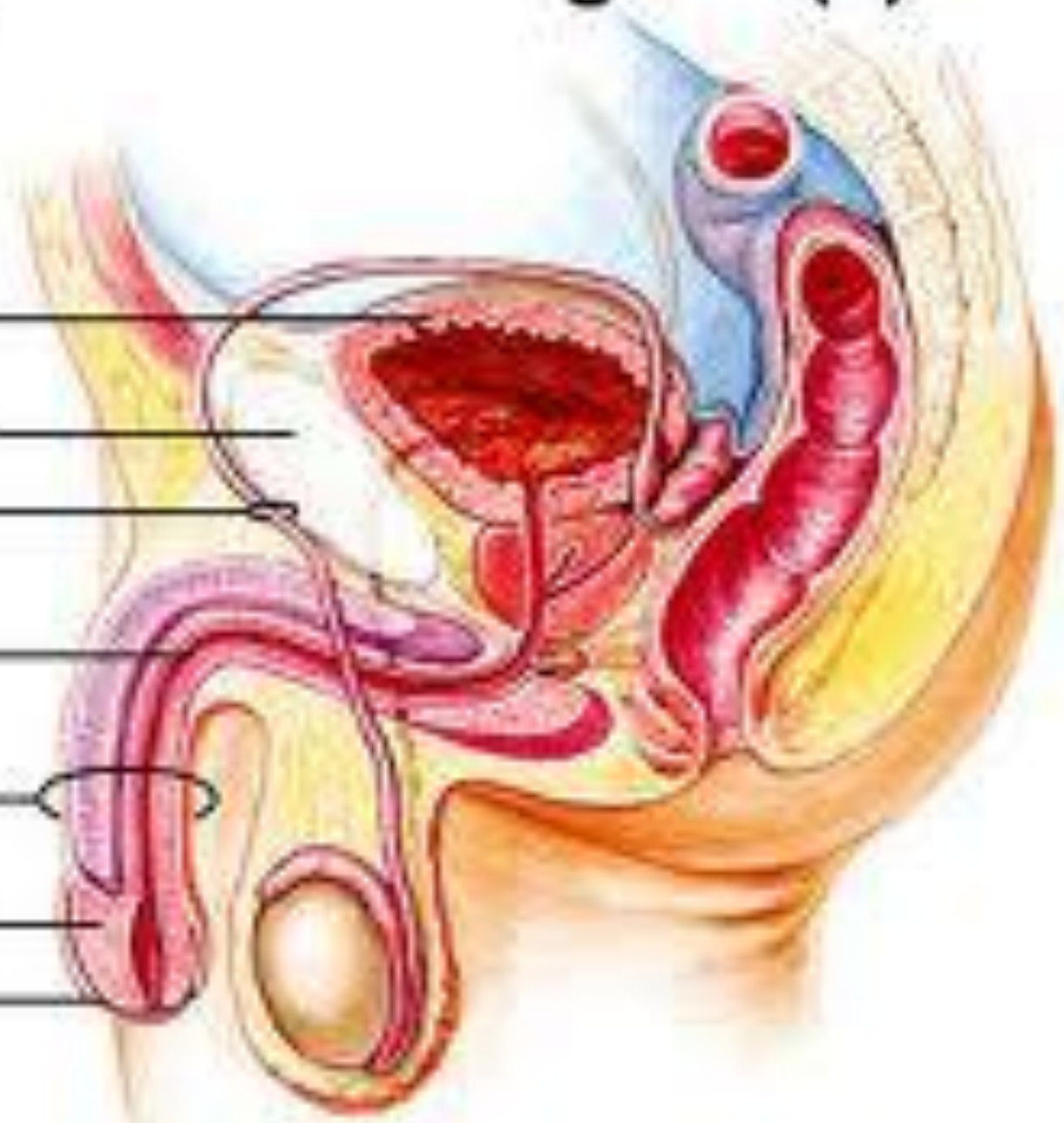
Penis

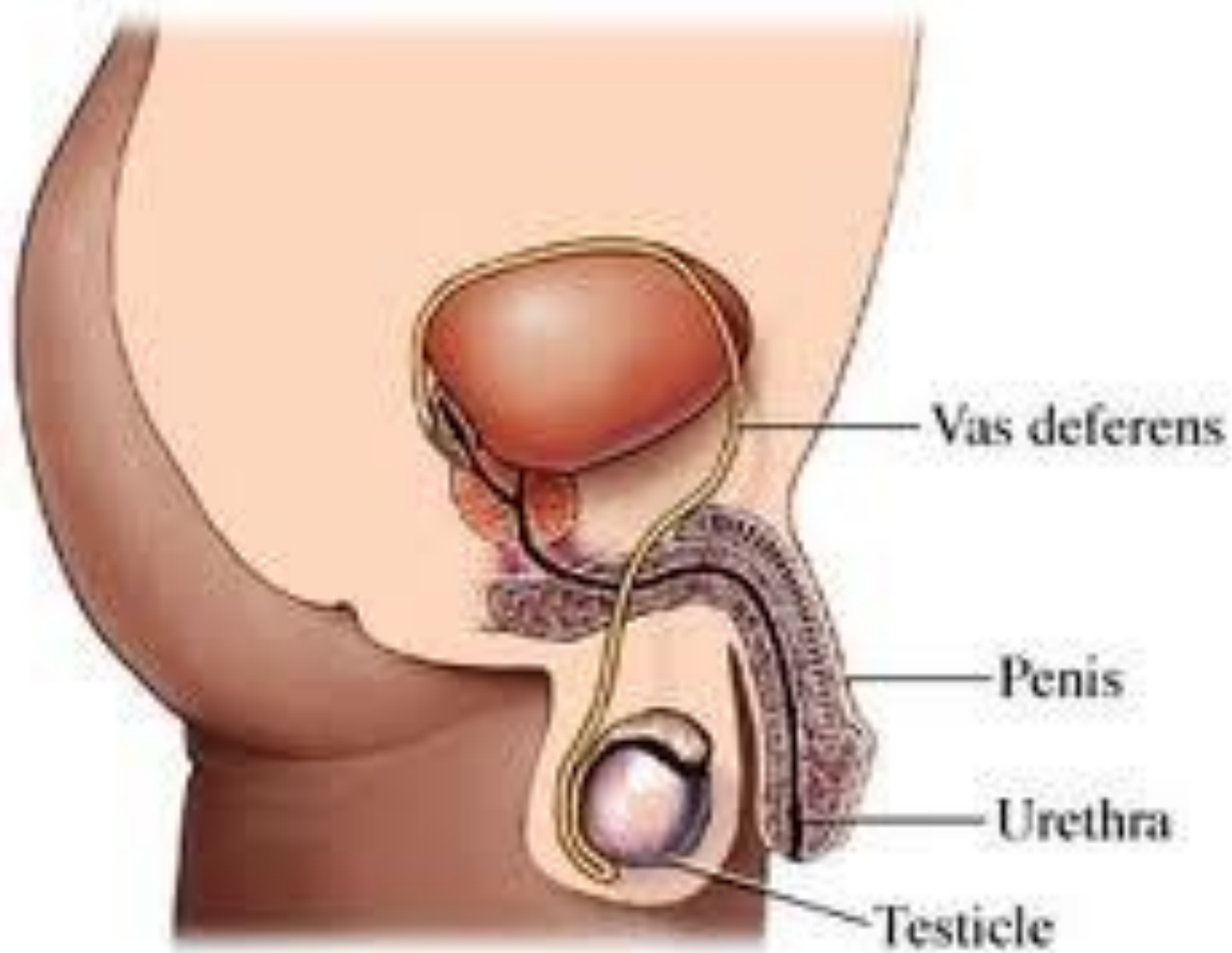
Testicle

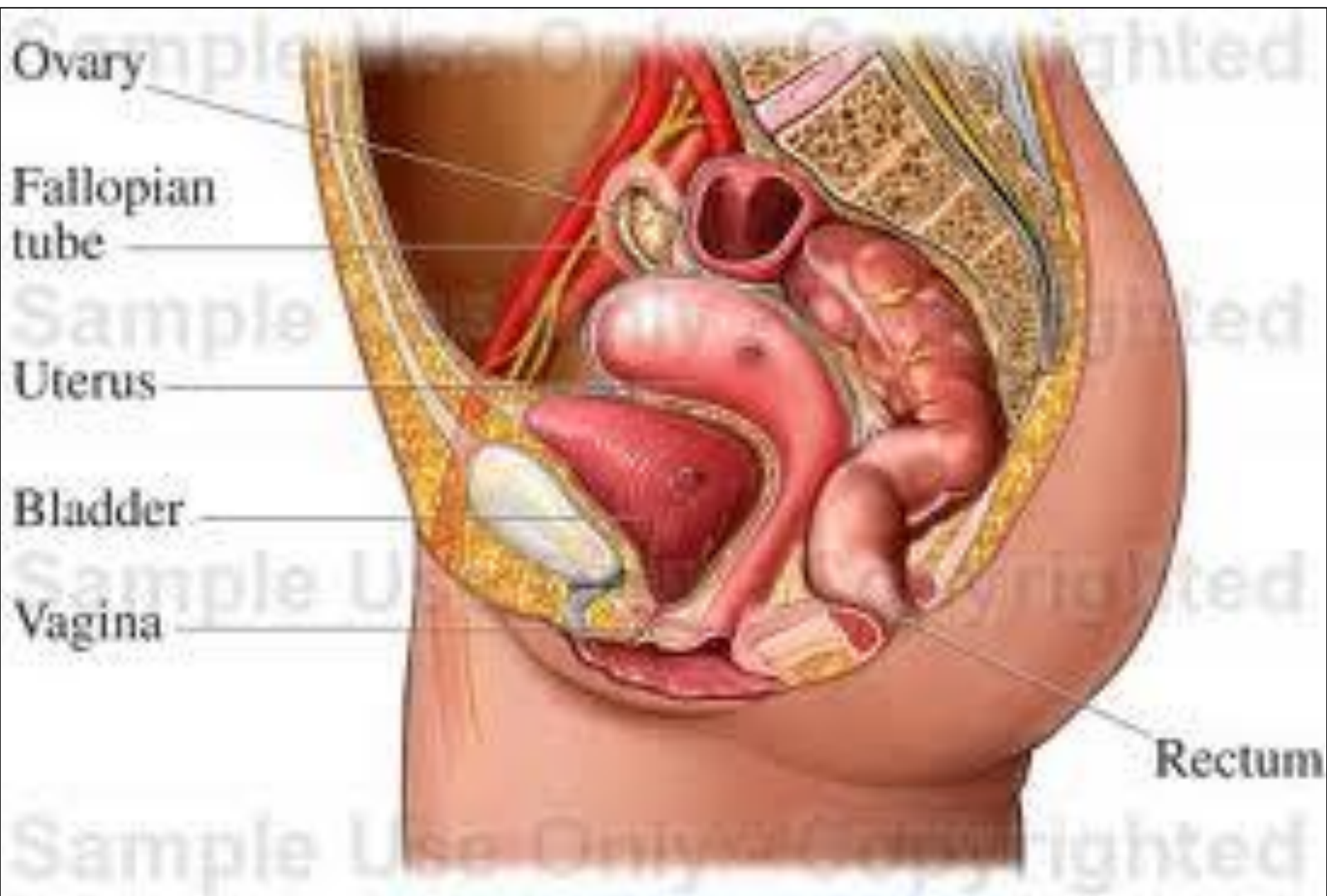


Male Reproductive Organs (1)

- Urinary bladder
- Symphysis pubis
- Vas deferens
- Urethra
- Penis
- Glans penis
- Prepuce







Ovary

Fallopian
tube

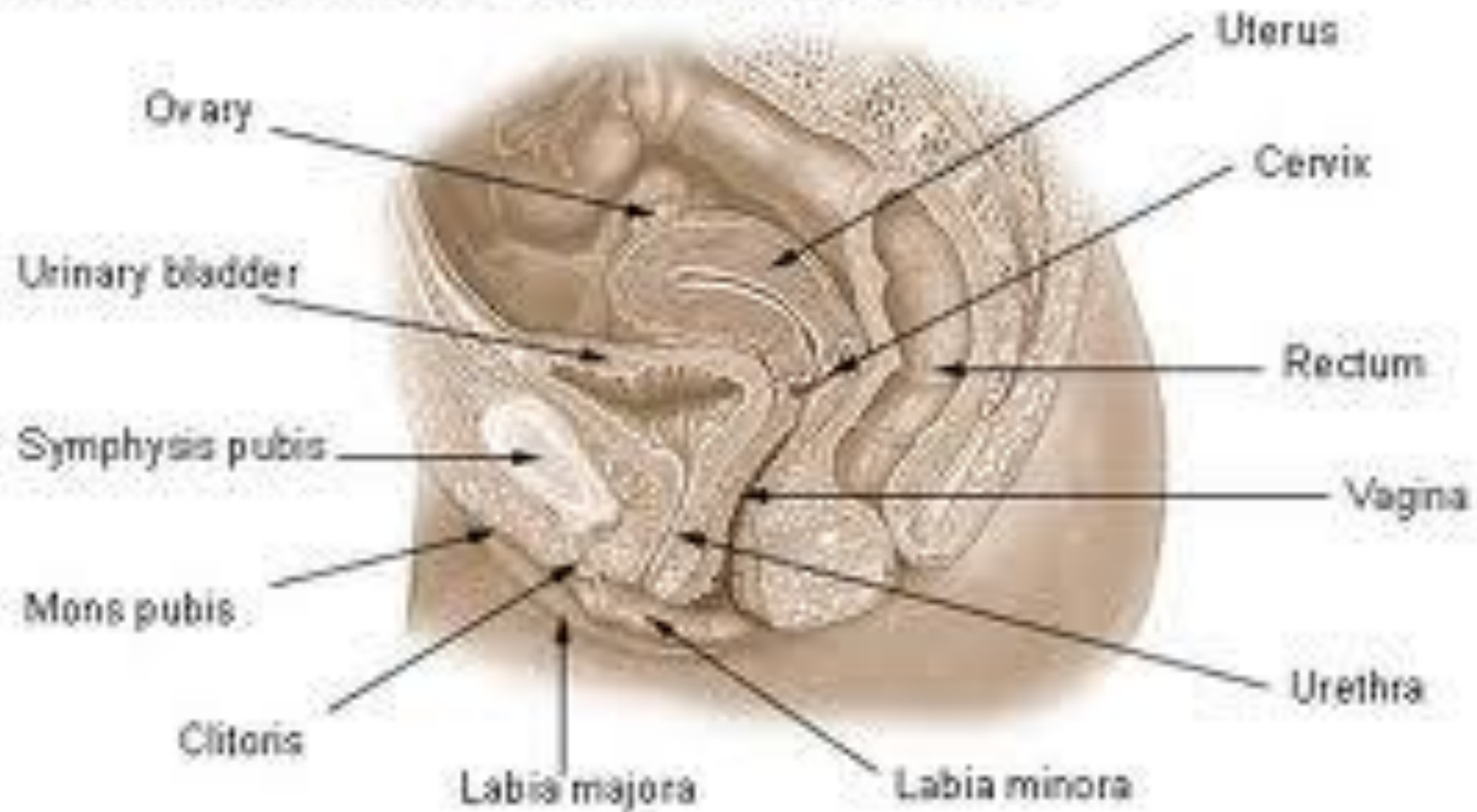
Uterus

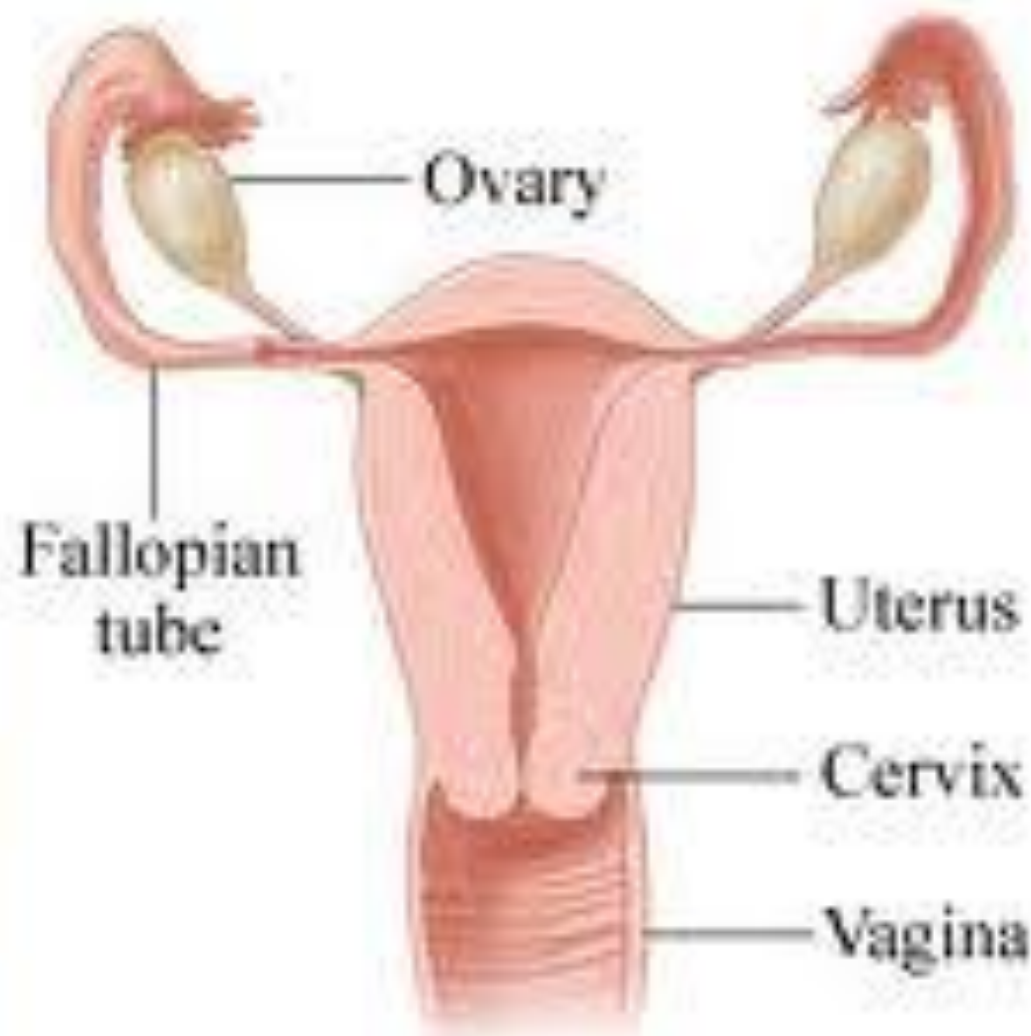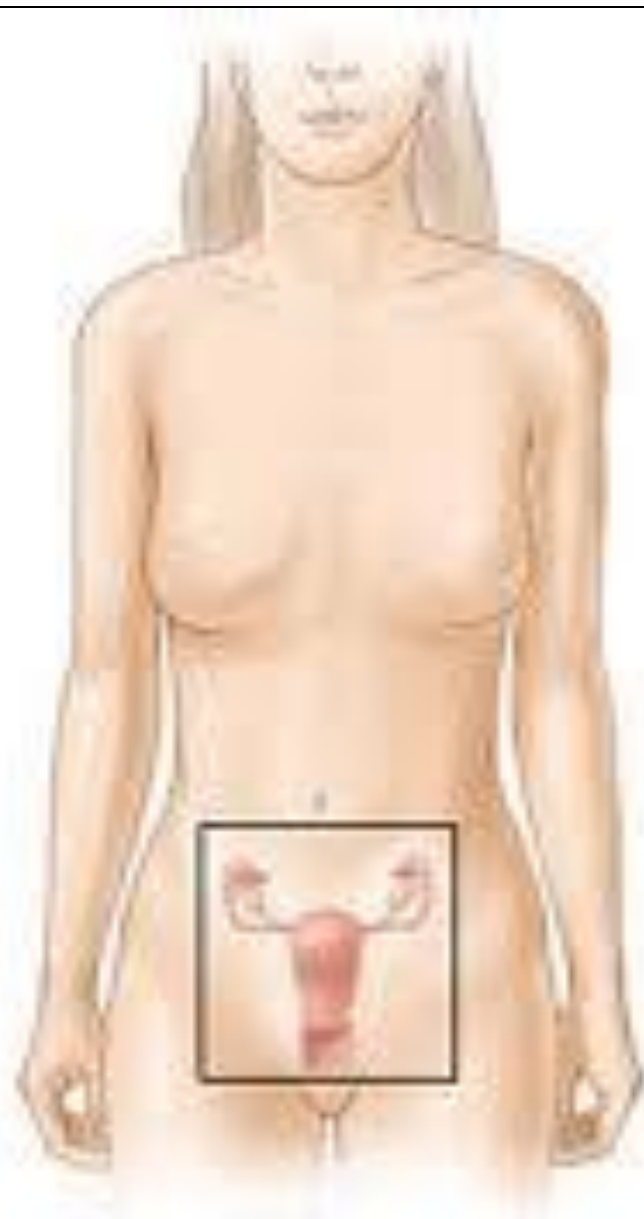Bladder

Vagina

Rectum

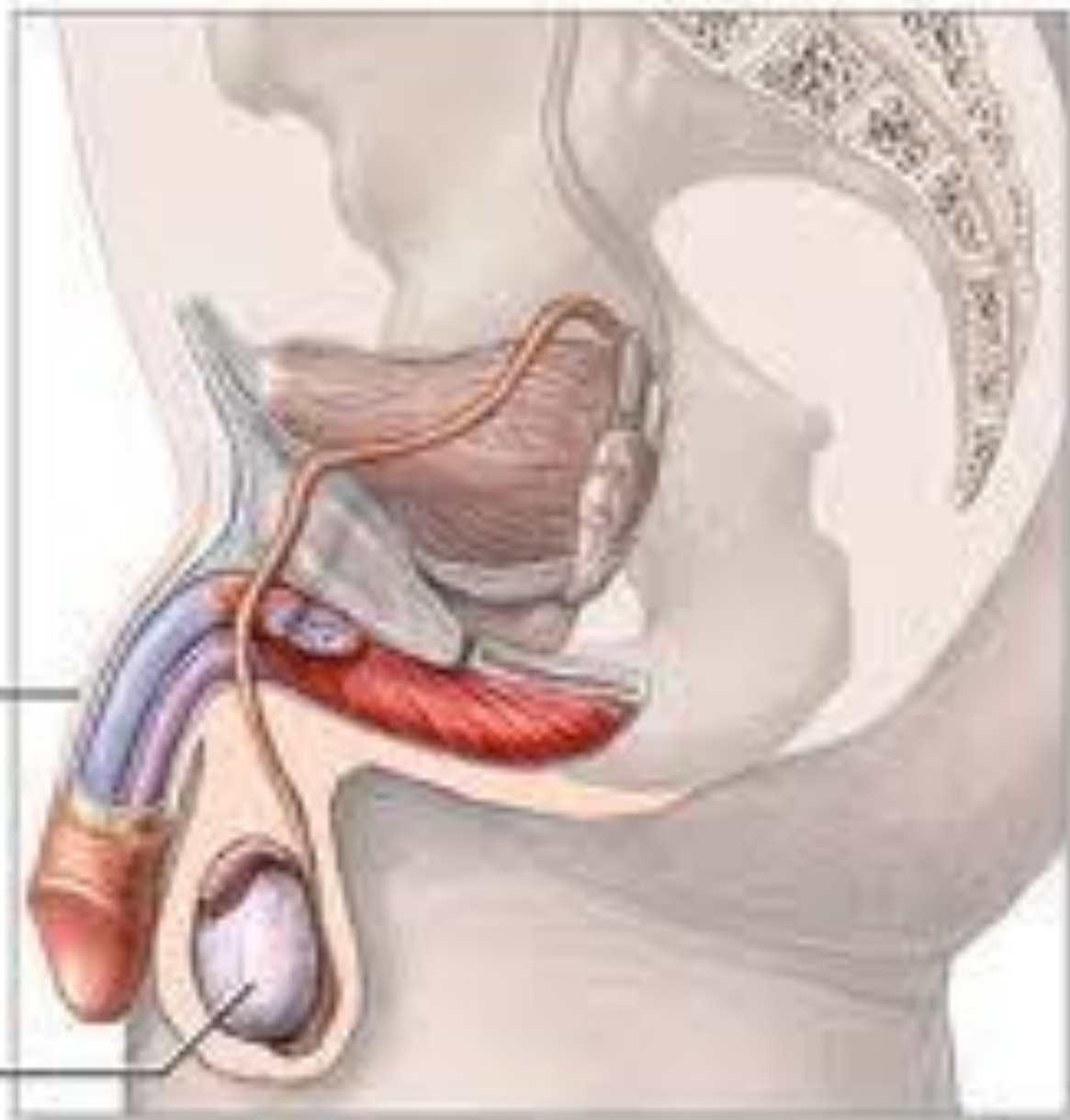
Organs of the Female Reproductive System

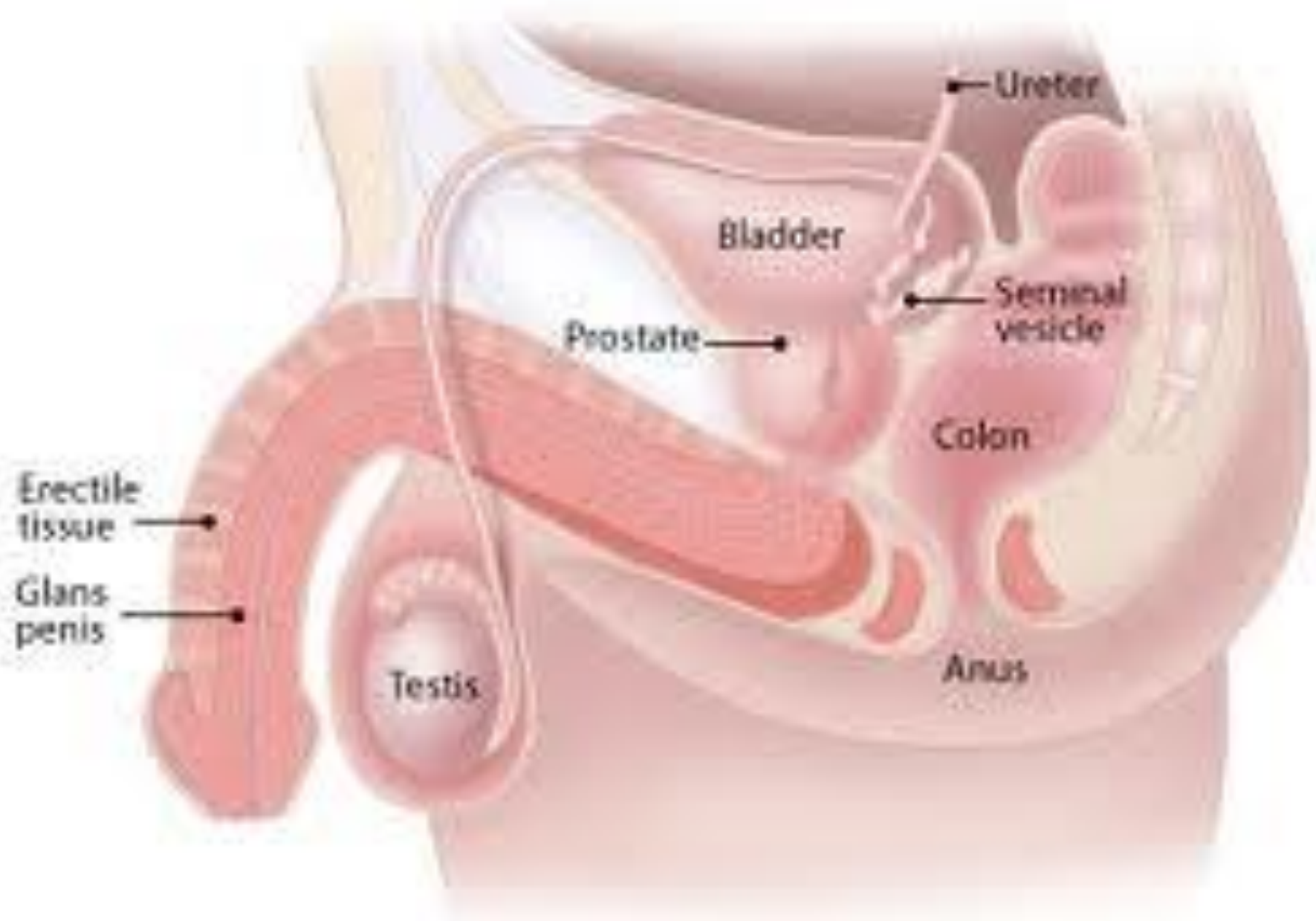


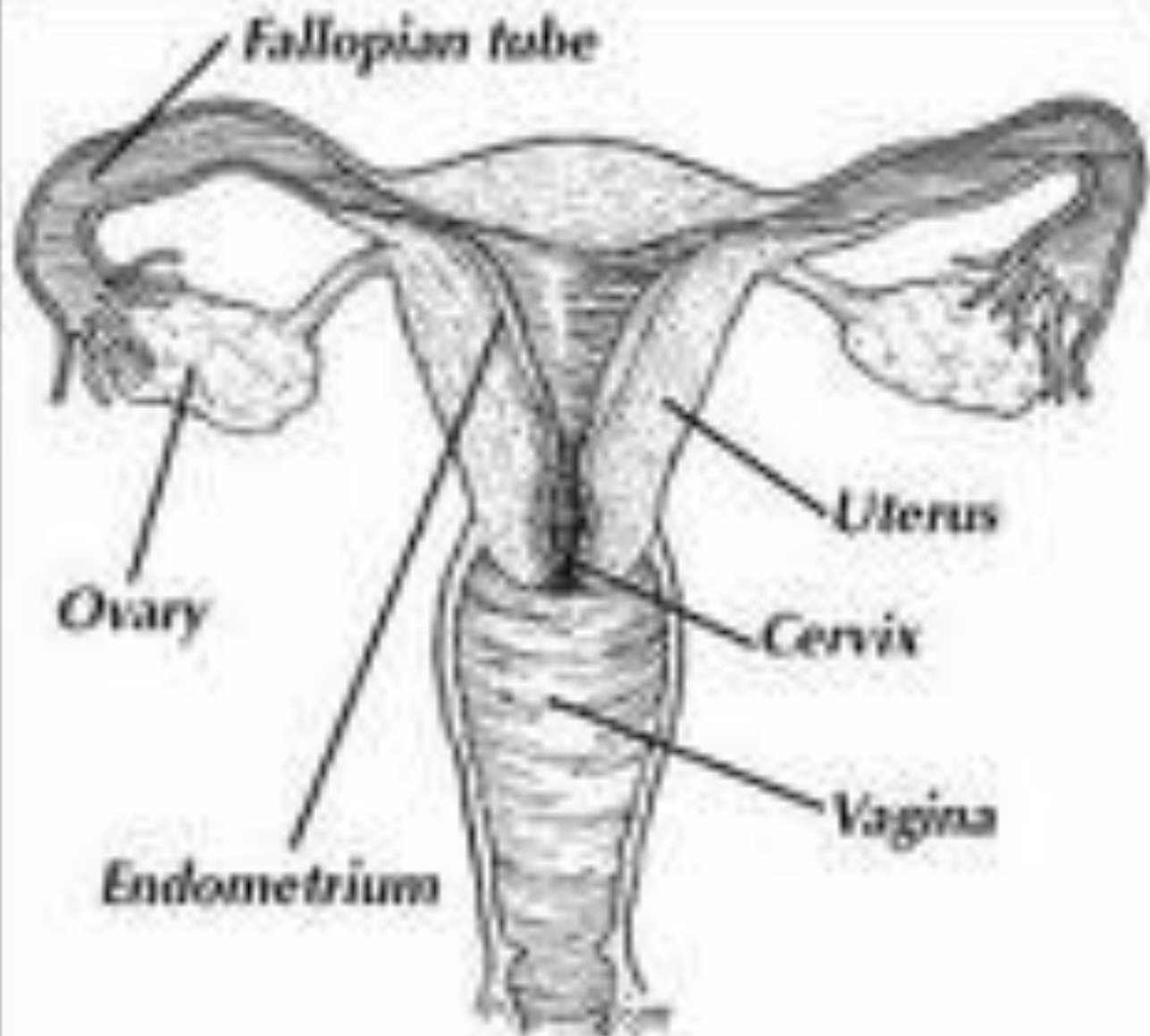


Penis

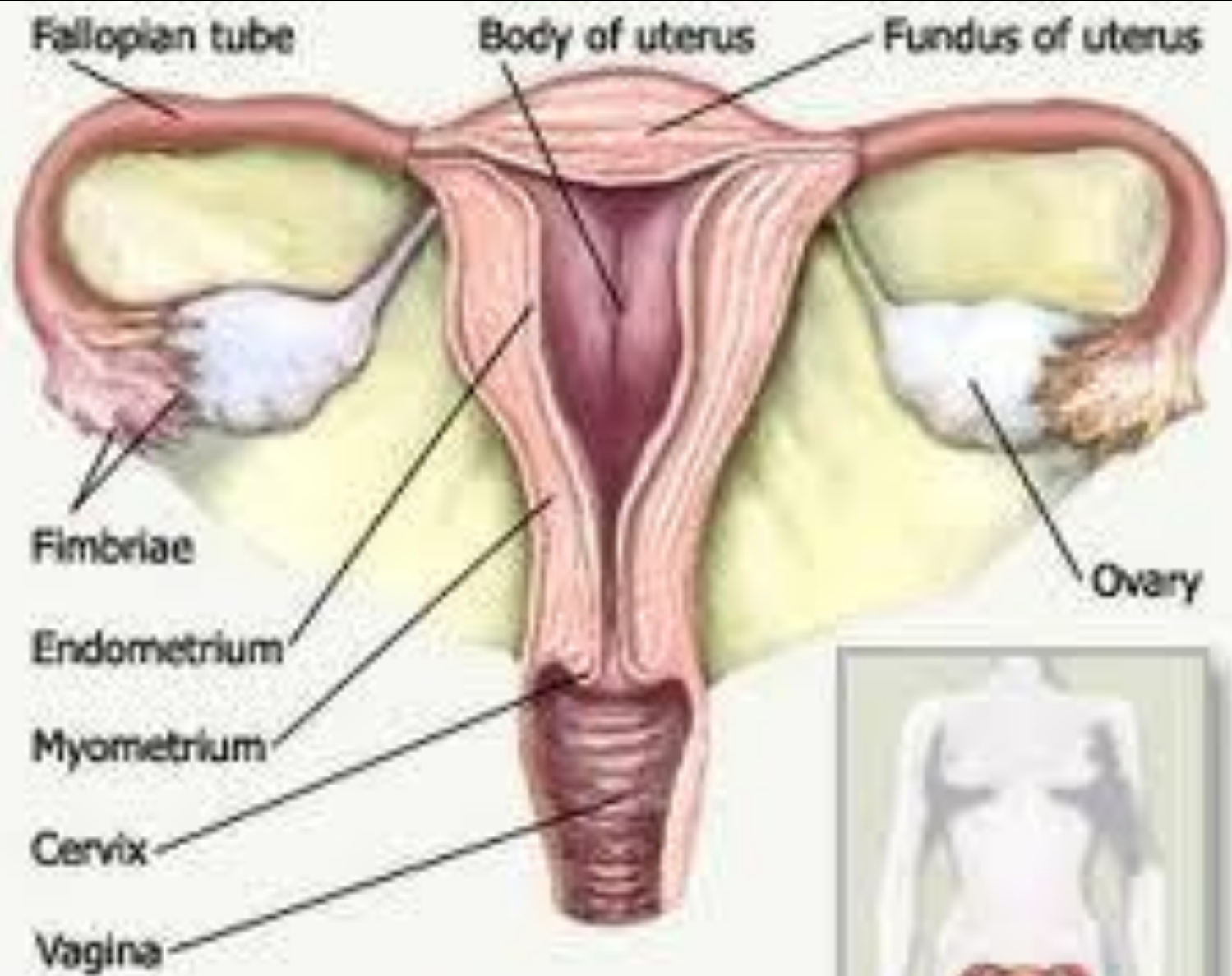
Testicle





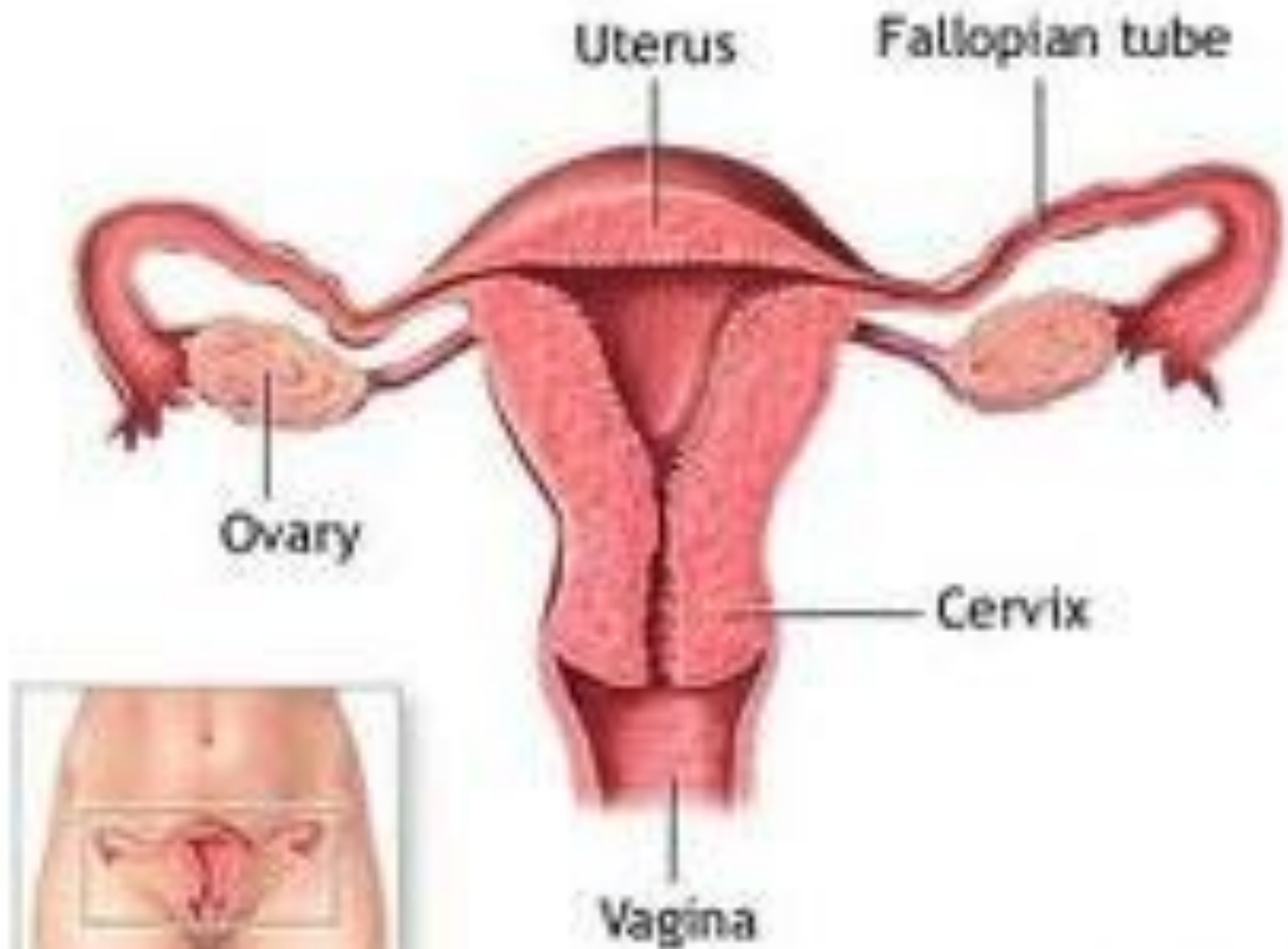

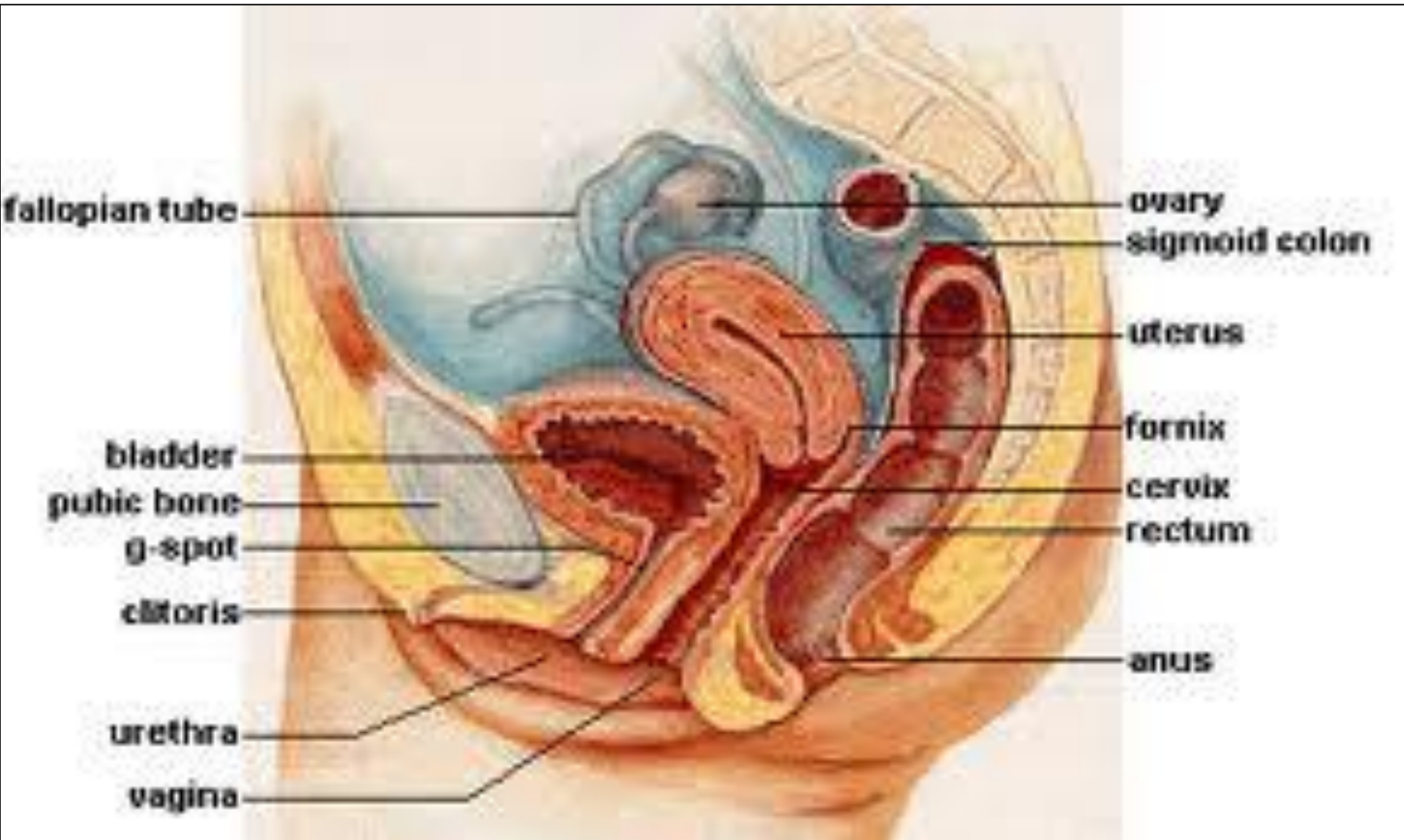A front view of the female reproductive organs.

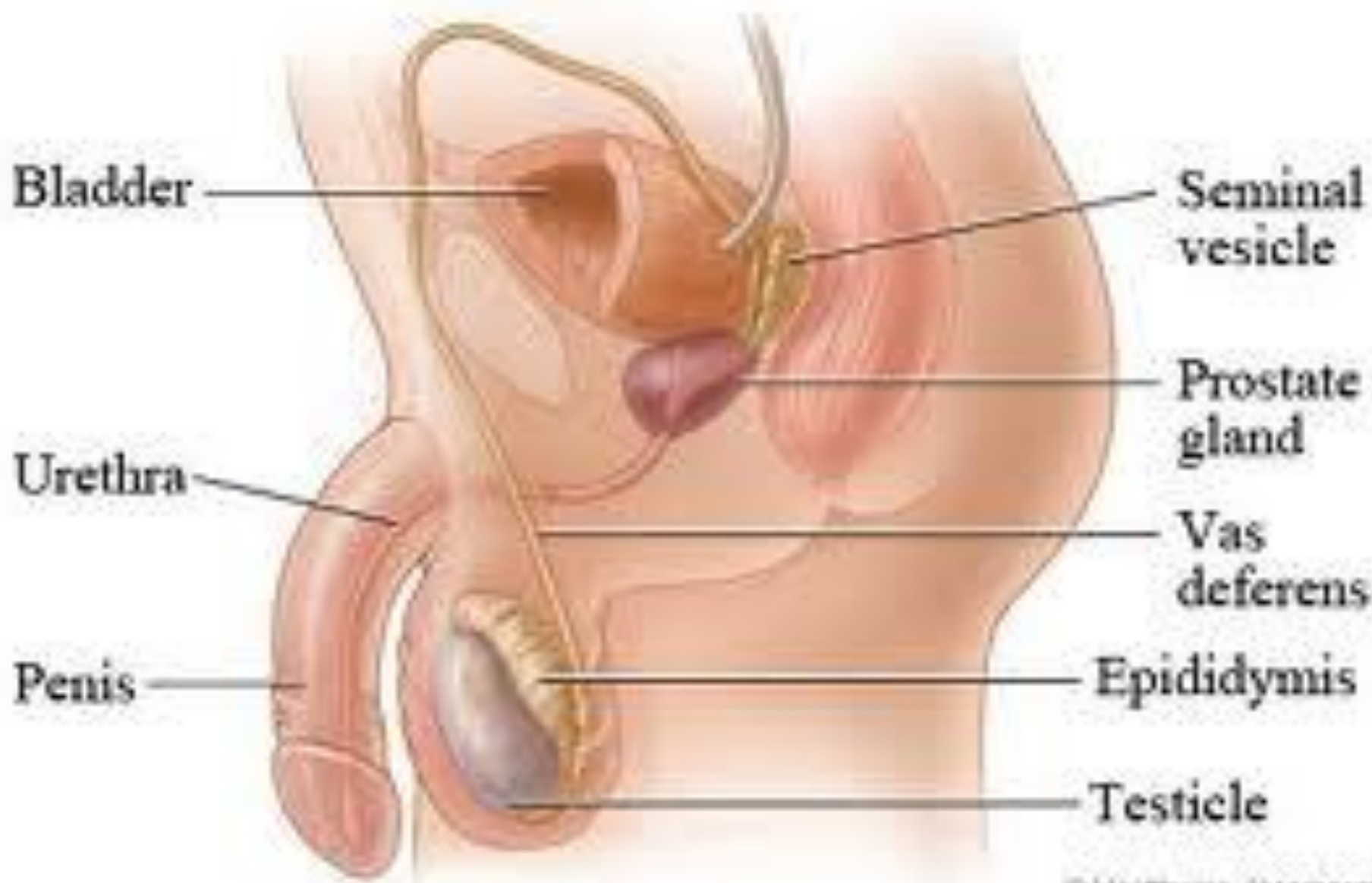


Female reproductive organs

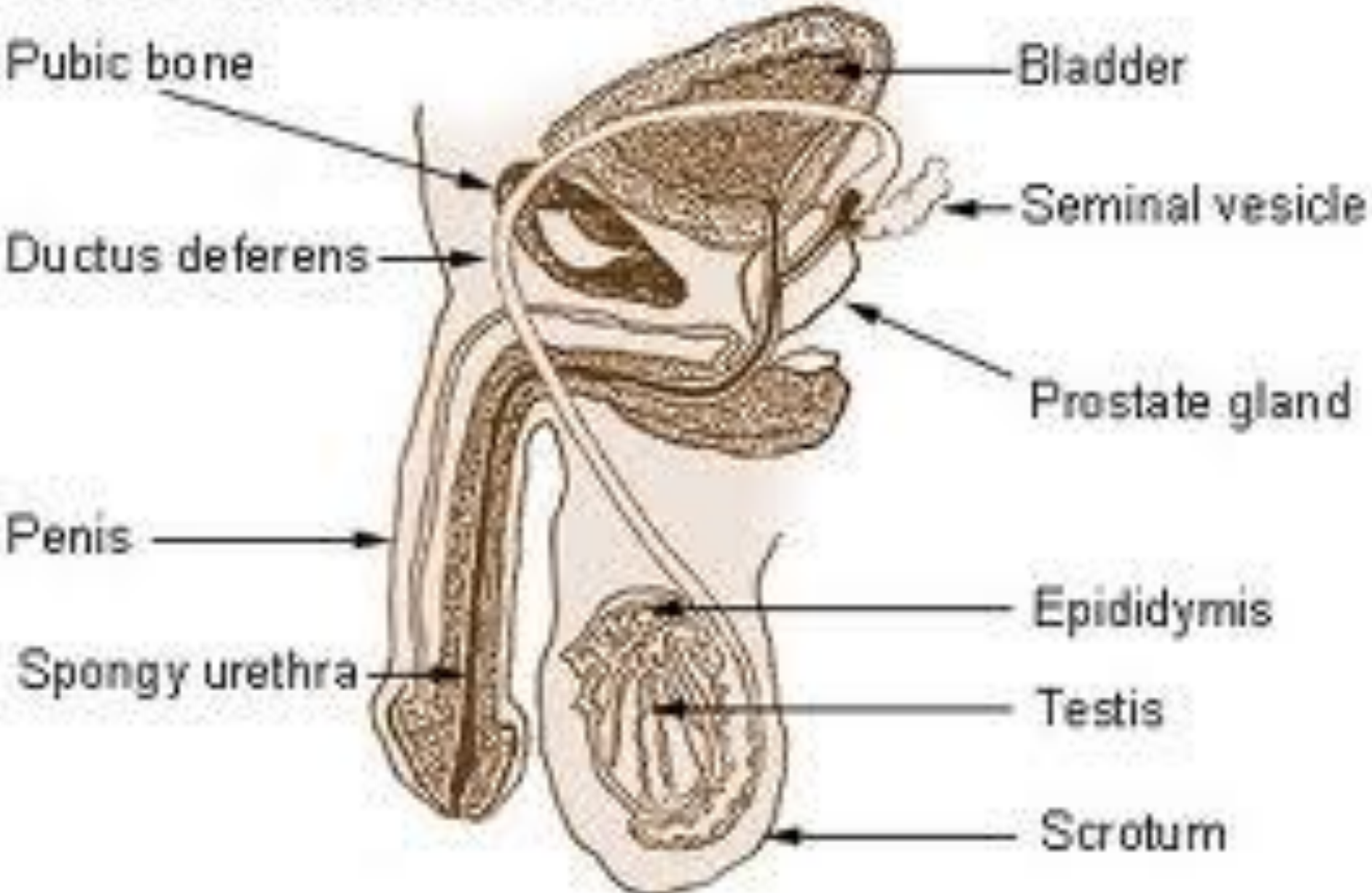








Male Reproductive System





Northern Cardinal



Carolina Chickadee



Turkey Vulture



Tufted Titmouse



Green Heron



Blue Jay



Cinnamon Egret



Carolina Wren



Great Blue Heron



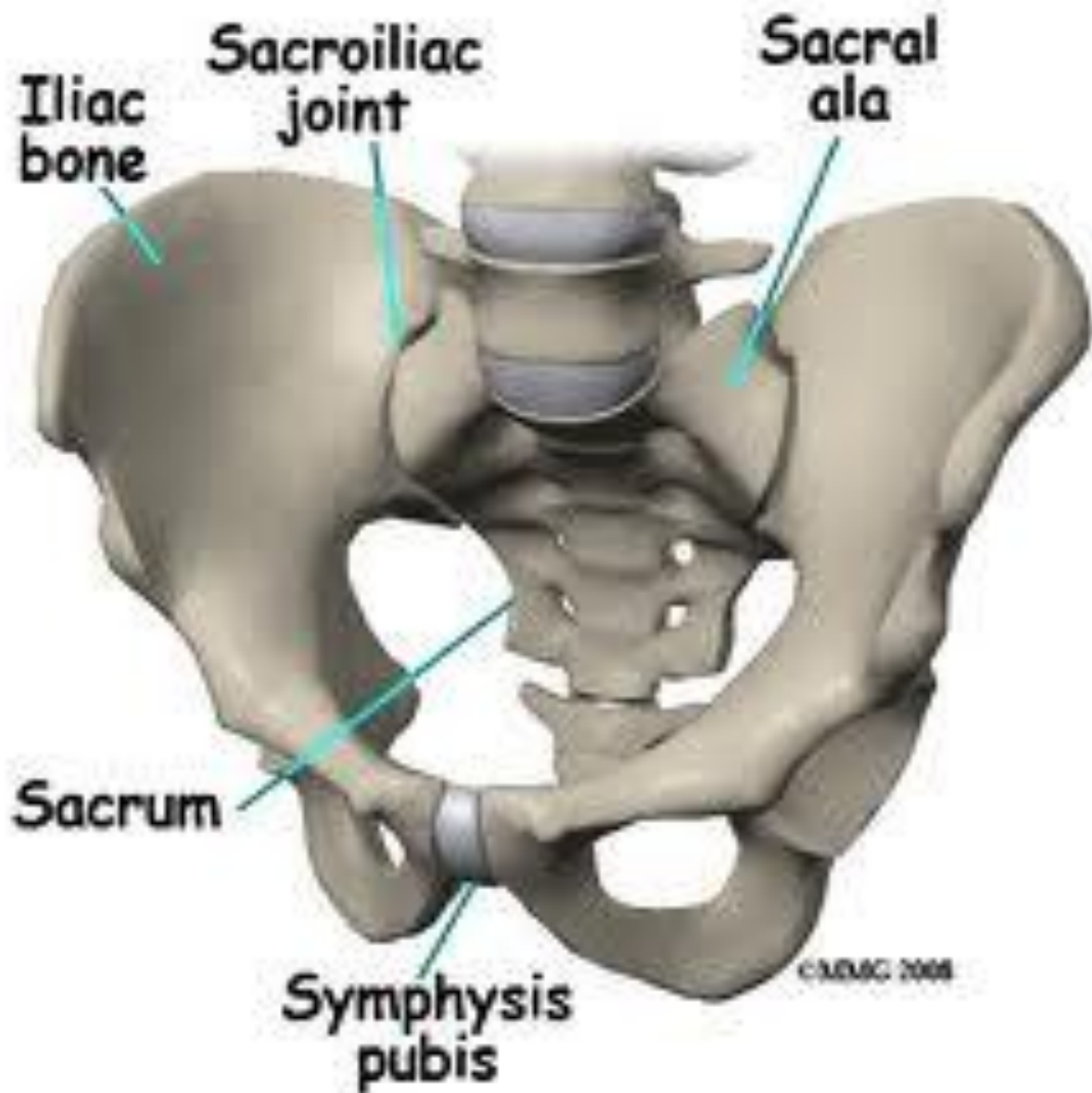


BIRDS OF THE FOREST BORDERS AND GRASS-LANDS

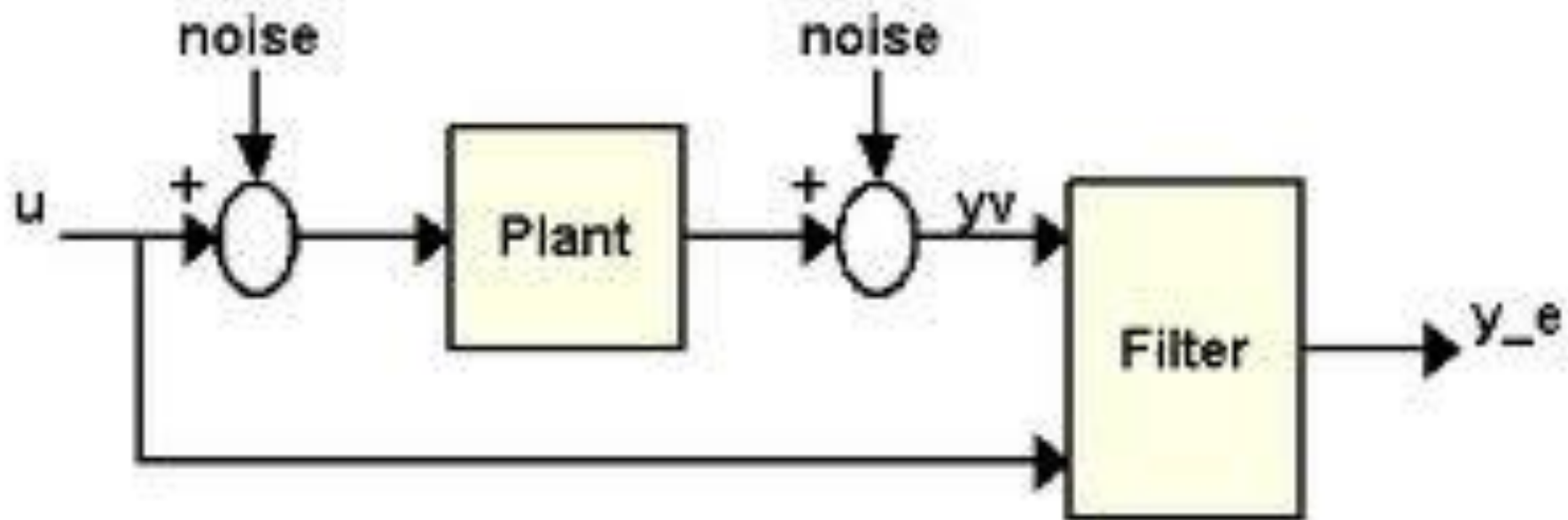


"Thank to you, we will have a home"









Cell
Wall

Cytoplasm

Reception

Transduction

Induction

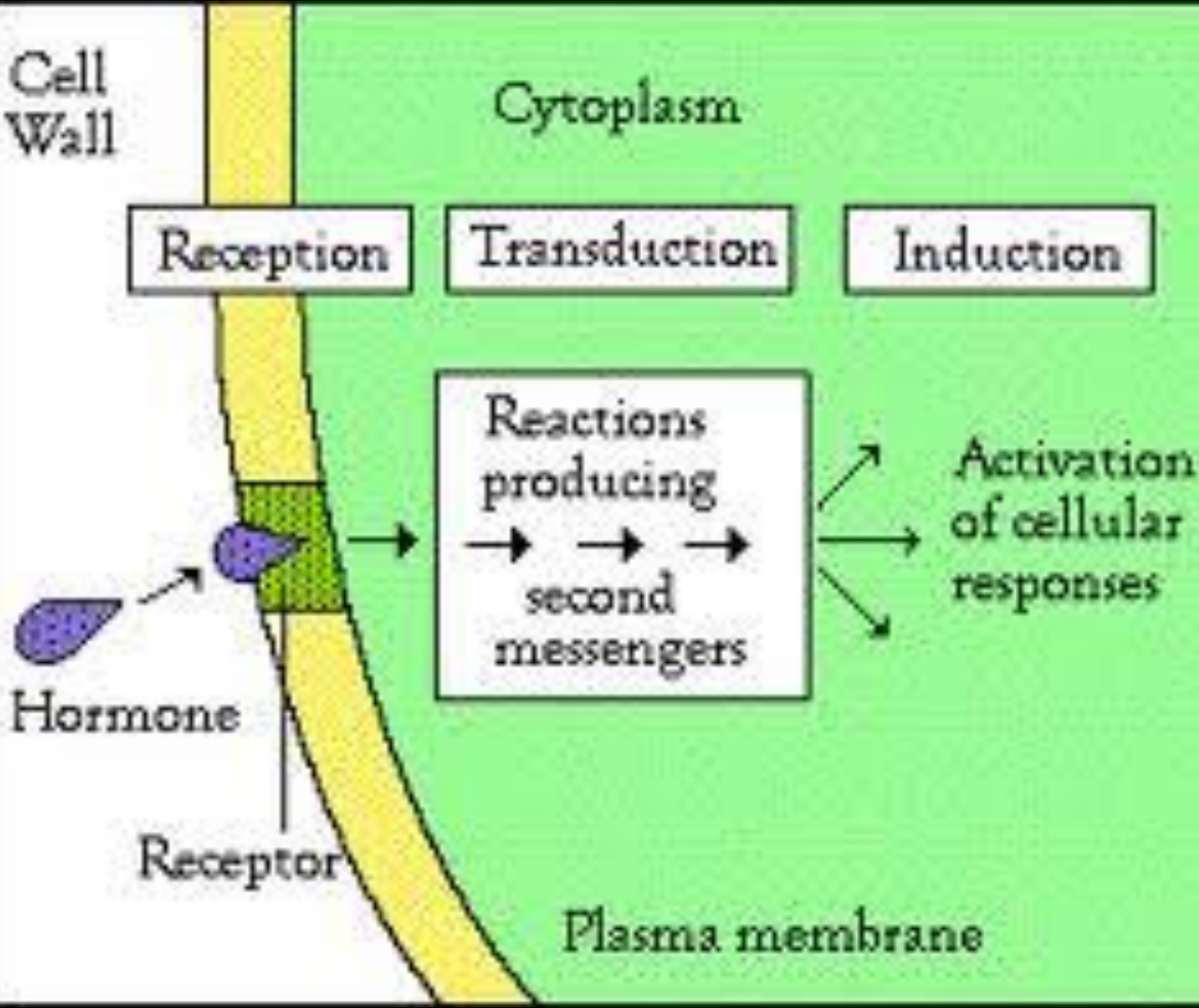
Reactions
producing
→ → →
second
messengers

Activation
of cellular
responses

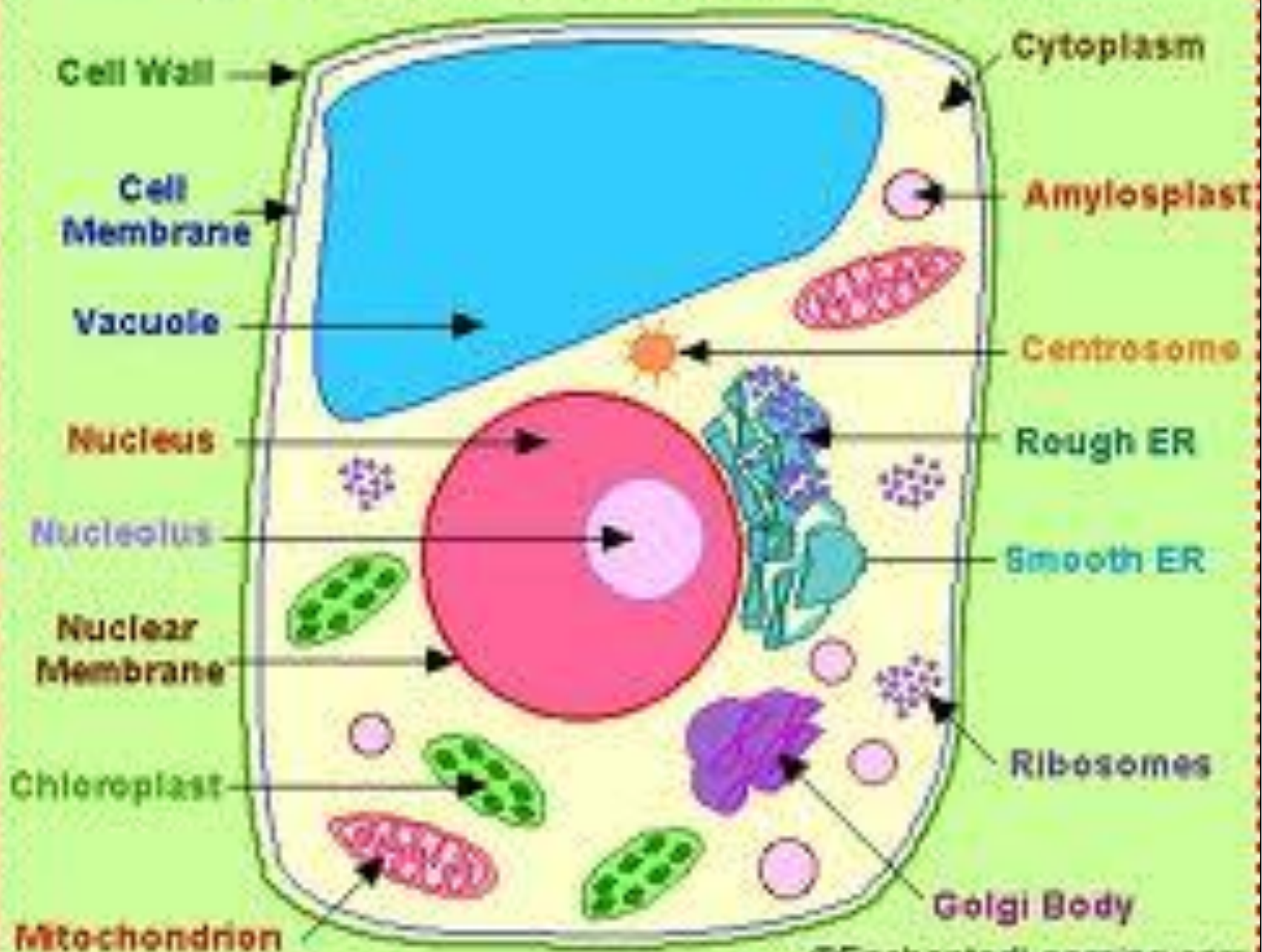
Hormone

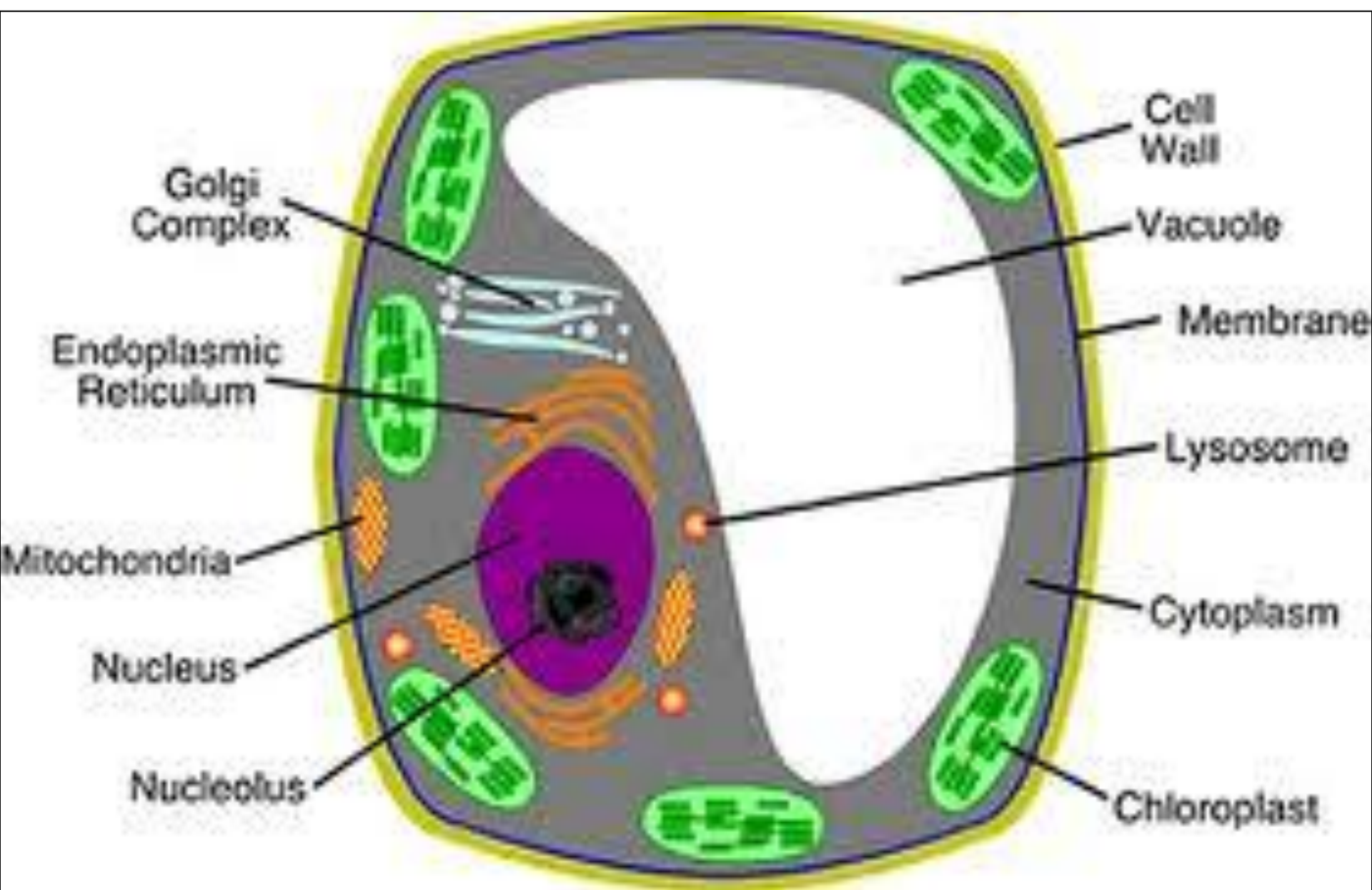
Receptor

Plasma membrane

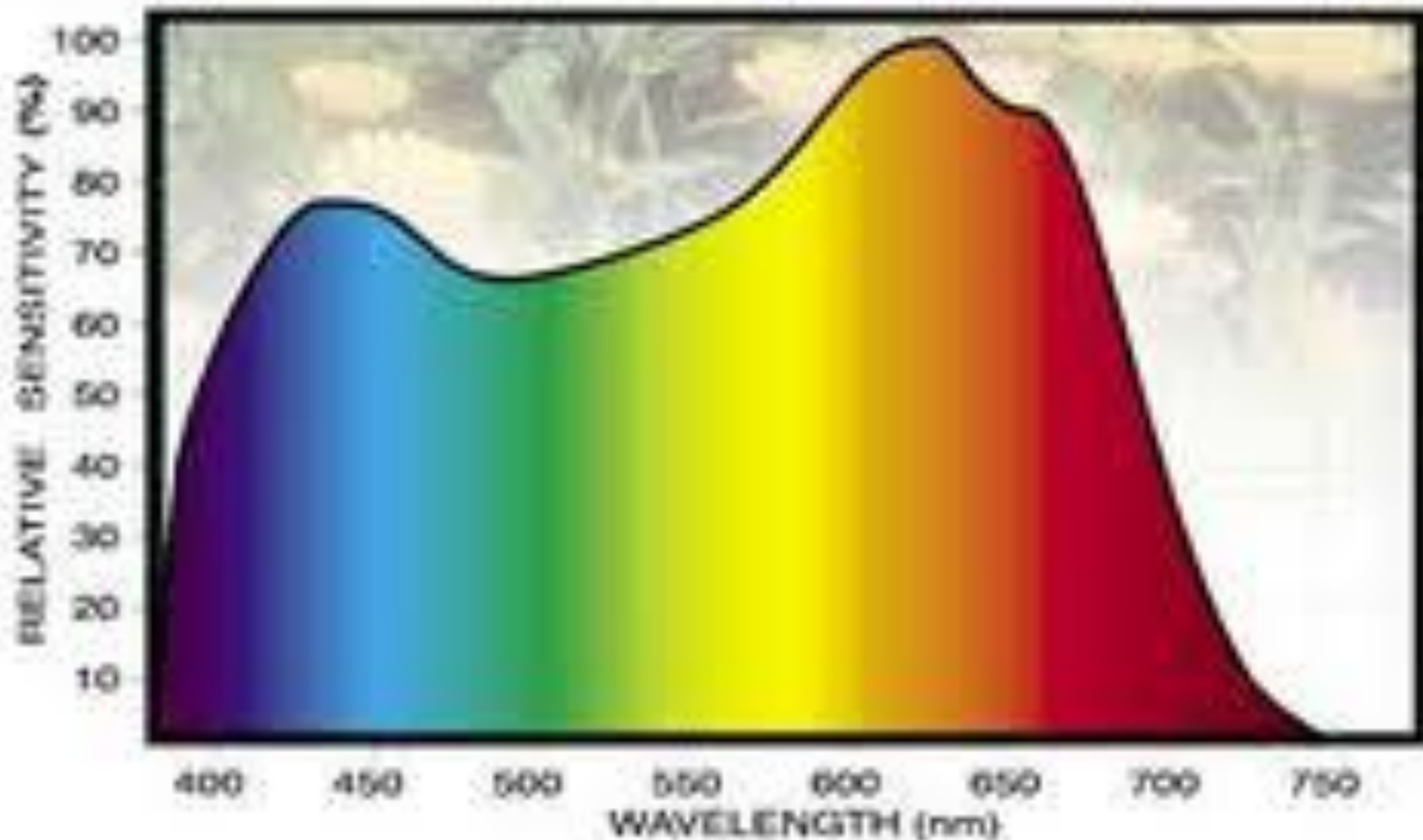


Cross-Section of a Plant Cell



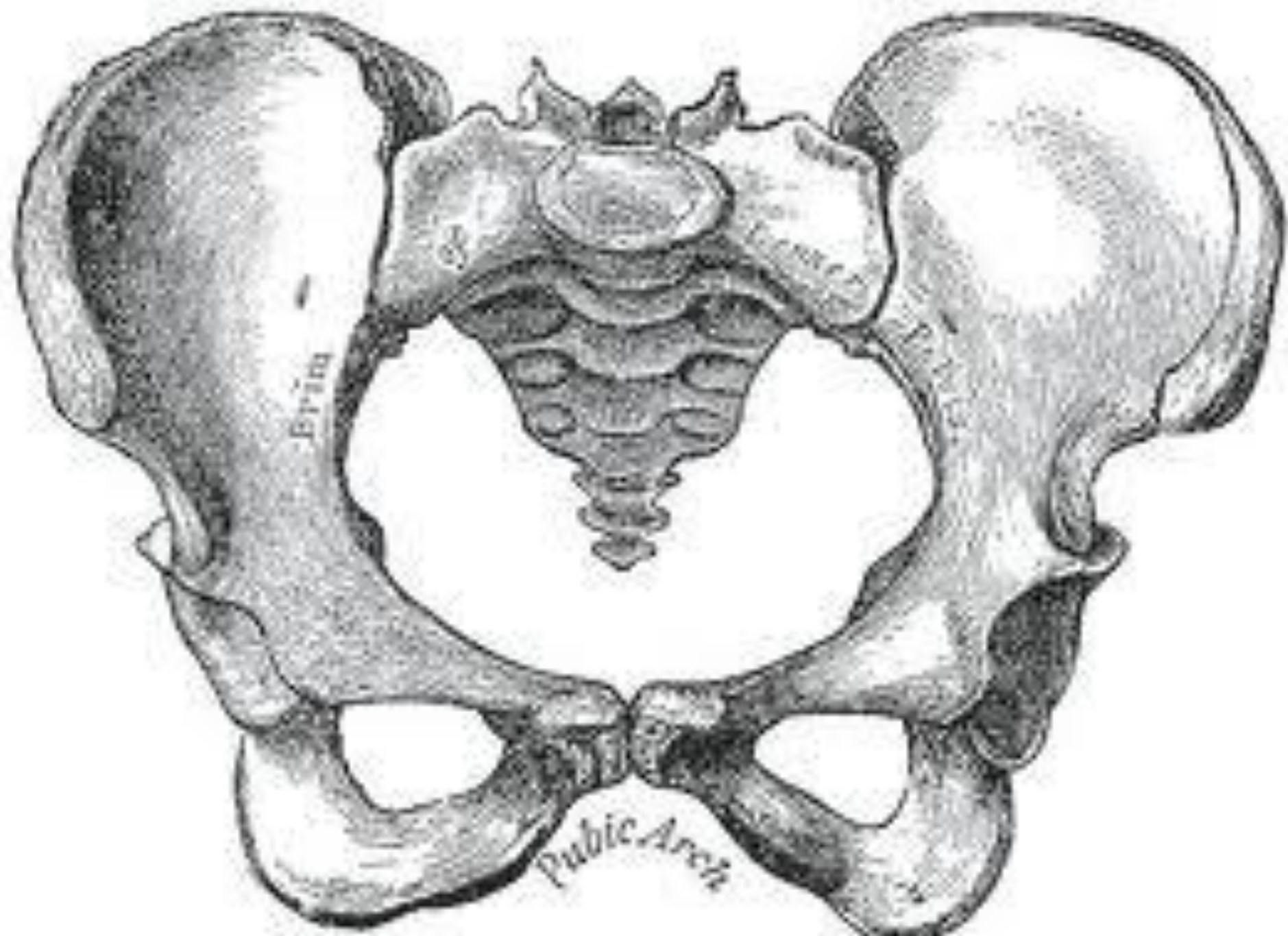


Photosynthetic Response Réponse photosynthétique



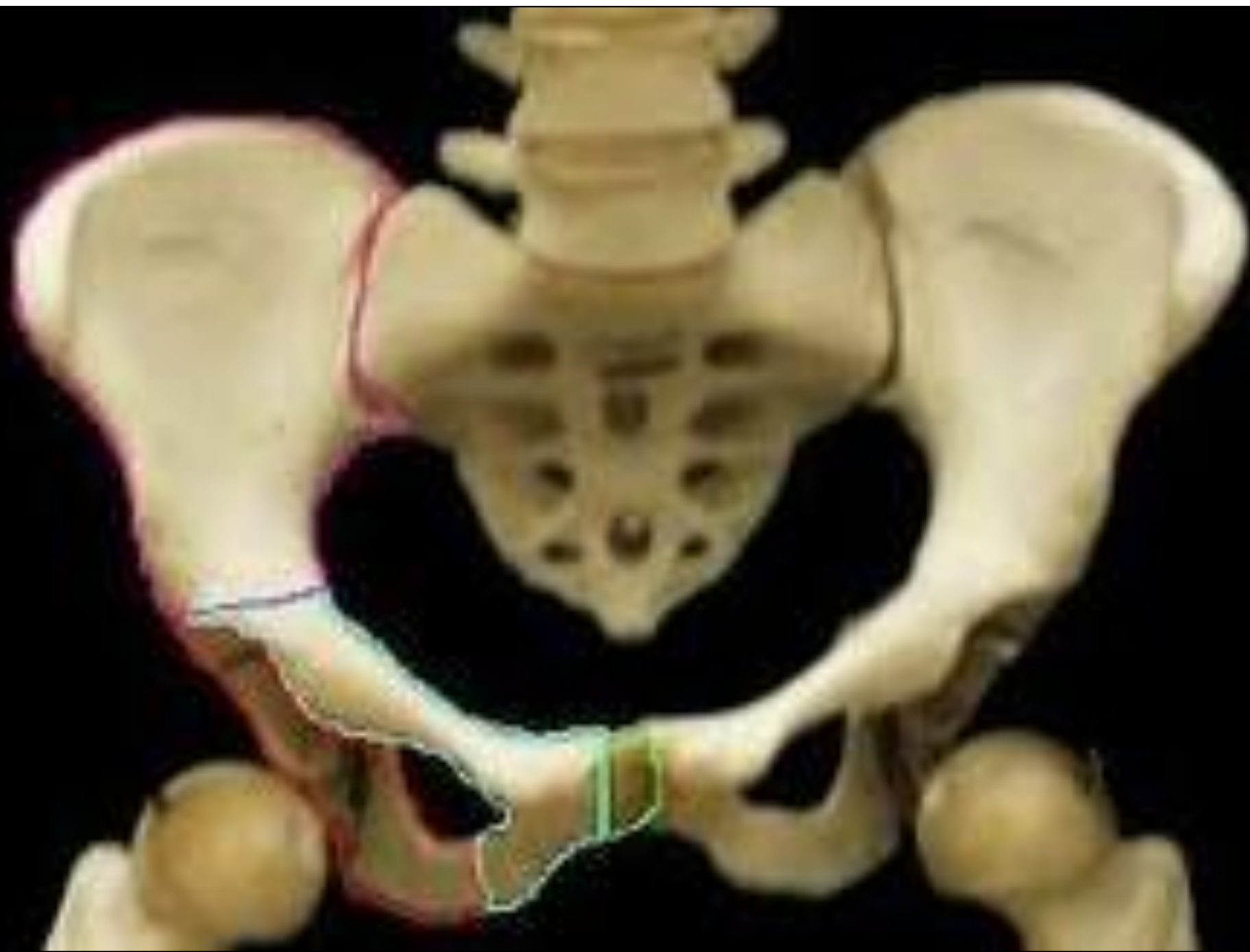


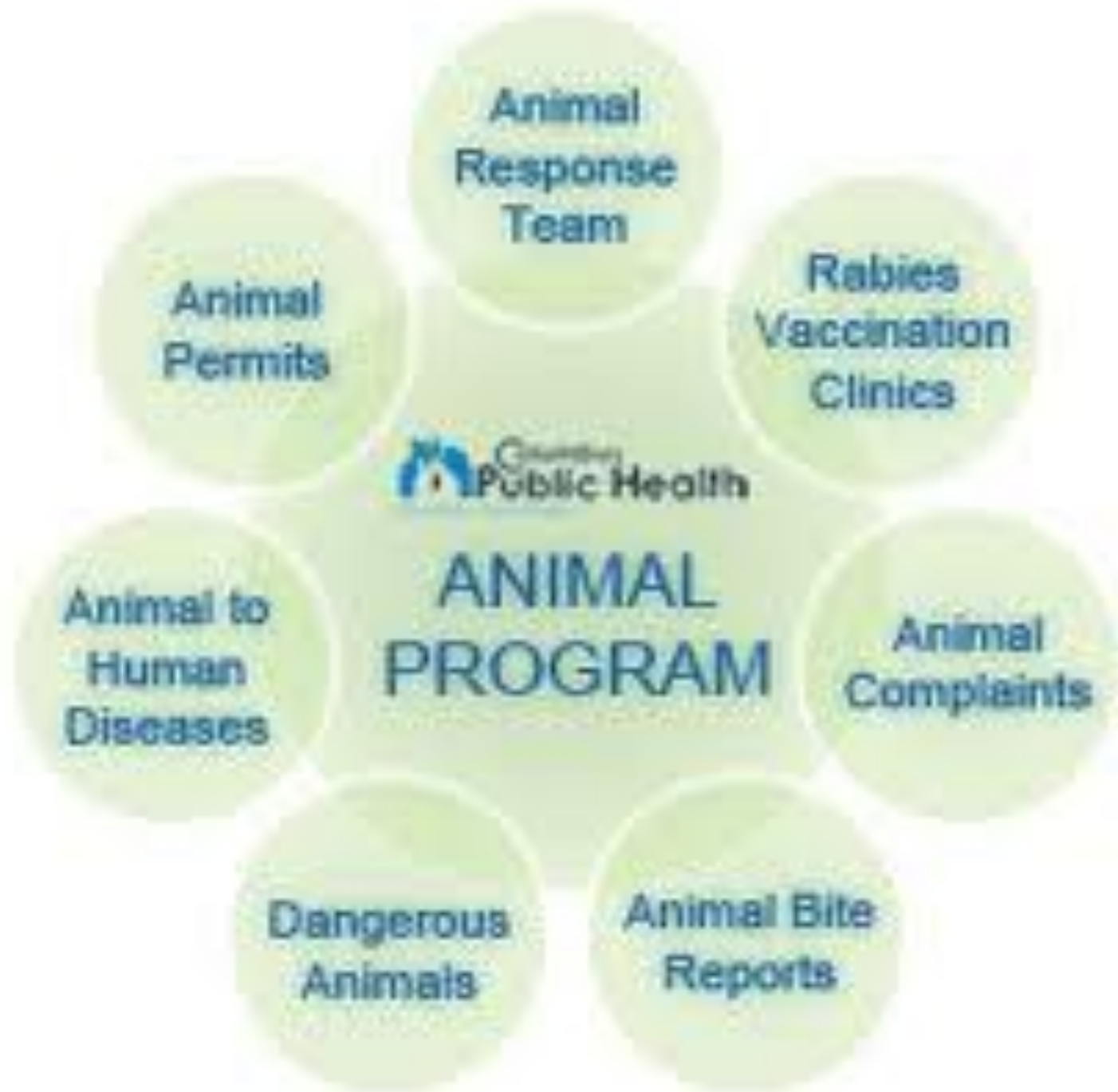



Ilium

Pubic Arch





Animal
Response
Team

Rabies
Vaccination
Clinics

Animal
Complaints

Animal Bite
Reports

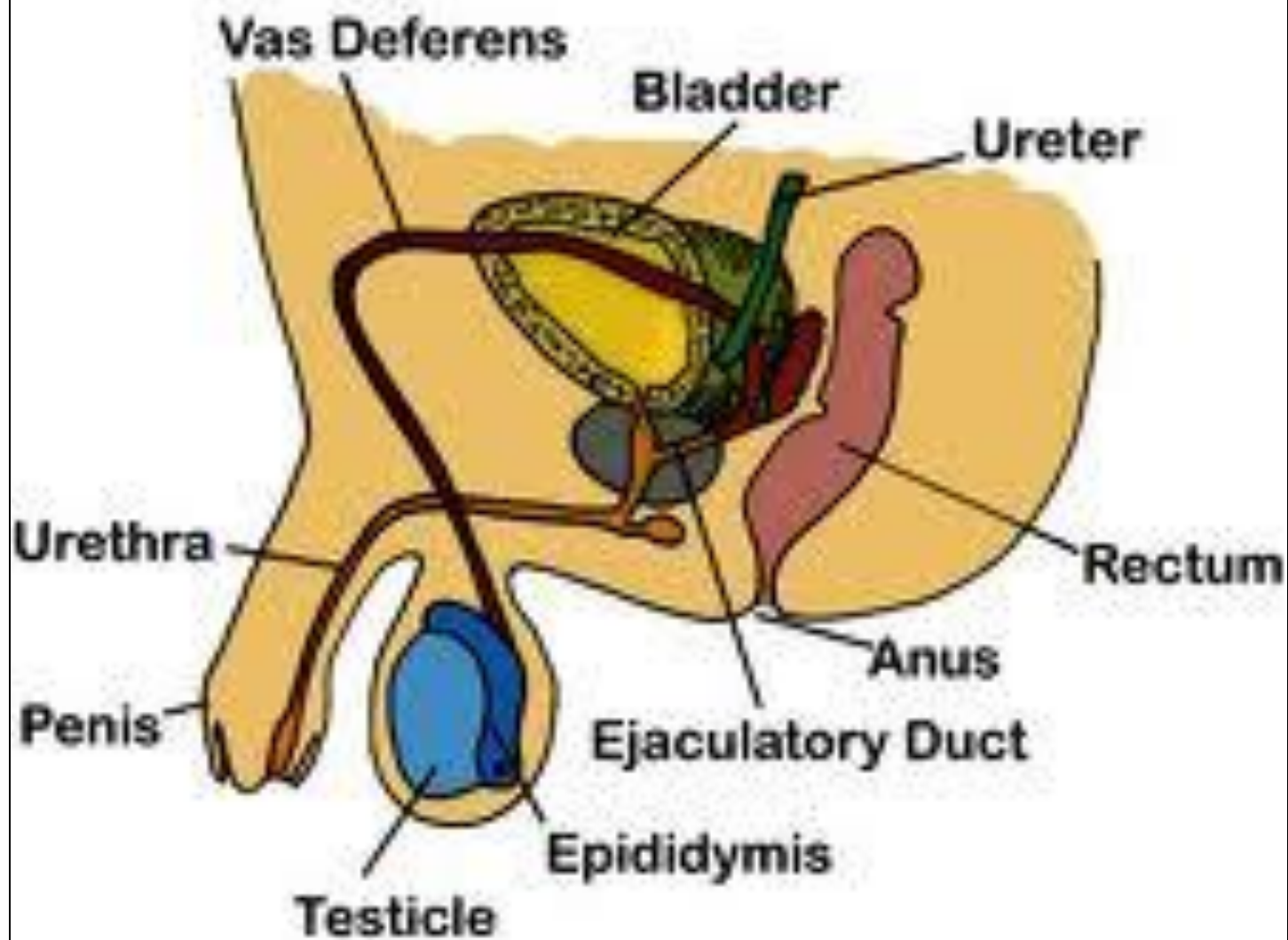
Dangerous
Animals

Animal to
Human
Diseases

Animal
Permits

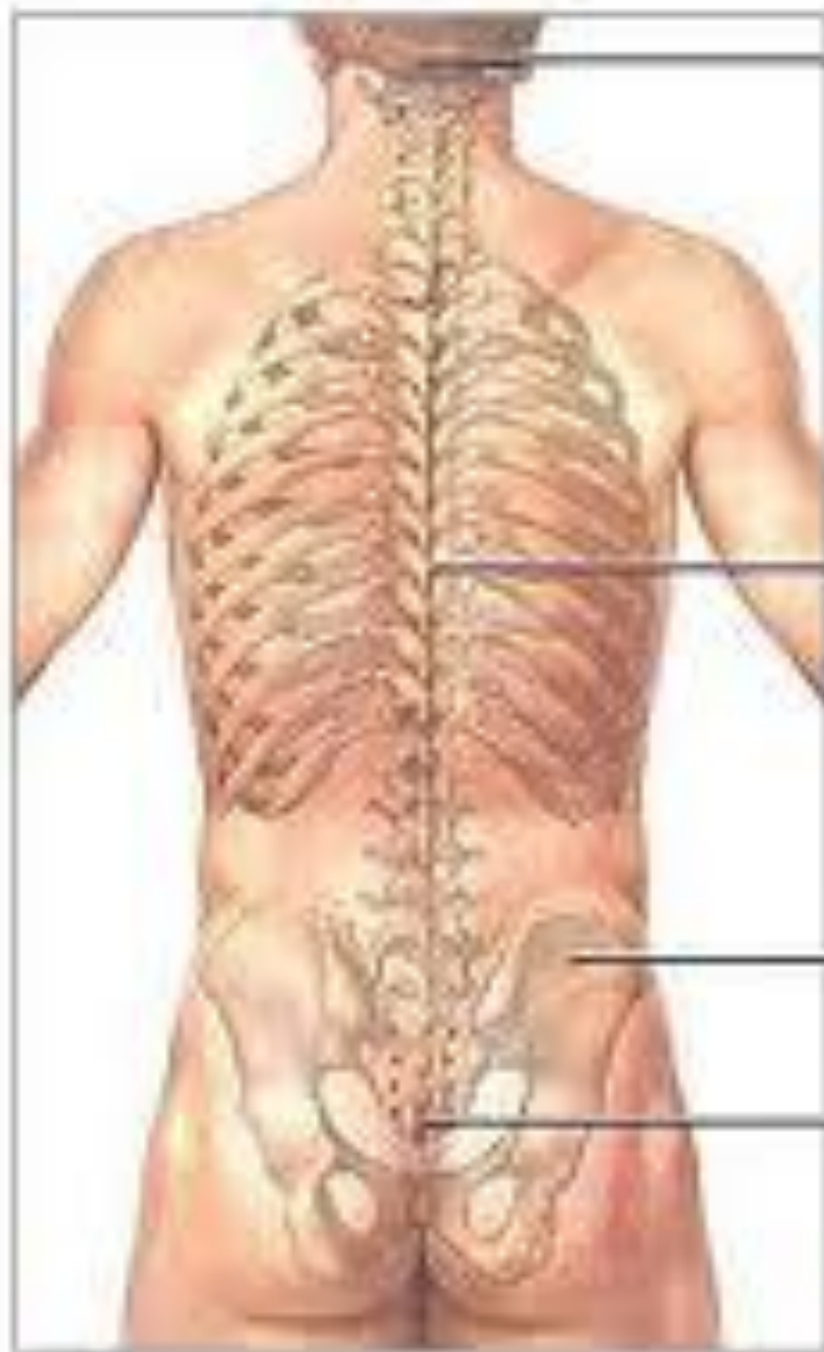County
Public Health

ANIMAL
PROGRAM



**MALE
HUMAN**



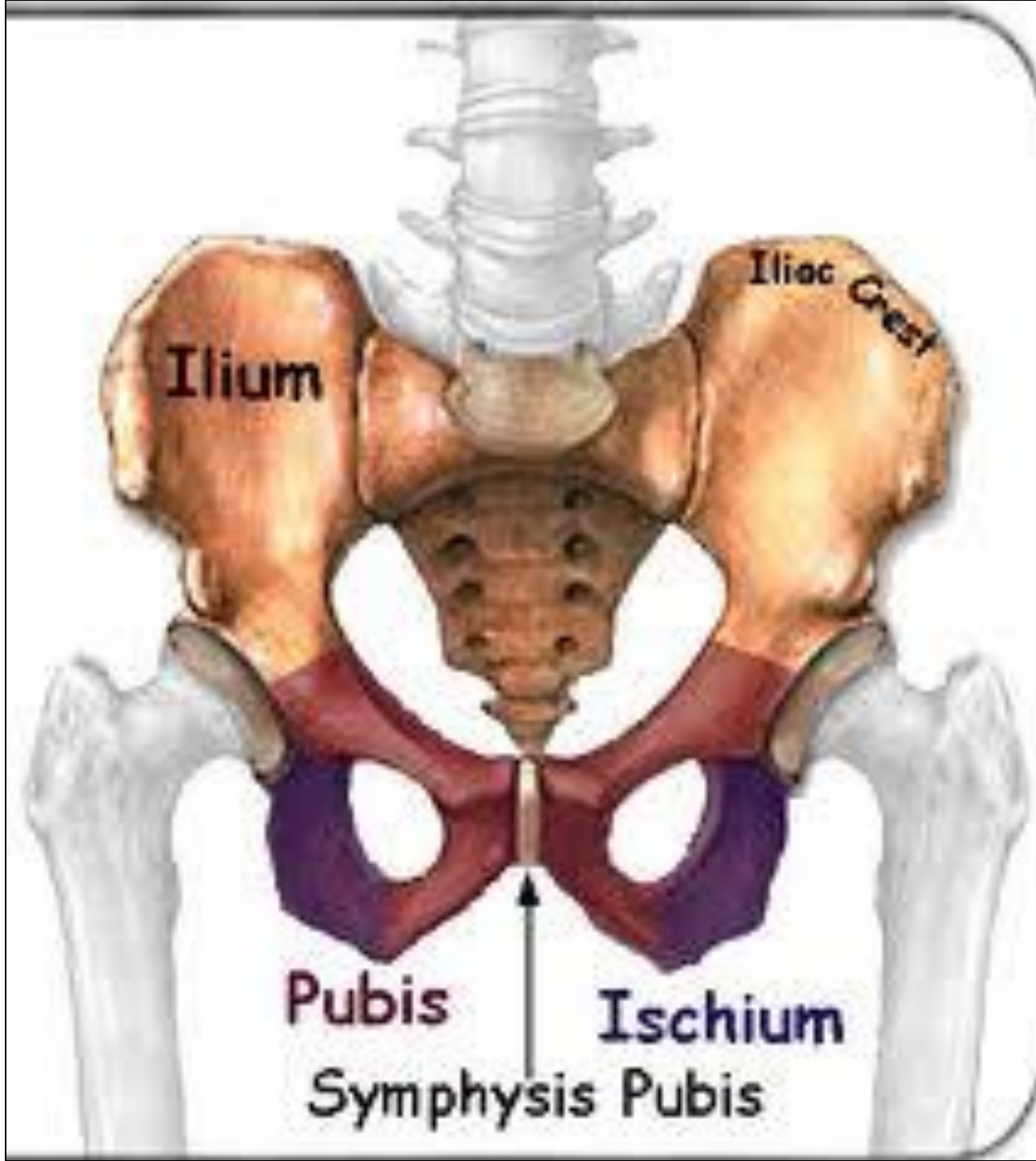


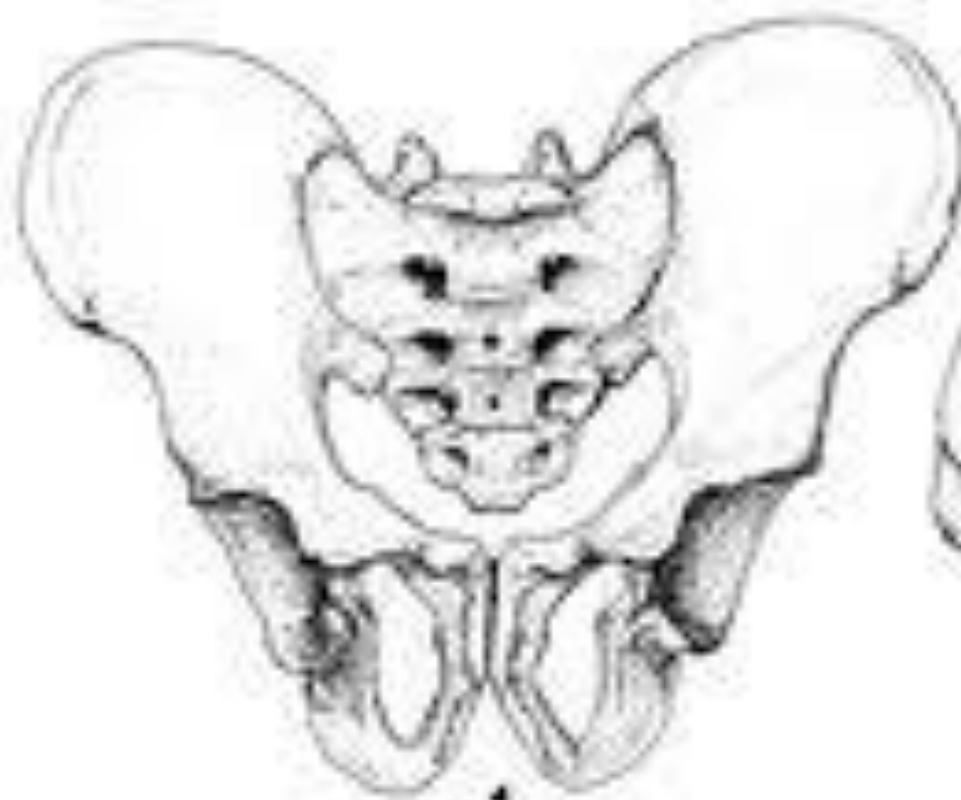
Skull

Vertebral column

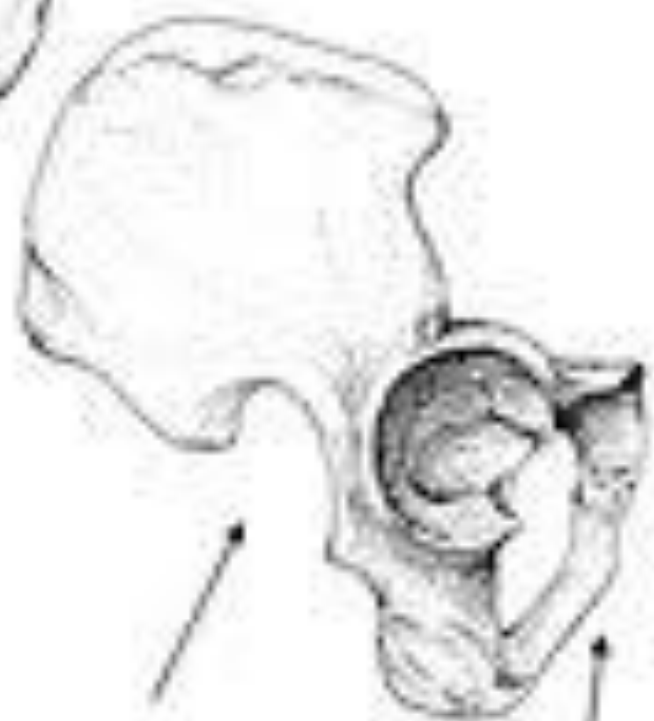Pelvis

Sacrum

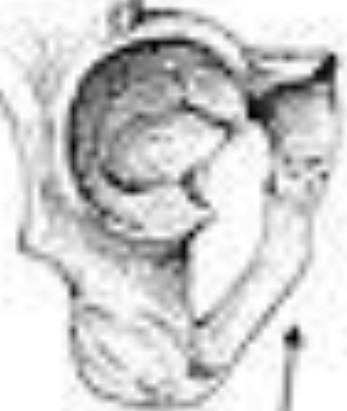



Narrow Subpubic Angle

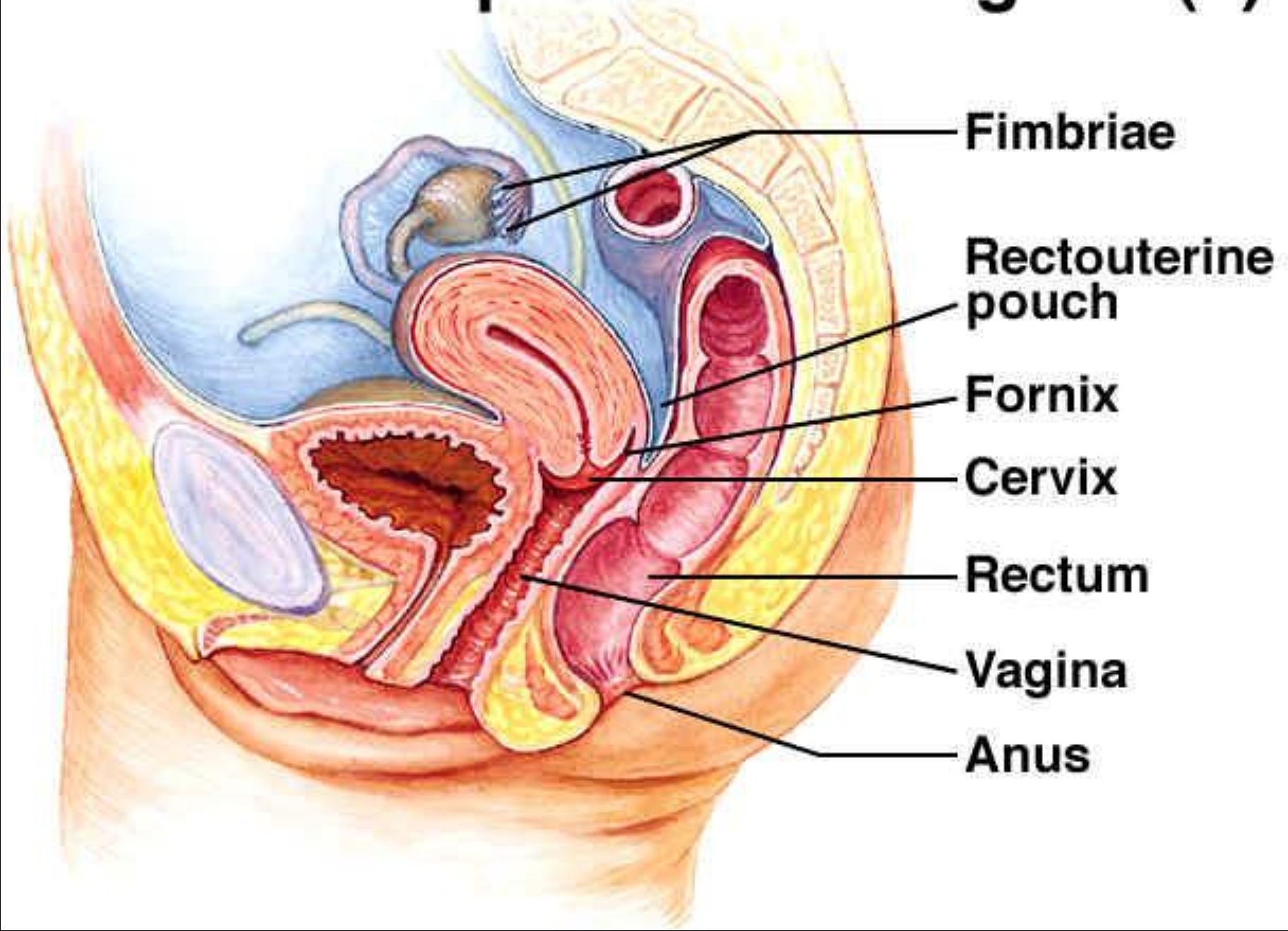


Narrow Greater Sciatic Notch



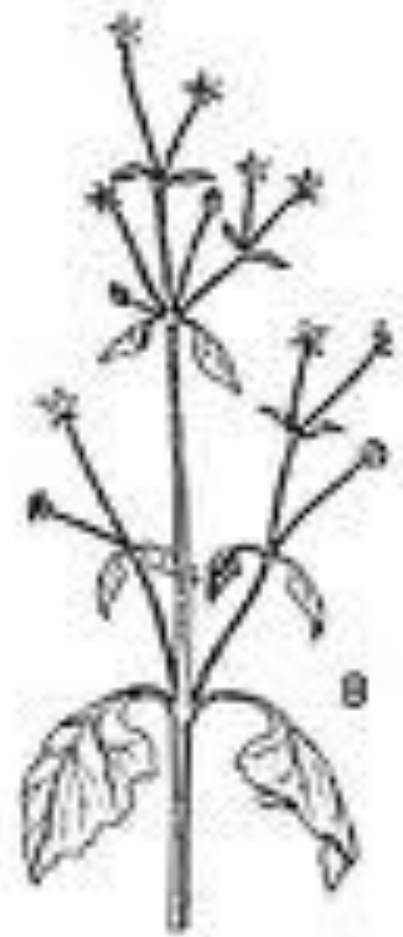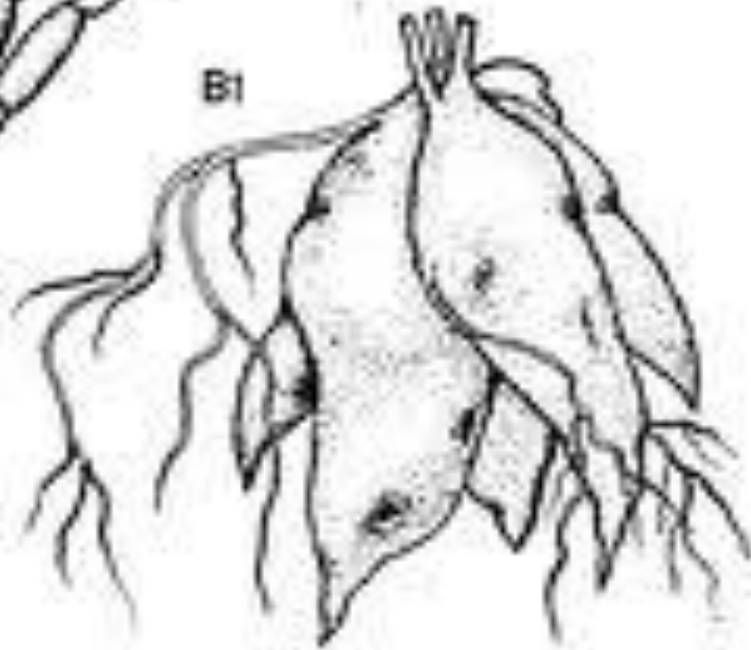
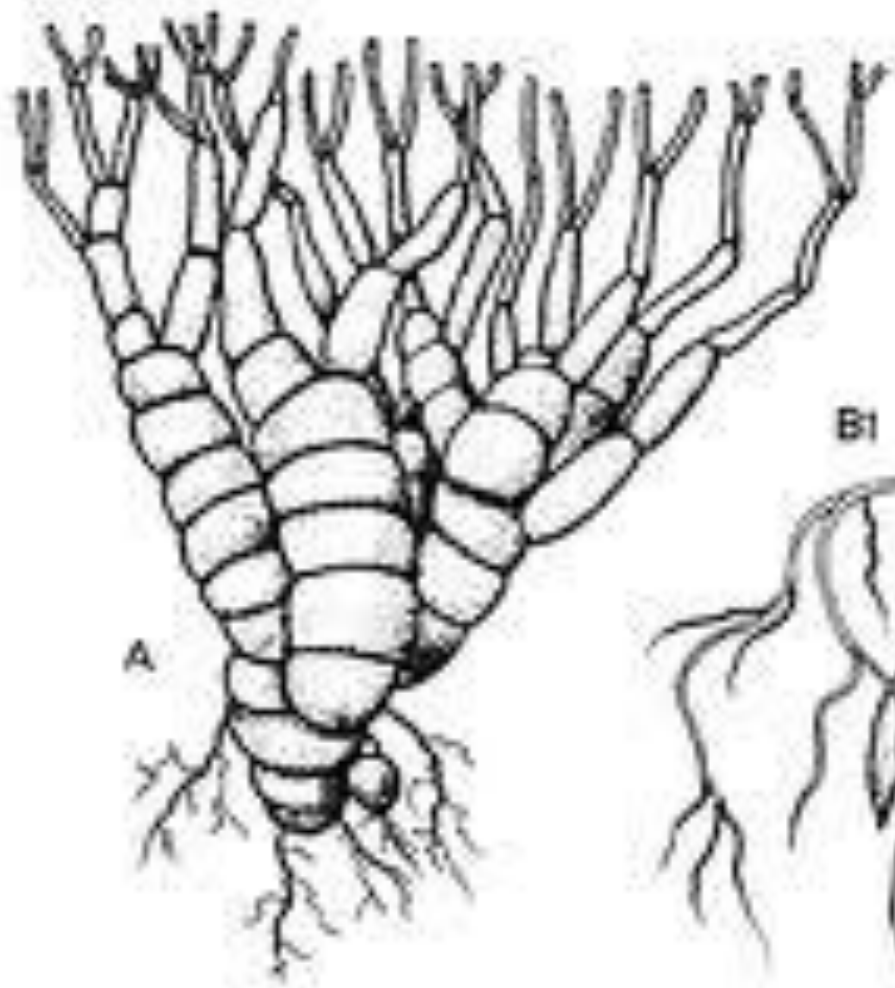
Narrow pubic bone

Female Reproductive Organs (2)

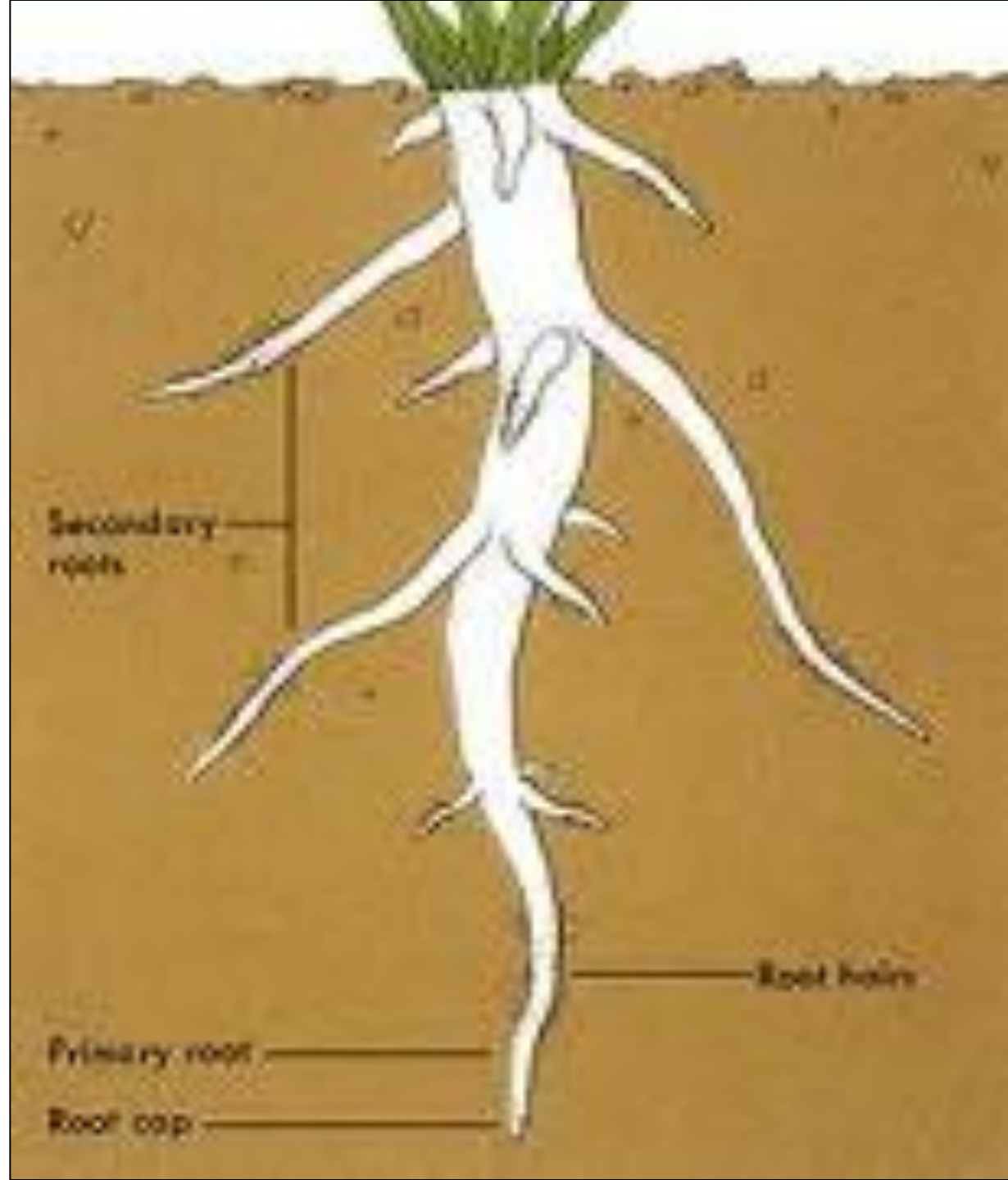










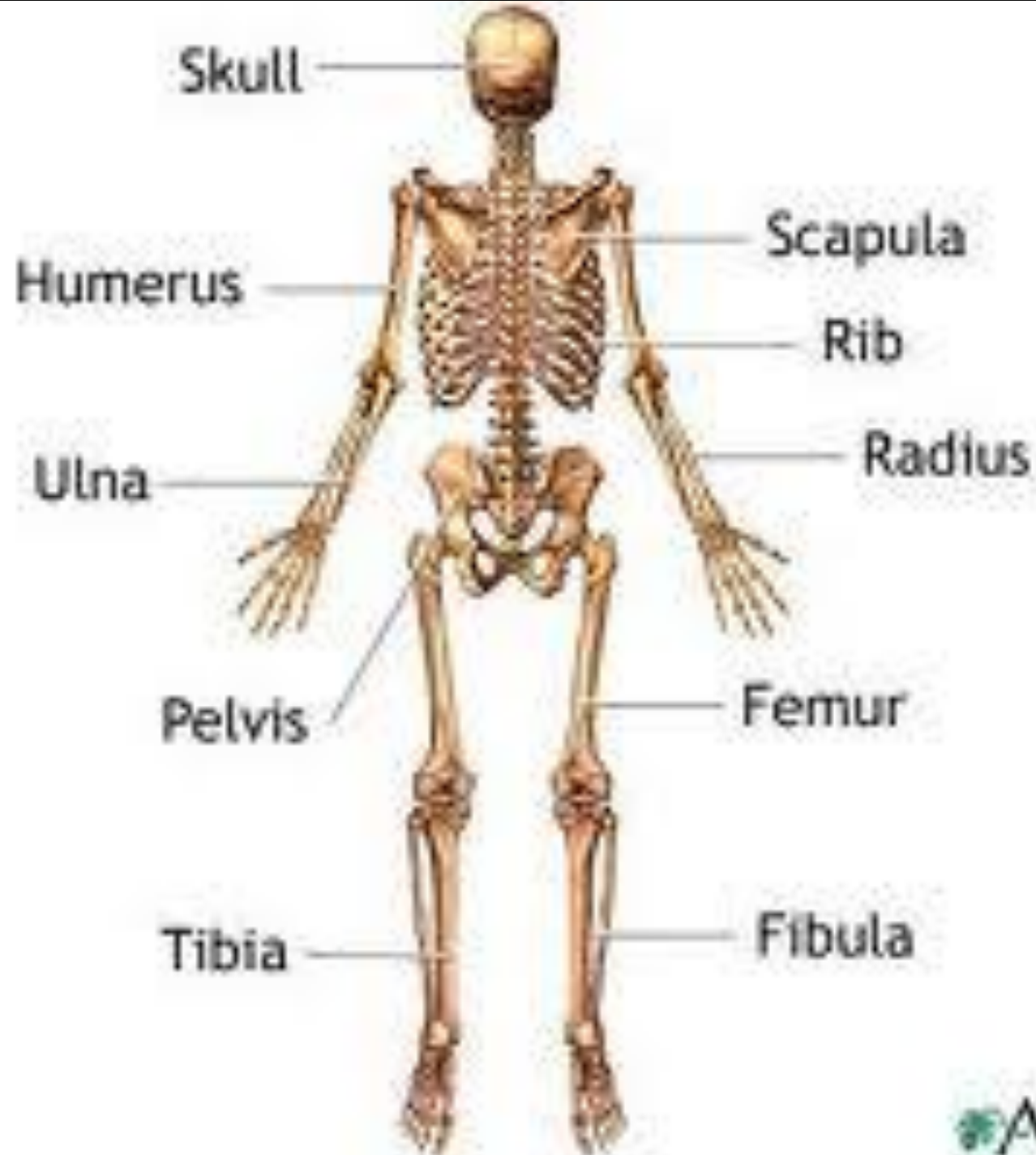


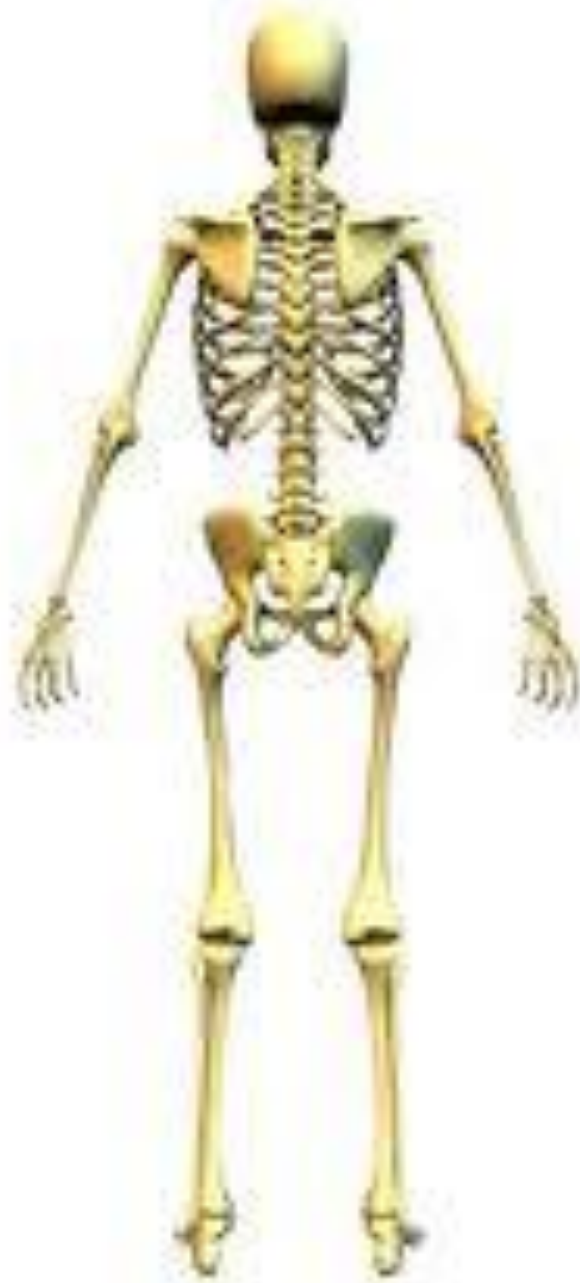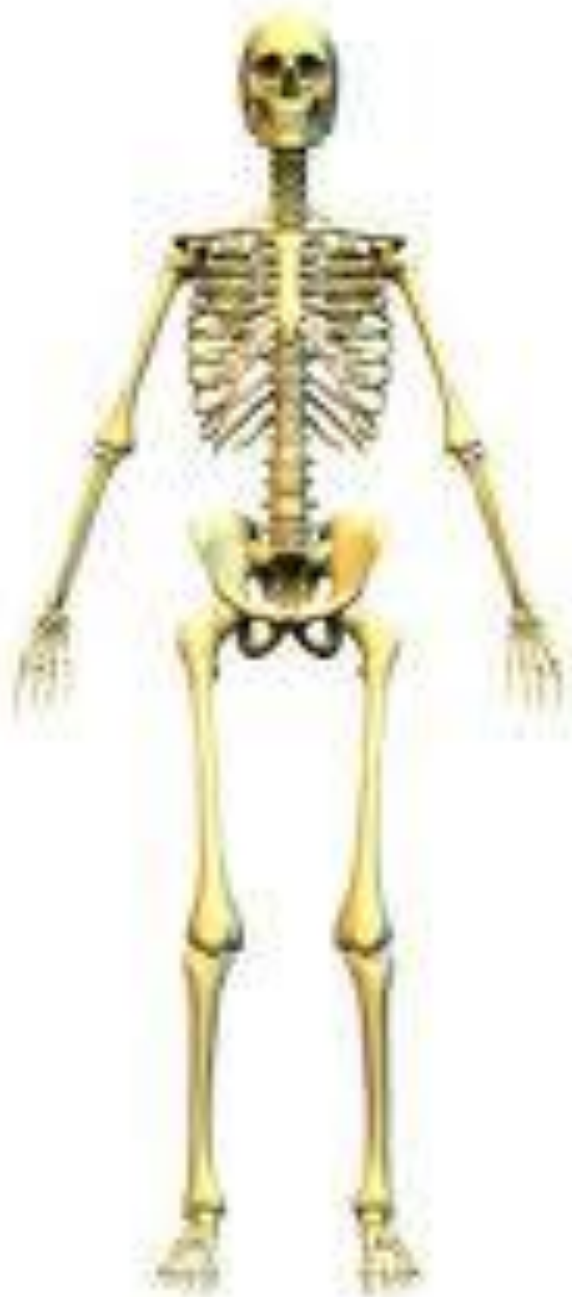Secondary roots

Root hairs

Primary root

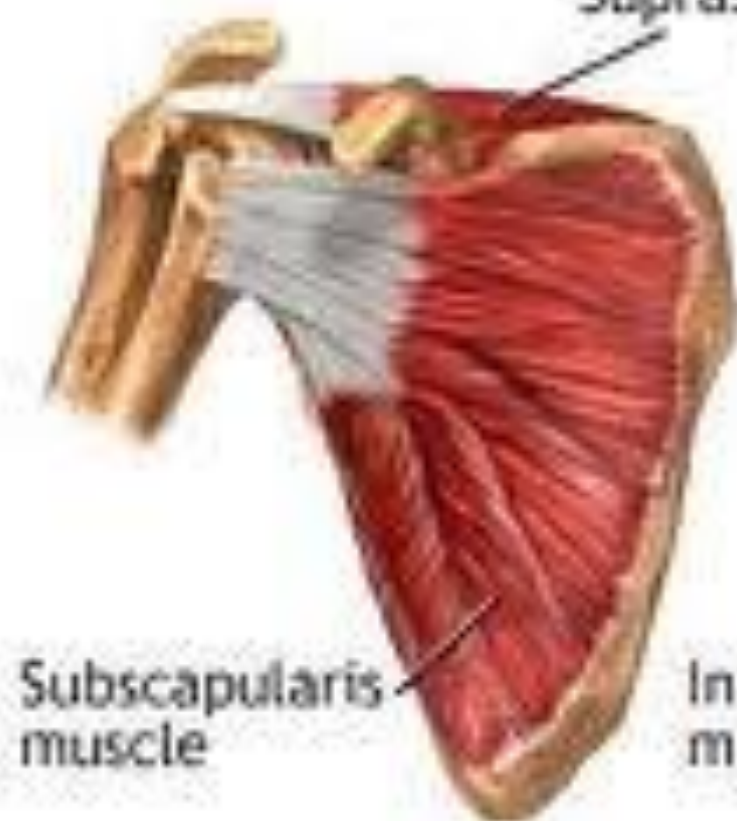
Root cap



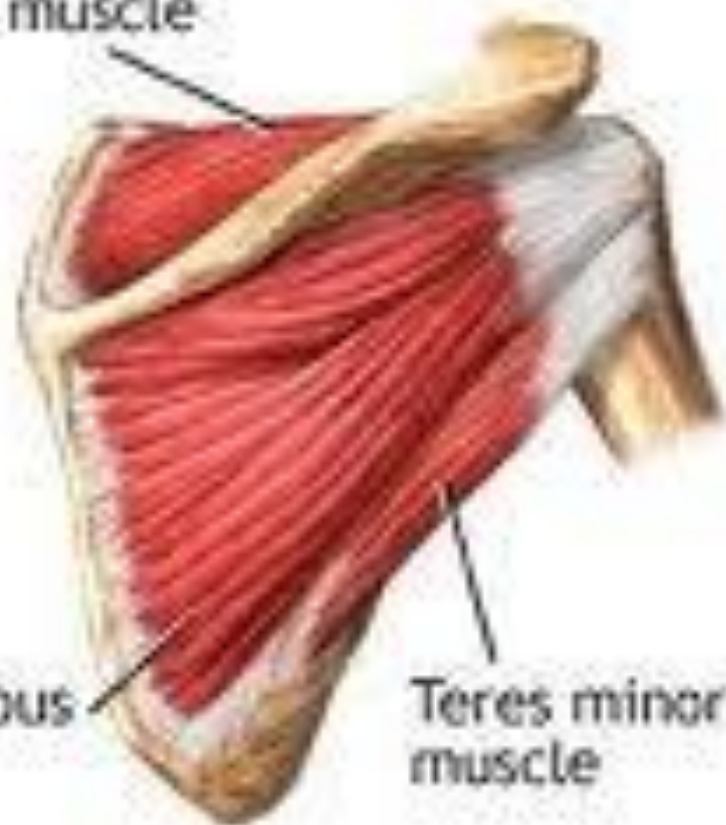

Rotator cuff muscles

Supraspinatous muscle

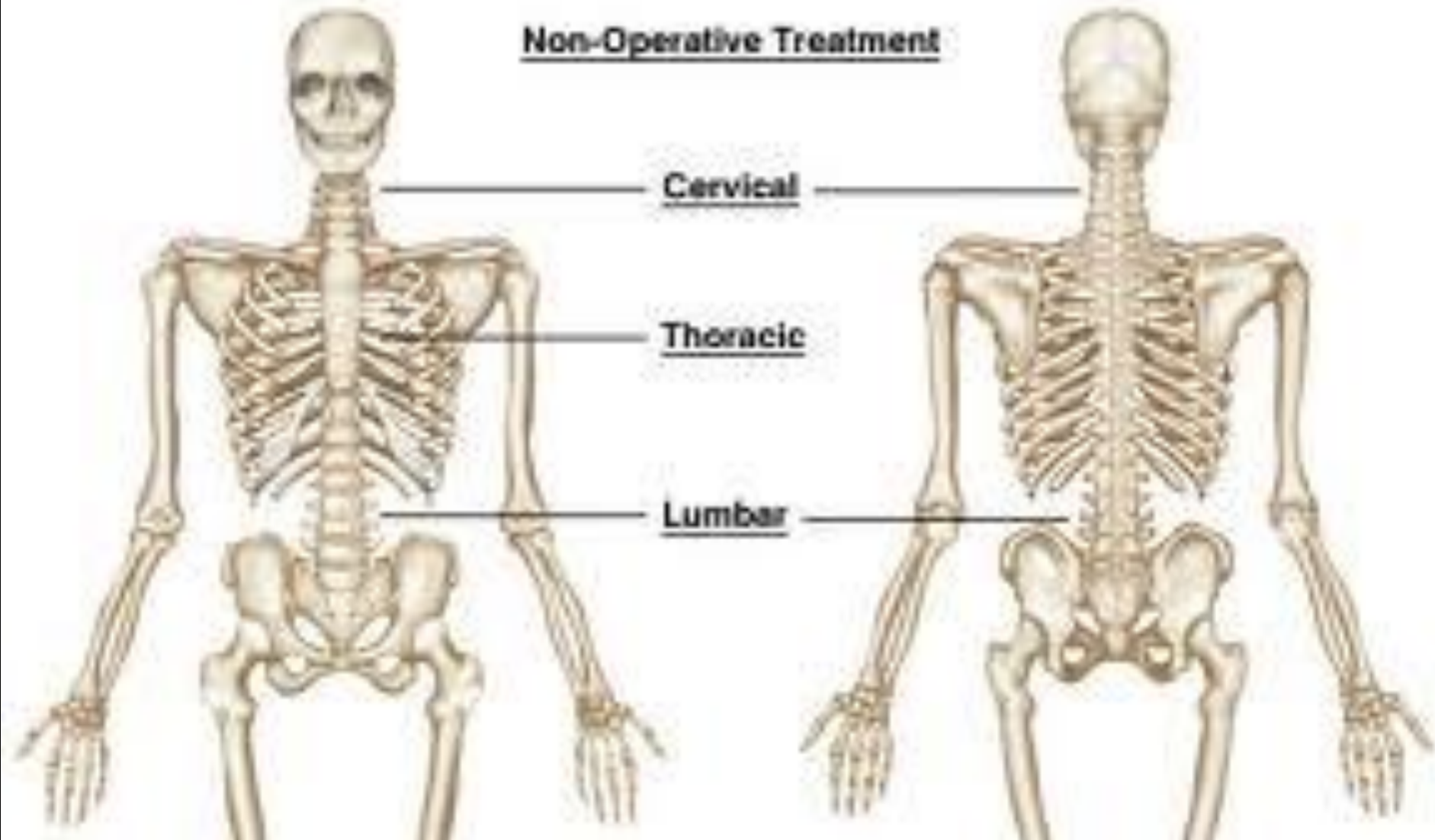


Anterior shoulder

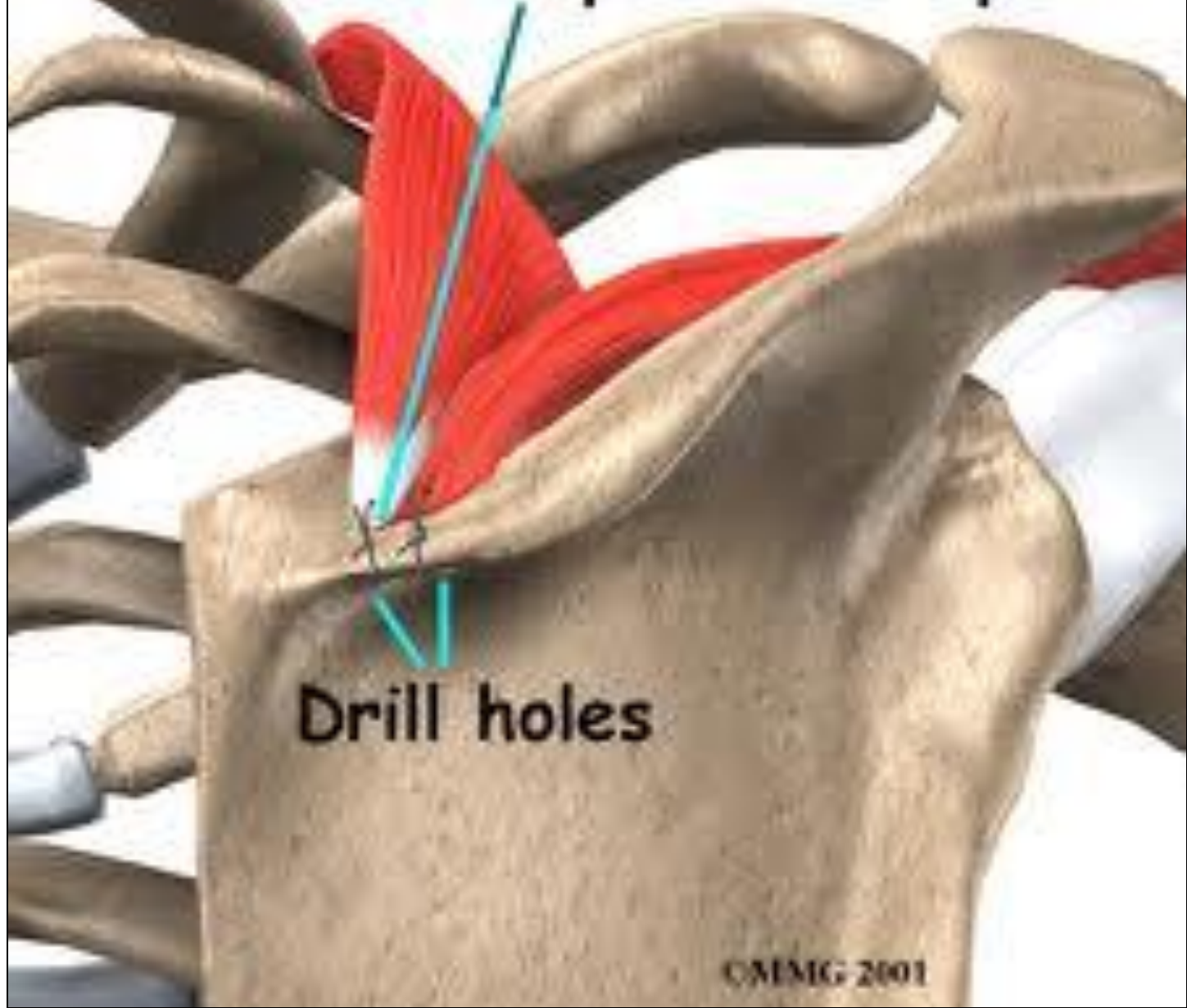


Posterior shoulder

Non-Operative Treatment



Ends of muscles sewn
onto spine of scapula

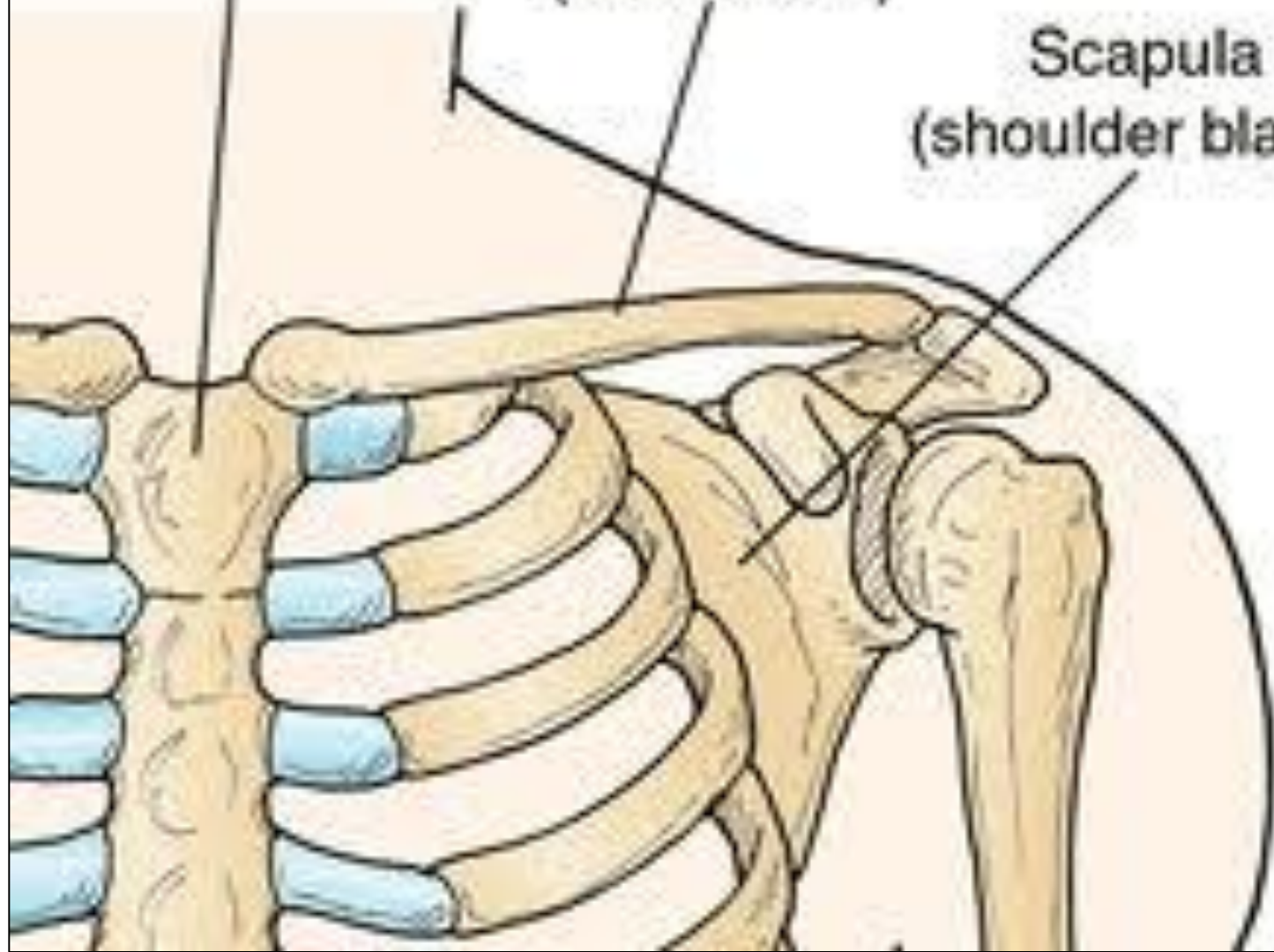


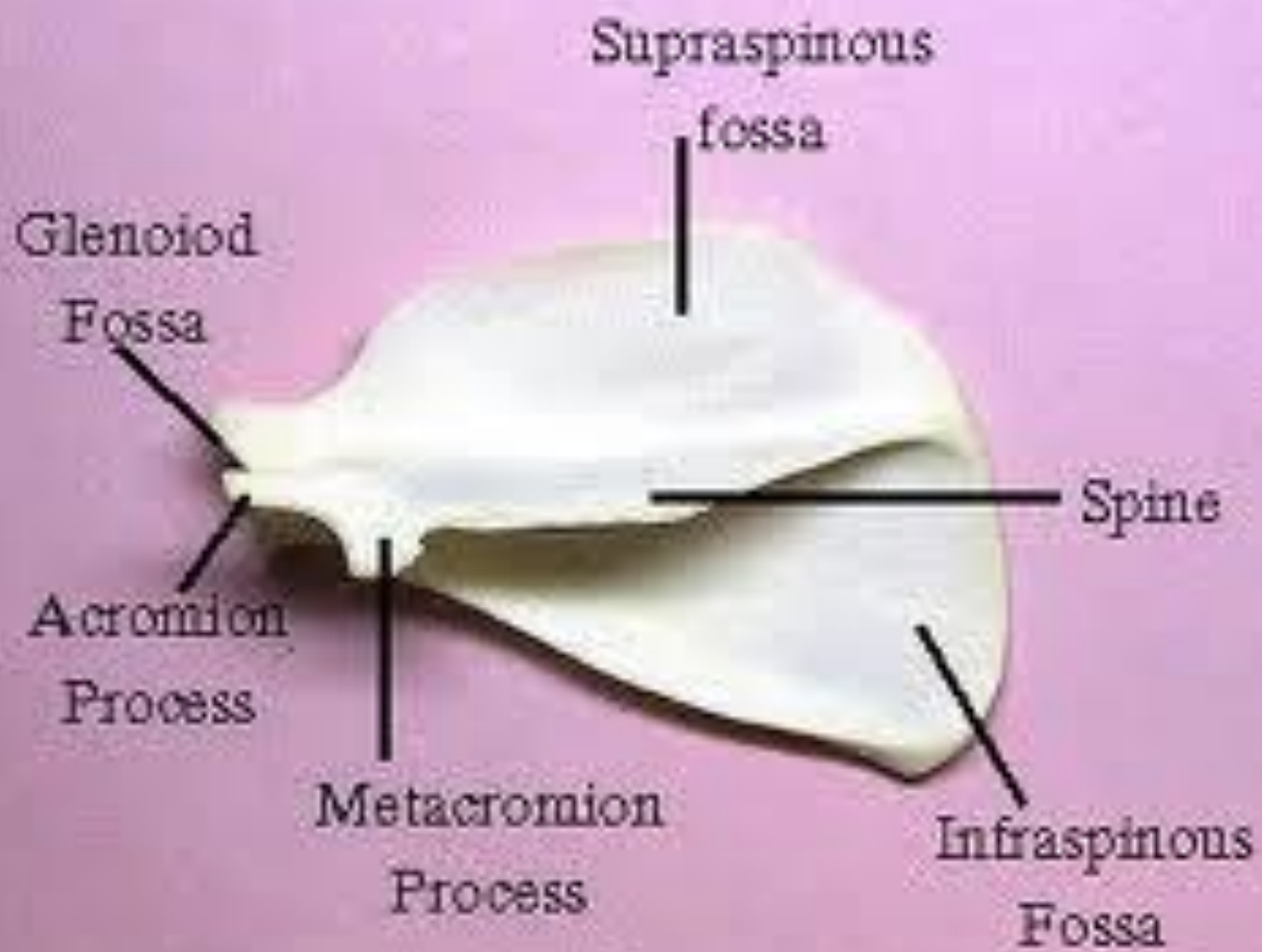Drill holes

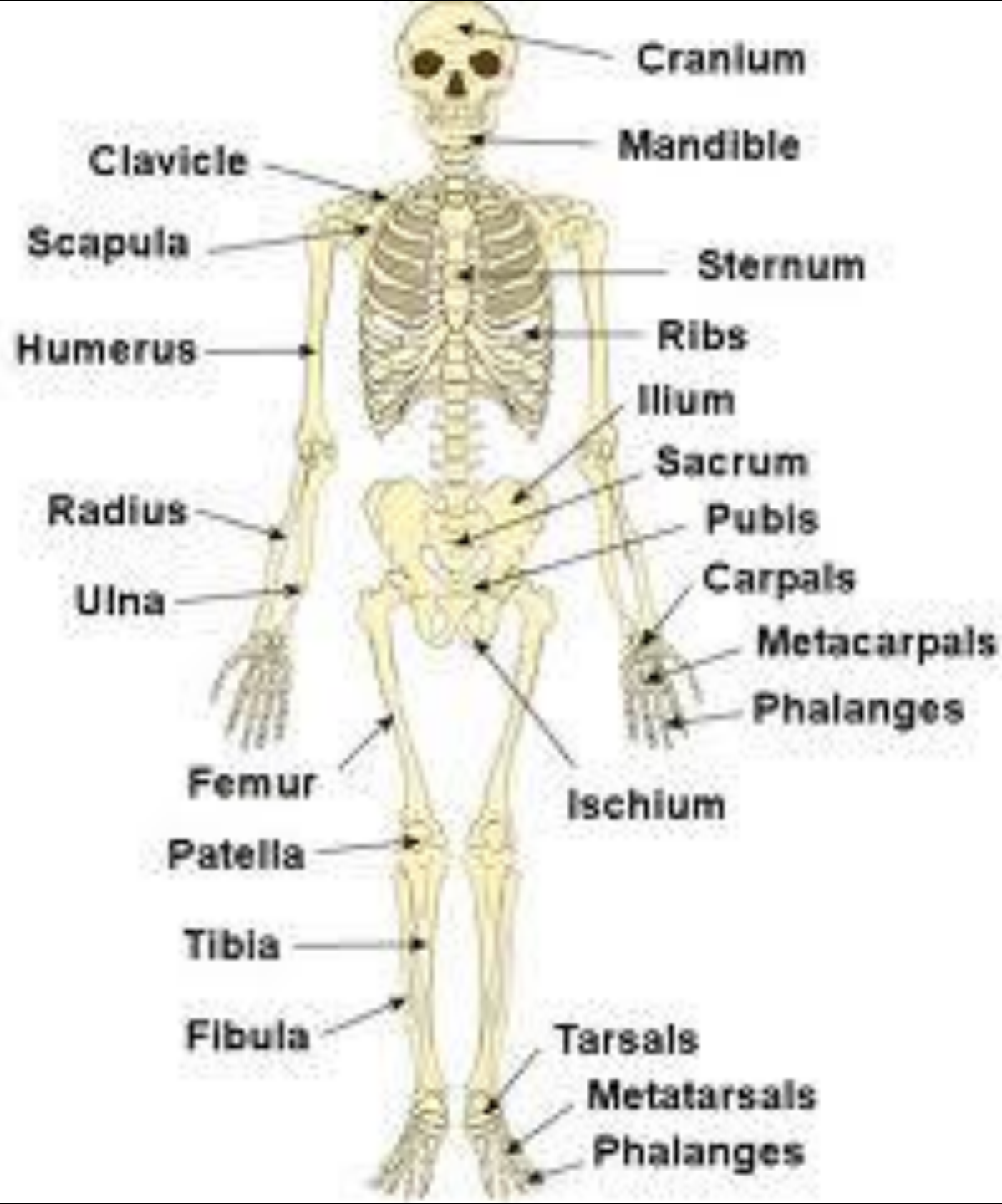Sternum
(breastbone)

Clavicle
(collarbone)

Scapula
(shoulder blade)







Acromion

Coracoid process

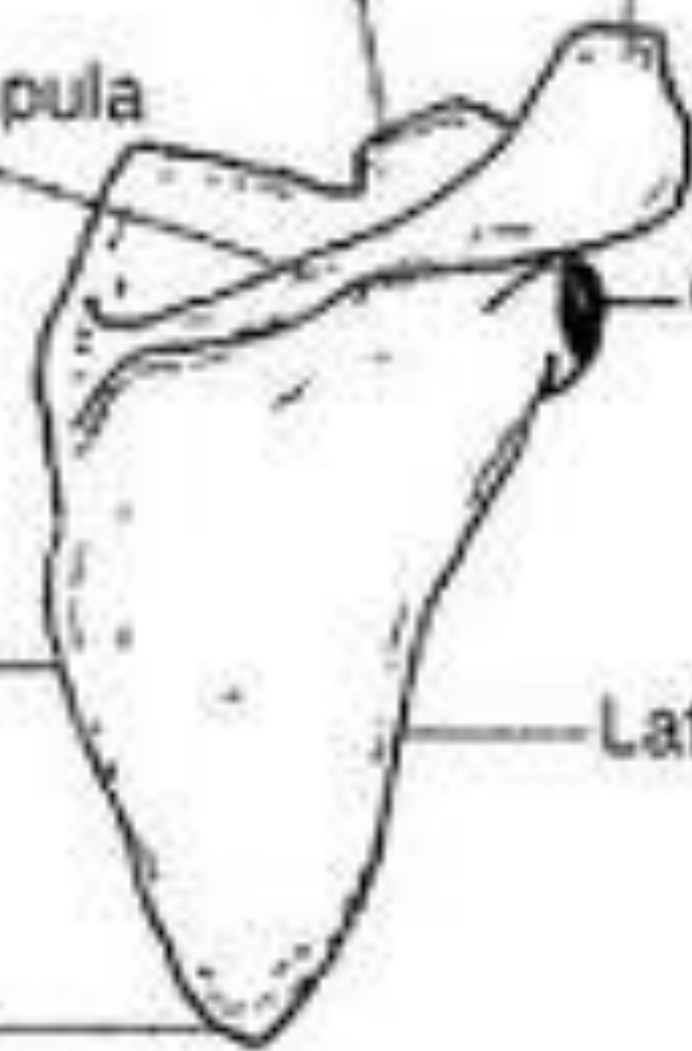Spine of scapula

Glenoid fossa

Medial border

Lateral border

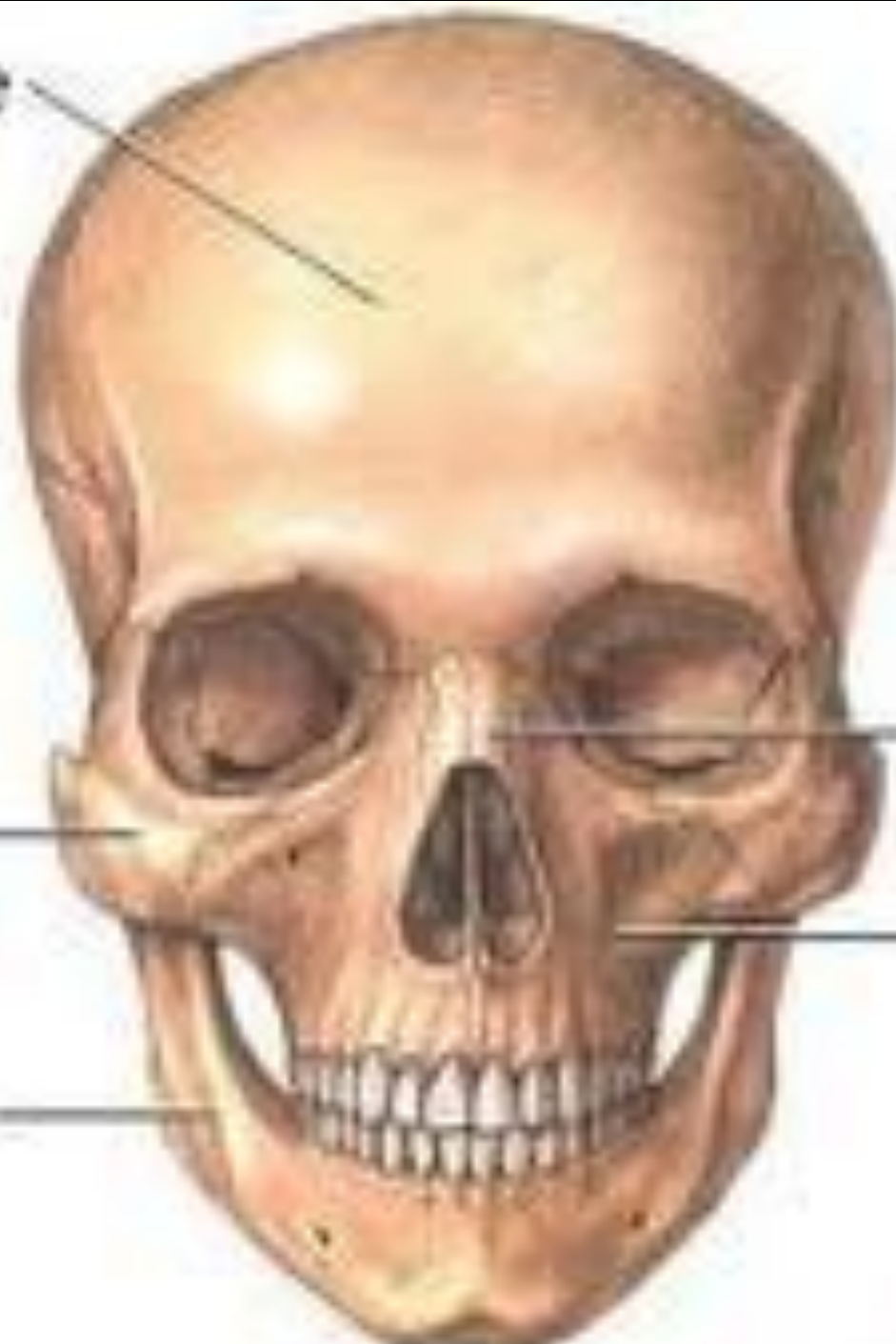
Inferior angle



Frontal bone

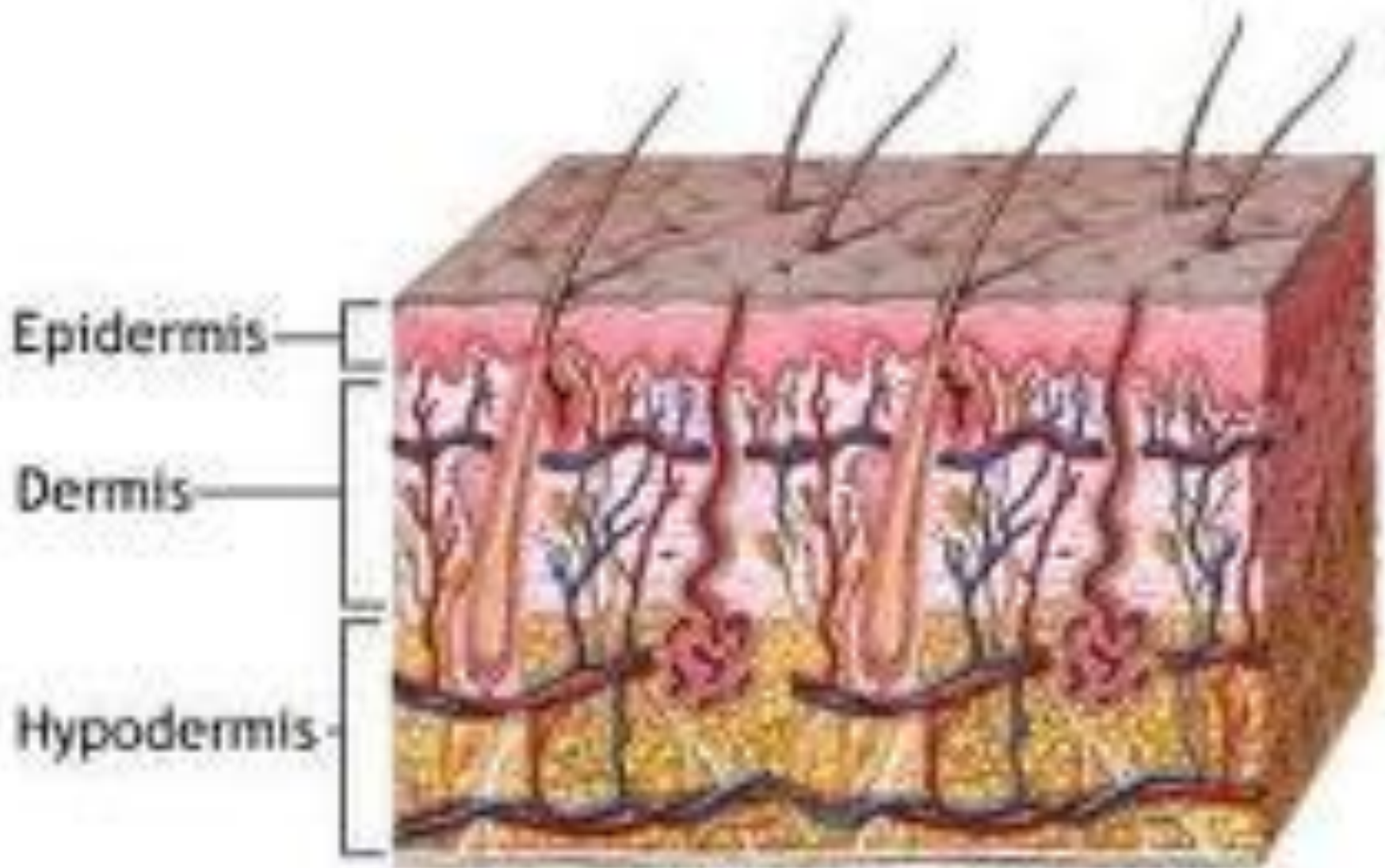
Zygomatic
bone

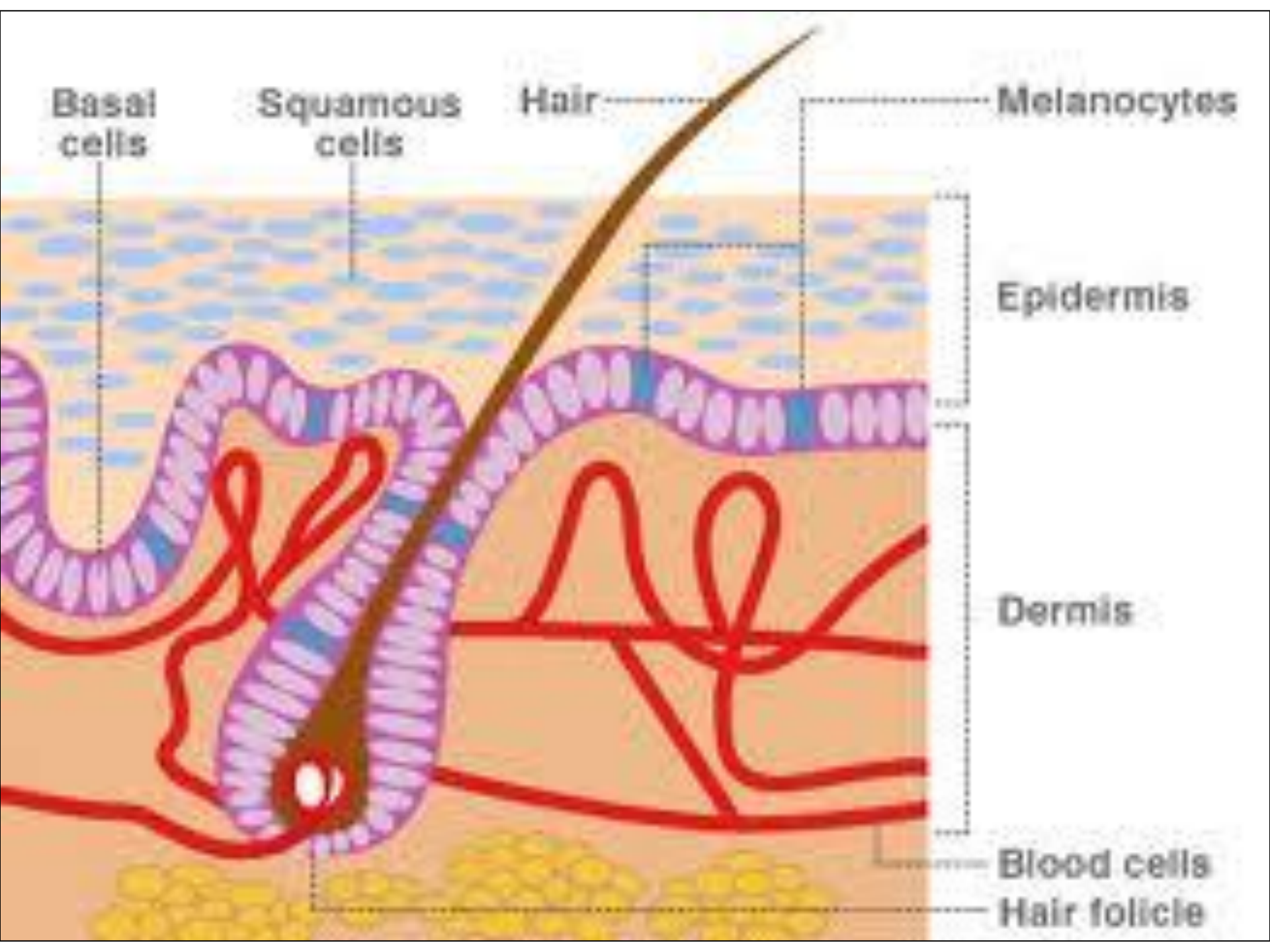
Mandible

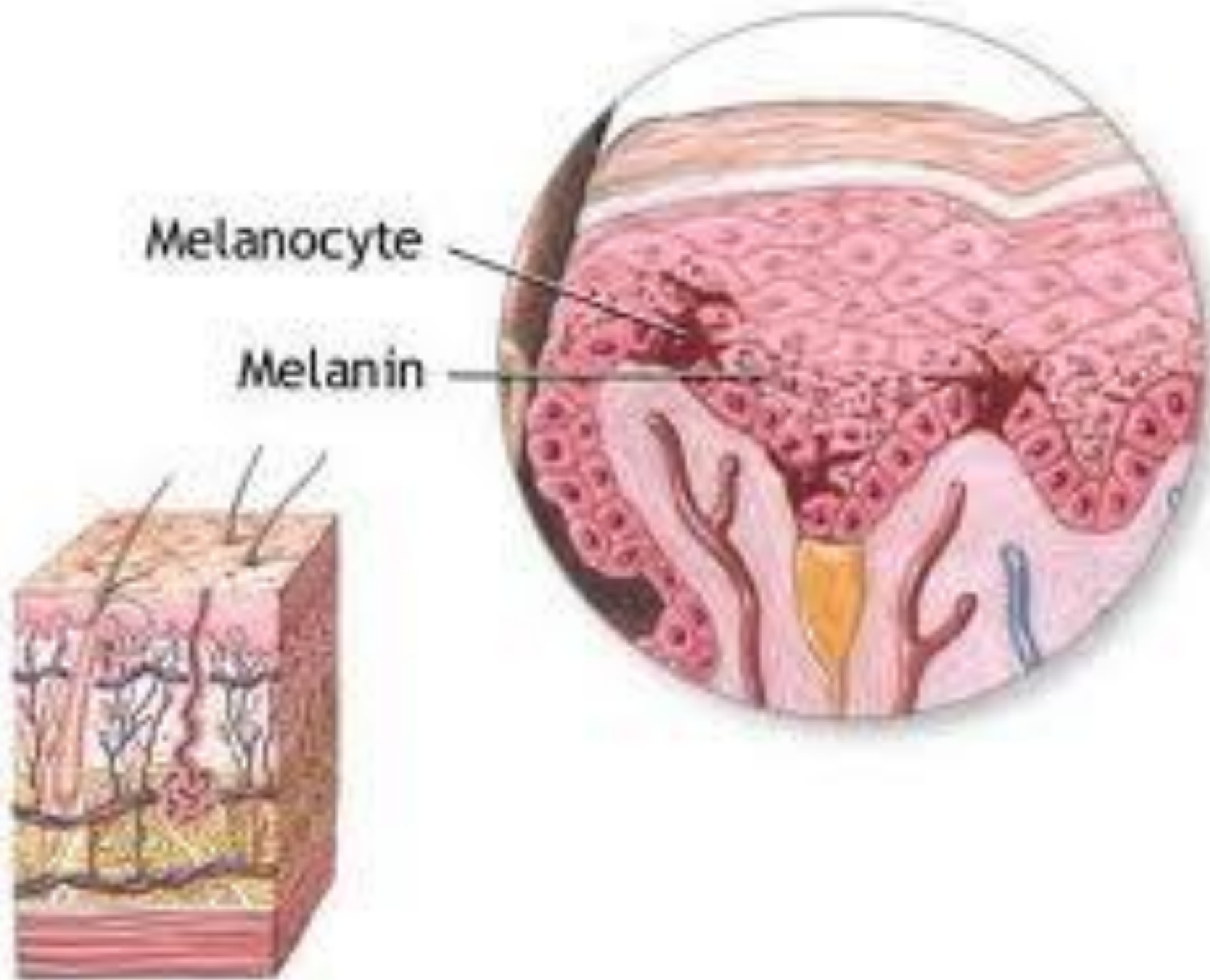


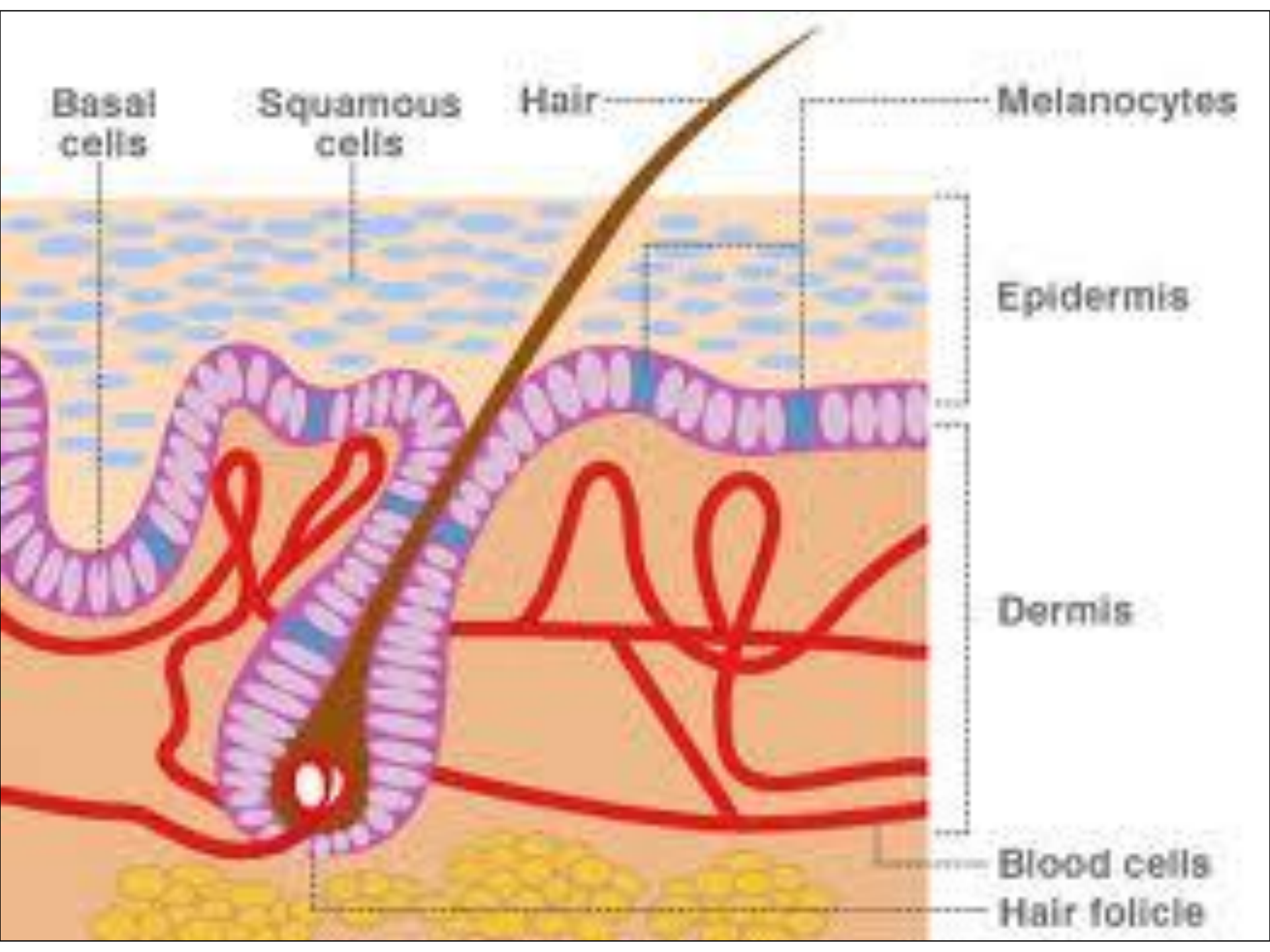
Nasal bone

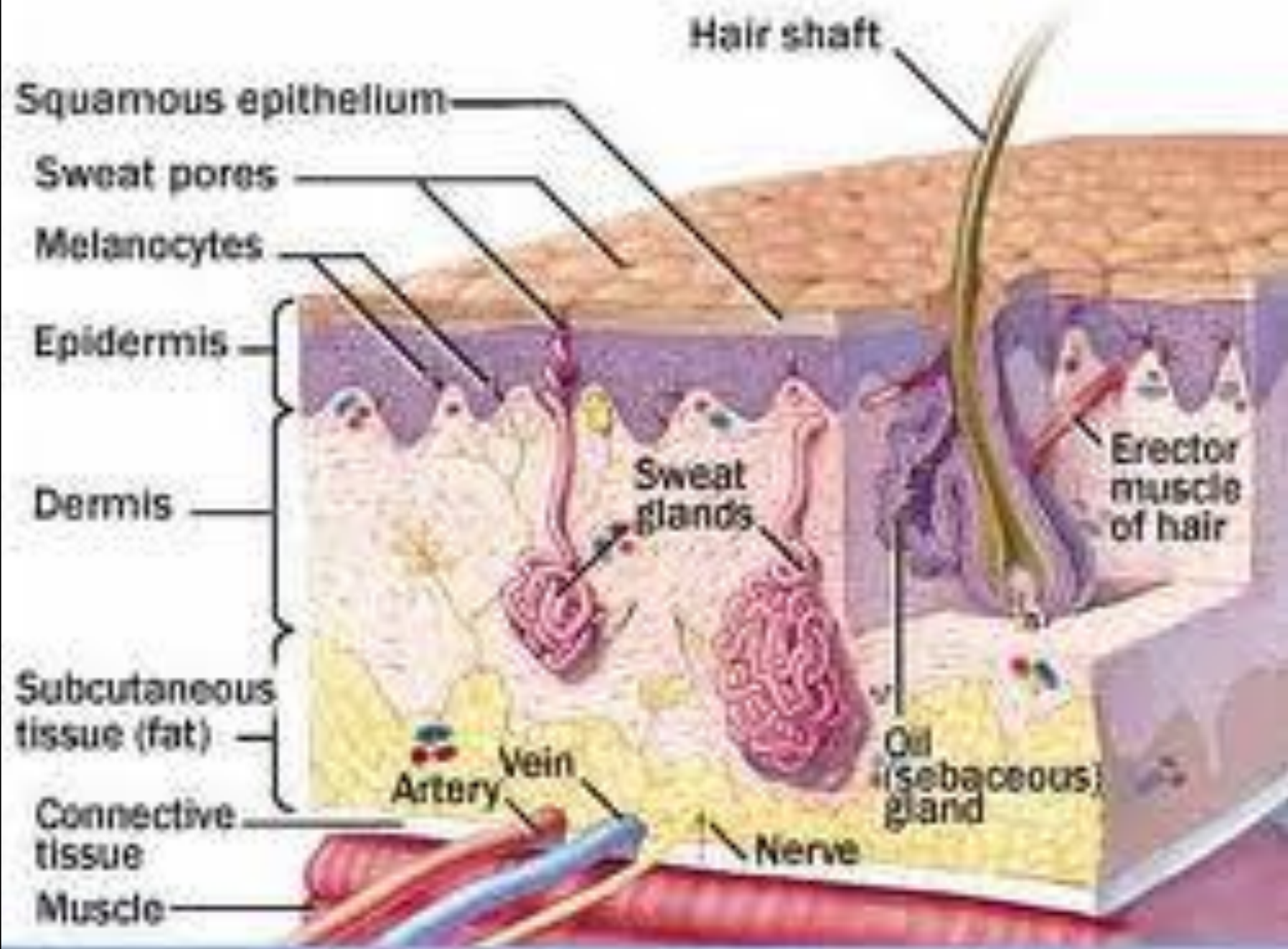
Maxilla

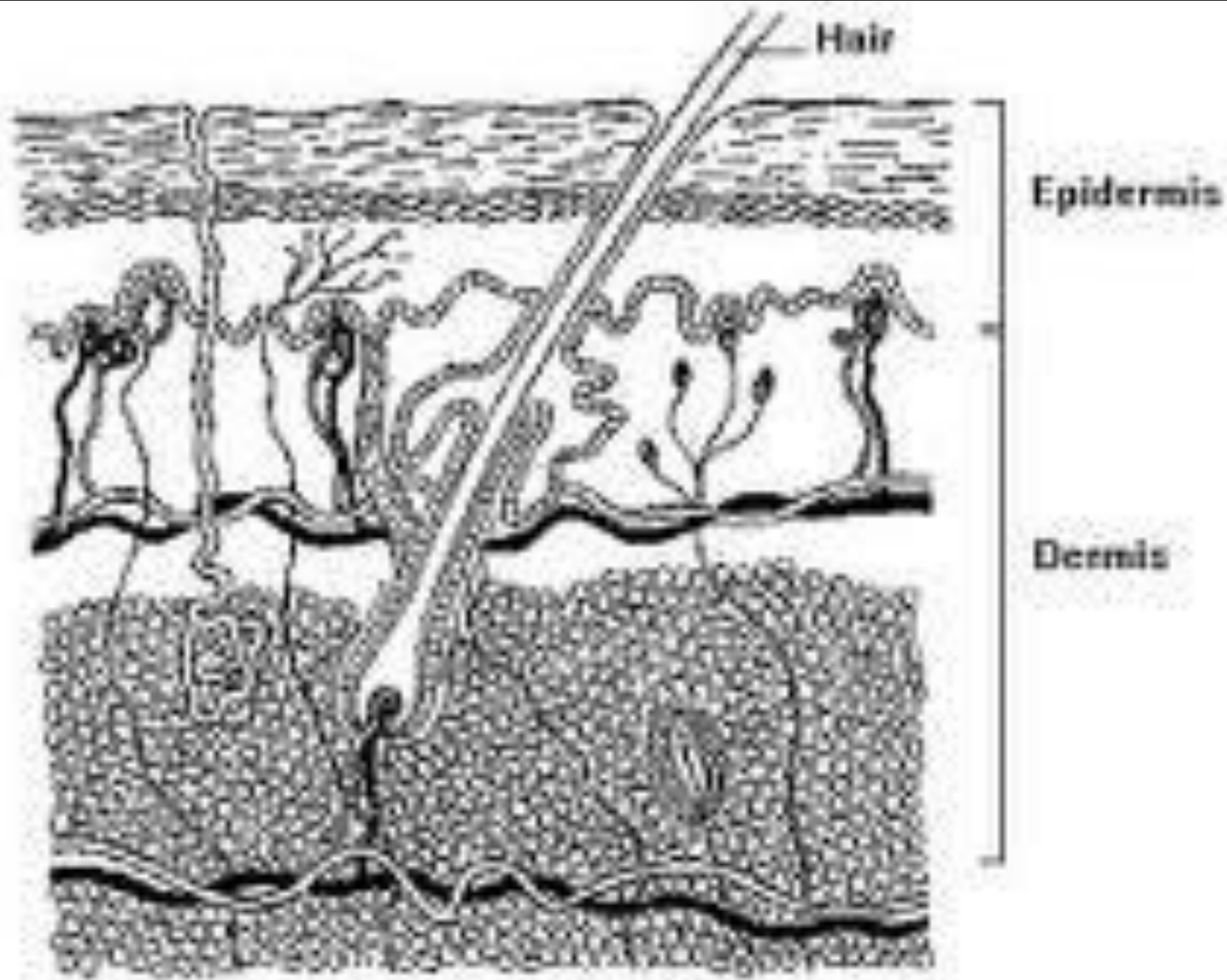












Parietal
bone

Frontal bone

Temporal
bone

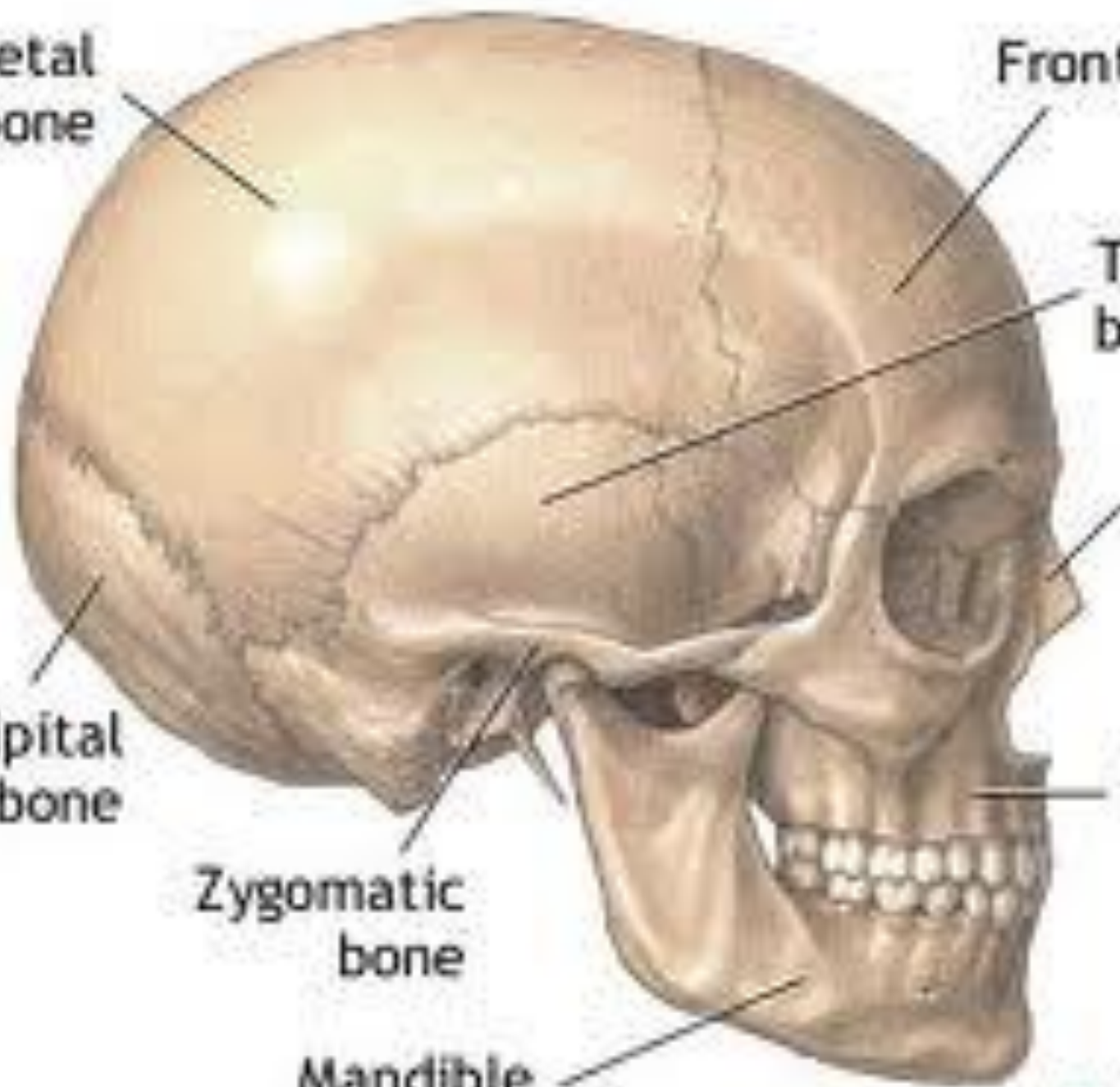
Nasal
bone

Occipital
bone

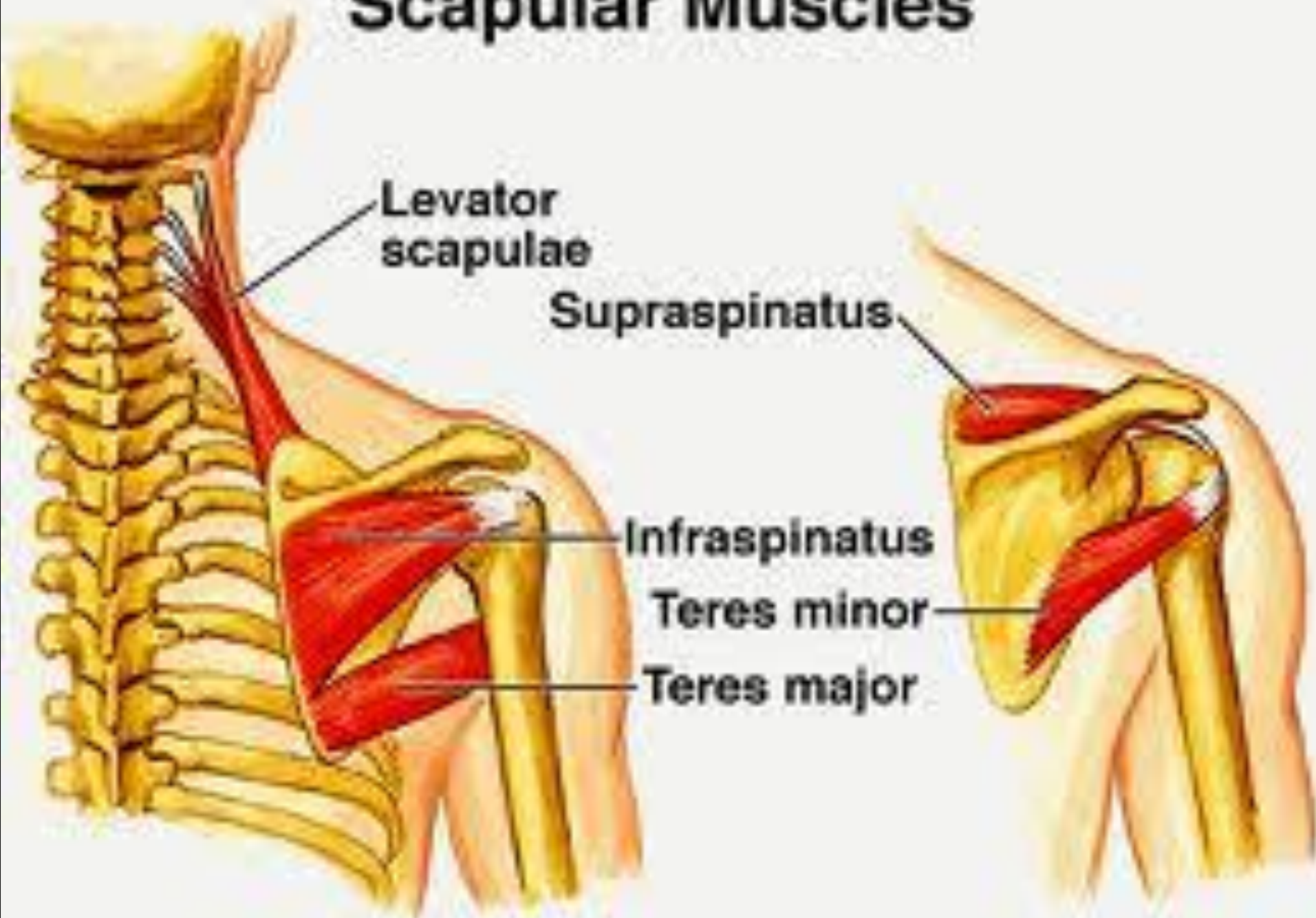Maxilla

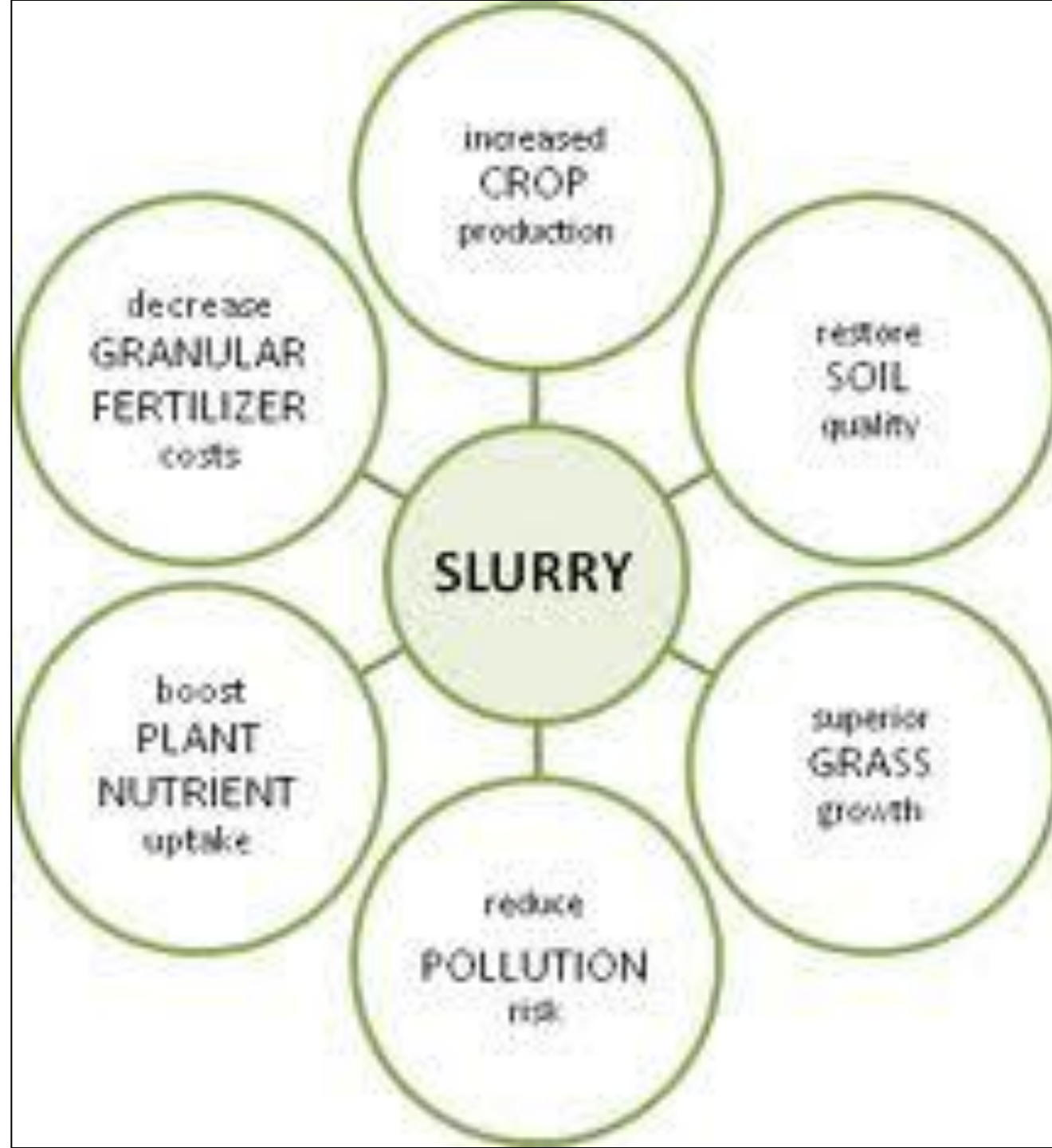Zygomatic
bone

Mandible

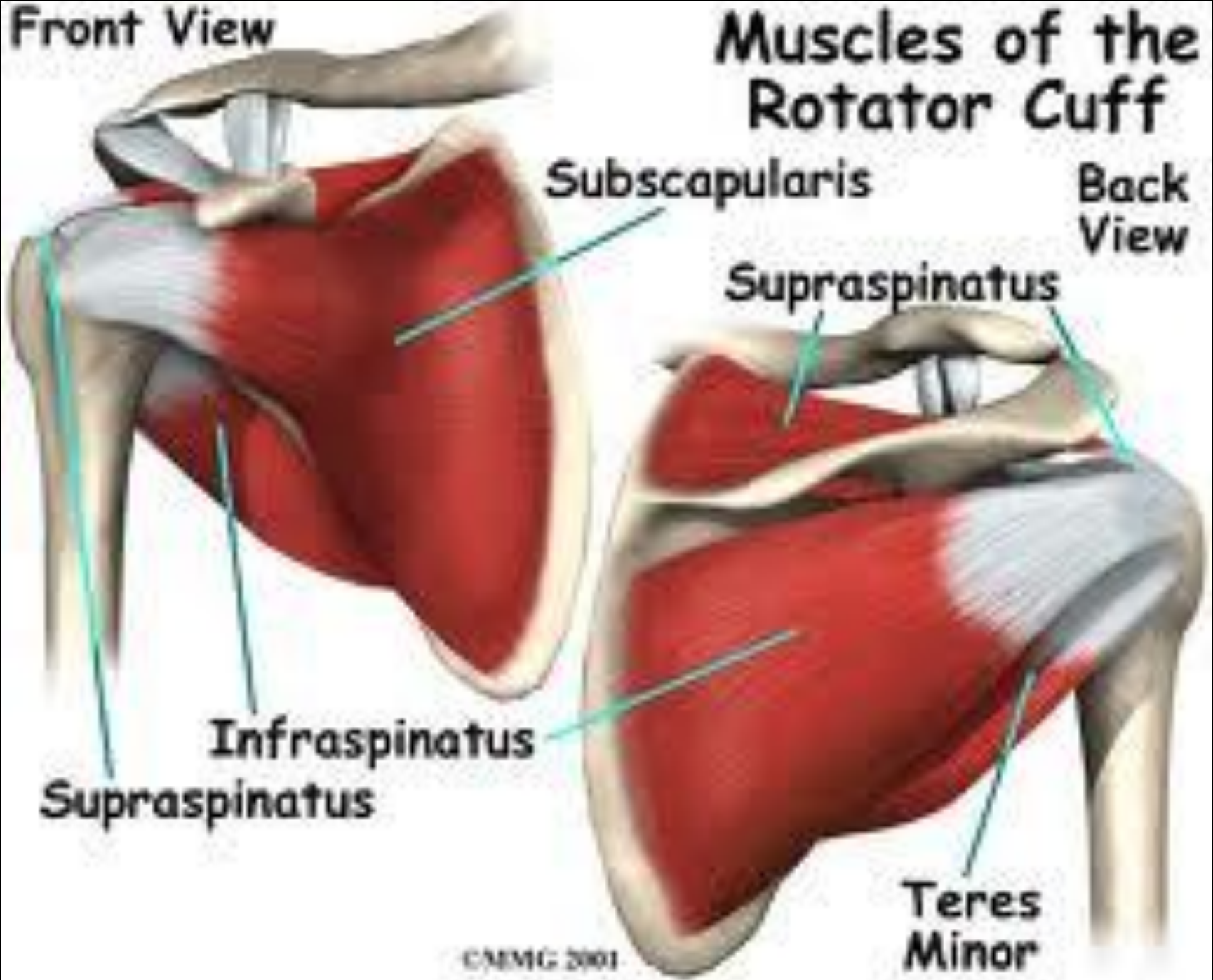


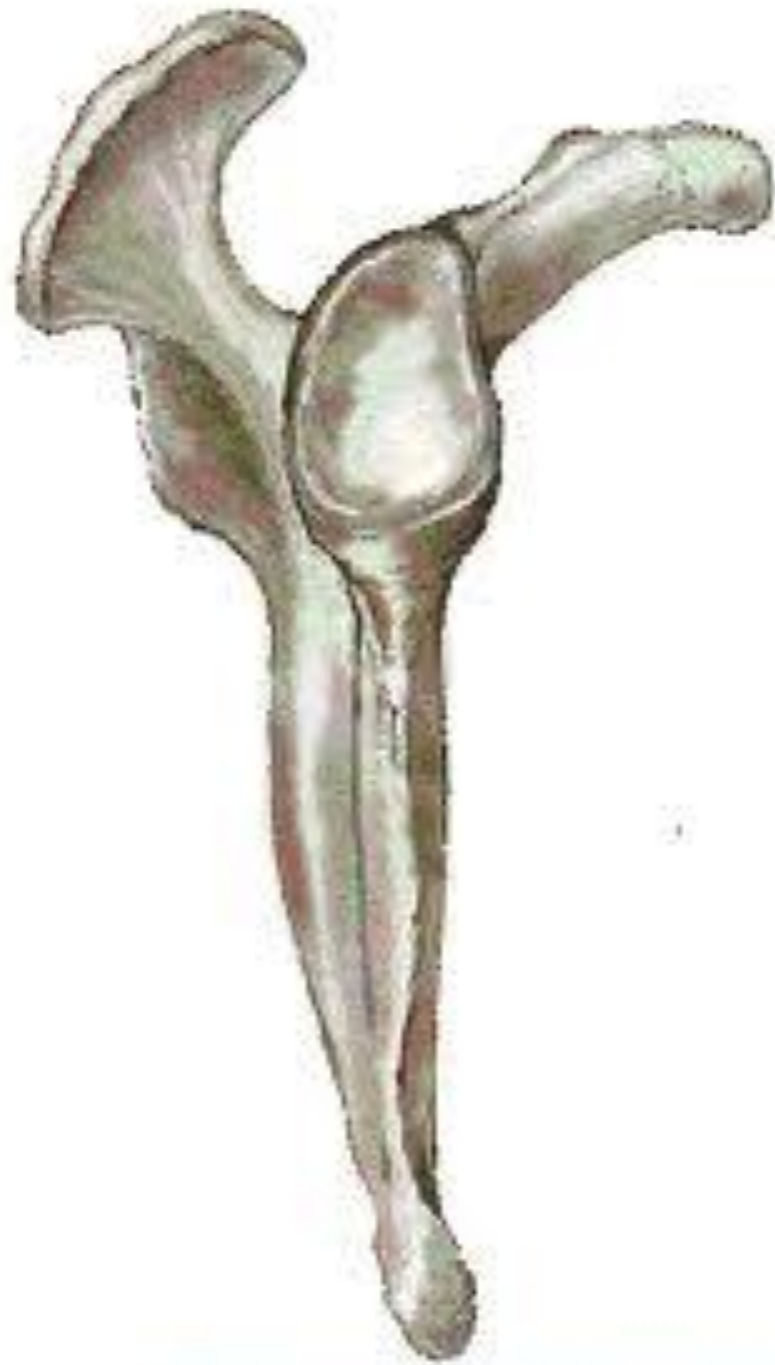Scapular Muscles

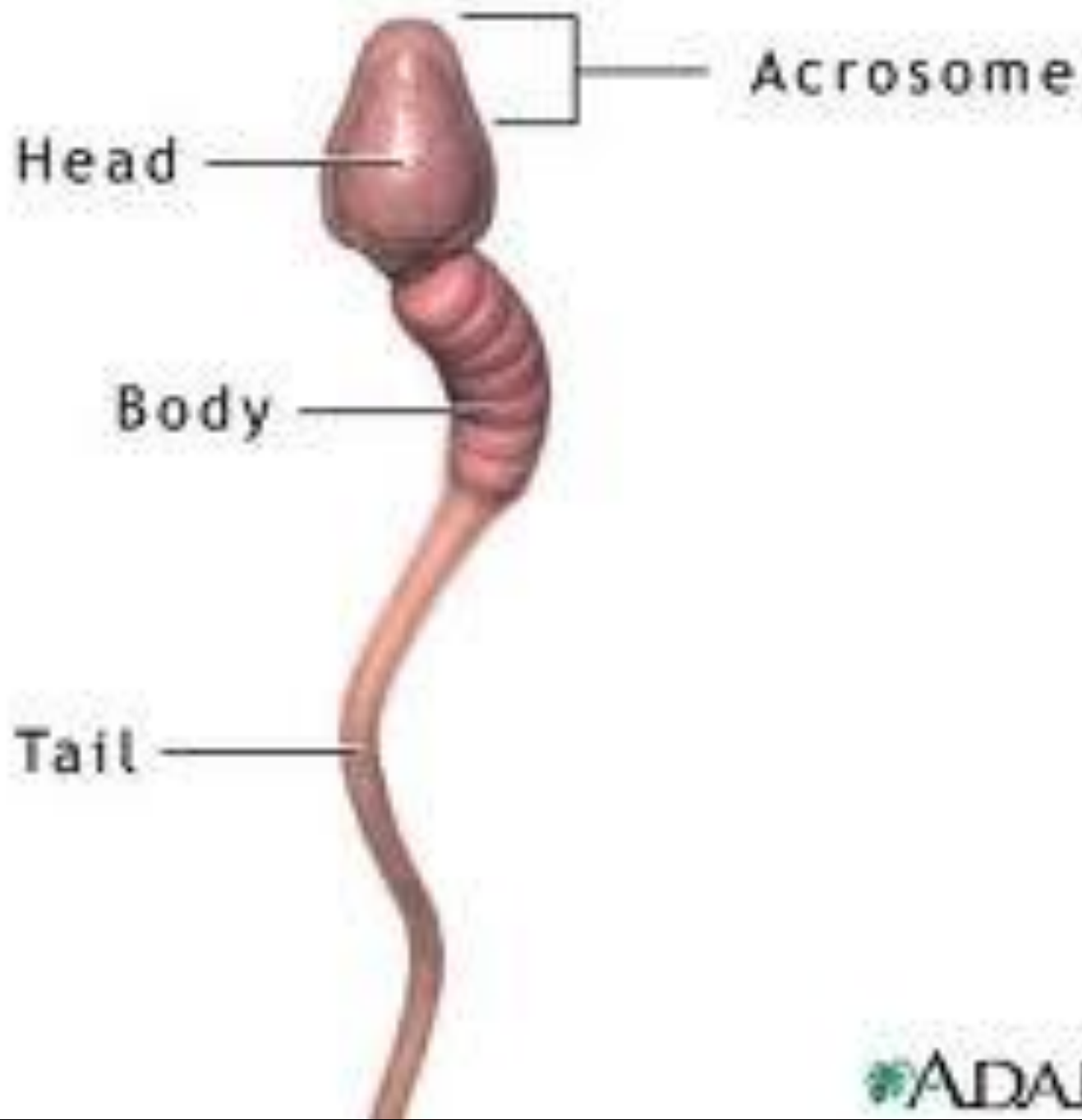


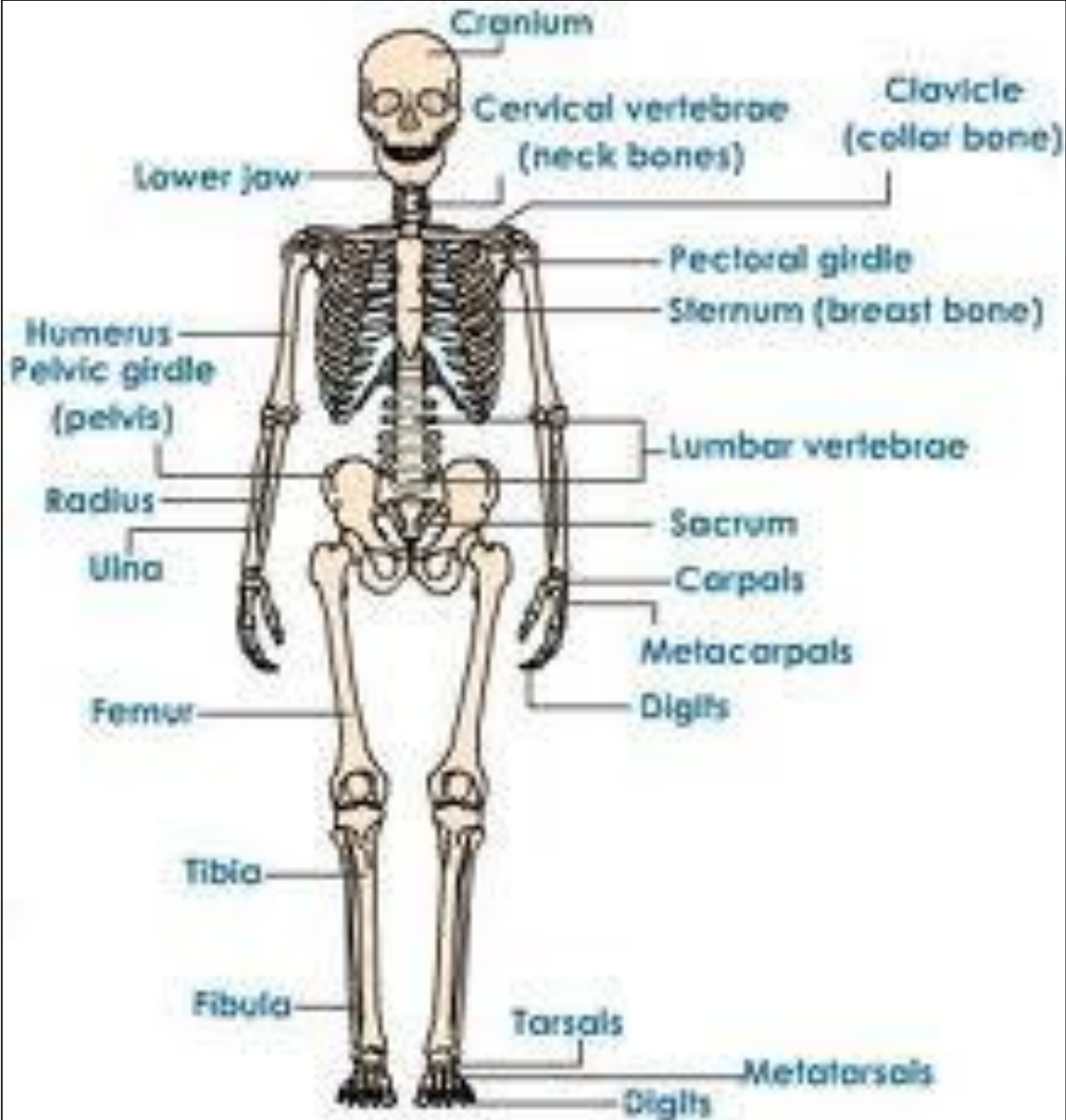


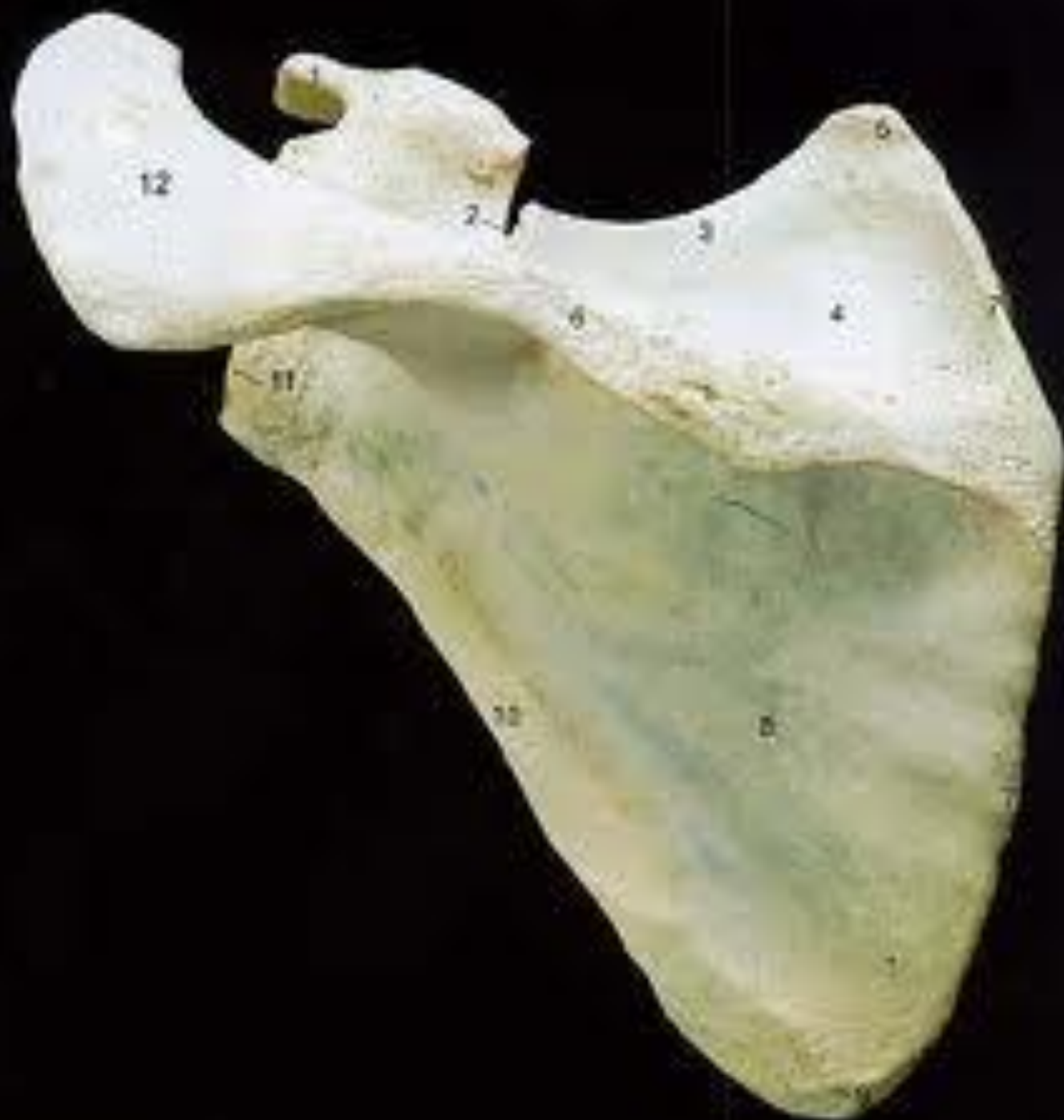Muscles of the Rotator Cuff



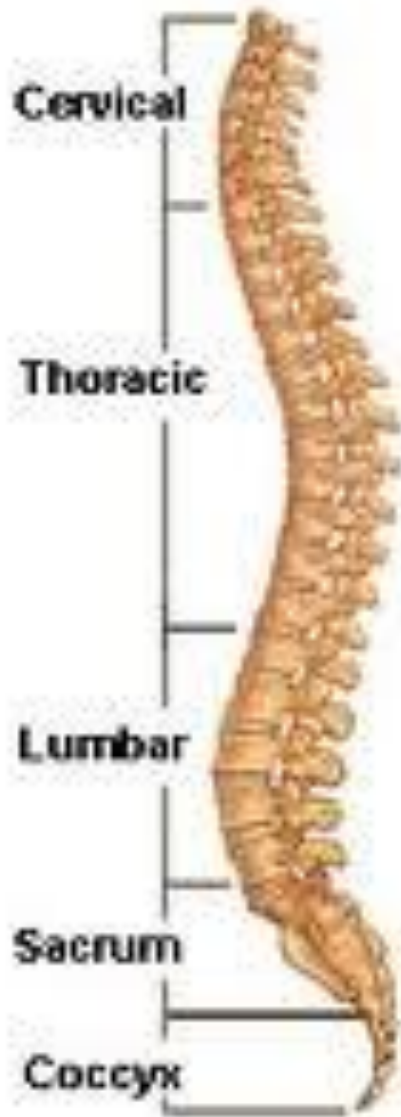



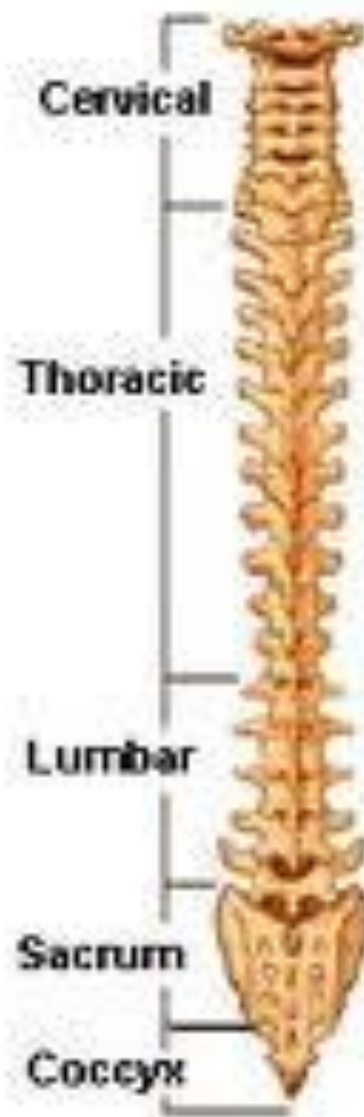




**Lateral (Side)
Spinal Column**



**Posterior (Back)
Spinal Column**



Bones of the Shoulder

Clavicle

Clavicle

Scapula

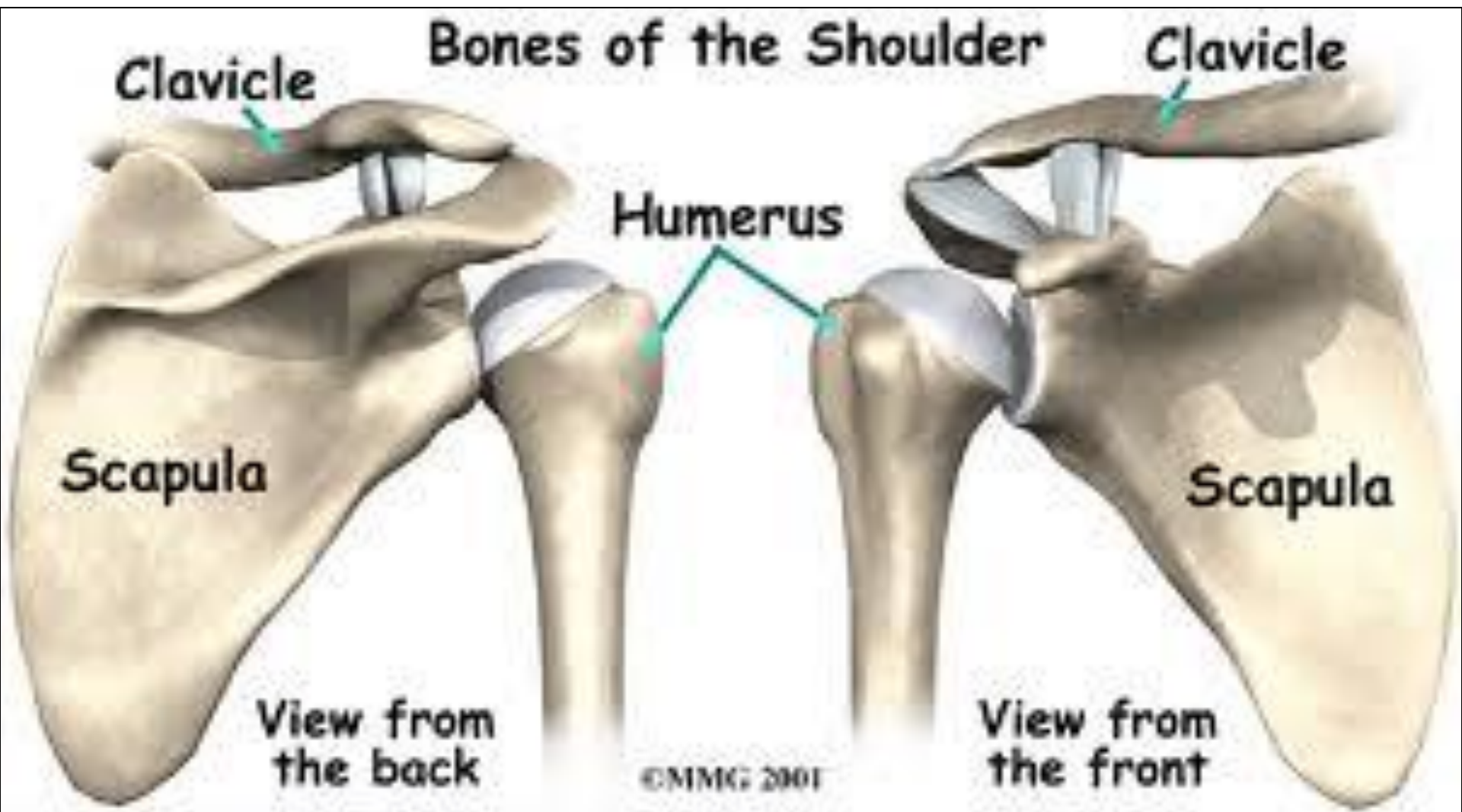
Humerus

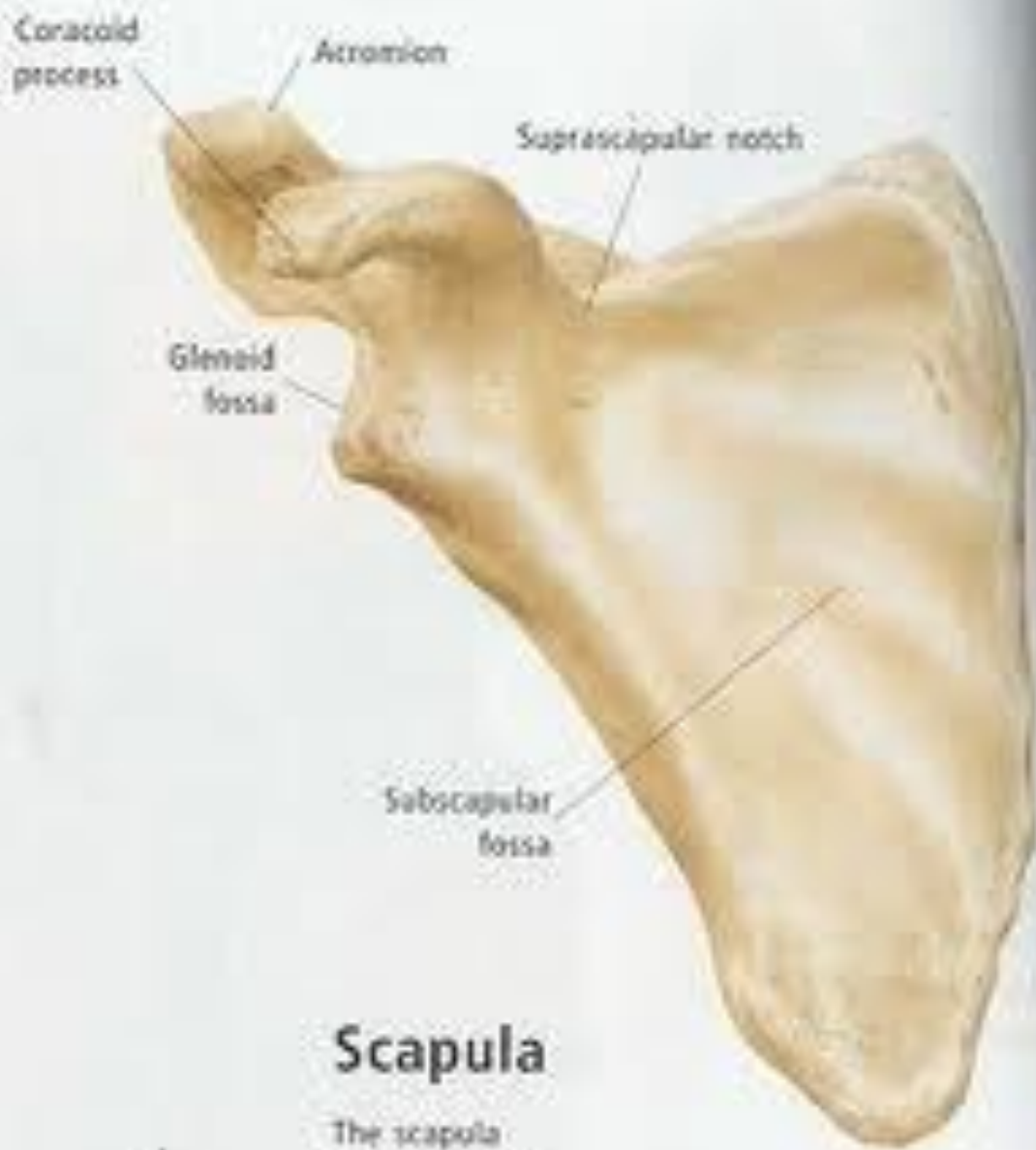Scapula

View from the back

View from the front

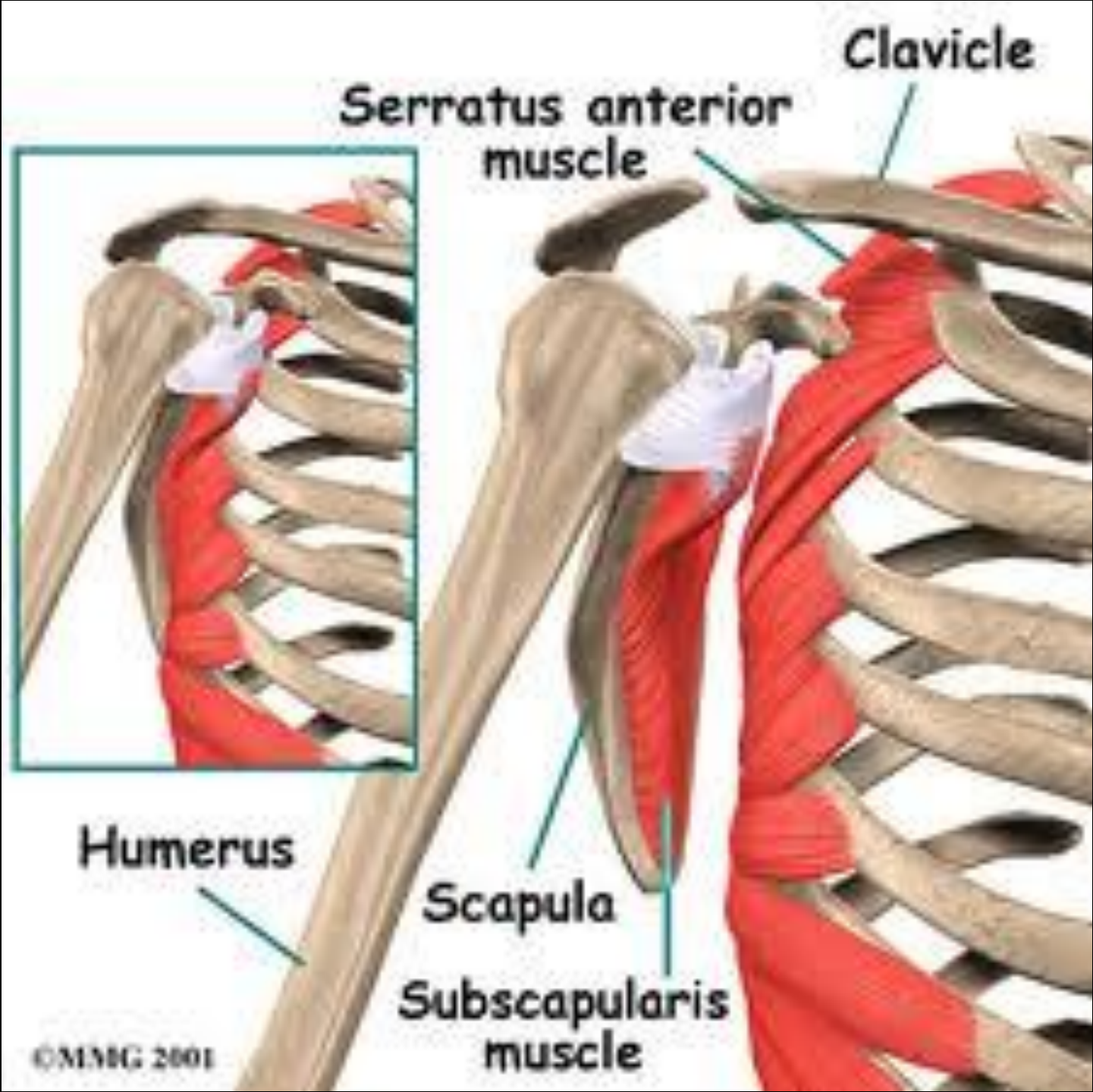
©MMG 2001



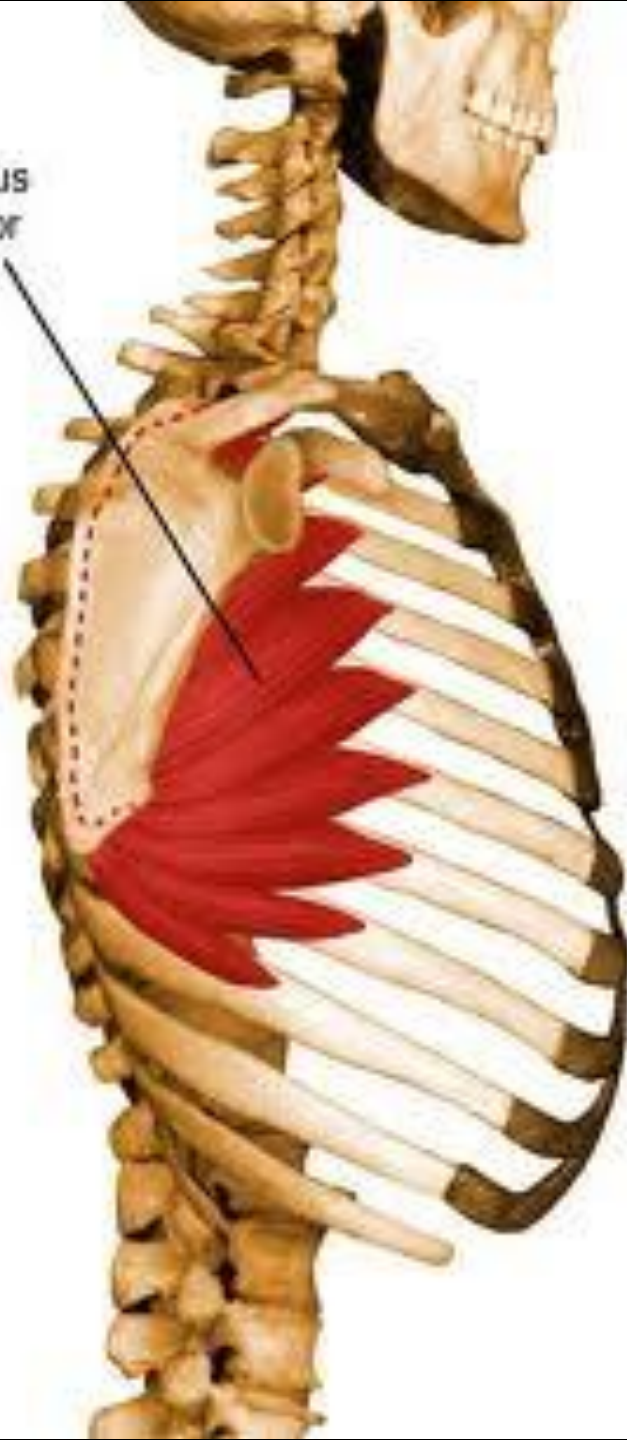


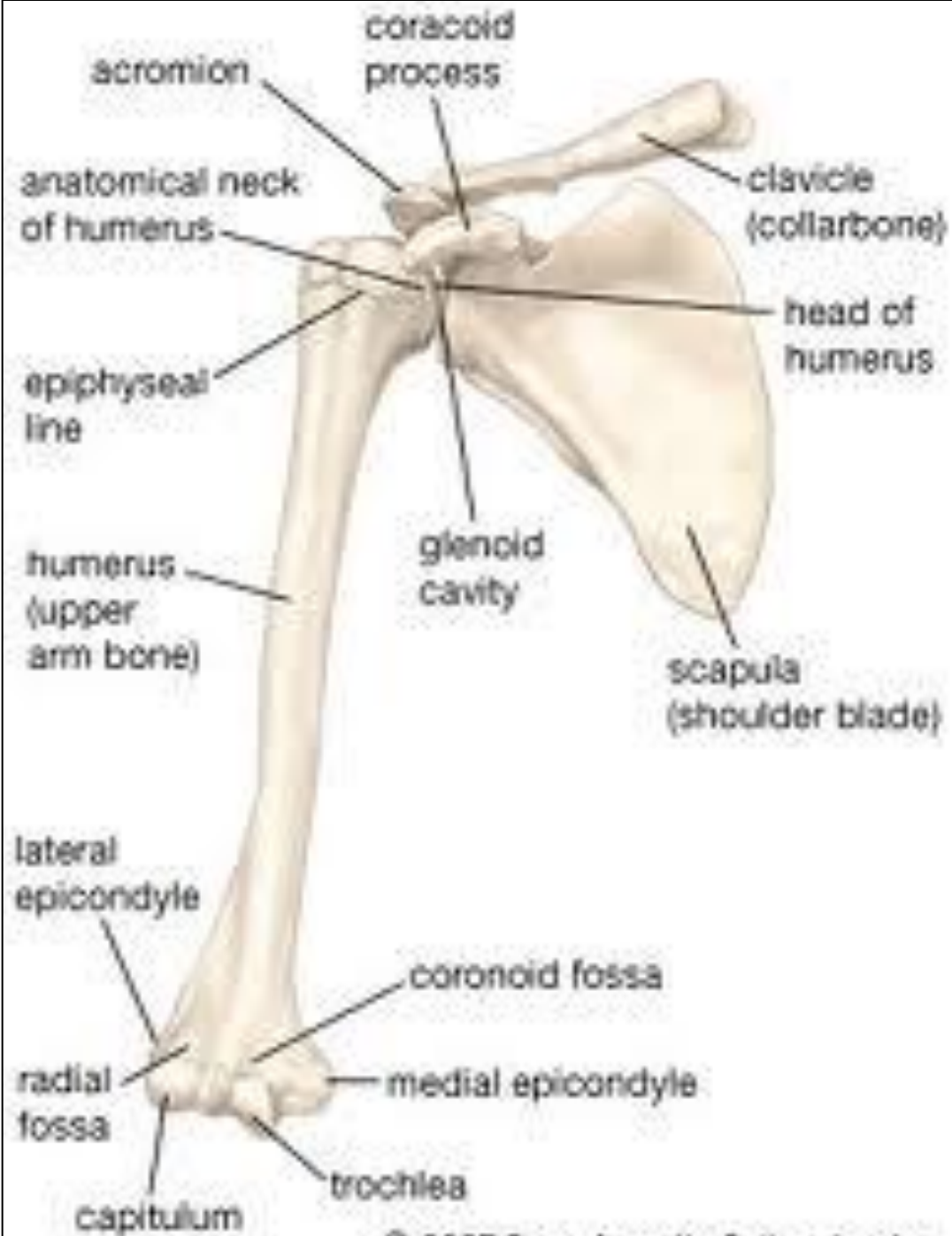
Scapula

The scapula (shoulder blade) is a flat triangular bone located in the back of the shoulder.



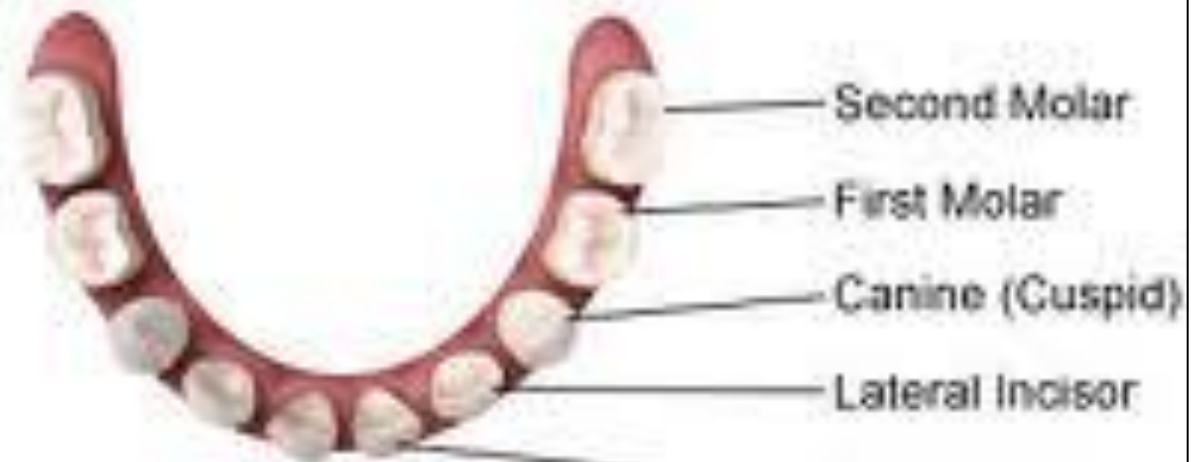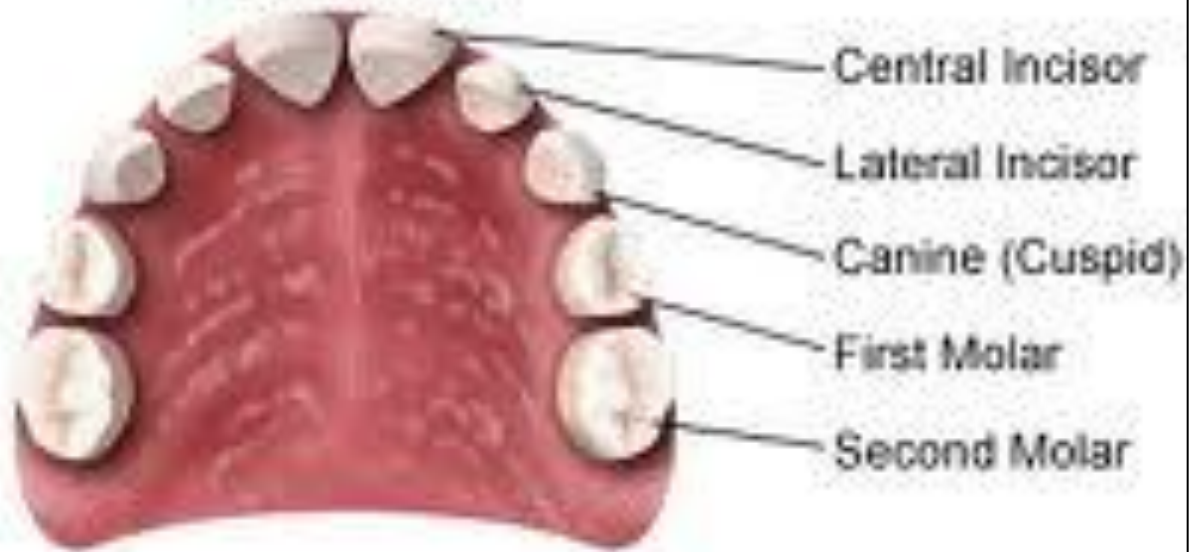
serratus
anterior





Baby Teeth

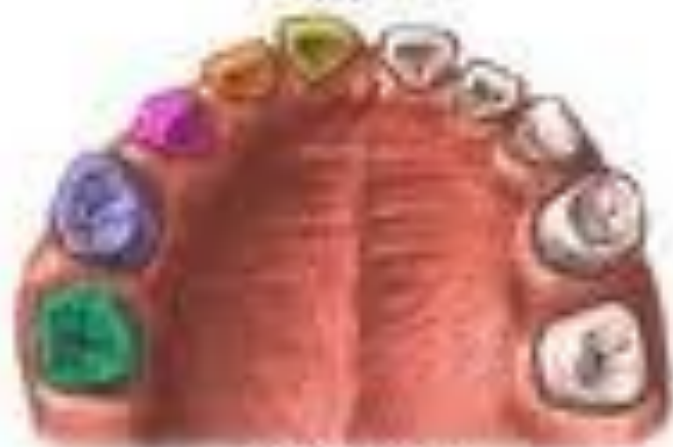Upper Teeth



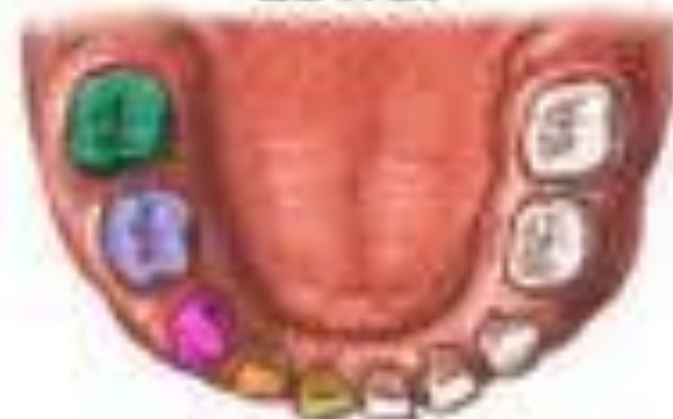Lower Teeth

Upper

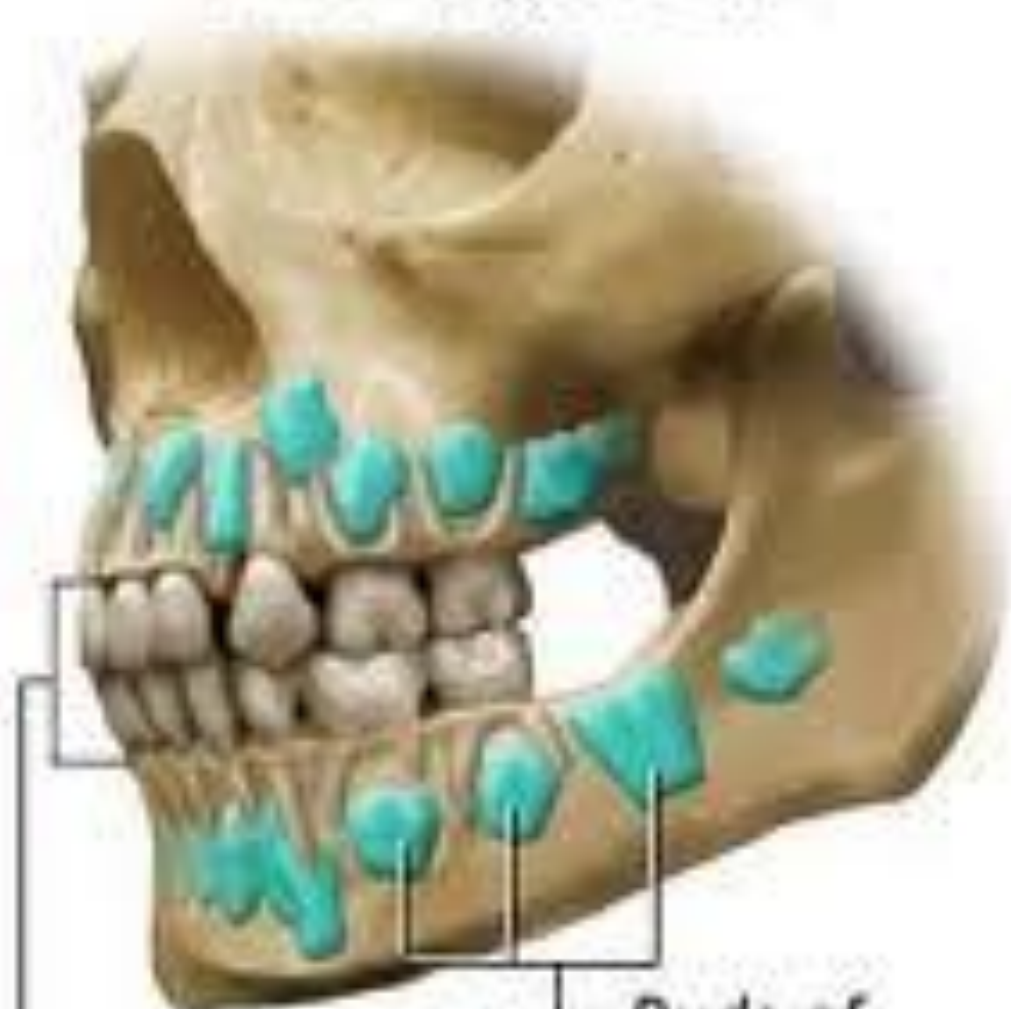Child 2-5 years old



Lower

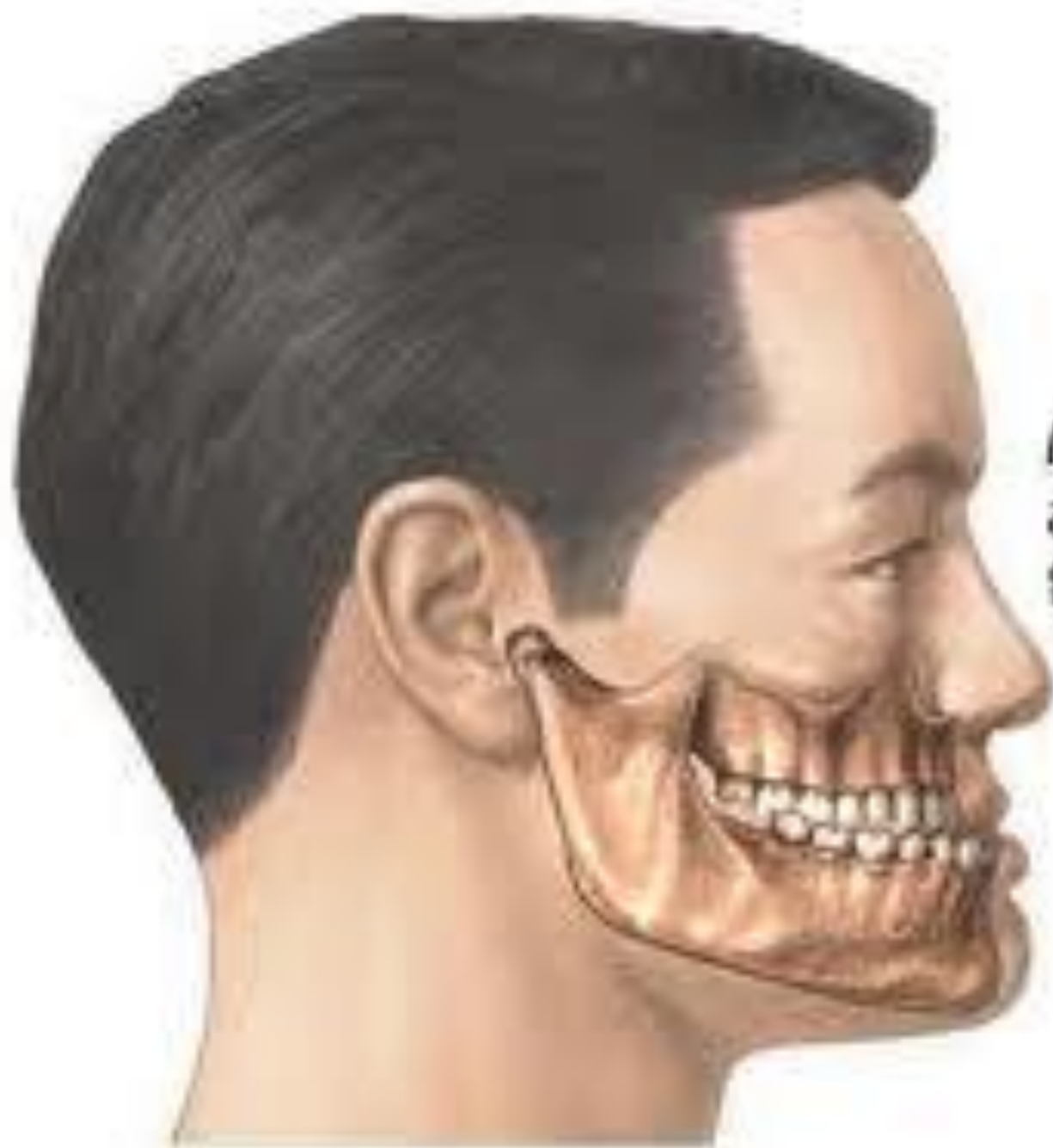

- Central incisor
- Lateral incisor
- Cuspid (canine)
- First molar
- Second molar



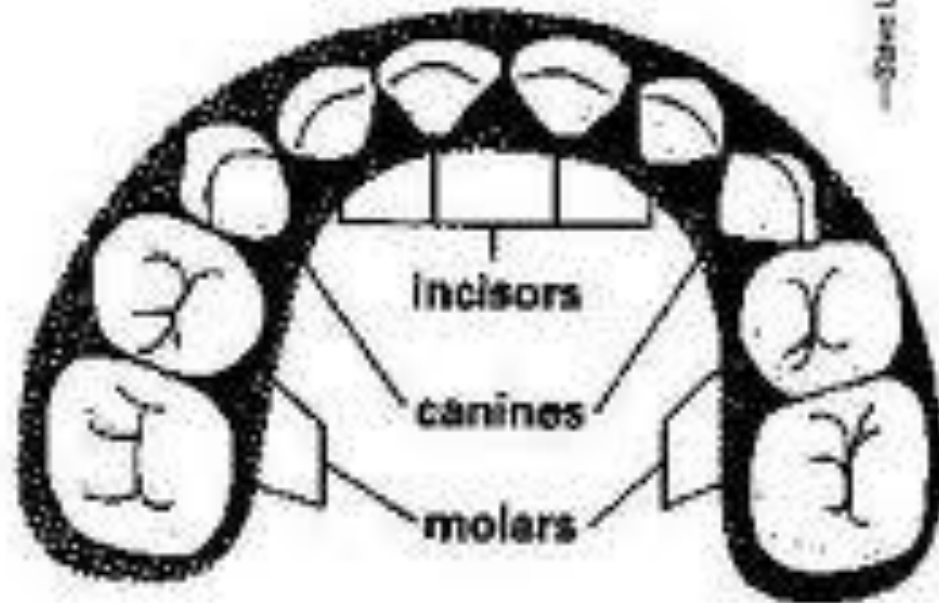
Deciduous (milk) teeth

Buds of permanent teeth



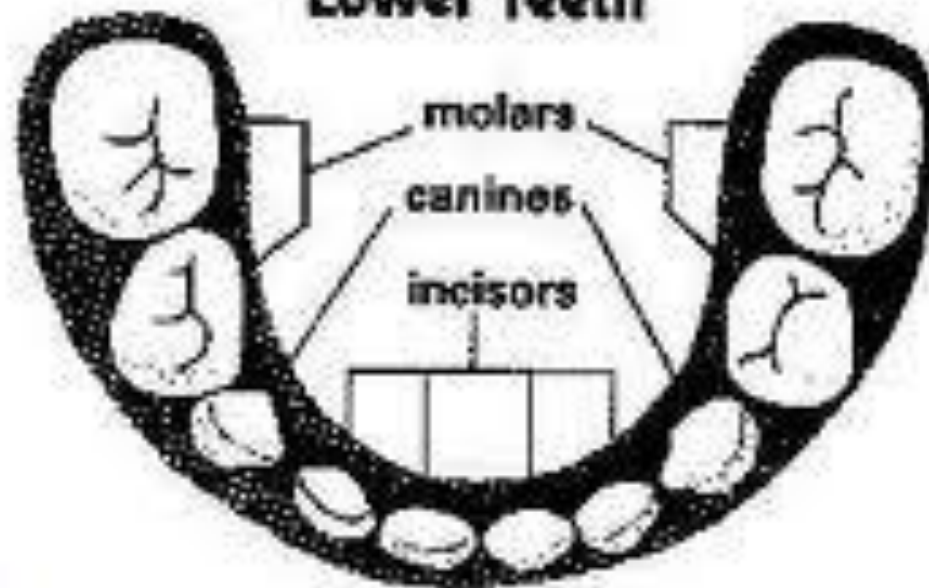
Malocclusion
and unbalanced
facial profile

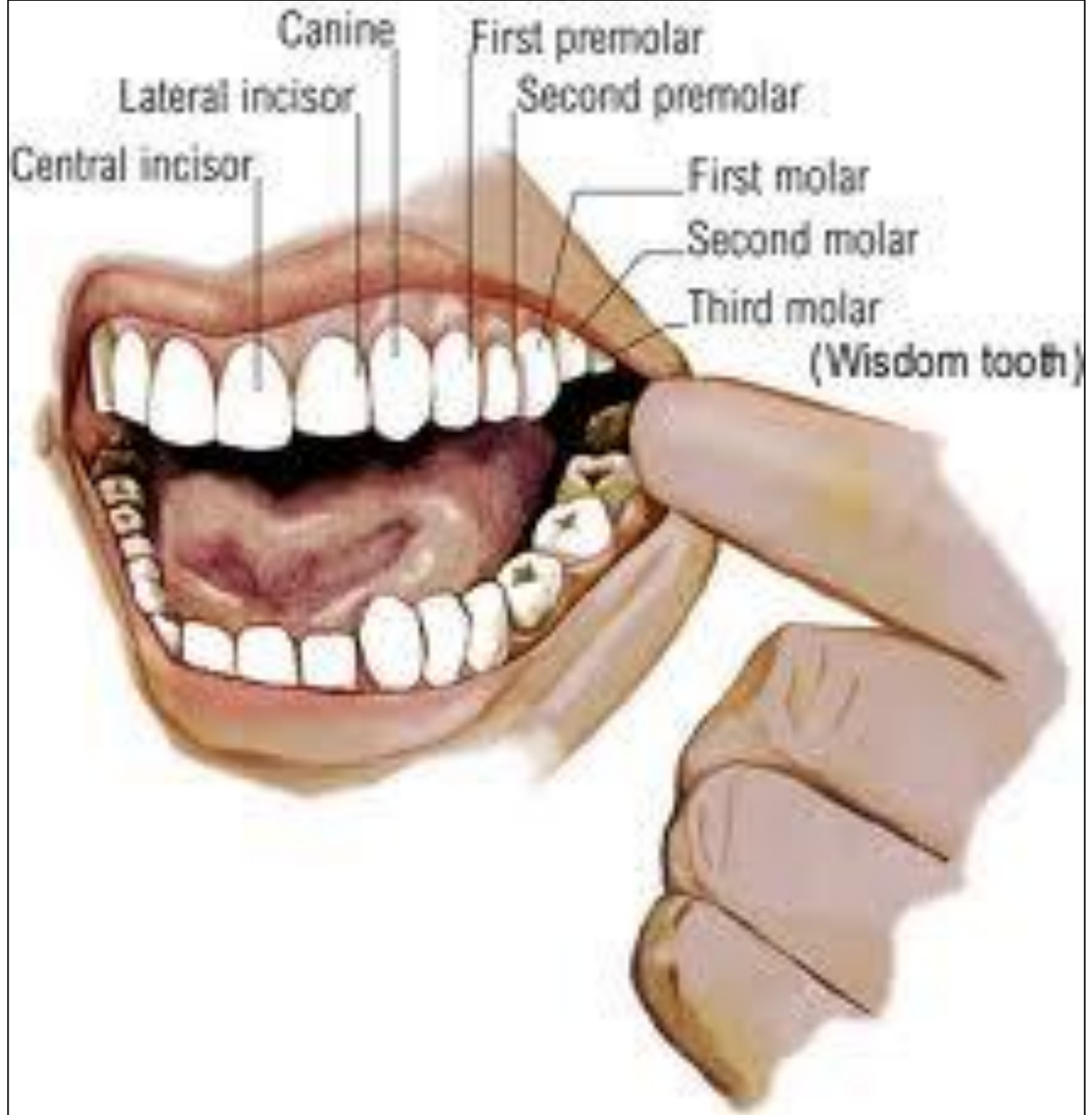
Upper Teeth



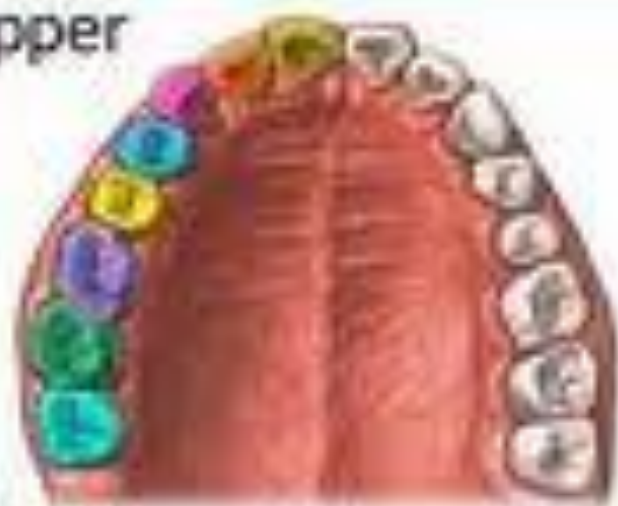—Steve Lefkowitz

Lower Teeth

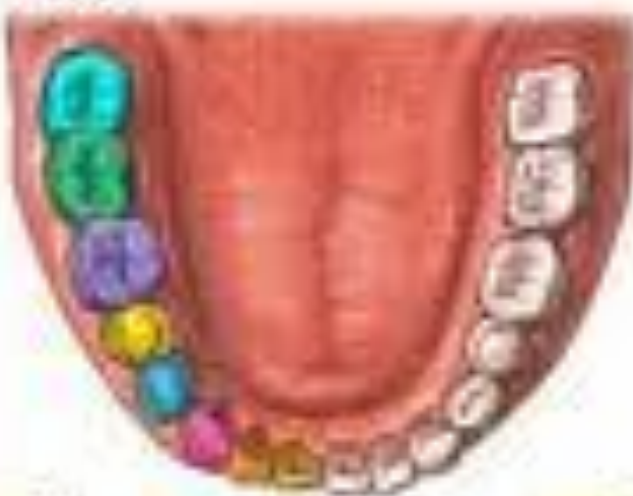



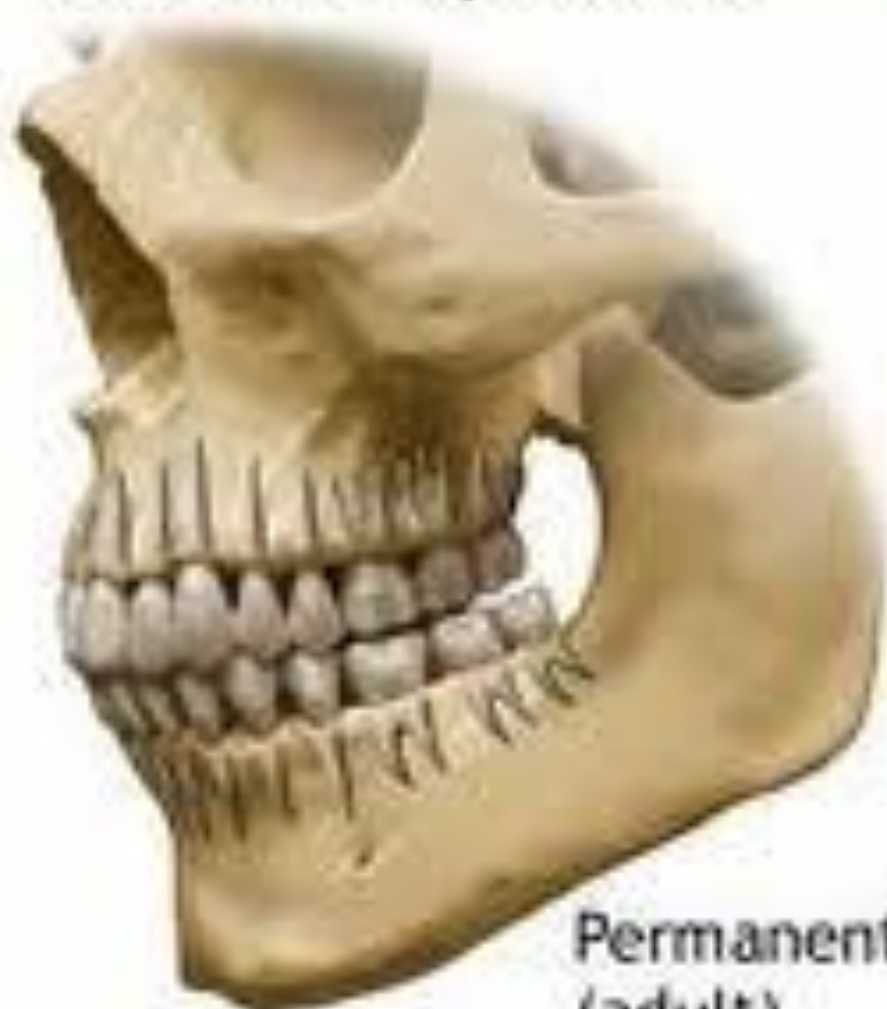Upper



Lower



Adult 21-25 years old



Permanent
(adult)
teeth

- | | |
|---|--|
|  Central incisor |  Second premolar (bicuspid) |
|  Lateral incisor |  First molar |
|  Cuspid (canine) |  Second molar |
|  First premolar (bicuspid) |  Third molar |

ADAM

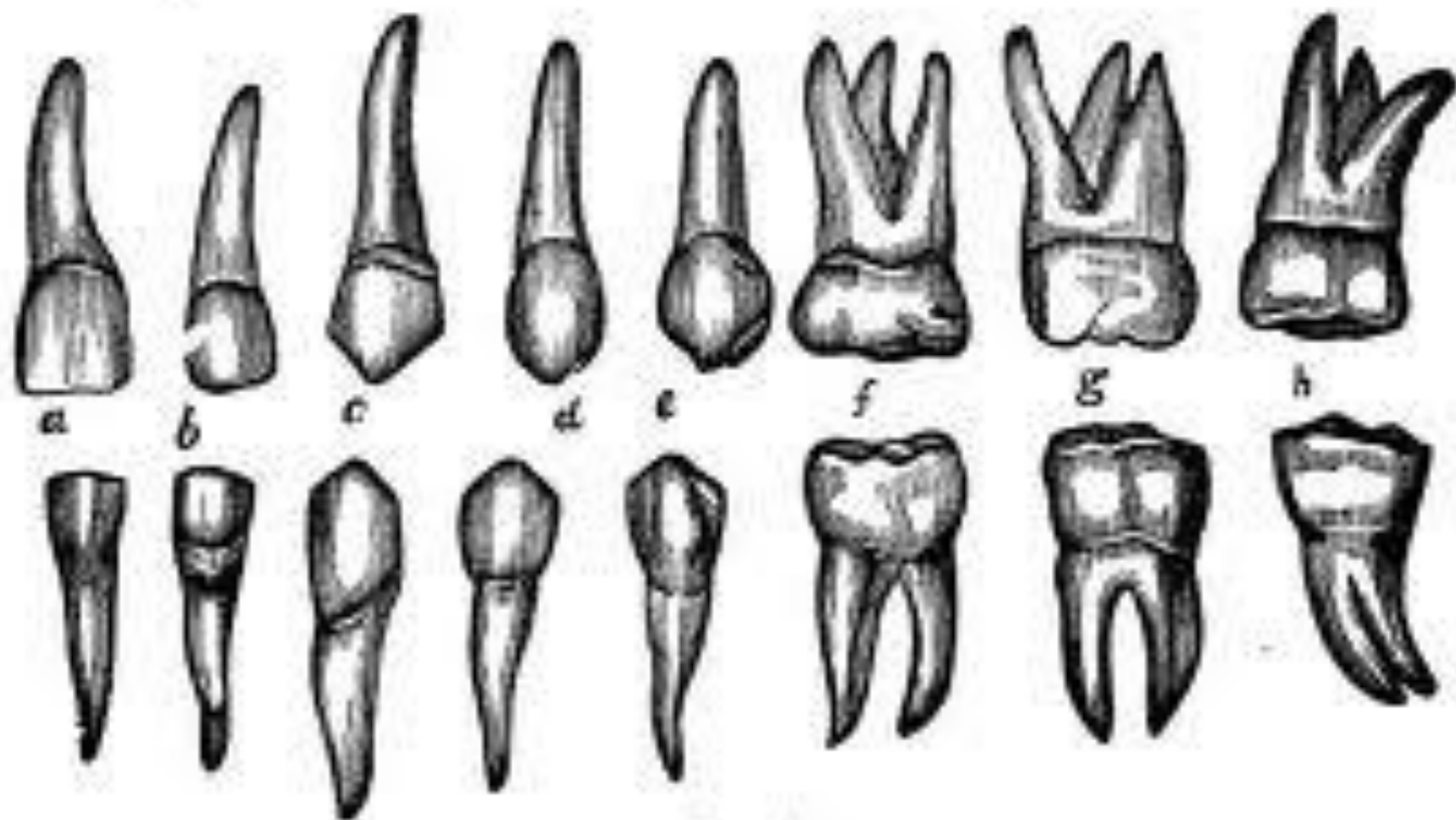
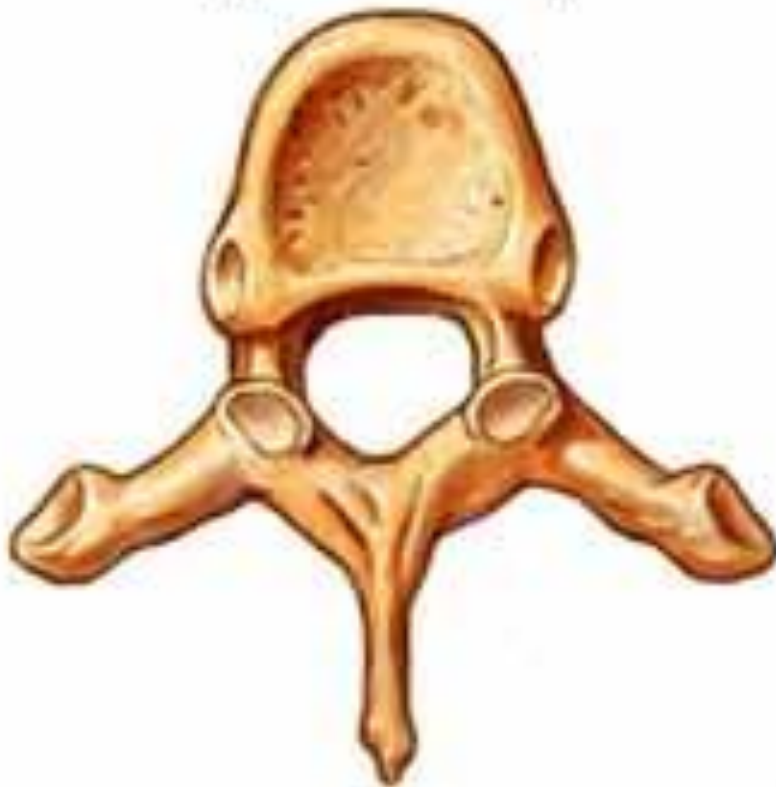

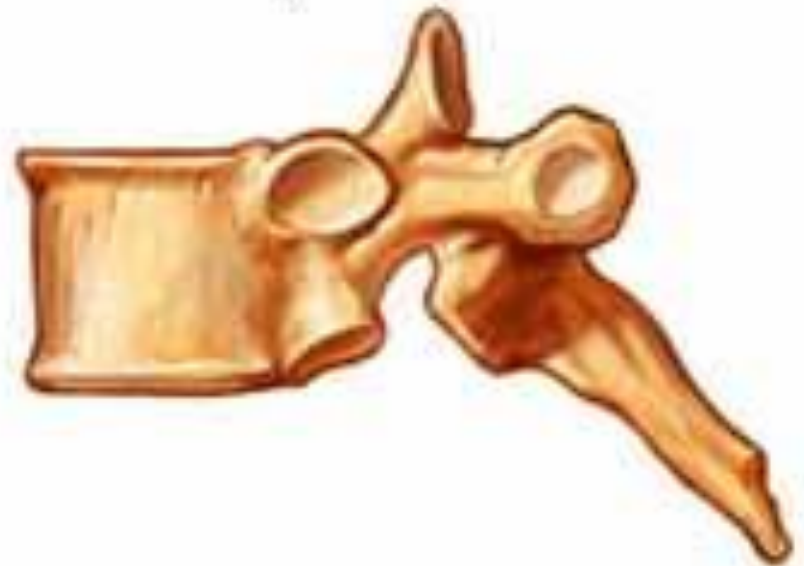Fig. 27.

Thoracic Vertebrae

Axial (Overhead) View



Lateral (Side) View



Crown

Root

Enamel

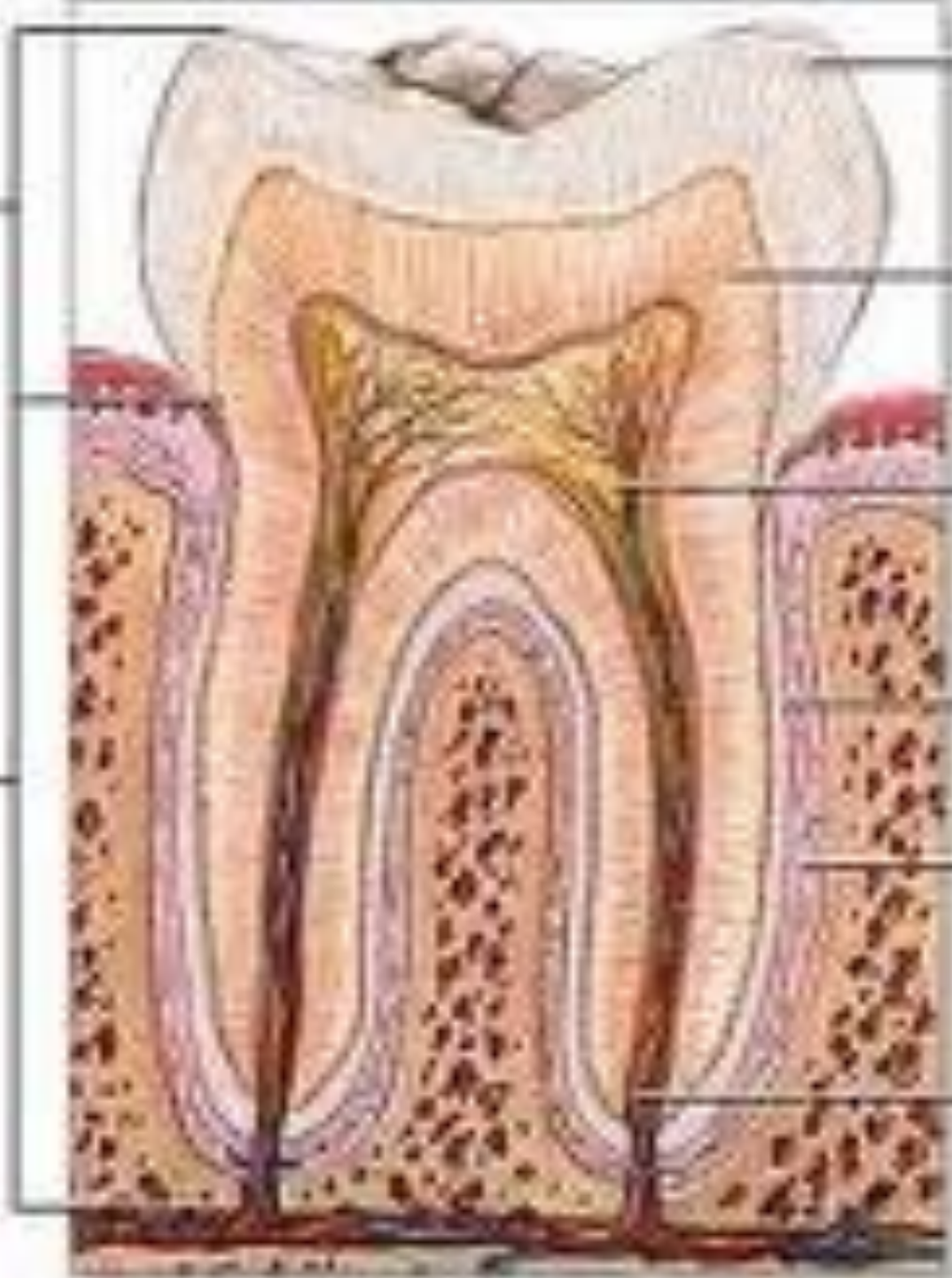
Dentin

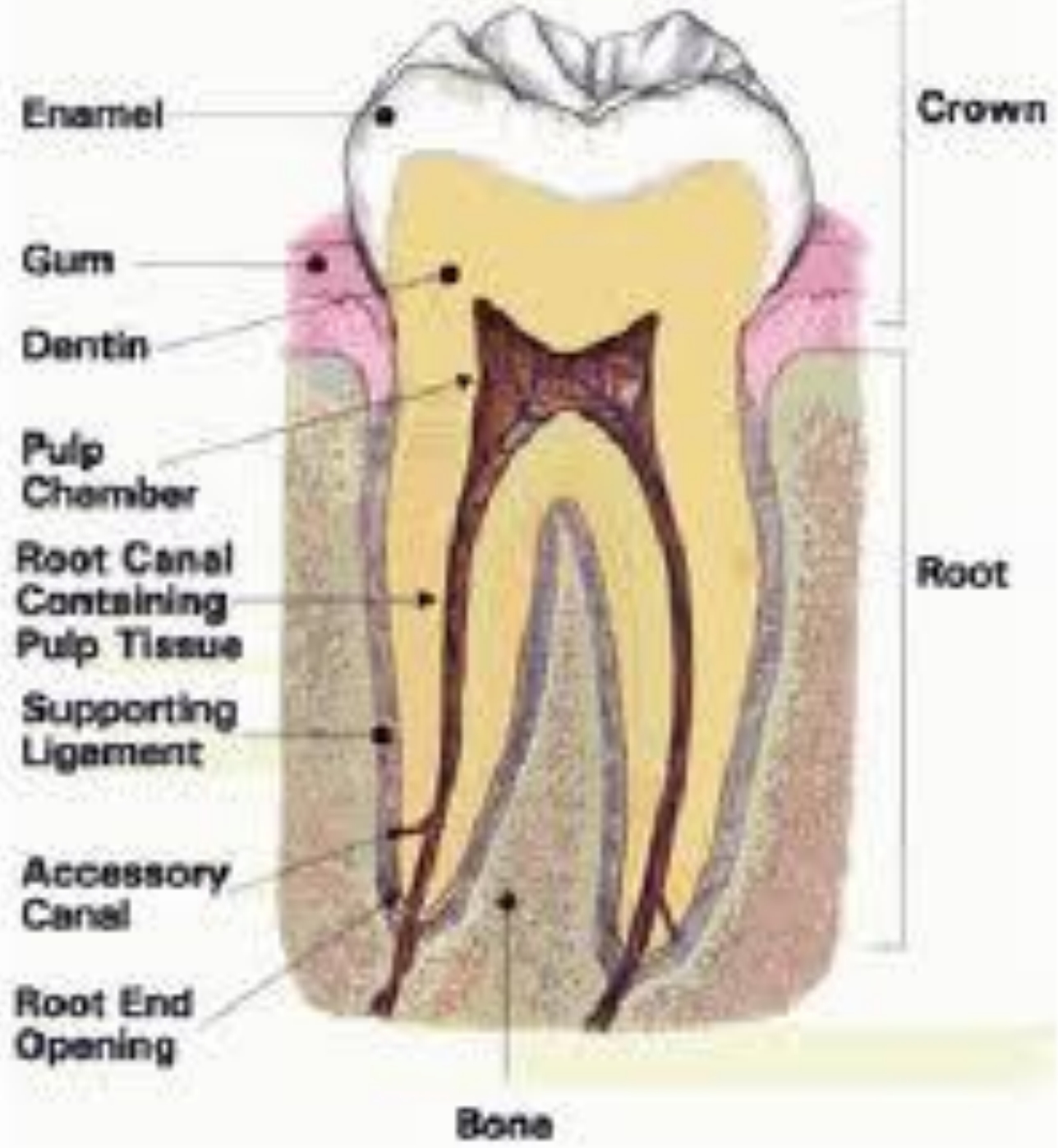
Pulp

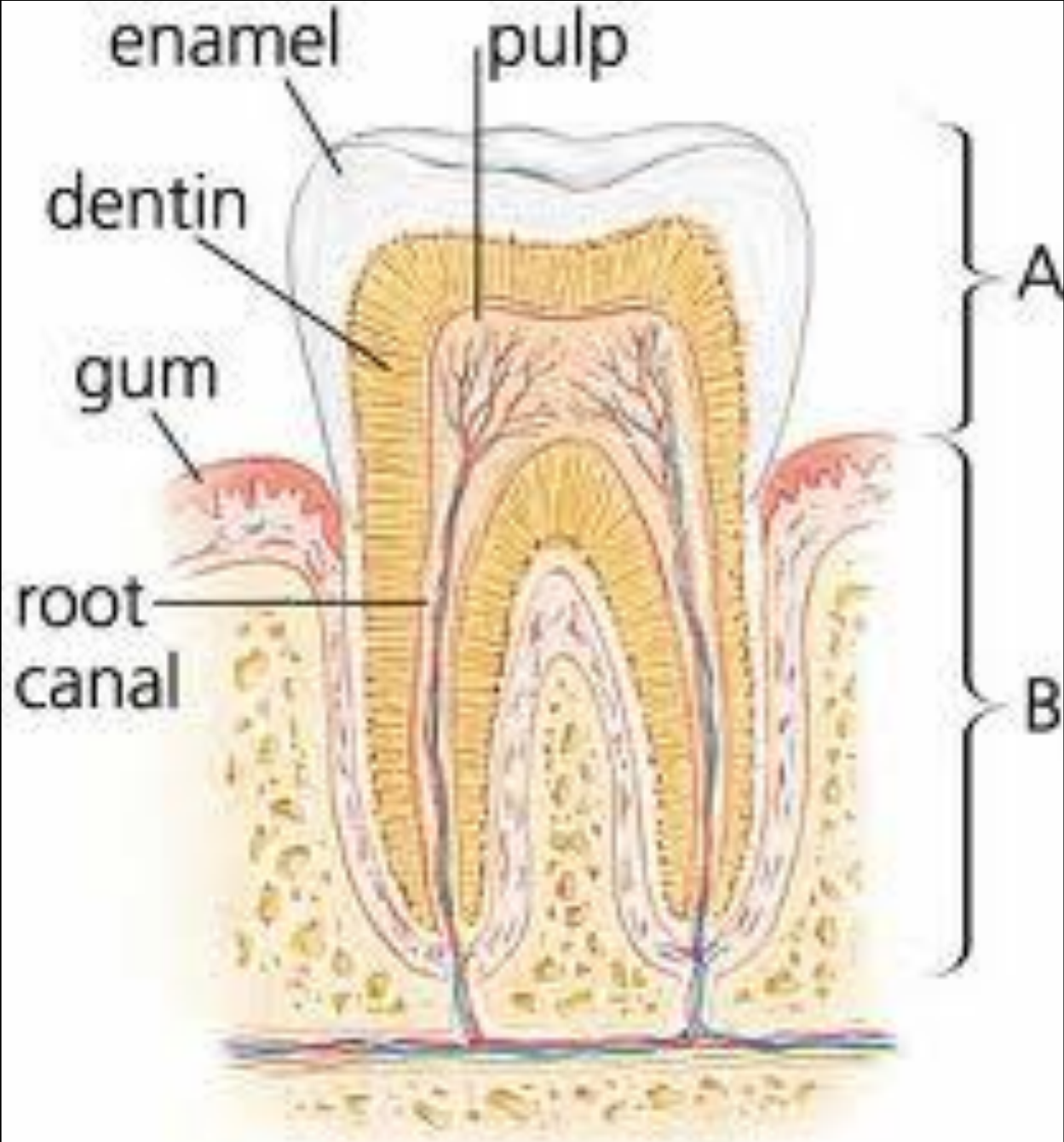Cementum

Periodontal membrane

Nerve and blood supply







enamel

pulp

dentin

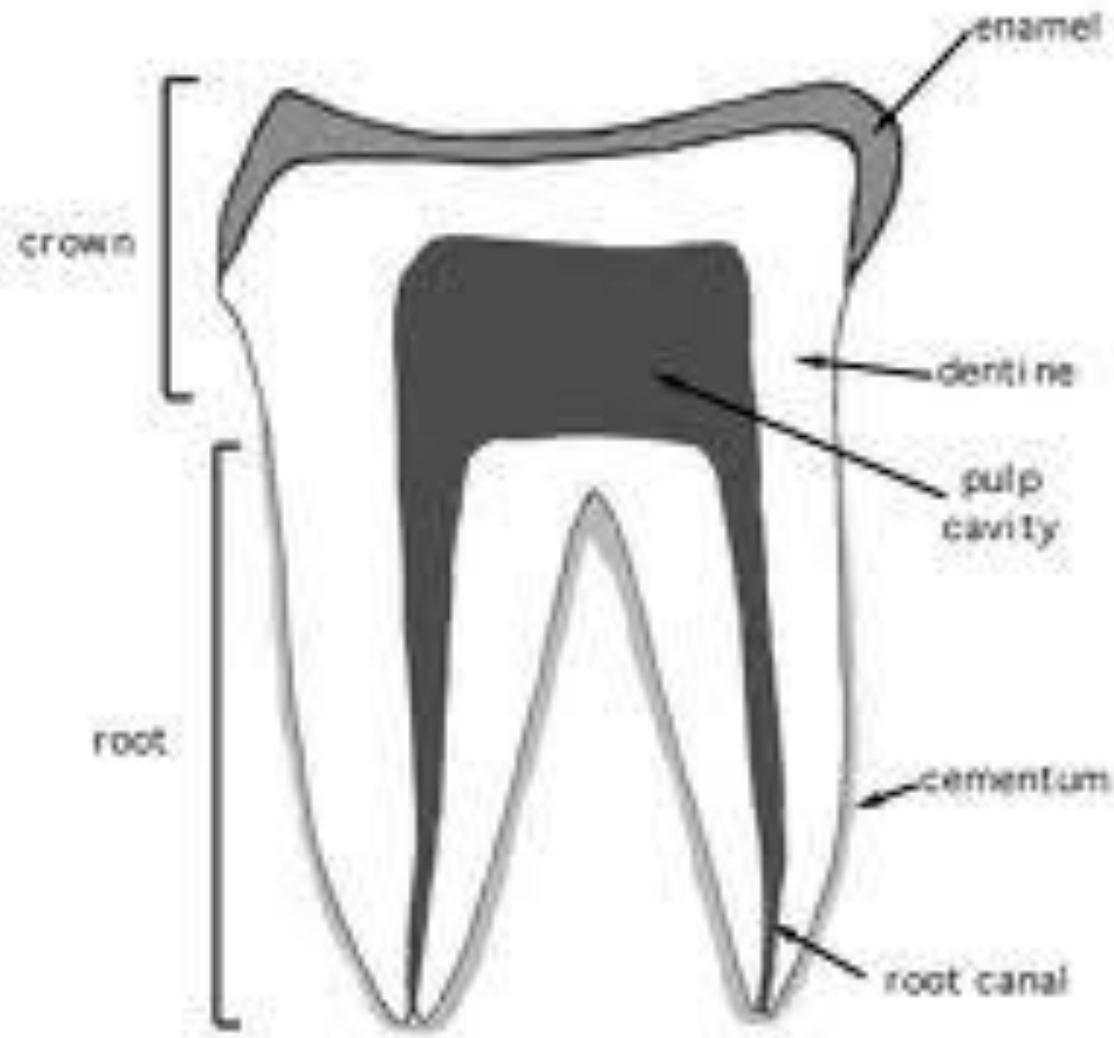
gum

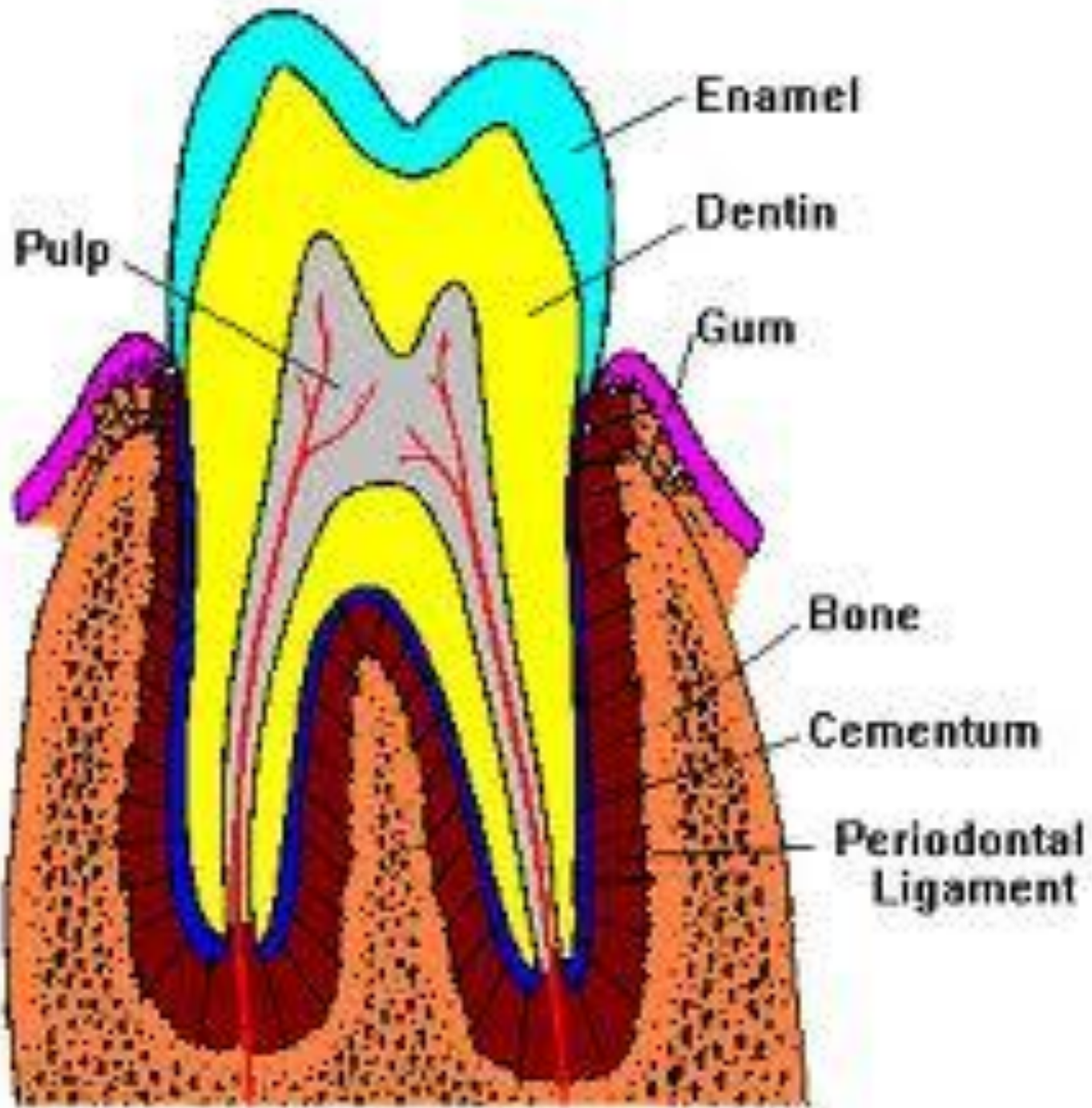
root canal

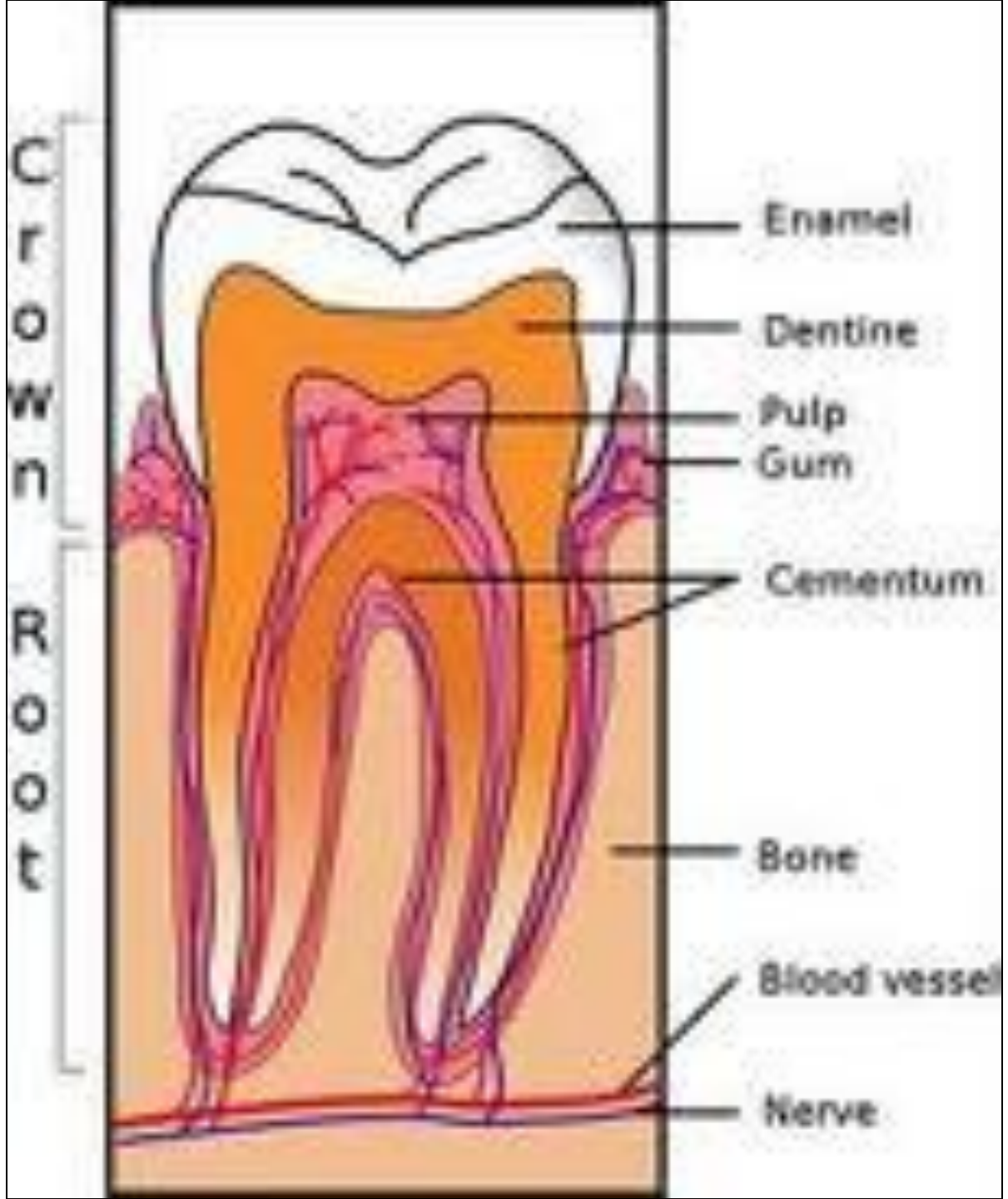
A

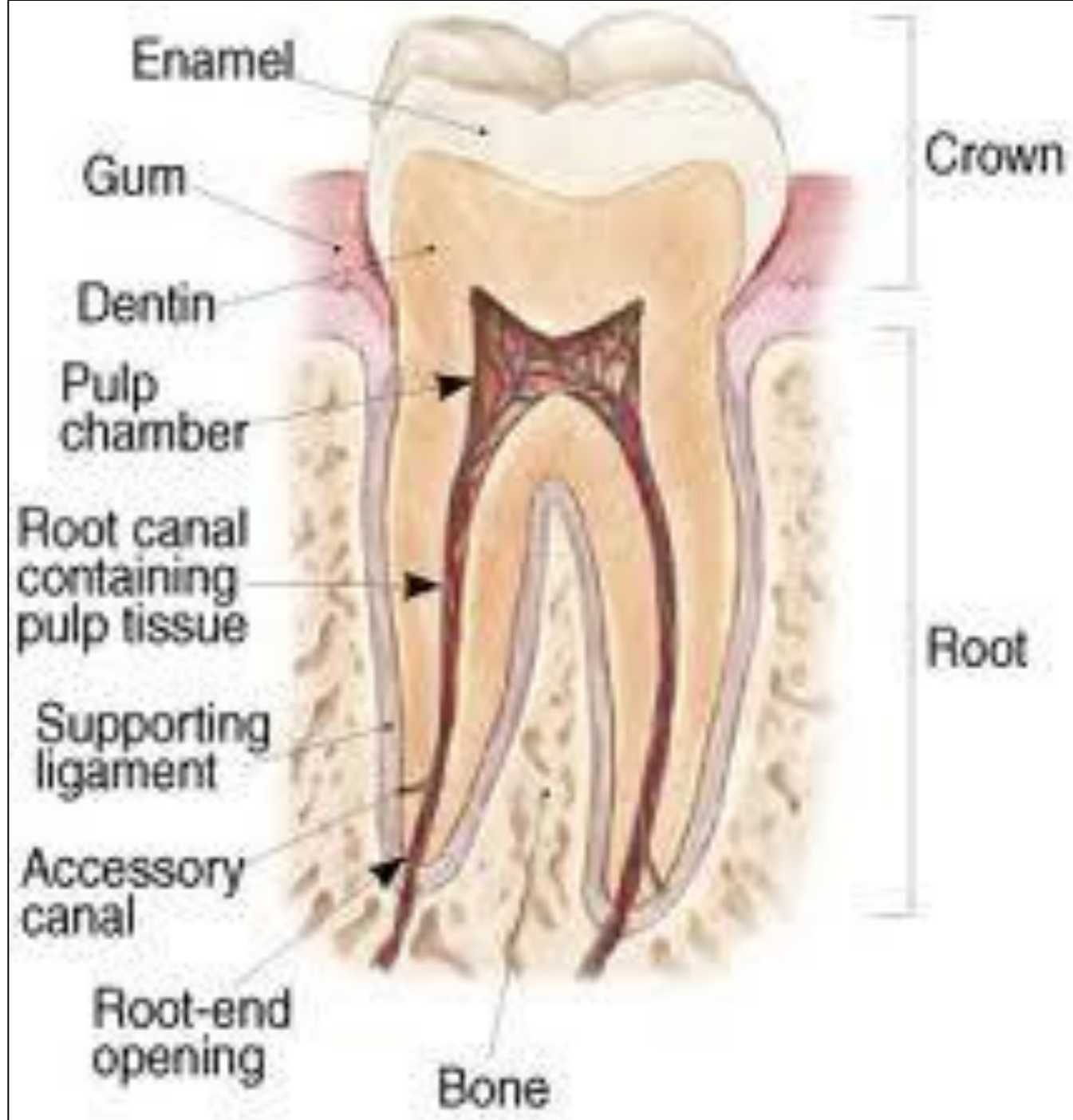
B

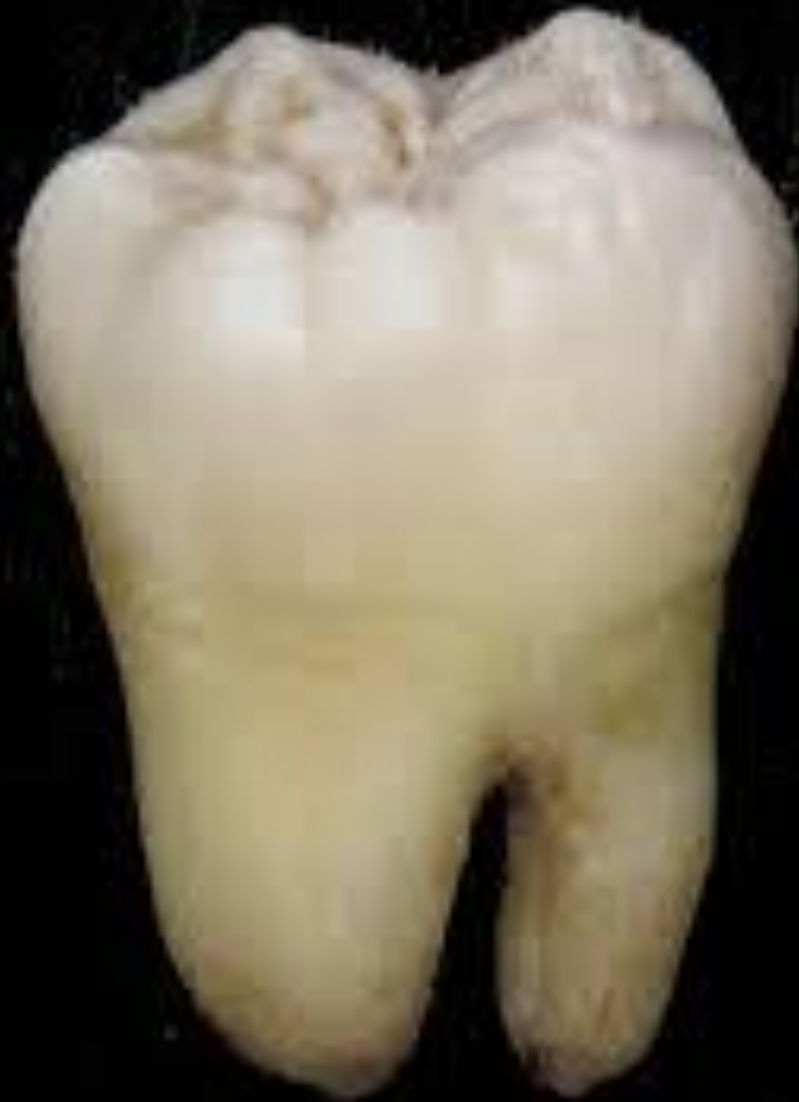Cross section of a tooth

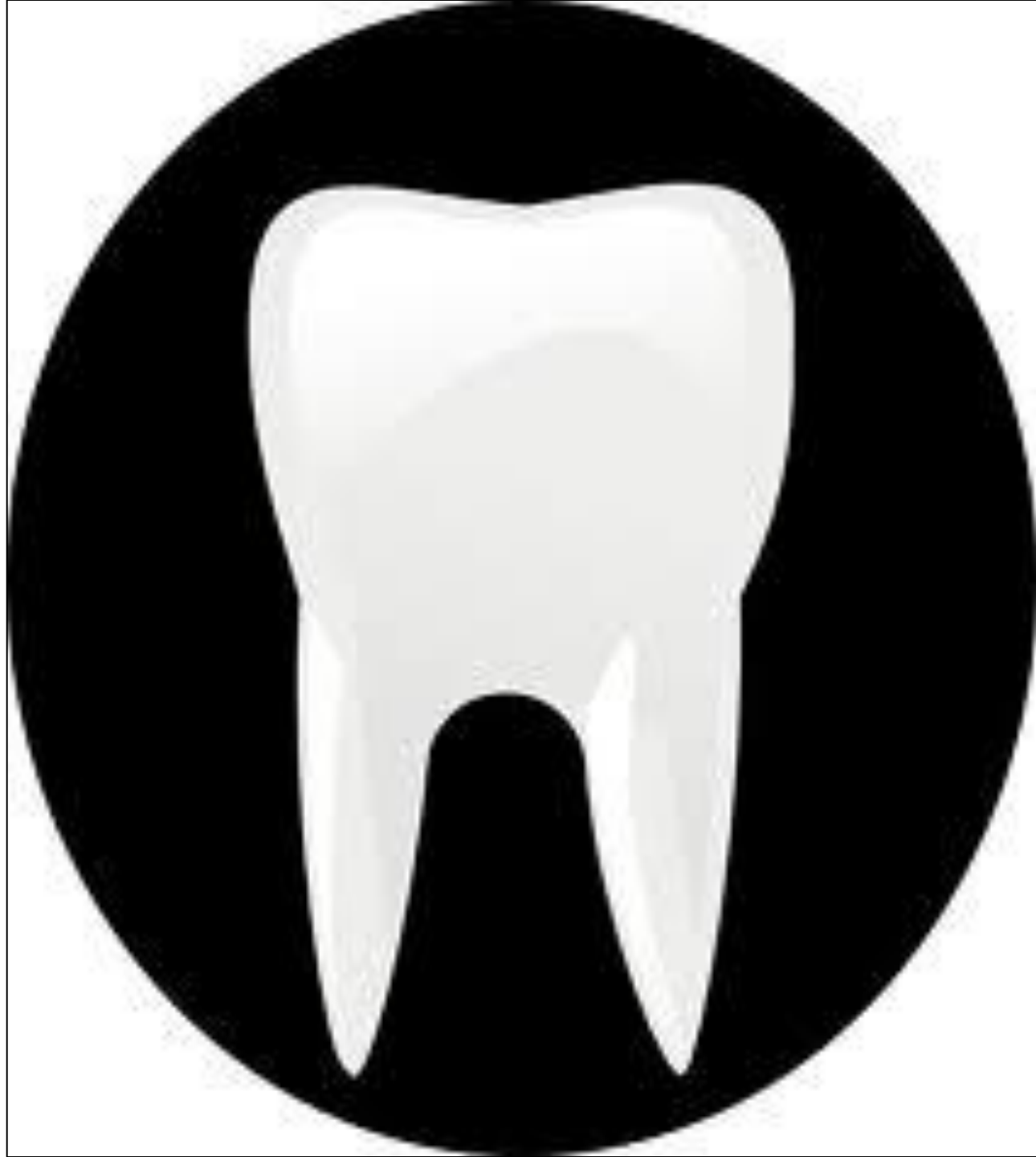


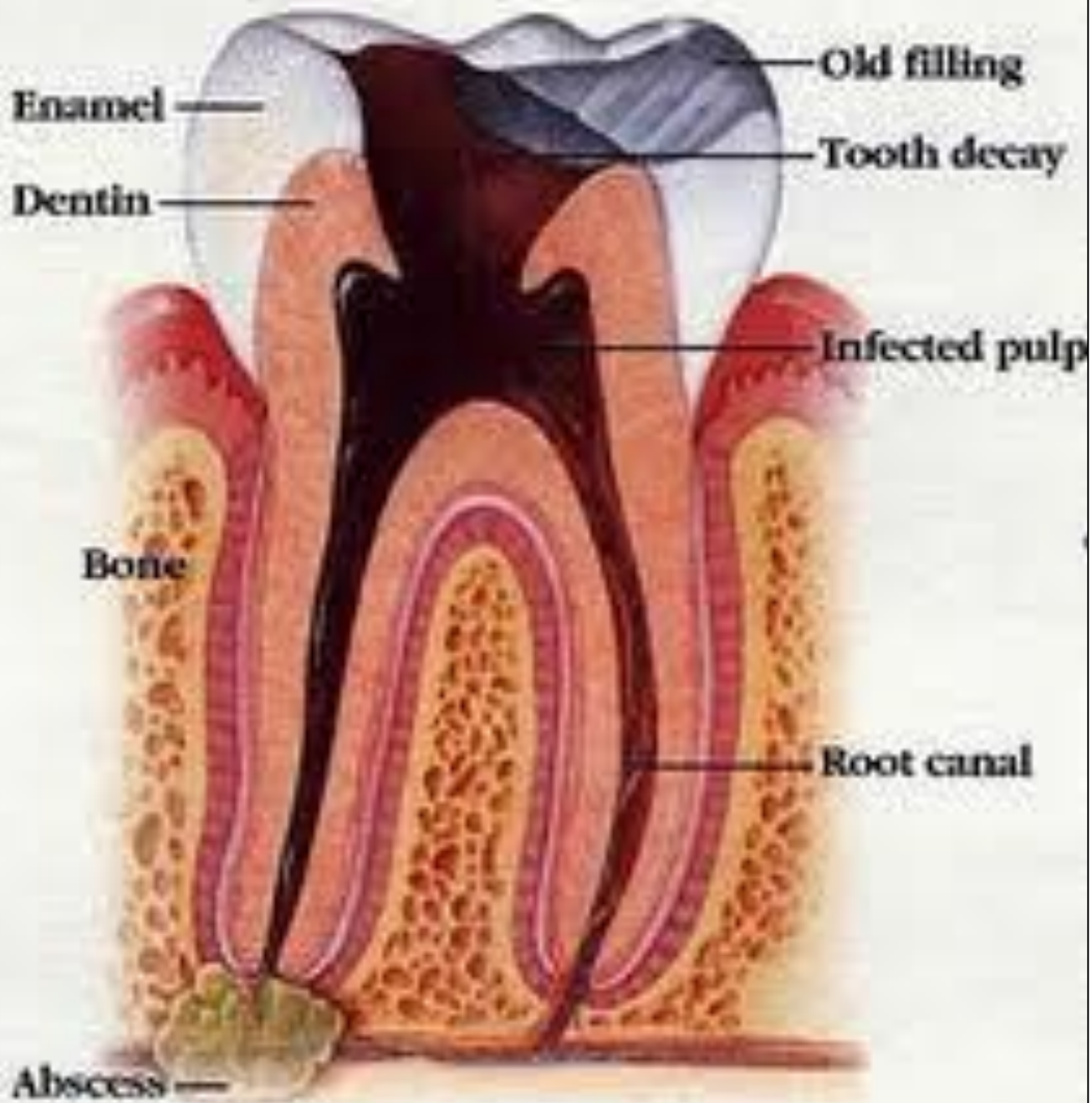


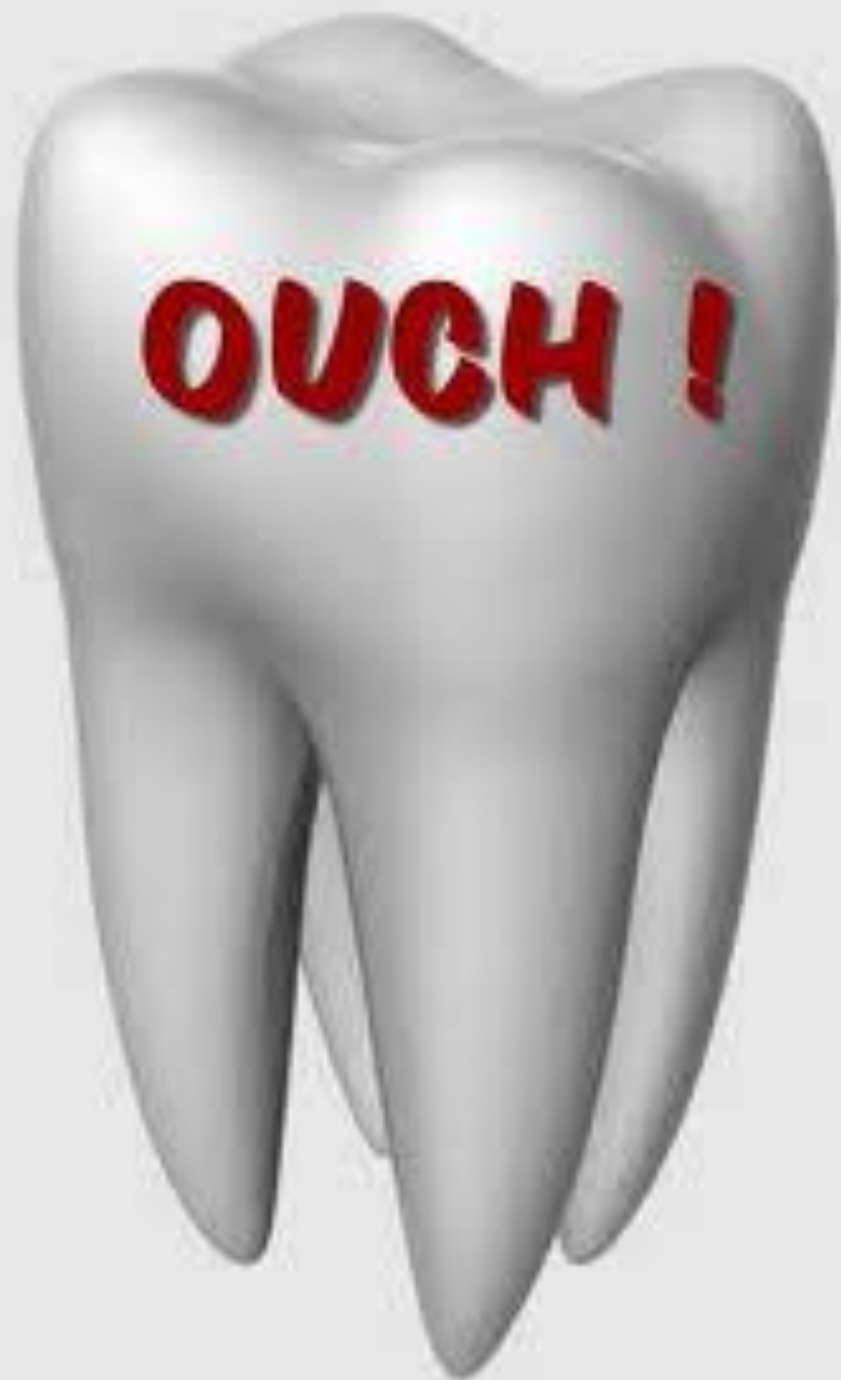









Infected Pulp Tissue

Inflamed Pulp Tissue

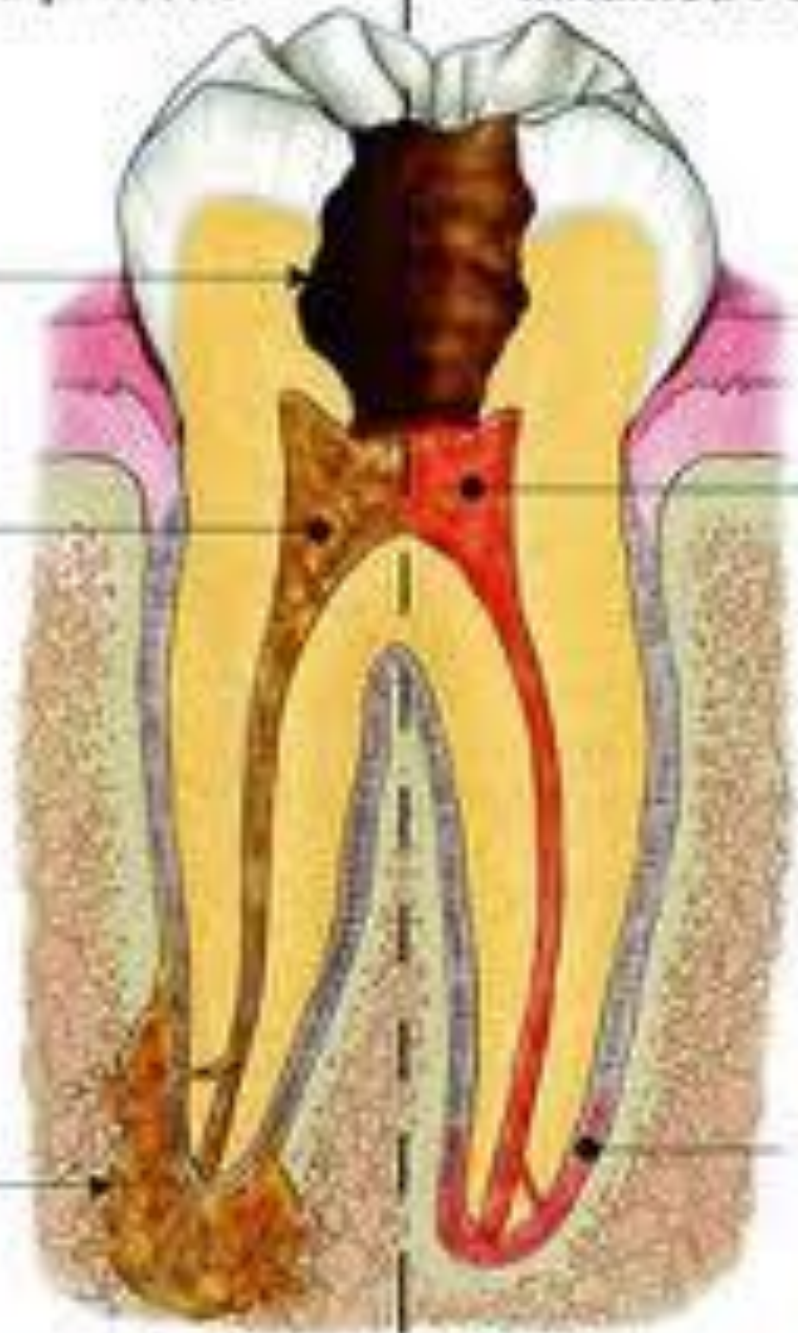
Decay

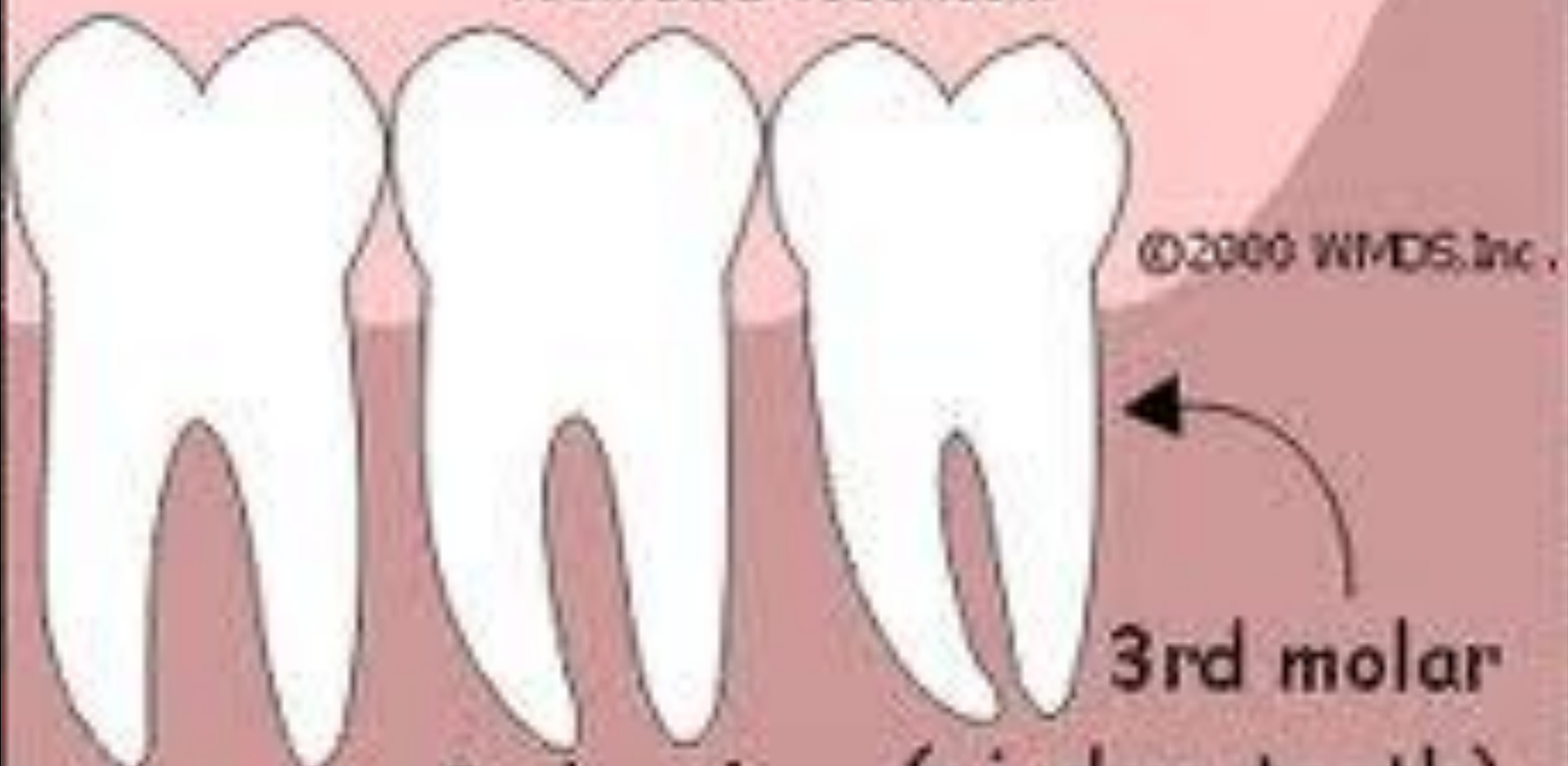Infected Pulp

Inflamed Pulp

Abscess

Inflamed Ligament






©2000 WMD5, Inc.

1st molar

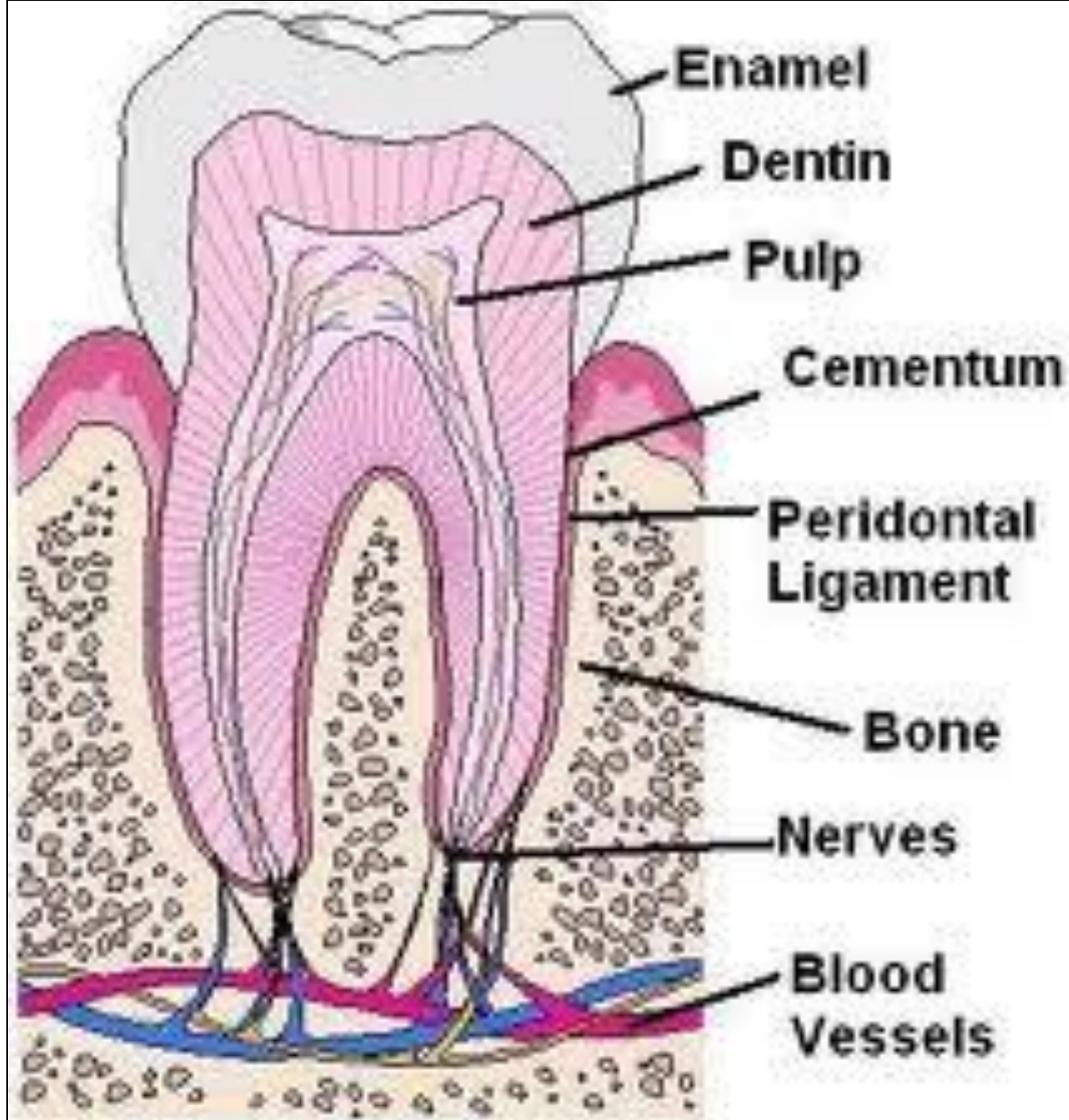
2nd molar

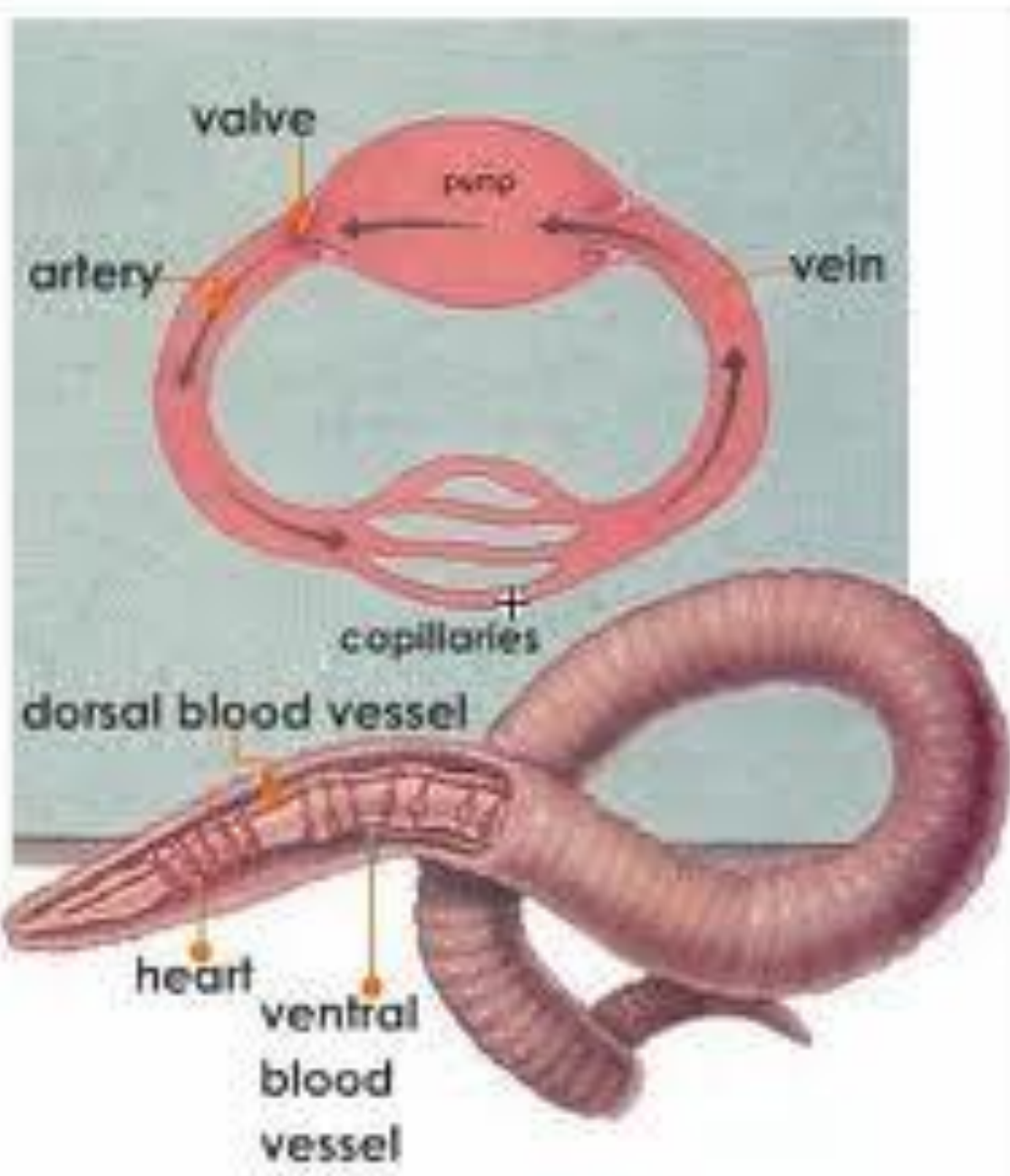
(wisdom tooth)

3rd molar

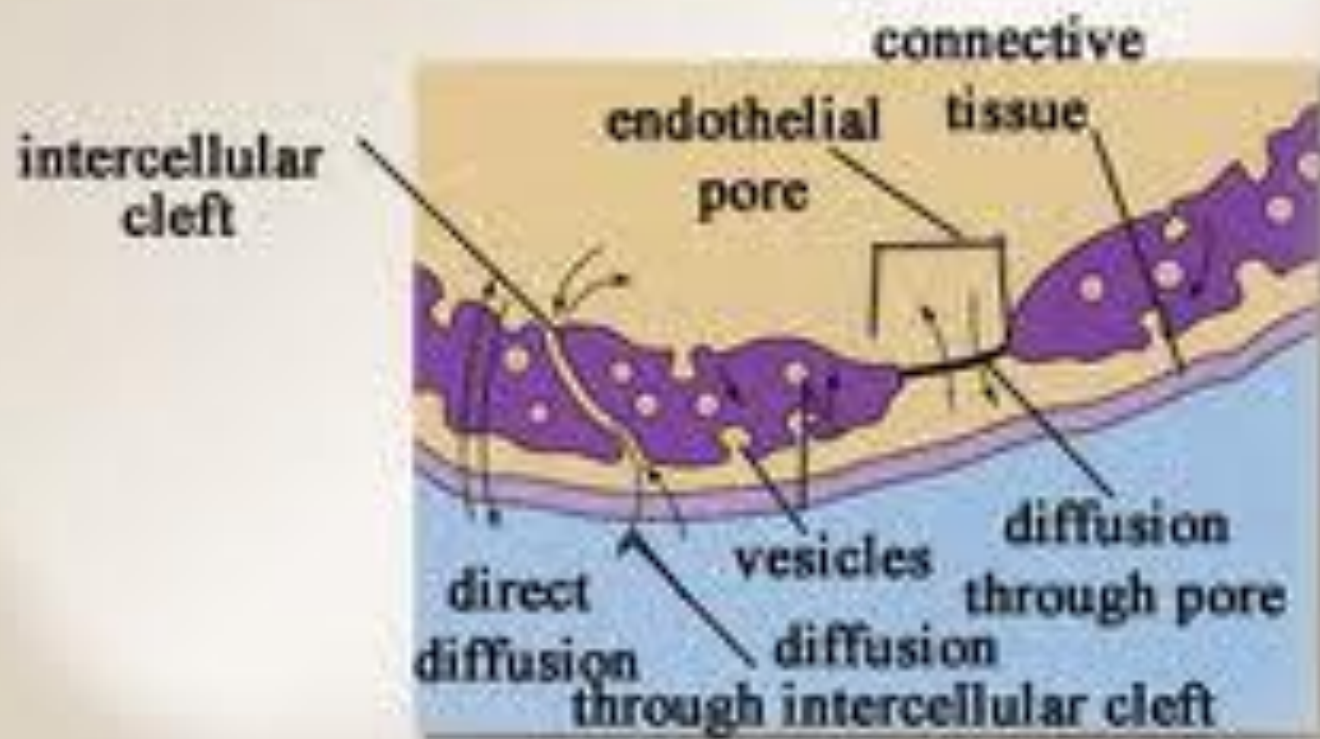
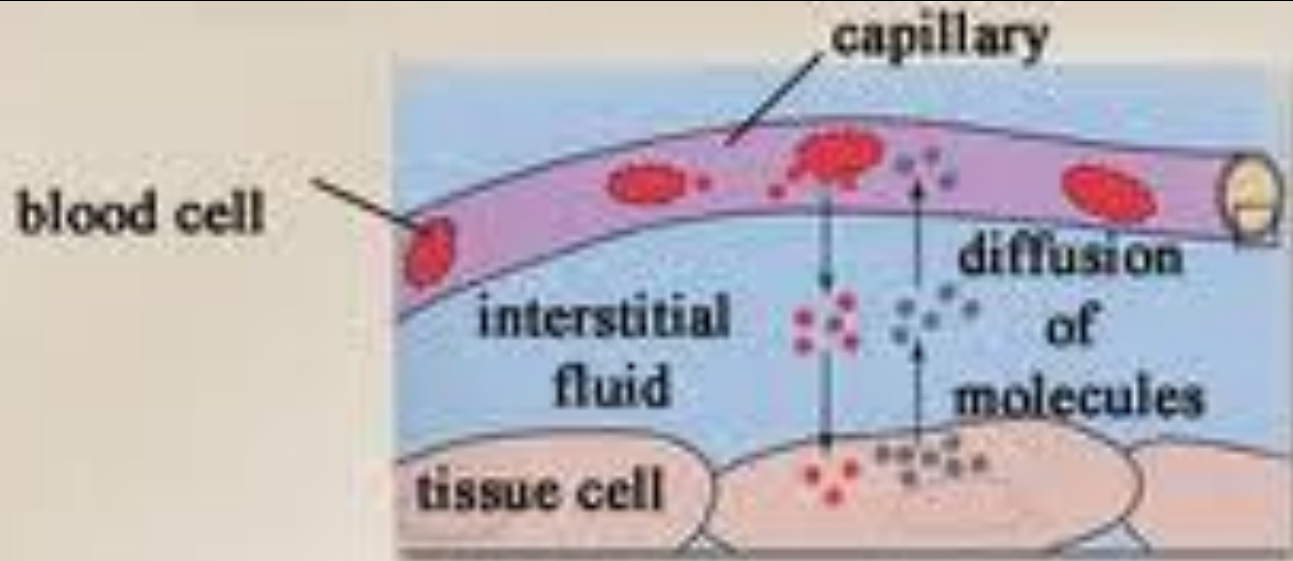


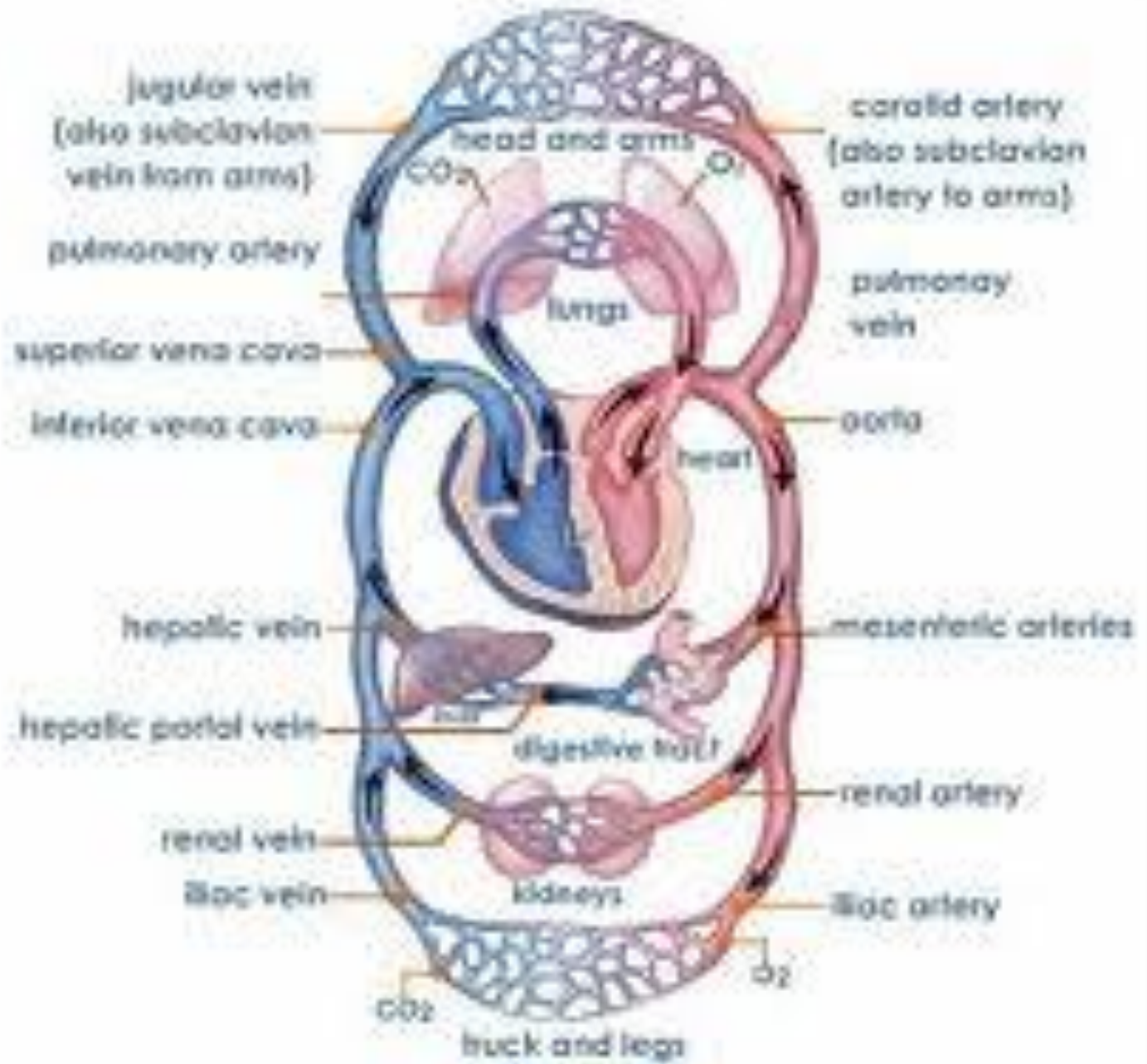
Front of mouth.





Closed Circulatory System





Jugular vein
(also subclavian
vein from arms)

pulmonary artery

superior vena cava

inferior vena cava

hepatic vein

hepatic portal vein

renal vein

iliac vein

head and arms

lungs

heart

digestive tract

kidneys

trunk and legs

carotid artery
(also subclavian
artery to arms)

pulmonary
vein

aorta

mesenteric arteries

renal artery

iliac artery

CO₂

O₂

CO₂

O₂

Path of Blood

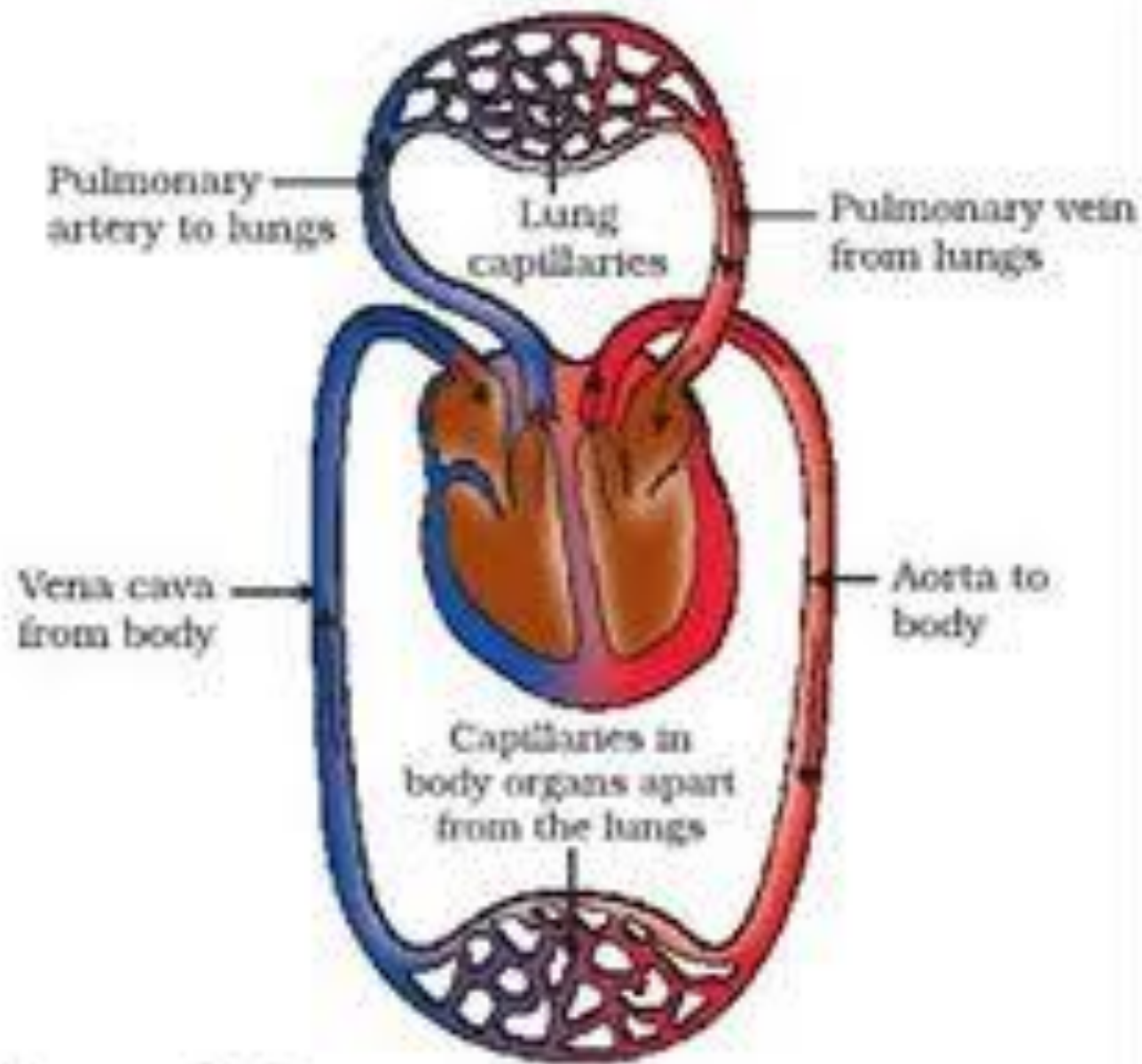
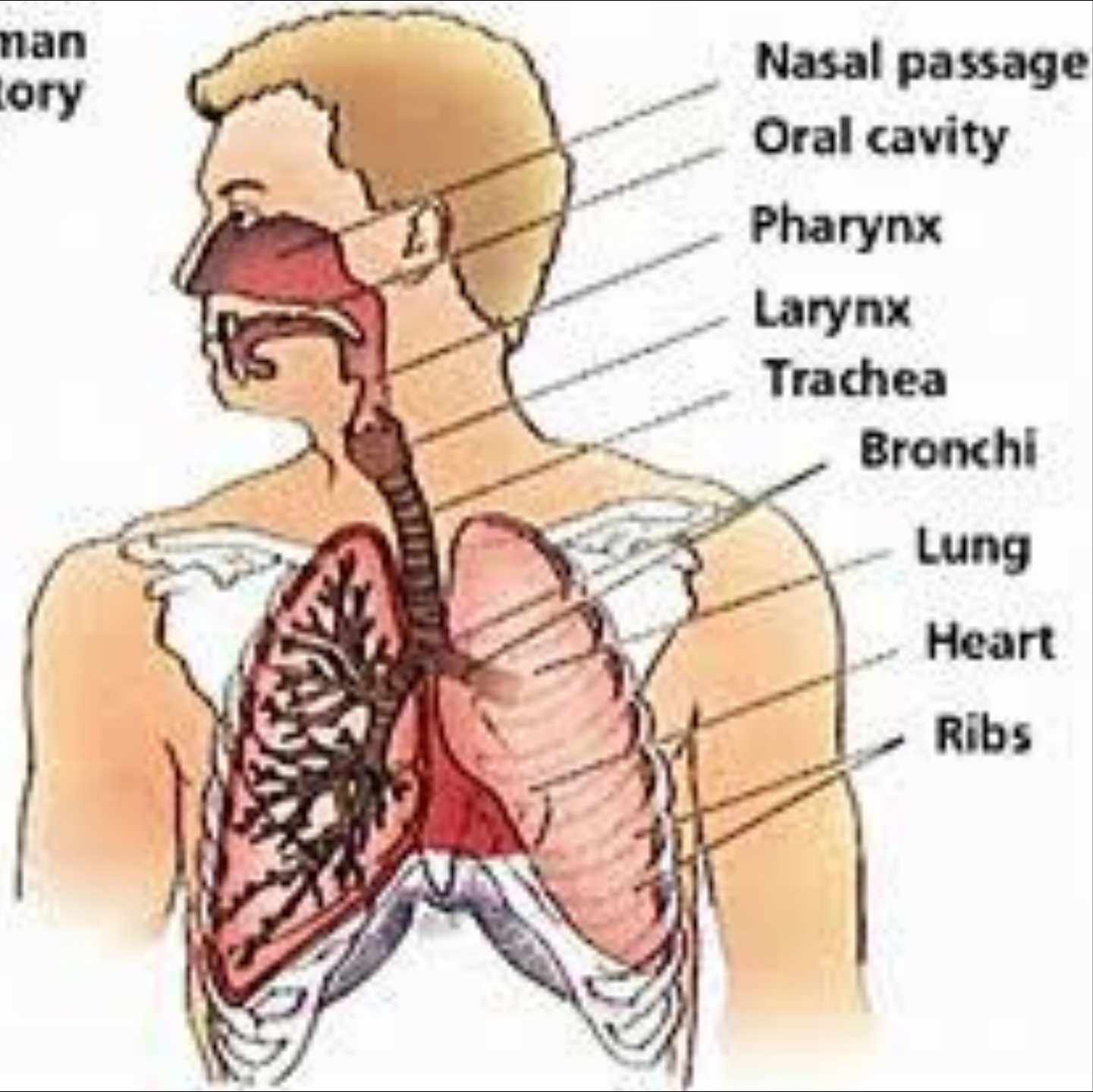


Figure 6.11

Schematic representation of transport and exchange of oxygen and carbon dioxide

The Human Respiratory System

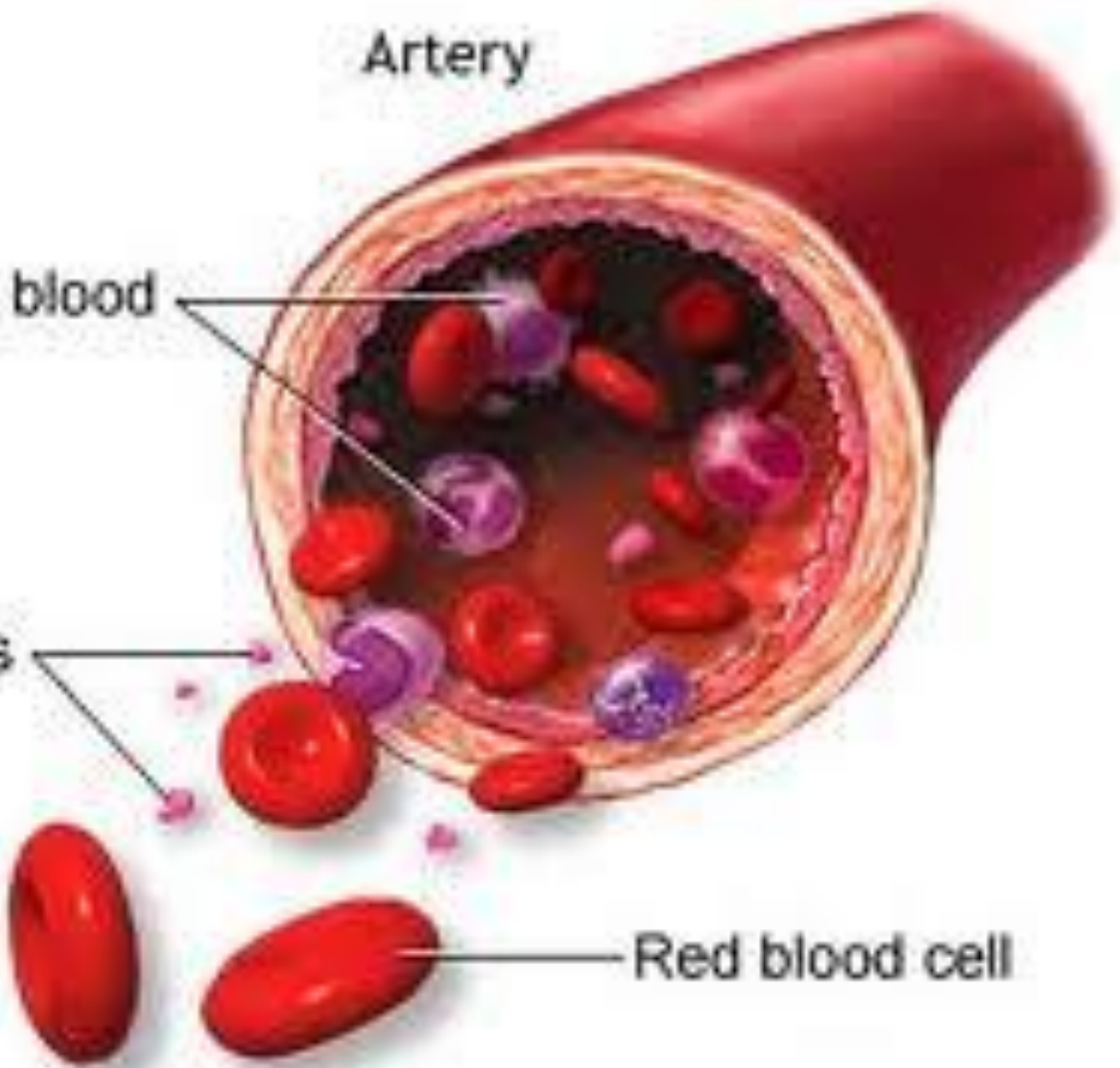



Artery

White blood cells

Platelets

Red blood cell





plasma

WBCs & platelets

RBCs

