



# Carotid Body Tumors

Jordan B. Strom, HMSIV

Gillian Lieberman, MD

May 2010



# Outline

- Patient Presentation
- Background of Carotid Body Tumors (CBT)
  - Epidemiology
  - Pathophysiology
  - Symptoms and Signs
- Imaging Modalities
  - Ultrasound
  - MRI/MRA
  - Angiography
- Return to Our Patient
- Treatment of CBT
- Outcome
- Conclusions
- Works Cited



# Our Patient: History

- A.B. is a 29 yo F
- HPI: h/o painless L lateral neck mass since 17 yo. “Lymph node” per PCP. MVC with husband in early 12/09. Concern for whiplash injury lead to MRI. No prior MRI, no sx referable to mass.
- ROS: Denies pain, dysphagia, odynophagia, hoarseness
- PMH: Asthma, Hashimoto’s thyroiditis, GERD, ASD (spontaneously closed during pregnancy)
- PSH: C-section 4/09, lithotripsy 4/08, nasal septoplasty
- Meds: levothyroxine, ativan prn
- Allergies: PCN
- SH: Works as R.N., married. (-)EtOH, (-) smoking, (-) IVDA
- FH: cancer, diabetes, hearing loss, migraines, bleeding diathesis, heart disease



# Our Patient: Physical Exam

- Physical Exam
  - VS: BP 118/74, HR 68, BMI 23.7
  - General: Well appearing in NAD
  - HEENT: pupils anicteric, TMs gray and mobile, external auditory canals clear, firm mass in L lateral neck, measuring 2.5 cm by palpation without bruit, freely moves horizontally, vertical movement restricted, no palpable LAD, thyroid wnl
  - Cor: nL S1 and S2, RRR no MRG
  - Pulm: CTAB
  - Abd: soft, NT/ND, no HSM
  - Ext: 2+ pulses, no c/c/e



# Ddx of Painless lateral neck mass

- Congenital
  - Branchial Cleft Cyst
- Inflammatory
  - Reactive lymphadenopathy
- Neoplastic
  - Lymphoma
  - Salivary Gland Tumors
  - Neurogenic tumors
  - **Paraganglioma**
- Vascular
  - Aneurysms of the carotid artery
  - Hematoma
  - Pseudoaneurysm

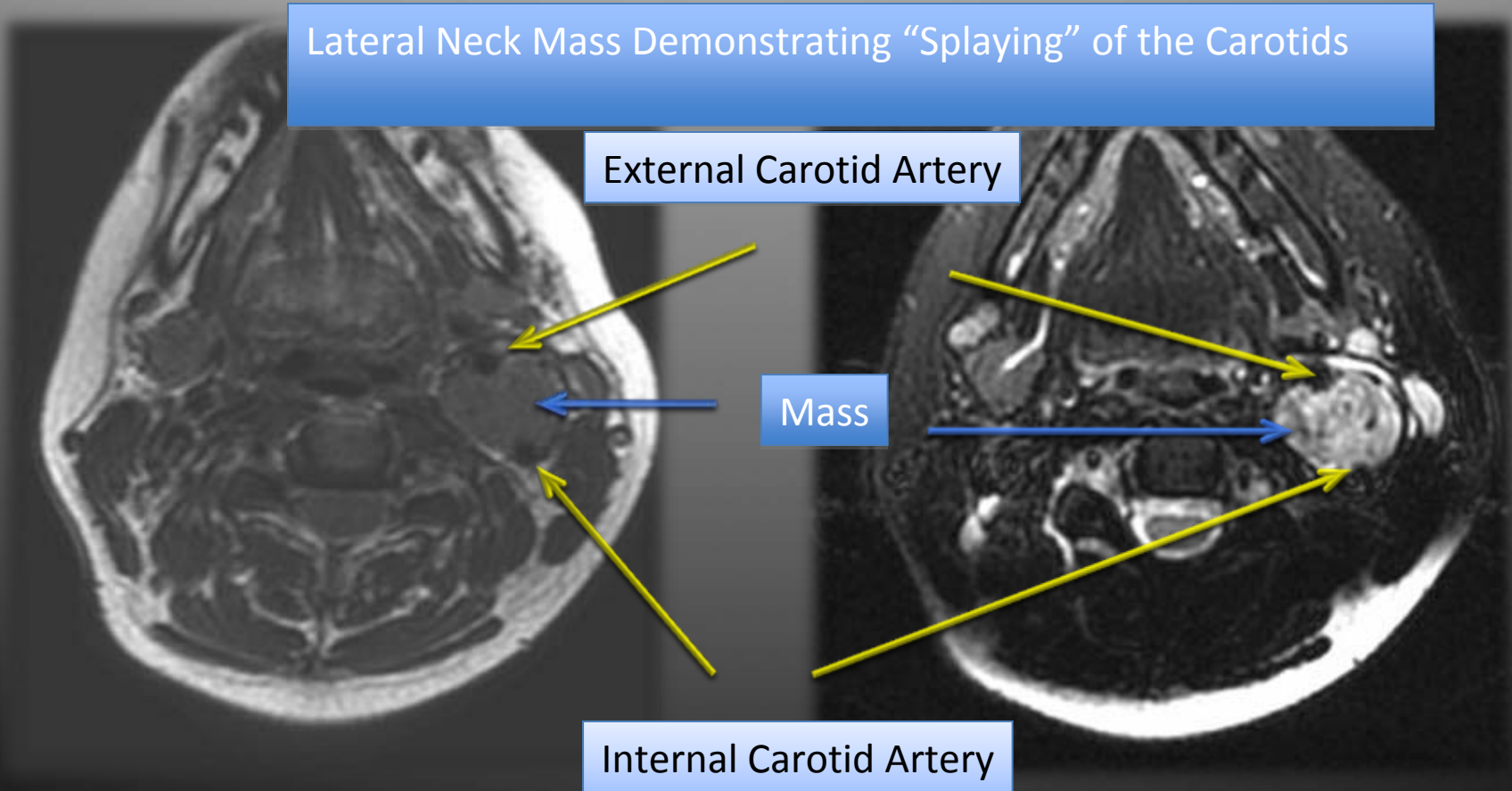


# Our Patient: MRI findings

Axial T1 weighted image with fat-saturation

Axial T2 weighted image with fat-saturation

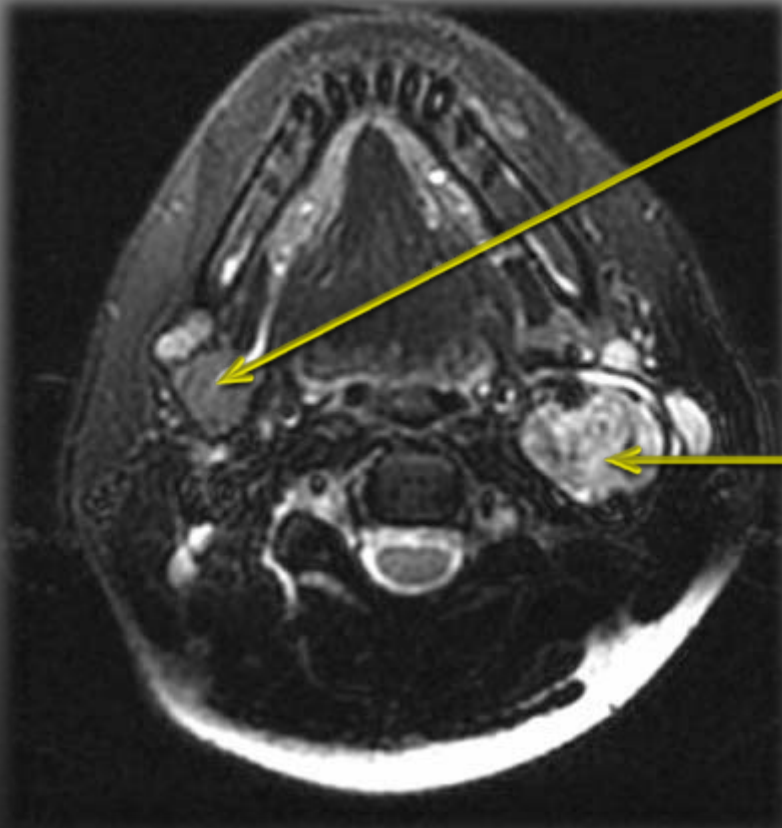
Lateral Neck Mass Demonstrating “Splaying” of the Carotids





# Our Patient: “Salt and Pepper” Appearance

Axial T2 weighted image with fat-saturation



Incidental note of mass on R side  
Could this represent another tumor?

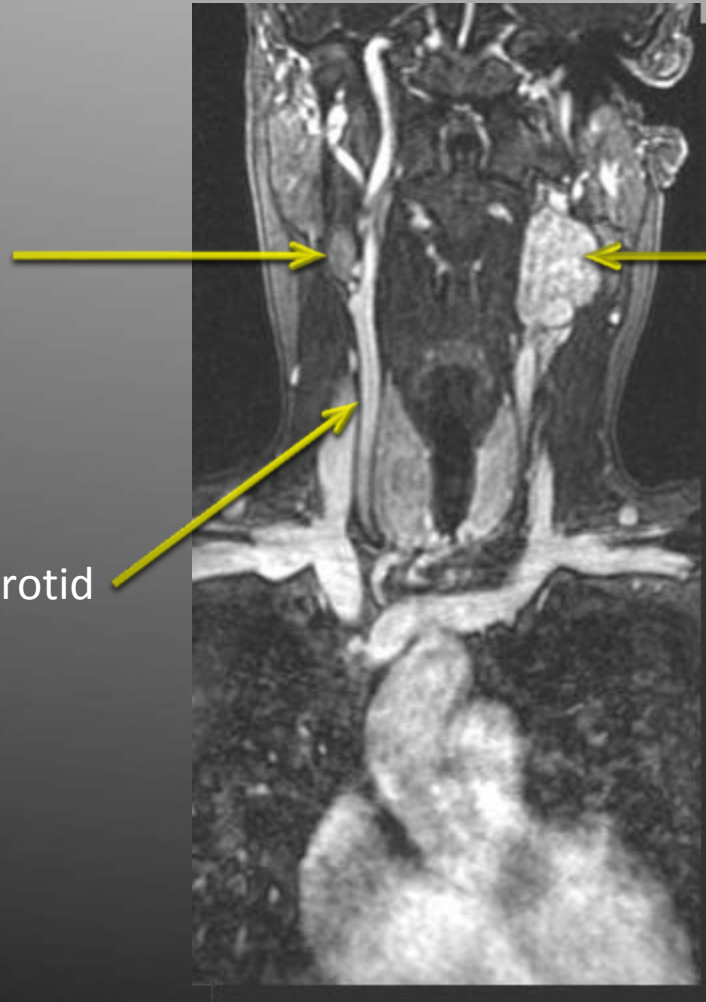- “Salt and Pepper” Appearance on T2 i.e., areas of signal void (dark) Surrounded by homogenous signal intensity (bright), representing multiple small vessels in tumor.
- Found in paragangliomas > 1.5 cm In size

Image courtesy of Dr. Jay Pahade



# Our Patient: MRA findings

Mass on R side does not enhance suggesting that it is a lymph node, not a synchronous primary tumor or metastasis



Coronal T2 weighted MRI post gadolinium demonstrates enhancement of the mass showing that it is highly vascular.

Common Carotid

The mass sits at the bifurcation of the carotids in between external and internal carotid.

Coronal T2 weighted C+ MRA with fat-saturation



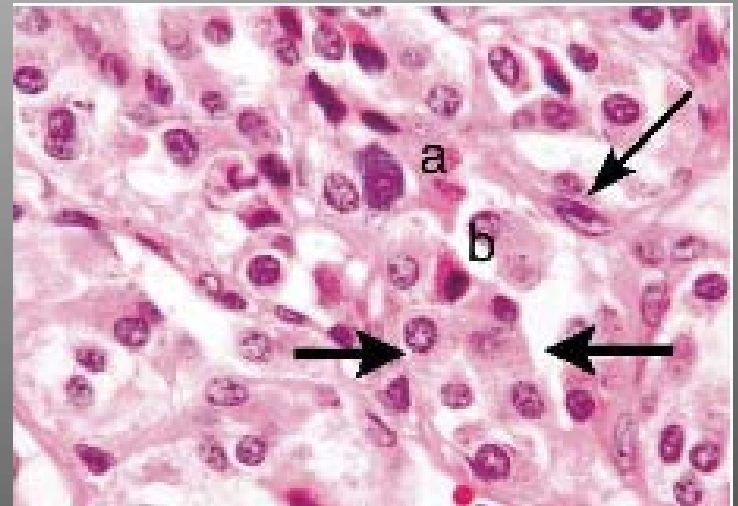


# Diagnosis: Carotid Body Tumor



# Background: What is a CBT?

- CBT is a type of paraganglioma (PG)
- PGs are rare tumors derived from neural crest cells
- PGs can occur anywhere neural crest cells migrate from the skull base to pelvis
- PGs of the head and neck are rare, representing 0.6% of all tumors
- CBT is the most common type of PG of the head and neck.
- Other types include (classified by origin or location): Jugular paraganglioma (at jugular bulb), tympanic paraganglioma (arising from the tympanic plexus), and vagal paragangliomas (can arise along the entire course of the vagal nerve)



Pathology of CBT demonstrating chief cells (between big arrows) surrounded by sustentacular cells (thin arrow) in a collagen stroma

Image from Knight TT, et al. Current concepts for the surgical management of carotid body tumor. American Journal of Surgery. 2006; 191: 104-110.



# Background: Epidemiology and Pathophysiology

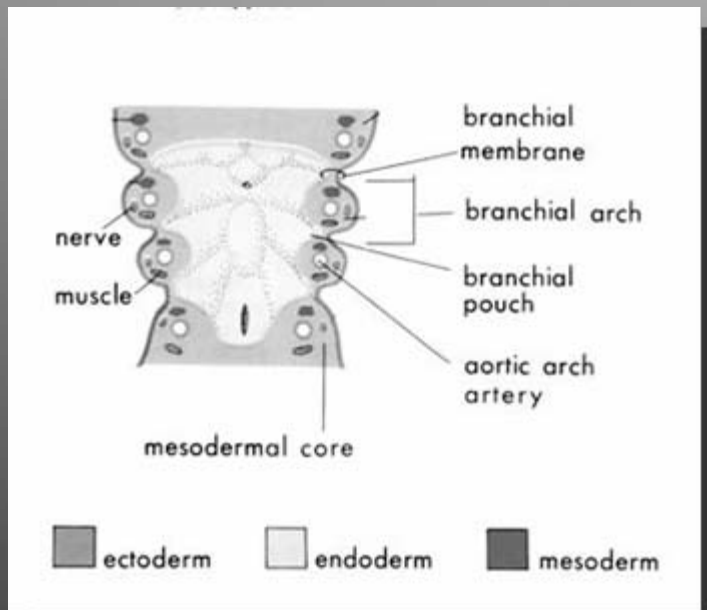
- PGs are 10x more common at high altitudes in the same population, reflecting hypoxia induced VEGF expression, and hyperplasia of chemoreceptor tissue
- 8:1 F:M at altitudes, 2:1 F:M at sea level, as lower Hgb in females
- 90% spontaneous – usually appears in 3<sup>rd</sup> and 4<sup>th</sup> decades
- < 10% malignant (usually vagal paragangliomas)
- 10% of PGs are hereditary from defects in the PGL1 gene on chromosome 11q22.3-q23, which encodes a key regulator in oxygen sensing.
- 80% of hereditary cases are multicentric. Presents in 2<sup>nd</sup> decade.
- Associated with VHL, NF1, and MENII



Image from Life in General: March 2007. Blogspot.  
[http://k53.pbase.com/v3/91/221591/1/47233114.MtEverestGokyoRi\\_02.jpg](http://k53.pbase.com/v3/91/221591/1/47233114.MtEverestGokyoRi_02.jpg). May 10. 2010.



# Background: Branchial Arch Origin



- Tumor of chromaffin cells, derived from neural crest cells, which cluster in “paraganglia”
- Head and neck PGs are linked to the third branchial arch and the paraganglia of the glossopharyngeal nerve (IX)
- CNIX gives off a carotid sinus branch, explaining the location of CBTs.
- The hypoglossal artery is the artery of third branchial arch. Later becomes ascending pharyngeal artery.
- The ascending pharyngeal artery thus plays a large role in the vascular supply to many CBTs

Image from Zill S. Marshall University's Joan C Edwards School of Medicine.  
[http://musom.marshall.edu/anatomy/grosshom/z\\_devbranc\\_files/image002.jpg](http://musom.marshall.edu/anatomy/grosshom/z_devbranc_files/image002.jpg). May 10, 2010.



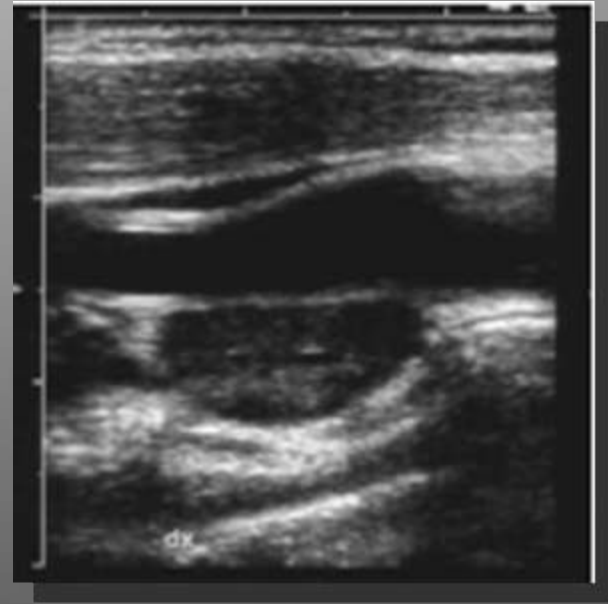
# Background: Symptoms and Signs

- Painless, slowly enlarging lateral neck mass
- More freely moveable horizontally than vertically owing to attachment to carotids (Fontaine's sign)
- May be associated with carotid bruit or pulsatility
- May cause dysphagia or odynophagia due to compression
- PGs in other locations can cause pulsatile tinnitus, conductive hearing loss, and Horner's syndrome from SNS fiber disruption.



# Imaging Modalities: Diagnosis

- B-mode ultrasonography and color doppler
  - First test for painless lateral neck mass demonstrates hypoechoic mass that appears hypervascular on color doppler with flow directed upwards
  - Often hard to differentiate from other solid masses
- MRI
  - Very good soft tissue resolution
  - MRA or MRI with 3D TOF imaging demonstrates avid enhancement
- CT
  - Sensitive for demonstrating bony destruction in other PGs
- Digital subtraction angiography (DSA)
  - Gold standard for diagnosis
  - Provides access for preoperative embolization of feeder vessels
  - Bilateral carotid DSAs should be done to locate other smaller tumors
  - Preoperative assessment of vasculature allows surgeon to remove arterial supply before venous, diminishing blood loss.
- PET
  - 18F-DOPA PET more sensitive than MRI for tumors < 1cm
  - May be used to screen patients with hereditary PGs



B-mode U/S demonstrates hypoechoic mass. Biopsy of this mass is contraindicated as the tumor is very vascular!

Image from Giannoni MF, et al. Carotid Body Tumors: Advantages of Contrast Ultrasound Investigation. J Neuroimaging. 2009;19: 388-390.



# Imaging Modalities: Staging

## Shamblin et al. Staging

- Class I CBT – localized with minimal vascular attachment.
- Class II CBT – partially surrounds carotids.
- Class III CBT – encases carotids. Surgical resection is difficult and may require temporary interruption of cerebral circulation.



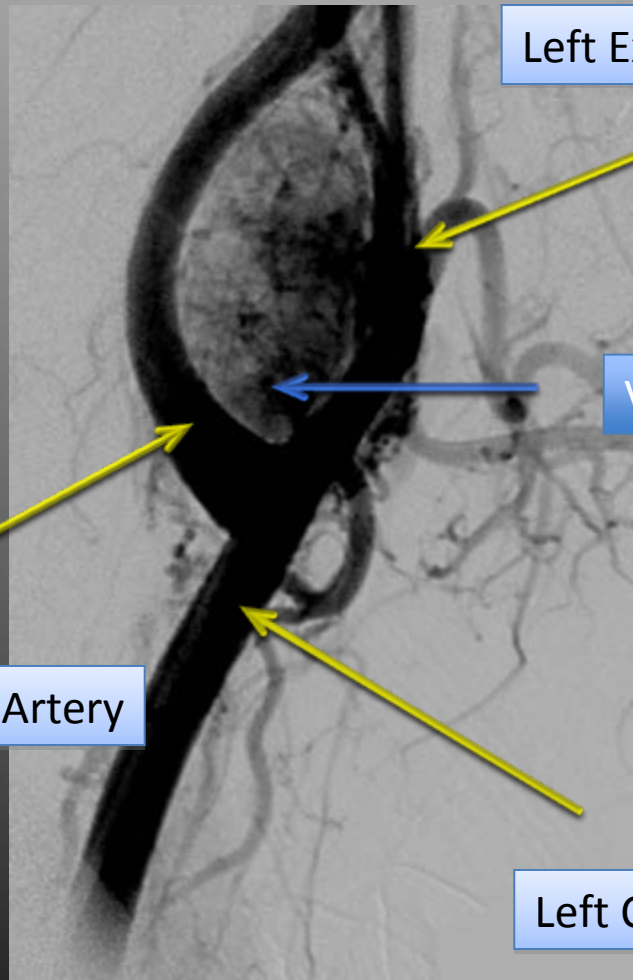
Now that we've reviewed background and imaging modalities, let's return to our patient.





# Our Patient: Angiogram

Pre-operative DSA reveals tumor splaying the carotids. The tumor demonstrates a vascular "blush"



Left External Carotid Artery

Vascular Blush

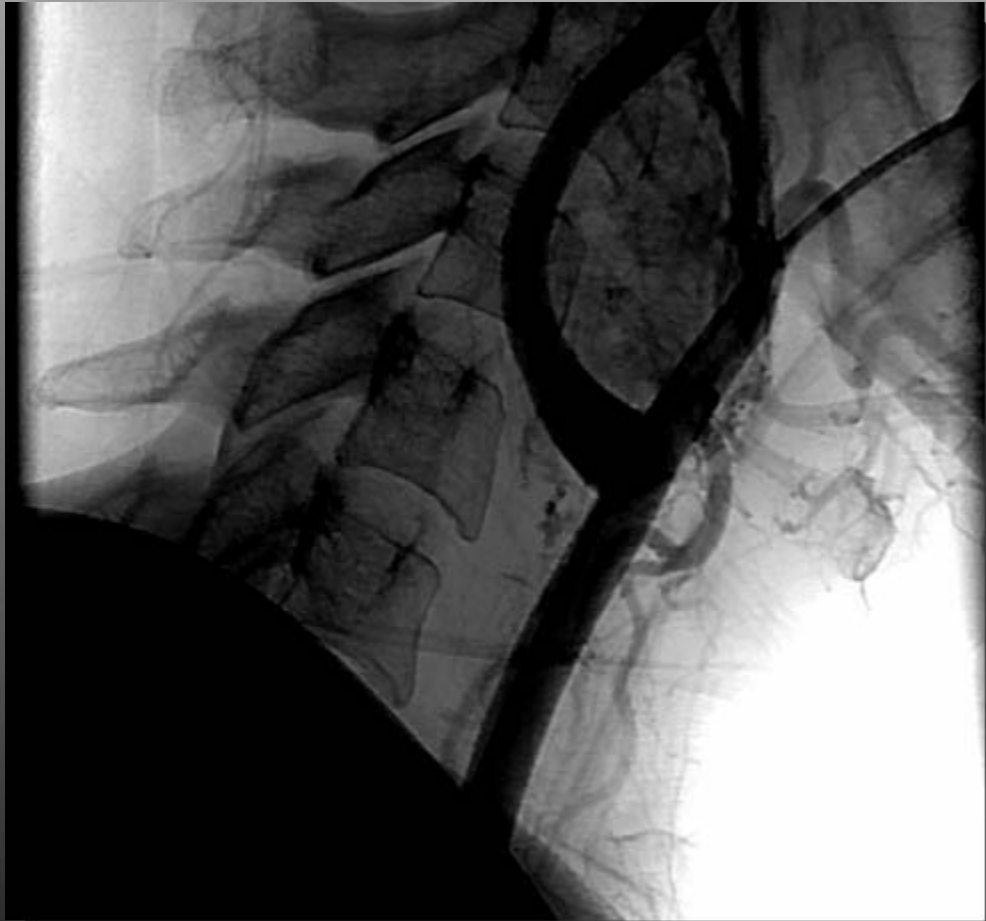Left Internal Carotid Artery

Left Common Carotid Artery

Digital Subtraction Angiogram: Right Lateral View



# Our Patient: Traditional angiogram showing vertebrae for size comparison

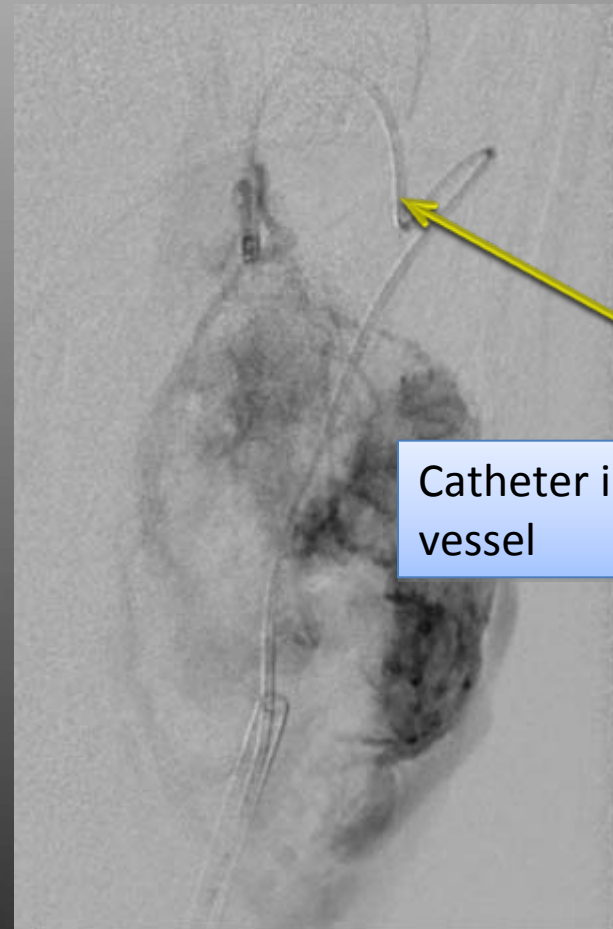


Angiogram: Right Lateral View



# Our Patient: Pre-operative embolization

- A.B. then underwent pre-operative tumor embolization with particle and coil embolization of the L ascending pharyngeal artery.
- Pre-operative embolization is considered by most to be useful in CBTs
- 70% of blood supply embolized.
- Risk of stroke and bleeding



Catheter in feeding vessel

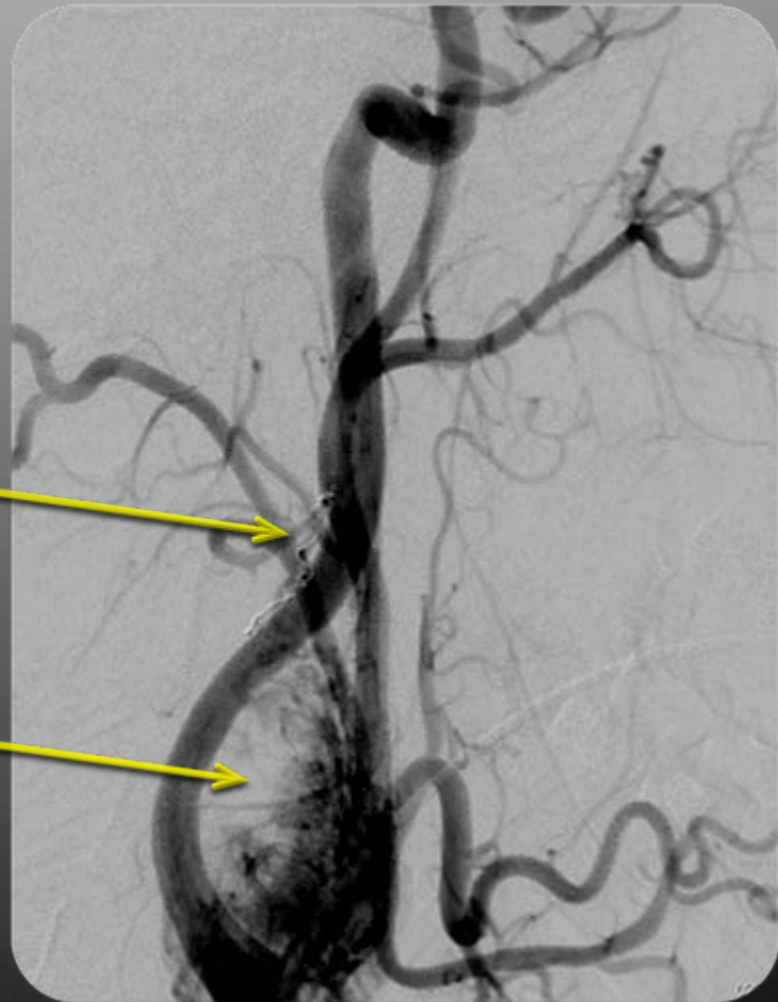


# Our Patient: Results of embolization

Digital Subtraction Angiogram: Right Lateral View

Embolization coil

Vascularity to tumor is now reduced





# Treatment: Surgery

- Transcervical approach
- Arteries cut before veins
- Ipsilateral lymph node removed to examine for metastases. Distant mets are rare.
- 89-100% cure rate
- 21.8% rate of postoperative CN deficit, esp. with larger tumors
- Radiation if cannot tolerate surgery or not-resectable, 96% overall long-term control rates

Intraoperative Photograph

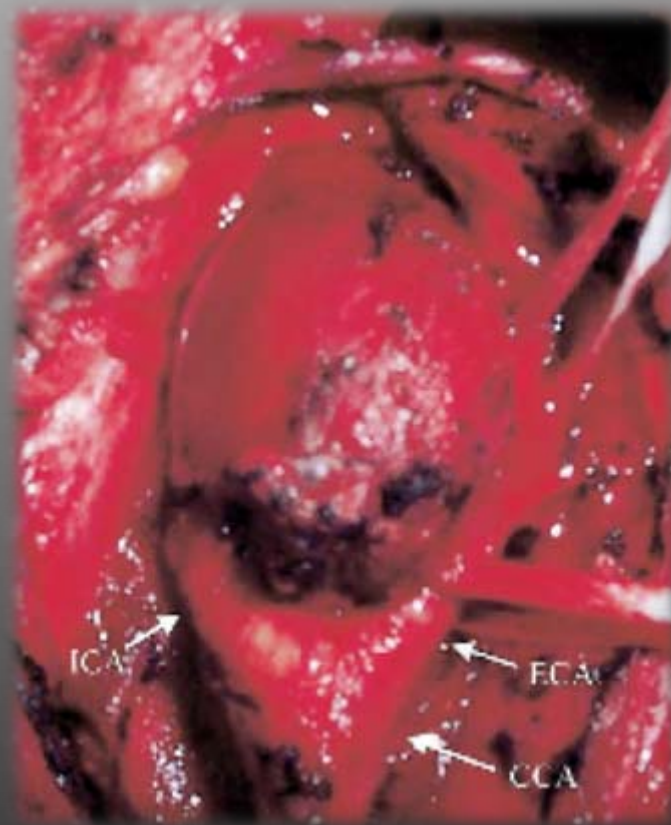


Image from Knight TT, et al. Current concepts for the surgical management of carotid body tumor. American Journal of Surgery. 2006; 191: 104-110.



# Our Patient: Outcome

- A.B. underwent a successful surgical resection of her CBT at BIDMC in April, 2010.
- She had a stable post-operative course and was discharged home on post-operative day 3.
- She remains without complications from her surgery and has gone back to working as an R.N.



# Conclusions

- CBTs are rare tumors of neural crest origin
- Most commonly they present as a painless lateral neck mass
- U/S, MRI, and DSA are the primary imaging modalities to make the diagnosis
- Preoperative embolization is useful in some tumors
- Surgery to remove the tumor is 89-100% successful at achieving a cure





# Acknowledgements

- Dr. Gillian Lieberman, MD
- Dr. Jay Pahade, MD
- Dr. Fargol Booya, MD
- Dr. Gul Moonis, MD
- Dr. Rajan Dewar, MD
- Maria Levantakis





# Works Cited

- Boedeker CC, Ridder GJ, and Schipper J. Paragangliomas of the Head and Neck: Diagnosis and Treatment. *Familial Cancer*. 2005;4: 55-9.
- Van den Berg R. Imaging and management of head and neck paragangliomas. *Eur Radiol*. 2005;15: 1310-1318.
- Athanasiou et al. Carotid Body Tumor: Review of the Literature and Report of a Case With a Rare Sensorineural Symptomatology. *J Oral Maxillofac Surg*. 2007;65: 1388-1393.
- Knight TT, et al. Current concepts for the surgical management of carotid body tumor. *American Journal of Surgery*. 2006; 191: 104-110.
- Giannoni MF, et al. Carotid Body Tumors: Advantages of Contrast Ultrasound Investigation. *J Neuroimaging*. 2009;19: 388-390