

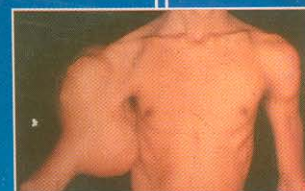
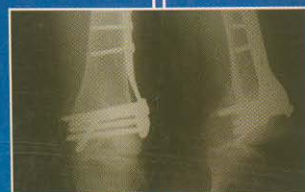
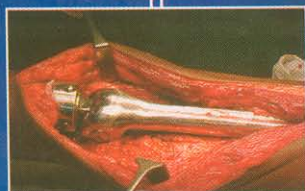NATARAJAN'S

A Question Bank of  
Multiple Choice Questions in

ORTHOPAEDICS

and

TRAUMATOLOGY



**Prof. Mayilvahanan Natarajan**

M.S.Orth (Ma's) MCh. Trauma (L'pool) Ph.D. (Orth. Onco.) D.Sc. Orth.

All India Publishers & Distributors, Regd. New Delhi • Chennai

A QUESTION BANK OF  
MULTIPLE CHOICE QUESTIONS IN  
**ORTHOPAEDICS**  
**AND**  
**TRAUMATOLOGY**

A COMPENDIUM OF MCQS INCORPORATING  
THE LATEST PAPERS OF ALL INDIA, AIIMS AND PGI  
ANSWERS RESEARCHED FROM  
NATARAJAN'S TEXTBOOK OF  
ORTHOPAEDICS AND TRAUMATOLOGY

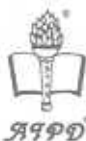**Prof. MAYILVAHANAN NATARAJAN**

M.B.B.S, D. Orth. M.S. Orth. M.Ch. Trauma (Liverpool) Ph.D.  
(Orth. Onco) D.S.C.

**Professor of Orthopedic Surgery**, Madras Medical College and  
Research Institute,

The Tamil Nadu Dr. M.G.R. Medical University,

**Orthopedic Surgeon**, Government General Hospital, Chennai,  
Tamil Nadu Medical Service, Government of Tamil Nadu.



*All India Publishers & Distributors Regd.*

Educational Publishers

New Delhi • Chennai

## **A QUESTION BANK OF MULTIPLE CHOICE QUESTIONS IN ORTHOPAEDICS AND TRAUMATOLOGY**

Copyright © **Dr. MAYILVAHANAN NATARAJAN**

All rights reserved, No part of this publication may be reproduced, stored in retrieval system or transmitted by any means, electronic, mechanical, photocopying or otherwise without the prior written permission of the publisher.

**Warning :** The doing of an unauthorised act in relation to a copyright work may result in both civil claim for damages and criminal prosecution.

**First Edition : 2005**

Published by Rajender K. Arya for ;

***All India Publishers & Distributors Regd.***

Publishers of Medical & Dental Books

New Delhi : 4380/4B, No. 6, Kaushalaya Building,  
Ansari Road, Darya Ganj, New Delhi - 110 002

Ph. : 23244429, 55250321 • Fax : 011 - 22467613

E-Mail : [aidraj@hotmail.com](mailto:aidraj@hotmail.com) & [aidraj@vsnl.com](mailto:aidraj@vsnl.com)

Chennai : Gee Gee Shroff Centre, 1st Floor,  
113, Poonamallee High Road, Chennai-600 084

Ph. : 28233004 • Fax : 044 - 28204911

I.S.B.N. No. : 81-8004-009-7

Printed at : Pashupati Offsets, New Delhi

**A QUESTION BANK OF  
MULTIPLE CHOICE QUESTIONS IN  
ORTHOPAEDICS AND TRAUMATOLOGY**

**A COMPENDIUM OF MCQS INCORPORATING  
THE LATEST PAPERS OF ALL INDIA, AIIMS AND PGI  
ANSWERS RESEARCHED FROM  
NATARAJAN'S TEXTBOOK OF  
ORTHOPAEDICS AND TRAUMATOLOGY**





M.N. ORTHOPAEDIC HOSPITAL



## PREFACE

---

As an academician the latest trends in the examination system of medical students has always been a fascinating study. Hence I have been following the advent of MCQs into the medical examination system with great interest. Multiple choice questions have evolved from a stage of studied disdain to grudging acceptance to a stage where they have become ubiquitous. Their value in objective testing of the student's grasp of the subject has been widely acknowledged by academicians the world over. So it is not surprising to see that they are now so entrenched in the system that the Under-graduate medical student becomes familiar with them from his first year itself and is rid of them only after his super-speciality days are over.

As it has always been my endeavour to help students learn the fascinating subject of Orthopaedics from all angles, I scoured the various books available for MCQs in Orthopaedics, but the dearth of a single, authentic question bank for MCQs was so glaring that it prodded me to bring out the first edition of "A Question Bank of Multiple Choice Questions in Orthopaedics and Traumatology".

This, I hope, will address the long-felt need for an authentic, researched book on MCQs for Orthopaedics. The questions have been drawn from various examinations conducted all over India. The questions have been so segregated that they are arranged in various chapters corresponding to the various topics in "Orthopaedics and Traumatology". The answers have been drawn from the author's "Textbook of Orthopaedics and Traumatology" and in case of doubt, the student is advised to refer to the book. An added feature of this book, is that it incorporates the latest

MCQs which have been asked in the recent papers of ALL INDIA, AIIMS, PGI Post-graduate Entrance Exams. This book is aimed to satisfy the needs of not only the Undergraduates preparing for their Orthopaedic Paper or their PG Entrance Exam, but also the Post-graduates who are preparing for their exams.

The purpose of this book would have been achieved if it kindles in the students an abiding interest in orthopedics.



## **PROF MAYILVAHANAN NATARAJAN**

M.S. Orth. (Ma's), M.Ch. Trauma (Liverpool), Ph.D.  
(Orth.Onco.), D.Sc

Professor of Orthopaedic Surgery,  
Madras Medical College and Govt. General Hospital,  
Chennai

# CONTENTS

|   |     |
|---|-----|
| 1. ORTHOPAEDICS : GENERAL   | 1   |
| 2. CONGENITAL DEFORMITIES   | 2   |
| 3. DEVELOPMENTAL DISORDERS OF BONES                               | 11  |
| 4. INFECTIONS OF BONES AND JOINTS                                 | 20  |
| 5. BONE AND JOINT TUBERCULOSIS                                    | 27  |
| 6. GENERALISED DISEASES OF BONES                                  | 38  |
| 7. DISEASES OF JOINTS   | 53  |
| 8. A VASCULAR NECROSIS OF BONE AND<br>EPIPHYSEAL OSTEOCHONDRITIS  | 69  |
| 9. TUMOURS OF BONE  | 72  |
| 10. NEUROLOGICAL AND MUSCULAR DISORDER                            | 101 |
| 11. REGIONAL CONDITIONS OF NECK AND UPPER LIMB                    | 104 |
| 12. REGIONAL CONDITIONS OF THE SPINE<br>AND UPPER LIMB            | 113 |
| 13. ADVANCES IN ORTHOPAEDIC SURGERY<br>APPENDICES IN ORTHOPAEDICS | 121 |
| 14. INJURIES TO BONES AND JOINTS                                  | 122 |
| 15. INJURIES OF THE SHOULDER AND ARM                              | 135 |
| 16. INJURIES OF THE ELBOW, FOREARM AND WRIST                      | 143 |
| 17. INJURIES OF THE HAND  | 159 |



## CONTENTS

|     |  |           |
|-----|--|-----------|
| 18. | INJURIES OF THE HIP AND THIGH                                  | 162       |
| 19. | INJURIES OF THE KNEE AND LEG                                   | 175       |
| 20. | INJURIES OF THE ANKLE AND FOOT                                 | 177       |
| 21. | INJURIES OF THE SPINE  | 180       |
| 22. | FRACTURE OF THE PELVIS   | 185       |
| 23. | POLYTRAUMA   | 186       |
| 24. | COMPOUND FRACTURES   | 187       |
| 25. | SOFT TISSUE INJURIES INCLUDING SPORT INJURIES                  | 189       |
| 26. | NERVE INJURIES   | 193       |
| 27. | AMPUTATIONS  | 205       |
| ●   | LATEST PAPERS(MCQ'S) OF<br>ALL INDIA, AIIMS & PGI EXAMINATIONS | 206 - 235 |

**1. The Term Orthopaedics was coined by**

- (a) Nicholas Andrey
- (b) Hugh Owen Thomas.
- (c) Thomas Bryant.
- (d) Sir Robert Jones.

*JIPMER 92***2. Which of the following muscles are stance phase muscles?**

- (a) Quadriceps.
- (b) Hamstring muscles.
- (c) Anterior tibial.
- (d) Peroneus longus.
- (e) Soleus – gastrocnemius.

*PGI 80,87***3. Ortolani's test is done for**

- (a) Congenital dislocation hip
- (b) Dislocation patella
- (c) Meniscal injury of knee joint
- (d) Perthes' disease

*UP : 1999***4. Waddling gait is due to**

- (a) Gluteal muscle weakness
- (b) Paravertebral muscle weakness
- (c) Obturator nerve palsy
- (d) Adductor muscle weakness

*NIMS : 2000***5. All of the following statements about a positive Trendelenberg's sign are true, except**

- (a) It occurs with coxa vara
- (b) It occurs with paralysis of hip adductors
- (c) If it is present on both the sides, the gait can look normal
- (d) If it is present on one side, the patient has a lurching gait downwards towards the unsupported side

6. Antalgic hip gait is related to which of the following

- (a) Waddling gait
- (b) Trendelenberg gait
- (c) Painful hip gait
- (d) Short leg gait

TAMIL NADU : 1994

**ANSWERS**

1. (a)

2. (a,e)

3. (a)

4. (a)

5. (c)

6. (c)

**2**

**CONGENITAL DEFORMITIES**

1. Which of the following is seen in bilateral congenital dislocation of hip?

- (a) Waddling Gait.
- (b) Shenton's line is broken.
- (c) Trendelenberg test positive.
- (d) Allis test positive

PGI. 90

2. Treatment of CTEV should begin :

- (a) Soon after birth.
- (b) After discharge from hospital.
- (c) After one month.
- (d) At 2 years.

PGI-90

3. Most important pathology in club foot is :

- (a) Congenital talonavicular dislocation.
- (b) Tightening of Tendoachilles.
- (c) Calcaneal fracture.
- (d) Lateral derangement.

TN-90

**4. In a newborn child, abduction and internal rotation produces a click sound. It is know as :**

- (a) Otorolani's sign.
- (b) Telescoping sign.
- (c) Mc Murray's sign.
- (d) Lachman's sign.

*JIPMER - 80.DELHI 93*

**5. Club foot seen in a 15 year old could be treated successfully by a :**

- (a) Appropriate footwear.
- (b) Soft tissue operation.
- (c) Triple arthrodesis.
- (d) Quadrple fusion.

*PGI 78. 83*

**6. Sprengel's deformity of scapula is :**

- (a) Undescended / Elevated scapula.
- (b) Undescended neck of scapula
- (c) Exostosis scapula.
- (d) None of the above.

*AIIMS 80,84*

**7. Treatment of club foot should begin :**

- (a) As soon as possible after birth
- (b) 1 month after birth
- (c) 1 year after birth.
- (d) None of the above.

*PGI 80, UPSC 93, Karn 95; JIPMER 95*

**8. Treatment for chronic cases of club foot is :**

- (a) Triple arthrodesis.
- (b) Dorso medial release.
- (c) Amputation.
- (d) None.

*JIPMER - 95*

**9. Phocomelia is best described as**

- (a) Defect in development of long bones.
- (b) Defect in development of flat bones
- (c) Defect of intramembranous ossification
- (d) Defect of cartilage replacement by bone.

*ALL INDIA 96*



**10. In correction of clubfoot by manipulation, which deformity should be corrected first :**

- (a) Forefoot adduction.
- (b) Varus.
- (c) Upper end tibia.
- (d) Calcaneum

*AMU.95*

**11. Child 3¼ years is treated for CTEV by**

- (a) Triple arthrodesis
- (b) Postero medial soft tissue release
- (c) Lateral wedge resection
- (d) Tendo Achilles lengthening and posterior capsulotomy.

*TN 97*

**12. Von Rosen Splint is used in**

- (a) CTEV.
- (b) CDH.
- (c) Fracture shaft of femur.
- (d) Fracture tibia.

*PGI.97*

**13. Commonest deformity in congenital dislocation of hip.**

- (a) Small head of femur.
- (b) Angle of torsion.
- (c) Decreased neck shaft angle.
- (d) Shallow acetabulum.

*PGI.97*

**14. Club foot in a new born is treated by**

- (a) Surgery
- (b) Manipulation by the mother
- (c) Dennis Brown splint
- (d) Strapping

*BHU 87*

**15. Treatment of clubfoot in new born is**

- (a) Manipulation and corrective splint
- (b) Corrective splint
- (c) Nothing to be done for 6 months
- (d) Surgical

*ANDHRA: 1993*

16. In a newborn child, abduction and internal rotation produces a click sound. It is  
(a) Otorolani's sign  
(b) Telescoping sign  
(c) Lachman's sign  
(d) Mc Murray's sign *ANDHRA: 1993*
17. Sprengel's shoulder is due to deformity  
(a) Scapula  
(b) Humerus  
(c) Clavicle  
(d) Vertebra *TN 2002*
18. Barlow's sign is related to the diagnosis of  
(a) Talipes equino varus  
(b) Ulnar nerve palsy  
(c) Genu varum  
(d) Congenital dislocation of the hip. *BIHAR.1988*
19. The word "Talipes" refers to  
(a) Long feet with spidery toes  
(b) Flat feet  
(c) Club feet  
(d) Hammer toes *BIHAR 1988*
20. In congenital dislocation of hip, not true is  
(a) Real shortening  
(b) Telescoping  
(c) Trendelenburg test  
(d) Head of femur downwards  
(e) Asymmetrical crease *AMC: 1989*
21. Congenital dislocation of hip is more commonly seen in  
(a) Caucasians  
(b) Negroes  
(c) Japanese  
(d) Eskimos *ANDHRA: 1989*

- 22. Rocker bottom foot is due to**
- (a) Over corrected club foot
  - (b) Poliomyelitis
  - (c) Vertical talus
  - (d) Deformities of spine
- 23. Concerning the diagnosis of congenital dislocation of the hip at the earliest possible moment in life all are true except**
- (a) All obstetricians, midwives and general practitioners can be able to diagnose congenital dislocation of the hip at birth
  - (b) The condition is diagnosed at birth by eliciting a 'click' or a 'clunk' from the hip
  - (c) The sign is known as Barlow's or Von Rosen's Sign
  - (d) Trendelenberg's sign is positive
  - (e) Shenton's test is positive
- 24. Club foot is commoner among**
- (a) Males
  - (b) Binovular twins
  - (c) Females
  - (d) Uniovular twins
- RAJASTAN:1992*
- 25. In a newborn child, abduction and internal rotation produces a click sound. It is**
- (a) Otorolani's sign
  - (b) Telescoping sign
  - (c) Lachman's sign
  - (d) Mc Murray's sign
- DELHI: 1993*
- 26. Causes of a painless limp since infancy includes**
- (a) Congenital dislocation of hip
  - (b) Infantile coxa vara
  - (c) Poliomyelitis
  - (d) All of the above.
- TAMIL NADU 1992*
- 27. Barlow's test is done for testing**
- (a) CDH in child

- (b) CDH in infancy
- (c) Femoral neck fracture
- (d) Slipped femoral epiphysis

**28. Early CTEV is treated by**

- (a) CTEV cast from 1<sup>st</sup> postnatal day
- (b) Manipulation
- (c) Manipulation & Strapping
- (d) Operative repair as early as possible *UP:1999*

**29. Which of the following test is useful in diagnosis of congenital dislocation of hip?**

- (a) Barlow's test
- (b) Thomas test
- (c) Hibb's test
- (d) Laguerres test *PGI : 1999*

**30. Sprengel's deformity is**

- (a) Absence of clavicle
- (b) Acomioclavicular dislocation
- (c) Congenital elevation of scapula
- (d) Recurrent dislocation of shoulder *UP : 2000*

**31. Which carpal bone fracture causes Median nerve involvement?**

- (a) Scaphoid
- (b) Lunate
- (c) Trapezium
- (d) Trapezoid *NIMS : 2000*

**32. A club foot is**

- (a) A consequence of placenta praevia
- (b) Characteristically associated with breech presentation
- (c) Most commonly of the equino valgus variety
- (d) None of the above.

**33. The most common congenital anomaly among the following is encountered in our country**

- (a) Congenital Pseudoarthrosis of Tibia



- (b) Congenital dislocation of hip
- (c) Congenital talipes equino varus
- (d) Multiple congenital contractures

*TAMIL NADU;1994*

**34. Madelung's deformity involves the following;**

- (a) Knee
- (b) Wrist
- (c) Hip
- (d) Elbow

*TAMIL NADU : 1994*

**35. Spina bifida occulta is**

- (a) Infection of the spine
- (b) Traumatic fracture of the spine
- (c) Congenital fusion of the body of the Vertebra
- (d) Congenital non fusion of the spinal lamina

*KARNATAKA:1997*

**36. The club foot characteristically involves**

- (a) Foot and ankle
- (b) Foot, ankle and leg
- (c) Foot only
- (d) Foot, ankle, leg and knee joint

*BIHAR:1999*

**37. The most common deformity seen in club foot is**

- (a) Talipes equino varus
- (b) Equinus
- (c) Equino valgus
- (d) Calcaneo equino varus

*BIHAR : 1999*

**38. Various congenital deformity of the ankle joint occurs at**

- (a) Calcaneonavicular joint
- (b) Talocalcaneal joint
- (c) Talonavicular joint
- (d) Tarsoonavicular joint

*BIHAR : 1999*

- (b) CDH in infancy
- (c) Femoral neck fracture
- (d) Slipped femoral epiphysis

**28. Early CTEV is treated by**

- (a) CTEV cast from 1<sup>st</sup> postnatal day
- (b) Manipulation
- (c) Manipulation & Strapping
- (d) Operative repair as early as possible *UP:1999*

**29. Which of the following test is useful in diagnosis of congenital dislocation of hip?**

- (a) Barlow's test
- (b) Thomas test
- (c) Hibb's test
- (d) Laguerres test *PGI : 1999*

**30. Sprengel's deformity is**

- (a) Absence of clavicle
- (b) Acomioclavicular dislocation
- (c) Congenital elevation of scapula
- (d) Recurrent dislocation of shoulder *UP : 2000*

**31. Which carpal bone fracture causes Median nerve involvement?**

- (a) Scaphoid
- (b) Lunate
- (c) Trapezium
- (d) Trapezoid *NIMS : 2000*

**32. A club foot is**

- (a) A consequence of placenta praevia
- (b) Characteristically associated with breech presentation
- (c) Most commonly of the equino valgus variety
- (d) None of the above.

**33. The most common congenital anomaly among the following is encountered in our country**

- (a) Congenital Pseudoarthrosis of Tibia

39. All of the following are absolute indications for radiological evaluation of pelvis for congenital dislocation of hip, except
- (a) Positive family history
  - (b) Breech presentation
  - (c) Shortening of limb
  - (d) Unstable hip
- AIIMS : 1999*
40. Talipes equinovarus is
- (a) Equinus, inversion, abduction
  - (b) Equinus, inversion, adduction
  - (c) Equinus, eversion, abduction
  - (d) Equinus, eversion, adduction
- PGI : 1997*
41. CDH is due to
- (a) Large acetabulum
  - (b) Rotation of femur
  - (c) Small neck femur
  - (d) Small femoral head
- PGI : 1997*
42. Phocomelia is
- (a) Absence of short bones
  - (b) Complete absence of extremities
  - (c) Defects of long bones of limb
  - (d) Partial absence of extremities
- ALL INDIA : 1998*
43. 'Pseudoarthrosis' in Triple fusion is seen at the joint of
- (a) Calcaneocuboid
  - (b) Calcaneonavicular
  - (c) Naviculocuboid
  - (d) Talonavicular
- DELHI : 1990*
44. Congenital bilateral dislocation of hip shows
- (a) Waddling gait
  - (b) Lordosis
  - (c) + ve Trendelenburg test
  - (d) + ve von Rosen's sign.
- PGI : 1990*

## ANSWERS

- |           |            |         |            |
|-----------|------------|---------|------------|
| 1. (b, c) | 2. (a)     | 3. (a)  | 4. (a)     |
| 5. (c)    | 6. (a)     | 7. (a)  | 8. (a)     |
| 9. (a)    | 10. (a)    | 11. (b) | 12. (b)    |
| 13. (a)   | 14. (b)    | 15. (a) | 16. (a)    |
| 17. (a)   | 18. (d)    | 19. (c) | 20. (d)    |
| 21. (a)   | 22. (c, a) | 23. (c) | 24. (a)    |
| 25. (a)   | 26. (d)    | 27. (b) | 28. (c)    |
| 29. (a)   | 30. (c)    | 31. (b) | 32. (b)    |
| 33. (c)   | 34. (b)    | 35. (d) | 36. (a)    |
| 37. (a)   | 38. (c)    | 39. (b) | 40. (b)    |
| 41. (d)   | 42. (c)    | 43. (d) | 44. (b, c) |
| 45. (c)   | 46. (b)    | 47. (b) | 48. (c)    |
| 49. (a)   | 50. (d)    |         |            |

### 3

## DEVELOPMENTAL DISORDERS OF BONES

- Musculoskeletal abnormalities in neurofibromatosis is**
  - Hypertrophy of limb
  - Scoliosis
  - Pseudo arthrosis
  - All
- Multiple bone fracture in a new born is seen in**
  - Scurvy
  - Syphilis
  - Osteogenesis imperfecta
  - Morquio's syndrome
- The following is false of Achondroplasia**
  - Autosomal dominant.

- (b) Mental retardation.
- (c) Due to gene mutation.
- (d) Shortening of limbs present.

*JIPMER - 91*

**4. Cleidocranial dysostosis may show:**

- (a) Wide foramen magnum.
- (b) Absence of clavicles.
- (c) Coxa vara.
- (d) All of the above.

*PGI 81, AMU 87*

**5. Pseudoarthrosis of tibia is best treated by**

- (a) Internal fixation.
- (b) Internal fixation and bone grafting
- (c) Above knee POP cast.
- (d) Below knee POP cast

*DELHI 96*

**6. Not associated with osteogenesis imperfecta is**

- (a) Blue Sclera.
- (b) Cataract.
- (c) Deafness.
- (d) Fractures.

*TN'98*

**7. Trident hand is seen in**

- (a) Achondroplasia.
- (b) Scurvy.
- (c) Mucopolysacchirodosis.
- (d) None.

*AIIMS 98*

**8. Shepherd's Crook deformity is seen in:**

- (a) Achondroplasia.
- (b) Gaucher's disease
- (c) Hypothyroidism.
- (d) Fibrous dysphasia.

*ORISSA R*

**9. Bone dysplasia is due to**

- (a) Faulty nutrition
- (b) Faulty development
- (c) Trauma
- (d) Parathyroid tumour

*BIHAR 98*

- 10. A child with multiple fractures is suffering from**  
(a) Rickets  
(b) Scurvy  
(c) Hypoparathyroidism  
(d) Osteogenesis imperfecta *DELHI 1988*
- 11. Diaphyseal achlasia is difficult to treat because**  
(a) Causes pressure on nerves  
(b) Pressure on tendon  
(c) Irregular growth  
(d) Causes limitation of movements *AIIMS 1989*
- 12. A 9-year old child with high arched palate has shoulders meeting in front of his chest. He has**  
(a) Erb's palsy  
(b) Cleidocranial dysostosis  
(c) Chondro-Osteodystrophy  
(d) Cortical hyperostosis *ESI 1989*
- 13. The characteristics of Morquio's disease include**  
(a) Spinal kyphosis  
(b) Subnormal / Normal intelligence  
(c) Excessive excretion of keratosulphate in urine  
(d) Dwarfism *KERALA 1989*  
(e) All of the above.
- 14. Absent calvicles are seen in**  
(a) Cleidocranial dysostosis  
(b) Achondroplasia  
(c) Moriquo's disease  
(d) Oliver's disease *AIIMS 1990*
- 15. Cause of congenital pseudoarthrosis is**  
(a) Intrauterine fracture  
(b) Neurofibromatosis  
(c) Fibrous dysplasia  
(d) Unknown. *ANDHRA 1994*



- 16. Ollier's disease is commonest in**  
(a) Fingers  
(b) Thigh  
(c) Spine  
(d) Ribs *DELHI 1994*
- 17. Wormian bones are seen in**  
(a) Osteogenesis imperfecta  
(b) Scheurmanns disease  
(c) Paget's disease  
(d) Osteoclastoma *DELHI 1994*
- 18. Sclerosis of bone is seen in all except**  
(a) Secondaries from prostate  
(b) Fluorosis  
(c) Hyperparathyroidism  
(d) Osteopetrosis *KERALA 1994*
- 19. Pseudoarthrosis can be due to all except**  
(a) Congenital  
(b) Post inflammatory  
(c) Trauma  
(d) None of the above *PGI 1993*
- 20. Wormian bones are not noted in**  
(a) Fibrous dysplasia  
(b) Osteogenesis imperfecta  
(c) Cretinism  
(d) Rickets *ANDHRA 1993*
- 21. The common features of Neurofibromatosis include all, except**  
(a) Optic glioma  
(b) Dumbell neurofibroma  
(c) Scoliosis  
(d) Periventricular calcifications *ANDHRA 1993*

22. **The features of Achondroplasia include all, except**
- (a) Defective head
  - (b) Mental retardation
  - (c) Autosomal recessive
  - (d) Familial
23. **Bone sequestrum is commonly associated with**
- (a) Tuberculosis
  - (b) Nonspecific chronic osteomyelitis
  - (c) Pyogenic osteomyelitis
  - (d) All of the above.
24. **Sequestrum is**
- (a) A piece of infected bone
  - (b) A Piece of dead bone
  - (c) Organised inflammatory exudates
  - (d) Segregated marrow tissue
25. **Club foot is commoner among**
- (a) Males
  - (b) Binovular twins
  - (c) Females
  - (d) Uniovular twins
26. **Marble bone disease is**
- (a) Osteitis fragilis
  - (b) Osteopetrosis
  - (c) Osteosarcoma
  - (d) Paget's disease
27. **Which of the following is a diagnostic test for Acute Haematogenous Osteomyelitis?**
- (a) Plain X-Ray
  - (b) Blood culture
  - (c) CT scan
  - (d) Clinical examination

28. In which of the following condition bilateral symmetrical fractures occur?  
(a) Rickets  
(b) Osteopetrosis  
(c) Osteogenesis imperfecta  
(d) Fluorosis *NIMS : 2000*
29. Which one of the following bone is more susceptible for direct invasion of organisms causing Osteomyelitis?  
(a) Femur  
(b) Tibia  
(c) Ulna  
(d) Humerus *NIMS : 2000*
30. Osteogenesis imperfecta is due to  
(a) Defective mineralization of bone  
(b) Fracture mobilization of calcium from bone  
(c) Abnormal collagen defect  
(d) Excessive Osteoid formation *MANIPAL : 1999*
31. The most common site for acute osteomyelitis in infants is  
(a) Radial  
(b) Femur  
(c) Hip joint  
(d) Tibia *NATIONAL BOARD : 1999*
32. A short statured patient brought to Orthopaedics OPD with a X ray showing flattened vertebra with beak. The probable diagnosis is  
(a) Achondroplasia  
(b) Ochronosis  
(c) Eosinophilic granuloma  
(d) Calve's disease *NIMS : 2000*
33. Albers-Schonberg disease is  
(a) Osteopetrosis  
(b) Osteoporosis  
(c) Osteomalacia  
(d) Osteitis deformans *PGI : 2000*

- 34. Not true about Osteogenesis imperfecta**  
(a) Impaired healing of fracture  
(b) Deafness  
(c) Laxity of joints  
(d) Fragile fracture *UP : 2000*
- 35. Mode of inheritance for Achondroplasia is**  
(a) Autosomal dominant  
(b) Autosomal recessive  
(c) X-linked dominant  
(d) X-linked recessive
- 36. Congenital pseudo arthrosis is seen in the following**  
(a) Hip joint  
(b) Femur  
(c) Radius – ulna  
(d) Tibia-fibula *TAMIL NADU : 1993*
- 37. In X ray, a dead bone looks as**  
(a) Radiolucent  
(b) Radio-opaque  
(c) Highly radio-opaque  
(d) Non visualized *TAMIL NADU : 1993*
- 38. Diaphysial achlasia is related to**  
(a) Multiple hereditary exostosis  
(b) Aneurysmal bone cysts  
(c) Multiple Neurofibromatosis  
(d) Multiple enchondromatosis *TAMIL NADU : 1994*
- 39. Osteogenesis imperfecta is due to the following**  
(a) Excessive Osteoblastic activity  
(b) Defective Osteoid formation  
(c) Defective osteoclast function  
(d) Defective mineralisation of bone *TAMIL NADU : 1994*
- 40. Trident hand is seen in**  
(a) Mucopolysacchroidosis  
(b) Cleido-cranial dysostosis

- (c) Metaphyseal achlasia
- (d) Achondroplasia

**41. Following are true about Osteogenesis imperfecta except**

- (a) Usually green stick fracture
- (b) Generally do not unite without T/t
- (c) Fracture frequency decreases during puberty
- (d) Fracture seen intrauterine life and during parturition.

*MP:1998*

**42. Albert Schonberg disease is**

- (a) Osteopetrosis
- (b) Osteitis punctati
- (c) Osteoporosis
- (d) Osteodystrophy

*PGI:1998*

**43. Osteogenesis imperfecta is defect in**

- (a) Bone
- (b) Calcification
- (c) Cartilage
- (d) Collagen

*PGI:1998*

**44. Not true about Osteogenesis imperfecta is**

- (a) Deafness
- (b) Fractures
- (c) Cataract
- (d) Blue Sclera

**45. All are seen in osteogenesis imperfecta except**

- (a) Blue sclera
- (b) Bilateral Hip dislocation
- (c) Lax ligament
- (d) Osteoporosis

*ALL INDIA:1998*

**46. Pseudoarthrosis is seen in all of the following except**

- (a) Idiopathic
- (b) Fracture
- (c) Osteomyelitis
- (d) Neurofibromatosis

*ALL INDIA:1998*

47. A female with chromosomal defect, cubitus valgus, and short neck, is most likely to have  
(a) Turner's syndrome  
(b) Klinefelter's syndrome  
(c) Marfan's syndrome  
(d) Sturge Weber's syndrome *AMC:1990*
48. Brittle bones disease is  
(a) Osteoporosis  
(b) Osteopetrosis  
(c) Osteogenesis imperfecta  
(d) Osteomalacia *NATIONAL BOARD:1990*
49. Osteogenesis imperfecta  
(a) Autosomal Dominant (AD)  
(b) Autosomal Recessive (AR)  
(c) Both AD and AR  
(d) Sex linked dominant None of the above. *PGI:1990*
50. Multiple bone fractures are seen in  
(a) Rickets  
(b) Osteomalacia  
(c) Scurvy  
(d) Osteogenesis imperfecta *AMC: 1991*
51. All are true of Achondroplasia except  
(a) Autosomal dominant  
(b) Shortening of limbs is present  
(c) Usually due to gene mutation  
(d) Mental retardation. *JIPMER: 1991*
52. Jaw tumour is seen in  
(a) Osteoporosis  
(b) Osteomalacia  
(c) Osteopetrosis  
(d) Caffey's disease *AIIMS : 1992*



## ANSWERS

- |         |         |         |         |
|---------|---------|---------|---------|
| 1. (d)  | 2. (b)  | 3. (b)  | 4. (d)  |
| 5. (b)  | 6. (b)  | 7. (a)  | 8. (d)  |
| 9. (b)  | 10. (d) | 11. (c) | 12. (b) |
| 13. (e) | 14. (a) | 15. (b) | 16. (a) |
| 17. (a) | 18. (c) | 19. (b) | 20. (a) |
| 21. (a) | 22. (c) | 23. (c) | 24. (a) |
| 25. (a) | 26. (b) | 27. (b) | 28. (c) |
| 29. (b) | 30. (c) | 31. (d) | 32. (a) |
| 33. (a) | 34. (a) | 35. (a) | 36. (d) |
| 37. (b) | 38. (a) | 39. (b) | 40. (d) |
| 41. (b) | 42. (a) | 43. (a) | 44. (c) |
| 45. (b) | 46. (b) | 47. (b) | 48. (b) |
| 49. (c) | 50. (d) | 51. (c) | 52. (d) |

## 4

### INFECTIONS OF BONES AND JOINTS

1. Acute Hematogenous osteomyelitis is treated with all except:
  - (a) Antibiotics.
  - (b) Splinting.
  - (c) Analgesics.
  - (d) Surgery. *PGI 88*
2. Which is false regarding acute osteomyelitis?
  - (a) Staphylococcus is the usual organism.
  - (b) Rest and elevation relieves pain.
  - (c) Parenteral antibiotics are given.
  - (d) Surgery is the only treatment. *KERALA. 89*

3. When osteomyelitis disseminates by Hematogenous way the most affected part of bone is;
- (a) Metaphyses.
  - (b) Epiphyses.
  - (c) Diaphyses
  - (d) Any of the above
- JIPMER - 95*
4. Tom Smith arthritis manifests as;
- (a) Increase hip mobility and instability.
  - (b) Hip Stiffness.
  - (c) A+ B.
  - (d) Shortening of limb
- PAL '96*
5. Bony ankylosis result from
- (a) Pyogenic arthritis
  - (b) Tuberculosis arthritis
  - (c) Osteoarthritis
  - (d) Rheumatic arthritis
- PGI 85,87*
6. Brodies abscess usually involves
- (a) long bones.
  - (b) short bones
  - (c) Pelvic bones.
  - (d) Flat bones.
- AI 91*
7. What is Brodie's abscess?
- (a) Long standing localized pyogenic abscess in the bone.
  - (b) Cold abscess
  - (c) Subperiosteal abscess
  - (d) Soft tissue abscess
- JIPMER 90*
8. Commonest cause of hematogenous osteomyelitis
- (a) Streptococcus.
  - (b) Staph aureus.
  - (c) Salmonella.
  - (d) H. influenza.
- JIPMER 98*
9. Actinomyces is commonly seen in
- (a) Tibia.

- (b) Mandible
- (c) Scapula
- (d) Femur.

**10. Sclerosis of a long bone may suggest**

- (a) Osteoid osteoma
- (b) Sclerosing Osteomyelitis
- (c) Both are correct
- (d) None of the above.

*PGI 1988*

**11. The most common cause of Osteomyelitis is**

- (a) Staphylococcus aureus
- (b) Streptococcus haemolyticus
- (c) Clostridium welchii
- (d) Esch. Coli

*UPSE 1988*

**12. A 9-year-old child with high arched palate has shoulders meeting in front of his chest. He has**

- (a) Erb's palsy
- (b) Cleidocranial dysostosis
- (c) Chondro-Osteodystrophy
- (d) Cortical hyperostosis

*ESI,1989*

**13. Non-healing sinus is a common clinical feature in chronic osteomyelitis. The most common frequent cause for this presentation is**

- (a) Resistant organisms
- (b) Retained foreign body
- (c) Presence of sequestrum
- (d) Intraosseous cavities

*KARNATAKA,1988*

**14. Which of the following terms is inappropriate to the condition of Osteomyelitis?**

- (a) Cloacae
- (b) Involucrum
- (c) Sequestrum
- (d) Myelocoele

*AMU:1989*

15. **The most common cause of Monoarthritis in Children is**  
(a) Septic arthritis  
(b) Tuberculous arthritis  
(c) Osteoarthritis  
(d) Rheumatoid arthritis  
(e) Any of the above *ANDHRA:1989*
16. **Acute suppurative arthritis is associated with all except**  
(a) May be caused by a penetrating wound  
(b) May be caused by a compound fracture involving a joint  
(c) May be due to blood borne infection  
(d) Causes the joint to be held in the position of ease  
(e) Tends to end with the formation of a fibrous ankylosis
17. **Tom smith's arthritis is due to**  
(a) Pyogenic infection in infancy  
(b) TB  
(c) RA  
(d) OA *PGI: 1999*
18. **Bony ankylosis occurs in**  
(a) Tuberculos arthritis  
(b) Osteo arthritis  
(c) Rheumatoid arthritis  
(d) Pyogenic arthritis *MANIPAL: 1999*
19. **Which never involves epiphyseal plate?**  
(a) Tuberculosis  
(b) Osteoclastoma  
(c) Acute osteomyelitis  
(d) Osteochondroma *JIPMER : 1999*
20. **The most common source of bone and joint infection is**  
(a) Direct spread  
(b) Percutaneous  
(c) Lymphatic  
(d) Haematogenous *TAMIL NADU : 1994*

**21. Involucrum means**

- (a) Fragment of dead bone
  - (b) Hole formed in the bone during the formation of a draining sinus
  - (c) Osteomyelitis of spine
  - (d) Periosteal new bone formation around necrotic sequestrum.
- MANIPAL : 1998*

**22. About Sequestrum not true is**

- (a) Infection nidus
  - (b) Lighter than live bone
  - (c) Dead piece of bone
  - (d) Heavier than live bone & trabeculated.
- PGI:1998*

**23. Blood spread of osteomyelitis is to**

- (a) Diaphysis
  - (b) Metaphysis
  - (c) Epiphysis
  - (d) Physeal plate
- ANDHRA:1997*

**24. Involucrum is found**

- (a) Underneath the sequestrum
  - (b) Around the sequestrum
  - (c) At metaphysis
  - (d) Beneath the periosteum
- ANDHRA: 1997*

**25. Madura Foot is**

- (a) Tuberculous infection of the bone
  - (b) Madura mycotic infection of the bone
  - (c) Parasytic infection of the bone
  - (d) Water borne disease of the foot.
- KARNATAKA:1997*

**26. Chronic osteomyelitis is diagnosed mainly by**

- (a) Sequestrum
  - (b) Bone fracture
  - (c) Deformity
  - (d) Brodie's abscess
- MANIPAL:1997*

27. All are associated with chronic osteomyelitis except  
(a) Amyloidosis  
(b) Sequestrum  
(c) Metastatic abnormality  
(d) Myositis ossificans *ALL INDIA:1999*
28. The most common organism causing osteomyelitis in drug abusers is  
(a) E.coli  
(b) Pseudomonas  
(c) Klebsiella  
(d) Staph. Aureus *PGI:1997*
29. When does the lesion of Osteomyelitis appear on X-ray  
(a) 2 hours  
(b) 24 hours  
(c) 1 week  
(d) 2 weeks *DELHI:1990*
30. Acute Osteomyelitis of long bones commonly affects the  
(a) Epiphysis  
(b) Diaphysis  
(c) Metaphysis  
(d) Articular surface *PGI:1998*
31. A patient with swelling foot, pus discharge, multiple sinuses. KOH smear shows filamentous structures. Diagnosis is  
(a) Osteomyelitis  
(b) Madura Mycosis  
(c) Anthrax  
(d) Tetanus unilateral *UPSC:1990*
32. Sabre tibia seen in  
(a) Tuberculous Osteomyelitis  
(b) Syphilitic osteitis  
(c) Rickets  
(d) Paget's disease *AIIMS:1991*



33. A dead piece of bone is known as  
(a) Involucrum  
(b) Sequestrum  
(c) Cloacae  
(d) All of these *BIHAR:1991*
34. Metaphyseal lesion in children includes  
(a) Fracture  
(b) Osteomyelitis  
(c) Dislocation  
(d) Ewing's tumour  
(e) Osteosarcoma *PGL: 1991*
35. The ideal treatment for acute Osteomyelitis of long bones is  
(a) Antibiotics only  
(b) Drilling of bone  
(c) Decompression  
(d) Antibiotics and delayed decompression.
36. Chondrolysis occurs commonly in  
(a) T.B. arthritis  
(b) Syphilitic arthritis  
(c) Chondrosarcoma only  
(d) Septic arthritis of infancy.
37. Arthritis of tertiary syphilis most frequently involves:  
(a) Shoulder joint  
(b) Elbow joint  
(c) Knee joint  
(d) All of these.

|                |
|----------------|
| <b>ANSWERS</b> |
|----------------|

- |        |         |         |         |
|--------|---------|---------|---------|
| 1. (d) | 2. (d)  | 3. (a)  | 4. (c)  |
| 5. (a) | 6. (a)  | 7. (a)  | 8. (b)  |
| 9. (b) | 10. (c) | 11. (a) | 12. (b) |

- |         |           |         |         |
|---------|-----------|---------|---------|
| 13. (c) | 14. (d)   | 15. (b) | 16. (e) |
| 17. (a) | 18. (d)   | 19. (b) | 20. (d) |
| 21. (d) | 22. (d)   | 23. (b) | 24. (b) |
| 25. (b) | 26. (a)   | 27. (d) | 28. (a) |
| 29. (d) | 30. (c)   | 31. (b) | 32. (b) |
| 33. (b) | 34. (b,e) | 35. (a) | 36. (d) |
| 37. (c) |           |         |         |

## 5

### BONE AND JOINT TUBERCULOSIS

1. Commonest site of skeletal tuberculosis is:

- (a) Tibia.
- (b) Radius.
- (c) Humerus.
- (d) Vertebrae.

*KERALA.88*

2. Tuberculosis of the spine is known as;

- (a) Pott's disease.
- (b) Scheuermann's disease.
- (c) Perthes disease.
- (d) Frieberg's disease.

*JIPMER - 88*

3. Tuberculous arthritis in advanced cases lead to:

- (a) Bony ankylosis.
- (b) Fibrous ankylosis.
- (c) Loose joints.
- (d) Charcots joints.

*TN.89*

4. Tuberculosis of the spine starts in:

- (a) Vertebral body.
- (b) Nucleous pulposus.
- (c) Annulus fibrosis.
- (d) Paravertebral fascia

*PGI 88*

5. Triple deformity of knee is seen in

- (a) Polio
- (b) Tuberculosis
- (c) Villonodular synovitis
- (d) Rheumatoid arthritis

*UPSC-95*

6. Treatment of triple deformity is

- (a) ATT
- (b) ATT+ Immobilisation.
- (c) ATT + Immobilisation + Débridement
- (d) None

*AMU.95*

7. The 1<sup>st</sup> sign of TB is

- (a) Narrowing of intervertebral space
- (b) Rarefaction of vertebral bodies
- (c) Destruction of laminae
- (d) Fusion of spinous processes.

*C.U.P.G.E.E.95*

8. Earliest features of TB vertebra

- (a) Decreased joint space
- (b) Soft tissue swelling.
- (c) Decreased movements.
- (d) Pain

*CUPGEE.99*

9. Commonest site of Tuberculosis spine is

- (a) C<sub>8</sub> - T<sub>2</sub>.
- (b) T<sub>2</sub> - T<sub>6</sub>
- (c) T<sub>10</sub> - L<sub>1</sub>
- (d) L<sub>1</sub> - L<sub>4</sub>

10. Earliest sign in X-Ray in T.B Spine:

- (a) Paravertabral shadow.
- (b) Narrowing of disc space.
- (c) Gibbus
- (d) Straightening of the spinal curves.

11. Commonest site of Tuberculosis Spine

- (a) Dorso lumbar

- (b) Lumbar
- (c) Sacral
- (d) Flexion and rotation.

*ALL INDIA 95*

**12. Triple deformity is a complication of**

- (a) Rheumatoid arthritis
- (b) Tuberculosis
- (c) Osteoarthritis
- (d) Septic arthritis

*AIIMS 97*

**13. In the majority of cases, the tuberculosis of the vertebra starts in the**

- (a) Body
- (b) Pedicle
- (c) Spine
- (d) Neural arch

*Bhu:1988*

**14. The most common type of Spinal Tuberculosis is**

- (a) Anterior
- (b) Posterior
- (c) Central
- (d) Paradiscal

*Bihar:1988*

**15. Earliest radiological sign of Spinal Tuberculosis is**

- (a) Wedging of vertebra
- (b) Syndesmophyte formation
- (c) Formation of paravertebral abscess
- (d) Decreased joint space

*BIHAR:1988*

**16. Spina Ventosa results from**

- (a) Sarcoidosis
- (b) Tuberculosis
- (c) Histiocytosis X syndrome
- (d) Both A + B but not C

*BIHAR:1988*

**17. Compression of single vertebra with narrow joint space is characteristic of**

- (a) Caries spine

- (b) Fracture spine
- (c) Prolapsed intervertebral disc
- (d) Secondaries spine.

*ORISSA:1988*

**18. Short long bones of hand and foot are commonly infected by the following organism**

- (a) Pyogenic
- (b) Tuberculous
- (c) Fungal
- (d) All of the above

*TAMIL NADU 1988*

**19. The most common site of skeletal tuberculosis is**

- (a) Humerus
- (b) Tibia
- (c) Vertebrae
- (d) Radius

*KERALA:1988*

**20. Treatment of Pott's paraplegia is**

- (a) Lateral decompression
- (b) Posterior decompression
- (c) Excision of vertebra
- (d) Antituberculous drugs

*UPSC:1988*

**21. Caries sicca is seen in**

- (a) Hip
- (b) Shoulder
- (c) Knee
- (d) None of the above

**22. Paraplegia is common in Tuberculosis of dorsal spine, because**

- (a) Incidence of Tuberculosis is commoner in dorsal spine
- (b) Natural tendency for kyphosis.
- (c) Canal is narrow.
- (d) Spinal cord ends at L<sub>1</sub>.
- (e) All of the Above.

- 23. All are features of joint Tuberculosis except**
- (a) Synovium is involved
  - (b) Synovial fluid has < 20% blood sugar
  - (c) Kissing arthritis-subchondral bone is involved
  - (d) Pain is a common feature
  - (e) Lymphocyte / Monocyte ratio is decreased.

- 24. In Antero-lateral decompression**
- (a) Laminectomy is performed
  - (b) Vertebral bodies are exposed
  - (c) Anterior longitudinal ligament is exposed
  - (d) Spinal nerve roots have to be exposed.

- 25. Pott's spine is commonest in spine**
- (a) Cervical
  - (b) Thoracic
  - (c) Lumbar
  - (d) Sacral

*DELHI: 1994*

- 26. Instillation treatment in Osteomyelitis is**
- (a) Continuous suction + continuous drainage
  - (b) Intermittent suction + continuous drainage
  - (c) Continuous suction + intermittent drainage
  - (d) Intermittent suction + intermittent drainage

- 27. Osteoid formation is normal in all of the following except**
- (a) Scurvy
  - (b) Osteoporosis
  - (c) Rickets
  - (d) Secondaries bone

*JIPMER:1993*

- 28. The most common cause of genuvalgum in children is**
- (a) Rickets
  - (b) Rheumatoid arthritis
  - (c) Osteoarthritis
  - (d) Paget's disease

*AIIMS 1993*



- 29. Paravertebral masses include all, except**  
(a) Tuberculous abscess  
(b) Neurofibroma  
(c) Oesophageal varices  
(d) Dermoid cyst *ANDHRA 1993*
- 30. Advanced cases of Tuberculous arthritis may lead to**  
(a) Hyperlaxity of joints  
(b) Clutton's joints  
(c) Fibrous ankylosis  
(d) Bony ankylosis *TAMIL NADU:1992*
- 31. The most common cause of Paraplegia of early onset of Tuberculosis of spine is**  
(a) Spinal artery thrombosis  
(b) Sudden collapse of vertebra  
(c) Granulation tissue pressing on cord  
(d) Cold abscess pressing on the cord *KARNATAKA.1992*
- 32. A psoas abscess present on the right side, the correct statement is**  
(a) Opposite hip flexion relieves pain  
(b) Same side hip flexion relieves pain  
(c) Same side extension relieves pain  
(d) Kyphosis may occur *NIIMS:1992*
- 33. Earliest feature of spinal tuberculosis is**  
(a) Gibbus  
(b) Muscle spasm  
(c) Pain  
(d) Psoas abscess *ORISSA:1992*
- 34. The earliest feature of tuberculosis of spine is**  
(a) Pain  
(b) Decreased movements  
(c) Soft tissue swelling  
(d) Night cries *WEST BENGAL: 1999*

35. Which of the following causes para vertebral abscess?  
(a) Brucella  
(b) Tuberculosis  
(c) Kala-azar  
(d) Typhoid *TAMIL NADU 1999*
36. Early features of spinal tuberculosis in a child includes  
(a) Pain on sudden movement  
(b) Gradual deformity  
(c) Night cries  
(d) Sudden deformity *UP : 1999*
37. In a fracture shaft of femur following accident, first thing to do is  
(a) Splinting  
(b) Secure airway and treat the shock  
(c) Internal fixation of fracture  
(d) Physical examination *KARNATAKA: 2000*
38. In Tuberculosis of spine, which one of the following is not a cause for Paraplegia?  
(a) Stretching of spinal cord in gibbus deformity  
(b) Spinal artery compression  
(c) Compression by granulation tissue  
(d) Oedema of spinal cord *NIMS : 2000*
39. X-ray showing decreased Intervertebral space and presence of Para vertebral shadow. What could be the diagnosis?  
(a) Tuberculosis of spine  
(b) Ankylosing spondylitis  
(c) Eosinophilic granuloma  
(d) Multiple Myeloma *NIMS : 2000*
40. All are true about Caries spine except  
(a) Most common in dorso lumbar spine  
(b) Early onset of paraplegia has better prognosis  
(c) Gradual onset paraplegia has better prognosis

(d) Usually associated with Para spinal cold abscess

*PGI : 2000*

**41. Tuberculosis of spine is best treated by**

- (a) Anterior fusion
- (b) Posterior fusion
- (c) Hong Kong procedure
- (d) Aspiration of Para spinal abscess and instillation of streptomycin

*TAMIL NADU : 1994*

**42. All of the following movements of the hip are painful in a patient with psoas abscess, except**

- (a) Extension
- (b) Adduction to abduction
- (c) Abduction to adduction
- (d) Fixed flexion to further full flexion

*TAMIL NADU : 1994*

**43. Cold abscess is commonly due to infection of**

- (a) Skull
- (b) Ribs
- (c) Spine
- (d) Sternum

**44. Tuberculosis of the spine is thought to originate from**

- (a) By extension from the para vertebral structures
- (b) In the cancellous vertebral body
- (c) In the ligamentous structures
- (d) In the nucleus pulposus

*BIHAR : 1998*

**45. Compound palmar ganglion is**

- (a) Tuberculosis affection of ulnar bursa
- (b) Pyogenic affection of ulnar bursa
- (c) Non specific affection of ulnar bursa
- (d) Ulnar bursitis due to compound injury

**46. The most common cause of Bony ankylosis at hip joint**

- (a) Rheumatoid arthritis
- (b) Septic arthritis of hip

(c) Tubercular arthritis

(d) Osteitis deformans

*UP:1998*

**47. In Bony ankylosis, there is**

(a) Painless, No movement

(b) Painful complete movement

(c) Painless complete movement

(d) Painful incomplete movement

*UP:1998*

**48. The most common cause of Kyphosis in a male is**

(a) Congenital

(b) Tuberculosis

(c) Trauma

(d) Secondaries

*NATIONAL BOARD:1997*

**49. Paraplegia due to Tuberculosis of spine most commonly occurs at**

(a) Cervical spine

(a) Upper thoracic spine

(a) Lower thoracic spine

(a) Lumbar spine

*NATIONAL BOARD:1997*

**50. Bony ankylosis is caused by**

(a) Tuberculous arthritis

(b) Rheumatoid arthritis

(c) Pyogenic arthritis

(d) Osteoarthritis

*PGI:1997*

**51. The ideal surgical treatment for Pott's paraplegia is**

(a) Laminectomy and decompression

(b) Anterior decompression and bone grafting

(c) Anterolateral decompression

(d) Costotransversectomy

*UPSC:1997*

**52. Bony ankylosis of a hip joint in adults is commonly caused by**

(a) Fractures dislocation of the hip

(b) Tuberculous arthritis

(c) Rheumatoid arthritis

- (d) Pyogenic arthritis
- (e) Ankylosing spondylitis

*PGI:1990*

**53. A five year old child is suffering from painful restriction of all movements of hip joint, the most likely cause in our country is**

- (a) Congenital coxa vara
- (b) Tuberculosis arthritis
- (c) Perthes' disease
- (d) Sequelae of septic arthritis of infancy
- (e) Psoas abscess

*ORISSA:1990*

**54. The most appropriate for a 20 year old man suffering from old tuberculosis arthritis of knee with triple deformity is**

- (a) Plaster immobilization
- (b) Joint clearance and traction
- (c) Total knee replacement
- (d) Charnley's Arthrodesis

*ORISSA:1990*

**55. Wandering acetabulum is seen in**

- (a) Fracture of acetabulum
- (b) Dislocation of femur
- (c) Congenital dislocation of hip
- (d) Tuberculosis of hip

*DELHI: 1991*

**56. Surgical treatment in Pott's spine is indicated if there is**

- (a) Progressive loss of function in spite of medical treatment
- (b) No improvement in motor power in spite of 3 months of treatment
- (c) There is no improvement in fever in 3 months of treatment
- (d) Patient who is an adult or middle aged.

*PGI: 1991*

**57. The most common site of skeletal tuberculosis is**

- (a) Hip + Spine
- (b) Knee + Hip joints
- (c) Knee joint
- (d) Cervical spine

*AMC : 1992*

58. Short long bones are commonly involved in  
 (a) Pyogenic  
 (b) T.B  
 (c) Fungal infection  
 (d) All of the above.
59. The commonest infective lesion of the spine in India is:  
 (a) Pyogenic infection  
 (b) Fungal  
 (c) T.B.  
 (d) Typhoid
60. The earliest change of tuberculous arthritis on X-ray is:  
 (a) Narrowing of space  
 (b) Bone density increases  
 (c) Rarefaction of bones adjacent to joint  
 (d) All of the above.

### ANSWERS

- |         |          |         |          |
|---------|----------|---------|----------|
| 1. (d)  | 2. (a)   | 3. (b)  | 4. (a)   |
| 5. (b)  | 6. (b)   | 7. (a)  | 8. (a)   |
| 9. (c)  | 10. (b)  | 11. (a) | 12. (b)  |
| 13. (a) | 14. (d)  | 15. (d) | 16. (d)  |
| 17. (a) | 18. (b)  | 19. (c) | 20. (ad) |
| 21. (b) | 22. (be) | 23. (e) | 24. (b)  |
| 25. (b) | 26. (a)  | 27. (a) | 28. (a)  |
| 29. (c) | 30. (c)  | 31. (d) | 32. (b)  |
| 33. (c) | 34. (a)  | 35. (b) | 36. (a)  |
| 37. (b) | 38. (b)  | 39. (a) | 40. (c)  |
| 41. (c) | 42. (d)  | 43. (c) | 44. (b)  |
| 45. (a) | 46. (c)  | 47. (a) | 48. (b)  |
| 49. (c) | 50. (a)  | 51. (b) | 52. (b)  |
| 53. (b) | 54. (d)  | 55. (d) | 56. (a)  |
| 57. (a) | 58. (b)  | 59. (c) | 60. (a)  |

# 6

## GENERALISED DISEASES OF BONES

- 1. Hand Schuler Christian Disease, which is correct?**
  - (a) Proliferation of reticulo endothelial cells.
  - (b) Foam cells seen.
  - (c) Punched out lesions in X-Ray
  - (d) Diabetes insipidus and Exophthalmos present
  - (e) All are correct. *KERALA.88*
- 2. Osteitis fibrosa cystica is seen in:**
  - (a) Hyperparathyroidism.
  - (b) Hypoparathyroidism.
  - (c) Hypothyroidism.
  - (d) Hyperthyroidism. *A.I.89*
- 3. Pain in Pagets disease is relieved best by:**
  - (a) Simple analgesics.
  - (b) Narcotic analgesics.
  - (c) Radiation.
  - (d) Calcitonin. *AIIMS-86*
- 4. The complications of Paget's disease is:**
  - (a) Osteogenic sarcoma.
  - (b) Deafness.
  - (c) Heart failure.
  - (d) All of the above. *AIIMS 87*
- 5. Increased bone density occurs in:**
  - (a) Cushing syndrome.
  - (b) Hypoparathyroidism.
  - (c) Fluorosis.
  - (d) Hyperthyroidism *UP 88*
- 6. Increased density in skull vault is seen in:**
  - (a) Hyperparathyroidism.
  - (b) Multiple myeloma.



- (c) Fluorosis.
- (d) Renal Osteodystrophy

*PGI 90*

**7. Deafness in cases of Paget's disease is due to:**

- (a) Thickened cranium.
- (b) Narrowing of foramina of skull.
- (c) Brain compression.
- (d) Otosclerosis.

*PGI 81, DNB 89*

**8. Not a complication of menopause**

- (a) Fracture spine.
- (b) Colles fracture.
- (c) Fracture neck of femur.
- (d) Supra condylar fracture humerus.

*KERALA.95*

**9. Soft tissue calcification occurs in all except**

- (a) Hyper parathyroidism.
- (b) Scleroderma.
- (c) Hyperthyroidism.
- (d) Hyper Vitaminosis D.

*KERALA.95*

**10. Resorption of the terminal phalanx is not seen in**

- (a) Hyperparathyroidism.
- (b) Reiter's Syndrome.
- (c) Scleroderma.
- (d) Psoriasis.

*KERALA.98*

**11. What is the diagnostic radiological finding skeletal fluorosis**

- (a) Sclerosis of sacroiliac joint.
- (b) Interosseous membrane ossification
- (c) Osteosclerosis of vertebral body.
- (d) Ossification of ligaments of knee joint.

*JIPMER.2K*

**12. Drug therapy of Paget's disease (Osteitis Deformans) include all except:**

- (a) Alendronate.
- (b) Etidronate.



- (c) Calcitonin.
- (d) Plicamycin.

KARNATAKA 2001

**13. Sclerotic lesion in the bone is seen in all except**

- (a) Osteitis fibrosa.
- (b) Osteopetrosis.
- (c) Melorheostosis.
- (d) Caffey's disease.

AI.91

**14. Absence of lamina dura in the alveolus occurs in**

- (a) Rickets.
- (b) Osteomalacia
- (c) Deficiency of vitamin C
- (d) Hyperparathyroidism

TN.91

**15. Osteomyelitis of Jaw is seen in**

- (a) Osteomalacia.
- (b) Osteopoikilosis
- (c) Osteoporosis
- (d) Caffey's disease.

AIIMS 92

**16. All of following conditions may be responsible for osteoporosis except**

- (a) Steroid therapy
- (b) Prolonged weightlessness in spaceship
- (c) Hyperparathyroidism
- (d) Hypoparathyroidism

AI.96

**17. Following are features of Paget's disease except**

- (a) Deformity of bones
- (b) Secondary osteosarcoma
- (c) Lowered serum alkaline phosphatase
- (d) Surgery

KARNAT.96

**18. Caffey's disease occurs in**

- (a) Infants below 6 months.
- (b) Above 5 years
- (c) Above 10-20 years
- (d) 20-40 years.

NIIMS.96

19. **Most Common site of Eosinophilic granuloma**  
(a) Radius  
(b) Femur  
(c) Skull  
(d) lumbar vertebrae *M.P. 98*
20. **Calcium content of bone is increased in**  
(a) Prolonged immobilisation.  
(b) Glucocorticoid administration  
(c) Hyperparathyroidism  
(d) Estrogen supplementation in post menopausal women *MAHE 98*
21. **Vertebra plana is caused by:**  
(a) Malignancy  
(b) Tuberculosis  
(c) Syphilis  
(d) Eosinophilic granuloma *PGI 81, AMU 88*
22. **Drug of choice for senile osteoporosis is**  
(a) Estrogens,  
(b) Androgens  
(c) Calcitonin  
(d) Ethidronate. *JIPMER 90*
23. **Which is correct regarding Hand Schuler Christian Disease?**  
(a) Punched out lesions in X-ray  
(b) Proliferation of reticuloendothelial cells  
(c) Diabetes insipidus and Exophthalmos present  
(d) Foam cells seen  
(e) All are correct. *KERALA:1988*
24. **Erosion of unguis tufts in terminal phalanges of hand may be due to**  
(a) Rheumatoid arthritis  
(b) Gout  
(c) Hyperparathyroidism  
(d) Psoriasis *PGI:1988*

**25. Action of Vitamin D is**

- (a) Stimulates bone marrow
- (b) Increases calcium loss
- (c) Stimulates absorption of calcium
- (d) Stimulates osteoclasts

*UPSC.1988*

**26. Note seen in Rickets**

- (a) Cupping of ends of bones
- (b) Irritability
- (c) Craniotabes
- (d) Decreased alkaline phosphatase

**27. Which is not a feature of Osteitis fibrosa cystica?**

- (a) Fracture
- (b) Tetany
- (c) Increased serum calcium
- (d) Increased alkaline phosphatase

*ANDHRA.1989*

**28. The histopathologic feature of Paget's disease includes**

- (a) Simultaneous osteoclastic and osteoblastic activity at places
- (b) Osteoclastic resorption
- (c) Replacement of bone marrow by fibro vascular tissue
- (d) All of the above
- (e) None of the above.

*BIHAR 1989*

**29. The type of Bone changes occurs in chronic renal failure includes**

- (a) Osteomalacia
- (b) Osteosclerosis
- (c) Osteopenia
- (d) Osteitis-fibrosa
- (e) Osteonecrosis

**30. A diet deficient in calcium will most commonly result in**

- (a) Osteomalacia
- (b) Rickets
- (c) Osteoporosis
- (d) Osteitis fibrosa

*ALL INDIA.1990*

- 31. Renal Osteo dystrophy does not include**
- (a) Osteo malacia
  - (b) Osteo sclerosis
  - (c) Osteo porosis
  - (d) Osteo mylitis
- 32. Sub-Periosteal erosions of middle phalanges at the radial aspect is characteristic of**
- (a) Hypothyroidism
  - (b) Hyperthyroidism
  - (c) Hypoparathyroidism
  - (d) Hyperparathyroidism
- ANDHRA: 1993*
- 33. Rickets of vitamin D deficiency is associated with**
- (a) Subperiosteal haemorrhage
  - (b) Ricketirosary at costochondral junction produced by subluxation of sternal plate
  - (c) Apt to develop during growth in low birth weight infants
  - (d) Inorganic serum phosphate concentration 4.5–6.5 mg/dl
- 34. Metaphyseal fracture is commonly seen in**
- (a) Osteogenesis imperfecta
  - (b) Scurvy
  - (c) Rickets
  - (d) None
- DELHI: 1992*
- 35. Which of the following is useful in the treatment of Osteoporosis?**
- (a) Potassium
  - (b) Sodium chloride
  - (c) Calcium
  - (d) Phosphate
- KARNATAKA: 1992*
- 36. A Bald child with swollen abdomen, hyperosteous bones with mental retardation has**
- (a) Hypervitaminosis A
  - (b) Hypervitaminosis D

- (c) Down's syndrome
- (d) Tuberos sclerosi

**37. All are sclerosing disorders of bone except**

- (a) Osteopetrosi
- (b) Melorheostosi
- (c) Caffey's
- (d) Osteiti

*ALL INDIA: 1993*

**38. Pseudo fracture is seen in**

- (a) Pseudo parathyroidism
- (b) Hypoparathyroidism
- (c) Osteomalacia
- (d) Osteoporosi

*ORISSA : 1992*

**39. The following is a radiological feature of Skeletal Fluorosi**

- (a) Intervertebral ligament calcification
- (b) Sacral sclerosis
- (c) Osteolytic lesion in pelvis
- (d) None

*JIPMER:2000*

**40. The characteristic finding in osteomalacia is**

- (a) ↓ P
- (b) ↓ Ca
- (c) ↓ Ca & ↑ P
- (d) ↓ Ca & ↓ P

*UP : 1999*

**41. Ring sign is seen in**

- (a) Rickets
- (b) Barlow's disease
- (c) Scurvy
- (d) Fibrous dysplasia

*NIMHANS: 1999*

**42. The metabolic indicator of Rickets is**

- (a) Low serum Ca
- (b) Low  $PO_4$
- (c) ↑ Alkaline phosphatase
- (d) ↑ Urinary hydroxy proline

*NIMHANS : 1999*

43. Spina ventosa is seen in  
(a) TB  
(b) Leprosy  
(c) RA  
(d) Sarcoidosis
44. A young patient presents with enlargement of costochondral junction and with the white line of Fraenkel at the metaphysis. The diagnosis is  
(a) Scurvy  
(b) Rickets  
(c) Hyperparathyroidism  
(d) Osteomalacia *KARNATAKA: 2000*
45. Which of the following is a primary defect in Paget's disease?  
(a) Osteoblast  
(b) Osteoclast  
(c) Osteocyte  
(d) Fibroblast *NATIONAL BOARD : 2000*
46. All of the following fractures are associated with osteoporosis except  
(a) Colles' fracture  
(b) Fracture of clavicle  
(c) Vertebral fracture  
(d) Fracture neck of femur *MANIPAL: 1999*
47. Osteoporosis is characterized most commonly by  
(a) Fracture vertebra  
(b) Backache  
(c) Bowing of legs  
(d) Abdominal pain *ALL INDIA; 1994*
48. Paget's disease is also known as  
(a) Osteitis fibrosa cystica  
(b) Osteitis deformans  
(c) Osteoporosis  
(d) Osteopetrosis *PGI: 2000*

- 49. A 65-Year-old female patient presents with osteoporosis. The treatment started with**
- (a) Calcium + Oestrogen + Prosgesterone
  - (b) Oestrogen + Progestrone
  - (c) Calcium + Oestrogen
  - (d) Calcium
- UP: 2000*
- 50. Subperiosteal erosion is seen in**
- (a) Scurvy
  - (b) Hyperparathyroidism
  - (c) Hyporparathyroidism
  - (d) Rickets
- NATIONAL BOARD : 1994*
- 51. Hormone required for skeletal maturation**
- (a) Thyroid
  - (b) Testicular androgen
  - (c) Adrenal steroid
  - (d) Aldosterone
- PGI : 1994*
- 52. The cause of osteomalacia is**
- (a) Phenytoin
  - (b) Melabsorption
  - (c) Vincristine
  - (d) Cushing's syndrome
- PGI:1994*
- 53. Soft tissue calcification with hypercalcaemia is abserved in**
- (a) Hyperparathyroidism
  - (b) Alkaptonuria
  - (c) Gout
  - (d) Cushing's disease
- Bihar : 1998*
- 54. The most common site of Eosinophilic granuloma is**
- (a) Skull
  - (b) Radius
  - (c) Femur
  - (d) Lumbar vertebrae
- MP:1998*

55. The most common site of Eosinophilic granuloma is  
(a) Skull  
(b) Radius  
(c) Femur  
(d) Lumbar vertebrae *MP:1998*
56. Vitamin C deficiency leads to  
(a) Defective mineralisation  
(b) Defective Osteoid formation  
(c) Normal collagen and Bone matrix  
(d) X-ray shows normal evidence *NIMS:1998*
57. Caffey's disease is  
(a) Renal osteodystrophy  
(b) Infantile cortical hyperostosis  
(c) Osteomyelitis of jaw in children  
(d) Chronic osteomyelitis in children *PGI:1998*
58. Osteoporosis is seen in following except  
(a) Old age  
(b) Prolonged Heparin administration  
(c) Hyperthyroidism  
(d) Steroid intake.
59. All of the following statements regarding Paget's disease are correct except  
(a) Females are affected more than males  
(b) It frequently leads to Osteogenic sarcoma  
(c) Serum alkaline phosphates level is increased  
(d) All called as Osteitis deformans *MANIPAL:1997*
60. Calcitonin is used in the treatment of  
(a) Post menopausal osteoporosis  
(b) Malignant hyper calcemia  
(c) Paget's disease  
(d) All of the above. *MANIPAL:1997*



61. A 67 year old man on biochemical analysis found to have three fold rise of level of serum alkaline phosphatase that of upper limit of norm value during a routine checkup but serum calcium and phosphorous concentration and liver function test results and normal. He is asymptomatic. The probable cause is

- (a) Multiple myeloma
- (b) Paget's disease of bone
- (c) Primary hyperparathyroidism
- (d) Osteomalacia

*AIIMS:1999*

62. Vitamin required for collagen is

- (a) Vitamin A
- (b) Vitamin C
- (c) Vitamin D
- (d) Vitamin E

*PGI:1997*

63. A scooter is hit from behind. The rider is thrown off and he lands with his head hitting the kerb. He does not move, complains of severe pain in the neck and is unable to turn his head. Well-meaning onlookers rush up to him and try to make him sit up. What would be the best course of action in this situation?

- (a) He should be propped up and given some water to drink
- (b) He should not be propped up but turned on his face and rushed to the hospital
- (c) He should be turned on his back and a support should be placed behind
- (d) He should not be moved at all but carried to the nearest hospital in the same position in which he has been since his fall.

*UPSC:1997*

64. Paget's disease

- (a) Is painless
- (b) Begins as an osteoblastic
- (c) Is frequently complicated by osteogenic sarcoma

- (d) Does not affect bones singly (e.g. Only the clavicle)
- (e) Is rare under the age of forty. *BIHAR:1990*

**65. Which of the following is not true regarding Paget's disease of bone?**

- (a) Serum alkaline phosphatase is low
- (b) It frequently leads to Osteogenic sarcoma
- (c) Males are affected more than females
- (d) Involved area shows rapid formation and resorption of bone. *KERALA:1990*

**66. In Scurvy there is deficit in**

- (a) Collagen
- (b) Fibroblasts
- (c) Elastic fibres
- (d) All of the above *NATIONAL BOARD: 1990*

**67. Manifestations of Fluorosis includes**

- (a) Stiffness of back ligaments
- (b) Caries teeth (due to deficiency of fluorine)
- (c) Genu valgum
- (d) Dental changes
- (e) Stiffness of bones and tendons *PGI:1990*

**68. The most common cause of bilateral Genu valgum in our country is**

- (a) Tuberculosis
- (b) Multiple trauma
- (c) Poliomyelitis
- (d) Osteoporosis
- (e) Rickets *PGI:1990*

**69. The commonest cause of osteomalacia in our country is**

- (a) Repeated systemic infections
- (b) Idiopathic steatorrhoea
- (c) Dietetic deficiency of vitamin D and calcium
- (d) Poor protein intake
- (e) Chronic renal disease. *PGI:1990*

- 70. The most common site of fracture of the following bone in senile osteoporosis is**  
(a) Vertebra  
(b) Neck of femur  
(c) Radius  
(d) Shaft of femur *TAMIL NAU:1990*
- 71. Calcitonin is used in**  
(a) Paget's disease  
(b) Hyperparathyroidism  
(c) Osteosclerosis  
(d) Vitamin D intoxication. *AIIMS:1991*
- 72. Bony lesion in Rickets is due to**  
(a) Increased parathormone leading to osteoclastic activity  
(b) Reduced dietary calcium absorption  
(c) Phosphaturia  
(d) Increased calcium excretion *AIIMS:1991*
- 73. Action of Vitamin D is that it**  
(a) Stimulates bone marrow  
(b) Increases calcium loss  
(c) Stimulates absorption of calcium  
(d) Stimulates osteoclasts *AMC: 1991*
- 74. A patient presents with bone pains and on investigating calcium and phosphorus levels in serum were found to be normal except with elevation of serum alkaline-phosphatase. The probable diagnosis is**  
(a) Osteomalacia  
(b) Paget's disease  
(c) Osteoporosis  
(d) Hyperparathyroidism *ANDHRA:1991*
- 75. In hyperparathyroidism bone resorption is seen in all except**  
(a) Jaws  
(b) Metacarpals

- (c) Ribs
- (d) End of long bones.

*ORISSA: 1991*

**76. Multiple osteolytic lesions in a 2 year old child in skull and long bones are due to**

- (a) Neuroblastoma
- (b) Histiocytosis – X
- (c) Wilm's tumour
- (d) Multiple Myeloma
- (e) Thalassemia major

*PGI:1991*

**77. Hypercalcemia occurs in**

- (a) Multiple Myeloma
- (b) Hyperparathyroidism
- (c) Vitamin A intoxication
- (d) Ileal resection
- (e) Thiazide diuretics

*PGI:1991*

**78. Generalised osteopenia**

- (a) Scurvy
- (b) Paget's disease
- (c) Osteoporosis
- (d) Steroids
- (e) Osteogenesis imperfecta

*PGI: 1991*

**79. Osteomalacia causes include**

- (a) Phenytoin
- (b) Malabsorption
- (c) Indoor stay
- (d) Vincristine
- (e) Cushing's syndrome

*PGI:1991*

**80. Which is not true about Paget's disease of bone?**

- (a) Often there is no symptom
- (b) Alkaline phosphates is low
- (c) Thickening of bone due to widening of cortex
- (d) All of these.

- 81. Which is / are X-ray finding of infantile scurvy?**  
 (a) A dense line between metaphysis and epi physial cartilage  
 (b) A clear band of rarefaction on the diaphysial side  
 (c) Both of these  
 (d) None of these.
- 82. In nutritional rickets changes occurs at the :**  
 (a) Metaphysis  
 (b) Epiphysis  
 (c) Diaphysis  
 (d) All of these.
- 83. Which is true about Osteomalacia?**  
 (a) Alkaline phosphatase is raised  
 (b) Serum phosphate is low  
 (c) Serum calcium is low or normal  
 (d) All the above.
- 84. Osteitis fibrosa cystica is due to**  
 (a) Paget's disease of bone  
 (b) Polyostotic fibrous dysplasia  
 (c) Parathyroid adenoma  
 (d) All of the above.

## ANSWERS

- |         |         |          |         |
|---------|---------|----------|---------|
| 1. (e)  | 2. (a)  | 3. (d)   | 4. (d)  |
| 5. (c)  | 6. (c)  | 7. (b)   | 8. (d)  |
| 9. (c)  | 10. (a) | 11. (b)  | 12. (d) |
| 13. (a) | 14. (c) | 15. (d)  | 16. (d) |
| 17. (c) | 18. (a) | 19. (b)  | 20. (d) |
| 21. (d) | 22. (a) | 23. (e)  | 24. (d) |
| 25. (c) | 26. (d) | 27. (b)  | 28. (d) |
| 29. (a) | 30. (a) | 31. (bd) | 32. (d) |
| 33. (b) | 34. (a) | 35. (c)  | 36. (b) |

- |         |          |           |          |
|---------|----------|-----------|----------|
| 37. (d) | 38. (c)  | 39. (a)   | 40. (d)  |
| 41. (c) | 42. (a)  | 43. (a)   | 44. (b)  |
| 45. (b) | 46. (b)  | 47. (a)   | 48. (b)  |
| 49. (c) | 50. (b)  | 51. (b)   | 52. (b)  |
| 53. (a) | 54. (c)  | 55. (c)   | 56. (b)  |
| 57. (b) | 58. (c)  | 59. (a)   | 60. (c)  |
| 61. (b) | 62. (b)  | 63. (c)   | 64. (cd) |
| 65. (a) | 66. (a)  | 67. (ad)  | 68. (e)  |
| 69. (c) | 70. (a)  | 71. (a)   | 72. (b)  |
| 73. (c) | 74. (b)  | 75. (a)   | 76. (c)  |
| 77. (a) | 78. (cd) | 79. (abc) | 80. (ab) |
| 81. (c) | 82. (a)  | 83. (d)   | 84. (c)  |

## 7

## DISEASES OF JOINTS

### 1. HLA B27 is associated with;

- (a) Rheumatoid arthritis.
- (b) Ankylosing spondylitis.
- (c) Rheumatic arthritis.
- (d) Gouty arthritis.

*A.I.89.*

### 2. Calcification of menisci is seen in:

- (a) Hyperparathyroidism.
- (b) Pseudogout.
- (c) Renal Osteodystrophy.
- (d) Acromegaly.

*A.I.89.*

### 3. Bamboo spine is seen in;

- (a) Tuberculosis.
- (b) Rheumatoid arthritis.
- (c) Ochronosis.
- (d) Ankylosing spondylosis.

*JIPMER.88*

4. **The following is involved in Rheumatoid arthritis:**  
(a) Synovial fluid.  
(b) Synovial membrane.  
(c) Cartilage.  
(d) Subchondral bone. *UP.88*
5. **Increased density of skull vault is seen in:**  
(a) Hyperparathyroidism.  
(b) Multiple Myeloma.  
(c) Fluorosis.  
(d) Renal osteodystrophy. *PGI.90*
6. **Soft tissue calcification around the knee is seen in:**  
(a) Scurvy.  
(b) Scleroderma.  
(c) Hyperparathyroidism.  
(d) Pseudogout *PGI.90*
7. **Osteo arthrosis does not affect**  
(a) Knee joint.  
(b) Hip joint.  
(c) Interphalangeal joint.  
(d) Metacarpophalangeal joint.  
(e) Shoulder Joint. *KERALA.96*
8. **Osteo arthritis following is not a predisposing factor**  
(a) Diabetes mellitus.  
(b) Defective joint Position.  
(c) Weight bearing joints.  
(d) Incongruity of articular surfaces.  
(e) Old age. *KERALA.96*
9. **Treatment of Osteo arthritis include all except:**  
(a) Graded muscle exercises.  
(b) Replacement of articular surfaces.  
(c) Correction of deformities.  
(d) Increase the weight bearing by the affected joint.  
(e) Rest to the joint in acute phase. *KERALA.96*

10. Treatment of Rheumatoid arthritis include all except  
(a) Give rest to the joint.  
(b) Correction of deformities.  
(c) Synovectomy  
(d) Exercises.  
(e) Immuno suppressive drugs. *KERALA.96*
11. Diabetic charcot's joint affect most commonly  
(a) Knee.  
(b) Ankle.  
(c) Hip.  
(d) Foot joint. *ALL INDIA.97*
12. Disease where distal Interphalangeal joint is characteristically involved.  
(a) Psoriatic arthritis  
(b) Rheumatoid.  
(c) SLE.  
(d) Gout. *TN.99*
13. The joint commonly involved in spherulitic arthritis is  
(a) Hip  
(b) Shoulder  
(c) Wrist  
(d) Knee
14. The cause of rheumatoid arthritis is  
(a) Familial  
(b) Immunological  
(c) Infective  
(d) Traumatic *PGI 88*
15. Bleeding into joint cavities is not common in  
(a) Hemophilia.  
(b) ITP.  
(c) Christmas disease.  
(d) None of the above. *JIPMER 90*



16. Para-articular erosion are most commonly seen in  
(a) Osteoarthritis  
(b) Rheumatoid arthritis  
(c) Gout  
(d) Acute suppurative arthritis *DELHI 96*
17. Positivity of HLA B 27 in Ankylosing spondylitis  
(a) 10%  
(b) 96%  
(c) 78%  
(d) 100%. *NIIMS 96*
18. Earliest radiological sign of the Osteoarthritis is  
(a) Narrowing of joint space  
(b) Osteophyte formation  
(c) Cystic lesion in cancellous bone  
(d) Sclerosis in subchondral bone *BIHAR : 1988*
19. The early X-Ray changes of Ankylosing spondylitis would be  
(a) Disc space narrowing  
(b) Anterior osteophyte formation  
(c) Sacroiliac joint erosion  
(d) Facetal joint ankylosis *AMU,70*
20. The earliest manifestation of Alkaptonuria is  
(a) Ankylosis of lumbodorsal spine  
(b) Ochronotic arthritis  
(c) Prostatic calculi  
(d) Pigmentation of tympanic membrane  
(e) All of the above
21. Swan neck deformity is a feature of  
(a) Syphilitic arthritis  
(b) Gouty arthritis  
(c) Rheumatoid arthritis  
(d) Osteo arthritis

22. Terminal interphalangeal joints of hands are commonly involved in
- (a) Psoriatic arthropathy
  - (b) Rheumatoid arthritis
  - (c) Still's disease
  - (d) Ankylosing spondylitis
23. Charcot's joints have all of the following characteristics except
- (a) Copious effusion in the joint
  - (b) Painful limitation of joint movements
  - (c) Hypermobility of joint
  - (d) Osteophyte formation.
24. Pseudogout has crystals of
- (a) Sodium Pyrophosphate
  - (b) Monosodium urate
  - (c) Calcium Pyrophosphate
  - (d) Sodium urate.
25. In Fracture acetabulum, late complication is
- (a) Osteoarthritis
  - (b) Tardy sciatic nerve palsy
  - (c) Recurrent Dislocation
  - (d) None of the above. *DEIHI : 1994*
26. In Fracture neck of femur in old persons is best treated by
- (a) Replacement arthroplasty
  - (b) Thomas's splint support
  - (c) No treatment
  - (d) Internal fixation with SP nail *KARNATAKA:1994*
27. Congenital dislocation of hip is usually due to
- (a) Short femur neck
  - (b) Small femur head
  - (c) Displacement of capital epiphysis
  - (d) Large acetabulum *PGI 1993*

- 28. In Reiter's disease, untrue is**  
(a) Conjunctivitis  
(b) Ulcer on palm & soles  
(c) Interstitial lung disease  
(d) After sexual contact. *AIIMS 1993*
- 29. The most common arthritis that affects the wrist is**  
(a) Osteoarthritis  
(b) Tuberculous arthritis  
(c) Rheumatoid arthritis  
(d) Gout *ANDHRA: 1993*
- 30. Periosteal reaction is not common in**  
(a) Syphilis  
(b) Gout  
(c) Osteomyelitis  
(d) Tuberculous dactylitis. *ANDHRA 1993*
- 31. Hypertrophic osteoarthropathy is best observed in**  
(a) Carcinoma of lung  
(b) Mesothelioma of pleura  
(c) AVM of lung  
(d) Cirrhosis of liver *ANDHRA:1993*
- 32. Erosive arthritis is not noted in**  
(a) Amyloidosis  
(b) Hyperparathyroidism  
(c) Psoriasis  
(d) Sickle-cell disorder *ANDHRA 1993*
- 33. Joint least affected by Neuropathy**  
(a) Shoulder  
(b) Hip  
(c) Wrist  
(d) Elbow *DELHI 1993*
- 34. Haemarthrosis with prolonged bleeding time is seen in**  
(a) Haemophilia

- (b) Christmas disease
- (c) Von Willebrand's disease
- (d) All of the above.

TAMIL NADU 1929

**35. Ankylosing spondylitis the joint least commonly involved is**

- (a) Elbow
- (b) Sacroiliac
- (c) Ankle
- (d) Spinal

AIIMS: 1993

**36. All are true about gouty arthritis except**

- (a) Arthritis is manifested after long attack of hyperuricemia
- (b) There is good correlation between level of uric acid and severity of gouty arthritis
- (c) Synovial analysis is diagnostic
- (d) Allopurinol is treatment of choice in acute gout.

AIIMS: 1993

**37. All of the following are well known features of Rheumatoid arthritis except**

- (a) Bilateral hip arthritis
- (b) Erosion of distal interphalangeal joints
- (c) Pleural effusion
- (d) Hypocomplementemia

PGI: 1992

**38. Which of the following structures prevent hyperextension of hip?**

- (a) Iliofemoral ligament
- (b) Ischiofemoral ligament
- (c) Pubofemoral ligament
- (d) Puboischial ligament

AIIMS: 1994

**39. Which of the following is not characterized by bony lesions?**

- (a) Gout
- (b) Psoriasis
- (c) SLE
- (d) Rh. Arthritis

AIIMS: 1994

40. The most common cause of Neuropathic joints is
- (a) Leprosy
  - (b) Diabetes
  - (c) Rheumatoid arthritis
  - (d) Syphilis
- JIPMER:1993*
41. All of the following are well known features of Rheumatoid arthritis except
- (a) Bilateral hip arthritis
  - (b) Erosion of distal interphalangeal joints
  - (c) Pleural effusion
  - (d) Hypocomplementemia
- PGI:1992*
42. Which one of the following is not associated with HLA B27?
- (a) Ankylosing spondylitis
  - (b) Reiter's syndrome
  - (c) Sjogren's syndrome
  - (d) Psoriatic arthritis
- UPSC : 1999*
43. Tertiary syphilitic arthritis most frequently involves
- (a) Spine
  - (b) Hip
  - (c) Ankle
  - (d) Knee
- TAMIL NADU : 1999*
44. Neuropathic joint of foot and ankle is most commonly due to
- (a) CTEV
  - (b) Hansen's disease
  - (c) Polio
  - (d) Mycetoma
- TAMIL NADU: 1999*
45. Swan-neck deformity is
- (a) Flexion of Metacarpophalangeal joint and extension at interphalangeal joint
  - (b) Extension at Proximal interphalangeal joint and flexion at Distal interphalangeal joint

- (c) Flexion at proximal interphalangeal joint and extension at distal interphalangeal joint
- (d) Extension at Metacarpophalangeal joint and flexion at interphalangeal joint *NIMS: 2000*
- 46. One of the following is to be considered as differential diagnosis for foreign body in plain X-ray of knee joint:**
- (a) Fabella
- (b) Calcified bursa
- (c) Patella
- (d) Chondromatosis *NIMS: 2000*
- 47. In a gouty arthritis, the characteristic X-ray findings includes**
- (a) Osteoporosis
- (b) Erosion of joint
- (c) Soft tissue calcification
- (d) Narrowing of joint space *NIMS : 2000*
- 48. Hyperextension of PIP joints and hyperflexion of DIP joint is known as**
- (a) Trigger finger
- (b) Boutonier's deformity
- (c) Swan-neck deformity
- (d) Mallet finger *KERALA : 1999*
- 49. The most common cause of Neuropathic joint is**
- (a) Diabetes
- (b) Syphilis
- (c) Leprosy
- (d) Rheumatoid *MANIPAL: 1999*
- 50. The most commonly involved joint in pseudo gout**
- (a) Knee
- (b) Great toe
- (c) Hip
- (d) Elbow *RAJASTHAN : 1993*

**51. In a patient suffering from tabes dorsalis Charcot's joint occurs most commonly at**

- (a) Elbow
- (b) Tarsometatarsal
- (c) Wrist
- (d) Knee

*RAJASTHAN : 1993*

**52. Dissociative sensory loss occurs in**

- (a) Tuberculosis of spine
- (b) Disc prolapse
- (c) Tabes dorsalis
- (d) Syringomyelia

*TAMIL NADU : 1993*

**53. Clinical features of Gout are all except**

- (a) Chronic patient with renal complication allopurinol is drug of choice
- (b) Positive birefringent crystal in the Synovial fluid
- (c) Hyperuricemia
- (d) Mostly affects smaller joint.

*UP 1993*

**54. Pain in small joints in an elderly lady is most likely due to**

- (a) Rheumatic arthritis
- (b) Rheumatoid arthritis
- (c) Psoriatic arthritis
- (d) Reiter's disease

*UPSC : 1993*

**55. Which of the following is inflammatory arthritis?**

- (a) Rheumatoid arthritis
- (b) Osteoarthritis
- (c) Osteochondritis
- (d) All of the above.

*ALL INDIA : 1994*

**56. The most common cause of large epiphysis is**

- (a) Hemophilia
- (b) Paget's disease
- (c) Osteomalacia
- (d) Cushing's disease

*ALL INDIA:1994*



- 57. Not true about Osteogenesis imperfecta**  
(a) Impaired healing of fracture  
(b) Deafness  
(c) Laxity of joints  
(d) Fragile fracture *UP : 2000*
- 58. Neuropathic joints of ankle and foot are most commonly caused by**  
(a) Polio  
(b) Club foot  
(c) Mycetoma  
(d) Hansen's disease *TAMIL NADU: 1999*
- 59. Deforming Polyarthritis is associated with all of the following except**  
(a) Rheumatoid arthritis  
(b) Psoriatic arthritis  
(c) Behcet's syndrome  
(d) Ankylosing spondylitis *JIPMER : 1999*
- 60. A 35-Year-old businessmen presents suddenly with severe pain, swelling and redness in left big toe in early morning. Most likely diagnosis is**  
(a) Rheumatoid arthritis  
(b) Gouty arthritis  
(c) Pseudogout  
(d) Septic arthritis *PGI : 1994*
- 61. RA factor is used mainly**  
(a) Screening patients for Rheumatoid arthritis  
(b) Predicting multisystem disease  
(c) Predicting severity of disease  
(d) Monitoring treatment
- 62. Which is true about Ankylosing spondylitis?**  
(a) Sacroliac joints unusually involved  
(b) Peripheral joint is rarely involved



(c) Common manifestation in females

(d) Iritis is seen more frequently

*UP:1994*

**63. One of the following is not associated with Ankylosing spondylitis**

(a) Pain is more in the early morning period

(b) Pain is relieved in lying down position

(c) Morning stiffness more than 3 months

(d) May be associated with uveitis

*NIMS:1998*

**64. A young male presents with joint pains and backache. X-ray of spine shows evidence of sacroilitis. The most likely diagnosis is**

(a) Rheumatoid arthritis

(b) Ankylosing spondylitis

(c) Polyarticular juvenile arthritis

(d) Psoriatic arthropathy

*UPSC:1998*

**65. The most common site of primary osteoarthrosis is**

(a) Hip joint

(b) Knee joint

(c) Ankle joint

(d) Shoulder joint

*TAMIL NADU:1997*

**66. Clutton's joints are**

(a) Syphilitic joints

(b) End stage Tuberculous joints

(c) Associated with trauma

(d) Usually painful

**67. The following is the commonest cause of loose body in a joint**

(a) Osteoarthritis

(b) Osteochondral fracture

(c) Synovial chondromatosis

(d) Osteochondritis dissecans

*BIHAR:1990*

- 68. Bleeding into joint cavities is not common in**  
(a) Christmas disease  
(b) Hemophilia  
(c) ITP  
(d) None of above. *JIPMER:1990*
- 69. Arthroscopy is contraindicated in**  
(a) Chronic joint disease  
(b) Loose bodies  
(c) Haemophila  
(d) Meniscal tear *NATIONAL BOARD:1990*
- 70. A woman presented with right shoulder pin and Rheumatoid factor test came as negative, but the pain responded to the Prednisolone therapy. The diagnosis includes**  
(a) Osteopetrosis  
(b) Seronegative Rheumatoid arthritis  
(c) Polymyalgia  
(d) Polymyalgia rheumatica *NATIONAL BOARD:1990*
- 71. One of the following is true regarding Ankylosing spondylitis**  
(a) Common in females  
(b) Sacrolitis is common  
(c) Anti DNA and antinuclear antibodies are present  
(d) Symmetrical peripheral arthritis  
*NATIONAL BOARD:1990*
- 72. Which of the following agent has / have proven to be a value in treatment of Ankylosing spondylitis?**  
(a) Phenylbutazone  
(b) Intramuscular gold  
(c) Naproxen  
(d) Penicillamine *PGI:1990*
- 73. Still's disease is**  
(a) Post traumatic bone formation in the lateral ligament of the knee

- (b) Spastic diplegia
- (c) Rheumatoid arthritis in child hood
- (d) Rheumatoid arthritis in the elderly. *BIHAR:1991*

**74. Subluxation of atlanto-occipital joint is seen in all except**

- (a) Gout
- (b) Parpharyngeal abscess
- (c) Rheumatoid arthritis
- (d) Ankylosing spondylitis *DELHI:1991*

**75. Neuropathic joint may arise in**

- (a) Syringomyelia
- (b) Tabes dorsalis
- (c) Leprosy
- (d) All of the above. *NATIONAL BOARD:1991*

**76 In which of the following Polyarthritis is skin lesion least likely**

- (a) Sarcoidosis
- (b) Psoriatic arthritis
- (c) Gonococcal arthritis
- (d) Ankylosing spondylitis *PGI: 1991*

**77. All of the following drugs are used in an attack of Gout except**

- (a) Aspirin
- (b) Idomethacin
- (c) Colchicine
- (d) Phenylbutazone *AMC:1992*

**78. Sudden attack of acute pain in great toe is due to**

- (a) Rheumatoid arthritis
- (b) Gout
- (c) Rheumatic fever
- (d) Psoriatic arthritis. *ANDHRA: 1992*

79. Following are the recognized causes of Hydrarthrosis, EXCEPT:
- (a) Tuberculosis
  - (b) Charcot's joint
  - (c) Sarcoidosis
  - (d) Osteo-arthritis
80. Following are the recognized causes of Charcot's (Neuropathic) joint, EXCEPT for:
- (a) Peripheral neuritis
  - (b) Syringomyelia
  - (c) Tabes dorsalis
  - (d) Hysterical joint.
81. The treatment of choice for Ankylosing spondylitis is
- (a) Phenylbutazone
  - (b) Radiotherapy
  - (c) Steroid
  - (d) All of the above.
82. Which joint is commonly affected in Ankylosing spondylitis?
- (a) Ankle
  - (b) Knee
  - (c) Shoulder
  - (d) All of the above.
83. In Rheumatoid arthritis, which is involved?
- (a) Synovial fluid
  - (b) Sub chondral bone
  - (c) Synovial membrane
  - (d) Cartilage.
84. Severe disability in primary osteo arthritis of hip is best managed by:
- (a) Arthrodesis
  - (b) Arthroplasty
  - (c) Mc Murray's osteotomy
  - (d) Intra-articular hydrocortisone and physiotherapy.

85. Which is characteristic F/O osteo arthritis on X-ray?

- (a) Spurring
- (b) Subchondral sclerosis
- (c) Diminution of cartilage space
- (d) All of these.

86. "Gouty arthritis" usually involves first:

- (a) Ankle
- (b) Great toe
- (c) Thumb
- (d) Shoulder joint.

### ANSWERS

- |         |          |         |         |
|---------|----------|---------|---------|
| 1. (b)  | 2. (b)   | 3. (d)  | 4. (b)  |
| 5. (c)  | 6. (d)   | 7. (e)  | 8. (a)  |
| 9. (d)  | 10. (d)  | 11. (b) | 12. (a) |
| 13. (d) | 14. (b)  | 15. (b) | 16. (b) |
| 17. (b) | 18. (a)  | 19. (c) | 20. (b) |
| 21. (c) | 22. (a)  | 23. (b) | 24. (c) |
| 25. (a) | 26. (a)  | 27. (d) | 28. (c) |
| 29. (c) | 30. (b)  | 31. (a) | 32. (b) |
| 33. (a) | 34. (c)  | 35. (a) | 36. (b) |
| 37. (b) | 38. (a)  | 39. (c) | 40. (b) |
| 41. (b) | 42. (b)  | 43. (b) | 44. (b) |
| 45. (b) | 46. (d)  | 47. (b) | 48. (b) |
| 49. (a) | 50. (a)  | 51. (d) | 52. (d) |
| 53. (b) | 54. (b)  | 55. (a) | 56. (c) |
| 57. (a) | 58. (d)  | 59. (c) | 60. (b) |
| 61. (b) | 62. (bd) | 63. (b) | 64. (b) |
| 65. (b) | 66. (a)  | 67. (a) | 68. (c) |
| 69. (c) | 70. (b)  | 71. (b) | 72. (a) |
| 73. (c) | 74. (a)  | 75. (d) | 76. (d) |
| 77. (a) | 78. (b)  | 79. (c) | 80. (d) |
| 81. (a) | 82. (b)  | 83. (c) | 84. (b) |
| 85. (d) | 86. (b)  |         |         |

1. **Avascular necrosis of head of femur can occur in:**
  - (a) Sickle cell anaemia.
  - (b) Caisson's disease.
  - (c) Intracapsular fracture neck.
  - (d) Trochanteric fracture. *PGI.89*
  
2. **Avascular necrosis of head of femur can occur in:**
  - (a) Subcapital fracture.
  - (b) Intertrochanteric fracture.
  - (c) Transcervical fracture.
  - (d) Central dislocation of hip. *ALL INDIA 92*
  
3. **Avascular necrosis occurs due to fracture of**
  - (a) Medial femoral epicondyle.
  - (b) Olecranon.
  - (c) Talus.
  - (d) Fibula. *ALL INDIA.99*
  
4. **Osteocondritis dessicans occurs at**
  - (a) Lateral surface lateral condyle.
  - (b) Medial surface of lateral condyle.
  - (c) Medial surface medial condyle.
  - (d) Lateral surface medial condyle. *AIIMS 98*
  
5. **Which is true about Perthe's disease**
  - (a) Not Painful.
  - (b) It manifests at puberty.
  - (c) Involves neck of femur.
  - (d) Viral etiology. *AI 91*
  
6. **Avascular necrosis of head of femur occurs at**
  - (a) Trochanteric region.
  - (b) Transcervical region.

(c) Subchondral region

(d) Subcapital region

AIIMS 92

7. Pathological changes in Caisson's disease is due to

(a)  $N_2$

(b)  $O_2$

(c)  $CO_2$

(d) CO

8. Legg-Calve-Perthes disease is commonly seen in the age group of

(a) 1-3 years

(b) 3-10 years

(c) 10-20 years

(d) 20 years & above.

ALL INDIA:1989

9. Osgood-Schlatter disease is

(a) A traction injury of femoral epiphysis

(b) A traction injury of the posterior epiphysis of os calcis

(c) A traction injury of vertebral epiphysis

(d) A traction injury of the tibial tubercle of the tibial epiphysis

(e) None of the above is true.

10. Punched out lesion in skull with beveled edges are seen in

(a) Secondary deposits

(b) Osteomyelitis

(c) Multiple Myeloma

(d) Eosinophilic granuloma

AIIMS: 2000

11. A 5-year-old girl presents with pain in the right hip, and limp. What is the probable diagnosis?

(a) Slipped capital femoral epiphysis

(b) Tuberculosis of hip

(c) Perthes' disease

(d) CDH.

NIMS:2000

12. A Patient is using oral steroids for a period of 5 years and patient complains of pain in the both hip regions.



**Which one of the following is a diagnostic modality for confirmation of diagnosis?**

- (a) Plain X ray.
- (b) CT scan.
- (c) MRI.
- (d) Isotope Bone scan.

*NIMS:2000*

**13. Osteochondritis is not seen in – disease**

- (a) Pelligrini-Stieda.
- (b) Panner's.
- (c) Calve's.
- (d) Kohler's.

*DELHI: 1999*

**14. Osteochondritis in Osgood Schlatter disease affect which bone?**

- (a) Capitulum's.
- (b) Metatarsal.
- (c) Navicular.
- (d) Tibial tuberosity.

*UP:1993*

**15. Legg-Calve-Perthes' disease is**

- (a) Femoral epiphyseal osteochondritis.
- (b) Osteochondritis of tibial tubercle.
- (c) Slipped upper femoral epiphysis.
- (d) Spinal osteochondritis.

**16. The late radiographic changes seen in active Perthes' disease are all except**

- (a) Narrow joint space.
- (b) A widened femoral neck.
- (c) An irregular density of the epiphysis.
- (d) An irregular epiphyseal line.
- (e) A flattened head.

*NATIONAL BOARD:1990*

**17. Legg-Calves-Perthes' disease is**

- (a) Mild pyogenic arthritis.
- (b) Slipped femoral epiphysis.



- (c) Avascular necrosis of head of femur  
(d) Low grade Tuberculosis of hip *ORISSA: 1991*

- 18. The commonest cause of limp in a child of seven years is:**  
(a) T.B. hip  
(b) C.D.H.  
(c) Perthe's disease  
(d) Slipped upper femoral epiphysis.

### ANSWERS

- |            |          |         |         |
|------------|----------|---------|---------|
| 1. (a,b,c) | 2. (a,c) | 3. (c)  | 4. (d)  |
| 5. (b)     | 6. (b)   | 7. (a)  | 8. (b)  |
| 9. (d)     | 10. (c)  | 11. (c) | 12. (d) |
| 13. (a)    | 14. (d)  | 15. (a) | 16. (a) |
| 17. (c)    | 18. (c)  |         |         |

## 9

### TUMOURS OF BONE

- 1. Commonest benign tumour of the bone is:**  
(a) Osteoma.  
(b) Osteochondroma.  
(c) Osteoid osteoma.  
(d) Chondroma *A.I.88*
- 2. Sunray appearance is seen in:**  
(a) Osteogenic sarcoma.  
(b) Ewing's Sarcoma.  
(c) Multiple myeloma.  
(d) Osteoclastoma. *A.I.89*
- 3. Tumour most sensitive to Radiotherapy is:**  
(a) Osteogenic sarcoma.  
(b) Ewing's sarcoma.

- (c) Chondrosarcoma.  
(d) Osteoclastoma A.I.87
- 4. Osteogenic sarcoma metastasizes commonly to:**  
(a) Liver.  
(b) Lung.  
(c) Brain.  
(d) Regional lymphnodes. UPSC 87
- 5. In Carcinoma prostate with metastasis which is raised:**  
(a) ESR.  
(b) Alkaline phosphatase.  
(c) Acid phosphatase.  
(d) Bilirubin TN.89
- 6. Which of the following arises from epiphysis:**  
(a) Osteosarcoma.  
(b) Ewing's sarcoma.  
(c) Osteoclastoma.  
(d) Multiple Myeloma. TN.89
- 7. In multiple myeloma which of the following is seen;**  
(a) Raised serum calcium.  
(b) Raised alkaline phosphatase.  
(c) Raised acid phosphatase.  
(d) All KERALA.90
- 8. Commonest tumour arising from the metaphysis is;**  
(a) Osteoclastoma.  
(b) Osteosarcoma.  
(c) Ewing's sarcoma.  
(d) Synovial sarcoma. KERALA.89
- 9. Treatment of solitary bone cyst is;**  
(a) Curettage.  
(b) Excision.  
(c) Curettage and bone grafting.  
(d) Irradiation. PGI.90

10. **Physalipharous cells (Large vacuolated cells) on Histo-pathology are characteristic of;**
- (a) Osteosarcoma.
  - (b) Osteoclastoma.
  - (c) Liposarcoma.
  - (d) Chondrosarcoma.
  - (e) Chordoma.
- JIPMER'78, AMU'84*
11. **Vertical striations on vertebral bodies are seen in**
- (a) Hemangioma.
  - (b) Pagets disease.
  - (c) Vertebral metastasis.
  - (d) Osteoporosis.
- JIPMER.95*
12. **Most reliable method for detecting bony metastases is;**
- (a) MRI
  - (b) CT Scan
  - (c) Radiography
  - (d) SPECT.
- JIPMER'95*
13. **True statement regarding osteogenic sarcoma is**
- (a) Affects middle aged people.
  - (b) X-Ray shows honey combing
  - (c) Can be a complication of Paget's disease of bone.
  - (d) All of the above.
- PAL'96*
14. **Commonest benign tumour under 21 years of age;**
- (a) Aneurysmal bone cyst.
  - (b) Osteochondroma
  - (c) Gaint Cell Tumour.
  - (d) Osteoid osteoma
- PAL'96*
15. **A boy presenting with swelling at lower end femur with calcified, nodular shadow in lung has;**
- (a) Osteosarcoma.
  - (b) Osteochondroma
  - (c) Tuberculosis femur lower end.
  - (d) Osteomyelitis.
- AIIMS.96*

16. In an 8-year-old child the least common cause of lytic bone lesion in proximal femur.  
(a) Plasmacytoma.  
(b) Histiocytoma.  
(c) Metastasis.  
(d) Brown tumour. *All MS.97*
17. Most Common lesion of hand is  
(a) Enchondroma.  
(b) Synovioma .  
(c) Exostosis.  
(d) Osteoclastoma. *All MS'97*
18. Rare site of metastasis in bone  
(a) Skull.  
(b) Spine.  
(c) Upper end of humerus.  
(d) Below elbow and knee. *TN'99*
19. A 8 year old child has a swelling in diaphysis of femur. Histology reveals, small clear round symmetrical cells, minimum cytoplasm, necrotic areas, and minimum osteoid and chondroid material cells. Most likely, it contains.  
(a) Mucin.  
(b) Lipid.  
(c) Iron  
(d) Glycogen *AIIMS.2K*
20. Most reliable method for detecting bony metastases is;  
(a) MRI  
(b) CT Scan  
(c) Radiography  
(d) SPECT. *JIPMER'2K*
21. Ivory osteoma commonly arises in the:  
(a) Skull.  
(b) Ribs.

(c) Pelvis.

(d) Vertebra

*UPSC 86, NIMHANS 86*

**22. Osteoblastic secondaries can arise from:**

(a) Carcinoma Prostate.

(b) Thyroid Carcinoma.

(c) Renal Carcinoma.

(d) Breast carcinoma.

*UPSC.85, AP.85*

**23. Enchondroma commonly arises from:**

(a) Ribs.

(b) Vertebra.

(c) Tibia.

(d) Phalanges.

*AMU 88*

**24. Osteogenic sarcoma can develop in:**

(a) Osteoblastoma.

(b) Pagets diseases.

(c) osteoid osteoma.

(d) All of the above.

*AMU 88*

**25. The treatment of enchondroma is:**

(a) Amputation.

(b) Irradiation.

(c) Local excision.

(d) Curettage and bone chip filling

*AMU 88*

**26. Onion peel appearance in X-ray suggests:**

(a) Osteogenic sarcoma.

(b) Ewing's sarcoma.

(c) Osteoclastoma.

(d) Chondrosarcoma

**27. Commonest site of a bone cyst:**

(a) Upper end of humerus.

(b) Lower end of tibia.

(c) Lower end of femur

(d) Upper end of femur

28. **Commonest site for osteogenic sarcoma is:**  
(a) Upper end of femur.  
(b) Lower end of femur.  
(c) Upper end of tibia.  
(d) Lower end of tibia.
29. **Kachrumal, a 46 year old man has expansive growth metaphysis with endosteal scalloping & dense punctate calcification. Most likely bone tumour is**  
(a) Osteosarcoma  
(b) Chondrosarcoma  
(c) Osteoclastoma  
(d) Osteoid osteoma *AI 2002*
30. **A 70 year old lady presented with mild low back pain tenderness in L3 vertebra. On examination Hb 8 gm ESR 110mg/1hr A/G ratio of 2:4, likely diagnosis is**  
(a) Waldenstroms  
(b) Multiple myeloma  
(c) Bone secondaries  
(d) None *AIIMS 2001*
31. **Age group of osteogenic sarcoma is**  
(a) 1-10  
(b) 10-20  
(c) 20-30  
(d) 30-40 *JIPMER 90*
32. **The lytic lesion in the epiphysis in children is seen in**  
(a) Osteogenic sarcoma  
(b) Osteoclastoma  
(c) Aneurysmal bone cyst  
(d) Chondroblastoma *AI 91*
33. **Pain in thigh more at night relieved by aspirin is**  
(a) Steosarcoma  
(b) Osteoclastoma

- (c) Ewings tumour
- (d) Osteoid osteoma

*KERALA 94*

**34. Bone tumour metastatising to bone is**

- (a) Giant Cell Tumour
- (b) Ewing's Sarcoma
- (c) Chondro Sarcoma
- (d) OsteoSarcoma

*KERALA 94*

**35. Osteoclastoma is common in age group of**

- (a) Below 10 years
- (b) 10-20 years
- (c) All age groups
- (d) 20-40 years

*KARN 94*

**36. Bone Cysts most commonly occur in**

- (a) Spine
- (b) Humerus
- (c) Femur
- (d) Tibia

*PGI 93*

**37. The most confirmatory test for myeloma is**

- (a) Aspiration of the lesion and histology
- (b) Bence-Jones protein in urine
- (c) Serum electrophoresis
- (d) Technitium 99 radionuclide bone scan

*AIIMS 80, BHU 87*

**38. On microscopic examination, suspected Giant Cell tumour must be differentiated from**

- (a) Osteosarcoma
- (b) Osteoid Osteoma
- (c) Both of the above
- (d) None of the above.

*BHU.1988*

**39. Ewing's tumour of bone**

- (a) Should be locally excised
- (b) Should be treated by immediate amputation

- (c) Looks like a cut onion on X-ray.  
(d) Has a soap-bubble appearance on X-ray.  
(e) None of the above is correct. *BIHAR 1988*
- 40. The most common Primary Malignant bone tumour is**  
(a) Osteoclastoma.  
(b) Ewing's sarcoma.  
(c) Osteogenic sarcoma.  
(d) Osteogenic sarcoma. *BIHAR.1988*
- 41. Osteoclastoma shows**  
(a) Expansile osteolytic area in the diaphysis.  
(b) Expansile osteolytic area in the epiphysis.  
(c) Osteosclerotic area in the metaphysis.  
(d) Osteolytic area in the metaphysis. *PGL.1988*
- 42. Ewing's sarcoma can be confused histologically with**  
(a) Myeloma.  
(b) Osteosarcoma.  
(c) Osteomyelitis.  
(d) Giant Cell tumour. *ROHTAK:1988*
- 43. A child has smooth tender swelling at lower end of knee for 6 months. On X-ray examination there is new bone formation but no joint involvement, diagnosis is:**  
(a) Osteosarcoma  
(b) Osteoclastoma  
(c) Arthritis followed by residual osteomyelitis  
(d) Chronic osteomyelitis  
(e) Any of the above. *AMC 1989*
- 44. Ewing's tumour is not associated with**  
(a) Sunray appearance  
(b) Pus like material on aspiration  
(c) Diaphysis involvement  
(d) Mottled appearance of bone marrow. *ANDHRA,1989*



45. Osteoclastoma characteristically involves  
(a) Hip joint.  
(b) Fibula lower end.  
(c) Tibia lower end.  
(d) Radius lower end. *BIHAR.1989*
46. The most common site of enchondroma is  
(a) Ribs.  
(b) Phalanges.  
(c) Clavicle.  
(d) Sternum. *DELHI.1989*
47. Ewing's tumour of bone  
(a) Is a giant cell tumour.  
(b) Is also a secondary deposit from a ganglioneruoma.  
(c) Usually occurs in middle age.  
(d) Is characterized by subperiosteal new bone formation, which gives the appearance of 'onion peel'.  
(e) Can be treated satisfactorily by resection and the insertion of prosthesis.
48. The common mode of presentation of a case of Solitary Bone Cyst is  
(a) Pain.  
(b) Fracture.  
(c) Inflammation.  
(d) Expansion of the involved area. *ROHTAK:1989*
49. Regarding Fibrosarcoma  
(a) It has predilection for femur and tibia.  
(b) Amputation is the answer to this.  
(c) X-ray shows moth eaten appearance about a lytic area  
(d) All of the are true.  
(e) None of the above is true. *ROHTAK.1989*
50. The most common Bone tumour is  
(a) Osteosarcoma.  
(b) Osteoclastoma.

- (c) Secondaries.  
(d) Multiple myeloma. *TAMIL NADU.1989*
- 51. Very poor prognosis of Osteosarcomas because these are**  
(a) Highly malignant tumours.  
(b) Inoperable usually.  
(c) Metastasize to lung very fastly.  
(d) Resistant to radiotherapy. *TAMIL NADU.1989*
- 52. Treatment of Fibrosarcoma is**  
(a) Surgery (wide excision).  
(b) Surgery + Radiotherapy.  
(c) Chemotherapy.  
(d) Surgery + Chemotherapy. *AIIMS:1990*
- 53. Pain in thigh more at night relieved by aspirin is**  
(a) Ewing's tumour.  
(b) Osteosarcoma.  
(c) Osteoid osteoma.  
(d) Osteoclastoma. *KERALA.1994.*
- 54. Osteosarcoma of distal femur is best treated by**  
(a) Amputation.  
(b) Disarticulation at hip.  
(c) Chemotherapy.  
(d) Radiotherapy. *ANDHRA.1994*
- 55. Tumour not arising from cartilage is**  
(a) Enchondroma.  
(b) Chondrosarcoma.  
(c) Osteoblastoma.  
(d) Osteochondroma. *PGI.1993*
- 56. Osteosarcoma differentiated from Myositis ossificans by radiology**  
(a) Location.  
(b) Infection is cause.  
(c) Shape of swelling.  
(d) Peripheral field of differentiation. *JIPMER:1993*

57. The most common cause of Neuropathic joints is
- (a) Leprosy.
  - (b) Diabetes.
  - (c) Rheumatoid arthritis.
  - (d) Syphilis.
- JIPMER:1993*
58. In tumour surgery, wide resection means;
- (a) Shelling out through pseudocapsule of tumour
  - (b) En block resection with a cuff of normal tissue
  - (c) Extra-compartmental En block resection
  - (d) None of the above.
- KARNATAKA.1993*
59. Ewing's sarcoma is treated by
- (a) Excision and filing with bone
  - (b) Surgery + Radiogharapy
  - (c) Surgery + Chemotherapy
  - (d) Whole bone irradiation + Chemotherapy.
- ANDHRA 1993*
60. The most common tumour that involves bone is
- (a) Giant Cell tumour
  - (b) Chondrosarcoma
  - (c) Multiple myeloma
  - (d) Metastatic tumour from extraosseous site.
- ANDHRA.1993.*
61. All of the following lesions arise from metaphysis, except.
- (a) Osteogenic sarcoma
  - (b) Osteoblastoma
  - (c) Condromyxoid fibroma
  - (d) Gaint cell tumour.
- ANDHRA 1993*
62. Chondroblast belongs to
- (a) Labile cells
  - (b) Permanent cells
  - (c) Stable cells
  - (d) All of the above.
- ANDHRA.1993.*

63. Osseus metastasis is most common if tumour is in  
(a) Bronchus  
(b) Colon  
(c) Pancreas  
(d) Adrenal *Delhi:1993*
64. Which is a diaphyseal bone tumour  
(a) Giant Cell tumour  
(b) Osteosarcoma  
(c) Fibrosarcoma  
(d) Osteoid Osteoma *UPSC:1992*
65. The most common site of Multiple myeloma is  
(a) Skull  
(b) Humerus  
(c) Pelvis  
(d) Vertebrae *ORISSA:1992*
66. The tumour associated with Hormonal abnormalities is  
(a) Fibrosarcoma  
(b) Chondrosarcoma  
(c) Osteosarcoma  
(d) Fibrous dysplasia *PGI:1992*
67. Treatment of Osteoclastoma of lower end of radius in early stage is  
(a) Bone curettage and filling  
(b) Amputation  
(c) Radiotherapy  
(d) Conservative *RAJASTAN: 1992*
68. Diagnostic investigation for bone tumours is  
(a) FNAC  
(b) Frozen section biopsy  
(c) Incisional biopsy  
(d) C.T.Scan. *DELHI:1992*

- 69. Soap bubble appearance is seen in**  
(a) Ewing's sarcoma  
(b) Osteoid osteoma  
(c) Osteoclastoma  
(d) Osteo sarcoma *DELHI:1992*
- 70. The most common primary malignant tumour of the bone is**  
(a) Osteogenic sarcoma  
(b) Ewing's sarcoma  
(c) Osteoclastoma  
(d) Fibro sarcoma *NIIMS:1992*
- 71. The treatment of choice for Enchondroma is**  
(a) Excision  
(b) Amputation  
(c) Curettage and bone grafting  
(d) Radiotherapy *ORISSA:1992*
- 72. Which is true about Osteosarcoma?**  
(a) It is due to osteoclast  
(b) It occurs in fifth to sixth decade  
(c) Lymphatic spread common  
(d) Sunray appearance is due to new bone formation. *AIIMS:2000*
- 73. The radiological diagnosis of Ewing's sarcoma includes**  
(a) Onion skin  
(b) Sun-ray  
(c) Soap bubble  
(d) Calcification *ANDHRA:2000*
- 74. Chondroblastoma invariably involves**  
(a) Epiphysis  
(b) Diaphysis  
(c) Metaphysis  
(d) Flat bones *ALL INDIA:2000*

75. **Adamantinoma of limb bones are most frequently found in the**  
(a) Humerus  
(b) Femur  
(c) Tibia  
(d) Radius *ALL INDIA: 2000*
76. **Which of the following is not associated with Multiple Myeloma**  
(a) Punched out lesions in the skull  
(b) Amyloid deposition in the joints  
(c) Aseptic necrosis of femoral head  
(d) Metastatic calcification *ALL INDIA: 2000*
77. **Which of the following is true regarding aneurismal bone cyst?**  
(a) More common after the age of 50 years  
(b) More common in vertebra  
(c) Characteristically elliptical in long bones  
(d) Due to atherosclerosis *ALL INDIA: 2000*
78. **Osteotropic Secondaries are all except**  
(a) Carcinoma lung  
(b) Carcinoma prostate  
(c) Multiple Myeloma  
(d) Carcinoma breast *ALL INDIA: 2000*
79. **Calcification is found in**  
(a) Chondroblastoma  
(b) Osteoclastoma  
(c) Chondrosarcoma  
(d) Osteosarcoma *ALL INDIA: 2000*
80. **The most common presentation of unicameral bone cyst is**  
(a) Asymptomatic  
(b) Infection  
(c) Swelling  
(d) Fracture through cyst *ALL INDIA: 2000*

- 81. Radiological feature of Ewing's sarcoma least mimics to all except**  
(a) Rheumatoid arthritis  
(b) Osteomyelitis  
(c) Osteogenic sarcoma  
(d) Reticulum sarcoma *ALL INDIA: 2000*
- 82. In multiple Myeloma main light chain defect lies in**  
(a) IgA  
(b) IgD  
(c) IgG  
(d) IgM *UP:1999*
- 83. Which is the rare site of metastasis in bone:**  
(a) Skull  
(b) Upper end of humerus  
(c) Spine  
(d) Below elbow & knee *TAMIL NADU:1999*
- 84. The most common site of Osteogenic sarcoma is**  
(a) Ribs  
(b) Distal end of femur  
(c) Proximal end of humerus  
(d) Distal end of tibia *TAMIL NADU: 1999*
- 85. Aneurysmal bone cyst is**  
(a) More common after the age of 50 years old  
(b) Most commonly affects vertebra  
(c) Due to atherosclerosis  
(d) Characteristically looks elliptical in long bones. *TAMIL NADU: 1999*
- 86. Acute Osteomyelitis resembles which primary bone tumour?**  
(a) Ewing's tumour  
(b) Osteochondroma  
(c) Osteosarcoma  
(d) Chondroma *TAMIL NADU 1999*



**87. Which of the following is a wrong statement regarding Chondrosarcoma?**

- (a) This tumour occurs mainly between the ages of 20 and 60 years
- (b) It can present as secondary malignant change in Paget's disease
- (c) High-grade tumours shows poorly differentiated cartilaginous pattern with anaplastic cells.
- (d) Central lesions having a better prognosis

*NIMS. 2000*

**88. All are true about Osteoid osteoma except**

- (a) Malignant conversion is not uncommon
- (b) They cause night pain which is relieved by aspirin
- (c) Commonly seen in females
- (d) Double density seen in X-ray

*KERALA: 1999.*

**89. Which of the following tumour arises from Metaphysis?**

- (a) Chondrosarcoma
- (b) Osteosarcoma
- (c) Ewing's sarcoma
- (d) Osteoclastoma

*MANIPAL: 1999*

**90. X-ray appearance of Ewing's sarcoma resembles**

- (a) Acute osteomyelitis
- (b) Eosinophilic granuloma
- (c) Neuroblastoma
- (d) Osteogenic sarcoma

*JIPMER: 1999*

**91. All are true regarding Ewing's tumour of bone except**

- (a) Arises from Endothelial cells in the bone marrow
- (b) Onion peel appearance on X-ray
- (c) Radiotherapy is the treatment of choice
- (d) Forms a differential diagnosis for osteomyelitis

**92. In bony metastasis, primary should be looked for in all except**

- (a) Prostate



- (b) Thyroid
- (c) Stomach
- (d) Bronchus

**93. Ewing's sarcoma can be confused histologically with**

- (a) Myeloma
- (b) Osteosarcoma
- (c) Osteomyelitis
- (d) Giant Cell Tumour

*UP: 1993*

**94. The most common site of Chondroblastoma is**

- (a) Diaphysis
- (b) Epiphysis
- (c) Soft tissue
- (d) Metaphysis

*UP: 1993*

**95. Osteoblastic Secondaries are seen in all except**

- (a) Carcinoma prostate
- (b) Carcinoma breast
- (c) Carcinoma thyroid
- (d) Multiple Myeloma

*ALL INDIA: 1994*

**96. The most common site for bone cyst is**

- (a) Lower end of femur
- (b) Upper end of humerus
- (c) Radius
- (d) Lower as such

*ALL INDIA: 1994*

**97. A 5-year-old child presents with swelling in the arm. X-ray shows circumferential growth in the mid shaft of humerus. The probable diagnosis is**

- (a) Osteogenic sarcoma
- (b) Ewing's sarcoma
- (c) Chondro sarcoma
- (d) Osteomyelitis

*NIIMS, 2000*

**98. Which of the following is wrong about Ewing's sarcoma?**

- (a) It is diaphyseal in origin
- (b) Rosette shaped cellular pattern is seen

- (c) 5-10% are Associated with chromosomal translocation  
(d) It is radio resistant tumour *PGI: 2000*

**99. 8-year-old child presents with one-year back fracture neck of humerus and X-ray reveals cystic lesion.**

**The probable diagnosis is**

- (a) Osteoclastoma  
(b) Osteogenic sarcoma  
(c) Osteomyelitis  
(d) Unicameral bone cyst *UP: 2000*

**100. A 10-year-old boy presented with pain and massive swelling left thigh. On examination reveals diaphyseal lesion and soft tissue swelling. The likely diagnosis is**

- (a) Osteosarcoma  
(b) Ewing's sarcoma  
(c) Osteoclastoma  
(d) Aneurysmal bony cyst. *AIIMS: NOV.2000*

**101. All of the following features are characteristic of Osteoclastoma, except**

- (a) Pathological fracture  
(b) Predilection for the female sex  
(c) Recurrence following local removal  
(d) 'Sun-ray' spicules on X-ray

**102. Bones most commonly involved in metastasis in carcinoma prostate is**

- (a) Skull  
(b) Sternum  
(c) Pelvis  
(d) Ribs *National Board : 1994*

**103. About unicameral bone cyst, true is**

- (a) Spongy tissue inside cyst  
(b) Fibrous septa  
(c) Bony septa  
(d) Angiomatous malformation

104. Sclerosis of vertebral end plates can occur in following except  
(a) Sarcoidosis  
(b) Osteoporosis  
(c) Rheumatoid arthritis  
(d) Healing Osteomalacia *RAJASTHAN : 1994*
105. The most common malignant bone tumour in 5-15 years age group is  
(a) Fibrosarcoma  
(b) Osteosarcoma  
(c) Osteoma  
(d) Osteochondroma *UP:1994*
106. Osteochondroma is commonly seen in  
(a) Ribs  
(b) Scapula  
(c) Epiphysis  
(d) Metaphysis in femur *UP:1994*
107. The majority of giant cell tumours (Osteoclastoma) of bone are anatomically located in the  
(a) Vertebrae  
(b) Small bones of hand and foot  
(c) Proximal humerus and proximal femur  
(d) Proximal tibia and distal femur *BIHAR : 1998*
108. The most common mode of metastasis in osteogenic sarcoma  
(a) Lymphatic  
(b) Subperiosteal spread  
(c) Transcortical  
(d) Haematogenous *JIPMER:1998*
109. Presence of Bence Jones Proteins is found in  
(a) Eosinophilic granuloma of bone  
(b) Alkaptonuria

(c) Multiple Myeloma of bone

(d) Osteogenic sarcoma

*KARNATAKA:1998*

**110. A child presented with upper leg swelling with pulmonary nodule. The most probable diagnosis is**

(a) Osteosarcoma

(b) Osteoclastoma

(c) Chondroblastoma

(d) Chondrosarcoma

*MP:1998*

**111. Giant cell tumour of bone (Osteoclastoma) is radiologically characterized by**

(a) Expansive osteolytic lesion

(b) Onion peel appearance

(c) Stippled osteoporosis

(d) Periosteal new bone formation and codmantriangle formation.

**112. Aneurysmal bone cysts**

(a) Are true aneurysms of nutrient arteries

(b) Occur only in flat bones

(c) Are the same as osseous haemangiomas

(d) Manifest as osteolytic lesions

*UPSC:1998*

**113. Which of the following is not true about Ewing's sarcoma?**

(a) Usually diaphyseal

(b) Periosteal thickening appears as onion peel appearance

(c) Egg shell crackling present

(d) Radiosensitive

*DELHI: 1997*

**114. All of the following statements regarding Osteosarcoma is true except**

(a) Spreads by lymphatics

(b) Arises from metaphysis

(c) Arises in Paget's diseases of bone

(d) Alkaline phosphate levels are increased.

*MANIPAL:1997*

- 115. A 65-year-old man presents with backache and urinary retention. The next line of investigation is**
- (a) Acid phosphatase
  - (b) Alkaline phosphatase
  - (c) Urodynamics
  - (d) Ultrasonography
- AIIMS:1999*
- 116. The most common site of osteoblastoma is**
- (a) Diaphysis
  - (b) Metaphysis
  - (c) Epiphysis
  - (d) B or C
- PGI:1997*
- 117. Giant cell tumour**
- (a) Periarticular epiphyseal in origin
  - (b) Never recurs after excision
  - (c) Malignant potential not predicted
  - (d) All of the above.
- PGI:1997*
- 118. Expansile growth arising from the end of long bone after epiphyseal closure is**
- (a) Aneurysmal bone cyst
  - (b) Simple bone cyst
  - (c) Osteosarcoma
  - (d) Giant cell tumour
  - (e) All of these.
- BIHAR:1990*
- 119. Clean-cut multiple, rounded lesions in bone are seen in**
- (a) Eosinophilic granuloma
  - (b) Multiple myeloma
  - (c) Letterer Siewe disease
  - (d) All of these
  - (e) None of these.
- BIHAR:1990*
- 120. Treatment of choice for Giant Cell Tumour is**
- (a) Surgery + Radiotherapy
  - (b) Local excision

- (c) Chemotherapy  
(d) Radiotherapy *DELHI:1990*
- 121. Age group of Osteogenic sarcoma is**  
(a) 20-30  
(b) 1-10  
(c) 30-40  
(d) 10-20 *JIPMER:1990*
- 122. Which of the following bone tumour presents with pain first and swelling later on?**  
(a) Osteoma  
(b) Osteoclastoma  
(c) Chondroma  
(d) Osteosarcoma  
(e) Ewings's tumour *NATIONAL BOARD:1990*
- 123. Which of the following is common site of bone cyst?**  
(a) Humerus  
(b) Femur  
(c) Fibula  
(d) Pelvis *NATIONAL BOARD: 1990*
- 124. The preferred treatment for unicameral bone cyst is**  
(a) X ray therapy  
(b) Surgical exposure and collapse of cavity  
(c) Surgical curettage and bone graft  
(d) Create a fracture and allow healing.  
*NATIONAL BOARD:1990*
- 125. Treatment of Ewing's sarcoma is by**  
(a) Chemotherapy  
(b) Radical excision  
(c) Radiotherapy  
(d) Immunotherapy *NATIONAL BOARD:1990*
- 126. Alkaline phosphatase is raised in**  
(a) Osteoclastoma

- (b) Osteosarcoma
  - (c) Chondrosarcoma
  - (d) Multiple myeloma
- NATIONAL BOARD:1990

**127. Tumour arising from Diaphysis is**

- (a) Osteoclastoma
  - (b) Multiple myeloma
  - (c) Osteosarcoma
  - (d) Ewing's sarcoma
- ORISSA:1990*

**128. Which of the following regions is most commonly involved in skeletal tuberculosis?**

- (a) Spine
  - (b) Hip
  - (c) Knee
  - (d) Ankle
  - (e) Elbow
- PGI:1990*

**129. Presently the best treatment for Osteosarcoma of tibia is**

- (a) Radiotherapy
  - (b) Amputation followed by local radiation
  - (c) Chemotherapy
  - (d) En block resection and reconstruction
  - (e) Amputation followed by chemotherapy.
- PGI:1990*

**130. Osteogenic sarcoma usually occurs in the following age group**

- (a) Below 15 years
- (b) Between 16 to 25 years
- (c) Between 26 to 40 years
- (d) Between 41 to 60 years

**131. Skeletal radiological survey of a 50 years old patient shows multiple lytic areas in the skeleton. Most likely diagnosis is**

- (a) Multiple pyemic abscesses

- (b) Paget's disease  
(c) Multiple Myeloma  
(d) Multiple neurofibromatosis  
(e) Multiple enchondromatosis *ORISSA:1990*
- 132. The most important feature of severance of median nerve at the elbow is**  
(a) Wasting of hypothenar muscles  
(b) Wasting of thenar eminence  
(c) Paralysis of flexor of index finger  
(d) Paralysis of flexors of wrist  
(e) Anaesthesia of radial 3.25 fingers. *ORISSA:1990*
- 133. Solitary bone cyst is treated by**  
(a) Curettage  
(b) Excision  
(c) Curettage and bone grafting  
(d) Irradiation *TAMIL NADU:1990*
- 134. A lytic lesion in the epiphysis of a long bone of a child is likely to be**  
(a) Osteoclastoma  
(b) Chondroblastoma  
(c) Aneurysmal bone cyst  
(d) Brodie's abscess *ALL INDIA;1991*
- 135. Bony metastasis is seen in all except**  
(a) Carcinoma thyroid  
(b) Carcinoma bronchus  
(c) Carcinoma breast  
(d) Cystosarcoma phylloides *AIIMS:1991*
- 136. Regarding osteoid osteoma**  
(a) Most commonly seen in patient between 10 and 25 years old.  
(b) Slightly more common in males  
(c) Usually occurs in long bones (tibia)



- (d) Most commonly involved bones being the femur  
(e) All of the above. *BIHAR:1991*

**137. The most common site of appearance of osteoma is**

- (a) Skull  
(b) Forearm  
(c) Pelvis  
(d) Hands and feet  
(e) Any of the above. *BIHAR:1991*

**138. Codman's triangle is found in cases of**

- (a) Osteoclastoma  
(b) Baker's cyst  
(c) Osteosarcoma  
(d) Ewing's tumour only  
(e) Any of the above. *BIHAR:1991*

**139. Treatment of Giant Cell Tumour of upper end of fibula is**

- (a) Amputation  
(b) Excision of upper end of fibula  
(c) Curettage with grafting  
(d) Radiation *NIMS: 1991*

**140. Fibrosarcoma**

- (a) Similar to Giant cell tumour on X-ray  
(b) Patchy opacity in X ray (Osteolytic lesion)  
(c) Osteoblastic lesion  
(d) Soap and bubble appearance  
(e) Associated endocrine abnormalities *PGI: 1991*

**141. Following one is a diaphyseal tumour**

- (a) Osteosarcoma  
(b) Synovial sarcoma  
(c) Osteoclastoma  
(d) Ewing's sarcoma *RAJASTHAN: 1991*

- 142. Initial treatment of choice for Giant Cell Tumour of bone is**
- (a) Curettage and bone grating
  - (b) Bone grafting
  - (c) Amputation
  - (d) Radiotherapy
- UPSC: 1991*
- 143. Which of the following occurs late in the course of Multiple Myeloma?**
- (a) M-Spike
  - (b) Renal failure
  - (c) Bony lytic lesions
  - (d) Increased alkaline phosphates
- AIIMS: 1992*
- 144. Ewing's tumour is**
- (a) Radiosensitive
  - (b) Radioresistant
  - (c) Radiosensitive but recurrent
  - (d) Radiocurable
- ANDHRA : 1992*
- 145. Osteogenic sarcoma most commonly arises from the :**
- (a) Epiphysis
  - (b) Metaphysis
  - (c) Diaphysis
  - (d) All of these.
- 146. Osteoclastoma arises from**
- (a) Epiphysis
  - (b) Metaphysis
  - (c) Diaphysis
  - (d) Femur
- 147. A define radiological feature of a bone sarcoma is the:**
- (a) Sun ray appearance
  - (b) Codman's triangle
  - (c) Presence of soft tissue shadow in the skiagram
  - (d) All of the above.

- 148. "Soap-bubble appearance" of X-ray picture is characteristic of:**
- (a) Osteoma
  - (b) Osteogenic sarcoma
  - (c) Ewing's tumour
  - (d) Osteoclastoma.
- 149. Among the following bone tumour, which is most radiosensitive?**
- (a) Osteoma
  - (b) Osteogenic sarcoma
  - (c) Ewing's tumour
  - (d) Osteoclastoma
- 150. The commonest site of chondrosarcoma is**
- (a) Ribs
  - (b) Pelvis
  - (c) Radius & humerus
  - (d) None of these.
- 151. Following are true regarding Osteosarcoma EXCEPT:**
- (a) Commonest sites are the lower end of the femur
  - (b) Codman's triangle is present
  - (c) Tumour occurs at Metaphysis
  - (d) Tumour usually metastasise by lymphatic rout
- 152. Which of the following has got best prognosis?**
- (a) Osteogenic sarcoma
  - (b) Ewing's sarcoma
  - (c) Chondrosarcoma
  - (d) Chordoma
- 153. The treatment of choice for multiple Myeloma is**
- (a) Surgery
  - (b) Radiotherapy
  - (c) Hormone
  - (d) All the above.

154. Which is not associated with multiple Myeloma?  
(a) Amyloid deposition in the joints  
(b) Metastatic calcification  
(c) Punched out lesions in the skull  
(d) Septic necrosis of femoral head.
155. Enchondroma should be treated by  
(a) Irradiation  
(b) Amputation  
(c) Local excision  
(d) Curettage and bone chips grafting.
156. Adamantinoma of limb bones are most frequently found in the  
(a) Ulna  
(b) Radius  
(c) Femur  
(d) Tibia
157. Chondrosarcoma arising in long bones occurs most frequently in the:  
(a) Tibia  
(b) Femur  
(c) Humerus  
(d) Radius only.
158. All the following are true about osteoclastoma, EXCEPT  
(a) Commonest site is lower end of femur  
(b) Commonly occurs in young adult  
(c) Soap bubble appearance is seen in X-ray  
(d) Never recur after local removal..

**ANSWERS**

- |         |         |         |         |
|---------|---------|---------|---------|
| 1. (b)  | 2. (a)  | 3. (b)  | 4. (b)  |
| 5. (b)  | 6. (b)  | 7. (c)  | 8. (b)  |
| 9. (c)  | 10. (e) | 11. (a) | 12. (d) |
| 13. (c) | 14. (b) | 15. (a) | 16. (a) |

|          |          |          |          |
|----------|----------|----------|----------|
| 17. (a)  | 18. (d)  | 19. (d)  | 20. (d)  |
| 21. (a)  | 22. (a)  | 23. (d)  | 24. (b)  |
| 25. (d)  | 26. (b)  | 27. (a)  | 28. (b)  |
| 29. (b)  | 30. (b)  | 31. (d)  | 32. (b)  |
| 33. (d)  | 34. (b)  | 35. (d)  | 36. (b)  |
| 37. (c)  | 38. (d)  | 39. (c)  | 40. (c)  |
| 41. (b)  | 42. (c)  | 43. (a)  | 44. (d)  |
| 45. (d)  | 46. (b)  | 47. (d)  | 48. (b)  |
| 49. (b)  | 50. (c)  | 51. (a)  | 52. (a)  |
| 53. (c)  | 54. (b)  | 55. (c)  | 56. (d)  |
| 57. (b)  | 58. (c)  | 59. (b)  | 60. (d)  |
| 61. (d)  | 62. (a)  | 63. (a)  | 64. (d)  |
| 65. (d)  | 66. (d)  | 67. (a)  | 68. (c)  |
| 69. (c)  | 70. (a)  | 71. (c)  | 72. (d)  |
| 73. (a)  | 74. (a)  | 75. (c)  | 76. (d)  |
| 77. (c)  | 78. (c)  | 79. (c)  | 80. (a)  |
| 81. (b)  | 82. (d)  | 83. (d)  | 84. (b)  |
| 85. (d)  | 86. (a)  | 87. (d)  | 88. (a)  |
| 89. (b)  | 90. (a)  | 91. (a)  | 92. (c)  |
| 93. (c)  | 94. (b)  | 95. (d)  | 96. (b)  |
| 97. (b)  | 98. (d)  | 99. (d)  | 100. (b) |
| 101. (d) | 102. (c) | 103. (c) | 104. (b) |
| 105. (b) | 106. (d) | 107. (d) | 108. (d) |
| 109. (c) | 110. (a) | 111. (a) | 112. (d) |
| 113. (c) | 114. (a) | 115. (a) | 116. (c) |
| 117. (a) | 118. (d) | 119. (b) | 120. (b) |
| 121. (d) | 122. (a) | 123. (a) | 124. (c) |
| 125. (c) | 126. (b) | 127. (d) | 128. (a) |
| 129. (b) | 130. (a) | 131. (c) | 132. (c) |
| 133. (c) | 134. (b) | 135. (d) | 136. (e) |
| 137. (a) | 138. (c) | 139. (b) | 140. (e) |
| 141. (d) | 142. (a) | 143. (b) | 144. (a) |
| 145. (b) | 146. (a) | 147. (a) | 148. (d) |
| 149. (c) | 150. (b) | 151. (d) | 152. (c) |
| 153. (b) | 154. (d) | 155. (d) | 156. (d) |
| 157. (b) | 158. (d) |          |          |

**1. Claw hand is seen in**

- (a) Ulnar nerve injury
- (b) Carpal tunnel syndrome
- (c) Syringomyelia
- (d) Cervical rib

*PDI 85, Kerala 88, JIPMER 86, AIIMS 85*

**2. Total Claw hand is caused by injury to**

- (a) Radial Nerve
- (b) Ulnar and Radial Nerve
- (c) Ulnar and Medial nerve
- (d) Radial and Median Nerve

*ALL INDIA 93*

**3. Polio paralysis differs from paralysis due to other causes**

- (a) Weakness
- (b) Deformity of limbs
- (c) No sensory loss
- (d) Full recovery is possible

*KARNATAKA 94*

**4. Foot drop is seen in**

- (a) Tibial nerve injury
- (b) Achilles tendon injury
- (c) Popliteal nerve injury
- (d) Common peroneal nerve injury

*DELHI.1988*

**5. The most common cause of pressure sore in the foot in India is**

- (a) Leprosy
- (b) Thorn prick
- (c) Diabetes
- (d) Syringomyelia

*KERALA.1988*

**6. Polio paralysis differs from paralysis due to other causes**

- (a) Weakness of muscles

- (b) Deformity of limbs
- (c) No sensory loss
- (d) Full recovery is possible.

*KARNATAKA:1994*

**7. Club foot is commoner among**

- (a) Males
- (b) Binovular twins
- (c) Females
- (d) Uniovular twins

*RAJASTAN:1992*

**8. Which of the following statement is wrong in Tendon transfer?**

- (a) Contracture should be released priorly
- (b) Synergistic muscles are used for tendon transfer
- (c) Adequate tendon should be mobilized to gain length
- (d) All of the above

*NIMS: 2000*

**9. Which of the following is not true about Myositis ossificans?**

- (a) Associated with muscle tendon rupture
- (b) Inflammation around the ruptured muscle deposition of hydroxyapatite crystals with
- (c) Common in supracondylar fracture
- (d) Ossification of musculo-periosteal haematoma.

*PGI : 2000*

**10. Tendon transfer in a 3 year old boy of poliomyelitis is done**

- (a) Within 6 months of wound healing
- (b) After 2 years
- (c) Within 6 months of wound healing
- (d) After 6-12 months.

**11. The most common site of ivory osteoma (Compact osteoma) is**

- (a) Pelvis
- (b) Mandible

- (c) Skull
- (d) Vertebrae

*BIHAR:1999*

**12. The basic pathology in Myositis Ossificans Progressiva is in**

- (a) Muscle fibres
- (b) Serum chemistry
- (c) Body collagen
- (d) None of the above

*NATIONAL BOARD:1990*

**13. Upper motor neuron type paralysis is seen in**

- (a) Poliomyelitis
- (b) Peripheral neuropathy
- (c) Cerebral palsy
- (d) Muscular dystrophy
- (e) Paraplegia due to L2 fractures dislocation.

*PGI:1990*

**14. Hypercalcemia is caused by all except**

- (a) Multiple Myeloma
- (b) Hyperparathyroidism
- (c) Sarcoidosis
- (d) Myositis ossificans progressiva

*AIIMS:1991*

**ANSWERS**

- |         |         |         |         |
|---------|---------|---------|---------|
| 1. (a)  | 2. (c)  | 3. (c)  | 4. (d)  |
| 5. (c)  | 6. (c)  | 7. (a)  | 8. (b)  |
| 9. (a)  | 10. (b) | 11. (c) | 12. (a) |
| 13. (c) | 14. (d) |         |         |



1. Dupuytren's contracture is;
  - (a) Thickening of palmar fascia.
  - (b) Base of little finger involved first.
  - (c) Seen in cirrhotics.
  - (d) Seen in epileptics on hydantoin.
  - (e) All of the above.

*A.I.88*
2. Dupuytren's contracture is fibrosis of
  - (a) Palmar fascia
  - (b) Forearm muscles
  - (c) Sartorius fascia
  - (d) None of the above

*KARNAT 96*
3. After L4-L5 or L5-S1 the next commonest site of Intervertebral disc prolapse is
  - (a) C7, T1
  - (b) T12, L1
  - (c) L1 L2
  - (d) L2 L2
4. Osteophytes developing at the joint at Luscka characteristically compresses spinal nerves at
  - (a) Intervertebral foramen
  - (b) Anterior part of body
  - (c) Posterior part of body
  - (d) Paradural areas

*NIMS 96*
5. Carrying angle is decreased in
  - (a) Cubitus varus
  - (b) Cubitus valgus
  - (c) Genu valgum
  - (d) Genu varum

*A.P.97*

- 6. The nerve involved in Carpal tunnel syndrome is**
- (a) Ulnar
  - (b) Radial
  - (c) Median
  - (d) Anterior cutaneous nerve.
- 7. The level of the constricting nodule in case of a Trigger finger is at**
- (a) Neck of the corresponding metacarpal bone
  - (b) Metacarpophalangeal joint
  - (c) Proximal interphalangeal joint
  - (d) Distal interphalangeal joint
- 8. True about Dupuytren's contracture**
- (a) Slight preponderance in males
  - (b) Slight preponderance in females
  - (c) Much more common in males
  - (d) Much more common in females *DELHI : 1994*
- 9. Thoracic Kyphosis in children is most often due to**
- (a) Traumatic
  - (b) Pott's spine
  - (c) Congenital
  - (d) Normal *DELHI:1994*
- 10. The best treatment for Dupuytren's contracture is**
- (a) Fasciotomy
  - (b) Fasciectomy
  - (c) Incision and release
  - (d) Fasciectomy + Skin transplantation. *ANDHRA 1994*
- 11. Tinel's sign is positive in**
- (a) Peripheral nerve regeneration
  - (b) Tendon injury
  - (c) Tenosynovitis
  - (d) Rheumatoid arthritis *ANDHRA:1994*

12. All of the following are true about Duchenne muscular dystrophy, except
- (a) Both sexes are affected
  - (b) Pseudohypertrophy
  - (c) Hereditary
  - (d) Death in second decade. *ANDHRA:1994*
13. The most common cause of scoliosis in children is
- (a) Hemivertebrae
  - (b) Unequal limb length
  - (c) Post poliomyelitis
  - (d) Marfan's syndrome *JIPMER:1993*
14. The least common cause of brachial neuralgia is
- (a) Cervical spondylosis
  - (b) Pancoast tumour
  - (c) Cervical rib
  - (d) Tietze's syndrome *ANDHRA 1993*
15. The thoracic outlet syndrome may be produced by all the following except
- (a) Cervical rib
  - (b) Scalenus anticus syndrome
  - (c) Costoclavicular compression
  - (d) Raynaud's disease
  - (e) Hyperabduction syndrome *NIMS: 1992*
16. Phalen's test is positive in
- (a) Carpal tunnel syndrome
  - (b) De Quervain's disease
  - (c) Tennis elbow
  - (d) Ulnar bursitis
17. Cervical spondylosis is more common at
- (a) C<sub>1</sub>-C<sub>2</sub>
  - (b) C<sub>2</sub>-C<sub>3</sub>
  - (c) C<sub>6</sub>-C<sub>7</sub>
  - (d) C<sub>4</sub>-C<sub>5</sub>

18. Which of the following movements are restricted in Frozen shoulder?  
(a) Abduction & Internal rotation  
(b) Adduction & external rotation  
(c) All range of movements  
(d) Only abduction *ANDHRA: 2000*
19. Consider the following statements about Carpal tunnel syndrome
1. It may occur in Acromegaly
  2. It may occur in pregnancy
  3. It causes delayed ulnar nerve conduction
  4. It may be associated with wasting of abductor pollicis brevis
- of these statements  
(a) 1,2 and 3 are correct  
(b) 2,3 and 4 are correct  
(c) 1,2 and 4 are correct  
(d) 1,3 and 4 are correct. *UPSC:1999*
20. Which one of the following is a correct statement regarding idiopathic Scoliosis?  
(a) Lateral curvature of spine  
(b) Curvature in antero-posterior direction  
(c) Curvature in postero-anterior direction  
(d) Curvature in diagonal direction.
21. In de Quervain's disease the following tendons are involved  
(a) Abductor pollicis longus + Extensor pollicis brevis  
(b) Abductor pollicis brevis + Extensor pollicis longus  
(c) Adductor pollicis brevis + Extensor pollicis longus  
(d) Extensor pollicis longus + Flexor pollicis longus *NIMS:2000*
22. In cervical spondylosis which part of vertebral body involved  
(a) Inferior articular facet

- (b) Pars interarticularis
- (c) Superior articular facet
- (d) All of the above.

*DELHI: 1999*

**23. In carpal tunnel syndrome, features are of**

- (a) Compression of ulnar nerve
- (b) Compression of median nerve under the flexor retinaculum
- (c) Anaesthesia over thenar eminence
- (d) Atrophy of hypothenar muscles

*JIPMER : 1999*

**24 The following structure is involved in Dupuytren's contracture**

- (a) Thickening of the palmar fascia
- (b) Thickening of the dorsal fascia
- (c) Contracture of the flexor tendons
- (d) Post burns contracture

*ALL INDIA : 1994*

**25 Trigger finger is**

- (a) A feature of carpal tunnel syndrome
- (b) Injury to fingers while operating a gun
- (c) Stenosis tenovaginitis of flexor tendon or affected finger
- (d) Any of the above.

*NATIONAL BOARD : 2000*

**26 Cervical spondylosis**

- (a) Most frequently results from an incidence of acute trauma
- (b) Causes compression of nerve roots to produce an upper motor neuron lesion in the lower limbs
- (b) Produces pain and Parasthesia over the lateral aspect of the forearm and thumb when affecting the 6<sup>th</sup> cervical nerve
- (b) Most frequently affects the upper cervical vertebrae.

*BIHAR : 1998*

**27. Dupuytren's contracture is seen in**

- (a) Colles' fracture
- (b) Thickening of plamar fascia

- (c) Radial nerve palsy  
(d) Supracondylar fracture of humerus *PGI:1998*
- 28. Trigger finger occurs in**  
(a) Rheumatoid arthritis  
(b) Trauma  
(c) Osteosarcoma  
(d) Osteoarthritis *PGI:1998*
- 29. Carrying angle is decreased in**  
(a) Cubitus varus  
(b) Cubitus valgus  
(c) Genu varum  
(d) Genu valgum *ANDHRA: 1997*
- 30. In Children, fracture neck of femur is best treated by**  
(a) Plaster in abduction  
(b) Closed reduction (Internal fixation)  
(c) Plaster in adduction  
(d) Traction *DELHI:1990*
- 31. True dislocations of spine are commonest in the**  
(a) Lumbo sacral junction  
(b) Mid lumbar region  
(c) Cervical region  
(d) Dorso lumbar junction *DELHI:1990*
- 32. Painful arc syndrome is due to**  
(a) Fracture of greater tubercle of humerus  
(b) Chronic supraspinatus tendonitis  
(c) Subacromial bursitis  
(d) All of the above. *JIPMER:1990*
- 33. The most common deformity in club foot is**  
(a) Equinus  
(b) Equino valgus  
(c) Equino varus  
(d) Calcaneo valgus *ORISSA:1990*

34. Trigger finger is due to  
(a) Tenovaginitis  
(b) Synovitis  
(c) Bursitis  
(d) Fibrositis *ORISSA:1990*
35. Gradual painful limitation of shoulder movements in an elderly suggest that the most probable diagnosis is  
(a) Arthritis  
(b) Osteoarthritis  
(c) Periarthritis  
(d) Myositis Ossificans  
(e) Fracture – dislocation *ORISSA:1990*
36. Adson's test is performed in  
(a) Scalenus anticus syndrome  
(b) Cervical Rib  
(c) Both of these  
(d) None of these *BIHAR: 1991*
37. Which nerve is involved in carpal tunnel syndrome?  
(a) Ulnar nerve  
(b) Radial nerve  
(c) Median nerve  
(d) Posterior cutaneous nerve of the forearm. *BIHAR:1991*
38. Dupuytren's Contracture of the hand commonly starts in  
(a) Thumbs  
(b) Index finger  
(c) Middle finger  
(d) Ring finger  
(e) Little finger only. *BIHAR:1991*
39. Dislocation of spine is commonest at  
(a) C<sub>5</sub>-C<sub>6</sub>  
(b) C<sub>6</sub>-C<sub>7</sub>



- (b) D<sub>12</sub>-L<sub>1</sub>
- (c) L<sub>4</sub>-L<sub>5</sub>
- (d) All of these.

BIHAR: 1991

**40. Trigger finger is caused by**

- (a) Rheumatoid arthritis
- (b) Tenosynovitis
- (c) Colles' fracture
- (d) Osteoarthritis

Delhi: 1991

**41. The most common form of Scoliosis is**

- (a) Idiopathic scoliosis
- (b) Congenital scoliosis
- (c) Paralytic scoliosis
- (d) Postural scoliosis

ANDHRA : 1992

**42. Cubitus valgus may actually predispose \_\_\_\_\_ to become stretched or exposed unduly to trauma.**

- (a) radial nerve
- (b) median nerve
- (c) ulnar nerve
- (d) All of these.

**43. Regarding carrying angle, which is correct?**

- (a) It is about 10° in male
- (b) It is about 20° in female
- (c) The carrying angle in male is always greater than female
- (d) Only a and b.

**44. Tennis elbow is:**

- (a) Olecranon bursitis
- (b) Pain over the medial epicondyle
- (c) Pain over the lateral epicondyle
- (d) Myositis ossificans.

**45. Finkelstein's test is associated with**

- (a) Dequervains disease
- (b) Dupuytren's Contracture



- (c) Carpal tunnel syndrome
- (d) Any of the above.

**46. Which movement at shoulder gets restricted when supraspinatous torn?**

- (a) Flexion
- (b) Adduction
- (c) Abduction
- (d) Rotation only.

### ANSWERS

- |         |         |           |         |
|---------|---------|-----------|---------|
| 1. (e)  | 2. (a)  | 3. (None) | 4. (a)  |
| 5. (a)  | 6. (c)  | 7. (b)    | 8. (c)  |
| 9. (c)  | 10. (c) | 11. (a)   | 12. (a) |
| 13. (c) | 14. (d) | 15. (d)   | 16. (a) |
| 17. (c) | 18. (b) | 19. (c)   | 20. (a) |
| 21. (a) | 22. (a) | 23. (b,c) | 24. (a) |
| 25. (c) | 26. (c) | 27. (b)   | 28. (a) |
| 29. (a) | 30. (b) | 31. (c)   | 32. (b) |
| 33. (c) | 34. (a) | 35. (c)   | 36. (a) |
| 37. (c) | 38. (d) | 39. (a)   | 40. (b) |
| 41. (a) | 42. (c) | 43. (d)   | 44. (c) |
| 45. (a) | 46. (c) |           |         |

1. **Commonest cause of loose bodies in joints;**
  - (a) Tuberculous tenosynovitis.
  - (b) Rheumatoid arthritis.
  - (c) Osteo arthritis.
  - (d) Osteochondritis descicans. *A.I.88*
  
2. **Traction injury to epiphyses of the vertebra is known as;**
  - (a) Osgood Schlatter's disease.
  - (b) Sinding Larsen disease
  - (c) Scheurmann's disease.
  - (d) Severe's disease. *JIPMER'8*
  
3. **Commonest site of Disc prolapse is**
  - (a) C5-C6.
  - (b) T8-T9.
  - (c) L4-L5.
  - (d) L5-S1. *KERALA.90*
  
4. **The following is true of spondylolisthesis**
  - (a) Slipping of S1 over L5.
  - (b) Posterior arch defect.
  - (c) Congenital defect.
  - (d) More in pregnancy *PGI.90*
  
5. **Recurrent dislocation of patella in an adolescent could be treated by**
  - (a) Patellectomy.
  - (b) Excision arthroplasty.
  - (c) Puttiplat operation.
  - (d) Lateral release *PGI.82*

**6. Causes of painful limb are all except**

- (a) Perthe's disease.
- (b) Congenital Coxa vara.
- (c) Slipped femoral epiphysis.
- (d) TB hip.

*ALL INDIA.95*

**7. In Hallux valgus surgery, the patients who are likely to be most satisfied are;**

- (a) Those with pain.
- (b) Those with hammertoe.
- (c) Those with metatarsus primus varus.
- (d) Young age.

*AIIMS.95*

**8. Slipped femoral epiphysis is comonly seen in the**

- (a) 1<sup>st</sup> decade
- (b) 2<sup>nd</sup> decade
- (c) 3<sup>rd</sup> decade
- (d) 4<sup>th</sup> decade

*A.I.88*

**9. Rocker bottom foot results from**

- (a) Congenital vertical talus.
- (b) Poliomyelitis
- (c) Club foot over correction
- (d) Spina bifida

*PDI 88*

**10. Coxa vara is found in**

- (a) Perthe's disease
- (b) Tuberculosis
- (c) Rickets
- (d) Rheumatoid arthritis

*PGI 86*

**11. Idiopathic scoliosis is**

- (a) A lateral curvature of the spine
- (b) Rotation of the spine
- (c) Lateral curvature with rotation of the spine
- (d) Flexion deformity of the spine

*BIHAR.1988.*

12. The most common site of Disc prolapse is
- $L_2-L_3$
  - $L_3-L_4$
  - $L_4-L_5$
  - $L_5-S_1$
- DELHI.1988*
13. The most common site for Prolapse of intervertebral Disc is
- Cervical region
  - Lower thoracic region
  - Upper thoracic region
  - Lumbar region
- ORISSA:1988*
14. Plantar fasciitis
- is not associated with infection else where in the body
  - is caused by a bony spur on the plantar surface of the OS calcis
  - can be relieved by supplying insoles
  - is a type of Dupuytren's disease.
- JIPMER:1989*
15. The most common cause of quadriceps femoris fibrosis is
- Arthrogryposis
  - Trauma
  - Repeated injections
  - Chronic osteomyelitis of femur
- ANDHRA.1989*
16. Common vertebral level of spondylolisthesis is
- $L_{4-5}$
  - $L_{3-4}$
  - $L_{1-2}$
  - $T_{12-L_1}$
  - $L_5-S_1$
- BIHAR.1989*
17. After  $L_4-S_{11}$  the next commonest site of intervertebral disc prolapse is
- $C_6-C_7$

- (b) T<sub>12</sub>-L<sub>1</sub>
- (c) L<sub>1</sub>-L<sub>2</sub>
- (d) L<sub>2</sub>-L<sub>3</sub>
- (e) L<sub>4</sub>-L<sub>5</sub>

**18. Narrow lumbar canal syndrome**

- (a) Associated with neurological claudication
- (b) Causes pain on rotation of spine
- (c) Can be diagnosed only by Myelography
- (d) May lead to spastic paraplegia
- (e) Occurs due to congenital vertebral anomaly.

*PGI:1969*

**19. The most important single special investigation in lumbar disc prolapse is**

- (a) Epidurography
- (b) Myelography
- (c) MRI
- (d) Discography
- (e) Spinal venography

*NATIONAL BOARD: 1992*

**20. Known factors for idiopathic scoliosis is**

- (a) Unknown
- (b) Polio
- (c) Postural
- (d) Congenital

*DELHI: 1992*

**21. Hallux valgus means**

- (a) Outward deviation of great toe
- (b) Inward deviation of great toe
- (c) Outward deviation of fifth toe
- (d) Inward deviation of fifth toe

*ANDHRA : 2000*

**22. All are true of Dupuytren's contracture except**

- (a) Usually 4<sup>th</sup> finger is involved
- (b) Bilateral disease is rare
- (c) Surgical release is useful
- (d) May be associated with Pyronie disease

*PGI: 1999*

23. Which sign is positive in de Quervain's disease?  
(a) Phalen's sign  
(b) Froment's sign  
(c) Cozen's sign  
(d) Finkelstein's sign *MANIPAL : 2000*
24. Which one of the following is a correct statement regarding idiopathic scoliosis?  
(a) Lateral curvature of spine  
(b) Curvature in antero-posterior direction  
(c) Curvature in postero-anterior direction  
(d) Curvature diagonal direction *NIMS : 2000*
25. Milwaukee brace is used for  
(a) Club foot  
(b) Spondylolisthesis  
(c) Scoliosis  
(d) Knock knee *DELHI: 1999*
26. Rocker bottom feet deformity is caused by  
(a) Vertical talus  
(b) Prolonged immobilization in plaster and over correction of club feet deformity  
(c) Over correction of Gracis operation  
(d) Poliomyelitis
27. Hallux valgus is associated with all except  
(a) An exostosis on the medial side of the head of the first metatarsal  
(b) A bunion  
(c) Osteo arthritis of the metatarsophalangeal joint  
(d) Over-riding or under-riding of the second toe by the third. *PGI: Dec - 2000*
28. Abnormally high patella is associated with  
(a) Nail patella syndrome  
(b) Rupture of quadriceps tendon

- (c) Recurrent dislocation
- (d) Fracture through patella

*UP : 1999*

**30. Rocker Bottom foot occurs in**

- (a) Hallux valgus
- (b) Hallux rigidus
- (c) Copngenital vertical talus
- (d) Congenital club foot

*KARNATAKA : 1999*

**31. Management in case of rupture of disc at L5, S1 is**

- (a) Emergency removal of disc
- (b) Joint fusion
- (c) Immobilization for 2 weeks with spinal back
- (d) Traction

**32. Which one of the following statement regarding bow-leg is correct**

- (a) Physiologically corrected
- (b) Surgery is required as early as possible
- (c) It is a progressive deformity
- (d) Idiopathic variety is rarest type

*ANDHRA : 1998*

**33. Commonest cause of scoliosis is**

- (a) Idiopathic
- (b) Traumatic
- (c) Congenital
- (d) Tuberculosis.

*ANDHRA : 1998*

**34. In spondylolisthesis, there is fracture of vertebra in**

- (a) Spinous process
- (b) Neural arch pars inter articularis
- (c) Transverse process
- (d) Body

*BIHAR : 1998*

**35. Cobb's angle is measured for**

- (a) Lordosis
- (b) Lateral flexion
- (c) Kyphosis
- (d) Scoliosis

*UP:1998*



- 36. Rocker bottom foot is due to**  
(a) Congenital  
(b) Over correction of club foot  
(c) Absent navicular bone  
(d) Flacid medial longitudinal arch *ANDHR:1999*
- 37. The most common cause of acute sciatica is due to**  
(a) Trauma  
(b) Secondaries of spine  
(c) Acute prolapsed Intervertebral disc  
(d) Tuberculosis of spine *ANDHRA: 1999*
- 38. The carpal tunnel syndrome usually occurs in**  
(a) Cushing's disease  
(b) Addison's disease  
(c) Acromegaly  
(d) All of the above *BIHAR:1999*
- 39. In cervical rib following are seen except**  
(a) Atrophy of muscles  
(b) Cervical rib palpable  
(c) Ischaemic pain of muscles  
(d) Radial pulse not palpable *PGI:1997*
- 40. Slipped femoral epiphysis**  
(a) Tends to occur in overweight boy between 10-18 years  
(b) Is fortunately a unilateral condition  
(c) Is a forward and anterior slip  
(d) May be sudden or slow  
(e) Is confirmed by a lateral X-ray of the hip  
*NATIONAL BOARD:1990*
- 41. Fibrositis is commonest in**  
(a) Tendocalcaneus  
(b) Sternocleidomastoid  
(c) Trapezius  
(d) Serratus anterior *NATIONAL BOARD:1990*



42. The primary defect in flat foot is the following  
(a) Weakness of short plantar ligament  
(b) Collapse of lateral longitudinal arch  
(c) Collapse of medial longitudinal arch  
(d) Shortening of plantar aponeurosis *ORISSIA:1990*
43. A building contractor suddenly complains of lower backache which increase on bending down He has  
(a) Renal colic  
(b) Tuberculosis of spine  
(c) Disc prolapsed  
(d) Fibrositis' *UPSC:1990*
44. Which of the following cysts is medially situated?  
(a) Housemaid's knee  
(b) Clergyman' knee  
(c) Bursa anserine  
(d) Semimembranosus bursitis  
(e) Marrant Baker's cyst *NATIONAL BOARD:1991*
45. True about spondylolisthesis is / are  
(a) Congenital defect of posterior arch  
(b) Slipping of L5 over S1  
(c) Progressive slipping  
(d) Abnormal congenital development  
(e) Commonest in cervical region. *PG I: 1991*
46. Which of the following causes kyphosis?  
(a) Ankylosing spondylitis  
(b) T.B. of spinal column  
(c) Scheuerman's osteochondritis  
(d) All of the above.

|                |
|----------------|
| <b>ANSWERS</b> |
|----------------|

- |        |        |        |        |
|--------|--------|--------|--------|
| 1. (c) | 2. (c) | 3. (c) | 4. (b) |
| 5. (d) | 6. (b) | 7. (d) | 8. (b) |

- |         |          |         |           |
|---------|----------|---------|-----------|
| 9. (ac) | 10. (a)  | 11. (c) | 12. (c)   |
| 13. (d) | 14. (c)  | 15. (c) | 16. (a)   |
| 17. (a) | 18. (a)  | 19. (c) | 20. (a)   |
| 21. (a) | 22. (b)  | 23. (d) | 24. (a)   |
| 25. (c) | 26. (ab) | 27. (a) | 28. (c)   |
| 29. (a) | 30. (c)  | 31. (c) | 32. (a)   |
| 33. (a) | 34. (b)  | 35. (c) | 36. (b)   |
| 37. (c) | 38. (c)  | 39. (d) | 40. (ade) |
| 41. (c) | 42. (c)  | 43. (c) | 44. (abc) |
| 45. (d) |          |         |           |

# 13

## ADVANCES IN ORTHOPAEDIC SURGERY APPENDICES IN ORTHOPAEDICS

### 1. Formula of dry Plaster of Paris is

- (a)  $\text{CaSO}_4 \cdot \frac{1}{2} \text{H}_2\text{O}$
- (b)  $\text{CaSO}_4$  only
- (c)  $\text{CaSO}_4 \cdot 2\text{H}_2\text{O}$
- (d)  $\text{CaSO}_4 \cdot 5\text{H}_2\text{O}$
- (e)  $\text{MgSO}_4 \cdot 2\text{H}_2\text{O}$

BIHAR.1989

### 2. The best bone graft is

- (a) Allograft
- (b) Autograft
- (c) Deproteinised graft
- (d) Demineralised graft

### 3. Treatment of choice for fracture shaft femur in children

- (a) Gallows or Russell's traction
- (b) Internal fixation
- (c) Kuntscher nail
- (d) Thomas splint

### 4. Bone chip grafts are used in

- (a) Osteotomy

- (b) In Arthrodesis  
(c) Arthroplasty  
(d) Pseudoarthrosis  
(e) Filling gap after removal of tumour. *PGI: 1991*

## ANSWERS

1. (a)                      2. (b)                      3. (a)                      4. (b,e,d)

# 14

## INJURIES TO BONES AND JOINTS

- 1. Myositis ossificans is most common around the ..... joint**

(a) Knee.  
(b) Elbow.  
(c) Wrist.  
(d) Hip
- 2. The most important sign in Volkmann's ischaemic contracture is;**

(a) Pain.  
(b) Pallor.  
(c) Numbness.  
(d) Obliteration of radial pulse. *TN.90*
- 3. Treatment of Acute Myositis Ossificans is**

(a) Active mobilization.  
(b) Passive mobilization.  
(c) Infra Red Therapy.  
(d) Immobilization. *AIIMS.91*
- 4. Which fracture in children requires open reduction:**

(a) Fracture tibial epiphysis.

- (b) Fracture shaft of femur
- (c) Fracture both bones forearm.
- (d) Fracture femoral condyle AIIMS.91

**5. Volkmann's ischaemic contracture mostly involves**

- (a) Flexor digitorum superficialis.
- (b) Pronator teres
- (c) Flexor digitorum profundus.
- (d) Flexor carpi radialis longus AIIMS.92

**6. The most important factor in fracture healing is;**

- (a) Good alignment.
- (b) Organisation of blood clot.
- (c) Accurate reduction and 100% apposition of fractured fragments.
- (d) Immobilisation.
- (e) Adequate calcium intake. ROHTAK.89

**7. A Lady presents with a History of fracture radius, which was put on plaster of Paris cast for 4 weeks. After that she developed swelling of hands with shiny skin. What is the most likely diagnosis?**

- (a) Rupture of extensor pollicis longus tendon.
- (b) Myositis ossificans
- (c) Reflex sympathetic dystrophy.
- (d) Malunion AIIMS.2K

**8. Which among the following benefits from cervical sympathectomy**

- (a) Sudeck's dystrophy
- (b) Compound palmar ganglion
- (c) Osteoarthritis of first MCP joint
- (d) De quervain's tenosynovitis AIIMS 99

**9. In Volkman's ischemia, surgery should be done;**

- (a) Immediately.
- (b) After 6 hours.

- (c) 24 hours
- (d) 72 hours.

*AMU 87*

**10. The treatment of choice in pathological fractures is**

- (a) Internal fixation
- (b) Plaster of Paris casts
- (c) Skin traction
- (d) External skeletal fixation.

*BIHAR 1988*

**11. Volkmann's Ischaemic contracture is due to**

- (a) Arterial injury
- (b) Venous injury
- (c) Nerve injury
- (d) Increase of compartment pressure in the limb.

*KARNATAKA:1988*

**12. Earliest Ischaemic feature after reduction of Supracondylar fracture is**

- (a) Coldness
- (b) Pain
- (c) Swelling
- (d) Tingling

*ANDHRA.1989*

**13. The time necessary for healing of fracture depends on the following factors**

- (a) Age of the patient
- (b) Location of the fracture
- (c) Type of the fracture
- (d) Degree of damage to soft tissues
- (e) All of the above.

*NB:1989*

**14. The most important factor in fracture healing is**

- (a) Good alignment
- (b) Organisation of blood clot
- (c) Accurate reduction and 100% apposition of fractured fragments
- (d) Immobilisation
- (e) Adequate calcium intake.

15. The most common cause of anterior compartment syndrome is
- (a) Fractures
  - (b) Post ischaemic swelling
  - (c) Superficial injury to muscles
  - (d) Operative trauma. *PGI:1993*
16. Earliest symptom of Volkmann's Ischaemic is
- (a) Pain in flexor muscles
  - (b) Absence of pulse
  - (c) Pain on passive extension
  - (d) Cyanosis of limb *JIPMER:1993*
17. Fat Embolism occurs in
- (a) Hyperlipidemia
  - (b) Diabetes mellitus
  - (c) Castor oil intake
  - (d) Fracture femur *ANDHRA:1993*
18. Earliest sign of Volkmann's Ischaemia is
- (a) Pallor distally
  - (b) Numbness
  - (c) Pain
  - (d) Parasthesia *ORISSA:1992*
19. All of the following are indications for open reduction and internal fixation of fractures except
- (a) Compound fracture
  - (b) Unsatisfactory closed reduction
  - (c) Multiple trauma
  - (d) Intra-articular fracture *CSE ; 2000*
20. A 4 year old female brought to casualty department with multiple fracture ribs, and inconspicuous history from parents. On examination show multiple bruise and healed fractures. The provable diagnosis is
- (a) Polytrauma for evaluation

- (b) Flail chest
- (c) Munchausen's syndrome
- (d) Battered baby syndrome

*NIMS : 2000*

**21. After an operation on femur bone, chest X-ray shows widespread mottling throughout the lung field like a snowstorm. It is diagnostic of**

- (a) Fat embolism
- (b) Shock lung
- (c) Bronchopneumonia
- (d) Atelectasis

*CSE:1999*

**22. Sudeck's atrophy is associated with**

- (a) Osteoporosis
- (b) Osteophyte formation
- (c) Osteopenia
- (d) Osteochondritis

*DELHI 1999*

**23. Last step in fracture healing is**

- (a) Haematoma
- (b) Callus formation
- (c) Remodelling
- (d) Consolidation

*RAJASTHAN : 1993*

**24. Internal fixation is probably needed in all of the following except**

- (a) Fracture condyle of humerus
- (b) Fracture neck of femur
- (c) Fracture of Olecranon
- (d) Fracture of scaphoid

*UPSC:1993*

**25. One of the following is associated with Volkmann's ischaemic contracture**

- (a) Supracondylar fracture of humerus
- (b) Fracture shaft humerus
- (c) Intercondylar fracture of humerus
- (d) Dislocation of elbow.

*PGI : 2000*



- 26. A patient presenting with Volkmann's Ischaemia all of the following are done except**
- (a) Split open the plaster of Paris cast and bandage
  - (b) Decompression by fasciotomy
  - (c) Exploration
  - (d) Sympathetic ganglion blockade *PGI: 2000*
- 27. All are causes of Pathological fracture except**
- (a) Anaemia
  - (b) Osteoporosis
  - (c) Radiation
  - (d) Osteomalacia *PGI : 2000*
- 28. The most common cause of scoliosis is**
- (a) Idiopathic
  - (b) Congenital
  - (c) Paralytic
  - (d) Postural *PGI : 1994*
- 29. Pathognomonic sign of traumatic fracture is**
- (a) Redness
  - (b) Swelling
  - (c) Crepitus
  - (d) Tenderness *JIPEMER:1998*
- 30. Sudeck's atrophy is more common in**
- (a) Malunited Colles' fracture
  - (b) Malunited fracture femur
  - (c) Pott's fracture
  - (d) Carries spine *KARNATAKA:1998*
- 31. The most common cause of non union is**
- (a) Infection
  - (b) Inadequate immobilization
  - (c) Ischaemia
  - (d) Soft tissue interposition *UP:1998*



**32. A 6-year-old child falls in right-sided forearm region and develops fracture in dorsal surface of mid region of radius. The best treatment is**

- (a) Antibiotics & sedative
- (b) Bone plating and external fixation
- (c) Slab with wait for bone remodeling
- (d) Break the cortex other side and immobilization by POP.

*UP:1998*

**33. Volkmann's contracture**

- (a) Is localized thickening of palmar fascia
- (b) Develops at the ankle in a case of chronic venous ulcer
- (c) Follows Ischaemia of the forearm
- (d) Is due to excessive scarring of the skin of the arm following a burn.

*UPSC:1998*

**34. Dislocations occur most frequently in the**

- (a) Shoulder joint
- (b) Elbow joint
- (c) Hip joint
- (d) Knee joint

*ANDHRA:1999*

**35. Which of the following statements pertaining to green stick fracture is true?**

- (a) Any fracture in a child
- (b) Fracture only in rickety children
- (c) Only if there is no deformity
- (d) All of the above.

*ANDHRA:1999*

**36. One of the features given below is essential in the diagnosis of a fracture of a bone**

- (a) Deformity
- (b) A crepitus
- (c) A partial or complete loss of continuity of the bone
- (d) None of the above.

*ANDHRA:1999*

37. **The most common nerve involved in Volkmann's ischaemic contracture of fore arm includes**
- (a) Radial
  - (b) Ulnar
  - (c) Median
  - (d) Posterior interosseous
- ALL INDIA:1999*
38. **Fat Embolism is commonly due to**
- (a) Fracture femur
  - (b) Fracture both bones of fore arm
  - (c) Fracture calcaneum
  - (d) Crush injury of foot
- AIIMS:1999*
39. **A 40-year-old patient sustained left shoulder injury and developed anterior dislocation of shoulder joint causing sensory loss over lateral side of forearm. The nerve involved is**
- (a) Radial nerve
  - (b) Auxiliary nerve
  - (c) Musculocutaneous nerve
  - (d) Ulnar nerve
- AIIMS:1999*
40. **Stellate ganglion block is mainly used for**
- (a) Compound palmar ganglion
  - (b) Dequervain's synovitis
  - (c) Sudek's dystrophy
  - (d) Osteoarthritis of carpometacarpal joint.
- AIIMS:1999*
41. **A 23-year-old female has brought to the casualty after sustaining a road traffic accident. When she was going to her residence in her vehicle, the bike skidded which lead to a cross injury to her with deep bone exposure. The best graft used to cover her exposed part of bone is**
- (a) Full thickness graft
  - (b) Partial thickness graft
  - (c) Pedicle graft
  - (d) Muscle flap with skin graft
- AIIMS:1999*

42. Match List – I with List – II and select the correct answer using the codes given below the lists.

List I List II

- |                            |  |
|----------------------------|--|
| (a) Volkmann's contracture | 1. Complication of fracture neck of femur                  |
| (b) Fat embolic syndrome   | 2. Often associated with supracondylar fracture of humerus |
| (c) Nerve injury           | 3. Common in fracture tibia.                               |
| (d) Non union              | 4. Complication of fracture humerus                        |

CODES :

|   | A | B | C | D |
|---|---|---|---|---|
| A | 3 | 2 | 1 | 4 |
| B | 2 | 3 | 1 | 4 |
| C | 3 | 2 | 4 | 1 |
| D | 2 | 3 | 4 | 1 |

43. Volkmann's ischaemic contracture is commonly due to

- (a) Tight plaster  
 (b) Tight splint  
 (c) Both  
 (d) None

BIHAR:1990

44. Fracture shaft of femur in adult unites by

- (a) 3 to 4 weeks  
 (b) 3 to 4 weeks  
 (c) 3 to 4 months  
 (d) 4 to 6 months  
 (e) None of these

BIHAR:1990

45. Myositis ossificans is due to

- (a) Ossification  
 (b) New bone formation  
 (c) Ossification of subperiosteal haematoma

(d) Migration osteoblasts to haematoma

(e) All of the above.

*BIHAR:1990*

**46. Initial stage of clinical union of bone is equivalent to**

(a) Callus formation

(b) Woven bone

(c) Haematoma formation

(d) Calcification only

(e) None of the above

*BIHAR:1990*

**47. The most common cause of pathological fracture is**

(a) Delayed union

(b) Mal union

(c) Non union

(d) Secondary deposits

(e) Any of these

*BIHAR:1990*

**48. Delayed union of fracture of a bone following a surgical treatment may be due to**

(a) Infection

(b) Inadequate circulation

(c) Inadequate mobilization

(d) All of the above.

*NATIONAL BOARD:1990*

**49. A recessive form of Osteogenesis imperfecta may closely resembles**

(a) Alkaptonuria

(b) Cretinism

(c) Hypophosphatasia

(d) Homocystinuria

*NATIONAL BOARD:1990*

**50. The most common complication of supracondylar fracture is**

(a) VIC

(b) Cubitus varus

(c) Malunion

(d) Delayed union

51. The one most consistent sign of fresh fracture is
- (a) Crepitus
  - (c) Bony tenderness
  - (d) Deformity
  - (d) Abnormal mobility
  - (e) Shortening of bone.
52. The most important sign in diagnosing Volkmann's ischaemia of forearm is
- (a) Pallor
  - (b) Pain
  - (c) Parathesia
  - (d) Pulselessness of radial artery *TAMIL NADU:1991*
53. Treatment of choice in Acute myositis ossificans is
- (a) Immobilization of elbow
  - (b) Short wave diathermy
  - (c) Passive movements of arm
  - (d) Active exercises *TAMIL NADU:1991*
54. Volkmann's Ischaemic Contracture is due to
- (a) Injury to ulnar and median nerve
  - (b) Injury to median nerve alone
  - (c) Contracture of the palmar fascia
  - (d) Ischaemic vascular injury to the muscle
  - (e) All of the above. *BIHAR:1991*
55. Which of the following is regarded as a definite sign of fracture?
- (a) Tenderness
  - (b) Local bony irregularity
  - (c) Crepitus
  - (d) Swelling
56. Strike the false statement(s)
- (a) In sprain the ligament is often torn
  - (b) In dislocation there is no contact in between the both the component of the joint

- (c) Sclerosis of the fractured ends indicate absolute nonunion
- (d) None of the above.
- 57. Following are recognized F/O Myositis ossificans EXCEPT:**
- (a) It is a post traumatic ossification
- (b) It follows either a posterior dislocation or a supracondylar fracture of elbow joint
- (c) The complication is less likely in children
- (d) Diagnosis is made with certainty by skiagraphy.
- 58. Which statements pertaining to green stick fracture is correct?**
- (a) Any fracture (#) in child
- (b) Is generally incomplete
- (c) # only in rickety children
- (d) All of the above.
- 59. Fat embolism may ensue following:**
- (a) Fracture of spine and ribs
- (b) Fractured fibula
- (c) Fracture of skull bone
- (d) Fracture of long bones only.
- 60. Which of the following statement regarding green stick fracture is correct?**
- (a) Fracture only occurs in rickety children
- (b) Any fracture in a child
- (c) Is generally incomplete.
- 61. Which of the following is true about fat embolism?**
- (a) Usually ensues after fracture of the lower limb
- (b) Uncommon complication of fracture
- (c) Spontaneously reversible process
- (d) All of the above.

62. Which is the commonest fracture in children?
- (a) Fracture clavicle  
 (b) Supracondylar fracture  
 (c) Green stick fracture of lower end of radius  
 (d) All of the above.
63. In Volkmann's ischaemia, surgery should be done within:
- (a) 24 hours  
 (b) 36 hours  
 (c) 1 hour  
 (d) 6 hours.

### ANSWERS

- |         |         |         |          |
|---------|---------|---------|----------|
| 1. (b)  | 2. (a)  | 3. (d)  | 4. (a)   |
| 5. (c)  | 6. (d)  | 7. (c)  | 8. (a)   |
| 9. (a)  | 10. (a) | 11. (d) | 12. (b)  |
| 13. (e) | 14. (d) | 15. (a) | 16. (c)  |
| 17. (d) | 18. (c) | 19. (a) | 20. (d)  |
| 21. (a) | 22. (c) | 23. (c) | 24. None |
| 25. (a) | 26. (d) | 27. (a) | 28. (a)  |
| 29. (c) | 30. (a) | 31. (b) | 32. (d)  |
| 33. (c) | 34. (a) | 35. (c) | 36. (c)  |
| 37. (e) | 38. (a) | 39. (b) | 40. (c)  |
| 41. (c) | 42. (d) | 43. (c) | 44. (c)  |
| 45. (e) | 46. (b) | 47. (d) | 48. (d)  |
| 49. (c) | 50. (b) | 51. (a) | 52. (b)  |
| 53. (a) | 54. (d) | 55. (c) | 56. (d)  |
| 57. (c) | 58. (b) | 59. (d) | 60. (c)  |
| 61. (a) | 62. (a) | 63. (c) |          |



- 1. Duga's test is helpful in**
  - (a) Dislocation of hip.
  - (b) Scaphoid fracture
  - (c) Fracture neck of femur.
  - (d) Anterior dislocation of shoulder *JIPMER.91*
- 2. Treatment of choice for fracture neck of humerus in a 70 year old male**
  - (a) Analgesic with arm sling.
  - (b) U-Slab
  - (c) Arthroplasty.
  - (d) Open reduction – Internal fixation. *PAL'96*
- 3. Luxatio erecta**
  - (a) Tear of the glenoidal labium.
  - (b) Inferior dislocation of shoulder
  - (c) Anterior dislocation of shoulder.
  - (d) Defect in the humeral head *TN'98*
- 4. A patient with recurrent dislocation of shoulder presents to the hospital. The doctor tries to abduct his arm and to extend the elbow and external rotation, but the patient doesn't allow to do so. This test is called;**
  - (a) Duga's test.
  - (b) Hamilton's test.
  - (c) Callway's test.
  - (d) Apprehension test. *AIIMS 2001*
- 5. Common injury to baby is**
  - (a) Fracture humerus.
  - (b) Fracture clavicle.
  - (c) Fracture
  - (d) Fracture femur. *CMC VELLORE*



- 6. Ideal treatment with fracture neck of humerus in a lady will be**
- (a) Triangular sling.
  - (b) Hemiarthroplasty.
  - (c) Chest arm bandage
  - (d) Internal Fixation. *UP 2K*
- 7. Bankart's lesion involves**
- (a) Anterior aspect of the head of humerus.
  - (b) Anterior aspect of glenoid labrum
  - (c) Posterior aspect of glenoid labrum
  - (d) Posterior aspect of head of humerus. *UP 2K*
- 8. Commonest type of shoulder dislocation:**
- (a) Subcoracoid.
  - (b) Subglenoid
  - (c) Posterior
  - (d) Subclavicular **PGI 87**
- 9. Treatment of fracture clavicle in an infant is best treated by**
- (a) Cuff and sling
  - (b) Figure of 8 bandage
  - (c) Open reduction
  - (d) Shoulder cast *JIPMER 87*
- 10. All are related to recurrent shoulder dislocation except**
- (a) Hill sachs defect
  - (b) Bankart lesion
  - (c) Lax capsule
  - (d) Rotator cuff injury *CMC 2001*
- 11. Fracture of the clavicle are very common injuries. The most frequent complication of this fracture is**
- (a) Malunion
  - (b) Delayed union
  - (c) Non union
  - (d) Nerve injury. *KARNATAKA.1989*

- 12. In Recurrent Anterior dislocation of shoulder, the movements that causes dislocation is**
- (a) Flexion and internal rotation
  - (b) Abduction and external rotation
  - (c) Abduction and internal rotation
  - (d) Extension
- ALL INDIA, 1989*
- 13. Recurrent dislocation is most common in the shoulder joint. Which one of the following is not an important cause for the same?**
- (a) Tear of the anterior capsule of the shoulder
  - (b) Associated fracture neck of the humerus
  - (c) Tear of the glenoid labrum
  - (d) Freedom of mobility in the shoulder.
- KARNATAKA: 1989*
- 14. Recurrent dislocation is least common in**
- (a) Shoulder
  - (b) Knee
  - (c) Patella
  - (d) None
- DELHI 1994*
- 15. All of the following statements about dislocation of the shoulder are true, except**
- (a) The injury is produced by a fall with the arm fully abducted
  - (b) The commonest position for the head of the humerus to move into is the subspinous
  - (c) The auxiliary (circumflex humeral) nerve is likely to be injured
  - (d) The easiest way to reduce it is by simple pressure with the patient under general anesthesia with muscle relaxation.
- MANIPAL 1994*
- 16. Attitude in subcoracoid dislocation of shoulder includes**
- (a) Adduction
  - (b) Limb on side of body

(c) Abduction

(d) Elevation

*ANDHRA:1994*

**17. All are true regarding Clavicular fracture except;**

(a) May be caused by a fall on to the outstretched arm

(b) Commonly occurs between the insertions of the coraco-Clavicular and the costo Clavicular ligaments

(c) May jeopardize blood supply to the overlying skin

(d) Usually requires careful reduction.

*TAMIL NADU:1992*

**18. All are true regarding Clavicle except**

(a) First bone to ossify

(b) No treatment required for fracture except rest

(c) Ossifies in membrane

(d) Break at mid point

*AIIMS:1993*

**19. Recurrent dislocation of shoulder occurs because of**

(a) Crushed glenoid labrum

(b) Incomplete labrum

(c) Weak posterior capsule

(d) Superadded secondary infection

*AIIMS:1993*

**20. In Anterior dislocation of the shoulder the nerve involved is**

(a) Radial nerve

(b) Circumflex nerve

(c) Ulnar nerve

(d) Median nerve

*NIIMS:1992*

**21. Hill-Sachs lesion is associated with**

(a) Recurrent dislocation of shoulder

(b) Recurrent dislocation of hip

(c) Perthes' disease

(d) Fracture neck of femur.

*JIPMER:1992*

**22. Bankart's lesion is seen in**

(a) Anterior border of head of humerus

- (b) Posterior border of head of humerus
- (c) Anterior glenoid cavity
- (d) Posterior glenoid cavity

*AIIMS:2000*

**23. True about fracture clavicle is**

- (a) Malunion
- (b) Most common site is medial 1/3<sup>rd</sup> & lateral 2/3<sup>rd</sup>
- (c) Comminuted fracture
- (d) Due to fall on outstretched hand

*ALL INDIA: 2000*

**24. Clavicular fracture is usually treated by**

- (a) Traction
- (b) Open Reduction & Internal fixation
- (c) Figure of eight bandage
- (d) Plate & Screw fixation.

*TAMIL NADU: 1999*

**25. In a fracture shaft humerus, which of the following complication requires immediate surgery?**

- (a) Compound fracture
- (b) Nerve injury
- (c) Brachial artery occlusion
- (d) Comminuted fracture

*NIMS:2000*

**26. A 65 years female presents with impacted fracture surgical neck of humerus. Treatment of choice is**

- (a) Arthroplasty
- (b) Arm-Chest strapping
- (c) Triangular sling
- (d) Wait and watch

*PGI:2000*

**27. A 22 year old male is admitted with fracture of the left femur. Two days later, he becomes mildly confused, has a respiratory rate of 40 / min and scattered petechial rash on his upper torso. Chest X-ray shows patchy alveolar opacities bilaterally. His arterial blood gas analysis is abnormal. The most likely diagnosis is**

- (a) Cerebral oedema with early neurogenic pulmonary oedema

- (b) Pulmonary thrombo-embolism
- (c) Chest contusion
- (d) Fat embolism

*CSE:1998*

**28. The most common complication of clavicle fracture is**

- (a) Injury to brachial plexus
- (b) Malunion
- (c) Stiffness of shoulder
- (d) Non union.

*MP:1998*

**29. The most common bone fractured during birth**

- (a) clavicle
- (b) Scapula
- (c) Radius
- (d) Humerus

*MP:1998*

**30. Following statement regarding dislocation of shoulder are true except**

- (a) Head of humerus usually dislocates forward from shoulder joint
- (b) Injury is produced by forced extension & external rotation of abducted arm
- (c) In posterior dislocation, appearance of shoulder is not normal
- (d) None of the above.

*NIMHANS:1997*

**31. In treating a fractured clavicle in a 14 month old child, the best procedure is**

- (a) Open reduction
- (b) Shoulder cast
- (c) Figure – of – eight bandage
- (d) Kirshner pin

*ANDHRA:1999*

**32. The position of arm in anterior dislocation of shoulder is**

- (a) By the side
- (b) In abduction

- (c) In abduction
- (d) In external rotation

*ANDHRA:1999*

**33. Anterior dislocation of shoulder is most commonly complicated by**

- (a) Axillary artery injury
- (b) Circumflex nerve injury
- (c) Recurrent dislocation
- (d) Axillary nerve injury

*PGI:1997*

**34. The Rotator cuff is composed of four of the following muscles except**

- (a) Teres minor
- (b) Supraspinatus
- (c) Infraspinatus
- (d) Teres major
- (e) Subscapularis

*NATIONAL BOARD:1990*

**35. Meyer's procedure is a method for treatment of**

- (a) Recurrent shoulder dislocation
- (b) Habitual dislocation of patella
- (c) Congenital dislocation of hip
- (d) Fracture neck of femur

*PGI:1990*

**36. Fracture of clavicle is commonest at**

- (a) Junction of medial 1/3<sup>rd</sup> and lateral 2/3<sup>rd</sup>
- (b) Junction of medial 2/3<sup>rd</sup> and lateral 1/3<sup>rd</sup>
- (c) Midpoint
- (d) Scapular end

*Delhi: 1991*

**37. Which of the following is true of shoulder joint?**

- (a) Composed of only 2 joints
- (b) Anterior posterior gliding of scapula of never occurs
- (c) Acromio clavicular joint is more important
- (d) Allows flexion, rotation and abduction.

*JIPMER:1991*

38. **The most common complication of dislocation of shoulder joint is**
- (a) Injury to brachial plexus
  - (b) Injury to circumflex nerve
  - (c) Rupture of supraspinatous muscle
  - (d) Rupture of deltoid muscle *ORISSA:1991*
39. **Hill-Sachs lesion in recurrent shoulder dislocation is**
- (a) Injury to humeral head
  - (b) Rupture of tendon of supraspinatus muscle
  - (c) Avulsion of glenoid labrum
  - (d) None of the above. *AIIMS : 1992*
40. **Regarding Recurrent dislocation of the shoulder, which of the following is false?**
- (a) All traumatic dislocations will be recurrent
  - (b) Recurrent dislocation results when the capsule is stripped, not torn
  - (c) The humeral head is always within the capsule
  - (d) All of these. *ANDHRA : 1992*
41. **Which is true regarding shoulder dislocation?**
- (a) Posterior dislocation is often over-looked
  - (b) Pain is severe in anterior dislocation
  - (c) Radiography may be misleading in posterior dislocation
  - (d) All of the above.
42. **“Figure of Eight” bandage used commonly in the fracture of:**
- (a) Scapula
  - (b) Humerus
  - (c) Clavicle
  - (d) Metacarpals
43. **Which is true about shoulder dislocation?**
- (a) Anterior dislocation is common than posterior
  - (b) Fixed medial rotation in posterior dislocation



- (c) Kocher's manoeuvre is effective in anterior dislocation  
(d) All of the above.

**44. Fracture neck Humerus is common in:**

- (a) Elderly woman  
(b) Young lady  
(c) Elderly man  
(d) All of these.

**ANSWERS**

- |         |         |         |         |
|---------|---------|---------|---------|
| 1. (d)  | 2. (a)  | 3. (b)  | 4. (d)  |
| 5. (b)  | 6. (a)  | 7. (b)  | 8. (a)  |
| 9. (b)  | 10. (d) | 11. (a) | 12. (b) |
| 13. (b) | 14. (b) | 15. (d) | 16. (b) |
| 17. (d) | 18. (d) | 19. (a) | 20. (b) |
| 21. (a) | 22. (c) | 23. (a) | 24. (c) |
| 25. (c) | 26. (c) | 27. (d) | 28. (b) |
| 29. (a) | 30. (c) | 31. (c) | 32. (a) |
| 33. (b) | 34. (d) | 35. (d) | 36. (b) |
| 37. (d) | 38. (b) | 39. (a) | 40. (a) |
| 41. (d) | 42. (c) | 43. (d) | 44. (a) |

**16**

**INJURIES OF THE ELBOW,  
FOREARM AND WRIST**

**1. The best radiological view for fracture scaphoid is;**

- (a) AP.  
(b) PA.  
(c) Lateral.  
(d) Oblique.

*A.I.89*

**2. Commonest fractures in childhood is;**

- (b) Femur.



- (b) Distal humerus.
- (c) Clavicle.
- (d) Radius.

*BHU.88*

**3. Triangular relation of Elbow is maintained in**

- (a) Fracture ulna.
- (b) Anterior dislocation of Elbow
- (c) Posterior dislocation of Elbow
- (d) Supracondylar fracture

*AIIMS.91*

**4. Avascular necrosis of bone is most common in**

- (a) Scapula.
- (b) Scaphoid.
- (c) Calcaneus.
- (d) Cervical spine.

*JIPMER.93*

**5. Pulled Elbow is;**

- (a) Disarticulation of elbow.
- (b) Subluxation of distal radio-ulnar joint.
- (c) Subluxation of proximal radio ulnar joint.
- (d) None of the above

*PGI.79, AMC.85*

**6. Oblique view is required to diagnose fracture of**

- (a) Capitate.
- (b) Scaphoid.
- (c) Navicular
- (d) Hamate.

*ASSAM.95*

**7. Suspected medial epicondylar fracture of humerus in a 4 year old child requires:**

- (a) X-Ray both arms with elbow for comparison.
- (b) X-ray same limb only
- (c) Examination under general anaesthesia.
- (d) POP in full flexed position.

*PAL'96*

**8. A young adult presenting with oblique, displaced fracture olecranon treatment of choice;**

- (a) Plaster cast.

- (b) Percutaneous wiring.
- (c) Tension band wiring.
- (d) Removal of displaced piece with triceps repair.

*AIIMS.96*

**9. In colles fracture not seen is**

- (a) Proximal impaction.
- (b) Lateral rotation.
- (c) Dorsal angulation.
- (d) Medial rotation

*All MS.97*

**10. Carpal bone which fracture commonly:**

- (a) Scaphoid
- (b) Lunate
- (c) Hamate
- (d) Pisiform

*NIMHANS 87, KERALA 87*

**11. The cause of gun stock deformity is**

- (a) Supracondylar fracture
- (b) Fracture both bones forearm
- (c) Fracture surgical head of humerus
- (d) Fracture fibula

*PGI 86*

**12. Osteotomy done for mal united supracondylar fracture is**

- (a) French
- (b) Shanz's
- (c) Mc Murry's
- (d) Mc Alister

*J&K 2001*

**13. Which one of the following statements is not correct regarding fracture of the scaphoid?**

- (a) It is the most commonly fractured carpal bone
- (b) Persistent tenderness in the anatomical snuffbox is highly suggestive of fracture
- (c) Immediate X-ray of hand may not reveal fracture line
- (d) Mal union is a frequent complication

*UPSC 2001*

- 14. The most common elbow injury in children is**
- (a) Extension type of supracondylar fracture of humerus
  - (b) Dislocation of elbow
  - (c) Fracture lateral condyle of humerus
  - (d) Fracture medial epicondyle of humerus
- KERALA.1988*
- 15. In supracondylar fracture of humerus, the distal segment is often displaced to;**
- (a) Anteriorly
  - (b) Laterally
  - (c) Posteriorly
  - (d) Medially
- Kerala.1988*
- 16. Long term administration of ACTH produces**
- (a) Osteopetrosis
  - (b) Osteochondritis
  - (c) Osteosarcoma
  - (d) Osteoporosis
  - (e) Calcification of cartilage.
- Kerala.1988*
- 17. Main risk in fracture Scaphoid is**
- (a) Non union
  - (b) Malunion
  - (c) Delayed union
  - (d) Avascular necrosis
  - (e) Carpal tunnel syndrome
- AMC.1989*
- 18. Fracture lateral condyle of the humerus is a common injury in children. Which one of the following is the most ideal treatment for a displaced fracture lateral condyle of the humerus in a 7-year-old child?**
- (a) Open reduction and plaster immobilization
  - (b) Closed reduction and plaster immobilization
  - (c) Open reduction and internal fixation
  - (d) Excision of the fractured fragment
- KARNATAKA.1989*

- 19. Fall on outstretched hand may lead to fracture of**
- (a) Shoulder
  - (b) Clavicle
  - (c) Scaphoid
  - (d) Coronoid process
- DELHI:1989*
- 20. The most common deformity seen in supracondylar fracture of humerus is**
- (a) Inability to supinate and pronate
  - (b) Varus
  - (c) Valgus
  - (d) None
- 21. Tardy ulnar nerve palsy occurs as a delay sequela of**
- (a) Supracondylar fracture of humerus
  - (b) Posterior dislocation of elbow
  - (c) Fracture of lateral condyle of humerus in children
  - (d) Fracture of olecranon.
- 22. Excision of head of radius in a child should not be done because**
- (a) It produces instability of elbow joint
  - (b) It leads to secondary Osteo arthritis of elbow
  - (c) It causes subluxation of inferior radio-Ulnar joint.
- 23. Complication of fracture scaphoid is**
- (a) Avascular necrosis of distal part
  - (b) Injury to radial artery
  - (c) Injury to radial nerve
  - (d) Avascular necrosis of proximal part. *KERALA: 1994*
- 24. Avascular necrosis of bone is most commonly seen in**
- (a) Calcaneus
  - (b) Cervical Spine
  - (c) Scaphoid
  - (d) Scapula
- JIPMER:1993*

25. **Medial epicondyle fracture results in injury to \_\_\_\_\_ nerve.**  
(a) Radial  
(b) Median  
(c) Ulnar  
(d) Axillary *NB:1993*
26. **Increased intercondylar distance is seen in fracture of all except**  
(a) Olecranon  
(b) Medial epicondyle  
(c) Lateral epicondyle  
(d) Lateral condyle *DELHI: 1993*
27. **The most common injury in a 7 years old child due to fall on outstretched hand is**  
(a) Dislocation of shoulder  
(b) Colles' fracture  
(c) Fracture of clavicle  
(d) Supracondylar Fracture of humerus *ANDHRA: 1993*
28. **Barton's fracture of the wrist**  
(a) Involves radio carpal subluxation  
(b) Is a severe form of a Colles' fracture  
(c) Is often treated by open reduction and internal fixation  
(d) All of the above. *TAMIL NADU:1992*
29. **The bony triangle is maintained in**  
(a) Supracondylar fracture of humerus  
(b) Posterior dislocation of elbow  
(c) Intercondylar fracture of humerus  
(d) Lateral condylar fracture of humerus.  
*ALL INDIA: 1993*
30. **Tardy ulnar nerve palsy occur as a delayed sequele of**  
(a) Supracondylar fracture of humerus  
(b) Posterior dislocation of elbow  
(c) Fracture of lateral condyle of humerus in children  
(b) Fracture of Olecranon *PGI:1992*

- 31. The treatment of choice of fracture of radius and ulna in a an adult is**
- (a) Plaster for 4 weeks
  - (b) Closed reduction and calipers
  - (c) Only plates
  - (d) Kuntscher nails
- DELHI: 1992*
- 32. In Monteggia fracture, which is true about ulnar fracture and head of radius**
- (a) Both ulnar fracture and head of radius is displaced posteriorly
  - (b) Both ulnar fracture and head of radius is displaced anteriorly
  - (c) Ulnar fractures is posteriorly and head of radius is displaced anteriorly
  - (d) Ulnar fracture is anteriorly and head of radius is displaced posteriorly.
- JIPMER 1992*
- 33. Relation between 3 bony point in elbow is reversed by**
- (a) Fracture lateral condyle of humerus
  - (b) Fracture medial condyle of humerus
  - (c) Posterior dislocation of elbow
  - (d) Supracondylar fracture of humerus
- AIIMS: 2000*
- 34. Not a complication of Colles' fracture**
- (a) Stiffness of wrist
  - (b) Stiffness of shoulder
  - (c) Carpal tunnel syndrome
  - (d) Wrist drop
- JIPMER: 2000*
- 35. Commonest complication of Colles' fracture is**
- (a) Nonunion
  - (b) Malunion
  - (c) Vascular injury
  - (d) Sudeck's osteodystrophy
- KARNATAKA: 2000*



36. Which carpal bone fracture causes median nerve involvement?  
(a) Scaphoid  
(b) Lunate  
(c) Trapezium  
(d) Trapezoid *NIMS: 2000*
37. The complication of Colles' fracture is  
(a) Radial nerve palsy  
(b) Stiffness of wrist joint  
(c) Ulnar nerve palsy  
(d) None of the above *NATIONAL BOARD: 2000*
38. The most common type of supracondylar fracture is  
(a) Neutral  
(b) Flexion  
(c) Extension  
(d) Lateral *TAMIL NADU: 1993*
39. Internal fixation is probably needed in all of the following except  
(a) Fracture condyle of humerus  
(b) Fracture neck of femur  
(c) Fracture of Olecranon  
(d) Fracture of scaphoid *UPSC: 1993*
40. Cubitus varus is most commonly seen in  
(a) Rickets  
(b) Post inflammatory epiphyseal damage  
(c) Fracture lateral condyle humerus  
(d) Malunited supracondylar fracture *ALL INDIA: 1994*
41. Treatment of Smith's fracture is  
(a) Above elbow cast applied in extension  
(b) Colles' plaster  
(c) Dorsal splintage  
(d) Internal fixation *ALL INDIA: 1994*

42. A 12-year-old child presents with tingling sensation and numbness in the little finger and gives history of fracture in the elbow region 4 years back. The probable fracture is
- (a) Lateral condyle fracture humerus
  - (b) Injury to ulnar nerve
  - (c) Supracondylar fracture humerus
  - (d) Dislocation of elbow
43. Three point relationship is maintained in the following
- (a) Dislocation of elbow joint
  - (b) Supracondylar fracture of humerus
  - (c) Fracture medial condyle fracture of humerus
  - (d) Lateral condyle fracture of humerus.
44. A 10-year-old boy presented with pain and massive swelling left thigh. On examination reveals diaphyseal lesion and soft tissue swelling. The likely diagnosis is
- (a) Osteosarcoma
  - (b) Ewing's sarcoma
  - (c) Osteoclastoma
  - (d) Aneurysmal bone cyst
- AIIMS:NOV:2000*
45. Pulled elbow is
- (a) A sprain of extensor tendons
  - (b) Dislocation of head of radius
  - (c) Fracture of lateral condyle of humerus
  - (d) Dislocation at elbow
- PGI:1994*
46. Which is not a feature of pseudoachondroplasia?
- (a) Short limbs in comparison to trunk
  - (b) Kyphosis
  - (c) Normal size skull
  - (d) None of the above
- PGI : 1994*
47. Galeazzi fracture is fracture of
- (a) Upper end of ulna
  - (b) Lower end of ulna



(c) Upper end of radius

(d) Lower end of radius

*ANDHRA : 1998*

**48. A patient reported with a history of fall on an outstretched hand, complains of pain in the anatomical snuffbox and clinically no deformities visible. The diagnosis is**

(a) Colles' fracture

(b) Lunate dislocation

(c) Barton's fracture

(d) Scaphoid fracture

*NIMS:1998*

**49. The most common nerve involvement is dislocation of Lunate is**

(a) Median nerve

(b) Anterior interosseus

(c) Posterior interosseus

(d) Median nerve.

*UP:1998*

**50. Galeazzi fracture is**

(a) Supracondylar fracture of the humerus

(b) Fracture of the distal radius with inferior radio ulnar joint dislocation

(c) Fracture of radius in the proximal site and dislocation of the elbow

(d) Fracture of the radial head.

*KARNATAKA: 1997*

**51. If an adolescent boy falls on a out-stretched hand, the most common bone to be injured is**

(a) Fracture of lower end of radius

(b) Fracture of both bones of forearm

(c) Scaphoid fracture

(d) Supracondylar fracture of humerus

*ANDHRA:1999*

**52. Posterior interosseous nerve is injured in**

(a) Posterior dislocation of elbow

(b) Monteggia fracture dislocation

- (c) Reversed Monteggia fracture dislocation  
(d) Supracondylar fracture of humerus *ANDHRA:1999*
- 53. The most common cause of Volkmann's ischaemic contracture (V.I.C) in a child is**  
(a) Intercondylar fracture of humerus  
(b) Fracture both bone of forearm  
(c) Fracture lateral condyle of humerus  
(d) Supracondylar fracture of humerus *AIIMS:1999*
- 54. The most common complication of supracondylar fracture is**  
(a) Genu valgum  
(b) Blood vessel injury  
(c) Volkmann's ischaemic contracture  
(d) Malunion with gun stock deformity *PGI:1997*
- 55. Gunstock deformity is due to**  
(a) Fracture of 1<sup>st</sup> metacarpal bone  
(b) Fracture of lower end of radius  
(c) Supracondylar fracture of humerus  
(d) Lateral condylar fracture of humerus  
*TAMIL NADU :1997*
- 56. Rupture of extensor pollicis longus occurs four weeks after**  
(a) Colles' fracture  
(b) Radial styloid fracture  
(c) Smith's fracture  
(d) Scaphoid fracture  
(e) All of these. *BIHAR:1990*
- 57. The most common cause of nonunion is**  
(a) Periosteal elevation  
(b) Haematoma between fragments  
(c) Callus formation  
(d) Diminished blood supply  
(e) All of the foregoing.

**58. Tardy ulnar neuritis may be due to**

- (a) Advanced osteo arthritis of elbow
- (b) Cubitus valgus deformity
- (c) Both of the above
- (d) None of the above.

*BIHAR:1990*

**59. The true statement regarding supracondylar fracture of the Humerus in children**

- (a) Admission to hospital is essential following reduction
- (b) It is due to a fall on the point of the elbow
- (c) It requires open reduction
- (d) It is usually compound

*KERALA:1990*

**60. A Colles fracture is**

- (a) Common in adolescence
- (b) A fracture about the ankle joint
- (c) Common in elderly women
- (d) A fracture of head of the radius

*NATIONAL BOARD:1990*

**61. Which of the following is known for Non union in children, if left untreated?**

- (a) Fracture shaft of humerus
- (b) Fracture shaft of femur
- (c) Fracture distal 1/3<sup>rd</sup> of tibia
- (d) Fracture lateral condyle of humerus
- (e) Supracondylar fracture of humerus

*NATIONAL BOARD:1990*

**62. The following fractures are known for Non-union except**

- (a) Fracture of lower half of tibia
- (b) Fracture of neck of femur
- (c) Fracture of scaphoid
- (d) Fracture of patella
- (e) Supracondylar fracture of humerus

*NATIONAL BOARD:1990*

- 63. Fracture of lateral condyle of humerus seen in age group of**
- (a) 2-3 years
  - (b) 3-5 years
  - (c) 5-15 years
  - (d) 15-25 years
  - (e) 35-45 years
- PGI:1990*
- 64. The most important cause of Nonunion of fracture of humeral shaft is**
- (a) Comminuted fracture
  - (b) Compound (Open) fracture
  - (c) Overriding of fracture ends
  - (d) Distraction at fracture site
  - (e) Operative reduction
- ORISSA:1990*
- 65. About displacement of distal fragment in Colles fracture, true is**
- (a) Anteriorly and medially
  - (b) Posteriorly and laterally
  - (c) Anteriorly and laterally
  - (d) Posteriorly and medially.
- UPSC:1990*
- 66. In children the following fracture often require open reduction**
- (a) Femoral condylar fracture
  - (b) Supracondylar fracture of the humerus.
  - (c) Fracture of the both bones of forearm
  - (d) Fracture of lateral condyle of the humerus.
- ALL INDIA:1991*
- 67. Tardy Ulnar nerve palsy is caused by**
- (a) Fracture lateral epicondyle of humerus
  - (b) Fracture medial epicondyle of humerus
  - (c) Elbow dislocation
  - (d) Supra condylar fracture of humerus
- AIIMS:1991*

- 68. Open reduction in children is required for**  
(a) Fracture both bones of forearm  
(b) Femoral condyles  
(c) Lateral humeral condyle  
(d) Distal tibial epiphysis *AIIMS:1991*
- 69. The basic principle in the treatment of fractures of both bones of the forearm is to**  
(a) Reduce angulation of radius and ulna  
(b) Restore the normal relationship of radius and ulna  
(c) Immobilize the elbow only  
(d) Prevent over riding of fragments  
(e) All of the above. *BIHAR:1991*
- 70. 'Dinner fork deformity' is present in case of**  
(a) Smith's fracture  
(b) Student's elbow  
(c) Colles' fracture  
(d) All of these. *BIHAR:1991*
- 71. Which of the following is commonly seen in Colles' fracture?**  
(a) Non union  
(b) Delayed union  
(c) Malunion  
(d) Rapid union *DELHI:1991*
- 72. The commonly injured carpal bone next to scaphoid is**  
(a) Trapeium  
(b) Trapezoid  
(c) Lunate  
(d) Capitate  
(e) Hamate *NATIONAL BOARD:1991*
- 73. In Scaphoid fracture, important views are all except**  
(a) AP  
(b) Lateral

(c) Oblique

(d) Cone

*PGI:1991*

**74. If head of the radius is removed, it will result in**

(a) Lengthening of limb

(b) Valgus deformity

(c) Varus deformity

(d) No deformity

*PGI:1991*

**75. In supra condylar fracture of humerus, the nerve most commonly injured is**

(a) Radial nerve

(b) Ulnar nerve

(c) Median nerve

(d) Auxiliary nerve

*UPSC:1991*

**76. Monteggia fracture is fracture of**

(a) Lower  $\frac{1}{3}$ <sup>rd</sup> of Radius

(b) Upper  $\frac{1}{3}$ <sup>rd</sup> of Radius

(c) Lower  $\frac{1}{3}$ <sup>rd</sup> of Ulna

(d) Upper  $\frac{1}{3}$ <sup>rd</sup> of Ulna

*UPSC: 1991*

**77. The most common cause for tardy Ulnar palsy is**

(a) Fracture of lateral condyle in child hood

(b) Supra condylar fracture

(c) Olecranon fracture

(d) Monteggia's fracture

*AIIMS : 1992*

**78. Which fracture requires open reduction in children?**

(a) Fracture of both bones of forearm

(b) Epiphyseal separation of tibia

(c) Intercondylar fracture of femur

(d) Lateral condyle fracture of humerus

*AIIMS: 1992*

**79. Following are the common sites of Avascular necrosis, EXCEPT:**

(a) Proximal half of scaphoid

(b) The body of talus



- (c) Patella  
(d) Head of the femur.
- 80. Which of the following statement(s) is / are true?**
- (a) Oedema & tenderness over the anatomical snuff box is the pathognomonic features of Fracture of the scaphoid  
(b) Normally the radial styloid is  $\frac{1}{2}$ " lower than the ulnar  
(c) Dinner fork deformity is characteristic of Colle's Fracture  
(d) All of the above.
- 81. Strike the false statement (s):**
- (a) Reversed Colle's is called Smith's Fracture  
(b) If the lower limb is externally rotated, it is most likely due to Fracture neck of femur  
(c) If the thigh assumes flexion, adduction and internal rotation following a history of severe injury, a posterior dislocation is the likely cause.  
(d) None of these.
- 82. Which complication may arise after supra-condylar fracture?**
- (a) Median nerve injury  
(b) Damage to brachial artery  
(c) Cubitus varus  
(d) All of the above.
- 83. Which tendon gets involved in Colle's fracture?**
- (a) Abductor pollicis longus  
(b) Extensor pollicis brevis  
(c) Extensor pollicis longus  
(d) All the above.

|                |
|----------------|
| <b>ANSWERS</b> |
|----------------|

- |        |        |        |        |
|--------|--------|--------|--------|
| 1. (d) | 2. (c) | 3. (d) | 4. (b) |
| 5. (c) | 6. (b) | 7. (a) | 8. (d) |

- |         |         |         |         |
|---------|---------|---------|---------|
| 9. (d)  | 10. (a) | 11. (a) | 12. (a) |
| 13. (d) | 14. (a) | 15. (c) | 16. (d) |
| 17. (d) | 18. (d) | 19. (c) | 20. (b) |
| 21. (c) | 22. (c) | 23. (d) | 24. (c) |
| 25. (c) | 26. (a) | 27. (d) | 28. (a) |
| 29. (a) | 30. (c) | 31. (c) | 32. (b) |
| 33. (c) | 34. (d) | 35. (b) | 36. (b) |
| 37. (b) | 38. (c) | 39. (d) | 40. (d) |
| 41. (c) | 42. (a) | 43. (b) | 44. (b) |
| 45. (b) | 46. (c) | 47. (d) | 48. (d) |
| 49. (a) | 50. (b) | 51. (c) | 52. (b) |
| 53. (d) | 54. (d) | 55. (c) | 56. (a) |
| 57. (d) | 58. (b) | 59. (a) | 60. (c) |
| 61. (d) | 62. (e) | 63. (b) | 64. (d) |
| 65. (b) | 66. (d) | 67. (a) | 68. (c) |
| 69. (b) | 70. (c) | 71. (c) | 72. (c) |
| 73. (d) | 74. (b) | 75. (c) | 76. (c) |
| 77. (a) | 78. (d) | 79. (c) | 80. (d) |
| 81. (d) | 82. (d) | 83. (c) |         |

# 17

## INJURIES OF THE HAND

- Bennett's fracture is fracture dislocation of base of .....metacarpal:
  - 4<sup>th</sup>.
  - 3<sup>rd</sup>.
  - 2<sup>nd</sup>.
  - 1<sup>st</sup>.

*UP.88*
- Mallet finger is
  - Avulsion fracture of extensor tendon of distal phalanx
  - Fracture of distal phalanx



- (c) Fracture of middle phalanx
- (d) Fracture of proximal phalanx

*UPSC 85,88, Kerala 87*

**3. The term Bennett's fracture is used to describe**

- (a) Fracture-dislocation of metacarpophalangeal joint of thumb
- (b) Interphalangeal fracture dislocation of thumb
- (c) Anterior marginal fracture of distal end of radius
- (d) Fracture dislocation of trapezometacarpal joint.

*Karnataka;1989*

**4. Which of the following Scaphoid fracture is most prone to develop Avascular necrosis?**

- (a) Fracture of waist of scaphoid
- (b) Fracture of tubercle
- (c) Fracture of distal pole
- (d) All of the above.

*KARNATAKA: 1992*

**5. A Bennett's fracture is difficult to maintain in a reduced position mainly because of the pull of the**

- (a) Flexor pollicis longus
- (b) Flexor pollicis brevis
- (c) Extensor pollicis brevis
- (d) Abductor pollicis longus

*PGI: 1992*

**6. Tardy ulnar nerve palsy occur as a delayed sequelae of**

- (a) Supracondylar fracture of humerus
- (b) Posterior dislocation of elbow
- (c) Fracture of lateral condyle of humerus in children
- (d) Fracture of Olecranon

*PGI: 1992*

**7. A middle aged male fell from a height presents with shortening of leg, internal rotation and tenderness in Scarpa's triangle. Diagnosis is**

- (a) Hip Dislocation
- (b) Fracture neck of femur

(b) Fracture shaft of femur

(b) Fracture of acetabulum

*UPSC: 1993*

**8. Position of the lower limb in posterior dislocation of hip is**

(a) Flexion, Abduction and external rotation

(b) Flexion, Adduction and external rotation

(c) Flexion, Abduction and internal rotation

(d) Flexion, Adduction and internal rotation

*AIIMS: NOV-2000*

**9. A Bennet's fracture is difficult to maintain in reduced position because of the pull of**

(a) Extensor pollicis longus

(b) Extensor pollicis brevis

(c) Abductor pollicis longus

(d) Abductor pollicis brevis

*KARNATAKA : 1999*

**10. Avulsion of extensor tendon gives rise to**

(a) Mallet finger

(b) Dupuytren's contracture

(c) Trigger finger

(d) Swan neck deformity

*ANDHRA:199*

**11. Lower branch of brachial plexus injury leads to**

(a) Erb's palsy

(b) Klumpke's palsy

(c) Bell's palsy

(d) Wrist drop

*ANDHRA:1997*

**12. Galeazzi's fracture is**

(a) Lower 1/3<sup>rd</sup> fracture ulna with radioulnar dislocation

(b) Upper 1/3<sup>rd</sup> fracture ulna with inferior radioulnar dislocation

(c) Lower 1/3<sup>rd</sup> fracture radius with radioulnar dislocation

(d) Upper 1/3<sup>rd</sup> fracture ulna with superior radioulnar dislocation

*PGI:1997*

**13. Middle palmar space ends distally**

- (a) Along the digital sheaths
- (b) Into the flexor tendon sheaths
- (c) Into the web space
- (d) By mixing with the superficial palmar space

*NATIONAL BOARD: 1991*

**ANSWERS**

- |         |         |         |         |
|---------|---------|---------|---------|
| 1. (a)  | 2. (a)  | 3. (d)  | 4. (a)  |
| 5. (d)  | 6. (c)  | 7. (a)  | 8. (d)  |
| 9. (c)  | 10. (a) | 11. (b) | 12. (c) |
| 13. (c) |         |         |         |

**18**

**INJURIES OF THE HIP AND THIGH**

**1. Commonest dislocation of the hip is**

- (a) Posterior.
- (b) Anterior.
- (c) Central.
- (d) None.

*TN.89*

**2. The following is true in the treatment of posterior dislocation:**

- (a) Closed reduction under anaesthesia.
- (b) Open reduction.
- (c) Skeletal traction.
- (d) Soft tissue

*PGI.90*

**3. Flexion, adduction and internal rotation is characteristic posture in**

- (a) Anterior dislocation of hip joint.
- (b) Posterior dislocation of hip joint.

(c) Fracture of femoral head.

(d) Fracture shaft of femur.

*JIPMER-95*

**4. Treatment of choice for old non-united fracture of shaft of femur**

(a) Compression plating.

(b) Bone grafting.

(c) Nailing.

(d) Compression plating with bone grafting. *AIIMS-94*

**5. In 65 year old male with history of fracture neck of femur 6 weeks old, treatment of choice**

(a) SP nailing.

(b) Mc Murray's osteotomy.

(c) Hemiarthroplasty.

(d) None.

*AIIMS-94*

**6. In the case of 65 year old person with fracture neck of femur the treatment of choice is**

(a) Closed reduction.

(b) Closed reduction with internal fixation

(c) Open reduction.

(d) Replacement of head and neck of the femur with a prosthesis. *UPSC*

**7. Commonest complication of extra capsular fracture of neck of femur is:**

(a) Non union

(b) Ischemic necrosis

(c) Malunion

(d) Pulmonary complications

*A.I. 88*

**8. Fracture femur in infants is best treated by:**

(a) Open reduction

(b) Closed reduction

(c) IM Nailing

(d) Gallows's splinting

*PDI 88*

9. **The attitude of limb in traumatic dislocation of hip joint is**  
(a) Flexion, adduction, external rotation  
(b) Flexion, adduction, internal rotation  
(c) Flexion, adduction, and external rotation  
(d) Flexion and adduction only *Delhi:1988*
10. **Flexion, abduction and external rotation at hip joint with limb length discrepancy is seen in**  
(a) Fracture neck of femur  
(b) Anterior dislocation of hip  
(c) Posterior dislocation of hip  
(d) None *ORISSA:1988*
11. **Fractured neck of femur is associated with all except**  
(a) Causes shortening of the leg  
(b) Causes internal rotation of the leg  
(c) May be pathological  
(d) May be treated with hemiarthroplasty. *TAMIL NADU:1988*
12. **The treatment of choice for a 4 week old Femoral neck fracture in a 55 years old man is**  
(a) Open reduction and internal fixation  
(b) Mc Murray's Osteotomy  
(c) Hemi replacement arthroplasty  
(d) Total hip replacement *ALL INDIA:1989*
13. **Which of the following fractures would best be treated by Open reduction?**  
(a) Fracture of the femoral shaft of the child  
(b) Collies' fracture  
(c) Displaced fracture of the femoral neck  
(d) Fracture of humeral shaft. *AMU:1989*
14. **Fracture of femur at the level of isthmus is best treated by**  
(a) Intramedullary nail fixation

- (b) Plate and screws
- (c) Closed method
- (d) External fixation

*ANDHRA, 1989*

**15. Nonunion is a very common complication of intracapsular fractures of the neck of femur. Which of the following is not a very important cause for the same?**

- (a) Inadequate immobilization
- (b) Inadequate blood supply
- (c) Inhibitory effect of synovial fluid
- (d) Stress at fracture site due to muscle spasm

*KARNATAKA: 1989*

**16. Traumatic dislocation of hip is characterized by**

- (a) Adduction internal rotation deformity
- (b) Abduction external rotation deformity
- (c) Adduction external rotation deformity
- (d) Abduction internal rotation deformity

*NATIONAL BOARD: 1989*

**17. Fracture shaft of femur in children of less than 2 years old is treated by**

- (a) Open reduction
- (b) External fixation
- (c) Gallows's traction
- (d) Closed reduction

*ANDHRA, 1989*

**18. Mc Murray's osteotomy is based on the following principle**

- (a) Biological
- (b) Bio mechanical
- (c) Bio technical
- (d) Mechanical

*ANDHRA 1994*

**19. A patient with hip in adduction and medial rotation and is unable to move Probable diagnosis is**

- (a) Posterior dislocation head of femur
- (b) Fracture shaft o femur

(c) Fracture neck of femur

(d) Sciatica

ANDHRA 1994

**20. Trochanteric fracture of femur is best treated by**

(a) Dynamic hip screw

(b) Inlay Plates

(c) Plaster in abduction

(d) Plaster in abduction and internal rotation. PGI 1993

**21. In fracture of femur popliteal artery is commonly damaged by**

(a) Proximal fragment

(b) Distal fragment

(c) Muscle haematoma

(d) Tissue swelling PGI 1993

**22. A fracture neck femur in a child is best treated by**

(a) Spica in abduction

(b) Spica in abduction + internal rotation

(c) Masterly inactivity

(d) Open reduction and internal fixation. PGI 1993

**23. The most common complication of Transcervical fracture of Femur is**

(a) Avascular necrosis

(b) Malunion

(c) Non union

(d) None TAMIL NADU 1992.

**24. Behcet's syndrome is commonest in**

(a) Ankle

(b) Wrist

(c) Knee

(d) Hip KARNATAKA: 1992

**25. Characteristic features of the acute compartment syndrome in the lower leg include all of the following except;**

(a) Acute pain on employing the stretch test



- (b) Normal pulses
- (c) Normal sensation distally
- (d) Venous occlusion.

**26. Which is most appropriate treatment for the femur with nonunion more than 3 weeks?**

- (a) Internal fixation
- (b) Bone grafting with internal fixation
- (c) External fixation
- (d) Prosthesis

*AIIMS:1994*

**27. In which one of the following femoral fractures is Avascular necrosis common?**

- (a) Pertrochanteric
- (b) Transcervical
- (c) Sub-Trochanteric
- (d) Shaft of femur

*CSE : 2000*

**28. In the case of a 70 year old lady with intra capsular fracture of the neck of femur, the ideal treatment would be**

- (a) Closed traction
- (b) Hemiarthroplasty
- (c) Internal fixation with nail
- (d) Internal fixation with nail and plate

*CSE : 2000*

**29. Late complication of Acetabular fracture with dislocation of hip includes**

- (a) Prone to trauma
- (b) Recurrent dislocation
- (c) Osteoarthritis
- (d) Stiff hip

*UP : 1999*

**30. In upper one third femoral shaft fracture, the displacement of proximal segment is**

- (a) Flexion, abduction and external rotation
- (b) Flexion, abduction and external rotation



- (c) Flexion, abduction and internal rotation  
(d) Flexion, abduction and internal rotation *CSE : 1999*
- 31. In anterior dislocation of hip, the posture of lower limb will be**  
(a) Abduction, externally rotated and extension  
(b) Abduction, externally rotated and flexion  
(c) Abducted externally rotated and flexion  
(d) Adducted, internally rotated and flexion  
*DELHI : 1999*
- 32. The femur is fractured at birth at**  
(a) Upper third of shaft  
(b) Middle third of shaft  
(c) Lowr third of shaft  
(d) Neck region  
*Rajasthan: 1993*
- 33. 3 days old intracapsular fracture neck of femur in a 50 year old patient is treated by**  
(a) POP hip spika  
(b) Total hip replacement  
(c) Cortical screw fixation  
(d) Hemi replacement arthroplasty  
*UP : 2000*
- 34. Avascular necrosis of head of femur occurs commonly at**  
(a) Transcervical region  
(b) Trochanteric region  
(c) Subcapital region  
(d) Subchondral region  
*NATIONAL BOARD : 2000*
- 35. Pauvel's angle is**  
(a) Neck shaft angle of femur  
(b) The difference between neck shaft angle between two femurs of a patient  
(c) Formed by joining a line extended from fracture line of femur neck to an arbitrary line depicting the horizontal plane  
(d) None of the above.  
*RAJASTHAN: 1994*

- 36. Garden's classification is applicable to**
- (a) Intertrochanteric fracture
  - (b) Fracture neck of femur
  - (c) Epiphyseal separation
  - (d) Posterior dislocation of hip
- UP: 1994*
- 37. 65-year-old lady falls from height. On examination the leg is extended and externally rotated. Diagnosis is**
- (a) Fracture of acetabulum
  - (b) Intertrochanteric fracture
  - (c) Neck femur fracture
  - (d) Posterior dislocation of hip
- 38. In per rectal examination, femoral head is palpable in**
- (a) Anterior dislocation of hip
  - (b) Posterior dislocation of hip
  - (c) Central dislocation of hip
  - (d) Lateral dislocation of hip
- ANDHRA: 1998*
- 39. Prosthetic replacement of femoral head is indicated for one of the following sites of fractures.**
- (a) Inter-trochanteric fracture of femoral neck
  - (b) Subcapital fracture neck femur
  - (c) Transtrochanteric fracture femur
  - (d) Basal fracture of femoral neck
- BIHAR: 1998*
- 40. Femoral neck fracture of three weeks old in a young adult should be best treated one of the following**
- (a) Total hip replacement
  - (b) Reduction of fracture and femoral osteotomy with head
  - (c) Prosthetic replacement of femoral head
  - (d) Reduction of fracture and multiple pin or screw fixation
  - (e) Upper femoral displacement osteotomy.
- BIHAR: 1998*
- 41. Intramedullary fixation is ideal in a case of fracture of shaft of femur when there is**
- (a) A transverse fracture

- (b) A compound fracture
- (c) Soft tissue interposition between the fractured ends
- (b) Such a fracture in a child. *CSE:1998*

**42. Features of fracture neck of femur includes**

- (a) Flexion at hip and lateral rotation
- (b) Flexion at hip abduction
- (c) Shortening and lateral rotation
- (d) Shortening and flexion *MANIPAL : 1998*

**43. A 60-year-old man fell in bathroom and was unable to stand on right buttock region echymosis with external rotation of the leg and lateral border of foot touching the bed. The most probable diagnosis is**

- (a) Extra capsular fracture neck of femur
- (b) Anterior dislocation of hip
- (c) Intra capsular fracture neck of femur
- (d) Posterior dislocation of hip *UP:1998*

**44. Prosthesis at head of femur applied in**

- (a) 40 years young male with # head of femur
- (b) 40 year young male with # neck of femur
- (c) 40 year young male with posterior dislocation of hip
- (d) 65 years old male with non united fracture neck of femur *UP:1998*

**45. Telescopic test is useful to diagnose**

- (a) Perthe's disease
- (b) Intracapsular fracture neck of femur
- (c) Malunited Trochanteric fracture
- (d) Ankylosis of hip joint

**46. Dashboard injury results in**

- (a) Anterior dislocation of hip
- (b) Posterior dislocation of hip
- (c) Central dislocation of hip
- (d) Fracture neck femur *ANDHRA:1997*

47. Match list I with List II select the correct answer.

| List I                                      | List II                                    |
|---|--|
| (Sites of Fracture Femur)                   | (Methods of treatment)                     |
| (a) Intracapsular neck fracture             | 1. Thomson Prosthesis                      |
| (b) Extra capsular subtrochanteric Fracture | 2. Conservative treatment                  |
| (c) Shaft fracture in children              | 3. Internal fixation using screw and Plate |
| (d) Supracondylar fracture                  | 4. Steinman pins                           |

|   | A | B | C | D |
|---|---|---|---|---|
| A | 1 | 2 | 4 | 3 |
| B | 2 | 1 | 3 | 4 |
| C | 2 | 3 | 4 | 1 |
| D | 1 | 3 | 2 | 4 |

48. The most common complication of extra capsular fracture of neck of femur is

- (a) Avascular necrosis
- (b) Nonunion
- (c) Malunion
- (d) Myositis ossificans

*DELHI:1997*

49. A 3 year old child presents with fracture of femoral shaft had immobilized on traction constantly for two months. The next step of management is

- (a) Hip Spica and if necessary internal fixation
- (b) Gallow traction for 2 months
- (c) Open reduction and Kuntscher's lover leaf intramedullary nailing or plating
- (d) Traction by Thomas splint

*BIHAR:1999*

50. A 65 year old patient who presents 10 days after fracture neck femur is best managed by

- (a) Internal fixation
- (b) Replacement arthroplasty

(c) Mc Murray's procedure

(d) Traction for 6 weeks.

*AIIMS:1998*

**51. Concerning fractures of the neck of the femur which statement is considered now to be incorrect?**

(a) It is common in elderly women

(b) It can occur in young adults due to fatigue

(c) It can occur in young adults following severe violence applied in the long axis of the femur

(d) The bone fractures in an elderly woman because she falls.

*AMU:1996*

**52. The most common complication of intracapsular fracture neck of femur is**

(a) Mal union

(b) Osteoarthritis

(c) Non-Union

(d) Shortening

*JIPMER:1990*

**53. All of the following names are associated with tests / operations around the hip joint except**

(a) Bryant

(b) Shenton

(c) Mc Murray

(d) Salter

(e) Nelton

*NATIONAL BOARD:1990*

**54. Flexion, abduction and external rotation with limb length discrepancy is seen in**

(a) Posterior dislocation of hip

(b) Central dislocation of hip

(c) Anterior dislocation of hip

(d) Fracture neck of femur

*ORISSA:1990*

**55. Prosthetic replacement of femoral head is usually indicated for**

(a) Fresh intracapsular fracture head of femur in old patients

- (b) Fresh intracapsular fracture of femoral neck in a young adult
  - (c) Unreduced posterior dislocation of hip
  - (b) Untreated femoral neck fracture in a patient over 65 years
  - (b) Pathological femoral neck fracture due to secondaries.
- PGI:1990*

**56. Vascular sign of Narath is noticed in**

- (a) Fracture neck of femur
  - (b) Perthes disease
  - (c) Posterior dislocation of hip
  - (d) All of the above.
- NATIONAL BOARD: 1991*

**57. In spondylarthritidis all are true except**

- (a) 50% of seronegative cases have HLA B27
  - (b) May be preceded by Urethritis
  - (c) SLE causes erosion of cartilage
  - (d) Have a greatly increased incidence of Psoriatic arthritis.
- NIMS:1991*

**58. Treatment of choice for a 4 week old femoral neck fracture in a 55 years old male is**

- (a) Open reduction and internal fixation
  - (b) Mac Murray's osteotomy
  - (c) Hemi replacement arthroplasty
  - (d) Total hip replacement
- RAJASTHAN: 1991*

**59. Commonest complication of Trans-cervical fracture of femur is**

- (a) Non union
- (b) Malunion
- (c) Avascular necrosis
- (d) All of the above.

**60. The commonest hip injury in the elderly patients is**

- (a) Stress #
- (b) Extracapsular #

- (c) Impacted # neck of femur  
 (d) Sub capital capsular fracture neck of femur.
- 61. Fracture femur in children is treated by**
- (a) Open reduction  
 (b) Gallow's splint  
 (c) Intra medullary nailing  
 (d) Closed reduction & splintage.
- 62. Which is true about dislocation of hip joint?**
- (a) Posterior dislocation is commoner  
 (b) In posterior dislocation whole lower limb is rotated medially  
 (c) In anterior dislocation whole lower limb is rotated laterally  
 (d) All of the above.

## ANSWERS

- |         |         |         |         |
|---------|---------|---------|---------|
| 1. (a)  | 2. (a)  | 3. (b)  | 4. (d)  |
| 5. (c)  | 6. (d)  | 7. (c)  | 8. (d)  |
| 9. (b)  | 10. (b) | 11. (b) | 12. (c) |
| 13. (c) | 14. (a) | 15. (d) | 16. (a) |
| 17. (c) | 18. (b) | 19. (a) | 20. (a) |
| 21. (b) | 22. (b) | 23. (c) | 24. (c) |
| 25. (c) | 26. (b) | 27. (b) | 28. (b) |
| 29. (c) | 30. (c) | 31. (b) | 32. (a) |
| 33. (d) | 34. (a) | 35. (c) | 36. (b) |
| 37. (c) | 38. (c) | 39. (b) | 40. (d) |
| 41. (a) | 42. (c) | 43. (a) | 44. (d) |
| 45. (b) | 46. (b) | 47. (d) | 48. (c) |
| 49. (a) | 50. (b) | 51. (c) | 52. (c) |
| 53. (d) | 54. (c) | 55. (d) | 56. (c) |
| 57. (d) | 58. (c) | 59. (a) | 60. (b) |
| 61. (b) | 62. (d) |         |         |



- 1. Which of the following causes acute compartment syndrome most frequently**
  - (a) Fractures.
  - (b) Postischemic swelling.
  - (c) Exercise initiated syndrome
  - (d) Soft tissue injury

*PGI.80, AIIMS.86*
- 2. In transverse fracture of the patella, the treatment is**
  - (a) Excision of a small fragment
  - (b) Wire fixation
  - (c) Plaster cylinder
  - (d) Patellectomy

*AIIMS 87, Kerala 87*
- 3. A comminuted fracture of the Patella should be treated by**
  - (a) Inserting screws and wires
  - (b) Physiotherapy alone
  - (c) Removal of all the patella
  - (d) Removal of smallest piece only
  - (e) Plastering & Immobilization.

*BIHAR.1989*
- 4. Non union is a common feature of fracture of**
  - (a) Supracondylar humerus
  - (b) Clavicle
  - (c) Lower tibia
  - (d) Coracoid process

*DELHI.1989*
- 5. A patient develops compartment syndrome (Swelling, pain and numbness) following manipulation and plaster for fracture of both bones of leg. What is the best treatment?**
  - (a) Split the plaster
  - (b) Infusion of low molecular weight dextran
  - (c) Elevate the leg after splitting the plaster
  - (d) Do operative decompression of fascial compartment.



**6. Compartmental syndrome is treated by**

- (a) Fasciotomy
- (b) Bicarbonate
- (c) Chloride rich fluid
- (d) Early aggressive fluid

*UP : 1999*

**7. In fracture neck of fibula, the following nerve is involved**

- (a) Common peroneal nerve
- (b) Anterior tibial nerve
- (c) Posterior tibial nerve
- (d) Medial popliteal nerve

*NIMS : 2000*

**8. Club foot with hypoplasia of calf muscles with inability to extend knee and hips is seen in**

- (a) Arthrogyrosis
- (b) Congenital dislocation of hip
- (c) Congenital myotonia
- (d) Still's disease
- (e) Reiter's disease

*PGI:1990*

**9. Healing below knee joint is slow because of**

- (a) Decreased subcutaneous fat
- (b) Increased movement
- (c) Weight bearing
- (d) Poor vascularity

*JIPMER:1991*

**10. The classical example of muscular violence is**

- (a) # of fibula
- (b) # of patella
- (c) # of clavicle
- (d) All of these.

**11. Transverse fracture of the patella with separation of fragments is best treated by**

- (a) Closed reduction with cylinder cast
- (b) Open reduction with screw fixation of the fragments
- (c) Blind fixation of the two fragments with Kirschner wire
- (d) Open reduction with Kirschner wire fixation of the fragment and tension band wiring.

## ANSWERS

- |        |         |         |        |
|--------|---------|---------|--------|
| 1. (a) | 2. (b)  | 3. (c)  | 4. (c) |
| 5. (d) | 6. (a)  | 7. (a)  | 8. (a) |
| 9. (d) | 10. (b) | 11. (d) |        |

## 20

### INJURIES OF THE ANKLE AND FOOT

- One of the following fracture requires plaster of paris cast with equinus position**
  - Distal fracture both bones leg
  - Distal fracture fibula
  - Bimalleolar
  - Fracture Talus

*PAL.96*
- Fatigue fractures (Stress fractures) are most commonly seen in**
  - Metatarsals
  - Tibia
  - Fibula
  - Neck of femur

*BIHAR.1989*
- Cotton's fracture is**
  - Avulsion fracture of  $C_7$
  - Trimaoleolar
  - Bimalleolar
  - Burst fracture of atlas
  - None of these

*BIHAR.1989*
- Fracture involving both the malleoli is**
  - Cotton's fracture
  - Potts's fracture

- (c) Pirogoff's fracture
- (d) Dupuytren's fracture.

*NIIMS:1992*

**5. Fall on heel with fracture os calcis is associated with commonly**

- (a) Fracture clavicle
- (b) Fracture vertebra
- (c) Fracture femur
- (d) Posterior dislocation of hip

*DELHI: 1992*

**6. What is March fracture?**

- (a) Fracture of 2<sup>nd</sup> metatarsal
- (b) Fracture of 4<sup>th</sup> metatarsal
- (c) Fracture of cuboids
- (d) Fracture of tibia

**7. The usual site of stress fracture includes**

- (a) Tibia
- (b) First metacarpal bone
- (c) Second metacarpal bone
- (d) Second metatarsal bone

*TAMIL NADU : 1993*

**8. Stress fracture not involves**

- (a) Metatarsals
- (b) Metacarpals
- (c) Tibia
- (d) Calcaneum

*PGI : 2000*

**9. The mechanism of injury of transverse fracture of medial malleolus results due to**

- (a) Abduction injury
- (b) Adduction injury
- (c) Rotation injury
- (d) Direct injury

*ANDHRA:1999*

**10. Avascular necrosis is a complication of**

- (a) Fracture of talus
- (b) Fracture of medial condyle of femur

- (c) Olecranon fracture
- (d) Radial head fracture

ALL INDIA : 1999

**11. In which type of fracture, the tuber-joint angle is reduced to about half**

- (a) Crush fracture of calcaneum
- (b) Fracture neck of humerus
- (c) Dislocation of shoulder
- (d) Spilt fracture of calcaneum
- (e) Fracture neck of femur.

AMU:1990

**12. Pott's fracture is fracture of**

- (a) Lower end of tibia
- (b) Lower end of tibia + fibula
- (c) Lower end of tibia + Calcaneum
- (d) Calcaneum + Talus

PGI : 1991

**13. The commonest cause of pathological fracture is generalised affection is:**

- (a) Carcinoma
- (b) Osteoporosis
- (c) Cyst
- (d) All of the above.

### ANSWERS

- |         |         |         |         |
|---------|---------|---------|---------|
| 1. (d)  | 2. (a)  | 3. (b)  | 4. (b)  |
| 5. (b)  | 6. (a)  | 7. (d)  | 8. (b)  |
| 9. (c)  | 10. (a) | 11. (a) | 12. (b) |
| 13. (b) |         |         |         |

1. **Jefferson fracture occurs at**
  - (a) C1.
  - (b) C2.
  - (c) C1, C2.
  - (d) C2, C3.

*ALL INDIA:99*
  
2. **In spinal cord injury, the patient should be transferred with pad and bandage in the following position:**
  - (a) Supine
  - (d) Prone
  - (c) Lateral
  - (d) Semi prone

*ORISSA : 1988*
  
3. **Cause of atonic bladder is**
  - (a) Injury to sacral plexus
  - (b) Injury to upper thoracic cord
  - (c) Pregnancy
  - (d) UTI

*UPSC:1988*
  
4. **The compression fracture is commonest in**
  - (a) Cervical spine
  - (b) Upper thoracic spine
  - (c) Lower thoracic spine
  - (d) Lumbosacral region

*NATIONALBOARD:1992*
  
5. **Emergency treatment required in**
  - (a) Fracture humerus
  - (b) Fracture pelvis
  - (c) Comminuted fracture femur
  - (d) Fracture tibia & Fibula

*RAJASTAN:1992*
  
6. **Burst fracture of cervical spine is due to**
  - (a) Whiplash injury
  - (b) Fall of weight on neck

- (c) Vertical compression injury  
(d) Car accident *BIHAR.1989*
- 7. Spinal shock is associated with**  
(a) Increased spinal reflexes  
(b) Absent spinal reflexes  
(c) Loss of autonomic reflexes  
(d) Bizarre reflexes *AIIMS:1990*
- 8. Position for transport of a patient with fracture lumbar spine in a patient**  
(a) Neutral  
(b) Hyper flexion  
(c) Alternating  
(d) Hyperextension *DELHI: 1994*
- 9. A paralysed bladder following spinal injury is best managed by**  
(a) Gibbon's catheter  
(b) Malicot catheter  
(c) Foley's catheter  
(d) Metallic catheter *AIIMS : 1993*
- 10. Vertebral disc prolapse with intact vertebra commonest in**  
(a) Idiopathic  
(b) Malignancy  
(c) Trauma  
(d) Tuberculosis *DELHI : 1992*
- 11. Careless handling of a suspected case of cervical spine injury may result in**  
(a) Injury to the spinal cord leading to quadriplegia or quadriparesis  
(b) Intracranial haemorrhage with cerebral irritation or unconsciousness.  
(c) Cervical haematoma with compression of brachial vessels  
(d) Complete paralysis of the affected upper extremity *UPSC : 1999*

**12. In spinal shock**

- (a) Knee jerk is the first reflex to return
- (b) High thoracic lesions are commonly associated with more severely associated with more severe neurological deficits
- (c) Failure of return of cord activity within 48 hours in a very poor prognostic sign
- (d) Both B & C

*NIMHANS : 1999*

**13. Return of Bulbocavernous reflex in spinal shock**

- (a) Sign of recovery indicates from paraplegia
- (b) Partial lesion of spinal cord
- (c) Complete transection of spinal cord
- (d) Incomplete transection of spinal cord

*JIPMER : 1999*

**14. Dislocation without fracture is seen in**

- (a) Sacral spine
- (b) Lumbar spine
- (c) Cervical spine
- (d) Thoracic spine

*DELHI : 1999*

**15. True regarding Hangman's fracture is**

- (a) Odontoid process fracture of C2
- (b) Spondylolisthesis of C2 over C3
- (c) Whiplash injury
- (d) Fracture of hyoid bone

*MANIPAL : 2000*

**16. The most important step in primary management of a patient with fracture vertebral column**

- (a) Careful transport of patient
- (b) Maintenance of airway
- (c) Treatment of shock
- (d) None of the above

*PGI : 1994*

**17. Hangman's fracture is**

- (a) Subluxation of C5 over C6
- (b) Fracture dislocation of C2



- (c) Fracture dislocation of ankle joint  
(d) Fracture of odontoid *KARNATAKA:1998*
- 18. A patient presented with Saddle anaesthesia, bladder & bowel are normal and muscle power is normal. The diagnosis is**
- (a) Cauda equina syndrome  
(b) L3-L4 root involvement  
(c) Conus medullaris lesion  
(d) L4-L5 disc prolapse *NIMS:1998*
- 19. Fatigue fracture does not occur in**
- (a) Tibia  
(b) Calcaneum  
(c) Metatarsal  
(d) Metacarpal *PGI : 1998*
- 20. In case of unconscious patient spinal injury is assessed by**
- (a) Absence of response to painful stimulus  
(b) Absence of deep reflexes  
(c) Abdominal respiration  
(d) Spinal tenderness. *WEST BENGAL:1998*
- 21. A scooter is hit from behind. The rider is thrown off and he lands with his head hitting the kerb. He does not move, complains of severe pain in the neck and is unable to turn his head. Well-meaning onlookers rush up to him and try to make him sit up. What would be the best course of action in this situation?**
- (a) He should be propped up and given some water to drink  
(b) He should not be propped up but turned on his face and rushed to the hospital  
(c) He should be turned on his back and a support should be placed behind his neck and transported to the nearest hospital  
(d) He should not be moved at all but carried to the nearest hospital in the same position in which he has been since his fall. *UPSC : 1997*

22. Stress fracture is treated by

- (a) Rest
- (b) Cast immobilisation
- (c) Closed reduction
- (d) Internal fixation

DELHI : 1990

23. In ulnar nerve palsy, structure paralysed is

- (a) All lumbricals
- (b) Interossei
- (c) Sensation on medial aspect of fingers
- (d) Adductor pollicis

DELHI : 1990

24. Regarding whiplash injury, a true statement includes

- (a) Contusion of the spinal cord and fracture of vertebra
- (b) Fracture of vertebral body
- (c) Spinal cord injury without vertebral fracture
- (d) Vertebral fracture without spinal cord injury

ANDHRA:1991

25. The commonest cause of spinal cord injuries in our country is:

- (a) Road traffic accident
- (b) Fall from a height
- (c) Fall into well
- (d) House collapse.

### ANSWERS

- |         |         |           |           |
|---------|---------|-----------|-----------|
| 1. (a)  | 2. (a)  | 3. (a)    | 4. (c)    |
| 5. (c)  | 6. (c)  | 7. (b,c)  | 8. (a)    |
| 9. (c)  | 10. (a) | 11. (a)   | 12. (b)   |
| 13. (a) | 14. (c) | 15. (b)   | 16. (b)   |
| 17. (b) | 18. (c) | 19. (d)   | 20. (a,c) |
| 21. (c) | 22. (b) | 23. (b,d) | 24. (c)   |
| 25. (b) |         |           |           |

1. **Late complication of Acetabular fracture**
  - (a) Avascular necrosis of head of femur.
  - (b) Avascular necrosis of iliac crest
  - (c) Fixed deformity of the hip joint.
  - (d) Secondary osteoarthritis of hip joint *PGI.97*
  
2. **In pelvis fracture, the amount of blood loss is around**
  - (a) 1-4 units
  - (b) 2-4 units
  - (c) 2-6 units
  - (d) 4-8 units *TAMIL NADU : 1999*
  
3. **If a patient with a suspected fracture of the pelvis has some bleeding from the urethra and is unable to pass urine**
  - (a) He should be encouraged to pass urine after being given antibiotics and analgesics
  - (b) He should be immediately catheterized in the ward
  - (c) A hot water bottle should be given followed by injection of carbachol
  - (d) He should be prepared for surgery and catheterization attempted in the O.T. *UPSC : 1997*

**ANSWERS**

1. (d)                      2. (d)                      3. (d)

1. Patients comes with fracture femur in an acute accident, the first things to do is
  - (a) Secure airway and treat the shock.
  - (b) Splinting.
  - (c) Physical examination.
  - (d) X-rays. *PGI.86*
  
2. In an injury with multiple fractures, most important is
  - (a) Airway maintenance
  - (b) Blood transfusion
  - (c) Intravenous fluids
  - (d) Open reduction of fractures. *DELHI.1988*
  
3. The correct order of priorities in the initial management of head injury is
  - (a) Airway, Breathing, Circulation Treatment of extra cranial injuries
  - (b) Treatment of extra cranial injuries Airway, Breathing, Circulation
  - (c) Circulation, Airway, Breathing Treatment of extra cranial injuries
  - (d) Airway, Circulation, Breathing Treatment of extra cranial injuries *CSE : 1999*
  
4. Consider the following sign (S)
  - (1) Increasing pallor
  - (2) Restlessness
  - (3) Air hunger
  - (4) Water-hammer pulse

Haemorrhagic shock due to acute blood loss includes

  - (a) 1 & 4
  - (b) 1 & 2
  - (c) 1,2 & 3
  - (d) 2,3 & 4 *CSE : 1999*

## ANSWERS

1. (a)                      2. (a)                      3. (a)                      4. (c)

# 24

## COMPOUND FRACTURES

### 1. Compound Fracture is

- (a) Fracture with artery involvement
- (b) Fracture with nerve involvement
- (c) Fracture with muscle involvement
- (d) Fracture with skin involvement

*DELHI:1988*

### 2. In shotgun injuries

- (a) Each and every shot should be removed
- (b) All the shots within accessible limits may be removed and thorough debridement of the tissue done
- (c) Shots lodged in joints must be removed
- (d) All the above are true

### 3. Tetanus is noticed usually in

- (a) Burn cases
- (b) Wounds contaminated with faecal matter
- (c) Open fractures
- (d) Gunshot wounds
- (e) All of the above.

### 4. Following are principles in the treatment of compound fractures except

- (a) Wound debridement
- (b) Immediate wound closure
- (c) Tendon repair
- (d) Aggressive antibiotic therapy

*JIPMER:1993*

5. A patient presents with compound fracture of Tibia with 1 cm opening in skin. Which grade it belongs?

- (a) Grade I
- (b) Grade II
- (c) Grade IIIA
- (d) Grade IIIB

*JIPMER : 2000*

6. Which of the following is the most appropriate hospital treatment of a patient with compound fracture?

- (a) Under anesthesia, thorough scrubbing and cleaning of the area getting the fracture end inside, suturing the wound and applying continuous skeletal traction with adequate antibiotic cover
- (b) Cleaning and suturing the wound, applying plaster Spica under traction on a Harly's table and administering antibiotics round the clock.
- (c) Scrubbing and cleaning the area, resecting the protruding one inch of the bone, suturing the wound, bringing the fractured ends into alignment and applying plaster Spica with continuous antibiotic cover.
- (d) Thorough cleaning of the area, extending the wound, bringing the fragments into alignment under vision, fixing them with intra-medullary nail and giving antibiotics to the patient. *UPSC : 1999*

7. Internal splints are used in all except

- (a) Compound fractures
- (b) Multiple fractures
- (c) Fractures in elderly patients
- (d) Fracture neck of femur

*MANIPAL : 1999*

8. Open fracture is treated by

- (a) Tourniquet
- (b) Internal fixation
- (c) Debridement
- (d) External fixation

*UP : 1998*



9. A compound fracture is initially treated by antibiotics, wound toilet and
- Skin cover
  - External splintage
  - Prosthesis
  - Internal fixation
10. Immediate treatment of compound fracture of tibia is
- Intravenous antibiotics
  - Thorough irrigation of wound with saline and splintage
  - Wound debridement
  - Internal fixation of fracture *DELHI: 1997*
11. Symmetrical multiple spontaneous fractures occur in
- Milk man syndrome
  - Osteogenesis imperfecta
  - Rickets
  - Scurvy *AIIMS : 1992*

### ANSWERS

- |        |         |         |         |
|--------|---------|---------|---------|
| 1. (d) | 2. (b)  | 3. (b)  | 4. (b)  |
| 5. (a) | 6. (a)  | 7. (a)  | 8. (cd) |
| 9. (b) | 10. (b) | 11. (b) |         |

# 25

## SOFT TISSUE INJURIES INCLUDING SPORTS INJURIES

1. Which of the following is correct in medical meniscus tear
- Rotation of femur on tibia
  - Mensici do not heal
  - Locking and unlocking episodes

- (d) Menisci should be excised  
(e) All of the about are correct *JIPMER 87,Kerala 87*
- 2. Best diagnostic procedure for ant. cruciate ligament injury is**  
(a) Lachman's test  
(b) Pivot shift test  
(c) Anterior drawer test  
(d) Mc Murray's test *JIPMER 2002*
- 3. Lachman test is positive in**  
(a) Anterior cruciate ligament injury  
(b) Posterior Cruciate ligament injury  
(c) Medial meniscus injury  
(d) Lateral meniscus injury *DELHI.1988*
- 4. The most common site for ligamentous injuries are those of the**  
(a) Shoulder joint  
(b) Elbow  
(c) Knee joint  
(d) Ankle joint *ANDHRA:1999*
- 5. Injury to the medial meniscus is rather impossible when the knee joint does not**  
(a) Extend  
(b) Flex  
(c) Rotate  
(d) Abduct Adduct *NATION BOARD:1989*
- 6. All of the following features in the knee are recognized to be consistent with a torn medial meniscus, except**  
(a) Excessive forward glide  
(b) Giving way  
(c) Locking  
(d) Mc. Murray's sign. *MANIPAL : 1994*



7. Investigation for injury of knee cartilage
- (a) Aspiration
  - (b) Arthrography
  - (c) X-ray
  - (d) Arthroscopy *AIIMS:1994*
8. Which is the investigation of choice for a sport injury of the knee?
- (a) Ultrasonography
  - (b) Plain radiography
  - (c) Arthrography
  - (d) Arthroscopy *ANDHRA:1993*
9. Drawer sign seen in
- (a) Cruciate ligament injury
  - (b) Scurvy
  - (c) Perthes's disease
  - (d) Hyperparathyroidism *RAJASTHAN:1992*
10. Athletic sustained an injury around the knee joint suspecting cartilage damage, which of the following is an investigation of choice ?
- (a) Pain X ray
  - (b) Clinical examination
  - (c) Arthroscopy
  - (d) Arthrotomy *ANDHRA : 2000*
11. Ruptured tendon is most commonly seen in
- (a) Stab injury
  - (b) Soft Tissue tumour
  - (c) Over use
  - (d) Congenital defect *ALL INDIA ; 2000*
12. In Neuronotemesis, the following statement is correct
- (a) There is only a physiological disruption, but anatomically the nerve is intact
  - (b) Only the Axon sheath is damaged
  - (c) Axonal sheath and supporting cells are damaged
  - (d) Axon and Axon sheaths are damaged. *NIMS : 2000*

13. **The most common type of mode of meniscal injury is**  
(a) Extensio of knee  
(b) Flexion of knee  
(c) Flexion and rotation movement  
(d) Extension and rotation of movement. *ANDHRA:1999*
14. **Injury around the ankle joint occurs at**  
(a) Inversion of foot  
(b) Eversion of foot  
(c) Internal rotation of foot  
(d) External rotation of foot *BIHAR:1999*
15. **The most common ligament injured around ankle joint is**  
(a) Anterior talofibular  
(b) Deltoid ligament  
(c) Posterior talofibular  
(d) Spring ligament *ALL INDIA.1998*
16. **Bucket handle tear at knee joint is due to**  
(a) Injury to medial collateral ligament  
(b) Injury to lateral collateral ligament  
(c) Injury to ligamentum patellae  
(d) Injury to menisci *ORISSA: 1991*
17. **Which of the following statement is / are true?**  
(a) Acute Osteomyelitis is common in children  
(b) Osteogenic sarcoma and Ewing's tumour occur commonly in 2<sup>nd</sup> decade  
(c) Ewing's tumour arises from the diaphysis of long bones  
(d) All of these.
18. **A patient gives a H/O twisting strain and locking of the knee joint, the most likely diagnosis is:**  
(a) Avulsion f tibial tubercle  
(b) Meniscal tear  
(c) Tearing of lateral collateral ligament  
(d) Tear of anterior cruciate ligament.

## ANSWERS

- |         |         |         |          |
|---------|---------|---------|----------|
| 1. (e)  | 2. (a)  | 3. (a)  | 4. (d)   |
| 5. (c)  | 6. (a)  | 7. (d)  | 8. (d)   |
| 9. (a)  | 10. (c) | 11. (c) | 12. none |
| 13. (c) | 14. (b) | 15. (a) | 16. (d)  |
| 17. (d) | 18. (b) |         |          |

## 26

### NERVE INJURIES

- Tardy ulnar nerve palsy is due to;**
  - Cubitus valgus.
  - Fixation of nerve in the groove by osteoarthritis.
  - Excision of elbow joint
  - Fracture of internal condyle *UPSC.86, KERALA.87*
- Tardy ulnar nerve palsy is seen with**
  - Lateral humeral condyle fracture.
  - Supracondylar fracture
  - Medial humeral condyle fracture.
  - Fracture capitulum *AIIMS.91*
- A Patient presented with claw hand after a Supracondylar fracture was reduced and plaster applied. The diagnosis is;**
  - Median Nerve injury.
  - Volkman's ischaemic contracture
  - Ulnar nerve injury.
  - Dupuytren's contracture *ALL INDIA.92*
- The "Card Test" tests the function of**
  - Median nerve.
  - Ulnar nerve.

(c) Axillary nerve.

(d) Radial nerve

*UPSC.95*

**5. Dislocation of which one of the following carpal bones can present as median nerve palsy?**

(a) Scaphoid.

(b) Hamate.

(c) Lunate.

(d) Trapezium

*UPSC.95*

**6. Cock up splint is used in management of**

(a) Ulnar nerve palsy.

(b) Brachial plexus palsy.

(c) Radial nerve palsy

(d) Combined ulnar & Median nerve palsy

*AIIMS.95*

**7. Injury of median nerve at wrist is best detected by**

(a) Action of abductor pollicis brevis.

(b) Action of flexor pollicis brevis

(c) Loss of sensation of radial half of palm

(d) Loss of sensation of tip of ring finger *ALL INDIA 97*

**8. Non Dynamic splint is :**

(a) Banjo

(b) Opponens

(c) Cock up

(d) Brand

*PGI 87*

**9. Pointing index sign is seen in ..... nerve palsy**

(a) Ulnar

(b) Radial

(c) Median

(d) Axillary

*UPSC 86, Kerala 87*

**10. Commonest cause of wrist drop is**

(a) Intramuscular injection

(b) Fracture humerus

(c) Dislocation of elbow

(d) Dislocation of shoulder

- 11. The lesion in Klumpke's paralysis is at**  
(a) Cervical plexus  
(b) Lower brachial  
(c) Upper brachial  
(d) Sacral Plexus *AP 88*
- 12. The mode of injury of Klumpke's paralysis is**  
(a) Forcible increase in the neck shoulder angle (as during child birth)  
(b) Forcible rotation of upper arm  
(c) Forcible hyperabduction of upper arm (Falling person trying to catch an object). *BIHAR : 1988*
- 13. Injury to which of the following nerves is most likely to result in Wrist drop?**  
(a) Radial  
(b) Ulnar  
(c) Median  
(d) Musculocutaneous
- 14. Legg-Calve-Perthe's disease is commonly seen in the age group of**  
(a) 1-3 years  
(b) 3-10 years  
(c) 10-20 years  
(d) 20 years & above. *ALL INDIA: 1989*
- 15. Saturday night palsy involves nerve**  
(a) Radial  
(b) Ulnar  
(c) Median  
(d) Axillary  
(e) Any of the above. *AMC. 1989*
- 16. After injury to Radial nerve in radial groove, first sign of recovery is**  
(a) Tinel's sign  
(b) Power in Extensor corpi radialis longus

- (c) Power in Brachioradialis  
 (d) Power in Triceps *AIIMS, 1989*
- 17. In fracture of distal half of humerus, the nerve injured is**  
 (a) Axillary  
 (b) Median  
 (c) Radial  
 (d) Ulnar *ESI, 1989*
- 18. In Seddon's classification, complete division of nerve is**  
 (a) Neuropraxia  
 (b) Axonotmesis  
 (c) Neurotmesis  
 (d) None of the above. *ROHTAK, 1989*
- 19. Anterior interosseous nerve is a branch of**  
 (a) Musculocutaneous  
 (b) Radial  
 (c) Median  
 (d) Ulnar *ALL INDIA, 1989*
- 20. Froment's sign is present in paralysis of ..... injury.**  
 (a) Ulnar  
 (b) Radial  
 (c) Median  
 (d) Axillary *DELHI 1994*
- 21. Which of the following nerve injuries produce the deformities?**
- |                     |                                |
|---------------------|--------------------------------|
| I. Upper trunk      | I. Wrist drop                  |
| II. Ulnar nerve     | II. Porter's tip hand          |
| III. Axillary nerve | III. Claw hand                 |
| IV. Radial nerve    | IV. Flattening of the shoulder |
- |           |          |           |         |
|-----------|----------|-----------|---------|
| A I (i)   | II (ii)  | III (iii) | IV (iv) |
| B I (ii)  | II (iii) | III (iv)  | IV (i)  |
| C I (iii) | II (iv)  | III (ii)  | IV (i)  |
| D I (iv)  | II (iii) | III (ii)  | IV (i)  |
- DNB 1993*

22. Which of the following nerve is most often damaged in fracture of shaft of humerus  
(a) Ulnar  
(b) Median  
(c) Radial  
(d) Axillary *PGI:1993*
23. Following indicate better prognosis is in injury except  
(a) Neuroproxia  
(b) Younger age  
(c) Pure motor nerve injury  
(d) Proximal injury *JIPMER 1993*
24. Meralgia Paraesthetica involves  
(a) Axillary nerve  
(b) Sural nerve  
(c) Median Nerve  
(d) Lateral cutaneous nerve of thigh. *DNB 1993*
25. Find the wrong match  
(a) Ankylosing spondylitis – Lumbosacral spine involved  
(b) Intervertebral disc prolapse – Sensory deficit  
(c) Pott's spine – Tuberculosis  
(d) Saturday night palsy – Radial nerve palsy in wrist. *UPSC.1992*
26. Median nerve is injured during  
(a) Elbow dislocation  
(b) Fracture lateral epicondyle of humerus  
(c) Fracture medial epicondyle of humerus  
(d) Supracondylar fracture of humerus *JIPMER : 2000*
27. Feature of radial nerve injury at spiral groove  
(a) No wrist drop  
(b) Sensory loss over deltoid  
(c) Thumb, finger, wrist drop  
(d) Wrist drop + Extensors of Forearm paralysis *TAMIL NADU : 1999\**



- 28. Erb's palsy is due to involvement of**
- Upper trunk of brachial plexus
  - Middle trunk of brachial plexus
  - Lower trunk of brachial plexus
  - Long thoracic nerve
- UP : 1999*
- 29. Claw hand is seen in**
- Cervical rib
  - Carpal tunnel syndrome
  - Multiple sclerosis
  - Ulcer nerve injury
- NATIONAL BOARD: 1999*
- 30. Which one of the following statement is wrong about Erb's palsy?**
- Abductors of the shoulder are weak
  - Upper part of brachial plexus is involved
  - Supinators are normal
  - Internal rotation of arm
- NIIMS : 2000*
- 31. In Neurotmesis, the following statement is correct**
- There is only a physiological disruption, but anatomically the nerve is intact
  - Only the Axon sheath is damaged
  - Axonal sheath and supporting cells are damaged
  - Axon and Axon sheaths are damaged
- NIMS : 2000*
- 32. Erb's point is located at the junction of**
- Anterior primary rami of C5 and C6
  - Anterior primary rami of C8 and T1
  - Superior and middle trunk of Brachial plexus
  - None of the above.
- 33. Match the following:**
- |                                       |                            |
|---------------------------------------|----------------------------|
| (i) Erb's paralysis                   | (i) Lower trunk injury     |
| (ii) Klumpke's paralysis              | (ii) Axillary nerve injury |
| (iii) Crutch paralysis                | (iii) Radial nerve injury  |
| (iv) Fractures surgical neck humerus. | (iv) Uper trunk injury     |



|   |         |          |           |         |
|---|---------|----------|-----------|---------|
| A | I (iv)  | II (iii) | III (ii)  | IV (i)  |
| B | I (iii) | II (ii)  | III (iv)  | IV (i)  |
| C | I (iv)  | II (i)   | III (iii) | IV (ii) |
| D | I (i)   | II (iii) | III (iv)  | IV (ii) |

NATIONAL BOARD: 1999

**34. Consider the following nerve injuries**

- (1) Axonotmesis
- (2) Neurotmesis
- (3) Neuropraxia

The Correct sequence of these injuries in terms of 'increasing' severity of damage to the nerve fibres and sheath, is

- (a) 1,2 and 3
- (b) 3,2 and 1
- (c) 2,1 and 3
- (d) 3,1 and 2

CSE : 1999

**35. Following an incised wound in the front of wrist, the subject is unable to oppose the tips of the little finger and the thumb. The nerve (s) involved is / are**

- (a) Ulnar nerve alone
- (b) Median nerve alone
- (c) Median and ulnar nerves
- (d) Radial and ulnar nerves

UPSC:2000

**36. The nerve roots involved in Erb's palsy are**

- (a) C3 C4
- (b) C4 C5
- (c) C5 C6
- (d) C6 C7

TAMIL NADU : 1994

**37. Radial nerve is most commonly injured in fracture of**

- (a) Mid shaft of humerus
- (b) Neck of humerus
- (c) Lateral condyle of humerus
- (d) Lower  $\frac{1}{3}$ <sup>rd</sup> of humerus

UP : 1994

38. "Ulnar paradox" is related with the following

- (a) Lumbricals
- (b) Intrinsic muscle
- (c) EPL
- (d) Ulnar half of FDP

UP : 1994

39. Wrist drop results in injury of

- (a) Ulnar nerve
- (b) Median nerve
- (c) Posterior interosseus nerve
- (d) Radial nerve

UP 1994

40. Match the following

- I. Erb's paralysis
- II. Klumpke's paralysis
- III. Crutch paralysis
- IV. Fracture surgical neck humerus
- (i) Lower trunk injury
- (ii) Axillary nerve injury
- (iii) Radial nerve injury
- (iv) Upper trunk injury

- |            |          |           |         |
|------------|----------|-----------|---------|
| A. I (iv)  | II (iii) | III (ii)  | IV (i)  |
| B. I (iii) | II (ii)  | III (iv)  | IV (i)  |
| C. I (iv)  | II (i)   | III (iii) | IV (ii) |
| D. I (i)   | II (iii) | III (iv)  | IV (ii) |

NATIONAL BOARD:1998

41. Median nerve injury at the wrist causes

- (a) Claw hand
- (b) Loss of apposition of thumb
- (c) Policeman's tip deformity
- (d) Saturday night palsy

PGI:1998

42. Ulnar nerve injury at wrist results in

- (a) Unable to grasp card between the fingers
- (b) Claw hand
- (c) Inability to abduct or adduct the fingers
- (d) All of the above.

MANIPAL:1997

43. In a full term newly born male baby, on routine check up soon after delivery has weak Moro's reflex on right hand but intact Grasp's reflex with weak abduction and supination movement of hand is found. This will suggest that most likely injury would be at
- (a) C<sub>5,6</sub> nerve.
  - (b) C<sub>7</sub>,C<sub>8</sub> nerve
  - (c) C<sub>8</sub>,T<sub>1</sub> nerve
  - (d) T<sub>1</sub>,T<sub>2</sub> nerve.
- AIIMS : 1999*
44. A 25-year-old lady sustained a lacerated wound on the back of right thigh by a horn of a bull. The wound was sutured. Two months later she developed foot drop and an ulcer on the dorsum of the foot. The most likely diagnosis is
- (a) Chronic ischaemia to limbs due to Popliteal artery injury
  - (b) Partial injury to sciatic nerve
  - (c) Complete division of sciatic nerve
  - (d) Injury to hamstring muscles
- UPSC:1997*
45. Nerve suturing in a clean cut injury is done best in
- (a) 6 hours
  - (b) 12 hours
  - (c) After one day
  - (d) After two day.
- DELHI:1990*
46. Tourniquet paralysis is an unfortunate complication leads to
- (a) Neuropraxia
  - (b) Axonotmesis
  - (c) Neurotmesis
  - (d) None of the above
- KARNATAKA : 1990*
47. Prognosis after secondary nerve suturing is better in pure than in mixed ones. Based on this criterion, which one of the following nerves should be given the best result after suturing in identical conditions?

- (a) Common peroneal nerve
- (b) Radial nerve
- (c) Ulnar nerve
- (d) Median nerve

*KARNATAKA:1990*

**48. Disability of hands is maximum with a lesion of**

- (a) Median nerve at elbow
- (b) Median nerve at wrist
- (c) Ulnar nerve at elbow
- (d) Ulnar nerve at wrist
- (e) Radial nerve lesion.

*PGI:1990*

**49. Following structures pass through spiral groove of humerus**

- (a) Radial nerve
- (b) Radial artery
- (c) Anterior circumflex humeral artery
- (d) Posterior circumflex humeral artery
- (e) Arteria profunda brachii

*PGI:1990*

**50. Injury to radial nerve – mid humerus level following occurs**

- (a) Paralysis of extensors of hand and wrist
- (b) Equally diagnosed by sensory and motor testing
- (c) Can be approached by a lifting triceps
- (d) Can be approached by splitting latissimus dorsi
- (e) Paralysis of Triceps

**51. Section of lateral Popliteal nerve at the neck of fibula causes**

- (a) Foot drop
- (b) Trophic ulcers on toes
- (c) Atrophy of calf muscle
- (d) Pain in the leg

*PGI:1990*

**52. Rate of regeneration of severed nerve is**

- (a) 0.1 mm/day
- (b) 1 mm / day

(c) 1 cm/day

(d) None.

ANDHRA:1991

**53. "Tinel's sign" indicates**

(a) Neurofibroma

(b) Injury to peripheral nerves

(c) Atrophy of nerves

(d) Regeneration of nerves.

BIHAR:1991

**54. 'Ape thumb deformity' is observed in lesions of**

(a) Radial nerve injury

(b) Ulnar nerve injury

(c) Median nerve injury

(d) Circumflex humeral nerve injury

(e) Posterior interosseous nerve injury

BIHAR:1991

**55. Cock's splint is used in**

(a) Radial nerve palsy

(b) Ulnar nerve palsy

(c) Median nerve palsy

(d) Dupuytren's Contracture

DELHI:1991

**56. Ulnar nerve severed above elbow causes**

(a) Complete loss of sensation in 4<sup>th</sup> and 5<sup>th</sup> finger

(b) Paralysis of all lumbricals

(c) Paralysis of all interossei

(d) Paralysis of flexor carpi ulnaris

(e) Paralysis of flexor profundus

PGI : 1991

**57. Foot drop result because of injury to**

(a) Superficial peroneal nerve

(b) Deep peroneal nerve

(c) Posterior tibial nerve

(d) Anterior tibial nerve

PGI : 1991

**58. A factory worker has laceration proximal to wrist with no opposition of thumb and fingers, loss of sensation over lateral aspect of thumb and fingers. Diagnosis is injury to**

(a) Median nerve + Ulnar nerves

- (b) Median + Radial nerves
- (c) Radial + Ulnar nerves
- (d) Median nerve only

*UPSC : 1991*

**59. Claw hand occurs in**

- (a) Volkmann's ischaemic Contracture
- (b) Dupuytren's Contracture
- (c) Ulnar nerve injury
- (d) Sudeck's atrophy

*ALL INDIA : 1991*

**60. Best results of nerve suturing are seen in**

- (a) Median nerve
- (b) Ulnar nerve
- (c) Sciatic nerve
- (d) Radial nerve

*AMC:1992*

**ANSWERS**

- |          |         |          |            |
|----------|---------|----------|------------|
| 1. (a)   | 2. (a)  | 3. (b)   | 4. (b)     |
| 5. (c)   | 6. (c)  | 7. (a)   | 8. (c)     |
| 9. (c)   | 10. (b) | 11. (b)  | 12. (c)    |
| 13. (a)  | 14. (b) | 15. (a)  | 16. (a)    |
| 17. (c)  | 18. (c) | 19. (c)  | 20. (a)    |
| 21. (b)  | 22. (c) | 23. (d)  | 24. (d)    |
| 25. (d)  | 26. (a) | 27. (c)  | 28. (a)    |
| 29. (d)  | 30. (c) | 31. None | 32. (a)    |
| 33. (c)  | 34. (d) | 35. (c)  | 36. (c)    |
| 37. (a)  | 38. (b) | 39. (d)  | 40. (c)    |
| 41. (b)  | 42. (d) | 43. (a)  | 44. (b)    |
| 45. (a)  | 46. (a) | 47. (b)  | 48. (d)    |
| 49. (ae) | 50. (a) | 51. (a)  | 52. (b)    |
| 53. (d)  | 54. (c) | 55. (a)  | 56. (bcde) |
| 57. (b)  | 58. (a) | 59. (c)  | 60. (d)    |

1. **Mc. Murray's sign is seen in injury to**  
(a) Medial meniscus  
(b) Medial collateral ligament  
(c) Anterior cruciate ligament  
(d) Posterior cruciate ligament *UPSC.1988*
2. **Distance from Olecranon in amputation should be**  
(a) 5-10 cm  
(b) 10-15 cm  
(c) 15-20 cm  
(d) 20-30 cm
3. **Ring sequestrum is seen in**  
(a) Typhoid osteomyelitis  
(b) Chronic osteomyelitis  
(c) Amputation stump  
(d) Tuberculosis osteomyelitis *TAMIL NADU:1992*
4. **In flap method of amputation which structure is kept shorter than the level of amputation:**  
(a) Bone  
(b) Muscles  
(c) Nerves  
(b) Skin  
(e) Vessels *NATIONAL BOARD :1992*

## ANSWERS

1. (a)                      2. (a)                      3. (c)                      4. (a)



# LATEST QUESTIONS

## AIIMS: NOVEMBER 2002

- 1. Medical meniscus of the knee joint is injured more often than the lateral meniscus because the medial meniscus is relatively:**
  - (a) More mobile
  - (b) Less mobile
  - (c) Thinner
  - (d) Attached lightly to femur
- 2. Which of the following is not a component of the crush syndrome:**
  - (a) Myohemoglobinuria
  - (b) Massive crushing of muscles
  - (c) Acute tubular necrosis
  - (d) Bleeding diathesis
- 3. A 40 year old man was repairing his wooden shed on Sunday morning. By afternoon, he felt that the hammer was becoming heavier and heavier. He felt pain in the lateral side of elbow and also found that squeezing water out of sponge hurt his elbow. Which of the muscles are most likely involved:**
  - (a) Biceps brachii and supinator
  - (b) Flexor digitorum superficialis
  - (c) Extensor carpi radialis longus and brevis
  - (d) Triceps brachii and anconeus.
- 4. In dislocation of the jaw, displacement of the articular disc beyond the articular tubercle of the temporomandibular joint results from spasm or excessive contraction of the following muscle:**
  - (a) Buccinator
  - (b) Lateral pterygoid
  - (c) Masseter
  - (d) Temporalis

5. The classical flexion and rotation deformities at hip and knee joints, as a sequelae of poliomyelitis are due to the contracture of:
- (a) Tensor fascia lata
  - (b) Gastrocnemius
  - (c) Tendo Achilles
  - (d) Hamstrings
6. What would be the most reliable test for an acutely injured knee of a 27 year old athlete:
- (a) Anterior drawer test
  - (b) Posterior drawer test
  - (c) Lachman test
  - (d) Steinmann test
7. A 11 year old boy presented with the complaints of pain in the right arm near the shoulder. X-ray examination revealed an expansile lytic lesion in the upper third of humerus. The most likely diagnosis is:
- (a) Giant cell tumour
  - (b) Unicameral bone cyst
  - (c) Osteochondroma
  - (d) Parosteal osteosarcoma
8. Which activity will be difficult to perform for a patient with an anterior cruciate deficient knee joint?
- (a) Walk downhill
  - (b) Walk uphill
  - (c) Sit cross leg
  - (d) Getting up from sitting.

## ANSWERS

- |        |        |        |        |
|--------|--------|--------|--------|
| 1. (b) | 2. (d) | 3. (c) | 4. (b) |
| 5. (a) | 6. (c) | 7. (b) | 8. (a) |

- 1. Most common site of adamantinoma of the long bones is:**
  - (a) Femur
  - (b) Ulna
  - (c) Tibia
  - (d) Fibula
- 2. Chondroblastoma most commonly occurs in:**
  - (a) Metaphysis
  - (b) Diaphysis
  - (c) Epiphysis
  - (d) Medullary cavity
- 3. Ramu, an 8 year old boy presented with pain in the arm. On x-ray, his upper end of humerus demonstrates an expansile lesion in the metaphysis with breach of the overlying cortex. Most likely diagnosis is:**
  - (a) Aneurysmal bone cyst
  - (b) Unicameral bone cyst
  - (c) Chondroblastoma
  - (d) Osteoclastoma
- 4. A twisting injury of knee in flexed position would result in injury to all except:**
  - (a) Meniscal tear
  - (b) Capsular tear
  - (c) Anterior cruciate ligament
  - (d) Fibular collateral ligament.
- 5. Chondrocalcinosis is seen in:**
  - (a) Ochronosis
  - (b) Hypoparathyroidism
  - (c) Rickets
  - (d) Hypervitaminosis D

6. **Torsion of knee results in injury most commonly to:**
- (a) Anterior cruciate ligament
  - (b) Medial meniscus
  - (c) Fibular collateral ligament
  - (d) Tibial collateral ligament

## ANSWERS

1. (a)                      2. (c)                      3. (a)                      4. (d)  
5. (a)                      6. (b)

## NOVEMBER 2001

1. **Painful arc syndrome is seen in all except:**
- (a) Complete tear of supraspinatus
  - (b) # greater tuberosity
  - (c) Subacromial bursitis
  - (d) Supraspinatus tendonitis
2. **A patient of nephritic syndrome taking steroids for 6 years presented with a limp gait and of limitation of abduction and internal rotation. He most probably has:**
- (a) Renal osteodystrophy
  - (b) Avascular necrosis of the hip
  - (c) Septic arthritis
  - (d) Osteomyelitis of the hip joint.
3. **An 11 year old 70 kg child presents with limitation of abduction and internal rotation. There is tenderness in the scarpa's triangle. On flexing the hip, the limb is adducted. The diagnosis is:**
- (a) Perthe's disease
  - (b) Slipped capital femoral epiphysis
  - (c) Observation hip
  - (d) Tuberculosis hip

4. A 19 year young patient with sclerotic lesion at the diaphysis. The diagnosis is:
- (a) Osteoid osteoma
  - (b) Ewing's sarcoma
  - (c) Osteoclastoma
  - (d) Metastasis.
5. Most common lesion of the mandible is:
- (a) Ameloblastoma
  - (b) Squamous cell carcinoma
  - (c) Osteosarcoma
  - (d) Osteoclastoma
6. Most common site of origin of adamantinoma is:
- (a) Mandible near molar tooth
  - (b) Middle alveolar margins
  - (c) Hard palate
  - (d) Mandible near symphysis menti.
7. Test for tight iliotibial band is:
- (a) Ober's test
  - (b) Osber's test
  - (c) Simmand's test
  - (d) Charnley's test
8. Bone apposition is best in:
- (a) Osteoblastic activity at the area of stress
  - (b) Endochondral ossification
  - (c) Subperiosteal cambian layer
  - (d) Osteoblastic activity in Howship's lacunae

### ANSWERS

- |        |        |        |        |
|--------|--------|--------|--------|
| 1. (a) | 2. (b) | 3. (b) | 4. (a) |
| 5. (b) | 6. (a) | 7. (a) | 8. (c) |

## MAY 2001

- 1. A 20 year old male, following a road traffic accident was brought to the casualty. His right leg is shortened, internally rotated and adducted. The diagnosis is:**
  - (a) Fracture neck of femur
  - (b) Anterior dislocation of the hip
  - (c) Posterior dislocation of the hip
  - (d) Trochanteric fracture of the femur.
- 2. An 8 year old boy presents with a gradually progressing swelling and pain since 6 months over the upper tibia. On x-ray, there is a lytic lesion with sclerotic margins in the upper tibial metaphysis. The diagnosis is:**
  - (a) Osteogenic sarcoma
  - (b) Osteoclastoma
  - (c) Brodie's abscess
  - (d) Ewing's sarcoma
- 3. An 8 year old boy with a history of fall from 10 feet height complains of pain in the right ankle. X-ray taken at that time are normal without any fracture line. But after 2 years, he developed a calcaneovalgus deformity. The diagnosis is:**
  - (a) Undiagnosed malunited fracture
  - (b) Avascular necrosis talus
  - (c) Tibial epiphyseal injury
  - (d) Ligamentous injury of ankle joint
- 4. A 6 year old boy has a history of recurrent dislocation of the right shoulder. On examination, the orthopaedician puts the patient in the supine position and abducts his arm to 90 degrees with the bed as the fulcrum and then externally rotates it but the boy doesnot allow the test to be performed. The test done by the orthopaedician is:**
  - (a) Apprehension test

- (b) Sulcus test
  - (c) Dugas test
  - (d) McMurray's test
5. Regarding bone remodeling, all are true except:
- (a) Osteoclastic activity at the compression site
  - (b) Osteoclastic activity at the tension site
  - (c) Osteoclastic activity and osteoblastic activity are both needed for bone remodeling in cortical and cancellous bones
  - (d) Osteoblasts transform into osteocytes.
6. A child is spun around by holding his hand by his father. While doing this, the child started crying and does not allow his father to touch his elbow. The diagnosis is:
- (a) Pulled elbow
  - (b) Radial head dislocation
  - (c) Annular ligament tear
  - (d) Fracture olecranon process
7. An 18 years old boy was playing football when he suddenly twisted his knee on the ankle and fell down. He got up after 10 minutes and again started playing, but next day, his knee was swollen and he could not move it. The most probable cause is:
- (a) Medial meniscus tear
  - (b) Anterior cruciate ligament tear
  - (c) Medial collateral ligament injury
  - (d) Posterior cruciate ligament injury.

### ANSWERS

- |        |        |        |        |
|--------|--------|--------|--------|
| 1. (c) | 2. (c) | 3. (c) | 4. (a) |
| 5. (a) | 6. (a) | 7. (a) |        |



## NOVEMBER 2000

- 1. Posterior dislocation of hip leads to which attitude of the lower leg:**
  - (a) Adduction, external rotation and flexion
  - (b) Adduction, internal rotation and flexion
  - (c) Abduction, external rotation and flexion
  - (d) Abduction, internal rotation and flexion
- 2. After falling from a height, a child lands on his fully out-stretched hands. On examination there is pain and swelling over his right elbow. Give your probable diagnosis:**
  - (a) Fracture olecranon
  - (b) Posterior dislocation of elbow
  - (c) Supracondylar fracture of humerus
  - (d) Fracture both bones forearm
- 3. A patient has 2 months POP cast for tibial fracture of left leg. Now he needs mobilization with a single crutch. You will use this crutch on which side:**
  - (a) Left side
  - (b) Right side
  - (c) Any side
  - (d) Both sides.
- 4. A child 10 years of age presents with a mass on his left thigh. The mass seems to be arising from the diaphysis of femur and involving the soft tissue of thigh. The child is having fever also. Give your most probable diagnosis:**
  - (a) Osteosarcoma
  - (b) Ewing's sarcoma
  - (c) Chondrosarcoma
  - (d) Malignant fibrous histiocytoma

## ANSWERS

1. (b)                      2. (c)                      3. (b)                      4. (b)

## JUNE 2000

- 1. Positive pivot shift test in knee is because of injury to:**
  - (a) Posterior cruciate ligament
  - (b) Anterior cruciate ligament
  - (c) Medial collateral ligament
  - (d) Posterior elbow ligament
- 2. Three point relationship is reversed in all except:**
  - (a) # medial epicondyle
  - (b) # lateral epicondyle
  - (c) Supracondylar #
  - (d) Posterior elbow dislocation
- 3. A patient with leprosy presents with clumsiness of hand. His ulnar nerve is affected. Clumsiness is due to palsy of which muscle**
  - (a) Extensor carpi ulnaris
  - (b) Abductor pollicis brevis
  - (c) Opponens pollicis
  - (d) Interosseous muscle
- 4. What is Kienbock's disease:**
  - (a) Osteochondritis of lunate
  - (b) Osteochondritis of neck of femur
  - (c) Osteochondritis of navicular
  - (d) Osteochondritis of tibial condyle
- 5. A patient developed paraplegia. On routine examination and x-ray it was found that there was an osteoblastic lesion in his spine. Most probable diagnosis is:**
  - (a) Carcinoma thyroid
  - (b) Ca. Prostate
  - (c) Breast Carcinoma
  - (d) Pancreatic Carcinoma

6. A patient with pain in back. Lab investigation shows an elevated ESR. X-ray skull shows multiple punched out lytic lesions. Most important investigation to be done is:
- (a) Serum acid phosphatase
  - (b) CT head with contrast
  - (c) Whole body scan
  - (d) Serum electrophoresis
7. Which of the following is seen in osteoporosis:
- (a) Low Calcium, high PO<sub>4</sub>, high alkaline phosphatase
  - (b) Low Ca, low PO<sub>4</sub>, low alkaline phosphatase
  - (c) Normal Ca, normal PO<sub>4</sub>, normal alkaline phosphatase
  - (d) Low Ca, low PO<sub>4</sub>, normal alkaline phosphatase.
8. A person is not able to extend his metacarpophalangeal joint. This is due to injury to which nerve:
- (a) Ulnar nerve
  - (b) Radial nerve injury
  - (c) Median nerve injury
  - (d) Post. Interosseous nerve injury
9. What is the most common site of osteosarcoma:
- (a) Lower end of femur
  - (b) Upper end of humerus
  - (c) Lower end of tibia
  - (d) Upper end of femur
10. Lytic bevelled lesions are seen in skull x-ray. Most likely cause is:
- (a) Multiple myeloma
  - (b) Eosinophilic granuloma
  - (c) Metastasis
  - (d) Osteosarcoma
11. True regarding osteosarcoma is:
- (a) Occurs because of proliferation of osteoclasts
  - (b) Sunray appearance in x-ray indicates new bone formation

- (c) Affects mainly males in the 5<sup>th</sup> or 6<sup>th</sup> decade
- (d) Lymphatic metastasis is most common

**12. Bankart's lesion is seen at:**

- (a) Posterior surface of glenoid labrum
- (b) Anterior surface of glenoid labrum
- (c) Anterior part of head of humerus
- (d) Posterior part of head of humerus

### ANSWERS

- |        |         |         |         |
|--------|---------|---------|---------|
| 1. (b) | 2. (c)  | 3. (d)  | 4. (a)  |
| 5. (b) | 6. (d)  | 7. (c)  | 8. (d)  |
| 9. (a) | 10. (a) | 11. (b) | 12. (b) |

### NOVEMBER 1999

1. A 8 year old child presents with fracture humerus after trivial injury, x-ray shows lytic lesion. Diagnosis is:
  - (a) Osteolastoma
  - (b) Osteomyelitis
  - (c) Unicameral bone cyst
  - (d) Aneurysmal bone cyst
2. On accident there is damage of cervical spine, first line of management is:
  - (a) X-ray
  - (b) turn head to side
  - (c) maintain airway
  - (d) stabilize the cervical spine
3. Deformity in the anterior dislocation of hip is
  - (a) external rotation, abduction, flexion
  - (b) external rotation, adduction, flexion
  - (c) internal rotation, abduction, flexion
  - (d) internal rotation, adduction, flexion

- 4. Stellate ganglion block is useful in:**
- (a) Sudeck's osteodystrophy
  - (b) Compound palmar ganglion
  - (c) Tenosynovitis
  - (d) Osteoarthritis of first CMC joint
- 5. A 10 year old male with pain in the left hip and limping on examination restricted abduction and internal rotation, probable diagnosis is:**
- (a) septic arthritis of hip
  - (c) tuberculous arthritis of hip
  - (b) congenital dislocation of hip
  - (d) Perthe's disease
- 6. Commonest dangerous complication of posterior dislocation of knee is:**
- (a) Popliteal artery injury
  - (b) Sciatic nerve injury
  - (c) Ischaemic of lower leg compartment
  - (d) Femoral artery injury.
- 7. A 3 year old male presented with progressive anaemia, hepatosplenomegaly and osteomyelitis of jaw with pathological fracture, x-ray shows chalky white deposits on bone, probable diagnosis is:**
- (a) Osteopetrosis
  - (b) Osteopoikilocytosis
  - (c) Alkaptonuria
  - (d) Myositis-ossificans progressiva
- 8. Most common cause of VIC in children is due to:**
- (a) Supracondylar # humerus
  - (b) Lateral condyle # humerus
  - (c) Medial condyle # humerus
  - (d) both bone forearm #

9. **True about bone tumour is:**
- (a) Multiple myeloma – more than 55 years age and above
  - (b) Osteogenic sarcoma – fourth decade
  - (c) Chondrosarcoma – first decade
  - (d) Osteoclastoma – fifth decade
10. **Line joining anterior superior iliac spine to ischial tuberosity and passes a greater trochanter:**
- (a) Nelaton's line
  - (b) Shoemaker's line
  - (c) Cniene's line
  - (d) Perkin's line

### ANSWERS

- |        |         |        |        |
|--------|---------|--------|--------|
| 1. (c) | 2. (d)  | 3. (a) | 4. (a) |
| 5. (d) | 6. (a)  | 7. (a) | 8. (a) |
| 9. (a) | 10. (a) |        |        |

### JUNE 1999

1. **A 40 year old patient having arthritis of PIP and DIP along with carpometacarpal joint of thumb and sparing of wrist and metacarpophalangeal joint, most likely diagnosis is:**
- (a) Rheumatoid arthritis
  - (b) Osteoarthritis
  - (c) Psoriatic arthritis
  - (d) Pseudogout
2. **Traumatic anterior dislocation of shoulder with sensory loss in lateral side of forearm and weakness of flexion of elbow joint, most likely injured nerve is:**
- (a) Radial nerve
  - (b) Ulnar nerve
  - (c) Axillary nerve
  - (d) Musculocutaneous nerve

3. A 65 year old female presented with # of T12 vertebra with increased alkaline phosphatase and parathormone level along with low calcium and low phosphate level, diagnosis is:
- (a) Osteoporosis
  - (b) Paget's disease
  - (c) Primary hyperparathyroidism
  - (d) Vitamin D deficiency
4. A 6 year old child has an accident and had # elbow, after four years presented with tingling and numbness in the ulnar side of finger, fracture is:
- (a) Supracondylar # of humerus
  - (b) Lateral condyle # of humerus
  - (c) Olecranon#
  - (d) Dislocation of elbow
5. A 50 years old male with fracture neck of femur comes after 3 days, treatment of choice is:
- (a) Hemiarthroplasty
  - (b) Total hip replacement
  - (c) Hip spica
  - (d) CR and IF
6. Fracture of both bones forearm at the same level, position of the arm in plaster is:
- (a) full supination
  - (b) 10 degree supination
  - (c) full pronation
  - (d) mid-prone
7. Treatment of choice in a 65 year old female with impacted # neck of humerus is:
- (a) Triangular sling
  - (b) Arm chest strapping
  - (c) Arthroplasty
  - (d) Observation



**8. Absolute indication of X-ray of pelvis in case of congenital dislocation of hip are all except:**

- (a) Positive family history
- (b) Breech presentation
- (c) Unstable hip
- (d) Shortening of limb

### ANSWERS

- |      |      |      |      |
|------|------|------|------|
| 1. b | 2. d | 3. d | 4. b |
| 5. d | 6. d | 7. a | 8. b |

# ALL INDIA ENTRANCE EXAMINATION 2003

- 1. Commonest cause for neuralgic pain in the foot is:**
  - (a) Compression of communication between medial and lateral plantar nerves
  - (b) Exaggeration of longitudinal arches
  - (c) Injury to deltoid ligament
  - (d) Shortening of plantar aponeurosis
- 2. Avascular necrosis can be a possible sequelae of fracture of all of the following bones except:**
  - (a) Femur neck
  - (b) Scaphoid
  - (c) Talus
  - (d) Calcaneum
- 3. Kienbock's disease is due to avascular necrosis of:**
  - (a) Femoral neck
  - (b) Medial cuneiform bone
  - (c) Lunate bone
  - (d) Scaphoid bone
- 4. A classical expansive lytic lesion in the transverse process of a vertebra is seen in:**
  - (a) Osteosarcoma
  - (b) Aneurysmal bone cyst
  - (c) Osteoblastoma
  - (d) Metastasis
- 5. A 30-year old male was brought to the casualty following a road-traffic accident. His physical examination revealed that his right lower limb was short, internally rotated and flexed and adducted at the hip. The most likely diagnosis is:**
  - (a) Fracture neck of femur
  - (b) Trochanteric fracture

- (c) Central fracture dislocation of hip
  - (d) Posterior dislocation of the hip
6. **Sciatic nerve palsy may occur in the following injury:**
- (a) Posterior dislocation of hip joint
  - (b) Fracture neck of femur
  - (c) Trochanteric fracture
  - (d) Anterior dislocation of hip
7. **Osteomalacia is associated with:**
- (a) Decrease in osteoid value
  - (b) Decrease in osteoid surface
  - (c) Increase in osteoid maturation time
  - (d) Increase in mineral apposition rate
8. **Which one of the following tests will you adopt while examining a knee joint where you suspect an old tear of anterior cruciate ligament?**
- (a) Posterior drawer test
  - (b) McMurray's test
  - (c) Lachman's test
  - (d) Pivot shift test
9. **A 64 year old hypertensive obese female was undergoing surgery for fracture femur under general anaesthesia. Intra-operatively her end-tidal carbon dioxide decreased to 20 from 40 mm of Hg followed by hypotension and oxygen saturation of 85%. What could be the most probable cause?**
- (a) Fat embolism
  - (b) Hypovolemia
  - (c) Bronchospasm
  - (d) Myocardial infarction
10. **In actinomycosis of the spine, the abscess usually erodes:**
- (a) Intervertebral disc
  - (b) Into the pleural cavity
  - (c) Into the retroperitoneal space
  - (d) Towards the skin

## ANSWERS

- |        |         |        |        |
|--------|---------|--------|--------|
| 1. (a) | 2. (d)  | 3. (c) | 4. (b) |
| 5. (d) | 6. (a)  | 7. (c) | 8. (c) |
| 9. (a) | 10. (d) |        |        |

## 2002

- Carpal tunnel syndrome is due to compression of:**
  - Radial nerve
  - Ulnar nerve
  - Palmar branch of the ulnar nerve
  - Median nerve
- Most common nerve involved in the fracture of surgical neck of humerus is:**
  - Median nerve
  - Radial
  - Ulnar
  - Axillary
- All of the following are associated with supracondylar fracture of humerus Except:**
  - It is uncommon after 15 years of age
  - Extension type fracture is more common than the flexion type
  - Cubitus varus deformity commonly results following malunion
  - Ulnar nerve is most commonly involved
- Ramesh Singh, a 40 year old man, was admitted with a fracture shaft of femur, following a road traffic accident. ON the 2<sup>nd</sup> day, he became disoriented, he was found to be tachypnoeic and had conjunctival petechiae.**
  - Pulmonary embolism
  - Sepsis syndrome

- (c) Fat embolism
  - (d) Haemothorax
5. **Kumar, a 31 year old motorcyclist sustained injury over his right hip joint, X-ray revealed a posterior dislocation of the right hip joint. The clinical attitude of the affected lower limb will be:**
- (a) External rotation, extension and abduction
  - (b) Internal rotation, flexion and adduction
  - (c) Internal rotation, extension and abduction
  - (d) External rotation, flexion and abduction.
6. **Pappu, a 7 years old young boy, had fracture of the lateral condyle of the femur. He developed malunion as the fracture was not reduced anatomically. Malunion will produce**
- (a) Genu valgum
  - (b) Genu varum
  - (c) Genu recurvatum
  - (d) Dislocation of the knee
7. **Patellar tendon bearing POP cast is indicated in the following fracture:**
- (a) Patella
  - (b) Tibia
  - (c) Medial Malleolus
  - (d) Femur
8. **Inversion injury at the ankle can cause all of the following except:**
- (a) Fracture tip of lateral malleolus
  - (b) Fracture base of the 5<sup>th</sup> metatarsal
  - (c) Sprain of Ext. Digitorum brevis
  - (d) Fracture of the sustentaculum tali
9. **A previously healthy 45 year old labourer suddenly develops acute low back pain with the right leg pain and**

**weakness of dorsiflexion of the right great toe. Which of the following is true:**

- (a) Immediate treatment should include analgesics, muscle relaxants and back strengthening exercises
- (b) The appearance of the foot drop indicate early surgical intervention
- (c) If the neurological sign resolve within 2 or 3 weeks but low back pain persists, the proper treatment would include fusion of affected lumbar vertebra.
- (d) If the neurological signs, fail to resolve within one week, lumbar laminectomy and excision of any herniated nucleus pulposus should be done

**10. Acute osteomyelitis is most commonly caused by:**

- (a) Staphylococcus aureus
- (b) Actinomyces bovis
- (c) Nocardia asteroides
- (d) Borrelia vincentii

**11. A 45 year male presented with an expansile lesion in the center of the femoral metaphysis. The lesion shows endosteal scalloping and punctate calcifications. Most likely diagnosis is:**

- (a) Osteosarcoma
- (b) Chondrosarcoma
- (c) Simple bone cyst
- (d) Fibrous dysplasia

**12. Raju, a 10 year old child presents with predisposition to fractures, anemia, hepatosplenomegaly and a diffusely increased radiographic density of bones. The most likely diagnosis is:**

- (a) Osteogenesis imperfecta
- (b) Pyknodysostosis
- (c) Myelofibrosis
- (d) Osteopetrosis

13. Harivardhaman, 9 years old child presents with scoliosis, hairy tuft in the skin of the back and neurological deficit. Plain x-rays reveal multiple vertebral anomalies and a vertical bony spur overlying lumbar spine on AP view. The most probable diagnosis is:
- (a) Dorsal dermal sinus
  - (b) Diastometamyelia
  - (c) Tight filum terminale
  - (d) Caudal regression syndrome
14. In a patient with head injury, unexplained hypotension warrants evaluation of
- (a) Upper cervical spine
  - (b) Lower cervical spine
  - (c) Thoracic spine
  - (d) Lumbar spine
15. Complete transection of the spinal cord at the C7 level produces all of the following effects except:
- (a) Hypotension
  - (b) Limited respiratory effort
  - (c) Anaesthesia below the level of the lesion
  - (d) A-reflexia below the level of the lesion

### ANSWERS

- |         |         |         |         |
|---------|---------|---------|---------|
| 1. (d)  | 2. (d)  | 3. (d)  | 4. (c)  |
| 5. (b)  | 6. (a)  | 7. (b)  | 8. (c)  |
| 9. (b)  | 10. (a) | 11. (b) | 12. (d) |
| 13. (b) | 14. (c) | 15. (b) |         |



- 1. Following anterior dislocation of the shoulder a patient develops weakness of flexion at elbow and lack of sensation over the lateral aspect of the forearm, nerve injured is:**
  - (a) Radial nerve
  - (b) Musculocutaneous nerve
  - (c) Axillary nerve
  - (d) Ulnar nerve
- 2. Babloo, a 10 year old boy presents with # of humerus. X-ray reveals a lytic lesion at the upper end. Likely condition is:**
  - (a) Unicameral bone cyst
  - (b) Osteosarcoma
  - (c) Osteoclastoma
  - (d) Aneurysmal bone cyst
- 3. A patient sustained injury to the upper limb 3 years back, he now presents with valgus deformity in the elbow and paraesthesias over the medial border of the hand. The injury is likely to have been:**
  - (a) Supracondylar # humerus
  - (b) Lateral condyle # of humerus
  - (c) Medial condyle # of humerus
  - (d) Posterior dislocation of the humerus
- 4. A woman aged 60 years suffers a fall, her lower limb is extended and externally rotated, likely diagnosis is:**
  - (a) Neck of femur #
  - (b) Intertrochanteric femur #
  - (c) Posterior dislocation of hip
  - (d) Anterior dislocation of hip
- 5. Triple arthrodesis involves**
  - (a) Calcaneocuboid, talonavicular and talocalcaneal

- (b) Tibiotalar, calcaneocuboid and talonavicular  
(c) Ankle joint, calcaneocuboid and talonavicular  
(d) None of the above.
6. Babu, a 19 year old male has a small circumscribed sclerotic swelling over diaphysis of femur, likely diagnosis is:  
(a) Osteoclastoma  
(b) Osteosarcoma  
(c) Ewing's sarcoma  
(d) Osteoid osteoma
7. Most common site of osteogenic sarcoma is:  
(a) Femur, upper end  
(b) Femur, lower end  
(c) Tibia, upper  
(d) Tibia, lower end
8. Involvement of PIP joint, DIP joint and the carpometacarpophalangeal joint of base of thumb with sparing of the wrist is seen in:  
(a) Rheumatoid arthritis  
(b) Osteoarthritis  
(c) Psoriatic arthritis  
(d) Pseudogout
9. The pivot test is for:  
(a) Anterior cruciate ligament  
(b) Posterior cruciate ligament  
(c) Medial meniscus  
(d) Lateral meniscus

## ANSWERS

- |        |        |        |        |
|--------|--------|--------|--------|
| 1. (b) | 2. (a) | 3. (b) | 4. (a) |
| 5. (a) | 6. (d) | 7. (b) | 8. (b) |
| 9. (a) |        |        |        |

- 1. Treatment regarding fracture of clavicle is:**
  - (a) Most common complication is malunion
  - (b) Occurs at the junction of medial 1/3<sup>rd</sup> and lateral 2/3<sup>rd</sup>s
  - (c) Usually occurs due to fall on elbow
  - (d) Comminuted fracture is common
- 2. A boy fell down from a tree and has fracture neck of humerus. He cannot raise his arm because of the involvement of:**
  - (a) Axillary nerve
  - (b) Supraspinatus nerve
  - (c) Musculocutaneous nerve
  - (d) Radial nerve
- 3. In children, all are true except:**
  - (a) Dislocations are rare
  - (b) Comminuted fractures are common
  - (c) Thick periosteum
  - (d) Soft bones
- 4. An 8 year old child is brought by parents to the casualty with a spiral fracture of femur and varying degree of ecchymosis all over the body. The etiology is:**
  - (a) Hit and run accident
  - (b) Battered baby syndrome
  - (c) Hockey stick injury
  - (d) Fall from height
- 5. Trendelenberg's sign is negative in an inter-trochanteric fracture because of:**
  - (a) Gluteus medius
  - (b) Gluteus maximus
  - (c) Gluteus minimus
  - (d) Tensor fascia lata

6. Post-poliomyelitis, a patient has grade II power in Gastrocnemius, grade III in peroneus, Grade IV in Tibialis anterior. The deformity is:
- (a) Calcaneovalgus
  - (b) Equinovarus
  - (c) Calcaneovarus
  - (d) Genu valgus
7. Decreased mineralization of epiphyseal plate in a growing child is seen in
- (a) Rickets
  - (b) Osteomalacia
  - (c) Scurvy
  - (d) Osteoporosis
8. Chondroblastoma is a tumour of:
- (a) Epiphysis
  - (b) Metaphysis
  - (c) Diaphysis
  - (d) Flat bone
9. Chordoma can occur over all the following sites except:
- (a) Rib
  - (b) Clivus
  - (c) Sacrum
  - (d) Vertebral body

### ANSWERS

- |        |        |        |        |
|--------|--------|--------|--------|
| 1. (a) | 2. (a) | 3. (b) | 4. (b) |
| 5. (d) | 6. (c) | 7. (a) | 8. (a) |
| 9. (a) |        |        |        |

**PGI ENTRANCE EXAMINATION**  
**JUNE 2003**

- 1. A 18 year old boy presented in OPD with Lt. Mono articular knee pain. Possible diagnosis is/are:**
  - (a) Gout
  - (c) Osteoarthritis
  - (c) Rheumatoid arthritis
  - (d) Reiter's disease
  - (e) Gonococcal arthritis
  
- 2. X-ray feature of osteosarcoma:**
  - (a) Sun-ray appearance
  - (b) Codman's triangle
  - (c) Soap bubble appearance
  - (d) Onion peel appearance
  - (e) New bone formation
  
- 3. Tophi of gout is found in:**
  - (a) Articular cartilage
  - (b) Synovium
  - (c) Skin
  - (d) Muscle
  - (e) Joint capsule
  
- 4. Treatment of histologically confirmed giant cell tumour:**
  - (a) Excision, bone grafting and chemical cautery
  - (b) Excision
  - (c) Radiotherapy
  - (d) Chemical excision
  
- 5. Clinical features of T.B. spine are all except:**
  - (b) Loss of lordosis
  - (b) Night sweats
  - (c) Weight gain
  - (d) Evening rise of temperature
  - (e) decreased appetite

- 6. Usual site of tubercular bursitis:**
- (a) Prepatellar
  - (b) Subdeltoid
  - (c) Subpatellar
  - (d) Trochanteric
  - (e) None
- 7. Rocker bottom feet is seen in:**
- (a) Congenital vertical talus
  - (b) CTEV over correction
  - (c) Grice procedure
- 8. Treatment of displaced transverse fracture of patella:**
- (a) POP
  - (b) Tension band wiring
  - (c) Screw
  - (d) Patellectomy
- 9. True about non-ossifying fibroma of bone:**
- (a) Present until 3<sup>rd</sup> and fourth decade
  - (b) Eccentric
  - (c) Prominent sclerotic margin
  - (d) Histologically giant cell with areolar tissue
  - (e) Metaphyseal lesion

### ANSWERS

1. (d, e)      2. (a, b, e)      3. (a, b, c, e)      4. (a, b, c)  
5. (c)      6. (e)      7. (a, b)      8. (a, b, c, d)  
9. (b, c, d, e)

1. **Bone forming tumours are:**
  - (a) Osteosarcoma
  - (b) Osteoid osteoma
  - (c) Giant cell tumour
  - (d) Osteoblastoma
  - (e) Chondrosarcoma
  
2. **Benign bone tumours are:**
  - (a) Osteoid osteoma
  - (b) Osteochondroma
  - (c) Chondroblastoma
  - (d) Chondromyxoid fibroma
  - (e) Multiple myeloma
  
3. **All are predisposing factors of osteogenic sarcoma except:**
  - (a) Paget's disease of bone
  - (b) Radiation
  - (c) Viral infection
  - (d) Bone infarction
  
4. **Factors that promotes callus formation:**
  - (a) Paget's disease of bone
  - (b) Radiation
  - (c) Viral infection
  - (d) Bone infarction
  
5. **In the management of long bone fracture following can be done:**
  - (a) Intramedullary nailing
  - (b) Plating
  - (c) External fixation
  - (d) Tension band wiring
  - (e) Screw



- 6. Poor prognostic factors in Pott's paraplegia:**
- (a) Acute onset of paraplegia
  - (b) Sudden progression of paraplegia
  - (c) Motor paralysis alone
  - (d) Long standing paraplegia
  - (e) Paraplegia in children
- 7. Differential diagnosis of simple bone cyst are:**
- (a) Giant cell tumour
  - (b) Non ossifying fibroma
  - (c) Enchondroma
  - (d) Fibrous dysplasia
  - (e) Eosinophilic granuloma
- 8. True about osteoarthritis except:**
- (a) Commonly found in adult before 50 years
  - (b) Heberden's nodules are found
  - (c) single joint involvement
  - (d) Lower limb deformity is seen
  - (e) Ankylosis
- 9. True about carpal tunnel syndrome:**
- (a) Paraesthesia of the lateral 2 fingers
  - (b) Atrophy of the thenar eminence
  - (c) Atrophy of the hypothenar eminence
  - (d) Claw hand
  - (e) Tinel sign is positive
- 10. True about osteogenesis imperfecta:**
- (a) Autosomal dominant
  - (b) Known as marble bone disease
  - (c) Blue sclera
  - (d) Associated with otosclerosis
  - (e) Defect in collagen-1

**11. True about ganglion:**

- (a) Common in volar aspect
- (b) Seen adjacent to the tendon sheath
- (c) Communicates with joint cavity and tendon sheath
- (d) It is unilocular

**ANSWERS**

1. (a, b, d)    2. (a, b, c, d)    3. (c)    4. (a, b)  
5. (a, b, c, e)    6. (b, d)    7. (a, b, d, e)    8. (a)  
9. (b, e)    10. (a, b, d, e)    8. (b, e)

# NATARAJAN'S

## A Question Bank of Multiple Choice Questions in **ORTHOPAEDICS** and **TRAUMATOLOGY**

As an academician the latest trends in the examination system of medical students has always been a fascinating study. Hence I have been following the advent of MCQs into the medical examination system with great interest. Multiple Choice Questions have evolved from a stage of studied disdain to grudging acceptance to a stage where they have become ubiquitous. Their value in objective testing of the student's grasp of the subject has been widely acknowledged by academicians the world over. So it is not surprising to see that they are now so entrenched in the system that the Under-graduate medical students becomes familiar with them from his first year itself and is rid of them only after his super-speciality days are over.

As it has always been my endeavour to help students learn the fascinating subject of Orthopaedics from all angles, I scoured the various books available for MCQs in Orthopaedics, but the dearth of a single, authentic question bank for MCQs was so glaring that it prodded me to bring out the first edition of "A Questions Bank of Multiple Choice Question in Orthopaedics and Traumatology".

This, I hope, will address the long-felt need for an authentic, researched book on MCQs for Orthopaedics. The questions have been drawn from various examinations conducted all over India. The questions have been so segregated that they are arranged in various chapters corresponding to the various topics in "Orthopaedics and Traumatology". The answers have been drawn from the author's "Textbook of Orthopaedics and Traumatology" and in case of doubt, the student is advised to refer to the book. An added feature of this book, is that it incorporates the latest MCQs which have been asked in the recent papers of ALL INDIA, AIIMS, PGI Post-graduate Entrance Exams. This book is aimed to satisfy the needs of not only the Undergraduates preparing for their Orthopaedic Paper of their PG Entrance Exam, but also the Post-graduates who are preparing for their exams.

ISBN 81-8004-009-7



Rs. 110/-



**All India Publishers & Distributors** Regd.

**Medical Books Publisher**

4380/4B, No.6, Kaushalya Building, Ansan Road, Daryaganj,  
New Delhi - 110002 • Ph: 232 44429, 552 50321 • Fax: 011-224 67613  
• E-mail: aipdraj@vsnl.com, aipdraj@hotmail.com

113, Poonamallee High Road, Gee Gee Shroff Centre, Chennai - 600 084  
• Ph: 282 33004 • Fax: 044-282 04911