

# OKELL NOTES SURGERY

---



## TABLE OF CONTENTS

ABDOMINAL WALL DEFECTS .....	1
ACUTE APPENDICITIS .....	3
ANAL FISSURES .....	7
ANORECTAL ABSCESS .....	9
ANORECTAL MALFORMATIONS .....	10
BENIGN PROSTATIC ENLARGEMENT (BPE).....	16
BLADDER CARCINOMA .....	22
BREAST CANCER:.....	24
BURNS .....	30
CARE OF COLOSTOMIES .....	37
CHEST TRAUMA.....	39
CLEFT LIP AND PALATE .....	45
COLORECTAL CANCER.....	47
CONGENITAL HYPERTROPHIC PYLORIC STENOSIS.....	50
CRANIOPHARYNGIOMA .....	51
CRYPTOCHIDISM.....	52
CYSTIC HYGROMA.....	54
DIABETIC (NEUROPATHIC) ULCERS.....	56
EMPHYEMA THORACIS.....	58
ESOPHAGEAL CANCER.....	61
FISTULA-IN-ANO.....	64
GASTRIC CARCINOMA .....	67
HEAD INJURY .....	70
HEMORRHOIDS .....	77
HIRSCHSPRUNG'S DISEASE.....	79
HYDROCEPHALUS.....	82
INTESTINAL FISTULA.....	85
INTESTINAL OSTRUCTION IN PEDRIATRICS.....	88
INTESTINAL OBSTRUCTION .....	91
CHRONIC LEG ULCERS .....	93
MALIGNANT MELANOMA.....	95
NUTRITIONAL SUPPORT.....	99
OBSTRUCTIVE JAUNDICE/ SURGICAL JAUNDICE.....	104
PAGETS DISEASE OF BREAST .....	108
PENETRATING ABDOMINAL INJURY .....	109
PERITONEAL ADHESIONS .....	112
POST OPERATIVE CARE OF THE SURGICAL PATIENT AND COMPLICATIONS OF SURGERY .....	115
POSTERIOR FOSSA TUMORS.....	119
PREPARATION FOR THEATRE OF PATIENT WITH TOXIC GOITRE.....	122
PRESSURE ULCERS .....	123
PRIMARY OPEN ANGLE GLAUCOMA .....	126
PROBLEMS OF ILEOSTOMIES .....	128
PROSTATE CANCER.....	129
RAISED INTRACRANIAL PRESSURE .....	132
RHABDOMYOSARCOMA.....	133
SIGMOID VOLVULUS.....	135
SKIN INFECTION .....	137

SNAKE BITES .....	138
SPINAL DYSRAPHISM/SPINA BIFIDA.....	139
SPINAL INJURY .....	142
SUB-ARACHNOID HAEMORRHAGE .....	148
SUB-DURAL HAEMATOMA .....	152
TESTICULAR TORSION.....	154
THORACIC OUTLET SYNDROME .....	156
TRACHEOESOPHAGEAL FISTULA .....	158
UPPER GIT BLEEDING .....	160
URETHRAL STRICTURES .....	163
URINE RETENTION CAUSES.....	166
VARICOSE VEINS.....	167
WOUND HEALING .....	170
ESSAYS.....	172

# ABDOMINAL WALL DEFECTS

## CONGENITAL UMBILICAL HERNIA

### Definition

-**Fascial defect at the umbilicus** is frequently present in the newborn, particularly in premature infants.

### Pathology

- The defect may have invagination of the intestines or omentum with an overlying skin covering
- Its size may actually increase with increase in intra-abdominal pressure.
- Protrusion of bowel through the umbilical defect rarely results in incarceration in childhood
- most dangerous defects are less than 2cm.

### Etiology

-Unknown

### Incidence

- Incidence thus decreases with age as the natural tendency is to close spontaneously.
- Is very common 1:1000
- Majority .50 % are small defects less than 1cm in size-belly button umbilical hernia in those < 2years.

### Race

-The incidence is highest in blacks.

### Clinical presentation

- Most asymptomatic.
- Omentum trapped in the hernia causes reflex vomiting without intestinal obstruction.
- Classical presentation is reducing mass in the umbilical area with or without vomiting associated with intermittent abdominal pain.
- the hernia may become obstructed, strangulated and present as acute abdomen.

### Course

- In most children, the umbilical ring progressively diminishes in size and eventually closes.
- Fascial defects less than 1 cm in diameter close spontaneously by 5 years of age in 95% of cases.
- When the fascial defect is greater than 1.5 cm in diameter, it seldom closes spontaneously.

### Surgical repair is indicated when

- 1) The intestine becomes incarcerated
- 2) Symptomatic hernia.
- 3) when the fascial defect is greater than 1 cm, in girls over 2 years
- 4) All children over 4 years of age.
- 5) Cosmesis

- In girls must be repaired because the defect may worsen in pregnancy.
- some patients with umbilical defects develop acquired umbilical hernia due to increase in abdominal pressure due to ascitis

### Mortality/Morbidity

- Intestinal obstruction and infection
- 2-12% recurrence after the corrective operation.

## OMPHALOCELE

### Introduction

- Omphalocele is a **congenital defect of the peri-umbilical abdominal wall in which the coelomic cavity is covered only by peritoneum and amnion (membrane covering).**
- There are two kinds of omphalocele: fetal and embryonic.
- Fetal omphalocele is a small abdominal defect (< 4 cm wide) with herniation of bowel into a sac of amnion that has the umbilical vessels located at the apex of the sac. This is due to

failure in development in the periumbilical abdominal wall after the first 8 weeks of gestation.

Other anomalies are present in less than 10% of these patients. About 15% of congenital abdominal wall defects are fetal omphaloceles.

-Embryonic omphalocele is due to failure of abdominal wall closure in the embryonic stage of development (before the eighth week).

-It is characterized by a wide abdominal wall defect, usually greater than 4 cm in width, in which the amnion does not protrude far beyond the abdomen, and the umbilical cord joins the abdominal wall at the perimeter of the defect rather than at the apex.

-Liver as well as bowel is herniated. Multiple anomalies are present in 50% of these cases, such as

- Congenital heart defects (20%) (tetralogy of Fallot; atrial septal defect)
- Trisomies 21, D, and E;
- Diaphragmatic hernia
- Renal anomalies.
- Pentalogy of Cantrell -omphalocele is in epigastric in position and there is a defect in the diaphragm and pericardium, allowing pericardial herniation of bowel, a split or shortened lower sternum, ventricular septal defect, and diverticulum from the heart--and a small thorax which may result in pulmonary hypoplasia
- Beckwith-Wiedemann syndrome, in which a midabdominal omphalocele is associated with a baby who is large for gestational age and who has macroglossia, visceromegaly of the kidneys, adrenal glands, and pancreas, hypoglycemia in early infancy, and a high frequency of hepatoblastoma, Wilms' tumor, or adrenocortical carcinoma; and
- Hypogastric omphalocele associated with cloacal exstrophy and spinal dysraphism.

### Treatment

-Omphaloceles with small abdominal defects can be treated by excising the omphalocele sac and reapproximating the linea alba and skin.

- Acute management of omphalocele involves covering the defect with a sterile dressing soaked with warm saline to prevent fluid loss.

- A nasogastric tube should be placed on suction to minimize intestinal distention and allow decompression

-Intravenous fluids and glucose, and antibiotics

-- A central venous catheter is required to monitor central venous pressure and blood gases in anticipation of postoperative hypovolemia from third space losses and for TPN.

-An umbilical artery catheter can be maintained without interfering with the repair.

-A bladder catheter can be used to monitor intra-abdominal pressure.

- Most large embryonic omphaloceles cannot be closed without staging the procedure which gradual reduction of the omphalocele contents into the abdominal cavity and a secondary closure.

-Without removing the amniotic sac, a silicone rubber sheet is formed into a tube (silastic silo), which is sutured to the skin at the perimeter of the omphalocele membrane.

-The silo is progressively compressed to invert the amniotic sac and its contents into the abdomen and to bring the edges of the linea alba together by stretching the abdominal wall muscles.

-This requires a number of days.

- Postoperatively, third-space fluid losses may be extensive; fluid and electrolyte therapy, therefore, must be carefully monitored.

## **GASTROSCHISIS**

### **Introduction**

Gastroschisis is a defect in the abdominal wall that usually is to the right of a normal insertion of the umbilical cord. There is no membrane or sac and no liver or spleen outside the abdomen.

-Gastroschisis is associated with no anomalies except intestinal atresia.

-The herniation is thought to occur as a rupture through an ischemic portion of the abdominal wall.

-It is probably produced by rupture of an embryonic omphalocele sac in utero.

-The remnants of the amnion are usually reabsorbed. The skin may continue to grow over the remnants of the amnion, and there may be a bridge of skin between the defect and the cord.

- The small and large bowel herniate through the abdominal wall defect.

-Having been bathed in the amniotic fluid, and with compression of the blood supply at the abdominal defect, the bowel wall has a very thick, shaggy membrane covering it.

-The loops of intestine are usually matted together, and the intestine appears to be abnormally short.

-The membrane thickens during delay in surgical closure and compromises the outcome

### **Complications**

-Since the bowel has not been contained intra-abdominally, the abdominal cavity fails to enlarge, and it frequently cannot accommodate the protuberant bowel.

-Over 70% of the infants are premature, but associated anomalies occur in less than 10% of cases.

-Nonrotation of the midgut is present.

-Intestinal atresia occurs frequently, because segments of intestine that have herniated through the defect become infarcted in utero.

### **Treatment & Prognosis**

-Small defects may be closed primarily after manually stretching the abdominal cavity.

-Frequently, a staged approach is required. Initially, the bowel should be covered by forming a tube from silicone-coated fabric and incorporating the protuberant bowel into the tube (silo). The end of the tube is tied off. As edema and shaggy membrane of the protuberant intestine are absorbed, the bowel will readily reduce into the abdominal cavity.

-A gastrostomy is valuable in postoperative care of the baby, because gastrointestinal function is often slow to return.

-The death rate for infants with gastroschisis has been greatly reduced by this technique.

-Poor gastrointestinal function and episodes of sepsis, presumably from compromised bowel, may occur.

- Total parenteral nutrition may be necessary for several weeks.

NB.

Diagnosis may be done in utero of the last 2 disorders by doing an U/S-at 16 and 32 weeks

-Alpha fetal protein raised in both cases.

-Cytology on the amniotic fluid for other associated disorders.

# ACUTE APPENDICITIS

## Definition

Appendicitis is inflammation of the inner lining of the vermiform appendix that subsequently spreads to its other parts.

## Frequency

The incidence of acute appendicitis is around 7% of the population

## Age

Persons of any age may be affected, with highest incidence occurring between 15-30 years of age.

## Sex

Before puberty and after 30yrs - M=F incidence  
Teenagers & young adults - M:F - 3:2 (slight male predominance)

## Relevant Anatomy

The appendix is a wormlike extension of the cecum, and its average length is 8-10cm (ranging from 2-20 cm). This organ appears during the fifth month of gestation, and its wall has an inner mucosal layer, 2 muscular layers, and a serosa. Several lymphoid follicles are scattered in its mucosa. The number of follicles increases when individuals are aged 8-20 years.

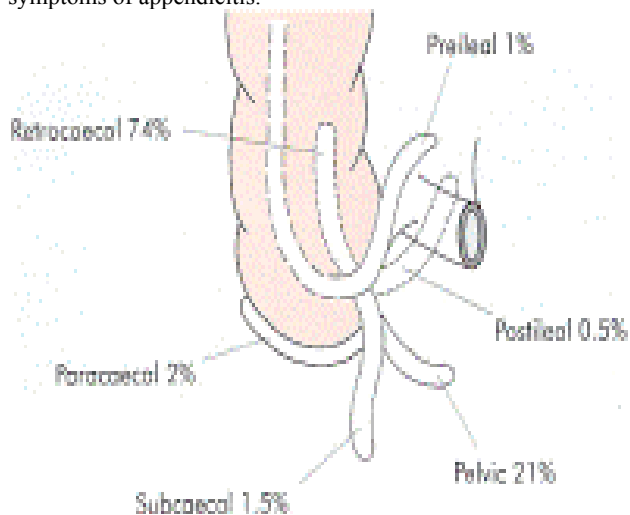
The inner muscular layer is circular, and the outer layer is longitudinal and derives from the taenia coli.

Taenia coli converge on the posteromedial area of the cecum. This site is the appendiceal base.

The appendix runs into a serosal sheet of the peritoneum called the mesoappendix. Within the mesoappendix courses the appendicular artery, which is derived from the ileocolic artery. Sometimes, an accessory appendicular artery (deriving from the posterior cecal artery) may be found.

The vasculature of the appendix must be addressed to avoid intraoperative hemorrhage.

The position of appendix vary thus the nonspecific signs and symptoms of appendicitis.



## Etiology

Appendicitis is caused by obstruction of the appendiceal lumen. The causes of the obstruction include:

- 1) Lymphoid hyperplasia secondary to irritable bowel disease (IBD) or infections (more common during childhood and in young adults)

- 2) Fecal stasis and fecaliths (more common in elderly patients)
- 3) Parasites
- 4) Foreign bodies
- 5) Neoplasm-carcinoids, lymphoma, carcinoma of caecum.
- 6) Strictures

NB

Lymphoid hyperplasia may also related to Crohn disease, mononucleosis, amebiasis, measles, and GI and respiratory infections.

Fecaliths are solid bodies within the appendix that form after precipitation of calcium salts and undigested fiber in a matrix of dehydrated fecal material

## Pathophysiology

-Independent of the etiology, obstruction causes an increase in pressure within the lumen due to continuous secretion of fluids and mucus from the mucosa and the stagnation of this material. At the same time, intestinal bacteria within the appendix multiply, leading to the recruitment of white cells and the formation of pus and even higher intraluminal pressure.

-If appendiceal obstruction persists, intraluminal pressure rises ultimately above that of the appendiceal veins, leading to venous outflow obstruction. As a consequence, appendiceal wall ischemia begins, resulting in a loss of epithelial integrity and allowing bacterial invasion of the appendiceal wall.

-Various specific bacteria, viruses, fungi, and parasites can be responsible agents of infection that affect the appendix, including Gram - bacilli, Viruses-adenovirus, cytomegalovirus, actinomycosis, *Mycobacteria* species, *Histoplasma* species, *Schistosoma* species, pinworms, and *Strongyloides stercoralis* -Uncorrected this leads to gangrene and perforation of the appendix. As this process continues, a peri appendicular abscess or peritonitis may occur.

-In neonates (due to a poorly developed omentum), the elderly (omentum shrinks in size) & the immunocompromised, the condition is not controlled lead free bacterial contamination of the peritoneal cavity and generalised peritonitis.

-In the rest, the greater omentum & loops of small bowel become adherent to the inflamed appendix, walling off the spread of peritoneal contamination, resulting in a phlegmonous mass & eventually may form a paracaecal abscess.

Rarely appendiceal inflammation *resolves* leaving a distended mucous-filled organ - **mucocele** of the appendix.

## Symptoms

- 1) Abdominal pain (100%) - periumbilical then right-lower-quadrant (RLQ). Pain lessened with flexion at the hip.
- 2) Anorexia (almost 100%)
- 3) Nausea (90%)
- 4) Vomiting (75%)-mild
- 5) Obstipation-inability to pass stool and flatus
- 6) Diarrhea-mild
- 7) Appendix next to bladder or ureter, inflammation may cause urinary symptoms of frequency, dysuria and (microscopic) pyuria

## Physical examination

-Vitals-fever and tachycardia  
-Dehydration

## Do full abdominal examination and DRE

### Inspection

Complicated appendix-movement with respiration may be absent, distension of the abdomen

### Palpation

- Maximal tenderness at "McBurney's point" 2/3 distance from umbilicus to Anterior superior iliac spine
- RLQ tenderness and rebound tenderness
- Voluntary contraction (guarding )
- Involuntary contraction (rigidity)

**Signs include:**

- 1-**Pointing sign** patient may localize a region in the RLQ where pain is maximal.(parietal peritoneum irritation)
  - 2-**Rovsing's sign** - RLQ pain with palpatory pressure in LLQ
  - 3-**Psoas sign**-pain with right thigh extension in retroperitoneal or retrocecal appendicitis
  - 4-**Obturator sign**-pain with internal rotation of flexed right thigh in pelvic appendicitis
  - 5- **Dunphy sign**- Increasing pain with cough
  - 6- **Blumberg sign** -Rebound tenderness related to peritoneal irritation elicited by deep palpation with quick release. When patient is on moving trolley patient feels pain.
- Retrocecal appendix-flank tenderness in RLQ

**Auscultation**

Bowel sounds-may absent in perforated appendix-paralytic ileus.May be increased in appendicitis associated with obstruction at caecum

**DRE**

Pelvic appendix-anterior and suprapubic pain on rectal exam.  
Blood in examining finger  
NB Signs of peritoneal inflammation in the right iliac fossa are often absent in the early stages of the illness.

The patient should be asked to cough, blow the abdominal wall out and draw it in; all of these cause pain if the parietal peritoneum is inflamed

**Pathology**

**Gross:**In the early stages of the disease, the appendix grossly appears edematous with dilation of the serosal vessels As time passes, the appendiceal wall grossly appears thickened, the lumen appears dilated, and a serosal exudate (fibrinous or fibrinopurulent) may be observed as granular roughening.

**Micro:** neutrophil infiltrate of the mucosal and muscularis layers extending into the lumen

**Investigations**

Usually a clinical diagnosis, investigations more useful in atypical presentations to rule out other differentials and confirm the diagnosis

**Laboratory**

**1.FHG**

A mild elevation of WBCs (ie, >12,000/mL) is a common finding in patients with acute appendicitis especially neutrophilia. Values greater than 17,000 cells indicate complicated appendicitis. Otherwise, the WBC count has low specificity.

**2.Urinalysis**

Differentiating appendicitis from urinary tract conditions. Mild pyuria may occur in patients with appendicitis because of the relationship of the appendix with the right ureter. Severe pyuria is a more common finding in UTI.  
Hematuria in ureteric colic.  
Glycosuria in Diabetic ketoacidosis  
Urobilinogen in acute porphyria

**3.U/E/C**

Detect any deranged electrolytes- Vomiting, diarrhea and anorexia. Correction done.  
Renal Pyelonephritis and colic R/o

**4.C-reactive protein and ESR**

C-reactive protein (CRP) has been reported to be useful in the diagnosis of appendicitis. This protein is physiologically produced by the liver when bacterial infections occur and rapidly increases within the first 12 hours

**5.Liver and pancreatic function tests** (eg, Transaminases, bilirubin, alkaline phosphatase, serum lipase, amylase) R/o Acute pancreatitis and cholecystitis

**6.Pregnacy test**-in females of childbearing age

**Imaging**

Used in differential diagnosis and to detect complications.

**1 .Abdomianl x-ray:** gas-filled appendix; radiopaque fecalith or ureteric calculi; deformed cecum; air-fluid levels a perforated appendix may allow sufficient free gas to escape to be revealed on plain X-rays

**2. Barium enema**-non-filling appendix; RLQ mass effect

**3. Ultrasound**-distended and thick walled appendix.

-Non distendable appendix.

-Using U/S probe to press appendix causes tenderness

-Up to 90% sensitive and 95% specific for appendicitis

-Rule out other differentials as ectopic pregnancy, pelvic abscess, endometriosis, ureteric colic  
inflamed gall bladder

**4. CT scan** for peri- appendiceal abscess and wall of appendix .May be used in obese patients where ultrasonography may be hampered

**5. Diagnostic laparoscopy**

Convergence of teniae coli is detected at the base of the appendix, beneath the Bauhin valve (ie, the ileocecal valve). Can be converted to therapeutic by doing laparoscopic appendisectomy.

**DIAGNOSIS OF ACUTE APPENDICITIS SCORING SYSTEM(AL-VARA-DO Scoring system(MANTRELS))**

Symptom	Score
Migratory abdominal pain	1
Anorexia	1
Nausea	1
<b>Sign</b>	
Tenderness	2
Rebound tenderness	1
Elevated Temperature	1
<b>Lab. Finding</b>	
Leukocytosis	2
Shift to the left	1
<b>Maximum</b>	<b>10</b>

A score of  $\geq 7$  is strongly predictive of acute appendicitis

**Staging**

Appendicitis usually has 3 stages.

**1.Edematous stage**

Appendicitis may have spontaneous regression or may evolve to the second stage.The mesoappendix is commonly involved with inflammation.

**2.Purulent (phlegmonous) stage**

Spontaneous regression rarely occurs.

Appendicitis usually evolves beyond perforation and rupture.Peritonitis may be possible.

**3.Gangrenous stage**

Spontaneous regression never occurs.



Peritonitis is present

**MANAGEMENT**

**Supportive**

- 1. Analgesics-diclofenac
  - 2. NG tube
  - 5. Maintenance fluids and correction of electrolytes
  - 4. Pre-op antibiotics broad spectrum antibiotic; cefoxitin, cefotetan plus Metrodiazole.
- Gangrenous or perforating appendicitis - broadened antibiotic coverage for aerobic and anaerobic enteric pathogen.

**Definitive**

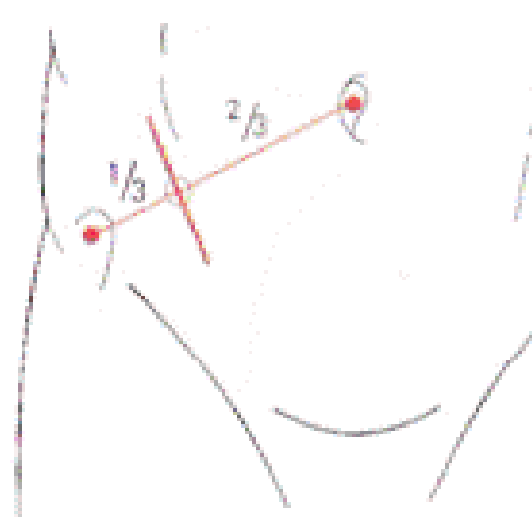
- Immediate appendectomy; open or laparoscopic.
- Drainage of abscess, if present

**Open appendectomy**

-Prior to incision, the surgeon should carefully perform a physical examination of the abdomen to detect any mass and to determine the site of the incision

**Incisions**

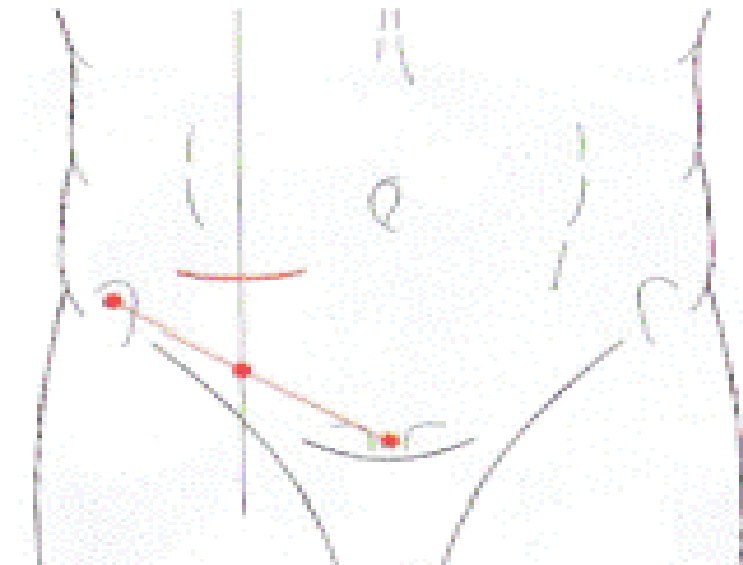
**a) Gridiron** Centred on **McBurney's point** perpendicular to line joining ASIS & umbilicus. Difficult to extend, more difficult to close & provides poorer access to the pelvis & peritoneal cavity



**b) Lanz incision (Transverse or skin crease incision)**

Centred on **midclavicular 2cm** below the umbilicus.

\*\* Exposure is better & extension when needed is easier especially when the diagnosis is in doubt, particularly in the presence of intestinal obstruction



**C) Rutherford Morison's incision**

Useful if the appendix is para- or retrocaecal & fixed

It is possible to convert the Gridiron incision to a Rutherford Morison by cutting the internal oblique & transversus muscles in the line of the incision)

**Procedure**

Incision go through the following layers

- Skin
- ↓
- Pad of fat
- ↓
- Superficial fascia-Scarpa and campas fascia
- ↓
- Subcutaneous tissue - an arterial twig from the *superficial circumflex iliac artery* usually requires ligation
- ↓
- External oblique - cut along the line of the incision
- ↓
- Internal oblique - split
- ↓
- Transverse Abdominis – split
- ↓
- Fascia transvasalis
- ↓
- Pre-peritoneal pad of fat
- ↓
- Peritoneum

- Character of any peritoneal fluid is noted; if purulent, collected for M/C/S.
  - Retractors are gently placed into the peritoneum.
  - The cecum is identified exteriorized by a moist gauze sponge or Babcock clamp
  - Appendix is identified by following the taenia coli until their convergence at base of caecum.
  - Mesoappendix is held between clamps, divided, and ligated.
  - The appendix is clamped proximally about 5 mm above the cecum to avoid contamination of the peritoneal cavity and is cut above the clamp by a scalpel.
  - The appendix stump may be inverted into the cecum with the use of a purse string suture or z-stitch
  - The cecum is placed back into the abdomen. The abdomen is irrigated.
- When evidence of free perforation exists, peritoneal lavage with several liters of warm saline is recommended.

-The use of a drain is not commonly required in patients with acute appendicitis, but obvious abscess with gross contamination requires drainage.

-The wound closure begins by closing the peritoneum with a running suture. Then, fascial layers are reapproximated and closed with a continuous or interrupted absorbable suture. Lastly, the skin is closed with subcutaneous sutures.

#### **NB.**

In case of normal appendix, other causes of the differentials ruled out, including ovarian pathology, Meckel diverticulum, sigmoid disease, and cholecystitis. Regardless of the findings, appendectomy should be performed.

This because the patient will have a RLQ incision and in case of another acute abdomen acute appendicitis may not be considered.

#### **Laparoscopic appendisectomy**

-3 cannulae are placed during the procedure.

-Two of them have a fixed position (ie, umbilical and suprapubic).

-The third is placed in the right periumbilical region position may vary.

-Umbilical incision for placement of a Hasson cannula or Veress needle

-Pneumoperitoneum (10-14 mm Hg) is established and maintained by insufflating carbon dioxide.

-Through the access, a laparoscope is inserted to view the entire abdomen cavity.

-Trocar is introduced suprapubic allow the introduction of instruments (eg, incisors, forceps, stapler).

-Another trocar is placed in the right periumbilical for insertion of an atraumatic grasper to expose the appendix. - The appendix may be removed through the umbilical or the suprapubic cannula using a laparoscopic pouch to prevent wound contamination.

- Peritoneal irrigation is performed with antibiotic or saline solution

#### **Advantages**

1. Decreased postoperative pain
2. Shorter time to return to usual activities
3. Lower incidence of wound infections or dehiscence. This procedure is cost effective but may require more operative time compared with open appendectomy

#### **Differential diagnosis**

##### **Pancreatico-Biliary**

- Cholecystitis
- Biliary colic
- Pancreatitis

##### **GIT**

- Gastroenteritis, enterocolitis
- Meckel diverticulitis
- Perforated duodenal ulcer
- Crohn disease, ulcerative colitis
- Colon carcinoma, peri caecal abscess
- Intussusception
- mesenteric adenitis

##### **Urinary system**

- Ureteric colic
- Urinary tract infection (UTI).
- Pyelonephritis

##### **Reproductive In women**

- ovarian cyst torsion
- Mittelschmerz
- Ectopic pregnancy

-Pelvic inflammatory disease (PID).

-Endometriosis

-Salpingitis

##### **Respiratory**

-Lobar pneumonia

#### **POSSIBLE COMPLICATIONS:**

- Wound infection
- Intra-abdominal abscess, sometimes diaphragmatic
- Fecal fistula
- Intestinal obstruction
- Incisional hernia
- Liver abscess (rare)
- Peritonitis with paralytic ileus

# ANAL FISSURES

## Definition

- Superficial linear tear in the squamous epith. of the anal canal distal to the dentate line.
- Most commonly caused by passage of a large, hard stool.
- In the short-term, usually involves only the epithelium and, in the long-term, involves the full thickness of the anal mucosa.

## Occurrence

- Anal fissures are common in infancy, and they represent the most common cause of bright rectal bleeding at any age.
- If not promptly diagnosed and treated, these small tears and their occasionally associated superficial infection cause severe anorectal pain during bowel movements and set in motion a cycle of stool negativism, constipation, and increasing pain with subsequent defecation.

## Etiology-Not exactly known But:

1. **Trauma** -passage of hard stool(constipation)
  - anal intercourse
  - rectal examination speculum
2. **Low-fiber diets**- lacking in raw fruits and vegetables
3. **Prior anal surgery** -scarring from the surgery may cause either stenosis or tethering of the anal canal
4. **Chronic diarrhea**
5. **Habitual use of cathartics**
6. **Abnormalities in internal sphincter tone** - hypertonicity and hypertrophy of the internal anal sphincter, leading to elevated anal canal and sphincter resting pressures
  - Most patients with anal fissures have an elevated resting pressure, and this resting pressure returns to normal levels after surgical sphincterotomy.
  - Pain accompanies each bowel movement as this raw area is stretched and the injured mucosa is abraded by the stool.
  - The internal sphincter also begins to spasm when a bowel movement is passed, which has 2 effects. First, the spasm itself is painful; second, the spasm further reduces the blood flow to the posterior midline and the anal fissure, contributing to the poor healing rate.

## Pathophysiology

- Constipation thought to cause initial trauma causing acute fissures.
- Acute anal fissures are superficial and are not normally associated with skin tag formation.
- Chronic anal fissure is associated with the development of both anal tags and polyps (hypertrophied anal papillae) as a result of inflammatory edema.
- Chronic sub epithelial infection at the fissure results in fibrosis and, in rare instances, anal stenosis.
- The torn edges of the anal epithelium become undermined and the ulcer deepens, exposing fibres of the internal sphincter muscle.
- A vicious cycle ensues in which subepithelial inflammation causes spasm of the internal sphincter, inhibiting free drainage of the infected fissure and permitting continued inflammation, resulting in a small, chronic, inadequately drained abscess.
- The reflex relaxation of the internal sphincter that normally follows defecation is lost in patients with anal fissure; instead contraction of the internal sphincter occurs.

## DIAGNOSIS

### History

Relatively specific dx usually on history alone.

- 1-Severe pain during a bowel movement, with the pain lasting minutes - hours afterward.
    - The pain leading to a cycle of worsening constipation, harder stools, and more anal pain.
  - 2- Bright red blood on the toilet paper or stool but no significant bleeding
  - 3- Mucous anal discharge and pruritus ani are also common.
- History of chronic anal fissure is typically cyclical; periods of acute pain are followed by temporary healing, only to be succeeded by further acute pain.

## PHYSICAL

- The patient should be examined in the left lateral position. Visual examination may disclose a posterior oedematous tag and, on parting the buttocks, an associated fissure may be seen..
- Note depth of fissure and its orientation to the midline, often described using clock orientation of hour hand.
  - Majority of tears are found in the posterior midline. Fissures occurring off the midline should raise the possibility of other etiologies. Sigmoidoscopy should be undertaken, under anaesthesia to exclude specific causes of fissure, IBD (esp. Crohn's disease), anal syphilis, anal herpes, anal carcinoma, lymphoma, anoreceptive intercourse (with or without HIV infection), and, in children, sexual abuse.
  - Rectal examination is generally difficult to tolerate because of sphincter spasm and pain.
  - Acute fissures are erythematous and bleed easily.
  - With chronic fissures, classic fissure triad may be seen.
    - a. Deep ulcer
    - b. Sentinel pile-skin tag
    - c. Enlarged anal papillae

## MANAGEMENT

The goals of treatment are to relieve the constipation and pain thus to break the cycle of hard bowel movement, associated pain, and worsening constipation and spasm of internal anal sphincter.

### Medical therapy

- Initial therapy for an anal fissure is medical in nature, and **more than 80% of acute anal fissures resolve** without further therapy.
- Softer bowel movements are easier and less painful for the patient to pass.

### First-line medical therapy

1. Diet modification increase -water and fibres-fruits and vegetables.
2. Stool-bulking agents/Stool softeners -such as fiber supplementation and stool softeners-polyethylene glycol
2. Laxatives are used as needed to maintain regular bowel movements.-Lactulose
3. Mineral oil may be added to facilitate passage of stool without as much stretching or abrasion of the anal not used for long.
3. Sitz baths after bowel movements - symptomatic relief as they relieve painful internal sphincter muscle spasm.

### 2<sup>nd</sup> medical therapy

Topical application of 0.2% nitroglycerin (NTG) ointment directly to the internal sphincter. NTG ointment is thought to relax the internal sphincter and to help relieve some of the pain associated with sphincter spasm; it also is thought to increase blood flow to the anal mucosa. main adverse effects are headache and dizziness; could be used directly before bedtime.

Others -hydrocortisone cream, lignocaine gels, Proctosedyl ointment (cinchocaine anaesthetic 0.5 per cent and hydrocortisone 0.5 per cent).

Newer therapy for acute and chronic anal fissures is botulinum toxin.

The toxin is injected directly into the internal anal sphincter and, in effect, performs a chemical sphincterotomy.

The effect lasts approximately 3 months, until the nerve endings regenerate. This 3-month period may allow acute fissures (and sometimes chronic fissures) to heal and symptoms to resolve. Recurrence indicates need for surgery.

#### **Surgical therapy:**

Surgical therapy is usually reserved for acute anal fissures that remain symptomatic after 3-4 weeks of medical therapy and for chronic anal fissures. Few chronic fissures heal spontaneously or from medical therapy and is indication for surgery

#### **Sphincter dilatation**

controlled anal stretch or dilatation under general anesthetic.

This is performed because one of the causative factors for anal fissure is thought to be a tight internal anal sphincter; stretching it helps correct the underlying abnormality, thus allowing the fissure to heal..

#### **Lateral internal sphincterotomy**

Current surgical procedure of choice. Done under general or spinal anesthesia.

The purpose of an internal sphincterotomy is to cut the hypertrophied internal sphincter, thereby releasing tension and allowing the fissure to heal.

Sphincterotomies are normally performed in the lateral quadrants as most fissures are posterior or anterior and cuts would not heal due to impaired blood supply.

Only the internal sphincter is cut; the external sphincter is not cut and must not be injured.

In chronic anal fissures, excision of the fissure in conjunction with the lateral sphincterotomy may be done. an advancement flap may be performed to cover the defect in the mucosa.

#### **Follow-up care**

stool softeners and fiber supplementation after the surgery

#### **Complications from surgery**

Infection

Bleeding

Anal abscess

fistula development,

the most feared—incontinence.

Recurrence of fissure

# ANORECTAL ABSCESS

## Definition

Anorectal abscess represents an infection of the soft tissues surrounding the anal canal, with formation of a discrete abscess cavity.

Often associated with formation of a fistulous track.

## Etiology

-Arise from obstruction of anal crypts.

-Infection of the now static glandular secretions results in suppuration and abscess formation within the anal gland. The abscess typically forms initially within the intersphincteric space and then spreads along adjacent potential spaces as ischioirectal, supralelevator or submucosal.

In about 20 per cent of patients there is a clear predisposing cause, IBD, anorectal cancer, anal fissure, complicated haemorrhoids, or local trauma

## Pathophysiology:

-Basic mechanism is the obstruction of anal crypts.

-Usually, from 4-10 anal glands are drained by respective crypts at the level of the dentate line.

-Obstruction of anal crypts results in stasis of glandular secretions and, when subsequently infected, suppuration and abscess formation within the anal gland results.

-The abscess typically forms in the intersphincteric space and can spread along various potential spaces.

-Common organisms implicated in abscess formation include *Escherichia coli*, *Enterococcus* species, and *Bacteroides* species

-Less common causes of anorectal abscess that must be considered in the differential diagnosis include tuberculosis, cancer, Crohn disease, trauma, leukemia, and lymphoma

## Classification of anorectal abscess

### 1. Perianal abscesses

The most common type of anorectal abscesses, 60% of cases. These superficial collections of purulent material are located beneath the skin of the anal canal and do not transverse the external sphincter

### 2. Ischioirectal

An ischioirectal abscess forms when suppuration transverses the external sphincter into the ischioirectal space.

### 3. Intersphincteric

Intersphincteric abscesses result from suppuration contained between the internal and external anal sphincters

### 4. Supralelevator.

A supralelevator abscess results either from suppuration extending cranially through the longitudinal muscle of the rectum from an origin in the intersphincteric space to reach above the levators or as a result of primary disease in the pelvis (eg, appendicitis, diverticular disease, gynecological sepsis).

### 5. Horseshoe abscesses

Rare, result from circumferential infiltration of pus within the intersphincteric planes.

## Clinical

Locations of abscess perianal 60%, ischioirectal 20%, intersphincteric 5%, supralelevator 4%, and submucosal 1%  
Clinical presentation correlates with the anatomical location of the abscess

## History

Pain is a prominent initial feature of perianal and superficial ischioirectal abscesses, followed by local signs of inflammation. Perianal pain often is exacerbated by movement and increased perineal pressure from sitting or defecation. Pts also complain of dull perianal discomfort and pruritus

Such symptoms are less evident or may even be absent with deep infections, which tend to develop insidiously with pyrexia and systemic upset.

## Physical

Superficial lesions produce obvious signs of acute inflammation.

Perianal abscess, there is a localized; fluctuant, red, hot, and tender swelling close to the anus. Such signs are more diffuse in patients with ischioirectal sepsis, where fluctuance is a late finding.

Other features that might be noted are skin necrosis, if there is gross swelling and crepitus if a gas-forming organism is present.

-Deeper infections produce less obvious abnormalities, and these are only apparent on digital rectal examination.- a fluctuant indurated mass may be encountered.

-Optimal physical assessment of an ischioirectal abscess may require anesthesia to alleviate patient discomfort that would otherwise limit the extent of the examination.

## Investigations

clinical suspicion of an intersphincteric or supralelevator abscess may require confirmation by CT scan, MRI, or anal ultrasonography

## Management

### Medical

Systemic broad spectrum antibiotics - change appropriately with the results of culture and sensitivity.

### Surgery

This is achieved by incision and drainage after the patient has been examined under an appropriate anesthetic.

For ischioirectal and perianal abscess a cruciate incision with probing of the abscess to break the pus loculations

The cavity should be curetted and necrotic tissue excised

### Post-op

-Sitz baths

-Analgesia

-Antibiotics

-Stool softeners.

6. Associated conditions - oesophageal atresia, duodenal atresia, and cardiovascular defects.

# ANORECTAL MALFORMATIONS

## Introduction

The spectrum of anorectal malformations ranges from simple anal stenosis to the persistence of a cloaca.

## Incidence

Ranges from 1 in 4000 to 5000 live births, being slightly more common in males.

The most common defect in both males and females is an imperforate anus with a fistula between the distal bowel and the urethra in males or the vestibule of the vagina in females. Low lesions are much more common than high lesions.

May occur as part of the **VACTREL** group of anomalies;

-Vertebral body segmentation defects - Hemivertebra, Sacral agenesis, spina bifida, scoliosis, kyphosis.

-Anorectal malformations.

-Cardiovascular - PDA, VSD

-Tracheo-Esophageal anomalies TOF, esophageal atresia

-Radial ray hypoplasia; unilateral Renal agenesis or ectopia

-Limb anomalies-amelia, pharyngeal anomalies-reduction or addition anomalies

## Embryology

From the 4th to 7th weeks, the Primitive cloaca, derived from the primitive hind gut (endoderm) is divided by the urorectal septum by its caudal growth into:

Ventral cloaca (urogenital sinus) - gives rise to the urinary bladder, urethra & vestibule of the vagina

Dorsal cloaca(anorectal canal) - gives rise to the rectum & anal canal which fuses with the Proctodeum (an invagination of the ectoderm which eventually breaks down by the 8th week) to give rise to the anus

-Failure of the urorectal septum to form results in a fistula between the bowel and urinary tract (in males) or the vagina (in females).

-The urorectal septum divides the cloacal membrane into the urogenital (anteriorly) and anal (membrane posteriorly).

Complete or partial failure of the anal membrane to resorb results in an anal agenesis or stenosis.

-The perineum also contributes to development of the external anal opening and genitalia by formation of cloacal folds that extend from the anterior genital tubercle to the anal membrane.

-The perineal body is formed by fusion of the cloacal folds between the anal and urogenital membranes. Breakdown of the cloacal membrane anywhere along its course results in the external anal opening being anterior to the external sphincter (ie, anteriorly displaced anus).

-Management of anorectal anomalies requires that the level of the rectal pouch and presence of fistula to the urinary tract or vagina be determined; this is important in early management. Evaluating the location of a fistula can be performed at a later time.

## Clinical presentation

1. Absence of anal opening

-Anorectal (or anal) agenesis without fistula

-Anal stenosis/agenesis

2. Single perineal opening with Rectovaginal & Urethral openings immediately behind the clitoris - Cloaca

3. Failure to pass stool/meconium

4. Passing meconium/stool/air;

-Per urethra (mixed with urine).

-Per vagina.

-Ectopic point in perineum.

5. Abdominal distension and Vomiting

## Classification

<b>Wing Spread Classification 1984</b>		<b>Alberto Pena Functional Classification (Requires colostomy)</b>
<b>Male</b>	<b>Female</b>	
<b>Perineal fistula</b>	<b>Perineal fistula</b>	<b>No</b>
<b>High – Above levator ani (Supra levator);</b>		<b>Yes</b>
<ul style="list-style-type: none"> <li>- Anorectal agenesis</li> <li>  * + Rectoprostatic urethral fistula</li> <li>  * Without fistula</li> <li>- Rectovesical fistula (Bladder neck)</li> <li>- Rectal atresia</li> </ul>	<ul style="list-style-type: none"> <li>- Anorectal agenesis</li> <li>  * + Cloaca <math>\geq 3</math>cm common channel – poor sphincter mechanism &amp; poor sacrum</li> <li>  * Without fistula</li> <li>-</li> <li>- Rectal atresia</li> </ul>	
<b>Intermediate – within the levator ani;</b>		<b>Yes</b>
<ul style="list-style-type: none"> <li>- Rectobulbar urethral fistula</li> <li>- Anal agenesis (Imperforate anus) without fistula</li> </ul>	<ul style="list-style-type: none"> <li>- Rectovestibular fistula</li> <li>- Anal agenesis (Imperforate anus) without fistula</li> </ul>	<b>**&gt;1cm bowel skin distance</b>
<b>Low – below the levator ani (Infralevator);</b>		<b>Yes</b>
<ul style="list-style-type: none"> <li>-</li> <li>- Anocutaneous fistula</li> <li>- Anal stenosis</li> </ul>	<ul style="list-style-type: none"> <li>- Anovestibular fistula (commonest)</li> <li>- Anocutaneous fistula</li> <li>- Anal stenosis</li> <li>- Cloaca;</li> <li>  * &lt;3cm common channel – well developed sphincters &amp; good sacrum</li> </ul>	

#### Physical examination

-A piece of gauze is placed around the tip of the penis can be used to check for particles of meconium filtered through this gauze. The presence of meconium in the urine and a flat bottom (flat perineum with short sacrum) are considered indications to create a protective colostomy.

-The presence of a single perineal orifice is pathognomonic of a cloaca. A palpable pelvic mass (hydrocolpos) reinforces the suspicions of a cloaca.

-The diagnosis of a vestibular fistula can be established by a careful separation of the labia to see the vestibule.

Examination to exclude other abnormalities.

#### Investigations

1. **Baby gram**-X-ray showing head to toe. Air in the abdomen may indicate small intestinal atresia

2.No Fistula - **Invertogram** - X-ray with head down hips flexed at 90 degrees and legs flexed at 90 degrees  
Baby held for several minutes to allow air to pass into the rectal pouch

(Alternative - Prone cross-table lateral view)

Best done after 16-24 hr of life - At birth the bowel is not distended; therefore, clinical and radiologic evaluations are not reliable during the first 16–24 hr of life.

To find out the level of the rectal atresia by viewing how far the gas has reached in relation to area where sphincter should be (Put a coin)



High lesions are above the levator. Intermediate lesions are characterized by the rectal pouch ending within the levator, low lesions, the rectal pouch has completely traversed the levator musculature, and a fistula usually is evident on the skin within the midline (ie, anteriorly displaced anus)

2. Fistula - **Colostogram** - Should be done under pressure to illustrate any fistula

### **3. Abdominal U/S**

During the first 24 hrs of life, all these patients need an abdominal ultrasound evaluation to identify an obstructive uropathy especially in patients with;

- Cloaca (Cervix faces posteriorly not downwards thus may obstruct the ureters)
- Rectovesical (Bladder neck) fistula
- Rectoprostatic urethral fistula

### **4. Perineal U/S or MRI**

If required, the level of the rectal pouch can be delineated more definitively by ultrasonography or magnetic resonance imaging. Perineal ultrasonography may be useful in determining the distance between the rectal pouch and the anal skin, In general, a lesion can be considered to be low if the distance from the rectal pouch to the skin, as determined by ultrasonography, is less than 1 cm.

### **Evaluation for other anomalies:**

- 1-Chest x-ray
- 2-Lumbosacral x-ray
- 3-Abdominal pelvic ultrasonography
- 4-Kidney Ureter Bladder KUB x-ray
- 5-IVU
- 6-Echocardiography and ECG
- 7-Passage of nasogastric tube

Congenital anorectal anomalies often co-exist with other lesions, and the VATER or VACTERL association must be considered. Bony abnormalities of the sacrum and spine occur in about one third of patients with anorectal anomalies and consist of absent, accessory, or hemivertebrae and/or an asymmetric or short sacrum.

The absence of two or more vertebrae is associated with poor prognosis in terms of bowel and bladder continence. Occult dysraphism of the spinal cord also may be present, and it consists of tethered cord, lipomeningocele, or fat within the filum.

-Vesicoureteral reflux and hydronephrosis are the most common abnormalities, but other findings such as horseshoe, dysplastic, or absent kidney as well as hypospadias or cryptorchidism also must be considered.

-The higher the anorectal malformation, the more frequent the associated urologic abnormalities. In patients with persistent cloacas or rectovesical fistula, the likelihood of a genitourinary abnormality is approximately 90%.

### **SURGICAL MANAGEMENT**

The newborn infant with a low lesion can have a primary, single-stage repair procedure on the perineum without need for a colostomy. Three basic approaches may be used.

For anal stenosis with a normal location of the anal opening, only simple serial dilatation is necessary.

This should be performed daily (12-Fr size for newborn infants), and the size of the dilator should be increased progressively. Over

several months, the anus ultimately will admit an index finger easily, and the dilatations can be discontinued.

If the anal opening is anterior to the external sphincter (ie, anteriorly displaced anus) with a small distance between the opening and the center of the external sphincter and perineal body also is intact, a cutback anoplasty is performed.

Infants with intermediate or high lesions require a colostomy as the first part of a three-stage reconstruction. In males without fistulae fashioning of a colostomy is an emergency procedure.

**NB.** In females with a fistulae a colostomy may be fashioned at 3months-times when food starts to solidify and cant go through the fistulae.

The colon is completely divided junction of the descending and sigmoid colon region(this is because of good blood supply ,length of gut good mobilization)

The proximal bowel as brought out as colostomy and the distal bowel as a mucous fistula.

The second-stage procedure usually is performed 2-3 months later.

Posterior saggital anorectoplasty it consists

-Surgically dividing the rectourinary or rectovaginal fistula "-Pull-through" of the terminal rectal pouch into the normal anal position.

The patient is left with the protective colostomy to afford healing of the new anal anastomosis.

In males, a urinary catheter remains in place to maintain the lumen of the urethra after repair of the rectourinary fistula.

The third and final stage is performed a few months after the second stage, and it consists of colostomy closure. Anal dilatations are begun 2 weeks after the pull-through procedure and continue for several months after the colostomy closure. A 12-Fr dilator is used for newborns, which is increased up to 14- or 16-Fr for older infants.

All stages of the surgery should be complete before 1 year of age when toilet training id meant to commence.

Alternative is an extended posterior saggital anorectovaginoplasty

### **Summary**

#### **PSARP + Abdominal approach**

- 1.Rectovesical (Bladder neck) fistulae in males
- 2.Rectoprostatic urethral fistula
- 3.≥3cm Cloaca

#### **PSARP only:**

- 1.Rectobulbar urethral fistula
- 2.Anal Agenesis <1cm (*No colostomy*)
- 3.Perineal fistula (*No colostomy*)
- 4.<3cm Cloaca (*Rectovaginal & Rectovestibular fistula*)

### **Post-operative management**

i)-4th day - Sitz baths to remove any bacteria

ii)-10th day - When the wound has healed, start daily Hegars dilatation - Always start the previous days dilator then increase to the next size - to prevent stenosis. Aim for a size in keeping with the child's age (or mother's index finger).

Once the size has been achieved, the mother is taught how to digitally dilate at home for some time.

iii)-Confirm adequacy of anus before closure of colostomy

iv)-If there is faecal soiling, reassess *the sphincter* by performing anal mapping under GA

-If rectum misplaced, then put a colostomy & redo PSARP  
-If rectum is appropriately placed, then manage the patient medically - *constipating diet & high daily enema*

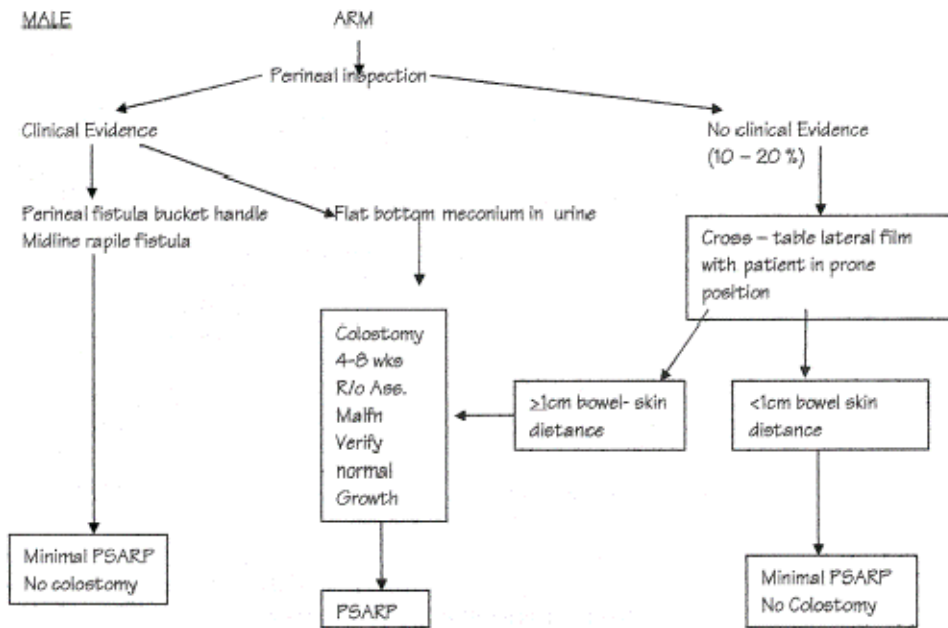
**Prognostic factors**

1.High lesions have poorer prognosis compared to low lesions  
High-Females-Cloacal complex, rectovaginal fistula,  
rectocutaneous fistula

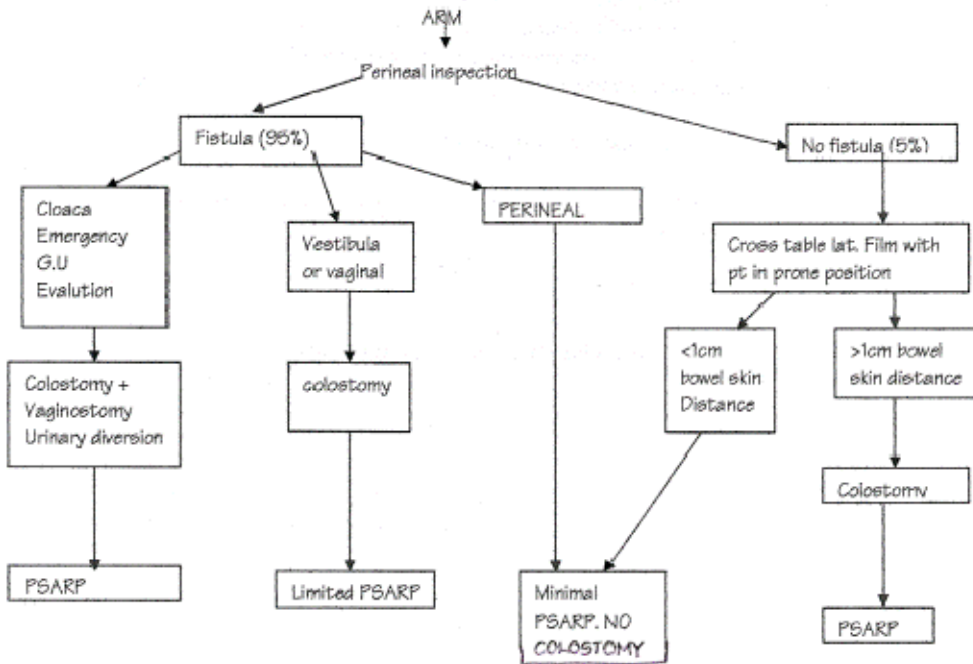
Males-Rectovesical fistula, rectoprostatic fistua(commonest lesion)

2. Timing of the surgery-earlier surgeries have better results.
- 3.Bony abnormalities are associated with poorer prognosis,
- 4.Number of operations-first attempt operation would achieve best results
- 5.Timing of colostomy-done early to avoid megacolon and peristalsis

MALE



FEMALE



# BENIGN PROSTATIC ENLARGEMENT (BPE)

## Etiology

### Thought to related to

1. **Hormones**—balance between testosterone, estrogen, prolactin and growth factors.
2. **Age**—the mesenchymal theory that apoptosis of cells is slowed in favor of cell proliferation with advancing age.

## Pathophysiology

Symptoms of benign prostatic hyperplasia related to either the obstructive component of the prostate or to the secondary response of the bladder to the outlet resistance. Obstruction can be due to either mechanical or dynamic

As prostatic enlargement occurs, mechanical obstruction may result from intrusion into the urethral lumen or bladder neck, resulting in a higher bladder outlet resistance. Prostatic size on digital rectal examination (DRE) correlates poorly with symptoms.

The dynamic component of prostatic obstruction explains the variable nature of the symptoms. The prostatic stroma is composed of smooth muscle and collagen and is rich in adrenergic nerve supply. Level of autonomic stimulation thus sets a "tone" to the prostatic urethra. Alpha-blocker therapy decreases this tone, resulting in a decrease in outlet resistance.

The irritative voiding complaints result from the secondary response of the bladder to the increased outlet resistance. Bladder outlet obstruction results in detrusor muscle hypertrophy and hyperplasia as well as collagen deposition. This leads to a decrease in bladder compliance, but detrusor instability also occurs. Also due to chemical from the urine deposit on the wall of bladder and stimulate contractility

## Clinical presentation

Quiz: Outline the clinical presentation of a patient with benign prostatic enlargement?

## History

Age usually greater than 40 years. With both irritative and obstructive urinary symptoms.

## Irritative Symptoms

Due to chemical from the urine deposit on the wall of bladder and stimulate contractility.

- Nocturia
- Frequency
- Urgency/urge incontinence
- Dysuria

## Obstructive symptoms

Can be mechanical due to the prostatic enlargement or dynamic obstruction- the increased tone of the bladder neck and internal sphincter

- Intermittency/hesitancy
- Poor urinary stream
- Incomplete emptying and dribbling-Acute or chronic RF
- Straining

## Any symptoms of complications:

- Acute urinary retention
  - Suprapubic pain
  - Complete inability to pass urine
- Chronic urinary retention
  - Usually painless
  - Can pass some urine –presence of other complications
- Signs of UTI- Fever, Dysuria and frequency.
- Pyelonephritis-flank pains, fever and vomiting
- Renal failure-Leg edema, scrotal edema

## Physical examination

### General examination-complications

Anemia-chronic renal failure  
Pitting edema.  
Fever-UTI

### Abdominal examination

- Suprapubic distension-acute retention-full bladder.
- Abdominal distension especially flanks-Hydronephrosis
- Suprapubic tenderness and full bladder.

### DRE

- Normal anal sphincter tone.
- Prostate is firm, smooth and mucosa over is mobile
- Medial sulcus felt, the symmetry maintained.

### Neurological examination

- Tests for the sacral plexus to rule out any cause of neurogenic bladder.
  - Perianal sensation and anal wink
  - S1, S2, S3 tests of sensation from the lateral foot and back of thigh and ischial tuberosity.
  - ? Diabetes neuropathy

## Investigations

### Laboratory

#### 1.FHG

- WBC and differential to rule out any UTI
- ESR and C-reactive proteins

#### 2.Urinalysis

Dipstick-nitrites show UTI R/o hematuria  
Microscopy-RBC casts,WBC

#### 3.U/E and Creatinine

Rule out obstructive uropathy to upper tracts

#### 4.PSA

Usually age dependent but 0-4 ng/dl regarded as normal range.

0-49 years	2.5ng/dl
50-59 years	3.5ng/dl
60-69 years	4.5ng /dl
70-79 years	5.5ng/L
>90 years	>6.5ng/dl

### Other conditions with increased PSA include

- 1.Prostatitis
  - 2.Prostatic infarction
  - 3.DRE or prostatic massage for culture
  - 4.Sexual intercourse(when doing PSA patient abstains for 3days)
  - 5.Instrumentation- passing sound
  - 6.Cancer of the prostate
- Predictive value of PSA for cancer prostate
- |                 |   |
|-----------------|---|
| <b>0-4 g/dl</b> | 5% chance(poorly differentiated cancer) |
| 4-10 g/dl       | 25%                                     |

>10g/dl >65%

5. Diabetic Neuropathy - RBS

6. Urine flow rate/urodynamic studies

Using a urine flow meter. Q max is the maximum flow rate in ml/sec.

Normal flow rate in male is 20-25 ml/sec

Females 25-30 ml/sec(short urethra)

Elderly male 60 years 10-15 ml/second

Qmax cut off for intervention is 10 ml/sec

### **Imaging**

1. Abdominal ultrasound

Features to be evaluated:

-Post void residual urine-U/s first on full bladder then patient

voids to determine the residual urine. (Normal - <30mL)

-Size of the prostate

-Upper urinary tract-Bladder, ureters, kidneys for any hydronephrosis

2. Transrectal U/S (TRUS) ± TruCut Biops

3. IVU

Any features of RF

Otherwise optional because its expensive and radiation exposure

IVU and U/S complimentary

4. Urodynamic studies-MCU

Graphic representation of micturition cycle depends on the bladder and the urethra.

Rule out other causes e.g. Strictures, Calculi

5. Pressure-flow studies

Neurological disorders eg

-Back surgery

-Spinal injury

-Medical conditions -DM, Multiple myeloma, Parkinsonism.

Intravesical pressure-chronic obstruction bladder loses its contractility. It gets low.

Maximum intravesical pressure is 60 mmHg. If pressure too low then the patient may not benefit from prostatectomy because of the lack of bladder wall contractility.

Detrusor pressure=Intra-abdominal pressure-intravesical pressure

### **MANAGEMENT-**

**Depend on presentation (acute or Chronic retention), IPSS and response to catheterization.**

**A.ACUTE URINE RETENTION**

-Relieve the obstruction by catheterization-Suprapubic or transurethral.

-Usually use foley's catheter

-Silicone catheter avoids irritation thus better.

-Usually use gauge 16 or 18 for adults

-Catheterization procedure.

- Aseptic technique
- Clean and drape the genitalia
- Clean glans and urethral meatus with 3-4 swabs dipped in antiseptic
- Lubricate foleys catheter with K-Y jelly and or remican jelly. Some jelly may also be applied at the tip of glans penis

- Hold the penile shaft on the palm of the left hand and Apply traction forwards
- Insert the catheter into the urethral meatus, and advance it down the penile urethra to the base of the penis with successive, steady movements.
- Advance the catheter to the hilt (even if urine is obtained earlier) to ensure that the balloon is not inflated in the urethra.
- Inflate the balloon with the proper amount of sterile water for its size (usually 5 mL), and withdraw the catheter until the balloon is pulled snugly against the trigone.
- Obtain a specimen for appropriate tests (at a minimum, routine urinalysis should be performed

Connect the urinary drainage system bag to the catheter

- Tape the catheter to the upper thigh, leaving sufficient slack so that movement of the leg will not pull on the catheter.
- Patient kept on catheter for 2 weeks.

-Meanwhile do urinalysis

-Keep patient on prophylactic antibiotics-Nitrofurantoin,

Nalidixic acid, Quinolones

-Offer medical therapy in terms of the following

a) Alpha-blockers

Prostate <40cm<sup>3</sup> - Drugs of choice -  $\alpha_{1A}$ -blockers e.g..

-Phenoxybenzamine-very toxic

-Prazosine

-Terazosin

-Doxazosine-long acting

-Tamulsine-highly selective for alpha 1 receptors

-Alfuzosine

These ↓ smooth muscle tone (prostate & bladder)

S/E - Drowsiness; depression; dizziness; BP↓; dry mouth;

ejaculatory failure; extrapyramidal signs; nasal congestion;

weight ↑

b) 5 $\alpha$ -reductase inhibitors

e.g. finasteride, duta-steride

Used Prostate >40cm<sup>3</sup> - Reduce testosterone's conversion to

dihydro-testosterone, the androgen which is effective.

Adverse-loss of hair, retrograde ejaculation, impotence

Combination of the two drugs often used.

c) Phytotherapy

Sans -palmetto berries

Pygium africanum

E.purpureae

After two weeks, do a trial without catheter of urine flow and the IPSS score

If the flow rate is more than 10 mls/sec then management depends on the IPSS score and patients desire.

IPSS score of 0-7 (mild) or 8-19(moderate symptoms)

management can be by watchful waiting and lifestyle

modification eg reducing fluid intake intake before bed

-The patient may continue with medical therapy above for 3 months.

Indications for surgery if any of the following:

1. Recurrent urinary retention

2. Flow rate less than 10 ml/second
3. Deteriorating IPSS score
4. Failed medical therapy-compliance? Drug expired?  
Usually medical treatment for 3 months.
5. Upper urinary tract complications as hydronephrosis
6. Recurrent/refractory UTI
7. Renal failure
8. Prostatic calculi
9. Haemorrhage - Occasionally venous bleeding from a ruptured vein overlying the prostate
10. Patient cant afford the medical therapy anymore
11. Patients choice
12. Presence of co-morbidity and deterioration of quality of life.
13. Occupational consideration

If the flow rate is less than 10 mls/sec and severe IPSS score(20-35) then surgical review  
Continue with catheter and medication as they await surgery.

NB. In chronic retention of urine –slow decompression of the bladder by catheterization to avoid bleeding  
If in renal failure then post catheterization go into a diuretic phase

#### **B. PATIENT WITHOUT ACUTE URINE RETENTION**

##### **Do IPSS**

Mild and moderate score do watchful waiting and lifestyle modification.

-reduce fluid intake in evening.

-Stop Alcohol and cigarette smoking

Severe without complications do medical treatment above 20-35 (IPSS).

With complications surgery

##### **Surgery**

##### **Minimally invasive**

1. Intraprostatic stents
2. Balloon dilatation
3. Laser
4. Thermal ablation
5. Cryotherapy
6. Bladder neck incision
7. High Intensity focused ultrasound (HIFU)
8. Transurethral Needle Ablation (TUNA)

##### **Invasive Surgery**

##### **Transurethral Procedures;**

i) **Transurethral Resection of the Prostate (TU-RP)** – (Main)

Indicated for small prostates - 50-60g; Post-op - Put a 3-way catheter (Balloning, irrigation & drainage) for 5-7days

ii) **Transurethral Incision of the Prostate (TU-IP)** - It relieves pressure on the urethra with minimal destruction & less risk of sexual dysfunction - Best surgical option for those with small glands <30gm

iii) **Transurethral Laser-Induced Prostatectomy (TU-LIP)**

##### **Open procedures**

Larger prostates (usually > 75 g) may require open surgery using the suprapubic or retropubic approach, permitting enucleation of the adenomatous tissue from within the surgical capsule. Because larger prostates require longer transurethral resection times, with

an increased risk of TURP syndrome and anesthesia complications.

Transurethral resection of the prostate (TURP)  
50-70g of prostate timed operation 90 minutes

i) **Transvesical prostatectomy** / (Frayer's prostatectomy)

\*Post-op - Twin-tube bladder irrigation with warm saline to wash out clots till effluent is clear (1-2days); Remove urethral catheter after 8-14days.

ii) **Retropubic prostatectomy** / (Milin's prostatectomy)

\*Post-op - Put a 3-way catheter (Balloning, irrigation & drainage) for 5-7days

##### **Advantages of Open Procedures:**

-Reduced re-operation rate (1.8%)

-Peak flow post-operation is good

##### **Transurethral resection of the prostate (TURP)**

Standard is surgery is Transurethral resection of the prostate (TURP) is preferred because of low morbidity . The major complications include bleeding requiring transfusion, failure to void, and infection; rarer is "TURP syndrome," severe hyponatremia due to systemic absorption of the hypotonic bladder irrigation fluid used intra-operatively. Symptoms are referable to excess ammonia production (a glycine metabolite), excess fluid absorption (hyponatremia, hypervolemia), or both (water intoxication)

##### **Ammonia intoxication**

Ammonia encephalopathy may be manifested as a delayed awakening in the postoperative period that persists despite correction of intravascular fluid volume and electrolyte balance. Severe forms-somnolence, marked alteration in consciousness seizures, coma

Patients may develop convulsions and/or oliguria up to 24 hours after the operation

##### **Hyponatremia-Hypervolemia**

Initial hypertension followed by hypotension, bradycardia, headache, visual disturbance, restlessness, chest pain, agitation, confusion, and lethargy

##### **Post-op Advice**

1. Avoid driving for 2wks after the operation

2. Avoid sex for 2wks after surgery

3. Expect to pass blood in the urine for the first 2wks

4. At first you may need to urinate more frequently than before.

In 6wks, things should be much better - but the operation cannot be guaranteed to work (8% fail, & lasting incontinence is a problem in 6%)

5. 12-20% may need repeat TURPs within 8yrs, compared with 1.8% of men undergoing open prostatectomy

6. If feverish, or if urination hurts, do urinalysis, m/c/s.

##### **Complications of TURP**

1. Haematuria/Haemorrhage

2. Infection; proctitis

3. Incontinence - ≤10%

4. Retrograde ejaculation - 65% - Resection of the sphincter in the upper part of the prostate & bladder neck that subserves a sexual function.

5. Erectile Dysfunction - ≤14% - results from damage of the region of the neurovascular bundle supplying the autonomic

innervation to the corpora of the penis in close relationship to the posterolateral aspect of the prostatic capsule

6. Haematospermia

7. Urethral trauma/Stricture

8. Clot retention near strictures

9. Post TURP syndrome ( $\downarrow T^{\circ}$ ,  $\downarrow Na^{+}$ ) - Systemic absorption of the hypotonic bladder irrigation fluid used intraoperatively (usually 1.2% Glycine or Purisol is used - isosmolar & high conductance)

leads to;

- Hypervolaemia with  $\uparrow BP$
- Dilutional  $\downarrow Na^{+}$
- Haemolysis
- Cerebral oedema

Management Diuresis - Furosemide + Mannitol

10. Rupture of the Denonvilliers' fascia causing a faecal fistula

11. 20% need redoing within 10yr

## International prostate symptom score (IPSS)

Name:

Date:

	Not at all	Less than 1	Less than half	About half the	More than half	Almost always	Your score
<b>Incomplete emptying</b> Over the past month, how often have you had a sensation of not emptying your bladder completely after you finish urinating?	0	1	2	3	4	5	
<b>Frequency</b> Over the past month, how often have you had to urinate again less than two hours after you finished urinating?	0	1	2	3	4	5	
<b>Intermittency</b> Over the past month, how often have you found you stopped and started again several times when you urinated?	0	1	2	3	4	5	
<b>Urgency</b> Over the last month, how difficult have you found it to postpone urination?	0	1	2	3	4	5	
<b>Weak stream</b> Over the past month, how often have you had a weak urinary stream?	0	1	2	3	4	5	
<b>Straining</b> Over the past month, how often have you had to push or strain to begin urination?	0	1	2	3	4	5	

	None	1 time	2 times	3 times	4 times	5 times or more	Your score
<b>Nocturia</b> Over the past month, many times did you most	0	1	2	3	4	5	



typically get up to urinate from the time you went to bed until the time you got up in the morning?							
---	--	--	--	--	--	--	--

<b>Total IPSS score</b>	
-------------------------	--

Quality of life due to urinary symptoms	Delighted	Pleased	Mostly satisfied	Mixed – about equally	Mostly dissatisfied	Unhappy	Terrible
If you were to spend the rest of your life with your urinary condition the way it is now, how would you feel about that?	0	1	2	3	4	5	6

**Total score:** 0-7 Mildly symptomatic; 8-19 moderately symptomatic; 20-35 severely symptomatic.

# BLADDER CARCINOMA

## Introduction

- Bladder cancer is a common urologic cancer.
- 4<sup>th</sup> most common tumour in men after lung, prostate and colorectal cancer.
- Most cases are transitional cell carcinoma (TCC) worldwide, often described as polyclonal field change defects. In Kenya the TCC and SCC are thought to be about 50% each.
- Urothelium in the entire urinary tract may be involved, including the renal pelvis, ureter, bladder, and urethra.
- Nonurothelial primary bladder tumors are rare and may include
  - 1) Primary lymphoma
  - 2) Rhabdomyosarcoma
  - 3) Small cell carcinoma
  - 4) Carcinosarcoma
  - 5) Sarcoma

## Sex and Age

- The male-to-female ratio is 3:1.
- Women generally have a worse prognosis than men.
- The median age at diagnosis is 68 years, and the incidence increases directly with age

## Race:

- Bladder cancer is more common in whites than blacks; however, blacks have a worse prognosis

## Pathophysiology:

- Predisposing factors below.
- Adenocarcinomas account for less than 2% of primary bladder tumors.
- These tumors are observed most commonly in exstrophic bladders and are poorly responsive to radiation and chemotherapy. Radical cystectomy is the treatment of choice. Also develop in persistent urachus.
- Most squamous cell carcinomas of the bladder in are associated with persistent inflammations from
  - 1) Chronic cystitis-schistosomiasis
  - 2) Long-term indwelling Foley catheters
  - 3) Bladder stones.
- Small cell carcinomas are thought to arise from neuroendocrine stem cells and are aggressive tumors that carry a poor prognosis.
- Carcinosarcomas are highly malignant tumors that contain both mesenchymal and epithelial elements.
- Primary bladder lymphomas arise in the submucosa of the bladder and are treated with radiation therapy.
- Leiomyosarcoma is the most common sarcoma of the bladder.
- Rhabdomyosarcomas most commonly occur in children and carry a poor prognosis

## Predisposing factors :Environmental

1. Cigarette Smoking-Nitrosamine, 2-naphthylamine, and 4-aminobiphenyl are possible carcinogenic agents
2. Industrial exposure to aromatic amines in dyes, paints, solvents, leather dust, inks, combustion products, rubber, and textiles
3. Prior radiation treatments to the pelvis
4. Exposure to acrolein, a urinary metabolite of cyclophosphamide, increases the risk of bladder cancer.
5. Artificial sweeteners (eg, saccharin, cyclamate)

## SCC

- 1)chronic cystitis-schistosomiasis
- 2)long-term indwelling Foley catheters
- 3)bladder stone

## Genetic

1. Mutations of the tumor suppressor gene *p53*, found on chromosome 17 and Rb gene in chromosome 13.
2. Mutations of the tumor suppressor genes *p15* and *p16*, found on chromosome 9.

## Clinical presentation

### History

1. Painless global hematuria mostly gross hematuria but may be microscopic
  2. Irritative symptoms-dysuria, frequency, urgency
  3. Obstructive symptoms especially around the bladder neck.-poor stream, straining, incomplete emptying
  4. Passage of tissue particles
  5. Mucosuria-Adenocarcinoma
  6. Renal failure signs -oedema
- Inquiry of signs of advanced disease
    - Back pains
    - Hematochezia
    - Pain on defecation
  - Any other bleeding from rest of the body
  - Inquiry of predisposing factors-above

## Physical examination

- Clinical examination is usually normal, although an abdominal or pelvic mass may be palpable in those with advanced disease.
- Anemia -hematuria

## DDX-Causes of heamaturia

1. Hemorrhagic Cystitis: Noninfectious
2. Nephrolithiasis
3. Renal Cell Carcinoma
4. Transitional Cell Carcinoma, Renal
5. Ureteral Trauma
6. UTI

## Investigations

1. FHG-Hb-Anaemia, WBC-UTI, Platelets-Hemorrhage
2. Urinalysis-Nitrites-UTI
  - Microscopy-Microscopic hematuria. In surgical hematuria the RBC are not dysmorphic but in medical RBC may appear dysmorphic.
3. Urine cytology -for malignant cells
4. U/E/C- Upper tract involvement
5. Tumour markers
  - Bladder tumor antigen [BTA-Stat]
  - Nuclear matrix protein [NMP-22]
  - Fibrin/fibrinogen degradation products [FDP]]
  - Telomerase
6. Flexible cystoscopy
  - Urine for cytology
  - Biopsy of the areas with lesions or just sampled biopsy.
  - Resection of superficial tumors.

## TNM Staging for Bladder Cancer

CIS Carcinoma in situ  
 T0-No tumour  
 TX-Tumour cant be assessed  
 Ta- Tumour confined to the epithelium  
 T1- Tumor invasion into the lamina propria  
 T2- Superficial muscle involvement  
 T3a-Deep muscle involvement  
 b-Perivesical fat involvement  
 T4a -Adjacent organs such as prostate, rectum  
 b-Pelvic sidewall involvement

N+ Lymph node metastasis  
 M+ Metastasis

**Medical therapy**

**Intravesical immunotherapy**

**Bacille Calmette-Guérin immunotherapy**

**Indication**

-CIS, T1 tumors, and high-risk Ta tumors  
 -This therapy may help to decrease the rate of recurrence and progression of superficial TCC and may help to treat CIS or unresectable superficial tumors.  
 -BCG immunotherapy is the most effective intravesical therapy and is a live attenuated strain of *Mycobacterium bovis*  
 -It induces a nonspecific, cytokine-mediated immune response to foreign protein. BCG is a live attenuated organism, it can cause an acute disseminated tuberculosis like illness if it enters the bloodstream.

**Imaging**

**1. IVP**

An intravenous pyelogram (IVP) is the criterion standard for upper-tract urothelium imaging. However high radiation and picks only the distortion caused by tumor-thus low sensitivity.

**2. Retrograde pyelography**

**2. Pelvic ultrasonography**

Cheap and available, no radiation. Picks tumours in the kidneys and bladder but poor in the ureters.

**3. CT-scan for staging**

**4. CXR**

-The use of BCG is contraindicated in patients with gross hematuria.  
 -BCG typically causes mild systemic symptoms that resolve within 24-48 hours after intravesical instillation.  
 -BCG also can cause granulomatous cystitis or prostatitis with bladder contraction.

**Other Immunotherapy**

-High dose vitamin A  
 -Interferons and IL-2 and 12  
 -Bropi-ramine

**Intravesical chemotherapy**

-Valrubicin used for CIS that is refractory to BCG  
 -Other forms of adjuvant intravesical chemotherapy for superficial bladder cancer include intravesical triethylenephosphoramidate (Thiotepa), mitomycin C, doxorubicin, and epirubicin.

**Chemotherapy for metastatic cancer**

-The Methotrexate, Vinblastine, Adriamycin, and Cisplatin (M-VAC) or (MAC-V ) combination is the standard treatment of metastatic bladder cancer.

**Surgical Care:**

**A) Superficial bladder cancer (Ta, T1, CIS)**

-Endoscopic resection and fulguration of the bladder tumor adequately treat superficial bladder cancer.  
 -Because bladder cancer is a polyclonal field change defect, continued surveillance is mandatory

**B) Organ-confined, muscle-invasive bladder cancer (eg, T2, T3)**

**Radical cystectomy with urinary diversions**

In men, this is the criterion standard -Remove the bladder, prostate, and pelvic lymph nodes.  
 In women, Anterior pelvic exenteration involves removal of the bladder, urethra, uterus, ovaries, and anterior vaginal wall

**Ileal conduit (incontinent diversion)**

The ileal conduit is the most common incontinent diversion performed.  
 -Small segment of ileum (at least 15 cm proximal to the ileocecal valve) out of gastrointestinal continuity, but maintained on its mesentery, taking care to preserve its blood supply.  
 Restore the gastrointestinal tract with a small bowel anastomosis. Anastomose the ureters to an end or side of this intestinal segment and bring the other end out as a stoma to the abdominal wall.  
 Urine continuously collects in an external collection device worn over the stoma.

**Indiana pouch (continent)**

This is a urinary reservoir created from a detubularized right colon and an efferent limb of terminal ileum  
 Plicate the terminal ileum and bring it to the abdominal wall. The continence mechanism is the ileocecal valve.  
 Empty the Indiana pouch with a clean intermittent catheterization 4-6 times per day.

**C) Locally advanced tumour**

T4-advanced the surrounding organs and pelvic wall.  
 Treatment with radical radiotherapy.  
 Role of salvage cystectomy if recurrence with radiotherapy.

# BREAST CANCER:

## DIAGNOSIS AND MANAGEMENT

### Introduction

- It is the commonest cause of cancer death in women
- It accounts for 6% of all female death

### DIAGNOSIS

#### Diagnosis is by Triple Assessment

- Clinical Evaluation** – Lump and regional nodes
- Imaging (ultrasound <35 years old or mammography >35 years old)**
- Cytology or Histology**

### History

#### Presenting complaints

- Painless breast lump more than 70% of patients.
  - Some present with painful breast lumps due to the following reasons
    - 1) Ishaemic changes and necrosis
    - 2) Inflammatory carcinoma of breast
    - 3) Lympeidema of the breast
    - 4) Local invasion into intercostals spaces and muscles plus nerves
    - 5) Superimposed infection
  - Mass rapid growth -Duration of the mass-Changes with menses
  - Nipple discharge
  - Ulceration and other skin changes-irritation and eczematous skin change
  - Rarely, patients show signs of metastatic disease without a palpable mass in either breast back pain ,cough with hemoptysis.
- #### Advanced disease symptoms
- Chronic cough-lung metastasis
  - Weight loss, anorexia and generalized fatigue
  - Upper limb swelling-axillary lymph nodes involvement with lymph edema
  - Back pain-metastasis to the back ,Yellowness of eyes
- #### History of predisposing factors

- 1) Breast cancer in the contra lateral breast
- 2) Benign breast disease with hyperplasia and atypia ,Benign breast disease with multiple papilomas
- 3) Advancing age>50 years.(Most ca 35-45 years)
- 4) Family history of breast cancer, GIT or ovarian cancer
- 5) Nulliparity
- 6) Early menarche<13 and late menopause>50
- 7) Age at first delivery -If aged 30 years or older, relative risk is 2 times that of patients who gave birth when younger than 20 years.
- 8) Oral contraceptive
- 9) Hormonal replacement therapy
- 10) Whether breast fed and Length of breastfeeding
- 11) Irradiation to chest-therapeutic or occupational
- 12) Obesity
- 13) Cigarette smoking and Alcohol consumption
- 14) Diet-Fatty diet

Any treatment or investigations thus far done

### Physical examination

#### General examination

- General condition
- Wasting ,dehydration
- Anemia
- Lymphenopathy

#### Breast examination

- Explain to the patient the examination and her consent.
- Exposure-All clothes up to the waist removed.
- Patient seated facing the examiner check:

#### Inspection

- Symmetry of the breasts –sizes and Level of the nipples
- Nature of the nipples-everted or inverted and any discharges
- Any masses obvious on inspection –its location and extent, skin changes over it , any ulcers or discharged from it.
- Any other skin changes-ulcers, hyperpigmentation ,peau d'orange ,discharges
- NB.Obvious size discrepancy, nipple inversion, skin dimpling, scaling, and edema (peau d'orange) are suggestive carcinoma

#### Palpation

- Started from the normal side.*
- Do quadrants-lower outer quadrant ,then lower inner ,upper inner, upper outer quadrant and the axillary's tail then peri-areaolar region.
- If any masses fully described-Site, size, shape, temperature,skin changes, tenderness, margins, mobility and attachments, consistency, any thrills or bruits
- Squeeze nipple for any discharge-Ask patient

#### Lymph nodes Exam

- Examine the tail and the axillary lymph nodes-apical, lateral, posterior and anterior
- Supraclavicular, infraclavicular, and axillary lymphadenopathy can be suggestive advanced disease.\

#### NB

- Benign lesions are more frequently smaller, rubbery, well-circumscribed, and mobile. Characteristics suggestive of malignancy include skin involvement, fixation to the chest wall, irregular border, firmness, and enlargement.
- Unilateral nipple discharge, nonmilky fluid, and origin from a single duct. Intraductal papilloma, a benign finding, is the most common cause of unilateral bloody nipple discharge. Other benign pathology associated with nipple discharge includes subareolar duct ectasia and fibrocystic changes. Usually, malignant pathology presenting with nipple discharge also is associated with a palpable mass and/or suggestive mammographic findings.

#### Also examine

- 1.Axillary lymph nodes and supracavicular nodes
- 2.Respiratory system
- 3.Abdominal exam

#### Differential diagnosis of breast cancer

- 1.Giant fibroadenoma , Fibrosarcoma
- 2.Deep breast mycosis
- 3.Chronic breast abscess eg TB
- 4.Secondary malignancies to the breast melanoma-lungs, melanoma
- 5.Cstysarcoma phyloides

### Investigation

#### Mammography

Mammography is the most useful technique for the detection of early breast cancer. The two methods of mammography in common use are ordinary film screen radiography and xeroradiography.

Its sensitivity of is decreased significantly in young patients with dense breast tissue and possibly with augmentation prosthesis. Useful in evaluating the breast for calcifications, architectural distortion, skin thickening, nipple changes, and axillary adenopathy.

Enlargement, stellate shape, irregular or spiculated margins, and the presence of pleomorphic calcifications less than 0.5 mm in a given lesion all are suggestive of malignancy.

**The American College of Radiology established the standard for classification of radiographic abnormalities, known as the Breast Imaging Reporting and Data System (BI-RADS), as follows:**

**0. Incomplete examination - Usually requiring further imaging or evaluation**

**I. Normal - With follow-up study recommended in 1 year**

**II. Benign - Follow-up study in 1 year**

**III. Likely to be benign - Follow-up mammogram in 6 months**

**IV. Suspicious - Consider biopsy**

**V. Highly suspicious for malignancy - Biopsy recommende**

### Ultrasound

As an adjunct to mammography, it can be particularly useful in younger patients or women with fibrocystic change. Its main use remains in distinguishing solid from cystic lesions. In the workup of nonpalpable lesions, US can be used to guide a needle biopsy or to place a localizing wire to direct an excisional biopsy. Other imaging modalities include CT and MRI are used n the evaluation of metastasis

### Diagnostic Procedures:

#### Fine-needle aspiration (FNA)

-One of the first-line diagnostic procedures in the evaluation of a palpable breast mass.

-It is particularly useful in evaluation of cystic lesions.

-Persistence of a palpable mass and recurrence following a repeat aspiration are general indications for open biopsy.

-Bloody cyst fluid should be examined by pathology and warrants an open biopsy.

-Clearly malignant and suggestive lesions warrant an open biopsy.

However, performing a biopsy of benign or indeterminate lesions depends on assessment of individual patient risk and correlation with physical examination findings.

### True-cut (core) needle biopsy

Gives architectural information and determine the invasiveness of a lesion.

This is a distinct advantage over FNA, particularly in patients with large palpable masses suggestive of cancer. In this instance, definitive diagnosis of malignancy by true-cut biopsy may eliminate the need for an open biopsy prior to definitive surgical treatment (eg, modified radical mastectomy, conservation).

### Tissue examination for Estrogen and Progesterone receptors

Benefit for treatment with Tamoxifen-Selective Estrogen

Receptor Modifier

### Also BRCA and 2

### Other Lab investigations

1. FHG
2. LFT
3. U/E/C
4. Tumour markers-carcinoembryonic antigen (CEA), cancer antigen (CA) 15-3, and CA 27.29
5. Chest x-ray

### Histology types

WHO Classification

#### A)Epithelial

##### Non-invasive

- Ductal carcinoma in situ (DCIS)
- Lobular carcinoma in situ (LCIS)

##### Invasive

- Ductal (85%)
- Lobular (1%)
- Mucinous (5%)
- Papillary (<5%)
- Medullary (<5%)

B)Mixed Connective tissue and Epithelial

C)Miscellaneous

### Staging

#### TNM Staging

Tx - Primary tumor cannot be assessed

T0 - No evidence of primary tumor

Tis - Carcinoma in situ

T1 - Tumor ≤ 2 cm in greatest dimension

T2 - Tumor > 2 cm but ≤ 5 cm

T3 - Tumor > 5 cm

T4 - Tumor of any size with direct extension to chest wall or skin (including inflammatory carcinoma)

Nx - Regional lymph nodes cannot be assessed

N0 - No regional lymph node metastases

N1 - Metastases to ipsilateral axillary lymph nodes without fixation

N2 - Metastases to ipsilateral axillary lymph nodes with fixation

N3 - Metastasis to ipsilateral supraclavicular or internal mammary lymph node

Mx - Cannot be assessed

M0 - No metastases

M1 - Distant metastases including ipsilateral supraclavicular lymph nodes

### **Manchester staging system**

Stage I. Tumour confined to breast. Any skin involvement covers an area less than the size of the tumour.

Stage II. Tumour confined to breast. Palpable, mobile axillary nodes.

Stage III. Tumour extends beyond the breast tissue because of skin fixation in an area greater than the size of the tumour or because of ulceration. Tumour fixity underlying fascia.

Stage IV. Distant metastases.

### **MANAGEMENT**

-Supportive

-Specific

-Preventive

#### **Supportive management**

1. Hydration
2. Hematinics or blood transfusion
3. Analgesia
4. Nutritional build up
5. Antibiotics if superimposed infection
6. Counselling

#### **Specific management**

##### **Surgical Management**

##### **Aims of breast cancer surgery**

- To achieve cure if excised before metastatic spread has occurred
- To prevent unpleasant sequelae of local recurrence

##### **Surgical options for the breast**

i) Breast Conserving Surgery (BCS)

BCS is regarded as either wide local excision (lumpectomy), quadrantectomy or segmentectomy

ii) Simple/Total mastectomy

iii) Radical mastectomy - obsolete

Mastectomy + reconstruction (immediate or delayed)

#### **Breast conserving surgery**

##### **Indications:**

- 1) Small (<5cm) single tumours in a large breast
- 2) Peripheral location
- 3) No local advancement or extensive nodal involvement

For tumours that are suitable for breast conservation there is no difference in local recurrence or overall survival when BCS + radiotherapy is compared to mastectomy

##### **Contraindications:**

- a) Multicentricity
- b) Widespread multifocal disease
- c) Central tumours beneath or involving the nipple
- d) Poor tumour differentiation
- e) Disseminated disease

Wide local excision

Remove tumour + a rim of at least 1cm of normal breast

##### **Aims of axillary surgery**

-30-40% of patients with early breast cancer have nodal involvement

-The aims of axillary surgery is to:

- To eradicate local disease

- To determine prognosis to guide adjuvant therapy

- Clinical evaluation of the axilla is unreliable (30% false positive, 30% false negative)

- No reliable imaging techniques available

- Surgical evaluation important and should be considered for all patients with invasive cancer

- Levels of axillary clearance are assessed relative to pectoralis minor

- Level 1 - below pectoralis minor

- Level 2 - up to upper border of pectoralis minor

- Level 3 - to the outer border of the 1<sup>st</sup> rib

- Axillary samplings removes more than 4 nodes

#### **Arguments for axillary clearance**

-Axillary clearance both stages and treats the axilla

-Sampling potentially misses nodes and understages the axilla

-Surgical clearance possibly gains better local control

-Avoids complications of axillary radiotherapy

#### **Arguments for axillary sampling**

-Only stages the axilla

-Must be followed by axillary radiotherapy

-The 60% of patients with node negative disease have unnecessary surgery

-Radical lymphadenectomy in other cancers (e.g. melanoma) produces disappointing results

-Avoids morbidity of axillary surgery

-The combination of axillary clearance and radiotherapy is to be avoided

-Produces unacceptable rate of lymphoedema

#### **Sentinel node biopsy**

-Aims to accurately stage the axilla without the morbidity of axillary clearance

-Technique used to identify the first nodes that tumour drains to

-Can be located following the injection of either

- Radioisotope

- Blue dye

- Combination of isotope and blue dye

-Can be injected in peritumoural, subdermal or subareolar site

-Allows more detailed examination of nodes removed

#### **b) MASTECTOMY**

##### **Indications:**

1. Congenital supernumerary breasts

2. Extensive destruction of breast architecture 2° to;

Chronic infections (*TB, Fungi*), Sarcoidosis, Severe trauma

3. Tumours;

- a) **Early breast cancer** (Carcinoma in-situ)

- b) Large tumours (in relation to the size of the breast)

- c) Central tumours beneath or involving the nipple

- d) Multifocal disease

- e) Local recurrence

- f) Palliative (*Toilet Mastectomy*)

- g) Prophylaxis where there is a strong family history

- h) Patient preference

Landmarks (Surgery is **medial to lateral**);

Upper - Clavicle

Lower - 6th Rib

Medially - Lateral sternal boarder

Laterally - Anterior Axillary Fold

### Types of surgery.

**Total or simple mastectomy:** This describes removal of breast parenchyma, including nipple-areolar complex, with no node dissection. Commonly done

Any form of radical surgery is rarely done

**Modified radical mastectomy:** This procedure involves resection of the breast parenchyma and axillary nodes lateral and behind the medial border of the pectoralis minor (levels I and II).

**Patey modified radical mastectomy:** This describes modified radical mastectomy (MRM) with additional removal of level III nodes requiring division or resection of the pectoralis minor; compared to MRM, this procedure increases lymphedema from 3-10% in the arm.

**Radical (Halsted) mastectomy:** This procedure entails removal of all breast, axillary nodes through level III, and both the pectoralis minor and major muscles.

Rarely done because of associated morbidity following surgery.

## 2. RADIOTHERAPY

Minimum 2 weeks after surgery

-Usually used to clear the breast bed of any residual tumour thus used for local-regional treatment.

Up to a total of 600 grays fractionated.

### Indications

1. Extensive local disease with infiltration of the chest wall-local regional control

2. Heavy node positive disease & Extensive lymphovascular invasion

3. Recurrent disease

4. Secondary to breast conservation surgery (Local radiotherapy) or simple mastectomy (Axillary radiotherapy)

5. Can be used in metastasis to the spine and bone for pain control

## 3. Chemotherapy in breast cancer

Can be given as:

-Primary systemic therapy prior to locoregional treatment -

Adjuvant therapy following locoregional treatment

-Post-operative adjuvant chemotherapy

-Depends primarily on:

- Age / menopausal status
- Nodal status
- Tumour grade

-Combination chemotherapy more effective than single drug

-Most commonly used regimen = CMF (Cyclophosphamide, Methotrexate, 5-Fluorouracil)

-Given **as six cycles at monthly intervals**

-No evidence that more than 6 months treatment is of benefit

-Greatest benefit is seen in pre-menopausal women

-High -dose chemotherapy with stem cell rescue produces no overall survival benefit

### -Primary (neoadjuvant) chemotherapy

-Chemotherapy prior to surgery for large or locally advanced tumours

-Shrinks tumour often allowing breast conserving surgery rather than mastectomy

-70% tumours show a clinical response. In 20-30% this is response is complete

-Surgery required even in those with complete clinical response

-80% of these patients still have histological evidence of tumour

-Primary systemic therapy has not to date been shown to improve survival.

## 4. Systemic Hormonal therapy

Directed at putative micrometastases to delay relapse & prolong survival;

- 1) To palliate symptoms in locally advanced or metastatic disease
- 2) Lymph node +ve
- 3) Poor prognostic node -ve women
- 4) For women with oestrogen or progesterone receptor +ve tumours; mostly post menopausal women. Effective in 8% receptor -ve patients

## Selective Estrogen Receptor Modulators (SERM), Oestrogen receptor antagonists e.g. Tamoxifen

Admin. At 20 mg OD for 5 years.

-Started immediately diagnosis is made

-Also beneficial in reducing tumours in the contra-lateral breast

-Risk of contralateral breast cancer reduced by 40%

-Greater benefit seen in oestrogen receptor rich tumours

Benefit still seen in oestrogen receptor negative tumours

Benefit observed in both pre and post menopausal women

### Adverse effects.

1. Endometrial changes - Hyperplasia, polyps, cancer & uterine sarcoma
2. Thromboembolism
3. Occasional cystic ovarian swellings in premenopausal women
4. Occasional hypercalcaemia if bony metastases

## Other hormonal drugs

### 1. Oral aromatase inhibitors e.g. anastrozole

-These block conversion of androgens to oestrogens in the peripheral tissues.

-For post-menopausal women who are unable to take tamoxifen therapy because of high risk thromboembolism or endometrial abnormalities

### 2. Gonadorelin (LHRH) analogues e.g. Goserelin

-Induce a reversible ovarian suppression.

-Ovarian ablation in pre-menopausal receptor +ve patients.

-Management of advanced breast cancer in pre-menopausal women

### 3. Monoclonal antibody -Tras-tuzu-mab

Tumours +ve for the **HER2** protein may respond

## Symptomatic & Terminal care

Hospice care

DXT to painful bony lesions

## Biochemical measurements

### 1. Hormone and growth factor receptors

-ER positivity predicts for response to endocrine manipulation  
-EGF receptors are negatively correlated with ER and poorer prognosis

### 2. Oncogenes

Tumours that express C-erb-B2 oncogene likely to be  
-Resistant to CMF chemotherapy  
-Resistant to hormonal therapy  
Respond to anthracycline and taxols

### 3. Proteases

-Urokinase and cathepsin D found in breast cancer  
-Presence confers a poorer prognosis

### Inflammatory Breast Cancer

Inflammatory breast cancer is the appearance of inflamed breasts (red and warm) with dimples and/or ridges caused by the infiltration of tumor cells into the lymphatics. Inflammatory breast cancer can sometimes be difficult to distinguish between benign (non-cancerous) conditions (such as mastitis) and inflammatory malignancy (cancerous conditions). Though rare, inflammatory breast cancer may spread quickly to other parts of the body.

Treatment of inflammatory breast cancer treatment is generally quite similar to the treatment of Stage IIIB or IV breast cancer. In addition, patients usually undergo chemotherapy, hormonal therapy and/or radiation treatment.

-Patients who respond positively to systemic treatment may be candidates for mastectomy.

### Paget's Disease of the Nipple

Paget's disease of the nipple is a rare form of breast cancer that begins in the milk ducts and spreads to the skin of the nipple and areola.

The skin may appear crusted, red, or oozing.

Prognosis is better if nipple changes are the only sign of the breast disease and no lump is felt.

### Recurrence of Breast Cancer

Women who experience a recurrence of breast cancer after lumpectomy are often treated simply by mastectomy (with or without breast reconstruction).

If cancer reoccurs after mastectomy, additional surgery may be necessary to remove tumors near the mastectomy site, followed by radiation therapy. Chemotherapy and/or hormonal therapy may also be administered.

Alternative treatment options for recurrent breast cancer include:

- Hormone therapy
- Surgery and/or radiation therapy if cancer is confined to one area and is operable
- Entry into a clinical trial testing new chemotherapy or hormonal drugs, or biological therapy

### PREVENTION

1. **Breast self-examination**, performed monthly, is recommended for women beginning at 18 years.

2. **Annual evaluation** -With mammography. is advised for those older than 40

3. **Same done annually irrespective** of age after removal of contra lateral breast for breast cancer

### 4. Removal of breast lumps

5. **Tamoxifen is approved** use in healthy women at high risk for the development of invasive breast cancer and for patients with early invasive lesions at risk of secondary contralateral cancer.

6. **Lifestyle modification**-diet, cigarette and alcohol smoking stopped

7. **Prophylactic mastectomy**-patients with strong family history and ask for it themselves

### Prognosis

#### Prognostic factors

-50% women with operable breast cancer who receive locoregional treatment alone will die from metastatic disease.

-Prognostic factors have three main uses:

1. To select appropriate adjuvant therapy according to prognosis
2. To allow comparison of treatment between similar groups of patient at risk of recurrence or death
3. To improve the understanding of the disease

### Prognostic factors can be grouped

#### Chronological prognostic factors

##### 1. Age

Younger women have poorer prognosis of equivalent stage

##### 2. Tumor size

Diameter of tumour correlates directly with survival

##### 3. Lymph node status

-Single best prognostic factor  
-Direct correlation between number and level of nodes involved and survival

##### 4. Metastases

Distant metastases worsen survival

#### Biological prognostic factors

##### 1. Histological type

Some histological types associated with improved prognosis:

Tubular, Cribriform, Mucinous, Papillary Micro-invasive

##### 2. Histological grade

Three characteristics allow scoring of grade into grades one, two or three depending on:

- Tubule formation
- Nuclear pleomorphism
- Mitotic frequency

##### 3. Lymphatic / vascular invasion

-25% operable breast cancers have lympho-vascular invasion  
• Double risk of local relapse, Higher risk of short term systemic relapse

### Paget's Disease of the Nipple

*Paget's disease of the nipple is a rare form of breast cancer that begins in the milk ducts and spreads to the skin of the nipple and areola.*

*The skin may appear crusted, red, or oozing.*

*Prognosis is better if nipple changes are the only sign of the breast disease and no lump is felt.*

### Recurrence of Breast Cancer

*Women who experience a recurrence of breast cancer after lumpectomy are often treated simply by mastectomy (with or without breast reconstruction).*

*If cancer reoccurs after mastectomy, additional surgery may be necessary to remove tumors near the mastectomy site, followed by radiation therapy. Chemotherapy and/or hormonal therapy may also be administered.*



*Alternative treatment options for recurrent breast cancer include:*

- *Hormone therapy*
- *Surgery and/or radiation therapy if cancer is confined to one area and is operable*
- *Entry into a clinical trial testing new chemotherapy or hormonal drugs, or biological therapy*

***Inflammatory Breast Cancer***

*Inflammatory breast cancer is the appearance of inflamed breasts (red and warm) with dimples and/or ridges caused by the infiltration of tumor cells into the lymphatics. Inflammatory breast cancer can sometimes be difficult to distinguish between benign (non-cancerous) conditions (such as mastitis) and inflammatory malignancy (cancerous conditions). Though rare, inflammatory breast cancer may spread quickly to other parts of the body.*

*Treatment of inflammatory breast cancer treatment is generally quite similar to the treatment of Stage IIIB or IV breast cancer. In addition, patients usually undergo chemotherapy, hormonal therapy and/or radiation treatment.*

*-Patients who respond positively to systemic treatment may be candidates for mastectomy.*

# BURNS

## Definition

Tissue injury caused by thermal, radiation, chemical, or electrical contact resulting in protein denaturation, loss of intravascular fluid volume due to increased vascular permeability and oedema.

## **Incidence**

100% about 1/3 of whom require admission

## **Etiology**

Chemical, Thermal, Electrical, Mechanical, Radiation, Frost bite

## **Persons at Risk of burns**

1. Extremes of age - the very young (<4yrs) or very old (>50yrs)
2. Those whose ability to protect themselves is impaired or prone to accidents Alcoholics, Sick, paraplegics, diabetics, psychiatric patients and patients of convulsive disorders
3. The unlucky - Innocent bystander
4. The careless - Storing petrol in the house, adding paraffin to a lit stove, smoking in bed, working close to high tension electric wires

## Skin Anatomy and Function

Skin is the largest organ of the body. It is 0.025 m<sup>2</sup> in children and **1.8m<sup>2</sup>** in adults. It has 3 major tissue layers.

## **Epidermis**

The outermost layer, the epidermis, is composed of stratified epithelium.

Epidermis has two components, an outer layer of anucleate cornified cells (stratum corneum) that covers inner layers of viable cells (Malpighian layers) from which the cornified surface cells arise by differentiation. The stratum corneum acts as a barrier to impede the entrance of microorganisms and toxic substances while allowing the body to retain water and electrolytes. Malpighian layers provide a continuous production of cornified cells. Malpighian layers can be further subdivided into the germinal basal cell layer, stratum spinosum, and stratum granulosum

## **Dermis**

Beneath the epidermis is the dermis, which is composed of a dense fibroelastic connective-tissue stroma containing collagen and elastic fibers and an extracellular gel termed ground substance.

The dermal layer contains an extensive vascular and nerve network, special glands, and appendages that communicate with the overlying epidermis. The dermis is divided into two parts.

- a) The most superficial portion, the papillary dermis, is molded against the epidermis and contains superficial elements of the microcirculation of the skin. Within the papillary dermis, dermal elevations indent the inner surface of the epidermis
- b) In the reticular portion of the dermis, collagen and elastic fibers are thicker and greater in number. Fewer cells and less ground substance are found in the reticular dermis than in the papillary dermis

**Subcutaneous tissue** The third layer of skin is subcutaneous tissue, which is composed primarily of areolar and fatty

connective tissue. This layer shows great regional variations in thickness and adipose content. It contains skin appendages, glands, and hair follicles

## Functions of skin

1. Protect entry of micro-organism
2. Protect against UV light
3. Vitamin D synthesis
4. Homeostasis-Thermoregulation and prevent excess water loss
5. Cosmesis, beauty and identification-finger prints

## Pathophysiology of Burns

-Tissue damage due to above agents leads to release of vasoactive substances e.g. prostaglandins, histamines, oxygen radicals, leukotrienes & platelet activating factors

-This cause microvascular instability w/ith increased capillary permeability for the first 24-36hrs fluid shift to extravascular compartment and oedema.

- This leads to decreased right atrial filling pressures decreased CO and Shock.

-The body tries to compensate for these physiological changes by

- Increased peripheral resistance (sympathetic stimulation)
- Tachycardia
- Decreased capacitance of great vessels

If the process goes uncorrected;

- Cardiac output is diverted to vital tissues reducing perfusion of skin, muscle & gut - Skin feels cold & clammy
- Reduced renal perfusion lead to acute RE

-Irreversible shock occurs as an end stage with falling BP, CO & PR

-In patients with serious burns, release of catecholamines, vasopressin, and angiotensin causes peripheral and splanchnic bed vasoconstriction that can compromise in-organ perfusion

-Myocardial contractility also may be reduced by the release of inflammatory cytokine TNF-alpha

-In deep third-degree burns, hemolysis may be encountered, necessitating blood transfusions to restore blood loss

-A decrease in pulmonary function can occur in severely burned patients without evidence of inhalation injury from the bronchoconstriction caused by humoral factors, such as histamine, serotonin, and thromboxane A<sub>2</sub>.

-A decrease in lung and tissue compliance is a manifestation of this reduction in pulmonary function.

Burned skin exhibits an increased evaporative water loss associated with an obligatory concurrent heat loss, which lead to dehydration and hypothermia.

## Classification

### A. According to Cause:

#### 1. Thermal

Open flames and Hot liquid are most common (heat usually ≥15-45°C)

2. Caustic chemicals or acids (may show little signs or symptoms for the first few days)

Mechanisms of injury:

#### -Extravasation

Due to drug leakage into tissues e.g. All Cytotoxics, Sulphur drugs, Potassium drugs, bismuth drugs

Causes Inflammation, vesicles; Skin necrosis may occur within 24hrs & Gangrene secondary to vascular spasm in 2-3days. Mx- Prevention close monitoring, Iv line in forearm and flush line well.

Once it occurs –stop drug Apply normal saline gauze and change every 2 hours

**Contact injury**

Paraffin: Types of injury

- Local chemical reaction
- Thermal injuries
- Inhalational injuries (chemical pneumonitis and bronchospasm)
- Systemic poisoning

Acids - Cause severe superficial **coagulative necrosis**. Burning stops within 1-2hrs for HCL & H2SO4 & 7-14days for HOCL - Amount ingested does not contribute to extent of injury. -Initial mx-pour a lot of water for long 1-2 hours, dress with clean material and control pain.

- Can Excise area to prevent continued reaction
- Usually the graft take is very disappointing
- Alkali - Causes deep **liquifactive necrosis** - penetrate tissue by saponification (Fat +alkali) , hydrolyzing structural proteins & dissolving cells along it's course thus amount ingested contributes to extent of injury. The burn runs for 7-14 days.

Management - Generously irrigate with fluid for 1-2 hours & Dress in gauze soaked in NS or Ice 2-3hrly.

DO NOT try to neutralize the chemical. Can excise the area to prevent continued reaction.

**3.Electricity**

Types low voltage ,high voltage and very high voltage Low voltage is <1000 volts while high voltage is > 1000 volts. Very high voltage include injury from the grid and lightening injuries

- Have entry and exit points. Main injuries are
- Myonecrosis, Renal failure and Heart arrhythmia
- Myonecrosis lead Myoglobinuria causing to Renal failure with very little damage to overlying skin.
- Arching burn -Occur around joints due to burn at joint surrounded by two areas of conductance.
- Side flash-Very high voltage burns due to lightening.
- Body resistance is about 500ohms.Current of 1 ampere is required to cause cardiac asystole this usually does not occur with domestic electric burns because the voltage is about 240V giving current of approx. 0.5 A.
- Thus TBSA is NOT an index for resuscitation. IV fluids are titrated against the volume of urine & specific gravity (1.010). Usually X2 the physiological requirements (3L/24hrs) of the patient.

- In microwave injuries, the area is normal looking but anaesthetic due to depolarization of nerves
- Flash burns occur in technicians & may resemble open flame burns

- Mx - Give plenty of fluids
- Alkalinizing the urine and admin of mannitol aid in Flushing the myoglobin from the kidney
- Do **fasciotomy** of muscle compartment to avoid Compartment syndrome. Normal pressure is 30mmHg
- Debride after 3-4days

**4.Frostbite**

**5.Mechanical (Frictional) burns**

**6.Radiation injury**

**B. According to Depth of Injury**

Depth of burn proportional to;

- Temperature applied
- Duration of contact
- Thickness of the skin
- Heat capacity of the agent
- Transfer coefficient
- The specific heat and conductivity of the local tissues

The depth of injury determines formation of scar tissue.

**1st Degree Burns;**

- Epidermis only involved
- Commonly caused by UV light or very short flash or flame exposure
- Skin is red, dry & hypersensitive thus painful
- No treatment except analgesia.
- Leaves no scarring on healing

**2nd Degree Burns:**

- Superficial 2<sup>nd</sup> Degree
- Epidermis + Upper 1/3 of Dermis
- Commonly caused by scald (spill or splash)
- Red, moist, weeping, cob blisters that Blanche with pressure
- Painful - due to nerve exposure, & heals from **10-14days**
- Leaves no scarring on healing but there is potential pigment changes

**Deep 2<sup>nd</sup> Degree**

- Epidermis + Upper 2/3 of Dermis
- Commonly caused by scald, flame, chemicals, oil & grease
- Cheesy white, wet or waxy dry; Do not Blanche with pressure
- Healing takes **14-21days**
- Severe scarring & risk of contractures

**3rd Degree Burns (Full Thickness Burns):**

- Full Epidermis + Dermis are destroyed leaving no cells to heal and extends to the subcutaneous tissue.
- Commonly caused by scald, steam, flame, chemicals, oil, grease & high voltage electricity
- Grey to charred & black, insensate, contracted, pale, leathery tissue
- Severe scarring & high risk of contractures

**4th Degree Burns**

Muscle involvement

**5th Degree Burns**

Bone involvement - Especially in epileptics who convulse during burning

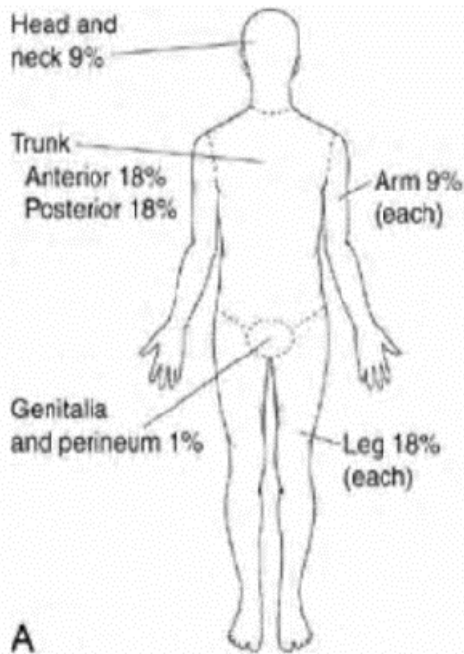
**C. According to Size of Burn**

Determines extent of fluid loss.

Wallace Rule of Nines - used in Adults to estimate BSA (Body surface Area)

	Minor burn	Moderate burn	Severe Burn
BSA in Young or Old	<10%	10-15%	>15%
BSA in	<15%	15-25%	>25%

Adults			
3 <sup>rd</sup> Degree burn	<1%	2-5%	>5%
Treatment	Outpatient	Inpatient	Burn unit/ICU



- ii) American Burn Association Burn Severity  
iii) **Lund-Browder Chart** for estimating the extent of burns in Children

**NB. Zones of a burn wound**

1. Centre-coagulate necrosis
  2. Immediate area-zone of stasis
  3. Further-zone of hyperemia
- Depth of wound estimation  
Clinical-Apperance, Pin prick test, use of dye  
Imaging-U/S,MRI

Major or Severe Burns also includes:

1. High voltage Electrical burns
2. Significant burn to face, eyes, ears, fingers, feet, joints, or genitalia
3. Significant associated injuries e.g. fractures & other major trauma
4. Inhalational Injuries

Inhalational injury

Classified as supraglottic ,subglottic , or Global  
Causes upper airway obstruction secondary to;  
-Reflex Laryngospasm  
-Oedema  
-Sloughing of the mucosa , reduced clearance blockage and infection( Pneumonia)

Clinical presentation

-History of having been injured in an enclosed space e.g. house, motor vehicle

-Physical examination

- 1) Facial burns
- 2) Soot in nasopharynx
- 3) Respiratory distress- Tachypnoea -  $\geq 25$  breaths/min ,Stridor, flaring of alae nasae
- 4) Coughing up carbonaceous sputum/soot
- 5) Hoarseness of voice (will indicate vocal cord swelling)

Management

- 1) **Admit** patient to High dependency care or ICU
- 2) **Intubate earliest opportunity** to avoid difficulty once edema sets in.

**Tracheostomy** is indicated in the first several days for patients who are expected to require ventilatory support for a few weeks or more.

If the neck is burned, excision and grafting followed by tracheostomy is indicated in order to improve pulmonary toilet.

- 3) **Give 100% O2 by Mask** or Endotracheal tube in serious inhalational injury. Should be moist the humidity will help loosen the secretions and prevent drying of the airway;
- 4) **Bronchodilators** by aerosol or aminophylline intravenously may help if wheezing is due to reflex bronchospasm.
- 5) **Suction /lavage of bronchial secretions** (bronchial toilet)
- 6) **Chest physiotherapy** with postural drainage is also required.
- 7) **Bronchoscopy** to evaluate extent of inhalational injury at same time do bronchial toilet
- 8) **Investigation**-Measure **carboxyhaemoglobin**; With 100% O2, t $\frac{1}{2}$  of CO Hb falls from 250mins to 40mins

**Others investigations**

- BGA
- Hb
- CXR.

NB Pulse oximetry - Unreliable (may be normal)  
Patient need about 10-15 % more of IV fluid calculated)

Rescue & First Aid

**General considerations;**

-Electric burns - turn off mains before touching patient  
-If the victims clothes are on fire - Stop, Drop & Roll.Can cover with blanket to put off the fire

**1st Degree Burns;**

-Cool burned area of skin for **5-10mins** (running water, cool compress or towel, immersion in cold water)  
-After 10mins, dry area & keep the patient warm to avoid hypothermia  
-Drink lots of fluids - Sweetened water with pinch of salt PRN  
-Analgesics  $\pm$  Anti-inflammatories e.g. Ibuprofen or Acetaminophen  
-Cover burn with cool sterile dressing

**2nd Degree Burns;**

-Call Emergency services  
-**DO NOT** break or drain the blisters  
-**DO NOT** remove stuck clothing  
-Cool burned area of skin for **5-10mins** (running water, cool compress or towel, immersion in cold water)  
Once immersed in cool water, carefully remove clothing & jewellery on burnt area

- After 10mins, dry area & keep the patient warm to avoid hypothermia
- Evaluate for signs of shock & treat accordingly
- Elevate burnt area if possible
- Cover burn with cool sterile dressing - DO NOT apply ointment, lotion or anything.

### Indications for Admission

#### A.Cause:

- 1)Electrical burns including lightning injuries
- 2)Chemical burns with serious threat of function or cosmetic impairment

#### B)Severity:

- 1) Moderate & Severe burns
- 2) 3rd & 4<sup>th</sup> Degree burns regardless of TBSA
- 3) Non-healing burns after **14-21days**

#### C)Anatomical location:

- 1)Head, neck, hands, soles, Perineum
- 2)Circumferential limb burns
- 3)Burns to the back
- 4) All inhalational injuries

#### D)Patient factors:

- 1)Extremes of age (<4yrs & >50yrs)
- 2)Burns of both limbs in an Obese patient
- 3)Pregnancy
- 4)Any burn with concomitant trauma in which the injury poses the greatest risk of morbidity or mortality
- 5)Burn injuries with pre-existing medical disorders that could complicate management, prolong recovery or affect mortality e.g.
  - Diabetes and Hypertension
  - Epilepsy
  - Blind or Deaf
  - Infection
  - Renal problems

### Casualty and Ward Management Goals

- A. The first 48hrs - All efforts are towards resuscitation & saving lives
- B.48hrs -6months- Prevention of complications
- C.>6months- Reconstructive surgery, Rehabilitation, Training

### The first 48hrs

#### On arrival at casualty

1.Primary Survey - Airway with cervical spine control (Look out for & manage inhalational injury), Breathing, Circulation & haemorrhage control, Disability & Exposure

At this point -IV access large bore

- Central Venous Pressure Monitor (CVP)
- Urethral catheterization
- NG tube
- Endotracheal intubation if inhalational burn

#### 2.Secondary Survey

- History of the burn
- Physical examination from head toe - Calculation of the BSA

#### 3.Medical Management

#### i) IV Fluids

For Moderate & Major/Severe Burns

#### **-Parkland's Formula**

#### **4mL/Kg /TBSA**

- Crystalloids: Ringers Lactate or Hartmann's solution, NS
- Give ½ within 8hrs since the burn occurred and the rest in the next 16hrs(most fluid loss occur 8-12 hours after the burn)
- Give ~50% more in electrical burns & inhalational injury

#### Monitoring of fluid therapy

1-Adequate resuscitation is measured by urine output; (best guide)

Adults - 30-50mls/hr and Children - 0.5-1ml/Kg/hr

-Increase rate of infusion if the urine is less than 20ml/hr and decrease rate of infusion if the urine output greater than 60ml/hr because of risk of pulmonary oedema especially in inhalational injury

-However in electrical burns aim for 100ml/hr of urine to flush the kidney. Alkalinization of the urine by adding sodium bicarbonate to the IV fluid increases the solubility and clearance rate of myoglobin in the urine

-Hemoglobinuria suggest deep burn hence flush the kidney with increased fluids and mannitol

-Decrease in BP and urine output suggest need for colloids but a decrease in urine output but normal BP suggest need for crystalloids

2- Pulse and BP recording .Pulse should be less than 120/minute

3-State of patient should be calm

4--Frequent chest auscultation to detect pulmonary oedema

5-Cerebral oedema especially in children may occur during fluid therapy

6-If possible CVP line is best guide for avoiding over infusion

7-Evaluate treatment every 3-4 hours

#### Causes of inadequate fluid resuscitation in a burns patient

Inaccurate estimate of burn size, Undiagnosed inhalational injury ,Concomitant traumatic injury, Cardiac dysfunction, Refractory shock, Mathematiciscalculation

-**Neosporin or Bacitracin** - Good for facial burns as they are not toxic to the eyes

OR - Apply antibiotic impregnated material

#### Other formulas for calculating fluids include:

##### 1.Evans Formula

**2ml/Kg/TBSA**

NB

-TBSA only up to 50 %

-Total fluid given as mixture of colloids and crystalloids in the ration of 1:1.

Colloid include, **blood and blood products**- plasma, albumin

,**dextrans, Gelatins** as haemacelle and Gelofulsine

Crystalloids are Normal Saline, Hartmans solutions

-Add 2000ml(2L) of 5% dextrose for insensible losses

-Half of all the fluids given I the 1<sup>st</sup> 8 hrs since occurrence of burn and the rest in next 16 hours

-After 24 hours give half of the fluids (1ml/kg/BSA) plus the 2L of 5 % dextrose.

##### 2.Brook Army formula

**2ml/Kg/TBSA**

NB

-TBSA only up to 50 %

-Total fluid given as mixture of crystalloids and colloids in the ration of 1.5:0.5 respectively

-Colloid include plasma, blood, dextrans, albumin

- Crystalloids are Saline, Hartmans solutions
- Add 2000ml(2L) of 5% dextrose for insensible losses
- Half of all the fluids given I the 1<sup>st</sup> 8 hrs since occurrence of burn and the rest in next 16 hours
- After 24 hours give half of the fluids (1ml/kg/BSA) plus the 2L of 5 % dextrose.

#### **ii) Analgesics**

Give opiate analgesics IV (IM is ineffective erratic absorption); NSAIDS

#### **iii) PPI or H2 Blocker**

protection from Curling's Ulcers (duodenal ulcers which occur in burned patients)

#### **iv) Tetanus toxoid**

#### **v) Prophylactic antibiotics If TBSA >15%**

If less do M/C and sensitivity before antibiotic administration

#### **vi) Optional Drugs**

- DVT prophylaxis in lower limb burns
- Tetracycline eye ointment for Face burns
- Insulin if Diabetic or hypertensive control if hypertensive

#### **Wound care**

- i) Remove all necrotic tissue & debris
- ii) Rupture blisters except those on the palms & soles of feet and those >1cm in diameter. Can do early escharectomy and grafting
- iii) Wash wound with soap & water or normal saline
- iv) Apply **topical antibiotic** e.g.
  - Silver sulphadiazine** (S/E - thrombocytopenia, leucopenia, rash-sulfonamide sensitivity)
  - 0.5% Silver Nitrate** - Stains tissues & can cause hypochloremic alkalosis & hyponatraemia; Good for grafts
  - Mafenide 10%** - can penetrate tissue & eschar. Good for infected wounds & eschars. very painful on application; carbonic anhydrase inhibition causing metabolic acidosis; sulfonamide sensitivity rash

#### **v) Dressing**

Open Dressing - No dressing applied  
 Exposure Dressing - Apply soothant e.g. Vaseline  
 Occlusive dressing e.g. for small superficial previously debrided wounds  
 Apply non-stick material e.g. Bactigras  
 -Apply **3-5 layers** of dry material e.g. gauze  
 -Cover with crepe bandage  
 -Change **after 3days** & then **daily** up to **day 21**. If there is no healing, consider skin grafting.  
 -Silver sulfadiazine/transparent polythene bags **for hands**  
 -Skin grafting e.g. for frictional burns.

#### **Indications for occlusive dressing**

- If the burn is oozing too much
- If there is risk of infection
- Children
- If co-morbid conditions present
- Joints
- Patient's comfort

#### **vi) Skin grafting**

If wounds don't heal between 21-30 days. Skin graft immediately for frictional burn. It encourages healing.

Graft-any tissue removed from one anatomical part of the body to recipient floor and its survival depend on the floor.(blood transfusion is not a graft)

Flap-(Pediculated graft) –removed with own blood supply. Any part of the body can donate except the perineum and below the eyes.

Skin graft types: Split thickness and Full thickness grafts

1<sup>st</sup> 24 hours –graft survives by osmosis

Next 48 hours Neovascularization .Beyond its take or non-take (rejected)

Donor site kept dressed for 10-14 days.

Grafting across joints should apply splints to facilitate take

#### **Biological dressing**

-Amniotic membrane

-Graft from mother allograft which is rejected in 2 weeks but left in situ as a biological graft.

#### **Other considerations:**

##### **Face burns**

Intubate patient & do temporary tarsorrhaphy (suturing eyelids together).

Whistling and blowing mouth for physiotherapy

##### **In neck burns**

A pillow is placed under the patients head to hyperextend the neck

Pillow below the shoulders to prevent contractures

##### **Chest wall burns**

2<sup>nd</sup> and 3<sup>rd</sup> degree burns do occlusive dressing

Do escharotomy for any scar constricting respiratory movements-

Do a checker-box release

##### **Upper limb burns**

Should be nursed elevated at 45° to reduce oedema

Escharotomy lateral and medial also in the web spaces

Patient on bed with a pillow between his shoulders to prevent contractures.

#### **Investigations in the first 48 hours**

1.FHG-Hb determination

Blood group and GXM if HB <10g/dl

2.U/E and Creatinine-Renal function and any electrolyte derangement

3.Blood Gas analysis and carboxy haemoglobin if inhalational burn

4.Input/output chart

#### **Nutritional support**

*Curreri formula* - 25KCal/Kg + (40KCal \* %TBSA)

Because burn injury causes a hypermetabolic state that is characterized by a dramatic increase in resting energy expenditure, nutritional support is essential, especially via the enteral route, to reduce intestinal villous atrophy

#### **48hrs - 6months Management is based on complication control**

##### **Escharotomies**

Surgical division of constricting eschars (scab formed especially after a burn).

Indications;

- 3rd & 4th Degree Burns
- Circumferential burns - may compromise distal extremity blood flow. Performed on the midlateral or medial aspects of limbs, chest burns that would impair respiration

### Escharectomy

**Surgical** –Tangential excision

**Medical** –Use of mafenide , soaking with NS

### After 6months - Reconstructive surgery, Training &

#### Rehabilitation

-Physiotherapy - Splint at night & Motion during the day

- To control pain
- Reduce oedema & swelling
- To protect the wound
- To minimize cosmetic defects
- To maximise patient's function

-Start physiotherapy from day after escharotomy- do it 5 times a week. At night do nocturnal splintage and for sleep comfort and avoid contractures

#### Lower limbs

Encourage movements to avoid DVT.

NB If  $\geq 80\%$  TBSA - Supervised Neglect

-Occupational therapy - To rehabilitate the patient back into functional living

-Psychiatric rehabilitation

#### **1month - 1yr**

Hypertrophic scars - Itchy, Hyperaemic, Uncomfortable

#### **Over 1yr**

**Keloids** - A keloid is a true tumour arising from the connective tissue elements of the dermis.

By definition, keloids grow beyond the margins of the original injury or scar; in some instances, they may grow to enormous size.

Mx - Local injection of Steroids & Bleomycin, Excision & Superficial irradiation

#### Contractures

#### **10yrs**

Marjolin's ulcer - SCC developing in old burn site

### COMPLICATIONS OF BURNS

#### Instant complications

1. Inhalational injury
2. Dehydration

#### Immediate-hours

1. Haemorrhage
2. Airway obstruction
3. Circulatory collapse

#### Early complications-days

##### 1. Anaemia

- 1. Haemorrhage (Wound, GIT)
- 2. Thermal injury to RBCs
- 3. Bone marrow depression-by the cytokines or by the drugs given.

- 4. Malnutrition
- 5. Helminthiasis
- All burn patients put on haematinic and anti-helminth drugs

#### 2. Electrolyte imbalances

- Severe burns decrease Na in circulation but total body Na is increased.
- Hyperkalemia

#### 3. Infection;

- 0-7days - Contamination
- >7 days – Sepsis

#### 4. ARDS-inflammatory response

### Systemic Complications

#### Fluid and .Electrolyte imbalances

-Severe burns decrease Na in circulation but total body Na is increased.

-Hyperkalemia

-Shock, dehydration –increased fluid loss

#### Infection;

0-7days - Contamination

>7 days – Sepsis

#### GIT;

1. Burns secondary to swallowing corrosive substances heal by fibrosis with formation of strictures in oesophagus Contractures of the oesophagus lead to obliteration of the angle of HIS, GERD more acid irritation & burns which cause more scarring & contractures

Nissen fundoplication done to break cycle.

2. Curling's ulcers may cause GIT bleeding

3. Pseudo-intestinal obstruction (paralytic ileus) 3rd-4th day

4. Diarrhoea 2° to Ileal atrophy in the 7th-8th day; Diarrhoea may also be due to the drugs

5. Pancreatitis

6. Acalculous cholecystitis

7. Ogilvie's syndrome

#### Respiratory

- 1) Inhalation burns, edema acute airway obstruction.
- 2) ARDS
- 3) Noxious gases-CO
- 4) Inhalational burns with atelectasis
- 5) Pneumostatic pneumonia

#### Genitourinary

- 1) Renal failure -Decreased urine output to less than 400ml/day -Need dialysis if not Hepatorenal syndrome may occur.
- 2) Urethral strictures

#### Skin

- 1) Hypertrophic scars
- 2) Keloids
- 3) Squamous cell carcinoma-Marjolin's ulcer

#### Musculoskeletal

- 1) Contracture formation with limitation of movement
- 2) DVT -Anti-coagulants
- 3) Electrical burns causes myonecrosis lead to loss of group of muscles or even lead to amputation.

## Eye

- 1) Iridocyclitis
- 2) Perforation of the globe
- 3) Lid deformities -exposure keratitis in ectropions
- 4) Cataracts

## Hematological

### Anaemia

1. Haemorrhage (Wound, GIT)
  2. Thermal injury to RBCs
  3. Bone marrow depression-by the cytokines or by the drugs given.
  4. Malnutrition
  5. Helminthiasis
- All burn patients put on haematinic and anti-helminth drugs

Other haematological complications- Leucopenia and thrombocytopenia ,DIC

### Multiple organ failure

- 1) Renal failure
- 2) Bleeding from orifices
- 3) Respiratory problems
- 4) Cardiac arrest
- 5) Malnutrition

## CNS

- 1) Psychiatric disturbances
- 2) Seizure electrolyte imbalances
- 3) CVS-

CVS-Shock, Arrhythmia, tachycardia, Cardiac arrest

### Factors Affecting Burn Mortality

1. Patient's age
2. Pre-existing medical conditions e.g. Cardiac, Pulmonary, Renal dysfunction
3. Presence of Inhalational injury
3. Size & Depth of Burn
4. Concomitant Injuries
5. Etiology of burn

### Preventive measures

1. Education
2. Legislation
3. Housing - adherence to building code
4. Improved industrial safety measures

## **Question**

Discuss the emergency management of child presenting with a 40 % burns?

### Outline

Start with brief introduction about types of burns and types of thermal burns.

### **Specific MX**

- Site of injury management
- During transport-fluids intake orally and counseling
- At Casualty-Primary survey ABCDE
- Secondary surveys

- Brief history of the incident and examination from head to toe during which time estimate the actual burn surface by rule of nine examinations. Resp-system-Signs of distress etc rule out inhalational injury.

- Initial medical management-Analgesia, Tetanus toxoid , H2 blockers or PPI, Antibiotics, Tetracycline eye ointment
- Investigation-Hb, GXM, Urea electrolyte and creatinine, Arterial blood gases, carboxyhaemoglobin assay
- Initial wound management-Above
- Anesthetic review
- Admit in ICU or Burns unit and continue management



# CARE OF COLOSTOMIES

- Definition
- Indications
- Types of colostomies
- Care of colostomies
- Complications of colostomy

## Definition

-Colostomy refers to surgical bringing out, through the abdominal wall, a portion of the large intestine to carry out stool.

## Indications for colostomies

1. Decompress an obstructed colon
2. Evacuation of stool when the distal colon or rectum is removed like in colorectal cancer
3. To divert the fecal stream in preparation for resection of an inflammatory, obstructive, or perforated lesion or following traumatic injury;
4. To protect a distal anastomosis following resection.

## Types of colostomy

### Classification by function

Temporary colostomies - created to divert stool from injured or diseased portions of the large intestine, allowing rest and healing before closure of colostomy and anastomosis of the colon is done  
Permanent colostomies are performed when the distal bowel (bowel at the farthest distance) must be removed or is blocked and inoperable.

### Classification by nature of stoma

#### Loop colostomy

-This colostomy is created by bringing a loop of bowel through an incision in the abdominal wall.  
-The loop is held in place outside the abdomen by a plastic rod slipped beneath it.  
-An incision is made in the loop to allow the passage of stool through the loop colostomy.  
-The supporting rod is removed approximately 7-10 days after surgery, when healing has occurred that will prevent the loop of bowel from retracting into the abdomen.  
A loop colostomy is most often performed for creation of a temporary stoma to divert stool away from an area of intestine that has been blocked or ruptured.

#### Terminal or end colostomy (Hartman's colostomy)

-The colon is divided and the proximal end is brought out (functional part) while the distal end closed and left intra abdominal (dysfunctional part)  
-The functioning end of the intestine (the section of bowel that remains connected to the upper gastrointestinal tract) is brought out onto the surface of the abdomen, forming the stoma by cuffing the intestine back on itself and suturing the end to the skin.  
-The surface of the stoma is actually the lining of the intestine, usually appearing moist and pink.  
-An end colostomy is usually a permanent ostomy, resulting from trauma, cancer or another pathological condition

#### Double barred colostomy

(Also **Divided colostomy /Paul-Mickulicz colostomy**)

Involves the creation of two separate stomas on the abdominal wall by exteriorizing both ends of the divided colon.

The proximal stoma is the functional end that is connected to the upper gastrointestinal tract and will drain stool. The distal stoma, connected to the rectum and also called a mucous fistula, drains small amounts of mucus material. This is most often a temporary colostomy performed to rest an area of bowel, and to be later closed.

## Care of colostomies

### Immediate post operative

#### General

1. Monitor vital signs every 15 minutes until patient is awake then 30 minutes until patient gets to the ward then every 4 hours
2. IV fluids (NS and Dextrose) at least 500mls every 6 hours
3. Continue prophylactic antibiotics
4. Analgesia- 1mg/kg of pethidine then introduce IM NSAIDs as decrease pethidine dose.
5. Keep patient nil per oral
6. Keep input and output chart thus keep NG tube, and urethral catheter.

### Stoma management.

1. The patient is instructed how to support the operative site during deep breathing and coughing
2. The stoma is observed for color and amount of wound drainage. Initially, the colostomy will drain bloody mucus.
3. Fluids and electrolytes are infused intravenously until the patient's diet is can gradually be resumed, beginning with liquids with the return of bowel sounds.  
Usually within 72 hours, passage of gas and stool through the stoma begins. Initially the stool is liquid, gradually thickening as the patient begins to take solid foods.  
The patient is usually out of bed in 8–24 hours after surgery and discharged in 2–4 days.
4. Counseling  
All patients should be counseled about colostomy before surgery and counseling and education continued after the surgery both within the ward and even after discharge.  
The counseling should also include the spouse and the family members to ensure support of the patient and to continue his usual lifestyle.
5. Education  
During the hospital stay, the patient and his or her caregivers will be educated on how to care for the colostomy.
  - i) Determination of appropriate pouching supplies
  - ii) Proper application of the pouch on the stoma to avoid leakage
  - ii) Schedule of how often to change the pouch
  - iii) Regular assessment and meticulous care of the skin.
  - iv) diet changes
  - v) counseling on regular activities and work

### Continued care of colostomy after discharge

#### 1. Skin care

- Frequent Cleaning of the area around the stoma with soap and water and adequate drying.
- The skin around the stoma may be protected by application of water repellants as zinc oxide and Vaseline.
- To make sure that the colostomy bag fits snugly around the stoma to avoid leakage to the surrounding skin

#### 2. Control of odor

- Well managed colostomy should not have disturbing odor. This should be achieved by.
- Prompt changing of the colostomy bags to avoid filling with effluent and leakage.
- Avoid diet with spices causes' bad odor.
- Cleaning the skin around the stoma
- General hygiene of the body
- Use of deodorants incase all this fails.

### **3.Diet**

- Patient is encouraged to take a balanced diet and to increase his fluid intake because of loss of water through the effluents.
- Avoid spices in food which give the effluents bad smell.
- Avoid food with lots of roughage as vegetables which increases the amounts of effluent discharged.

### **4.Lifestyle**

As much as possible, Patient should continue with the normal lifestyle.

- Should continue with his work or employment as normal.
- Should continue to have normal sexual function without hindrance

However, few modifications

Bathing – You can shower or bathe with the pouch on or off.

Swimming – Use waterproof tape around the stoma

Lifting – Heavy lifting should be avoided and if previous job involved this then should change job.

### **5.Colostomy bags**

Patient should be able to get regular supply of affordable colostomy bags for continued use.

### **6.Social support**

Patient should be supported by the family thus the importance counseling spouse and family.

Should be linked to colostomy society and associations for social support and continued education

### **7.Know when to consult a doctor**

- Change in stoma color, swelling or bleeding.
- Skin irritation, redness, or rash around stoma.
- Change in color, amount or appearance of stool.
- Vomiting, abdominal swelling, or cramping with fever

## **Complications of colostomy**

### **1.Gangrene of stomal tissue**

Caused by inadequate blood supply, this complication is usually visible 12–24 hours after the operation and may require additional surgery.

### **2.Stomal Stenosis**

(Narrowing at the opening of the stoma). Often associated with infection around the stoma or scarring. Mild stenosis can be removed under local anesthesia. Severe stenosis may require surgery for reshaping the stoma.

### **3.Stomal Retraction**

-Stoma is flush with the abdomen surface or has moved below it.

Caused by insufficient stomal length, this complication may be managed by use of special pouching supplies.

-Elective revision of the stoma is also an option.

### **4.Stomal Prolapse**

-Stoma increases length above the surface of the abdomen).

-Most often results from an overly large opening in the abdominal wall or inadequate fixation of the bowel to the abdominal wall.

-Surgical correction is required when blood supply is compromised.

### **5.Parastomal hernia**

-Bowel causing bulge in the abdominal wall next to the stoma. This is due to placement of the stoma where the abdominal wall is weak or creation of an overly large opening in the abdominal wall. The use of an ostomy support belt and special pouching supplies may be adequate. If severe, the defect in the abdominal wall should be repaired and the stoma moved to another location

### **6. Parastomal abscess formation**

#### **Others**

- 7.Infection/sepsis
- 8.Skin irritation around the stoma
- 9.Feecal impaction
- 10.Diarrhea.
- 11.Psychological

NB Location of colostomy Consider:

- The contour of abdomen
- The belt line should be placed away from it.
- Away from bony prominences

-Placed in the descending colon-if possible. Semi-solid discharge reduce the water loss

# CHEST TRAUMA

Broadly chest trauma could be:

- Mechanical-high or low velocity
- Chemical
- Thermal

Mechanical trauma may be further classified as:

- Penetrating
- Non-penetrating –Blunt and Crush injuries
- Inhalational injury
- Aspiration of foreign body

2 major forces within the chest which lead to injury are the compression and distraction injuries.

Compression results in destruction of vascular structures, haemorrhage, edema and impairment of function. Distraction injuries usually result in shearing forces which destroy the integrity of intrathoracic viscera.

## Penetrating injuries

-61% of chest trauma admissions. Result in parenchymal damage related to track of missile or stabbing, implant used and velocity.

Solid structures as the heart and major great vessels suffer more injuries

-Most lethal complication is haemorrhage

-Often associated with abdominal injury

## Non-penetrating injuries

### Blunt (acceleration and deceleration injuries)

Sudden reduction in speed as in RTA. Aortic rupture as a cause of death on spot is not uncommon.

Care should be taken while dealing with the very young or the elderly.

### Crush injuries

Occurs where the elastic limit of the chest wall and its limit have been exceeded. Patients usually have AP deformity

Majority have flail chests, hemothorax or pneumothorax Most has pulmonary contusion. Injuries of the heart ,Aorta, liver ,spleen ,kidney are common

In "Traumatic asphyxia" syndrome-constrictive forces are applied in wide area for as little as 2-5 minutes

Crush injuries have high mortality.

## Clinical presentation

### History

History of chest trauma

Pain on breathing especially inspiration

Guarding of injury

Haemoptysis

### Physical exam

Cyanosis, pale, cold skin

Tachypnea and tachycardia

Chest exam-Below

## Pathophysiology in chest injury

1.Hypoxia –Reduced air exchange

2.Acidosis –Anaerobic respiration

3.Low Cardiac output-Hypovolemia and cardiogenic shock

## CASUALTY MANAGEMENT

1.PRIMARY SURVEY

2.SECONDARY SURVEY

3.INVESTIGATION

4.TRANSFER TO WARD OR THEATRE

## PRIMARY SURVEY

The majority of chest injuries are confined to the thoracic cage.

These consist of rib fractures with underlying pulmonary contusion, haemothorax, or pneumothorax.

Can be treated effectively simply by chest drain insertion and fluid restriction

Early deaths caused by in chest injuries are usually caused by:

Conditions that would impair breathing

- Airway obstruction
- Open pneumothorax
- Massive hemothorax
- Tension pneumothorax
- Flail chest
- Cardiac tamponade

Later deaths are due to

- Respiratory failure
- Sepsis
- Unrecognized injuries

The basis for successful management of thoracic trauma is effective cardio pulmonary resuscitation followed by early detection and treatment of life-threatening injuries.

## INITIAL MANAGEMENT-Primary Survey

1<sup>st</sup> is A,B,C,D of resuscitation plus vital signs

### 1. Airway and cervical spine.

Maintain cervical spine immobilization in all unconscious or symptomatic (neck pain or tenderness) patients.

i)-Inspect mouth remove debris by sweeping through

ii)Chin lift/jaw thrust (tongue is attached to the jaw) and always airway in tongue falling back

To perform a *chin lift*, place two fingers under the mandible and gently lift upward to bring the chin anterior. During this manoeuvre, be careful not to hyperextend the neck. Care should be given to neck stabilization, if appropriate.

The *jaw thrust* is performed by manually elevating the angles of the mandible to obtain the same effect.

iii) Secure airway by Guedel airway/oropharyngeal airway.

Insert the oral airway into the mouth behind the tongue; it is usually inserted upside down until the palate is encountered and is then rotated 180 degrees.

iv) Intubations; keep the neck immobilized in neutral position.

Use sedation and short acting neuromuscular blockade if necessary. If not possible to intubate:

- Tracheostomy
- Cricothyrotomy

### 2. Breathing: Oxygenation and ventilation.

Check for the six conditions that would impair breathing.

#### 1 Inspect (LOOK)

Inspection of respiratory rate and evidence of respiratory distress is essential. Are any of the following present?

- Use of accessory muscles,flaring of alae nasae
- Cyanosis-lips
- Chest movements(chest excursions)

-Penetrating injury in the chest or sucking chest wounds  
-Presence of flail chest

#### 2. Palpate (FEEL)

-Tracheal shift  
-Broken ribs  
-Subcutaneous emphysema.  
-Chest expansion

#### 3. Percussion

Percussion is useful for diagnosis of haemothorax (dull) and pneumothorax (hyperresonant)

#### 4. Auscultate (LISTEN)

-Pneumothorax/hemothorax (decreased breath sounds on site of injury)

-Detection of abnormal sounds in the chest.

Immediate intervention

1. Tension pneumothorax-put through a needle then chest tube insertion
2. Massive pneumothorax-chest tubes insertion
3. Sucking wounds-strap the open wound then chest tube insertion.
4. Flail chest-positive pressure ventilation
5. Cardiac tamponade

#### Resuscitation action

-Insert an intercostal drainage tube as a matter of priority, and before chest X-ray if respiratory distress exists, to drain the chest pleura of air and blood

-When indications for intubation exist but the trachea cannot be intubated, consider using a laryngeal mask airway or direct access via a cricothyroidotomy.

If available, maintain the patient on oxygen until complete stabilization is achieved

-If you suspect a tension pneumothorax, introduce a large-bore needle into the pleural cavity through the second intercostal space, mid clavicular line, to decompress the tension and allow time for the placement of an intercostal tube

- If intubation in one or two attempts is not possible, a cricothyroidotomy should be considered a priority

#### **3. Circulation and arrest of bleeding**

“Shock” is defined as inadequate organ perfusion and tissue oxygenation. In the trauma patient, it is most often due to haemorrhage and hypovolaemia.

The diagnosis of shock is based on clinical findings:

- Hypotension
- Hypothermia
- Tachycardia
- Tachypnoea
- Pallor
- Cold extremities
- Decreased capillary refill
- Decreased urine production

#### Haemorrhagic (hypovolaemic)

-Shock is due to acute loss of blood or fluids. The amount of blood loss after trauma is often poorly assessed and in blunt trauma is usually underestimated. Remember:

-Large volumes of blood may be hidden in the abdominal and pleural cavity.

-Femoral shaft fracture may lose up to 1.0-1.5 litres of blood

-Pelvic fracture often loses in excess of 2 litres of blood.

#### Cardiogenic shock

Cardiogenic shock is due to inadequate heart function. This may result from

-Myocardial contusion (bruising)  
-Cardiac tamponade  
-Tension pneumothorax (preventing blood returning to heart)  
- Penetrating wound of the heart  
-Myocardial infarction.

Assessment of the jugular venous pressure is essential in these circumstances and an ECG should be recorded, if available.

#### Neurogenic shock

Is due to the loss of sympathetic tone, usually resulting from spinal cord injury. The classical presentation is hypotension without reflex tachycardia or skin vasoconstriction.

#### Septic shock

Is rare in the early phase of trauma, but is a common cause of late death (via multi-organ failure) in the weeks following injury. It is most commonly seen in penetrating abdominal injury and burns patients.

#### **Resuscitation**

-First priority is to stop any obvious bleeding by sub fascial gauze pack placement and manual compression on the proximal artery. Carefully applied compressive dressing of the entire injured limb can be done. Then

-Vascular access 2 large bore size 16 on the 2-basilic veins

-Fluids: infuse 0.9% NaCl initially 2L to run as fast as possible through 2 large bore IV lines in the antecubital fossa then re-assess

-Resuscitate to goal of mean arterial pressure (MAP)>90 mmHg to maintain a presumptive cerebral perfusion pressure (CPP)>60 mmHg

-Urinary catheter insertion and monitor the input and output chart at least 30-50 ml/hour or 0.5/kg/hour of urine flow

-Monitor by vital signs, pallor, sweating, anxiety, skin warmth clammy, input and output

-Blood transfusion must be considered when the patient has persistent haemodynamic instability despite fluid (colloid/crystalloid) infusion.

If type specific or cross matched blood is not available, use group O negative packed red blood cells. Transfusion should, however, be seriously considered if the haemoglobin level is less than 7 g/dl and the patient is still bleeding.

#### **4. Neurological dysfunction**

Establish preliminary level of consciousness by AVPU

**A** –Awake, **V** -Verbal response, **P**- Painful response

**U** -Unresponsive

and any focal neurologic deficits.

#### **5. Exposure and environmental modification**

Cover patient in case of shock and shivering

#### **ANATOMICAL CLASSIFICATION OF CHEST INJURIES**

##### A. Skin and Subcutaneous tissue

Cuts and bruises

Superficial cuts-surgical toilet and suturing, analgesia and tetanus toxoid

##### **B. RIBS**

Usually fracture. Types of rib fracture include:

- 1) Simple fracture
- 2) Compound fracture
- 3) Multiple fractures-many ribs or rib plus sternal fracture.  
May or may not cause Flail chest
- 4) Flail chest

### 1.Simple fractures

Main management is to provide analgesia, reduce pain and allow ventilatory movements.

Analgesia may be systemic or local

#### Systemic analgesia

- i. Paracetamol
- ii. NSAIDS
- iii. Opioids
- iv. Combination

#### Local analgesia

-Intercostal block usually administered as a mixture of short acting (cylocaine or Procaine) and long acting(Bupivacine) local anaesthetic plus a steroid

-Inject the intercostals space involved plus two above and two below because of the overlap of the sensory innervation

-Usually is cumbersome to do this for a single fracture, more reasonable for multiple rib fractures.

-Injection is done below the rib and along the medial border of the scapula.

#### Risks

-Bleeding

-Penetration of pleura-pneumothorax and hemothorax

### 2.Multiple fractures

-Firm strapping of the thorax in a hemi-thorax fashion.

-May give systemic analgesia or local analgesia as above.

Firm strapping not done in older patients because may interfere with respiration.

### 3.Flail chest/segment

A portion of the chest wall becomes isolated by multiple fractures moves in and out with inspiration and expiration with severe reduction in ventilatory efficiency.

Is dangerous because of the paradoxical movement of the flail segment to the rest of the ribs cage and thus the area of the lung under it is not ventilated and may collapse.

Atelectasis, hypercapnia, hypoxia, accumulation of secretions, and ineffective cough occur.

#### **Management options**

Less severe cases, intercostal nerve block or continuous epidural analgesia may be adequate treatment otherwise

##### i)Hemi-thorax strapping

Pack with gauze and Strap 3-4 ribs in hemi thorax fashion

##### ii)Positive pressure ventilation

Sedate patient and do the positive pressure ventilation

##### iii) Tracheostomy

This reduces the work of breathing by reduction of dead space and thus reduces the paradoxical movement of the flail segment.

Give humidified oxygen.

##### iv) Thoracotomy and ORIF

Drill two holes in each rib and hold using wire.

### C.PLEURA

Pleural injuries also involves lung parenchyma

#### Hemothorax

Classified according to the amount of blood:

1.Minimal, 350 mL

2.Moderate, 350-1500 mL;

3. Massive, >1500 mL

-Rate of bleeding after evacuation of the hemothorax even more important. If air is also present, the condition is called hemopneumothorax

-Hemothorax should be suspected with penetrating or severe blunt thoracic injury.

-Clinically-Reduced chest movements, dullness to percussion and decreased breath sounds

-CXR (upright or semiupright,) should be promptly obtained.

-Tube thoracostomy using one or two large-bore pleural catheters should be performed promptly

In 85% of cases, tube thoracostomy and circulatory support are the only treatment required.

-If bleeding is persistent, as noted by continued output from the chest tubes, it is more likely to be from a systemic (eg, intercostal) rather than a pulmonary artery.

In most cases, the chest wall is the source of hemorrhage, but the lung, heart, pericardium, and great vessels account for 15-25%.

#### Indication for thoracotomy

1.Initial drainage of fluid >1500L and still draining

2.Drainage rate >200ml /hr for 3 or more hours

#### **Pneumothorax**

##### Types

1.*Open pneumothorax*

2.*Closed*

3.*Tension*

-Lacerations of the lung or chest wall following penetrating or blunt chest trauma. Prompt occlusive dressing should be done for open pneumothorax before tube insertion.

-Hyperinflation (eg, blast injuries, diving accidents) can also rupture the lungs. After penetrating injury, 80% of patients with pneumothorax also have blood in the pleural cavity.

-Tension pneumothorax develops when a flap-valve leak allows air to enter the pleural space but prevents its escape; intrapleural pressure rises causing total collapse of the lung and a shift of the mediastinal viscera to the opposite side.

-It must be relieved immediately to avoid interference with ventilation in the opposite lung and impairment of cardiac function.

NB For any impaled or penetrating objects still on the chest should left in situ until the patient is in theatre.

Bandage and stabilize the object to avoid further injury.

#### **Indications for thoracotomy**

1.Cardiac tamponade

2.Initial drain through the chest tube>1.5 L and continuing

3.Hourly drain >200ml/hr for more than 3 hours

2.Electro cardiac dissociation

3.Intraabdominal bleeding in excess indicating a thoraco-abdominal injury

4. Persistent pneumothorax even with adequate drainage suggesting injury to trachea or bronchi. Confirmed by bronchoscopy

- 5 Diaphragmatic injury
6. Large Chest wall defects
7. High velocity injuries
8. Impaled objects on the chest in situ
9. Trans mediastinal injury
9. Delayed indications Clotted hemothorax, Lung abscess or fistula formation.
10. Failure of resuscitation measures

#### **Trachea and Bronchus:**

- Blunt tracheobronchial injuries are often due to compression of the airway between the sternum and the vertebral column in decelerating injury
- Patients present with
  - Pneumothorax or hemopneumothorax
  - Subcutaneous emphysema
  - Cervicofacial emphysema
  - Pneumo mediastinum
  - Hemoptysis.
- Suspected with massive air leak or when the lung does not readily re-expand after chest tube placement
- In penetrating injuries of the trachea or main bronchi, there is usually massive hemorrhage and hemoptysis.
- Systemic air embolism resulting in cardiopulmonary arrest may occur if a bronchovenous fistula is present.
- Diagnosis may require tracheobronchoscopy. Primary repair is indicated for tracheobronchial lacerations.

#### **Lung Injury**

- Pulmonary contusion due to blunt or penetrating injuries.
- Alveolar rupture with fluid transudation and extravasation of blood are early findings. These enter alveolar spaces and bronchi and produce localized airway obstruction and atelectasis.
- Increased mucous secretions and overzealous intravenous fluid therapy may combine to produce copious secretions (wet lung) and further atelectasis.
- Blood oxygenation and pH drop and PCO<sub>2</sub> rises.
- Treatment is often delayed because clinical and x-ray findings may not appear until 12-24 hours after injury.
- The clinical findings are loose, copious, blood-tinged secretions, chest pain, restlessness, apprehensiveness, and labored respirations. Eventually, dyspnea, cyanosis, tachypnea, and tachycardia develop.
- X-ray changes consist of patchy parenchymal opacification or diffuse linear peribronchial densities that may progress to diffuse opacification ("white-out").
- Mechanical ventilatory support permits adequate alveolar ventilation with oxygen.
- Most lung lacerations are caused by penetrating injuries, and hemopneumothorax is usually present. Tube thoracostomy is indicated to evacuate pleural air or blood and to monitor continuing leak

#### **Heart and Pericardium:**

- The injury varies from localized contusion to cardiac rupture.
- Early clinical findings include friction rubs, chest pain, tachycardia, murmurs, dysrhythmias, or signs of low cardiac output.
- ECGs show nonspecific ST and T wave changes. Serial tracings should be obtained, since abnormalities may not appear for 24 hours.

-Hemopericardium may occur without tamponade and can be treated by pericardiocentesis. Tamponade in blunt cardiac trauma is often due to myocardial rupture or coronary artery laceration.

-Cardiac Tamponade produces

- Distended neck veins
- Muffled heart sounds
- Shock
- Cyanosis.

-Immediate thoracotomy and control of the injury are indicated.

-Treatment of injuries to the valves, papillary muscles, and septum must be individualized; when tolerated, delayed repair is usually recommended.

-Pericardial lacerations from stab wounds tend to seal and cause tamponade, whereas gunshot wounds leave a sufficient pericardial opening for drainage.

-Gunshot wounds produce more extensive myocardial damage multiple perforations, and massive bleeding into the pleural space.

Hemothorax, shock, and exsanguination occur in nearly all cases of cardiac gunshot wounds.

-Treatment of penetrating cardiac injuries has gradually changed from initial management by pericardiocentesis to prompt thoracotomy and pericardial decompression.

-Pericardiocentesis is reserved for selected cases when the diagnosis is uncertain or in preparation for thoracotomy. The myocardial laceration is closed with sutures

#### **Diaphragm**

-Penetrating injuries of the diaphragm outnumber blunt diaphragmatic injuries by at least 4:1.

-Wounds of the diaphragm must not be overlooked, because they rarely heal spontaneously and because herniation of abdominal viscera into the chest can occur either immediately or years after the injuries.

-More common on the left hemi diaphragm as the right is protected by the liver.

#### Presentation

- Abdominal tenderness
- Dyspnea
- shoulder pain
- unilateral breath sounds

-CXR it is entirely normal in about 20% of cases. The most common finding is ipsilateral hemothorax.

-Once the diagnosis is made, immediate thoracotomy and the diaphragm sutured with heavy nonabsorbable sutures. -In delayed diagnosis, when repair can not be done without tension Marlex mesh or a pericardial flap are employed.

-Because pulmonary complications are frequent; diaphragmatic injury should be approached through the abdomen when there is no other injury requiring thoracotomy.

If any aspects of the A,B,C,D,E deteriorates re-evaluate the patient for stabilization

#### Esophagus:

-Esophagus is well protected, and perforation from external penetrating trauma is relatively infrequent. Blunt injuries are very rare.

-Symptom of esophageal perforation is chest pain; fever develops within hours in most patients.

- Regurgitation of blood
- Hoarseness

- Dysphagia
  - Respiratory distress may also be present.
- Physical findings include
- Shock
  - Pneumothorax and pneumomediastinum
  - Local tenderness
  - Subcutaneous emphysema,
  - Hamman's sign (ie, pericardial or mediastinal "crunch" synchronous with cardiac sounds)
  - Leukocytosis occurs soon after injury.
- A nasogastric tube should be passed to evacuate gastric contents. If recognized within 24-48 hours of injury, the esophageal perforation should be closed and pleural drainage instituted with large-bore catheters.
- Illness and death are due to pneumothorax or mediastinum, mediastinal and pleural infection.

#### **Thoracic Duct:**

- Chylothorax and chylopericardium are rare complications of trauma but, when they occur, are difficult to manage.
- Penetrating injuries of the neck, thorax, or upper abdomen can injure the thoracic duct or its major tributaries. The occurrence of chylothorax after a trivial injury should lead one to suspect underlying cancer.
- Chest tube drainage should be instituted if the effusion recurs. Intravenous hyperalimentation with no oral intake may be effective in persistent leaks.
- Three or 4 weeks of conservative treatment usually are curative.
- If daily chyle loss exceeds 1500 mL for 5 successive days or persists after 2-3 weeks of conservative treatment, the thoracic duct should be ligated via a right thoracotomy.

#### **The sternum**

- These fractures are usually transverse and may overlap, causing agonizing pain.
- Internal fixation is required to correct deformity and relieve the discomfort of instability.
- This is performed by making an incision in the xiphisternum and passing a Steinmann pin up through the medulla of both sternum fragments from underneath.

#### **B.SECONDARY SURVEY**

This is a second examination from the head to the toe while still monitoring the vital signs.

#### **C.INVESTIGATIONS**

##### **Basic Trauma investigation**

- 1.CXR
- 2.Pelvic X-ray
- 3.C-spine x-ray
- 4.Skull x-ray

##### **Other investigations as required for chest injury**

- 1.Arterial blood gases
- 2.ECG
- 3.Tracheobronchoscopy for tracheobronchial injuries
4. Aortography
- 5.Trans esophageal ECHO
- 6.MRI and CT-scan

##### **What to check for in CXR**

- 1.Pneumothorax

- 2.Hemothorax
- 3.Subcutaneous emphysema
- 4.Pneumo-mediastinum
- 5.widening of mediastinum
- 5.Fractures-ribs,clavicle.sternum
- 6.Pneumo or hemopericardium
- 7.Lung contusions
- 8.Aspiration

#### **UNDERWATER SEAL DRAINAGE (U.W.S.D)**

##### **Indications**

- 1) Fluid in the pleural space
- 2) Greater than 20 % pneumothorax
- 3) Tension pneumothorax

##### **Components of UWSD system**

- 1.Chest tube
- 2.Bottle for fluid collection
- 3.Connecting tubes
- 4.Sealing fluid
- 5.-/+Suction mechanism

##### **Types of collecting Bottles**

- 1.Single Tube Edwards Bottle system
- 2.Separate Reservoir and Seal
- 3.Three bottle system with controlled suction
- 4.Commercial system

##### **Characteristics of good chest tube**

- 1.Be transparent
- 2.Be flexible
- 3.Radio-opaque line in tube
4. Last tube hole goes through the radio-opaque line.
- 5.Must be graduated

##### **Principles of under water seal drainage**

1. Drainage of fluid influenced by gravity.
2. Drainage of air influenced by the pressure difference of the chest cavity and the UWSD system.
3. The return of air/fluid is prevented by the under water seal
3. The rate of fluid drainage is influenced level of seal under water

##### **Insertion of a chest tube**

-Explain to the patient his condition and the need to have a chest tube inserted

-Collect materials needed

UWSD system, sterilized drapes., Scalpel, Local anaesthetic, antiseptics, curved artery forceps, surgical gloves

##### **Procedure**

1. Have patient lie lateral position with the side with pathology facing upwards.
2. Expose the whole chest wall and identify the intercostal space of insertion.  
Usually in the 4<sup>th</sup> intercostal space just above the 5<sup>th</sup> rib in triangle of safety (bordered anteriorly by anterior axillary line, posteriorly by mid axillary line and inferiorly by the upper border of fifth rib.
3. Clean the area with antiseptic and drape the patient leaving the identified intercostals space.

4. Infiltrate the skin, muscle and pleura with 1% lidocaine at the appropriate intercostal space.
- Aspirate fluid from the chest cavity to confirm your diagnosis
5. Using a sterile scalpel a small transverse incision just above the rib to avoid damaging the vessels under the lower part of the rib
6. Using a pair of large, curved artery forceps, do blunt dissection penetrating the pleura and enlarging the opening.
7. Using the same forceps to grasp the chest tube at its tip (clamped distally) and introduce it into the chest.
8. Advance the chest tube Posteriorly into the costovertebral angle (hemothorax) or towards the apex for pneumothorax.
9. Close the incision with interrupted skin sutures, using one stitch to anchor the tube.
- Leave an additional suture untied adjacent to the tube for closing the wound after the tube is removed.
10. Apply dressing around the chest tube.
11. Remove the clamp and Connect the tube to the underwater-seal drainage system and mark the initial level of fluid in the drainage bottle.
12. Do a check x-ray to know the position of the chest tube

#### **Management of chest tube in situ.**

1. Monitor the vital signs of the patient with his respiratory pattern.
2. Observe the UWSD system for the initial level, the nature of the drainage, the movement of the water seal up and down with respiration, the volume of initial drainage.
3. Observe for bubbling of air-continuous air bubbles in both expiration and inspiration may be sign of deep chest tube into the airway or the presence of brochopleural fistula
4. Secure the UWSD system in clearly lit area and protect it –in ward using a stool to avoid accidents.
5. Always keep the UWSD system at a level below the patient to facilitate drainage of fluid by gravity.
6. Chest drains should never be clamped except when changing drain bottles, whenever the chest drain bottle has to be lifted above the level of the patient's chest
7. Educate patient on the need to keep the chest tube secure and avoid turning or movements that would kink or dislodge the chest tube. Encourage the patient to sit upright, take deep breaths and slight coughs to encourage drainage of fluid or gases from the pleural space
- Chest physiotherapy is equally important
- Establish original level of fluid in drainage bottle before reconnecting as this provides a baseline for future measurements. The fluid level should be clearly marked on the bottle either in the area provided or using a strip of tape
8. Continuously monitor the amount and nature of drainage- >1.5L of hemothorax and continuing or >200ml/hr for more than 3hrs are indications for thoracotomy.
9. Change the bottle every 24 hours noting the nature and volume of drainage which is noted as part of the output in the 24hr input/output chart.
10. Use of prophylactic antibiotics especially in penetrating chest injuries-contaminated wounds.
- Also give analgesics appropriate.
11. Inspect the wound at point of chest tube insertion for exudates, discharges or signs of infection and change dressing every 3 days.
12. Palpate area of chest wall around the chest tube for any crepitation-subcutaneous emphysema.

13. Do regular respiratory examination for any features of distress, chest expansion, air entry bilaterally.
14. Do regular CXR to monitor the drainage of the hemothorax or pneumothorax and thus chest expansion

#### **When to remove the chest tube**

When it has done its work of draining the hemothorax or pneumothorax.

This is assessed both

- A) Clinically by respiratory examination
- B) Radiologically by taking CXR
- C) Drainage from the chest tube 50-100ml/24 hrs

#### **Removal of chest tube.**

1. Remove the dressing and clean the area with antiseptic.
2. Remove the suture securing the chest tube and ask the patient to deeply breathe in and do Valsalva manoeuvre.
3. Remove the chest tube while the assistant ties the purse string stitch around the chest opening.

#### **Complications of chest tubes.**

There is no organ in the thoracic or abdominal cavity that has not been pierced by a chest drain."

#### **Acute complications (Poor technique)**

1. Haemothorax, usually from laceration of intercostal vessel (may require thoracotomy)
2. Lung laceration (pleural adhesions not broken down)
3. Diaphragm / Abdominal cavity penetration (placed too low)
4. Stomach / colon injury (diaphragmatic hernia not recognised)
5. Tube placed subcutaneously (not in thoracic cavity)
5. Tube placed too far (pain)
6. Tube falls out (not secured)

#### **Late complications**

1. Blocked tube (clot, lung)
2. Retained haemothorax
3. Empyema or sepsis
5. Pneumothorax after removal (poor technique)



# CLEFT LIP AND PALATE

Are part of Orofacial clefts /defect anomalies

- cleft lip [CL]
- cleft lip and palate [CLP]
- cleft palate [CP] alone
- median, lateral [transversal], oblique facial clefts

## Prevalence

are among the most common congenital anomalies.

Approximately 1 case of orofacial cleft occurs in every 500-550 births.

From a genetic standpoint, **cleft lip** with or without **cleft palate** is distinct from isolated **cleft palate**.

-Cleft lip more common in males, the cleft palate in females.

-Although both can occur in a single family, particularly in association with certain syndromes, this pattern is unusual.

Race

There is racial variation in the incidence of facial clefting.

Among Asians, whites, and blacks, the incidence is 1.61, 0.9, and 0.31, respectively, per 1000 live births.

## Clinical Findings

-A **cleft lip** may be unilateral or bilateral and complete or incomplete.

- It may occur with a **cleft** of the entire palate or just the primary (anterior and gingival ridge) or secondary (posterior) palate.

- An isolated **cleft palate** can involve only the soft palate or both the soft and hard palates.

-It can be a V-shaped or wide horseshoe **cleft**.

-A **cleft** associated with **micrognathia** and **glossoptosis** (a tongue that falls back and causes respiratory or feeding problems) is called **Pierre Robin syndrome**.

-Among individuals with facial clefts-more commonly those with isolated **cleft palate**-there is an increased incidence of other congenital abnormalities.

- The incidence of congenital heart disease, for example, is between 1% and 2% in liveborn infants, but among those with Pierre Robin syndrome it can be as high as 15%.

-Associated abnormalities should be identified in the period immediately after birth and before surgery

## Problems

Problems associated with facial clefts include

- 1.early feeding difficulties, which may be severe;
- 2.recurrent serous otitis media associated with fluctuating hearing and language delays
3. speech problems, including hypernasality and articulation errors
- 4.dental and orthodontic complications.

Long-term management should ideally be through a multidisciplinary **cleft palate** clinic.

Gaining weight and preventing aspiration and ear infections are the most important parts of caring for neonates with a cleft during their first days and weeks of life.

## Management

Below is the most common treatment protocol presently used in most cleft treatment centers:

### **Newborn –**

Diagnostic examination

general counseling of parents

feeding instructions

palatal obturator (if necessary)

genetic evaluation and specification of diagnosis

empiric risk of recurrence of cleft calculated;

### **Age 3 months**

-Repair of CL (and placement of ventilation tubes)

### **Age 6 months**

- Presurgical orthodontics, if necessary; first speech evaluation

### **Age 9 months**

-Speech therapy begins

### **Age 9-12 months**

-Repair of CP (placement of ventilation tubes if not done at the time of CL repair)

### **Age 1-7 years**

-Orthodontic treatment

### **Age 7-8 years**

-Alveolar bone graft

-Older than 8 years - Orthodontic treatment continues Other surgical procedures can be performed in patients with severe clefts as necessary

## **Surgical therapy:**

-Undoubtedly, closure of the CL is the first major procedure that tremendously changes children's future development and ability to thrive.

-Variations occur in timing of the first lip surgery; however, the most usual time occurs at approximately age 3 months.

-Pediatricians used to strictly follow a rule of "three 10s" as a necessary requirement for identifying the child's status as suitable for surgery (ie, 10 lb, 10 mg/L of hemoglobin, and age 10 wk).

-Although pediatricians are presently much more flexible, and some surgeons may well justify a neonatal lip closure, considering the rule of three 10s is still very useful.

Team for the multidisciplinary treatment of a child with an orofacial cleft includes the following specialists:

- Pediatrician
- Nurse practitioner
- Plastic surgeon
- Pediatric dentist
- Otolaryngologist

## Breastfeeding an infant with a cleft

- In a case of an isolated CL, the infant typically does not experience feeding problems beyond learning how to "latch on" to the nipple at the beginning of the feeding. Infants with CP must squeeze the milk out of the nipple by compressing the nipple between the tongue and whatever portion of the palate that remains.

- Massaging the breast and applying hot packs on the breast 20 minutes before nursing usually helps.
- The mother should apply pressure to the areola with her fingers to help the engorged nipple protrude. She should hold the infant in a semi-upright, straddle, or football position. She should support the breast by holding it between her thumb and middle finger, making sure that the infant's lower lip is turned out and the tongue is under the nipple.
- If the infant cannot hold onto the nipple any more, the mother can collect the remaining milk using an electrical or manual breast pump or by squeezing the breast with both hands and can finish the feeding with collected milk in a bottle.
- The mother should increase her fluid intake (drink lots of water).

#### Feeding breast milk with a bottle

- Particularly for infants with bilateral CLP, breastfeeding is not possible.
- The mother can use a breast pump (an electric pump ensures the highest level of success). Then, she can feed the baby with a bottle (see below).

#### Other recommendations

- More upright or seated positions prevent the milk from leaking to the nose and causing the infant to choke.
- Advise the mother to stop feeding and allow the infant to cough or sneeze for a few seconds when nasal regurgitation occurs. A palatal obturator may be used.

# COLORECTAL CANCER

## Introduction

-Ninety percent of colorectal cancers occur in patients over 50 years of age.

-Adenomas precede carcinomas. -Early cancers are asymptomatic. -Fecal occult blood testing can detect preneoplastic lesions and early cancers.

-Microcytic anemia in the elderly suggests the presence of colorectal cancer. - Hematochezia may be a sign of colorectal cancer (especially of the distal colon and rectum).

Weight loss and obstructive symptoms are late findings.

## **Diagnosis**

### **History-symptoms**

#### 1. Per rectal Bleeding

This is the most common symptom of rectal cancer and occurs in 60% of patients.

Higher tumors may present with occult bleeding. The bleeding mixed with stool usually no heavy bleeding. May be mucoid.

Occult bleeding: This is detected on screening fecal occult blood test (FOBT)

#### 2. Change in bowel habit

Often, it occurs in the form of diarrhea, particularly if the tumor has a large villous component.

But may also present with alternating constipation and diarrhea.

#### 3. Incomplete evacuation

Tumors located low in the rectum can cause a feeling of incomplete evacuation and tenesmus.

#### 4. Abdominal pain

Partial large-bowel obstruction may cause colicky abdominal pain and bloating

#### 5. Back pain

Usually is a late sign caused by a tumor invading or compressing nerve trunks.

#### 6. Urinary symptoms

May occur if the tumor is invading or compressing the bladder or prostate.

#### 7. Malaise, weight loss, night sweat, anorexia

Non specific constitutional signs of malignancy.

#### 8. Bowel obstruction features

Complete obstruction of the large bowel is rare.

9. Other presentations include emergencies such as peritonitis from perforation (3%) or jaundice, which may occur with liver metastases (<1%).

## **Predisposing factors**

1. **Diet-fatty diet** Omega-3 monounsaturated fatty acids and omega-6 monounsaturated fatty acids also appeared to be less carcinogenic than saturated or polyunsaturated fats

-The ingestion of a high-fiber diet appears to be protective against colorectal cancer. Fiber causes the formation of a soft, bulky stool that dilutes out carcinogens; it also decreases colonic transit time, allowing less time for harmful substances to contact the mucosa.

-Increased dietary intake of calcium appears to have a protective effect on colorectal mucosa by binding with bile acids and fatty acids.

-Other dietary components, such as selenium, carotenoids, and vitamins A, C, and E, may have protective effects by scavenging free-oxygen radicals in the colon

2. **Alcohol:** Daily alcohol drinkers experience a 2-fold increased risk of developing colorectal carcinoma.

3. **Cigarette smoking**

4. **Pelvic radiation**

## 5. Inflammatory bowel disease (IBD)

a) Ulcerative colitis The incidence of malignancy increases with duration.

Evaluate patients for dysplastic changes with annual colonoscopy. Dysplasia is a precursor of cancer and, when present, the risk of cancer is 30%.

b) Crohn disease The incidence of colorectal cancer in patients with Crohn disease is 4-20 times greater than that of the general population.

Cancers often develop in areas of strictures and in defunctionalized segments of intestine. In patients with perianal Crohn disease, malignancy often presents in fistulous tracts.

## 6. Genetic predispositions.

a) Hereditary nonpolyposis colorectal cancer (HNPCC)

HNPCC is an autosomal dominant inherited syndrome that occurs because of defective mismatch repair genes located on chromosomes 2, 3, and 7.

b) Familial adenomatous polyposis coli (FAP)

The defect is in the *APC* gene, which is located on chromosome 5 at locus q21. FAP is an autosomal dominant inherited syndrome that results in the development of more than 100 adenomatous polyps

The disease process causes the formation of hundreds of intestinal polyps, osteomas of the bone, desmoid tumors, and, occasionally, brain tumors.

If left untreated, colorectal cancer develops in nearly 100% of these patients by age 40 years.

## Gross morphology

1. Cauliflower is the least malignant form

2. The Annular type tends to give rise to obstructive symptoms, whereas the others more commonly will present with bleeding.

3. Ulcerative type.

4. Tubular type

## Histology:

The microscopic appearance of colonic adenocarcinomas may be that of well-differentiated or poorly differentiated glandular structures.

-Normal topological architecture of colonic epithelium in terms of a crypt-villous axis is lost.

- Anorectal lesions have a squamous morphology

## Spread:

a) Local spread

b) Lymphatic spread - 90%;

N1 - Nodes in the immediate vicinity of the bowel wall (Epicolic)

N2 - Nodes arranged along the; (Paracolic)

Ileocolic, Right colic, Midcolic, Left colic, Sigmoid arteries

N3 - Apical nodes around the superior & inferior mesenteric vessels where they arise from the abdominal aorta → Left supraclavicular nodes (Virchow's node)

c) Haematogenous - 10% - Metastases first to the Liver via portal system, Lung, Bone

d) Transcoelomic

e) Iatrogenic

## INVESTIGATIONS

### **Lab Studies:**

- 1.CBC-Anaemia (microcytic)
2. LFT and U/E/C
3. (CEA Screen

Liver function tests usually are part of the preoperative workup; these test results often are normal even with metastases to the liver.

Carcinoembryonic antigen test: Perform a CEA test in all patients with rectal cancer. A baseline level is obtained before surgery and a follow-up level is obtained after surgery. This may alert to a possible recurrence if a previously normalized CEA begins to rise in the postoperative period. A CEA higher than 100 ng/mL usually indicates metastatic disease and warrants a thorough investigation

### **Imaging**

#### **1.Proctoscopy**

##### **1.Proctosigmoidoscopy/Colonoscopy AND Biopsy**

Allows direct visualization of the lesion, and provides an estimation of the size of the lesion and degree of obstruction. Colonoscopy is better for higher lesions

-This procedure is used to obtain biopsies of the lesion, assess ulceration, and determine the degree of fixation.

- In addition, it gives an accurate measurement of the distance of the lesion from the dentate line; critical in deciding which operation is appropriate

#### **2.Double contrast barium enema**

For location, size & relations- Blow in air to stretch out the rugae in the colon in addition to the barium enema

-Constant irregular filling defect

-'Apple core' Appearance i.e. A short, irregular stenosis with sharp shoulders at each end

#### **3.Endorectal ultrasound**

-Invaluable in assessing depth of invasion of rectal by visualization of the layers of the wall

-cancers detection of lymph node involvement

-Also used in determination of local recurrence when used after surgery.

-Endorectal surface-coil MRI: An alternative to ERUS, this technique is touted as equally or more accurate than ERUS in lymph node staging.

#### **4.Metastatic workup**

a)Abdominal pelvic ultrasound-metastasis to the bladder cervix or other abdominal organs

b)Chest radiograph: rule out pulmonary metastases

c)CT scan: This study generally is used to determine the presence or absence of metastases lesions in the liver, adrenals, ovaries, lymph nodes, and other organs

-Depth of penetration of the primary rectal tumor and nodal involvement.

d)MRI actually is the most sensitive test for determining the presence of liver metastases and often is used if liver resection is considered

#### **Low anterior resection**

Generally is performed for lesions in the middle and upper third of the rectum and, occasionally, for lesions in the lower third. Tumor lesion should be more than 8cm from the dentate line.

Operation entails full mobilization of the rectum, sigmoid colon, and, usually, the splenic flexure. Mobilization of the rectum requires a technique called total mesorectal excision (TME) A circular stapling device is used to create the anastomosis. A double-stapled technique is performed.

Coloanal anastomosis Very distal rectal cancers that are located just above the sphincters occasionally can be resected without the need for a permanent colostomy.

Closure of the temporary colostomy done 6-8 weeks.

### **5).Abdominal perineal resection**

#### **Surgery**

Abdominal perineal resection (APR) is performed in patients with lower-third rectal cancers who cannot undergo a sphincter-sparing procedure.

This includes patients with complex involvement of the sphincters, preexisting significant sphincter dysfunction, or pelvic fixation, and sometimes is a matter of patient preference

A 2-team approach often is used, with the patient in modified lithotomy position. One team mobilizes the colon and rectum, transects the colon proximally, and creates an end-sigmoid colostomy.

The perineal team begins by closing the anus with a purse-string suture and making a generous elliptical incision.

The dissection plane continues posteriorly, anterior to the coccyx to the level of the levator ani muscles.

Care must be taken to avoid the prostatic capsule in the male and the vagina in the female (unless posterior vaginectomy was planned).

A closed-suction drain is left in place, and the perineal wound is closed in layers by using absorbable sutures.

#### **1)Hemicolectomies:**

i)Right - Caecal tumours, ascending or proximal transverse colon (Right extended Hemicolectomy)

ii)Left - Distal transverse colon or descending colon (Left extended Hemicolectomy)

#### **2)Transverse colon**

When there is no obstruction, excision of the transverse colon & the 2 flexures together with the transverse mesocolon & the greater omentum, followed by end-end anastomosis

#### **3) Sigmoid colectomy**

Tumours of the sigmoid colon - Done at the pelvic brim with a 5cm clean margin above pelvic diaphragm for anastomosis.

Modes of surgery

#### **Anorectal cancers**

**6) Posterior sagittal anorectoplasty (PSAR) - Small tumour in rectum**

#### **Staging**

##### **Dukes staging**

Originally, system divided tumor classification into 3 stages, as follows:

-Those limited to the rectal wall (Dukes A)

-Those that extended through the rectal wall into extrarectal tissue (Dukes B)

-Those with metastases to regional lymph nodes (Dukes C)

##### **Modification by Astler -Coller into the following.**

Stage A- limited to rectal mucosa

Stage B1- Extend into muscularis propria

B2- Extend through muscularis propria  
Stage C1- B1 plus nodal involvement  
C2- B2 plus nodal involvement  
Stage D Was added to indicate distant metastasis

### **TNM classification for cancer of the colon and rectum (AJCC)**

#### Primary tumor (T)

TX - Primary tumor cannot be assessed or depth of penetration not specified  
T0 - No evidence of primary tumor  
Tis - Carcinoma in situ (mucosal); intraepithelial or invasion of the submucosa  
T1 - Tumor invades lamina propria  
T2 - Tumor invades muscularis propria  
T3 - Tumor invades through the muscularis propria into the subserosa or into nonperitonealized pericolic or perirectal tissue  
T4 - Tumor perforates the visceral peritoneum or directly invades other organs or structures

#### Regional lymph nodes (N)

NX - Regional lymph nodes cannot be assessed  
N0 - No regional lymph node metastasis  
N1 - Metastasis in 1-3 pericolic or perirectal lymph nodes  
N2 - Metastasis in 4 or more pericolic or perirectal lymph nodes  
N3 - Metastasis in any lymph node along the course of a named vascular trunk

#### Distant metastasis (M)

MX - Presence of metastasis cannot be assessed  
M0 - No distant metastasis  
M1 - Distant metastasis

### **MANAGEMENT**

#### **Treatment of polyps**

-10% of polyps larger than 1 cm contain carcinoma.  
-Not all polyps are amenable to colonoscopic excision.  
-Sessile polyps that contain invasive carcinoma require resection.  
-Pedunculated, cancer-containing polyps may be removed colonoscopically if they meet certain established criteria. If not met, surgical resection  
(1) The carcinoma must be well or moderately differentiated with no venous or lymphatic invasion.  
(2) The carcinoma must not invade further than the stalk of the polyp, and the margins of resection must not contain tumor

#### **7) Inoperable tumour with obstructive features**

-Ascending colon - A bypass using an ileocolic anastomosis  
-Left colon-Upper part of left colon - A transverse colostomy  
-Pelvic colon - Left iliac fossa colostomy

#### **Radiotherapy**

##### Preoperative radiation therapy

Advantages of this treatment include tumor down-staging; an increase in resectability, possibly with a sphincter-sparing procedure; and a decrease in tumor viability, which may decrease the risk of local recurrence. The disadvantages include delaying surgery, loss of accurate surgical staging, and increased postoperative morbidity and mortality rates.

##### Post operative Radiotherapy

Postoperative RT decreases the rate of local recurrence when compared to surgery alone

#### **Chemotherapy**

-Drugs that have been used include 5-fluorouracil with immunomodulant levamisole.  
-Irinotecan and methyl-CCNU

### **Prevention**

#### Screening:

The process of malignant transformation from adenoma to carcinoma takes several years.  
The purpose of screening is to eradicate potential cancers while they are still in the benign stage of the adenoma-carcinoma sequence.  
Screening also increases the likelihood of discovering existing cancers while they are still in the early stage  
High-risk screening  
People at increased risk for colorectal cancer include those with affected first-degree relatives, those with a family history of FAP or HNPCC, and those with a personal history of adenomatous polyps, colorectal cancer, or IBD.  
Colonoscopy: Allows full visualization of the colon and excision and biopsy of any lesions  
Double-contrast barium enema: usually in combination with flexible sigmoidoscopy. Lesions detected by this method require colonoscopy for biopsy or excision.  
Combined FOBT(fecal oral blood Tests) and flexible sigmoidoscopy

#### Prognosis

Overall 5-year survival rates for rectal cancer are as follows:

Stage I - 72%  
Stage II - 54%  
Stage III - 39%  
Stage IV - 7%

Fifty percent of patients develop recurrence, which may be local, distant, or both.

Factors that influence the development of recurrence include surgeon variability, grade and stage of the primary tumor, location of the primary tumor, and ability to obtain negative margins

#### Prognosis

Poor prognostic factors following surgery;

1. Pre-op ↑CEA ( $>5\text{ng/mL}$ )
2. Tumour penetration through the bowel wall
3. Tumour adherence to adjacent organs
4. Perforation
5. Tumour spread to regional LN
6. Number of regional LN involved
7. Venous invasion
8. Poorly differentiated histology
9. Aneuploidy
10. Specific chromosomal deletion (e.g. allelic loss on chromosome 18q)

# CONGENITAL HYPERTROPHIC PYLORIC STENOSIS

## Introduction

A progressive stenosis of the pyloric canal occurring in infancy.

## Etiology

The cause is not known.  
-positive family history

## Incidence

The incidence is 1-8:1000 births, with a 4:1 male predominance

## Onset

Onset usually at 3-4 weeks of age.

## Clinical presentation

- 1) Intermittent, non-bilious, projectile vomiting of increasing frequency and severity
- 2) Initially hungry and feeds avidly, later weakness due to electrolyte imbalances
- 3) Epigastric distention
- 4) Visible gastric peristalsis, from left to right
- 5) An olive-sized mass can often be felt on deep palpation in the right upper abdomen, especially after the child has vomited.
- 6) Jaundice, occasional
- 7) Late signs: dehydration, weight loss
- 8) Constipation

## Laboratory Findings:

1. There is hypochloremic metabolic alkalosis with potassium depletion.
2. Hemoconcentration is reflected by elevated hemoglobin and hematocrit values.
3. Elevated unconjugated bilirubin occurs in 2-5% of cases.

## Imaging

1. **Ultrasonography** (1st choice) **shows a hypoechoic ring with a hyperechoic center.** Thickness of circular muscle is greater than 4 mm in pyloric stenosis.
2. An upper gastrointestinal series reveals delay in gastric emptying and an **elongated narrowed pyloric channel** with a double tract of barium. The enlarged pyloric muscle causes characteristic semilunar impressions on the gastric antrum

## Differential diagnosis

1. In esophageal stenosis or achalasia, the vomitus contains no gastric contents, and metabolic alkalosis is rare.
2. With annular pancreas, malrotation, volvulus, and lesions causing small bowel obstruction, the vomitus is bilious.
3. The absence of virilization and hyperkalemia generally rules out congenital adrenal hyperplasia with adrenal insufficiency. Pylorospasm during barium x-ray may cause delay in gastric emptying, but the elongated narrow pyloric canal is not seen and no mass is palpable.  
Others-Antral webs or diaphragms, duplications, cysts.

## Management

Pyloro-myotomy-Ramstedt surgery

Is the treatment of choice and consists of incision down to the mucosa along the pyloric length.  
Prior to surgery, it is imperative to correct dehydration and electrolyte abnormalities

# CRANIOPHARYNGIOMA

**Other names** Rathke pouch tumor, suprasellar cyst, pituitary epidermoid tumor, ameloblastoma  
pituitary adamantinoma

## Definition

Are histologically benign tumors that are found in the sella turcica and are composed of squamous epithelial cells.

## Origin

The origin of these tumors is presumed to be from rests of embryonic tissue located in Rathke pouch, an embryonic structure that later forms the anterior pituitary gland.

## Age

These tumors may appear clinically at any age and constitute 6 to 10% of all intracranial tumors in children. Although craniopharyngiomas usually occur in the suprasellar region they may extend superiorly into the third ventricle, or inferiorly along the base of the brain.

**Usual course** - progressive.

## Morbidity

Although histologically benign, the clinical behavior of this tumour and its proximity to the optic chiasm, carotid arteries, third cranial nerve, and pituitary stalk, make this a difficult tumor to treat without morbidity.

## Clinical presentation

Most often the presenting complaints are secondary to central-nervous-system involvement by the tumor; they include headaches, vomiting, visual disturbances, symptoms of diabetes insipidus, and changes in sensorium.

Abnormal visual examination, include papilledema (27%),  
■ bitemporal hemianopia (52%), homonymous hemianopia (8%), unilateral hemianopia (8%), significant unilateral visual acuity deficit (35%), and bilateral visual acuity deficit

In some patients there are no signs of endocrine deficiency ; in others growth arrest and pubertal delay may be obvious features  
If the tumor invades the hypothalamus, signs of impaired vegetative function may occur. These include poikilothermia, hypersomnia, and obesity.

## Anatomy

The most common location of these tumors is a combination of intrasellar and suprasellar (70%).

Twenty percent are only suprasellar, and 10% are purely intrasellar. These tumors occasionally grow into the third ventricle, causing hydrocephalus.

The arterial supply is usually from the anterior cerebral and anterior communicating arteries or from the internal carotid and posterior communicating arteries.

## Investigations

Laboratory

**Lab Studies:**A full pituitary endocrine workup is mandatory.

- 1.Corticotropin (ie, adrenocorticotrophic hormone [ACTH])
- 2.Growth hormone (GH) and insulin growth factor (IGF-1)

3.Cortisol

4.Prolactin

5.Luteinizing hormone (LH)

6.Follicle-stimulating hormone (FSH)

7.Thyrotropin (ie, thyroid-stimulating hormone [TSH])

8.Triiodothyronine (T<sub>3</sub>), Thyroxine (T<sub>4</sub>)

Routine CBC count, chemistry panel, and coagulation studies are needed before surgery.

## Imaging

1. Skull x-ray Because many as 88% of patients have suprasellar or intrasellar calcification Even when calcification is not present there is often ballooning of the sella or erosion of the sella walls and posterior clinoid processes

3. CT-scan

3. MRI Advantage over CT is that MRI can easily visualize the tumor in multiple planes and also give the surgeon a better view of the relationship of the tumor to the arteries of the Circle of Willis, pituitary stalk, and the optic and oculomotor nerves.

## Management

Controversy with respect to the extent of surgical resection and the use of postoperative irradiation

The ultimate goal is to prevent recurrence of the tumor with the least impairment of endocrine and intellectual function.

These goals can be achieved either by complete surgical removal of the tumor, or by cyst drainage or partial resection followed by radiotherapy.

Surgery is by the trans-sphenoidal approach, in which the surgeon approaches the sella turcica by a submucosal incision through the nose along the nasal septum approaching the pituitary fossa via the sphenoid sinus.

The pterional craniotomy is the standard approach to suprasellar lesions because it allows good visualization of the optic nerves and chiasm. Variations of the pterional craniotomy have been proposed to include resection of the orbital rim and zygoma so as to provide a more basal view and therefore better access to the superior aspects of this tumor

Complete surgical resection will obviate the need for irradiation, but such aggressive surgery usually results in permanent endocrine dysfunction and sometimes behavioral and intellectual abnormalities. Radiotherapy usually spares remaining endocrine dysfunction, but can cause intellectual problems, especially in the younger child.

# CRYPTOCHIDISM

Cryptorchidism is the most common genital problem encountered in pediatrics, refers to an un-descended or mal-descended testis.

## Testicular embryology

Normal testicular development begins at conception. The testis-determining factor is now identified as the *SRY* gene (sex-determining region on Y chromosome). The presence of this gene and an intact downstream pathway generally result in testicular formation.

At 3-5 weeks' gestation, the gonadal ridge or indifferent gonad develops, and at 6 weeks, primordial germ cell migration occurs. Soon after, Sertoli cells develop and secrete müllerian-inhibiting substance (MIS), the level of which remains high throughout gestation and causes regression of müllerian ducts.

At 9 weeks, Leydig cells develop and secrete testosterone. Up to 28 weeks there is transabdominal movement to the internal inguinal ring. Transinguinal migration, thought to be under hormonal control, occurs from weeks 28-40, usually resulting in a scrotal testis by the end of a full term of gestation.

## Occurrence

Seen in 3% of full-term newborn boys, decreasing to 1% in boys aged 1 year. Spontaneous descent after the first year of life is uncommon

## Predisposing factors

- Prematurity- The prevalence rate is 30% in premature boys.
- Low birth weight
- Twinning
- Maternal exposure to estrogen during the first trimester.
- Siblings of boys with undescended testes A 7% incidence rate is seen.

## Etiology

The multifactorial mechanism of occurrence involves

- 1) Differential body growth relative to spermatic cord/gubernaculum
- 2) Increased abdominal pressure
- 3) hormonal factors, including testosterone, MIS, and extrinsic estrogen
- 4) development/maturation of the epididymis
- 5) gubernacular attachment
- 6) genitofemoral nerve/calcitonin gene-related peptide (CGRP).

## Clinical:

The most useful classification is whether testes are palpable upon physical examination.

-If nonpalpable, testes may be intra-abdominal or absent.

-If palpable, testes may be undescended, ectopic, or retractile.

Nonpalpable testes occur in approximately 20-30% of those who have cryptorchidism. The absent testis is thought to occur from an intrauterine or perinatal vascular event. Only 20-40% of nonpalpable testes are absent upon surgical exploration.

Were abdominal 10%; inguinal 68%; prescrotal, 24%; ectopic/SIP, 11.5%; bilateral, 30%;

Associated anomalies/conditions may include the following:

Patent processus vaginalis

- Abnormal epididymis

- Cerebral palsy
- Mental retardation
- Wilms tumor
- Abdominal wall defects (eg, gastroschisis, omphalocele, prune belly)
- Hypospadias
- Inguinal hernia
- Hemiscrotum
- Hydrocele
- Abnormalities of vas deferens and epididymis
- Klinefelter's syndrome
- Hypogonadotropic hypogonadism

Overall, 32-79% of undescended testes are reported to be associated with some type of epididymal abnormality. However, abnormalities that inhibit sperm transport (eg, complete caput separation, atresia, agenesis ) have been reported in only 8% of patients.

## History

- Determination of whether the testis has ever been palpable in scrotum
- History of prior inguinal surgery
- Prenatal history, ie, assisted reproductive technique, maternal hormonal treatment, multiple gestations, prematurity
- Family history, ie, cryptorchidism, hypospadias, intersex, precocious puberty, infertility, consanguinity

## Physical examination

- Warm, relaxed patient
- Observation prior to examination
- Frog-leg position
- Milk down, palpating from iliac crest to scrotum (soap or lubrication on fingertips may help)
- Scrotum, ie, hypoplastic, bifid, rugae, transposition, pigmentation
- Contralateral testicular hypertrophy
- Ectopic sites, ie, superficial inguinal pouch or transverse scrotal, femoral, prepenile, perineal, or contralateral hemiscrotum
- Presence of hypospadias/chordee, normal stretched penile length
- Serial examinations, if equivocal

Indications for hormonal or surgical correction of cryptorchidism include the following: Possible improved fertility

- Self-examination for testis mass (cancer)
- Correction of associated hernia
- Prevention of testicular torsion
- Avoidance of injury against pubic bone
- Psychological effects of empty scrotum

**Lab Studies:** For unilateral undescended testis without hypospadias, no lab studies are needed.

For unilateral or bilateral undescended testes with hypospadias or bilateral nonpalpable testes, tests include the following:

- Testing to rule out intersex condition (mandatory)
- 17-hydroxylase progesterone
- Testosterone
- Luteinizing hormone (LH)
- Follicle-stimulating hormone (FSH)

## Imaging Studies:



Abdominopelvic ultrasonography to determine the location of ectopic testis and rule out other associated abnormalities in the upper urinary tracts.

#### **Medical therapy:**

The appropriate time for treatment is when the individual is aged approximately 1 year. This age limit has decreased over the recent decades and is based on

(1) the rarity of spontaneous descent after age 1 year and (2) the possible salvage of improved fertility by earlier intervention.

Primary hormonal therapy with hCG or gonadotropin-releasing hormone (GnRH or LH-releasing hormone [LHRH])

#### **Human chorionic gonadotropin**

The action of hCG is virtually identical to that of pituitary LH, although hCG also appears to have a small degree of FSH activity. It stimulates production of gonadal steroid hormones by stimulating the Leydig cells to produce androgens.

**Gonadotropin-releasing hormone** Agonistic analogs of GnRH such as nafarelin or buserelin stimulate the release of the pituitary gonadotropins, LH and FSH, resulting in a temporary increase of gonadal steroidogenesis.

#### **Surgery**

##### **Non-palpable testis-Exploratory laparotomy and orchidopexy.**

Usually surgery should be done before the age of 2 years as past this age structural changes are noticed to occur in the testis which compromise the blood testis barrier and this lead to auto immunity.

However its thought that cryptorchidism may b part of chromosomal abnormality part of which affect the spermatogenesis.

##### **Palpable testis**

An incision is made over the inguinal canal along the Langer lines. For gonadal identification, care is taken when incising the Scarpa fascia because the testis may be located in the superficial inguinal pouch and not in the inguinal canal.

For mobilization of the testis, the distal gubernacular attachments are divided. Then, the cremasteric muscle fibers are transected. Separate the cord structures from the peritoneum above the internal inguinal ring during ligation of the hernia sac. Divide the lateral spermatic fascia to allow medial movement of the testis. Isolate and perform high ligation of the patent processus vaginalis on the anteromedial surface of the cord. Relocate the testis into the scrotum in a subcutaneous or subdartos pouch.

##### **Complications of orchidopexy are as follows**

1. Inadequate testis position occurs in as many incomplete retroperitoneal dissection.
2. Testicular atrophy occurs in approximately 5% of cases due to devascularization.
3. Accidental division of the vas deferens occurs in 1-2% of patients..
4. Epididymoorchitis is uncommon and may be treated with antibiotics.
5. Scrotal swelling may occur and usually is secondary to edema. If progressive, it may be due to bleeding and should be explored. A later presentation of swelling may be secondary to a hydrocele, which, if large, requires transscrotal repair

6. Higher risk (20-46 times) of testicular cancer (risk may remain despite orchidopexy)
7. Hernia development (25%)

NB Orchidopexy is not protective against subsequent testis cancer. Testicular tumors after previously successful orchidopexy most frequently are nonseminomatous germ cell tumors, while abdominal testes may develop seminomas

# CYSTIC HYGROMA

## Definition

Cystic hygromas are multiloculated cystic structures that are benign in nature.

- They form as the result of budding lymphatics and, thus, may occur anywhere in the body, although they are most frequently encountered in the neck (75%) and axilla (20%).
- Cystic hygromas frequently abut and/or encompass neurovascular structures.
- Surgical excision remains the therapy of choice and usually is performed shortly after diagnosis.

## Pathophysiology:

Lymphatic channels are formed from a series of clefts that develop in the mesenchyme around the sixth week of gestation.

- From these channels, sacs are formed that establish drainage with the venous system.
- Failure to establish venous drainage results in dilated disorganized lymph channels, which, in the largest form, present as cystic hygromas.

## Mortality/Morbidity:

### Airway obstruction

- Is the most critical complication of cystic hygroma occurring in the neck.
- To assess risk of airway obstruction, carefully evaluate children with cystic hygromas of the head and neck for any signs of tracheal deviation and for involvement of the oropharynx, airway, and pharynx, such as the hypopharynx and hypolarynx.
- Often the tongue, base of tongue, and supraglottic larynx are involved when the airway is involved, not just mediastinal or neck fullness causing tracheal deviation. Secure the airways in patients with high risk of obstruction.

### Risk of infection

- In a cystic hygroma is approximately 16%. Infection may result in additional swelling, pain, fever, and localized erythema.

### Risk of hemorrhage

- Is approximately 13%. Consider this complication in an enlarging painful cystic hygroma in a patient with evidence of acute blood loss.

### Age:

- Most cystic hygromas are evident at birth (65%), with the remainder evident by the time the individual is aged 2 years.

### Etiology

- Fetal cystic hygromas have almost a 50% association with chromosomal disorders such as aneuploidy
- Cystic hygroma is strongly associated with Turner syndrome (predominantly a 45 XO karyotype), trisomy 21 (Down syndrome), trisomy 18 (Edwards syndrome), and Noonan syndrome.
- Some cystic hygromas can occur in otherwise healthy fetuses and babies.

### Physical:

- The masses are usually large soft structures without clear margins.

- Physical examination may reveal extension into adjacent structures (eg, oral cavity).
- Examine neck for tracheal deviation or other evidence of impending airway obstruction.
- Closely inspect the tongue, oral cavity, hypopharynx, and larynx because any involvement may lead to airway obstruction
- At the time of presentation, include physical examination and chest radiograph with evaluation.
- Chest radiography and/or computed tomography are necessary to determine whether the mediastinum is involved
- Ultrasonography and Magnetic resonance imaging (MRI) often is required preoperatively to determine extent of invasion into adjacent structures and tumor involvement with neurovascular structures.

## DDX

- [Hemangiomas](#)
- [Lymphangiomas](#)
- Neck tumors
- Anterior cystic hygroma
- Laryngocele
- Posterior encephalocele
- Cervical meningocele or meningocele
- Transient cervical cyst
- [Branchial Cleft Cysts](#)
- [Encephalocele](#)
- Dermoid cyst
- Sebaceous cyst.

## Management

### Medical Care:

- The medical treatment of cystic hygroma includes injection of sclerosing agents and/or steroids.
- Treat an infection with intravenous antibiotics and perform definitive surgery once the infection has resolved.
- However, some infected cystic hygromas may improve with use of a sclerosing agent, such as OK-432, which contains penicillin and streptococci.
- Medical therapy with sclerosing agents is an alternative and should be discussed with the patient.
- Absolute alcohol as a sclerosing agent has been used with some success in some patients; alcohol works well in vascular malformations.
- If unresectable lesions are small cysts, they may not respond to sclerosis.
- Recurrent disease may respond poorly to sclerosis. .
- Medical therapies also are being studied for in utero application.
- This approach is appealing because it avoids the difficulties of delivery of a child with a large cystic hygroma. .

### Surgical Care:

- The mainstay of therapy is surgical excision.
- The goal of performing surgical therapy is to remove the lymphangioma completely or to remove as much lymphangioma as possible, sparing all vital neurovascular structures.
- The exceptions include premature infants of small size and those with involvement of crucial neurovascular structures that are small and difficult to identify (eg, facial nerve).
- In such infants, delay surgery until the child is aged 2 years to allow growth of the child to a size that facilitates surgical excision without increased morbidity

-Many newborns who have cervical hygromas with stable airways and food ways can be observed, especially individuals with parotid hygromas.

-Do not attempt drainage of the cyst because it increases the risk of infection through possible contamination and causes increased difficulty during resection because the thin walls of the cyst are not located easily when not fluid filled.

-Tracheotomy may be necessary to secure the airway when obstruction is observed.

**Complications resulting from excision of a cystic hygroma include**

- damage to a neurovascular structure
- chylous fistula
- chylothorax
- hemorrhage.

# DIABETIC (NEUROPATHIC) ULCERS

Ulceration is caused by several factors acting together, but particularly by neuropathathy. Peripheral neuropathy results in loss of the protective sensation of pain and in autonomic dysfunction, with sympathetic denervation, dry skin, and warm feet.

Other important component causes of ulceration include peripheral vascular disease, callus, edema, and deformity. The triad of neuropathy, deformity, and trauma is present in almost two thirds of patients with foot ulcers.

## Diagnosis

### History

Information relating to ulcer history should be recorded in a structured format and may include

- year first ulcer occurred
- site of ulcer and of any previous ulcers
- number of previous episodes of ulceration
- time to healing in previous episodes
- time free of ulcers
- past treatment methods (both successful and unsuccessful)
- previous operations on venous system
- previous and current use of compression

Intermittent claudication, varices, lack of sensation, pain

Family hx of DM, HTN

Features of ischemic heart dz, retinopathy, nephropathy

### Ulcer Assessment

If the ulcer has been present for months and is asymptomatic and if foot pulses are palpable, neuropathy should be considered as a major cause.

However, given the variability of assessment of foot pulses, noninvasive assessment of the peripheral circulation is recommended if there is any suggestion of peripheral ischemia. Callus formation and a plantar site of ulceration also suggest neuropathy as a major contributory cause. A combination of lack of sensation, limited joint mobility, autonomic dysfunction resulting in dry skin, and repetitive high pressure may lead to callus formation.

The relative risk of ulcer development at an area of high pressure (i.e., the metatarsal heads, as compared with the mid-foot) is and that of an ulcer developing at a site of callus

Vascular status must be assessed pulses, parlour, parasthesia, pain, temperature

### Investigations

- Pulses
- BP
- Random blood sugar
- Doppler Ultrasound
- Arteriogram

### Infection of the Ulcer

Infection is usually a consequence, rather than a cause, of ulceration, which allows the entry and

multiplication of microorganisms.

A commonly accepted definition of foot infection is the presence of systemic signs of infection (e.g., fever, leukocytosis ) or purulent secretions, or two or more local symptoms or signs (redness, warmth, induration, pain, or tenderness).

Since foot infection has the potential to threaten the limb, appropriate diagnosis and therapy are urgently required. If infection is present, a deep-tissue specimen should be obtained aseptically, if possible; such specimens are superior to superficial swab specimens for the isolation of resistant organisms.

Polymicrobial isolates, including aerobic and anaerobic species, are common.

### Osteomyelitis

The findings on plain radiographs are often suggestive of osteomyelitis (manifested as bone destruction or periosteal reaction, especially as compared with findings on prior films) and radiographs are therefore recommended by many experts when there is evidence of infection.

Histologic evaluation and culture of a bone-biopsy specimen are regarded as the gold standard

Although white-cell scans are sensitive for the diagnosis, magnetic resonance imaging (MRI) is now considered the imaging test of choice when osteomyelitis is suspected; the sensitivity and specificity of MRI for osteomyelitis in diabetic patients are 90 percent or greater.

### Management

The principles of management of neuropathic ulcers include eradication of infection and removal of pressure from the ulcer.

### General Care

1-Glycemic control is important, since leukocyte function is impaired in patients with chronic hyperglycemia.

2-Patients should be advised to stop smoking, smoking may affect vascular factors, but also because smokers have higher rates of incisional-wound infections than nonsmokers or former smokers.

3-Do not go barefoot- well fitting shoes Inspect the feet daily, especially between the toes

4-Keep the feet clean and dry

5- Seek help trim toenails, or if corns/callouses develop

6-Comply with medications

7- Avoid exposure to cold, friction, moisture between toes

8•-Aviod use of external heat (heat pad, hot water bottle, hydrotherapy)

### Wound Management

1. Sharp débridement-the removal of necrotic and senescent tissue as well as foreign and infected material from the wound

2. Treatment of local edema. Intermittent foot compression by a pneumatic pump results in a higher rate of healing at 12 weeks

3. Removal of Pressure-reducing mechanical stress, or off-loading. Techniques for removing pressure include the use of casts or boots, half shoes, sandals, and felted foam dressings. Use of a total-contact cast (i.e., a non removable cast) over the involved limb has been shown to be superior to standard therapy and other techniques for removing pressure.

Contraindications to total contact casts and other un removable casts include infected or ischemic wounds.

4. Dressings-The development of dressings that promote a moist environment to assist healing has been a focus of care for chronic wounds.

The selection of a dressing involves matching the properties of the dressing (such as control of exudates) with the characteristics of the ulcer and the patient.

#### 5. Infection control

The choice of antibiotic for infected foot ulcers is initially based on the pathogens presumed to be present. Commonly used broad-spectrum antibiotics include clindamycin, cephalexin, ciprofloxacin, and amoxicillin-clavulanic acid (Augmentin).

Intravenous antibiotic options for more serious infections (e.g., cellulitis) include imipenem, (ampicillin-sulbactam and piperacillin-azobactam), and broadspectrum cephalosporins

Soft-tissue infections usually require one to two weeks of therapy, whereas osteomyelitis may require more than six weeks of antibiotics, often accompanied by surgical débridement of infected bone.

Swab wound for microscopy, culture and sensitivity

# EMPHYEMA THORACIS

- ❖ Definition
- ❖ Presentation
- ❖ Pathophysiology
- ❖ Investigations-Lab and Imaging
- ❖ Management-Medical
- Surgical

## Definition

Empyema is a localized or free collection of purulent material in the pleural space. It is an advanced Para pneumonic effusion. Para pneumonic Pleural effusions are divided into 3 based on pathogenesis

### **1. Uncomplicated pleural effusion**

-Exudative predominantly neutrophilic effusion that occurs as the lung interstitial fluid increases during pneumonia. These effusions are resolved with appropriate antibiotic treatment of pneumonia.

### **2. Complicated pleural effusion**

Bacterial invasion of the pleural space that leads to an increased number of neutrophils, pleural fluid acidosis, and elevated lactic dehydrogenase (LDH) concentration. These effusions often are sterile because bacteria are usually cleared rapidly from the pleural space

### **3. Thoracic empyema.**

Thoracic empyema is characterized by either aspiration of pus on thoracentesis or the presence of bacterial organisms on Gram stain. A positive culture is not required for diagnosis.

## **Etiology -Predisposition**

1. Pulmonary infection-Unresolved pneumonia – Acute bacterial
2. Pulmonary tuberculosis, mycotic
3. Bronchiectasis
4. Lung abscess
5. Subphrenic abscess
6. Trauma -Penetrating injury chest, Esophageal perforation
7. Iatrogenic- postoperative infection or aspiration of pleural fluid. Follow thoracentesis, thoracotomy or thoracoscopy
8. Generalized sepsis
9. Adjacent infections
  - a) Retropharyngeal
  - b) Mediastinal abscess
  - c) Osteomyelitis of ribs
  - d) Para vertebral abscess

## **Bacteriology**

-Tubercula empyema  
-Nontubercular empyema are Staphylococcus aureus , Pneumococci , E. coli , Pseudomonas , Klebsiella , and anaerobes.

## **Pathophysiology**

American Thoracic society identifies 3-stage development of empyema:

### **1. Exudative (acute) stage .**

- The pleural inflammation results in increased permeability and a small fluid collection.
- The fluid is thin, contains few cellular elements mostly neutrophils, and is often sterile and amenable to thoracentesis.
- This stage lasts only 24-72 h and then progresses to the fibrinopurulent stage.

### **2. Fibrinopurulent (transitional)**

- invasion of the organism into the pleural space
- progressive inflammation
- polymorphonuclear (PMN) leukocyte invasion.
- There is an accumulation of protein and fibrinous material with formation of fibrin membranes, which forms partitions or loculations within the pleural space.
- There is decrease pleural fluid glucose and pH and increased protein and lactate dehydrogenase (LDH).
- This stage lasts for 7-10 days and often requires more aggressive treatment such as tube thoracostomy.

### **3. Organizing (chronic) stage.**

- A thick pleural peel is formed by resorption of fluid and as a result of fibroblast proliferation.
- The lung parenchyma becomes entrapped, forming a fibrothorax. Activation of the coagulation cascade is common with pleural empyema. The pleural inflammatory response favors increased procoagulant activity as well as depressed fibrinolytic activity, favoring fibrin deposition. Loculations result, with these fibrin strands being covered rapidly by a meshwork of fibroblasts that both proliferate and deposit basement membrane proteins onto the surface of the pleura. These proteins obscure the separation of the visceral and parietal pleura and lead to the formation of the pleural peel.
- This stage usually occurs within 2-4 weeks after the initial presentation
- Following timely initiation of proper antibiotic therapy, the inflammatory process resolves. Re-epithelialization of the pleura occurs with the migration of pleural mesothelial cells into areas of denudation.
- However, inappropriate or delayed treatment leads to exuberant pleural inflammation resulting in pleural fibrosis, and restrictive lung disease.

## **Incidence:**

increased incidence of pneumonia and tuberculosis likely to cause increased incidence of empyema

## **Mortality/Morbidity:**

Early recognition of pneumonia with parapneumonic effusion, effective intervention to identify the infecting organism, and initiation of definitive therapy reduce the morbidity and complications associated with this process

## **Clinical presentation**

### **History**

Most patients with empyema present with clinical manifestations of bacterial pneumonia. ie

1. Acute febrile response
2. pleuritic chest pain
3. cough
4. dyspnea
5. Hemoptysis

Some patients are severely systemically toxic or even comatose. May be cyanotic, hypotensive, dehydrated, and oliguric, weakness. The inflammation of the pleural space may cause abdominal pain and vomiting. Frequently, patients exhibit characteristic splinting of the affected side. Symptoms may be blunted, and fever may not be present in patients who are immunocompromised.

The therapy instituted depends on the :

- causative factor
- stage of empyema
- state of the underlying lung
- presence of bronchopleural fistula (BPF) if any,
- ability to obliterate the space
- condition of the patient

### Physical

Features of pleural effusion in the chest crackles, decreased air entry and stony dullness  
Cyanosis, dehydration and hypotensive in toxic patients

### Differential diagnosis

Heart Failure, Congestive  
Hemothorax  
Nephrotic Syndrome  
Pleural Effusion  
Pulmonary Infarction  
Pulmonary Sequestration  
Pulmonary abscess

### INVESTIGATIONS

#### Laboratory

1. FBC

2. Thoracentesis done and fluid sent for:

NB Performing thoracentesis before the initiation of antibiotics increases the diagnostic yield of the fluid cultures and allows for more specific antimicrobial therapy

a) WBC counts usually >15000/dl WBC & differential count predominantly PMN'S

b) Gram stain and AFB

c) Culture and sensitivity Bacterial, mycobacterial, and fungal cultures

d) Pleural fluid latex agglutination

e) Biochemistry Glucose, LDH, pH, protein, amylase, lipid stain or triglycerides,

Treatment should be initiated on the basis of the clinical course and should not wait for above tests.

Pleural fluid latex agglutination [or counter immunoelectrophoresis (CIE) for specific bacteria] may be helpful if the cause of the infection cannot be ascertained from culture results

3. Blood cultures

4. Sputum – AFB, cultures and Radionuclide studies

#### Imaging

1. CXR- Features of pleural effusion as obliteration of costophrenic angle and fluid level plus diffuse opacity.

Severe effusion may show displacement of the mediastinum to the contralateral hemithorax as well as scoliosis

2. Ultrasound for septation of fluids.

3. Complex fluid collections, chest CT imaging has emerged as the study of choice.

Chest CT imaging can be used to detect and define pleural fluid and image the airways, guide interventional procedures, and discriminate between pleural fluid and chest consolidation.

### MANAGEMENT

#### -Medical

#### -Surgical

-Combination of both medical and surgical mx is often employed.

-The objectives of treatment are to

a) Control infection

b) Drainage of the purulent fluid

c) Eradication of the sac to prevent chronicity and allow re-expansion of the affected lung to restore function

The treatment needs to be individualized and it depends on the available clinical, radiological, and laboratory evidence.

#### Medical care

General measures include:

-Increase in the protein and fluid intake.

-Physiotherapy and breathing exercises will help in early re-expansion of the lung following evacuation of the fluid.

-NSAIDS

#### Antibiotics

An empiric selection of the most appropriate antibiotics is necessary before result of culture and sensitivity.

Base the choice on the most common pathogens causing pneumonia for the patient's age and geographic location and history.

The patient receives 10-14 days of intravenous antibiotics and receives treatment until he or she is afebrile, off supplemental oxygen, and appropriately responding to therapy. Followed by oral antibiotics for 1-3 weeks

#### 1. Thoracentesis

Thoracentesis may provide, both significant diagnostic information and therapeutic relief for parapneumonic effusions.

In cases of streptococcal infection, the pus is very thin and the volume is also small, with fluid pH above 7.2, glucose above 40 mg/dl and with LDH levels below 1000 IU/l. In such cases, only a diagnostic needle aspiration suffices.

In cases tubercular etiology, the antitubercular chemotherapy started and the pus in the pleural space aspirated through a wide-bore needle.

A 6-month course with 4+2 drugs or a 9-month course with 3 drugs is recommended. The treatment may be required for a longer time in cases with associated Pott's spine.

#### 2. Tube thoracostomy

Chest tube drainage with an underwater seal is done for cases in stage 2.

Diagnostic thoracentesis and chest tube drainage are effective therapy in more than 50% of patients.

Prompt drainage of a free-flowing effusion prevents the development of loculations and a fibrous peel.

If the fluid is not free flowing, further radiological imaging may be required.

#### 3. Interventional radiology

The U/S or CT-Scan guided placement of small-bore catheters, specifically directed to the loculated pleural fluid collections, has helped to facilitate drainage. Radiologists can lyse adhesions

directly using imaging during the tube placement. Interventional radiologists have used fibrinolytics such as urokinase, streptokinase, and tissue plasminogen activator (TPA) in complicated empyemas with loculations and ameliorated fibrous peel formation and fibrin deposition.

### **Surgical intervention**

-Chronic empyema, that may be caused by delayed medical attention, inadequate antibiotic therapy, inadequate drainage, presence of foreign body, infliction of postresectional space.  
-chronic pulmonary infection such as mismanaged tuberculosis.  
- Other causes of ICD failure include improper positioning of tube, improper selection of tube size, inadequate physiotherapy, and presence of Broncho Pulmonary fistula  
-Multiloculated empyema or persistently symptomatic effusion is likely to require surgical intervention.

#### **a) Rib resection**

Altho' not highly practiced rib resection becomes mandatory to gain adequate access while dealing with the chronic cases.

Rib resection becomes necessary if the pus is thick and loculated, or if the patient remains toxic after inter costal tube drainage.

This not only provides adequate exposure but also allows one to evacuate the pus, break up loculations and adhesions, and assess the need for decortication.

After cleaning the cavity thoroughly, a tube may be placed in its most dependent portion and attached to underwater seal drainage. A properly placed intercostal tube would be as effective as two or three tubes.

#### **b) Open drainage**

In chronic cases with a regular discharge of thick pus, a wide bore tube may be left in place, open to atmospheric pressure. This is helpful in pts with chronic tubercular empyema, after prolonged (3-5 weeks) chest tube drainage.

#### **c) Thoracotomy and Decortication**

-Thoracotomy is done to remove the pleural peel and lyse the adhesions if the patient does not respond promptly to the treatment above.

- Decortication comprises removal of the organized inflammatory membrane. It comprises of two types of procedures:

1. Removal of the visceral peel alone, and
2. Empyemectomy comprising of extrapleural dissection outside the parietal pleura and removal of the complete cavity.

Length of hospital stay, duration of antibiotics, and long-term morbidity are reduced by this more aggressive approach with rapid resolution of symptoms, but it is a major operative procedure with increased cost and short-term morbidity.

Thoracotomy and decortication is very effective, with a reported 95% success rate for patients with fibrinopurulent effusions, and is likely to remain a treatment of choice for advanced empyema.

#### **d) Video-assisted thoracoscopic surgery (VATS)**

Pre operative CT scan will help to assess the location and thickness of pleural peels and enable to site thoracoscopic ports more effectively.

Thoracoscopic debridement closely imitates open thoracotomy and drainage. However, not suitable in late stages of empyema due to thick pleura which needs to be removed. (Stage 3).

The VATS has proved to be an effective and less invasive replacement for the limited decortication procedure

Its drawbacks:

- suboptimal decortication incase of bleeding
- inadvertent lung injury

#### **e) Lobectomy and pneumonectomy**

Surgical excision of a lobe or the whole lung esp. where tuberculosis is prevalent.

In some patients, even after adequate decortication, the lung does not expand owing to underlying necrosis. In such cases, resection of the affected lung segment will be prudent.

Lung excision (complete or in part) is frequently required to prevent the other lung from being flooded with the secretions from the infected lung.

Also, rib excision may sometimes be required to have a good access to thorax in the advanced cases of empyema with crowding of the ribs.

### **Indications for pulmonary resection in cases of tubercular empyema.**

1. Resistant tuberculosis Relative indications for surgical intervention such as severe cavitation, bronchiectasis, or bronchial stenosis may contribute to the failure of chemotherapy i.
2. A mass lesion of the lung in an area of tubercular involvement. This helps for simultaneous diagnosis of the mass lesion and treatment of tuberculosis.
3. Massive life-threatening hemoptysis or recurrent severe hemoptysis.
4. A broncho-pleural fistula that does not respond to tube thoracostomy.

### **Complications**

1. Empyema necessitans-A swelling appears over the chest wall, which is in communication with the underlying empyema. It has a positive cough impulse. It usually does not require any additional treatment and heals spontaneously with adequate treatment of the underlying empyema.
2. Fibrothorax, is a rare complication seen in adolescents who have presented very late.
3. Broncho-pleural fistula (BPF)
4. Long-term effects -suffer restrictive lung disease and abnormal spirometry.



# ESOPHAGEAL CANCER

## DIAGNOSIS AND MANAGEMENT

### Introduction, definition, age, pathology –Refer.

#### **Sex**

M:F - 25:1

#### **Age**

Average age - 58.2yrs (12-103yrs)

Prevalent region - Central Nyanza province

#### **Predisposing factors**

Contribute to repeated long term minimal trauma

##### a) Lifestyle

1. Smoking - SCC

2. Alcohol excess – SCC

-Betel chewing

##### b) Diet

3-Hot foods

4-Deficiency of antioxidants which have been found to inhibit carcinogenesis, including selenium, vitamins C and E, retinoids, & β-carotene, & plant sterols.

5-Exposure to N-nitroso compounds (from Nitrates & Nitrites converted by bacteria in the body)

6-Charred meat, Smoked fish

##### c) Disorders of esophagus

7.Achalasia

8.Long standing oesophageal strictures

9.Post-irradiation

10.Paterson-Brown-Kelly (Plummer-Vinson) Syndrome - Post cricoid web + IDA

11.Barrett's oesophagus - there is a 44-fold ↑ risk of Adenocarcinoma if severe reflux for >10yrs

##### d) Genetics

12.Tylosis (Palmar hyperkeratosis)

13.Coeliac disease - Predisposes to Adenocarcinomas

14-Epidrmlolysis bullosa

15-P53 and RB genes

#### **Pathology**

##### Types:

Squamous cell carcinoma- Most common worldwide

Adenocarcinoma - Most common in most Westernised countries

Oat cell carcinoma

##### **Site:**

20% - Upper 1/3 - Squamous cell carcinoma

50% - Middle 1/3 - Squamous cell carcinoma

30% - Lower 1/3 - Adenocarcinoma

##### Spread:

1. Local-regional - Occurs through submucosal infiltration of the wall of the oesophagus into adjacent structures, along the length of the oesophagus in the submucosal lymphatics & to regional lymph nodes. This is often discontinuous i.e. distant regional lymph nodes may be invaded even when local nodes are free of tumour, & there may be satellite nodules in the oesophagus proximal to the main tumour.

2.Systemic (Haematogenous) - Mainly to the liver & lungs, but practically any organ can be involved

#### **Staging**

##### **TNM Staging**

**Tis** Carcinoma-in-situ

**T1** invading lamina propria/submucosa

**T2** invading muscularis propria

**T3** invading adventitia

**T4** invasion of adjacent structures

**NX, N0, N1**

**M0** no distant spread

**M1** distant metastasis; Spread to the *coeliac axis nodes* from a lesion in the intrathoracic oesophagus - Regarded as **metastatic (M)** rather than nodal (N) disease in the TNM classification.

##### Predisposing factors.

- Cigarette smoking or smoking in immediate family and alcohol intake.

-ingestion of corrosive liquids-strictures

-peptic ulcer and GERD-predispose adenocarcinoma

-chronic drug intake-esophagitis

-Consumption of chemically preserved vegetables-nitrates

Smoked fish or meat

-Chest irradiation-therapeutic or otherwise

-cancer in patient or Family history of similar illness

#### **DIAGNOSIS**

##### History

##### Symptomatology

-Progressive dysphasia initially to solids then to liquids.

-Associated odynophagia- involvement of somatic structures.

-Associated choking while eating-possibility of Tracheo-esophageal fistula

-Hoarseness of voice-involvement of recurrent laryngeal nerve

-Associated regurgitation and vomiting-colour-no bile pigment. (Due to the obstruction)

-History of hematemesis or hemoptysis

-Difficulty in breathing, cough-pulm. mets

-Progressive weight loss, generalized fatigue and night sweats.

-Steady deep chest pain often indicates mediastinal invasion.

##### Physical Examination

##### Usually non-revealing:

##### General examination-

1.Anemia- chronic disease or Plummer Vinson syndrome

Also check glossitis and angular stomatitis

2.Dehydration and wasting –malnutrition

3.Oedema-malnutrition

4.Supraclavicular lymphadenopathy-**Virchows node**

-Examination of Chest crucial because of tumor infiltration.

-Trachea central, air entry.

-Resp exam-TOF creates effusion and pneumonia.

#### **INVESTIGATIONS**

##### Laboratory

1.FHG-Anemia can be due to bleeding or nutritional deficiency or can be secondary to chronic disease and pre op preparation

2.U/E/C pre op

3. Liver function tests Serum protein levels (albumin, prealbumin, and transferrin) may be low, reflecting the extent of malnutrition.

-Abnormal liver function tests may indicate liver metastases

### **Imaging**

#### **1. Esophagoscopy and biopsy-Gold standard**

Allows visualization histological (or cytological) confirmation of suspected carcinoma.

It is important to measure the length of the lesion and the distance from the incisors for staging and treatment planning.

Typical tumours are friable and bleed easily. Multiple biopsies from suspicious areas should be performed.

Bronchoscopy may be done to check invasion of the bronchi

#### **2. Barrium swallow-in case OGD absent**

Done early in course of dysphagia. Characteristic findings include

1. Rat tail appearance
2. Proximal dilatation.
3. Sholdering effects
4. Mucosal erosion/defects

#### **3. CXR**

- a) Check for mediastinal widening-invasion by tumor or lymphadenopathy
- b) Pleural effusion indicate pleural dissemination
- c) TOF pneumonic process features of aspiration pneumonia.
- d) The diaphragm doming in involvement of phrenic nerve causing paralysis.
- e) Lung nodules-lung metastasis or lung abscess
- e) An esophageal air-fluid level-obstruction

#### **4. Endoscopic ultrasonography**

-Endoscopic ultrasound improves the ability to determine wall penetration and abnormal lymph nodes.

- Used in pre-operative staging. Five distinct wall layers can be identified that correspond to the mucosa, lamina propria, muscularis mucosa, muscularis propria, and adventitia. Carcinoma appears as an irregular hypoechoic mass. Depth of penetration of the wall can be accurately assessed.

The ability to detect regional lymph-node involvement may be further enhanced by the use of endoscopic, ultrasonographically guided fine-needle aspiration, which has an accuracy of more than 90 percent at many centers

#### **5. CT-Scan of the chest**

Local invasion of the tumour and extension. Used in staging of the tumour.

#### **Other investigations**

- a) **Bronchoscopy** should be done in lesions of the upper or middle 1/3, where there is potential for tracheo-bronchial invasion.
- b) **Staging laparoscopy** is useful for assessing Adenocarcinoma of the distal oesophagus, particularly if it is likely to extend below the phreno-oesophageal ligament. Also, transperitoneal spread & liver metastasis

#### **Differential diagnosis**

1. Benign papillomas, polyps, or granulomatous masses
2. Esophageal webs, rings and strictures
3. Achalasia cardia

4. Mediastinal tumours-Lymphoma

### **MANAGEMENT**

The goal of treatment in carcinoma of the oesophagus is two fold: palliation of dysphagia and cure of the cancer. The standard of therapy is oesophageal resection.

-However most patients present with advanced tumour which are unresectable. Palliative management to relieve the dysphagia is instituted.

-Esophageal carcinoma is treated by surgery, radiotherapy, chemotherapy, or a combination of these methods.

- It is important to stage the lesion as accurately as possible before deciding on the treatment plan.

-Resectability of the primary lesion must first be determined. Nonresectability is suggested by:

1. Direct spread to the trachea-bronchial tree or aorta
2. Angulation of the esophageal axis.
3. Tracheoesophageal fistula
4. Hoarseness associated with vocal cord paralysis
5. Primary tumors larger than 10 cm are rarely resectable

### **A. SURGERY**

#### **Mucosal resection at endoscopy-CIS**

For the carcinoma in situ

#### **Types of Curative Subtotal Oesophagectomy;**

The, main determinants of the operation chosen are the surgeon's preference and level of the tumour.

The three most common approaches currently in use are:

1. Grey –Turner's Transhiatal oesophagectomy
2. Lewis' laparotomy and right thoracotomy
3. Sweets' left thoraco-abdominal

#### **1. Grey –Turner's Trans-hiatal oesophagectomy**

Best used to remove upper-third or lower-third neoplasms

The operation is done in a supine position with a single lumen endotracheal tube.

A laparotomy is performed first and the abdomen is explored.

The stomach is prepared as an oesophageal substitute.

The stomach is mobilized on the right gastric and gastroepiploic arteries. The omentum is divided, preserving the right gastroepiploic artery. The left gastric artery is double ligated.

The gastrohepatic omentum is divided with care taken to identify accessory arteries to the left lobe of liver.

The hiatus is dissected. It is helpful to open the hiatus anteriorly as described by Pinotti. This facilitates exposure of the distal oesophagus almost to the level of the carina.

The side of left neck is opened and the oesophagus exposed; The upper third of the oesophagus can be dissected under direct vision. Cancerous portion of oesophagus is removed and the stomach is brought up through the posterior mediastinal oesophageal bed and a cervical anastomosis performed.

#### **2. Lewis' laparotomy and right thoracotomy**

Best for mid- or lower-third lesions.

An upper midline laparotomy is performed and the upper abdomen explored.

The stomach is mobilized as previously described. It is important to enlarge the hiatus to prevent compression of the stomach when it is brought into the chest.

Patient is then positioned for right thoracotomy. The stomach is then elevated up into the chest and a high intrathoracic anastomosis is made at the apex of the right chest.

**3.-3 stage McKeown operation** - As Ivor Lewis (above) but a third incision on the right of the neck is made to complete the cervical anastomosis. A neck incision is required if;

- lymph node dissection is to be done
- there are technical difficulties with an anastomosis at the thoracic inlet
- For upper & middle 1/3 tumours

#### **4. Sweets' left thoraco-abdominal**

Best employed for gastro-oesophageal junction carcinomas or low oesophageal carcinomas. Tumours 35 cm or more from the incisors are ideally suited to this approach.

The patient is placed in the right lateral decubitus position. An oblique left upper quadrant laparotomy is performed to explore the gastro-oesophageal junction area and the liver.

Then a thoracoabdominal incision through the sixth or seventh interspace is performed. The diaphragm is incised circumferentially to avoid injury to the phrenic nerve branches. The stomach is mobilized as above.

The hiatus is dissected. A pyloromyotomy or pyloroplasty is then done according to the surgeon's preference. The oesophagus is then dissected in en-bloc fashion from the pericardium to aorta. Advantage of this approach is the excellent exposure of the gastro-oesophageal junction and the ease of mobilizing the stomach, especially in obese patients.

#### **Post-op:**

A chest tube is left in place after thoracotomy  
NPO for **1-2 days** & then perform a **contrast swallow** (*Methylene Blue, Gastrografin, Dilute Barium*) to detect leakage. If present, NPO is maintained until it has healed

#### **ADVANCED DISEASE (T3/4)**

##### **Palliative therapy for Dysphagia**

###### **1) Intubation**

For middle & lower 1/3 tumours; Not for upper 1/3 as the tube may become displaced upwards & may block the airway. It is inserted by;

###### **i) Oesophagoscopy**

Pulsion tubes e.g.,

- ✓ Proctar Livingstone
- ✓ Atkinson
- ✓ Souttar tubes

At endoscopy dilate through the tumour mass and mount the tube and push through the tumour. Done under sedation. Are expensive tubes.

###### **ii) Laparotomy**

Traction tubes e.g.

- ✓ Celestin tube (rubber)-better for lower 1/3 tumours.
- ✓ Mousseau-Barbin tube (Plastic)

At endoscopy dilate through the tumour and push the tube up to the stomach.

Do laparotomy then open through the stomach, pull the lower edge (traction applied) until they can't move anymore. Can fix the lower edge to the stomach.

#### **Complications of tubes**

- a) Dislodged
- b) Blocked with food

- c) Overgrown and blocked by tumour
- d) Aggravation of chest pain.
- e) Haemorrhage
- f) Perforation

-Furthermore, concomitant radiotherapy increases the complications of tubes e.g., bleeding, perforation.

-Therefore, intubation should be reserved for patients with extensive disease and a life expectancy limited to 1-2 months.

-Patient should rest at 45 degrees to reduce reflux

-Should take meals at least 3 hours before sleeping.

Drink pure pineapple juice.

**2) Laser therapy** - a core of tumour is vaporized, opening the lumen without perforating the oesophagus.

**3) Radiation therapy**-For patients with unresectable disease and for poor operative candidates, radiation therapy may afford significant short-term palliation of pain and dysphagia. Better for upper third tumours which are mostly squamous cell carcinoma. During therapy, esophagitis may lead to worsening of dysphagia and odynophagia. Combined radiation therapy and chemotherapy may achieve palliation in two-thirds of patients. The most common agents for treating esophageal cancer include **5-fluorouracil, cisplatin, mitomycin, and vincristine.**

#### **4) Stenting**

**5) Photodynamic therapy** is a newer, experimental treatment for local esophageal cancer obliteration. Patients are injected with a photosensitizing chemical that is preferentially retained in cancer tissue. Under endoscopic guidance, a diffusing fiber attached to a tunable argon-pump dye laser is placed adjacent to the tumor. Laser activation emits non thermal light, which at the appropriate wave length causes selective necrosis of the sensitized tumor

**6) Repeated dilatation**-poor results

**7) Sclerosis** with absolute alcohol

#### **Prognosis**

Resectable rate - 30%

5YSR - 5-10% (KNH - 25%)

# FISTULA-IN-ANO

## Definition

- An anorectal fistula (Fistula-in-Ano) is an abnormal communication between the anus and the perianal skin.
- It occurs as hollow tract lined with granulation tissue connecting a primary opening inside the anal canal to a secondary opening in the perianal skin.
- Secondary tracts may be multiple and from the same primary opening.

## Sex and Age

The male-to-female ratio approx. 2:1  
The mean age of patients is 38 years.

## Etiology:

-Fistula-in-ano is nearly always caused by a previous anorectal abscess.

-Anal canal glands situated at the dentate line afford a path for infecting organisms to reach the intramuscular spaces.

Other predisposing factors

- 1) Trauma
- 2) Crohn disease
- 3) Anal fissures
- 4) Anorectal Carcinoma
- 5) Radiation therapy
- 6) Infection -actinomycoses, tuberculosis, and chlamydial infections.
- 7) Prolapsed internal hemorrhoid
- 8) Acute appendicitis, salpingitis, diverticulitis
- 9) Immunosuppression

## Pathophysiology:

### The cryptoglandular hypothesis

The infection begins in cryptoglandular situated at the dentate line in the anal canal and progresses into the muscular wall of the anal sphincters to cause an anorectal abscess.

Following surgical or spontaneous drainage in the perianal skin, occasionally a granulation tissue-lined tract is left behind, forming the fistula in-ano which causes recurrent symptoms.

## Classification of fistula in-ano

### Parks classification system

The Parks classification system defines 4 types of fistula-in-ano that result from cryptoglandular infections.

#### 1.Intersphincteric-commonest-70%

Common course - Via internal sphincter to the intersphincteric space and then to the perineum. They result from perianal abscesses

#### 2. Transsphincteric -25%

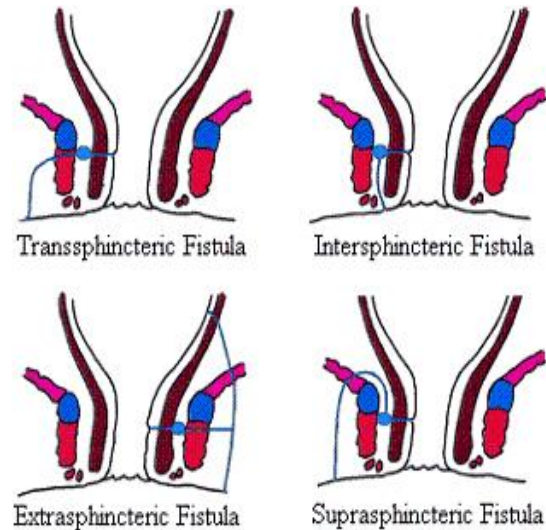
Common course - Low via internal and external sphincters into the ischioanal fossa and then to the perineum. Originate from ischioanal abscesses

#### 3.Suprasphincteric -5%

Common course - Via intersphincteric space superiorly to above puborectalis muscle into ischioanal fossa and then to perineum. Result from supralevator abscesses

#### 4. Extrasphincteric-1%

Bypass the anal canal and sphincter mechanism, passing through the ischioanal fossa and levator ani muscle, and open high in the rectum



## Current procedural terminology codes classification

1.Subcutaneous

2.Submuscular (intersphincteric, low transsphincteric)

3.Complex, recurrent (high transsphincteric, suprasphincteric and extrasphincteric, multiple tracts, recurrent)

3.Second stage

## Clinical presentation

History (in order of prevalence)

- 1) Perianal discharge-intermittent or constant
- 2) Perianal pain-worse during defecation, may be constant
- 3) Swelling /lump in the perianal area
- 4) Bleeding in the perianal area
- 5) Diarrhea
- 6) Discoloration of skin surrounding the fistula
- 7) External opening in the perianal discharging
- 8) Fever

## Past medical history

Important points in the history that may suggest a complex fistula include the following:

- Inflammatory bowel disease
- Diverticulitis
- History of trauma
- Previous radiation therapy for prostate or rectal cancer
- Tuberculosis
- Immune suppression-Steroid therapy , HIV infection

## Review of symptoms

- Abdominal pain
- Weight loss
- Change in bowel habits

### Physical examination

Physical examination findings remain the mainstay of diagnosis.

- The examiner should observe the entire perineum
- external opening that appears as an open sinus or elevation of granulation tissue
- Spontaneous discharge via the external opening may be apparent or expressible upon digital rectal examination.

### DRE

- External Anal sphincter tone
- Tenderness on examination
- Fibrous tract or cord beneath the skin.
- Boggy- any abscesses.
- Lateral or posterior induration suggests deep postanal or ischiorectal extension.

### Differential diagnoses

The following do not communicate with the anal canal:

- Perianal abscess
- Urethroperineal fistulas
- Abscesses-Ischiorectal abscess, Submucous or high muscular abscess, Pelvirectal abscess (rare)
- Crohn's disease
- Carcinoma
- Retrorectal tumors
- Hidradenitis suppurativa
- Infected inclusion cysts
- Pilonidal disease
- Bartholin gland abscess in females

### The Goodsall Rule

Help to anticipate the anatomy of fistula-in-ano.

The rule states that fistulae with an external opening anterior to a plane passing transversely through the center of the anus will follow a straight radial course to the dentate line. Fistulae with their openings posterior to this line will follow a curved course to the posterior midline.

### Investigations

#### Lab Studies:

No specific laboratory studies are required; the normal preoperative studies are performed based on age and comorbidities.

#### Imaging Studies:

These are not performed for routine fistula evaluation. They can be helpful when the primary opening is difficult to identify or in the case of recurrent or multiple fistulae to identify secondary tracts or missed primary openings.

#### 1. Fistulography

This involves injection of contrast via the internal opening, which is followed by anteroposterior, lateral, and oblique x-ray images to outline the course of the fistula tract.

#### 2. Endoanal/endorectal ultrasound

To help define muscular anatomy differentiating intersphincteric from transsphincteric lesions.

#### 3. MRI

MRI is becoming the study of choice when evaluating complex fistulae

#### 4. CT scan

A CT scan is more helpful in the setting of perirectal inflammatory disease than in the setting of small fistulae because it is better for delineating fluid pockets that require drainage than for small fistulae

### Procedures

#### Proctosigmoidoscopy/colonoscopy

Rigid sigmoidoscopy can be performed at the initial evaluation to help rule out any associated disease process in the rectum  
-Complete fistulectomy creates larger wounds that take longer to heal and offers no recurrence advantage over fistulotomy.  
Perform a biopsy on any firm, suggestive tissue

### MANAGEMENT

#### Medical

Broad spectrum antibiotics

#### Surgery

##### Fistulotomy

-The laying-open technique (fistulotomy) is useful for 85-95% of primary fistulae (ie, submucosal, intersphincteric, low transsphincteric).

-A probe is passed into the tract through the external and internal openings.

-The overlying skin, subcutaneous tissue, and internal sphincter muscle are divided with a knife or electrocautery, thereby opening the entire fibrous tract.

-If the fistula tract courses higher into the sphincter mechanism, seton placement should be performed.

##### Fistulectomy

-As above with Curettage performed to remove all granulation tissue in the tract base.

#### Seton placement

A Seton can be placed alone, combined with fistulotomy, or in a staged fashion. This technique indicated in:

1. **Complex fistulae** -high transsphincteric, suprasphincteric, extrasphincteric, multiple fistulae

2. **Recurrent fistulae** after previous fistulotomy

3. **Anterior fistulae** in female patients

4. **Poor preoperative sphincter pressures**

5. Patients with **Crohn disease** or patients who are immunosuppressed

Setons have 2 purposes beyond giving a visual identification of the amount of sphincter muscle involved.

(1) drain and promote fibrosis

(2) Cut through the fistula.

Setons can be made from large silk suture, silastic vessel markers, or rubber bands that are threaded through the fistula tract.

#### Procedure

-Pass the seton through the fistula tract around the deep external sphincter after opening the skin, subcutaneous tissue, internal sphincter muscle, and subcutaneous external sphincter muscle.

-The seton is tightened down and secured with a separate silk tie.

-With time, fibrosis occurs above the seton as it gradually cuts through the sphincter muscles and essentially exteriorizes the tract.

-The seton is tightened on subsequent office visits until it is pulled through over 6-8 weeks.

#### **In complex multiple fistula**

-Colostomy may be fashioned

-Posterior Sagittal anorectoplasty done for multiple fistulectomies

#### **Preoperative details:**

-Rectal irrigation with enemas should be performed on the morning of the operation.

-Administer preoperative antibiotics.

-Prone jackknife position with buttocks apart is the most advantageous position

#### **Post-operative management**

1. Sitz baths, analgesics, and stool bulking agents (eg, bran, psyllium products).

2. Internal wound should not close prematurely, causing a recurrent fistula.

Digital examination findings can help distinguish early fibrosis.

3. Wound healing usually occurs within 6 weeks

#### **COMPLICATIONS**

##### **Early postoperative**

- Urinary retention

- Bleeding
- Fecal impaction
- Thrombosed hemorrhoids

##### **Delayed postoperative**

- Recurrence
- Incontinence (stool)
- Anal stenosis: The healing process causes fibrosis of the anal canal. Bulking agents for stool help prevent narrowing.
- Delayed wound healing: Complete healing occurs by 12 weeks unless an underlying disease process is present (ie, recurrence, Crohn disease)

# GASTRIC CARCINOMA

## Predisposing factors

- 1.H.pylori infection
- 2.Gastric ulcers
- 3.Chronic gastritis-atrophic or pernicious anemia
- 4.Gastric adenomas
- 5.Cigarette smoking and alcohol consumption
- 6.Nitrosamines in the preservation of foods
- 8.Partial gastrectomy-bilous reflux
- 9.Barrets esophagus
- 10.Radiation therapy
- 11.Genetic Factors

## Clinical presentation and management

### History

Most gastric cancers present at an advanced stage. The presentations equally non-specific -5A's

(Asthenia, abdominal pain, Anorexia, Anaemia, Achlorhydria)

- 1.Weight loss (asthenia) most common symptom
2. Abdominal pain .This may be epigastric, substernal, or back. Abdominal pain may mimic that of benign peptic ulcer disease, with relief of pain obtained by ingesting antacids, H<sub>2</sub>-blockers, and food. In other patients, pain is worse after eating
3. Anorexia and vomiting are present, especially if distal tumors cause pyloric obstruction.

There is also associated dyspepsia and early satiety.

4. Constipation- Because of reduced dietary intake, this is common.
5. Both acute and chronic upper gastrointestinal bleeding may occur, with hematemesis and melena, though frank hemorrhage occurs infrequently, usually in less than 10% of patients.
6. Anemia- Weakness and fatigue related to anemia and also due to weight loss due to decreased dietary intake. Worsening angina pectoris and dyspnea may be related to progressive anemia.
7. Dysphagia is an important symptom of adenocarcinoma of the fundus of the stomach, which involves the cardioesophageal junction.

### Symptoms suggestive of metastasis include:

- Jaundice may be present secondary to liver metastasis or extension of the cancer into the porta hepatis.
- Large bowel involvement by metastasis spreading through the gastrocolic ligament may be mistaken for primary colonic cancer and may cause large intestinal obstruction.
- Bone pain or neurologic symptoms of cord compression signal metastatic disease.

### Predisposing factors

- Alcohol intake
- Cigarette smoking
- History of treatment for PUD-gastric ulcer and H. pylori
- History of GIT cancer
- Familial history
- Diet
- Radiation

### Physical examination

May not reveal abnormality except in advanced disease.

- 1.Anemia
- 2.Jaundice may be present if liver metastases are extensive or positioned at the porta hepatis

3. Recent weight loss with temporal wasting and loss of muscle mass. May also be dehydrated
4. Lymph node enlargement, particularly in the left supraclavicular area (or Virchow's signal node) or the left side of the neck. Termed Troisier's sign
  - Umbilical nodules indicate the presence of metastatic disease.(sister Mary Joseph's sign)
5. Palpable abdominal mass if the cancer is large or hepatic enlargement related to metastatic disease, gastric dilatation, and a succussion splash.
6. Malignant ascites can occur with metastatic gastric cancer.
- 7-**Rectal examination** may reveal a rectal "shelf" (Blumer's shelf). Metastases are thought to spread by gravity to the true pelvis and form the shelf noted on rectal examination.
  - Rarely, acanthosis nigricans may be found on examination of the patient's skin, particularly in the axillae or other body folds.
  - ovarian metastases (Krukenberg tumor)
  - Superficial thrombophlebitis on the legs (Trousseau's sign), It is also associated with pancreatic cancer.

## Investigations

### Imaging

#### 1.Gastroscopy, biopsy, and cytology-Gold standard

-Upper gastrointestinal endoscopy provides the best overall method of diagnosing gastric cancer.

-Both biopsy and brush cytologic evaluation should be done, because they are complementary.

In general, the more biopsies obtained, the higher the diagnostic yield. At least four to six biopsy specimens should be obtained from each separate lesion for histology.

#### 2.Barium meal-double contrast(with Air)

In absence of an upper GI endoscopy, this can be done. Some of the abnormalities noted include

- Lack of distensibility of the stomach
- An ulcerated mass or mass effect surrounding an ulcer
- A mass in any portion of the stomach
- Enlarged gastric folds
- Obstructing lesions at the cardioesophageal junction or at the pylorus.

#### 3.Endoscopic ultrasonography

Combines endoscopy and ultrasonography to produce detailed images of the stomach wall allowing an accurate assessment of depth of tumor invasion.

It is more accurate in assessing depth of cancer invasion and also appears to be more accurate in determining cancer spread to regional lymph nodes.

#### 4. CT-scan

-Used to evaluate gastric wall thickness, direct extension of tumor into adjacent organs, regional and retroperitoneal lymph node enlargement, ascites, and liver metastases thus stage the tumour.

-CT has been shown to predict with reasonable accuracy which patients can undergo curative surgery and which tumors are unresectable.

#### 5.Abdominal ultrasonography

Seeding of peritoneum and in females the krunkenburg tumors can be visualized

## **6.Laparoscopy**

- Stage of the tumour
- Assess Lymph node involvement
- Biopsy for diagnosis
- Peritoneal washout for cytology
- Check on the operability of the tumour

**CXR**-involvement

### **Laboratory**

1. **FHG** –evaluation of the anemia-microcytic hypochromic picture due to chronic blood loss but may also be megaloblastic in pernicious anaemia.

2. **Liver function tests** in jaundiced patients

Evaluation of the bilirubin, alkaline phosphatase, and 5'-nucleotidase may indicate metastatic liver disease.

3. **Carcinoembryonic antigen (CEA)**

Concentration may be elevated in patients with gastric cancer, usually with advanced disease. If CEA level is elevated preoperatively and becomes normal after surgery, it can be used in follow-up evaluations like in colonic cancer.

4. **Stool test for occult blood** is frequently positive, and melena occurs occasionally.

### **Staging of gastric cancer TNM**

#### **TX,TO,TIS**

T1 tumors invade to the submucosa

T2 invade the muscularis propria

T3 penetrate the serosa/adventitia

T4 invade adjacent structures.

#### **Nodes**

N1 if there are metastases to peri gastric nodes

N2 if regional lymph nodes are involved

N3-IVC and Aorta nodes

MX-Metastasis can't be assessed.

M1-Presence of metastasis

## **MANAGEMENT**

### **Surgery**

#### **Gastrectomy**

-Early disease-mucosal

-Mucosal resection at endoscopy use of lugols iodine plus wide excision confined to <2cm

-Enhanced by cold knife which is laser tipped knife for resecting tumours.

#### **Invasive tumour confined to stomach.**

##### **Issues are:**

a)Extent of gastric resection

b)Extent of lymph node resection.

##### **Extent of gastric resection**

Adequate gastrectomy implies surgical margins in the stomach free of tumour.

##### **Partial Gastrectomy**

-Billroth surgery with Gastrojejunostomy. This is done when tumour is distal

-Adequate resection margins in the stomach are defined as an 8- to 10-cm proximal and distal clearance in the unstretched stomach.

-Failure to resect the stomach widely with microscopic clear margins is highly detrimental to survival. If the resection margin is not confirmed to be free of microscopic disease

##### **Total gastrectomy**

-Proximal tumours-cardia and fundal tumours necessitates total gastrectomy.

-This carries a lower risk of recurrence or a second gastric cancer in long-term survivors.

-Total gastrectomy with a Roux-en-Y esophago-jejunostomy to prevent alkaline reflux.

-The preferred method of reconstruction after total gastrectomy is as a Roux-en-Y with a 60-cm Roux to prevent bile reflux.

-Gastric cancer at the cardia the tumour may infiltrate the lower oesophagus, and a 10-cm oesophageal clearance is advised to be certain of clear resection margins.

-Thus surgery involves principles of gastric as well as oesophageal surgery, and in certain respects it should be regarded as a separate entity.

##### **Extent of lymphadenectomy**

R0 gastrectomy does not remove any lymph node group,

R1 gastrectomy removes those nodes in group I (N1), which are predominantly perigastric lymph nodes, but leaves a large portion of the greater omentum. Nodes along the lesser curvature, greater curvature, sub-pyloric nodes,

R2 gastrectomy carries the same criteria for adequate gastric removal but includes lymphadenectomy to remove Group II (N2) nodes en bloc with stomach.

In general the entire greater omentum is removed, with the superior leaf of the transverse mesocolon, pancreatic capsule, and lesser omentum.

Lymph node dissection starts by removing the nodes along the gastroduodenal artery to its origin at the hepatic and is continued laterally to the porta hepatitis along the common hepatic artery.

The nodes are cleared medially along the common hepatic artery to the coeliac axis which is cleared and continued along the splenic artery to the hilum of the spleen. Supra pancreatic and retropancreatic nodes and nodes along porto-hepatis

R3 gastrectomy attempts to remove nodes in Group III (N3) and involves pancreatic and splenic resection. Nodes involved include those along IVC and Aorta

##### **Palliative surgery**

Palliative operation to relieve gastric outlet obstruction for unresectable tumours.

1. Billroth II -Resection of the distal stomach, closing the transected duodenum and stomach and restoring continuity by a gastrojejunostomy to the posterior wall of the stomach-

2. Gastrostomy

3. Stents in gastro esophageal junction

Non-operative palliation, including laser therapy and intubation for dysphagia, and interstitial laser therapy for bleeding gastric cancers.

##### **Radiotherapy**



Gastric adenocarcinoma has generally been regarded as radioresistant and, although it is less sensitive than squamous cell carcinoma, useful response and tumour shrinkage has been achieved in patients given palliative radiotherapy for malignant dysphagia.

The major limitation to radiotherapy has been the problem of achieving a dose that will spare adjacent normal tissue, including the liver and the small intestine

#### **Chemotherapy**

-Gastrointestinal cancers are generally unresponsive to chemotherapy, but gastric cancers appear to be more sensitive than most and in particular respond better than colorectal cancer.

-Despite evidence to suggest that combined chemotherapy is better, most studies have been performed with single agents.

Mitomycin C, doxorubicin, 5-fluorouracil, and the nitrosoureas will produce tumour shrinkage in up to 30 per cent of patients with advanced disease.

-The combination of 5-fluorouracil, doxorubicin, and mitomycin C at present represents the most effective regimen for advanced gastric cancer

#### **Follow up**

1. CEA assay to detect recurrence of tumour
2. Follow endoscopies if mucosal resection at endoscopy.

#### **Prevention of Gastric cancer**

1. Triple therapy to eradicate H.pylori
2. Good nutrition-Vitamins C,E, A intake.
3. Endoscopy in strong family history or patients post-gastrectomy.

# HEAD INJURY

**Definition:** Trauma to the head causing neurological manifestations.

**Etiology:** most common causes include motor vehicle accidents (eg, collisions between vehicles, pedestrians struck by motor vehicles, bicycle accidents), falls, assaults, sports-related injuries, and penetrating trauma.

The male-to-female ratio for TBI is nearly 2:1, and TBI is much more common in persons younger than 35 years.

## CLASSIFICATION OF HEAD INJURIES.

Head injuries can be classified according to.

1. Severity of the injury.
2. Anatomical classification
3. Pathological classification-penetrating or blunt injury
4. Primary and secondary brain injury.

### A. SEVERITY OF INJURY

Severity is assessed by the following methods notably:  
Glasgow Coma Scale.

Score below 8 is considered to represent severe head injury while 8 to 12 is assessed as moderate head injury. 13 to 15 is mild head injury.

### B. ANATOMICAL CLASSIFICATION

Injury can involve one or more of the following.

#### 1 SCALP

This consists of five layers; the first three layers are bound together and moved as a unit. The layers are:

**S** -Skin

**C** -Connective tissue: Dense

This is a fibro-fatty layer. The fibrous septa unite the skin to the underlying aponeurosis of the fronto-occipitalis muscle. The scalp vessels lie within this layer.

**A**- Aponeurosis of Galea

This is a thin fibrous sheath attached to the bellies of the Fronto-occipitalis muscle. Deep to it is the sub aponeurotic space.

**L**- Loose connective(areolar) layer

-Occupying the sub aponeurotic space. This layer contains emissary veins. Is large potential space and can contain large amount of bleeds or pus following skull injury.

**P** Pericranium

Which is periosteum of the skull bone.

The scalp is very vascular and laceration can cause severe loss of blood. The vessels within the scalp do not constrict when injured because the wall is adherent to the surrounding fibre fatty tissue in the dense connective tissue layer. Bleeding can be controlled by applying pressure or suturing the scalp.

### B. SKULL INJURIES

Skull fractures are simple or compound. Simple if there is no communication between the fracture and the atmosphere, while the fracture is compound if there is such communication. Skull fractures are classified as follows:

#### Simple/Closed Fractures

##### 1. Linear or fissure fracture.

This involves the skull vault and can extend down to the base of the skull. The linear fracture indicates that there has been

significant injuries to the head. Management is usually hospital admission and close observation for any complications.

2. Comminuted fracture

3. Cracked pot fracture

4. Ping-pong fracture

This is a green stick fracture of the skull, it occurs in the first few months of life when the skull bones are still soft. It is caused after falls when the skull hit the edge of a blunt structure as the edge of a table. It shows as a deformity of the skull, it looks as a shallow trench on the surface of the skull. If large and showing as a significant deformity it can be easily treated by elevating the depressed bone fragment

5. Depressed fracture

Skull fragment pushed below the level of the skull. Significant depression is depression twice the thickness of the diploe. This can result in dural tear and laceration of the underlying brain. Skull fragments should be replaced to avoid the creation of skull defect and need for cranioplasty. The underlying dura should be repaired and any bleeding controlled. This is important in children below the age of 4 to avoid the complication of growing skull fracture.

Bone fragments should be replaced even in compound fractures and wound debrided.

#### **Compound Fracture/open fracture e.g. Fracture Skull Base.**

This starts as vault linear fracture and extends into the skull base. It follows the weak points in the skull as the Cribriform plate, foramina and internal ear. Nerve injury can result involving the olfactory nerve, facial nerve. etc

If the fracture extends into the Cribriform plate and is associated with dural tear CSF leak can result and this is called rhinorrhea. If the fracture extends into the internal ear and the middle ear we can get otorrhea, which is CSF leak from the ear.

### C. BRAIN INJURY

Injury to the brain is either localised or diffuse and can be either primary or secondary.

#### PRIMARY BRAIN INJURY

Injury directly due to the insult and occurring at the time of the injury

-Brain concussion-temporary physiological disruption of brain function.

-Brain contusion-Small petechial and hemorrhages

-Brain laceration-obvious deformity

#### Localised injury

-Deformation of the brain at the point of impact.

-Associated with dural laceration and underlying brain contusion or laceration. Usually there is a localized surrounding oedema around the site of the impact.

#### Diffuse injury

This carries a greater risk of damage to the brain and the mechanisms involved in this injury are:

#### Acceleration/deceleration injury.

In acceleration injury the head is put into motion from a stand still position, as a result of which the different layers of the brain travels at different velocities with shearing effects and rotation of the brain within the skull.

-The shearing stresses between different layers of the brain result in petechial haemorrhages as well as diffuse axonal injury involving the white matter and brain stem. In deceleration injury

the head is brought to a stand still from a moving position as in falls. The same mechanism applies.

The extent of the diffuse injury and the axonal damage determines the outcome.

-The more severe the injury is, more brain damage occurs with more axonal injury. This would be associated with higher morbidity and mortality.

#### Penetrating injury

-High velocity or slow velocity injury as a result of penetration with sharp objects.

-The base of the skull is thin bone and could easily be penetrated especially in children.

-This results in skull base fracture and damage to the brain overlying that area.

#### Compression injury

The head is compressed between two solid objects as in motor vehicle accidents. The result is multiple linear fractures particularly in the weak areas of the skull base resulting in multiple cranial nerve injuries.

### SECONDARY BRAIN INJURY

This results as consequence to the primary brain injury and this includes :

#### A. INTRACRANIAL HAEMATOMAS. Include

##### **1 Epidural haematoma**

-Epidural hematomas are located between the inner table of the skull and the dura. Usually due to laceration of middle meningeal artery.

-They are typically biconvex (lenticular) in shape because their outer border follows the inner table of the skull and their inner border is limited by locations at which the dura is firmly adherent to the skull.

-Up to 10% of epidural hematomas may be venous in origin.

- In about 60 or 70% of cases there is an associated skull fracture.

-Usually located in the temporal area. Occasionally it is in the frontal, parietal or posterior fossa region.

-As it is an arterial bleed the clot can get to a significant size within a short period of time with rapid rise in the intracranial pressure. If untreated there is a high rate of morbidity and mortality but effective and early treatment can result in complete recovery. In these cases there is no diffuse brain injury and the injury is localised to the area where the fracture and the haematoma is. The aim of the management is to evacuate the clot as soon as possible and control the bleeding meningeal vessel. In most cases this is an acute condition, however occasionally the bleeding is a result of venous tear and the blood clot develops slowly. This is particularly the case in the frontal and occipital regions. The clot is evacuated through a craniotomy but in acute situations where there are no facilities for major neurosurgical procedure a burr hole should be done to release the intracranial clot and reduce the intracranial pressure. Only 1/3 pts present with Classic "lucid interval," normal brain function after the insult followed by focal neurologic deficits later.

##### **2 Subdural hematoma**

This is the result of tear in one of the bridging veins between the surface of the cortex and the dural sinuses. The blood collects gradually and slowly as the bleed is of venous origin. Their outer edge is convex, while their inner border is usually irregularly concave. Subdural hematomas are not limited by the intracranial suture lines; this is an important feature that aids in their differentiation from epidural hematomas.

#### Acute subdural haematomas

Are rare in children. Subdural hematomas are more common in alcoholics and patients > 50 yr, in whom the head injury may have been relatively trivial, even forgotten. As the brain atrophies over time, the bridging veins become more exposed and, as a result, are more easily injured. These haematomas are usually a part of severe and diffuse brain injury. It causes significant morbidity and mortality because of associated diffuse brain injury. Causes increased ICP with transtentorial or tonsillar herniation, widening pulse pressure, pupils in mid position or dilated and fixed, spastic hemiplegia with hyperreflexia, quadriparesis, decorticate rigidity, or decerebrate rigidity (due to progressive rostral-caudal neurologic deterioration).

Chronic subdural hematomas may not produce symptoms until several weeks after trauma. Although early diagnosis (2 to 4 wk after trauma) may be suggested by delayed neurologic deterioration, later diagnosis can be overlooked because of the time lapse between trauma and the onset of symptoms and signs. Subdural hematomas are more common in alcoholics and patients > 50 yr. Increasing daily headache, fluctuating drowsiness or confusion (which may mimic early dementia), and mild-to-moderate hemiparesis are typical. In infants, chronic subdural hematomas can cause head circumference to enlarge, suggesting hydrocephalus. MRI scans are diagnostic; CT scans are less consistently

#### **3. Subarachnoid hemorrhage**

The subarachnoid bleeding itself does not usually cause neurologic damage, but hydrocephalus and cerebral vasospasm, which are delayed complications typically seen days to weeks following subarachnoid hemorrhage, can lead to neurologic impairment. Subarachnoid hemorrhages that occur because of trauma are typically located over gyri on the convexity of the brain. The subarachnoid hemorrhages that result from a ruptured cerebral aneurysm are usually located in the subarachnoid cisterns at the base of the brain.

#### 4. Intraventricular haemorrhage

#### B. BRAIN OEDEMA

Children are prone to develop significant oedema and this does not always occur as a result of severe head injury.

Brain edema could be localised around an area of brain damage or diffuse as seen in diffuse axonal brain injury.

Intracranial Pressure - Normal ~ 0-10mmHg (5-18 cmH2O)

Monro-Kellie Doctrine - "The total volume of intracranial contents must remain constant" The cranial cavity normally contains a brain weighing approximately 1400gm, 75mL of blood, and 75mL of CSF. Addition of a mass e.g. a haematoma results in the squeezing out of an equal volume of CSF & venous blood to maintain the ICP. However, when this compensatory mechanism is exhausted, there is an exponential increase in ICP for even a small additional increase in the volume of the haematoma

Cerebral Perfusion Pressure =  $MAP - ICP = \geq 70\text{mmHg}$

\*\* Mean Arterial Pressure (MAP) =  $DBP + \frac{1}{3} \text{Pulse pressure}$

\*\* Pulse pressure =  $SBP - DBP = \sim 50\text{mmHg} (< \sim \frac{1}{2} \text{SBP})$

Cerebral Blood Flow -  $\sim 50\text{mL}/100\text{gm of brain}/\text{minute}$ ;

$< 5\text{mL}/100\text{gm of brain}/\text{minute}$  - there is cell death or irreversible damage.

Auto regulation maintains CPP between 50-160mmHg. <50mmHg, the CBF declines steeply, & >160mmHg, there is passive dilatation of the cerebral vessels & an increase in CBF

### **C. INFECTION**

This can occur in compound skull fractures and skull base fractures. Rhinorrhea and otorrhea prophylactic 3<sup>rd</sup> generation Cephalosporin

### **D. HYDROCEPHALUS**

Hydrocephalus can be caused by blockage of the ventricular system by blood clot in cases of intra-ventricular haemorrhage or due to cicatrization and fibrosis of sub-arachnoid space or the arachnoid villi along the sagittal sinus from deposition of blood products.

### **E. CSF LEAK**

This is a result of skull fractures crossing the nasal sinuses. In case of ethmoid sinuses -rhinorrhea and fracture internal ear and the middle ear with rupture of tympanic membrane cause otorrhea. Often these leaks are temporary and spontaneous closure within one week occurs. If it persists then surgical intervention should be considered.

### **DIAGNOSIS**

#### **History**

Detail description of the event leading to injury to the head either from the relatives or from the patient.

- Aetiology-RTA, Assault, Fall, Missiles, Explosive. Detail of exact mechanism leading to head injury.
- Site of trauma, any wounds
- Any history of bleeding
- Signs of shock-dizziness, confusion, sweating
- Any history of loss of consciousness
- History of headache, vomiting, Blurring of vision-increased ICP
- History of otorrhea or rhinorrhea
- Any lateralizing signs-loss of power in the limbs or loss of sensation.
- History of alcohol or other drug consumption raise the risk of intracranial bleeding and cloud the mental status assessment.
- The history of previous head injuries-Premorbid illness -DM, HTN, Epilepsy

#### **Physical examination**

Suspect significant head trauma in any traumatized patient with cranial hematomas or lacerations or with altered sensorium with or without focal neurologic findings.

Obtain complete vital signs, including core temperature.

The GCS is the mainstay for rapid neurologic assessment in acute head injury. Both initial and worst GCS post resuscitation scores have correlated significantly with 1-year outcomes following severe head injury

A. Examine the scalp carefully for evidence of trauma. Inspect the head, and palpate carefully for scalp lacerations, subgaleal hematomas, ecchymoses, and deformity. Inspect neck, chest, abdomen, back, and extremities-tenderness, pain, and deformity are often signs of associated injuries that require specific early treatment

B. Any clear fluid in the ear canal or coming from the nares must be assumed to be cerebrospinal fluid. If the fluid is cerebrospinal fluid, a dipstick glucose test will usually be positive, since

cerebrospinal fluid contains glucose and mucus does not. False-negative results may occur in patients with hypoglycemia. C. Blood behind the eardrum, a post auricular hematoma (Battle's sign), suggest basilar skull fracture or bilateral circum orbital hematomas ("raccoon eyes")

### **Neurologic Examination**

#### **CN Exam-Systemic exam**

- Anosmia -shearing of the olfactory nerves at the cribriform plate. If accompanied by rhinorrhea, risk of ascending meningitis.
- Abnormal postresuscitation pupillary reactivity correlates with a poor 1-year outcome. A unilaterally dilated pupil with or without ipsilateral cranial nerve (CN) III paralysis may indicate impending herniation.
- CN VI palsies may indicate raised intracranial pressure. --CN VII palsy, particularly in association with decreased hearing, may indicate a fracture of the temporal bone.
- Dysphagia raises the risk of both aspiration and inadequate nutrition.
- Focal motor findings may be manifestations of a localized contusion or, more ominously, an early herniation syndrome.
- Flexor or extensor posturing obviously implies extensive intracranial pathology or raised intracranial pressure. In the chronic phase, motoric manifestations typically include spasticity or, more unusually, akinesia and rigidity
- Dilated or constricted pupils-Pupillary dilatation may occur when transtentorial compression occurs and parasympathetic tone of the pupil is totally lost. Conversely, pinpoint pupils after head injury may indicate loss of sympathetic tone resulting from a lesion in the brain stem caudal to the oculomotor nuclei (eg, pontine hemorrhage).
- 2. Deep reflexes
- 3. Sensory exam
- 4. Muscle tone

### **INVESTIGATIONS IN HEAD INJURIES**

#### **1 Plain skull x-ray**

This is useful in screening head injuries. It is indicated if there is a loss of consciousness or localised contusion or swelling over the head. Plain skull x-ray shows skull fractures and intracranial air. Patients with skull fractures should be admitted to hospital for observation.

AP, lateral and Town views-OccipitoFrontal

#### **2 CT scan**

##### **Indications**

- a. All moderate to Severe head injury GCS below 12
- b. History of loss of consciousness or decreasing level of consciousness
- d. Post-traumatic seizure
- c. Lateralizing signs-weakness of limb or un reactive pupil
- f. Type of injury-Penetrating injury Or Skull fractures
- h. Otorrhea and rhinorrhea

#### **3. MRI**

This examination is useful to show long term effects of head injury. Depending on the availability it also could be used in investigating acute cases.

#### **4. Beta transferrin**

This is a test for an enzyme which is only found in CSF. It is the optimum test for CSF leak.

### Other Important Baseline Tests

- 1.PCV
- 2.Urea and electrolytes
- 3.Arterial blood gases
- 4.Blood alcohol level
- 5.Random blood glucose

### MANAGEMENT

#### **INITIAL MANAGEMENT-Primary Survey**

1<sup>st</sup> is A,B,C,D of resuscitation plus vital signs

#### **1. Airway and cervical spine.**

Maintain cervical spine immobilization in all unconscious or symptomatic (neck pain or tenderness) patients.

- i)-Inspect mouth remove debris by sweeping through
- ii)Chin lift/jaw thrust (tongue is attached to the jaw) and always airway in tongue falling back

To perform a *chin lift*, place two fingers under the mandible and gently lift upward to bring the chin anterior. During this manoeuvre, be careful not to hyperextend the neck. Care should be given to neck stabilization, if appropriate.

The *jaw thrust* is performed by manually elevating the angles of the mandible to obtain the same effect.

- iii) Guedel airway/nasopharyngeal airway to secure airway. Insert the oral airway into the mouth behind the tongue; it is usually inserted upside down until the palate is encountered and is then rotated 180 degrees.

iv) Intubations: keep the neck immobilized in neutral position. Intubate all unconscious patients (GCS < 9) to secure airway. Use sedation and short acting neuromuscular blockade if necessary. If not possible

- v)Tracheostomy
- vii)cricothyrotomy

#### **2. Breathing: Oxygenation and ventilation.**

LOOK OUT for the five major problems that may impair breathing -ie

6. Tension pneumothorax-put through a needle
7. Massive pneumothorax-chest tubes insertion
8. Sucking wounds-strap the open wound
9. Flail chest-positive pressure ventilation
10. Cardiac tamponade
6. Airway obstruction

#### 1 Inspect (LOOK)

Inspection of respiratory rate is essential. Are any of the following present?

- Cyanosis
- Any signs of respiratory distress- Use of accessory muscles, flaring of alae nasae, subcostal recession
- Inspect Chest- movements, Penetrating injury, Presence of flail chest, Sucking chest wounds

#### 2 Palpate (FEEL)

- Tracheal shift
- Broken ribs
- Subcutaneous emphysema.
- Chest expansion

#### 3.Percussion

For dullness is useful for diagnosis of haemothorax and pneumothorax.

#### 4 Auscultate (LISTEN)

-Pneumothorax (decreased breath sounds on site of injury)

-Detection of abnormal sounds in the chest.

If available, maintain the patient on oxygen until complete stabilization is achieved

-If a you suspect a tension pneumothorax, introduce a large-bore needle into the pleural cavity through the second intercostal space, mid clavicular line, to decompress the tension and allow time for the placement of an intercostal tube

- If intubation in one or two attempts is not possible, a cricothyroidotomy should be considered a priority

#### **3. Circulation and arrest of bleeding.**

“Shock” is defined as inadequate organ perfusion and tissue oxygenation. In the trauma patient, it is most often due to haemorrhage and hypovolaemia.

The diagnosis of shock is based on clinical findings:

- 1) Hypotension
- 2) Hypothermia
- 3) Tachycardia
- 4) Tachypnoea
- 5) Cool extremities
- 6) Decreased capillary refill
- 7) Pallor
- 8) Decreased urine production

#### Haemorrhagic (hypovolaemic)

Shock is due to acute loss of blood or fluids. The amount of blood loss after trauma is often poorly assessed and in blunt trauma is usually underestimated. Remember:

-Large volumes of blood may be hidden in the abdominal and pleural cavity

-Femoral shaft fracture may lose up to 2 litres of blood

-Pelvic fracture often loses in excess of 2 litres of blood.

#### Cardiogenic shock

Cardiogenic shock is due to inadequate heart function. This may result from

-Myocardial contusion (bruising)

-Cardiac tamponade

-Tension pneumothorax (preventing blood returning to heart)-

- Penetrating wound of the heart

-Myocardial infarction.

Assessment of the jugular venous pressure is essential in these circumstances and an ECG should be recorded, if available.

#### Neurogenic shock

Is due to the loss of sympathetic tone, usually resulting from spinal cord injury. The classical presentation is hypotension without reflex tachycardia or skin vasoconstriction.

#### Septic shock

Is rare in the early phase of trauma, but is a common cause of late death (via multi-organ failure) in the weeks following injury. It is most commonly seen in penetrating abdominal injury and burns patients.

#### **Resuscitation**

-First priority is to stop any obvious bleeding by Sub fascial gauze pack placement and Manual compression on the proximal artery. Carefully applied compressive dressing of the entire injured limb can be done.Then

-Vascular access 2 large bore size 16 on the 2-basilic veins

Fluids: infuse 0.9% NaCl initially 2L to run as fast as possible through 2 large bore IV lines in the antecubital fossa then reassess

#### Resuscitation action

-Insert an intercostal drainage tube as a matter of priority, and before chest X-ray if respiratory distress exists, to drain the chest pleura of air and blood

-When indications for intubation exist but the trachea cannot be intubated, consider using a laryngeal mask airway or direct access via a cricothyroidotomy.

-Resuscitate to goal of mean arterial pressure (MAP)>90 mmHg to maintain a presumptive cerebral perfusion pressure (CPP)>70-80mmHg

-Urinary catheter insertion and monitor the input and output chart at least 30-50 ml/hour or 0.5/kg/hour of urine flow

-Asses by vital signs, pallor, sweating, anxiety ,skin warmth clammy, input and output

-Blood transfusion must be considered when the patient has persistent haemodynamic instability despite fluid (colloid/crystalloid) infusion.

If type specific or cross matched blood is not available, use group O negative packed red blood cells. Transfusion should, however, be seriously considered if the haemoglobin level is less than 7 g/dl and the patient is still bleeding.

#### 4. Neurological dysfunction

Establish preliminary level of consciousness by AVPU

**A** –Awake, **V** -Verbal response, **P**- Painful response

**U** –Unresponsive and any focal neurologic deficits.

#### 5. Exposure and environmental modification

Cover patient in case of shock and shivering.

### SECONDARY SURVEY

#### Head to toe exam with emphasis on the evaluation of head injury

##### HEAD EXAMINATION

-Scalp and ocular abnormalities-Raccoon eye and battle signs, wounds ,bleeding around the head

-External ear and tympanic membrane

-Periorbital soft tissue injuries

##### NEUROLOGICAL EXAMINATION

1. Glasgow coma scale-Is the Gold standard for the evaluation of the severity of head injury.

Used for monitoring the improvement or deterioration of the head injury.

a) Minimal head injury-GCS-15

b) Mild head injury GCS-14-15 history of loss of consciousness for less than 5 minutes.

c) Moderate head injury 9-13 with history of loss of consciousness more than 5 minutes

d) Severe head injury GSC 5-8

e) critical head injury GSC 3-5

2. All cranial Nerve examination

3. Peripheral sensory and motor examination

##### NECK EXAMINATION

\_ Penetrating wounds and bleeds

\_ Subcutaneous emphysema

\_ Tracheal deviation

\_ Neck vein appearance.

##### CHEST EXAMINATION

\_ Clavicles and all ribs

-Breath sounds and heart tones

-ECG monitoring (if available).

##### ABDOMINAL EXAMINATION

-Penetrating abdominal wound requiring surgical exploration

-Blunt trauma: insert a nasogastric tube (not in the presence of facial trauma)

-Rectal examination

-Insert urinary catheter (check for meatal blood before insertion)

##### PELVIS AND LIMBS

-Fractures

-Peripheral pulses

-Cuts, bruises and other minor injuries.

##### X-RAYS (if possible and where indicated)

-Chest, C-spine and pelvis X-rays may be needed during primary survey

NB-Cervical spine films (must see all 7 vertebrae)

-Pelvic and long bone X-rays

### INTRACRANIAL PRESSURE (ICP) and CEREBRAL PERFUSION PRESSURE (CPP) MONITORING

#### Signs /Symptoms of increased ICP

##### Symptoms

- 1) -Severe bursting headache
- 2) -Projectile vomiting
- 3) -Blurring of vision
- 4) -Convulsions/seizures
- 5) -Drowsiness

##### Signs

- 1) -Vital signs-increased BP and decreased pulse rate (cushings reflex)
- 2) -Anisocoria-unequal pupils
- 3) -Papiloedema on fundoscopy
- 4) -Nerve palsy eg 3<sup>rd</sup> and 6<sup>th</sup> cranial nerves
- 5) -Tense fontanel.
- 6) -Irregular breathing/slowed fats

Parameters: Normal ICP = 0-10 mmHg. Treatment threshold > 20-25 mmHg. Goal CPP = 60-70 mmHg.

#### 1. Elevation of head

To promote venous drainage from the head.

#### 2. Ventilation o2 by mask

Prevention of hypoxia and hypercapnia which increase ICP

#### 3. Mannitol.

i. Effective doses range from **0.25-1 gram/kg**, given by intermittent bolus infusion every 4-6 hrs.

ii. Euvolemia must be maintained.

iii. Monitor osmolality. Do not exceed 320mOsm/kg

#### 4. Hyperventilation

To blow out the co2 and reduce hypercapnia and maintain pCO2 of 30-35 mmHg

#### 5. Anticonvulsant therapy

Phenytoin is used to prevent or control seizure activity that increases cerebral blood flow and subsequently intracranial pressure. Anticonvulsant medications should be used for 1 week following injury and then discontinued if seizures are not recurrent.

#### 6. Nimodipine

The calcium channel blocker reduces death and severe disability when instituted acutely in patients with head injuries.

7. **Relieve and prevent pyrexia** which increases intracranial pressure. eg NSAIDS Provision of analgesia has similar effects

8. **Sedatives**

High dose diazepam may be considered for hemodynamically stable, salvageable, severe head injury patients with intracranial hypertension refractory to maximal medical and surgical therapy. Other narcotics may depress respiration

9. **Steroids** Dexamethasone use is controversial in head injury

**Early post-traumatic seizure prophylaxis (7 days):**

1. Phenytoin(Dilantin) is indicated for:

- a. Glasgow coma scale score < 10.
- b. Cortical contusion.
- c. Depressed skull fracture.
- d. Subdural hematoma.
- e. Epidural hematoma.
- f. Penetrating head wound.
- g. Seizure within 24 hrs. of injury.

2. Therapy should be instituted for 7 days.

**HEAD INJURY OBSERVATION CHART**

Monitoring the following in half, hourly or 2 hourly

1. **Continuous monitor of level of consciousness**

Best eye opening score  
Best verbal response score  
Best motor response

2. **Vital signs**

Pulse  
Temperature  
BP  
Respiratory rate

3. **Pupillary reflexes**

Reaction to light  
Size of the pupil

4. **Motor examination of limbs**

Spontaneous movement of all the limbs  
Paralysis

5. **Monitor danger signs**

-Severe headache  
-Vomiting  
-Convulsions/seizures.  
-Drainage of fluids ear or nose

**Presence of other injuries**

Chest  
Abdomen  
Neck  
Spine  
Arm or leg

**SCALP INJURIES**

**Scalp wound**

-Analgesia plus tetanus toxoid  
-Clean the wound  
-Debride  
-Stitch  
-Antibiotics

**Scalp wound plus fracture**

-Surgical toilet under GA  
-Clean

-Stitch

-Antibiotics

**Depressed Fracture**

Conservatively managed

Surgical elevation if depression is twice the table width or clinically lateralizing sings.

**INTRACRANIAL HAEMATOMA**

**Extra-dural hematoma**

Any haematoma greater than 1.5 cm from the inner table should be evacuated. If less then manage conservatively.

Do craniotomy-burr hole and raise flap.

Arrest the bleed by dural hitch-tie dura to pericarnium.

**Sub dural hematoma**

Follow brain surface acute is hyperdense, Subacute are isodense and chronic is hypodense

Evacuate using burr hole .open dura with cruciate incision. 2 burr holes done. Flash with normal saline –with small catheter

**Nutritional support**

1. Enteral feeds should be instituted within 72 hours of injury.

2. Goals:

a. kcal: **CHO=50%, lipid=30 %,proteins 15-20%**

i. Nonparalyzed patient – replace 140% of estimated energy expenditure.(normal person at rest need about 3000kcal pr day)  
ii. Paralyzed patient – replace 100% of estimated energy expenditure.

NB. Protein: Use high protein formula. Provides 25% of kcal as protein.

3. Administration:

a. Start via NGT at initial rate of 10 ml/hr increasing 10 ml/hr every 4 hrs. Until goal is reached.

b. Hold for residual > 100 ml, or if abdominal injury present or surgery required.

4. Parenteral nutrition

a. Use only if enteral feeds contraindicated or not tolerated.

b. Use same caloric requirements.

c. Give at least 15% of total kcal as protein.

1g of CHO =**4 kcal**

1g of lipid=**9 kcal**

**OTHER GENERAL CARE UNCONSCIOUS PATIENTS**

1. Bladder care

2. Bowel care

3. Physiotherapy chest and limbs

4. Skin care

5. Analgesics

**1. Analgesics**

-Use analgesics appropriately and aggressively to maintain the patient's comfort if he or she has been lying on a hard backboard for an extended period.

Start of opiod analgesia initially then NSAIDS

**2. Urinary catheter-Condom catheter**

Use of condom catheters to avoid complications of prolonged urethral catheterization.

Monitor input output of fluids initially. Also avoid ulcers due to the urination on the bed.

### **3. Bowel care**

Manual evacuation by sweeping thro the rectum which cause irritation or the use warm saline enemas

### **4. Physiotherapy-both chest and limbs**

Prevention of contractures and maintenance of range of motion are important in all patients with spinal cord injury and should begin immediately following the injury.

Chest physiotherapy to avoid pneumostatic pneumonia

### **5. Skin care**

- -Pneumatic mattress
- -Ripple mattresses
- -Turning of patient every 2 hours
- -Adequate cleaning and drying of the patient.
- -Encourage mobility as soon as the patient is able to.

### **COMPLICATIONS OF HEAD INJURY**

1. CN palsies and Focal neurological signs

3. Infections

4. Hydrocephalus

5. Convulsive disorder/epilepsy

6. Psychiatric disorders

7. Cerebrospinal fluid fistulae, either in the form of rhinorrhea or otorrhea

8. Posttraumatic movement disorders Tremor, dystonia, parkinsonism, myoclonus, and hemiballism

9. Vascular injuries

Arterial injuries that occur following head trauma include arterial transactions, thromboembolic phenomena, posttraumatic aneurysms, dissections, and carotid-cavernous fistulae (CCF).

9. Post-concussional symptoms e.g. Transient LOC, Bradycardia, Hypertension

10. Cumulative brain damage ('Punch-drunk syndrome')

11. Neurological & neuropsychological deficits e.g. Parkinsonism, Dementia

12. Neuroendocrine & metabolic disturbances e.g. Diabetes insipidus.



# HEMORRHOIDS

## Definition

-Are vascular and connective tissue cushions in anal mucosa.  
-Hemorrhoids function as protective pillows that engorge with blood during the act of defecation, protecting the anal canal from direct trauma due to passage of stool.  
-Hemorrhoidal tissues engorge when intra-abdominal pressure is increased.  
This occurs with obesity, pregnancy, lifting, and defecation.

## Classification

### Internal hemorrhoids

-Are found superior to the dentate line and lined with columnar epithelium.

-They have autonomic innervation and thus not painful.

-They are further classified as:

1st degree. Do not prolapse only bleeding announces their presence

2nd degree -Spontaneously reducing prolapse at defecation

3rd degree. prolapse requiring manual replacement;

4th degree. permanent prolapse.

### External hemorrhoids

-Are found below the dentate line and lined by squamous epithelium .

-Are innervated by cutaneous nerves that supply the perianal area. These nerves include the pudendal nerve and sacral plexus. Thus are very painful.

### Etiology-not clearly known but risk factors

1. Pregnancy
2. Colon malignancy
3. Liver disease-Portal hypertension
4. Constipation
5. low-fiber diets cause small-caliber stools, which result in straining with defecation
6. Occupations that require prolonged sitting
7. Loss of muscle tone in old age
8. rectal surgery, episiotomy, anal intercourse
9. Obesity

### Pathophysiology

-Hemorrhoids generally cause symptoms when they become enlarged, inflamed, thrombosed, or prolapsed

-Abnormal hemorrhoidal tissue development is related to chronic straining that leads to engorgement, vascular dilatation due to decreased venous return.

-This leads to stretching of the supporting connective tissue. The most common cause of prolonged straining is the act of defecation.

-Aging causes weakening of the support structures, which facilitates prolapse. Weakening of support structures can occur as early as the third decade of life.

### SIGNS AND SYMPTOMS:

1. Constipation
2. Straining with defecation
3. Episodic bleeding on stool
4. Feeling of incomplete evacuation
5. Pruritus

6. Severe acute pain may be due to thrombosis of the veins but hemorrhoids are classically painless.
7. Ulceration

### DIAGNOSTIC PROCEDURES:

- Ano-rectal examination including anoscopy
- Sigmoidoscopy
- Inspection following straining at stool

### Differential diagnosis

- 1.carcinoma of the colon and rectum, diverticular disease,
- 2.adenomatous polyps
- 3.ulcerative colitis
- 4.Rectal prolapse (proctientia)

### MANAGEMENT

-This is only done when the hemorrhoids become symptomatic.  
-The goal of treatment is not to obliterate hemorrhoidal plexuses but rather to render the patient asymptomatic.

### A.Medical Treatment:

Most patients with early hemorrhoids (first- and second-degree) can be managed by simple local measures and dietary advice.

Decreasing straining and constipation shrinks internal hemorrhoids and decreases their symptoms; therefore, first-line treatment for all first- and second-degree (and many third- and fourth-degree) internal hemorrhoids should include measures to decrease straining and constipation.

1. **Avoid constipation**-The diet should be high in fiber (vegetables, fruits), and increased water intake must be stressed. Unrefined bran can be used to augment dietary bulk.

2.**Avoid straining**-no prolonged stay in the toilet seat

2.**Stool softeners** may be used-lactulose

3. **Rectal suppositories and astringents**-local anaesthetics+steroids sometimes antibiotics

Topical hydrocortisone can sometimes ease internal hemorrhoidal bleeding.

4. **Warm sitz baths** may also offer symptomatic relief.

Done 3times a day for 30 minutes each time on just warm water-tasted first

5.**Sclerotherapy**-Injection treatment, a form of sclerotherapy, consists of injecting an irritating chemical solution (eg, 5% phenol in vegetable oil) submucosally into the loose areolar tissue above the internal hemorrhoid

6.**Cryosurgery**: Hemorrhoids can be necrosed by freezing with a cryoprobe, using CO<sub>2</sub> or N<sub>2</sub>O.

7. **Strangulation -Rubber Band Ligation**: For enlarged or prolapsing hemorrhoids, band ligation is excellent treatment. With the aid of an anoscope, the redundant mucosa above the hemorrhoid is grasped with forceps and advanced through the barrel of a special ligator. Ischemic necrosis occurs over several days, with eventual slough, fibrosis, and fixation of the tissues. major complication of this technique is pain severe enough to require removal of the band

### Others

- Infrared photocoagulation
- Laser ablation
- Lord dilatation

### Surgical therapy:

Operative resection is reserved for patients with

1. grade III and grade IV hemorrhoids
2. Fail non operative therapy
3. Significant symptoms from external hemorrhoids or skin tags

-External hemorrhoids generally elicit symptoms due to acute thrombosis, recurrent thromboses, or hygiene problems.

-Manage acute thromboses and recurrent thromboses in a similar fashion.

-Identify the offending vascular cluster inject local anesthetic, then perform excision of the overlying skin and underlying veins.

- Enucleation of the thrombosis alone can result in recurrence of the hemorrhoid at the same spot in the future. Excision of the underlying vein completely prevents this. Electrocoagulation or topical astringent (Monsel solution) provides hemostasis.

-Suturing the wound closed is not necessary and may cause more pain.

Stapled hemorrhoid surgery, or procedure for prolapse and hemorrhoids (PPH), a specially designed circular stapler with smaller staples is used.

The technique involves placing a suture in the mucosa and submucosal layers circumferentially approximately 3-4 cm above the dentate line. The stapler is placed and slowly closed around the purse string. Care is taken to draw excess hemorrhoid tissue into the stapler. The stapler is fired, resecting the excess tissue and placing a circular staple line above the dentate line. This results in resection of excessive internal hemorrhoidal tissue, pexy of the internal hemorrhoidal tissue left behind and interruption of the blood supply from above

#### **COMPLICATIONS**

1. Stenosis
2. Haemorrhage
3. Infection-perianal abscesses
4. Recurrence
5. Non healing wounds
6. fistula formation
7. Urinary retention is directly related to the anesthetic technique used and to the peri operative fluids administered

#### **Summary of Management 6 S**

1. Stool softeners and diet modification- diet rich in roughage as fruits and vegetables plus a lot of water
2. Suppositories and astringents
3. Sitz baths
4. Sclerotherapy
5. Strangulation-band
6. Surgery

# HIRSCHSPRUNG'S DISEASE

(aganglionic megacolon)

## Definition

Presence of large, non-functional distal intestine usually the rectum with variable involvement of the colon and small gut

## Sites

- Only the terminal rectum occurs in about **10%** of cases
- Extension to the sigmoid colon in **65%**
- More proximal colon in **10%**
- Entire colon with small bowel involvement in **10-15%**

## Race

More common in Caucasians, then blacks. Least common among the Asians Whites >Blacks

## Sex

- Males are affected **X5** more frequently than females in cases in which the diseased segment is of the usual length.
- Up to 70-80 % of the involved patients are male.
- Females tend to have longer aganglionic segments.
- A familial association occurs in 5-10% of cases--more frequently when females are affected.

## Incidence

KNH-12 cases per year Or 1: 4 500

## Etiology

Can be broadly classified as Sporadic-up to **80-90%** of cases or **Familial 15-17%**.

### Familial cases:

- Maternal transmission more common than paternal transmission. If both parents are involved risk of 12.5% of the offspring getting affected. In familial cases 20% have associated congenital anomaly compared to 10% in sporadic case.
- Autosomal dominant inheritance with incomplete penetrance is responsible for the long segment familial disease. Autosomal recessive in short segment disease.
- 3 genes have been identified
- i)RET gene in chromosome 10-Autosomal dominant inheritance
- ii)Endothelial Receptor B gene in chromosome 13-autosomal Recessive
- iii)Endothelial 3 gene chromosome 20-Autosomal recessive

## Pathophysiology

### Exact cause unknown -2 theories

1. **Due to failure in the cephalo-caudal migration** of the neuro crest cells into the distal bowel.
  - Therefore, the absence of ganglion cells always begins at the anus and extends a varying distance proximally.
  - The aganglionic bowel produces a functional obstruction, because the bowel does not have normal propulsive waves and contracts en masse in response to distention.
2. **Hostile microenvironment** in the colon that damages already present neuroblasts. It is thought that the abnormality in chromosome causes the hostile environment

## Other associations

- Trisomy 21 (Down's syndrome);
- Genitourinary abnormalities.

- Neural crest abnormalities, such as congenital central hypoventilation syndrome (Ondine's curse)
- Waardenburg's syndrome
- Anorectal malformations

-The histological hallmark of Hirschsprung's disease is Aganglionosis in the **submucosal plexus of Meissner** and in the **intermyenteric plexus of Auerbach**.

-The nerves affected are the non-cholinergic non adrenergic ie NO, VIP and NADPH transmitters  
-This leads to unopposed autonomic nervous system functioning which causes;

- 1-Reduced or absent peristaltic(propulsive) activity
- 2-Increased intestinal sphincter tone

### The pathological hallmark is

1. There is marked distension & hypertrophy of gut proximal to the aganglionic segment
2. There is funneling (coning) of the gut between the two - transition zone
3. Constricted or collapsed gut at & distal to the aganglionic portion

### Spectrum of the disease

1. Complete absence.
2. Hypoganglionosis.
3. Abnormal ganglion cells ( hirschsprung like disease).
4. Also Intestinal neuronal dysplasia

### Acquired hirschsprungs disease

-Vascular causes e.g. Post-op 2° to Pull-through operation, with damage to the mesenteric vessels  
-Non-vascular e.g. TB, Diabetes

-Abnormal connective tissue and smooth muscle

### DDX

1. Anatomic Anorectal malformation
2. Metabolic
  - DM mothers-electrolyte imbalances
  - Hypothyroidism or hyperthyroidism
3. Drugs-Heavy sedation eg in eclampsia of mother
4. Meconium plug/ileus
5. Sepsis
6. Immaturity

## Clinical presentation

### Symptoms

- Vary widely in severity but almost always occur shortly after birth.
  - The time of presentation depends on amount of intestine involved as long segment -present early.
  - 1-Delayed passage of meconium
  - 2-Chronic or intermittent constipation with diarrhea
  - 3-Passage of flatus and stool requires great effort, and the stools are small in caliber.
  - 4-Progressive abdominal distention
  - 5-Vomiting and Reluctance to feed/anorexia
  - 6-Listlessness, irritability,
  - 7-Poor growth and development These children are sluggish, with wasted extremities and flared costal margins
- NB. Some pts present with acute enterocolitis or toxic megacolon with gross abdominal distension, vomiting, shock, septic and febrile

## Signs

-**Small for age infant, irritable, dehydrated,**

## P/A

Impacted stools in the greatly dilated and distended sigmoid colon can be palpated across the lower abdomen  
Abdominal distension-increased bowel movts

## DRE

-Normal anal tone.  
-Rectum collapsed ,tight and empty(no fecal matter).  
-Rectal examination in the infant may be followed by expulsion of stool and flatus, with remarkable decompression of abdominal distention passage of foul-smelling diarrhea

## INVESTIGATIONS

### Imaging

#### 1. Plain abdominal x-rays

-In infants show dilated loops of bowel, but it is difficult to distinguish small and large bowel in infancy.  
-Air fluid levels  
-Absence of air in the rectum

#### 2. Barium enema

-Should be done at least 48 hrs after birth.  
-The aganglionic segment appears relatively narrow compared to the dilated proximal bowel.  
-The proximal intestine can be dilated by impacted stool or enema, giving a false impression of the level of the normal colon.  
-The contrast is left and another x-ray taken after 24hours and failure to evacuate the contrast is very suggestive of the disease.

#### 3. Manometric studies

-Normal resting pressure of the rectum taken before inflation of the balloon and its shown to be elevated.  
-It also reveals abnormal irregularly, irregular contractions.  
- Rectal distention by a balloon inflation, a failure of relaxation of the internal sphincter.

### Biopsy

Definitive diagnosis is made by rectal biopsy 2 methods

1. Mucosal biopsies may be taken from the posterior rectal wall with a suction biopsy capsule without anesthesia.

Features:

-Aganglionic segment  
-Nerve trunk hyperplasia  
-Increased acetyl cholinesterase level  
-Immunohistochemistry

#### 2. Full thickness biopsy

If equivocal, it is necessary to remove a 1- x 2-cm full-thickness strip of mucosa and muscularis from the posterior rectum proximal to the dentate line under general anesthesia or at laparotomy.

## MANAGEMENT

### Supportive

1. Manage fluid  
2. Electrolyte imbalances  
2. Insert a soft rectal tube & give patient soft enemas - **5ml/kg warm Normal Saline**(NOT SOAP) & irrigate GIT until patient settles  
3. Antiotics- if fever and peritonism

## Definitive management

### Principles

a)Decompression and improve nutrition  
b)Establish extent of disease  
c)Definitive surgery

### Temporary colostomy and serial biopsy

-Laparotomy and **serial biopsy** on the rectum and colon with aim of determining extent of disease.  
-A colostomy is fashioned at the transitional zone to continue the decompression and allow the patient to gain weight before definitive surgery.  
-The points of biopsy are marked with non-absorbable sutures.  
Function of the colostomy  
-To decompress normal gut to allow normal growth & development until when definitive management can be instituted.  
-Reduce - NOT eliminate risk of enterocolitis

### Definitive Surgery

#### Principles

1. Resection of aganglionic segment  
2. Anastomosis of proximal to the distal segment

#### Modes of surgery

##### 1. Swenson Operation:

In the Swenson procedure, the overly dilated and aganglionic colon and rectum are excised to within 2cm above the dentate line.

-The transected end of the normally ganglionated bowel is sutured end-to- end with the distal anorectal segment.

##### 2. Duhamel:

Operation the rectum is oversewn, and the proximal bowel is brought between the sacrum and the rectum and sutured end-to-side to the rectum above the dentate line. The intervening spur of rectum and bowel is divided, and a side-to-side anastomosis is made with a stapler

There is risk of *faecaloma* forming in the aganglionated rectal cuff - **Lester-Martin** modification takes care of this complication

##### 3. Soave Operation:

The Soave operation consists of dissecting between the mucosa and the muscularis layer, pulling the proximal bowel through out of the residual rectal stump and suturing it to the rectum just 2 cm above the dentate line.

##### 4. Lynn Operation:

Rectal myectomy is used for distal rectal (short-segment) aganglionosis

##### 5. Total colonic aganglionosis - Martin's procedure:

Some colon is left for absorption of water & storage of faeces. Ileum is anastomosed at the dentate line & a side to side anastomosis of ileum to remaining colon. The ileum will provide peristalsis.

### Approaches

1. Open Laparotomy  
2. Laparoscopy  
3. Transanal

### Age at Surgery

Depends on the age at which the diagnosis is confirmed –tissue)  
and the availability of care.

# HYDROCEPHALUS

## Definition

-Hydrocephalus is the abnormal rise in cerebrospinal fluid volume with ventricular dilatation due to imbalance of cerebrospinal fluid production and absorption.

It is usually accompanied by increased intracranial pressure. Hydrocephalus is a diverse group of conditions, which result from;

- 1) Impaired circulation of CSF
- 2) Impaired absorption of CSF
- 3) In the rare circumstance, from increased production by a choroid plexus papilloma

The most common causes of hydrocephalus in acquired cases are tumor obstruction, trauma, intracranial hemorrhage, and infection.

## Pathophysiology

### Flow of CSF

CSF is produced in the lateral ventricle choroid plexus at 30mL/hr (20mL/hr in infants)

Foramen of Monro ↓

3rd Ventricle

Cerebral aqueduct of Sylvius ↓

4th Ventricle

Foramen of Lushka(2-lateral) ↓ magendie foramen

Subarachnoid basal cisterns posteriorly over the cerebellum and cerebral cortex, and anteriorly through the cistern system and over the convexities of the cerebral hemispheres.

arachnoid granulations ↓

superior sagittal sinus

↓

Venous circulation

NB. Main CSF production is from the lateral ventricles, some from the 4<sup>th</sup> ventricle. 25% CSF is produced from the ependymal lining of the ventricles.

Infants – volume of CSF 50mls

Adults – volume of CSF 125-150mls. Daily production of CSF 30ml/hr up to 720 ml/day

## TYPES OF HYDROCEPHALUS

### a) Obstructive / Non-communicating hydrocephalus

Hydrocephalus resulting from obstruction within the ventricular system. Proximal dilatation from obstruction.

#### 1. An abnormality of the Aqueduct:

Stenosis: Congenital - inherited as a sex-linked recessive trait

Acquired in Neurofibromatosis

Gliosis: Intrauterine viral infections, SAH in a premature infant, Neonatal meningitis, Mumps meningoencephalitis

#### 2. Lesions in the fourth ventricle:

##### Chiari malformation

Type II is characterized by progressive hydrocephalus and a myelomeningocele which results in elongation of the fourth ventricle and kinking of the brain stem, with displacement of the inferior vermis, pons, and medulla into the cervical canal.

Produce symptoms during infancy consisting of **stridor**, **weak cry**, and **apnea**, which may be relieved by shunting or by posterior fossa decompression.

Type I produces symptoms during adolescence or adult life and is usually not associated with hydrocephalus.

These patients complain of recurrent headache, neck pain, urinary frequency, and progressive lower extremity spasticity. The deformity consists of tonsillar herniation.

##### Dandy-Walker syndrome

Consists of a cystic expansion of the fourth ventricle in the posterior fossa, which results from a developmental failure of the roof of the 4th ventricle during embryogenesis.

Posterior fossa brain tumors- Medulloblastomas, hemangiomas, ependymomas.

3. Space occupying lesions may obstruct the flow along anyway along the ventricular system-Tumors, bleeds etc

### b) Non-obstructive / Communicating hydrocephalus -

Hydrocephalus resulting from obliteration of the subarachnoid cisterns or malfunction of the arachnoid granulations.

#### 1. Infections:

-Intrauterine infections may destroy the CSF pathways. ---

Pneumococcal and TB *meningitis* have a propensity to produce a thick, tenacious exudate that obstructs the basal cisterns

#### 2. SAH

Blood in the subarachnoid spaces may cause obliteration of the cisterns or arachnoid villi, and obstruction of CSF flow.

#### 3. Leukemic infiltrates

may seed the subarachnoid space and produce communicating hydrocephalus

#### 4. Superior sagittal sinus thrombosis

This impairs venous drainage and impairs re-absorption through the arachnoid villi.

#### 5. Overproduction of CSF-choroid plexus papilloma

### c) Normal-Pressure Hydrocephalus

Cerebral ventricular dilation with normal lumbar CSF pressure (5-18cmH<sub>2</sub>O)

**Actiology** – Same as Non-Obstructive or communicating hydrocephalus above

**Presentation**- Triad of normal pressure hydrocephalus.

-Dementia - rare cause of dementia in the elderly

-Apraxia of gait - initiation of gait is hesitant - described as a "slipping clutch" or "feet stuck to the floor" gait - and walking eventually occurs. Motor weakness and staggering are absent

-Urinary incontinence

#### Investigations

CSF pressure is normal

CT/MRI - the ventricles are dilated

#### **Mx;**

Shunting - Brief improvement after removing about 50mL of CSF indicates a better prognosis with shunting but the longer the disease has been present, the less likely shunting will be curative

### d) Ex Vacuo Hydrocephalus

Enlarged ventricles resulting from a loss of brain tissue

#### **Other terms**

-Arrested hydrocephalus-the ventricles dilated but the pressures not increasing. Seen more in children

-Occult hydrocephalus-dilated ventricles but no signs of raised ICP or suggestive of hydrocephalus.

Composition of CSF-Clear fluid, 15-45 mg/ml of protein

-60-80mg/ml of glucose, 3 lymphocytes or fewer

### **Presenting complaints**

**Infants**; sutures still open

#### **History**

1. Accelerated rate of enlargement of the head is the most prominent sign
2. Irritability, lethargy, poor appetite, and vomiting
3. Delayed milestones
4. Failure to thrive
5. Family history
6. Premature delivery
7. Previous history of treatment for meningitis
8. Maternal infections and drug intake in prenatal period.

#### **Physical examination**

1. Enlarged head for the age. At birth head circumference is 35cm +/- 2cm. this increases by:

- 2cm per month for first 3 months
- 1cm per month next 3 months
- ½ cm per month for next 6months
- ¼ cm per month from 1year to 3 years old.

The occipitofrontal head circumference is recorded and kept for monitoring the head progression.

- 2-Scalp veins are dilated and congested
- 3-The forehead is broad
- 4-Anterior fontanel is wide open and bulging
- 5-Percussion of the skull may produce a "cracked-pot" or Macewen sign, indicating separation of the sutures
- 6-Craniotables
- 7-A foreshortened occiput suggests the Chiari malformation, and a prominent occiput suggests the Dandy-Walker malformation.
- 8-Dilatation of the 3rd ventricle → dilatation of the suprapineal recess which then impinges on the tectum → eyes deviate downward - "setting-sun" eye sign.  
Also lid lag
- 9.Long tract signs-due to stretching and compression of cortico-spinal tract eg brisk tendon reflexes, spasticity, clonus in lower extremities, babinski reflex up going
10. Transillumination of the skull is positive with massive dilatation of the ventricular system or in the Dandy-Walker syndrome.
- 11.Funduscopy-Papilloedema is observed in older children but is rarely present in infants because the cranial sutures separate as a result of the increased pressure  
-In the older child, the cranial sutures are partially closed so that the signs of hydrocephalus may be more subtle. The signs of increased ICP become more prominent.

#### **DDx**

The head may appear enlarged secondary to a thickened cranium resulting from;

- 1) Familial-autosomal dominant
- 2) Chronic anemia eg Haemoglobinopathies, SCD, Thalassemia
- 3) Rickets
- 4) Achondroplasia
- 5) Osteogenesis imperfecta
- 6) Epiphyseal dysplasia
- 7) Neurofibromatosis
- 8) Storage diseases-Gaucher's disease, Tay Sachs disease.

#### **Investigations in infants**

1. **Skull X-ray** – Not very revealing but may show

- Separation of the sutures
- Erosion of the posterior clinoids in the older child
- Increase in convolutional markings ("beaten-silver appearance") with longstanding increased intracranial pressure.
- Flattening of gyri and obliteration of sulci
- Herniations-tentorial and through foramen magnum

#### **2. Ultrasonography**

Through the open anterior fontanel.

#### **3. CT-scan**

Show ventricular dilatation

4. MRI

#### **Adults**

#### **Clinical presentation**

Mainly signs of increased intracranial pressure.

**Signs /Symptoms of increased ICP**

#### **Symptoms**

- 6) -Severe bursting headache
- 7) -Projectile vomiting
- 8) -Blurring of vision
- 9) -Convulsions/seizures
- 10) -Drowsiness and altered consciousness.

#### **Signs**

- 7) -Vital signs-increased BP and decreased pulse rate (Cushings reflex)
- 8) -Anisocoria-unequal pupils
- 9) -Papilloedema on funduscopy
- 10) -Nerve palsy eg 3<sup>rd</sup> and 6<sup>th</sup> cranial nerves
- 11) -Irregular breathing/slowed rate

#### **MANAGEMENT**

#### **Aims**

1. Reduce the intracranial pressure-Medical treatment or CSF diversion
2. Remove the underlying cause-Definitive surgery

#### **Medical treatment**

When patients have slowly progressive hydrocephalus with few symptoms or signs, and when the condition of the patient has prohibited surgery.

-Medical therapy usually is a temporizing measure. In transient conditions, such as sinus occlusion, meningitis, or neonatal intraventricular hemorrhage, medical therapy can be effective.

**Acetazolamide** (25 mg/kg/d in 3 doses): Careful monitoring of respiratory status and electrolytes is crucial. Treatment beyond 6 months is not recommended. **Furosemide** (1 mg/kg/d in 3 doses):

Again, electrolyte balance and fluid balance need to be monitored carefully. **Lumbar punctures**: In neonates recovering from intraventricular hemorrhage, serial lumbar punctures can resolve hydrocephalus in some cases. If possible, this is the preferred method of treatment.

Removal of the underlying cause resolves hydrocephalus in most cases

#### **SURGERY**

#### **CSF DIVERSION**

#### **Short-term**

-Acute intraventricular bleeds, subarachnoid bleeds, infections.

There is high protein concentration in the CSF which would cause coagulum and block the valve.

-Do external ventricular drains until blood is cleared from the CSF. And the infection has settled.

-Exteriorization of the shunt can also be used for the administration of antibodies.

### **Permanent CSF diversion**

1. Ventriculoperitoneal shunt
2. Ventriculo-atrial Shunt
3. Ventriculopleural shunt

#### **Ventriculoperitoneal shunt**

A shunt is placed from the lateral ventricle to the peritoneum

#### **Procedure**

- Standard pre-operative preparation
- Patient in supine position
- Clean and drape the right parietal, neck, chest and abdomen. Right side of the head to be away from the speech areas-Broca's and Wernicke's left in most people.
- Do right parietal burr hole
- Right subcostal minilaparotomy
- Subcuticular tunneling
- Insertion of the shunt system.
- Cannulation of lateral ventricle and confirm that the shunt is functioning
- Standard wound closure.

#### **Complications:**

- 1-Bacterial infection, usually due to Staphylococcus epidermidis
- 2-Shunt blockade-mechanical kinks, choroid plexus block, omentum
- 3-Shunt disconnection-from the drainage of the lateral ventricle.
- 4-Shunt migration-can migrate downward the peritoneum
- 5-Subdural bleed due to rapid decompression seen with patients who have had sutural closure.

### **DEFINITIVE SURGERY**

- Operation for tumors
- Appropriate craniotomy dependent on the location of the tumor.

#### **Prognosis**

- Depend on the cause of the dilated ventricles and not on the size of the cortical mantle at the time of the shunting.
  - Increased risk of developmental problems
  - Mean intelligence quotient is reduced compared to general population
  - Risk of aggressive and delinquent behaviour
  - Accelerated pubertal development in patients with shunted hydrocephalus or meningomyelocele due to increased gonadotropins due to increased ICP



# INTESTINAL FISTULA

## Definition

A fistula is an abnormal tract between two or more epithelial lined surfaces. Tract is lined by granulation or epithelial tissue. It may involve a communication tract from one body cavity or hollow organ to another hollow organ or to the skin. Enterocutaneous fistula is an abnormal communication between bowel and skin.

## Classification

There are several ways to classify fistulae and these are useful in selecting measures for management and for comparison of therapeutic approaches.

1. Descriptive includes the sites of origin and termination: e.g. jejunocutaneous, ileovesical fistulas

### 2. Anatomical Classification

Modified Sitzes-Serra classification

Type I fistulae are esophageal, gastric, and duodenal fistulae

Type II fistulae involve small bowel

Type III fistulae involve large bowel and

Type IV fistulae where all the above drains through a large abdominal wall defect.

### 2. Internal versus external

Internal fistulae include ileocolic or ileoileo fistulae.

Rarely follow a surgical procedure; usually result from local perforation of diseased bowel. An abscess forms that affects an adjacent structure.

External fistulae include duodenocutaneous or ileovaginal.

### 3. Physiological classification

Quantifies fistula output over a 24-hour period

-Low volume fistula <200 ml/24-hour

-Moderate volume 200 and 500 ml/24 hours

-High volume >500 ml/24 hours.

### 4. Etiological

Spontaneous Fistulae arise without prior surgery.

Iatrogenic-post surgical are the most common causes. Also post radiation enteritis.

### 5. Characteristics of the tract (simple or complex)

Simple fistulas-Single, short, direct tract, no abscess associated.

Complex-multiple tracts. Several types

Type 1-abscess or multiple organ involvement

Type 2 -distal end within the base of a disrupted wound

6. End fistula, which encompasses the entire diameter of the bowel, and lateral fistula, which arises from one side only.

## **Etiology**

### **Iatrogenic fistulas**

Fistulas are either iatrogenic or spontaneous in development. Iatrogenic..... Surgical misadventure or 'post operative' is the commonest cause.

Fistulas may develop immediately or years later in conjunction with other processes such as diabetes mellitus, pelvic

inflammatory disease, pelvic surgery, hypertension and atherosclerosis.

Surgical complications that may cause fistulas include:

1. Unintentional enterotomy
2. Anastomotic breakdown (85%–90%) as a result of:
  - Foreign body close to the suture line,
  - Tension on the suture line
  - Complicated suture techniques
  - Distal obstruction
  - Hematoma, abscess formation at the anastomotic site
  - Sepsis
  - Tumor
3. Emergent/urgent surgical procedures involving
  - Unprepared bowel,
  - under resuscitation,
  - malnourishment
  - or previously radiated tissue

### **Spontaneous 10%–15%**

1. Intestinal diseases such as Crohn's disease, malignancy

2. Infectious processes, as in tuberculosis, diverticulitis,

3. Vascular insufficiency, mesenteric ischemia.

4. Radiation exposure

### **Effect of fistula**

Loss of enteric contents is attended to by

1. Nutritional deficits due to nutrient loss/ lack of absorptive exposure

2. Loss of fluid, electrolyte and acid base imbalance

3. Contents contaminate sterile cavities like peritoneum with sepsis with its attendant metabolic and immunologic consequences

### Some effects of Sepsis

-Worsens the hypovolemic state

-Increases the metabolic demand worsens the nutritional state.

-Toxemia and circulatory disturbance can lead to Multiple Organ Failure Syndrome.

-In presence of sepsis spontaneous closure cannot occur

Sepsis is manifested by pyrexia, leucocytosis, tachycardia and hypoalbuminemia.

Cachexia may be the only manifestation

### **Fluid Type/ Origin Of Fistula**

-Watery .....Gastric

-Bile .....Gastric, biliary, duodenum

-Yellow/orange..Small bowel

-Colourless.....Pancreas

-Brown fecal.... Large bowel

### **Presentation.**

1. Fever and sepsis.

2. Abdominal pain.

3. Localized abdominal tenderness.

4. External drainage of small bowel contents.

5. Severely excoriated skin and abdominal wall tissues

6. Dehydration and malnutrition-loss of fluids and nutrients

### **MANAGEMENT**

The goal is to achieve permanent closure of the fistula in the shortest time and with the lowest possible risk to the patient. This is achieved either surgically or by conservative management

Meticulous skin care is also provided around the fistula using skin protective creams eg zinc oxide, Aluminium paste, karaya powder.

These can be categorized into phase Four phases:

- A. Stabilization,
- B. Investigations
- C. Conservative treatment
- D Surgery

#### **A.STABILIZATION**

- 1.Fluid and electrolyte replacement
- 2.Adequate nutrition
- 3.Perifistular skin protection
- 4.Infection control
- 5.Measures to reduce fistula output

#### **1.Rehydration and electrolyte replenishment**

-Many fistula patients are profoundly depleted of intravascular and interstitial volume.

-The gastrointestinal tract secretes 5-9L of fluids with sodium, potassium, chloride and bicarbonate daily.

-Loss of these essential electrolytes and fluid volume threatens the overall circulatory system.

-Hypovolemia, inadequate tissue perfusion, renal failure and circulatory collapse can occur in the presence of a high output fistula.

-Thus replacement of these fluids with isotonic saline solution takes first priority.

Monitoring of fluid resuscitation

- Central venous pressure
- Urine production per hour-at least 30-50ml/hr
- Input/output chart -Fluid should be collected from fistula output, nasogastric suction, and urine for measurement of volume output versus the input of fluid
- Skin turgor.
- Pulse

-Blood collected for electrolytes and BGA.

Results of these studies assist in correcting electrolyte deficits and deranged acid-base balance.

Body weight is recorded daily. Fluid and electrolyte resuscitation can usually be accomplished within the first day or two.

-Subsequent maintenance of homeostasis depends on accurately measuring losses and replacing them

#### **2.Nutritional assessment and supplementation**

Good nutrition is needed for:

- Closure of the fistula
- Reduce chances of infection
- Appropriate mode of nutrition to allow gut to rest.

Route of nutritional support either oral, enteral or parenteral nutrition dependent

- upon patient tolerance
- ability to ingest sufficient quantities
- the fistula tract location
- the bowel mucosa absorptive capacity

Oral route of nutrition is reasonable for patients with colonic fistulas.

Patients with esophageal and distal ileum fistulas could be supported via the enteral route

Ultimately, total parenteral nutrition (TPN) is the route of choice for those with high output proximal small bowel fistulas. Central

parenteral hyperalimentation will allow the intestinal tract to be placed completely at rest.

#### **3. Measures to protect the Perifistular skin from excoriation**

Fistula drainage fluid must be collected to avoid excoriation of skin and abdominal wall tissues and to record volume losses. Stomachesive appliances eg Ileostomy bag is placed on the opening to protect skin, allow for evaluation of spontaneous closure and monitoring the daily output.

#### **4.Infection control**

Local and systemic sepsis treated with appropriate drainage and antibiotics guided by appropriate microbiological investigations Abscesses should be drained as soon as they are diagnosed.. Drainage is accomplished, and the fistula may close as the sump tube is gradually withdrawn over a period of weeks.

#### **5.Measures to decrease fistula output**

This simplifies management and increases the rate of spontaneous closure.

The initial measure is the placement of a nasogastric tube or if long-term use may be indicated a gastrostomy tube. Sometimes this can be placed at the time of another operative procedure. 'Nothing by mouth' regimen minimizes intestinal output as this decreases content within the intestinal lumen, reduce intestinal stimulation and pancreaticobiliary secretions.

Pharmacological methods includes:

- H2 antagonists/PPIs to prevent stress ulcers and to decrease gastric secretions
- Somatostatin to inhibit stomach, pancreas, biliary tract and small intestinal secretions

#### **B.INVESTIGATIONS**

##### **Lab investigation**

- 1.FHG-WBC rise with neutrophilia
- 2.Electrolytes-imbalance hypokalemia, hyponatremia
- 3.LFT-sepsis may cause acute enzyme rise of liver injury
- 4.U/C -may show deranged kidney function due to sepsis

##### **Imaging**

##### **Fistulogram**

Assess the anatomical features of the fistula by radiography Maturation of the fistula track occurs postoperatively after 7- 10 days. Then water-soluble iodinated media dye can be introduced for fistulogram

Fistulogram determines:

- 1) Origin of the fistula
- 2) Length of the tract
- 3) Continuity the bowel
- 4) Other manifestations such as an abscess or distal obstruction.

Combination with barium studies can accurately establish the site of the fistula in case of difficulty.

Orally administered barium will usually give the most information, including information about the size of the leak, the absence of distal obstruction and the presence of a tumour, or extent of inflammatory changes in the intestine itself

##### **Ultrasonography and CT-Scan**

US and CT scan of the abdomen useful in detecting intra abdominal abscesses and US guided aspiration of the abscess

Hydrogen peroxide enhanced US-fistulography could be considered  
Scintigraphy (Indium 111-WBC Scintigraphy) is useful in chronic disease such as Crohns disease .... distinguish fibrosis or scarring from active disease.

### **C. CONSERVATIVE MANAGEMENT**

This involves the five aspects of stabilization which are continued.  
Once stable ,continuous close monitoring of

- ✓ Fluid and electrolyte status
- ✓ The nutritional status and feeding
- ✓ Continued protection of skin around fistula
- ✓ Control of any infections to enhance spontaneous closure of fistula tract
- ✓ Measures to decrease output from fistula with close monitoring of output from the fistula Control of fistula by percutaneous intubation of tract may be done

### **D. SURGERY**

Indications of surgery include the following

1. Dehiscence of a suture line
  2. Presence of distal intestinal obstruction.
  3. Presence of foreign body
  4. Epithelialization of the fistulas tract
  5. Continuous high output even with measures to decrease output
  6. Extensive disruption of intestinal continuity >50%
  7. A short (< 2 cm) fistula tract
  8. Increasing abdominal distension
  9. Hemodynamic instability
  10. Complex fistulas.
  11. Underlying gut disease- Malignancy ,Irradiated Bowel, Inflammatory Bowel disease.
  12. Flaring sepsis due to abscesses inadequately drained percutaneously.
- Sepsis, hemorrhage and evisceration call for immediate surgical intervention.

#### **Surgical Intervention involves**

Exteriorization of the affected bowel ends followed by definitive surgery after 12 weeks i.e. after the intra abdominal septic process has been treated remains the mainstay of surgical treatment.

#### **Muscle Flaps**

If previous extensive resection, the use of muscle flaps may be helpful.

Muscle flaps provide well-vascularized coverage and help control fistula drainage when multiple fistulas occur in a large abdominal wall defect.

Flaps also useful in the presence of infection because they provide phagocytically active tissue.

#### **Laparoscopy**

Advances in instrumentation and accumulation of experience has allowed minimally invasive surgery to become an alternative to laparotomy in selected cases

# INTESTINAL OSTRUCTION IN PEDRIATRICS

## Common Causes of intestinal obstruction

### A. Extramural causes

1. Congenital hernia
2. Malrotation
3. Peritoneal bands or volvulus
4. Annular pancreas

### B. Intra luminal causes

1. Intestinal atresia or stenosis
2. Congenital hypertrophic pyloric stenosis
3. Meconium ileus
4. Meconium plug syndrome
5. Feccal impaction
6. Intussusceptions
7. Anorectal malformation .Also involve the wall defects

### C. Mural causes/within wall

1. Hirschsprung's disease
2. Neonatal small left colon syndrome.
3. Paralytic ileus-infections, electrolyte imbalances

### Clinical presentation

The cardinal signs and symptoms of intestinal obstruction are

- (1) Polyhydramnios in the mother-prenatal diagnosis
- (2) Vomiting
- (3) Abdominal distention
- (4) Failure to pass meconium

**1-Polyhydramnios** is related to the level of obstruction and occurs in approximate 5% of women who have infants with duodenal atresia and 15% of those who have infants with ileal atresia.

**2-Vomiting** occurs early in upper intestinal obstruction, and it is bile-stained if the obstruction is distal to the ampulla of Vater.

Lead to:

- Dehydration - most commonly in small bowel obstruction
- Signs of Shock - ↓urine output (Children- 0.5-1ml/Kg/hr), ↑pulses, ↓BP
- Hypochloreaemic metabolic alkalosis with Paradoxical aciduria
- Hypokalaemia-loss of electrolytes in vomiting.

**3-Abdominal distention** is related to the level of obstruction, being most marked for distal obstructions.

**4-Failure to pass Meconium** is passed in 30-50% of newborn infants with intestinal obstruction, but failure to pass meconium within the first 24 hours is distinctly abnormal.

**5-Constipation** - initially stool may be reduced in quantity progressing to constipation

Absolute (Obstipation) - No faeces or flatus passes

Relative - Flatus but no faeces especially if obstruction is high

## INTUSSUSCEPTION

### Definition

-This occurs when one portion of the gut becomes invaginated within an immediately adjacent segment ie the proximal over the distal bowel.

-This telescoping of a segment of bowel (**intussusceptum**) into the adjacent segment (**intussusciens**) is the most common cause of intestinal obstruction in children under 2 years

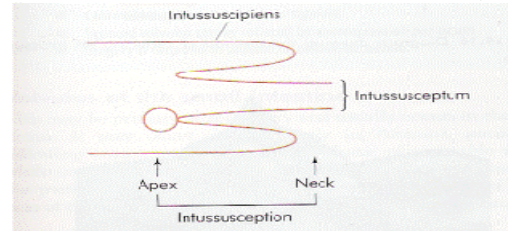


Figure 69.13 Mechanism and nomenclature of intussusception.

-The process of intussusception may result in gangrene of the intussusceptum.

### Types

-The most common form is intussusception of terminal ileum into the right colon (**ileocolic intussusception**).

-Others include:

- Ileoileal
- Ileoileo-colic
- Jejunojejunal
- colocolic intussusceptions also occur

### Age and Sex

-The ratio of **males to females is 3:1**.

-The peak age is in **infants 5-9 months** of age; 80% of patients are under the age of 2 years

### Aetiology

-In **95% of infants and children**, **no contributing factor**.

-No fixation of cecum cause **idiopathic intussusception**.

-**Seasonal** following upper respiratory tract infection in the community

### Predisposing factors/conditions:

1. Hyperplasia of Peyer's patches in the terminal ileum 2° to weaning, URI e.g. adenovirus or rotavirus may be the initiating factor
  2. Meckel's diverticulum - 2 ft proximal to the ileocaecal junction, 2" long, in 2% of 2yr olds
  3. Polyps
  4. Duplication
  5. Henoch-Scholein purpura
  6. Appendicitis
  7. Lymphedema
  8. Post op intussusception-ENT, Non-GIT
- Post appendisectomy or anastomosis  
-Post chemotherapy

### Clinical presentation

#### History

1. **Intermittent Colicky abdominal pain**

-An otherwise fit & well male child of 6 months develops **sudden onset** of screaming associated with drawing up of the legs

-The attacks last for a few minutes recur every 15 minutes & become progressively severe.

- During attacks the child has facial pallor while between episodes he is listless & drawn
- 2. Reflex vomiting following pain -Becomes conspicuous with time
- 3. 'Redcurrant jelly stool' due to exudation of mucus & blood due to vascular compromise → Ischemia ± perforation → Tenderness on palpation
- 4. Lethargy, pallor and sweating are other symptoms.

### Physical examination

#### A. General:

Dehydration, pallor

#### B. Abdomen

1-Initially between episodes of pain, the abdomen is soft and non tender with Sausage shaped lump in the right upper quadrant or in the mid upper abdomen with concavity towards the umbilicus.

-Lump that hardens on palpation (lump in only 50-60% of case )

2-With time, the abdomen will become distended and tender and the examination more difficult

3-Feeling of emptiness in the Right Iliac Fossa (the sign of Dance)

#### DRE;

1. Blood-stained mucus may be found on finger
2. Occasionally in extensive **ileocolic** or **colocolic** intussusception, the apex may be palpable or even protrude from the anus

#### DDX

- 1-Adhesive band small bowel obstruction
- 2-Appendicitis
- 3-Gastroenteritis

### Investigations

#### Imaging

1. **Abdominal radiograph** should be examined for a soft-tissue mass displacing loops of bowel. The leading edge of the intussusceptum sometimes will be outlined with air, thus establishing the diagnosis. Evidence of bowel obstruction may be present. However, a normal abdominal radiograph does not exclude intussusception

#### 2. Abdominal ultrasound

- ring within a ring sign.
- Thickened bowel loop
- Pseudo kidney appearance

3. **A contrast enema** (preferably using air as the contrast agent) with fluoroscopic guidance is required to exclude intussusception in a patient with a suggestive history. (both diagnostic and therapeutic)

-Preparation for laparotomy is required before administering the enema because of the risk of perforation.

-Although barium and water-soluble contrast media have been used in the past, the air enema has proven to be more effective in reducing intussusceptions as is associated with fewer perforations.

-In few cases of perforation it causes less peritoneal cavity contamination.

-Radiologic reduction should be attempted unless the patient has evidence of peritoneal irritation, which is an absolute contraindication to hydrostatic reduction

### Laboratory tests

1. **Electrolytes**-hypokalemia, hypochloremia
2. **CBC**-leucocytosis in perforation
3. **ABG** -metabolic alkalosis
3. **Urinalysis**-paradoxic aciduria
4. Stool guaiac

### MANAGEMENT

#### Supportive

-Monitor vital signs

1. Replacement of IV fluids and Electrolytes
2. Administration of analgesia
3. Administration of prophylactic antibiotic in cases with signs of peritonism ... then 3 tubes....
4. NG tube for decompression
5. Urethral catheter to monitor input output.
5. Passage of flatus tube.
6. Obtain consent, do PCV, U/E and GXM if shows signs of peritonitis.

#### Non-operative management

##### A. Hydrostatic or Pneumatic reduction

-This is done in early presentation with no signs of peritonism.

-Pneumatic is preferred to hydrostatic reduction as it causes less complication.

-Patient is under sedation but not put under anaesthesia to observe for complications.

-Air, Normal saline, Barium enema may be used under controlled pressure (should not be >30mmHg or 100ml of water) with fluoroscopic guidance.

-Air (the contrast) is pushed into the patient PR and the rectum blocked by balloon.

##### End point

-Pressure gives

-Reduction is confirmed by visualisation of contrast or air in the terminal ileum by x-ray

##### Contraindications

1. Peritonism-absolute contraindication
- Relative contraindications
2. Prolonged history >24 hrs
3. Presence of complex intussusception
4. Mass palpable per rectum-extensive intussusceptum

##### Post operative

-Nil by mouth

-The recurrence rate after radiographic reduction is 3 to 5%, and recurrences usually occur relatively soon after reduction within 24 hours.

-Patient kept in ward for this period for observation. (check pain, vomiting, abdominal distension)

-Confirm reduction by U/S before discharge

##### B. Surgery

-Incisions Transverse-for good exposure

-Right iliac fossa commonest-Ileocolic , ileoileal

##### Indications

1. Duration > 24 hours
2. Evidence of peritonitis
3. Presence of double or compound intussusception on U/S
4. Failure of radiologic reduction -Pneumatic or hydrostatic

- Reduction is achieved by squeezing the most distal part of the mass in a cephalad direction slowly and patiently-NO PULLING!
- The viability of the entire bowel should be checked carefully.
- In the presence of an irreducible or gangrenous intussusception , the mass should be excised in situ & an anastomosis if small gut.
- However resection of terminal ileum would lead to megaloblastic anaemia-Vitamin B12 .also lead to bile stones due to reduction n enterohepatic circulation of bile salts
- Colonic gangrene or perforation-temporary end colostomy fashioned with anastomosis done later with colostomy closure.

# INTESTINAL OBSTRUCTION

## Definition

Failure, reversal or impairment of the normal transit of intestinal contents.

## Classification & Etiology

### A dynamic obstruction

Due to failure of peristalsis. May be caused by:

1. Neuronal defect eg spinal injuries
2. Electrolyte imbalances especially hypokalemia, acid and base imbalances, Uraemia
3. Ischemic causes venous or arterial defects
4. Infections-peritonitis
5. Retroperitoneal hematomas

### Mechanical intestinal obstruction

#### 1. Luminal lesions

- a) Impactions
- b) Gallstones
- c) Bezoars and other foreign matter
- d) Meconium in newborns
- e) Intussusception in infants

#### 2. Intramural lesions

- a) Congenital (e.g., atresia and stenosis, imperforate anus, duplications, Meckel's diverticulum)
- b) Trauma
- c) Inflammatory (e.g., Crohn's disease, diverticulitis, ulcerative colitis, radiation, toxic [ingestions])
- d) Neuromuscular defect (e.g., megacolon, neuro/myopathic motility disorders)
- e) Neoplastic (most common etiology of colon obstruction)

#### 3. Extrinsic lesions

- a) Adhesions (most common etiology of small bowel obstruction)
- b) Hernia and wound dehiscence
- c) Masses (e.g., annular pancreas, anomalous vasculature, abscess and hematoma, neoplasms)
- d) Volvulus

## Pathophysiology

In simple mechanical obstruction, blockage occurs without vascular or neurological compromise.

Ingested fluid and food, digestive secretions, and gas accumulate in excessive amounts if obstruction is complete causing proximal bowel distension and blockade of the venous drainage.

There is impaired circulation leading to ischemia and inflammation ensues with more secretions into the lumen.

The normal secretory and absorptive functions of the mucous membrane are depressed, and the bowel wall becomes edematous and congested. Severe intestinal distention is self-perpetuating and progressive, intensifying peristaltic and secretory derangements and increasing the risks of dehydration, electrolyte imbalances, ischemia, necrosis, perforation, peritonitis, and death.

## Symptoms, Signs, and Diagnosis

### Obstruction of the small bowel:

Diagnosis of simple obstruction is based on a triad of symptoms:

(1) Abdominal cramps are centered around the umbilicus or in the epigastrium; if cramps become severe and steady, strangulation probably has occurred.

(2) Vomiting starts early with small-bowel and late with large-bowel obstruction.

(3) Obstipation occurs with complete obstruction, but diarrhea may be present with partial obstruction. Strangulating obstruction occurs in nearly 25% of cases of small-bowel obstruction and can progress to gangrene in as little as 6 h; it is manifested by steady, severe abdominal pain from the outset or beginning a few hours after the onset of crampy pain.

On thorough examination of the abdomen, groin, and rectum.

## Abdominal examination done like in acute abdomen

### - Inspection

*What is the abdominal contour?*

Distension – intestinal obstruction or ascites

*Does the abdomen move with respiration?*

Rigid abdomen – peritonitis

*Can the patient blow out/suck in the abdomen?*

Rigid abdomen – peritonitis

*Does the patient lie still or writhe about?*

Fear of movement – peritonitis

Writhe about – colic

*Are there visible abnormalities?*

Scars – relevant previous illness, adhesions

Hernia – intestinal obstruction

Visible peristalsis – intestinal obstruction

Visible masses – relevant pathology

*Gentle palpation*

*Is there tenderness, guarding or rigidity?* Tenderness/guarding – inflamed parietal peritoneum

Rigidity – peritonitis

*Deep palpation*

*Are there abnormal masses/palpable organs?*

Palpable organs/masses – relevant pathology

*Is there rebound tenderness?*

Rebound tenderness – peritonitis

*Percussion*

*Is the percussion note abnormal?*

Resonance – intestinal obstruction

Loss of liver dullness – gastrointestinal perforation

Dullness – free fluid, full bladder

Shifting dullness – free fluid

*Auscultation*

*Are bowel sounds present /abnormal?*

Absent sounds – paralytic ileus

Hyperactive sounds – mechanical obstruction – gastroenteritis

*Is there a bruit?* Bruit – vascular disease

## Examination of inguinal and femoral regions

This should be an integral part of the examination.

Incarcerated hernias represent a frequently missed cause of bowel obstruction.

## Digital rectal examination

-Hard stools suggest impaction.

-Soft stools suggest obstipation.

-An empty vault suggests obstruction proximal to the level that the examining finger can reach.

-Fecal occult blood testing should be performed, and a positive result may suggest the possibility of a more proximal neoplasm.

**Do a vaginal examination when appropriate**

**Examine the chest**

**Laboratory Tests**

- 1.FHG:A rising white blood cell count may herald the development of strangulation, but strangulation may be present in the absence of leukocytosis
- 2.Electrolyte
- 3.Urea and creatinine

**Imaging**

Plain films of the abdomen (KUB) show dilated loops of bowel.

Air fluid levels more than 3 in adults

Upright films of the abdomen or of the chest should be obtained also, to look for the free air under the diaphragm if a perforation has occurred

**MANAGEMENT**

**Initial conservative management**

- 1.Nasogastric tube for decompression
  - 2.Intravenous fluids for dehydration
  - 3.Catheterize and monitor input and output
  - 4.Visualization of foreign material
  - 5.Prophylactic antibiotics.
  6. Soapy enema may be used in partial distal obstruction.
- Double contract barium enema has a role in intussusception reduction

**Surgical management**

**Indication**

- 1.Peritonism
  - 2.Contiued deterioration of general condition of the patient
- Closed bowel procedures: lysis of adhesions, reduction of intussusception, reduction of volvulus, reduction of incarcerated hernia
- Enterotomy for removal of bezoars, foreign bodies, gallstones
  - Resection of bowel for obstructing lesions, strangulated bowel
  - Bypasses of intestine around obstruction
  - Enterocutaneous fistulae proximal to obstruction: colostomy, cecostomy



# CHRONIC LEG ULCERS

It is vital that any patient with leg ulceration has a full assessment. Lack of assessment can lead to long periods of inappropriate and potentially dangerous treatment.

For example, applying compression bandaging to a limb where the arterial blood supply is compromised may result in gangrene; withholding compression bandaging where there is venous insufficiency may result in failure to heal and/or rapid extension of the ulceration.

## Etiology

The most common cause of leg ulceration is tropical ulcers. Damaged to valves within the veins results in reflux of venous blood and consequent high pressures in the smaller vessels. This in turn leads to oedema and leakage of blood cells and fibrin into the tissues causing discolouration and hardening of the tissues (lipodermatosclerosis).

These tissues are then prone to injury and once injured slow to heal. However, there are other causes of ulceration and these should be excluded before treatment is begun.

## Other causes

1. Arterial insufficiency to the lower limb
2. Infections (tropical ulcers)
3. Blood disorders (sickle cell anaemia)
4. Neoplasms (squamous cell carcinoma, basal cell carcinoma)
5. Trauma
6. Neuropathic (normally associated with diabetes and occurring on the feet)
7. Mixed arterial and venous insufficiency
8. Small vessel disease (associated with diabetes)
9. Vasculitis (associated with rheumatoid arthritis and other auto-immune disorders such as lupus erythematosus)
10. Gross obesity
11. Hypertension
12. Lymphoedema
13. Fectitious injury (rare)
14. Other rare conditions (scleroderma, pyoderma gangrenosum)

## ASSESSMENT OF LEG ULCERS

### History

#### -Ulcer

- Onset, location, number, discharge or bleeding, pain, pruritus, abnormal odour, skin changes around ulcers
- The ulcer healing or enlarging, recurrences and previous history of treatment
- History of trauma at the site
- Associated leg swelling
- Associated fever
- Associated weight loss, fatigue
- Associated chronic cough, past TB treatment or history of contact with person of chronic cough
- Associated loss of sensation on the limb
- History of yellowness of eyes, recurrent pains in limb or abdomen. Any other history suggestive of sickle cell disease.
- Associated groin swellings
- Hypertension and diabetes mellitus

- History of smoking
- Intake of any drugs

### Past medical history

- Vascular history including: history of DVT

### Physical examination

#### Examination of ulcers

- Site and number of wounds
- Size
- Shape
- Edges (undermined e.g. buruli ulcer, overhanging e.g. malignant ulcer, irregular or regular)
- Depth
- Floor-clean, necrotic tissue, granulation tissue, bleeds
- Base-palpated mobility, tenderness
- Exudates, discharges from the wound and odour
- Surrounding areas eczema, maceration, signs of scratching, blistering

#### -Leg examination

- Oedema
- prominent varicosities
- Skin discoloration
- skin condition colour and temperature
- examine calf-swelling and tender

#### Other examination

1. Report pulses-dorsalis pedis, popliteal and femoral pulses to rule out arterial insufficiency
- Blood pressure measurement in both arms
2. Lymphadenopathy –inguinal to rule out malignant ulcers especially malignant melanoma.
- infectious causes
3. Sensory examination of the lower limb to rule out the neuropathic ulcers

#### Venous disease

- usually shallow ulcers (situated on the gaiter area of the leg)
- oedema
- eczema
- ankle flare
- lipodermatosclerosis
- varicose veins
- hyperpigmentation
- atrophic blanche

#### Arterial disease-Pain,parlour,parasthesia,paralysis

- ulcers with a 'punched out' appearance
- base of wound poorly perfused and pale
- cold legs/feet (in a warm environment)
- shiny, taut skin
- dependent rubor
- pale or blue feet
- gangrenous toes

#### INVESTIGATIONS

1. FHG -Anemia, Infections ,leukemia
2. Doppler measurement of ABPI (ankle brachial pressure index) in both feet (essential to rule out arterial disease).
3. Blood or urine screen for diabetes.
4. Swab ulcer for M/C and sensitivity

Additional blood investigations will depend on the patient's clinical history

Biopsy is indicated where areas of depigmentation and tissue proliferation raise the suspicion of malignant change

Radiology may be indicated to show bone changes, especially malignant erosion, pathological fracture, inflammatory changes, or dystrophic calcification.

Full assessment should be carried out when the patient first presents and should be repeated if the patient fails to respond to treatment. Foot pulses should be palpated and if not palpable, Doppler examination should be repeated at regular intervals (at least three monthly as long as compression therapy is being used). Doppler examination should also be repeated if there is a sudden increase in pain.

### **MANAGEMENT**

Treatment of uncomplicated chronic tropical ulcer comprises three main aspects;

1-control of infection

2-control of any factors hindering healing

3-provision of robust epithelial cover which will protect against further ulceration and malignant change.

-For control of infection patients require systemic treatment with antibiotics, chosen on the basis of laboratory determined sensitivities.

-Excision of indolent granulation tissue, areas of dense fibrosis, and severely scarred depigmented skin may be essential to achieve ultimate healing. Contractures and bone deformity will usually need to be corrected before the ulcer is covered. Bone infection must be controlled.

-Epithelial cover is usually achieved by applying a split-thickness skin graft to the granulating bed of the ulcer or after excision of the ulcer.

Management of underlying condition leading to ulceration.

### **Malignant Transformation**

-Rolled up edges, undermined edges, bleeding, irregular edges, rough floor with necrotic debris

The primary carcinoma

On presentation, most patients have large squamous cell carcinomas with bone attachment or invasion. Despite advanced local disease, metastatic disease is not common and potentially curable primary lesions should be treated by surgery in otherwise well patients. Small localized lesions may be treated by wide excision and split-thickness skin grafting; however, most lesions require more extensive surgery.

Amputation has been the mainstay of treatment for large lesions showing extensive bone invasion. The associated morbidity is poorly

# MALIGNANT MELANOMA

## Introduction

-Melanoma is a tumor that develops as a result of the malignant transformation of melanocytes.

-Melanocytes cells are derived from the neural crest.

-Melanomas usually occur on the skin but can arise in other locations where neural crest cells migrate, such as in the gastrointestinal tract, eye or brain.

-Melanoma predominantly is an adult disease with a peak incidence in the 4<sup>th</sup> decade and **no sex prevalence**.

A patient's risk of developing a second primary melanoma after diagnosis of the first one is **3-5%**.

## Incidence

-The incidence is estimated to be rising rapidly by almost 6% per year.

## Morbidity and Mortality

-Early diagnosis and treatment before metastasis most important in management.

While only 5% of skin cancers are melanomas, about two-thirds of all deaths from skin cancer are due to melanomas

## Etiology/risk factors

### 1. Family history

Positive family history in 5-10% of patients

With at least one affected relative, 2.2-fold higher risk

### 2. Personal characteristics

-Blue eyes, fair and/or red hair, pale complexion

-Skin reaction to sunlight - Easily sunburned

-Freckling

**3. Benign and/or dysplastic melanocytic nevi** - Number rather than size has better correlation

**4. Immunosuppressive states** - Transplant patients, hematologic malignancies

### 5. Sun exposure during adolescence

➤ High UV-B radiation

➤ Low latitude

➤ Number of blistering sunburns

**6. Atypical mole syndrome** (formerly termed B-K mole syndrome, dysplastic nevus syndrome, familial atypical multiple mole melanoma)

## Pathophysiology

Benign melanocytic nevi are markers of melanoma risk rather than direct precursors; however, dysplastic nevi are believed to degenerate over time into melanoma.

Lentigo maligna is believed to be a pre-invasive precursor of lentigo maligna melanoma, and at least 5% progress to malignancy

## Clinical presentation

Patients usually present with skin lesions that have changed in size, color, contour, or configuration. The acronym "ABCDE" is the hallmark of international public awareness campaigns and may be used to remember the physical characteristics suggestive of malignancy. ABCDE stands for

**A-Asymmetry** of shape

**B-Border** irregular

**C-Color** variations (especially red, white, and blue tones in a brown or black lesion) or deepening of pigmentation

**D-Diameter** greater than 6 mm(size),or recent increase in size

**E-Elevated** surface, erosions or ulcerations, bleeding ,crusting

Other symptoms of the lesions

➤ Itching, pain,ulcerate, Bleed, Develop satellites

➤ Location in areas of constant trauma or irritation ,lower limb or the back.

## Pigmented Lesions

-The appearance of a new pigmented nevus should arouse suspicion of **melanoma**.

-About one-third of all melanomas arise from pigmented nevi.

-Since the average white adult has 15-20 nevi, a clear idea of the indications for biopsy or excision should be developed.

Recognition and early excision of atypical pigmented lesions are potentially lifesaving, since surgery is the only effective treatment.

## Benign /common naevi

### Junctional nevi

-Are usually small, circumscribed, light brown or black, flat or only slightly elevated, and rarely contain hair. They are found on all areas of the body, and moles of the mucous membranes, genitalia, soles, and palms are usually of this type.

-The nevus cells are located in the epidermis and at the dermal-epidermal junction.

### Intradermal nevi

-Range from small spots to extensive areas covering much of the body.

-Have variable shape and surface configuration, are usually brown or black, and often are slightly elevated.

-Nevus cells are confined to the dermis, and the lesions are basically benign.

**Compound nevi** have both junctional and intradermal elements.

### Blue nevi

-Are circumscribed, flat or dome-shaped, bluish-black lesions, usually on the hands, face, or arms.

-Although benign, they may closely resemble nodular melanoma and require diagnostic excisional biopsy.

## Premalignant lesions

### Dysplastic nevi

Are larger (5-12 mm) than common nevi.

-They have macular and papular components, are variegated in color (tan-brown) on a pink base, and have indistinct, irregular edges.

-Unlike common nevi, dysplastic nevi are most prevalent on covered body areas, though they can appear anywhere. Any suspicious lesions should be excised. An accurate family history should be obtained in such cases, and first-degree relatives should be examined.

### Congenital nevi

-Occur in about 1% of newborns, and most lesions are small.

-Along with dysplastic nevi, these lesions are now classified as precursors of melanoma.

-Lifetime risk of melanoma developing in large congenital nevi (> 20 cm) is 5-20%, with some increased risk in smaller lesions as well.

-Prophylactic excision is cosmetically prohibitive in many cases, and these lesions must be carefully monitored for suspicious change.

Other pigmented lesions, including basal cell carcinomas, seborrheic keratoses, and actinic keratoses, occasionally resemble melanoma and require biopsy for diagnosis.

### **Biopsy**

-Perform biopsy on all lesions suggestive of melanoma in the thickest part.

-If the resection will not result in a disfiguring defect, excisional biopsy with a 2-cm skin margin and extending to the subcutaneous tissue is suggested for lesions less than 1.5 cm in diameter.

-If the lesion is large or located in an anatomic area where skin removal would cause disfigurement, an incisional biopsy may be performed.

-A full-thickness core punch biopsy in the most raised or irregular area is suggested with the understanding that this area may not be the thickest area.

### **Skin anatomy**

The skin is composed of multiple layers. The epidermis is the most superficial layer, and it contains keratinocytes in various stages of development. Melanocytes are located in the deepest layer of the epidermis. A basement membrane separates the epidermis from the underlying dermis, which is divided into 2 zones, papillary dermis and reticular dermis. Subcutaneous tissue is deep to the reticular dermis.

### **Histological classification**

Four major types of melanomas exist **based on growth pattern**.

1. Superficial spreading melanoma
2. Nodular melanoma
3. Lentigo maligna melanoma
4. Acral lentiginous melanoma

Other more unusual types include mucosal lentiginous melanoma, desmoplastic melanoma, and verrucous melanoma.

#### **1. Superficial spreading melanoma**

Commonest up to 70% of melanomas in white population.

Histologically

- Appear singly or in nests along the dermal-epidermal junction
- May migrate into the stratum granulosum or stratum corneum
- These cells can invade the papillary dermis with an inflammatory lymphocytic infiltrate.

Clinically

- Usually arise in a preexisting dysplastic nevus.
- Typically, this lesion changes slowly over several months to years.
- They are usually flat but may become irregular and elevated in later stages.
- The lesions average 2 cm in diameter with variegated colors and peripheral notches and/or indentations.

#### **2. Nodular melanoma**

They comprise approximately 15-30% of melanoma Histology

- Characterized by extensive vertical growth into the dermis with a minimal radial component.

Clinical

- These tumors typically are blue-black but may lack pigment in some circumstances.
- They are known to arise without a preexisting lesion. May develop at the site of a preexisting nevus and rapidly becomes a palpable, elevated, firm nodule

#### **3. Lentigo maligna melanoma**

-4-10% of melanomas. Show dermal and epidermal changes from sun exposure.

Clinical.

- Larger than 3 cm
- Flat, tan, and begin as small, freckle-like lesions.
- They occur in sun-exposed areas (eg, face and neck of older individuals).
- Marked notching of the borders is present.

-Lentigo maligna melanoma usually arises within a Hutchinsonian freckle (lentigo maligna).

The histologic appearance

- Irregularly shaped hyperchromatic cells that form spindle-shaped nests.
- The epidermis is atrophic
- The dermis contains solar elastosis with chronic inflammatory infiltrates.

#### **4. Acral lentiginous melanoma**

This tumor comprises 2-8% of melanomas in whites and 35-60% of melanomas in dark-skinned people.

Histology

- Occur in dermal-epidermal junction with microinvasion into the papillary dermis.
- The cells have increased melanin granule production, which fills their dendritic extensions.

Clinical

- Occur on the palms of the hands, beneath the nailbeds, and on the soles of the feet.
- They may appear as flat, tan, or brown stains with irregular borders on the palms and soles
- Subungual lesions can be brown or black, with ulcerations in later stages.

No correlation with a worse prognosis is demonstrated for these lesions when tumor thickness is considered.

#### **5. Desmoplastic melanoma**

-These lesions account for approximately 1% of melanoma cases; they are fairly rare.

- They demonstrate a tendency for perineural invasion, especially in the head and neck.

-They have a propensity for higher local recurrence rates but lower regional metastasis rates.

#### **Classification and staging**

Two classification schemes have been developed, based on either:

1. The **vertical thickness** of the lesion in millimeters (**Breslow classification**)
2. The **anatomic level of invasion** of the layers of skin (**Clarks staging**)

Breslow classification scheme is used almost exclusively now since it more accurately predicts future tumor behavior.

The TNM (tumor, node, metastasis) system is used for clinical staging

### **Breslow classification -Thickness of lesion**

Stage 1 Thickness of 0.75 mm or less  
Stage 2 Thickness of **0.76-1.50 mm**  
Stage 3 Thickness of **1.51-4.00 mm**  
Stage 4 Thickness greater than 4.00 mm

### **Clark classification**

Level I - Involves only epidermis (in situ melanoma); no invasion  
Level II - Invades papillary dermis  
Level III – Papillary-reticular dermis interface  
Level IV - Invades reticular dermis  
Level V - Invades into subcutaneous tissue

### **TNM classification**

#### **Primary tumor (pT)**

pTX - Primary tumor cannot be assessed  
pT0 - No evidence of primary tumor  
pTis - Melanoma in situ (Clark level [CL] I)  
pT1 - Tumor 0.75 mm or less in thickness; invades papillary dermis (CL II)  
pT2 - Tumor 0.76-1.50 mm in thickness and/or invades to papillary-reticular dermal interface (CL III)  
pT3 - Tumor 1.51-4.00 mm in thickness and/or invades reticular dermis (CL IV)  
pT3a - Tumor 1.51-3.00 mm in thickness  
pT3b - Tumor 3.01-4.00 mm in thickness  
pT4 - Tumor greater than 4.00 mm in thickness and/or invades subcutaneous tissue (CL V) and/or satellite(s) within 2 cm of the primary tumor  
pT4a - Tumor greater than 4.00 mm in thickness and/or invades subcutaneous tissue  
pT4b - Satellite(s) within 2 cm of primary tumor

#### **Regional lymph nodes (N)**

NX - Regional lymph nodes cannot be assessed  
N0 - No regional lymph node metastasis  
N1 - Metastasis 3 cm or less in greatest dimension in any regional lymph node  
N2 - Metastasis more than 3 cm in greatest dimension in any regional lymph node(s) and/or in-transit metastasis  
N2a - Metastasis more than 3 cm in greatest dimension in any regional lymph node(s)  
N2b - In-transit metastasis  
N2c - Both N2a and N2b

#### **Distant metastasis (M)**

MX - Distant metastasis cannot be assessed  
M0 - No distant metastasis  
M1 - Distant metastasis  
M1a - Metastasis in skin or subcutaneous tissue or lymph node(s) beyond the regional lymph nodes  
M1b - Visceral metastasis.

### **Management**

Surgical therapy-wide margin excision. If the lesion has not spread beyond the primary site, it is potentially curable.

#### **Stage I**

For a T1 lesion, 1-cm excision margins are adequate, but lesions greater than 1 mm require 2-cm margins. Studies demonstrate no improvement in recurrence or survival rates with larger margins of resection. Attempt primary closure and perform skin grafting or flap closure if necessary. For lesions with a depth greater than 1 mm, many recommend sentinel lymph node biopsy at the time of wide local excision (see "Stage II," below).

#### **Stage II**

Perform a 2-cm surgical resection on stage II lesions. No recurrence or survival advantage exists when 2-cm margins are compared to wider margins (4-6 cm).

Smaller resection decreases the need for skin grafting and inpatient hospital stay.

-Perform a complete therapeutic lymphadenectomy on patients with suspected lymph node metastases based on physical examination. This consists of excision of all lymph nodes in the affected regional lymph node basin.

-Consider sentinel lymph node biopsy if no clinically positive nodes are present. Using blue dye and/or radioisotope injected at the site of the primary melanoma, the first-echelon node can be identified within the regional lymph node basin. Send this sentinel node to the pathologist for analysis using routine stains, immunohistochemistry, and even polymerase chain reaction in some centers.

-If the sentinel node is positive, then predictive importance exists of regional lymph node metastases; perform a complete lymph node dissection.

-The correlation is based on the thickness of the primary tumor. If the sentinel lymph node is negative, a 99% chance exists that all others are negative. This procedure is becoming the standard of care for tumors greater than 1 mm in depth.

-Hyperthermic arterial limb perfusion with melphalan for extremity melanomas has been studied as an adjuvant therapy.

One study found it to be beneficial in that it produced higher response rates and overall survival rates than those for surgery alone. Other studies do not demonstrate benefit.

-Adjuvant chemotherapy and/or biological therapy also are under clinical evaluation. One study demonstrated that **high-dose interferon alfa-2b** resulted in prolonged relapse-free survival and overall survival compared to no adjuvant therapy. A follow-up study by the same group demonstrated in preliminary results that high-dose interferon offered patients a relapse-free survival benefit over patients who did not receive adjuvant treatment but not over those who received low-dose interferon.

-Neither high-dose nor low-dose interferon had a significant overall survival advantage compared to observation alone. High-dose interferon can be associated with significant toxic side effects (ie, liver toxicity), and some patients require dose reduction since it may not be well tolerated.

#### **Stage III**

-Wide local excision of the primary tumor with 2-cm margins remains the first-line therapy.

- Skin grafting or other tissue-transfer technique may be necessary to close the defect.

-Perform regional lymph node dissection, since a stage III melanoma represents nodal disease.

- If the nodal status is unknown, consider a sentinel lymph node biopsy to determine if the disease is stage I, II, or III.

-As in stage II disease, a higher rate of treatment failure exists with wide local excision alone in this group compared to stages 0

and I. Many clinical trials currently are exploring similar options as adjuvant therapy.

#### **Stage IV**

Advanced metastatic melanoma usually is refractory to standard therapy; thus, consider these patients for clinical trials.

Some treatments have reported various objective responses, although they usually are short lived. Dacarbazine (DTIC) and the nitrosoureas, carmustine (BCNU) and lomustine (CCNU), produced a 20% objective response rate.

Response rates for interferon alfa and interleukin-2 range from 8-22% and 10-20%, respectively. Currently, other studies in progress are comparing other cytotoxic and biologic drug regimens.

#### **Prognosis**

- 1) Size of the tumor and the depth of invasion. Small tumors with minimal invasion ( $< 0.7$  mm) are usually curable by wide local excision.
- 2) The prognosis is usually favorable in lentigo maligna melanoma and in superficial spreading melanomas without deep invasion. Most nodular melanomas, particularly if ulcerated and associated with deep invasion, have a poor prognosis.
- 3) Lesions of the extremities have a more favorable prognosis than those of the trunk, and women with malignant melanoma have better survival statistics at 5 and 10 years than men.

# NUTRITIONAL SUPPORT

*Nutritional Support may supplement normal feeding, or completely replace normal feeding into the gastrointestinal tract.*

## Benefits of Nutritional Support

- 1. Preservation of nutritional status*
- 2. Prevention of complications of protein malnutrition*
- 3. Reduce Post-operative complications*

## Who requires nutritional support?

- 1-Patients already with malnutrition - surgery/trauma/sepsis*
- 2-Patients at risk of malnutrition Thus*
  - a) Depleted reserves*
  - b) Cannot eat for > 5 days*
  - c) Impaired bowel function*
  - d) Critical illness*
  - e) Need for prolonged bowel rest*

## How do we detect malnutrition?

### Nutritional Assessment

#### *1. History*

*Dietary history, significant weight loss within last 6 months*

- > 15% loss of body weight*
- Compare with ideal weight*
- Beware the patient with ascites/ oedema*

#### *2. Physical examination*

#### *3. Anthropometric measurements*

#### *4. Laboratory investigations*

## Types of Nutritional Support

### *Enteral Nutrition*

### *Parenteral Nutrition*

## Enteral Feeding is best

- 1. More physiologic*
- 2. Less complications*
- 3. Gut mucosa preserved*
- 4. No bacterial translocation*
- 5. Cheaper*

## Enteral Feeding is indicated

- 1. When nutritional support is needed*
- 2. Functioning gut present*
- 3. No contra-indications no ileus, no recent anastomosis, no fistula*

## Types of feeding tubes

### *-Naso-gastric tubes*

### *-Oro-gastric tubes*

### *-Naso-duodenal tubes*

### *-Naso-jejunal tubes*

### *-Gastrostomy tubes*

- Percutaneous Endoscopic Gastrostomy (PEG)*
- Open Gastrostomy*

## **-Jejunostomy tubes**

### Complications of enteral feeding

12% overall complication rate

1. Gastrointestinal complications -Distension, Nausea and vomiting, Diarrhea, Constipation, Intestinal ischaemia

2. **Mechanical complications Malposition of feeding tube**

**Sinusitis, Ulcerations / erosions, Blockage of tubes**

3. **Metabolic complications**

5. **Infectious complications Aspiration Pneumonia, Bacterial**

**Contamination**

### Parenteral Nutrition

**Allows greater caloric intake BUT:**

**-Is more expensive**

**-Has more complications**

**-Needs more technical expertise**

### Indications for parenteral nutrition

1. Abnormal Gut function-cannot absorb

2. Cannot consume adequate amounts of nutrients by enteral feeding

3. Can not retain orally

4. Are anticipated to not be able to eat orally by 5 days

5. Prognosis warrants aggressive nutritional support

### Two main forms of parenteral nutrition

- **Peripheral Parenteral Nutrition**
- **Central (Total) Parenteral Nutrition**

### Peripheral Parenteral Nutrition: Given through peripheral vein

**-short term use**

**-mildly stressed patients**

**-low caloric requirements**

**-needs large amounts of fluid**

**-contraindications to central TPN**

### TPN

### What to do before starting TPN

a)-Nutritional Assessment

**b)-Venous access evaluation -Need venous access to a "large" central line with fast flow to avoid thrombophlebitis**

c)-Baseline weight

d)-Baseline lab investigations

1. Full blood count

2. Coagulation screen

3. Screening Panel # 1

4. Ca<sup>++</sup>, Mg<sup>++</sup>, PO<sub>4</sub><sup>2-</sup>

5. Lipid Panel # 1

6. Other tests when indicated

### How much Fluids to give?

- **Cater for maintenance & on going losses**
- **Normal maintenance requirements**
  - By body weight 30 to 50 ml/kg/day
- **Add on going losses based on I/O chart**
- **Consider insensible fluid losses also**



Eg add 10% for every 0 C rise in temperature

### **Caloric requirements:**

#### **Based on Total Energy Expenditure**

Can be estimated using predictive equations

$$TEE = REE + \text{Stress Factor} + \text{Activity Factor}$$

Can be measured using metabolic chart

#### ***Schofield Equation 35 to 40 kcal/kg/day***

***(2000-3000kcal/day at rest)***

### **How much CHO & Fats?**

Not more than 4 mg / kg / min Dextrose(less than 6 g / kg / day)

Not more than 0.7 mg / kg / min Lipid(less than 1 g / kg / day)

### **How much Fat?**

#### ***Fats usually form 25 to 30% of calories required***

1g of fat = 9 kcal

- Not more than 40 to 50%
- Increase usually in severe stress
- Aim for serum TG levels < 350 mg/dl (3.95 mmol /L)

### **How much CHO?**

#### ***CHO usually form 70-75 % of calories***

1g of CHO= 4kcal

### **How much protein to give?**

#### ***Based on calorie : nitrogen ratio***

#### ***Based on degree of stress & body weight***

#### ***Based on Nitrogen Balance***

Calorie: Nitrogen Ratio

Normal ratio is

***150 cal: 1g Nitrogen***

#### ***Critically ill patients***

***85 to 100 cal: 1 g Nitrogen in***

#### **Based on Stress & BW Protein requirement**

- ***Non-stress patients***      ***0.8 g / kg / day***
  
- ***Mild stress***                      ***1.0 to 1.2 g / kg / day***
  
- ***Moderate stress***                ***1.3 to 1.75 g / kg / day***
  
- ***Severe stress***                      ***2 to 2.5 g / kg / day***

Based on Nitrogen Balance Aim for positive balance of

**1.5 to 2 g / kg / day**

### **Electrolyte Requirements**

*Cater for maintenance + replacement needs*

**Na+** 1 to 2 mmol/kg/d (or 60-120 meq/d)

**K+** 0.5 to 1 mmol/kg/d (or 30 - 60 meq/d)

**Mg++** 0.35 to 0.45 meq/kg/d (or 10 to 20 meq /d)

**Ca++** 0.2 to 0.3 meq/kg/d (or 10 to 15 meq/d)

**PO42-** 20 to 30 mmol/d

### **Trace Elements**

*Total requirements not well established*

*Commercial preparations exist to provide RDA*

- **Zn** 2-4 mg/day
- **Cr** 10-15 ug/day
- **Cu** 0.3 to 0.5 mg/day
- **Mn** 0.4 to 0.8 mg/day

### Complications related to TPN

- **Mechanical Complications**
- **Metabolic Complications**
- **Infectious Complications**

### Mechanical Complications

- Pneumothorax
- Air embolism
- Arterial injury
- Bleeding
- Brachial plexus injury
- Catheter malplacement
- Catheter embolism
- Thoracic duct injury

### Metabolic Complications

**Abnormalities related to excessive or inadequate administration**

**-Hyper / hypoglycaemia**

**-Electrolyte abnormalities**

**-Acid-base disorders**

**-Hyperlipidaemia**

**-Hepatic complications**

**-Biochemical abnormalities**

**-Cholestatic jaundice too much calories (carbohydrate intake too much fat**

**-Acalculous cholecystitis**

### Infectious Complications

- **Insertion site contamination**
- **Catheter contamination**
  - Improper insertion technique
  - Use of catheter for non-feeding purposes
  - Contaminated TPN solution
  - Contaminated tubing
- **Secondary contamination**
  - septicaemia

### Stopping TPN

- **Stop TPN when enteral feeding can restart**
- **Wean slowly to avoid hypoglycaemia**
- **Monitor hypocounts during wean**
  - Give IV Dextrose 10% solution at previous infusion rate for at least 4 to 6h
  - Alternatively, wean TPN while introducing enteral feeding and stop when enteral intake meets TEE

### **Other Additives**

- **Vitamins**
  - Give 2-3x that recommended for oral intake
  - us give 1 ampoule MultiVit per bag of TPN

- MultiVit does not include Vit K
  - can give 1 mg/day or 5-10 mg/wk

#### Other Additives

- **Medications**
  - Insulin
    - can give initial SI based on sliding scale according to hypocount q6h (keep <11 mmol/l)
    - once stable, give 2/3 total requirements in TPN & review daily
    - alternate regimes
      - 0.1 u per g dextrose in TPN
      - 10 u per litre TPN initial dose
  - Other medications

#### TPN Monitoring Clinical Review

##### *Lab investigations*

##### *Adjust TPN order accordingly*

##### Clinical Review

- **Clinical examination**
- **Vital signs**
- **Fluid balance**
- **Catheter care**
- **Sepsis review**
- **Blood sugar profile**
- **Body weight**

##### Lab investigations

- **Full Blood Count**
- **Renal Panel # 1**
- **Ca<sup>++</sup>, Mg<sup>++</sup>, PO<sub>4</sub><sup>2-</sup>**
- **Liver Function Test**
- **Iron Panel**
- **Lipid Panel**
- **Nitrogen Balance**

# OBSTRUCTIVE JAUNDICE/ SURGICAL JAUNDICE

## Definition

Jaundice amenable to surgical treatment –usually due to extra hepatic obstruction in the flow of bile.

## Common causes include:

1. Cholelithiasis/choledocholithiasis
2. Pancreatic head carcinoma
3. Common bile duct strictures mostly iatrogenic-ERCP and cholecystectomy.
4. Cholangiocarcinoma
5. Choledochoceles, Choledochal cysts and congenital atresia
6. Infections
  - Parasitic-Clonorchis sinensis and Ascaris Lumbricoides
  - Opportunistic infections in HIV-Cryptosporidium, CMV, Microsporidia, TB adenitis
7. Other Tumours- Hepatoma, lymphomas, stomach cancer, Colorectal cancer, Ampullary cancer of Duodenum, Gallbladder Adenocarcinoma
8. Pancreatic pseudo- cysts

## **CHOLELITHIASIS**

-Cholelithiasis is the presence of gallstones in the gallbladder.

The spectrum of gallbladder disease in cholelithiasis ranges:

- 1) Asymptomatic gallstones-Up to 90%
- 2) gallbladder colic/biliary colic.
- 3) Cholecystitis
- 4) Choledocholithiasis
- 5) Cholangitis

-Gallbladder colic is pain caused by a stone temporarily obstructing the cystic duct or common bile duct (CBD)

-Cholecystitis is inflammation of the gallbladder from obstruction of the cystic duct or CBD (choledocholithiasis or common bile duct stone)

-Cholangitis is infection of the biliary tree.

## Pathophysiology:

Three types of gallstones exist.

- (1) Cholesterol (most common)
- (2) Pigment-calcium bilirubinate-15%
- (3) Mixed stones

-Impaired gallbladder motility, bile stasis and bile content alteration predispose people to the formation of gallstones

-An increase in the cholesterol concentration or a decrease in the bile salt concentration results in supersaturation of bile with cholesterol, and the formation of a liquid crystalline phase of cholesterol.

-Normally, bile salts (ursodeoxycholic and cheno deoxycholic), lecithin, and phospholipids help to maintain cholesterol as a solute in the bile.

-When bile is supersaturated with cholesterol, it crystallizes and forms a nidus for stone formation.

Cholesterol stones are the most common type of stone

Calcium and pigment also may be incorporated in the stone.

Pigment stones, which comprise 15% of gallstones, are formed by the crystallization of calcium bilirubinate. Diseases that lead to increased destruction of red blood cells (hemolysis), abnormal

metabolism of hemoglobin (cirrhosis), or infections (including parasitic) predispose people to pigment stones.

Black stones are found in people with hemolytic disorders.

Brown stones are found in the intrahepatic or extrahepatic duct and are associated with infection in the gallbladder.

-Usually mild jaundice, deep jaundice suggestive of choledocholithiasis

Crohn's disease, terminal ileal resection, and jejunioileal bypass

## Clinical presentation

### **Biliary colic**

-Due to impaction of a stone in the neck of the gallbladder. The severe pain starts abruptly in the epigastrium, often after a heavy meal, and lasts for several hours. Pain is usually intense for 1 to 4 hours and then resolves slowly, leaving vague residual ache or soreness. (stone drops back into the fundus of the gallbladder or migrates out of the common duct into the duodenum)

-It usually constant and is associated with restlessness, vomiting, and sweating.

-The pain may radiate through to the back rarely to radiate to the shoulder, as in acute cholecystitis.

-General examination may disclose a patient in obvious severe pain (writhing in bed), with a mild tachycardia and normal temperature.

-Abdominal examination shows only mild tenderness in the epigastrium. In contrast to acute cholecystitis, tenderness over the gallbladder is absent.

### **Acute cholecystitis**

-It is usually due to persistent impaction of a stone in the neck of the gallbladder.

-The result is initially a chemical inflammation of the gallbladder wall perhaps due to the mucosal toxin lysolecithin, produced by the action of phospholipase on biliary lecithin.

-This is soon followed by bacterial infection

-Because of cystic duct occlusion the inflammatory process is particularly aggressive and the gallbladder becomes acutely distended, with accompanying lymphatic and venous obstruction.

-The serosa may be covered by a fibrinous exudate and subserosal haemorrhage gives the appearance of patchy gangrene. The gallbladder wall itself is grossly thickened and oedematous and the underlying mucosa may show hyperaemia or patchy necrosis.

-Three grades of inflammation are recognized: acute cholecystitis, acute suppurative cholecystitis, and acute gangrenous cholecystitis.

- Rarely an abscess or empyema develops within the gallbladder, while perforation of an ischaemic area leads to a pericholecystic abscess, bile peritonitis, or a cholecystoenteric fistula.

## Clinical Presentation

-RUQ Pain becomes severe, constant localizing to the right upper quadrant, often radiating to the tip right scapula and hyperalgesia on medial border of scapula (**boas sign**) and shoulder

-Pain is worsened by movement especially respiratory movements.

-**Murphy's sign** -Patient asked to expire then Palpation at intersection of 9<sup>th</sup> intercostals space and mid clavicular line patient then inspires, there is inspiratory arrest during subcostal palpation. Is widely regarded as pathognomonic of cholecystitis. However, positive in chronic cholecystitis, acute hepatitis, and a localized abscess around a perforated duodenal ulcer

-Gallbladder becomes palpable in < 50% of cases due to distension -Nausea and vomiting are usual

-Mild-moderate fever and tachycardia

NB The combination of **jaundice; fever, usually with rigors; and upper quadrant abdominal pain. Charcots triad.** Occurs as a result of cholangitis. When the presentation also includes **hypotension and mental status changes**, it is known as **Reynolds' pentad**

-Itchiness of the body

-Dark urine and pale stool

#### DDx of acute cholecystitis

-Acute pancreatitis, Pancreatic cancer

-Perforation of a peptic ulcer, duodenal cancer

-Biliary colic.

-Cholangitis

-Cholangiocarcinoma

-Hepatocellular carcinoma

-Acute appendicitis

-Acute pyelonephritis

A raised white cell count and serum amylase level may occur in several of these conditions

In the majority of patients with cholecystitis, as with recurrent biliary colic, the treatment of choice is early surgery. In most cases, cholecystectomy done after initial stabilization in 1<sup>st</sup> 24 hrs.-72 hrs

1. IV Fluids 2. NG tube for decompression. 3.IV antibiotics 4. Prepare for surgery 5.Analgesia

#### Risk factors for cholelithiasis

(Fair, fat, fertile, female of forty)

-Female sex

-Dietary influence-fatty diet

-Hypercholesterolemia

-Increased risk in pregnancy

-Oral contraceptive-high estrogen content

- Estrogen replacement therapy

-Obesity

- Rapid weight loss

-Increased hemolysis -sickle cell, thalasemia

-Chronic alcoholism with liver cirrhosis

-Formation of stones increases with age

-Infections (including parasitic)-pigment stones

-Terminal ileal resection, and jejunioileal bypass

-Other illnesses predispose people to gallstone formation.

Burns, Total parenteral nutrition, Paralysis, ICU care and

Major trauma

#### Investigations Cholelithiasis

##### Imaging

1.Abdominal x-ray-show radioopaque stones if present

2.Abdominal ultrasound

3.MRCP(magnetic resonance cholangiopancreatography)

Rarely ERCP-diagnostic and therapeutic.

4.CT-scan, tumors are better shown

5.PTC-Percutaneous trans hepatic cholangiography

6.MR Angiography

##### Laboratory

1.FHG-WBC and differential

2.LFT-Alkaline phosphatase and GGT,AST and ALT

Bilirubin –Total and Direct

3.Coagulation screen-, PTI, INR

(INR acceptable for surgery 1-1.5). Patients need to be given vitamin k prophylaxis 10 mg IM

#### Complications of cholelithiasis

1. cholecystitis(chronic or acute)

2. Acute pancreatitis

3..Acute cholangitis

4.Choledocholithiasis 5. Obstructive jaundice

6.Gallstone ileus

7.Cholangiocarcinoma

8.Liver abscess

9.Biliary-enteric fistula

10.Peritonitis

11.Gallbladder Adenocarcinoma

#### Management of Cholelithiasis

1.Medical therapy

2.Lithotripsy

3.ERCP and sphincterotomy

3.Cholecystectomy –open or laparoscopic

5.Close follow up

#### 1.MEDICAL TREATMENT:

-Gallstone dissolution therapy.

-Cholesterol gallstones can be dissolved by decreasing the cholesterol saturation of bile.

-The naturally occurring bile salt chenodeoxycholic acid and the synthetic ursodeoxycholic acid when given by mouth achieve this.

M.O.A - reducing the hepatic synthesis of cholesterol rather than by expanding the bile acid pool.

Ursodeoxycholic acid is more efficient at reducing the cholesterol saturation of bile.

-Unexplained benefit is that some patients experience relief of their symptoms without much change in the size of the stones.

-Dissolution therapy can only be used for non-calcified stones within a functioning gallbladder

-Less than 20 per cent of patients are suitable candidates

-Unsuitable for patients with acute symptoms and are less effective in obese patients and in stones >15 mm

-Chenodeoxycholic acid (10-15 mg/kg/day)

ursodeoxycholic acid (8-12 mg/kg/day) and up to ( 15 mg/kg/day in obese patients)

-Liver function is carefully monitored and the stones are measured at 6 months.

-If there has been no reduction in size there is no point in continuing with treatment. Eighty per cent of small stones dissolve in 6 months, but larger stones require up to 2 years treatment.

-Recurrence common.

-Useful in patients who are poor anaesthetic risks or who refuse surgery.

#### 2.EXTRA-CORPOREAL SHOCK WAVE LITHOTRIPSY

Fragmentation of both gallbladder and common bile duct stones using high energy sound.

#### Munich criteria for lithotripsy

1-Functioning gallbladder >50% emptying

2-Stones must be radiolucent

- 3-Stones should be less than 30 mm in diameter or 40ml in volume
- 4-Should not be more than three (ideally only one)..

These criteria restrict the use of extracorporeal shock wave lithotripsy to between 5 per cent and 10 per cent of patients.

#### **Contraindications**

- Pregnancy
- Cholecystitis
- Cholangitis
- Pancreatitis
- Gastroduodenal ulcers

Patients are partly immersed in a water bath or placed in contact with a water cushion. An electromagnetic impulse, a piezoelectric generator or a high-voltage spark from an underwater electrode produces a shock wave that is transmitted through water. The acoustic impedance of most body tissue is similar to that of water, while stones have different impedance.

The wave, guided by ultrasound or fluoroscopy to focus directly at the stone, penetrates the body with only slight attenuation. When the wave reaches the stone, tear and shear forces develop, disintegrating it.

Patients generally take an oral gallstone-dissolving drug such as ursodiol -for one week before lithotripsy and continue it for at least three months after disappearance of stone fragments.

#### **3.ERCP and SPHINCTEROTOMY**

Endoscopic retrograde cholangiopancreatography and endoscopic sphincterotomy offer effective minimally invasive effective procedure as the procedure of choice.

#### **4.CHOLECYSTECTOMY-OPEN OR LAPAROSCOPIC**

##### **Open cholecystectomy**

- Dissecting the Calots triangle is the first step in cholecystectomy
- Borders of calots triangle are cystic duct laterally, CBD medially and the inferior aspect of the liver superiorly
- The cystic artery crosses the triangle from left to right, running behind the bile duct and arising from the right hepatic artery.
- Once the cystic duct and artery have been definitely identified, the cystic artery is ligated in continuity and divided between ligatures.
- The cystic duct is dissected as far as is necessary to expose a sufficient length for easy cannulation for operative cholangiography. Any stones in the cystic duct are milked back into the gallbladder and the cystic duct is ligated close to the gallbladder.
- The dissection of the gallbladder from the liver can begin either at the fundus or in the region of the cystic duct.

##### **Complication**

Sudden hemorrhage is usually from the cystic artery. If this cant be controlled by clamping then occluding the hepatic artery with the fingers and thumb of the left hand placed across the entrance of the lesser sac (Pringle's manoeuvre).

##### **Laparoscopic cholecystectomy**

Laparoscopic cholecystectomy is rapidly replacing open cholecystectomy

#### **PANCREATIC HEAD CANCER**

Pancreatic cancer is the second most common gastrointestinal malignancy after colorectal cancer, which affects five times more people.

However, it's the malignancy with the lowest 5-year survival.

##### **Age**

Malignant neoplasms of the pancreas can occur at any age, but they are rare before the age of 40: the mean age of diagnosis is 64 years, after which the incidence increases rapidly.

##### **Risk factors**

- 1.Cigarette smoking-most consistent risk factor
- 2.Diet-Fatty diet
- 3.Association with Diabetes mellitus
- 4.Chronic pancreatitis
- 5.Exposure to several chemical agents, including naphthylamine, benzidine, and petrol has also been linked to pancreatic cancer.
6. Prior surgery in the alimentary tract has also been implicated as a causative factor. Patients with a history of gastrectomy have at least a X3 risk
- 7.Genetic predisposition

##### **Sites**

About 75% are in the head and 25% in the body and tail of the organ.

##### **Pathology**

Malignant tumours of the pancreas can occur in either the exocrine parenchyma or in the endocrine cells of the islets of Langerhans

Exocrine neoplasms are far more common. Adeno-carcinoma accounts for around 80 per cent of pancreatic neoplasms, and is thought to be of ductal origin.

At time of diagnosis more than 85 per cent of these tumours have extended beyond the limits of the organ. Perineural invasion within and beyond the gland is particularly prominent in this type of cancer, although lymphatic spread also leads to early metastasis to adjacent and distant lymph nodes.

The most common sites of extralymphatic involvement are the liver and peritoneum.

The lungs are the most frequently affected of the extra-abdominal organs.

Some rare types of cancers with relatively favorable diagnosis include:

Mucinous cystadenoma-cystadenocarcinoma and the papillary-cystic tumor mostly occur in women. Lymphomas constitute up to 5% of pancreatic cancers are of favorable outcome.

##### **Clinical presentation**

1. Epigastric or left upper quadrant of the abdomen pain ; it has a dull, aching nature and can radiate to the back. The patient may experience some relief when lying or sitting in a flexed or curled position. The pain becomes more severe as the disease advances.
2. Jaundice-Usually insidious in onset, progressive deep jaundice associated with severe pruritus. It is painless in a third of cases.
3. Weight loss, night sweats and generalized fatigue. Anorexia and vomiting may occur in duodenal obstruction.
4. Psychiatric disturbances, particularly depression, which are seen in up to 75 per cent of patients.

5. Gastrointestinal bleeding may also occur; this is most commonly secondary to gastric or duodenal invasion by the tumor.

6. Migratory thrombophlebitis

### **Physical exam**

In the early stages of pancreatic cancer

1. Jaundice.
2. Evidence of weight loss.
3. Hepatomegaly, which reflects bile duct obstruction.
4. A non-tender gallbladder can be palpated in 50 per cent of jaundiced patients (Courvoisier's sign).
5. In advanced disease, ascites and a palpable mass are indicative of an unresectable tumour.

### **Diagnosis**

#### **Imaging**

1. Upper abdominal ultrasonography

Demonstrate pancreatic masses, dilation of the pancreatic duct as well as of the bile duct and gallbladder, hepatic metastasis.

Shows pancreatic tumours to be less echogenic than the surrounding parenchyma, and accompanied by changes in the contour of the gland.

Endoscopic ultrasonography, especially for tumours located in the head of the pancreas.

2. CT-Scan

Important in delineating the tumour and its local spread and staging of the tumour.

3. (ERCP)

is a valuable tool in the differential diagnosis of the cause of obstructive jaundice when pancreatic or other peri-ampullary cancer is suspected.

. Virtually all pancreatic cancers show abnormalities in the pancreatogram, these consisting mainly of stenosis or obstruction of the pancreatic duct.

#### **Laboratory**

1. FPG-Hb level
2. LFT-Alkaline phosphatase and GGT, AST and ALT  
Bilirubin –Total and Direct.
3. Coagulation screen- PTI, INR.
4. An elevated carcinoembryonic antigen (CEA) has been noted in over 70% of patients with confirmed pancreatic neoplasm.
5. The CA19-9 antigen correlate with the degree of differentiation of the tumor and with advancing stages of the disease.
6. Percutaneous fine-needle aspiration of the tumour for cytological examination is invaluable, particularly for patients with advanced stage pancreatic cancer, who otherwise would require surgical exploration. The procedure is usually performed under direct guidance by ultrasonography or CT.

### **Management**

Pancreatoduodenectomy has been the standard operation for carcinoma of the pancreatic head since its demonstration by Whipple in 1935(Whipple surgery)

Variations on this procedure include total, subtotal, and radical pancreatectomy, as well as the pylorus-preserving pancreatoduodenectomy

In unresectable tumors palliative surgery involves by pass surgery. A triple or Double by-pass may be performed

1. Cholecystojejunostomy-By-pass bile
2. Gastrojejunostomy –tumour head of pancreas causes obstruction at duodenum and this to by-pass gastric contents.

3. Jejunojejunostomy-To prevent reflux of bile into the stomach.

### **Chemotherapy**

Single-agent chemotherapy does not provide substantive palliation and improvement in survival for patients with non-resectable pancreatic cancer

The mean survival time after the administration of 5-fluorouracil (5-FU) is less than 20 weeks, with a response rate of only 10-15%. Mitomycin, streptozotocin, ifosfamide, and doxorubicin likewise provide only a 10-25% response rate without improvement in long-term survival.

## PAGETS DISEASE OF BREAST

Chronic eczematous disease on the skin of the nipple and the areola in with an associated intraductal carcinoma of the mammary gland

Proper recognition of this disorder is required to initiate an appropriate workup (eg, skin biopsy) for differentiating it from other benign inflammatory dermatosis and for detecting an underlying breast carcinoma.

A similar disease involving the skin of female and male external genitalia (ie, vulva, glans penis) is known as extramammary PD. Histologic features of mammary PD and extramammary PD are similar; however, the histogenesis and the pathogenesis are different.

### Pathophysiology

-Caused by underlying intraductal carcinoma of the breast with retrograde extension into the overlying epidermis through mammary duct epithelium.

-Malignant Paget cells infiltrate and proliferate in the epidermis, causing thickening of the nipple and the areolar skin. These tumor cells are derived from luminal lactiferous ductal epithelium of the breast tissue. They possess microscopic features of glandular epithelial cells.

-Paget cells have cell markers like underlying breast carcinoma, including tumour markers carcinoembryonic antigen (CEA); Ca 15-3 (milk fat globule protein); some oncogenes (p53, c-erb B-2); and other cell markers, such as epithelial membrane antigen (EMA) and gross cystic disease fluid protein (GCDFP-15) that are found in tumor cells of ductal carcinoma of the breast.

-However, Cytokeratin 7 (CK7) is thought to be specific and nearly 100% sensitive marker for mammary PD.

-Paget cells (large neoplastic cells of glandular origin) infiltrate and spread to the overlying epidermal layers of the nipple and adjacent areola is thro' induction by a mobility factor (heregulin-alpha) that acts through the HER2/NEU receptor that are expressed by paget cells.

Normal epidermal keratinocytes produce and release the mobility factor heregulin-alpha.

The binding of this receptor-mobility factor complexes results in chemotaxis paget cells to the epidermis in the nipple and areola area.

-Nearly 100% of mammary PD cases are associated with an underlying carcinoma, either in situ (intraductal, 10%) or infiltrating cancer (90%).

**History:** Patients with mammary PD present with a relatively long history of an eczematous skin lesion in the nipple and adjacent areas.

Eczematous skin lesions are associated with several symptoms.

- Erythema
- Scaling
- Itching
- Burning sensation
- Ulceration
- Oozing with serosanguinous discharge
- Bleeding

Early symptoms and signs of mammary PD

- Excoriation from itching
- Resolution and recurrence of small vesicles within the skin lesion

- Symptoms of pain, itching, and a burning sensation prompt patients to seek medical attention.

### **Physical:**

- Scaly, erythematous, crusty, and thickened plaques on the nipple, spreading to the surrounding areolar areas, are typical.
- Retraction of the nipple or the presence of palpable nodules indicates an underlying breast cancer; as many as two thirds of patients have a palpable breast tumor
- Serosanguinous discharge from the nipple may be present.
- Usually the lesion is unilateral.

### Differentials

- Bowens disease of the breast
- contact dermatitis
- malignant melanoma
- Drug reaction

### **Investigation**

-Scrape cytology a noninvasive and reliable, rapid diagnostic screening method for mammary PD.

Stain the smears with Papanicolaou or Giemsa stain.

Paget cells

- A high nuclear-to-cytoplasmic ratio
- occasional acinar formation
- intracytoplasmic vacuoles

-Punch, wedge, or excisional biopsy of the lesional skin of the nipple-areola complex to include the dermal and subcutaneous tissue for detailed microscopic examination provides an adequate sample for the accurate diagnosis of mammary PD.

### **Histologic Findings:**

-The epidermis exhibits hyperkeratosis, parakeratosis, and acanthosis.

-Infiltration occurs by variable numbers of large, rounded or ovoid, malignant-appearing tumor cells that are present in all layers of the epidermis.

-The tumor cells contain abundant pale-staining or sometimes eosinophilic cytoplasm and large vesicular-to-hyperchromatic nuclei with prominent nucleoli

### **Management**

Like breast cancer



# PENETRATING ABDOMINAL INJURY

- Gun shot wounds-GSW
- Stab wound
- Blast injury

## Introduction

GSW is caused by a missile propelled by combustion of powder. It implies high-energy transfer and unpredictability of the extent of intra-abdominal injuries. Not only is the missile track unpredictable, but also, secondary missiles such as bone fragments or fragments of the bullet are capable of inflicting additional injuries

Stab wounds are caused by a sharp object penetrating the abdominal wall. This type of injury usually is more predictable with regard to injured organs, but a high index of suspicion must be maintained to avoid overlooking occult injuries.

## **MANAGEMENT**

Management should begin with the scene of accident because in addition to the abdominal injury patients may have sustained injury to the other systems.

ATLS-Advanced Trauma life support protocol should be followed. Triage and safe fast transport should be afforded to the patient.

Triage-Patients most likely to benefit from your intervention. Very badly off patients who may not make it to the nearest hospital are unlikely to benefit and the loudly screaming patients may not be the most critical

### **A. Primary Survey (Life Support)**

- 1. Airway:** guarantee patency and assure that the patient can protect his/her airway.
  - a. Possible C-spine injury – cervical collar and maintain in-line stabilization if intubation required.
  - b. Rapid Sequence Induction (RSI) is appropriate in most patients when needed, possible exceptions below.
  - c. Anterior neck injury, stridor, but no acute airway obstruction: consider awake, fiberoptic intubation or urgent surgical airway under local anesthesia in OR.
  - d. Anterior neck injury, stridor, and acute airway obstruction: consider emergent surgical airway without prior attempts at intubation.
  - e. Head injury – intubate when GCS is less than or equal to 8, consider neurosurgical evaluation prior to intubation when feasible.
  - f. Apnea – immediate orotracheal intubation with in-line stabilization, RSI generally unnecessary.

**2. Breathing:** assess breath sounds bilaterally. Acute causes causing dyspnea

- a. Airway obstruction.
- b. Tension Pneumothorax – immediate needle decompression, followed by tube thoracostomy
- c. Simple Pneumothorax – tube thoracostomy after X-ray confirmation.
- d. Cardiac tamponade-distant heart sounds,distended neck veins

- e. Massive Hemothorax– tube thoracostomy after fluid resuscitation, consider OR thoracotomy for initial chest tube output > 1500 cc.
- f. Open pneumothorax -strap the opening
- g. Flail chest-pack gauze and strap hemothorax,Positive pressure ventilation
- h. Confirm position and function of all chest tubes with CXR.

**3. Circulation:** assess for signs of obvious and occult shock via signs of adequate organ perfusion (mental status, capillary refill, urine production), vital signs, Arterial Blood Gas (ABG) analysis, cold extremity, sweating, pallor

All GSW require emergency laparotomy to look for other abdominal injury. After initial primary survey the patient should be prepared for laparotomy.

If hemodynamically unstable go directly to exploratory laparotomy GXM and carry blood to theatre.

With stable patient other investigations may be done before theatre.

- a. Hemostasis – direct pressure to bleeding wounds; consider immediate, rapid closure for intensely bleeding scalp wounds.
- b. Treat Shock

i. Assess for etiology. Consider hypovolemic shock as most common cause.

Neurogenic shock considered if evidence of spinal cord injury. Shock state should never be assumed to result from head injury.

ii. Initial therapy should consist of 2 liters of isotonic crystalloid solution, failure to respond or shock state that is difficult to correct should illicit a search for bleeding that requires operative or angiographic control.

iv. Cardiac Tamponade – consider diagnosis with shock that does not respond to volume, especially in penetrating chest trauma, neck vein distension may or may not be present. FAST may confirm diagnosis. Consider ED thoracotomy with loss of vital signs; otherwise proceed emergently to OR for pericardial window or sternotomy/thoracotomy.

v. Indications for ED Thoracotomy:

- (a) Penetrating Chest Trauma and one of the following:
- (b) Loss of vital signs (pulse) en route to ED, with electrical activity on presentation.
- (c) Loss of vital signs or sustained systolic BP <90 in ED.

### **4. Disability:**

- a. Calculate GCS. Consider Neurosurgery consult when GCS <14, consider intubation when GCS <9.
- c. Assess for sensory and motor deficits.

### **5. Exposure and environmental modifications**

- a. Remove clothing, log roll to examine back, remove backboard when present.
- b. Maintain normothermia – blankets, warm fluids, warm room.

### **B.Secondary Survey (head to toe exam, adjuncts)**

With focus on abdomen injury

### **History**

Gunshot-range of shot, from front or back, whether shot while fleeing or confrontation, presence of exit wound, bleeding and features of shock-dizziness and confusion or loss of consciousness, sweating.

Abdominal pain or chest pain afterwards. Description of the pain.

- Exact circumstances mechanism of injury
- if gunshot range of shot and how many shots
- If stab the size and type of knife and direction of stab from the side, front or back .Number of stabs
- If there was a struggle and if the assailant twisted the knife and shoved it in.
- Knife left sticking or withdrawn by the assailant of patient
- Immediate period after the stab-abdominal pain location and radiation relieved by bending forward or bending to the side, worsened by cough or walking.
- Whether patient was able to walk or lost consciousness.
- Wound the location, bleeding, intestinal evisceration, fecal matter
- Hematemesis, hematochezia-upper GI or lower GI injury
- Abdominal swelling progressive?
- Chest pain-diaphragmatic injury
- signs of shock if bleeding
- Any other injury other any place in the body.

### **Physical exam**

For physical examination, completely undressing the patient for the primary survey and examining the entire body surface for entry and exit wounds is important. Wounds that look like entry and exit marks actually may be 2 separate entry wounds. Patients brought in as presumed cases of blunt trauma may have penetrating injuries that have been overlooked initially. Carefully record the pattern of the wounds and characteristics. Patients with penetrating abdominal trauma who present with abdominal pain, tenderness, and guarding should undergo exploration without unnecessary delays

### **Stab wound :Indications for laparotomy include**

- a. Hemodynamic instability-vital sings
  - b. Evisceration of the intestines
  - c. Extrusion of feces through the stab wound
  - d. Peritoneal signs.
- Stable patients may be investigated further to determine presence of other visceral injury which is indication for laparotomy.

### **Other examination**

1. Head/Maxillofacial – examine wounds, control bleeding, pupil exam, and assess facial stability.
2. Neck – examine for wounds, palpate for tenderness, deformity, etc...
3. Chest – examine for wounds, etc..., re-evaluate breath sounds.
- 4 Pelvis – examine for wounds, assess for tenderness, avoid excessive motion/compression, x-ray to diagnose fracture.
6. Extremities
  - a. Complete pulse exam.
  - b. Reduce fracture dislocations.
  - c. Splint as needed.
7. Spine – assess for tenderness or deformity.

### **8. Adjuncts:**

- a. Naso/orogastric tube – consider placement in all blunt trauma victims.
- b. Foley – place after rectal exam
- c. X-rays -c-spine, supine CXR and pelvic x-ray for blunt trauma.

### **D. Frequent Re-Assessment:**

1. Vital Signs should be documented no less then every 30 min. until initial work-up is complete and patient has stabilized.

2. Outputs (chest tubes, urinary) – to be recorded at frequent intervals.
3. Patients with shock/blood loss or high base deficit need serial determinations of perfusion status *i.e.* ABG, Hb, Lactate.

### **Imaging Studies:**

**1.Chest radiographs (CXR)** are part of a routine workup in all patients with penetrating abdominal trauma.  
 -In patients with a GSW, findings can reveal hemothorax or pneumothorax secondary to penetration of the missile into the chest.  
 -In patients with thoracoabdominal stab wounds, x-ray films can indicate violation of the thoracic cavity by the stab wound. Air under the diaphragm indicates peritoneal penetration. The cardiac silhouette needs to be evaluated to help rule out penetrating cardiac trauma.

**2.Abdominal radiographs-** predict the pattern of the injury based on the location of the missile. AP erect/ lateral decubitus and Supine views

### **3.Ultrasound (FAST-focused Abdominal Sonography for Trauma)**

-Four views are used in trauma, with visualization of the right upper and lower quadrants, left upper and lower quadrants, pelvis, and pericardium. Ultrasound is up to 95% sensitive for helping detect intra-abdominal hemorrhage but is not sensitive for helping detect hollow organ injuries.

**4. CT scan of the abdomen** with triple contrast (ie, oral, intravenous, rectal) is indicated in stable patients with stab wounds to the flank and back.

Extravasation of the contrast, hematoma, violation of the peritoneum, and free fluid in the abdomen are indications for exploration.

**5.Exploratory Laparoscopy-**Evaluating the injury and can be therapeutic as well

### **Laboratory Tests**

- 1.PCV- Findings may indicate hemorrhage. Acute bleeding frequently does not reflect the hemoglobin level until fluid resuscitation is in progress.
- 2.U/E/C-Renal function and theatre preparation
3. Prothrombin/partial thromboplastin time (Findings may indicate coagulopathy.
4. Arterial blood gas determination (ABG) (all patients): hemodynamic status of the patient. Patients with profound metabolic acidosis may require immediate exploration.
- 5.Type and cross match blood
- 6.Urine dipstick test for blood (all patients): This is a quick test to help evaluate for potential genitourinary injuries
- 7.Serum amylase levels-Pancreatic injury.

### **Diagnostic Procedures:**

#### **1.Nasogastric intubation**

Is needed for all patients to decompress the stomach before endotracheal intubation.

Nasogastric intubation can help detect gastric injury by the presence of blood in the nasogastric tube (NGT).

2. **Foley catheter** insertion (all patients)

can help indicate injury to the urogenital system by the presence of blood. Catheter insertion also enables monitoring of the fluid resuscitation at least 30-50ml/hour urine or 0.5ml/Min

### 3. Diagnostic peritoneal lavage

DPL used in stable patients detect hollow organ injuries. Two commonly accepted methods of DPL are open DPL and closed DPL.

a)-The open method involves exposure of the peritoneum through a small infraumbilical midline incision and insertion of the lavage catheter into the peritoneal cavity under direct vision.

-This step is followed by aspiration, and if aspirate is grossly negative for blood, 1 liter of warm peritoneal dialysate (or isotonic sodium chloride solution) is infused into the peritoneum. Fluid then is retrieved by gravity siphonage

#### Positive DPL:

1. Presence of RBCs (Blunt injury >20,000/ml); But >100,000/ml in penetrating abdominal injury
2. WBCs (>500/mm<sup>3</sup>);
3. Bile or fecal matter
4. Food particles;
5. Lavage fluid from the Foley catheter, NGT, or chest tube.
6. Serum Amylase levels >20 IU/L
7. Alkaline phosphatase >10 IU/L

The closed technique involves blind insertion of the catheter into the peritoneum over the guide wire through a small skin puncture.

4. **Tube thoracostomy**- is indicated in thoraco abdominal injuries

#### **Intra-operative**

-Systematic inspection of the abdominal quadrants

-Hollow organs and solid organs

-Retroperitoneal structures

-Vessels

-Any immediate bleeding is packed first as inspection continues

NB. special attention to the retroperitoneal structures.

#### Injury to small bowel.

Small laceration-freshen the edges and anastomosis.

If circumferential or large defect – resection of the segment and anastomosis

Large bowel injury

Resect the involved part and fashion a colostomy.

Closure of the colostomy after gut preparation in 6 weeks time.

### **SPLENIC INJURY**

#### **Causes;**

1. Blunt abdominal trauma
2. A fall with a diseased or enlarged spleen
3. Fractured overlying ribs - **9, 10, 11**
4. Iatrogenic complications of any surgical procedure especially those in the LUQ when adhesions are present.

#### **Clinical presentation**

-The patient succumbs rapidly from massive haemorrhage, usually as a consequence of trauma

-Initial shock, recovery, signs of late bleeding

#### **Physical examination**

##### Splendid syndrome;

-Pain in LUQ

-**Kerr's sign** - Referred pain felt in the left shoulder or cervical region - Demonstrated 15mins following elevation of the foot of the bed.

-**Balance sign** - On percussion;

Dull note on Left is wider than Right

When the patient is turned on the Right, the dull note persists on the Left. When the patient is turned on the Left, the dull note on the Right side goes

#### **Investigation**

CXR - 2 gastric bubbles

#### **Management**

##### Conservative Management

##### Indications;

Stable patients <55yrs in whom associated abdominal injuries have been excluded

Children - Haemodynamically stable or requires replacement of <½ of estimated blood volume (i.e. Requires <40mL/Kg)

Absence of hilar involvement & massive disruption of the spleen

-Admit & observe for 10-14days, then Bed rest for 1wk

-No strenuous activity for 6-8wks

-No contact sport for 6 months

#### **Surgery**

##### Spleen conserving surgery for Minor capsular parenchymal injuries;

Topical haemostatic agents

Careful compression of the spleen to control bleeding - Can be achieved using the omentum

Parenchymal injuries involving the lower or upper pole may be managed by partial segmental resection.

##### Immediate splenectomy + Polyvalent pneumococcal vaccine;

Severe multiple injuries

Splenic avulsion

Fragmentation or rupture (Delayed rupture of contained subcapsular hematoma can occur several days after splenic injury, usually within **48hrs**)

Extensive hilar injuries

Failure of haemostasis

Peritoneal contamination from GI injury

Rupture of diseased spleen

# PERITONEAL ADHESIONS

## Introduction

### Definition

An adhesion is a band of scar tissue that joins two separate internal body surfaces together.

Adhesions usually occur between two serous membranes which are close together.

Adhesion formation after abdominal and pelvic operations remains extremely common and is a source of considerable morbidity. Adhesion formation occurs following any procedure, including cholecystectomy, gastrectomy, appendectomy, hysterectomy, colectomy, abdominoperineal resection, and abdominal vascular operations. The operations that frequently lead to adhesive obstruction include colon and rectal surgery, gynecologic procedures, and nonelective appendectomy. The incidence of intraperitoneal adhesions ranges from 67 to 93% after general surgical abdominal operations and up to 97% after open gynecologic pelvic procedures.

## Classification

### Congenital and Acquired

#### A. Congenital Adhesions

Are present from birth as embryological anomaly in the development of the peritoneal cavity (vitellointestinal bands, adhesions seen across the lesser sac).

#### B. Acquired adhesions

Are subdivided into inflammatory and post-surgical adhesions.

#### Inflammatory adhesions

Arise after intra-abdominal inflammatory processes, such as

- Appendicitis
- acute cholecystitis
- acute diverticulitis
- pelvic inflammatory disease
- Previous use of an intrauterine contraceptive device.

The true proportion of each of these types is not known, but it has been reported that the majority of adhesions are postsurgical.

#### Post surgical adhesions

Results when injured tissue surfaces following incision, cauterization, suturing or other means of trauma, fuse together to form scar tissue.

Recently, it was found that all patients who had undergone at least one prior abdominal surgery developed one to more than ten adhesions.

Factors associated with the formation of post surgical adhesions include:

1. Trauma
2. Thermal injury
3. Infection
4. Ischemia
5. Foreign bodies.

Multiple other factors, including:

- Tight suturing, where tension within the sutured peritoneum produces ischemia, abrasions
- Exposure to foreign bodies such as talc and powders from gloves, lint from abdominal packs, or fibers from disposable paper items, reactive sutures, intestinal contents, overheating by

lamps, or irrigation fluid, may contribute to postoperative adhesion formation

Such adhesions often contain multiple foreign body granulomas. This suggests a relationships between foreign material, foreign-body granulomas, and adhesion formation.

Microscopic examination of adhesions shows in a large proportion both suture and starch granulomas. Suture granulomas are often found in patients who recently underwent surgery

## Clinical Significance

### Importance and Complications from Intraperitoneal Adhesions

Most common complications of adhesions

- small-bowel obstruction
- difficult reoperative surgery
- chronic abdominal and pelvic pain
- female infertility

Adhesions form between the wound and the omentum in over 80% of the patients, and they may involve the intestines in 50% of the patients

Intra-abdominal adhesions are almost inevitable after major abdominal surgery.

Re-operating through a previous wound can be extremely difficult, risky, and potentially dangerous.

Also, adhesiolysis extends operating time, anesthesia, and recovery time and causes additional risks to the patient such as blood loss, visceral damage including injury to the bladder, enterocutaneous fistulas, and resection of damaged bowel.

### Intestinal obstruction

Adhesions are the most common cause of large and small intestinal obstructions account for approximately one third to one half of all intestinal and for 60–70% of the small-bowel obstructions

Congenital or inflammatory adhesions rarely give rise to intestinal obstructions, except for malrotation].

However, between 49 and 74% of the small-bowel obstructions are caused by post surgical adhesions

Extensive soft adhesions will form within 72 h after laparotomy. These seem most extensive at about 10 days to 2 weeks, by which time they become dense and vascular.

Over 20% of adhesive obstructions occur within 1 month of surgery, and up to 40% occur within 1 year .

Obstruction by adhesions is usually the result of kinking or angulation or by creating bands of tissue that compress the bowel .

Impairment of the local circulation of the small intestine due to strangulation is caused by adhesions in 30% of the cases.

Although it is not clear how often adhesive obstruction recurs after conservative or surgical treatment, it is well known that adhesions create a lifetime risk of intestinal obstruction.

An operation for obstruction due to adhesions carries a higher likelihood of recurrence than a laparotomy for other indications.

The problem of postsurgical adhesions increases with the patient's age, the number of laparotomies, and the complexity of surgical procedures.

Simple adhesive obstruction may be resolved without surgical intervention in the majority of the cases, in contrast to other forms of obstruction. According to recent series, up to 80% of episodes of partial small-bowel obstruction caused by adhesions resolve nonoperatively

Adhesions more likely to become obstructive are those involving the small intestine; however, intestinal adhesions occur less frequently than those involving the omentum. Most of the patients with adhesive intestinal obstructions have been found to have had surgery in the infracolic part of the abdomen, where the loops of small intestine adhere and become obstructed

### Gynecologic Considerations and Sterility

- Abdominal hysterectomy is among the most commonly performed operations contributing to intestinal obstruction associated with postoperative adhesions.
- Myomectomy is associated with a high degree of adnexal adhesions, especially after incision performed on the posterior uterine wall.
- Surgical treatment of gynecologic malignancy, such as ovarian cancer debulking surgery, may commonly be associated with intestinal obstruction either by persistent tumor growth or by postoperative adhesions
- The incidence of adhesions can increase with postoperative radiation therapy .
- Also, postoperative adhesions have been implicated in inadequate distribution of chemotherapeutic regimens when they are given intraperitoneally for treatment of ovarian carcinoma
- Endometriosis is associated with fibrous adhesion formation following conservative surgical procedures and excision of ovarian endometriomas. Fibrous adhesions often form as a response to chronic irritation of the peritoneal surface by the endometriotic implant and its secretory products.
- Fifteen to 20% of female infertility is caused by adhesions peritubal as well as intratubal adhesions may affect tubal motility and ovum transport.
- The slowing of or preventing the embryo from reaching the uterus may lead to either infertility or an ectopic pregnancy. Chronic pelvic pain is one of the sequelae of intra peritoneal adhesions. They were thought to be caused from increased tension, stretching, and traction of pelvic organs which stimulate peritoneal pain receptors and from the restriction of the mobility or expansibility of pelvic organs

### Pathogenesis

Peritoneal healing differs from that of skin. Skin re-epithelialization takes place through proliferation of epithelial cells from the periphery toward the center of the skin wound. By contrast, the peritoneum becomes mesothelialized simultaneously, and regardless of the size of the injury, with new mesothelium developing from islands of mesothelial cells which later proliferate into sheets of cells. Thus, Larger peritoneal wounds remesothelialize about as quickly as small peritoneal wounds, within 5–6 days for the parietal peritoneum and within 5–8 days for the visceral mesothelium

The key site in adhesion formation is the surface lining of the peritoneum. The delicacy of the peritoneal surface and its subsequent susceptibility to damage as well as the rapid rate of remesothelialization within 5–8 days are important factors in adhesion formation.

Various other traumatic factors such as ischemia caused by grafting or suturing of peritoneal defects, the use of retractors by their mechanical effects of pressure, crushing, stripping, excessive handling of the peritoneum, the presence of foreign materials (starch powder), inflammation-induced peritonitis,

intraperitoneal blood, and serosal drying can inhibit fibrinolysis and lead to adhesion formation

Injury or inflammation of the peritoneum triggers a coagulative state at the beginning of post surgical peritoneal repair that releases multiple chemical messengers at the injury site. Leukocytes, mesothelial cells, and fibrin play a major role in this cascade of events.

Also present in the peritoneal cavity prior to surgery is a small amount of fluid that contains macrophages and plasma proteins containing a large amount of fibrinogen

Following surgery, the macrophages increase in number and change function. These postsurgical macrophages are entirely different from the resident macrophages and secrete variable substances including

- cyclooxygenase and lipoxygenase metabolites,
- plasminogen activator
- plasminogen activator inhibitor (PAI)
- collagenase, elastase
- interleukins (IL) 1 and 6, tumor necrosis factor (TNF), leukotriene B4, prostaglandin E2

Postsurgical intraperitoneal macrophages recruit new mesothelial cells onto the surface of the injury. These mesothelial cells proliferate injured area which will lead to peritoneal remesothelialization

The organization of the fibrin gel matrix is of major importance in adhesion formation. This matrix forms in several steps, beginning from fibrinogen to fibrin monomer, then to soluble fibrin polymer, then insoluble fibrin polymer.

This last product interacts with proteins, including fibronectin, to form the fibrin gel matrix.

The fibrin gel matrix includes leukocytes, erythrocytes, platelets, endothelium, epithelium, mast cells, and cellular and surgical debris.

Two damaged peritoneal surfaces coming into apposition while covered with fibrin gel matrix may form an adhesion, not only at the time of surgical injury, but also during the next 3–5 days. Finally, adhesions will mature into fibrous bands containing collagen, elastin fibers, and blood vessels and may be lined by mesothelial cells.

### Management and Strategies for Adhesion Prevention

#### a) Adjusting surgical techniques

- meticulous hemostasis are necessary to avoid presence of free blood and ischemic tissues which provide a source of fibrin.
- careful and delicate handling of the bowel in order to reduce severe trauma
- keeping tissues moist with irrigation
- avoiding large abdominal wounds and unnecessary dissection
- micro and atraumatic instruments to reduce serosal injury.

Surgical techniques summary:

- 1 Tissue injury
- 2 Peritoneal suturing
- 3 Foreign material
- 4 Sponges
- 5 Intraperitoneal blood deposits
- 6 Minimally invasive surgery

#### B). Applying adjuvants to decrease adhesion formation

Antiadhesion barriers basically fall under two main categories: macromolecular solutions and mechanical devices

Barriers

#### *Solutions*

- 1 Crystalloids
- 2 32% dextran 70
- 3 Hyaluronic acid
- 4 HA-PBS/Sepracat
- 5 Carboxymethylcellulose

#### *Solids*

- 1 Autologous peritoneal transplants
- 2 PTFE (Gore-Tex)
- 3 Oxidized-regenerated cellulose (Interceed)
- 4 HA-CMC (Seprafilm)

C). Exclusion of foreign-body material from the abdominal cavity  
Postsurgical coalescing adhesions will form only when both contacting peritoneal surfaces have been traumatized during surgery.

Peritoneal fibrinolytic activity has been hypothesized to play an important role in the pathophysiology of adhesiogenesis. Tissue plasminogen activator (tPA) found in mesothelial cells is an important natural defense against postsurgical adhesion formation. The active enzyme plasmin, which is produced from the inactive plasminogen by the tPA and the urokinase-type plasminogen activator, degrades the fibrin gel matrix into fibrin split products which have no effect on adhesion formation. Fibrinous adhesions are lysed, if local fibrinolysis is sufficient; Hypofibrinolytic activity and increased adhesion formation At sites of surgical or inflammatory injury, increased levels of PAI1 and PAI2 prevent tPA and urokinase plasminogen activator from stimulating plasmin to remove the fibrin gel matrix.

Inadequate blood supply and reduced tissue oxygenation, occurring frequently with surgical injury, inhibit fibrinolysis and decrease fibrinolytic activity, allowing the fibroproliferative structure to persist, leading to fibrovascular adhesion development

#### MANAGEMENT

Manage the complication eg intestinal obstruction.

Surgery may not be done to remove non complicating adhesions as surgery causes more adhesions formation.

Adhesion removal (adhesiolysis) can be done laparoscopically or by open surgery laparotomy.

Some drugs under investigations for the prevention of adhesions include:

- 1 NSAIDs
- 2 Corticosteroids
- 3 Antihistamines
- 4 Progesterone/estrogen
- 5 Anticoagulants
- 6 Fibrinolytics
- 7 Antibiotics

# POST OPERATIVE CARE OF THE SURGICAL PATIENT AND COMPLICATIONS OF SURGERY

## POST OPERATIVE CARE:

The care of a patient who has had a surgical procedure in order to prevent, detect and or handle complications that may arise, with main objectives being reduction in morbidity and mortality from surgery and anesthesia.

## PHASES OF POST-OP CARE:

Three phases are considered.

### Phase I - Immediate post-operative period

#### **This can be in either the recovery ward or the Intensive care unit**

(ICU) depending on the patients needs and the nature of the operation done.

- a) The recovery ward
  - i) usually located within the theatre complex
  - ii) Staff involved – trained nurses assisted by an anaesthetist
  - ii) Equipment – Monitoring facilities which should include today Pulse Oximeters in addition to e.g Bp machines etc

The recovery room should be ready to deal with immediate life threatening complications eg haemorrhage, cardiac arrest

Possibility of immediate re-access to theatre.

- b) ICU or HDU (High Dependency Unit)
  - ii) For patients who need intensive monitoring and life support
  - iii) The ICU should be easily accessible from theatre
  - iv) ICU care involves anaesthetist (or intensive care specialist), the surgeon and well trained ICU nurses, other supportive staff (lab technicians, physiotherapists etc)

### Phase II Intermediate

This could be in the ward for patient who was in the recovery ward or sometimes continued in the ICU or HDU for some category of patients.

### Phase III Late

This involves rehabilitation and follow up.

## DOCUMENTATION AND POST-OPERATIVE INSTRUCTIONS

Proper documentation by the surgeon is important.

The operation notes should be written clearly and should be comprehensive.

### **The data should include**

**Patient details** Name, age, sex hospital registration number

**Date of operation**

**Diagnosis**

## **Operation**

**Incision/approach**

## **Details of the procedure**

Operative findings

Actual surgical procedure performed (detailed)

Name of **the surgeon(s)** and **assistant(s)**

Name of **anaesthetist (s)**

Type of **anesthesia** used eg general , LA regional etc

Name of **scrub nurse**

The **post operative instructions** to be followed by others looking after the patient should include – The observations to be taken and how often eg., blood pressure, respiratory rate, pulse, temp ¼ hourly x 2 hours, then hourly for 4 hours etc.

Special investigations required eg. X-rays of chest, Ultra sound, etc. Blood gases

Post-operative prescriptions for

Drugs (for pain, antibiotics, etc)

Fluids I.V or per other routes

Transfusions etc

Other instructions eg

Feed or not – Nil by mouth

Prop – up in bed

Elevation of limbs etc.

## **POST-OP CARE THEREFORE INVOLVES:-**

A) MONITORING

C) PRESCRIPTIONS OR ORDERS TO MAINTAIN, RESTORE NORMAL HOMEOSTASIS OR AVOID COMPLICATIONS

## **PAIN RELIEF**

FLUID + ELECTROLYTES

NUTRITION

TRANSFUSIONS

ANTICOAGULATION

ANTI ULCER THERAPY ETC

MONITORING

Is necessary to recognize or detect early any physiological derangements or surgical complications that may occur.

It involves:-

a) Clinical observations

Vital signs taken eg ¼ hourly or even continuously

General examination of the patient

System oriented approach – physical examination of the various organ systems.

However parameters normally monitored

Eg CVS - Pulse (rate, volume, rhythm), Bp, CVP, ECG

Renal eg urine output

CNS level of consciousness/alertness etc

RS – RR etc (Blood gases etc)

Others output from drains

**Invasive monitoring. The use of eg in-dwelling probes eg pressure cannulas for BP, CVP, TEMPERATURE probes in the oesophagus or per rectum usually in ICU and may be on a continuous basis.**

b) Lab data

- e.g. – Hb or Hct
  - Blood gas analysis
  - Urea and electrolytes + creatinine

c) Radiological assessments

- eg – CXR's
  - Ultrasound scans
  - CT Scans, MRI etc

Other special tests where indicated eg Echocardiography

**PAIN RELIEF**

Need for pain relief

a) Patient comfort and avoidance of adverse psychological effects.

Its inhuman for anyone to be allowed to undergo pain if something can be done. "Comfort always, cure sometimes".

b) Avoidance or prevention of pulmonary complications

Pain → poor respiratory effort → poor effective coughing → Inability to clear the airways of secretions (low tidal volume)

Alveolar collapse – lung collapse  
 - Bronchopneumonia (-hypoxia etc)

c) Avoidance of DVT (Thrombo-embolism).

Pain leads to reluctance to move venous Stasis → DVT formation → Thrombo-embolism →

**METHODS OF PAIN RELIEF**

1. Intramuscular inj. Of opioids
2. Intravenous infusions
3. Subcutaneous infusions
4. Spinal opioids
5. Rectal opioids
6. Transdermal opioids
9. Local anaesthesia
  - infiltrations
  - nerve blocks
  - epidural

**SOME CONCEPTS IN PAIN RELIEF**

1. PRE-EMPTIVE ANALGESIA - To avoid hypersensitisation to painful sensory input and prolongation of duration of pain beyond duration of tissue injury.
2. PATIENT CONTROLLED ANALGESIA (PCA) - Devise that allows patient to press a button that self administers analgesia when required
3. MULTIMODAL ANALGESIA optimizes the pain control and reduces side effects of the individual analgesic

**FLUID . ELECTROLYTES . NUTRITION**

**Consideration of this is important in patients who**

- Have had GIT surgery
- Are very sick – who are unlikely to start feeding immediately.

**In such cases**

1. I.V. fluids
2. Parenteral nutritional support may be necessary
3. Other forms of enteral feeding eg NG tube, jejunostomy etc

I.V. Fluids:

Most adults will require about 3L/day given usually as 500mls/4 hourly eg as 5% dextrose alternating with Hartmans solution. NB with increased losses eg from drains this is adjusted upwards accordingly.

**Electrolytes**

Esp K+ is important in patients who are not feeding as urine losses continue hence K+ supplementation may be necessary.

Nutritional Supplements

If the non feeding phase is prolonged especially with pre-existing malnutrition, TPN through a central line to give nutritional supplements or other form of nutritional supplementaion.

**OTHERS**

i) ANTIBIOTICS

- As prophylaxis) depending on indications

- As treatment )

ii) **TRANSFUSIONS**

iii) **H2 Antagonists/proton Pump inhibitors for stress ulcers.**

iv) **ANTICOAGULANTS**

Prophylaxis for thrombo-embolic disease

**POST –OPERATIVE COMPLICATIONS**

"Regardless of how technically gifted, bright, and capable a surgeon is, surgical complications are a virtually guaranteed aspect of life".

"The possibility of post-operative complications is a part of every surgeon's thought process – something with which all surgeons will be required to deal".

"strive for the best but be prepared for the worst".

- After every operation, complications may occur which if not recognized early and acted upon can cause morbidity or even death.
- Complications may be related to the disease process per se, or errors of omission or commission in technique.

Can be classified as





- i) Loss of ventilatory drive eg
  - sedative drugs (eg midazolam, anesthesia)
  - Opioids (eg morphine, fentanyl)
- ii) Airway obstruction
  - reduced level of consciousness
  - trauma
  - neck haematomas eg in thyroid surgery
- iii) Respiratory muscle failure
  - Persistent muscle relaxant effect
  - Electrolyte abnormality eg hypokalaemia
  - Splinting of the diaphragm eg due to pain, raised intrabdominal pressure, subphrenic abscess etc.

Pulmonary pathology (Pneumothorax, haemothorax pleural effusion, broncho-spasm).

b) Failure of Gas Exchange

*Alveolar causes*

- Atelectasis
- Pneumonia
- Aspiration
- Pulmonary oedema – eg fluid overload, LV failure
- ARDS
- Pulmonary haemorrhage

*Vascular causes*

- Pulmonary embolism

6 GIT COMPLICATIONS

May include

- i) Post-op nausea and vomiting, may lead to
  - aspiration
  - stress on suture line
 should be controlled by anti-emetics.
- ii) Paralytic ileus – which can be due to
  - infection eg peritonitis
  - mechanical after gut handling
  - electrolyte imbalance eg low K<sup>+</sup>
- iii) hiccups
- iv) Stress ulcers

7. RENAL COMPLICATION

Oliguria or even ARF may occur

Can be due to – low cardiac output (caused by hypovolaemia or cardiac failure). Hypovolaemia may be due to blood loss, dehydration

8. OTHERS

- CARDIAC – Low cardiac output
  - arrhythmias
  - myocardial infarction
- LIVER
- CNS
  - Disorders of consciousness
  - Confusion
  - Psychiatric disturbances,
  - CVA
- ANAESTHETIC COMPLICATIONS
- FEVER (Wind, Water, wound + phlebitis. Etc.
- MODS

## POSTERIOR FOSSA TUMORS

Tumors in the posterior fossa are considered some of the most critical brain lesions. This is due primarily to the limited space within the posterior fossa, as well as the potential involvement of the vital brain stem nuclei.

Some patients should undergo operation on an emergency basis, especially if they present with acute symptoms of brain stem involvement or herniation.

### Occurrence

Posterior fossa tumors are more common in children than the adult populations.

Between 54% and 70% of all childhood brain tumors originate in the posterior fossa.

About 15-20% of brain tumors in adults occur in the posterior fossa.

Certain types of posterior fossa tumors, such as medulloblastoma, pineoblastoma, ependymomas, primitive neuroectodermal tumors (PNETs), and astrocytomas of the cerebellum and brain stem, occur more frequently in children.

### Etiology:

No specific causes for posterior fossa tumors exist. However, genetic factors, such as dysfunction of some tumor suppressor genes (*p53* gene) and activation of some oncogenes, may play a role in their development

**Pathophysiology:** Common types of posterior fossa tumors include the following:

### Cerebellar astrocytoma

Cystic cerebellar astrocytoma comprises about 33% of all posterior fossa tumors in children.

It represents 25% of all pediatric tumors. Average age of presentation is 9 years. Typically, cerebellar astrocytoma presents as a laterally located cyst with a well-defined solid component. It may be solid or cystic. It may be located medially in the vermis or laterally in the cerebellar hemisphere.

### Primary neuroectodermal tumors

PNETs include

- Medulloblastomas
- Medulloepitheliomas
- Pigmented medulloblastomas
- Ependymoblastomas
- Pineoblastomas
- Cerebral neuroblastomas.

These tumors originate from a pool of undifferentiated cells in the subependymal region in the fetal brain. PNETs are second to the cerebellar astrocytoma in frequency, comprising 25% of intracranial tumors in children.

### Medulloblastoma

Medulloblastoma initially arises in the inferior medullary velum and then grows to fill the fourth ventricle, infiltrating the surrounding structures. It falsely was thought to arise from medulloblast cells, which do not exist. It is better included in the family of PNETs.

### Ependymoma and ependymoblastoma

Ependymomas are derived from ependymal cells. They occur more frequently in females, with 50% presenting in people younger than 3 years. Ependymoma has much better prognosis than anaplastic ependymomas (ependymoblastoma). Plastic ependymoma can mold itself to the available spaces inside or outside the ventricle without adhering to the ventricle.

### Choroid plexus papilloma and carcinoma

Choroid plexus papilloma and carcinoma represent 0.4-0.6% of all intracranial tumors. They are more frequent in children than adults (3% of childhood brain tumors). Sixty percent occur in the lateral ventricle and 30% in the fourth ventricle. Third ventricle and cerebellopontine angle are rare locations for this type of tumor. Overproduction of cerebrospinal fluid (CSF) that may reach 4 times more than normal occurs. In most of cases, CSF analysis shows increased protein, xanthochromia, or both.

### Dermoid tumors

Dermoid tumors arise due to incomplete separation of epithelial ectoderm from the neuroectoderm at the region of the anterior neuropore; this usually occurs during the fourth week of gestation. The cyst wall usually includes hair follicles, sweat glands, and sebaceous glands. The cyst grows slowly and gradually becomes filled by desquamated epithelium, sweat, and sebaceous materials. Aseptic meningitis is a sequela of cyst rupture. The cyst is located more commonly in the posterior fossa, at or near the midline. It may be extradural, vermian, or intraventricular. A dermal sinus may be connected to the mass. It may be detected clinically or by MRI.

### Hemangioblastoma

Hemangioblastoma represents about 7-12% of all posterior fossa tumors.

About 70% of hemangioblastomas occurring in the cerebellum are cystic.

Age of presentation is 30-40 years old. Hemangioblastomas are more common in males. Hemangioblastoma may be associated with von Hippel-Lindau disease.

### Metastatic tumors

Three percent and 18% of all cranial metastatic lesions occur in the brainstem and cerebellum, respectively. Primary sites include breast, lung, skin, and kidney. Solitary metastasis is better treated by surgical removal before radiation therapy. Surgery also should be considered in case of radiosensitive original tumors or when the primary source is unknown.

### Brainstem gliomas

Brainstem gliomas constitute 15% of all brain tumors. In children, brainstem glioma represents 25-30% of all brain tumors. Most brainstem gliomas are low-grade astrocytoma.

### Clinical presentation

The clinical presentation depends on the site of the tumor and the rate of growth.

Symptoms may be caused by focal compression of the cerebellum or brain stem centers and increase of intracranial pressure.

compression of the brainstem include

- Cranial nerve dysfunction, as with involvement of the nuclei or tracts of the third, fourth, or the sixth cranial nerves; ocular palsies and diplopia;
- Long tract signs (hemiparesis).

### focal compression of the cerebellum.

- Truncal ataxia is a common finding in midline tumors eg medulloblastomas, ependymomas and vermian astrocytomas. It will be manifested as tendency to fall frequently and walk with a wide based gait.
- Hemi-cerebellar syndrome involves limb ataxia, nystagmus, and dysmetria.
- Tumors that occur in the cerebellar hemisphere, such as metastases, cerebellar astrocytomas, or cystic hemangioblastomas, may present by ataxia of the contralateral limbs. Nystagmus usually occurs late in the course of the disease. Vertical nystagmus suggests a lesion in the anterior vermis, periaqueductal region, or craniocervical junction. Horizontal nystagmus implies involvement of the cerebellar hemisphere.

### Intracranial hypertension causes the following symptoms:

- Headache: It is the most common complaint in patients with posterior fossa tumors.

Associated neck pain, stiffness, or head tilt suggest tonsillar herniation into the foramen magnum. It is insidious and intermittent. It is most severe in the morning or after a nap due to increased intracranial pressure from hypoventilation occurring during sleeping and from recumbency. Headache manifests itself in children as irritability and difficulty to be handled.

- Vomiting: It may be due to generalized intracranial hypertension or due to local irritation of the vagal nuclei in the medulla oblongata or area postrema of the fourth ventricle.

It may be projectile vomiting, usually in the morning.

Vomiting sometimes relieves headache.

- Strabismus: It is secondary to sixth nerve palsies from intracranial hypertension. Third nerve palsies may also occur.
- Blurring of vision due to papilledema
- Meningismus
- Dizziness
- Macrocephaly in children
- Hydrocephalus

Patients presenting with posterior fossa tumors undergo surgery for the following reasons:

1. To decompress the posterior fossa for the purpose of relieving pressure on the brain stem and/or to release intracranial pressure and avert the risk of herniation
2. To histopathologically diagnose the tumor
3. To determine further plan of management depending on the nature of the tumor
4. When indicated, to shunt CSF to the peritoneal cavity to treat obstructive hydrocephalus associated with the tumor

### **Lab Studies:**

1. Complete blood profile: In some cases of hemangioblastoma, erythrocytosis may be found, presumably from erythropoietic factors secreted by the tumor.
2. Coagulation profile
3. Blood grouping
4. Renal function tests
5. Liver function tests
6. Tumor markers 1) carcinoembryonic antigen (CEA), (2) alpha-fetoprotein (AFP), and (3) placental proteins

### **Imaging**

#### **1.Plain x-ray skull**

- It may show signs of chronic intracranial hypertension-sutural diastasis, copper beaten appearance of inner table, signs of herniation-tentorial, erosion of post. clinoid processes
- It may show calcification.
- In case of a dermoid cyst, a bone defect with sclerotic margins may be detected.

**2.CT scanning:** CT scan of the posterior fossa is a limited study because of the artifact produced from the surrounding thick bone.

#### **3.Cerebral angiography**

Cerebral angiography is useful to assess the vascular supply of the tumor.

With the wide availability of MRI, cerebral angiography is no longer used as the first option in brain tumor assessment.

#### **4.Magnetic resonance imaging-superior**

##### **MRI appearance of cerebellar astrocytoma**

Intra-axial, either midline or hemispheric, mass Displacement of effacement of the fourth ventricle  
Hydrocephalic changes due to obstruction of the CSF pathway  
Nodule that usually is enhanced with contrast

**Medical therapy:** Medications, such as Lasix and corticosteroids, are administered before surgery to reduce the effect of edema on the surrounding structures.

### **Surgery**

General operative principles

- Midline incision extends from theinion to the upper cervical vertebra.
- The paracervical and suboccipital muscles are separated by diathermy.
- Craniectomy is performed according to the site and size of the tumor.
- The foramen magnum is opened, and the C1 arch may be removed, especially in tumors extending to, or beyond, the craniocervical junction.
- The dura is opened in Y-shape, with the base upward.
- Bipolar and self-retaining retractors are used for cerebellar cortical incision to expose the tumor.
- Tumors are removed using gentle suction, ultrasonic surgical aspirator.
- The extent of tumor removal should be weighed with the possible risk of complication, especially with tumors adherent to the brainstem.
- The dura is closed in a watertight fashion. Dural grafting may be needed for complete closure

### **Late postoperative care**

#### **Medulloblastoma:**

In this type of tumor, both the brain and spinal cord receive radiation therapy.

Adjuvant chemotherapy also is administered in poor-risk patients with medulloblastoma in the form of cyclophosphamide-cisplatin-vincristine.

#### **Ependymomas**

craniospinal irradiation should be considered because subarachnoid seeding sometimes is found, especially in the anaplastic type and those in the fourth ventricle. Recurrent cases may be administered adjuvant chemotherapy as bischloroethylnitrosourea (BCNU) and dibromodulcitol.

### **Hemangioblastoma**

Complete surgical resection should be the aim of surgery. However, in case of subtotal removal, radiation therapy may be useful to eradicate the residual

Complications of the posterior fossa tumors include the following:

1.Lower cranial nerve dysfunction

Facial nerve palsy ,Deafness

2.Long tract deficits -Hemiplegia ,Hemiparesis ,Sensory abnormalities

3.Hydrocephalus

4.Severe compression of brainstem

5.herniation

### **Other postoperative complications**

Infection ,Prolonged coma ,Shunt obstruction or malfunction,Chest infection ,Deep venous thrombosis, Pulmonary embolism ,Cerebrospinal fluid leak

## PREPARATION FOR THEATRE OF PATIENT WITH TOXIC GOITRE.

Preparation is directed to ensure safe induction of anaesthesia and a trouble free intra- and postoperative course.

Thyrotoxic patients need to be rendered euthyroid and the peripheral effects of high circulating levels of thyroxine blocked. Anti-thyroid drugs used are carbimazole and in case of adverse drug reaction then propylthiouracil (expensive) used. Usually administered for between 3-6 months.

Carbimazole dose of 20 mg TDS (max dose 60 mg/day)

However if not well controlled can increase dose to 30 mg TDS plus steroid.

Propylthiouracil given at a dose of 100mg TDS.

To block the adrenergic effects Propranolol is administered at dose of 40-80 mg BD while monitoring pulse to check on the control.

The antithyroid drugs are stopped 1 week prior to surgery because of their tendency to cause BM suppression and prothrombin deficiency.

Propranolol continued until the morning before surgery or until induction of anaesthesia

For very vascular goiters then Lugol's iodine may be administered from 1 week before surgery to reduce hypervascularity of the gland.

### Base line preparations

1. Hemoglobin estimation
2. U/E/creatinine
3. Chest radiology and ECG
4. GXM blood

### Other investigations required:

#### 1. CT scan

Of the neck and thoracic inlet. Indications

- ✓ In case the enlargement is massive or retrosternal
- ✓ patient shows clinical signs of respiratory embarrassment or superior vena caval obstruction

Indicate the possible need to enter the chest and potential problems which may be encountered on intubation.

#### 2. Indirect laryngoscopy

to determine before surgery whether or not the vocal cords are moving normally. Especially in malignancy and invasion of vocal cords suspected – hoarseness of voice or previous history of thyroid surgery.

### COMPLICATION OF SURGERY

#### **Hypoparathyroidism**

The serum calcium level should be monitored postop. Patients may develop vague lethargy and depression, insidious cataracts, mental deterioration, and psychosis. Hypocalcaemia due to parathyroid deficiency will usually be evident within 1 week of operation

Suspected if the patient appears unduly agitated or depressed or hyperventilates.

#### **Other signs**

**Circumoral tingling** first and most sensitive indicator of a low serum calcium

**Paraesthesia in the fingers and toes** preceding frank tetany is seen when hypocalcaemia is profound.

**Chvostek- Weiss sign** Tapping over the facial nerve will cause contraction of the facial muscles

**Trousseau's sign**- Carpopedal spasm, provoked by occlusion of the circulation to the arm

### **Treatment**

1. Intravenous infusion of 10 ml of 10 % calcium gluconate (given slowly to avoid cardiac arrest in systole)

This infusion may need to be repeated every 4 to 6 h.

2. Oral effervescent calcium should also be administered 4 to 6 g daily, depending on response.

If hypocalcaemia persists, vitamin D (calciferol 25 000-100,000 units) plus 2 to 3 g oral calcium per day are given until a normocalcaemic state is achieved.

Signs and symptoms of hypocalcaemia will recur in these patients at times of metabolic stress, such as pregnancy or the menopause.

### Thyroid crisis

This is now very rare, with the improved methods of control of thyrotoxicosis, but when fully expressed, is characterized by high fever, tachycardia (atrial fibrillation), extreme restlessness, and delirium.

High doses of antithyroid drugs (Neo Mercazole (carbimazole) 30 mg immediately and then 15 mg 8-hourly), plus 1 g of sodium iodide IV should be given promptly.

Propranolol (2 mg) is slowly infused IV, with electrocardiographic control.

Fluid replacement, ice pack cooling, and sedation may help to abort the crisis.

# PRESSURE ULCERS

Also decubitus, from the Latin *decumbere*, means "to lie down." Thus describes ulcers due to prolonged lying on bed not other types of pressure ulcers.

## Frequency

At any given time, 3-10% of hospitalized persons have pressure sores and 2.7% develop new pressure sores. Pressure sores also occur with a higher frequency in neurologically impaired young patients. Immobility and lack of sensation make these patients susceptible to developing pressure sores

## Pathophysiology

The primary pathophysiological event is chronic pressure on skin over a bony prominence.

Tissue ischaemia follows, producing areas of necrosis with ulceration that are susceptible to infection.

Friction and prolonged contact with urine or faeces are additional predisposing factors.

These pressures often are in excess of capillary filling pressure, approximately 32 mm Hg.

Tissues are capable of withstanding enormous pressures when brief in duration, but prolonged pressure leads to ischemia, tissue necrosis and ulceration. Irreversible changes may occur during as little as 2 hours of uninterrupted pressure.

In patients with normal sensitivity, mobility, and mental faculty, pressure sores do not occur. Feedback, both conscious and unconscious, from the areas of compression leads to change in position.

This shifts the pressure from one area to another prior to any irreversible ischemic damage to the tissues.

The elderly, the neurologically impaired, and patients hospitalized with acute illness are more at risk.

## Sites

Anatomically, the hip and buttock region account > 67% of all pressure sores. Most common areas:

- Ischial tuberosity
- Trochanteric
- Sacral locations

The lower extremities account for an additional 25% of all pressure sores with malleolar, heel, patellar, and pretibial locations being most common.

The remaining approximately 10% of pressure sores may occur in any location that experiences long periods of uninterrupted pressure. Nose, chin, forehead, occiput, chest, back, and elbow are among the infrequent sites for pressure ulceration.

There is no surface of the body that may be considered immune to the ischemic effects of unrelieved pressure, but ulcers most often occur over a bony prominence.

## Mortality/Morbidity

Pressure sores are listed as the direct cause of death in 7-8% of all patients with paraplegia.

## Sex

Most younger individuals suffering from pressure ulceration are males. This reflects the greater number of men suffering

traumatic spinal cord injuries. In the older population, most patients are women because of their survival advantage over men

## Age:

The prevalence of pressure sores appears to have a bimodal age distribution. A small peak occurs during the third decade of life, reflecting ulceration in those with traumatic neurologic injury, and a much larger peak occurs during the eighth decade of life. Two thirds of pressure sores occur in patients older than 70 years.

## History

When initially evaluating a patient with pressure ulceration, it is important to note the following information from the history: -

- Overall physical and mental health including
- Presence of neurological deficits-sensory loss hx of spinal trauma or head trauma, pelvic fractures etc.
- Fecal and urinary continence
- Presence of spasticity or flexion contractures
- How long the admission has been and nursing care-turning, ripple mattress, pneumatic mattress
- Average number of hours spent sitting or lying down per day.
- Prior hospitalizations, operations, or ulcerations
- Chronic illness hypertension and diabetes mellitus
- Diet and recent weight changes
- Medications and allergies to medications
- Tobacco, alcohol, and recreational drug use
- If developed at home
- Place of residence and the support surface used in bed or while sitting
- Level of independence, mobility, and ability to comprehend and cooperate with care
- Underlying social and financial support structure
- Presence of specific cultural, religious, or ethnic issues
- All cases presence of signs or symptoms related to the current ulceration

- Pain
- Fever
- Discharge
- Odor

Natural history of the present ulcer

- Length of time the ulcer has been present
- Local treatments employed

## Physical:

A thorough physical examination is necessary to evaluate the overall state of health, comorbidities, nutritional status, and mental status of the patient.

The level of comprehension and cooperation indicate the intensity of nursing care that will be required.

The presence of contractures or spasticity is important to note and may help identify additional areas at risk for pressure ulceration.

Neurological examination especially sensory examination

Following the general physical examination, turn attention to the wound.

Adequate examination of the wound may require the administration of intravenous or oral pain medications to ensure patient comfort.

Chronic pain is common among these patients and may be exacerbated by ulcer examination.

**Shea**, the most widely accepted system describe the degree of tissue damage observed at the specific time of examination

### Stage I

Represents intact skin with signs of impending ulceration.

Initially, this presents as blanchable erythema indicating reactive hyperemia.

Reactive hyperemia should resolve within 24 hours of the relief of pressure. Warmth and induration also may be present.

Continued pressure creates erythema that does not blanch with pressure and may well represent the first outward sign of tissue destruction.

Finally, the skin may appear white from ischemia.

### Stage II

Represents a partial thickness loss of skin involving epidermis and possibly dermis. This lesion may present as an abrasion, blister, or superficial ulceration.

### Stage III

Represents a full thickness loss of skin with extension into subcutaneous tissue but not through the underlying fascia.

This lesion presents as an ulcer with or without undermining of adjacent tissue.

### Stage IV

Represents extension into muscle, bone, tendon, or joint capsule.

Osteomyelitis with bone destruction and dislocations or pathologic fractures may be present. Sinus tracts and severe undermining commonly are present

NB

The presence of an eschar or necrotic material does not allow adequate assessment of wound depth until the eschar or necrotic material is removed.

Necrosis may begin deep within the tissues in the absence of an outward sign thus just small ulceration on the skin may just be tip of the iceberg.

Examination of ulcer

- Size of the skin opening
- Floor
- Edges
- Presence of any surrounding maceration or induration.
- presence or absence of foul odors
- wound drainage
- soilage from urinary or fecal incontinence.

### Etiology

1. **Impaired mobility** is probably the most common reason patients are exposed to uninterrupted pressure. Predisposed patients are

- Neurologically impaired
- Heavily sedated or anesthetized
- Restrained
- Demented
- Traumatic injury such as a pelvic or femur fracture

These patients are incapable of assuming the responsibility of altering their position to relieve pressure.

Moreover, this immobility, if prolonged, leads to muscle and soft tissue atrophy, decreasing the bulk over which bony prominences are supported.

2. **Contractures and spasticity** often contribute by repeatedly exposing tissues to trauma through flexion of a joint.

Contractures rigidly hold a joint in flexion, while spasticity subjects tissues to repeated friction and shear forces.

3. **The inability to perceive pain**, from neurologic impairment or medication, contributes to pressure ulceration by removing one of the most important stimuli for repositioning and pressure relief.

Conversely, pain from surgical incisions, fracture sites, or other sources may make the patient unwilling to change position.

4. **Skin quality** also affects whether pressure leads to ulceration. Paralysis, insensibility and aging lead to atrophy of the skin with thinning of this protective barrier.

A decrease in epidermal turnover, flattening of the dermal-epidermal junction, and loss of vascularity occur. The skin becomes more susceptible to minor traumatic forces, such as friction and shear forces typically exerted during the moving of a patient. Trauma causing de-epithelialization removes the barrier to bacterial contamination and leads to transdermal water loss, creating maceration and adherence of the skin to clothing and bedding.

### 5. Incontinence or presence of a fistula

Cause the skin to be continually moist, leading to maceration.

Also chemical irritation from the urine, soiling has the effect of regularly introducing bacteria to the wound.

6. **Bacterial contamination** from improper skin care or urinary or fecal incontinence, while not truly an etiologic factor is an important element to consider in the treatment of pressure sores and can delay wound healing.

These wounds serve as warm, moist reservoirs for bacterial overgrowth where antibiotic resistance may develop as a result of the injudicious use of antibiotics.

Pressure sores may progress from being simply contaminated, as all open wounds are, to being seriously infected, which indicates tissue invasion by bacteria. This may lead to uncommon but life-threatening complications such as sepsis, myonecrosis, gangrene, or necrotizing fasciitis

### 7. Malnutrition, hypoproteinemia, and anemia

Reflect the overall status of the patient and can contribute to tissue vulnerability to trauma as well as cause delayed wound healing.

Poor nutritional status certainly contributes to the chronicity often seen in these lesions and inhibits the ability of the immune system to prevent infections. Anemia indicates poor oxygen carrying capacity of the blood. Vascular disease and hypovolemia also may impair blood flow to the region of ulceration.

### Lab Studies:

- 1) CBC with differential
- 2) Electrolyte determination
- 3) Evaluation of nutritional parameters-Albumin, Prealbumin, Transferrin, Serum protein level
- 4) Urinalysis and culture in the presence of urinary incontinence
- 5) Stool examination for fecal white blood cells and *Clostridium difficile* toxin when pseudomembranous colitis may be the cause of fecal incontinence
- 6) Blood cultures if bacteremia or sepsis is suggested
- 7) Pus swab for the ulcer for M/C and sensitivity
- 8) Biopsy the chronic ulcers to rule out underlying malignancy

### TREATMENT

#### Medical Care

##### 1. Relieve pressure

The first step in healing is to reduce or eliminate the cause, ie, pressure. Turning and repositioning the patient remains the cornerstone of prevention and treatment through pressure relief. Perform this every 2 hours

##### 2. Wound cleaning



The wound must be kept clean and free of urine and feces. The surrounding intact skin must be kept clean and dry. This should be done through frequent inspection and cleansing. Urethral catheterization and urinary incontinence secondary to urinary tract infection should be treated with antibiotics. Manual disimpaction and the addition of stool bulking agents to the diet may relieve overflow fecal incontinence. Fecal incontinence secondary to diarrhea may be related to an infectious cause such as *C difficile* pseudomembranous colitis that will resolve with appropriate antibiotics.

### 3. Wound dressings

Vary with the state of the wound, and the goal is to achieve a clean, a moist environment to facilitate healing wound with granulation tissue and reepithelialization. Topical antibiotics may be applied with the dressing in infected wounds e.g. silver sulfadiazine.

### 4. Antibiotics

Bacterial contamination must be assessed and treated appropriately. Antibiotics also are indicated when accompanying osteomyelitis, cellulitis, bacteremia, or sepsis is present.

### 6. Relieve Spasticity

Use diazepam, baclofen, or dantrolene sodium. Refractory patients are candidates for surgical release of the contractures or neurosurgical ablation.

### 7. Nutrition

Nutritional status should be evaluated and optimized to ensure adequate intake of calories, proteins, and vitamins. This may require dietary supplements, enteral feedings, or even parenteral feedings.

### 8. Adequate Analgesia.

These are directed at preventing vasoconstriction in the wound and optimizing the oxygen carrying capacity of the blood.

Other important aspects include:

- a. Cessation of smoking
- b. Maintenance of adequate blood volume and correction of anemia.

By medical management, most of the signs of impending ulceration of stage I pressure sores will resolve. Approximately 75% of stage II pressure sores also will heal with conservative management.

However, stage III and IV ulcers are much less likely to heal spontaneously and often require a surgical approach.

### Surgical Care

Even with optimal medical management, many patients require operative debridement, diversion of urinary or fecal stream, release of flexion contractures, neurosurgical ablation of spasticity, amputation, or reconstruction.

1. **Debridement** is aimed at removing all devitalized tissue that serves as a reservoir for ongoing bacterial contamination and possible infection.

2. **Urinary or fecal diversion** to prevent frequent bathing of the wound with urine or feces may be necessary in difficult instances where incontinence or fistulas do not resolve with medical therapy.

3. **Release of flexion contractures** or neurosurgical ablation of spasticity may assist with positioning problems and make tissues over the involved joint less susceptible to further injury.

4. **Amputation** may be necessary for a nonhealing extremity wound in a patient who is not a candidate for reconstructive surgery.

### 5. Goals of pressure sore reconstruction

- Improvement of patient hygiene and appearance
- Prevention or resolution of osteomyelitis or infection
- Reduction of fluid and protein loss through the wound
- Prevention of future malignancy (Marjolin ulcer).

Well-vascularized pad of tissue should be placed in the wound to eliminate dead space, enhance perfusion, decrease tension on the wound closure provide a new source of padding over the bony prominence.

### Complications of pressure sores

1. Autonomic dysreflexia is a disordered autonomic response to specific stimuli. Includes sweating, flushing, nasal congestion, headache, intermittent hypertension, piloerection, and bradycardia.

The most common precipitating factors are bladder distension and fecal impaction.

2. Osteomyelitis

3. Pyarthrosis of the hip joint can occur with communication of ischial or trochanteric ulcers.

4. Recurrence of pressure sores due to patient noncompliance, seromas, hematomas, wound infections, and dehiscence.

5. Pressure sores can also erode into the urethra causing a urethral fistula. Management involves urinary diversion. Pressure sore reconstruction can be considered once the fistula has healed.

6. Marjolin ulcer has been used interchangeably for malignant transformation of any chronic wound, including pressure sores, osteomyelitis, venous stasis ulcers, urethral fistulas, anal fistulas, and other traumatic wounds.

From pressure sores is usually more aggressive than any other chronic wound.

# PRIMARY OPEN ANGLE GLAUCOMA

## History:

The initial patient interview is extremely important in the evaluation for POAG or other ocular diseases secondarily causing elevated IOP.

Because of the silent nature of the disease, patients usually will not present with any visual complaints until late in the course.

Therefore, attention should be given to the following:

-History of eye pain or redness

-Multicolored halos

-Headache

-Previous ocular disease including

- Cataracts
- Uveitis
- Diabetic retinopathy
- Vascular occlusions

-Previous ocular surgery, including photocoagulation or refractive procedures

-Ocular/head trauma

-Past medical history - Any surgeries or pertinent vasculopathic systemic illnesses

-Current medications, including any hypertensive medications (which may indirectly cause fluctuation of IOP) or topical/systemic corticosteroids

-Risk factors for glaucomatous optic neuropathy

- Family history

Possible implications are as follows:

Systemic cardiovascular disease

Diabetes mellitus

Migraine headache

Systemic hypertension

Vasospasm

Anecdotal risk factors Obesity\_ Smoking\_ Alcohol \_History of stress\_ Anxiety

## Physical:

- Compare visual acuity with previous known acuities. If declining, rule out secondary causes of vision loss, whether it is from cataracts, age-related macular degeneration (ARMD), ocular surface disorders (eg, dry eye), or adverse effects from topical medications (especially if using miotics).
- Pupils - Test for presence/absence of afferent pupillary defect (Marcus Gunn pupil).
- Slit lamp examination of the anterior segment
  - Cornea - Signs of microcystic edema (found only with acute elevation of IOP); keratic precipitates, pigment on endothelium (Krukenberg spindle); congenital anomalies
  - Anterior chamber - Cell or flare, uveitis, hyphema, angle closure
  - Iris - Transillumination defects, iris atrophy, synechiae, rubeosis, ectropion uveae, iris bombe,

difference in iris coloration bilaterally (eg, Fuchs heterochromic iridocyclitis), pseudoexfoliation (PXF) material

- Lens - Cataract progression (ie, signs of phacomorphic glaucoma, pseudoexfoliation, phacolytic glaucoma with a Morgagnian cataract)
- Optic nerve/nerve fiber layer - Stereoscopically examine for evidence of glaucomatous damage, including the following: cup-to-disc ratio in horizontal and vertical meridians (describe by color and slope, and diagram, if needed); appearance of disc; progressive enlargement of the cup; evidence of nerve fiber layer damage with red-free filter; notching or thinning of disc rim, particularly at superior and inferior poles (because nerve fibers at the superior and inferior poles of the disc can often be affected first); pallor; presence of hemorrhage (most common inferotemporally); asymmetry between discs; parapapillary atrophy (possible association with development of glaucoma); or congenital nerve abnormalities.
- Fundus - Other abnormalities that could account for any nonglaucomatous visual field defects or vision loss present (eg, disc drusen, optic pits, retinal disease), vitreous hemorrhage, or proliferative retinopathy.
- Baseline stereo fundus photographs for future reference/comparison; if unavailable, record representative drawings.
- Tonometry
  - IOP varies from hour-to-hour in any individual. The circadian rhythm of IOP usually causes it to rise most in the early hours of the morning; IOP also rises with a supine posture.
  - When checking IOP, measurements for both eyes, the method used (Goldmann applanation is the criterion standard), and the time of the measurement should all be recorded.
  - Previous tonometry readings, if available, should be reviewed (eg, Is the reading reproducible? What method was used to obtain the reading? What time of the day was it? Where does it fall on the diurnal pressure curve? Do both eyes have similar measurements?).
  - In obese patients, the possibility of a Valsalva movement causing an increased IOP should be considered when measured in the slit lamp by Goldman applanation. Measurement should be tried via Tono-Pen, Perkins, or pneumotonometer with the patient resting back in the examination chair.
  - A difference between the 2 eyes of 3 mm Hg or more indicates greater suspicion of glaucoma. An average of 10% difference between individual measurements should be expected. The measurements should be repeated on at least 2-3 occasions before deciding on a treatment plan. The measurement should be completed in the morning

and at night to check the diurnal variation, if possible. (A diurnal variation of more than 5-6 mm Hg may be suggestive of increased risk for POAG.) Early POAG is suspected strongly when a steadily increasing IOP is present.

- Perform gonioscopy to rule out angle-closure or secondary causes of IOP elevation, such as angle recession, pigmentary glaucoma, and PXF.
  - Check the peripheral contour of the iris for plateau iris, and examine the trabecular meshwork for peripheral anterior synechiae, as well as neovascular or inflammatory membranes.
  - The Schlemm canal may be seen with blood refluxing through the canal into the posterior trabecular meshwork. This possibly could indicate elevated episcleral venous pressure, with such conditions as carotid-cavernous fistula, Graves orbitopathy, or Sturge-Weber syndrome needing to be ruled out.
  
- Pachymetry: Pachymetry is used to measure CCT. According to the OHTS, pachymetry is now the criterion standard for every baseline examination in patients who are at risk for or suspected of having glaucoma (see [Image 11](#)).
  
- Visual field testing
  - Perform automated threshold testing (eg, Humphrey 24-2) to rule out any glaucomatous visual field defects.
  - If the patient is unable to perform automated testing, Goldmann testing may be substituted.
  
- Caveats about visual field analysis are outlined below. (See [Other Tests](#).)

## PROBLEMS OF ILEOSTOMIES

Physiologic changes after ileostomy are due to the loss of the water- and salt-absorbing capacity of the colon. If the small bowel is free of disease and extensive resection has not been done, an ileostomy puts out 1-2 L of fluid per day initially.

The volume of effluent diminishes to between 500 and 800 mL/d after a month or two.

This loss of fluid is obligatory and is not reduced by manipulations of diet.

Obligatory sodium losses are about 50 meq/d and potassium losses are also increased.

Healthy ileostomy patients have low total exchangeable sodium and potassium but normal serum electrolyte concentrations. The depletion, therefore, is primarily intracellular.

The patient with an ileostomy is susceptible to acute or subacute salt and water depletion manifested by fatigue, anorexia, irritability, headache, drowsiness, muscle cramps, and thirst. Patients should be counseled to salt food liberally, but salt tablets will not be required in usual circumstances. Patients with unusually high ileostomy outputs may need supplemental potassium in the form of bananas or orange juice. Water intake in response to thirst may not be adequate to maintain hydration, and patients should consume enough water to keep the urine pale or to maintain a urine output of at least 1 L/d.

Nutritional loss depending on the amount of the small intestine resected.

### Other complications

- (1) **Intestinal obstruction:** Obstruction may be due to adhesive bands, volvulus, or paraileostomy herniation of bowel.
- (2) **Stenosis:** Circumferential scar formation at the skin or subcutaneous level is usually at fault. Stenosis may cause profuse watery discharge from the ileostomy. Treatment requires a minor local procedure to release the scar.
- (3) **Retraction:** The stoma should protrude 2-3 cm above the skin level to avoid leakage beneath the ileostomy pouch. Retracted stoma functions poorly and should be revised.
- (4) **Prolapse:** This is uncommon if the mesentery has been sutured to the parietal peritoneum.
- (5) **Paraileostomy abscess and fistula:** Perforation of the ileum by sutures, pressure necrosis from an ill-fitted appliance, or recurrent disease may cause abscess and fistula.
- (6) **Skin irritation:** This is the single most common complication of ileostomy and is due to leakage of ileal effluent onto the peristomal skin; it is usually minor but can be very severe if neglected. Treatment is directed toward the cause of leakage, usually an ill-fitted pouch. Protection of the skin by a barrier material (eg, karaya [Sterculia] gum, or a variety of synthetic products) will resolve the problem.
- (7) **Offensive odors:** Odor-proof appliances, commercial deodorants placed in the appliance, and attention to diet usually control the problem.
- (8) **Diarrhea:** Excessive output should be reported to the physician promptly, and supplemental water, salt, and potassium should be given. Codeine, diphenoxylate with atropine (Lomotil), or loperamide (Imodium) may slow the output. Recurrent intestinal disease, bowel obstruction, or ileostomy stenosis should be looked for.

9. **Urinary tract calculi:** Uric acid and calcium stones occur in about 5-10% of patients after ileostomy and are probably the result of chronic dehydration due to inadequate fluid intake.

Ileostomy is associated with lower urinary pH and volume and higher urinary concentration of calcium, oxalate, and uric acid than an intact gastrointestinal tract

10) **Gallstones:** Cholesterol gallstones are three times more common in ileostomy patients than in the general population. Altered bile acid absorption preoperatively may be responsible.

(11) **Ileitis:** Patients who develop inflammation of the ileum just proximal to the ileostomy usually have recurrence of their original inflammatory bowel disease. Stenosis of the stoma is another cause.

# PROSTATE CANCER

## DIAGNOSIS AND MANAGEMENT

### Symptoms and Signs:

Stage 1 carcinoma of the prostate presents no physical signs (it is non-palpable) may be picked TRUS or PSA monitoring.

Stage 2 or higher disease has a hard nodule on the prostate that can be felt during rectal examination.

Only advanced disease (stage 3 and 4) gives rise to S/S usually within 6 months

- 1) Obstructive symptoms incomplete emptying, weak stream, intermittency, strain
- 2) Irritative symptoms urgency, frequency, nocturia, urge incontinence
- 3) Advanced disease with complications
  - Renal failure with lower limb edema
  - Limb swelling due to lymph edema
  - Pelvic pain & haematuria
  - Lumbar masses-hydronephrosis
- 4) Evidence of metastases/advanced disease.
  - Weight loss, night sweat, Anemia
  - Bone pain (in the lumbosacral area)
  - Acute neurologic deficit in the lower limbs-prolapse disc
  - Pathological fracture

### DRE

#### Signs of malignancy

- 1) Prostate enlargement .If cant get above>70 g
- 2) Gland asymmetry
- 3) Median sulcus obliteration
- 4) Fixity of prostate mucosa and the overlying rectal mucosa
- 5) Nodularity
- 6) Woody hard prostate
- 7) Tenderness
- 8) Blood on the examining finger

Since only the peripheral zone is accessible to digital rectal examination, tumors confined to the central or transitional zones may be missed.

### Laboratory investigations

1. **FHG**-Extensive metastases may have anemia due to bone marrow replacement by tumor or anaemia of chronic disease.

-**Urinalysis-r/o UTI**

2. **U/E/C**-Uremia due to obstructive uropathy-CRF hydronephrosis.

3. **Alkaline phosphatase**-in bone metastasis

Osteoblastic reaction in bone due to metastasis.

Acid phosphatase increase in relation to the volume of the prostate.

4. **PSA**-Both diagnostic and for to get baseline to follow up during treatment.

PSA is age dependent: Normal below 4ng/L

0-49yrs below 2.5 ng/L

50-59yrs below 3.5 ng/L

60-69yrs below 4.5ng/L

>70yrs below 6.5

### Chances of CA based on PSA figures

0-4 ng/L 5 % risk

4-10 ng/L 20%

10-20 ng/L 50-60%

>20 ng/L 70%

In the grey zone of 4-10ng/L then

### i) Ratio of free to total PSA level.

Free PSA

Total PSA

>**15 % BPE**

<**15 % Prostatic cancer**

Carcinoma less free PSA than BPE thus less ratio.

PSA bound to alpha 1-chymotrypsin and alpha2-macroglobulin.

### ii) PSA velocity

Rate at which the PSA level rises per year if done serially.

Rise by 0.67 ng/L per year.

### iii) PSA Density

PSA level

Volume of the prostate

### Imaging Studies

#### 1. Transrectal ultrasound

Has become the most accurate diagnostic imaging study, revealing typical hyper-echoic peripheral zone. Also

- a) Size of the prostate
- b) Can be used to guide biopsy
- c) Local staging

2. **Abdominal U/S** state of kidney and ureters in advanced disease. Estimation of residual urine.

2. **An intravenous urogram (IVU)** may reveal urinary retention or distal ureteral obstruction. Extensive lesions may exhibit a ragged-edged filling defect in the bladder base

4. **Lumbosacral x-ray** may reveal metastases in the lumbosacral spine or ilium

5. **CT- Scan** of the pelvis may show enlarged prostate and large pelvic or para-aortic lymph nodes. Used in staging

6. **MRI** -more helpful in pelvic staging of prostate cancer than is CT scan.

Useful in neurological deficits due to metastasis

7. **Bone Scan** Isotopic (technetium Tc 99m) bone scan will rule out bone metastases

8. **CXR** may identify uncommon lung metastases but more often shows typical osteoblastic metastases in the thoracic spine or ribs

### Differential diagnosis

1. Bladder neck stenosis- trauma, congenital

2. Carcinoma bladder neck

3. Bladder calculi

4. Neurogenic bladder

5. Bladder clots

6. Urethral strictures

7. Urethritis -UTI

9. Benign prostatic enlargement

10. Chronic prostatitis

11. Prostatic calculi

### Biopsy

1. TRUS-guided transrectal biopsies (Trucut biopsy) are quite accurate for diagnosis when typical hypoechoic areas are identified.

### Procedure

-Evacuate rectum

-Antibiotic prophylaxis

Ciprofloxacin –500mg

Gentamycin - 160mg

- Gets the cells plus the surrounding stroma for the architecture
  - Can be done in lateral or supine position
  - Sextants-six different quadrants
  - Put in formalin and send for histology
  - Can leave a pack with betadine in the rectum for some hours
2. Transrectal needle aspiration and cytologic studies may be used but less appropriate compared to biopsy.

### Histological Gleason Score and Sum

Score of the most prominent 2 histological patterns

Small cells	1
Medium cells	2
Distortion	3
Cellular atypia	4
Anaplasia	5
Poor differentiated	8-10
Moderate differentiated	5-7
Well differentiated	2-4

### Staging-American Association of Urologist

#### Stage 1-Non palpable tumour

1a-Less than 3 well differentiated foci. (<5% of biopsy)

1b-more than 3 well differentiated foci (>5% of biopsy)

#### Stage2-Clinically palpable and confined to capsule

2a- Involving one lobe

2b- Involving both lobes.

#### Stage3-Extending beyond the capsule

3a-Minimal extra capsular extension(No seminal vesicles)

3b-Bulky extra capsular extension-seminal vesicles involvement.

#### Stage 4- Metastatic disease

4a- Involvement of pelvic lymph nodes

4b- Involvement of lymph nodes above the bifurcation of aorta and /or distant metastasis

### MANAGEMENT

Dependent on -Stage of tumor

Early disease- (Stage 1 and 2)

Radical prostatectomy or Radical radiotherapy

Advanced disease(Stage 3 and 4)

-Hormonal manipulation

#### A. For early disease/Localized disease

##### Radical prostatectomy (curative therapy)

-Removal of the prostate plus its covering and the seminal vesicles.

-Laparoscopic nerve sparing radical prostatectomy to avoid injury to the nerves is even better.

##### Complications

- 1.Bleeding
- 2.Pulmonary embolism
- 4.Infections
- 5.urinary incontinence
- 6.impotence
- 7.Urethral strictures
- 8.Rectal injuries

#### Radical Radiotherapy

##### 1.Teletherapy- Three-Dimensional Conformal Radiotherapy:

CT-assisted localization of beam that allows delivering high

doses of radiation that conform to the target volume of interest while sparing more of the surrounding normal tissues than is possible using conventional techniques

2. **Brachytherapy**-involves the implantation of radioactive seeds of iodine or palladium.

### B .Metastatic/late disease/Palliative

#### Hormonal treatment (Total androgen ablation)

##### 1.Orchiectomy

Bilateral subcapsular orchiectomy is simple, safe, and produces castrate levels in about 3 h.

The main side effects are gynaecomastia, impotence, and hot flushes.

- Anaesthesia may be general, regional, or local.

-If a normal appearing scrotum is important to the patient then subcapsular orchiectomy (preserving the tunica albuginea), or implantation of a synthetic testicular prosthesis are appropriate options

##### 2.Luteinizing hormone releasing hormone (LHRH) analogues

###### eg Goserelin, Nafarelin

-Results in a flare of testosterone after about 3 days, but testosterone levels then drop paradoxically to castrate levels after 2 weeks

-The clinical effect is equivalent to orchiectomy or diethylstilboestrol.

-There is a lower incidence of gynaecomastia and fluid retention but a higher incidence of hot flushes.

-In addition, unless the early flare period is covered by diethylstilboestrol or an antiandrogen, there is danger of tumour expansion leading to spinal cord compression or ureteral obstruction.

-LHRH analogues are available as daily subcutaneous injection, nasal spray, or as a monthly depot injection.

##### 3.Anti-androgens

###### a)Receptor Blockers

###### Flutamide

Pure antiandrogens such as **flutamide** block binding of dihydrotestosterone and testosterone to the androgen receptor.

Use of pure antiandrogens is the only hormone treatment that preserves libido and potency, but the potential for increasing testosterone levels precludes their use as monotherapy

###### Cypro-terone acetate

Is a synthetic progestational agent that blocks the dihydrotestosterone receptor but also has central gonadotropin blocking effects, making it particularly helpful in patients with hot flushes on other therapy.

-The central effect may be lost with prolonged use

###### b) 5 alpha reductase

inhibitors as Finasteride and Deusteride

#### Total Androgen Blockade.

Orchiectomy or GNRH analog plus Anti -androgen

#### Chemotherapy

-Cytotoxic chemotherapy has produced very disappointing results to date.

-The most promising agents have been Adriamycin and 5-fluorouracil.

-Docetaxel (mitotic spindle poison through the enhancement of tubulin polymerization) is used for Hormone Refractory Prostate cancer

**Non-hormonal therapy**

The most promising include suramin, which blocks growth factors and decreases binding of tumour growth factor; estramustine phosphate which has some oestrogenic effect but also produces mitotic arrest in tumours; Diphosphonates, which inhibit bone mineralization and resorption, producing symptomatic relief of bone metastases. Radiotherapy for bone relief in case of metastasis.

# RAISED INTRACRANIAL PRESSURE

## Causes

### Trauma

#### I. Trauma

- 1) Haematoma-epidural, subdural, intraventricular, subarachnoid hemorrhage
- 2) Cerebral edema
- 3) Depressed skull fractures

#### B. Infections

- 1) Bacterial-Staphylococcus, streptococcus, Haemophilus, tuberculous meningitis.
- 2) Parasitic-Cysticercosis, Toxoplasmosis, Echinococcus
- 3) Fungal-Cryptococcus, histoplasmosis Aspergilosis
- 4) Intracranial Abscesses

#### C. Neoplastic causes

1. Neuroepithelial tumors; glioma.
  - > Astrocytoma.
  - > Astroblastoma.
  - > Chordoid glioma.
  - > Ependymoma
  - > Oligodendroglioma.
2. Pineal region tumors; pineoblastoma.
3. Neuronal and mixed glial tumors
4. Embryonal tumors; medulloblastoma.
5. Meningeal tumors; meningioma.
6. Peripheral neuroblastic tumors; neuroblastoma.
7. Lymphoma and hemopoietic tumors; microglioma.
8. Germ cell tumors; germinoma.
9. Tumors of cranial and spinal nerves; neurofibroma.
10. Metastases; lung, breast, thyroid, renal etc.

#### D. Metabolic

1. Electrolyte imbalances-hyponatremia
2. Hypoventilation-hypercapnia.

#### E. Others

- 1) Hypertension
- 2) Hydrocephalus
- 3) Dural sinus thrombosis
- 4) ARDS
- 5) Seizures and convulsions

## MANAGEMENT

### Symptoms

- 1) -Severe bursting headache
- 2) -Projectile vomiting
- 3) -Blurring of vision
- 4) -Convulsions/seizures
- 5) -Drowsiness

### Signs

- 1) -Vital signs-increased BP and decreased pulse rate (Cushing's reflex)
- 2) -Anisocoria-unequal pupils
- 3) -Papilloedema on fundoscopy
- 4) -Nerve palsy e.g. 3<sup>rd</sup> and 6<sup>th</sup> cranial nerves
- 5) -Tense fontanelles.
- 6) -Irregular breathing/slowed rate

Parameters: Normal ICP = 0-10 mmHg. Treatment threshold > 20-25 mmHg. Goal CPP = 60-70 mmHg.

### **1. Elevation of head**

To promote venous drainage from the head.

### **2. Ventilation O<sub>2</sub> by mask**

Prevention of hypoxia and hypercapnia which increase ICP

### **3. Mannitol.**

- i. Effective doses range from **0.25-1 gram/kg**, given by intermittent bolus infusion every 4-6 hrs.
- ii. Euvolemia must be maintained.
- iii. Monitor osmolality. Do not exceed 320mOsm/kg

### **4. Anticonvulsant therapy**

Phenytoin is used to prevent or control seizure activity that increases cerebral blood flow and subsequently intracranial pressure. Anticonvulsant medications should be used for 1 week following injury and then discontinued if seizures are not recurrent.

### **5. Nimodipine**

The calcium channel blocker reduces death and severe disability when instituted acutely in patients with head injuries

### **6. Sedatives**

High dose diazepam may be considered for hemodynamically stable, salvageable, severe head injury patients with intracranial hypertension refractory to maximal medical and surgical therapy. Other narcotics may depress respiration.

### **7. Relieve and prevent pyrexia**

Which increases intracranial pressure. eg NSAIDs. Provision of analgesia has similar effects

### **8. Steroids**

Dexamethasone use is controversial in head injury

### **9. Hyperventilation**

To blow out the CO<sub>2</sub> and reduce hypercapnia and keep the partial pressure of CO<sub>2</sub> between 30-40 mmHg. The use of prophylactic hyperventilation (PaCO<sub>2</sub> < 35 mm Hg) therapy during the first 24 hours after severe TBI should be avoided because it can compromise cerebral perfusion during a time when cerebral blood flow (CBF) is reduced. Hyperventilation therapy may be necessary for brief periods when there is acute neurologic deterioration, or for longer periods if there is intracranial hypertension refractory to sedation, paralysis, cerebrospinal fluid (CSF) drainage, and osmotic diuretics.



# RHABDOMYOSARCOMA

## Introduction

Rhabdomyosarcoma is the most common soft-tissue tumor in children, accounting for approximately 5% of all pediatric cancers.

## Age

-The tumor presents throughout childhood and has even been reported at birth.  
-The peak incidence is between 2 and 5 years of age, with 70% of children diagnosed before 10 years of age.  
-A second smaller peak is seen in adolescents with extremity tumors.

## Sex

Males are affected more commonly than females (1.4:1).

## Race

Whites x3 more affected

## Aetiology

Unknown

- Associated with Fraumeni syndrome is an inherited mutation of the p53 tumor suppressor gene that results in a high risk of bone and soft tissue sarcomas in childhood plus breast cancer and other malignant neoplasms before age 45. But characteristic chromosomal changes have been reported, including t(2;13) translocation and loss of allelic heterozygosity on chromosome 11.

## Site of Presentation

There are four major anatomic sites of involvement:

- Head-and-neck region (35 to 40%)
- Genitourinary tract (20%)
- Extremities (15 to 20%),
- Trunk (10 to 15%)

-In the head-and-neck region occurs predominantly in the orbit, nasopharynx, maxillary antrum, middle ear, and soft tissues of the scalp, face, or neck.

-Within genitourinary tract of younger children, presents in the urinary bladder, prostate, and vagina.

In adolescents, the tumor occurs in the paratesticular soft tissues or spermatic cord.

-A small proportion (ie, 1 to 3%) of patients are diagnosed as having disseminated disease involving primarily the bones and bone marrow without an identifiable primary tumor site.

## Symptoms and signs

Are usually pressure or obstructive phenomena.

- Nasopharyngeal tumors may put pressure on the eustachian tubes and produce chronic otitis media
- Orbit-proptosis
- Bladder or prostate –hematuria and urinary obstruction.
- Vagina and uterus-A protruding mass of polypoid tissue presenting with pelvic mass or vaginal discharge
- Paratesticular-painless mass.
- Infiltration of tumors arising in the nasopharynx, middle ear, or infratemporal fossa into the middle cranial fossa may be associated with cranial nerve dysfunction
- Extremity-progressive swelling of the affected part.

-Evaluation of children with soft-tissue masses should include a complete examination of the suspected site. Extensive examination of the ears, nose, and throat for head-and-neck primaries as well as rectal or bimanual examination for genitourinary

## Investigations

- Incisional biopsy.
- CT Scan-The local tumor extension
- MRI- In head-and-neck, extremity, and pelvic tumors evaluation
- Assessment for metastatic disease involves chest radiography, thoracic CT, bone scan, and bone marrow aspiration

## Histological classification

Rhabdomyosarcoma consists of rhabdomyoblasts, which are primitive cells of mesenchymal origin. Tumors can be classified into four histologic types:

- Embryonal type-63%** is the most common. It predominantly affects children under 15 years of age in the head-and-neck region and the genitourinary tract. The botryoid type is a variant of the embryonal type. It arises as polypoid, grape-like lesions in mucosal-lined hollow organs such as the vagina and urinary bladder.
- Alveolar type19%** is a more aggressive tumor, occurring in children and young adults. It commonly involves the muscles of the extremities or trunk.
- Anaplastic type-10%**
- Pleomorphic type1%** is the least common, usually arising in muscles of the extremities.

Embryonal and botryoid tumors are felt to have "favorable histology." Alveolar, pleomorphic, and other less common subtypes are classified as "unfavorable histology."

## DDX

- small, round-cell tumors of childhood such as Ewing sarcoma, neuroblastoma, and malignant lymphoma. Electron microscopy and immunohistochemistry may facilitate the diagnosis.

## Staging

The extent of local, regional, and distant disease determines the tumor stage or group.

## Intergroup Rhabdomyosarcoma Study Group

This system is based on disease extent and resectability, defining groups I to IV by local disease status, involvement of the regional lymph nodes, and extent of residual tumor *after* primary surgery.

- Stage 1- Completely resectable, localized disease  
Stage 2-Resectable but with residual microscopic disease  
Stage 3a-Resectable but with gross residual tumour  
3b- no residual disease but regional lymph node metastases  
3c-both gross residual tumor and regional lymph nodes  
Stage IV- tumors have distant metastasis

## MANAGEMENT

Combined modality treatment of rhabdomyosarcoma constituted has resulted in significant improvement of survival. Surgical resection of the primary tumor usually offers the best prospect for local tumor control in limited disease presentations.

Integrating chemotherapeutic and radiotherapeutic modalities with surgery in has decreased the indications for radical surgery, thus permitting more limited surgical resection and sometimes potentially eliminating the need for surgery altogether. Radiation therapy is not necessary in patients with localized, completely resected tumors (ie, group I). Vincristine, dactinomycin, and cyclophosphamide have shown the greatest efficacy in the treatment of rhabdomyosarcoma.

**Prognosis**

The extent of tumor at diagnosis, the primary site, pathologic subtype, and response to treatment all influence long-term disease-free survival from the time of diagnosis.

# SIGMOID VOLVULUS

## Definition

Axial rotation or twisting of sigmoid colon on an axis formed by its mesentery.

Result in partial or complete obstruction of the lumen and may be followed by circulatory impairment of the bowel which may lead to gut gangrene.

Accounts for >50% of intestinal obstruction in parts of Africa. Commonest cause of large bowel obstruction.

## Predisposing factors

1. High dietary fibre diet major contributing factor .
2. Chronic constipation
3. Long redundant colon
4. Acquired megacolon eg. TB, Diabetes
5. Narrowly based mesentery.

## Age

- Occur in the elderly.
- Peak age - >70yrs
- Especially elderly patients suffering from psychiatric & chronic neurological diseases such as stroke or multiple sclerosis.
- Also, cardiovascular disease and diabetes.

## Clinical presentation

### History

1. Acute colicky abdominal pain usually with persistence of pain between spasms.

May be a previous history of transient attacks in which spontaneous reduction of the volvulus has occurred.

2. Abdominal swelling
3. Constipation is absolute-obstipation.
4. Vomiting-if present appear late.

### Physical examination

1. Most striking finding is of a tensely distended, tympanitic, drum-like abdomen.
  2. The rectum is empty of stool.
  3. Bowel sounds are often increased
  4. Signs of peritoneal inflammation such as rebound tenderness or guarding are unusual.
- When these signs are present they suggest that colonic infarction or gangrene has occurred.
5. Signs of dehydration may be apparent if presentation has been delayed and these should always be sought.

## Investigations

### Radiology

1. Plain supine abdominal radiograph.

The most useful investigation This alone may be diagnostic in 70 to 80 per cent of patients.

The typical appearance is that of a single grossly distended loop of colon arising out the pelvis from the let and extending towards the diaphragm.

- ✓ Inverted U sign
- ✓ M-sign
- ✓ Inner tube sign
- ✓ Frieman's Dohls sign

-Haustral markings are usually lost

2. Contrast enema

Investigation by a contrast enema such as dilute barium or a water-soluble contrast medium will increase the diagnostic yield of radiology to over 90 per cent of patients. If gangrenous bowel or perforation is suspected a water-soluble contrast must be used rather than barium, as the latter will produce a severe peritonitis. The pathognomonic sign on a contrast enema is described as a **birds beak or ace of spades**; appearance, produced as the upper end of the barium column tapers into the spirally twisted distal sigmoid colon

## MANAGEMENT

### Supportive management

1. NG tube for gut decompression.
  2. Flatus tube-decompression
  3. Analgesia
  4. IV fluid rehydration and maintenance fluids
  5. Correction of electrolyte derangement.
  6. IV antibiotics if signs of peritonism
  7. Keep nil per oral
- obtain consent if signs of perforation or peritonism

### Non-operative management

- Patients who present with no signs of peritonism can be treated initially by non-operative means.
- Careful flexible sigmoidoscopy and the passage of a flatus tube via the sigmoidoscope is successful in up to 90 per cent of cases, and is well worth trying in the first instance.
- Protective clothing is recommended as the results of a successful decompression are usually explosive.
- Following a successful deflation, the flatus tube should be left in place for at least 48 h, and some would recommend as long as 5 days.
- Unless this is done the likelihood of an early recurrence is very high (50-90 per cent).
- Due to high recurrence rates >50 % patients should be admitted back to the ward, gut prepared and surgery planned for resection of sigmoid colon and primary anastomosis.
- If the follow up of patient is good then elective surgery may be planned.

### Emergency Surgery

Patients with features of peritonitis require emergency surgery before perforation and gram negative toxemia ensues.

#### Option:

1. Sigmoid colectomy with a Hartmann's colostomy which is closed 6-8 weeks later.
2. On Table mechanical gut preparation by doing colonic washout with warm normal saline until the washout is clear. Antegrade colonic irrigation via caecal intubation. Then sigmoid colectomy with a primary anastomosis is done.

#### DDx

- Bowel obstruction due to other causes
- ✓ sigmoid colon CA
  - ✓ Giant sigmoid diverticulum
  - ✓ Pseudo obstruction

#### Complications

- ✓ Colonic ischemia and gangrene
- ✓ Perforation
- ✓ Peritonitis
- ✓ Endotoxic shock.

### **VOLVULUS OF THE CAECUM**

-Caecal volvulus is much less common than volvulus of the sigmoid colon, accounting for 33% compared to sigmoid 65% of large bowel obstruction.

-It carries a mortality of 20 per cent. In this condition the caecum remains mobile and shares a common mesentery with the ileum.

-It is therefore free to rotate, usually clockwise, out of the right iliac fossa to the mid- or left side of the upper abdomen, producing a closed loop obstruction of the ascending colon and distal ileum.

### **Presentation and clinical features**

-Caecal volvulus may present as a fulminant condition with intestinal strangulation secondary to mesenteric torsion or, less dramatically, with features of intestinal obstruction.

Rarely it is a chronic intermittent condition. The peak age of presentation is 30 to 40 years of much younger than that for sigmoid volvulus, and it is more common in females.

There often appear to have been a triggering event, such as a recent laparotomy and it is well recognized following gynaecological procedures.

Occasionally it can occur secondary to an obstructing colonic carcinoma and, like sigmoid volvulus, it may be related to a high fibre intake.

The presenting symptoms are usually non-specific. Abdominal pain is almost invariably present and nausea, vomiting, constipation, and distension will occur in about one-third of patients. In thin patients it may be possible to palpate the resonant distended caecum in the central or upper abdomen while the right iliac fossa is empty.

### **Radiology**

The key to the diagnosis of caecal volvulus, as with sigmoid volvulus, is the plain abdominal radiograph. The caecum typically assumes a gas-filled comma shaped facing inferiorly and to the right.

Other radiological appearances are of non-specific colonic obstruction or of small bowel obstruction.

A barium enema may be useful to exclude any other predisposing colonic lesion and on occasions it has been effective in reducing the volvulus.

### **Treatment**

The mainstay of treatment for this condition is surgery and, unlike sigmoid volvulus, endoscopic deflation has little place. Prompt caecal resection is mandatory in those with caecal perforation or infarction and this is usually possible with a primary ileocaecal anastomosis.

In severely ill patients, however, it may be expedient to exteriorize the proximal and distal bowel ends following resection, as an ileostomy and mucous fistula. These can then be anastomosed at a second operation 6 weeks later. The mortality in patients with gangrenous bowel is as high as 40 per cent.

## SKIN INFECTION

### **Furuncle (boil)**

An abscess is a localized collection of pus within the skin associated with erythema, tenderness, and showing marked infiltration by polymorphonuclear leucocytes.

An abscess which involves the hair follicle is termed a furuncle. Staphylococcus aureus is the most common causative organism; streptococci and Gram-negative organisms may also be present.

### **Folliculitis**

Inflammation of hair follicles, often in clusters, often due to local infection or chemical irritation or associated with underlying disease. May be superficial or deep. Characteristic lesions are small yellow or gray pustules surrounded by erythema and pierced by a hair. Common **folliculitis** can appear on any part of the body.

### **Carbuncle**

A carbuncle is a suppurative extension of several contiguous furuncles into the subcutaneous fat. The maintenance of fascial attachments to the skin results in the production of multilocular compartments.

### **Hidradenitis suppurativa (suppurative hidradenitis, apocrinitis)**

Acute, tender, cyst-like abscesses in apocrine gland bearing skin (axillae, anogenital area, pubes, areolae, also apocrine glands scattered around umbilicus, scalp, trunk and face). Frequently seen as a tetrad of hidradenitis suppurativa, severe cystic acne (acne conglobata), pilonidal sinus, and perifolliculitis capitis (dissecting folliculitis).

### **Cellulitis (erysipelas)**

This cutaneous non-suppurative infection of the connective tissue (dermal) and subcutaneous layers of the skin may be caused by several types of bacteria, of which haemolytic streptococci are the most common. These are usually group A organisms, but  $\beta$ -haemolytic streptococci of groups B, C, or G may also be responsible. Clinical appearance  
Erythema, swelling, and tenderness spreads rapidly with sharp or vaguely defined borders.

## **SNAKE BITES**

At presentation of casualty A,B,C of resuscitation ,some of the venomous snakes can complicate with hemorrhagic shock,cardiotoxicity

### Secondary survey

- 1-History of the snake bites and if possible establishes whether it was venomous or not.
- 2-Examination of the wound inflicted can give indication whether the snake was venomous or not. Nonvenomous snakes do not produce fang marks, but rather rows of tiny puncture wounds or scratches.
- 3-Removal of any tight clothing on the limb or tourniquet that had been applied.
- 4- Obtain IV access in the non-affected limb and keep on IV fluids
- 5-Take vital signs continuously monitor
- 6-Clean the bitten part and irrigate with copious amounts of water.
- 7-Elevate the limb as much as possible.
- 8-Provide analgesia
- 9-Administer tetanus toxoids
- 10-Give prophylactic antibiotics
- 11-Measure circumference of the bitten part at several levels, comparing these with similar measurements carried out once on the unaffected side.
- Monitor for any continued swelling.
- 12-If anti venom available this can be given in the IV fluid infusion and run slowly looking out for any allergic reactions.
- 13-If there is continued swelling of the limb even with elevation, then fasciotomy may be necessary to prevent occurrence of compartment syndrome.

### Initial investigations

- 1.Full blood count-Hb ,can draw blood for GXM
  - 2.LFT-Liver transaminases ,serum bilirubin
  - 3.Urea,electrolyte and creatinine
  - Urinalysis-protenuria and hematuria
  - 4.Creatine kinase
  - 5.Coagulation profile- platelet count, clotting time, prothrombin time, partial thromboplastin time, fibrinogen level
  6. ECG studies.
- Manage any complications as appropriate:  
Abnormal coagulation profile-Fresh frozen plasma transfusion.  
Hemolytic anemia-Whole blood transfusion  
Shock-IV fluid –crystalloids and Colloids

# SPINAL DYSRAPHISM/SPINA BIFIDA

-Spectrum of **abnormalities of development of spinal vertebrae and the spinal cord**, ranging from the **absence of a single vertebral spinous process to craniospinal rachischisis** (failure of neural tube closure incompatible with life)  
-All of these conditions have in common a failure of the bony spinal column to close fully, defining bifid spine. The frequent associated defects include:

## A.Spina bifida occulta

-Usually an incidental radiographic diagnosis representing incomplete closure of the posterior laminar arches without involvement of the nervous tissue.  
-Affects about 30 per cent of the population.

## B.Occult spinal dysraphism

-The bony anomaly is associated with a number of abnormalities within the spinal canal. These include

- Thick filum terminale
- Intradural epidermoid and dermoid cysts
- Intradural lipoma (lipomyelomeningocele)
- Teratoma
- Dias-tomato-myelia (local midline splitting of the spinal cord with interruption by a midline bony or fibrous peg)
- Combination of abnormalities.

-Intradural pathology causing a tethered spinal cord is often associated with some type of overlying skin abnormality, such as hyperpigmentation, dermal sinus tract, or a hairy patch.

-There are generally no other associated central nervous system anomalies (such as hydrocephalus or the Chiari malformation) in occult spinal dysraphism. The spinal cord is usually normal except in relationship to the distal tethering(diastematomyelia)

## C.Open neural tube defects

Spina bifida cystica- protrusion of a sac through the defect in the posterior lamina of the vertebral column.This sac can contain meninges or meninges plus neural tissue. Thus

i) Meningocele, where there is a cystic outpouching of rudimentary meninges with an underlying intact spinal cord  
ii) Myelomeningocele, where the malformed neural tube is present at the base of or within the cyst.

iii) Myelorachis-chisis, where the malformed neural tube is splayed over a number of spinal segments, without meningeal or skin coverage.

## Incidence and epidemiology

-Incidental spina bifida occulta is found in up to 30 per cent of the general population and has no clinical significance.  
-The incidence of occult spinal dysraphism is unknown; however, its clinical presentation as the tethered spinal cord syndrome is uncommon  
-The incidence of myelomeningocele is approximately 1 per 1000 live births.

## Sex

-Higher incidence in females.(menigomyelocoles)

## Risk factors

-Largely unknown

-However it tends to occur in families

-General population risk of myelomeningocele is 0.1% but previous child with the defect risk is 5%.

-Environmental factors- intake of drugs during pregnancy as well as radiation exposure early in pregnancy may play a role. Thus  
1.1st trimester valproic acid and derivatives (valproate sodium) use

2. previous children with spina bifida or close relative born with the defect

3.Insufficient maternal levels of folic acid

However **greater than 90%** of spina bifida infants there no above risk factors thus **sporadic**.

## Clinical presentation

The symptoms associated with dysraphism vary with the degree of malformation of the underlying neural tissue. Spinal bifida occulta

-Frequently seen as an incidental finding on routine spine radiographs, most commonly at the L5 and S1 levels.

-In itself, it is of no neurological significance.

-When it is associated with overlying skin abnormalities, especially hypertrichosis, cutaneous haemangiomas, lipomas, or a sinus tract, an occult intraspinal lesion should be suspected.

## Occult spinal dysraphism

-These abnormalities may be noted at birth or during childhood, with the overlying skin abnormalities above Patient may be asymptomatic for many years. Some of these children (and, occasionally, adults) develop a progressive neurological deficit involving the lumbosacral roots-the tethered cord syndrome. This appears as bowel or bladder difficulty, foot or leg weakness muscle atrophy, sensory loss, pes cavus and scoliosis.

## Open neural tube defects

-Present at birth, with an estimated incidence of 1 in 1000 live births, although this shows regional variation.

-An infant with a meningocele is usually neurologically normal  
-In myelomeningocele neurological deficits are present at birth, these deficits become more severe as more of the placode becomes involved.

-These lesions are most common in the lumbosacral area, causing abnormalities of bowel and bladder function, as well as variable degrees of leg weakness and sensory loss.

-Lesions higher in the spinal cord will be accompanied by relatively more severe deficits.

-In addition to the local neurological deficits, affected infants are at risk of meningitis precipitated by contamination of cerebrospinal fluid from incompetent dura.

NB Spina bifida is most common in the lower thoracic, lumbar, or sacral region and usually extends for 3 to 6 vertebral segments.

## Associated abnormalities of spinal bifida

A)Brain anomalies associated with myelomeningocele include

- Hydrocephalus-Chiari and other intracranial malformations - 80 per cent of infants with myelomeningoceles have hydrocephalus
- Agenesis of the corpus callosum
- Lobar agenesis
- Polymicrogyria
- Rim-cortex (holoprosencephaly)

- Intracranial cysts and lipomas
- Encephaloceles.

#### B) Musculoskeletal

- Hip dislocations
- Club feet
- Kyphoscoliosis
- Rib cage anomalies

#### C) Genitourinary

- Hydronephrosis
- Hydroureters
- Horse shoe kidneys
- Un-descended testis

#### D) Cardiopulmonary

- VSD, ASD

#### c) Gastrointestinal systems

- Malrotations
- Emphaloceles
- Merckels diverticulum

-The likelihood of associated somatic anomalies increases with the severity of the neural tube defect; however, on average a child can be expected to have more than one abnormality.

#### Investigations

##### Prenatal

-Family history of spina bifida is an indication for further evaluation of an unborn child. This by:

- Antenatal ultrasonography
- Maternal serum and amniotic fluid alpha-fetoprotein levels measurements.

-An open spinal column or a meningocele sac are readily apparent on an obstetrical ultrasound examination. –

-Elevated maternal serum alpha-fetoprotein levels can be associated with myelomeningocele and should prompt a close ultrasonographic examination.

Counselling the parents of a spina bifida child is of the utmost importance, particularly when the diagnosis is made antepartum.

Open discussion of possible outcome with option for abortion should be carried out.

##### Post natal

##### Evaluation of spina bifida

1. Spinal x-ray
2. spinal MRI

##### Other abnormalities

1. Plain x-ray and CT scan of the head to evaluate for hydrocephalus, Chiari malformations and other associated cerebral malformations eg encephaloceles

Ultrasonography has role in evaluation of hydrocephalus in cases with open fontanelles.

##### Urinary system

1. Abdominal ultrasound-also evaluate GIT anomalies

2. IVU

3. BUN and creatinine

-urinalysis, urine culture may be done for evaluation of UTI

##### Cardiac

Echocardiography

##### Musculoskeletal

Image the area affected Hip x-ray, foot x-ray

##### Complications

1. If not well covered with skin, the sac can easily rupture, increasing the risk of meningitis.

2. When the spinal cord or lumbosacral nerve roots are involved, as is usual, varying degrees of paralysis occur below the involved level.

Since this paralysis occurs in the fetus, congenital orthopedic problems can present at birth (eg, clubfoot, arthrogryposis, dislocated hip). The paralysis usually affects bladder and rectal functions, and the resulting GU disorder can eventually lead to severely damaged kidneys.

3. Kyphosis, sometimes associated with spina bifida, can hinder surgical closure and prevent the patient from lying supine.

4. Hydrocephalus occurs commonly and may be related to aqueductal stenosis or an Arnold-Chiari malformation.

#### MANAGEMENT

##### Treatment

##### Spina bifida occulta

Has no neurological implications and re-assurance and counselling of the patients.

##### Occult spinal dysraphism

Patients presenting with progressive deterioration of neurological function then immediate complete evaluation of the spine and surgery to decompress or release the tethered cord is indicated.

Midline cutaneous stigmata require complete evaluation and the presence of occult dysraphism require planning for surgery even if no neurological signs are present

##### Myelomeningocele

Requires multidisciplinary approach with specialists from several disciplines.

Initially important are

- Neurosurgical
- Urologic
- Orthopedic
- Pediatric
- social service evaluations.

-Thorough evaluation of the infant and counseling of the family should generally precede intervention.

-It is important to assess the type, level, and extent of the lesion; the infant's general health status and associated deficits; the family's strengths, desires, and resources; and the community resources, including ongoing care.

Once evaluation is complete, a decision can be made on how aggressive treatment should be.

If the defect is leaking CSF, antibiotics and urgent neurosurgical evaluation and repair will reduce the risk of meningeal or ventricular infection.

However with already manifest neurological deficit with good skin cover then early surgery does not improve the function but its only for cosmetic function. Parents should be counseled about this.

With compromised urinary and fecal continence then at point of repair of bony defect then urine and fecal diversion procedures could be attempted. Fecal incontinence may necessitate the fashioning of permanent colostomy.

Other congenital anomaly-interval management as appropriate.

Hydrocephalus may require a shunt procedure



Hdronephrosis-nephrostomy may be done to preserve the existing parenchymal tissue. Kidney function must be followed closely, and UTI should be treated promptly.

Obstructive uropathy at either the bladder outlet or ureteral level must be treated vigorously, especially when infection occurs.

Orthopedic care should begin early. If a clubfoot is present, serial casting should start birth. The hip joints should be checked closely for dislocation. Other continuing orthopedic concerns are scoliosis, pathologic fractures, development of pressure sores, and muscle weakness and spasm, which may cause further deformities.

# SPINAL INJURY

## Definition

Spinal cord injury (SCI) is an insult to the spinal cord resulting in a change, either temporary or permanent, in its normal motor, sensory, or autonomic function

## Background

Patients with spinal cord injury (SCI) usually have permanent and often devastating neurologic deficits and disability.

The goals for the emergency physician are to

1. Establish the diagnosis
2. Initiate treatment to prevent further neurologic injury from either pathologic motion of the injured vertebrae or secondary injury from the deleterious effects of cardiovascular instability or respiratory insufficiency

## Pathophysiology

### Anatomy

The spinal cord is divided into 31 segments, each with a pair of anterior (motor) and dorsal (sensory) spinal nerve roots. On each side, the anterior and dorsal nerve roots combine to form the spinal nerve as it exits from the vertebral column through the neuroforamina.

Spinal cord ends at lower margin of the L1 vertebral body.

Thereafter, the spinal canal contains the lumbar, sacral, and coccygeal spinal nerves that comprise the cauda equina.

Therefore, injuries below L1 are not considered SCIs because they involve the segmental spinal nerves and/or cauda equina.

The spinal cord organized into a series of tracts or neuropathways that carry motor (descending) and sensory (ascending) pathways.

The **corticospinal tracts** are **descending motor pathways** located anteriorly within the spinal cord. Axons extend from the cerebral cortex in the brain as far as the corresponding segment, where they form synapses with motor neurons in the anterior (ventral) horn. They decussate (cross over) in the medulla prior to entering the spinal cord.

The **dorsal columns** are **ascending sensory tracts** that transmit **light touch, proprioception, and vibration** information to the sensory cortex. They do not decussate until they reach the medulla.

The **lateral spinothalamic tracts** transmit **pain and temperature sensation**. These tracts usually decussate within 3 segments of their origin as they ascend.

The **anterior spinothalamic tract** transmits **light touch**.

Autonomic function traverses within the anterior interomedial tract.

Sympathetic nervous system fibers exit the spinal cord between **C7 and L1**, while parasympathetic system pathways exit between **S2 and S4**.

### Injury manifestation

-Injury to the corticospinal tract or dorsal columns, respectively, results in ipsilateral paralysis or loss of sensation of light touch, proprioception, and vibration. -----injury to the lateral spinothalamic tract causes contralateral loss of pain and temperature sensation

-Anterior cord injury causes paralysis and incomplete loss of light touch sensation (anterior spinothalamic spared.)

-**Spinal shock** is defined as the complete loss of all neurologic function, including reflexes and rectal tone, below a specific level that is associated with autonomic dysfunction.

-Autonomic function is transmitted in the anterior interomedial tract. Progressively higher spinal cord lesions or injury causes increasing degrees of autonomic dysfunction (lower exit of roots)  
-Neurogenic shock refers to the hemodynamic triad of hypotension, bradycardia, and peripheral vasodilation resulting from autonomic dysfunction and the interruption of sympathetic nervous system control in acute SCI. It does not usually occur with SCI below the level of **T6**.

### Blood supply

-The blood supply of the spinal cord consists of 1 anterior and 2 posterior spinal arteries.

-The anterior spinal artery supplies the anterior two thirds of the cord. injury to this vessel results in dysfunction of the corticospinal, lateral spinothalamic, and autonomic interomedial pathways.

Anterior spinal artery syndrome involves paraplegia, loss of pain and temperature sensation, and autonomic dysfunction.

-The posterior spinal arteries primarily supply the dorsal columns.

-The anterior and posterior spinal arteries arise from the vertebral arteries in the neck and descend from the base of the skull.

Various radicular arteries branch off the thoracic and abdominal aorta to provide collateral flow

-At any given level of the spinal cord, the central part is a watershed area. Cervical hyperextension injuries may cause ischemic injury to the central part of the cord, causing a central cord syndrome.

### Etiology

SCIs may be primary or secondary.

#### Primary SCIs

Arise due to direct effect of the trauma on the spine.

This follows compression or severe angulation of the vertebral spine.

This leads to mechanical disruption, transection, or distraction of neural elements. This injury usually occurs with fracture and/or dislocation of the spine.

However, primary SCI may occur in the absence of spinal fracture or dislocation just by severe distraction thus the term SCIWORA (spinal cord injury without radiologic abnormality)

Penetrating injuries due to bullets or weapons may also cause primary SCI. More commonly, displaced bony fragments cause penetrating spinal cord and/or segmental spinal nerve injuries.

Extradural pathology may also cause a primary SCI. Spinal epidural hematomas or abscesses cause acute cord compression and injury.

Spinal cord compression from metastatic disease is a common oncologic emergency.

#### Secondary SCI's

-Vascular injury to the spinal cord caused by arterial disruption, arterial thrombosis, or hypoperfusion due to shock are the major causes of secondary SCI.

-Anoxic or hypoxic effects compound the extent of SCI.

-Movement around unstable spinal column causing further injury

#### Spinal cord injuries syndromes

1. **Complete cord injury** complete loss of motor and sensory function below the level of the traumatic lesion.

2. **Incomplete cord injury** partial loss of sensory and/or motor function below the level of injury.

The incomplete SCI syndromes are further characterized clinically as follows:

a) **Anterior cord syndrome** involves variable loss of motor function and pain and/or temperature sensation, with preservation of proprioception.

B) **Brown-Séquard syndrome**(hemi-section cord) ipsilateral loss of proprioception and motor function, with contralateral loss of pain and temperature sensation.

c) **Central cord syndrome** usually involves a cervical lesion, with greater motor weakness in the upper extremities than in the lower extremities.

The pattern of motor weakness shows greater distal involvement in the affected extremity than proximal muscle weakness.

Sensory loss is variable, and the patient is more likely to lose pain and/or temperature sensation than proprioception and/or vibration.

Dysesthesias, especially those in the upper extremities (eg, sensation of burning in the hands or arms), are common. Sacral sensory sparing usually exists.

d) **Conus medullaris syndrome** is a sacral cord injury with or without involvement of the lumbar nerve roots. This syndrome is characterized by areflexia in the bladder, bowel, and to a lesser degree, lower limbs. Motor and sensory loss in the lower limbs is variable.

e) **Cauda equina syndrome** involves injury to the lumbosacral nerve roots and is characterized by an areflexic bowel and/or bladder, with variable motor and sensory loss in the lower limbs. Because this syndrome is a nerve root injury rather than a true SCI, the affected limbs are areflexic. This injury is usually caused by a central lumbar disk herniation.

A spinal cord concussion is characterized by a transient neurologic deficit localized to the spinal cord that fully recovers without any apparent structural damage.

### Spinal shock

-Spinal shock is a state of transient physiological (rather than anatomical) reflex depression of cord function below the level of injury with associated loss of all sensorimotor functions. Present with:

- 1.Hypotension
- 2.Hypothermia
- 3.Bradycardia
- 4.Flaccid paralysis
- 5.Loss of sensation
- 6.Areflexia or depressed reflexes
- 7.Urinary and bladder incontinence.
- 8.Sweating .
- 9.Sometimes sustained priapism develops.

These symptoms tend to last 24-48hrs. Until the return of the bulbocavernosus reflex and the anal wink. The diagnosis of complete spinal cord injury cannot be made until the period of spinal shock is over, as evidenced by the return of the bulbocavernosus reflex. To elicit this reflex, the clinician digitally examines the patient's rectum, feeling for contraction of the anal sphincter while squeezing the glans penis or clitoris.

### Sex:

The male-to-female ratio is approximately 2.5-3.0:1.

### Age:

About 80% of males with SCIs are aged 18-25 years. SCIWORA occurs primarily in children.

### Motor testing for spinal level:

- C5 - Elbow flexors (biceps, brachialis) and shoulder abduction
- C6 - Wrist extensors (extensor carpi radialis longus and brevis)
- C7 - Elbow extensors (triceps)
- C8 - Finger flexors (flexor digitorum profundus) to the middle finger
- T1 - Small finger abductors (abductor digiti minimi)
- L2 - Hip flexors (iliopsoas)
- L3 - Knee extensors (quadriceps)
- L4 - Ankle dorsiflexors (tibialis anterior)
- L5 - Long toe extensors (extensors hallucis longus)
- S1 - Ankle plantar flexors (gastrocnemius, soleus)

### SENSORY testing for spinal level

- C2 - Occipital protuberance
- C3 - Supraclavicular fossa
- C4 - Top of the acromioclavicular joint
- C5 - Lateral side of arm
- C6 - Thumb and lateral aspect forearm
- C7 - Middle finger
- C8 - Little finger
- T1 - Medial side of arm
- T2 - Apex of axilla OR 2<sup>nd</sup> intercostals space
- T3 - Third intercostal space (IS)
- T4 - 4th IS at nipple line
- T5 - 5th IS (midway between T4 and T6)
- T6 - 6th IS at the level of the xiphisternum
- T7 - 7th IS (midway between T6 and T8)
- T8 - 8th IS (midway between T6 and T10)
- T9 - 9th IS (midway between T8 and T10)
- T10 - 10th IS or umbilicus
- T11 - 11th IS (midway between T10 and T12)
- T12 - Midpoint of inguinal ligament.
- L1 - Half the distance between T12 and L2
- L2 - Mid-anterior thigh
- L3 - Medial femoral condyle or lateral femoral condyle
- L4 - Medial malleolus or medial aspect leg
- L5-lateral aspect of leg or lateral malleolus or Dorsum of the foot at third metatarsophalangeal joint
- S1 - Lateral heel
- S2 - Popliteal fossa in the midline
- S3 - Ischial tuberosity
- S4-5 -Perianal area (taken as one level).

**Neurogenic shock** Neurogenic shock is manifested by the triad of hypotension, bradycardia, and hypothermia. Shock tends to occur more commonly in injuries above T6, secondary to the disruption of the sympathetic outflow from T1-L2 and to unopposed vagal tone, leading to decrease in vascular resistance with associated vascular dilatation. Neurogenic shock needs to be differentiated from spinal and hypovolemic shock. Hypovolemic shock tends to be associated with tachycardia

## **DIAGNOSIS**

### **History**

- Ascertaining the mechanism of injury is also important in identifying the potential for spinal injury. Fall with neck hyperextension/flexion, back trauma etc.
- Symptoms related to the vertebral column (most commonly pain) and any motor or sensory deficits.
- Hemorrhagic shock may be difficult to diagnose because the clinical findings may be affected by autonomic dysfunction..
- To distinguish hemorrhagic shock from neurogenic shock: Neurogenic shock occurs only in the presence of acute SCI above T6. Hypotension and/or shock with acute SCI at or below T6 are caused by hemorrhage.

### **Physical exam:**

- As with all trauma patients, initial clinical evaluation begins with a primary survey.-ABCDE. An SCI must be considered concurrently. Spinal exam should involve:
  - a) Pulmonary function** – respiratory rate, cyanosis, respiratory distress, air entry bilaterally, added sounds, chest wall expansion, abdominal wall movement, cough, and chest wall and/or pulmonary injuries. Arterial blood gas (ABG) analysis and pulse oximetry  
Respiratory dysfunction is ultimately dependent on preexisting pulmonary comorbidity, the level of SCI, and any associated chest wall or lung injury. Any or all of the following determinants of pulmonary function may be impaired in the setting of SCI:
    1. Loss of ventilatory muscle function from denervation and/or associated chest wall injury
    2. Lung injury, such as pneumothorax, hemothorax, or pulmonary contusion
    3. Decreased central ventilatory drive that is associated with head injury or exogenous effects of alcohol and drugs.
  - b) CVS**-Pulse rate and volume, BP (hemorrhagic or neurogenic shock)
  - c) Temperature**-Hypothermia-spinal shock
  - d) Thorough Neurological Examination**  
Spinal level or decide whether complete or incomplete injury

- Motor exam**-Bulk, Tone, Power, Reflexes, Co-ordination  
In all patients, assessment of deep tendon reflexes and perineal evaluation is critical. The presence or absence of sacral sparing is a key prognostic indicator.  
The sacral roots may be evaluated by documenting the following:
  - Perineal sensation to light touch and pinprick
  - Bulbocavernous reflex (S3 or S4)
  - Anal wink (S5)
  - Rectal tone
  - Urine retention or incontinence
  - Priapism

- Sensory testing –pain, temperature, crude and fine touch and proprioception.
- Neurologic level of injury** - Most caudal level at which both motor and sensory levels are intact, with motor level as defined above and sensory level defined by a sensory score of 2
- Sensory level** - Most caudal dermatome with a normal score of 2/2 for both pinprick and light touch

**Motor level** - Determined by the most caudal key muscles that have muscle strength of 3 or above while the segment above is normal (= 5)

## **INVESTIGATIONS**

### **Lab Studies:**

1. Hemoglobin and/or hematocrit levels may be measured initially and monitored serially to detect or monitor sources of blood loss.
2. Perform urinalysis to detect associated genitourinary injury

### **Imaging**

#### **Plain x-Ray**

- The standard 3 views of the cervical spine are recommended:
  1. Anteroposterior
  2. Lateral view
  3. Odontoid view-open mouth x-ray
- Other oblique views include depressed shoulder view
- Anteroposterior and lateral views of the thoracic and lumbar spine are recommended.
- The cervical spine radiographs must include the C7-T1 junction to be considered adequate

### **CT Scan**

CT scanning is reserved for delineating bony abnormalities or fracture.

### **MRI**

MRI is best for suspected spinal cord lesions, ligamentous injuries, or other nonosseous conditions.  
MRI may be used to evaluate nonosseous lesions, such as extradural spinal hematoma; abscess or tumor; and spinal cord hemorrhage, contusion, and/or edema.

### **Motor strengths and sensory testing**

The extent of injury is defined by the American Spinal Injury Association (ASIA) Impairment Scale (modified from the **Frankel classification**), using the following categories:  
**A - Complete:** No sensory or motor function is preserved in sacral segments S4-S5.  
**B - Incomplete:** Sensory, but not motor, function is preserved below the neurologic level and extends through sacral segments S4-S5.  
**C - Incomplete:** Motor function is preserved below the neurologic level, and most key muscles below the neurologic level have muscle grade less than 3.  
**D - Incomplete:** Motor function is preserved below the neurologic level, and most key muscles below the neurologic level have muscle grade greater than or equal to 3.  
**E - Normal:** Sensory and motor functions are normal.

### **MANAGEMENT Starts at the site of injury follow:**

#### **Principles of management**

1. The injury must be recognized.
2. Measures to prevent further damage ("secondary" injury) and to detect deteriorating neurologic function so that corrective measures can be taken.
3. The patient must be maintained in optimal condition to allow the greatest possible nervous system repair and recovery.
4. Evaluation and rehabilitation of the patient must be actively pursued to maximize the function of surviving but dysfunctional nervous tissue

### **Pre-hospital**

-ABC of resuscitation  
-stabilize and immobilize the spine thus cervical collar and transport patient on hard board.  
Transportation can be by ambulances in short distances but if possible air lift is better to avoid movements that would interfere with splinting.

### **Casualty**

-Keep the **cervical collar** and patient on the backboard  
-**Resuscitation** following ABCDE should be done.

### **Airway**

Securing the airway while keeping the cervical column in place may be challenging  
-The cervical spine must be maintained in neutral alignment at all times. Clearing of oral secretions and/or debris is essential to maintain airway patency and to prevent aspiration. The modified jaw thrust and insertion of an oral airway may be all that is required to maintain an airway in some cases. However, intubation may be required in others.

### **Breathing**

Management for pulmonary complications and/or injury in patients with SCI includes supplementary oxygen for all patients and chest tube thoracostomy for those with pneumothorax and/or hemothorax

### **Circulation**

-Hypotension may be hemorrhagic and/or neurogenic in acute SCI. This should be urgently corrected to prevent secondary SCI. Judicious fluid replacement with isotonic crystalloid solution to a maximum of 2 liters is the initial treatment of choice. Overzealous crystalloid administration may cause pulmonary edema because these patients are at risk for the acute respiratory distress syndrome.  
Adequate perfusion with the following parameters should be maintained

- Systolic blood pressure (BP) should be 90-100 mm Hg. Systolic.
- Heart rate should be 60-100 beats per minute in normal sinus rhythm. Hemodynamically significant bradycardia may be treated with atropine.
- Urine output should be more than 30 mL/h. Placement of a Foley catheter to monitor urine output is essential
- Prevent hypothermia.

NB Associated head injury occurs in about 25% of SCI patients. A careful neurologic assessment for associated head injury is compulsory

### **In patient management involves-**

1. Prevention of secondary injury-splints, corticosteroid, oxygen
2. Analgesia
3. Bladder care-Condom catheter
4. Bowel care
5. Skin care
6. Physiotherapy chest and limbs

### **1) Splints**

Optimal immobilization is obtained by placing the patient supine (face up) on a firm, flat surface (eg, rigid, long spine board) without a pillow and with lateral motion of the neck restricted by a rigid cervical collar (Philadelphia), lateral neck rolls connected

with tape across the forehead, or traction. Traction is the most effective method .

-Skull traction with a 3-kg (7-lb) weight on a rope off the end of the bed provides the best means of emergency splinting and traction.

-Thoracolumbar orthosis TLO only used for injuries below T6, not used above T6

-Halos jacket used for cervical fractures used to hold the cervical spine and thorax

-Submental mandible occipital strut(SiMO)

-Logrolling the patient to the supine position is safe to facilitate diagnostic evaluation and treatment at least five people needed for leg rolling.

### **2) Steroids**

-Treat all SCI patients within 3 hours of injury with the following steroid protocol: **methylprednisolone 30 mg/kg bolus over 15 minutes** and an infusion of methyl prednisolone at **5.4 mg/kg/h for 23 hours beginning** 45 minutes after the bolus. Significant improvement in motor function and sensation in patients with complete or incomplete SCIs noted

### **3) Analgesics**

-Use analgesics appropriately and aggressively to maintain the patient's comfort if he or she has been lying on a hard backboard for an extended period.  
Start of opioid analgesia initially then NSAIDS

### **4) Bladder care: Condom catheter**

Monitor input output of fluids initially. Also if loss of bladder function

**5) Bowel care** -Manual evacuation by sweeping thro the rectum which cause irritation or the use of enemas(warm soap enema)

### **6) +NG tube**

-Placement of a nasogastric tube for decompression. Ileus is common This may also be used for nutritional support.

### **7) Anti emetics**

Aspiration pneumonitis is a serious complication in the SCI patient with compromised respiratory function. Antiemetics should be used aggressively

### **8) Skin care**

Prevent pressure sores-Denervated skin is particularly prone to pressure necrosis.  
-Remove belts and back pocket keys or wallets.  
-Turn the patient every 1-2 hours.  
-Pad all extensor surfaces.  
-Use pneumatic mattresses, continuous motion or ripple mattress.  
-Good nursing care to prevent wetness-ZNO

### **9) Pvsiotherapy-both chest and limbs**

Prevention of contractures and maintenance of range of motion are important in all patients with spinal cord injury and should begin immediately following the injury.  
Chest physiotherapy to prevent pneumostatic pneumonia

### **SURGICAL TREATMENT**

**The vertebral divided into column (Dennis)**

1. Anterior column –include anterior 2/3 of the body, anterior longitudinal ligament, annular ligament and nucleus polposus anterior half.
  2. Middle column-posterior 1/3 of the body and PLL plus the nucleus polposus and the annular ligament upto facet joint
  3. Posterior column-include lamina, the spinous process and the ligaments plus the ligamentum flavum.
- Instability after fractures occur if involvement of at least two columns or most of the anterior column

#### Types of fractures include.

1. Anterior wedge fracture
2. Posterior wedge fracture
3. Burst fracture
4. Subluxation-displaced not out of articulation
5. Dislocation
6. Fracture of spinous process , pedicles, transverse process

#### **Decompression**

Indications for decompression-If a patient has an incomplete spinal cord injury and evidence of continued neural element compression, decompression may be indicated. At the time of surgery, stabilization in the form of fusion, Often accompanied by instrumentation, may be performed.

If decompression is felt to be indicated, the surgical approach used should depend on where the compression lies. Similar neurologic outcomes have been reported with anterior decompression and posterolateral decompression. retractor bone can be removed or pushed back into place

#### **Surgical stabilization**

In a patient who has a burst fracture in which the posterior elements remain intact, treatment may consist of an anterior vertebrectomy, strut grafting, and fusion without instrumentation. Such a patient can be braced post-operatively without undue risk of graft displacement or spinal instability.

Use of rods and pedicle screws

Use of cages to stabilize burst fracture

#### **SPECIAL CONSIDERATION**

##### **CERVICAL INJURY**

Jefferson Injury- 4 fragment fracture of C1. due to shearing and rotation and present with neurological injury

Upper cervical fractures the spinal canal is large and accommodates rotation rarely present with neurological deficits. Management by halos jacket.

Hangman injury-hyperextension fractures of C2 pedicle plus fracture of disc between C3 and C4.

Classification

Type 1-undisplaced fracture of C2.

Type 2-displacement less than 3 cm

Type 3-displacement greater than 3cm and C2and C3 articulation disrupted

Types 1 and 2 managed by a Philadelphia collar while type 3 managed by halos jacket which prevents movement in all planes.

##### **COMPLICATIONS of spinal injury**

1. Neurologic deterioration is the extension of the sensory deficit cephalad.
2. Pressure sores-Careful and frequent turning of the patient is required to prevent pressure sores.

3. Aspiration pneumonia-Nasogastric decompression of the stomach is mandatory.
4. Hypothermia Prevent hypothermia by using external rewarming techniques and/or warm humidified oxygen.
5. Pulmonary complications in SCI are common. Pulmonary complications are directly correlated with mortality, and both are related to the level of neurologic injury. Pulmonary complications of SCI include the following:
  - Atelectasis secondary to decreased vital capacity and decreased functional residual capacity
  - Ventilation-perfusion mismatch due to sympathectomy and/or adrenergic blockade
  - Increased work of breathing because of decreased compliance
  - Decreased coughing, which increases the risk of retained secretions, atelectasis, and pneumonia
  - Muscle fatigue
6. Muscle wasting, joint stiffness and contractures

Philadelphia collar only prevents extension-flexion movement at the neck, rotational and sideway movement can occur.

##### Lower cervical injuries

Occur by rotational, compression and distraction forces

Compression occur by axial loading mostly anterior aspect of vertebral body fractured

Burst fracture the whole body involved in fracture

Facet dislocation can be uniaxial or biaxial dislocation

Uniaxial dislocation occur when there is less than 25 % anterolithesis

Biaxial dislocation occurs with more than 25 % anterolithesis.

##### Radiology of Cervical Spine

X-ray of the cervical spine must see all the cervical vertebrae plus proximal half of T1.

##### 3-views

-AP

See spinous processes-should be in line.

Dislocations and misalignment

End plates

-Lateral

-Odontoid(open mouth view)

This done to visualize the odontoid process

##### Classification of Odontoid fractures

Type 1 avulsion at the tip

Heal managed by a collar

Type 2 Fracture along the base of odontoid.

]Worst type. High risk of non union.

If less than 5cm displacement then can be managed by halos jacket. Greater than 5cm then internal fixation screw or C1-C2 transarticular screw.

Type 3 involves the body-managed by a halos jacket

-In interpretation check the soft tissues around the cervical column, the discs spaces the vertebral bodies, retropharyngeal space.

The distance anterior to the body of C2 is 6 mm and that anterior to C6 is 2 cm. The 6 at 2 and 2 at 6 rule.

The atlantodens distance is usually 3mm and this is increased in the transverse ligament tear.

Radiological lines

- The anterior and posterior aspect the vertebral bodies curved anteriorly.
- Posterior aspect of facets curved anteriorly.
- Tips of spinous processes in line
- Spinolaminar line curved anteriorly.

# SUB-ARACHNOID HAEMORRHAGE

Subarachnoid hemorrhage (SAH) refers to extravasation of blood into the subarachnoid space between the pial and arachnoid membranes.

It comprises half of spontaneous atraumatic intracranial hemorrhages, the other half consist of bleeding that occurs within the brain parenchyma.

NB the most common cause of SAH is head trauma. However, the familiar medical use of the term SAH refers to nontraumatic (or spontaneous) hemorrhage, which usually occurs in the setting of a ruptured cerebral aneurysm or arteriovenous malformation (AVM).

Its devastating condition with high morbidity and mortality

## Etiology

Rupture of "berry," or saccular, aneurysms of the basal vessels of the brain comprises 77% of nontraumatic SAH cases

Aneurysms mostly arise from the terminal portion of the internal carotid artery (ICA) and from the major branches of the anterior portion of the circle of Willis.

## Pathophysiology

Congenital and acquired factors are thought to play a role in occurrence of aneurysm.

Aneurysms usually occur at the branching sites on the large cerebral arteries of the circle of Willis. The early precursors of aneurysms are small outpouchings through defects in the media of the arteries.

These defects are thought to expand as a result of hydrostatic pressure from pulsatile blood flow and blood turbulence, which is greatest at the arterial bifurcations. A mature aneurysm has a paucity of media, replaced by connective tissue, and has diminished or absent elastic lamina.

The rate of rupture is directly related to the size of the aneurysm. Aneurysms with a diameter of 5 mm or less have a 2% risk of rupture, whereas 40% of those 6-10 mm have already ruptured upon diagnosis.

Brain injury from cerebral aneurysm formation can occur in the absence of rupture via compressive forces that cause injury to local tissues and/or compromise of distal blood supply (mass effect).

When an aneurysm ruptures, blood extravasates under arterial pressure into the subarachnoid space and quickly spreads through the cerebrospinal fluid (CSF) around the brain and spinal cord. Blood released under high pressure may directly cause damage to local tissues. Blood extravasation causes a global increase in intracranial pressure (ICP). Meningeal irritation occurs.

Congenital defects in the muscle and elastic tissue of the arterial media in the vessels. These defects lead to microaneurysmal dilatation.

Aneurysms are acquired lesions related to hemodynamic stress on the arterial walls at bifurcation points and bends.

AVMs are the second most identifiable cause of SAH, accounting for 10% of cases of SAH

## Risk factors for aneurysmal SAH:

1. Hypertension - Fibromuscular dysplasia, polycystic kidney disease, and aortic coarctation

2. Increased blood flow - Cerebral arteriovenous malformation (AVM); persistent carotid-basilar anastomosis; ligated, aplastic, or hypoplastic contralateral vessel

3. Blood vessel disorders - Atherosclerosis, Systemic lupus erythematosus (SLE), Moyamoya disease, and granulomatous angiitis

4. Genetic - Marfan syndrome, Ehlers-Danlos syndrome, Osler-Weber-Rendu syndrome, pseudoxanthoma elasticum, and Klippel-Trenaunay-Weber syndrome

5. Congenital - Persistent fetal circulation and hypoplastic/absent arterial circulation

6. Metastatic tumors to cerebral arteries - Atrial myxoma, choriocarcinoma, and undifferentiated carcinoma

7. Infectious - Bacterial, fungal

Use of oral contraceptives, Hormone replacement therapy, Hypercholesterolemia and alcohol consumption may contribute to HTN or atherosclerosis.

Saccular or berry aneurysms are specific to the intracranial arteries because their walls lack an external elastic lamina and contain a very thin adventitia—factors that may predispose to the formation of aneurysms. An additional feature is that they lie unsupported in the subarachnoid space.

## Mortality/Morbidity:

As many as 60% of patients die in the first 30 days as the result of SAH.

**Sex:** The incidence of SAH is slightly higher in women than in men.

**Age:** The mean age for SAH is 50 years.

## Clinical presentation

### History

The signs and symptoms of SAH range from subtle prodromal events, which often are misdiagnosed, to the classic presentation of catastrophic headache.

A) **Sentinel, or "warning," leaks** that produce minor blood leakage

Sentinel leaks produce sudden focal or generalized head pain that may be severe. In addition to headaches, sentinel leaks may produce nausea, vomiting, photophobia, malaise, or, less commonly, neck pain. Signs of raised ICP don't occur

### B) Aneurysmal rupture SAH

The classic symptoms and signs of aneurysmal rupture into the subarachnoid space comprise one of the most pathognomonic presentations in all of clinical medicine

1. A sudden onset of very severe headache, often described as the "worst headache of my life"

2. Nausea and/or vomiting

3. Symptoms of meningeal irritation, including nuchal rigidity and pain, back pain, and bilateral leg pain (but may take several hours to manifest).

4. Photophobia and visual changes are common.

5. A sudden loss of consciousness (LOC) occurs at the ictus in as many as 45% of patients as ICP exceeds cerebral perfusion pressure. LOC often is transient; however some patients are comatose for several days, depending on the location of the aneurysm and the amount of bleeding.

6. Seizures during the acute phase



### c) Mass effect

Expanding aneurysm or hemorrhage, characteristic features based upon aneurysm location. 1. Posterior communicating artery/internal carotid artery - Focal, progressive retro-orbital headaches and oculomotor nerve palsy  
2. Middle cerebral artery - Contralateral face or hand paresis, aphasia (left side), contralateral visual neglect (right side)  
3. Anterior communicating artery - Bilateral leg paresis and bilateral Babinski sign  
4. Basilar artery apex - Vertical gaze, paresis, and coma  
5. Intracranial vertebral artery/posterior inferior cerebellar artery - Vertigo, components of lateral medullary syndrome.

### Physical Examination

1. Focal neurologic signs hemiparesis, aphasia, hemineglect, cranial nerve palsies, and memory loss
2. Ophthalmologic examination may reveal subhyaloid retinal hemorrhages and papilledema.
3. Blood pressure elevation is observed in about .BP often becomes labile as ICP increases. Bradycardia may occur
4. Temperature elevation, secondary to chemical meningitis.

### Hunt and Hess grading system of SAH

Grade 1 - Asymptomatic or mild headache  
Grade 2 - Moderate-to-severe headache, nuchal rigidity, and no neurological deficit other than possible cranial nerve palsy  
Grade 3 - Mild alteration in mental status (confusion, lethargy), mild focal neurological deficit  
Grade 4 - Stupor and/or hemi paresis  
Grade 5 - Comatose and/or decerebrate

### MANAGEMENT

Indications for surgical management have been described recently and include the following:

For patients with a mild- or intermediate-grade SAH (Hunt and Hess 1-3), surgical treatment (**Surgical clipping**) is strongly recommended because the risks of SAH complications greatly exceed the risk of surgical complications

For patients with a poor grade of SAH (Hunt and Hess grades 4-5) The overall outcome is poor, with or without surgical intervention.

Patients with a higher grade of SAH or poor medical status that do not qualify for early surgery may be candidates for delayed surgery or endovascular obliteration of the aneurysm. Other indications of surgery

- Large and giant aneurysm
- Wide-necked aneurysms
- Vessels emanating from the aneurysm dome
- Mass effect or hematoma associated with the aneurysm
- Recurrent aneurysm after coil embolization

### Indications for endovascular treatment

Endovascular treatment with the Guglielmi detachable coil system

- Patients with poor clinical grade
- Patients who are medically unstable
- In situations where aneurysm location imparts an increased surgical risk, such as cavernous sinus and many basilar tip aneurysms
- Small-neck aneurysms in the posterior fossa
- Patients with early vasospasm

- Cases where the aneurysm lacks a defined surgical neck (although these are also difficult to "coil")
- Patients with multiple aneurysms in different arterial territories if surgical risk is high

### Location of aneurysm rupture

Approximately 85% of saccular aneurysms occur in the anterior circulation. The most common sites of rupture are as follows:

- The internal carotid artery, including the posterior communicating junction (41%)
- The anterior communicating artery/anterior cerebral artery (34%)
- The middle cerebral artery (20%)
- The vertebral-basilar arteries (4%)
- Other arteries (1%)

### Lab Studies:

1. CBC count - For evaluation of possible infection or hematologic abnormality
2. Prothrombin time (PT) and activated partial thromboplastin time (aPTT) - For evaluation of possible coagulopathy
3. Serum electrolytes - To establish a baseline for detection of future complications
4. Blood type and screen - In case intraoperative transfusion is required or in the setting of massive hemorrhage
5. Cardiac enzymes - For evaluation of possible myocardial ischemia
6. Arterial blood gas (ABG) - Assessment is necessary in cases with pulmonary compromise

### Imaging Studies:

1. CT scan: the location of the hemorrhage and the mass effects of the hemorrhage on the ventricles.
2. LP If diagnosis not clear, do lumbar puncture after funduscopy to rule out raised ICP.  
D-dimer assay: can be used to discriminate SAH from traumatic LP.  
After 24 hours, CSF samples may demonstrate a polymorphonuclear and mononuclear polycytosis secondary to chemical meningitis caused by the degradation products of subarachnoid blood.
3. Cerebral angiography can provide the following important surgical information in the setting of SAH: a) Cerebrovascular anatomy  
b) Aneurysm location and source of bleeding  
c) Aneurysm size and shape, as well as orientation of the aneurysm dome and neck  
d) Relation of the aneurysm to the parent artery and perforating arteries  
e) Presence of multiple or mirror aneurysms (identically placed aneurysms in both the left and right circulations)

### Other Tests

1. Transcranial Doppler studies are useful in the detection and monitoring of arterial vasospasm.
2. Chest radiograph: All patients with SAH should have a baseline chest radiograph to serve as a reference point for evaluation of possible pulmonary complications.
3. Evaluation of ventricular wall motion via echocardiogram may be necessary in cases with suspected myocardial ischemia.

4. ECG- Nonspecific ST and T wave changes  
Decreased PR intervals, Increased QRS intervals, Increased QT intervals, Presence of U waves

### Medical Management

The initial management of patients with SAH is directed at patient stabilization. Assess the level of consciousness and airway, as well as breathing and circulation (ABCs). Endotracheal intubation should be performed for patients presenting with coma, depressed level of consciousness, inability to protect their airway, or increased ICP. Intravenous (IV) access should be obtained, including central and arterial lines. A short-acting benzodiazepine, such as midazolam, should be administered prior to all procedures

### Hypertension control

The traditional treatment of ruptured cerebral aneurysms included strict blood pressure control, with fluid restriction and antihypertensive therapy.

The current recommendations advocate the use of antihypertensive agents when the mean arterial pressure (MAP) exceeds 130 mm Hg.

Intravenous beta-blockers, which have a relatively short half-life, can be titrated easily and do not increase ICP. Beta-blockers are the agents of choice in patients without contraindications.

Most clinicians avoid the use of nitrates, such as nitroprusside or nitroglycerin, which elevate ICP. Hydralazine and calcium channel blockers have a fast onset and lead to relatively less increase in ICP than do nitrates.

Angiotensin-converting enzyme inhibitors have a relatively slow onset and are not first-line agents in the setting of acute SAH.

### Increased ICP

1. Patients with signs of increased ICP or herniation should be intubated and hyperventilated. Minute ventilation should be titrated to achieve a PCO<sub>2</sub> of 30-35 mm Hg. Avoid excessive hyperventilation, which may potentiate vasospasm and ischemia.

2. Osmotic agents (eg, mannitol), which can decrease ICP dramatically (50% after 30 min postadministration) Loop diuretics (eg, furosemide) also can decrease ICP

3. The use of IV steroids (eg, Decadron) is controversial

Additional medical management is directed to prevent and treat the following common complications of SAH:

- Rebleeding
- Vasospasm
- Hydrocephalus
- Hyponatremia
- Seizures
- Pulmonary complications
- Cardiac complications

### Rebleeding

Is the most dreaded early complication of SAH. The greatest risk of rebleeding occurs within the first 24 hours of rupture. The overall mortality rate from rebleeding is reported to be as high as 78%.

Measures to prevent rebleeding include the following: 1. Bedrest in a quiet room

2. Analgesia, preferably with a short-acting and reversible agent such as fentanyl: Pain is associated with a transient elevation in blood pressure and increased risk of rebleeding.

3. Sedation (used with caution to avoid distorting subsequent neurologic evaluation) with a short-acting benzodiazepine such as midazolam

4. Stool softeners

5. Antifibrinolytics have been shown to reduce the occurrence of rebleeding.

However, outcome likely does not improve because of a concurrent increase in the incidence of cerebral ischemia

### Cerebral vasospasm

The delayed narrowing of the large capacitance vessels at the base of the brain, is a leading cause of morbidity and mortality in survivors of nontraumatic SAH.

-Vasospasm is reported to occur in as many as 70% of patients. Most commonly, this occurs 4-14 days after the hemorrhage.

-Vasospasm can lead to impaired cerebral auto regulation and may progress to cerebral ischemia and infarction. Measures used for prevention of vasospasm include the following:

1. Maintenance of normovolemia, normothermia, and normal oxygenation are paramount to vasospasm prophylaxis. Volume status should be monitored closely, with avoidance of volume contraction, which can predispose to vasospasm.

2. Prophylaxis with oral nimodipine:

-Calcium channel blockers have been shown to reduce the incidence of ischemic neurological deficits, and nimodipine has been shown to improve overall outcome within 3 months of aneurysmal SAH.

-Nimodipine may prevent the ischemic complications of vasospasm by the neuroprotective effect of blocking the influx of calcium into damaged neurons.

-Should be used cautiously to avoid the deleterious effects of hypotension.

If vasospasm becomes symptomatic use of hypertensive, hypervolemic, and hemodilutional (HHH) therapy.

There is demonstrated improved cerebral blood flow and resolution of the ischemic effects of vasospasm with this therapy.

Initiation of HHH therapy requires placement of a pulmonary artery catheter in order to guide volume expansion and inotropic or vasopressor therapy.

This therapy should be reserved for patients with aneurysms secured by surgical clipping or endovascular techniques in order to reduce the risk of rebleeding.

Hypervolemia may be achieved by using packed erythrocytes, isotonic crystalloid, and colloid and albumin infusions in conjunction with vasopressin injection. Corticosteroids may be of some benefit; however, such treatment remains controversial.

The hematocrit should be maintained at 30-35% via hemodilution or transfusion in order to optimize blood viscosity and oxygen delivery.

Aggressive hypertensive therapy with inotropes and vasopressors (eg, dobutamine) can be initiated, if warranted

### Hydrocephalus

Acute type Occurs within the first 24 hours after hemorrhage.

This condition can precipitate life-threatening brainstem compression and occlusion of blood vessels. Hydrocephalus presents as a relatively abrupt mental status change, including lethargy, stupor, or coma. CT scan differentiates hydrocephalus from rebleeding.

Treatment for acute hydrocephalus includes external ventricular drainage, depending on the severity of clinical neurologic dysfunction or CT scan findings.

Chronic hydrocephalus usually the communicating type

### **Hyponatremia**

Elevated levels of atrial natriuretic factor (ANF) and syndrome of inappropriate secretion of antidiuretic hormone (SIADH) have been implicated in recent studies of post-SAH hyponatremia. Use of slightly hypertonic sodium chloride (1.5% sodium chloride) at rates above maintenance requirements usually is efficacious for SAH-induced hyponatremia. Avoid fluid restriction in patients with SAH.

### **Seizures**

Agents used for seizure prophylaxis include the following: Phenytoin, the agent of choice, can achieve rapid therapeutic concentrations when loaded intravenously, and it does not cause alterations in consciousness. Phenobarbital produces a sedative effect, which may mask the neurological evaluation; phenobarbital is used less frequently than phenytoin.

### **Acute pulmonary edema and hypoxia**

Are almost universal in severe SAH. Neurogenic in origin and unrelated to HHH therapy; however, the latter is associated with an increased risk of fluid overload. Treatment of acute pulmonary edema may include the use of gentle diuresis, dobutamine, and positive end-expiratory pressure (PEEP).

Cardiac dysfunction occurs in a significant number of people with SAH. Neurogenic sympathetic hyperactivity, as well as increased levels of systemic catecholamines, has been implicated in SAH-associated cardiac dysfunction. Arrhythmias occur in as many as 90% of patients and most commonly include the following

- Premature ventricular complexes (PVCs)
- Bradyarrhythmias Supraventricular tachycardia
- Arrhythmias are most prevalent in the first 48 hours following SAH. Only a small percentage of arrhythmias (usually those associated with hypokalemia) are life threatening

# SUB-DURAL HAEMATOMA

A subdural hematoma (SDH) is classified by the amount of time that has elapsed from the inciting event, if known, to the diagnosis. When the inciting event is unknown, the appearance of the hematoma on CT scan or MRI can help date the hematoma.

1. **Acute SDHs** are less than 72 hours old and are hyperdense compared to the brain on CT scan.
2. **Subacute SDHs** are 3-20 days old and are isodense or hypodense compared to the brain.
3. **Chronic SDHs** are older than 20 days and are hypodense compared to the brain.

An acute SDH commonly is associated with extensive primary brain injury. This diffuse parenchymal injury correlates strongly with the outcome of the patient

The presence of brain atrophy or loss of brain tissue due to any cause, such as old age, alcoholism, or stroke, provides a potential space between the dura and the brain surface for a SDH to form

## Pathophysiology:

### Acute subdural hematoma

The usual mechanism to produce an acute SDH is high-speed impact to the skull. This causes brain tissue to accelerate relative to a fixed dural structure, which, in turn, tears bridging veins. This mechanism also leads to associated contusions, brain edema, and diffuse axonal injury.

The ruptured blood vessel often is a vein connecting the cortical surface to the dural sinuses. Alternatively, a cortical vessel can be damaged by direct laceration. An acute SDH due to a ruptured cortical artery may be associated with only minor head injury, and no cerebral contusions may be associated.

### **Chronic subdural hematoma**

A higher incidence of chronic SDH exists in men. The male-to-female ratio is 2:1. Most adults with chronic SDH are older than 50 years.

25-50% of chronic SDH pts have no identifiable history of head trauma. If a patient does have a history of head trauma, it usually is mild.

The average time between head trauma and chronic SDH diagnosis is 4-5 weeks.

### **Risk factors for a chronic SDH**

1. Chronic alcoholism
2. Epilepsy
3. Coagulopathy
4. Arachnoid cysts
5. Anticoagulant therapy (including aspirin)
6. Cardiovascular disease (hypertension, arteriosclerosis),
7. Thrombocytopenia
8. Diabetes
9. Severe dehydration
10. Extremes of ages

Clinical presentation often is insidious, with symptoms of decreased level of consciousness, balance problems, cognitive dysfunction and memory loss, motor deficit (such as a hemiparesis), headache, or aphasia. Acute presentation also is possible, as in the case of a patient who presents with a seizure.

Neurologic examination may demonstrate hemiparesis, papilledema, hemianopsia, or third cranial nerve dysfunction, such as an unreactive dilated pupil or a laterally deviated eye of limited movement. In patients aged 60 years or older, hemiparesis and reflex asymmetry are common presenting signs. In patients younger than 60 years, headache is a common presenting symptom. Chronic SDHs are observed bilaterally in 8.7-32% of cases.

### **Indications for surgery**

Emergent surgical evacuation should occur in patients with an acute SDH larger than 5 mm in thickness (as measured by axial CT scan) and causing any neurological signs, such as lethargy, unresponsiveness (coma), or focal neurological deterioration. Surgery for chronic SDH is indicated if SDH is symptomatic or producing significant mass effect on imaging studies

### **Lab Studies:**

-To determine whether defective coagulation was involved in the formation of the acute SDH and to correct any coagulation abnormalities a prothrombin time (PT), activated partial thromboplastin time (aPTT), and a platelet count should be performed. A bleeding time may detect platelet dysfunction. -Routine trauma lab studies that aid in the initial assessment include hemoglobin, electrolytes, and a drug/alcohol screen. Obviously, the drug and alcohol screens are important in correlating the neurological examination with the imaging studies.

### **Imaging Studies:**

a) Computed tomography scan of the head without contrast  
Acute SDH appears on CT scan as a crescent-shaped hyperdense area between the inner table of the skull and the surface of the cerebral hemisphere

### **Medical therapy:**

#### **Acute subdural hematoma**

Small acute SDHs less than 5 mm thick on axial CT images, without sufficient mass effect to cause midline shift or neurological signs, can be followed clinically. Hematoma resolution should be documented by serial imaging because an acute SDH that is treated conservatively can evolve into a chronic hematoma. Emergent medical treatment of an acute SDH causing impending transtentorial herniation is the bolus administration of mannitol (in the patient who is adequately fluid resuscitated with an adequate blood pressure). Surgical evacuation of the lesion is the definitive treatment and should not be delayed.

#### **Chronic subdural hematoma**

Without mass effect on imaging studies and no neurological symptoms or signs except mild headache, a chronic SDH can be followed with serial scans and may resolve. No medical therapy has been shown to be effective in expediting rapid resolution of acute or chronic SDHs

### **Surgical therapy:**

#### Acute subdural hematoma

Surgery for acute SDH consists of a large craniotomy (centered over the thickest portion of the clot) to decompress the brain, stop any active subdural bleeding, and evacuate any intraparenchymal hematomas in the immediate vicinity of the acute SDH.

The craniotomy exposure should include the sylvian fissure because this can be a likely source of a ruptured cortical vessel. If brain injury and edema are associated, an intracranial pressure (ICP) monitor should be placed.

#### Chronic subdural hematoma

Liquefied chronic SDHs commonly can be treated with drainage through 1-2 burr holes. Burr holes are placed so that conversion to a craniotomy is possible if needed. A closed drainage system sometimes is left in the subdural space for 24-72 hours postoperatively. Small catheter drainage via twist drill craniotomy at the bedside also has been described as adequate treatment.

A nonliquefied chronic SDH cannot be decompressed adequately by burr holes and must be removed by craniotomy.

Bilateral chronic hematomas must be drained from both sides, usually during the same operation through burr holes placed on each side of the head.

#### **Preoperative details:**

Phenytoin (Dilantin) is administered to decrease the risk of developing early posttraumatic seizures (within the first 7 d after the injury). Patients have an estimated risk of greater than 20% for developing posttraumatic epilepsy after an acute SDH.

Phenytoin only should be continued for 7 days after the injury because it is not effective in preventing late posttraumatic seizures (beginning 1 wk or more after the injury).

#### **Acute subdural hematoma**

After the evacuation of an acute SDH, medical treatment is aimed at controlling the ICP below 20 mm Hg and maintaining the cerebral perfusion pressure above 60-70 mm Hg. These parameters are vital to maintain during the perioperative period. Within 24 hours of removing an acute SDH, a follow-up CT scan should be obtained routinely

# TESTICULAR TORSION

Testicular torsion refers to twisting of the spermatic cord structures, either in the inguinal canal or just below the inguinal canal.

It is a surgical emergency because it causes strangulation of gonadal blood supply with subsequent testicular necrosis and atrophy.

Acute scrotal swelling in children and adolescent indicates torsion of the testis until proven otherwise.

## Types

1. **Extravaginal torsion:** This type manifests in the neonatal period and most commonly develops prenatally in the spermatic cord, proximal to the attachments of the tunica vaginalis.

2. **Intravaginal torsion:** This type occurs within the tunica vaginalis, usually in older children.

## Etiology:

**Extravaginal torsion:** The testes may freely rotate prior to the development of testicular fixation via the tunica vaginalis within the scrotum.

**Intravaginal torsion:** Normal testicular suspension ensures firm fixation of the epididymal-testicular complex posteriorly and effectively prevents twisting of the spermatic cord. Torsion is usually spontaneous and idiopathic but some predisposing factors include:

1. Bell-clapper deformity lack of fixation posteriorly to the tunica by the testis, resulting in the testis being freely suspended within the tunica vaginalis.
2. A large mesentery between the epididymis and the testis
3. History of trauma in 20% of patients
4. 1/3 have had prior episodic testicular pain which may denote previous torsion that rotated
5. Contraction of cremasteric muscle or dartos muscles shortens the spermatic cord and may initiate testicular torsion may play a role and is stimulated by trauma, exercise, cold, sexual stimulate.
6. Cryptorchidism.
7. Testicular atrophy-post infectious or traumatic.

## Age

Tends to occur in young men-it is uncommon in men over 25 years of age and rare in men over 30 years of age. It peaks at 14-18 years.

## Pathophysiology

Torsion of the spermatic cord interrupts blood flow to the testis and epididymis. The thick walled arteries initially remain patent as venous congestion occur leading which lead ischemia and infarction of the testis.

The degree of torsion may vary from 180-720°. Increasing testicular and epididymal congestion promotes progression of torsion.

The extent and duration of torsion prominently influence both the immediate salvage rate and late testicular atrophy.

Testicular salvage most likely occurs if the duration of torsion is less than 4-6 hours. If 24 hours or more elapse, testicular necrosis develops in most patients.

## Clinical presentation

Prenatal torsion manifests as a firm, hard, scrotal mass, which does not transilluminate in an otherwise asymptomatic newborn

male. The scrotal skin characteristically fixes to the necrotic gonad

## Presentation in older patients

1. The sudden onset of severe testicular pain followed by inguinal and/or scrotal swelling
2. Nausea and vomiting may occur
3. Fever may occur
4. Testis may be high in scrotum with a transverse lie
5. Scrotum is enlarged, red, erythematous and echymosis may be evident
6. Absence of cremasteric reflex

## Differential Diagnosis of scrotal swelling and pain.

1. **Trauma:** History of injury and examination may reveal a hematoma. Urinalysis may show hematuria

2. **Viral Orchitis:** Mumps virus and the enteroviruses may cause acute unilateral or bilateral orchitis. In orchitis due to mumps virus, there is usually associated parotitis.

3. **Urolithiasis:** Rarely, patients with urolithiasis present with pain localized mainly in the scrotum; however, in most cases, back or flank pain has preceded the scrotal pain, or there is a history of nephrolithiasis. Ureteric colic radiates to the testis. In such cases, the testicle and epididymis are normal to palpation. Hematuria is an important diagnostic clue. The diagnosis may be confirmed by excretory urography.

4. **Incarcerated Hernia:** Inguinal hernias incarcerated in the scrotum may cause scrotal pain that may be confused with testicular pain.

Bowel sounds are heard in the scrotum early in incarceration; if the hernia strangulates bowel sounds are no longer audible. Intestinal hernia is almost always associated with clinical findings of intestinal obstruction. Nausea, abdominal pain and vomiting. Ultrasonography is diagnostic.

## 5. Epididymitis, orchitis, epididymo-orchitis

-These conditions most commonly occur from the reflux of infected urine or from sexually acquired disease caused by gonococci and *Chlamydia*

-Tends to occur in sexually active men over 20 of age.

-There may be a history of urinary tract infection or urethritis and urethral discharge.

-Pain begins gradually and is less severe than in testicular torsion

- Often associated with systemic signs and symptoms associated with urinary tract infection

-Patients occasionally develop these conditions following excessive straining or lifting and the reflux of urine-chemical epididymitis

-**Prehn's sign** may be helpful in differentiating between torsion and epididymitis: If pain is reduced when the scrotum is lifted over the symphysis pubica, the pain is due to epididymitis; if pain increases, the cause is probably torsion.

-Physical examination reveals a tender epididymis, often unilateral and often with erythema and edema of the scrotal skin. Early on, the testicle may be normal or minimally tender. Later edema and erythema worsens and becomes very tender.

-Urinalysis or microscopic examination of urethral mucus will show leukocytes in most cases of epididymitis, indicating preceding urinary tract infection or urethritis.

-A complete urological evaluation (ie, renal sonography, urodynamic study) is necessary in prepubertal boys with acute epididymitis.

Organisms in younger men-STD like-Chlamydia and gonorrhea  
Older men-Gram -ve organisms.

Treatment consists of bed rest, scrotal elevation, NSAIDs for pain relief and antibiotics(broad spectrum- augmented penicilins or 2<sup>nd</sup> cephalosporins)

#### 6. Torsion of testicular or epididymal appendage

This condition usually occurs in children aged 7-12 years.

Systemic symptoms are rare. Usually, localized tenderness occurs but only in the upper pole of the testis.

Occasionally, the blue dot sign is present in light-skinned boys

#### 7. Hydrocele

Usually associated with patent processus vaginalis Painless swelling is usually present.

Scrotal contents can be visualized with transillumination.

Scrotal enlargement occurs, only rarely accompanied by pain.  
Presentation is rarely acute.

#### Others

9. **Acute varicocele**-feel like a bag of worms

10. **Henoch-Schonlein purpura**

11. **Scrotal abscess**

12. **Leukemic infiltrate**

#### INVESTIGATIONS

To rule out differential diagnosis and confirm testicular torsion.

#### Lab Studies:

1. FHG, Urinalysis and culture

If no clinical evidence of testicular torsion, a urinalysis and culture may help exclude urinary tract infection and epididymitis.

If testicular torsion is clinically suggested, perform immediate surgical exploration, regardless of laboratory studies because a negative finding upon exploration of the scrotum is more acceptable than the loss of a salvageable testis.

#### Imaging

Should not delay emergent surgical treatment of patients with high probability of testicular torsion (ie, patients under 18 years of age with acute unilateral testicular pain and no signs or recent history of urinary tract infection).

a) **Spermatic cord block**-Anesthetizing the scrotal contents will facilitate accurate examination. Inject lidocaine without epinephrine (2%), 5-10 mL, around the spermatic cord at the external inguinal ring.

b) **Scrotal colour Doppler sonogram** is usually diagnostic by verifying arterial flow.

c) **Radionuclide scan**-In epididymitis, scanning of the scrotum after intravenous injection of technetium Tc 99m sodium pertechnetate reveals increased scrotal uptake on the affected side, whereas torsion shows decreased uptake. Rign or halo sign in torsion, only outer part is perfused inner part ischemic.

d) **U/S**-can differentiate between swelling of the testis and swelling of the epididymis and show if there is an incarcerated hernia. Ultrasonography can also detect the presence of varicocele and testicular cysts and masses

Aspiration of abscesses may also be done.

#### MANAGEMENT

Emergency exploratory surgery is indicated if torsion is clinically suspected.

Even if its not torsion some relief usually come from decompression of swelling.

Salvage of testis only possible 4-6 hours after onset of torsion.

-operation through the midline scrotal raphe.

-Enter the ipsilateral scrotal compartment; then, deliver and untwist the testis.

-Evaluate the testis for viability. Signs of a viable testis after detorsion include

- ✓ Return of color to pink
- ✓ Return of Doppler flow
- ✓ Arterial bleeding after incision of tunica albuginea.

-If the testis is not viable, remove all the necrotic testis to avoid prolonged, debilitating pain and tenderness. Retention of a necrotic testis may exacerbate the potential for subfertility, presumably because of development of an autoimmune phenomenon which also affect the contralateral testis.

-To prevent subsequent torsion, fix the contralateral testis to the scrotal wall with 3-4 non absorbable sutures. (Orchidopexy). This is also important because bilateral involvement --ie, the "bell clapper" deformity (lack of fixation of the cord structures by the testicular mediastinum) --and the high incidence of recurrent torsion and infertility in bilateral cases.

#### Complications

1. Delay of more than 4-6 hours between onset of symptoms and the time of surgical (or manual) detorsion reduces the salvage rate to 55-85%.
2. Retention of an injured testis can induce pathologic changes to the contralateral testis.
3. Recurrence if orchidopexy not done
4. Infertility

# THORACIC OUTLET SYNDROME

## Background:

- Compression of the neurovascular structures at the superior aperture of the thorax.
- It represents a constellation of symptoms.
- The cause, diagnosis, and treatment are controversial.
- The brachial plexus (95%), subclavian vein (4%), and subclavian artery (1%) are affected

## Pathophysiology:

- The brachial plexus trunks and subclavian vessels are subject to compression or irritation as they course through 3 narrow passageways from the base of the neck toward the axilla and the proximal arm.
- The most important of these passageways is the interscalene triangle, which is also the most proximal. This triangle is bordered by the anterior scalene muscle anteriorly, the middle scalene muscle posteriorly, and the medial surface of the first rib inferiorly.
- This area may be small at rest and may become even smaller with certain provocative maneuvers.
- Anomalous structures, such as fibrous bands, cervical ribs, and anomalous muscles, may constrict this triangle further.
- Repetitive trauma to the plexus elements, particularly the lower trunk and C8-T1 spinal nerves, is thought to play an important role in the pathogenesis of TOS.
- The second passageway is the costoclavicular triangle, which is bordered anteriorly by the middle third of the clavicle, posteromedially by the first rib, and posterolaterally by the upper border of the scapula.
- The last passageway is the subcoracoid space beneath the coracoid process just deep to the pectoralis minor tendon
- The sex ratio varies depending on the type of TOS (eg, neurologic, venous, arterial). Overall, the entity is approximately 3 times more common in women than in men.
- Neurologic - Female-to-male ratio approximately 3.5:1
- Venous - More common in males than in females
- Arterial - No sexual predilection

**Age:** The onset of symptoms usually occurs in persons aged 20-50 years.

## History:

- Neurologic symptoms occur in 95% of cases. The lower 2 nerve roots of the brachial plexus, C8 and T1, are most commonly (90%) involved, producing pain and paresthesias in the ulnar nerve distribution.
- The second most common anatomic pattern involves the upper 3 nerve roots of the brachial plexus, C5, C6, and C7, with symptoms referred to the neck, ear, upper chest, upper back, and outer arm in the radial nerve distribution.

## Neurologic

- Pain, particularly in the medial aspect of the arm, forearm, and the ring and small digits
- Paresthesias, often nocturnal, awakening the patient with pain or numbness
- Loss of dexterity
- Cold intolerance-Raynauds phenomenon
- Headache

**Venous** - Pain, often in younger men and often associated with strenuous work

**Arterial**-Pain, Claudication, Often in young adults with a history of vigorous arm activity

## Physical Exam

- In most cases, the physical examination findings are completely normal.
- Other times, the examination is difficult because the patient may guard the extremity and exhibit giveaway-type weakness. The sensory examination is often unreliable.
- Provocative tests, such as the Adson, costoclavicular, and hyperabduction maneuvers, are unreliable. Approximately 92% of asymptomatic patients have variation in the strength of the radial pulse during positional changes.
- In the Adson test, the patient takes a deep breath and tilts his or her head back and turns it to one side. The physician tests to see if the strength of the patient's pulse is reduced in the wrist on the arm on the opposite side of the head turn.
- In the Allen test, the arm in which the patient is experiencing symptoms is raised and rotated while the head is turned to the opposite side. The physician tests to see if the pulse strength at the wrist is reduced. If the strength of the pulse is reduced in either of these two tests it indicates compression of the subclavian artery.
- The elevated arm stress test (EAST) is of debatable use, but it may be the most reliable screening test. It evaluates all 3 types of thoracic outlet syndrome (TOS).
- To perform this test, the patient sits with the arms abducted 90 degrees from the thorax and the elbows flexed 90 degrees. The patient then opens and closes the hands for 3 minutes.
- Patients with TOS cannot continue this for 3 minutes because of reproduction of symptoms. Patients with carpal tunnel syndrome experience dysesthesias in the fingers, but do not have shoulder or arm pain.
- Neurologic**
- A typical patient is a young, thin female with a long neck and dropping shoulders.
- A positive EAST result and the presence of a radial pulse are strong indicators of neurologic involvement of the brachial plexus.
- Supraclavicular tenderness
- Usually no evidence of muscle atrophy is present, although the classic finding is known as the Gilliatt-Sumner hand with the most dramatic atrophy in the abductor pollicis brevis, with lesser involvement of the interossei and hypothenar muscles
- Paresthesias/sensory loss is restricted to the ulnar aspect of the hand and forearm
- Weakness (usually subtle) of affected
- Venous**
- Edema of the upper extremity
- Cyanosis of the upper extremity
- Distended superficial veins of the shoulder and chest
- Arterial**
- Pallor and pulselessness
- Coolness on the affected upper extremity
- Lower blood pressure in affected arm of greater than 20 mm Hg (a reliable indicator of arterial involvement)
- Rarely can produce multiple small infarcts on the hand and fingers (embolization)



**Causes:** The 3 major causes of TOS are anatomic, trauma/repetitive activities, and neurovascular entrapment at the costoclavicular space.

#### **Anatomic**

**Scalene triangle:** Anterior scalene muscle frontally, middle scalene muscle posteriorly, and the upper border of the first rib inferiorly account for most cases of neurologic and arterial TOS.

**Cervical ribs** are found in most arterial cases but rarely in venous and neurologic cases.

**Congenital fibromuscular** bands are noted in as many as 80% of patients with neurologic TOS.

**Transverse process** of C7 is elongated.

#### **Trauma or repetitive activitie**

-Motor vehicle accident hyperextension injury, with subsequent fibrosis and scarring

-Effort vein thrombosis (ie, spontaneous thrombosis of the axillary veins following vigorous arm exertion)

-Playing a musical instrument: Musicians can be particularly susceptible owing to their need to maintain the shoulder in abduction or extension for long periods

#### **Neurovascular entrapment:**

This occurs in the costoclavicular space between the first rib and the head of the clavicle.

#### **DDX**

Acute Coronary Syndrome

Carpal Tunnel Syndrome

Multiple Sclerosis

Neoplasms, Spinal Cord

Rotator Cuff Injuries

Spinal Cord Injuries

Thrombophlebitis, Superficial

Cervical spondylitis

Mediastinal venous obstruction (eg, Pancoast tumor)

Brachial plexitis

Fibromyalgia

Postural palsy

Raynaud disease

Trauma

Ulnar nerve compression at the elbow

Vasculitis

Vasospastic disorder

#### **Imaging Studies:**

**1.Cervical radiography** - May demonstrate a skeletal abnormality

**2.Chest radiography**

-Cervical or first rib

-Clavicle deformity

-Pulmonary disease

-Pancoast tumour

**3.Color flow duplex scanning** for suspected vascular thoracic outlet syndrome (TOS)

**4.Arteriogram (indications)**

-Evidence of peripheral emboli in the upper extremity

-Suspected subclavian stenosis or aneurysm (eg, bruit or abnormal supraclavicular pulsation)

-Blood pressure differential greater than 20 mm Hg

-Obliteration of radial pulse during EAS

#### **Venography (indications)**

-Persistent or intermittent edema of the hand or arm

-Peripheral unilateral cyanosis

-Prominent venous pattern over the arm, shoulder, or chest

#### **Other Tests:**

**Nerve conduction evaluation** via root stimulation and F wave is the best direct approach to evaluation of neurologic TOS.

**Electromyography (EMG)** is unreliable and does not provide objective evidence of TOS.

**Cervical myelogram, CT scan, or MRI** may be appropriate for patients suspected of having cervical disk disease or spinal cord disease.

# TRACHEOESOPHAGEAL FISTULA

## Introduction

- Blockage of the oesophagus occurs with an incidence of 1 in 3000-4500 live births.
- About **1/3** of the affected infants are **born pre-maturely.**
- Oesophageal Atresia is associated with trachea oesophageal fistula (TOF) in 85% of cases.

## Embryology

- Oesophageal Atresia results from deviation of Tracheoesophageal septum in a posterior direction hence incomplete separation of oesophagus from the laryngotracheal tube.
- There can be failure of recanalization of oesophagus in the 8th week, due to defective growth of endodermal cells

## Types of Esophageal Atresia

1. Proximal blind pouch and distal oesophagus with fistula to trachea >85% Type C)
2. Pure oesophageal atresia/no fistula – 8%.-type A
3. Fistula from both upper and lower oesophageal ends 2%.-type B
4. Isolated tracheoesophageal fistula H type 2%.
5. Atresia with fistula to trachea from both esophageal pouches.

## Clinical presentation

### In Utero

A foetus with oesophageal atresia is unable to swallow amniotic fluid.  
Presents with polyhydramnios.

### At birth

- The newborn appears healthy.
- 1-Excessive Frothy saliva through mouth and nostrils.
- 2-Could be in respiratory distress if they aspirate saliva.
- 3-Repeated episodes of coughing, choking, and cyanosis.
- 4-Attempts at feeding result in choking, gagging, and regurgitation.
- 5-Inability to pass a nasogastric tube into the stomach is suggestive of oesophageal atresia
- 6. VACTER-associated anomalies.

## Investigation

1. CXR- with the NG tube in situ shows the coiled tube in the upper pouch.
2. Plain X-Ray of abdomen showing gas in the stomach indicates a tracheo oesophageal fistula.  
Absence of gas in abdomen indicates no fistula and often this is a long gap defect
- 3.The presence and position of the fistula can also be determined by bronchoscopy
- 4.Water soluble contrast media shows blockage of oesophagus (not recommended) as there is risk of aspiration  
Investigate for other anomalies –VACTREL.

## MANAGEMENT

### INITIAL

#### -Nil per oral

- 1.Insertion of a soft plastic, double-lumen orogastric catheter into the blind upper esophageal pouch, taping it in this position, and

connecting it to constant, low, negative pressure(continuous suction) through **Repro-gel tube**

2. Keeping the **head elevated (ie, 45°)** both facilitates the drainage of secretion into the pouch for suctioning and prevents the reflux of gastric contents into the lungs
- 3.**IV fluids and monitor electrolytes**
- 4..**Prophylactic antibiotics**
- 5.**Maintenance on 5 %Dextrose IV**
6. **Maintain temperature** placed in a humidified incubator

## Definitive management

After the patient is stabilized, there are three potential surgical approaches to this anomaly.

Considerations are:

- 1) Prematurity
- 2) Overall clinical condition
- 3) Associated anomalies
- 4) Length of the gap between the ends of the esophagus

-Usually, the gap is 1 to 2 cm, allowing primary anastomosis of the two ends.

-In a healthy, full-term infant without other severe anomalies and minimal pneumonitis, primary closure of the fistula and an esophageal anastomosis can be performed within the first 24 to 72 hours after birth.

- In this circumstance, a gastrostomy may or may not be performed.

-However, if the infant has a severe pneumonia or other associated significant medical problems that increase the risk of major surgery, only decompressive gastrostomy is performed, thus allowing time for the medical problem to resolve.

-Head-of-bed elevation and upper pouch suction are maintained until surgery can be accomplished.

-In an extremely small infant with or without other severe anomalies and in whom it is apparent that surgical correction of the tracheoesophageal anomaly must be delayed, a decompressive gastrostomy, surgical closure of the tracheoesophageal fistula, and continuous suction of the upper esophageal pouch is appropriate, with the esophageal anastomosis being performed at a much later date.

## Esophageal anastomosis

Primary anastomosis done with short segments of atresia.

If the atretic segment is > than 4cm or more than 6 vertebral bodies then esophageal replacement required.

## Short Gap;

-Performed on the side opposite to the aortic arch, usually the right at the level of the 4th ICS -approximately at the carina

-Performed Extra pleural to avoid leaving a chest tube for drainage after (not drained)

-Ligate the azygous vein as it crosses the lower oesophagus to the SVC

-Identify the vagus nerve as it lies on the oesophagus & safeguard it

-Identify proximal pouch - Identification of the upper pouch is facilitated by intermittent pressure by the anaesthetist on a previously positioned large upper pouch tube.

-A traction suture is placed in the tip of the pouch and the pouch dissected as high as possible, taking care not to enter the closely adherent trachea.

-Achieve end-to-end anastomosis between the blind upper segment & the lower segment - Use 6 isolated single stitches with

lots of tissue in-between to avoid stricture formation & to ensure the ring will grow.  
-A transanastomotic NG tube for suctioning & later feeding is passed across the posterior wall into the stomach and the anterior wall is completed.

#### **Long Gap options;**

-Cervical Oesophagostomy to drain saliva & Gastrostomy for feeding then;  
-Reversed gastric tube - A tube flap is made from the greater curvature of the stomach based on left gastroepiploic vessels & rotated to bridge the gap

#### **Types of esophageal replacements**

- 1.Colonic interposition-most popular
- 2.Gastro-tuboesophagoplasty
- 3.Gastric transposition
- 4.Jejunal interposition

#### **POSTOPERATIVE MANAGEMENT**

- 1.Start NGT feeding on Day 4
2. Day 10 - Do a **Danosil swallow** - to visualise anastomosis - Check for leakage; if any, wait for further healing. If no leakage, remove transanastomotic tube & feed PO
- 3.Stenosis will require dilatation later in theatre under GA by a radiologist

#### **COMPLICATIONS OF ESOPHAGEAL REPAIR**

##### **1. Leakage through the anastomosis**

-Common-in up to 50% of patients.  
- Feedings are introduced very slowly, because reflux into the esophagus could threaten the integrity of the anastomosis.  
-If the infant is well for 1 week, radiographic contrast studies are performed, and if the anastomosis is intact, the infant is gradually allowed to begin oral feedings.  
-An anastomotic leak usually presents with tachypnea and sepsis on the third or fourth postoperative day.  
-Management usually is conservative, with antibiotics and, if necessary, placement of a chest tube.  
Over time, the leak usually seals, and feeding can be started.

##### **2. Stricture formation**

-at the site of the esophageal anastomosis frequently occurs in the first weeks to months after repair.  
-This narrowing may require repeated dilatation.  
-Severe strictures require resection and secondary anastomosis.

##### **3. Dysphagia-**

Particularly for solids) is common because peristalsis is abnormal in the lower esophageal segment.

##### **4.Gastroesophageal reflux disease**

-With esophagitis risk of Barrett's esophagus and adenocarcinoma later on  
-Anti reflux fundoplication may be necessary early  
Children who have required an esophageal replacement procedure are at even higher risk of gastroesophageal reflux with ulceration of the interposed segment

##### **5.Distended interposed segments**

-Particularly colonic or gastric interposition may distend with time, further compromising pulmonary function and occasionally requiring surgical revision.

#### **Other complication**

- 6.Respiratory complications
  - Either pre or post operative pneumonia.
  - Pulmonary collapse or pneumothorax.
7. Recurrence of tracheoesophageal fistula.
- 8.Tracheal malacia

# UPPER GIT BLEEDING

UGIB is defined as bleeding derived from a source proximal to the ligament of Treitz.

Acute gastrointestinal (GI) bleeding is a potentially life-threatening abdominal emergency

## Incidence

- The incidence of upper gastrointestinal bleeding (UGIB) is approximately 0.1 % of the general population.
- Bleeding from the upper GI tract is approximately 4 times as common as bleeding from the lower GI tract and is a major cause of morbidity and mortality.
- The use of various endoscopic techniques, medical therapies, and visceral angiography has progressively diminished the role of surgery in the emergent management of UGIB
- Nevertheless, operative intervention still represents the most definitive intervention and remains the final therapeutic option for many bleeding lesions of the upper GI tract.
- Of patients who develop UGIB, 3-15% require a surgical procedure.

## Clinical presentation

Hematemesis and melena are the most common presentations of acute UGIB, and patients may present with both symptoms. Occasionally, a brisk UGIB manifests as hematochezia.

### In order of frequency:

1. Hematemesis in 40-50% patients.
2. Melena in 70-80% of patients.
3. Hematochezia
4. Syncope
5. Presyncope

### Symptoms 30 days prior to admission

1. Dyspepsia, Epigastric pain, Heartburn
2. Diffuse abdominal pain
3. Dysphagia
4. Weight loss
5. Jaundice

The history findings can be extremely helpful in determining the location of the GI hemorrhage.

- Alcohol abuse or a history of cirrhosis should elicit consideration of portal gastropathy or esophageal varices -A history of recent nonsteroidal anti-inflammatory drug (NSAID) abuse -a gastric ulcer or chronic back -pain -need for NSAIDs
- History of treatment for Peptic ulcers-bleeding could be PUD or gastric ulcers.

## Differential diagnoses for UGIB

- 1) Gastric ulcer and Duodenal ulcer
- 2) Esophageal varices /Gastric varices
- 3) Mallory-Weiss tear, Boerhave tear
- 4) Esophagitis, Hemorrhagic gastritis
- 5) Neoplasm-Esophageal ca, stomach ca, Kaposi sarcoma.
- 6) Dieulafoy lesion
- 7) Arterio-venous malformations.
- 8) Angiodysplasia
- 9) Hemobilia
- 10) Pancreatic pseudocyst and Pancreatic pseudoaneurysm
- 11) Foreign body 14. Merks diverticulum
- 12) Coagulopathy 13. Aortoenteric fistula

## MANAGEMENT

Resuscitation of a hemodynamically unstable patient begins with assessing and addressing the ABCs (ie, airway, breathing, circulation) of initial management.

Earliest opportunity is taken to intubate the patient and avoid risk of aspiration.

Using two large bore venous access in the antecubital fossa.

Replace blood loss with crystalloid in the ratio of 1 ml of blood loss replaced by 3ml of crystalloid.

Urethral catheter for monitoring the urine production.

Continuously monitor the resuscitation measures especially the circulatory aspect:

- ✓ Urine output should be 30-50ml/hr
- ✓ BP monitoring systolic BP not <90mmHg
- ✓ Decrease in BP and urine output suggest need for colloids but a decrease in urine output but normal BP suggest need for crystalloids
- ✓ Pulse. Pulse should be less than 120/minute
- ✓ Pulse oximetry
- ✓ CVP monitoring the best to avoid over-infusion
- ✓ State of patient should be calm

-Once the maneuvers to resuscitate are underway, insert a nasogastric tube (NGT) and perform an aspirate and lavage procedure.

-This should be the first procedure performed to determine whether the GI bleeding is emanating from above or below the ligament of Treitz.

- If the stomach contains bile but no blood, UGIB is less likely. If the aspirate reveals clear gastric fluid, a duodenal site of bleeding may still be possible

## Surgical therapy:

### Endoscopy

Both diagnostic and therapeutic Upper GIT bleeding.

Endoscopy should be performed immediately after endotracheal intubation (if indicated) and hemodynamic stabilization.

Endoscopy is now the method of choice for controlling active ulcer hemorrhage and variceal bleeds.

### Methods for hemostasis.

- 1) Injection of vasoactive agents
- 2) Injection of sclerosing agents
- 3) Coagulation-types
  - ✓ Bipolar electrocoagulation
  - ✓ Thermal probe coagulation
  - ✓ Laser photocoagulation
  - ✓ Argon plasma coagulator
- 4) Band ligation
- 5) Pressure tamponade -with Constant probe
- 6) Application of hemostatic materials, including biologic glue

The 3 most popular methods of hemostasis are injection therapy, coaptive coagulation, and laser phototherapy

### Vasoactive agent injection

a) Epinephrine -diluted (1:10,000) and injected as 0.5- to 1-mL aliquots. Works by inducing vasoconstriction and decreasing blood flow to the area.

This allows for increased platelet function and clot formation to attain hemostasis.

However, the tamponade effect produced by injecting the volume of drug into the tissue surrounding the bleeding lesion may also facilitate hemostasis.

b) Injecting a volume of sterile **isotonic sodium chloride** solution and providing a tamponade effect also leads to hemostasis, although not as effectively as epinephrine

### **2. Sclerosant injection**

The sclerosant solutions used today include

- ✓ Absolute ethanol
- ✓ Polido-canol
- ✓ Sodium tetradecyl sulfate.

-These achieve hemostasis by inducing thrombosis, tissue necrosis, and inflammation at the site of injection.

-When large volumes are injected, the area of tissue necrosis can produce an increased risk of local complications such as perforation.

### **3. Coaptive coagulation**

-Uses direct pressure and thermal therapy to achieve hemostasis.

-Thermal therapy includes monopolar and bipolar electrocoagulation and heater-probe application.

-The bleeding vessel is isolated, compressed, and tamponaded prior to coagulation therapy. By using both maneuvers, the depth of tissue injury is minimized.

-Coaptive coagulation is as effective as injection therapy in achieving hemostasis

-Combining injection therapy with heater-probe coagulation can be used in an attempt to reduce the rebleeding rate in high-risk patients who have spurting arterial bleeding observed during endoscopy

### **Other aspects of treatment**

#### **Duodenal Ulcers**

Proton pump inhibitors decrease rebleeding rates in patients with bleeding ulcers associated with an overlying clot or visible nonbleeding vessel in the base of the ulcer.

It is administered at the same time as endoscopy.

The indications for surgery in patients with bleeding peptic ulcers are as follows:

- 1) Severe life-threatening hemorrhage not responsive to resuscitative efforts
- 2) Failure of medical therapy and endoscopic hemostasis with persistent recurrent bleeding
- 3) A coexisting reason for surgery such as perforation, obstruction, or malignancy
- 4) Prolonged bleeding with loss of 50% or more of the patient's blood volume
- 5) A second hospitalization for peptic ulcer hemorrhage

The 3 most common operations performed for a bleeding duodenal ulcer are as follows

a) Truncal vagotomy and pyloroplasty with suture ligation of the bleeding ulcer

c) Truncal vagotomy and antrectomy with resection or suture ligation of the bleeding ulcer

d) Proximal (highly selective) gastric vagotomy with duodenostomy and suture ligation of the bleeding ulcer

-The purpose of the vagotomy is to divide the nerves to the acid-producing body and fundus of the stomach.

-This inhibits the acid production that occurs during the cephalic phase of gastric secretion.

-Although acid secretion is controlled, gastric motility and gastric emptying is affected

-Eradication of *H pylori* can reduce the risk of rebleeding

-Lansoprazole 30 mg plus amoxicillin at 1 g plus clarithromycin at 500 mg q12h for 2 weeks.

### **To diagnose H.pylori**

a) The endoscopic tests include culture, histology, and a rapid urease test (RUT). RUTs are based on the urease-producing activity of *H pylori*. If urease is present, then urea is hydrolyzed, thus releasing ammonia that raises the pH.

b) Available nonendoscopic tests are the urea breath test and serologic testing.

### **GASTRIC ULCERS**

The 3 most common complications of a gastric ulcer that surgical intervention is hemorrhage, perforation, and obstruction.

The goals of surgery are to correct the underlying emergent problem, prevent recurrent bleeding or ulceration, and exclude malignancy.

A bleeding gastric ulcer is most commonly managed by a distal gastrectomy that includes the ulcer with a gastroduodenostomy or a gastrojejunostomy reconstruction.

The common operations for the management of a bleeding gastric ulcer include

(1) truncal vagotomy and pyloroplasty with a wedge resection of the ulcer

(2) antrectomy with wedge excision of the proximal ulcer, (3) Distal gastrectomy to include the ulcer with or without truncal vagotomy

(4) Wedge resection of the ulcer only.

The choice of operation type of ulcer and hemodynamic stability of the patient to withstand an operation.

Five types of gastric ulcers occur, based on their location and acid-secretory status.

Type 1 gastric ulcers are located on the lesser curvature of the stomach and are not associated with a hypersecretory acid state.

Type 2 ulcers represent a combination of 2 ulcers that are associated with a hypersecretory acid state. The 1<sup>st</sup> ulcer is in the body of the stomach, 2<sup>nd</sup> ulcer in the duodenum.

Type 3 ulcers are prepyloric ulcers. They are associated with high acid output and are usually within 3 cm of the pylorus.

Type 4 ulcers are located high on the lesser curvature of the stomach and (as with type 1 ulcers) are not associated with high acid output.

Type 5 ulcers are related to the ingestion of NSAIDs or aspirin. These ulcers can occur anywhere in the stomach.

A vagotomy is added to manage type 2 or type 3 gastric ulcers.

### **3. VARICEAL BLEEDS**

#### **Pharmacologic therapy**

The patient with acute variceal bleeding may initially be treated with

- intravenous vasopressin and nitroglycerine
- somatostatin, or one of its analogs (eg, octreotide).

Vasopressin is a potent splanchnic and systemic vasoconstrictor, including coronary vasoconstriction. Nitroglycerin should be concomitantly administered to titrate and maintain the SBP in the range of 90-100 mm Hg. Nitroglycerin should be initiated at 40 mcg/min to protect the coronary arteries from the profound adverse cardiovascular effects of the vasopressin. The intravenous infusion of vasopressin is started at 0.2-0.4 U/min.

### **Endoscopy**

The 2 main endoscopic techniques available to control variceal bleeding are endoscopic sclerotherapy and endoscopic variceal band ligation.

Endoscopic sclerotherapy involves injecting a sclerosing agent, such as ethanolamine or polidocanol, into the varix lumen (intravariceal) or immediately adjacent to the vessel (paravariceal) to create fibrosis in the mucosa overlying the varix, which leads to hemostasis. Endoscopic variceal banding ligation consists of the placement of a rubber band around the varix. This technique is performed by first sucking the varix into a sheath attached to the distal end of the endoscope. Once the varix is suctioned into the sheath, a trigger device allows the deployment of a rubber band around the varix, a procedure that strangulates the varix.

Variceal banding associated with significantly lower mortality rates, lower variceal rebleeding, less esophageal perforation, and stricture formation compared to sclerosants

### **Balloon tamponade**

Can be a life-saving maneuver when medical and endoscopic efforts fail to control the bleeding. Achieve temporary control of the bleeding but recurrent bleeding with release of the tamponade occurs in most patients

They are also cause complications as

- ✓ Airway obstruction
- ✓ Aspiration
- ✓ esophageal necrosis with rupture

Because of the severe life-threatening complications and limited use, the tubes are used only as a temporary measure while the patient is resuscitated.

The tubes act as a bridge to help stabilize the patient until a time when the patient is prepared for either a repeat endoscopy procedure or a portal pressure decompression through a radiological or surgical method

The 2 most commonly used tubes are the Sengstaken-Blakemore tube and the Minnesota tube. These tubes have an esophageal balloon and a gastric balloon that are inflated to produce a tamponade effect after confirming appropriate anatomical placement.

Before use endotracheal intubation to secure and protect the patient's airway

Major complications of balloon tamponade

- 1) Esophageal rupture
- 2) Tracheal rupture
- 3) Duodenal rupture
- 4) Respiratory tract obstruction
- 5) Aspiration
- 6) Hemoptysis
- 7) Tracheoesophageal fistula
- 8) Jejunal rupture
- 9) Thoracic lymph duct obstruction
- 10) Esophageal necrosis
- 11) Esophageal ulcer

Minor complications

- 1) Nasopharyngeal bleeding
- 2) Chest pain
- 3) Balloon impaction and/or migration (nausea and vomiting)
- 4) Alar necrosis

The tube is first introduced into the stomach, and a small amount of air is injected into the gastric balloon. A radiograph is then obtained to confirm placement in the stomach. Once proper placement is confirmed, the gastric balloon is inflated with 300-350 mL of air and is pulled up into the gastric fundus, compressing the gastroesophageal junction. The tube is secured to the facemask of a football helmet placed on the patient's head. The esophageal balloon is then inflated to a pressure of 40 mm Hg. Another radiograph is obtained to confirm proper placement of both tubes. Deflate the esophageal balloon every 4 hours for 15 minutes to avoid esophageal pressure necrosis. Do not leave the entire tube in place for more than 24-48 hours.

### **Transjugular intrahepatic portosystemic shunt**

Transjugular intrahepatic portosystemic shunt (TIPS) decompression of the portal system can be achieved through either radiologic or surgical methods. The goal is to reduce intravariceal pressure to less than 12 mm Hg. The TIPS procedure for bleeding esophagogastric varices that are unresponsive to endoscopic and pharmacologic first-line treatment

By surgery -Portacaval shunt (end-to-side) or (side-to-side)

# URETHRAL STRICTURES

## Definition

-Fibrosis of the urethral urothelium leading to scar tissue formation which contracts and reduces the caliber of the urethral lumen, causing resistance to the antegrade flow of urine.

## -Relevant Anatomy:

The urethra is divided into anterior and posterior segments. The anterior urethra (from distal to proximal) includes the meatus, fossa navicularis, penile or pendulous urethra, and bulbar urethra. It lies within the corpus spongiosum, beginning at the level of the bulbous urethra and extending distally through the length of the penile urethra.

-The bulbar urethra begins at the root of the penis and ends at the urogenital diaphragm.

-The penile urethra has a more central position within the corpus spongiosum in contrast to the bulbous urethra, which is more dorsally positioned

The posterior urethra (from distal to proximal) includes the membranous urethra and the prostatic urethra.

-The membranous urethra involves the segment extending from the urogenital diaphragm to the verumontanum.

- The prostatic urethra extends proximally from the verumontanum to the bladder neck.

The soft tissue layers of the penis, from external to internal

- Skin
- Superficial (dartos) fascia
- Deep (Buck) fascia,
- Tunica albuginea surrounding the corpora cavernosa and corpus spongiosum.

-The superficial vascular supply to the penis comes from the external pudendal vessels, which arise from the femoral vessels.

-The deep penile structures receive their arterial supply from the common penile artery, which arises from the internal pudendal artery.

-The scrotum receives its vascular supply via branches from both the external and internal pudendal arteries

## Etiology:

Congenital or acquired.

## Congenital

1. Epispadias-Abnormal urethral opening on the dorsal aspect of the penis.

Some epispadias are accompanied by anterior abdominal wall defects and bladder extrophy

2. Hypospadias-abnormal urethral opening on the ventral aspect

3. Urethral valves especially the posterior urethral valves

4. Congenital stenosis of the meatus urethra

## Acquired

The most common causes of urethral stricture

1. Traumatic (commonest cause) e.g. pelvic fracture (of the pubis & ischial rami), saddle injury, penile fracture

2. Iatrogenic-surgery (Prostatectomy) and instrumentation (Indwelling catheter,Urethral endoscopy)

3. Infectious- Post-gonorrhoea, tuberculous urethritis, chlamydial infection of the membranous urethra or schistosomiasis

4. Malignancy-penile shaft squamous cell cancer, field effect from transitional bladder cancer.

The male urethra is about 15-17cm

The female urethra is 3.5-5.5 cm

## Investigations

### Lab Tests

1. FHG-for theatre
2. Urinalysis-UTI
3. Random blood sugar-DM neurogenic bladder can present in similar fashion
4. U/E/C-theatre prep and hydronephrosis.
5. Elderly patients PSA –prostatic cancer or enlargement

### Imaging Studies:

The entire urethra, both proximal and distal to the strictured area, must be evaluated endoscopically and/or radiographically prior to any surgical intervention.

Radiographic evaluation of the urethra with contrast studies is best achieved by retrograde urethrogram or antegrade cystourethrogram if the patient has an existing suprapubic catheter

Accurately documenting the extent and location of the stricture is important so that the most effective treatment options can be offered to the patient

Complete stricture - MCU + Ascending /Retrograde CU

Incomplete stricture - MCU

### 1-Retrograde urethrogram

involve placing a nonlubricated 8F or 10F urethral catheter into the fossa navicularis and inflating the balloon with 1-3 mL of sterile water until the balloon occludes the urethral lumen.

Approximately 10 mL of iodinated contrast media then is injected into the catheter under fluoroscopy, and images of the anterior urethra are taken.

This must be combined with MCU to localize the stricture

### 2-An antegrade cystourethrogram

involves distending the bladder with water-soluble contrast media via a suprapubic tube or urethral catheter.

A scout film is taken before administration of contrast material.

Once the bladder is fully distended with contrast media, the suprapubic tube is clamped or the urethral catheter is removed and the patient is asked to void. Spot films are taken before, during, and after the voiding phase.

### 3.Micturating cystourethrogram

This is usually sufficient is posterior urethral valves in children.

### 4. Cystourethroscopy

Endoscopic evaluation can be conducted by flexible cystourethroscopy +/- biopsy

### 5.Abdominal pelvic ultrasound

Evaluate the bladder wall for fibrosis and hypertrophy.

Ureters and kidneys evaluated for dilated uropathy

### 6.IVU

This is indicated if hydronephrosis and hydroureters.

## MANAGEMENT

### Dilatation

-The goal is to stretch and dilate the stricture without producing additional scarring and allow for urine flow

-Serial dilatations first 2 weekly ,then monthly,2 monthly ,6 monthly and aim for dilatation annually.

-It may be curative in patients with isolated epithelial strictures (no involvement of corpus spongiosum). -However, the trend has been towards endoscopic and open surgical management of the strictures.

#### Complications of DVU

- Recurrence of stricture - is the most common complication –very high up to 50 %of case
- Bleeding.
- Extravasation of irrigation fluid into perispungial tissues.
- Increasing fibrotic response worsening the stricture.

Typically, an indwelling urethral catheter is left in place for 14 days to allow granulation tissue re-epithelization

#### Open reconstruction

##### Primary repair –One stage open urethroplasty

Primary repair involves complete excision of the fibrotic urethral segment with re-anastomosis. The key technical points that must be followed include

- Complete excision of the area of fibrosis
- Tension-free anastomosis
- Widely patent anastomosis.

Primary urethrotomy depend on site and length of the stricture. Primary repair typically is used for stricture lengths of less than 2 cm. Complete strictures resection and free tube graft or pedicle graft can be done

In pedicle graft the scrotal or penile skin may be rotated and used as a tissue graft although it has many disadvantages and less popular. The scrotal skin has ruggae, hair and sebaceous gland. Leads to collection of urine and stasis and infection.

Commonly used is buccal mucosa. Advantages include: 1. The tissue is resistant to infection and trauma.

- The epithelium is thick, making it easy to handle.
- The lamina propria is thin and highly vascular, allowing efficient imbibition and inosulation.
- Harvesting is easier than other free grafts or pedicled flaps
- Elastic and can be stretched.

NB. In penile strictures no primary anastomosis done because of risk of chordee formation. Do grafting or staged urethral repair. The repair is left stented with a small silicone catheter in the urethra for 2weeks.

##### Staged urethroplasty

###### Two-stage urethroplasty

- If previous procedures are unsuccessful
- Stricture >2cm
- Penile strictures-avoid chordee formation
- Multiple strictures

###### 1st stage

-Open up the urethra and excise stricture and surrounding fibrotic tissues

-Suture it to the surrounding skin & leave urethral catheter in-situ for 2wks as the wound heals.

-After 2 weeks remove the catheter and start serial dilatation every 2 weeks of the proximal stoma for 8 weeks.

During this time the urine may be passed from the proximal stoma created in the urethra.

###### 2nd stage

Refashioning of the urethra & perineum by covering of the urethra with skin flaps from both sides.

The various parts of the male urethra have relatively different acquired etiology of the urethral stricture

##### Anterior urethra.

- Bulbar urethra

Trauma-falling astride(man-hole injuries),instrumentation-passing sounds ,infections especially around the glands around this segment makes treatment difficult

ii)Penile urethra –instrumentation, infections

iii) Glans meatus-instrumentation, infections especially the **BXO(the balanitis xerotica obliterans)**. It is thought to be caused by lichens causing inflammation and leukoplakia.It is usually very painful.

##### Posterior urethra

i)Bladder neck-Instrumentation, cystitis, TURP

ii)Prostatic urethra/membranous urethra-Trauma-Fracture pelvic rami ,surgery-open or closed prostatectomy ,instrumentation

#### DIAGNOSIS

Diagnosis is made based on a suggestive history, findings on physical examination, and radiographic or endoscopic techniques.

##### Clinical presentation.

The most common presentation includes obstructive voiding symptoms

The patient may present with acute urinary retention-acute onset, painful and patient can't pass urine.

Chronic urinary retention-gradual occurrence, not painful and patient can pass some urine.

- Straining at urination
- Weak stream, splaying of the urinary stream
- Urinary retention/ incomplete emptying of the bladder
- Urinary terminal dribbling,
- Urinary intermittency/hesitancy
- Dysuria
- Nocturia
- Recurrent Urinary tract infections

These symptoms are progressive for many patients.

##### Stricture Complications

- Recurrent Infection e.g. UTI, STI
- Calculi formation
- Urine Extravasation
- Urethral diverticulum
- Periurethral abscess
- Urethral fistula - Usually 2° to bursting or incision of a periurethral abscess. If the fistulae arise behind a tight stricture, there may be multiple openings - watering-can perineum
- Abdominal straining to void urine causes; Hernia ,Haemorrhoids, Rectal prolapse
- Dilated uropathy- hydroureters, hydronephrosis

##### Permanent urethral stents

Permanent urethral stents are endoscopically placed. Stents are designed to be incorporated into the wall of the urethra and provide a patent lumen. They are most successful in short-length strictures in the bulbous urethra. Complications occur when a stent is placed distal to the bulbous urethra, causing the patient pain while sitting or during intercourse. Other complications involve migration of the stent.

-It may be best reserved for patients who are medically unfit to undergo lengthy open urethral reconstruction procedures

##### Internal urethrotomy

Internal urethrotomy involves incising the stricture transurethral using endoscopic equipment. The incision allows release of scar tissue. Success depends on the epithelialization process finishing



before wound contraction significantly reduces the urethral lumen caliber.

**i) Direct vision internal urethrotomy (DVIU)**

Endoscopic incision is made under direct vision at the 12 o'clock position with a urethrotome. Care must be taken not to injure the corpora cavernosa because this could lead to erectile dysfunction. It is not done for membranous urethra because of the proximity to the internal sphincter mechanism.

DVIU is not appropriate for bulbar urethra and open urethrotomy advocated

- ii) Internal Blind urethrotomy
- iii) Perineal urethrotomy

**Postoperative details**

1. Patients are placed on bedrest for 24-48 hours, depending on the extent of the procedure.
  2. Intravenous antibiotics are continued for 24 hours and then followed with oral culture-specific antibiotics or antibiotics with good gram-negative coverage for 2-3 days.
  3. Advise on sexual abstinence
  4. Catheter left in situ for 2 weeks
  5. Wounds should be washed with soap and water daily after drains are removed.
- Prior to removal of the urethral catheter, a voiding cystourethrogram is conducted with contrast, instilled through the suprapubic tube. If no evidence of contrast extravasation occurs and the suture line is intact, then the urethral catheter is removed and the suprapubic tube is capped.

**Complications**

1. Urinary tract infection
2. Wound infection
3. Wound dehiscence
4. Urethrocutaneous fistula
5. Recurrence of urethral stricture

**Post-op**

- Catheterize with a 3-way catheter for irrigation for 1-2 days (Until clear on irrigation)
- Insert urethral catheter for 2wks
- Repeat Urethral calibration/Flow rate to determine improvement
- Discharge on clean intermittent self catheterization with Nélaton catheter (Filiform is better)

## URINE RETENTION CAUSES

### **a) Bladder wall causes;**

1. Congenital e.g. Ectopia vesicae, Brune belly syndrome
2. Infections e.g. Schistosomiasis, TB
3. Trauma-Blood clots ,muscle injury
4. Tumours - Ca bladder
5. Neurogenic bladder

### **b) Bladder Neck**

1. Congenital -Posterior urethral Valve in boys, Bladder neck stenosis
2. Urinary Calculi
3. Strictures
4. Tumours-Urothelial cancer, polyps, cysts
5. Trauma-blood clots, pubic rami fractures

### **c) Prostrate urethra**

1. Prostatitis
2. BPE
3. Ca prostate
4. Prostatic calculi

### **d) Anterior Urethra**

1. Congenital e.g. hypospadias, epispadias
2. Strictures usually 2° to chlamydial infection ,iatrogenic-catheter insertion, surgery
3. Trauma - Fracture of the penis
4. Urinary calculi
5. Tumours - Ca urethra. Penile cancer
6. Meatal stenosis ,Phimosis

# VARICOSE VEINS

## DIAGNOSIS AND MANAGEMENT.

### Definition

Varicose veins are dilated, elongated and tortuous veins. Varicose veins are signs of chronic venous insufficiency

### Incidence

It is estimated that 10-20% of the world's population has varicose veins in the lower extremities.

### Sex

They are more common in women, and the prevalence increases with age.

### Location

They are most common in the lower extremities-medial aspect of leg.

But also occur in other areas, such as the spermatic cord (varicocele), esophagus (esophageal varices), and anorectum (hemorrhoids).

### Classification

On the basis of predisposing factors varicose veins are divided into two classes: primary and secondary.

Primary varicose veins are associated with normal deep veins.

Secondary varicose veins, are complication of deep venous disease or arteriovenous fistula.

### Etiology

#### **Primary varicose**

1. Incompetence of the valves- either in the main saphenous trunks or in the communicating veins ( perforators)Incompetent valves cause higher pressure at the subjacent valve and localized dilatation of the affected venous segment.

2. Weak wall theory assumes an inherited weakness of the vein wall, producing venous dilatation even with normal pressures and secondary failure of valvular competence.

-50% of patients give a family history of the illness.

-Varicose veins more common in pts with diverticular disease of the colon and low-roughage diet.

-Aggravating factors associated with an increased incidence of varicose veins are

- Female sex
- Parity
- Constricting clothing
- Prolonged standing
- Marked obesity
- Estrogens replacement or oral contraceptives.

#### **Secondary varicose veins**

##### DVT

-Develop following damage or obstruction to the deep veins.

Recanalization of the thrombosed deep veins leaves the valves incompetent, and this loss of valve sufficiency leads to reflux and places an unusual strain on the superficial veins, which have little external support because of their location relative to the deep fascia of the leg.

Obstruction of the inferior vena cava or iliac veins can result in secondary varicosities in the lower extremities.

### An arteriovenous fistula

An arteriovenous fistula may also lead to regional varicose veins. Klippel-Trenaunay syndrome (congenital arteriovenous malformation)associated with extensive varicosities of the lower extremities, usually in atypical locations (eg, lateral), and absence or maldevelopment of the deep veins.

## DIAGNOSIS

### History

-Leg pain and discomfort- Pain dull, heavy, bursting sensation, especially after prolonged standing , prolonged inactivity and is relieved by elevation of the leg , by the use of an elastic stocking and activity as walking

-Leg swelling-The swelling is mild and usually involves the feet and ankles only. It resolves completely on elevation of the leg in bed overnight.

-Skin itchiness and changes in pigmentation.

-In women, symptoms are often more severe in the few days just prior to menses

-The symptoms of primary varicose veins are rarely severe, and most patients seek medical advice for cosmetic reasons.

Secondary varicose veins due to chronic deep venous insufficiency often cause more severe symptoms.

-Leg ulcers-Progression to ankle ulcers is relatively common in secondary ulcers, whereas this complication is rare with primary varicosities.

-Hemorrhage, sometimes of serious magnitude, may be induced by traumatic rupture of a varix or may be spontaneous

-Predisposing factors

-Hormonal contraceptives

-Parity-Multiparity predispose

-Current or last pregnancy

-Occupation- prolonged standing?

-Cigarette smoking

-HTN and DM

-Family history

-Previous hx of deep venous thrombosis

-Previous fractures of femur or pelvis or surgery

-Prolonged immobilization-chronic illness or fractures

-Rule out other causes of ulcers

## MIDNIGHT

M-Metabolic causes as diabetes mellitus

I-Insufficiencies-Ischemia-Venous ,arterial insufficiency (atherosclerosis,embolic,thrombotic)

D-Degenerative conditions-SLE,RA, Ulcerative colitis

N-Neoplastic causes-SCC, Malignant melanoma, Basal cell carcinoma

N-Neuropathic -DM,Leprosy,Tarbes dorsalis,Paraplegia

I -Infectious causes-tropical ulcers-TB, Fungi

H-Hematological -Sickle cell disease, Leukemia

T-Trauma

## ON EXAMINATION

General examination

CVS examination

## LOCAL EXAMINATION

Should be done when the patient is standing:

### Inspection

1. Reveals dilated, elongated, and tortuous subcutaneous veins of the thigh and leg.

### 2. Swelling

This is mainly due to oedema which may be localized or found extensively over the limb.

The volume of over distended veins can also make a significant contribution to the bulk of a limb, especially in foot. Measure the limb girth from tibial tuberosity.

General inspection of calf muscles for any signs of DVT – swollen, skin stretched and shiny

3. Sacculles along the veins

4. Induration- A characteristic diffuse fibrosis develops in the subcutaneous tissues

5. Pigmentation- is due to the accumulation of haemosiderin in the skin. It is often the earliest

6. Ulceration-A venous ulcer will always be surrounded by pigmented skin and at least some indurations. Causes of ulcerations in Varicose veins:

-ischemia and poor perfusion

-Infection

-Poor healing

-Itchiness and scratching

### Examination of ulcers

- Site
- Size
- Shape
- Edges(undermined eg buruli ulcer, overhanging eg malignant ulcer,irregular or regular)
- Depth
- Floor-clean, necrotic tissue, granulation tissue,bleeds
- Base-palpated ,mobility, tenderness
- Surrounding areas

7. Eczema and dermatitis

### Palpation

-If there is apparent swelling, is there any pitting edema?

-Are varicose veins warm to touch ?

-Do they show a cough impulse ? Varicose veins commonly give a palpable impulse when the patient coughs. This is because there is no functioning valve between the abdomen and the vein, and it confirms incompetence in the valves of deep and superficial veins leading down to this point.

-If there is an isolated bulge on the inner thigh, is there a thrill on coughing indicating an underlying jet of blood through a leaking valve?

### Tap-wave test (percussion test of Chevrier)

In the standing patient with fully distended veins, a tap or sharp compression of a vein will send a corresponding wave of movement along its length, easily detected by light touch. This assists in mapping out the varicose vein involved.

### Examination with patient horizontal and the limb elevated to 45

Hollows and grooves in the elevated limb

When the limb is elevated the veins will empty and the space occupied by large varicose veins becomes a hollow or a groove readily palpable or even visible. This is particularly marked when the surrounding tissues have become fibrotic in response to venous hypertension.

### The Brodie- Trendelenburg type of test (selective occlusion test)

Brodie-Trendelenburg test is a useful maneuver to test the valvular competence of the perforating veins and those in the greater saphenous system. With the patient supine, the leg is elevated until all the blood is drained from the superficial veins. The saphenofemoral junction is occluded with a tourniquet and the patient asked to stand and the filling pattern of the veins observed.

If the veins fill rapidly from below, the valves in the perforating veins are incompetent and the varices are being filled from the deep system.

If varicosities are due to saphenofemoral valve insufficiency, the varicosities will remain flat or undetectable when the patient stands.

The tourniquet can be applied at different levels to get the level of the incompetent perforators.

### Perth's Test

Tests the deep venous pumping system and perforators. If positive then the problem lies in the superficial veins.

### Other examination

1. Report pulses-dorsalis pedis,popliteal and femoral pulses to rule out arterial insufficiency

2. Lymphadenopathy –inguinal to rule out malignant ulcers especially malignant melanoma.

- infectious causes

3. Sensory examination of the lower limb to rule out the neuropathic ulcers

### Investigations

#### Laboratory

1. Random blood sugar-Diabetic mellitus

2. FDP-Fibrinogen Degradation Products

3. D-Dimers

4. Homocysteine

#### Other Baseline

U/E and Creatinine-end organ failure ulcers, HTN

FHG-Anemia, Infections ,leukemia

### Imaging

1. Doppler Ultrasonography- 3-D,2-D,Colour Doppler

Hand held Doppler check for:

-DVT

-Incompetent perforators

-Reflux

-At sonography compressibility test of veins shows venous HTN if the veins can not be compressed.

2. Venogram

3. Ples-thysmo-graphy

4. Vascular MRI

### MANAGEMENT

-Ulcer management

-Management of varicose veins

-Management of underlying cause

### Ulcer management

-Pus swab for MCS

-Clean and dress wound daily. Dress with honey or sugar dressing.

- Antibiotics as appropriate if infected.
- If wound clean- secondary wound closure may be done if not skin graft.
- Eczematous skin-Dexamethasone cream

### Varicose veins Management

- Treatment of varicose veins should relieve discomfort, prevent or ameliorate the complications of venous stasis, improve the appearance of the extremity, and, if possible, eliminate the cause of the varicosities to prevent progression of the disease.
- About one-third of patients with simple varicose veins require no therapy at all or only advice about taking care of their legs.

#### 1.Nonoperative Management:

- Aim to improve venous return and reduce pressure in varicose superficial veins.
- Encourage walking discourage prolonged sitting and standing.
- Elevate the leg as frequently as possible to reduce venous pressure.
- Properly fitted elastic stockings will compress the superficial veins and prevent reflux of blood from the deep to the superficial veins via incompetent perforators, prevent edema, and assist the muscular pumping action of the calf.
- Elastic support combined with periodic elevation and exercise is the treatment of choice for most patients with uncomplicated varicose veins and gives excellent relief of symptoms when the varicosities are mild.

#### 2. Sclerotherapy

- Obliterates and produces permanent fibrotic obliteration of collapsed veins.
- With the patient recumbent and the vein collapsed, small amounts (**0.5 mL**) of sclerosing solution (**3% sodium tetradecyl sulfate**) are injected into each varix with a fine-gauge needle.
- Isolation of the injected segment is maintained by digital pressure; thereafter, continuous pressure on the veins is maintained for 1-2 weeks with elastic bandages. This prevents thrombosis and allows a fibrous union to form between the two walls of the collapsed vein.
- Extravasation necrosis of the skin is the most serious local complication
- Best reserved for small unsightly veins, dilated superficial veins, lower leg perforators, and recurrent or persistent veins after operation.
- With incompetence of the main long or short saphenous vein, the only effective treatment is surgery

#### 3.Surgery:

##### Indications

- 1) Severe symptoms
  - 2) Very large varices, even if asymptomatic
  - 3) Superficial phlebitis;
  - 4) Hemorrhage from a ruptured varix
  - 5) Ulceration from venous stasis (usually in conjunction with deep venous insufficiency);
  - (6) Cosmetic reasons.
- Surgical treatment entails removal of the varicose veins and ligation of incompetent perforating branches.

#### Venous stripping

- Incompetent superficial and perforating veins must all be identified and marked preoperatively.

- Introduce the stripper distally and drive it proximally.
- Proximal high tie(at the sphenofemoral junction)can be done.
- Once it is tied and the veins ligated at the end then the stripper is pulled stripping the veins.
- Postoperatively, the legs are supported with elastic bandages for approximately **6 weeks**.
- Elevation of the legs in bed minimizes postoperative swelling.
- Walking is encouraged, but sitting and standing are forbidden.

#### Stab avulsion

- Patient with less significant varicosity.
- Does not involve the great saphenous or small saphenous veins.
- Indicated for small isolated varicosities.

#### Modern management

- Endoluminal lazer
- Radiofrequency ablation

#### Complications of varicose veins

- 1.Ulcers
- 2.Dermatitis and eczema
- 3.Cellulitis
- 4.Venous thrombophlebitis
- 5.Haemorrhage

#### Results & Prognosis

- After surgical treatment, varicosities recur in about 10% of patients.
- The most common causes of recurrence are failure to ligate all the tributaries of the greater saphenous system at the saphenofemoral junction and failure to ligate the incompetent perforators

# WOUND HEALING

Forms of wound healing:

1. First intention
2. Second intention.

First intention (primary) healing occurs when tissue is cleanly incised and re approximated and repair occurs without complication.

Second intention (secondary) healing occurs in open wounds through formation of granulation tissue\* and eventual coverage of the defect by spontaneous migration of epithelial cells. Most infected wounds and burns heal in this manner

Granulation tissue is the red, granular, moist tissue that appears during healing of open wounds. Microscopically, it contains new collagen, new blood vessels, fibroblasts, and inflammatory cells, especially macrophages.

Primary healing is simpler and requires less time and material than secondary healing. It sometimes happens that primary healing is possible but there is insufficient reserve to support secondary healing.

Eg. Ischemic limb may heal primarily, but if the wound opens and becomes secondarily infected, it may not heal.

## Healing phases

Injury profoundly disrupts the chemical environment and architecture of tissues.

The postinjury environment, characterized by impaired perfusion coinciding with inflammation, invokes a number of fundamental biochemical, physiologic, and cellular coping mechanisms in process of healing.

Process includes

- Coagulation
- Inflammation
- Fibroplasias and matrix deposition
- Angiogenesis
- Epithelialization
- Contraction.

Cells involved are platelets, leukocytes (especially macrophages), fibroblasts, vascular endothelial cells, and epithelial cells.

Signals that direct them cytokines and growth factors as Insulin, insulin-like growth factors (IGFs), transforming growth factors (TGFs), fibroblast growth factors (FGFs), leukocyte-derived growth factors (LDGFs), platelet-derived growth factors (PDGFs), and EDGF.

These molecules may also behave as chemoattractants, inhibitors of differentiation, and stimulants of specific protein synthesis. In higher doses, they may be cytolytic. Cytokines include interleukins 1,2,6 and TNF-alpha

## 1.COAGULATION & INFLAMMATION

Clotting of blood contributes the first reparative signals.

Fibrinopeptides, fibrin, thrombin and platelets released PDGF, IGF-1, and TGF(beta) attract other inflammatory cells esp macrophages into injured tissue.

Inflammation begins as damaged endothelial cells release cytokines, which induce integrin and integrin receptor expression in passing leukocytes.

The leukocytes adhere to local endothelial cells and enter the injured extravascular space attracted by tissue complement factors, fibrinopeptides, growth factors, and cytokines. Initially, inflammatory components such as histamine, serotonin, and

kinins cause vessels to constrict as an aid to hemostasis and then to dilate a short time later

During inflammation, vessels become porous and release cells and blood plasma into the injured area.

The newly arrived inflammatory cells increase metabolic demand. Since the local microvasculature has been damaged, PO<sub>2</sub> falls while CO<sub>2</sub> and lactate accumulate. Lactate in produce more vasodilatation and attract more inflammatory cells. Vicious cycle is thus set with macrophages taking the role of releasing chemo attractants as coagulation derived factors decrease.

Macrophages release more lactate even in the presence of oxygen, thereby maintaining the environment of injury. The environment causes them to release growth promoters and more lactate, which in turn stimulates angiogenesis and collagen deposition.

By 2<sup>nd</sup> -3<sup>rd</sup> day Unless the wound becomes infected, its granulocyte population, which dominated on the first day, has diminished. Macrophages now cover the cut surface.

In 3<sup>rd</sup> -4<sup>th</sup> Immature fibroblasts, the product of growth signals, lie just beneath, mixed with bud of new vessels. More mature fibroblasts are scattered behind

## 2.FIBROPLASIA & MATRIX DEPOSITION

### Fibroplasia

Replication of fibroblasts is stimulated by PDGF, IGF-1, and TGF (beta) released by platelets and continuing with cytokine released by macrophages. Fibroblasts appear to release IGF-1. EGF and IGF-1 are also delivered by blood.

Fibroplasia is mainly near the wound edge, where they are exposed to the growth environment and to an higher oxygen tension.

Smooth muscle cells are likely progenitors of fibroblasts as they seem to stream from the adventitia and media of vessel.

### Matrix Deposition

Replicated fibroblasts secrete the collagen and proteoglycans of the connective tissue matrix that weld wound edges together.

Both assume high-molecular-weight polymeric forms and become the physical basis of wound strength.

Some growth factors (TGF(beta) and IGF-1) promote collagen gene transcription. Accumulation of lactate in the extra cellular environment directly stimulates transcription of collagen genes as well as synthesis and deposition of the protein itself.

## 3.ANGIOGENESIS

It becomes visible about 4 days after injury but begins 2 or 3 days earlier when new capillaries sprout out of preexisting venules and grow toward the injury in response to chemo attractants released by platelets and macrophages.

In primarily closed wounds sprouting vessels soon meet counterparts migrating from the other side of the wound, and blood flow across the wound is established. In unclosed wounds or those not well closed, the new capillaries fuse only with neighbors migrating in the same direction, and granulation tissue is formed instead.

Wound angiogenesis appears to be a response to local energy depletion, hypoxia and lactate accumulation.

## 4.EPITHELIALIZATION

Epithelial cells respond to many of the same stimuli as do fibroblasts and endothelial cells. A variety of growth factors

regulate replication. TGF(beta), for instance, tends to keep epithelial cells from differentiating and thus may potentiate and perpetuate mitogenesis, though it is not itself a mitogen for these cells. TGF(alpha) is an epithelial cell mitogen.

Mitoses appear in epithelium a few cells away from the **wound** edge. The new cells migrate over the cells at the edge and into the unhealed area, perhaps attracted by a growth factor or cytokine, and anchor on the first unepithelized place, forming a new wound edge.

The PO<sub>2</sub> on the underside of the cell at the anchor point is likely to be low. Low PO<sub>2</sub> stimulates squamous epithelial cells to produce TGF(beta), presumably hindering terminal differentiation and favoring mitosis. This process repeats itself until the wound is closed.

Squamous epithelialization and differentiation proceed maximally when the local PO<sub>2</sub> approaches about 700 mm Hg and when surface wounds are kept moist, even short periods of drying can impair the process. The exudate from acute, uninfected, superficial wounds also contains growth factors and lactate and therefore recapitulates the growth environment found internally.

### **5. COLLAGEN FIBER MATURATION, LYSIS, & CONTRACTION**

Replacement of an extracellular matrix is a complex process. First, fibroblasts replace the provisional fibrin then extracellular matrix with collagen monomers.

Extra cellular enzymes, some of which are PO<sub>2</sub>-dependent, quickly polymerize these monomers but in a pattern that is much more random than normal, thus leaving young wounds weak and brittle.

This brittleness is overcome when the hastily placed matrix is replaced with a more mature one consisting of larger, better organized, stronger, and more durable fibers.

Fibroblasts and leukocytes secrete collagenases that ensure the lytic component. Turnover occurs rapidly at first and then more slowly. Even in simple wounds, increased turnover can be detected chemically for as long as 18 months. Healing is successful when a net excess of matrix is deposited despite concomitant lysis.

During rapid turnover, wounds gain strength and durability but also are vulnerable to contraction and stretching. Fibroblasts provide the motive force for contraction. Receptors in fibroblast membranes attach to collagen molecules and pull them together when the cell membranes shorten as the fibroblasts migrate. The fibers are then fixed in the packed positions, probably by a variety of cross-linking mechanisms. Both open and closed wounds tend to contract if not subjected to a superior distorting force. The phenomenon is best seen in surface wounds, which in areas of loose skin may close 90% or more by contraction alone.

On the back, the buttock, or the neck, this is often a beneficial process, whereas in the face and about joints, the results may be disabling or disfiguring formation of contractures or strictures. Skin grafts, especially thick ones, impede but do not totally stop the process.

Dynamic splints, passive or active stretching, or insertion of flaps containing dermis and subdermis may be needed to counteract contraction. The force can be quite strong, though even severely contracted joints can usually be straightened with countertraction. Contraction occurs as long as collagen deposition is active, and

chronic, slowly healing wounds (eg, as in ischemic tissues) are particularly likely to contract. Prevention of a stricture in a ureteric repair, for example, depends on ensuring that the opposing tissue edges are well perfused so that healing can proceed quickly to completion.

Healing wounds may also stretch during active turnover when tension overcomes contraction. This may account for the laxity of scars in ligaments of injured but unsplinted joints and the tendency for hernia formation in abdominal wounds of obese patients

### **6. COMPLETION OF HEALING**

Normally, the final stimuli to release of growth factors and cytokines seem to be local hypoxia and lactic acidosis. When these stimuli disappear as the new microcirculation matures, healing should stop.

Keloids, local overgrowths of connective tissue, and hypertrophic scars, which occur particularly in pigmented skin, probably represent a loss of normal control over the healing process.

#### **Factors impairing healing**

1. Disorders of inflammation-steroids, immune suppression, cytotoxics
2. Impaired perfusion- Prevention or resolution of problems can be achieved by turning off sympathetic activity by correcting blood volume deficits, alleviating pain, and avoiding hypothermia. Wounds in highly vascularized tissues (eg, head, anus) heal fast and are quite resistant to infection.
3. Malnutrition
4. Endocrine disorders
5. Infestation.
6. Radiation
7. Foreign body

## ESSAYS

### End of term 2006

1. A 30yr old man falls astride onto the edge of a stone fence. Discuss the immediate and late urological complications in this man and their management.
2. Discuss the classification, management and complications of ankle fractures.
3. A 40 yr old lady presents with excessive itchiness and yellowness of her mucosa. What are the possible differential diagnoses?  
Discuss in detail the presentation and management of obstructive jaundice.
4. A 50 yr old man presents with progressive loss in weight and dysphagia. Discuss the management of such a patient.
5. Write short notes on
  - a) Chronic subdural haematoma
  - b) Extradural haematoma
  - c) Depressed skull fractures

### End of year 2005

1. Discuss the causes and management of a patient with high output enterocutaneous fistula.
2. Discuss the classification, management and complications of open tibial fractures.
3. Discuss the management of an adult patient with penetrating stab injury on the left anterior chest.
4. Write short notes on:-
  - a) Cleft lip and palate
  - b) Squamous cell carcinoma of the skin on burn scar.
  - c) Unilateral chronic lymphoedema of the lower limb.
5. Discuss the management of a 50yr old female with multinodular goitre.
6.
  - a) Discuss the indications for general anaesthesia.
  - b) Discuss the indications for tracheal intubation
  - c) Discuss the complications of cardiopulmonary resuscitation

### End term 2005

1.
  - a) Describe the possible fractures sustained in a nine year old boy falling on an outstretched upper limb.
  - b) Discuss the management of distal humerus fracture in this 9 yr old child.
2. Discuss the management of a 40 yr old lady presenting with a breast mass.
3.
  - a) Discuss the causes of dysphagia
  - b) Describe the treatment of a middle aged man with early carcinoma of the oesophagus.
4.
  - a) A one month baby presents with progressively enlarging head since birth. Discuss the evaluation and management.
  - b) What are the possible complications related to the treatment in (a) above.
5.
  - a) Describe the presentation of a patient with benign enlargement of the prostate.
  - b) Describe the treatment modalities for benign prostate enlargement and their outcomes

### End term 2005

1. Discuss the management of a 25 yr old University

- student admitted to hospital with haematuria and abdominal pains following a blow to his left loin.
2. Discuss the causes of severe post-operative bleeding.
3. Discuss the causes, prevention and management of stricture of the male urethra.
4. Discuss the factors that influence wound healing.
5. A 5 yr old boy has been admitted to the hospital after falling down from a desk in school on his right arm. Clinically there is an angulation and deformity of the humerus above the elbow and this area is swollen. Discuss his management.
6. A boxer is admitted to casualty with history of trauma to his head. He only responds to painful stimuli. Discuss his management with emphasis on the diagnosis, investigation and the care of the patient in the ward.

### End term 2005

1.
  - a) What is head injury?
  - b) Describe the possible types of head injury.
  - c) Describe the evaluation of the head injured patient.
  - d) Discuss the pathophysiology of chronic subdural haematoma.
2.
  - a) Describe the types of congenital anomalies of the oesophagus.
  - b) Discuss the presentation of neonate with tracheo-oesophageal fistula.
  - c) Outline the treatment of congenital tracheo-oesophageal fistula
3.
  - a) Describe briefly causes of dysphagia.
  - b) Describe the treatment of an elderly man with locally metastatic carcinoma of the oesophagus.
4. A 25 yr old male construction worker presents with history of a fall from height. X-rays show bilateral ischial pubic ramus fracture. While in the ward he develops retention of urine.
  - a) Describe the immediate intervention
  - b) Discuss the evaluation of such a patient
  - c) Discuss the treatment of the possible urethral stricture
5. Discuss the management of a 40 yr old man presenting with sigmoid volvulus.

### End of year 2004

1. Discuss the differential diagnosis of pain in the right iliac fossa. Outline the management of an appendicular mass.
2. A child falls from a height. Discuss briefly the likely fractures and their management.
3. Write an essay on the presentation, diagnosis and principles of treatment of Wilm's tumour.
4. Describe the indications and post operative management of any one of the following operations:
  - a) Transvesical prostatectomy
  - b) Kuntscher nailing
  - c) Splenectomy
5. Write an essay on the pathology, presentation, diagnosis and treatment of cancer of the oesophagus as seen in Kenya.
6. Discuss the pathology and management of a patient with deep fungal infection involving one foot.



**End term 2004**

- What is the definition of empyema thoracis and what are the various types.
    - Describe the investigations for empyema thoracis
    - What are the treatments and sequelae of the treatment of empyema thoracis.
  - Describe the various types of anorectal malformations.
    - How is the diagnosis of anorectal malformation made?
    - What are the treatment for anorectal malformations
  - What are the types and presentations of spinal dysraphism.
    - What are the investigations, treatment and followup for spina bifida?
- How would you manage a 20 yr old man presenting with retention of urine after a fall causing a fracture pelvis.
- Discuss the diagnosis, treatment and followup of late breast cancer.

**End term 2004**

- What are the causes of urethral stricture?
  - How do you investigate a patient with urethral stricture?
  - Describe the treatment of a 25 yr old man with perineal trauma and inability to pass urine.
- What are the possible presentations of a patient with trauma to the chest?
  - How do you investigate such a patient?
  - What are the available treatments of such a patient and what are the sequelae?
- Describe the treatment of one year old 6 kg baby girl with cleft lip and palate
  - Write short notes on skin grafting.
- Describe the various forms of spinal dysraphism and their treatments.
- Discuss the management of a 2 yr old presenting with abdominal distension, pain, vomiting and a sausage shaped abdominal mass after a bout of diarrhoea.

**End term 2004**

- What is the presentation of locally advanced prostate cancer?
  - How do you investigate such a patient?
  - How do you treat such a patient?
- Write short notes on:-
  - Sigmoid volvulus
  - Colorectal cancer
  - Inguinal hernia
- What are the causes and types of empyema thoracis
  - What are the investigations in empyema thoracis?
  - What is the treatment of various types of empyema thoracis
- Discuss the management of a 5yr old with 15% scald burns involving the face and neck.
- Discuss the management of 2 month old child with projectile vomiting and a mobile epigastric mass.

**End of year 2003(6<sup>th</sup> year)**

- Describe the pathology, clinical presentation and management of carcinoma of the oesophagus.

- Describe the clinical presentation and management of patient presenting with tuberculosis of the thoracolumbar spine.
- Describe the aetiology, pathology and management of madura foot.
- Describe the pathology and management of urethral stricture.
- Discuss the differential diagnosis of pain in the right iliac fossa.  
Outline the management of patient with an appendicular mass.
- What is spina bifida cystica?  
Discuss the aetiology and management of spina bifida cystica.

**End of year 2003(5<sup>th</sup> year)**

- Discuss postoperative wound sepsis with special reference to origin, control and prevention.
- Describe the clinical presentation and management of patient presenting with tuberculosis of the thoracolumbar spine.
- What are causes of haematemesis. Describe how you will manage a patient who presents with a severe haematemesis.
- Enumerate parasites of major surgical importance in Kenya. Outline the pathology, diagnosis and treatment of surgical lesion(s) due to any one of these parasites.
- Describe the indications and postoperative management and complications of any one of the following operations:-
  - Transvesical prostatectomy
  - Kuntscher nailing
  - Splenectomy
- Describe how you would manage a 10 yr old patient who presents with pain in the right hip joint. What would be your differential diagnosis?

**End of year 2003**

- Describe the presentation, pathology, investigations and management of a 25 yr old with pyloric stenosis.
- Describe how you would manage a 35 yr old male who presents with compound fracture of bones of the right forearm or fracture of radius and ulna.
- Write short notes on the following:
  - Indications for tracheostomy
  - Congenital infantile hypertrophic pyloric stenosis
  - Acute subdural haematoma
  - Renal calculus
- What are the causes of empyema thoracis? Describe the presentation, investigation and management of a 25 yr old male with empyema thoracis of the left chest.
- What are the causes of an enlarged thyroid?
- Describe the aetiology, pathology and management of acute osteomyelitis presenting in a 6 yr old child.

**End term 2003 (6<sup>th</sup> yr)**

- Discuss the management of a 9 yr old boy with 31% burns involving head, neck and trunk.
- Discuss the management of a 60 yr old man presenting with acute urinary retention.
- Describe the management of a 25 yr old male found unconscious after a road traffic accident.

4. Discuss the presentation, treatment and follow-up of a 3 yr old child with intussusception.
5.
  - a) What is intestinal obstruction?
  - b) What are its clinical features?
  - c) What are the principles of its treatment?

#### End term 2003

1. Give a detailed account of the management of chronic osteomyelitis of the femur in a 40 yr man. What are the complications of chronic osteomyelitis?
2. What is intussusception? What are the clinical features, investigations and management of a 2 yr old child who presents with intussusception?
3. Write an essay on the diagnosis, investigations and total management of a patient who is brought to casualty unconscious after a car accident having sustained head injury.
4. Discuss in detail the management of 30 yr old lady has 60% burns.
5. Discuss the management of a lump in the breast.

#### End term 2003

1. Discuss the management of a male aged 60 yrs with a left loin mass, abdominal pain and haematuria.
2. Discuss the presentation, investigations and treatment of a patient with mechanical intestinal obstruction,
  - a) What is the presentation of facial burns.
  - b) What is the treatment of a patient with facial burns
  - c) What are the sequelae of facial burns
4.
  - a) Write short notes on spinal dysraphism
  - b) Discuss briefly the evaluation of the head injured patient.
  - c) Briefly discuss the outcome of head injury.
5. Discuss the presentation, investigation and treatment of cancer of the oesophagus.
6. Discuss the presentation and treatment of tracheoesophageal fistula.

#### End term

1.
  - a) Write short notes on classification of burns according to the depth of injured tissues.
  - b) Describe the immediate evaluation of the burn injured patient.
  - c) Describe the dermal care and fluid management of the burn injured patient.
2.
  - a) Write short notes on the epidemiology of cancer of the stomach.
  - b) Describe the presentation of cancer of the stomach.
  - c) Describe the treatment options for a patient with lesser curve fungating tumour of the stomach.
  - d) What are the possible outcomes for the patient in (c)
3.
  - a) Describe the various types of spinal dysraphism
  - b) Describe the clinical presentation of the types in (a) and other congenital malformations associated with them.
  - c) Discuss the evaluation of the patients in (a).
  - d) Briefly describe the treatments currently available for the patients described above.
4.
  - a) Describe the presentation of the patient with benign prostate enlargement.
  - b) Describe the treatment modalities for benign prostate enlargement and their outcomes.

5. A 1½ yr child presents with sudden onset abdominal pain and vomiting. The mother describes a sausage shaped mass palpable. Discuss the further history, physical examination and possible treatments and outcomes for this baby.

#### End of year 2002

1.
  - a) Define the term goitre.
  - b) Classify the causes of goitre.
  - c) Describe the pathogenesis, history, clinical presentation and investigations of goitre.
2. A 70 yr old falls in the house and fails to stand up due to pain in the left hip. Discuss the management including complications.
3. Describe the aetiology, pathology, clinical presentation and pre-operative management of a right sided colonic carcinoma.
4. A male infant has been born with an imperforate anus. Describe the condition and its classification. Discuss the aetiology, clinical presentation, investigations and treatment.
5. Describe the causes and management of a patient with spinal cord compression.
6. Discuss the causes, clinical presentation and management of empyema thoracis.

#### End of year 2001

1. What is surgical jaundice? Discuss the investigations you would undertake on a patient with such a condition. What pre-operative preparations are necessary?
2. A burn patient aged 4 yrs is admitted with 65% burns. Discuss the management in the first 24 hrs.
3. Discuss the causes, prevention and management of stricture of the male urethra.
4. Discuss the management and complications of supracondylar fractures of the humerus in children.
5. Discuss the various causes of haematemesis and treatment of any one of the causes.
6. What is spina bifida cystica? Discuss the aetiology and management of spina bifida cystica.

#### 7<sup>th</sup> August 2000

1. Discuss the differential diagnosis of pain in the right iliac fossa. Outline the management of an appendicular mass.
2. Discuss the management and complications of supracondylar fractures of the humerus in children.
3. Describe the different IV anaesthetic drugs that you would use currently. Outline the steps in successful oral intubation.
4. A 40 yr old man presents with a history of assault on the head. On arrival in the casualty he starts to vomit and quickly lapses into a state of unconsciousness. Discuss the management.
5. A 70 yr old female falls in the house and fails to stand up due to pain in the left hip. How would you manage her and what complications would you expect and how can they be prevented?
6. Mention malignant tumours of children. Discuss the diagnosis and management of Wilm's tumour.

**23<sup>rd</sup> August 1999**

1. Discuss the management of a 30 yr old engineer involved in a high speed car accident. In casualty he presented fully awake but subsequently lapsed into a state of unconsciousness.
2. Discuss the pathology, clinical presentation, diagnosis and management of acute testicular torsion.
3. Classify bone tumours. Discuss the management of osteogenic sarcoma.
4. Discuss the principles of management of a woman aged 65 years with advanced cancer of the breast
5. Write short notes on:
  - a) Cleft lip
  - b) Parophthalmitis
  - c) Hirschsprung disease
  - d) Congenital hypertrophic pyloric stenosis
6. List the differential diagnosis of a painful swollen knee in a 12 yr old boy. Discuss in detail the management of one cause.
7. Discuss the pathology, clinical presentation and management of cancer of the oesophagus.

**End of term 1999**

1. Discuss briefly the management of acute cholecystitis in a 30 yr old female.
2. Discuss presentation and management of rectal sigmoid carcinoma
3. What are the various causes of upper GIT bleeding? Outline the management of a patient with upper GIT bleeding.
4. Write short notes on:
  - a) Malignant melanoma
  - b) Kaposi sarcoma
5. Describe briefly the symptoms and signs of small intestinal obstruction.

**Supplementary 1998**

1. Discuss the pathology, pathogenesis and clinical features of acute intestinal obstruction in adults. Discuss the treatment.
2. Discuss the management of compound tibial fractures
3. Define shock. Discuss briefly the management of a 30 yr old patient who comes with 30% surface burns during the first hour.
4. Discuss the management of an adult presenting with an anterior neck mass.
5. Write short notes on
  - a) Epistaxis
  - b) Tinnitus
  - c) Tracheostomy indications
  - d) Acute otitis media
6. Discuss the management of a patient presenting in coma following a road traffic accident.
7. Discuss the management of a patient with chronic osteomyelitis of the humerus.

**End of year 1998**

1. Discuss the management of a 60yr old gentleman who presents with haematuria following a road traffic accident.
2. Enumerate injuries sustained following a fall on

outstretched hand. Briefly describe the management of each of these injuries.

3. What is meant by the term paralytic ileus? Discuss the aetiology and management.
4. Discuss methods used in investigation and treatment of obstructive jaundice.
5. Discuss the management of a 4yr old child who sustains 40% burns involving neck, upper limbs and chest.
6. Discuss causes and management of 30yr old male with epistaxis.
7. Discuss management of 70 yr old man with penetrating right sided chest injury.

**End term 1998**

1. List causes of dysphagia. Discuss management of a 50 yr old lady whose main complaint is difficulty swallowing.
2. What is a hernia? Discuss how you could manage a 25 yr old man with obstructed right inguinal hernia.
3. Discuss briefly intussusception in a 2yr old child.
4. Enumerate indications for a tracheostomy.
5. List causes of urethral strictures. Discuss briefly how you would manage a 30 yr old with fracture pelvis complicating posterior urethra.

**End term 1998**

1. Discuss the diagnosis and management of a 70 yr old male with haematuria.
2. Discuss the diagnosis and management of acute appendicitis.
3. Discuss the diagnosis and treatment of goitre. How would you manage a patient with Grave's disease?
4. Write short notes on
  - a) Squamous cell carcinoma of the skin
  - b) Kaposi's sarcoma
5. Write short notes on presentation and diagnosis of sigmoid volvulus. How would you manage a patient with sigmoid volvulus?

**End of year 1997**

1. Discuss the total management of post operative oliguria following major abdominal surgery.
2. Discuss the management of a 6 yr old standard one pupil with a supracondylar fracture of the right humerus.
3. Write short notes on :
  - a) Hazards of massive blood transfusion
  - b) Congenital hypertrophic pyloric stenosis.
  - c) Surgical aspects of sickle cell disease
4. List the causes of dysphagia
5. Outline the principles of management of a 21 yr old medical student with closed head injury.
6. Discuss the pathology, investigations and management of early breast cancer.

**End term 1997**

1. Discuss blunt and perforating wounds of the abdomen.
2. What is the cause of acute appendicitis? Give the symptoms and signs in order of their usual appearance. Give the differential diagnosis of this

condition.

3. Write short notes on management of burns.
4. Enumerate indications for tracheostomy.
5. Summarise the principles of management of closed head injuries.

#### End term 1997

1. Write short notes on
  - a) Upper airway obstruction
  - b) Chronic suppurative otitis media
  - c) Ca postnasal space
  - d) Vertigo
2. Discuss how you would manage a 25 yr old man with acute appendicitis.
  - a) What are differential diagnoses of above?
3. Write short notes on how you would manage a 70 yr old patient with acute retention of urine.
4. Define shock. How would you manage a 30 yr old man with 25% surface area burn within the first 48 hours?
5. Give an account of the
  - a) clinical features
  - b) diagnosis
  - c) treatment of stage II carcinoma of the breast

#### End term 1997

1.
  - a) Write short notes on sigmoid volvulus.
  - b) How would you carry out the definitive treatment of sigmoid volvulus?
2.
  - a) What are the signs/symptoms of acute traumatic haemothorax
  - b) Outline your management of such a patient.
3.
  - a) Describe the different types of anorectal malformation
  - b) Outline the treatment of one of them.
4.
  - a) What are the various causes of upper GIT bleeding?
  - b) Outline how you would manage such a patient.
5.
  - a) Outline the management of a patient with acute retention of urine.
  - b) List the causes of haematuria.

#### End of year 1996

1. Discuss the possible causes of urinary retention in a 50 yr old male. How could you investigate this patient?
2. Outline the causes of upper tibial pain in a 12 yr old child. Describe the diagnosis and the treatment of upper tibial osteomyelitis.
3. Discuss how ultrasound can help in the abdomen surgical diagnosis.
4. Discuss the fluid and electrolyte management of a patient who has had vagotomy and drainage until he starts feeding.
5. What are the common causes of the infections of the eye? Discuss the total management of neonatal conjunctivitis?
6. Discuss the common causes of post-operative chest complications. How can these be prevented?
7. Outline the causes of sore throat. Discuss the management of tonsillitis.
8. Discuss the anaesthetic pre-operative intra- and post-operative management of a patient who is about to undergo a major operation.

#### End term 1996

1. Write short notes on
  - a) Epistaxis
  - b) Chronic suppurative otitis media
  - c) Vertigo
  - d) Upper airway obstruction
2.
  - a) Discuss briefly extradural haematoma
  - b) Write short notes on depressed skull fractures
3. Discuss the underwater seal drainage of the chest
4. What is a hernia?  
Discuss how you would manage a 25 yr old man with obstructed right inguinal hernia.
5.
  - a) Discuss the pathology and pathophysiology of obstructive uropathy.
  - b) Outline the indications of prostatectomy and various approaches to the prostate.

#### End of year 1995

1. Discuss the incidence, pathology, treatment and prognosis of epidemic Kaposi sarcoma.
2. A child falls from a height. Discuss briefly the likely fractures and their management.
3. Enumerate the conditions that are meant by hamatomatosis. Discuss and manage vonRecklinghausen disease
4. Discuss the indications for tracheostomy. How do you manage a tracheostomy tube?
5. Mention malignant tumours of children. Discuss the diagnosis and management of Wilm's tumour.
6. Discuss the differential diagnosis of pain in the right iliac fossa. What investigations can you do to assist you?

#### End term 1995

1. Discuss briefly the intussusception in a 2 yr old child.
2. Write short notes on
  - a) Sigmoid volvulus
  - b) Malignant melanoma
  - c) Peptic ulcers
  - d) Kaposi sarcoma
3. Discuss the pathology, diagnosis and management of
  - a) Acute subdural haematoma
  - b) Chronic subdural haematoma
4. Discuss how you would manage a 25 yr old lady with suspected acute appendicitis
5. Write short notes on
  - a) Chronic suppurative otitis media
  - b) Management of a 25 yr old man with 25% surface area burn within the first 48 hours?

#### End term 1995

1. List the causes of urethral stricture.  
Discuss briefly how you would manage a 30 yr old man with fracture pelvis complicating the posterior urethra.
2. Discuss the pathology, diagnosis and management of
  - a) Acute subdural haematoma
  - b) Chronic subdural haematoma
3. Describe the presentation, pathology and management of a 2 yr old child with pyloric stenosis.
4. Write short notes on
  - a) Ca PNS
  - b) Epistaxis

- c) Chronic suppurative otitis media
  - d) Swallowed foreign bodies
5. Discuss osteoarthritis and management of a 60 yr old male with osteoarthritis of the right hip.

#### End of year 1993

1. Describe the presentation, pathology, investigations and management of a 25 yr old female with pyloric stenosis.
2. Describe how you would manage a 35 yr old male who presents with compound fracture of the bones of the right forearm (or fracture of radius and ulna)
3. Write short notes on the following:-
  - a) Indications for tracheostomy
  - b) Congenital infantile hypertrophic pyloric stenosis
  - c) Acute subdural haematoma
  - d) Renal calculus
4. What are the causes of empyema thoracis? Describe the presentation, investigations and management of a 25 yr old male with empyema thoracis of the left chest.
5. What are the causes of an enlarged thyroid? Describe the management of a 35 yr old female with a solitary thyroid nodule of the right lobe.
6. Describe the aetiology, pathology and management of acute osteomyelitis presenting in a 6 yr old child.

#### End term 1993

1.
  - a) List the indications for admitting a patient who has sustained burns.
  - b) Outline the management of a patient with burns in the first 48 hrs of admission into the hospital.
2.
  - a) What are the criteria for admitting the patients with head injury?
  - b) What signs would make you recommend craniotomy?
3.
  - a) What are indications for prostatectomy?
  - b) What pre-operative management and preparation are necessary to make the patient fit for prostatectomy?
4.
  - a) What are may cause gastric outlet obstruction?
  - b) What metabolic derangement is associated with this syndrome?
5.
  - a) What are the signs of an acute traumatic right sided haemopneumothorax?
  - b) Outline your management of such a patient.
6.
  - a) Why is it necessary to stage breast carcinoma?
  - b) Outline the principles of management of patient with stage IV carcinoma of the breast.
7. What forms of skin graft are used? Outline the indications for the use of any one form of skin graft.
8. Write short notes on the pathology, clinical features, diagnosis and management of:-
  - a) Acute anterior dislocation of the shoulder joint.
  - b) Carpal tunnel syndrome
  - c) Volkman's contractures
  - d) Pyogenic arthritis of the knee
9.
  - a) Enumerate the indications for internal fixation of fractures
  - b) What are the mechanisms of an injury to the cervical spine?

- c) What are the signs and symptoms and the management of a herniated lumbar 4- 5 nucleus pulposus
- d) Give a classification of fracture of femur.

#### End of year 1992

1. Discuss the management of a 7 yr old boy who presents with supracondylar fracture of the left humerus.
2. List the causes of urethral stricture. Discuss the management of a 25 yr old man with acute retention of urine
3. Write short notes on
  - a) Obstructive jaundice
  - b) Intussusception
  - c) Madura foot
4. Discuss the pathology, diagnosis and management of
  - a) Acute subdural haematoma
  - b) Chronic subdural haematoma
5. What are the causes of dysphagia? Discuss the management of a 35 yr old man whose main complaint is difficulty in swallowing
6. Discuss the pathology, investigations and management of carcinoma of the breast

#### End term 1992

1. Write short notes on
  - a) Epistaxis
  - b) Foreign bodies in the ear
  - c) Chronic suppurative otitis media
  - d) Upper airway obstruction
2. Write short notes on
  - a) Extradural haematoma
  - b) Traumatic paraplegia
3. What is a hernia? Discuss how you would manage a 25 yr old man with an obstructed right inguinal hernia
4. Define acute abdomen. How would you manage a 40 yr old female with history of intermittent jaundice and right upper quadrant abdominal pain?
5. Describe the different types of anorectal malformations. Outline the treatment of one of them
6. Define shock. Discuss the acute management of an adult with 20% burns.
7. Outline the management of a patient with acute retention of urine.
8. Discuss briefly the management of patient presenting with a thyroid nodule.
9. What are the clinical features of pneumothorax? Outline the management of spontaneous pneumothorax?
10. What are the various causes of upper GIT bleeding? Outline how you would manage such a patient with upper GIT bleeding.

#### End term

1. Write short notes on
  - a) Swallowed foreign bodies
  - b) Indications for appendicectomy
  - c) Post operative management in abdominal surgery

2. Write short notes on
  - a) Extradural haematoma
  - b) What are the criteria for admitting patients with head injuries
3. Discuss the investigation of a patient suffering from jaundice
4. Describe the different types of anorectal malformations. Outline the treatment of one of them.
5. Write short notes on:
  - a) Carpal tunnel syndrome
  - b) Pyogenic arthritis of the knee
6. Classify fractures of long bones. Discuss the principles of their management
7. Discuss the management of a patient presenting with a solitary thyroid nodule.
8.
  - a) What are the signs of an acute traumatic right sided haemothorax
  - b) Outline your management of such a patient
9. Discuss the acute management of an adult with 20% burns
10. Write short notes on
  - a) Otitis media
  - b) Allergic rhinitis
  - c) Indications for tracheostomy
  - d) Epistaxis

#### End term

1. Discuss blunt and perforating wounds of the abdomen.
2. Give the indications for amputation of an extremity. What are the areas of election for amputation of the forearm, leg and thigh?
3. Discuss delayed union and non-union of fractures. What are the frequent sites of non-union?
4. Describe the preparation for surgery for a patient with thyrotoxic goitre.
5. What are the physical signs of breast cancer? Describe the palliative measures available in advanced mammary carcinoma.
6. Describe the management of acute cardiac arrest?
7. What is the cause of acute appendicitis? Give the symptoms and signs in order of their usual appearance. Give the differential diagnosis of this condition.
8. Differentiate indirect inguinal hernia and describe its anatomical features from direct inguinal hernia, femoral hernia.
9. What are the common causes of intestinal obstruction in the newborn?
10. Write short notes on the management of burns.

#### End of year 1991

1. Write short notes on:-
  - a) Cancer of the oesophagus
  - b) Empyema
2. Write short notes on:-
  - a) Management of a 60 yr old with haematochezia.
  - b) Causes of breast lump and management of early breast cancer.
3. What is cellulitis? Discuss the presentation, diagnosis and treatment of a 45 yr old male with cellulitis of the left leg.
4. Discuss the causes of haematuria

5. Discuss the treatment of superficial cancer of the bladder.

#### End of year 1990

1. What is sickle cell disease? Discuss the problem that face a person having this condition as well as the problem of surgical management.
2. What are the fractures of the proximal third of the femur? Discuss their complications and outline their management.
3. Discuss late burn complications.
4. Give the causes, diagnosis and treatment of empyema thoracis.
5. A 50 yr old unconscious male is brought to your casualty by a Good Samaritan who has no details about the history. Describe your approach to the diagnosis of this patient.
6. Give the signs and symptoms of patient with acute abdomen. Discuss how you would manage a ruptured spleen?

#### End term 1990

1. Discuss management of a patient presenting with a mass in the right iliac fossa.
2. Write short notes on
  - a) Haemorrhoids
  - b) Fibroadenoma of the breast
  - c) Inguinal hernia
3. Discuss the management of a 60 yr old male presenting with retention of urine.
4. Write short notes on
  - a) Haemothorax
  - b) Bronchogenic carcinoma
5. Discuss the different types of skin grafts. Outline the various causes of burns.
6. Discuss the differential diagnosis of a neonate presenting with vomiting.
7. Describe how you would manage a 55 yr old man with progressive dysphagia.
8. Write short notes on
  - a) Postnasal space neoplasms
  - b) Inhaled foreign body
9. Discuss management of a patient with paraplegia.
10. Discuss indications for use of drains in surgery. Outline the various types of drains you know.

#### End of year 1989

1. What do you understand by 'Acquired Immune Deficiency Syndrome' (AIDS)? Outline the known methods of spread for this disease and explain how they would affect the practice of surgery in Kenya. Design a community based program to prevent the spread of AIDS in Kenya.
2. Write an essay on the differential diagnosis of haemarthrosis of the knee joint in a 20 yr old male.
3. Write short notes on:
  - a) Partial thickness skin grafts
  - b) Cancrum oris
  - c) Cleft lip and palate
  - d) Lymphoedema

4. Discuss the possible causes of increasing constipation in a 1 yr old child and 50 yr old male. How would you investigate the problem?
5. Discuss the management of a 35 yr old male who presents with epistaxis.
6. Discuss the aetiology, investigations and treatment of haematuria.

#### End of year 1988

1. Write a detailed account on the management of an unconscious patient after a road traffic accident.
2. Discuss the pathology, presentation, treatment and complication of supracondylar fracture of the humerus.
3. What are the signs of increased intracranial pressure?
4. List the investigations you would do for a 10 yr old male suspected of suffering from a right cerebellar tumour. Indicate the value for every investigation you site.  
Give an account of the parasite infections of surgical importance and indicate their management.
5. Discuss the diagnosis and management of a 40 yr old woman with an enlarged swelling in the posterior triangle of the neck.
6. Discuss the principles involved in the treatment of TB of the spine.

#### End term 1988

1. Briefly discuss your management of:-
  - a) A patient with a stab wound of the abdomen
  - b) A patient with a stab wound of the chest
2. Discuss the presentation, investigation and management of a man aged 40 yr with tuberculosis of the skin
3. Give an account of the differential diagnosis and investigations of dysphagia in a male patient aged 50 yrs.
4. Classify the fractures of forearm in adults. Discuss their clinical features and the principles of management.  
List the complications that may arise.
5. Write briefly on:
  - a) Indications for surgery on thyroid gland.
  - b) Causes and the initial management of acute urinary retention

#### End of year 1986

1. Discuss how you would manage a patient with compound fracture of the tibia. What complications can follow this injury?
2. How would you manage a 15 yr old boy with 20% deep burns?
3. What are the causes of post-operative pyrexia? How would you investigate and manage a patient with post-operative pyrexia occurring 2 days after operation?

#### End of year 1981

1. Discuss the aetiology, pathology and complications of chronic osteomyelitis of a long bone.
2. Discuss the management of a case of severe upper GIT bleeding.
3. Define paraplegia and list 6 causes excluding trauma. Discuss how you would look after a patient with

established paraplegia.

4. A 40 yr old male presents with multiple skin nodules on his lower limb. Give the differential diagnosis and discuss the treatment of the most likely causes.
5. Describe the diagnostic processes involved in a case of prolonged jaundice. Outline the causes of extrahepatic obstructive jaundice.
6. A 16 yr old girl presents with right lower abdominal pain. Give differential diagnosis and describe how you would manage her.

#### End term 1981

1. Discuss the differential diagnosis and investigations of acute abdomen
2. Describe the diagnostic features and treatment of anorectal malformations.
3. Discuss the cause, investigations and treatment of chronic ulceration in the lower extremities.
4. A young adult male presents with a 2 wk history of painless haematuria. Discuss the management.

#### End term

1.
  - a) What is the presentation of adenocarcinoma of the rectum?
  - b) What are the investigations of cancer of the rectum?
  - c) What are the curative and palliative options in the treatment of cancer of the rectum and what are the outcomes?
2. Discuss the presentation and management of a 70 yr old man presenting with acute retention of urine.
3. Discuss presentation and treatment of tracheo-oesophageal fistula.
4.
  - a) What is the presentation of penetrating chest injury and how is it investigated?
  - b) Describe the treatment option in penetrating chest injury.
  - c) What are the immediate and long term complications of penetrating chest injury and how are they treated
5. How do you manage the patient with a head injury from the scene of the trauma throughout hospital stay and follow-up

#### End of term

1. List the common causes of acute retention of urine in this locality. Describe in detail principles of management of one of them.
2. Write short notes on the management and complications of burns.
3. What is the cause of chronic osteomyelitis in this locality? Outline the principles of management of this condition.
4. What are the common causes of intestinal obstruction in the new born? Outline the principles of management.
5. Outline the principles of management of early breast cancer.
6. How would you manage a patient with septic shock?
7. What is the cause of acute appendicitis?
8. Give the symptoms and signs in order of their usual appearance. Give the differential diagnosis of this condition.
9. Describe the preparation of surgery for a patient with

thyrotoxic goitre.

10. Give the indications for amputation of an extremity. What are the areas of election for amputation of the forearm, legs and the thigh?

**End term**

1. Describe the assessment and the initial management of a patient with multiple injuries following a road traffic accident during the first 2 hrs after admission. Explain the priority of each procedure.
2. Discuss the aetiology, diagnosis and treatment of acute osteomyelitis. Indicate the complications which can arise from this lesion.
3. Discuss the important differential diagnosis of the acute abdomen in Kenya. Indicate the clinical features of each and the investigations which may assist you to make a diagnosis.
4. A man 40 yrs presents with an ulcer of the sole of the foot which he has had for 10 months. Describe the diagnostic steps you would take and the appropriate investigations.
5. Write short notes on
  - a) Management of a patient with depressed skull fracture with no neurological signs.
  - b) Common causes and clinical features of optic atrophy.
  - c) Aetiology and management of otitis media
  - d) Management and complications of acute empyema

**End term**

1. Write short notes on pre-operative preparation of patient scheduled for major GIT surgery.
2. List the complications arising from blood transfusion and how to manage such.
3. List the indications for tracheostomy and discuss the management of complications following the procedure.
4. Write short notes on management of a patient who presents with an ulcer in the right leg.
5. Discuss the total management of a patient who presents with head injury.
6. List the indications, complications and care of colostomies.
7. List the pre-operative complications following abdominal surgery.
8. List the causes of obstructive uropathy in surgical patients
9. A young adult male presents with a right scrotal swelling. List your differential diagnosis and how you will investigate and manage this patient.
10. Give a broad outline of the management of patient who presents with 15% burns of the left upper thigh.

**End term**

1. A watchman has sustained a deep laceration on the anterior aspect of his wrist. Discuss the management of the patient in the first 3 hours after the injury.
2. Describe your physical examination of a newborn baby who has no oral orifice. What would be appropriate?
3. What injuries may occur as a result of a fall on the outstretched hand? What would be appropriate?
4. Write short notes on:-

- a) Tracheostomy and complications
- b) Premedication
- c) Management of penetrating ocular injuries

5. Write an essay on skin grafts

**End term**

1. What type of endoscopies do you know? Describe the indications and for the procedure of oesophagoscopy.
2. Discuss the differential diagnosis of a painful swollen knee in a 20 yr old male. What investigations would you carry out to arrive at a diagnosis?
3. A child aged 6 yrs is admitted with 6% burns. Describe in detail how you would manage him if he weighed 20kg.
4. Give detailed basis of chronic leg ulcers. How would you investigate and manage him.
5. Discuss the management of a 65 yr old man with acute retention of urine.
6. Give a classification of head injuries. How would you manage a 20 yr old female with closed head injury.