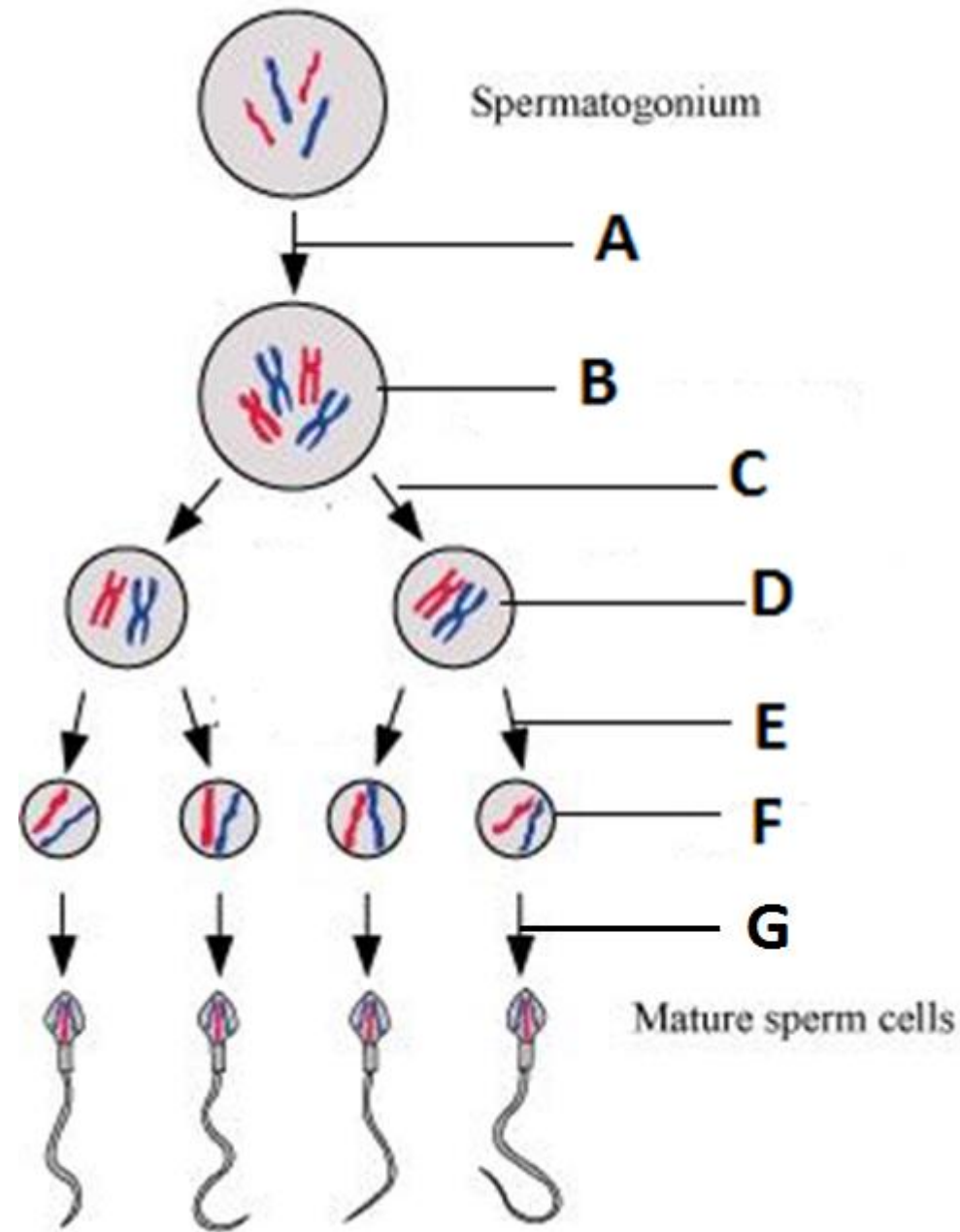
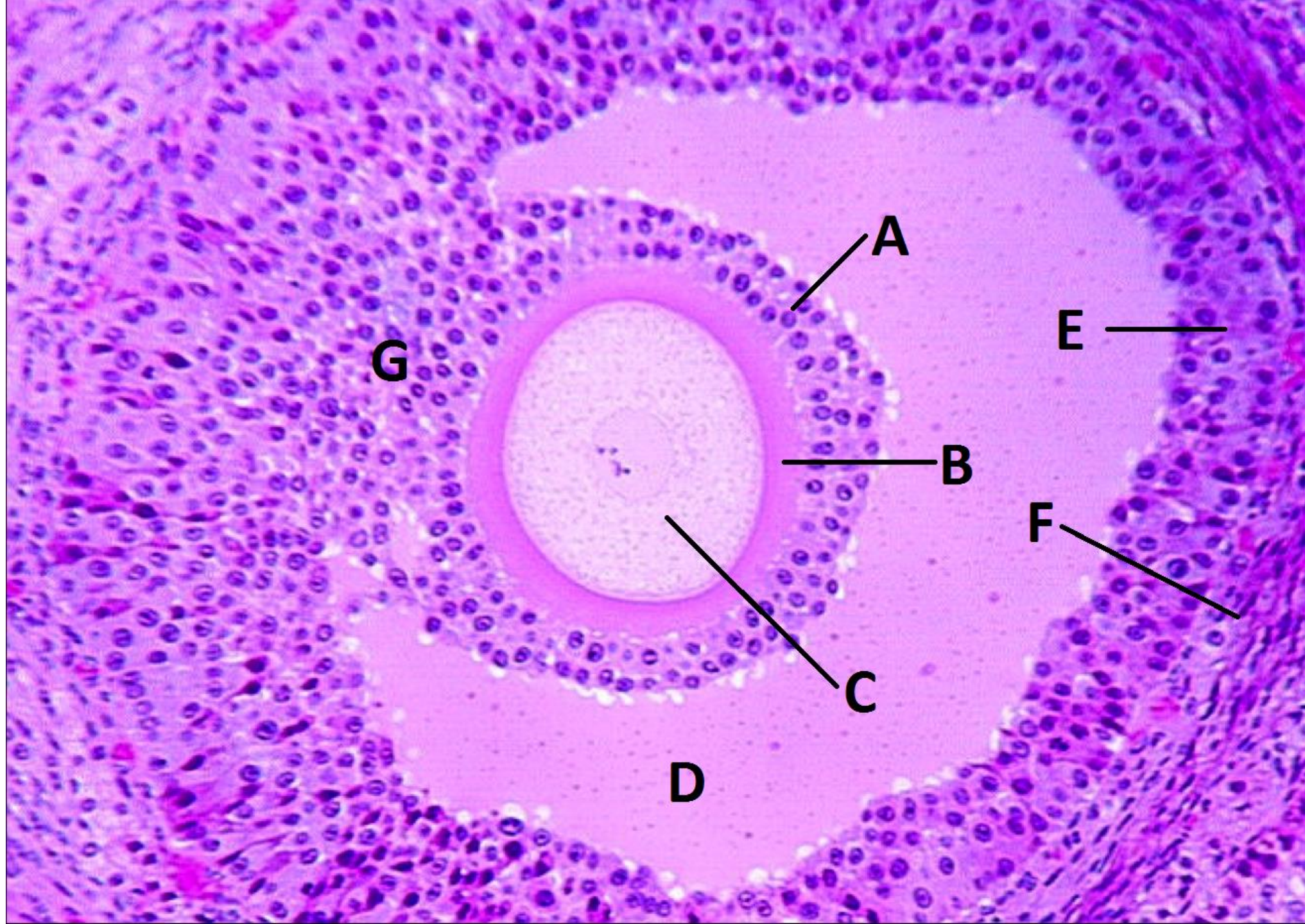


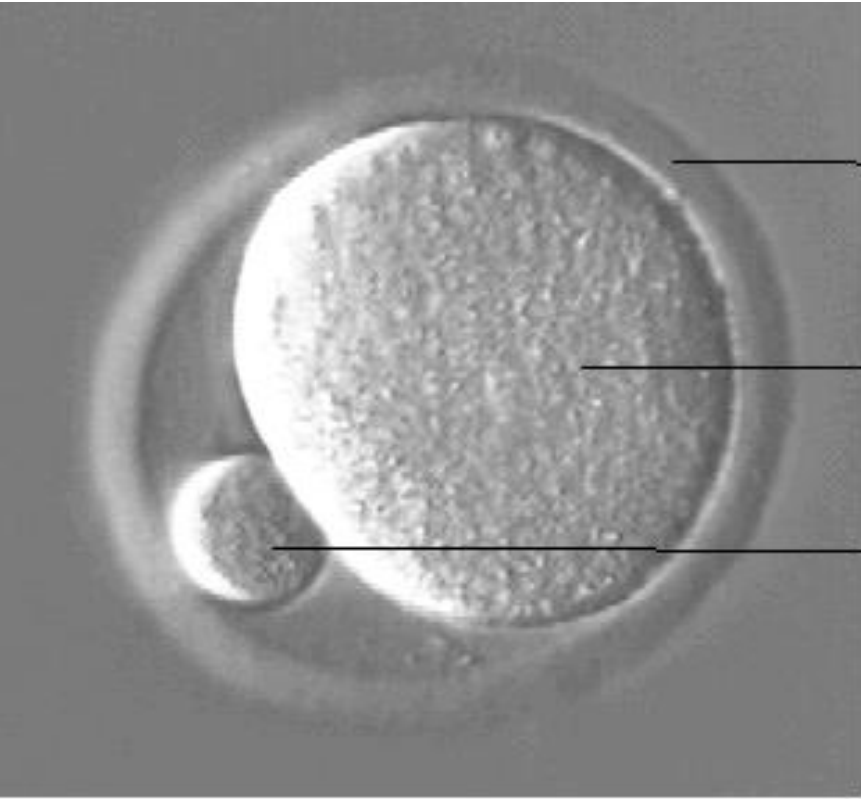
EMBRYOLOGY SLIDE
REVIEW

Spermatogenesis



Process of spermatogenesis

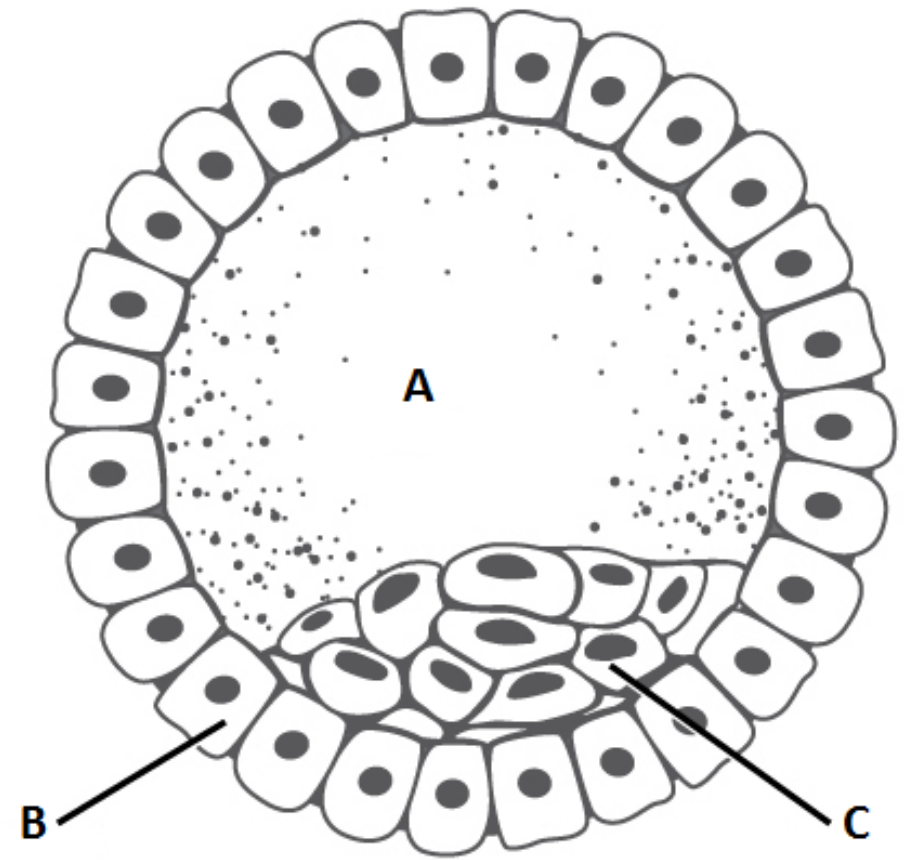




A

B

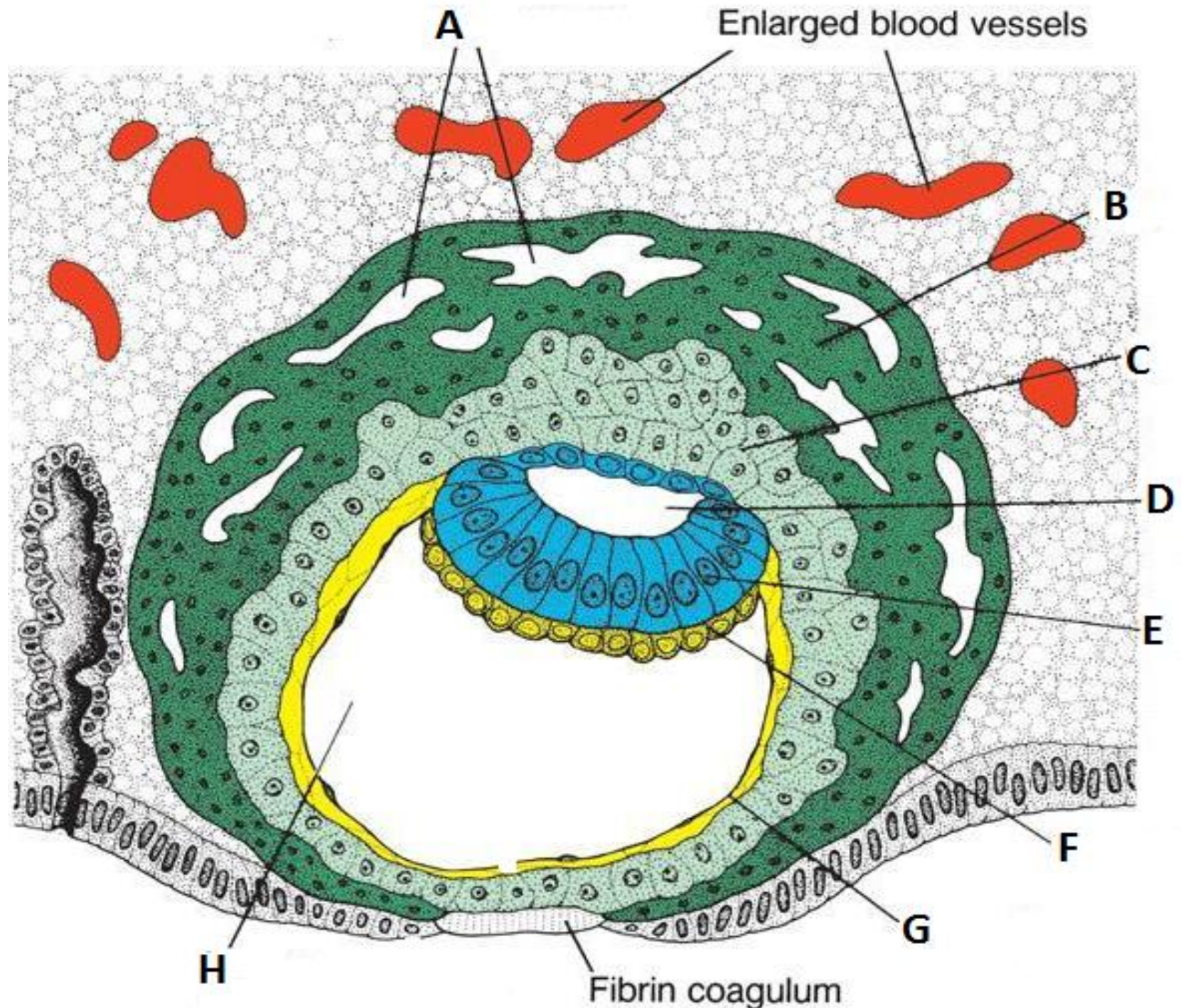
C

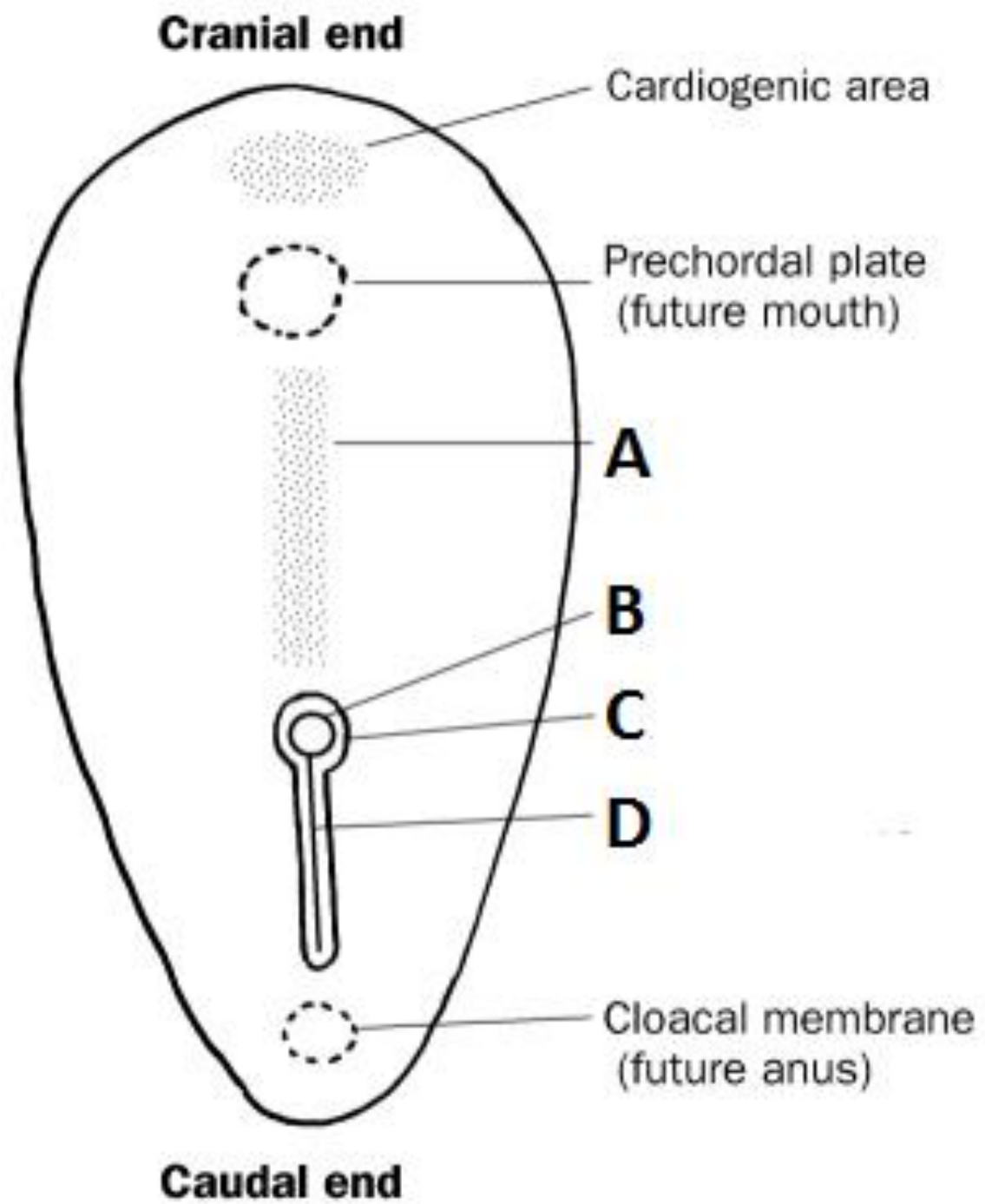


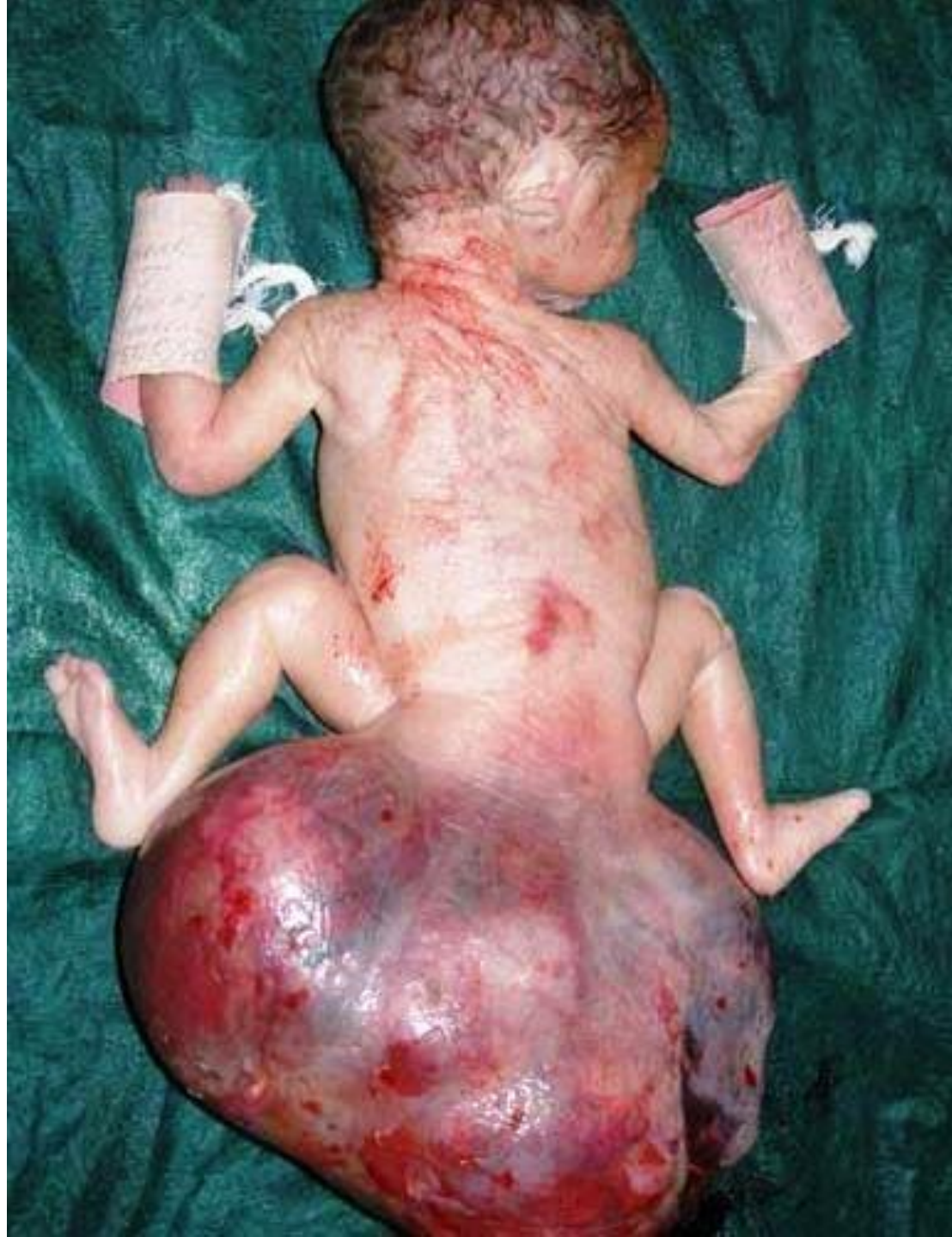A

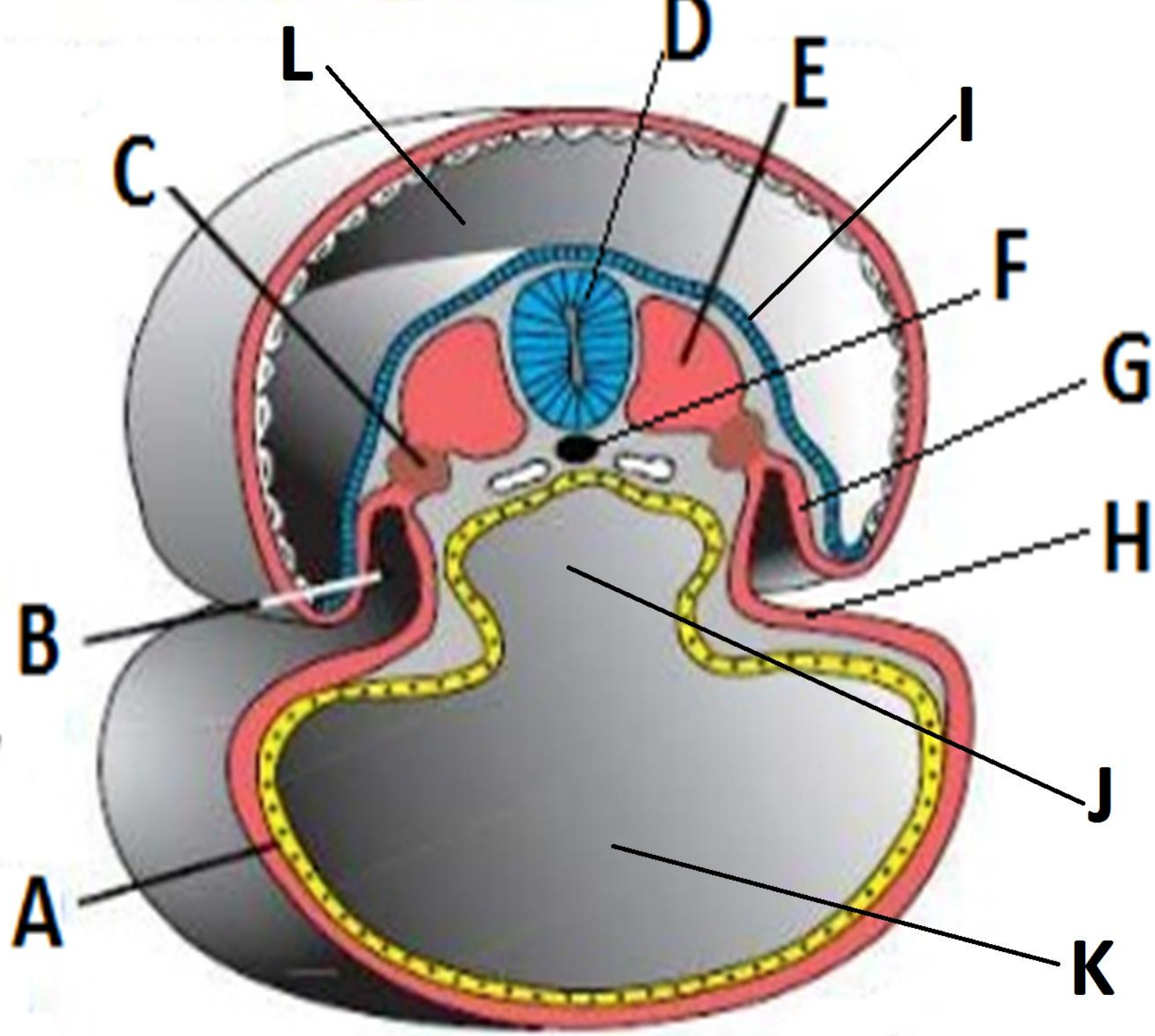
B

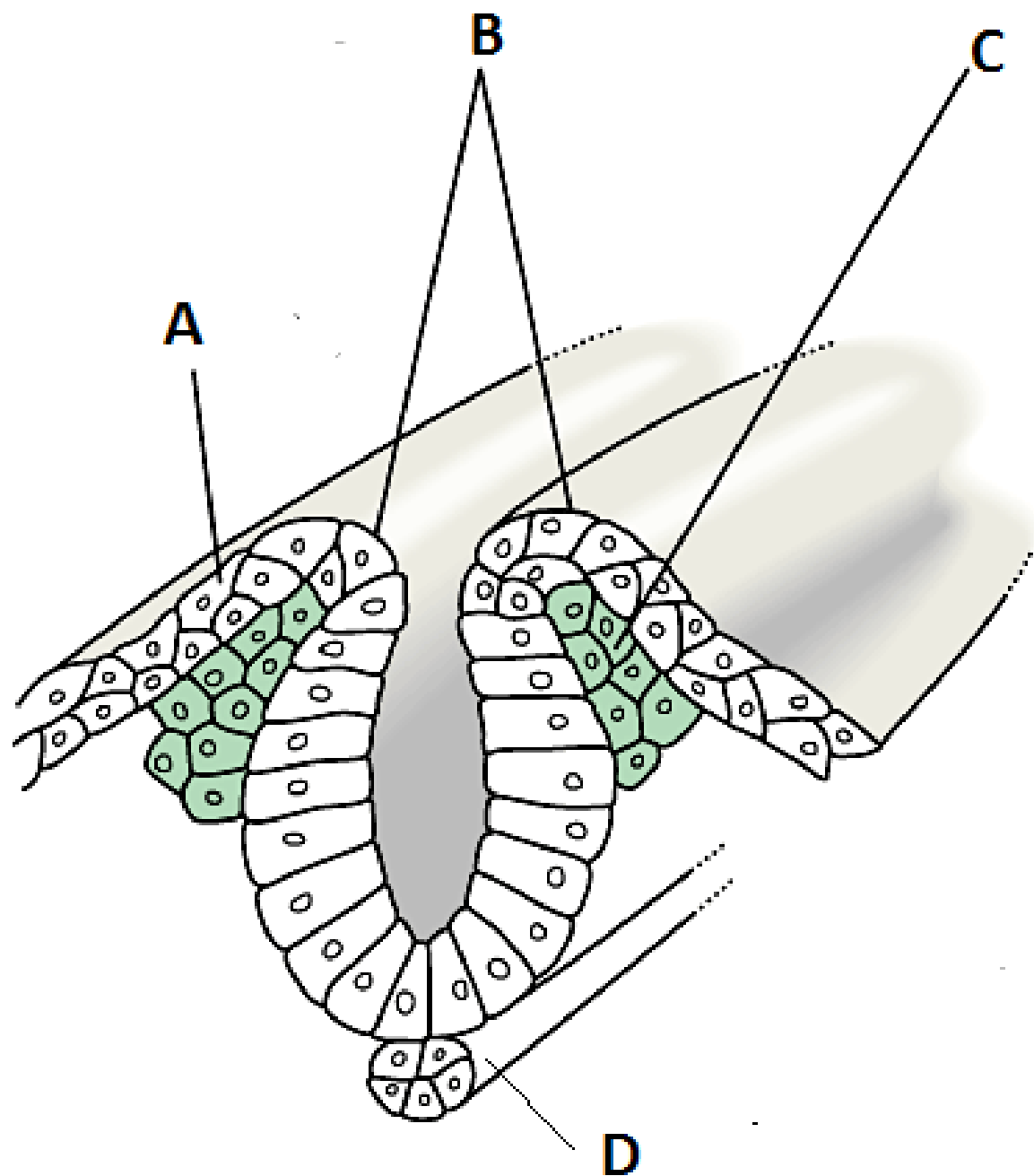
C

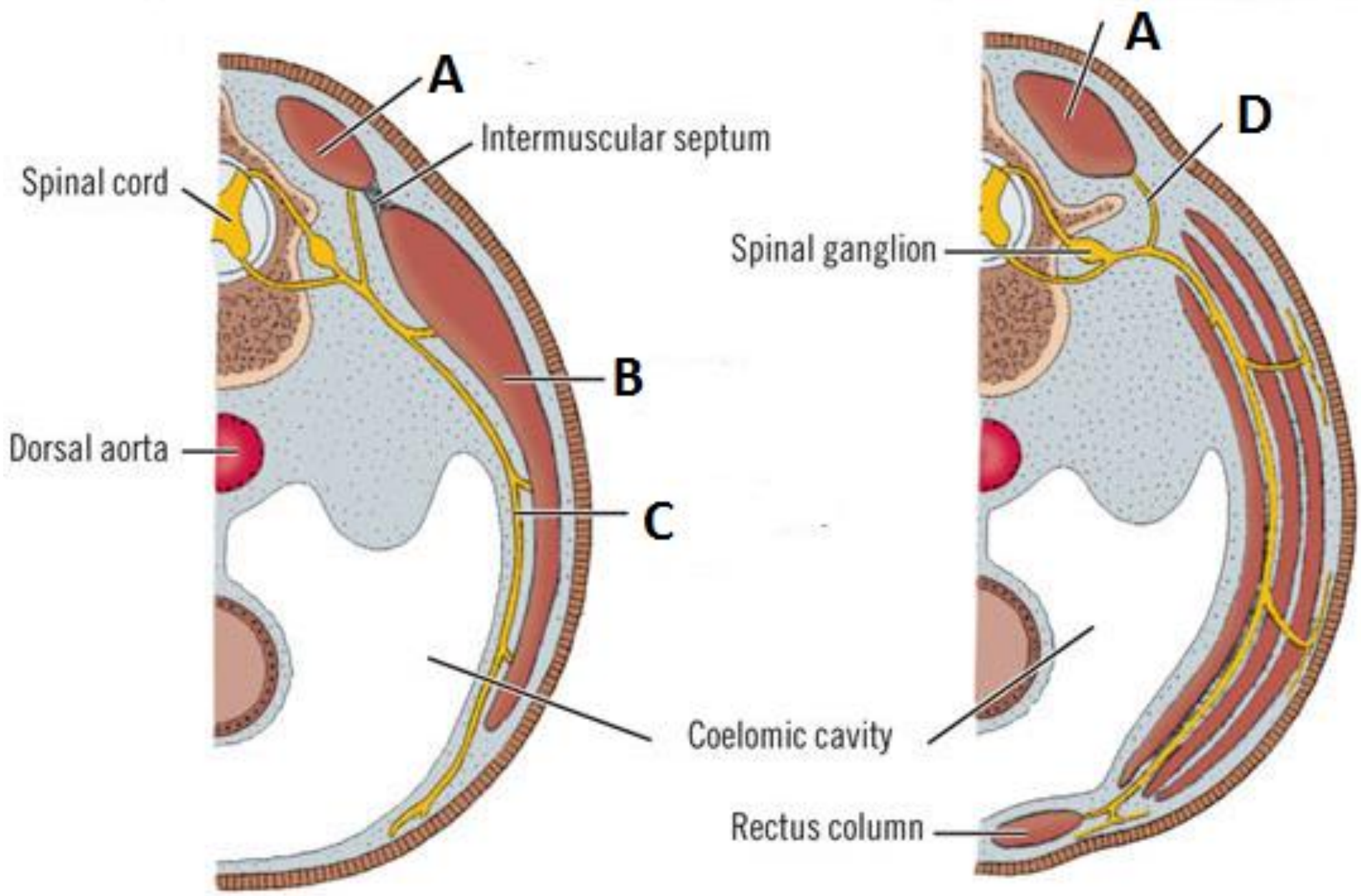


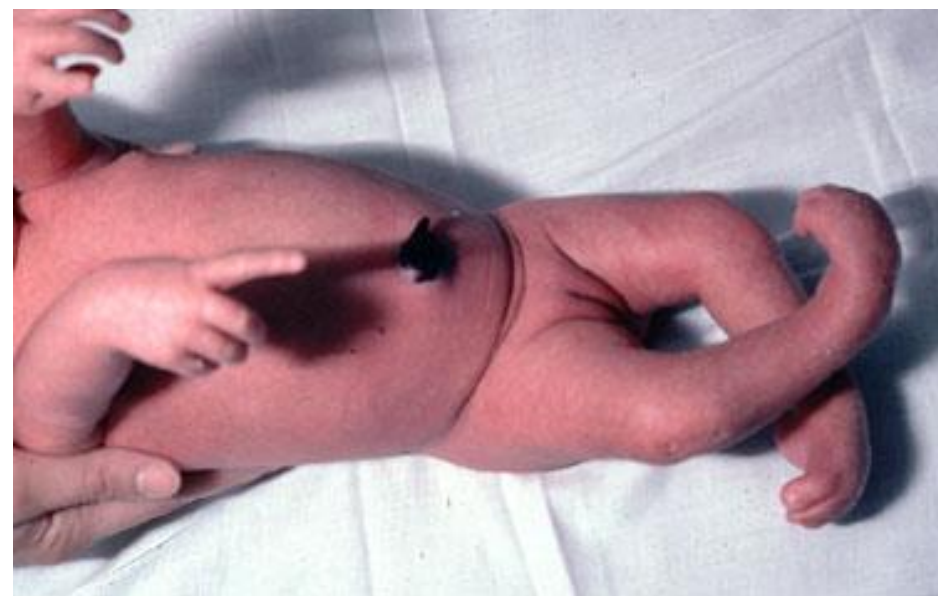
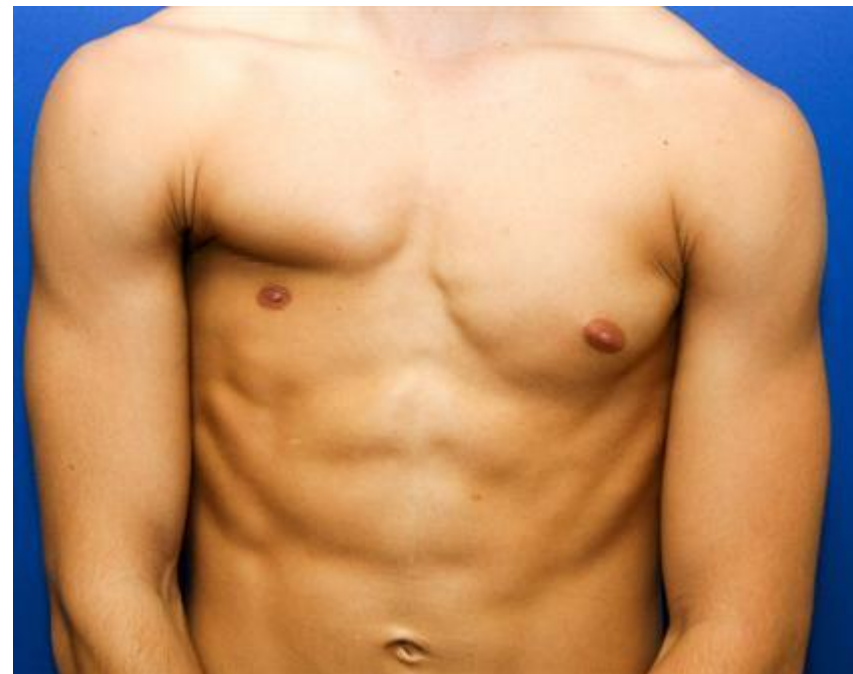
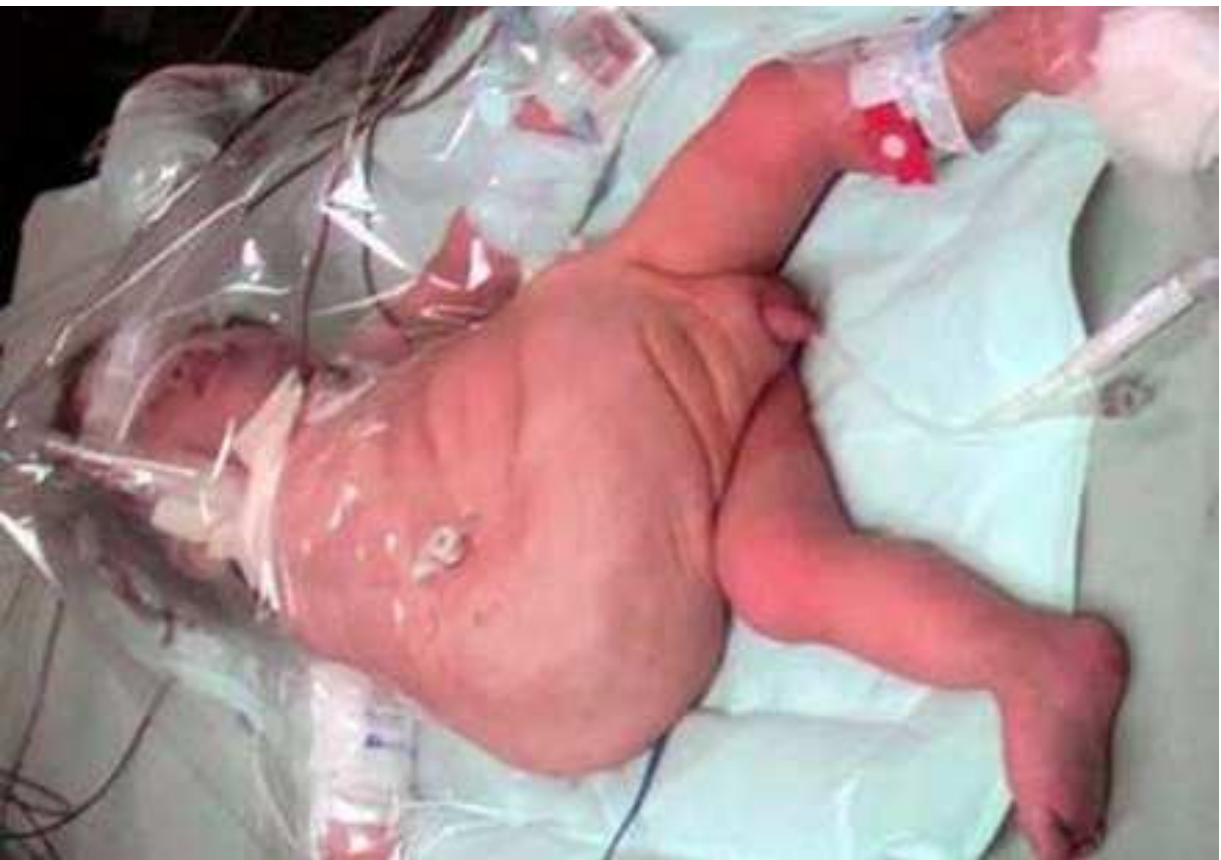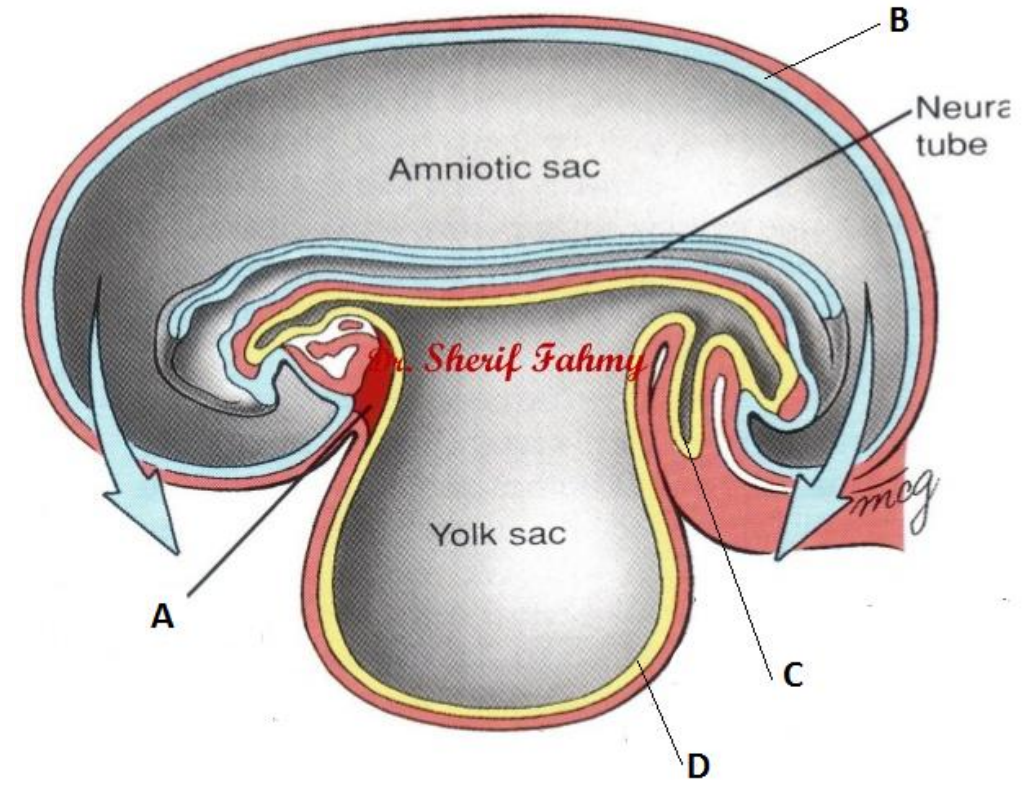
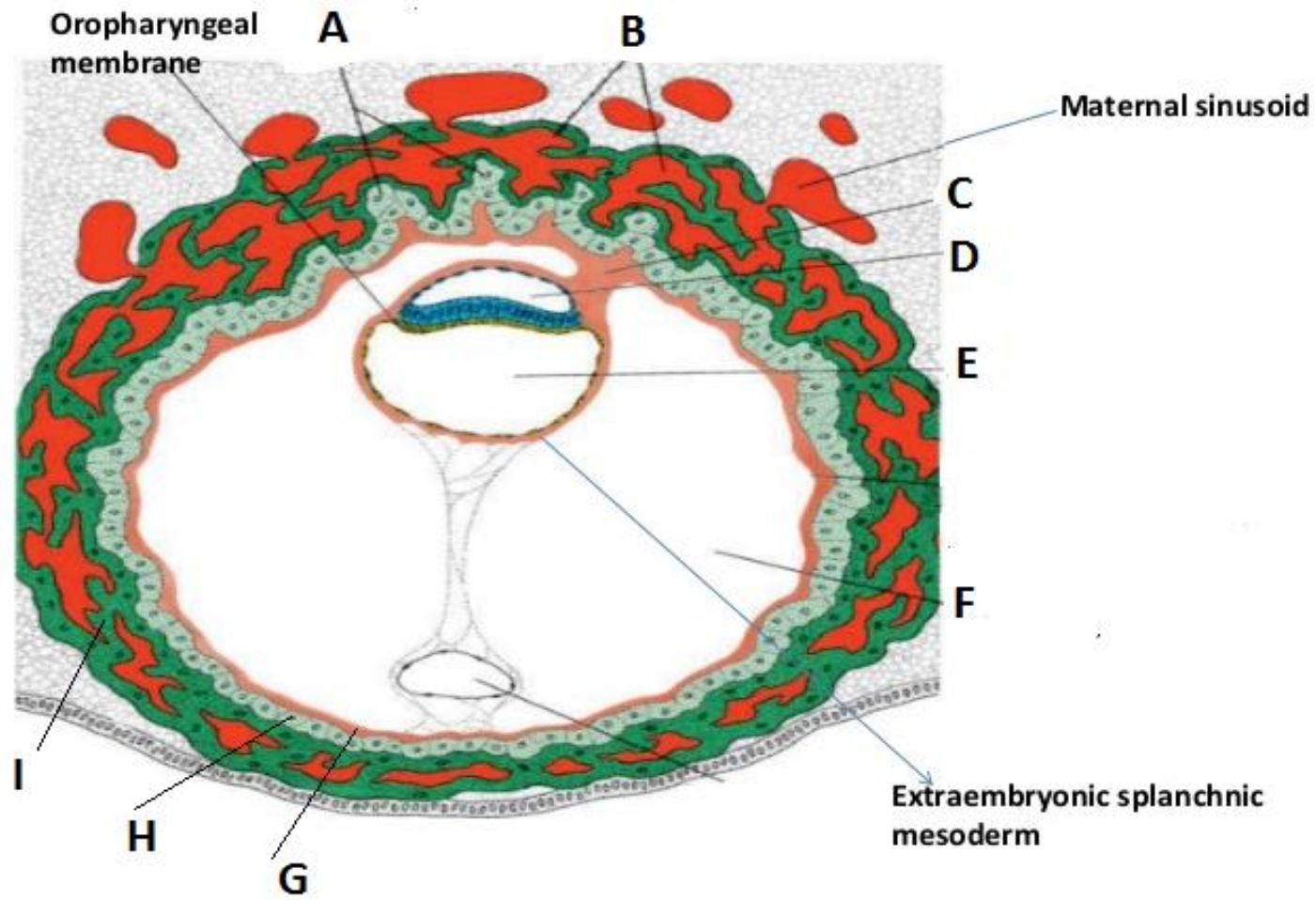


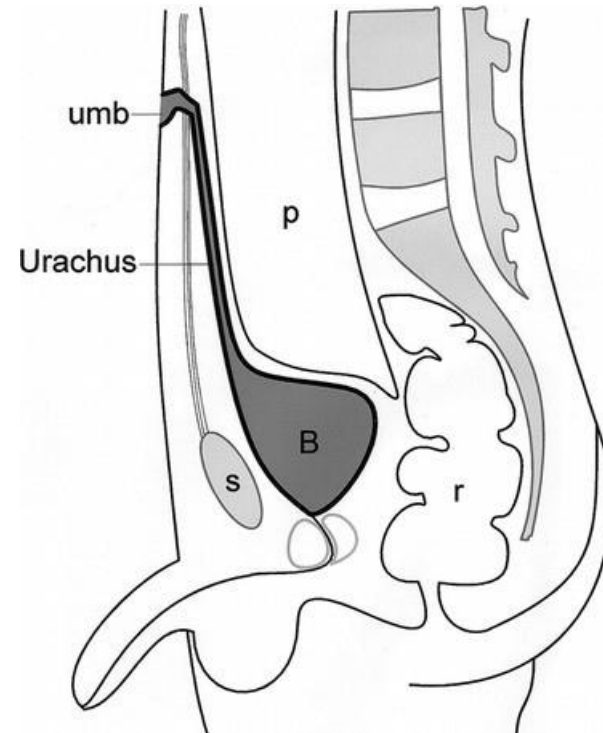


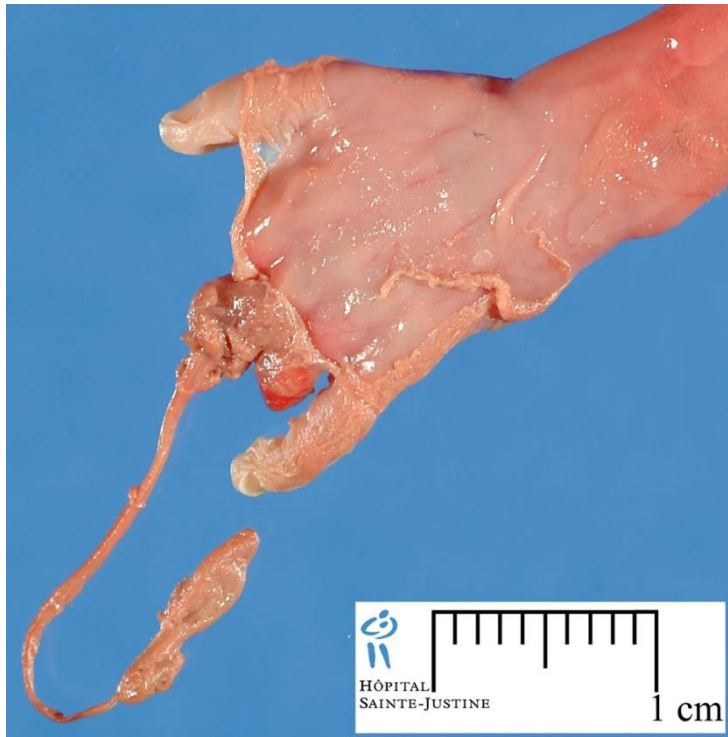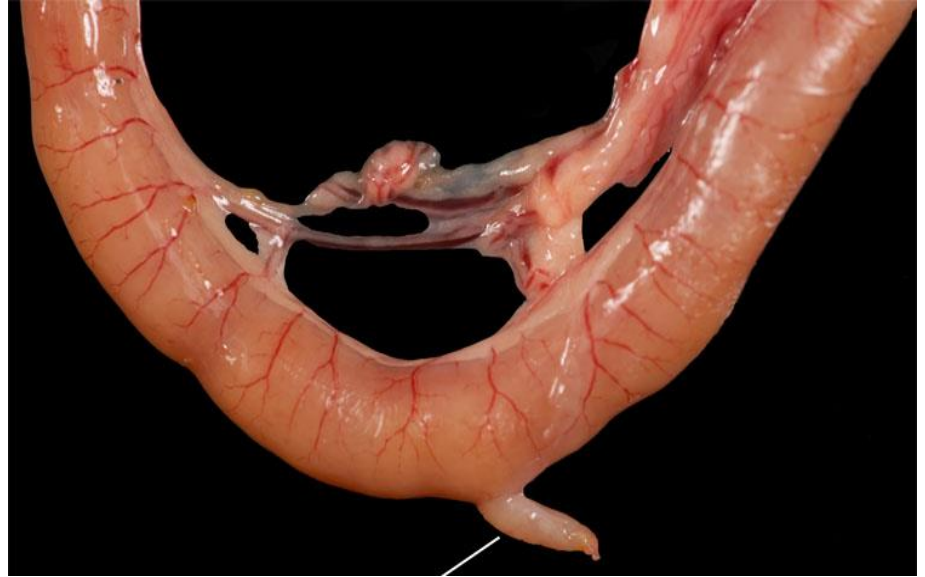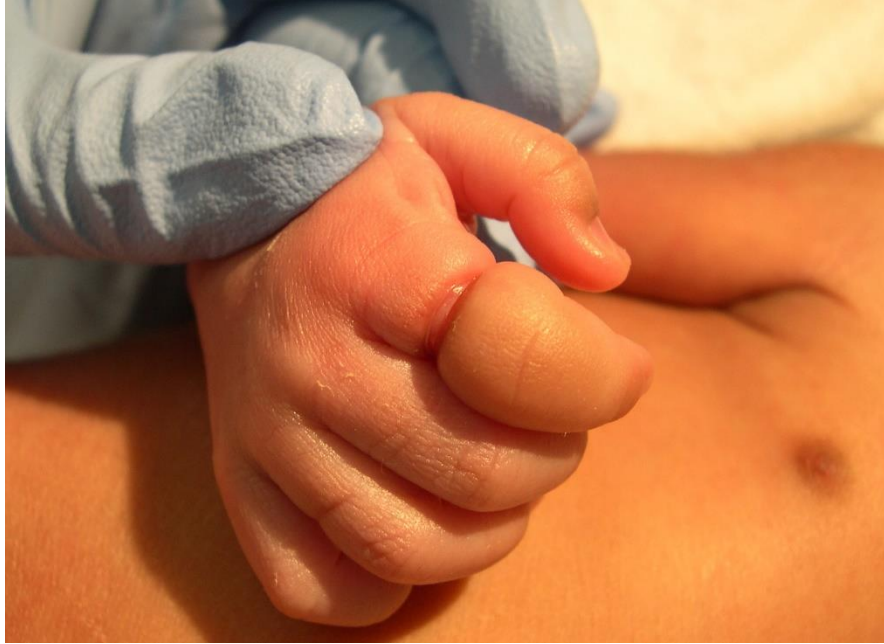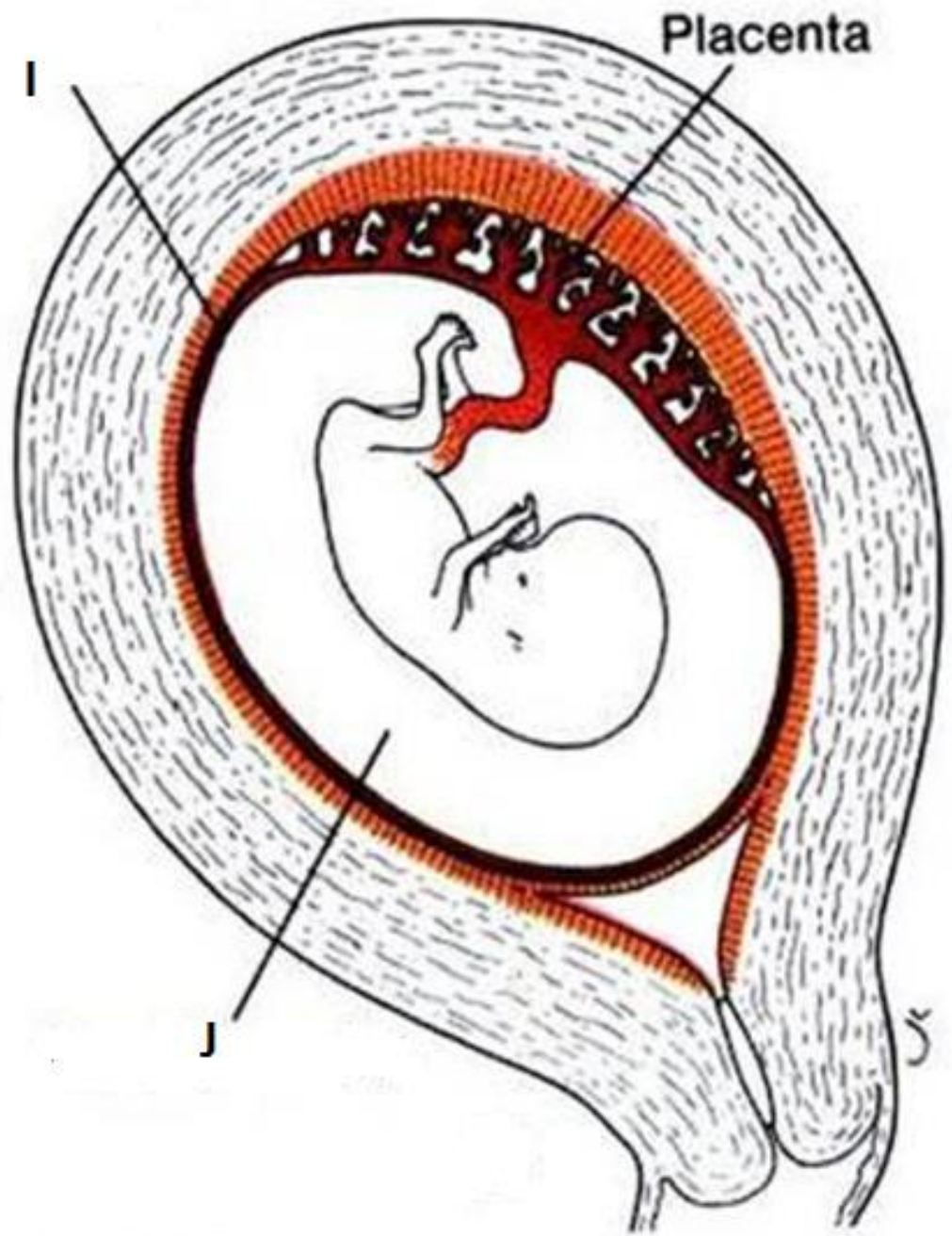
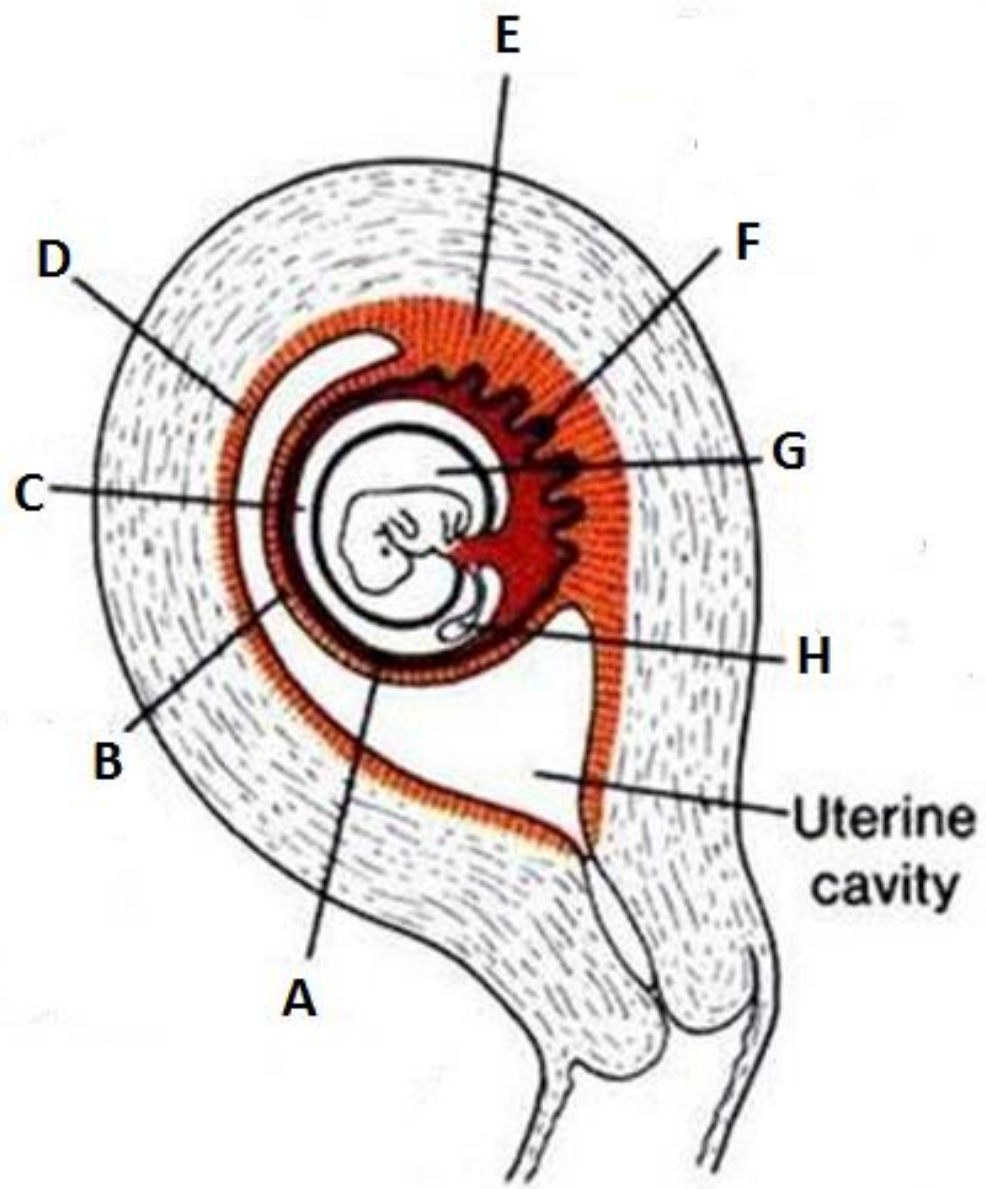



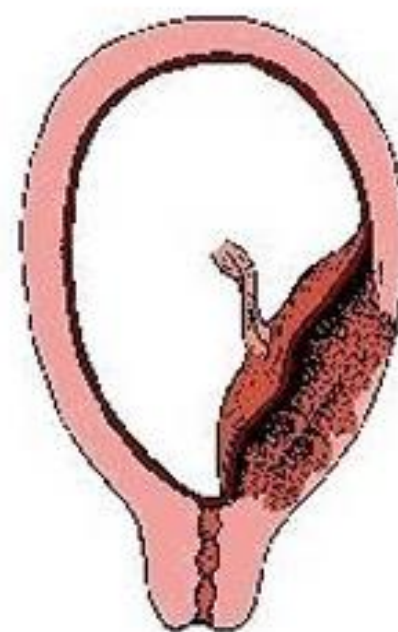
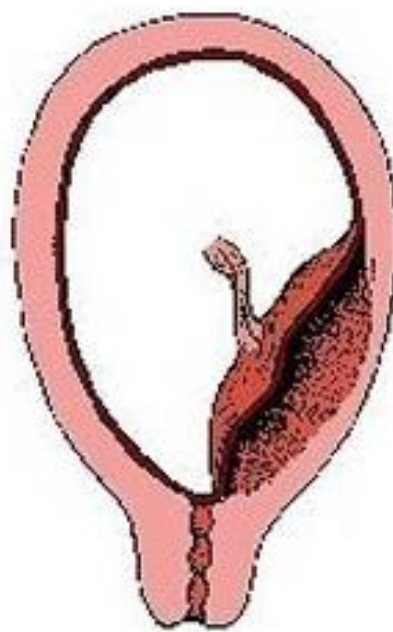
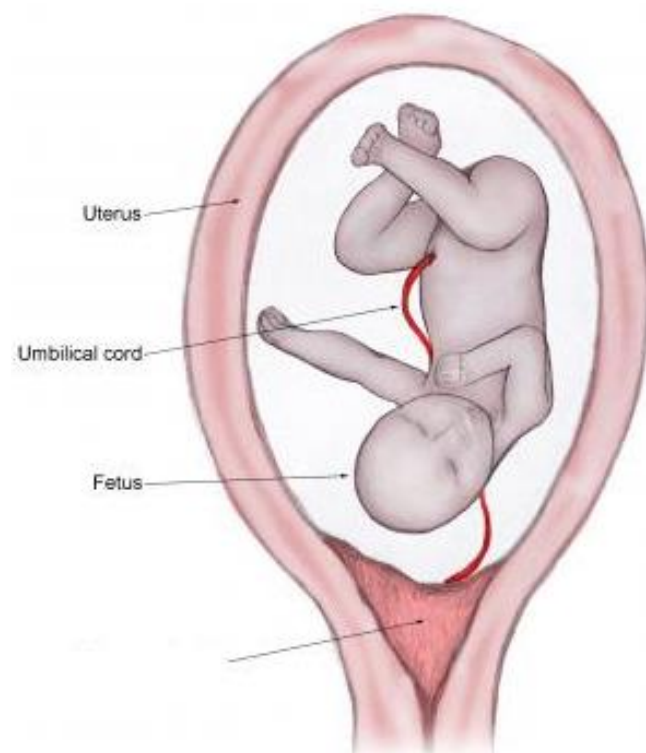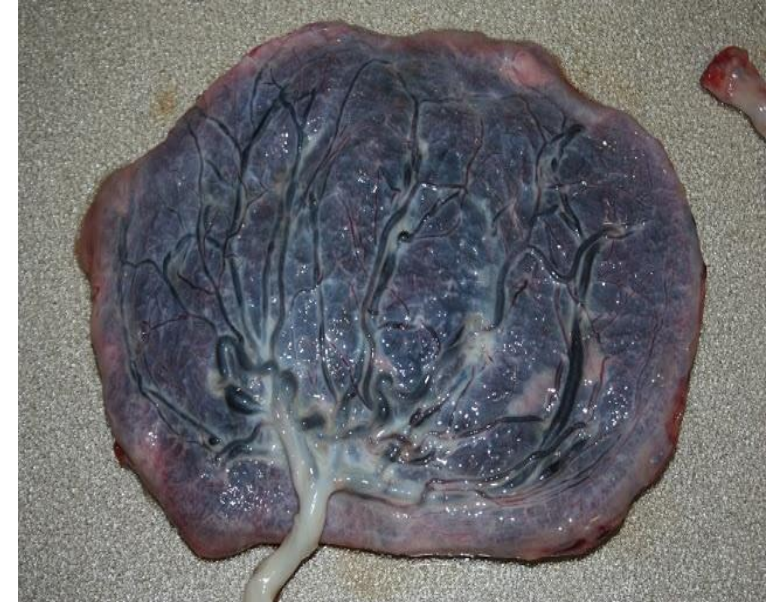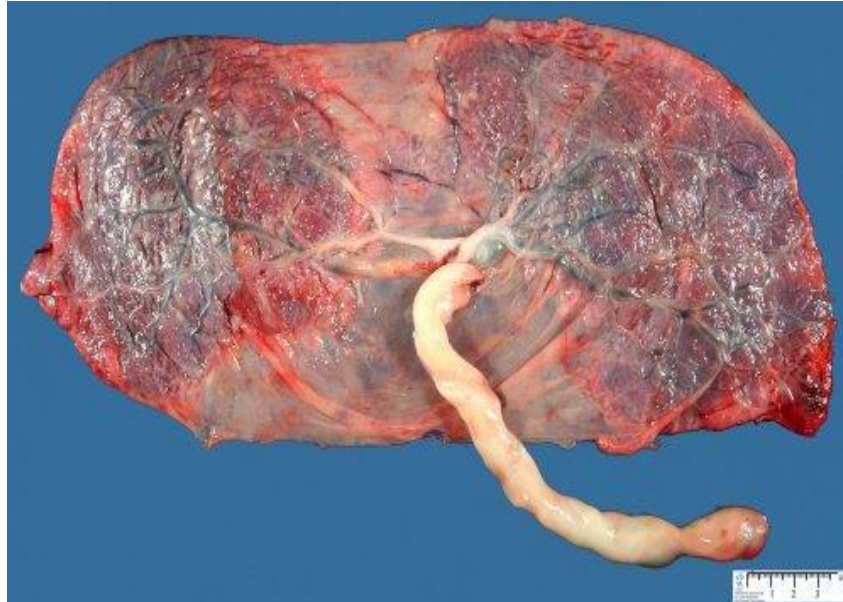
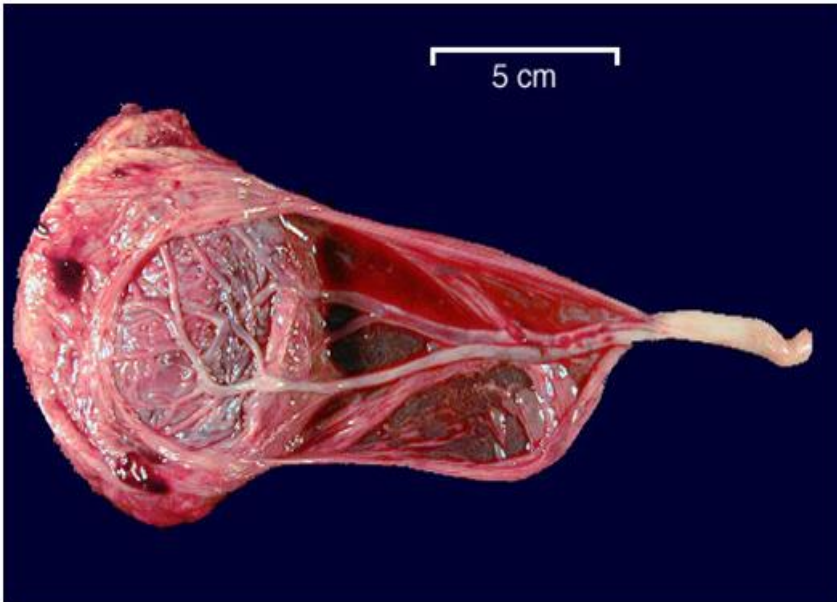


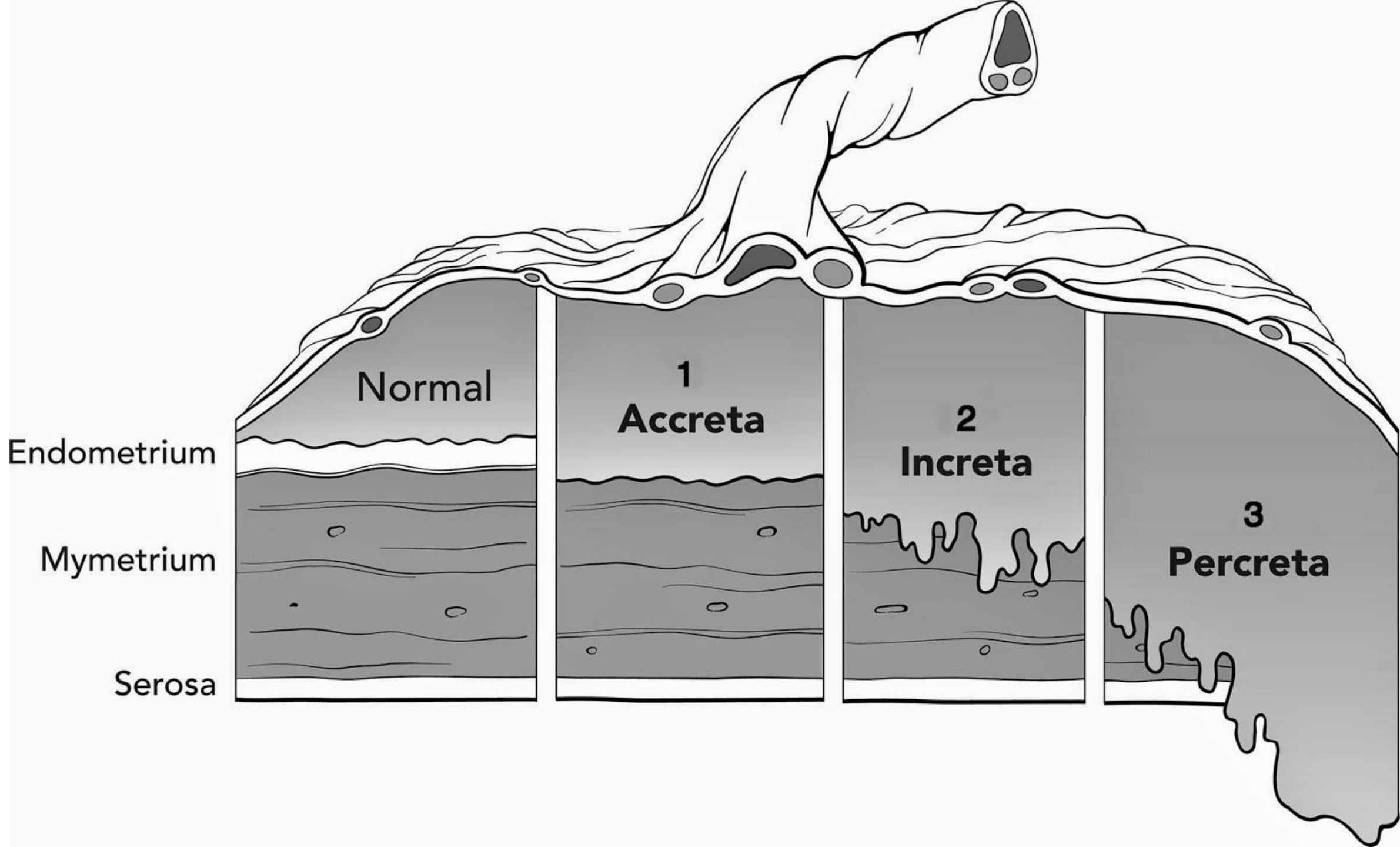




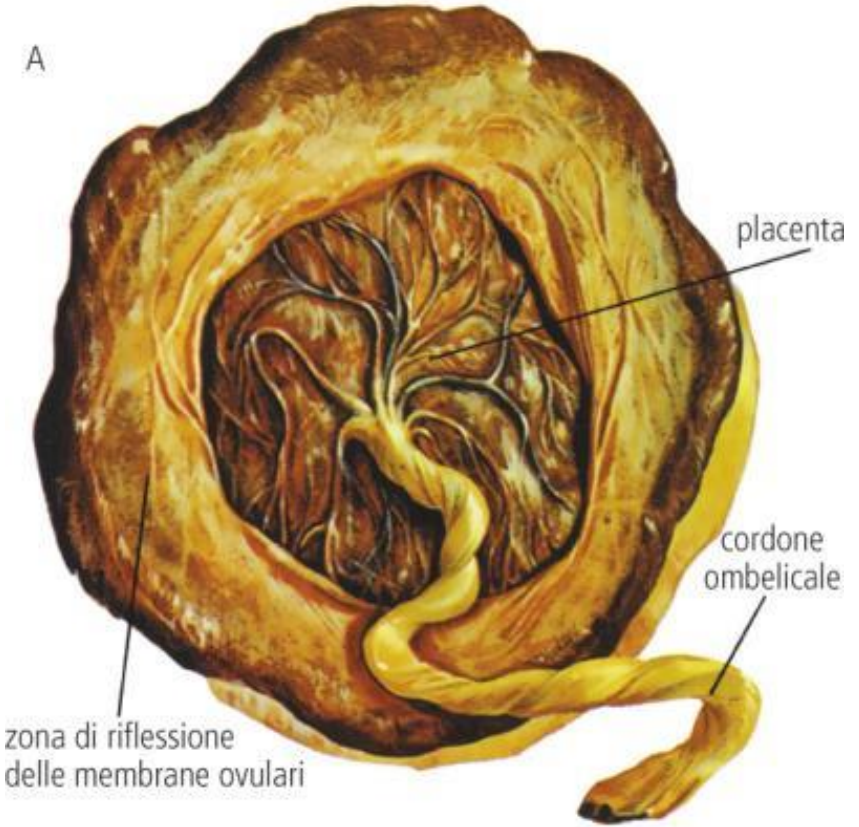


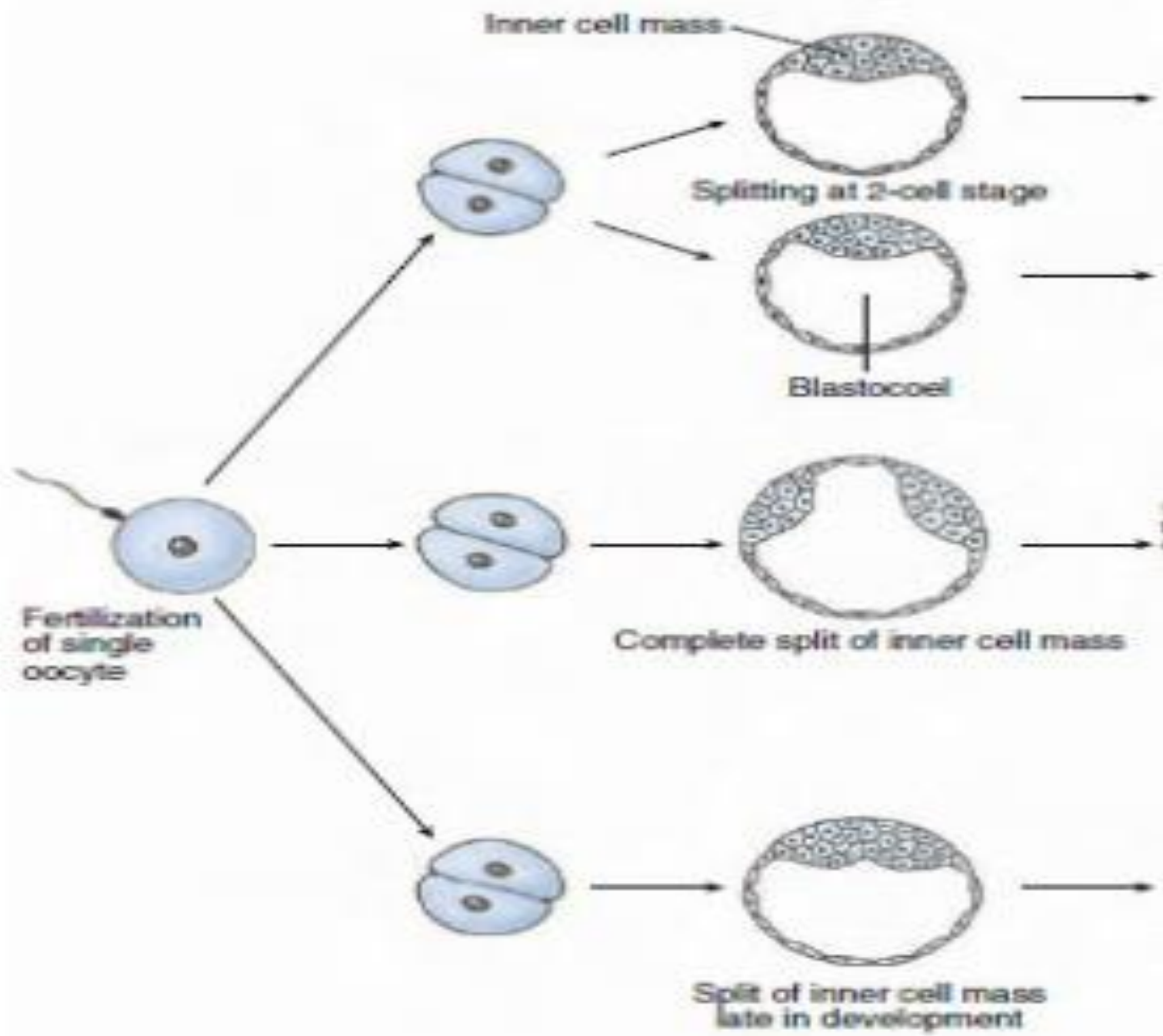




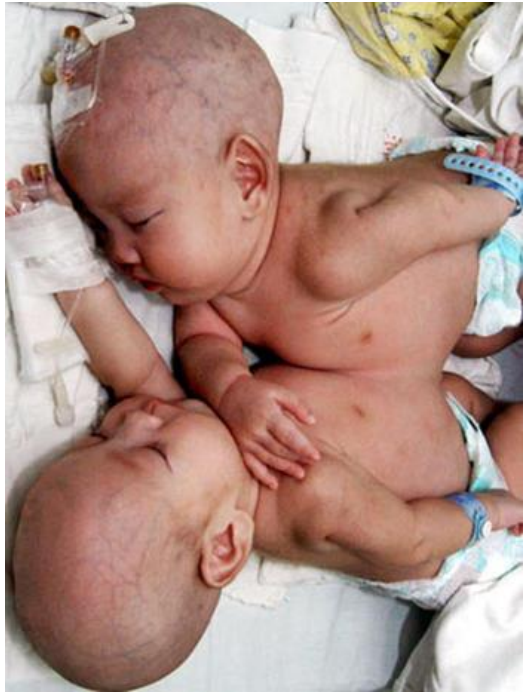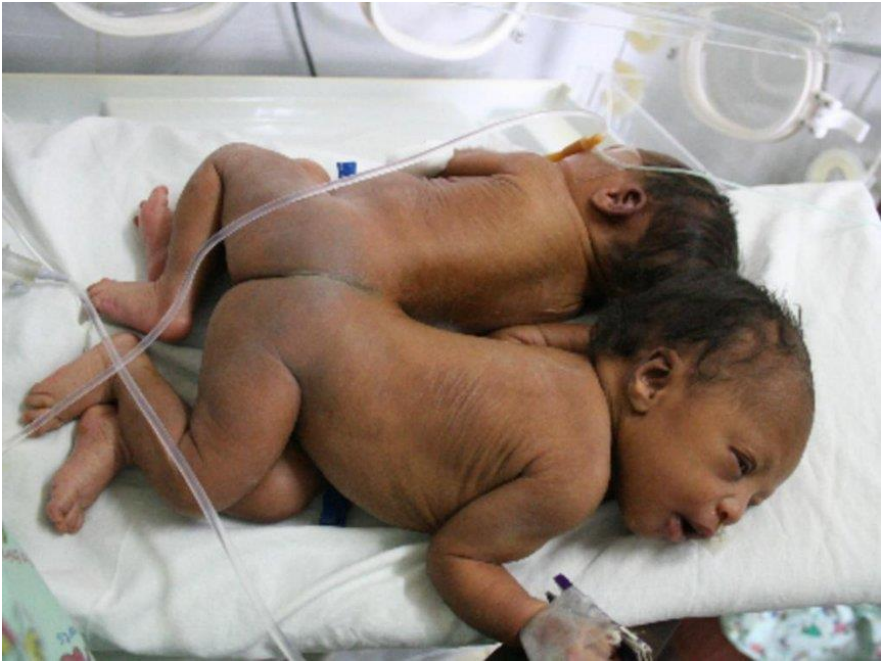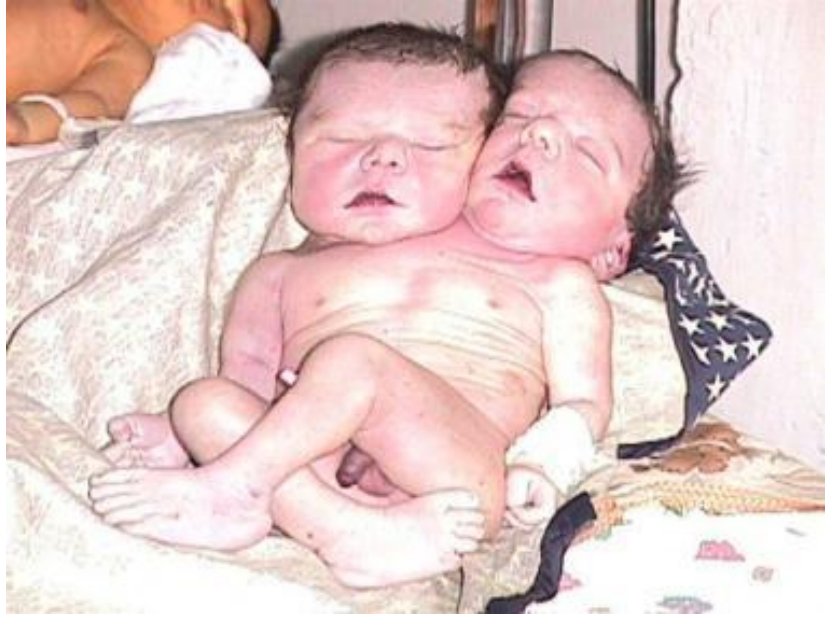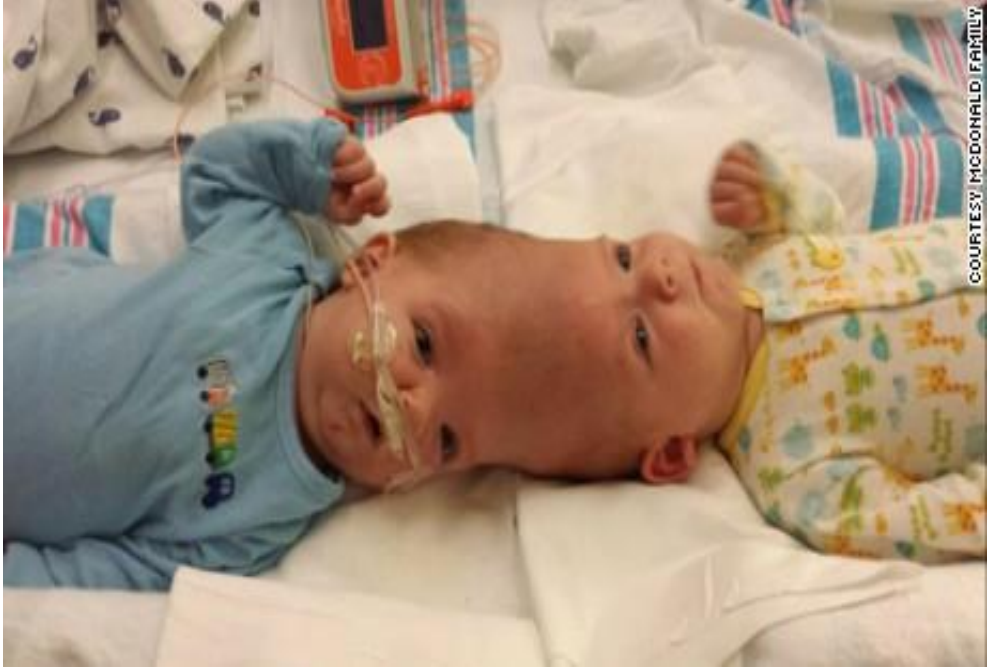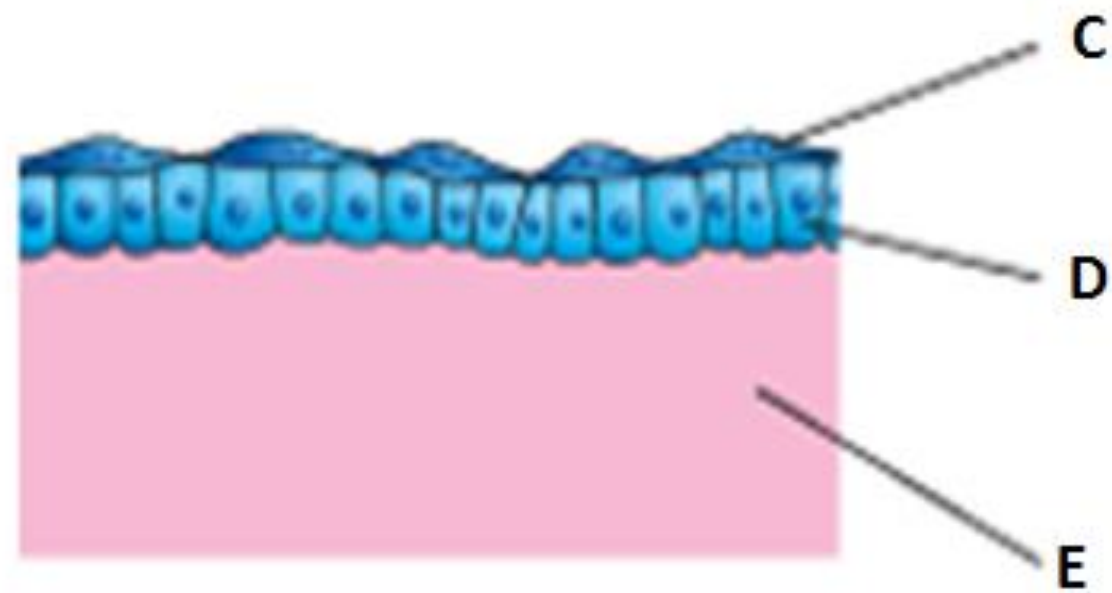


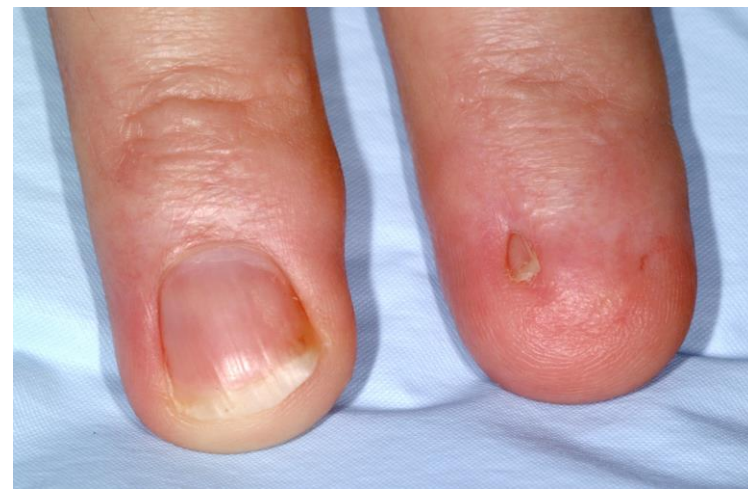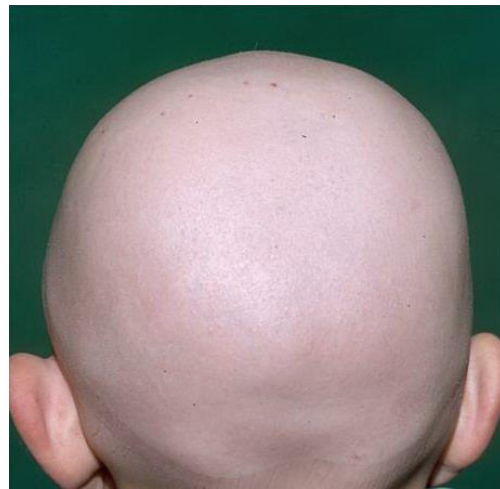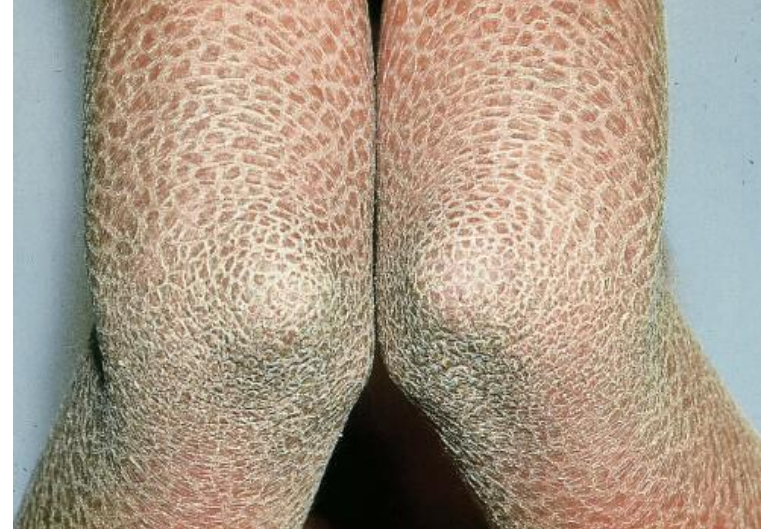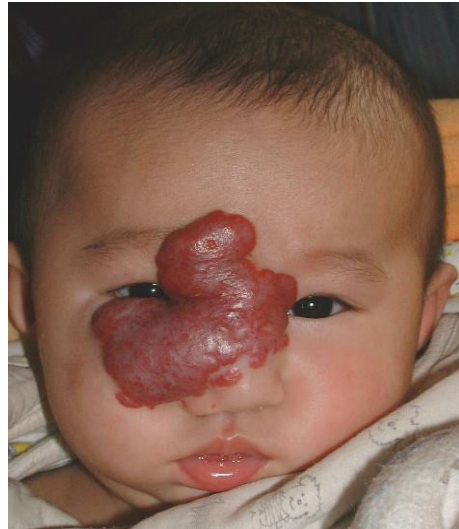
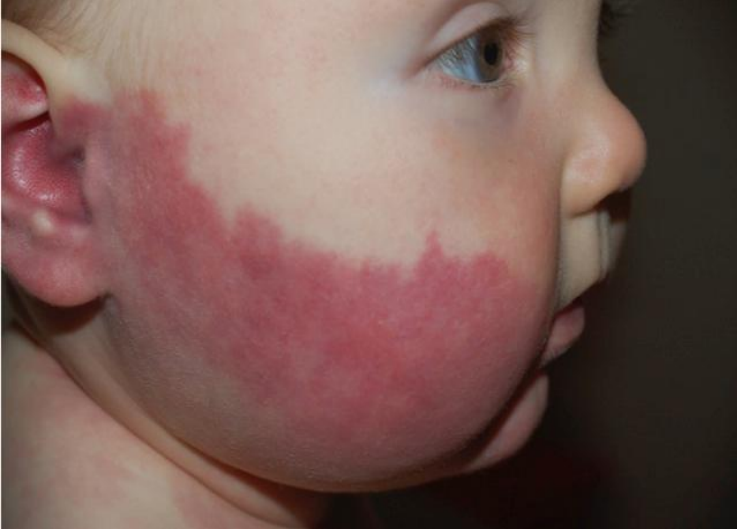A

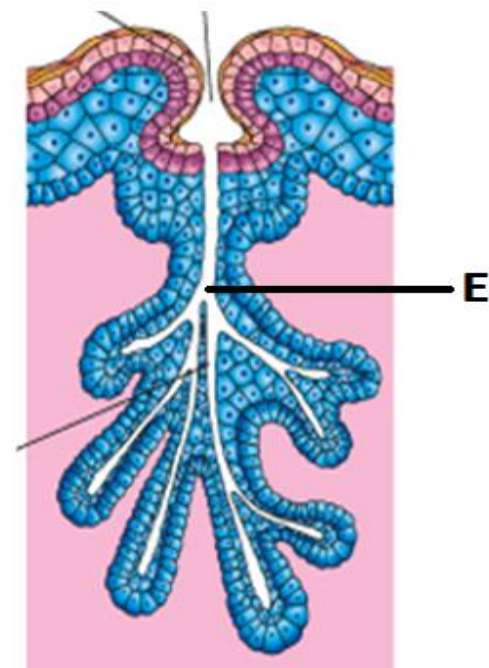
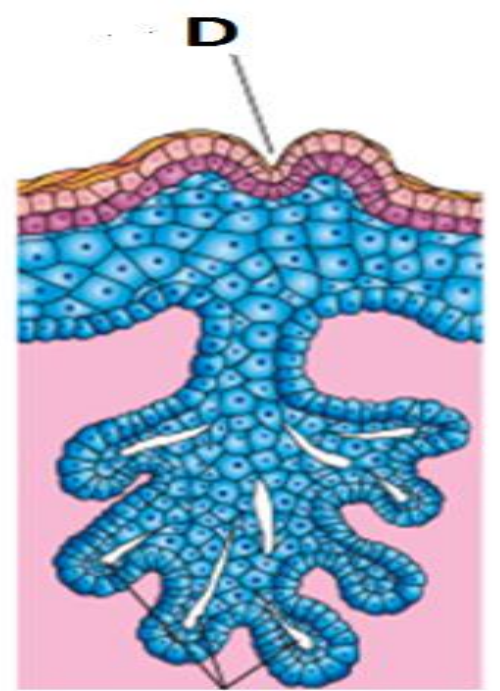
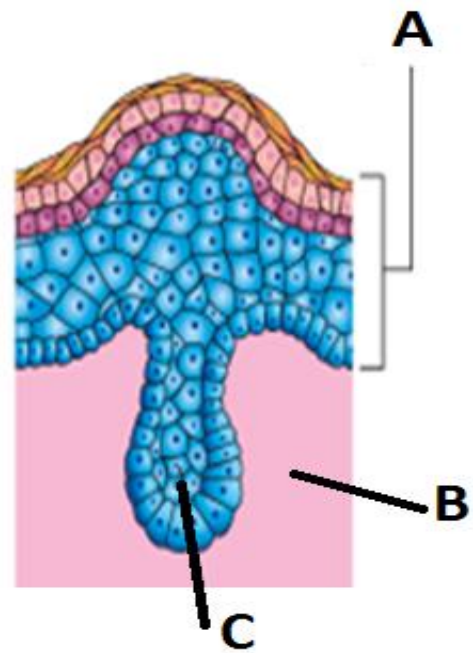
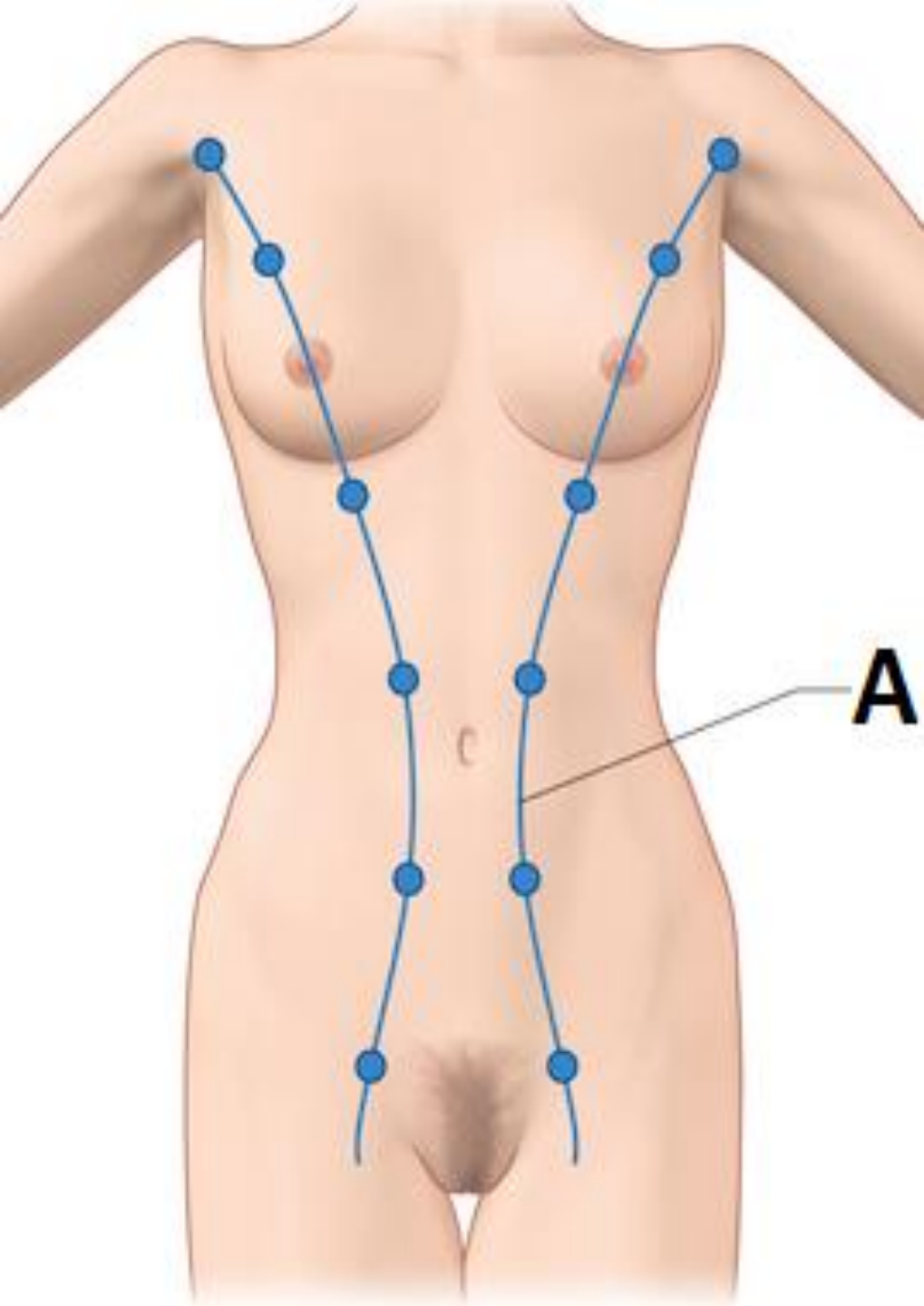


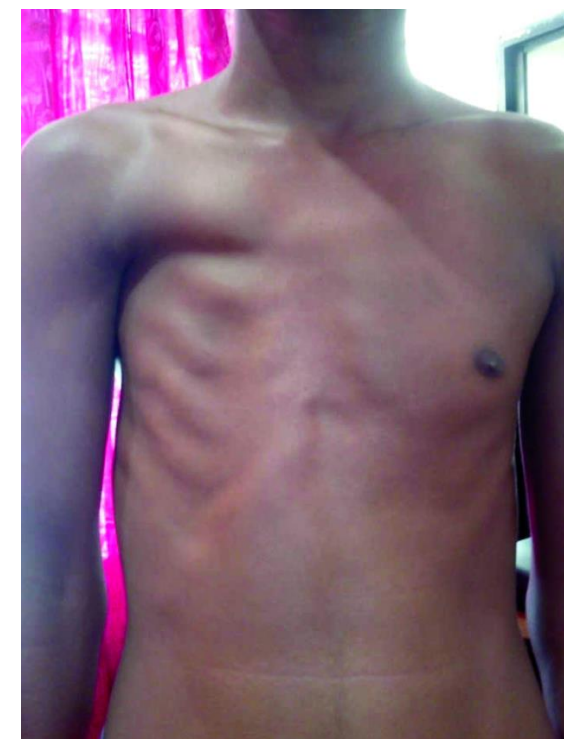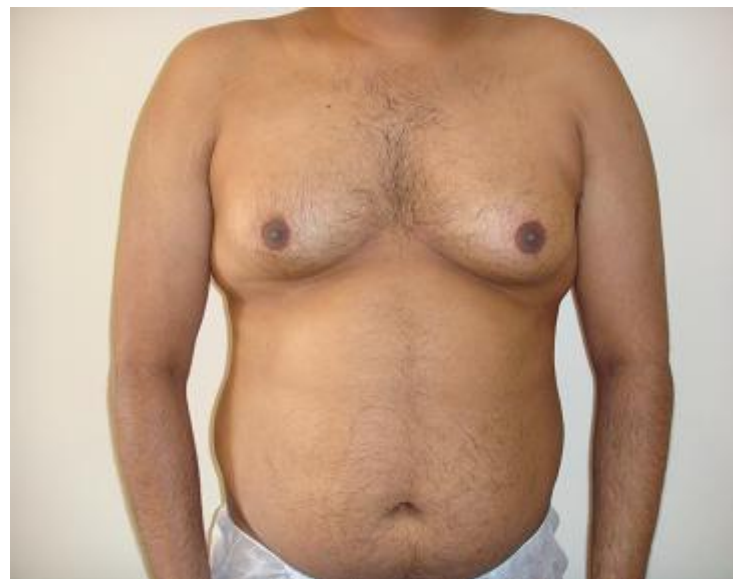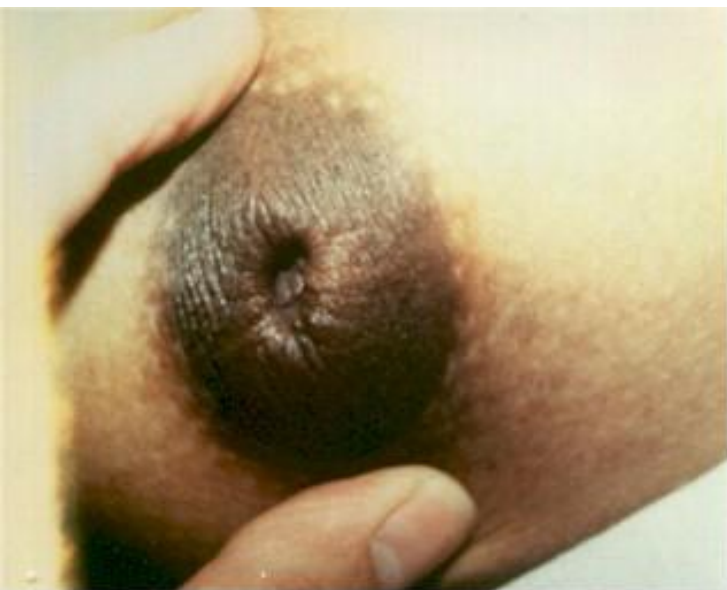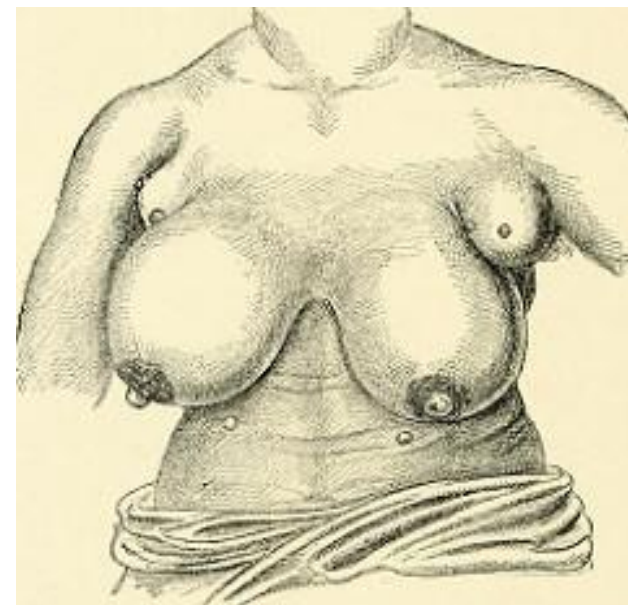


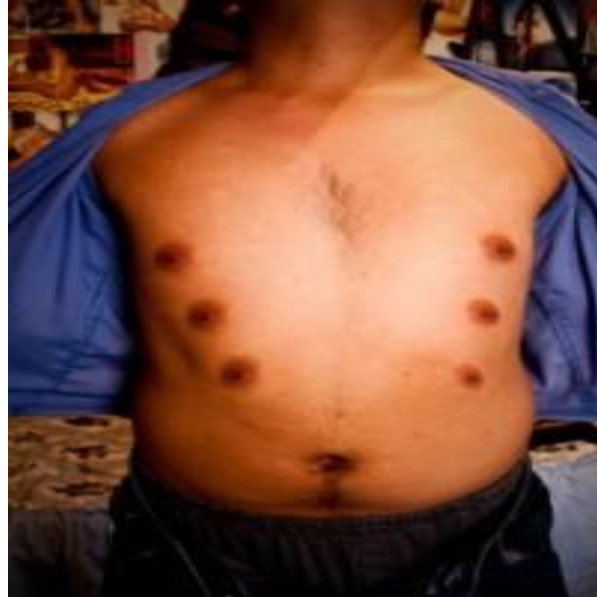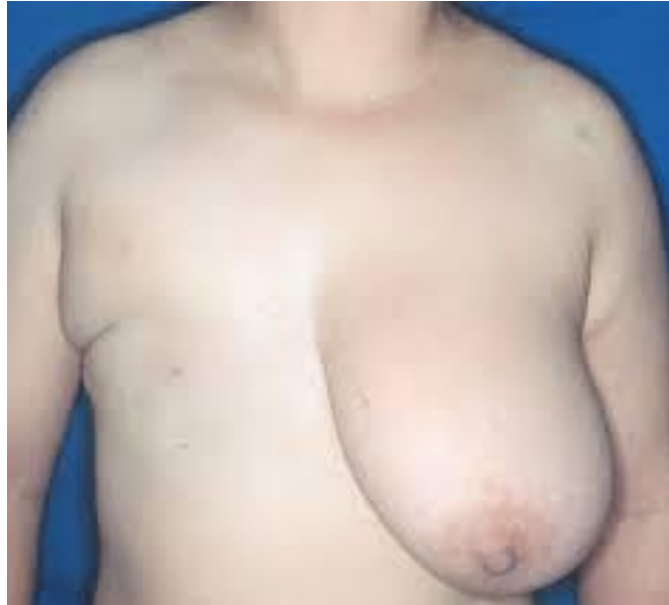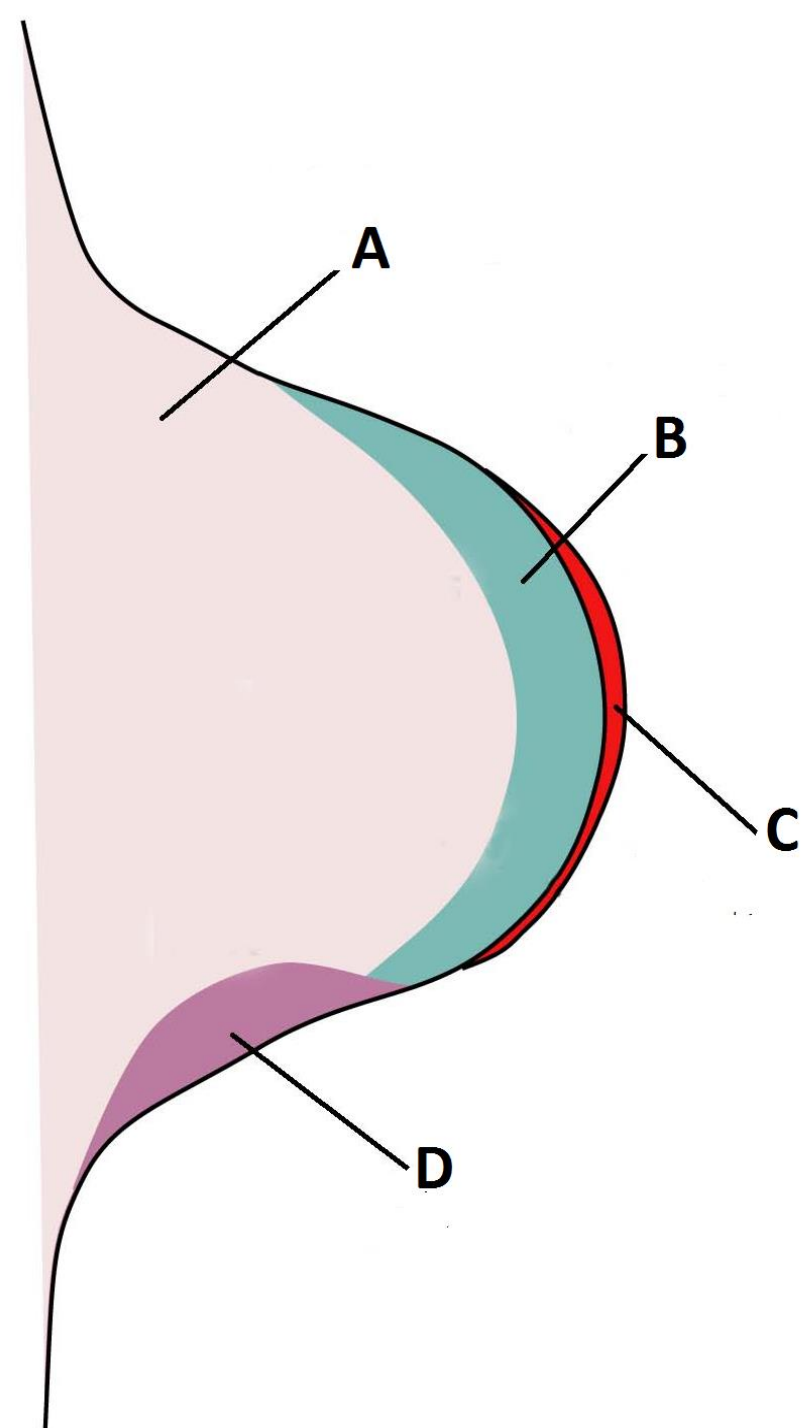
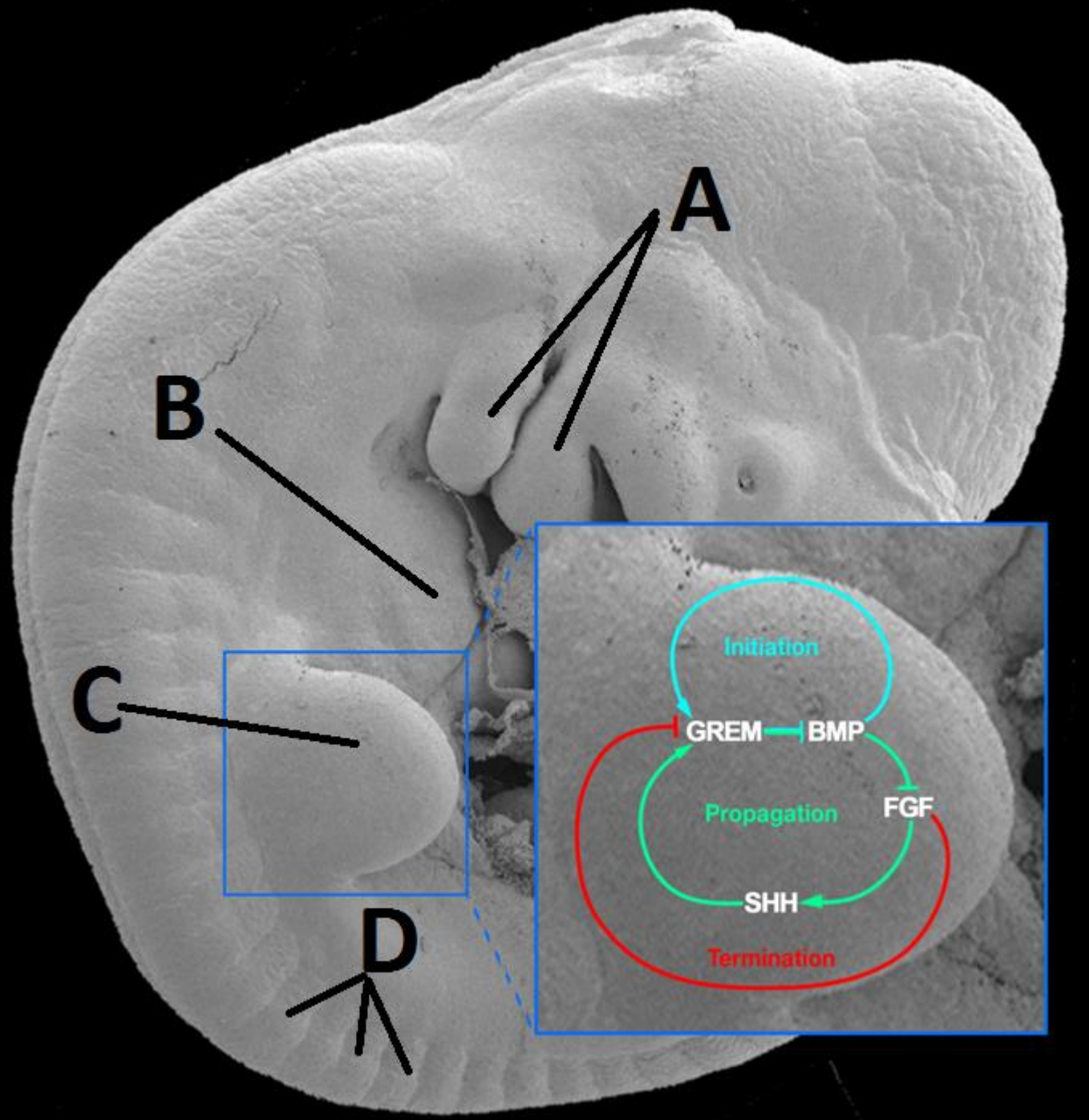


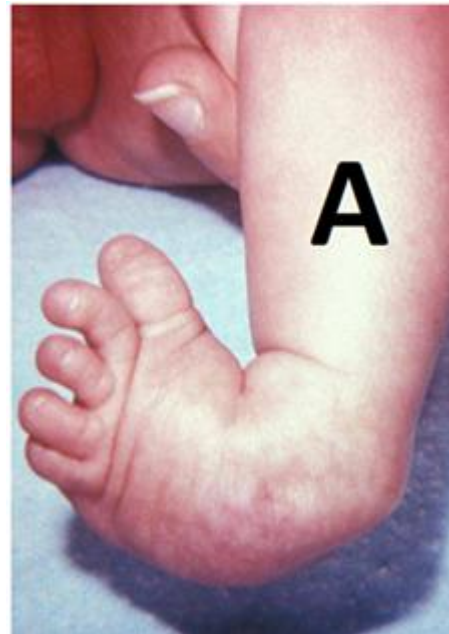
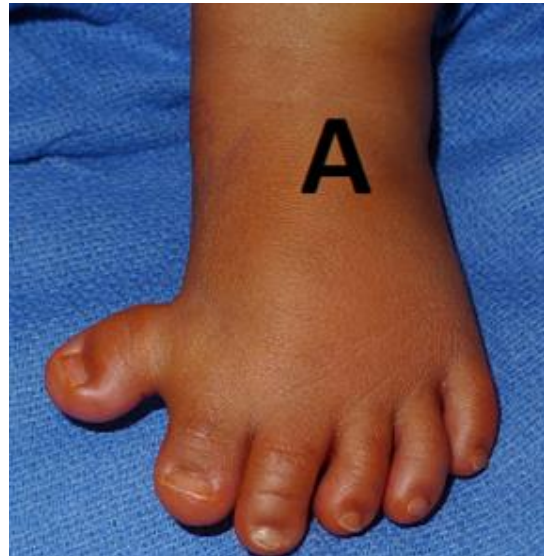
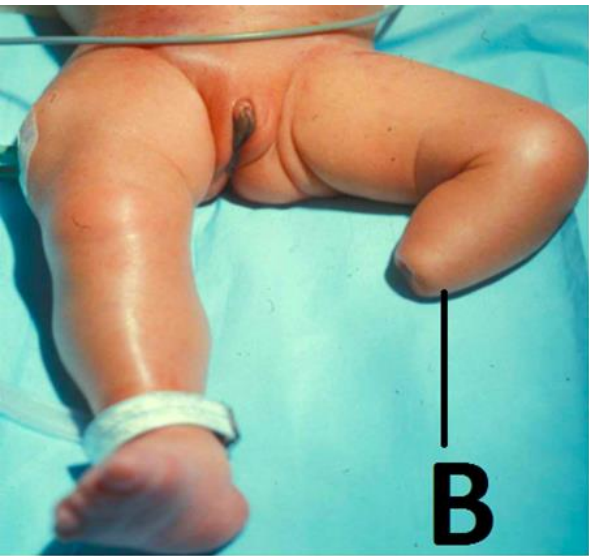
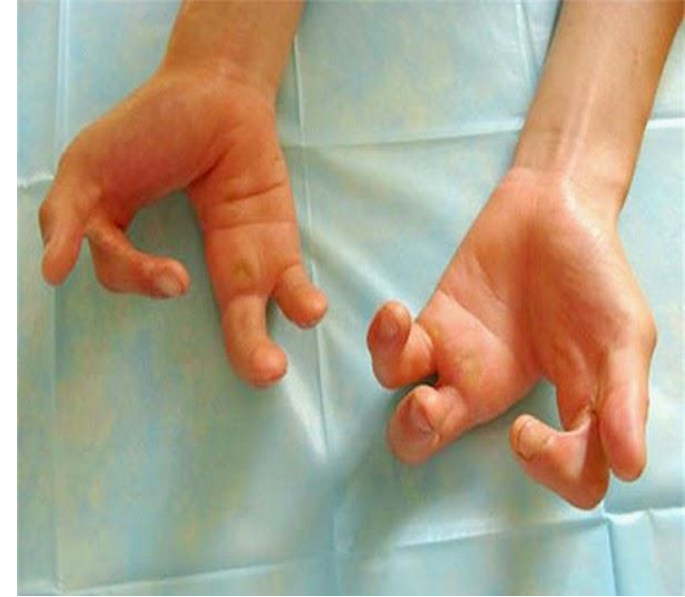


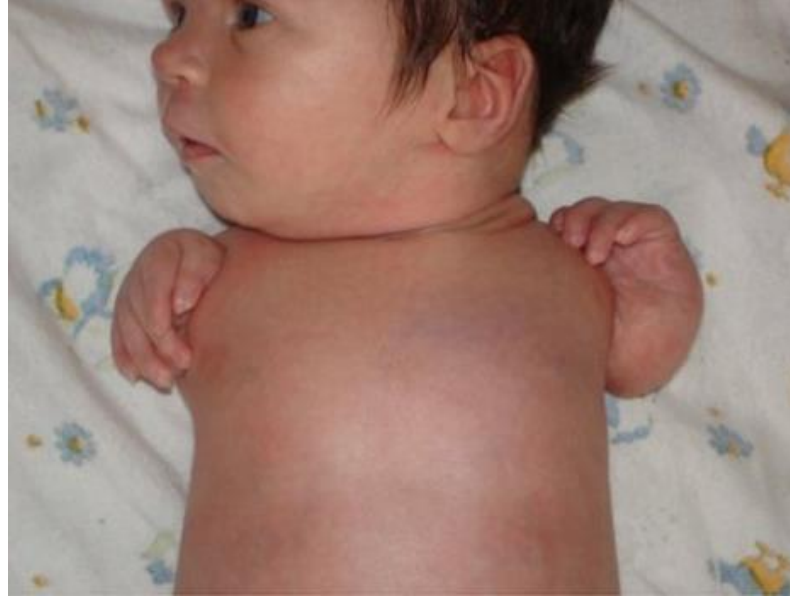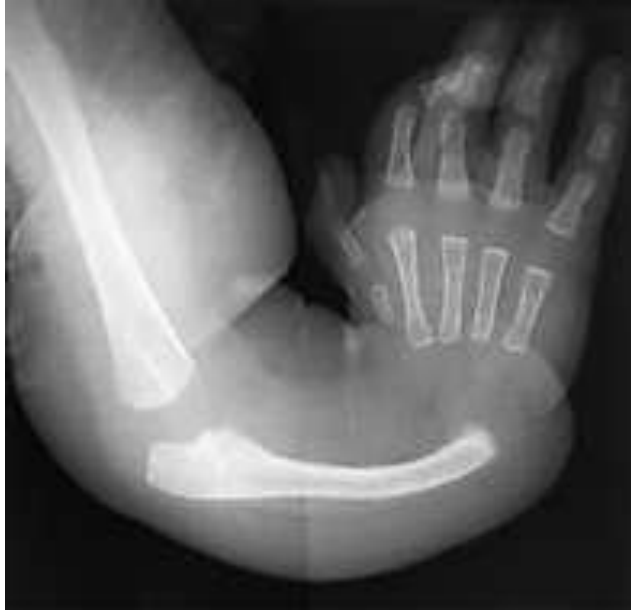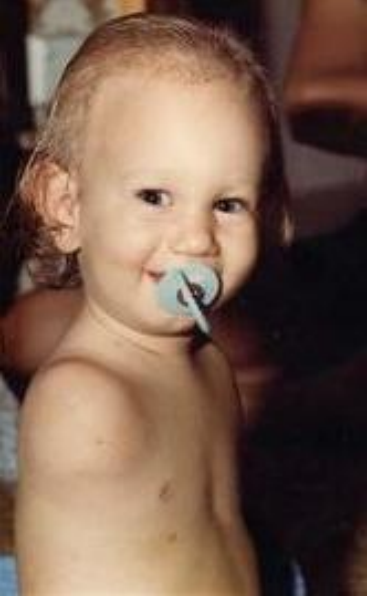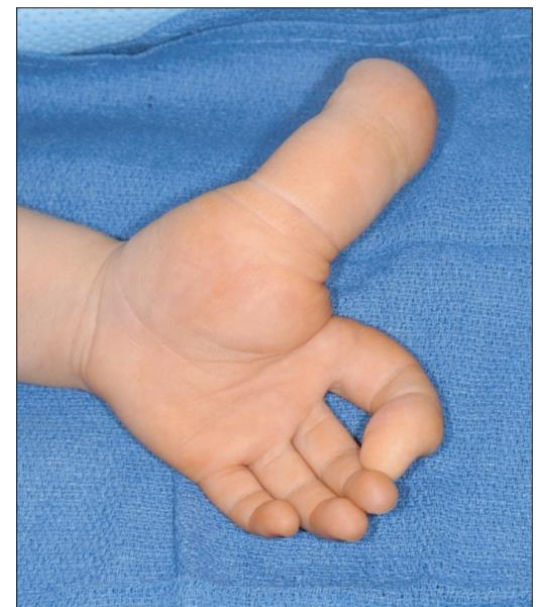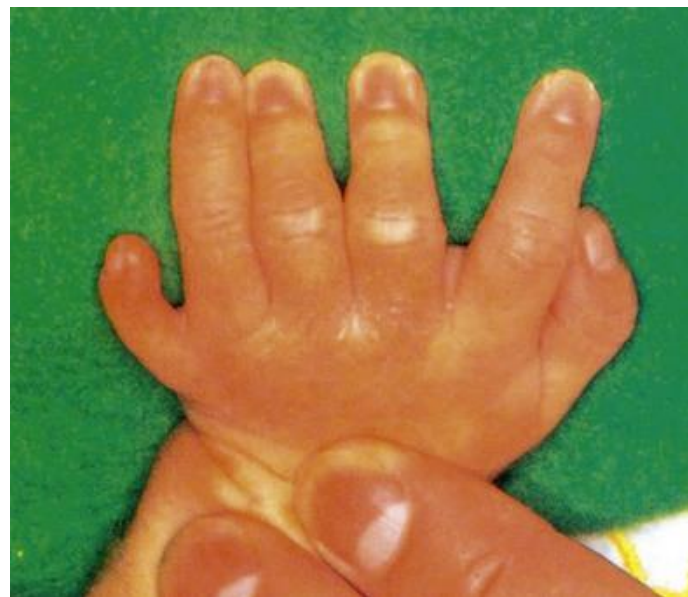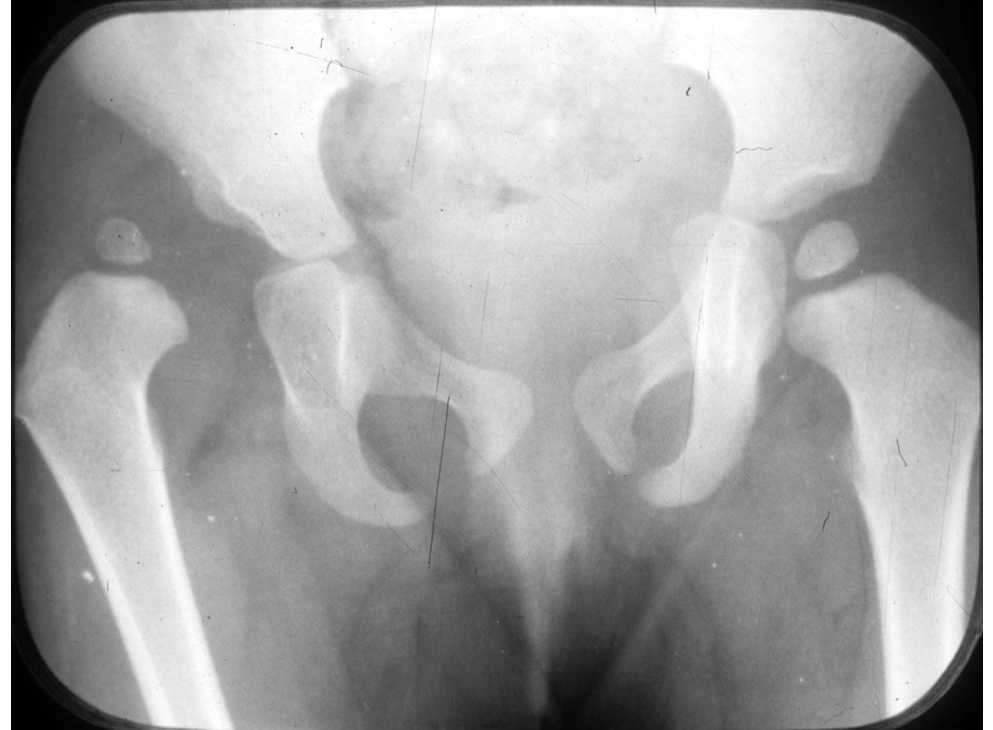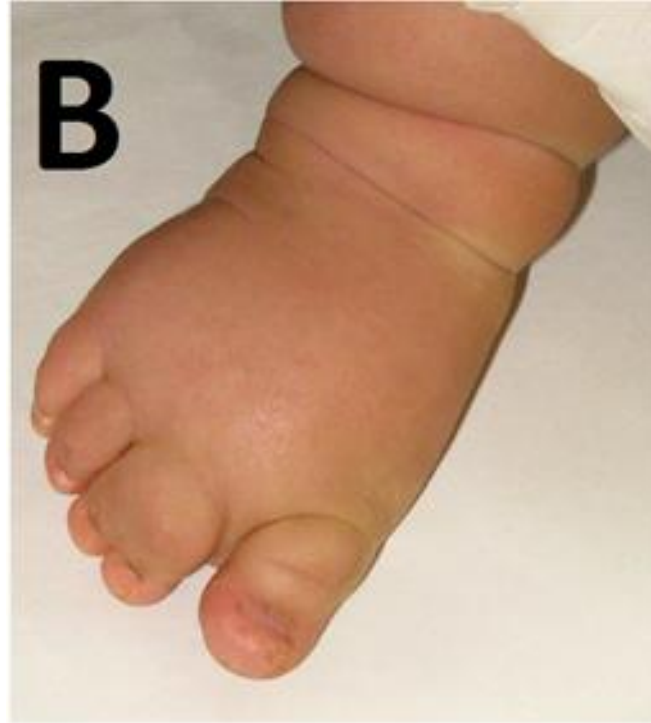
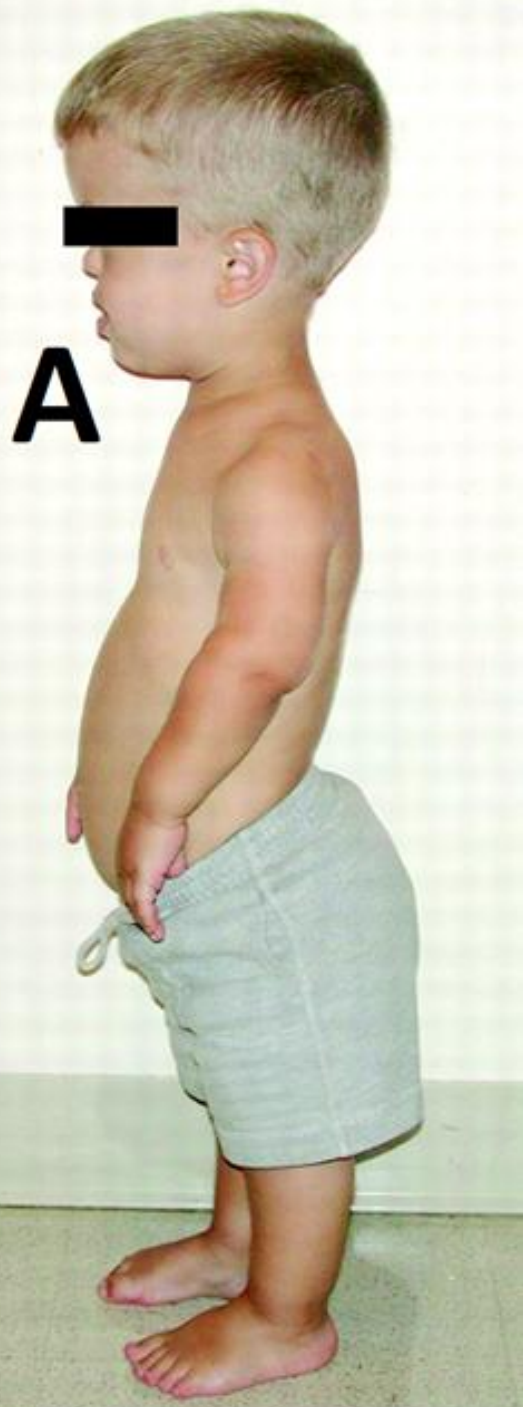


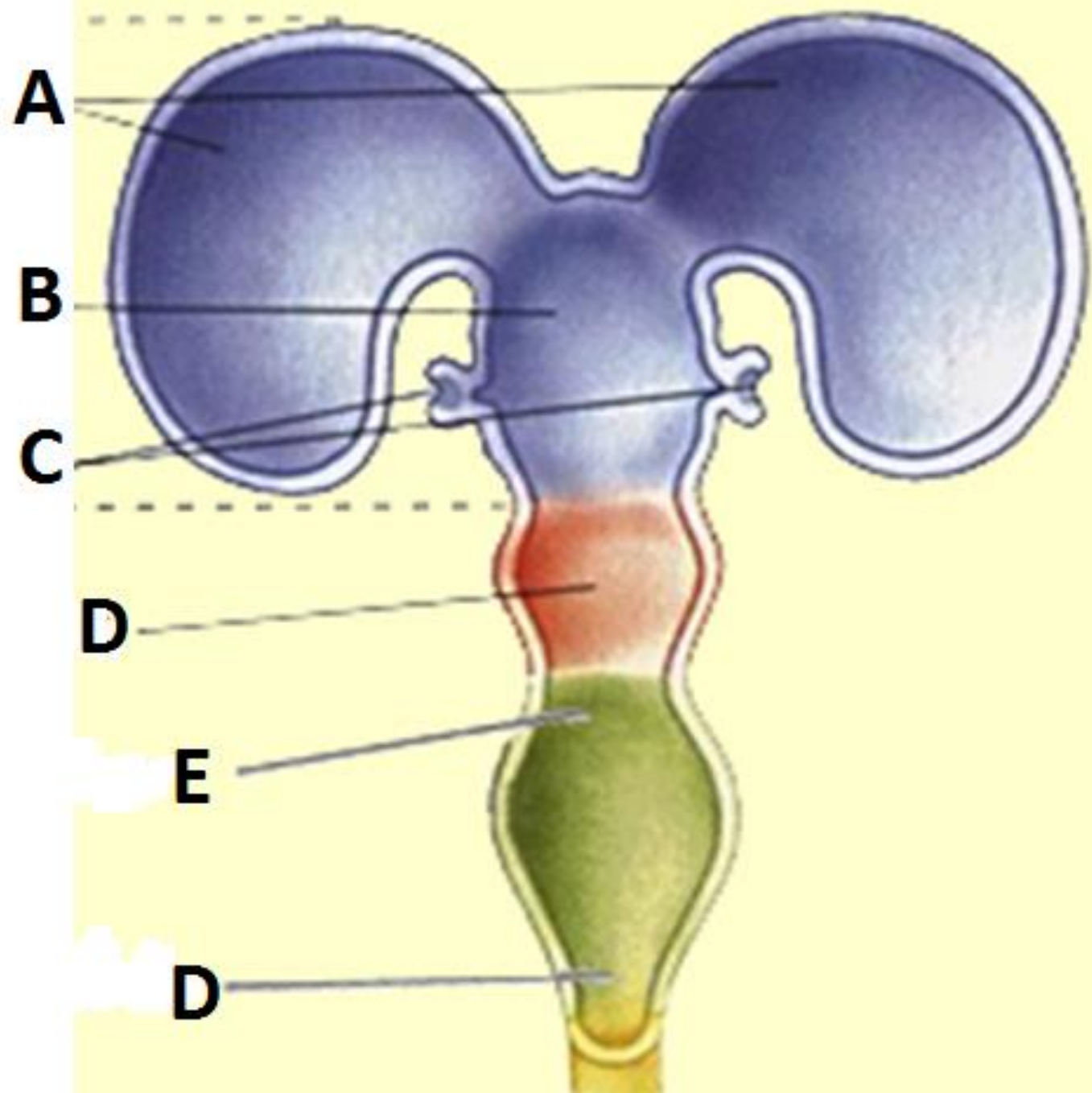
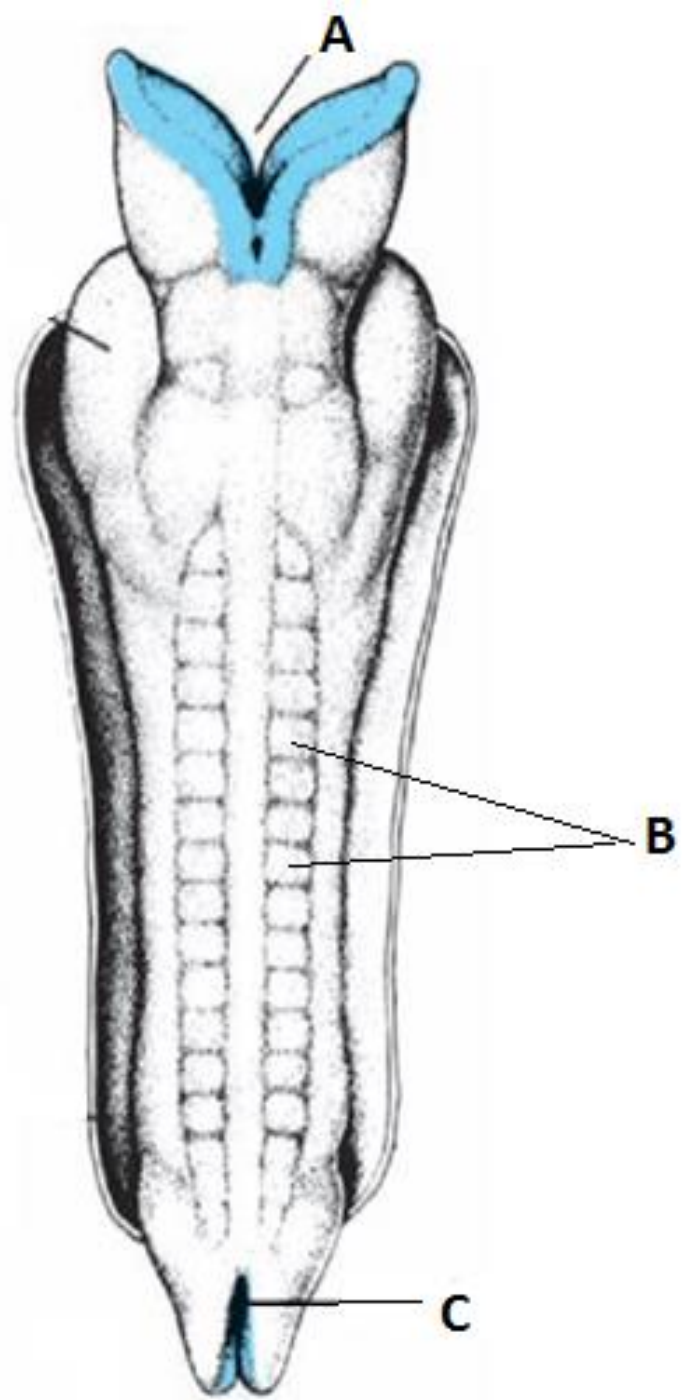


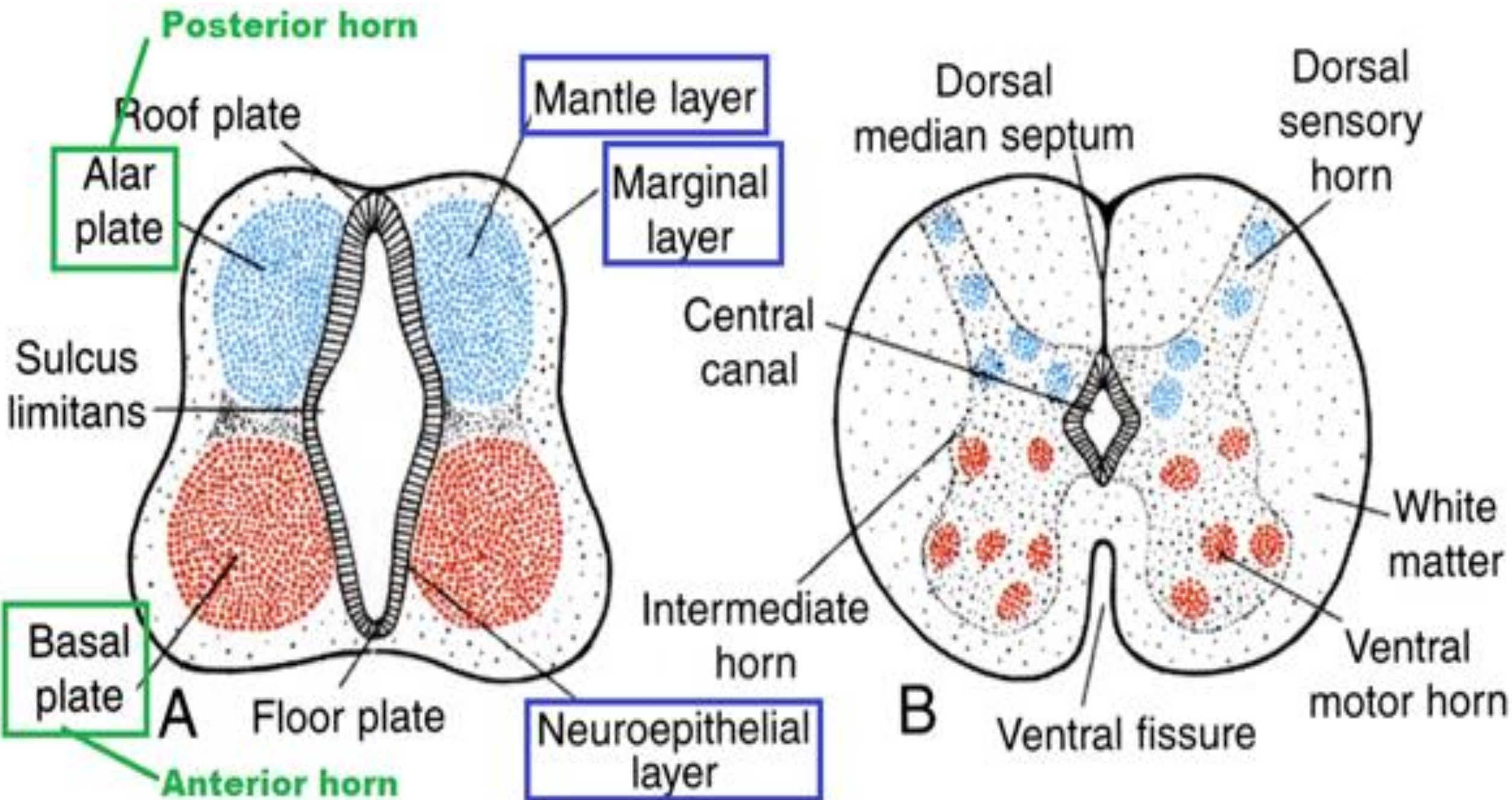












Forebrain

Midbrain

Hindbrain

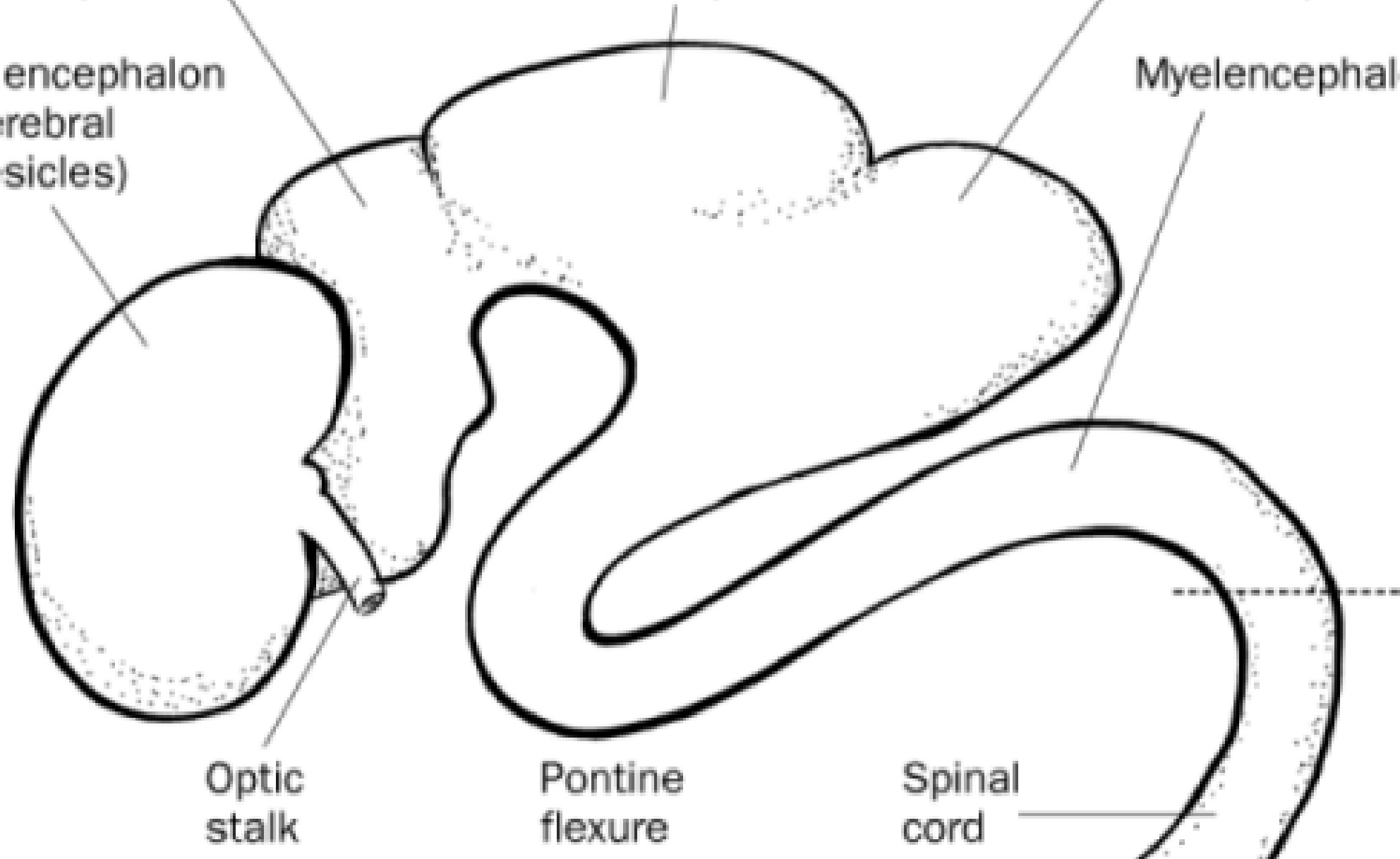
Diencephalon

Mesencephalon

Metencephalon

Telencephalon
(cerebral vesicles)

Myelencephalon



Optic stalk

Pontine flexure

Spinal cord

