

# General

## Paediatric Surgery

- Oesophageal atresia
- Hypertrophic pyloric stenosis - OHCM 494
- Obstructive jaundice
- Intestinal obstruction - Intussusceptions; Hirschsprung's disease
- Omphaloceles
- ARMs
- Ambiguous genitalia
- UTO - PUV & VUR

## Cardiovascular Surgery

- Chest injury
- Lung tumours - OHCM 182
- Venous hypertension
  - Pulmonary Embolism - OHCM 194
  - Portal Hypertension
  - Varicose veins - OHCM 528
- Rheumatic fever
- Cardiology
- Valvular heart disease - OHCM 146-151
- TOF
- VSD - OHCM 160
- Pericardial diseases - OHCM 158

## Neurosurgery

- Head Injury
- Hydrocephalus
- The Spine
- SOLs - OHCM 386
- Tracheostomy

## Plastic Surgery

- Burns
- Wound management
- Skin malignancies - OHCM 430
- KS - HIV

## General Surgery

- Pre- & Post op
- Liver tumours - OHCM 242
- Carcinoma of the pancreas - OHCM 248
- Hydatid disease - OHCM 616
- Oncology - OHCM + Pg 704
- Practical procedures - OHCM
- Emergencies - OHCM

# Head Injury

## Anatomy

- **Extent** - From the **root of the nose** to the **base of the skull posteriorly**; **3-5Kg**

## Scalp

- Skin
- Connective tissue
- Aponeurosis or galeal aponeurotica
- Loose areolar tissue - Site for **subgaleal haematomas & scalping injuries** - Bleed a lot cause the vessel *intima* has more elastic tissue thus they *retract* on trauma keeping the edges of the vessel apart.
- Pericranium

## Skull

- a) The **Calvarium** - Layers;
- Outer table
  - Diploe
  - Inner table

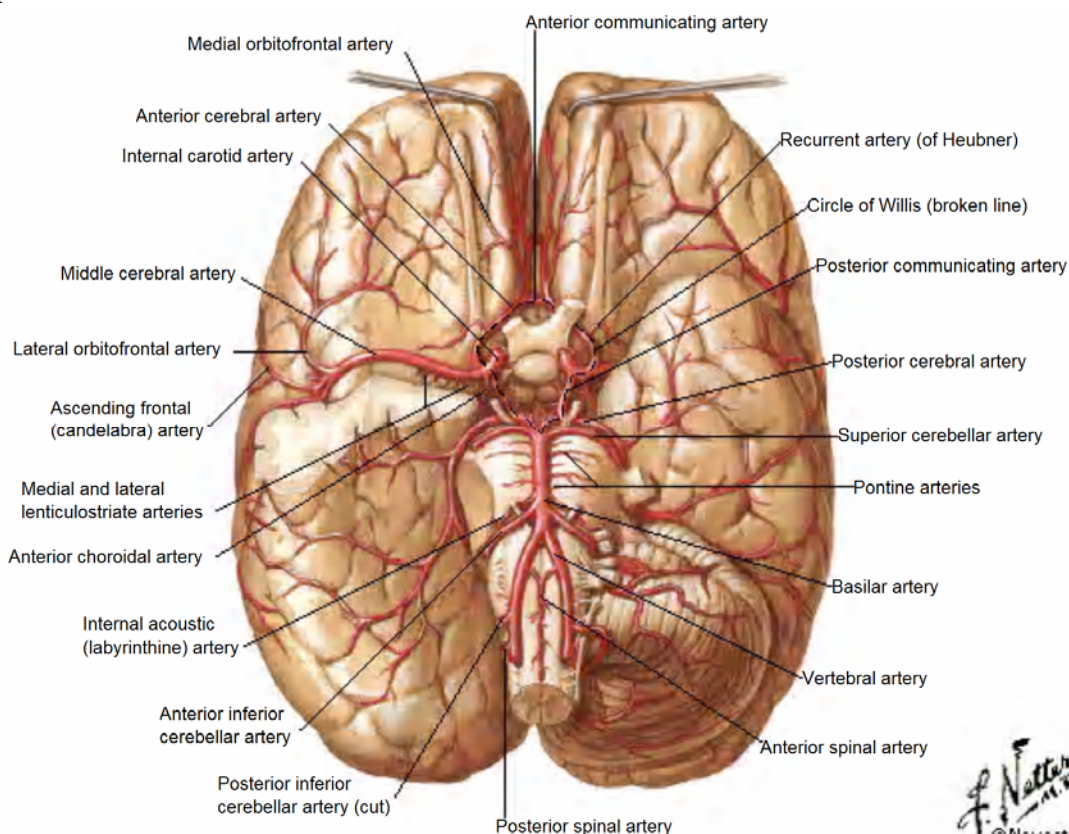
It is especially **thin** in the **temporal** regions, but is cushioned here by the **temporalis muscle**.

- b) The **base of the skull** is **irregular**, & this may contribute to injury of the **frontal & temporal lobes** as the brain moves within the skull during acceleration & deceleration.

## Meninges

- Lacerations of **meningeal arteries** located between the dura & the internal surface of the skull (**epidural space**) may result in an **arterial epidural haematoma**; the most commonly injured meningeal vessel is the **middle meningeal artery**, which is located **over the temporal fossa**.
- **Dural venous sinuses** can bleed massively if injured - **DO NOT** ligate the **superior sagittal sinus** *except* if collaterals have formed when the **anterior** 1/3 may be ligated when absolutely necessary with relatively little risk.
- In head injury, the veins that travel from the **surface of the brain** to the **superior sagittal sinus** in the midline (**bridging veins**) may tear, leading to the formation of a **subdural haematoma**.
- Haemorrhage may also occur in the **subarachnoid space** though is **more commonly associated** with a **ruptured aneurysm** but **head injury** is the **more frequent cause**.

## Brain



- a) Cerebrum;
- **Left hemisphere** - Language centres (*dominant hemisphere in approximately all right handed people & 85% left-handed people*)
  - **Frontal lobe** - Behaviour & Emotions, *motor* function & on the dominant side, *expression* of speech (*motor speech areas*)
  - **Parietal lobe** - *Sensory* function & spatial orientation
  - **Temporal lobe** - regulates certain *memory* functions
  - **Occipital lobe** - *Vision*
- b) Brainstem;
- Midbrain & upper pons - *Reticular activating system* - responsible for the state of alertness
  - Medulla - *Cardio-respiratory centres*
- c) Cerebellum - *Coordination & balance*

**Tentorium** - The tentorium cerebelli divides the head into the **supratentorial compartment** (*anterior & middle fossae*) & the **infratentorial compartment** (*posterior fossa*) with the **midbrain** through the **tentorial incisura** connecting the **cerebral hemispheres** to the rest of the **brainstem**.

The **medial** part of the **temporal lobe** - the **uncus** - usually herniates through the tentorial notch - **Uncal herniation** - causing compression of the;

- midbrain reticular activating system** causing *depressed level of consciousness*
- oculomotor nerve** (**Parasympathetic fibres** that are **pupillary constrictors** lie on the **surface of CN III**) that runs along the edge of the tentorium causing **Ipsilateral pupillary dilatation** (due to unopposed sympathetic activity) and **loss of the pupillary light reflex**
- corticospinal (pyramidal) tract** in the midbrain causing **Contralateral hemiplegia**

Thus, an **intracranial haematoma** is more likely to be **on the side of the dilated pupil**, but infrequently (**25%**), mass lesions may push the **opposite side** of the midbrain against the tentorial edge, resulting in **ipsilateral hemiplegia** - **Kernohan's notch syndrome**

With further compression of **CN III**, a full **oculomotor paralysis** develops, causing the eye to deviate **inferiorly & laterally** ("down & out")

## CSF

- **Intracranial Pressure** - Normal ~ **0-10mmHg (5-18cmH<sub>2</sub>O)**
- **Monro-Kellie Doctrine** - "*The total volume of intracranial contents must remain constant*"  
The cranial cavity normally contains a **brain** weighing approximately **1400gm**, **75mL of blood**, and **75mL of CSF**. Addition of a mass e.g. a haematoma results in the squeezing out of an equal volume of CSF & venous blood to maintain the ICP. However, when this compensatory mechanism is exhausted, there is an exponential increase in ICP for even a small additional increase in the volume of the haematoma
- **Cerebral Perfusion Pressure** =  $MAP - ICP = \sim \geq 70\text{mmHg}$   
\*\* Mean Arterial Pressure (MAP) =  $DBP + \frac{1}{3} \text{ Pulse pressure}$   
\*\* **Pulse pressure** =  $SBP - DBP = \sim 50\text{mmHg}$  ( $< \sim \frac{1}{2} \text{ SBP}$ )
- **Cerebral Blood Flow** - ~ **50mL/100gm of brain/minute**;  $< 5\text{mL}/100\text{gm}$  of brain/minute - there is **cell death or irreversible damage**.
- Autoregulation maintains CPP between **50-160mmHg**.  $< 50\text{mmHg}$ , the CBF declines steeply, &  $> 160\text{mmHg}$ , there is passive dilatation of the cerebral vessels & an increase in CBF

## Pathophysiology of Head Injury

The initial trauma causes **Hypoxia** of the brain tissues by **Ischemia or Anoxia** →  $\uparrow \text{PCO}_2$  → Vasodilatation →  $\uparrow$  Cerebral blood flow →  $\uparrow$  ICP → Pressure & narrowing of the blood vessels → **Hypoxia**

# Classification of Head Injuries

## a) Mechanism of injury;

- Blunt;
  - i) High velocity e.g. Automobile collision
  - ii) Low velocity e.g. fall, assault
- Penetrating;
  - i) Gunshot wounds
  - ii) Other penetrating injuries

## b) Severity;

- Mild - GCS score **13-15**
- Moderate - GCS score **9-12**
- Severe (**Coma**) - GCS score **3-8**

## c) Morphology;

- Skull fractures;
  - i) Vault;
    - \* Open / Closed
    - \* Linear / Stellate
    - \* Depressed / Non-depressed
  - ii) Basilar;
    - \* ± CSF leak
    - \* ± CN VII palsy
- Intracranial lesions;
  - i) Focal (**Haematomas**);
    - \* Epidural haematoma
    - \* Subdural haematoma
    - \* Intracerebral haematoma (**contusions**) - Bruising of the brain best seen on *CT scan*; comes to the surface & *recovers in 1-2wks*
  - ii) Diffuse (**Parenchymal**);
    - \* Mild concussion
    - \* Classic concussion
    - \* Diffuse axonal injury

## d) 1° or 2°

a) **1° Brain damage** - *Initial trauma to the brain parenchyma - Can't do much about it.*

b) **2° Effects/Complications** - *result after initial (1°) head injury*

- Haemorrhage ± Intracranial haematomas
- Hypoxic ischemia
- Infections especially with penetrating injuries
- Cerebral oedema
- Epilepsy
- Hydrocephalus;
  - Early e.g. *after ventricular haemorrhage*
  - Late e.g. *after SAH*
- Pneumocephalus

## O/E

Signs of basilar fractures;

- i) Periorbital ecchymosis (**raccoon eyes/panda sign**)
- ii) Retroauricular ecchymosis (**Battles's sign**)
- iii) CSF leaks - nose (**rhinorrhoea**) or ear (**otorrhoea**) -

**CSF rhinorrhea** contains **glucose** while nasal mucus does not

**Halo test:** put a drop of bloody nasal discharge on *filter paper*. If it contains both CSF and blood, there will be **two rings**; a **central ring of blood** followed by a **paler outer ring of CSF** - **double-halo sign**.

- iv) CN VII palsy
- v) Subconjunctival haemorrhage - *Cannot see posterior limit of bleed (DDx - corneal bleeds)*
- vi) Blood behind the ear drum (haemato-tympanum)

## Subdural & Epidural haematomas - OHCM - Pg 366

Diffuse injuries - **Most common type of head injury**;

- **Mild concussion** - *Consciousness is preserved* but there is a noticeable degree of temporary neurologic dysfunction - **Confusion & disorientation without amnesia** (loss of memory)



dysfunction - ***Confusion & disorientation without amnesia*** (loss of memory)

- **Classic concussion** - Injury that results in a ***LOC ( $\leq 6$ hrs) & amnesia*** of the events relating to the injury; some patients may have more long-lasting neurologic deficits including, *memory difficulties, dizziness, nausea, anosmia & depression* - ***Post-concussion syndrome***
- **Diffuse axonal injury** - Used to define ***prolonged post-traumatic coma*** that is ***NOT due to a mass lesion or ischemic results.***

# Management

## Objectives

- Adequate oxygenation
- Maintenance of sufficient blood pressure to perfuse the brain & to avoid 2° brain damage

**1° survey & resuscitation** - Airway with cervical spine control, **B**reathing, **C**irculation & haemorrhage control, Disability & Exposure

- \* Immobilize & Stabilize the cervical spine
- \* Perform a mini-neurologic exam - **AVPU or GCS score** (with particular emphasis on the motor response) & **Pupillary reactions**

Pupil Size	Light Response	Interpretation
Unilaterally dilated	Sluggish or fixed	CN III compression 2° to tentorial herniation
Unilaterally dilated or Equal	Cross-reactive (Marcus-Gunn)	Optic nerve injury
Bilaterally dilated	Sluggish or fixed	Inadequate brain perfusion. Bilateral CN III palsy
Unilaterally constricted	Preserved	Injured sympathetic pathway e.g. carotid sheath injury
Bilaterally constricted	May be difficult to determine	Drugs (Opiates); Metabolic encephalopathy; Pontine lesion

## 2° survey;

- Presence & type of associated injuries
- Perform a mini-neurological examination & determine GCS score
- Examine cervical spine, immobilize & X-Ray

**AMPLE** (Allergies, Medications, Past medical history, Last meal, Events preceding present condition) **history;**

- Age of patient & the mechanism & time of injury
- Loss of consciousness & amnesia
- Headache & Seizures

## Ix

- FHG, ESR; U/E/C
- Blood-alcohol level
- Urine toxic screen
- *Lateral & Open mouth* C-spine X-rays - *If there is any pain/tenderness or unconscious*
- Skull x-ray - look for;
  - \* Linear or depressed skull fractures
  - \* Facial fractures
  - \* Midline position of the pineal gland (*if calcified*)
  - \* Air-fluid levels in the sinuses
  - \* Pneumocephalus
  - \* Foreign bodies
- CT scan - **Brain** or **'Direct stick' carotid angiogram**
  - \* Signs of ↑ICP;
    - Flattening of gyri
    - Widening of the sulci
    - Decreased ventricular size
- CXR
- Diagnostic peritoneal lavage (DPL)/CT abdomen

## Indications for Monitored Observation or Hospital Admission

- **Moderate to severe** headache
- History of LOC
- Deteriorating LOC
- Amnesia
- **All** penetrating head injuries
- Skull fractures
- CSF leak (*Rhinorrhoea &/or Otorrhoea*)
- Significant alcohol/drug intoxication
- Significant associated injuries
- Abnormal CT scan
- No CT scanner available
- No reliable companion at home
- Unable to return promptly

## Conservative measures;

- Nurse the patient with the **head elevated at 30°**
- 100% O<sub>2</sub>
- Intubate & ventilate
- Catheterize

## Medical therapy;

- **Non-narcotic analgesics or codeine**
- **Antibiotic cover**
- **IVF** - NS or Ringer's lactate
- **Tetanus toxoid** if there is any associated open wound
- **Anticonvulsants - Phenytoin** reduces the incidence of seizures in the **1<sup>st</sup> wk** of injury. Also *Phenobarbital, Diazepam or Lorazepam*. Indications;
  - \* Early seizures occurring within the 1<sup>st</sup> wk
  - \* An intracranial haematoma
  - \* Depressed skull fracture

## Reducing ICP

- **Hyperventilation** - Acts by reducing PCO<sub>2</sub> & causing cerebral *vasoconstriction* reducing intracranial volume - Keep the PCO<sub>2</sub> at **≥25-30mmHg (3.3-4KPa)** in the presence of **↑ICP**.
- **Mannitol** - 1gm/Kg 20% IV to reduce ICP; Indications;
  - \* A comatose patient who initially has normal, reactive pupils, but then develops *pupillary dilatation ± hemiparesis*
  - \* *Bilateral dilated & non-reactive pupils* which are **NOT** hypotensive
- **Furosemide** - Used in conjunction with mannitol in the treatment of **↑ICP**.  
**\*\*Steroids** are only used in the management of **chronic** **↑ICP** when oedema is **vasogenic**. In head trauma, the oedema is **cytotoxic**.
- **Barbiturates** - Effective in reducing intracranial pressure **refractory** to other measures. *C/I: Causes hypotension thus not indicated in the acute injury resuscitative phase or hypotension.*

## Surgical Management;

- Open fractures
- Elevate Depressed skull fractures if;
  - \* **>50% (2/3)** the thickness of the skull
  - \* Over motor area of the brain
  - \* Haematoma
  - \* Neurological deficit - *Convulsions, Patient not improving***\*\* DO NOT elevate if over the Sagittal sinus.**
- Rapidly expanding intracranial haematoma - **Emergency Burr holes or Craniotomy** on the side of the **larger pupil** in comatose patients with **decerebrate or decorticate posturing** that does **not** respond to *endotracheal intubation, moderate hyperventilation & Mannitol*. Always put a **hitch stitch** to close off the **epidural space**.

## Warning discharge instructions;

Return immediately if;

- Severe headaches
- Nausea or vomiting
- Drowsiness or increasing difficulty in awakening patient (*Awaken patient every 2hrs during period of sleep*)
- Confusion or strange behaviour
- Convulsions or fits
- One pupil much larger than the other; peculiar movements of the eyes, double vision, or other visual disturbances
- A very slow or very rapid pulse, or an unusual breathing pattern.
- Weakness or loss of feeling in the arm or leg
- Bleeding or watery drainage from the nose or ear
- **No** alcoholic beverages for at least **3 days** after your injury
- **Do not** take any *sedatives or any pain relievers stronger than acetaminophen*, at least for the first **24hrs**.  
**Do not use aspirin-containing medicines.**

## Complications of head injury

- Post-traumatic epilepsy
- Chronic subdural haemorrhage
- CSF fistula
- Post-concussional symptoms e.g. *Transient LOC, Bradycardia, Hypertension*
- Cumulative brain damage (*Punch-drunk syndrome*)
- Neurological & neuropsychological deficits e.g. *Parkinsonism, Dementia*
- Neuroendocrine & metabolic disturbances e.g. *Diabetes insipidus*
- Normal pressure hydrocephalus

OHCM 814 - 817

# Hydrocephalus

## Definition

Hydrocephalus is a **diverse group of conditions**, which result from;

- impaired **circulation** of CSF
- Impaired **absorption** of CSF
- in the rare circumstance, from **increased production** by a **choroid plexus papilloma**

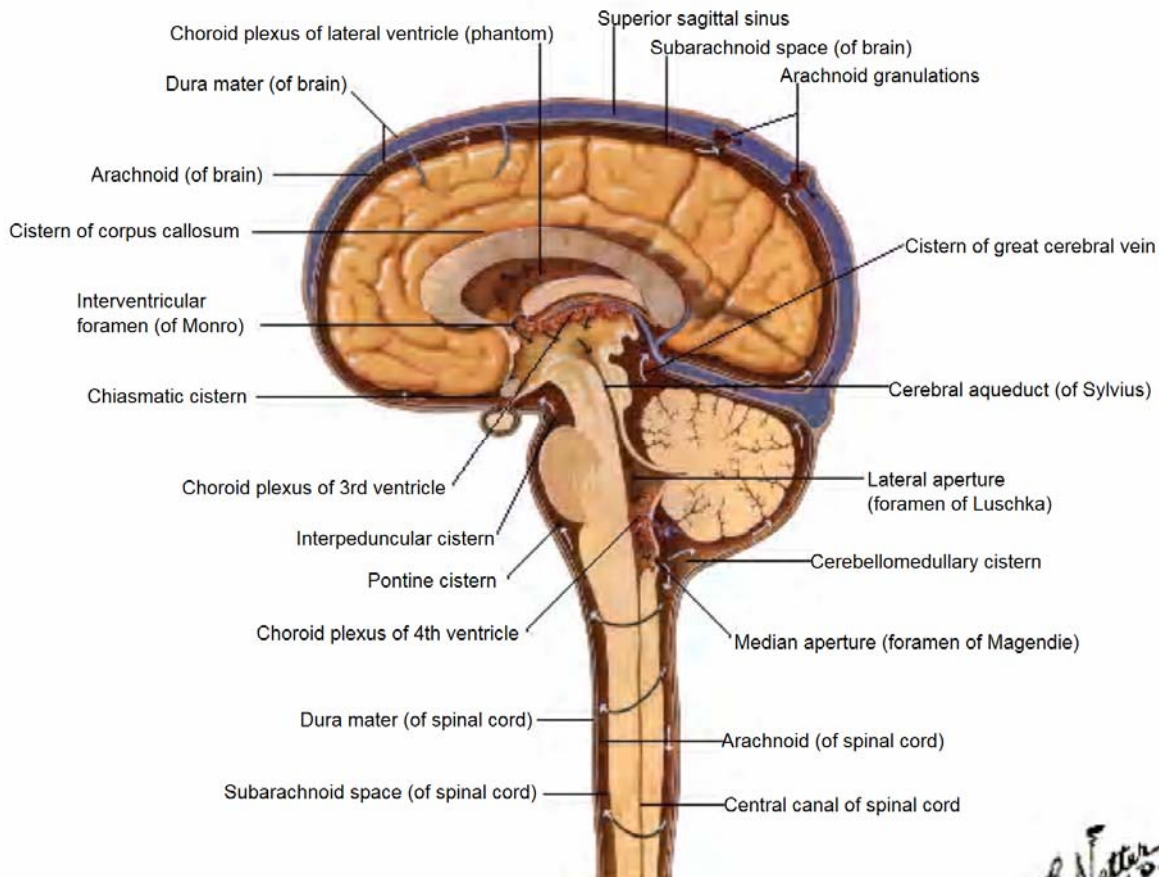
## Pathophysiology

CSF is produced in the **lateral ventricle choroid plexus** at **30mL/hr (20mL/hr in infants)** → Foramen of Munro → 3<sup>rd</sup> Ventricle → Aqueduct of Sylvius → 4<sup>th</sup> Ventricle →

- **Paired lateral foramina of Luschka** → into the **Subarachnoid basal cisterns** posteriorly over the cerebellum and cerebral cortex, and anteriorly through the cistern system and over the convexities of the cerebral hemispheres.
- **Midline foramen of Magendie** → **Subarachnoid space of the spinal cord**

→ Subarachnoid space → **Reabsorbed into the venous circulation** through the **arachnoid granulations** that project into the **superior sagittal sinus**

- \* **25% CSF** is produced from the **ependymal lining of the ventricles**.
- \* Infants - **50mls**
- \* Adults - **125-150mls**



## Types

a) Obstructive / Non-communicating hydrocephalus - Hydrocephalus resulting from **obstruction within the ventricular system**;

i) An **abnormality of the Aqueduct**:

- Stenosis;
  - \* Congenital - *inherited as a sex-linked recessive trait*
  - \* Neurofibromatosis
- Gliosis;
  - \* Intrauterine viral infections
  - \* SAH in a premature infant
  - \* Neonatal meningitis
  - \* Mumps meningoencephalitis

ii) **A lesion in the fourth ventricle**:

- **Chiari malformation**;

**Type II** is characterized by **progressive hydrocephalus** and a **myelomeningocele** which results in *elongation of the fourth ventricle and kinking of the brain stem*, with displacement of the **inferior vermis, pons, and medulla** into the **cervical canal**. Produce symptoms during **infancy** consisting of *stridor, weak cry, and apnea*, which may be relieved by *shunting* or by *posterior fossa decompression*.

- \* **Type I** typically produces symptoms during *adolescence or adult life* and is usually **not associated with hydrocephalus**. These patients complain of *recurrent headache, neck pain, urinary frequency, and progressive lower extremity spasticity*. The deformity consists of *tonsillar herniation*.

- **Dandy-Walker syndrome** - consists of a **cystic expansion of the fourth ventricle** in the posterior fossa, which results from a **developmental failure of the roof of the 4<sup>th</sup> ventricle** during embryogenesis
- **Posterior fossa brain tumors**

b) Non-obstructive / Communicating hydrocephalus - Hydrocephalus resulting from **obliteration of the subarachnoid cisterns or malfunction of the arachnoid villi**;

- **Infections**;

- \* **Intrauterine infections** may destroy the *CSF pathways*.
- \* **Pneumococcal and TB meningitis** have a propensity to produce a thick, tenacious exudate that obstructs the basal cisterns

- **SAH** - Blood in the subarachnoid spaces may cause obliteration of the cisterns or arachnoid villi, and obstruction of CSF flow.
- **Leukemic infiltrates** may seed the subarachnoid space and produce communicating hydrocephalus.

c) Normal-Pressure Hydrocephalus

Cerebral **ventricular dilation** with **normal lumbar CSF pressure (5-18cmH<sub>2</sub>O)**

**Aetiology** - See Non-Obstructive or communicating hydrocephalus above

**C/P - Triad**;

- i) **Dementia** - rare cause of dementia in the elderly
- ii) **Apraxia of gait** - *initiation of gait is hesitant* - described as a "**slipping clutch**" or "**feet stuck to the floor**" gait - and walking eventually occurs. *Motor weakness and staggering are absent*
- iii) **Urinary incontinence**

**Ix**;

- **CSF pressure is normal**
- CT/MRI - the **ventricles are dilated**

**Mx**;

- **Shunting** - Brief improvement after removing about **50mL of CSF** indicates a better prognosis with shunting but the longer the disease has been present, the less likely shunting will be curative.

d) Ex Vacuo Hydrocephalus - **Enlarged ventricles resulting from a loss of brain tissue**

## C/P

### ↑ICP;

- Headache
- Nausea & vomiting
- Drowsiness
- Papilloedema

### Infants;

- Failure to thrive
- **Accelerated rate of enlargement of the head** is the *most prominent sign*
  - **Scalp veins are dilated**
  - **The forehead is broad**
  - **Anterior fontanel is wide open and bulging**
  - Percussion of the skull may produce a "**cracked-pot**" or **Macewen sign**, indicating *separation of the sutures*
  - A *foreshortened occiput* suggests the **Chiari malformation**, and a *prominent occiput* suggests the **Dandy-Walker malformation**.
- Dilatation of the **3<sup>rd</sup> ventricle** → dilatation of the **suprapineal recess** which then impinges on the **tectum** → **eyes** deviate downward - "**setting-sun**" eye sign
- In the older child, the cranial sutures are partially closed so that the signs of hydrocephalus may be more subtle. **Irritability, lethargy, poor appetite, and vomiting** are common to both age groups, and **headache** is a prominent symptom in the older age patient.

## DDx

*The head may appear enlarged secondary to a thickened cranium resulting from;*

- Familial
- Chronic anemia
- Haemoglobinopathies e.g. *SCD, Thalassaemia*
- Rickets
- Achondroplasia
- Osteogenesis imperfecta
- Epiphyseal dysplasia.

## Ix

- The **occipitofrontal head circumference** is recorded and compared with previous measurements.
- **Transillumination** of the skull is **positive** with massive dilatation of the ventricular system or in the Dandy-Walker syndrome.
- **Papilloedema** is observed in older children but is **rarely present in infants** because the cranial sutures separate as a result of the increased pressure.
- **Skull X-ray** - typically show;
  - *Separation of the sutures*
  - *Erosion of the posterior clinoids* in the older child
  - *Increase in convolitional markings ("**beaten-silver appearance**")* with longstanding increased intracranial pressure.

## Mx

- **Medical** - when patients have slowly progressive hydrocephalus with few symptoms or signs, and when the condition of the patient has prohibited surgery.
  - **Surgical**;
    - Treat 1<sup>o</sup> cause
    - Cannulation of the aqueduct of sylvius
    - 3<sup>rd</sup> Ventriculostomy
    - **Ventriculoperitoneal shunt** - A shunt is placed from the **lateral ventricle to the peritoneum**
- Complications;
- Bacterial infection, usually due to **Staphylococcus epidermidis**
  - Hemorrhage e.g. Chronic subdural haematomas
  - Shunt malfunction & over drainage resulting in low pressure symptoms

# Chest Injury

## Types

- Mechanical
- Thermal
- Chemical

## Classification;

- Penetrating injuries
- Non-penetrating injuries;
  - Blunt trauma
  - Crush injuries
- Inhalational
- Aspiration of foreign bodies

### a) Penetrating injury;

- A defect in the chest wall through *to the pleura* is a '**sucking wound**'. The underlying lung collapses & air moves in & out of the thorax with each breath. Emergency treatment involves **sealing the wound & intercostal drainage**.
- **Bullet wounds** create a **cavitating defect** in the tissues that they pass through. *Bullets lodged in the lung do not need to be removed if they are not causing any problems.*
- **Cardiac tamponade** can occur from a penetrating wound of the heart. S/S - *Low BP, tachycardia, a high CVP, pulsus paradoxicus & faint heart sound.* Thoracotomy is indicated after emergency treatment.

### b) Non-penetrating injuries;

#### • Rib fractures

Require **sufficient analgesia (oral or intercostal nerve blockade)** to encourage a normal respiratory pattern & effective coughing.

Early ambulation with vigorous physiotherapy (& oral antibiotics if necessary) is encouraged.

- **Flail chest** - This occurs when several adjacent ribs are **fractured in 2 places** either on one side of the chest or either side of the sternum usually following **crush injuries**. The **flail segment** moves **paradoxically**, i.e. *Inwards during inspiration & outwards during expiration*, thereby reducing effective gas exchange.
  - \* In the absence of any other injuries &, if the segment is **small & not embarrassing respiration**, the patient may be nursed in a **HDU with regular BGAs & good analgesia** until the flail segment stabilises.
  - \* In the more **severe case, endotracheal intubation** is required with **positive pressure ventilation** for up to **3wks**, until the fracture becomes less mobile
- **Fractures of the lower ribs** (especially if below the **6<sup>th</sup> ICS**) may involve underlying abdominal viscera (*spleen on the left & liver on the right*)
- **Sternal fracture** may occur during *closed cardiac massage*
- **Intercostal arterial** bleeding may still be severe, resulting in **haemothorax**.
- If the **visceral pleura** is breached (*most commonly by a rib fracture*), **pneumothorax** follows. Generation of **positive pressure** in the airways by **coughing straining, groaning or positive-pressure ventilation** will result in **tension pneumothorax**. *Conservative management* is indicated if **<15%** pneumothorax &/or **<2cm** rim of air on CXR or *no planned positive pressure ventilation*. **Otherwise, insert a chest tube.**

The pleural space may also fill with blood as a result of injury anywhere in its vicinity - **Haemothorax** - Drainage is essential because re-expansion of the lacerated lung compresses the torn vessels & reduces further blood loss. It will also allow the mediastinal structures to return to the midline & relieve compression of the contralateral lung.

Continuing blood loss **>200mL/h** may require urgent thoracotomy within the first few hours.
- **Lung contusion** - This usually occurs following **crush injuries** leading to **pulmonary oedema** within 24hrs. Lacerations with persistent air leak may require exploration by thoracotomy. It is important to prevent infection of the underlying lung by *early mobilisation, prophylactic antibiotics, suction drainage & physiotherapy*.
- **Injury to major airways** presents with a combination of **surgical emphysema, haemoptysis & pneumothorax**. **Traumatic asphyxia syndrome** is caused by *constrictive forces applied over a wide area for as little as 2-5mins* leading to **retrograde venous flow** from the right side of the heart. Treatment is exploration & repair if possible. Resection of the lung *should be avoided* as a surprising degree of recovery may occur.
- The mechanism of **diaphragmatic rupture** is *high-speed blunt abdominal trauma with a closed glottis*. The sudden rise of intra-abdominal pressure breaches the weakest part of the abdominal wall, *namely the diaphragm*. This occurs more commonly on the **left hemidiaphragm** (*the right is protected by the liver*)



- **Cardiac injury;**

- **Myocardial contusion** - This must be suspected if the **sternum is fractured**. Myocardial damage after trauma will give an *ECG pattern* similar to **MI** & *enzyme changes may occur*. In severe trauma, there may be arrhythmias & signs of heart failure. *Conservative management & monitoring*.
- **Chamber rupture & valve blow-out** - Occurs if the ventricle is compressed just before systole at the point of maximal diastolic filling. Likely to be **fatal** & those who survive have an *atrial rupture & mitral & tricuspid valve rupture*.
- **Aorta (Aortic transection)** - Usually **fatal** following a major deceleration injury (*RTA or a fall from a height*). The aorta is relatively **fixed** at the site of the **ligamentum arteriosum**, just distal to the left subclavian artery, & from down is tethered to the vertebral column by **intercostal arteries & mediastinal pleura**. The shear forces from a sudden impact disrupt the *intima & media*, resulting in retraction.

S/S - Interscapular pain, a murmur, hoarseness & *radiofemoral delay* of the arterial pulse.

A CXR showing **widening of the mediastinum**, is very suspicious. Also, Aortogram.

Mx - *Left thoracotomy through the 4<sup>th</sup> ICS*

## Mx

- **History of trauma**

- **S/S**

- Pain on inspiration
- "Guarding" of the injury
- Haemoptysis - *2° to airway disruption*
- ± Cyanosis
- Shock - *Pale cold clammy skin, rapid pulse, rapid shallow breathing*
- Danger signs;
  - \* Respiratory rate >20/min & rising
  - \* Heart rate >100bpm
  - \* SBP <100mmHg
  - \* PaO<sub>2</sub> <9KPa on room air
  - \* PaCO<sub>2</sub> >8KPa
  - \* ↑ size of Pneumo/haemothorax or widening mediastinum on CXR

- **Definitive treatment;**

- i) 1° survey - Airway + C-spine control, **Breathing**, Circulation + haemorrhage control, **Disability & Exposure**  
Emergency conditions;

- \* Tension pneumothorax
- \* Cardiac tamponade

- ii) 2° survey;

- CXR - **Erect &/or Lateral decubitus**
- BGAs
- ECG

- iii) Indications for **insertion of an UWS intercostal chest tube drain;**

The intercostal drain is simply a conduit used to remove **air or fluid** (*blood, pus, effusion*) from the pleural cavity, thereby *preventing compression of the lung and allowing it to re-expand*.

- Any blunting of the costophrenic angle (Indicates >700mLs of fluid)
- >20% Pneumothorax or >2cm rim of air on CXR
- Tension pneumothorax
- Stable patient but due for surgery (*Intubated*)

**Underwater seal drains** - Components;

- a) **Chest tube** - A good chest tube;

- Transparent
- Flexible
- The last tube hole goes through the radiopaque line
- Graduated
- Has a radiopaque line in tube

- b) **Connecting tube**

- c) **Collecting container** below chest level & with a vent tube

- d) **One-way valve mechanism** - a *water seal or valve* to prevent the return of air or fluid encouraged by negative intrapleural pressure created by breathing in.

- e) ± **suction mechanism**

Types;

- Single Tube or Edwards bottle system
- 3 Bottle system with controlled suction

Principle;

- Because **air rises** and **liquid sinks**, the tip of a tube to drain **air** is traditionally placed in the **apex of the pleural space** and that for **liquid** at the **base posterolaterally** in the costophrenic angle. Although these relative positions are used in thoracic surgery where drains are placed accurately with the chest open, percutaneous drain insertion usually results in a single tube **sited towards the apex posteriorly**. The chest drain is joined to about **1.8m of connecting tubing** which allows the patient to turn and move and minimizes the chance that a deep breath could suck liquid back into the chest. The position of the bottle and underwater seal takes advantage of gravity by establishing the patient's pleural space as the area of higher pressure and the collecting bottle as the area of lower pressure. The non-patient end of the tubing is led **below the surface of sterile water** which serves to create a water seal and to establish a **closed system** by sealing off the open end of the tubing from the atmosphere. The positive pressure in the chest during **exhalation** can push air and liquid out of the pleural cavity. The air bubbles out through the water and out of the vent tube of the drainage bottle while liquid mixes with the water, raising its level. The length of **tube drain below the water surface** should be **short** so that the **resistance to air escape** is  $\leq 2-3 \text{ cmH}_2\text{O}$  pressure.

Complications;

- "Fell out"
- Advanced too far into the chest or not advanced far enough
- Excessive side leak
- Tube kinking
- Incorrect anatomical site

Mx;

- Antibiotic cover
- Inspect daily
- Remove in *expiration or a valsalva manoeuvre*

iv) **Indications for thoracotomy;**

- $\geq 1\text{L}$  drained at **insertion** of chest drain
- Continued brisk bleeding  $>100\text{ml}/15\text{min}$  or  $>200\text{ml}/\text{hr}$  for  $\geq 3\text{hrs}$
- Rupture of **bronchus, aorta, oesophagus, diaphragm**
- Cardiac tamponade
- Massive air leak
- High velocity injury
- Sharp object near vital structure
- Dirt debris in wound

Types of incisions;

- **Lateral** - Surgery of the *lung & diaphragm* - **commonest**
- *Median sternotomy* - Surgery of the *Pericardium, Heart, great vessels, thymus*
- Thoraco-abdominal incision
- Axillary incision - Cervical rib excision

Physiological effects of thoracotomy;

- $\downarrow$  VC, TLC, FRC (forced respiratory capacity) & RV- by *altering chest wall mechanics & reducing lung compliance*
- Ventilatory reserve & gas exchange is impaired by *small airway closure & V/Q mismatch*.
- Respiratory function may also be affected by;
  - Collapse of lung
  - Secretions
  - Chest wall splinting due to pain
  - IV fluid overload
  - $\downarrow$  cardiac function
  - 1° lung pathology

### Complications;

- Effusion (*Bleeding, Air, Chylothorax*)
- Nerve damage
- Subcutaneous emphysema
- Scar tissue formation

### Complications of chest injuries;

- Pneumonia 2° to atelectasis
- ARDS 2° to excessive trauma to the lung tissue
- Clotted haemothorax (*especially >48hrs*)
- Lung abscess
- Empyema thoracis
- Fistulae
- Osteomyelitis
- Early death after chest trauma are caused by;
  - Hypoxaemia
  - Hypovolaemia
  - Tamponade

### Additional Reading;

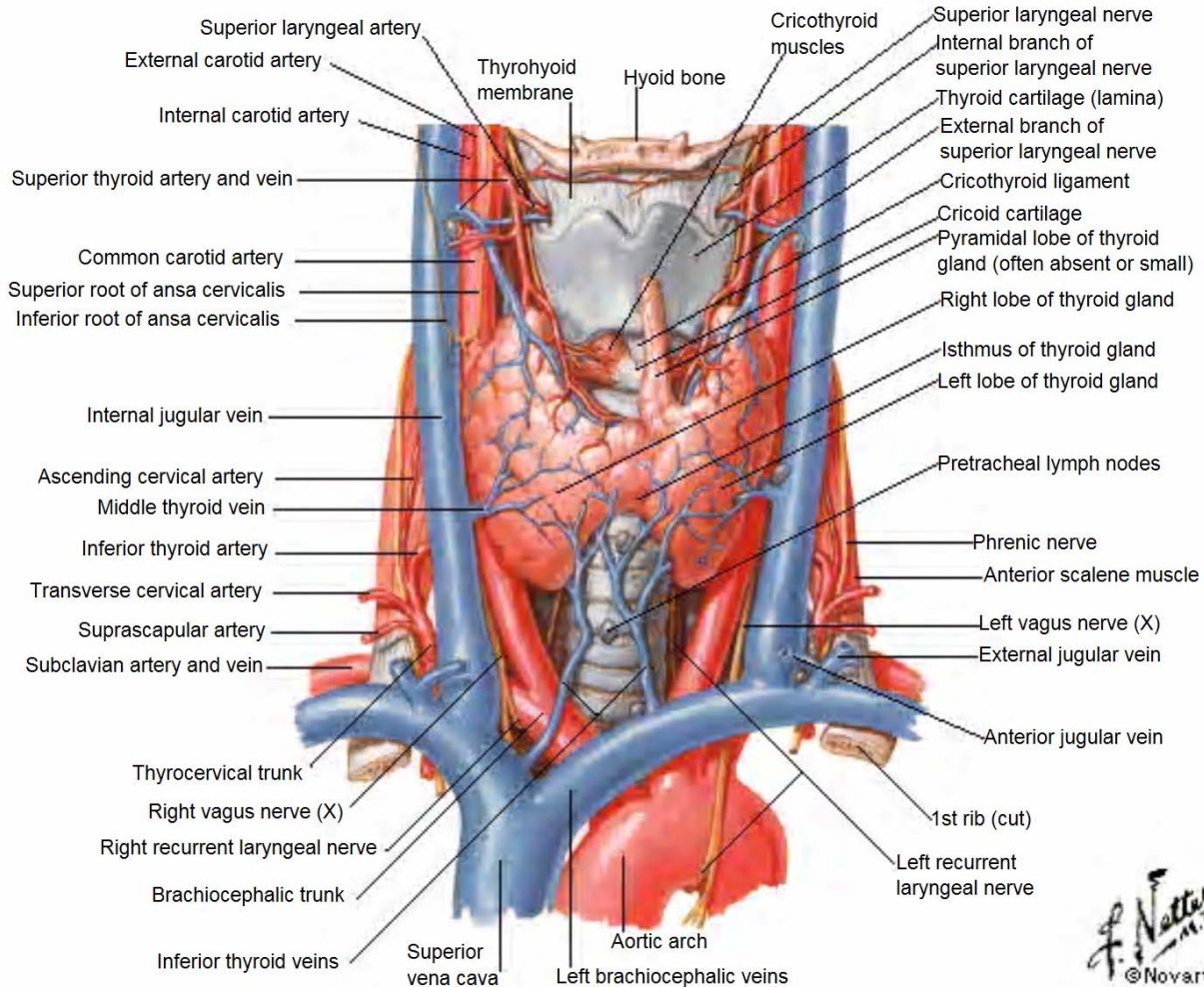
- Tension pneumothorax - OHCM PG 798
- Pleural Effusion - OHCM 196
- Empyema thoracis - OHCM 176
- Insertion of a UWS intercostal chest tube drain - OHCM PG 750
- Cardiac tamponade - OHCM PG 788

# The Thyroid

## Anatomy

er

### Thyroid Gland Anterior View



The normal gland weighs **20-25gm** & the functional unit is the **lobule**, supplied by a single arteriole & consisting of **24-40 follicles** lined with cuboidal epithelium & contains **colloid** in which **thyroglobulin** is stored.

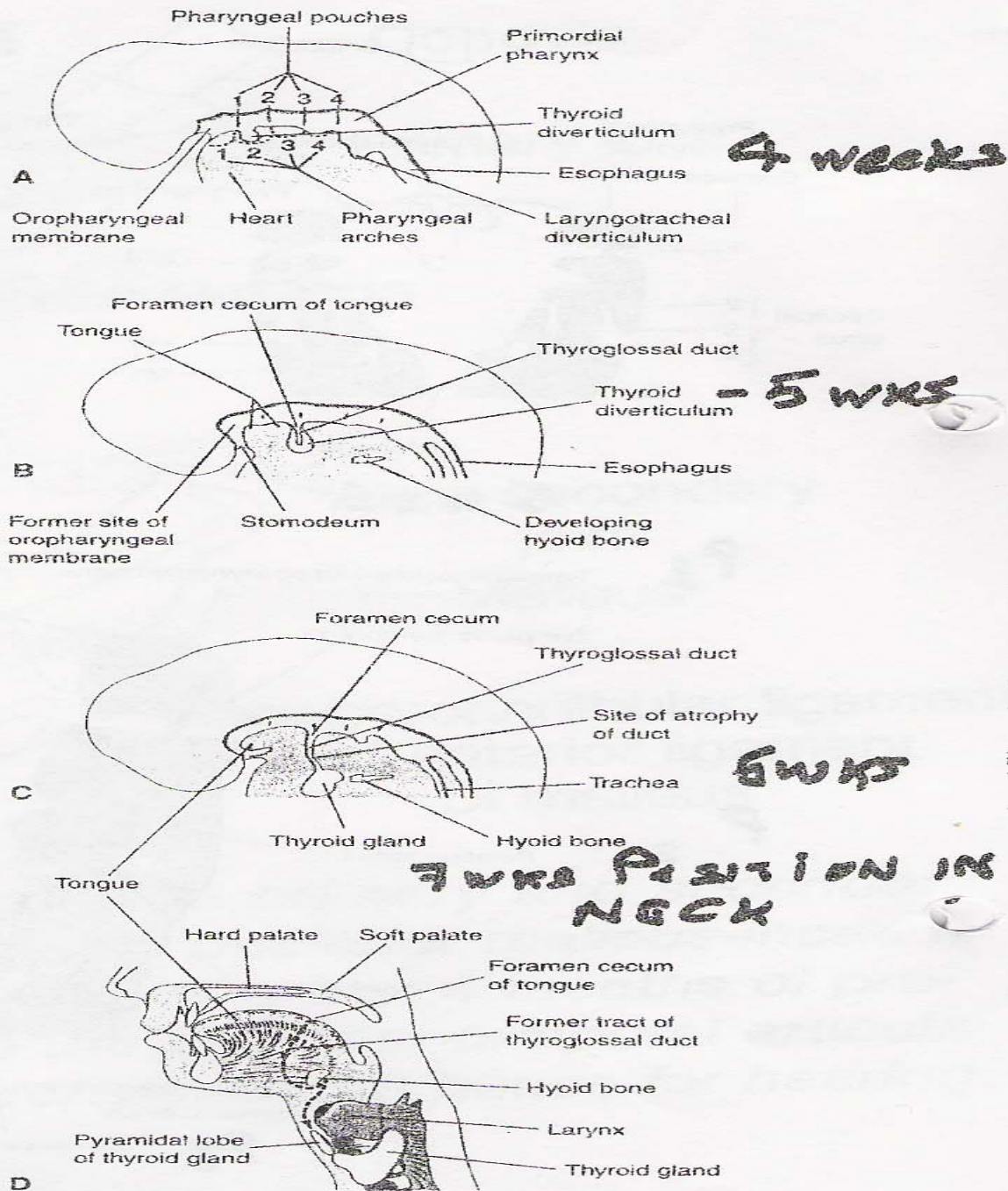
#### Blood supply;

- Superior & Inferior thyroid artery
- Superior, Middle & Inferior thyroid veins

#### Important surgical relationships;

- Superior laryngeal nerve
- Recurrent laryngeal nerve
- Cervical sympathetic chain
- Parathyroid glands

# Thyroglossal Cyst Embryology



**Figure 11-17.** Development of the thyroid gland. *A, B, and C*, Schematic sagittal sections of the head and neck regions of embryos at 4, 5, and 6 weeks, illustrating successive stages in the development of the thyroid gland. *D*, Similar section of an adult head and neck, showing the path taken by the thyroid gland during its embryonic descent (indicated by the former tract of the thyroglossal duct).

The thyroid is of **endodermal origin**, arising from a **median downgrowth in the floor of the pharynx**. The **parafollicular cells** are derived from the **neural crest cells** that migrate into the **ultimobranchial body of the 4<sup>th</sup> pharyngeal pouches**.

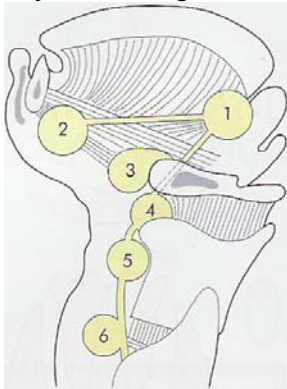
The thyroglossal duct develops from the **median bud of the pharynx**. The foramen caecum at the base of the tongue is the vestigial remnant of the duct. This initially hollow structure migrates caudally & passes in close continuity with, & sometimes through, the developing hyoid cartilage.

Some residual thyroid tissue along the course of the thyroglossal tract is common & a **pyramidal lobe** is present in **50%** of individuals. Substantial rests of thyroid tissue may be **lingual or cervical**

It begins functioning at about the **10<sup>th</sup> week of foetal life**.



Very rarely the whole gland is **ectopic**. This may present in any part of the thyroglossal tract;



1. Beneath the foramen caecum
2. In the floor of the mouth
3. Suprahyoid\*
4. Subhyoid\*
5. In the region of the thyroid cartilage\*
6. On the level of the cricoid cartilage

#### C/P

- Midline neck mass
  - \* **Non-tender**, unless infected
  - \* Rises in the neck with **tongue protrusion** as well as on **swallowing**, because of the attachment of the tract to the foramen caecum.
  - \* **80%** juxtaposed to the hyoid bone
- The wall contains *nodules of lymphatic tissue* & the initial presentation often follows an **URI**.

#### DDx

- Ectopic midline thyroid
- Thyroid adenoma of isthmus or pyramidal lobe
- Dermoid cyst
- Lymphadenitis

#### Ix

- *Thyroid scan* if midline ectopic thyroid or thyroid nodule is suspected. Thyroid tissue seen in *10-45% of cysts*.

#### Mx

- A thyroglossal cyst **>1cm** in size, **which persists**, should be excised because infection is inevitable.  
**Sistrunk's Operation** - Because the thyroglossal cyst is so closely related to the body of the hyoid bone & to prevent recurrence, the *central part of the hyoid* must be excised, together with the *cyst or fistula*, upwards towards the *foramen caecum with a core of lingual muscle*.

#### Complications

- **Infection** - An infected cyst is often mistaken for an abscess & incised, which may result in a **thyroglossal fistula**
- **Malignant degeneration** if not excised

# Classification of Thyroid swellings

## ***Simple goitre (euthyroid)***

Diffuse hyperplastic

Physiological

Pubertal

Pregnancy

Multinodular goitre

## ***Toxic***

Diffuse

Graves' disease

Multinodular

Toxic adenoma

## ***Neoplastic***

Benign

Malignant

## ***Inflammatory***

Autoimmune

Chronic lymphocytic thyroiditis

Hashimoto's disease

Granulomatous

De Quervain's thyroiditis

Fibrosing

Riedel's thyroiditis

Infective

Acute (bacterial thyroiditis, viral thyroiditis, 'subacute thyroiditis')

Chronic (tuberculous, syphilitic)

Other

Amyloid

# Classification of Thyroid Neoplasms

# Classification of Thyroid Neoplasms

## **Benign**

Follicular adenoma

## **Malignant**

### **Primary**

Follicular epithelium – differentiated

Follicular

Papillary

Follicular epithelium – undifferentiated

Anaplastic

Parafollicular cells

Medullary

Lymphoid cells

Lymphoma

### **Secondary**

Metastatic

Local infiltration



**Table 53.8** Major differences between papillary and follicular carcinoma (after Cady)

	Papillary (%)	Follicular (%)
Male incidence	22	35
Lymph node metastases	35	13
Blood vessel invasion	40	60
Recurrence rate	19	29
Overall mortality rate	11	24
<b>Location of recurrent carcinoma</b>		
Distant metastases	45	75
Nodal metastases	34	12
Local recurrence	20	12

## Indications for Surgery

Condition	1° Therapy
<b>Simple Goitres</b>	<ul style="list-style-type: none"> <li>• <b>Watchful waiting</b></li> <li>• <b>&lt;2cm – Thyroxine</b></li> <li>• <b>Partial Thyroidectomy</b> – aims at removing the bulk of the gland, leaving up to <b>8gm</b> of relatively tissue in each remnant + <b>Thyroxine</b> to suppress TSH secretion, with the aim of preventing recurrence.</li> </ul> Indications; <ul style="list-style-type: none"> <li>• Cosmesis</li> <li>• Pressure symptoms</li> <li>• Patient anxiety</li> <li>• Retrosternal extension with actual or incipient tracheal compression</li> <li>• Dominant area of enlargement that may be Neoplastic</li> </ul>
<b>Toxic Goitres;</b> <ul style="list-style-type: none"> <li>• <b>Diffuse (Graves' Disease)</b></li> <li>• <b>Multinodular</b></li> <li>• <b>Toxic adenoma</b></li> </ul>	<b>&lt;45yrs</b> <ul style="list-style-type: none"> <li>• Small goitre – Antithyroid drugs or Radioiodine</li> <li>• Large goitre – Surgery</li> </ul> <b>&gt;45yrs - Radioiodine</b> Surgery <b>&lt;45yrs – Surgery</b> <b>&gt;45yrs - Radioiodine</b>
<b>Malignant Goitres;</b> <ul style="list-style-type: none"> <li>• <b>Differentiated carcinoma</b></li> <li>• <b>Anaplastic</b></li> <li>• <b>Medullary</b></li> <li>• <b>Lymphoma</b></li> </ul>	<ul style="list-style-type: none"> <li>• Conservative approach - <b>Lobectomy with isthmusectomy</b></li> <li>• <b>Total thyroidectomy;</b> <ul style="list-style-type: none"> <li>Bilateral disease</li> <li>High risk patients</li> </ul> </li> <li>• Palliative Radiotherapy</li> <li>• <b>Total thyroidectomy</b> &amp; resection of involved LN with either a radical or modified radical neck dissection.</li> <li>• <b>Total thyroidectomy</b></li> </ul>

## Pre-Op Preparation

- Monitor TFTs, Pulse rate & Weight
- Indirect laryngoscopy - Visualise the functioning of the vocal cords for medico-legal reasons
- Thyroid antibodies
- Serum calcium levels
- Radioactive Iodine Uptake Scan (RAIU) in case innodulation is planned
- Manage thyrotoxicosis;
  - \* Mild - *β-blockers & lugol's iodine* at 1<sup>st</sup> consultation; Stop *β-blockers 5 days post-op*
  - \* Severe - *Carbimazole* until euthyroid & *Lugol's iodine* for **10-14 days pre-op**

## Post-op Complications

- **Haemorrhage**
- **Respiratory obstruction** - usually 2° to;
  - \* anaesthetic complications
  - \* tension haematoma - *Open sutures to release the haematoma*
  - \* laryngeal oedema
  - \* tracheal collapse

If goitre was big, intubate the patient for **2wks post-op** to allow fibrosis around the trachea to prevent collapse.
- **Parathyroid insufficiency (30%)** - 2° to *removal of the glands or infarction* through damage to the parathyroid end artery
- **Thyroid insufficiency** - occurs within **2-5yrs**
- **Thyrotoxic crisis (storm)**
- **Wound infection** - A subcutaneous or deep cervical abscess
- **Recurrent laryngeal nerve paralysis** - Transient paralysis occurs in **3%** & recovers in **3wks-3months**; Leads to vocal cord paralysis with blockage of the upper airway especially if bilateral. If no recovery, do **lateralization of the vocal cords** (abduct & stitch to the sides)
- **Stitch granuloma**
- **Hypertrophic or keloid scar** - especially if the incision overlies the sternum

# The Breast

## Aberrations of Normal Development & Involution (ANDI)

### Pathology

Features (microscopic) of ANDI;

- i) **Cysts**
- ii) **Adenosis**
- iii) **Fibrosis** - *Fat & elastic tissue* disappears & is replaced with *dense white fibrous trabeculae*. The interstitial tissue is infiltrated with chronic inflammatory cells.
- iv) **Hyperplasia** of epithelium in the lining of the ducts & acini  $\pm$  **Atypia**
- v) **Papillomatosis** - the *epithelial hyperplasia* may be so extensive that it results in papillomatous overgrowth within the ducts.

### Classification

Physiological State of the Breast	Normal	Benign Disorder	Benign Disease
<b>Development</b>	Duct development Lobular development Stromal development	Nipple inversion Fibroadenoma Adolescent Hypertrophy	Mammary fistula Giant fibroadenoma
<b>Cyclical change</b>	Hormonal activity Epithelial activity	Mastalgia & nodularity Benign papilloma	
<b>Pregnancy &amp; Lactation</b>	Epithelial hyperplasia Lactation	Blood-stained discharge Galactocele	
<b>Involution</b>	Ductal involution  Lobular involution Involutional epithelial hyperplasia	Duct ectasia, nipple retraction Cysts, sclerosing adenosis Hyperplasia & micropapillomatosis	Periductal mastitis with suppuration  Lobular & Ductal hyperplasia with atypia

### S/S

- **Mastalgia;**
  - a) Cyclical
  - b) Non-cyclical;
    - \* Sclerosing adenosis
    - \* Post-op
    - \* Musculoskeletal
    - \* Cervical root pain
- **Breast lumps** - Commonly *upper outer quadrant*  $\pm$  Bilateral;
  - i) Fibroadenoma
  - ii) Cyclical nodularity - *Increase in lumpiness & often tenderness before a menstrual period*
  - iii) Chronic abscess
  - iv) Cysts
  - v) Lipoma
  - vi) Fat necrosis (*traumatic*)
  - vii) Galactocele
  - viii) Sclerosing adenosis
  - ix) Normal structures (*prominent rib, edge of previous breast biopsy, margin of breast tissue, etc*)
- **Breast infection;**
  - a) Lactational
  - b) Non-lactational
- **Disorders of the nipple & peri-areolar region;**
  - Discharge
  - Sepsis
  - Retraction

## Discharges from the nipple (the principal causes are italicised)

### Discharge from the surface

- Paget's disease
- Skin diseases (eczema, psoriasis)
- Rare causes (e.g. chancre)

### Discharge from a single duct

#### **Blood-stained**

- *Intraduct carcinoma*
- *Intraduct papilloma*
- Duct ectasia

#### **Serous (any colour)**

- *Fibrocystic disease*
- *Duct ectasia*
- Carcinoma

### Discharge from more than one duct

#### **Blood-stained**

- Carcinoma
- Ectasia
- Fibrocystic disease

#### **Grumous**

- *Duct ectasia*

#### **Purulent**

- *Infection*

#### **Serous**

- *Fibrocystic disease*
- *Duct ectasia*
- Carcinoma

#### **Milk**

- *Lactation*
- Rare causes
- (hypothyroidism, pituitary tumour)

## Ix for Nipple Discharge;

- m/c/s
- Cytology
- Ductography
- Mammography

## Sx;

- \* If massive discharge
  - \* Affects patients lifestyle
- One duct - *Microdochectomy***
  - Multiple - *Total duct excision***

## Mx;

Triple therapy;

- History
- Examination
- Investigation - **To Exclude Cancer & Make a diagnosis**
  - Mammography / U/S
  - FNAC

## ► Mastalgia (All ANDI);

- Exclude cancer - *FNAC indicates NO Atypia or Proliferation*
- Reassure - Use pain chart if unsure if cyclical or non-cyclical. Also allows for reassurance to become active.
- An appropriately fitting & supportive bra during the day & a soft bra (e.g. sports bra), at night
- Diet;
  - Exclude caffeine - *works for some*
  - Reduction in dietary fat
- Medication - *Indications*;
  - Pain interfering with the woman's **life, sleep &/or sexual activity**
  - Symptoms persist for **>6months**

**Analgesics +;**

- Avion 600mg OD** - Vitamin E based (antioxidant) - **3 months**
- Evening primrose oil** - over **3 months** especially in patients **>35yrs old**
- For intractable symptoms - GnRH antagonist e.g. **Danazol**, or Prolactin inhibitor e.g. **Bromocriptine**
- Severe cases - Anti-oestrogens e.g. **tamoxifen**

## ► Fibroadenomas (20-25yrs peak);

- Reassurance & Watchful waiting;
  - If **<5cm**
  - It has **no increased risk of malignancy**
  - **40%** regress spontaneously
- Fibroadenectomy;**

- **>5cm** (Giant fibroadenoma)
- Symptomatic
- Increased rate of growth
- Cosmesis
- Pressure effects
- Has a higher risk to malignancy
- Patient preference

▶ **Fibrocystic disease (35yrs peak) - *Do not excise if you can avoid it*** as it has ill defined margins & excision is done under GA. Watchful waiting.

## Prognosis

### **No increased risk**

Adenosis, sclerosing or florid  
Apocrine metaplasia  
Cysts macro and/or micro  
Duct ectasia  
Fibroadenoma  
Fibrosis  
Hyperplasia  
Mastitis (inflammation)  
Periductal mastitis  
Squamous metaplasia

### **Slightly increased risk (1.5–2 times)**

Hyperplasia, moderate or florid, solid or papillary  
Papilloma with a fibrovascular core

### **Moderately increased risk (5 times)**

Atypical hyperplasia (ductal or lobular)

### **Insufficient data to assign a risk**

Solitary papilloma of lactiferous sinus  
Radial scar lesion

## Malignant Conditions of the Breast

- a) **Carcinoma of the breast** - *Majority*
- b) **Phylloides tumour** - Still referred to erroneously as '*Giant fibroadenoma*'
- c) **Sarcomas**
- d) **Lymphomas**
- e) **Metastases;**
  - \* Bronchial carcinoma
  - \* Generalised lymphoid neoplasms
  - \* Granulocytic leukaemias

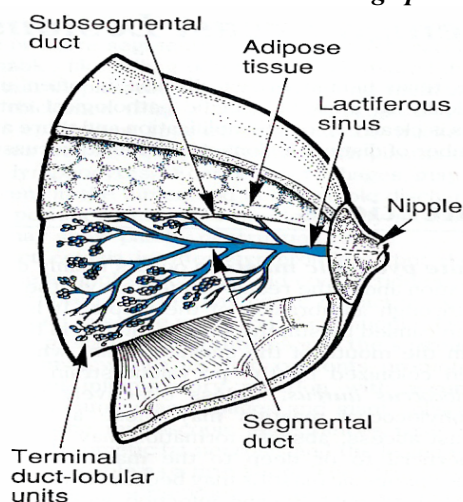
# Ca Breast

## Aetiological Factors

- Geographical - High SES; Commoner in the Western worlds
- Age - **30-40yrs (42yrs)** in Kenya (30-60yrs internationally)
- Gender- **Females>Males**
  - **Males - 7%** → **Infiltrating ductal carcinoma** - Risk factors;
    - \* BRCA 2(13q) (*Not 1*)
    - \* Gynaecomastia
    - \* Excess *oestrogen*
- Familial;
  - More common in women with a family history of breast cancer especially;
    - \* If **1<sup>st</sup> degree relation** *e.g. mother or sister*
    - \* If relation had cancer **before menopause** - Cancers are *more virulent* in the *young* patient
    - \* If it was **bilateral**
- Genetic;
  - Breast cancer related to a specific **mutation** in **BRCA 1(17q) & 2(13q)** which function as **tumour suppressor genes** - **5%**; Also **p53**
- Endocrine;
  - Risk factors;
    - \* **Early menarche & Late menopause** - ↑ exposure to *oestrogen*
    - \* **Nulliparous** women
    - \* In *post-menopausal women*, breast cancer is more common in the **obese** & is thought to be because of an **increased conversion of steroid hormones to oestradiol** in the body fat
    - \* Use of high hormone **Oestrogen contraceptive pills, IUCDs & HRT** - Breast cancer risk is ↑ **10%** within **1-2yrs** of *initiating* treatment. The increased risk is related to the **duration** of HRT use (but **not** to the age at which HRT is started) & this excess risk **disappears within 5yrs of stopping**.
  - **Protective factors** - ↑**Progesterones**;
    - \* Breast feeding
    - \* Having a first child at an early age (**<30yrs**)
    - \* Many pregnancies
    - \* Oophrectomy
- Diet - Risks increase in;
  - ↑ Alcohol intake
  - ↑ fats & protein intake in diet
- Benign breast disease especially **fibroadenosis** - *Takes 10-15yrs for a lump to evolve to cancer.*
- One breasted cancer
- **Cigarette smoking** is a risk factor for **lobular carcinoma**

## Pathology

Carcinoma of the breast arises from the **lining epithelium of the terminal duct-lobular system**



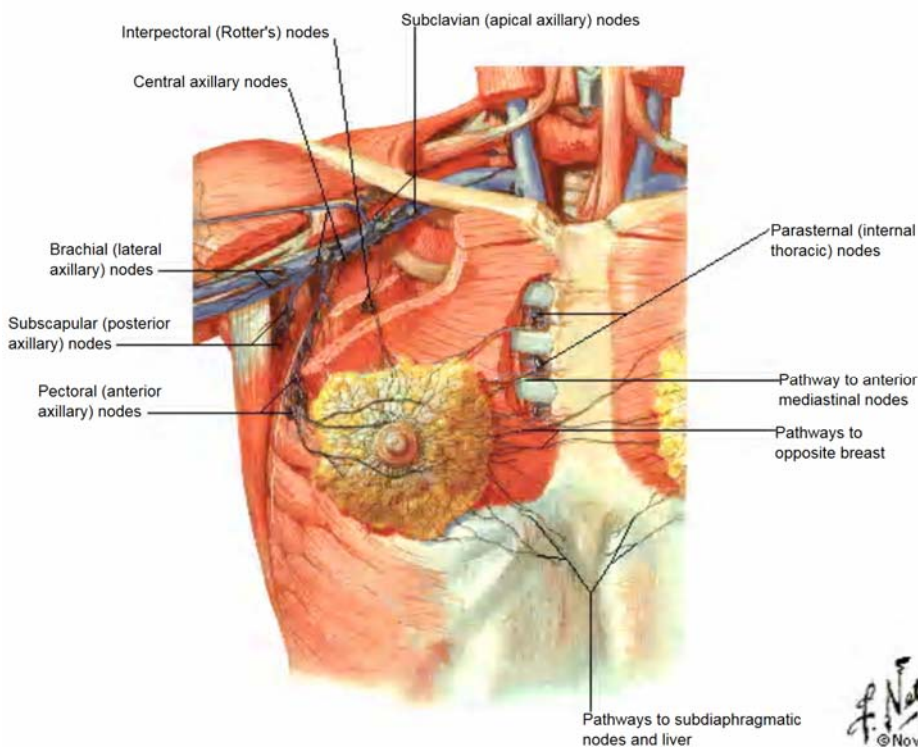


## Classification;

- i) **Early Breast Cancer - In-situ carcinoma** - cytological changes of malignancy are present in the epithelial cells but the **basement membrane remains intact** & no invasion is seen - **20%** go on to develop invasive carcinoma
  - a) **Ductal carcinoma in situ** - Usually presents as a palpable mass but may extend along the major ducts as far as the nipple & areola & the affected skin produces a characteristic *eczematous appearance* - **Paget's disease of the breast** characterized microscopically by large ovoid cells with abundant, clear, pale staining cytoplasm in the **Malpighian layer** of the epidermis.
  - b) **Lobular carcinoma in situ** - often *multifocal & bilateral* - **less common** & usually an incidental finding.
- ii) **Late Breast Cancer - Invasive Carcinoma;**
  - a) **Ductal carcinoma** - **Most common** variant; Grossly they form a firm, often hard, moderately defined lump (10-40mm diameter). They cut like an **unripe pear** - formerly **Scirrhus carcinoma**
  - b) **Lobular carcinoma** - **15%** - often *multifocal & bilateral*
    - i) Classical - *Better prognosis*
    - ii) Pleomorphic
  - c) Rarer histological variants - *Have a better prognosis;*
    - Tubular carcinomas
    - Medullary carcinomas
    - Mucoid/colloid carcinomas
    - Inflammatory carcinoma

## Spread

- **Local spread** to the *rest of the breast, the deep fascia, pectoral muscle & chest wall & overlying skin*
- **Lymphatic metastasis** to;
  - Axillary LN (**5 groups**)
  - Internal thoracic chain of LN
  - **In advanced disease;**
    - \* Supraclavicular LN
    - \* Any contra lateral LN

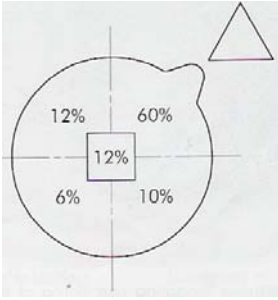


- **Haematogenous spread;**
  - Lung, Liver, **Brain** (especially to the *cerebellum & posterior pituitary gland*)
  - Skeletal areas - usually *osteolytic* lesions (in order of frequency);
    - \* Lumbar vertebrae
    - \* Femur
    - \* Thoracic vertebrae
    - \* Rib
    - \* Skull
  - \*\* Cancers that metastasize to the *bone rarely metastasize to the brain*
  - Occasionally - *Adrenals & Ovaries*



## C/P

### Commonest site - Upper, Outer Quadrant



#### Clinical indications;

- **Age of patient - 30-40yrs in Kenya** (30-60yrs internationally)
- **A lump** - Classically this is **hard, painless (10% may be painful), immobile, irregular** mass and demonstrates a degree of **fixity** to *surrounding tissues, overlying skin, or the underlying pectoral muscle*. The lump may be visible on inspection and may cause distortion of the breast on elevation of the arms or when tensing the pectoral muscles.
- **Lymphadenopathy** - regional lymph nodes, such as those in the **axilla or supraclavicular**
- **Cancer-en-cuirasse (Frozen breast)** - *fixation to the chest wall* due to infiltration of the **skin** of the chest with carcinoma. This is the **commonest** late presentation.

#### Also;

- Increased discomfort in the lump prior to menstruation or persistent terrible pain
- **Peau d'orange** (feature of advanced cancer) - **lymphatic obstruction** of the breast as a result of **axillary metastasis** leads to **oedema of the skin** which is **tethered by the sweat ducts** thus cannot swell leading to an appearance like orange skin
- **Nipple disease;**
  - \* *Distortion and inversion*
  - \* *A unifocal or blood-stained nipple discharge*
  - \* *Paget's disease*
- In advanced, untreated cases the skin may be broken, and tumour **ulcerates** through the skin, with associated **haemorrhage and odour**.
- **Metastatic disease** - This may be either *to regional lymph nodes*, such as those in the axilla or supraclavicular fossa, or *to distant sites* such as *bone, lung, liver, or brain*.
- **Late oedema** of the arm from *lymphatic & venous* blockage 2° to;
  - \* Neoplastic infiltration of the axilla - *usually painful due to brachial plexus nerve involvement*
  - \* Radical axillary dissection
  - \* Radiotherapy to axilla

**Lymphangiosarcoma** is a rare complication of lymphoedema presenting with multiple subcutaneous nodules in the upper limb - **Rx - Cytotoxics or irradiation or interscapulothoracic amputation**

\*\* Up to **15%** are **younger patients** with **lobular carcinoma** who present with a **diffuse tumour** which produces distortion, puckering, and the eventual feeling of heaviness as the tumour extends through the breast. Later there may be **nipple retraction** and discomfort.

#### DDx

- Fibroadenoma
- Cyclical nodularity
- Chronic abscess
- Cysts
- Lipoma
- Fat necrosis (*traumatic*)
- Galactocele
- Sclerosing adenosis
- Normal structures (*prominent rib, edge of previous breast biopsy, margin of breast tissue, etc*)

## Ix

- **FNAC - Gold standard - 95% sensitive**
- **Mammography (U/S if <35yrs or ↑ breast density);**
  - Indications;
    - \* >35yrs old - Due to ↓ breast density 2° to involution.
    - \* If there is a **malignant** lump;
      - \* **Ipsilateral** mammography to **r/o multiple foci** where *conservative surgery* is considered.
      - \* **Contralateral** mammography to **r/o malignancy** especially in high risk patients
  - Classic features of Breast cancer;
    - \* **Microcalcification**
    - \* **Mass effect**
      - Tissue asymmetry
      - Skin thickening
      - Nipple inversion
- Screening for staging, treatment & prognosis;
  - Clinical examination
  - FHG + ESR
  - LFTs - ALP & γGT
  - Liver U/S if *LFTs abnormal*
  - CXR
  - Isotope bone scan
- Staining for;
  - **Estrogen & Progesterone receptors (ER & PR)** - Their presence will indicate the use of adjuvant hormonal therapy with **tamoxifen**.
  - **c-erbB2 (A growth factor receptor)** - Patients can be treated with the **monoclonal antibody** against this receptor if they relapse.
- **Sentinel node biopsy** - Used in the management of the axilla in patients with **clinically node-negative disease**. The sentinel node is localised preoperatively by the injection of patent *blue dye &/or radioisotope-labelled albumin near the tumour*. The marker passes to the 1° node draining the area & is resected for histology.  
 In patients in whom there is **no tumour involvement** of the sentinel node, further *axillary dissection can be avoided* as skip lesions occur in <3% of patients.

## Staging

### a) The Manchester system

- I** - Tumour **confined** to breast. Any **skin involvement** covers an area < *the size of the tumour*.
- II** - Tumour **confined** to breast + **Palpable, mobile axillary nodes**.
- III** - Tumour **extends** beyond the breast tissue;
  - \* **Skin fixation** in an area > **the size of the tumour**
  - \* **Ulceration**
  - \* *Tumour fixity to underlying fascia*
- IV** - **Fixed axillary nodes**  
**Supraclavicular nodal involvement**  
**Satellite nodules**  
**Distant metastases**

### b) The TNM Classification (International Union Against Cancer)

Stage	Tumour grade	Clinical extent	Node grade	Clinical extent	Distant metastases
TIS	TIS	No palpable tumour	N0	No nodal metastases	M0 = no known distant metastases
I	T1	< 2cm	N0	No nodal metastases	
II	T2	2-5 cm	N1	Mobile axillary nodes	
IIIa	T3	> 5cm	N2	Fixed axillary nodes	
IIIb	T4	Any size invading skin or chest wall	N3	Supraclavicular ipsilateral nodes	
IV					M1 = distant metastases

# Management

Principles;

- Reduce the chance of *local recurrence*
- Reduce the risk of *metastatic spread*

Surgery ± Radiotherapy

a) **Breast Conservation Surgery;**

Indications;

- Tumour size <**5cm**
- Ample breast tissue
- Single nodule
- No C/I
- Patient preference

Contraindications;

- Multicentricity
- Widespread multifocal disease
- Central tumours beneath or involving the nipple
- Poor tumour differentiation
- Disseminated disease

i) **Wide local excision** - Remove tumour + a ream of at least **1cm** of normal breast tissue + **Axillary dissection** + **Local Radiotherapy**

ii) **Quadrectomy** + **Axillary dissection** + **Local Radiotherapy**

b) **Mastectomy;**

Indications;

- Congenital supranumerary breasts
- Extensive destruction of breast architecture 2° to;
  - \* Chronic infections (*TB, Fungi*)
  - \* Sarcoidosis
  - \* Severe trauma
- Tumours;
  - \* **Early breast cancer** (Carcinoma in-situ)
  - \* Large tumours (in relation to the size of the breast)
  - \* Central tumours beneath or involving the nipple
  - \* Multifocal disease
  - \* Local recurrence
  - \* Palliative (*Toilet Mastectomy*)
  - \* Prophylaxis where there is a strong family history
- Patient preference

Landmarks (Surgery is **medial to lateral**);

- Upper - **Clavicle**
- Lower - **6<sup>th</sup> Rib**
- Medially - **Lateral sternal boarder**
- Laterally - **Anterior Axillary Fold**

Types;

i) **Simple mastectomy** - Removal of the breast only with **no dissection of the axilla**, except for the region of the axillary tail of the breast, which usually has attached to it a few nodes low in the anterior group. Often followed by **Axillary Radiotherapy**.

ii) **Modified Radical ('Patey') mastectomy**

- **Whole breast + Axillary Lymph nodes - NO Radiotherapy**

Of Historical importance (**No longer indicated**);

- **Radical Halsted mastectomy** - Excision of the *breast, axillary LN, pectoralis major & minor muscles* - Causes excessive morbidity with no survival benefit

c) **Radiotherapy** - Shown to be as **equally effective as surgery**;

- High-grade & Large tumours - *Extensive local disease with infiltration of the chest wall*
- Heavy **node +ve** disease & Extensive lymphovascular invasion
- Recurrent disease
- 2° to Breast conservation surgery (*Local radiotherapy*) or Simple mastectomy (*Axillary radiotherapy*)

Systemic therapy - Chemotherapy &/or hormone therapy directed at putative micrometastases to delay relapse & prolong survival;

- \* To palliate symptoms in locally advanced or metastatic disease
- \* Lymph **node +ve**
- \* Poor prognostic **node -ve** women
- \* Women with **oestrogen receptor +ve** tumours

**i) Chemotherapy - Cyclophosphamide, Methotrexate & 5-Fluorouracil (CMF);**

- Large but operable tumours to shrink the tumour to enable **breast conserving surgery**.
- **Young node +ve** patients
- **Node -ve** patients if other prognostic factors e.g. tumour grade, imply a **high risk of recurrence**

**ii) Hormone therapy - For women with oestrogen or progesterone receptor +ve tumours;**

Effective in **8% receptor -ve** patients; Given **after chemotherapy** to reduce side-effects

- **Oestrogen receptor antagonists e.g. Tamoxifen** for **3-5yrs** - Started immediately diagnosis is made; Also beneficial in reducing tumours in the contra-lateral breast.

**SE:**

- \* Endometrial changes - Hyperplasia, polyps, cancer & uterine sarcoma
- \* Thromboembolism
- \* Occasional cystic ovarian swellings in premenopausal women
- \* Occasional hypercalcaemia if bony metastases
- Oral **aromatase inhibitors e.g. anastrozole** - they block conversion of *androgens to oestrogens* in the peripheral tissues. **For post-menopausal women** who are unable to take tamoxifen therapy because of high risk thromboembolism or endometrial abnormalities
- **Ovarian ablation** in **pre-menopausal receptor +ve** patients;
  - \* **Gonadorelin (LHRH) analogues e.g. Goserelin** - Induce a **reversible** ovarian suppression - Management of advanced breast cancer in **pre-menopausal** women
  - \* Surgery & Radiotherapy - **Not done**
- Tumours +ve for the **HER2** protein may respond to the monoclonal antibody **trastuzumab**

**Symptomatic & Terminal care**

- Hospice care
- DXT to painful bony lesions

## Prognosis

Prognostic factors;

- Stage of cancer at presentation - *Tumour size & LN status - Mammography screening recommended for early detection*
- Histological grade of the tumour
- Hormone receptor status
- Presence of lympho-vascular invasion

# The Oesophagus

## Dysphagia

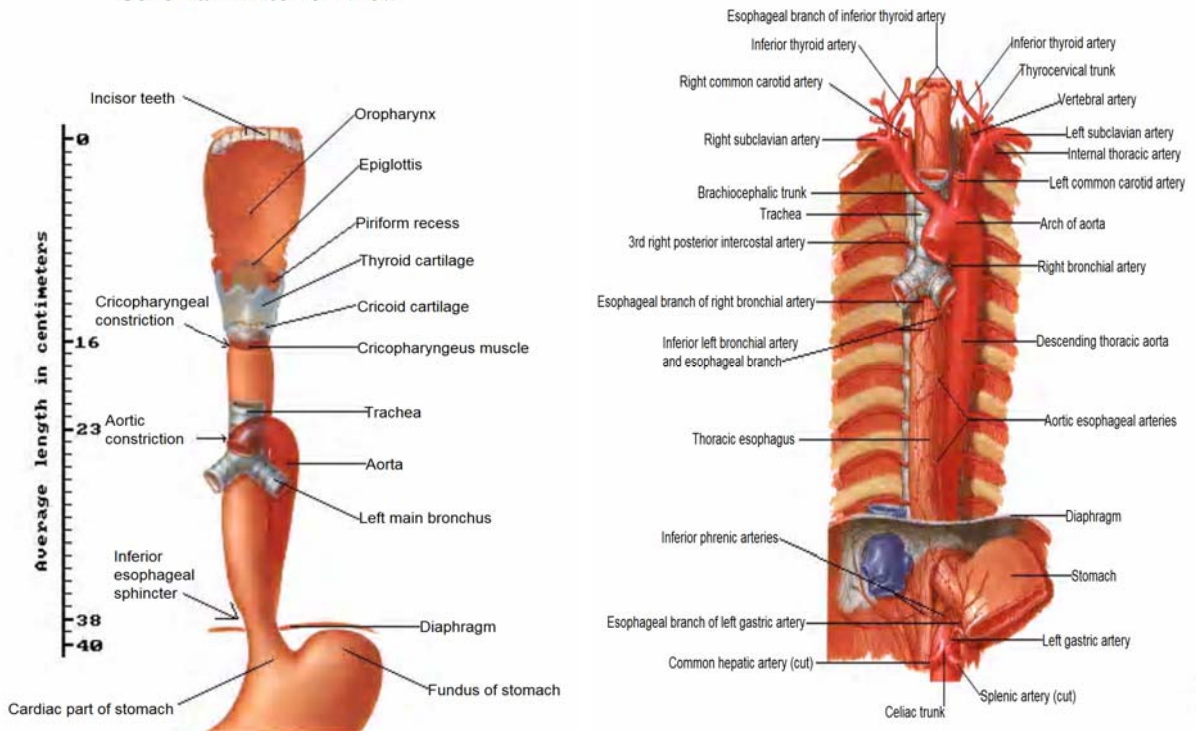
Difficulty in swallowing *once the swallowing process has been initiated*

### Anatomy

- Length - **25cm**
- More commonly to the **right** in the **upper** 1/3 then moves to the **left** in the **lower** 1/3
- Has a segmental blood supply;
  - **Upper** 1/3 - Cervical blood supply from Oesophageal branches of the **inferior thyroid & right & left bronchial arteries**
  - **Middle** 1/3 - **Aortic oesophageal arteries**
  - **Lower** 1/3 - Oesophageal branch of the **Left gastric artery**
- Constrictions;
  - Cricopharyngeal constriction - **15cm**
  - Aortic & Bronchial constrictions - **25cm**
  - Lower oesophageal sphincter & Diaphragm - **40cm**

### Topography and Constrictions of Esophagus

#### Schema - Anterior View



\*\* Upper incisors are used as the 1<sup>st</sup> part of the GIT cause they are **fixed** of the lower incisors.

### Physiology

The normal act of swallowing may be divided into **oropharyngeal**, and **oesophageal** stages.

- The **oropharyngeal phase** involves the process of chewing and mixing solid food with saliva so that individual food particles are sufficiently reduced in size and lubricated to allow easy passage through the pharynx and oesophagus. With the **voluntary initiation** of swallowing, the food bolus is **propelled posteriorly by the tongue** into the **pharynx**. A rapid series of carefully orchestrated **involuntary** events follow in which the **soft palate and larynx close** (*to prevent nasal regurgitation and aspiration*), the **upper oesophageal sphincter** opens, and a wave of **pharyngeal peristalsis** propels the food bolus into the upper oesophagus. This **involuntary** process of food bolus transfer is controlled by the **swallowing centre** located in the **medulla**. Respiration is inhibited **centrally** during the act of swallowing. **Afferent** input to the swallowing centre is provided by cranial nerves **V, X, and XI**, and **efferent motor function** is provided by cranial nerves **V, VII, IX, X, and XII**.
- Once the food bolus has reached the **upper oesophagus**, the **oesophageal phase** of swallowing takes place. A primary peristaltic wave propels the food bolus down the oesophagus. The **lower oesophageal sphincter** relaxes in anticipation of the peristaltic wave, allowing passage of the food bolus into the stomach.

relaxes in anticipation of the peristaltic wave, allowing passage of the food bolus into the stomach.

## Classification

a) Oropharyngeal dysphagia (also termed **Transfer dysphagia**) is produced by an *abnormality in the preparation or transfer* of food from the **mouth to the upper oesophagus**

This may occur as a result of **poor motor control** of the *tongue, jaw, or other oral structures* or may be due to an **abnormality of the swallowing reflex**.

### Causes;

- Neurologic disorders;
  - CVAs (especially brainstem) - Brainstem tumours
  - Alzheimer's disease - Bulbar poliomyelitis
  - Parkinson's disease - Peripheral neuropathies
  - Multiple sclerosis - Huntington's disease
- Diseases of myoneural junction
  - Myasthenia gravis
  - Eaton-Lambert syndrome
  - Botulism
- Muscular Disorders
  - Muscular dystrophies e.g. *Myotonic dystrophy, Occulopharyngeal dystrophy*
  - Dermatomyositis/polymyositis
  - Sarcoidosis
  - Metabolic myopathies (*Hypo- or Hyperthyroidism*)
  - Amyloidosis
  - Steroid-induced myopathy
- Structural Abnormalities
  - Oropharyngeal neoplasms
  - Extrinsic compression (*cervical osteophytes, Retrosternal goitre*)
  - Post-surgical/Radiation stenosis
  - Infections (*Candida, HSV*)
  - Tonsillar enlargement (*abscess*)
  - Caustic Oesophagitis
  - Oesophageal web
  - Zenker's diverticulum
- Upper Oesophageal Sphincter (UES) Dysfunction
  - Cricopharyngeal achalasia
  - Hypertensive UES

### S/S

- Difficulty initiating a swallow
- Nasal regurgitation
- Coughing during swallowing

b) Oesophageal dysphagia is caused by a **"mechanical" or "motor abnormality"** of the oesophagus which impairs movement of the food bolus through the oesophagus into the stomach. Patients are able to transfer food from the mouth into the upper oesophagus, but experience a sensation of food **"hanging up" or "sticking"** after it is swallowed.

### Causes;

- A **structural or mechanical process** impairing movement of a food bolus through the oesophageal lumen.
  - **Intrinsic** mechanical abnormalities;
    - \* Foreign bodies
    - \* Peptic (reflux-induced) stricture
    - \* Oesophageal Carcinoma
    - \* Oesophageal webs/rings
    - \* Oesophageal Diverticula
  - **Extrinsic** oesophageal compression;
    - \* Cervical osteophytes
    - \* Mediastinal mass (*Retrosternal goitre, Mediastinal LN, Aortic aneurysm, LAE*)
    - \* Mediastinal tumours (*Pharyngeal, Oesophagus, Gastric, Bronchus*)
    - \* Vascular compression
- **Motility disorders** of the oesophagus (**OHCM Pg 212**)
  - Achalasia
  - Diffuse oesophageal spasm
  - Hypertensive LES
  - Non-specific motility disorders
  - Chaga's disease

- Scleroderma/Progressive systemic sclerosis
- Severe GORD



## Mx S/S

- Dysphagia to **solids alone** suggests a *mechanical or structural abnormality*, whereas dysphagia to **both solids and liquids** suggests a *neuromuscular disturbance*.
- A long history of *intermittent dysphagia* to solids (particularly steak or bread) suggests a *fixed oesophageal ring or web*, which has not changed in size. In contrast, *progressively worsening* of solid food dysphagia suggests a *peptic stricture, neoplasm, or achalasia*.
- Associated symptoms of **chest pain** with *intermittent dysphagia* may indicate *diffuse oesophageal spasm or achalasia*.
- An associated history of **heartburn or acid regurgitation** suggest *scleroderma or a peptic stricture*.
- Suspicion of an *oesophageal neoplasm* should be heightened among **older patients** presenting with **weight loss and a history of alcohol or tobacco use**.
- **Regurgitation** of undigested food in association with coughing while in the recumbent position or **recurrent pneumonia** suggest *achalasia* (vomit food eaten **24hrs ago**), *Pharyngeal pouch* (vomit food eaten **48hrs ago**), *Ca oesophagus* at cardia or *Ca stomach*.
- If associated with neck swelling - *Goitre, Pharyngeal pouch* (gurgles on drinking)
- Patients with **AIDS** may have dysphagia from *opportunistic infections* or *mass lesions* (e.g., *Kaposi's sarcoma and lymphoma*).
- **Odynophagia** - *Ca, Oesophagitis, achalasia or oesophageal spasm*

## O/E

- Do a general examination
- **Profound weight loss** may be seen in patients with *advanced oesophageal malignancy* or *achalasia*, but is uncommon in other benign conditions.
- The presence of a **positive faecal occult blood** test may be found in *malignancy* or *reflux oesophagitis*.

## Grading

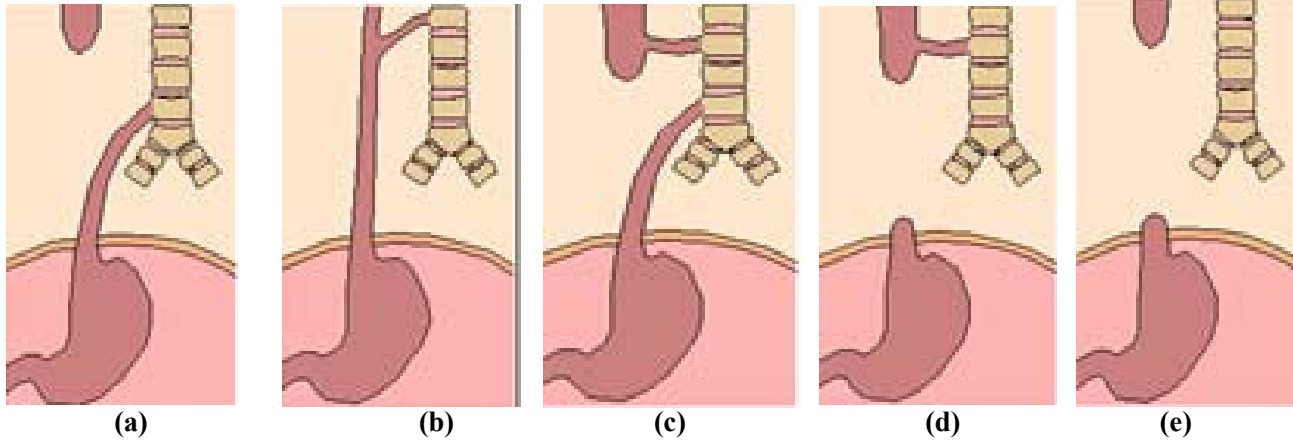
- 0 - **Normal** swallowing
- 1 - Difficulty with **solids** only
- 2 - Difficulty with **semi-solids**
- 3 - **Swallows liquids only**
- 4 - **Total Dysphagia**

## Ix

- FBC - *Anaemia*
- U/E/C - *Dehydration*
- **CXR** - *Mediastinal fluid level, absent gastric bubble, aspiration*
- Radiology;
  - Barium contrast oesophagography (Barium swallow)
  - Upper GI endoscopy & Biopsy - *Rigid oesophagoscope or Flexible video-gastroduodenoscope*
  - Video pharyngeal fluoroscopic swallowing study (VFSS)
  - Video endoscopic swallowing study
- Oesophageal manometry (*if normal Barium swallow*)
- ENT consultation if suspected *pharyngeal causes*

# Oesophageal Atresia & Tracheo-Oesophageal Fistula

## Classification



- Oesophageal atresia with **distal fistula** - **82%**
- TEF** without oesophageal atresia/**H-Type** - **7%** - *More common in the **Upper 1/3***
- Proximal & Distal Fistula** (formerly Type 3C) - **6%**
- Oesophageal atresia with **proximal fistula** - **3%**
- Oesophageal atresia **without a fistula** - **2%**

## Embryology & Aetiology

Approximately **3 weeks** after fertilization, the **cranial end of the foregut** begins to become demarcated into the **oesophagus and trachea** by a **longitudinal groove** & as the ridges proximate one another, the foregut divides into **tracheal & oesophageal channels** by **8wks**, failure of which results in **atresia ± fistula**

## Associated Malformations

Oesophageal atresia may occur as part of the **VACTER** group of anomalies;

- **Vertebral body segmentation defects** - *Hemivertebra, Sacral agenesis*
- **Anorectal malformations**
- **Cardiovascular** - *PDA, VSD*
- **Tracheo-Oesophageal fistula**
- **Radial ray hypoplasia**; unilateral **Renal agenesis** or ectopia

## C/P

- In utero, the foetus is *unable to swallow amniotic fluid* leading to **polyhydramnios**
- The newborn baby *regurgitates all of its first & subsequent feeds*
- **Frothy saliva through mouth & nostrils** - This is the **classical sign of atresia**
- Respiratory distress if saliva is aspirated;
  - *Cyanosis, Choking, Coughing & Dyspnoea* especially on *changing position & feeding*
  - *Reflux acid contents from stomach* cause *chemical pneumonitis*
- A NGT typically comes against an obstruction **within 10cm**
- **VACTER**

## Ix

### CXR - PA & Lateral;

- NGT in proximal pouch
- The side on which the aortic arch is located
- Pneumonia
- Bowel gas;
  - If **Present**, there must be a fistula to the distal oesophagus & one can bridge the gap in the same sitting - **Short gap**
  - **Absent** - **Long gap** between oesophageal ends - **NO fistula**

Mx

- i) **Stop all feeds**
- ii) Nurse baby propped up at **45°** in incubator
- iii) Pass NGT for continuous suction of saliva **every 20mins**.
- iv) Start IV dextrose
- v) **Thoracotomy;**

**Short Gap;**

- a) Performed on the side **opposite** to the **aortic arch**, usually the **right** at the level of the **4<sup>th</sup> ICS** which is approximately at the *carina*
- b) Performed **Extrapleural** to avoid leaving a chest tube for drainage after (*not drained*)
- c) **Ligate the azygous vein** as it crosses the lower oesophagus to the *SVC*
- d) Identify the **vagus nerve** as it lies on the oesophagus & **safeguard it**
- e) Identify proximal pouch - Identification of the upper pouch is facilitated by intermittent pressure by the anaesthetist on a previously positioned large upper pouch tube.
- f) A traction suture is placed in the tip of the pouch and the pouch **dissected as high as possible**, taking care not to enter the closely adherent trachea.
- g) Achieve **end-to-end anastomosis** between the *blind upper segment & the lower segment* - Use **6 isolated single stitches** with lots of tissue in-between to **avoid stricture formation** & to **ensure the ring will grow**.
- h) A **transanastomotic NG tube** for **suctioning & later feeding** is passed across the posterior wall into the stomach and the anterior wall is completed.

**Long Gap options;**

*Cervical Oesophagostomy* to drain saliva & *Gastrostomy* for feeding then;

- *Reversed gastric tube* - A tube flap is made from the greater curvature of the stomach based on *left gastroepiploic vessels* & rotated to bridge the gap
- *Colonic interposition*

**Post-op;**

- i) Start NGT feeding on **Day 4**
- ii) **Day 10** - Do a **Danosil swallow** - to visualise anastomosis - Check for leakage; if any, wait for further healing. If no leakage, **remove transanastomotic tube** & feed PO
- iii) **Stenosis** will require **dilatation** later in theatre under GA by a radiologist

**Complications;**

- Pre- or Post-op pneumonia
- Pulmonary collapse or pneumothorax
- Tracheal malacia 2° to weak cartilage
- Leakage of the anastomosis
- Anastomotic stricture can occur even without a leak
- Recurrence of TOF
- GERD could lead to stricture of lower oesophagus which may be due to reduction of the angle of HIS due to pulling of the oesophagus - *managed by fundoplication*

# Ca Oesophagus

## Incidence

- M:F - **25:1**
- Average age - **58.2yrs (12-103yrs)**
- Prevalent region - **Central Nyanza** province

## Risk Factors - *Contribute to repeated long term minimal trauma*

- Smoking - **SCC**
- Alcohol excess - **SCC**
- Diet;
  - Hot foods
  - Deficiency of antioxidants which have been found to **inhibit carcinogenesis**, including **selenium, vitamins C and E, retinoids, & β-carotene, & plant sterols.**
  - Exposure to N-nitroso compounds (from Nitrates & Nitrites converted by bacteria in the body) - *Charred meat, Smoked fish*
  - Obesity
- Achalasia
- Tylosis (*Palmar hyperkeratosis*)
- Long standing oesophageal strictures
- Post-irradiation
- Pre-malignant conditions;
  - Paterson-Brown-Kelly (Plummer-Vinson) Syndrome - *Post cricoid web + IDA*
  - *Barrett's oesophagus* - there is a **44-fold** ↑ risk of **Adenocarcinoma** if severe reflux for **>10yrs**
- Coeliac disease - Predisposes to **Adenocarcinomas**

## Pathology

### Types;

- **Squamous cell carcinoma**- *Most common worldwide*
- **Adenocarcinoma** - *Most common in most Westernised countries*
- **Oat cell carcinoma**

### Site;

- **20%** - Upper 1/3 - **Squamous cell carcinoma**
- **50%** - Middle 1/3 - **Squamous cell carcinoma**
- **30%** - Lower 1/3 - **Adenocarcinoma**

### Spread;

- **Locoregional** - Occurs through **submucosal infiltration** of the wall of the oesophagus into adjacent structures, along the length of the oesophagus in the **submucosal lymphatics & to regional lymph nodes.** This is often **discontinuous** i.e. distant regional lymph nodes may be invaded even when local nodes are free of tumour, & there may be satellite nodules in the oesophagus *proximal* to the main tumour.
- **Systemic (Haematogenous)** - Mainly to the **liver & lungs**, but practically any organ can be involved

### S/S (*Generally of Advanced Disease*)

- **Progressive Dysphagia**
- Retrosternal chest pain
- Weight loss
- Lymphadenopathy (rare)
- S/S of **Upper** 1/3 of oesophagus;
  - Hoarseness - *due to recurrent laryngeal nerve palsy*
  - Cough (*may be paroxysmal if aspiration pneumonia*)
- **If anaemic, r/o Ca Stomach that has migrated upwards**

### DDx - *See Dysphagia*

## Ix

- **Endoscopic U/S with Biopsy/Brushings (*Gold standard*)** - Determines the extent of local regional spread
- **Bronchoscopy** should be done in lesions of the **upper or middle** 1/3, where there is potential for tracheo-bronchial invasion.
- **CT/MRI of Chest & Abdomen** - To assess 1° lesions & to exclude metastatic disease *from the lungs & liver*; On CT, *tumour oedema* may give a *false positive* indication of the spread of the tumour.
- **CXR** - to exclude metastatic disease from the *lungs*;
  - Pleural effusions
  - Fistulas
  - Lung destruction
  - Diaphragmatic paralysis if lesions involve the *phrenic nerve*
- **Abdominal U/S** - Indicated for;
  - carcinomas *from 35cm & lower down*
  - to exclude metastatic disease from the *liver*
  - differentiate tumours from oedematous surroundings seen on CT
- **Staging laparoscopy** is useful for assessing *Adenocarcinoma* of the **distal oesophagus**, particularly if it is likely to extend **below the phreno-oesophageal ligament**. Also, *transperitoneal spread & liver metastasis*
- **Barium swallow** - Shows the lesion & extent of adjacent spread (kinking) *for radiotherapy purposes*

## TNM Staging

**T<sub>is</sub>** Carcinoma-in-situ

**T1** invading *lamina propria/submucosa*

**T2** invading *muscularis propria*

**T3** invading *adventitia*

**T4** invasion of *adjacent structures*

**NX, N0, N1**

**M0** no distant spread

**M1** distant metastasis; Spread to the *coeliac axis nodes* from a lesion in the intrathoracic oesophagus - Regarded as **metastatic (M)** rather than nodal (N) disease in the TNM classification.

## Mx

i) **T<sub>is</sub>** may be cured by *endoscopic mucosal resection*.

ii) **Localised T1/T2;**

- ▶ **Chemoradiotherapy without surgery** for **Proximal SCC** - may be the definitive treatment but poses technical problems at the lower end of the oesophagus - **Curative**
- ▶ **Neo-adjuvant chemotherapy (Cisplatin + 5FU) + Radical Curative Subtotal Oesophagectomy;**
  - \* **an appropriate length of the oesophagus** (with generous proximal clearance (at least 5cm) to give the best chance of clearing satellite nodules in the submucosal lymphatics - usually resected just below the thoracic inlet)
  - \* **any involved stomach - (the cardia & the upper part of the lesser curvature including the whole left gastric artery)**
  - \* **locoregional lymphatics**

The **oesophagus** is anastomosed to the **fundus** by **hand or staple** anastomosis (latter reduces hospital stay but has no real benefit).

The viability of the transposed stomach mainly depends on the **right gastroepiploic vessels**, with a small contribution from the **right gastric**.

**Types of Curative Subtotal Oesophagectomy;**

- a) **Transhiatal oesophagectomy** is the fastest & is associated with less morbidity. The stomach is mobilised through a **midline abdominal incision** & the cervical oesophagus is mobilised through an incision in the **neck - For Upper & Lower 1/3**  
*Disadv* - Blunt blind transection
- b) **2 stage Ivor Lewis (or Lewis Tanner) operation** - The abdomen is opened first through a **midline incision**, closed & then the oesophagus is approached from a **right thoracotomy (the left side has the descending aorta) above the 5<sup>th</sup> rib** is performed - *For lower 1/3*
- c) **3 stage McKeown operation** - As Ivor Lewis (above) but a third incision on the **left side of the neck** is made to complete the cervical anastomosis. A neck incision is required if;
  - \* a lymph node dissection is to be done
  - \* there are technical difficulties with an anastomosis at the thoracic inlet- *For upper & middle 1/3s*
- d) **Thoracoabdominal - Abandoned**

**Post-op;**

- A chest tube is left in place after thoracotomy
- NPO for **5-7days** & then perform a **contrast swallow (Methylene Blue, Gastrografin, Dilute Barium)** to detect leakage. If present, NPO is maintained until it has healed.

**C/I;**

- Advanced nutritional debilitation
- Inadequate pulmonary reserve
- Widespread metastases;
  - Malignant effusion or ascites
  - Recurrent laryngeal nerve palsy
  - SVC syndrome
  - Malignant TEF

**Complications;**

- Strictures (*Benign or malignant*)
- Anastomotic leak - The **Mc Keown** operation is preferred as leakage is within the **neck** & usually closes with time but the **Ivor Lewis** operation leaks into the **pleural cavity** → **Pleural effusion**
- Recurrent laryngeal nerve injury
- Chylothorax
- DVT

iii) **Advanced disease (T3/4) - Palliative therapy to restore swallowing;**

- a) Chemo/radiotherapy - for **upper 1/3** tumours
- b) **Intubation** - For **middle & lower 1/3** tumours; *Not for upper 1/3* as the tube may become displaced upwards & may block the airway. It is inserted by;
  - *Oesophagoscopy* - **Pulsion tubes e.g., Proctar Livingstone, Atkinson, Souttar tubes**
  - *Laparotomy* - **Traction tubes e.g. Celestin tube (rubber), Mousseau-Barbin tube (Plastic)**

Unfortunately, the tube has a tendency to become dislodged or blocked with food, thus aggravating pain. Furthermore, concomitant radiotherapy increases the complications of tubes e.g., **bleeding, perforation**. Therefore, intubation should be reserved for patients with *extensive disease and a life expectancy limited to 1-2 months*.

- c) Laser therapy - *a core of tumour is vaporized, opening the lumen without perforating the*

*oesophagus.*

**d) Stenting**

**Prognosis**

\* Resectable rate - **30%**

\* 5YSR - **5-10%** (KNH - **25%**)

# Dyspepsia & Peptic Ulceration

## Surgical Notes - OHCM 213-217

### i) Duodenal Ulcers

- Most duodenal ulcers occur in the **1<sup>st</sup> part of the duodenum**
- A chronic ulcer penetrates the mucosa & into the muscle coat, leading to fibrosis which causes deformities such as **pyloric stenosis**
- When there is both a posterior & anterior duodenal ulcer - '**Kissing Ulcers**'
- **Anteriorly** placed ulcers tend to **perforate** due to the **poor blood supply** of the anterior duodenal wall which is a **watershed area** thus heals poorly.  
In contrast, **posterior** duodenal ulcers tend to **bleed**, sometimes by eroding a large vessel e.g. the **gastroduodenal artery**.
- Malignancy in this region is **uncommon (1-5%)**

### ii) Gastric Ulcers

- Gastric ulcers are **independent of acid secretion** & can occur in achlorhydric states
- Gastric ulcers may become **malignant (15%)** & an ulcerated gastric cancer may mimic a benign ulcer
- Fibrosis when it occurs, may result in the now rarely seen **hour-glass contraction** of the stomach
- **Chronic ulcers** - Occur more commonly on the **lesser curve** especially at the **incisura angularis** & even when high on the lesser curve, they tend to be at the **boundary between the acid secreting & the non-acid secreting epithelia**.
- Gastric ulcers may also occur in *ectopic gastric mucosa* e.g. in **Meckel's diverticulitis**

iii) **Stomal ulcers** - occur after a **gastroenterostomy** e.g. *Billroth II type (Gastrojejunostomy)*. This ulcer is usually found on the **jejunal** side of the stoma.

## Ix - Oesophagogastroduodenoscopy (OGD)

- Biopsies of the **antrum** are taken;
  - \* to see whether there is *histological evidence of gastritis*
  - \* a **CLO test** performed to determine the *presence of H.pylori*.
- A '**U**' **manoeuvre** should be performed to exclude ulcers around the **gastro-oesophageal junction**
- In the presence of a stoma, both afferent & efferent loops must be entered as almost all stomal ulcers will be very close to the junction between the jejunal & gastric mucosa
- The **pylorus** is examined for ulcers or deformity, which is often the case with **chronic duodenal ulceration**.
- If bleeding ulcer, inject **sclerosant or adrenaline (1:10,000)**
- View **all** of the **1<sup>st</sup> part of the duodenum**.

## Surgical management of PUD Complications;

Aim;

- Reduce gastric acid secretion
- Remove the diseased mucosa

Indications;

- **Emergency Surgery - Complicated ulcers**
  - Acute **perforation**
  - Acute **massive haemorrhage**
  - Gastric outlet obstruction - **Pyloric stenosis**
- **Elective surgery - Others;**
  - *Intractability* - delayed healing or recurrence after healing, even in the absence of pain: such apparently benign ulcers can actually be malignant.
  - *Repeated episodes of minor bleeding*
  - *Fistula formation* (gastrocolic, duodenocolic, or from the duodenum into any portion of the biliary tree).



# Emergency surgery

## Haemorrhage - OHCM 224

**Incidence** - Usually the **elderly** & associated with use of **NSAIDs**

- \* **70%** - **Do not** rebleed in the same admission
- \* **5%** - Continue bleeding
- \* **25%** - **Re-bleed in same admission** - *Worry about these ones*

**Sites** - **Posterior** duodenal ulcers tend to **bleed**, sometimes by eroding a large vessel e.g. the **gastroduodenal artery**.

**Mx;**

- **Medical** - *Fibrinolysis inhibitor* e.g. Tranexamic acid
- **Endoscopic** - *Adrenaline injection (1:9), diathermy, laser coagulation or heat probe.*
- **Sx** - *The bleeding ulcer base is **underrun or oversewn***

Indications for surgery - The 25% above;

- Severe haemorrhage - A patient who has required **>6 units** of blood for resuscitation
- Rebleeding especially in the elderly (**>60yrs old**)
- Patients with a *visible vessel* in the ulcer base, a *spurting vessel* or an ulcer with a *clot* in the base
- Patient on *aspirin or anticoagulant therapy*

## Perforation

**Incidence** - Commonly in **elderly females** - **NSAIDs** appear to be responsible; Also **Smoking**

**Sites;**

- **Anterior** duodenal ulcers - **Most common (25% will perforate)**
- **Anterior & incisural** gastric ulcers

**C/P;**

- Hx of peptic ulceration
- **Crescendo abdominal pain** - Initially **severe localised abdominal pain** that climaxes then subsides to **moderate generalised abdominal pain** due to the irritant effect of gastric acid on the peritoneum
- Bacterial peritonitis
- Vomiting of large amounts of food some hours after meals

**S/S** - Peritonitis

**DDx** - Diverticulosis with perforation

**Ix;**

- **Erect AXR** - Free gas under the diaphragm
- Gastrograffin study (Barium meal is irritating to the peritoneum) - *Free peritoneal leak*
- DPL
- Serum Amylase - *to r/o acute pancreatitis*
- CT scan
- **DO NOT Endoscopy** as it blows air down the GIT that could push intestinal content into the peritoneum

**Mx;**

**Pre-op;**

- **Resuscitation & analgesia**
- **Conservative Mx** - *In patients **without** generalized peritonitis*
  - NBM, NG tube, IV antibiotics

**Sx;**

- **Laparoscopic repair of the hole** - an omental patch is placed over the perforation in the hope of enhancing the chances of sealing the leak
- **Gastric ulcers *MUST* be excised** (& tissue histology done - to exclude malignancy) & *closed*
- **If massive** - **Billroth II gastrectomy (Gastrojejunostomy)**
- *Peritoneal toilet* to remove all the fluid & food debris

**Post-op;**

- IV antibiotics
- H. pylori eradication

## Gastric Outlet Obstruction

### Causes;

- *Gastric cancer* - **Short** history in an **old patient**
- *Pyloric stenosis*;
  - Congenital - **OHCM 494**
  - 2° to **duodenal ulceration** - The stenosis is found in the **1<sup>st</sup> part of the duodenum**, the most common site for a peptic ulcer

### C/P;

- Hx of **long standing** PUD
- Vomiting **without bile**
- Weight loss, malaise & dehydration

### O/E;

- Distended stomach
- **Succussion splash** may be audible on shaking the patient's abdomen **3hrs post-prandial**

### Ix;

- The vomiting of HCL results in **Hypochloreaemic metabolic alkalosis** - Usually only seen with PUD;
  - \* Initially vomiting leads to **hypok<sup>+</sup> & alkalosis** thus initially the kidneys compensate by retaining CL<sup>-</sup> & secreting NaHCO<sub>3</sub><sup>-</sup> (*alkalotic urine*) leading to *HypoNa<sup>+</sup>* which coupled with the dehydration causes the kidney to **retain Na<sup>+</sup> & excrete H<sup>+</sup>** instead of K<sup>+</sup> because of hypokalaemia, producing **acidic urine**. Alkalosis leads to ↓Ca<sup>2+</sup>, & **tetany** can occur.
- Endoscopic biopsy to r/o malignancy

### Mx;

- Hypochloreaemic alkalosis - **NS + K<sup>+</sup>**
- Mx anaemia

**Conservative** - For early cases; Presumably as the oedema around the ulcer diminishes, the obstruction is healed

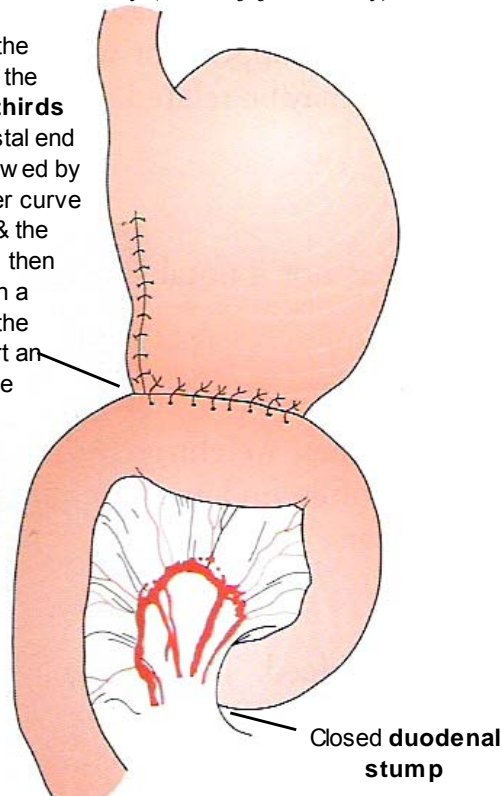
**Endoscopic** balloon dilatation followed by maximal acid suppression

**Drainage procedure** (e.g. *gastro-enterostomy* or *pyloroplasty*) ± **high selective vagotomy**

## Elective Surgery for Duodenal ulcer;

### a) *Billroth II gastrectomy/Polya Gastrectomy (Gastrojejunostomy)*

Following resection of the antrum & distal body of the stomach (**Distal Two-thirds** of the stomach), the distal end of the stomach is narrowed by the closure of the lesser curve aspect of the remnant & the greater curve aspect is then anastomosed, usually in a **retrocolic** fashion, to the jejunum leaving as short an afferent loop as feasible



### Complications;

- Leakage from the duodenal stump - associated with **kinking of the afferent loop**

b) **Gastrojejunostomy** - *Reflux alkali from the small bowel into the stomach* reduces duodenal acid exposure & is often successful in healing the ulcer

\* **Disadvantage** - Because the jejunal loop is exposed directly to gastric acid, *stomal ulceration* is extremely common hence the procedure in isolation is ineffective

c) **Truncal vagotomy & Drainage** - Involves *division of the anterior & posterior vagal trunks* at the level of the *distal oesophagus & dissection of all the nerves in the lower 7cm of the oesophagus* in order to *eliminate the 'criminal nerve of Grassi'* otherwise, appreciable vagal innervation would remain.

Based on the principle that *section of the vagus nerve;*

i) *reduces the maximal acid output* by approximately **50%** from the **stomach body & fundus**

ii) *reduces gastrin production*

iii) Causes *motor denervation* of the **antropyloroduodenal segment** *resulting in gastric stasis* thus requiring **drainage** by;

\* **Heineke-Mikulicz pyloroplasty** or

\* **Gastrojejunostomy**

d) **Truncal vagotomy & Antrectomy** - In addition to truncal vagotomy, the **antrum** of the stomach is **removed**, thus removing the source of the **gastrin**, & the **gastric remnant** is **joined to the duodenum (Billroth I)**

e) **High Selective vagotomy** - *Only the parietal cell mass* of the stomach is denervated by complete **neurovascular clearance** of the **proximal lesser curve, fundus & body of stomach, up to the lower 7cm** of the oesophagus.

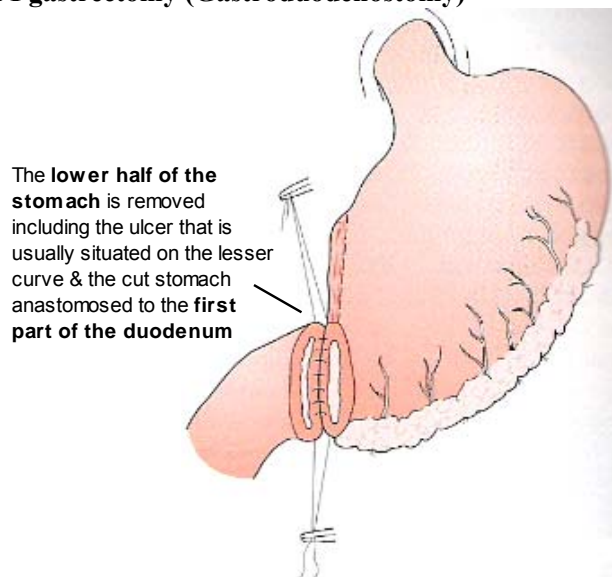
\* *The anterior & posterior vagus nerves are preserved.*

\* *The nerve of Latarjet to the pylorus is left intact; thus gastric emptying is unaffected.*

## Elective Surgery for Gastric Ulcers

Major objective is to remove the diseased tissue & although levels of gastric acid secretion are not abnormally high, acid is still a prerequisite & hence operations have been commonly used to lower acid secretion.

a) **Billroth I gastrectomy (Gastroduodenostomy)**



b) **Billroth II gastrectomy (Gastrojejunostomy)** - Used for the **high & lesser curve gastric ulcer** where gastroduodenostomy is technically difficult

c) **Vagotomy, Pyloroplasty & Ulcer excision**

# Complications of Peptic Ulcer Surgery

## i) Early & Late dumping

	Early	Late
<b>Incidence</b>	5-10%	5%
<b>Relation to meals</b>	Almost immediate	2 <sup>nd</sup> Hour after meal
<b>Duration of attack</b>	30-40mins	30-40mins
<b>Relief</b>	Lying down	Food
<b>Aggravated by</b>	More food	Exercise
<b>Precipitating factor</b>	Food, especially carbohydrate-rich & wet	As early dumping
<b>Pathogenesis</b>	Fainting & sweating after eating due to food of high osmotic potential being dumped in the jejunum leading to sequestration of fluid from the circulation into the GIT causing <b>oligaemia</b>	This is <b>reactive hypoglycaemia</b> . The carbohydrate load in the small bowel causes a rise in the plasma glucose, which in turn, causes insulin levels to rise, causing a 2° hypoglycaemia.
<b>Major symptoms</b>	Epigastric fullness, sweating, light-headedness, tachycardia, colic, sometimes diarrhoea	Tremor, faintness, prostration
<b>Treatment</b>	<b>i. Dietary manipulation</b> – Small, dry meals & avoid fluids with a high carbohydrate content <b>ii. Somatostatin analogue – Ocreotide; S/E</b> – Gallstones, does not treat diarrhoea; <b>Acarbose</b> may help to reduce the early hyperglycaemic stimulus to insulin secretion. <b>ii. Revisional surgery</b> – Antrectomy with Roux-en-Y reconstruction	

## ii) Recurrent ulceration - Manage as other peptic ulcers

**Gastrojejunalcolic fistula** forms where the *anastomotic ulcer* penetrates into the transverse colon.

**C/P** - Diarrhoea, foul breath & may vomit formed faeces

**Pathogenesis** - Severe contamination of the jejunum with colonic bacteria

**Mx** - Correct dehydration & malnutrition & do revisional surgery

## iii) Small stomach syndrome - Early satiety due to *reduced stomach size or loss of receptive relaxation following vagotomy* - Heals with time.

## iv) Bilius vomiting - Prevented by *Roux-en-Y diversion after gastrectomy*; In gastroenterostomy - *Pyloroplasty*

## v) Post-vagotomy Diarrhoea - Most patients will suffer some looseness of bowel action to some degree (with the **exception** of **highly selective vagotomy**) - Patient is managed as early dumping with *dietary manipulation & anti-diarrhoeal agents* though **ocreotide & revisional surgery are ineffective**.

## vi) Malignant transformation - **Gastrectomy or vagotomy (except High selective vagotomy) & drainage** are independent risk factors for the development of gastric cancer as **bile reflux gastritis, intestinal metaplasia & gastric cancer** are linked.

## vii) Others;

Gastrectomy causes;

- *Weight loss*
- *Bone disease* - Principally in women 2° to *osteomalacia*
- *Nutritional deficiencies* - IDA - Usually from lack of iron 2° to hypochlorhydria & stomach resection
- *Gallstones* - Following truncal vagotomy, the biliary tree, as well as the stomach, is denervated, leading to stasis & hence stone formation.
- *Blind loop syndrome* - Bacterial overgrowth ± malabsorption

## ▶ Upper GI Bleeding - OHCM 224-229

# The Stomach

Neoplastic conditions of the stomach;

- *Benign* - 5%
  - Leiomyomas
  - Neurofibromas
  - Lymphomas
- *Adenocarcinomas* - 95%
  - Well & Moderately differentiated - 30%
  - Poorly Differentiated - 70%

## Adenocarcinoma of the Stomach

Incidence

- **Commonest** GIT tumour
- **10/100,000; M>F - 2:1**
- **50-70yrs old**

Associations

✓ **Proximal gastric cancer is associated with;**

- Obesity
- High SES
- **Adenocarcinoma** of the oesophagus

✓ **Carcinoma of the *body & distal stomach*;**

- Blood Group A
- Cigarette Smoking & dust ingestion from a variety of industrial processes e.g. *Tar, asbestos, painting industries, clay & ceramics*
- Diet;
  - Spirits may induce gastritis & in the long-term, cancer
  - Deficiency of antioxidants which have been found to **inhibit carcinogenesis**, including **selenium, vitamins C and E, retinoids, & β-carotene, & plant sterols.**
  - Exposure to N-nitroso compounds (from Nitrates & Nitrites converted by bacteria in the body) - *Charred meat, Smoked fish*
  - Excessive salt intake
- **Pre-malignant conditions;**
  - **Adenomatous polyps;**
    - \* *Single* - Endoscopic resection
    - \* *Multiple* - Partial gastrectomy
  - *H. pylori* - +ve in **90%** of the general population. Also associated with;
    - \* **Gastritis**
    - \* **Intestinal metaplasia**
    - \* **Atrophic gastritis** (*pernicious anaemia*)
  - **Gastric ulcers** - They are **independent of acid secretion** & can occur in achlorhydric states. Also, **Stasis** - Antral ulcers heal by fibrosis while duodenal ulcers heal by scarring causing chronic gastric outlet obstruction
  - Patients who have had *peptic ulcer surgery* (*within 10yrs*) - Presumably **duodenogastric reflux (Bile) & reflux gastritis** are related to the increased risk of malignancy.
  - Hypogammaglobulinaemia
  - Menetrier's disease (**Hyperplastic gastropathy**)
- Low SES

# Pathology

The Adenocarcinoma may be;

- **Ulcerative - 50%**
- **Polypoid - 30%**
- **Infiltrative - *Leather bottle type (linitis plastica)* - 20%**

Some are confined to the mucosa & submucosa - '**Early**' gastric carcinoma

## a) *Lauren Classification*

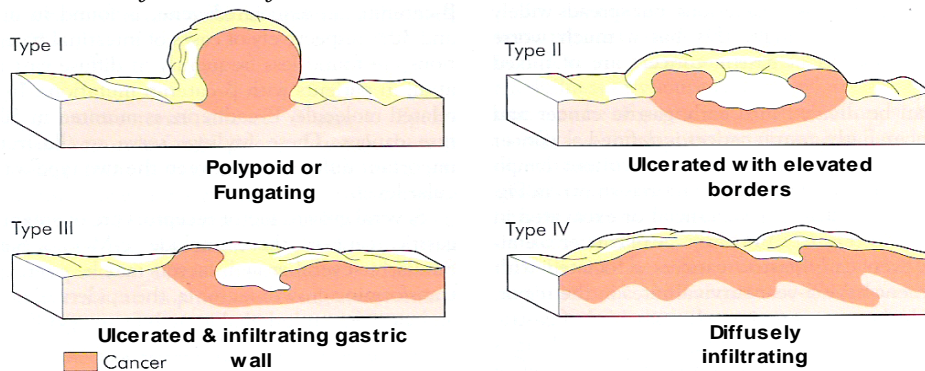
i) **Intestinal gastric cancer** - Forms *polypoid tumours or ulcers* & probably arises from areas of *intestinal metaplasia*;

- *Endemic*
- **Distal - Antrum**
- *Low SES*

ii) **Diffuse gastric cancer** - Infiltrates deeply into the stomach via **submucosal & subserosal lymphatic plexuses** *without forming obvious mass lesions*, but spreads widely in the gastric wall.

- *Sporadic*
- **Proximal - Cardia**
- *High SES*
- *Poor prognosis*

## b) *Borrmann Classification of Advanced Gastric Cancer*

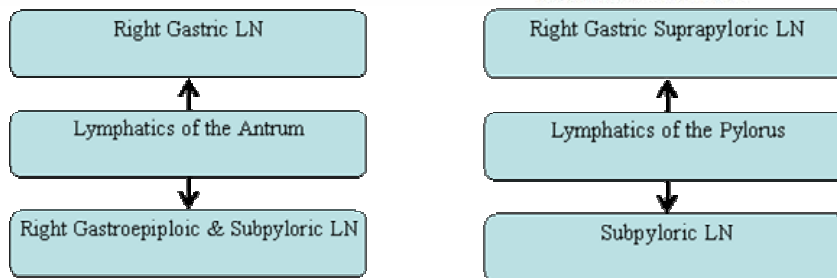
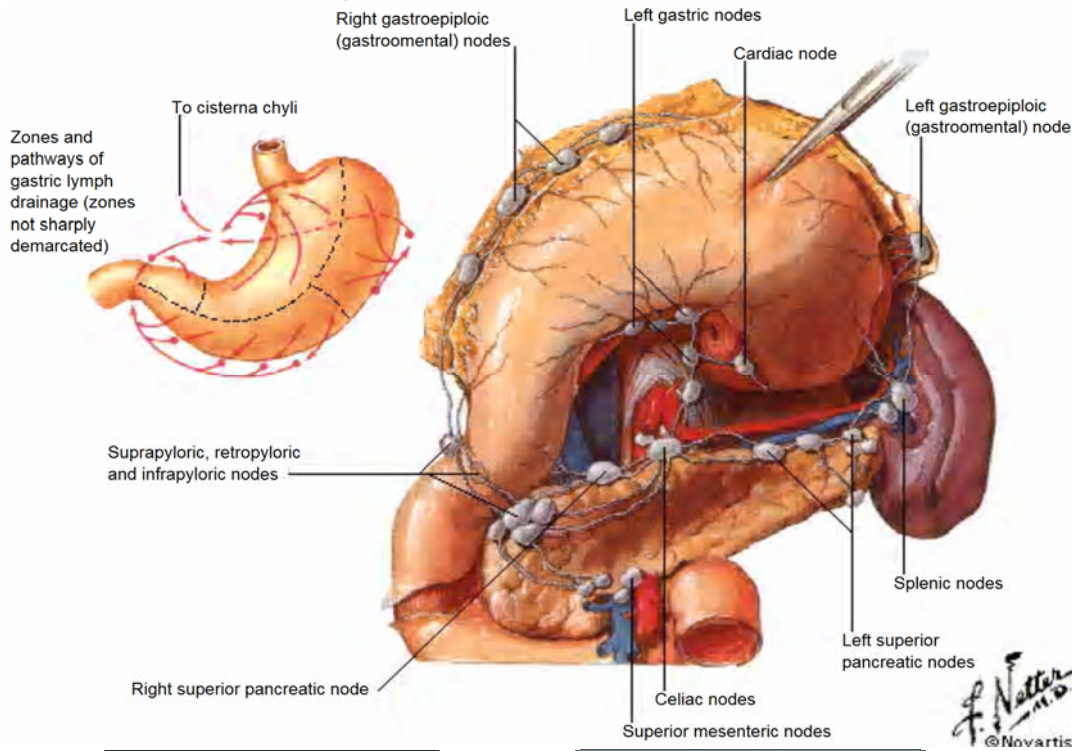


Sites;

- **Antral - 65%**
- **Body - 25%**
- **Cardia - 4%**
- **Diffuse - 6%**

## Spread

- i) **Local** - Tumour penetrates the muscularis, serosa & ultimately adjacent organs e.g. *pancreas, colon & liver*
- ii) **Lymphatic** - This is both by **permeation & embolization** to the affected tiers of nodes. *Distant metastases is uncommon in the absence of LN involvement*



\* **Suprapyloric LN** → Para aortic nodes around the coeliac axis

\* **Subpyloric LN** → Superior mesenteric LN

\* The lymphatic related to the cardiac orifice of the stomach communicate freely with those of the oesophagus.

- iii) **Haematogenous** - This occurs first to the **liver** & subsequently to other organs, including **lung & bone** - *Uncommon in the absence of nodal disease*
- iv) **Transcoelomic** - Common mode of spread once the tumour has reached the serosa & indicates incurability. Manifest anywhere in the peritoneal cavity & commonly give rise to **ascites**. Also, **ovaries (Krukenberg's tumours)**, **umbilicus (Sister Joseph's nodule)** - Detected by laparoscopy & cytology.
- v) **Transplantation** - Iatrogenic



## C/P

**New &/or Persistent Dyspepsia lasting >1month in patients aged ≥40yrs**

Suggesting incurable disease;

- i) **Anorexia**
  - ii) **Asthenia** - *Weight loss*
  - iii) **Acanthosis nigricans** - Skin disease characterized by grey-black warty patches usually situated in the *axilla or groin* or on *elbows or knees* & sometimes associated with cancer of abdominal viscera
  - iv) **Anaemia** - *IDA -from tumour bleeding*
  - v) **Ascites**
  - vi) **Achlorhydria**
    - Epigastric mass - leads to obstruction causing *dysphagia, epigastric fullness, Early satiety, bloating, distension or vomiting*
    - Hepatomegaly
    - Jaundice
    - **Troissier's sign** - *Left large supraclavicular (Virchow's) node*
- DDx; Ca**
- Nasopharyngeal carcinoma
  - Any GIT malignancy
  - Bladder
  - Prostate
  - Testes
  - Ovaries
- Non-metastatic effects - **Thrombophlebitis & DVT** - result from the effects of the tumour on thrombotic & haemostatic mechanisms (para-neoplastic)

## DDx

- Polyps
- Chronic Ulcers
- Hypertrophic gastropathy
- Leiomyomas

## Ix

- *Gastroscopy + multiple ulcer edge biopsies;*
  - Any **new dyspepsia**, however mild, in a patient **>40yrs old**
  - A patient of **any age** with **persistent dyspepsia >1 month** or **any unusual feature**
- Barium meal with contrast - *Can be used in poor resource settings*
- For staging;
  - Endoscopic U/S (Endosona) & Biopsy
  - CT/MRI

## TNM Staging

**Table 62.5** UICC staging of gastric cancer

T1	Tumour involves lamina propria
T2	Tumour invades muscularis or subserosa
T3	Tumour involves serosa
T4	Tumour invades adjacent organs
N0	No lymph nodes
N1	Metastasis in 1–6 regional nodes
N2	Metastasis in 7–15 regional nodes
N3	Metastasis in more than 15 regional nodes
M0	No distant metastasis
M1	Distant metastasis (this includes peritoneum and distant lymph nodes)

## Pre-op Bowel Preparation for Surgery;

- i) Diet;
  - From **72Hrs** pre-op - Whites only - e.g. Milk, Rice, Bread
  - **48Hrs** " " - White Foods + Clear fluids only
  - **24Hrs** " " - Clear fluids only up to **6hrs pre-op** then switch to **IVF**
- ii) ↓ Faecal material;
  - a) Diet (as above)



- a) Diet (as above)
  - b) Bisacodyl 2tabs BD/TDS - 72hrs
  - c) **Warm Soap & water (3L) Enemas BD (Morning & evening) for 72hrs + 1hr pre-op**  
\*\* In **children**, use **warm saline (4.5mL/Kg)** as water is easily absorbed leading to oedema.
  - d) NGT Polyethylene glycol (PEG) washouts
  - e) On table - Lavage with **warm saline** (*Also in emergency situations*)
- iii) **IV Antibiotics 1hr before surgery (Normal colonic bacteria concentration -  $10^{20}$ ; Antibiotic reduce to  $10^6$ )**
- *Ampicillin* - Gram +ve
  - *Gentamicin* - Gram -ve
  - *Metronidazole* - Anaerobes
- iv) **GXM - 3units**

## Mx

i) Endoscopic mucosal resection - Early tumours confined to the mucosa

ii) Gastrectomy & Resection of Local LN

- a) Total gastrectomy - For **proximal tumours (Upper 1/3-1/2)** - The **stomach** is removed en bloc, including the tissues of the **entire greater & lesser omentum** with adequate **resection margins** in the stomach (defined as a **5 cm proximal and distal clearance** in the **unstretched** stomach). Gastrointestinal continuity is reconstructed by means of a **Roux-en-Y loop** that should be at least **50cm** long to **avoid bile reflux oesophagitis**

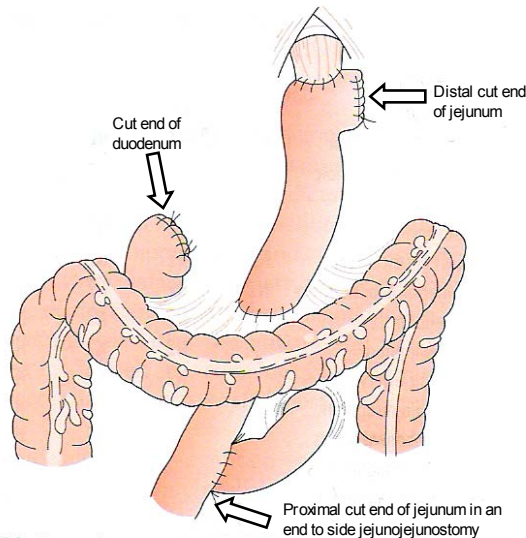


Figure 62.34 Oesophagojejunostomy Roux-en-Y.

- b) Partial gastrectomy - For **tumours in the distal 2/3**. Similar to total gastrectomy but the **proximal 1/3 stomach is preserved**, the blood supply being derived from the **short gastric arteries**. Gastrointestinal continuity is reconstructed by means of a **Roux-en-Y loop** as above.
- c) D2 Resection - Either above + N2 node resection.

iii) Palliative surgery;

Evidence of incurability;

- Haematogenous metastasis
- Involvement of the distal peritoneum
- $\geq N4$  nodal disease
- Fixation to structures that cannot be removed.

• **Resection of tumour**

• **Palliative gastrojejunostomy - Antecolic** procedure as the tumour can recur with metastasis & adhesions

• **Palliative Oesophagocolejejunostomy**

iv) Other treatment modalities

• **Chemotherapy** - *Epirubicin, Cis-platinum & 5-FU (ECF)*

• **Radiotherapy** - There are a number of radiosensitive tissues in the region of the gastric bed, which limits the dose that can be given but radiotherapy has a role in the **palliative treatment of painful bony metastases**.

## Complications of Gastrectomy

- Leakage of the oesophagojejunostomy or duodenal stump (Biliary peritonitis) - Perform a water-soluble contrast swallow at **5-7days post-op**
- Fistula from wound or drain site

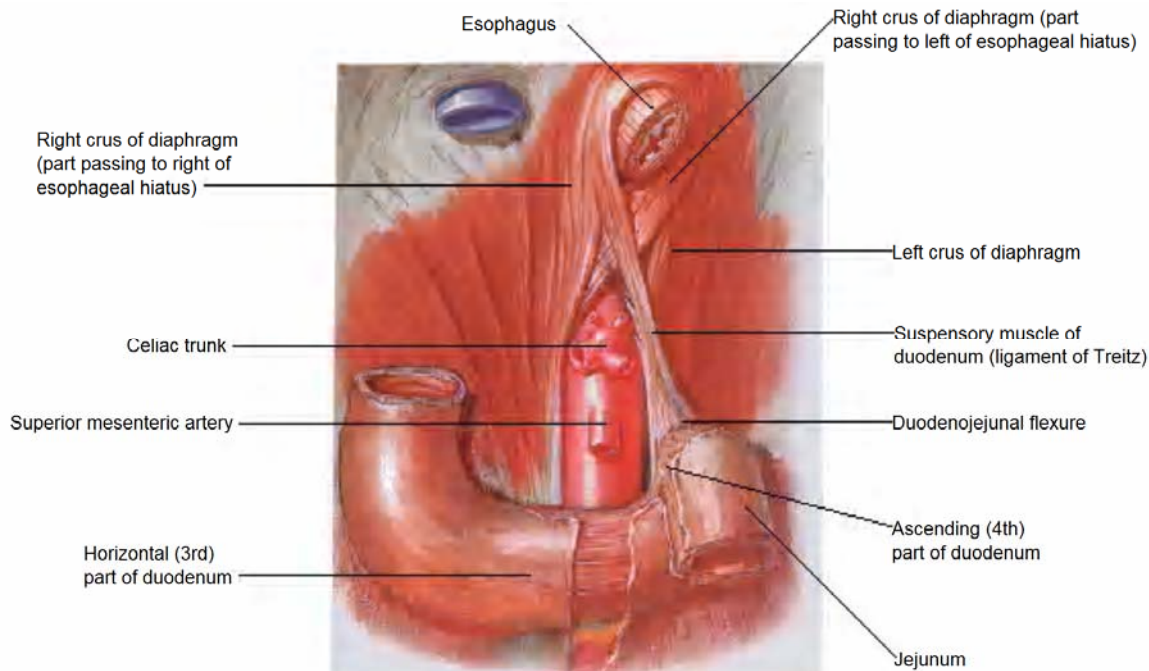
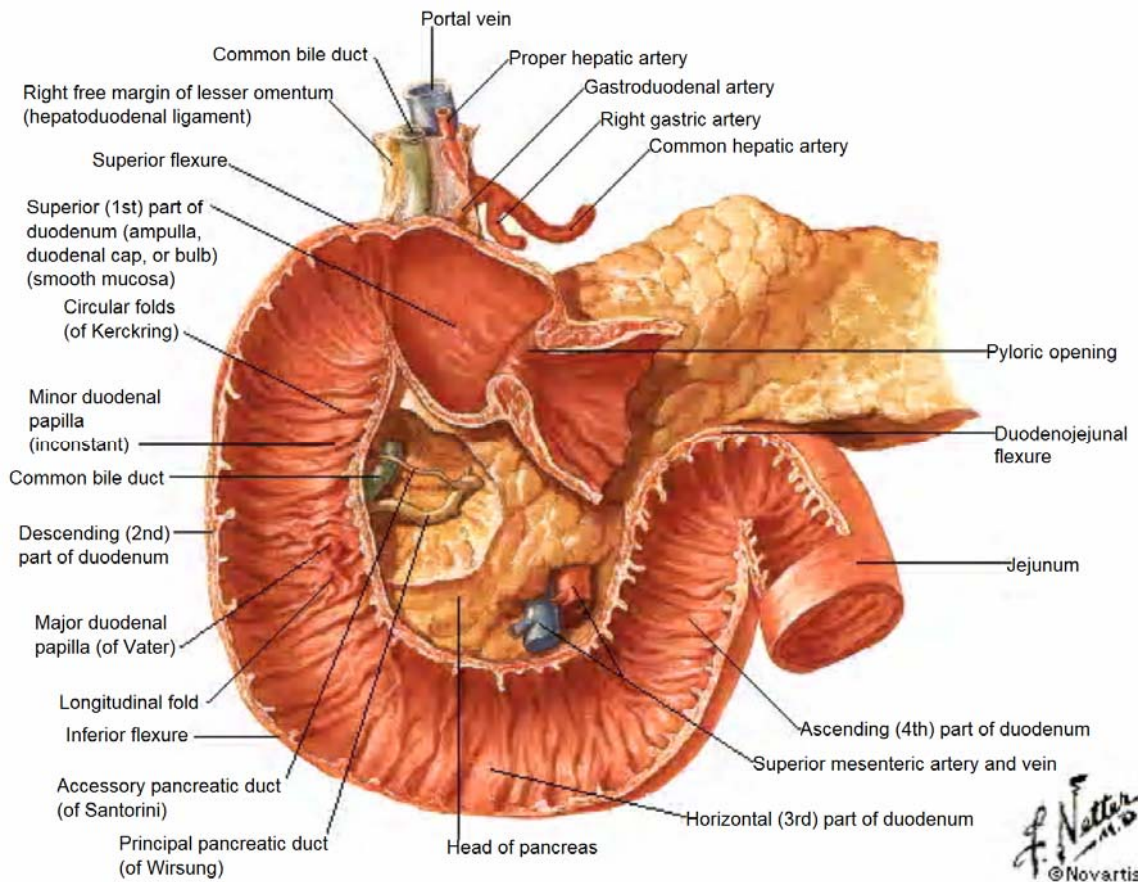
## Prognosis

- **90%** of the patients are **inoperable** at presentation & die within **7yrs**
- **5YSR - 5%**

# Anatomy of GIT

## Anatomy of the GIT

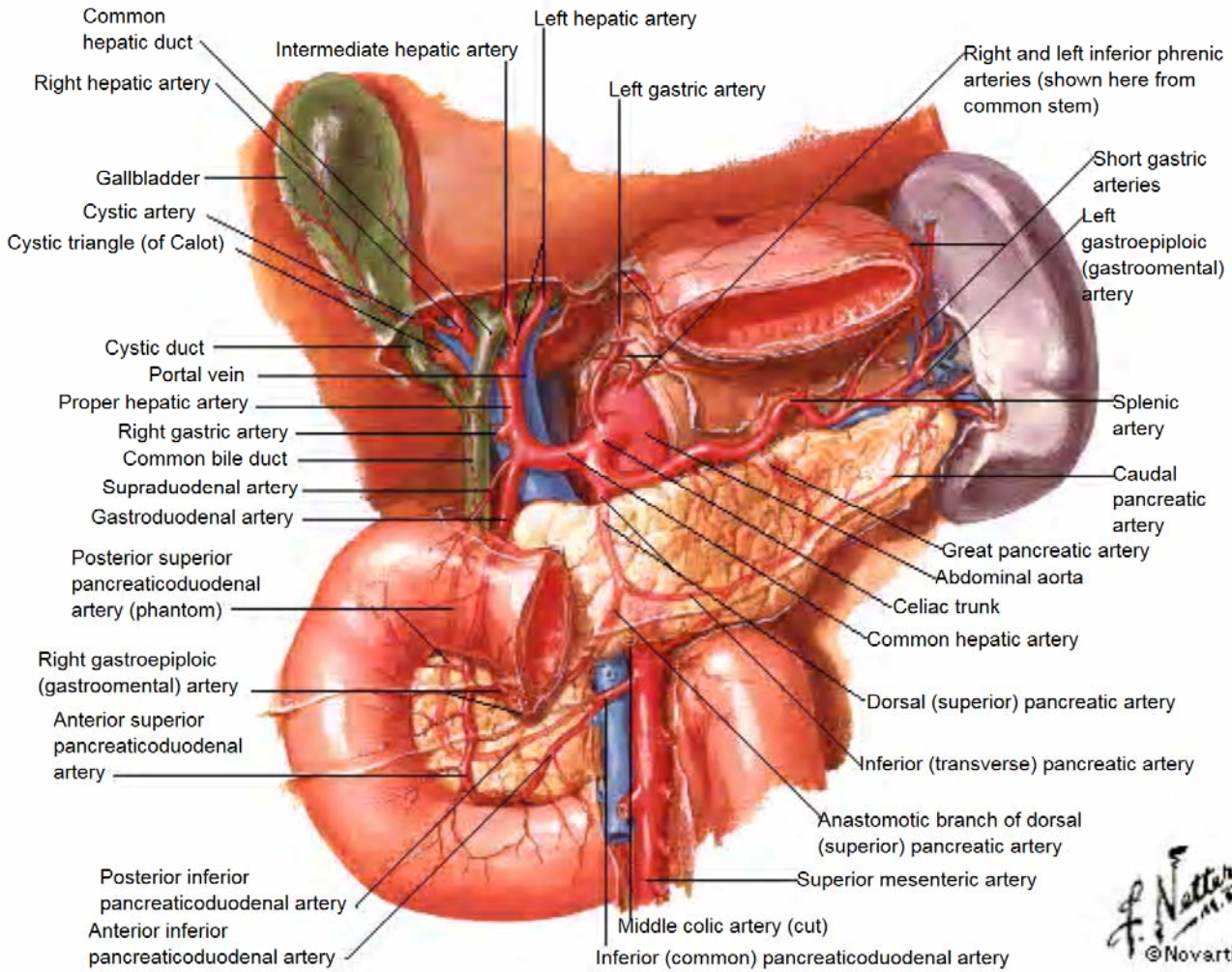
### Parts of the duodenum



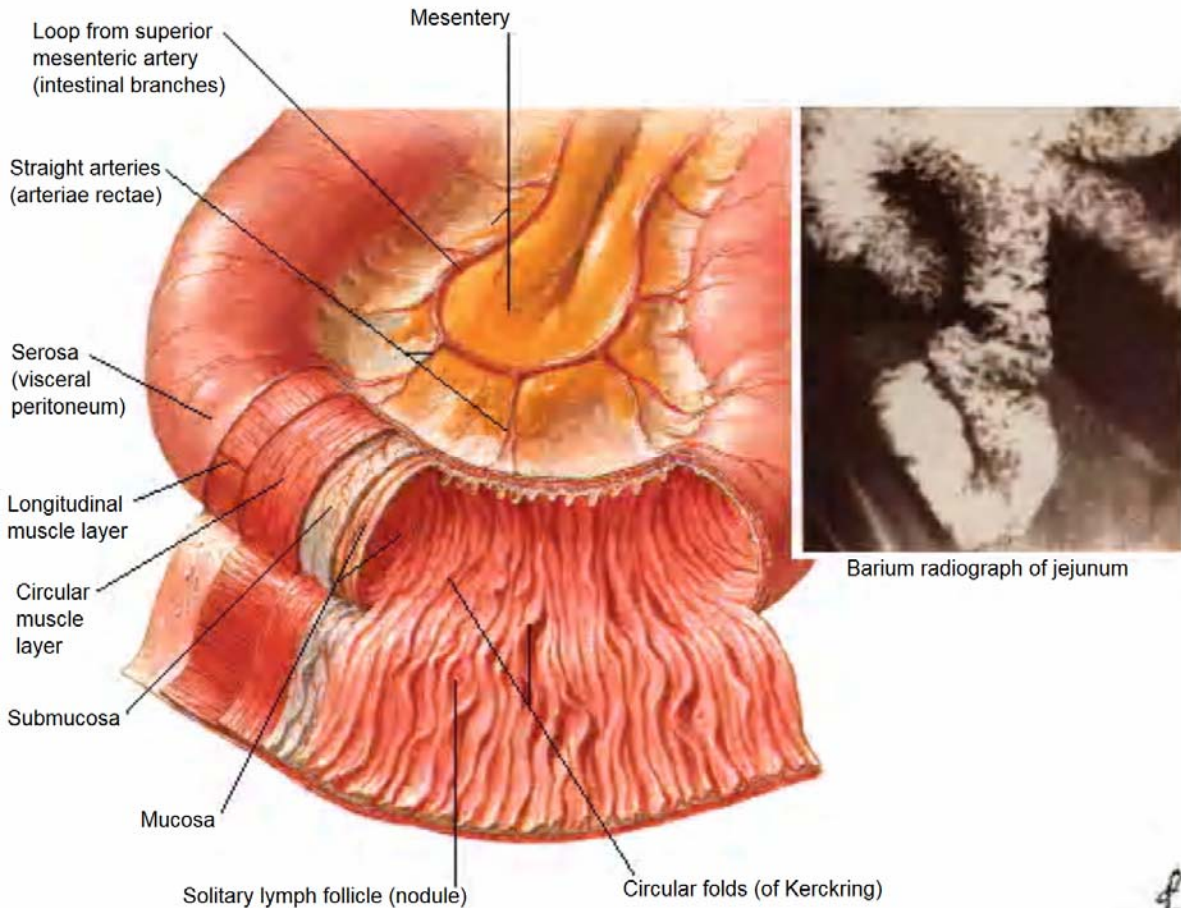
The **Ligament of Treitz** is at the junction of the **Ascending (4<sup>th</sup>) part of the duodenum & the jejunum**. It divides the GIT into **Upper GIT & Lower GIT**



# The Celiac Trunk



# Mucosa & Musculature of the GIT



# Abdominal Injury

## Acute Abdomen OHCM Pg 474

### Peritonitis

Peritonitis is defined as **inflammation** of the peritoneal cavity, where the **peritoneal fluid increases in volume** with the passage of a **transudate** rich in **leukocyte polymorphs and fibrin**.

### Types

According to extent;

1. Local peritonitis - The affected area is contained by a *wrapping of greater omentum, adjacent bowel, and fibrinous adhesions*.
2. Generalised peritonitis - If the inflammatory focus is part of an ongoing process, or if host defences are lowered, localized peritonitis may progress to life-threatening generalized peritonitis characterized by;
  - Massive exudation of inflammatory fluid into the peritoneal cavity causing **hypovolaemia**
  - **Toxaemia** from absorbed products
  - **Septicaemia** if infection is present
  - Diffuse peritoneal irritation causes **peristaltic paralysis** with the cessation of bowel motility.

According to duration;

1. Acute peritonitis
  - a) **Primary (spontaneous)** - where an infection has arisen **de novo** within the peritoneum e.g. **pneumococci (commonest)**. Also, haemolytic Streptococci, Escherichia coli, and Klebsiella spp. In adults, it occurs most commonly in conjunction with **cirrhosis of the liver** (frequently the result of alcoholism) - **≤10%**. It virtually always develops in patients with ascites.
  - b) **Secondary** - where the inflammatory process involving the peritoneum is the result of an identifiable primary process e.g.
    - i) **Acute suppurative peritonitis** - Results from;
      - **Perforation** of a viscus (e.g. appendix, peptic ulcer, bowel, diverticulum, or gallbladder)
      - **Ischemia** of an intra-abdominal organ (e.g. strangulated hernia, volvulus, mesenteric artery occlusion), or
      - Extension of an **existing infection** of an abdominal organ (e.g. appendix abscess, liver abscess, pyosalpinx).
    - ii) **Granulomatous peritonitis** - Result from infection, most commonly with **tuberculosis** but occasionally with *fungi such as Candida albicans*.
    - iii) **Chemical (aseptic) peritonitis** - Refers to the peritoneal inflammation from substances other than bacteria but bacterial contamination and overgrowth soon follow e.g.
      - A perforated **peptic ulcer** provides the **most severe and common form** of chemical peritonitis with gastric juice and bile contaminating the peritoneal cavity.
      - **Biliary peritonitis** alone may follow gangrene and perforation of the gallbladder, or, after cholecystectomy, may be the result of unrecognized division of an accessory hepatic duct, an insecure ligature on the cystic duct remnant or displacement of a T-tube following exploration of the common bile duct.
      - **Blood** in the peritoneum is also a cause of peritoneal irritation after slow bleeding (e.g. a *ruptured graafian follicle or following splenic injury*)
      - **Meconium** and **urine** may also precipitate chemical peritonitis.
    - iv) **Interventional peritonitis;**
      - **Viscus perforation** following *endoscopy, cystoscopy, CT guided biopsy and drainage, PTHC and stenting*
      - Peritonitis may follow *abdominal surgery* following **anastomotic dehiscence**.
      - In patients with renal failure treated by **CAPD**, a permanent indwelling catheter in the abdominal cavity provides a portal of entry for exogenous bacteria
    - v) **Traumatic peritonitis** secondary to *abdominal trauma*
    - vi) **Drug-induced peritonitis** - **Warfarin** anticoagulation can cause peritoneal irritation and peritonitis through leakage from a spontaneous retroperitoneal haematoma. The symptoms of acute peritonitis have also been described during treatment with the antituberculous agent, **isoniazid**.

2. Chronic (sclerosing) peritonitis - Characterized by **dense adhesions**, especially *between loops of small bowel*, and in the most extreme cases the *entire small bowel and even the large intestine and liver* is cocooned in a dense adhesive membrane of fibrous tissue. This is the end result of;

- Infections e.g. TB
- Drug-induced
- Chemical e.g. *Talc in gloves*
- Foreign body
- Carcinomatosis

## Cardinal Symptoms

- Patient lying still
- +ve Cough test
- Guarding
- Board-like abdominal rigidity (May be absent in the elderly)
- Rebound tenderness
- No Bowel sounds

## Differences between Somatic Pain & Visceral pain

### Somatic Pain

- Localised, sharper, brighter & lateralised
- Transmitted through *intercostal & phrenic nerves* to CNS
- Irritation of *parietal peritoneum, root of mesentery & diaphragm*

### Visceral pain

- Dull, vague & poorly localised; **Not** lateralised
- Transmitted through *sympathetic & parasympathetic nerves*
- Increased tension in wall, stretching of capsule of solid organ, ischemia & certain chemicals

## Mx

### Pre-op;

- **NGT** aspiration to reduce abdominal distension and prevent aspiration pneumonia through inhalation of vomitus
- **Analgesia** - Opiate analgesics
- Correction of hypovolaemia and electrolyte imbalance by **IVI** fluid replacement
- **Antibiotic** therapy (against both aerobes and anaerobes)

Surgical intervention is the treatment of choice and in most cases is mandatory, being aimed at the primary disease process.

# Abdominal Injury

## Regions of the Abdomen

- a) Peritoneal cavity;
  - i) Intrathoracic segment - Covered by bony thorax up to 5<sup>th</sup> ICS & includes;
    - Diaphragm
    - Stomach
    - Liver
    - Spleen
    - Transverse colon
  - ii) Abdominal segment - Small intestines, Caecum, Appendix, Sigmoid colon & 1<sup>st</sup> part of Rectum
- b) Retroperitoneum;
  - Abdominal Aorta
  - IVC
  - Pancreas
  - Kidneys
  - Ureters
  - Duodenum, Ascending & Descending colon
- c) Pelvic organs;
  - Iliac vessels
  - Bladder
  - Female internal genitalia
  - 2<sup>nd</sup> & 3<sup>rd</sup> part of rectum

## Types

- Blunt injury
- Penetrating injury

## O/E

- Thoracic cage
- Back
- P/A;
  - **London's sign** - Patterned abrasion on the abdomen suggesting blunt trauma e.g. sole of shoe
  - Listening for bowel sounds is **NOT** useful
- Pelvis including perineum & DRE for;
  - Anal tone
  - Prostatic position
  - Blood or other evidence of injury
- Indications for **Emergency laparotomy** without further investigations;
  - \* **Shocked patients with signs of intra-abdominal haemorrhage** e.g. peritonism or increasing distension
  - \* **Penetrating trauma**
  - \* **Evisceration**
  - \* **Peritonism**

## Ix

- i) Gastric aspirate
- ii) Urinalysis
- iii) Erect AXR or Lateral Decubitus if patient cannot stand - Free intraperitoneal gas is seen;
  - Erect - Under surface of diaphragm
  - Lateral decubitus - Under surface of Abdominal wall
- iv) **Abdominal U/S** - Specific in detecting haemoperitoneum; Also **Focussed Abdominal Sonography for Trauma (FAST)**
- v) "One shot" IVU

vi) **Diagnostic peritoneal lavage (DPL)** - Detects free blood in the abdominal cavity with **97%** accuracy;

**Indications;**

- Haemodynamic instability with unreliable clinical findings e.g. due to *head injury, intoxication or paraplegia*
- Abdominal examination is equivocal e.g. *lower rib, lumbar spine or pelvic fractures* causing abdominal tenderness & tensing
- Abdominal examination of a repeated nature is impractical because of anticipated lengthy X-Ray studies or GA for extra-abdominal injuries

**Contra-indications;**

- \* Absolute;
  - An existing indication for emergency laparotomy
  - Unconscious patient
  - History of peritonitis
- \* Relative (Use **supra-umbilical open method**);
  - Pregnancy
  - Significant obesity
  - Previous abdominal surgery due to ± adhesions of viscera to abdominal wall
  - Pelvic fractures

**Procedure;**

- i) Insert NG tube & urinary catheter
- ii) **Open (Preferred)** or Closed methods
- iii) Inject local anaesthesia **2cm below** the umbilicus
- iv) Make a small midline incision & do blunt dissection through the linea alba to the peritoneum
- v) Insert a catheter to drain the peritoneum
- vi) If nothing comes out; attach a bottle of **20mL/Kg (~1L) NS** on opposite side of catheter over **15-20mins** & invert the same bottle to drain it.

**Criteria for +ve DPL;**

- a) Clinical criteria;
  - \* Initial drainage of **>10mL frank blood.**
  - \* Egress of lavage fluid through chest drain or urinary catheter
  - \* Bile or vegetable matter in lavage fluid
  - \* Inability to read newsprint through the tubing leading from the peritoneal drainage catheter because of the presence of blood
- b) Laboratory criteria;

Test	Blunt Trauma	Penetrating Trauma
<b>RBC;</b>		
· <b>Definite injury</b>	>100,000/mL	>20,000/mL
· <b>Indeterminate</b>	50-100,000/mL	5-20,000/mL
<b>WCC</b>	>500/mL	
<b>Amylase</b>	>20IU/L	
<b>ALP</b>	>10IU/L	

False -ves; *Isolated injuries to the;*

- Diaphragm
- Duodenum
- Pancreas
- Small bowel
- Bladder

vii) **Contrast enhanced CT Scan;**

**Indications;**

- To asses retroperitoneum
- Indeterminate DPL
- C/I DPL
- Persistent abdominal pain despite a -ve DPL
- Penetrating flank trauma
- Mild abdominal tenderness in alert patients

**C/I** - Haemodynamically unstable patients

**Sensitivity;**

- Sensitive for injury to solid organs e.g. splenic injury
- **Not** sensitive to bowel & pancreatic injury (*Helical abdominal CT has higher sensitivity for*



*detecting blunt bowel injury)*

- Free fluid in the abdominal cavity suggests an injury to GI tract &/or it's mesentery

## Mx

- i) Put NG tube & aspirate
- ii) Catheterize
- iii) IVI NS
- iv) Vitals every 15mins in the acute stage
- v) Take & record serial measurements of the *abdominal girth with the umbilicus as the reference point*
- vi) Take & record serial *bowel sounds*
- vii) Monitor & Repeat above if **no** acute abdomen **3-4hourly**
- viii) Indications for Laparotomy;
  - Acute abdomen
  - Gunshot wounds
    - \*\*Never probe** a penetrating wound **except in gunshot injuries under local anaesthesia with no evidence of Blood, Urine or Faeces in the abdomen.**
  - Deterioration despite **adequate** resuscitation
  - Free intraperitoneal gas on AXR
  - +ve DPL
  - Penetrating injuries with;
    - Evisceration
    - Leakage of GIT contents or Bile
    - Diaphragmatic injury
  - **Consider** laparotomy if *NG tube aspirate, Catheter or DRE* are **bloody**

# Splenic Injury

## Causes;

- Blunt abdominal trauma
- A fall with a diseased or enlarged spleen
- Fractured overlying ribs - **9, 10, 11**
- Iatrogenic complications of any surgical procedure especially those in the LUQ when adhesions are present.

## C/P;

- The patient succumbs rapidly from massive haemorrhage, usually as a consequence of trauma
- Initial shock, recovery, signs of late bleeding

## O/E;

- **Splenic syndrome;**
  - Pain in LUQ
  - **Kehr's sign** - Referred pain felt in the **left shoulder or cervical region** - Demonstrated **15mins** following elevation of the foot of the bed.
- **Balance sign** - On percussion;
  - Dull note on Left is wider than Right
  - When the patient is turned on the Right, the dull note persists on the Left. When the patient is turned on the Left, the dull note on the Right side goes

## Ix;

- **CXR** - **2** gastric bubbles

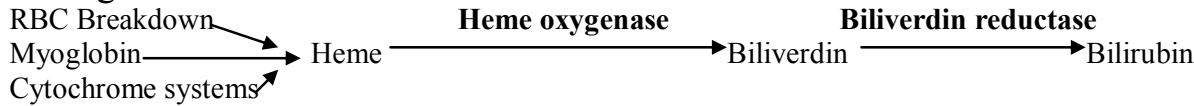
## Mx;

- **Conservative Mx;**
  - \* Indications;
    - **Stable** patients **<55yrs** in whom associated abdominal injuries have been excluded
    - **Children** - Haemodynamically stable or requires replacement of **<1/2 of estimated blood volume** (i.e. Requires **<40mL/Kg**)
    - Absence of hilar involvement & massive disruption of the spleen
  - \* Mx;
    - **Admit & observe** for **10-14days**, then **Bed rest** for **1wk**
    - **No** strenuous activity for **6-8wks**
    - **No** contact sport for **6 months**
- **Spleen conserving surgery for *Minor capsular parenchymal injuries;***
  - i) Topical haemostatic agents
  - ii) Careful compression of the spleen to control bleeding - Can be achieved using the omentum
  - iii) Parenchymal injuries involving the *lower or upper pole* may be managed by *partial segmental resection*.
- **Immediate splenectomy + Polyvalent pneumococcal vaccine;**
  - Severe multiple injuries
  - Splenic avulsion
  - Fragmentation or rupture (Delayed rupture of contained subcapsular hematoma can occur several days after splenic injury, usually within **48hrs**)
  - Extensive hilar injuries
  - Failure of haemostasis
  - Peritoneal contamination from GI injury
  - Rupture of diseased spleen

# Jaundice in Children

## Jaundice and Hyperbilirubinemia in the Infant - OHCM 222

### Pathogenesis



Bilirubin occurs in plasma in four forms:

- **Unconjugated bilirubin** - *Lipid soluble, Indirect reacting*
  - Free/unbound* - the form **responsible for kernicterus**, because it can cross cell membranes
  - Albumin bound*
- **Conjugated bilirubin** - *Water soluble, Direct reacting*
  - Free/unbound* - the only fraction to **appear in urine**
  - Albumin bound ( $\delta$  fraction)* - which appears in serum when **hepatic excretion of conjugated bilirubin is impaired** in patients with hepatobiliary disease. The  $\delta$  fraction permits conjugated bilirubin to persist in the circulation and delays resolution of jaundice.

The colour usually results from the accumulation in the skin of bilirubin  $>35\mu\text{mol/L}$ . Mild elevations of bilirubin may have *antioxidant* properties.

### Aetiology.

- **Pre Hepatic** – Rare.  $\uparrow$  Indirect/unconjugated bilirubin.
- **Hepatic** –  $\uparrow$  AST/ALT.  $\uparrow$  both direct and indirect bilirubin. Caused by *HIV, Hepatitis A/B/C, CMV, EBV*
- **Post hepatic** -  $\uparrow$   $\gamma$ GT/ALP.  $\uparrow$  Direct (conjugated) bilirubin. **Pruritus**, intense generalized itching especially at **night**, may occur in patients with cholestasis (conjugated hyperbilirubinemia) presumably owing to retained components of bile such as **bile salts**. Treat with *bile acid-binding agents* such as **cholestyramine** or *choleric agents* such as **ursodeoxycholic acid or phenobarbital**.

### DDx

- **Pre-hepatic;**
  - Congenital Haemolytic Anaemias
  - Infection e.g. TORCHES, Hepatitis B/C, HIV, malaria parasites. Hepatitis A causes more acute symptoms of nausea, vomiting and diarrhoea.
  - Hypoproteinemia
  - Displacement of bilirubin from its binding sites on albumin by competitive binding of drugs such as *sulfisoxazole and moxalactam; oxytocin* and chemicals employed in the nursery such as *phenolic detergents*.
  - Acidosis
  - Increased free fatty acid concentration secondary to *hypoglycaemia, starvation, or hypothermia*
- **Hepatic** - Infection e.g. Hepatitis B/C, CMV, Rubella
- **Post-hepatic (Obstructive jaundice);**
  - Congenital;
    - \* Biliary atresia
    - \* Biliary stenosis 2° to *aberrant vessels, aberrant bands, Failure of recanalization*
    - \* Annular pancreas
  - Choledochal cysts - *Intermittent S/S*
  - Gall stones - *Intermittent S/S*
  - Migrating Ascaris - In older children
  - Generalised lymphadenopathy with *LN at the porta hepatis*

### Ix;

- **Total bilirubin** – 3.4 – 17.1  $\mu\text{mol/L}$
- **Direct Bilirubin** – 0 – 3.4  $\mu\text{mol/L}$
- **LFTs**
  - **Total protein** – 60 – 80 g/L
  - **Albumin** – 35 – 50 g/L
  - **ALT & AST** – 5 - 45 U/L
  - **$\gamma$ -GT** – 5 – 32 U/L

$\gamma$ -GT – 5 – 32 U/L

- **ALP (& 5' Nucleotidase** - Confirms **ALP** elevation is **hepatic** (not from bone))

# Congenital Biliary Atresia

## Types

- I - **Extrahepatic - Distal segmental CBD obliteration** with *patent extrahepatic ducts up to the porta hepatis*. This is a surgically **correctable** lesion, but it is **uncommon**.
- II - **Intrahepatic - Obliteration of the entire extrahepatic biliary tree at or above the porta hepatis**. This presents a much more difficult problem in surgical management (**uncorrectable**).

## C/P

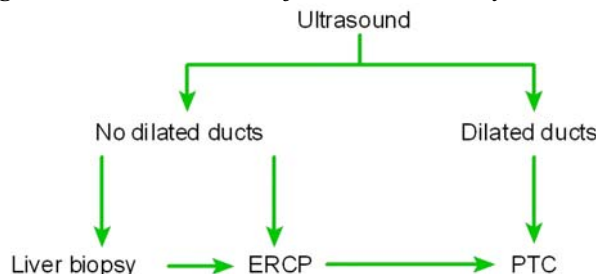
- **Icterus** starting **>1wk old - Deep green** - Check nail bed & tip of nose
- **Pruritus** mostly at **night**
- Persistently **light clay coloured or acholic stools** due to the **absence of stercobilinogen** and **steatorrhea**.
- **Dark urine** caused by **conjugated bilirubinuria**
- **Hepatomegaly**; *initially* enlarged and smooth but as the disease progresses and the liver becomes cirrhotic; it becomes small, firm and granular/nodular. Gall bladder may be palpable if dilated.
- **Bleeding disorders**

## DDx

- Choledochal cysts
- Biliary stenosis 2° to *aberrant vessels, aberrant bands, Failure of recanalization*
- Annular pancreas

## Investigations

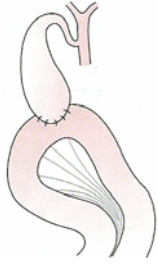
- Urinalysis for bilirubin levels
- Stool for stercobilinogen
- LFTs;
  - \* **Direct** bilirubinaemia (0–3.4µmol/L)
  - \* **↑ALP** - *Excreted through biliary tree*; ± **↑ AST/ALT** - *If hepatocyte damage present*
  - \* **PTI** - (>75% / INR (0.9-1.2))
  - \* **↑γ proteins**
- Duodenal aspirate - *Presence of bile r/o biliary atresia*
- **Fasting abdominal ultrasound for Liver & Biliary tree anatomy**;



- \* Diagnostic features;
  - *Dilatation of biliary ducts*
  - **Triangular cord** of fibrous tissue at the **porta hepatis (90%)** - indicative of biliary atresia
- \* ± Poor or no flow of bile distally
- \* ± Dilated gall bladder - *If present can be used to bypass the obstruction*
- U/S guided Percutaneous TransHepatic Cholangiography (PTHCh) - *Done if U/S shows dilated ducts, dye is injected into the left hepatic duct to map out the biliary tree.*
- **Hepatic ImmunoDiacetic Acid (HIDA) Cholescintigraphy**

Mx

- Administration of **Vit. K** 10mg/d **IV** for **3d** + **platelets** (Vitamin K is *not* given IM as it may cause haemolysis & haematoma formation at site) should be considered in the initial management of cholestatic infants in order to prevent haemorrhage. Aim for a **PTI >75%**. Also **vitamins A, D, E**
  - Proper **hydration** to prevent **hepatorenal syndrome**
- ▶ **Type I - If gall bladder dilated;**  
a) **Cholecystojejunostomy**



Some surgeons also perform an **enteroenterostomy** in addition so that;

- \* Intestinal contents are diverted from the biliary tree to **avoid food impaction**
- \* Also to **avoid bile reflux**

**OR**

b) **Choledochojejunostomy** - *Anastomosis between the **CBD** (above the obstruction) and the jejunum*

- ▶ **Type II - Hepatopertoenterostomy procedure of Kasai Kimura** can be carried out. The rationale for this operation is that minute bile duct remnants, representing residual channels, may be present in the **fibrous tissue of the porta hepatis**; such channels may be in direct continuity with the intrahepatic ductule system. In such cases, **transection of the porta hepatis until there is evidence of dilated bile ducts with anastomosis of bowel mucosa** to the proximal surface of the transection may allow bile drainage.

If flow is not rapidly established within the first **4-6 months of life**, progressive obliteration and cirrhosis will ensue. The Kasai operation is most successful (**90%**) if performed **before 8 wk** of life. Some patients with biliary atresia, even of the "noncorrectable" type, derive long-term benefits from interventions as the Kasai procedure. In most, however, a degree of hepatic dysfunction persists. Patients with biliary atresia usually have **persistent inflammation of the intrahepatic biliary tree**, which suggests that biliary atresia reflects a **dynamic process** involving the entire hepatobiliary system. This may account for the ultimate development of complications such as **portal hypertension**.

The short-term benefit of hepatopertoenterostomy is **decompression and drainage** sufficient to forestall the onset of cirrhosis and *sustain growth until a successful liver transplantation can be done*.

Long term - **Liver transplantation;**

- i) **Othrotopic** - *Same site*
- ii) **Heterotopic** - *Different site e.g. RIF*

**Post-Op** - Cover with prophylactic antibiotics (*metronidazole + cefuroxime*) to prevent **ascending cholangitis**

## Choledochal Cyst

*Cystic dilatation* of part of the biliary tree 2° to *reflux of pancreatic juices* into the CBD leading to weakening of the wall of the CBD

**Types; (Areas of dilatation)**

- Hepatic ducts
- Common Bile duct
- At the sphincter of Oddi - *Choledochocele*
- Multiple - *Congenital & unresectable - Caroli's Syndrome*

**Dx triad;**

- Intermittent Jaundice
- Abdominal mass
- Abdominal pain

**Mx - Sx;**

- Excise cyst + *Cholecystojejunostomy*
- If not possible then *excise mucosa* to avoid it becoming **malignant**

# Intestinal Obstruction

## *Interference with the normal caudal progression of intestinal contents*

### Classification

#### a) **Functional/Adynamic** - *Absent peristalsis* e.g. paralytic ileus or *Peristalsis present in a non-propulsive form*

##### Causes;

##### i) Congenital

- Prematurity
- Mucosal enzyme deficiency
- Neurovascular defects e.g. *Hirschsprung's disease*

##### ii) Acquired

- Peritonitis
- Retroperitoneal lesions
- *Chronic* intestinal obstruction
- Simple handling of the gut e.g. laparotomy
- Drugs e.g. *Opiates, Metoclopramide*
- Systemic causes - *Electrolyte imbalance* ( $\downarrow K^+$ ,  $\downarrow Ca^{2+}$ ) · *Septicaemia, Toxaemia*
- Neurovascular defects e.g. *Mesenteric arterial thrombosis*

##### C/P;

- There is **no pain**
- *Non projectile* vomiting  $\pm$  constipation
- Bowel sounds are **absent**

#### b) **Mechanical/Dynamic** - Where peristalsis is working against a *mechanical obstruction*;

##### i) **Intraluminal**

- Congenital
  - \* Meconium plug
  - \* Imperforate anus
- Acquired
  - \* Faecal Impaction
  - \* Worms (*Ascaris lumbricoides*, Tapeworms) especially **after** antihelminthic administration
  - \* Gallstone ileus
  - \* Bezoars
  - \* Iatrogenic e.g. gauzes

##### ii) **Extraluminal**

##### \* *Intramural*;

- Congenital
  - \* Atresia
  - \* *Hirschsprung's disease*
  - \* Diverticulitis
  - \* Congenital Hypertrophic Pyloric stenosis
- Acquired
  - \* Acquired megacolon
  - \* Intussusception
  - \* Strictures (post irradiation)
  - \* Stenosis
  - \* Tumours

##### \* *Extramural*;

- Adhesions (Post laparotomy)
- Hernias
- Malrotation - *Sigmoid or Caecal Volvulus*
- Extrinsic masses e.g. lymphomas





## Types of Obstruction

### According to duration

- a) **Acute obstruction** - Usually occurs in **small bowel obstruction** with sudden onset of *severe colicky central abdominal pain, distension & early vomiting & constipation*; If vomitus is **bilious stained**, the obstruction is **distal** to the 2<sup>nd</sup> part of the duodenum
- b) **Chronic obstruction** - Usually in **large bowel obstruction** with *lower abdominal colic & constipation, followed by distension*.
- c) **Acute on chronic** - There is a *short history of distension & vomiting* against a *background of pain & constipation*
- d) **Subacute obstruction** - *Incomplete/Partial obstruction* usually caused by **adhesions** following laparotomy

### According to Blood supply

- a) **Simple** - *Blood supply is intact*
- b) **Strangulated** - Strangulated bowel causes loss of blood/plasma like fluid, gut becomes gangrenous with leakage of contents into peritoneal cavity → *Peritonitis*; Toxins may be absorbed into the circulation → *Toxaemia*

#### Causes;

- 1° - Mesenteric infarction
- 2° -
  - External;
    - Intraperitoneal Adhesions/Bands
    - Hernial rings
  - Interrupted blood flow;
    - Volvulus
    - Intussusception
  - Increased intraluminal pressure - *Closed loop obstruction*

#### C/P;

- *The patient is more ill than you would expect*
- **Blood in stool** - Indicative of an ischemic process at the level of obstruction
- **Peritonism** - A symptom complex marked by **vomiting; sharper, constant localised pain, and shock** associated with inflammation of any of the abdominal viscera in which the peritoneum is involved.
  - Tenderness with rigidity
  - Fever & ↑WCC
  - ↑ K<sup>+</sup>, Amylase or LDH

## Pathophysiology

Initially, **peristalsis is increased proximal to the obstruction** to overcome the obstruction, with the **length of time** it remains vigorous being **proportional** to the **distance of obstruction**. If the obstruction is not relieved, the bowel begins to **dilate**, causing a reduction in peristaltic strength, ultimately resulting in **flaccidity & paralysis**. This is a **protective phenomenon** to prevent vascular damage 2° to increased intraluminal pressure.

The **distension proximal to an obstruction** is produced by;

- i) **Gas;**
  - \* Nitrogen (**90%**) & H<sub>2</sub>S from bacterial action (O<sub>2</sub> & CO<sub>2</sub> is reabsorbed)
  - \* Aerophagy
- ii) **Fluids/24hrs;**
  - \* Saliva - 1-1.5L
  - \* Gastric juice - 1.5-2L
  - \* Bile - 1L
  - \* Pancreatic juices - 1.5L
  - \* Succus entericus (Small Intestinal juice) - 3L
- iii) **Faeces**
- iv) **Hypertrophy of the muscles of the gut** *if the obstruction is long standing*

**Distal to obstruction** - The bowel exhibits **normal peristalsis & absorption** until it becomes empty, when it **contracts & becomes immobile**.

S/S

**Cardinal symptoms;**

- i) **Colicky abdominal pain**
- ii) **Abdominal Distension**
- iii) **Constipation** - initially stool may be reduced in quantity progressing to constipation
  - \* **Absolute (Obstipation)** - No faeces or flatus passes
  - \* **Relative** - Flatus but no faeces especially if **obstruction is high**
- iv) **Vomiting (with relief)** →
  - \* Dehydration - most commonly in *small bowel obstruction*
  - \* Signs of Shock - ↓urine output (Adults- 30-50mls/hr; Children- 0.5-1ml/Kg/hr), ↑pulses, ↓BP
  - \* Hypochloreaemic metabolic alkalosis with Paradoxical aciduria
  - \* Hypokalaemia

**Others**

- Fluid & electrolyte deficiencies due to;
  - Reduced oral intake
  - Defective intestinal absorption
  - Sequestration into lumen of bowel (*Osmotic flow*)
  - Vomiting
- Anorexia

• **Small Bowel Obstruction;**

C/P;

- **Proximal;**
  - \* Pain is **higher** in the abdomen (*may be absent in long standing cases e.g. long standing atresia in children*)
  - \* Minimal distension
  - \* Profuse **early vomiting** with rapid dehydration
  - \* **Little evidence of fluid levels on AXR**
- **Distal;**
  - \* Pain is at the **centre** of the abdomen
  - \* **Central** abdominal distension
  - \* **Vomiting is delayed**
  - \* **Multiple central fluid levels are seen on AXR**

• **Large Bowel Obstruction;**

C/P

- \* Pain is more **constant**
- \* If the ileocaecal valve is;
  - **Competent** - Pain may be felt over a distended caecum - **Closed loop Obstruction**
  - **Incompetent** - **Gross abdominal distension** ± faecal vomitus if chronic
- \* Vomiting is **late or absent**
- \* Active '**tinkling**' bowel sounds 2° to presence of **large air pockets**

O/E

- **Rising pulse**

P/A

- **Visible** peristaltic movements if **dynamic**
- Generalised abdominal tenderness & rigidity ± mass
- **Resonant** on percussion
- **DO NOT** do **DRE or Enema evacuation** if you intend to do an **AXR** as this will stimulate GIT contractions.

## Ix

### • AXR - *Supine & Erect*;

i) Abnormal **Gas patterns** (gas in the *fundus of stomach & throughout the large bowel* is normal) is best seen on **Supine AXR**.

- **Small Bowel Obstruction** - **Central** gas shadows & **NO** gas in the large bowel & is ~ **3-6cm wide**;

\* The **jejunum** is centrally placed & identified by **pronounced valvulae conniventes** that **completely cross the lumen** - **concertina effect** (Like curtain gatherings)

\* The **ileum** has **NO** characteristics

- **Large Bowel Obstruction** - Gas is **proximal** to the block (e.g. in caecum) but **not in the rectum**

\* The Large bowel has **few peripheral loops & haustral (scalloped patterned) folds** that **do not cross all the lumen's width** & is ~**5cm wide**.

ii) On **Erect AXR** look for **horizontal Fluid levels** - **>3** confirm intestinal obstruction in **adults (>5** - in **children)**. The fluid levels must be **>2.5cm** in height; *May be absent in proximal small bowel obstruction*.

• **Barium enema** - Especially in **colonic lesions**; It is **therapeutic** in **intussusception** but carries the danger of **leakage** into the peritoneum if gut is **gangrenous**

• Abdominal U/S

• **IVU** - Demonstrates **ureteric calculi** which may lead to *inflammation & paralytic ileus*

• CT scan/MRI

## Mx

### • **Conservative** (*initial management before surgery*);

Indications;

▫ **Functional/Adynamic** causes

▫ **Incomplete** small bowel obstruction

▫ Large bowel obstruction that is **not** 'closed loop obstruction'

i) **NBM**

ii) *Fluid & Electrolyte therapy* to correct  $\downarrow K^+$ ,  $\downarrow Ca^{2+}$  &  $\downarrow Na^+$  - IV NS clears aciduria

iii) *Decompression* by passage of a;

- NGT

- Flatus tube

- Enema - especially large bowel obstruction that is **NOT 'closed loop obstruction'**

iv) **DO NOT** give **Analgesics** as they may mask deterioration of the obstruction e.g. perforation

v) GXM 3units

### • **Surgery - Laparotomy**;

Indications;

\* Evidence of ischemia or inflammation - **Intussusception & Malrotation**

\* '**Closed loop obstruction**' - **Large** bowel obstruction with tenderness over a **grossly dilated caecum (>8cm)**, which occurs when the ileocaecal valve remains **competent** despite bowel distension. Also **Volvulus**.

Has a **high risk of perforation**

Usually occurs in;

- Malignancy e.g. Hepatic flexure tumours

- Following Billroth II (Gastrojejunostomy)

\* Failed conservative management

\* Hernias

\* Adhesions - Indications for surgery;

- Strangulation

- Peritonitis

- Pain

- Infection

\* Unresectable Ca colon to relieve the obstruction

# Volvulus

A volvulus is a **twisting or axial rotation** of a portion of bowel about its mesentery. When complete, it forms a **closed loop of obstruction** with resultant ischemia 2° to vascular occlusion.

May involve **Small intestines, Caecum or Sigmoid colon**

## Types

1° - E.g. Volvulus neonatorum, *Caecal & Sigmoid* volvulus - 2° to;

- Congenital malrotation of the gut - **Anticlockwise** rotation of gut along the axis of **superior mesenteric artery**
- Abnormal mesenteric attachments
- Congenital bands

2° - Occurs secondary to actual rotation of a piece of bowel around an **acquired adhesion or stoma** - **More common**

## Volvulus of the small intestine

1° or 2° & usually occurs in the **lower ileum**.

Predisposing factors;

- Consumption of a large volume of vegetable matter
- 2° to adhesions

## Caecal volvulus

Occurs as **part of volvulus neonatorum** or **de novo** & is usually a **clockwise** twist.

**F>M**

**O/E;**

- Features of Intestinal obstruction
- A palpable tympanic swelling in the **midline or left side** of the abdomen - In **25%** cases

**Ix;**

- AXR - Gas filled **ileum** ± a **distended caecum**
- Barium enema - Absence of barium in the caecum & a **bird beak deformity**

**Mx - Surgery;**

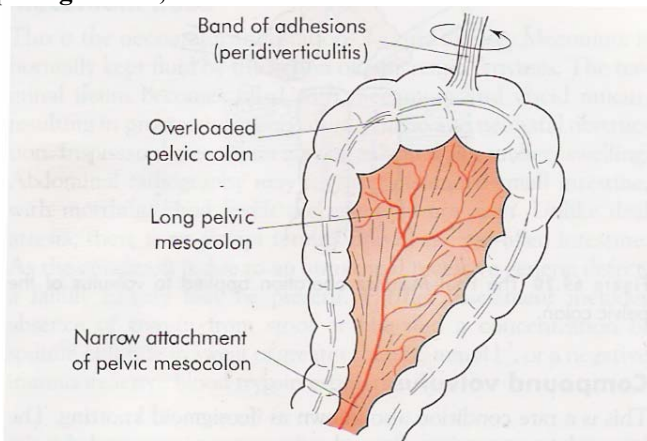
- Decompress the caecum with a needle then reduce the volvulus
- Fix the caecum to the RIF (**caecopexy**) &/or a **caecostomy**
- If the caecum is **ischemic or gangrenous**, a **right hemicolectomy** should be performed.

## Sigmoid Volvulus

**Commonest** spontaneous type & cause of **large bowel** obstruction

Peak age - **>70yrs**; Especially elderly patients suffering from **psychiatric & chronic neurological diseases** such as **stroke or multiple sclerosis**. Also, **cardiovascular disease and diabetes**.

**Predisposing causes;**



**Figure 69.18** Predisposing causes of volvulus of the sigmoid colon.

- Idiopathic megacolon usually precedes the volvulus in Africans.
- High residue diet - *Bananas are rich in serotonin which relaxes the gut*
- Acquired megacolon e.g. *TB, Diabetes*
- Chronic constipation

\*\* Rotation nearly always occurs in an **anticlockwise** direction.

### C/P

- **Acute** in the **young** & **chronic** in the **elderly** ('old Kamba gentleman')
- **Acute colicky abdominal pain**, almost invariably associated with early progressive **abdominal distension** ± hiccough & wretching
- **Intermittent** large bowel obstruction followed by the passage of large quantities of flatus & faeces
- Constipation is **absolute (Obstipation)**
- Vomiting occurs **late**

### O/E

- *Tensely distended, tympanitic 'drum-like'* abdomen. The **rectum is empty** of stool.
- Bowel sounds are often **increased**
- Signs of **peritoneal inflammation** such as rebound tenderness or guarding suggest that **colonic infarction or gangrene has occurred**.
- Signs of dehydration may be apparent if presentation has been delayed

### Ix

- **AXR** - Massive colonic distension - The characteristic appearance is that of a grossly enlarged, gas-filled sigmoid colon arising from the pelvis and deviating to the **left or right flank** with **2 fluid levels**. The apex of the loop is positioned high in the abdomen. Three dense curved lines, representing the walls of the enlarged loop, converge towards the stenosis over the left part of the sacrum - '**Inverted U**' sign. **Haustral markings** are usually **lost**.

### Mx

#### a) Non-operative;

- **Endoscopic deflation** - Careful sigmoidoscopy and the passage of a flatus tube via the sigmoidoscope. Following a successful deflation, the flatus tube should be left in place for **at least 48hrs** to reduce the likelihood of an early recurrence. **C/I** - if there is evidence of **strangulation or perforation**.  
If decompression is successful, good-risk **young patients** should be scheduled for **elective resection** as soon as the colon can be prepared, because the recurrence rate after decompression alone is **50%**.  
**No operation** is indicated after endoscopic decompression of the **first episode** of sigmoid volvulus in **elderly patients** or those with **severe disease of other organ systems**.

#### b) Surgery;

- **Hartmann procedure** - Primary resection **without** anastomosis (**2-stage procedure**)-The diseased bowel is removed, the proximal end of the colon is brought out as a temporary colostomy, and the distal colonic stump is closed. Intestinal continuity is restored in a **second operation after 6wks**

**Emergency operation** is performed if;

- \* attempts to decompress the bowel per rectum are unsuccessful.
- \* **strangulation or perforation** is suspected

**Prognosis** - Mortality - **40%**

### Compound Volvulus/Ileosigmoid knotting

The long pelvic mesocolon allows the **ileum to twist around the sigmoid colon**, resulting in gangrene of either or both segments of bowel.

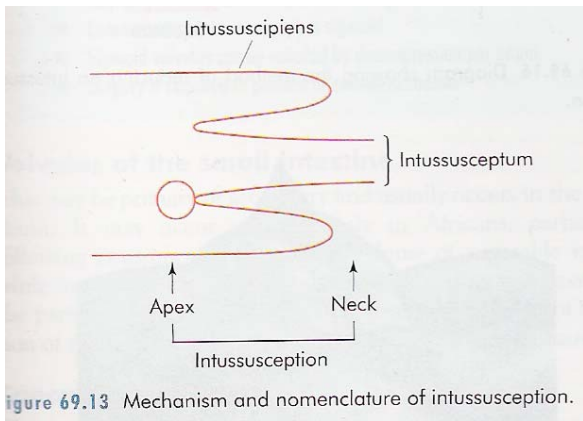
The patient presents with **acute intestinal obstruction** but **distension** is comparatively **mild**.

**AXR** - Distended ileal loops in a distended sigmoid colon.

Has a **60% mortality**

# Intussusception

This occurs when one portion of the gut becomes invaginated within an immediately adjacent segment, *it is the proximal over the distal bowel.*



## Types;

- Ileoileal
- Ileo-ileo-colic
- **Ileocolic** - *Neonates*
- **Colocolic** - *Adults*

## Aetiology;

Predisposing factors/conditions;

- Idiopathic - **Ileocolic more common**; Peak age - **3-9 months** - *Hyperplasia of Peyer's patches in the terminal ileum 2° to weaning, URI* e.g. adenovirus or rotavirus may be the initiating factor
- In **older children**;
  - Meckel's diverticulum - *2 ft proximal to the ileocaecal junction, 2" long, in 2% of 2yr olds*
  - Polyp
  - Duplication
  - Henoch-Scholein purpura
  - Appendicitis
- **Adults** - **Colocolic more common**;
  - Polyp (e.g. Peutz-Jegher's syndrome)
  - Submucosal lipoma
  - Tumour

## C/P

- **Colicky abdominal pain** - An otherwise fit & well **male child of 6 months** develops **sudden onset** of screaming associated with drawing up of the legs; The attacks last for a few minutes, recur every **15 minutes** & become progressively severe. During attacks the child has **facial pallor** while between episodes he is *listless & drawn*
- **Reflex vomiting following** pain - Becomes conspicuous with time
- **'Redcurrant jelly stool'** due to exudation of *mucus & blood* due to vascular compromise → Ischemia ± perforation → **Tenderness** on palpation

## O/E

- The abdomen is **not distended**
- **Sausage shaped lump** with concavity towards the umbilicus that **hardens on palpation** (+ve in only **50-60%**)
- Feeling of *emptiness* in the **RIF** (*the sign of Dance*)

## DRE;

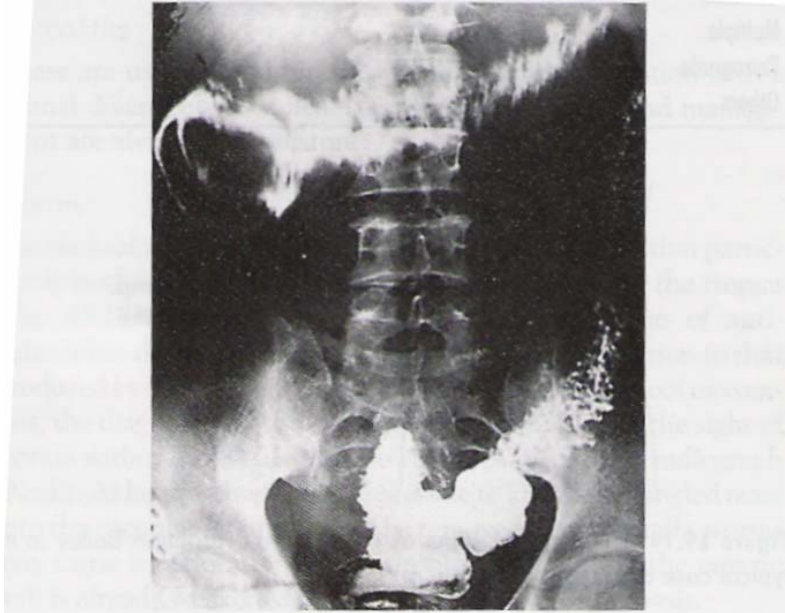
- Blood-stained mucus may be found on finger
- Occasionally in extensive **ileocolic** or **colocolic** intussusception, the apex may be palpable or even protrude from the anus

## DDx

- Acute enterocolitis
- HSP
- Rectal prolapse

## Ix

- **AXR** - small or large bowel obstruction with an **absent caecal gas shadow** in **ileoileal or ileocolic** cases
- **Barium enema** - may be used to diagnose the presence of an **ileocolic or colocolic** form (*the claw sign*) but would be **negative** for the **ileoileal** variant in the presence of a **competent ileocaecal valve**



**Figure 69.15** 'Claw' sign of ileocolic intussusception. The barium in the intussusception is seen as a claw around a negative shadow of the intussusception (courtesy of R.S. Naik, Durg, India).

## Mx

### a) Non-op;

- **Hydrostatic or Pneumatic reduction** - **Barium enema** at a height of **1m** or **air under controlled pressure** respectively is pushed into the patient **PR** & reduction is confirmed by visualisation of contrast or air enters the terminal ileum by x-ray

### C/I;

- \* Presence of obstruction
- \* Peritonism
- \* Prolonged history (>48hrs)

### b) Surgery;

Indicated if **Ischemia ± perforation** is suspected (*tenderness on palpation*)

Reduction is achieved by **squeezing the most distal part of the mass in a cephalad direction**. **Do not pull**. The viability of all the bowel should be checked carefully.

In the presence of an **irreducible or gangrenous intussusception**, the mass should be excised in situ & an *anastomosis or temporary end stoma* created.



# Hirschsprung's Disease (*Congenital aganglionic megacolon*)

Incidence - **1:5000** births; M:F - **4:1**

Associated with;

- IND - **25%**
- **Down's syndrome - 3%**
- ARMs

Causes

- Congenital (commonest)** - Failure of migration of ganglion cells from the **neural crest** to the gut (*usually hind gut*) - normal innervation is **cranio-caudal** thus affects the gut **Distally** → **Proximally**
- Acquired;**
  - Vascular causes e.g. *Post-op 2° to Pull-through operation, with damage to the mesenteric vessels*
  - Non-vascular e.g. *TB, Diabetes*

Pathological Anatomy

The *histological hallmark* of Hirschsprung's disease is **Aganglioneurosis in the submucosal plexus of Meissner and Hypoganglioneurosis & 'skip-area' Aganglioneurosis** (may exist or coexist) *in the intermyenteric plexus of Auerbach.*

This leads to *unopposed autonomic nervous system* functioning which causes;

- \* Reduced or absent peristaltic activity
- \* Increased intestinal sphincter tone

The *pathological hallmark* is;

- There is marked **distension & hypertrophy** of gut **proximal** to the aganglionic segment
- There is **funnelling (coning)** of the gut **between** the two - **transition zone**
- **Constricted or collapsed** gut **at & distal** to the aganglionic portion

Anatomical Distribution

- **85%** - Left colon
- **2%** - Total colonic aganglioneurosis
- **Ultra short segment disease-** Aganglioneurosis *only at dentate line*

C/P

- Chronic constipation since birth (*Up to 4 days constipation in an exclusively breast feeding baby could be normal*)
- Delayed passage of meconium
- Abdominal distension
- Failure to thrive
- **Necrotizing enterocolitis** - *Bloody diarrhoea, Fever, Sepsis, Bile stained vomitus, Shock*

O/E

- Abdominal distension
  - **DRE;**
    - Increased intestinal sphincter tone
    - Empty rectum
    - Followed by explosive passage of stool & flatus
- \*\* Do DRE **after Barium meal** to prevent stimulating GIT contractions

DDx

- Mechanical intestinal obstruction e.g. *Meconium plug syndrome*
- **Intestinal neuronal dysplasia (IND);**
  - Incidence of **<5% that of Hirschsprung's disease.** It is estimated that **25%** of children with Hirschsprung's disease have **concomitant** neuronal intestinal dysplasia, which may explain why some patients continue to have symptoms following definitive surgery.
  - Features;
    - **Ectopic ganglion cells**
    - *Hyperplasia of the submucosal and intermyenteric plexuses*
    - $\pm$  *Hypertrophic nerve trunks and aberrant neurofibrils* identified by *acetylcholinesterase stain*
  - **C/P** - *A long-standing history of constipation, often dating from early infancy.*
  - **Ix** -  $\uparrow$ NADPH &  $\uparrow$ LDH in **intermyenteric** plexus
- Hypoganglioneurosis - *Ganglion cells are reduced by a factor of 10 & nerve fibres by a factor of 5*
- Hollow visceral myopathy e.g. *Desmosis of the colon* - abnormal connective tissue of the colon.
- Metabolic disorders
- Conditions affecting stool composition
- Muscular or neurological disorders
- Medications administered to the mother



## Ix

- Barium meal;
  - Massive distension of proximal colon
  - Funnelling (coning) of transition zone
  - Shows narrowing/constricted rectumRepeat **after 24Hrs** to monitor flow of contrast.
- Rectal biopsy;
  - **Suction biopsy** - *For neonates* - Done **up to 5cm** above the dentate line
  - **Full thickness biopsy** - Under GA *for older children* - Done **from 2cm** above the dentate line
- Anorectal manometry - To **r/o IND** -  $\uparrow$  resting anal pressure  $\geq 25\text{mmHg}$  - Insert balloon & dilate it above intestinal sphincter - The sphincter normally should relax - **rectosphincteric inhibitory reflex** is **Absent**; Sphincter relaxation may occur without peristaltic waves & instead there is high pressure segmental contractions 2° to normal smooth muscle reflex activity

## Mx

### Pre-op;

- Manage fluid & electrolyte imbalances
- Insert a soft rectal tube & give patient soft enemas - **4.5ml/kg warm NS** & irrigate GIT until patient settles.

### Conservative surgery;

- **Levelling colostomy** - *Colostomy in the normal colon or Ileostomy in total colonic aganglionosis*

#### Indications;

- To *decompress* normal gut to *allow normal growth & development* until when definitive management can be instituted.
- Avoid - **NOT** eliminate risk of enterocolitis

3 Serial biopsies are taken & submitted in frozen section to determine the extent of the disease intra-op of the;

- Undilated segment (*most affected*);
  - *Absent ganglion cells*
  - *Increased acetyl cholinesterase activity* on histochemical staining due to lack of consumption by the ganglion cells
- Maximally dilated segment - Presence of *hypertrophic nerve bundles*
- Normal gut - Normal anatomy

### Definitive surgery;

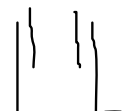- Left colon disease** - *Resect aganglionated gut then anastomose normal gut at the dentate line*

- Soave procedure;**

- *Mucosectomy* of the rectal cuff up to the dentate line
- The anastomosis of normal gut at the dentate line - (modified by Boley)
- There is risk of cuff abscess so always drain the cuff.



Original Soave procedure



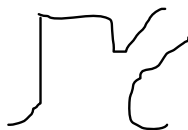
Boley modification

- Swenson's operation** - End-to-End anastomosis at the dentate line

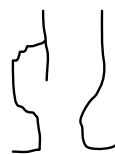

- Duhamel-Grob princen procedure;**

- End of normal gut anastomosed to the side of rectal cuff at the dentate line
- There is risk of *faecaloma* forming in the aganglionated rectal cuff - **Lester-Martin** modification takes care of this complication



Duhamel Procedure




Lester-Martin modification



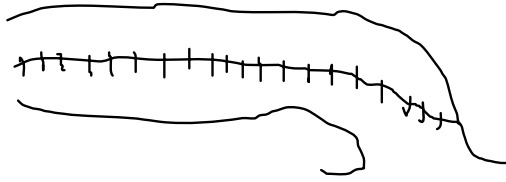
Resultant common chamber

- Total colonic aganglionosis** - *Martin's procedure;*

- Some colon is left for absorption of water & storage of faeces. Ileum is anastomosed at the dentate line & a **side to side** anastomosis of ileum to remaining colon. The ileum will provide peristalsis.



& a **side to side** anastomosis of ileum to remaining colon. The ileum will provide peristalsis.



c) Ultra short segment disease - *Submucosal myomectomy*

# Anorectal Malformations

## Incidence

- 1:4000 - 6000 live births
  - M>F - **55-65:1**
  - **Low lesions>High lesions**
- May occur as part of the **VACTER** group of anomalies;
- Vertebral body segmentation defects - *Hemivertebra, Sacral agenesis*
  - Anorectal malformations
  - Cardiovascular - *PDA, VSD*
  - Tracheo-Esophageal fistula
  - Radial ray hypoplasia; unilateral **Renal** agenesis or ectopia

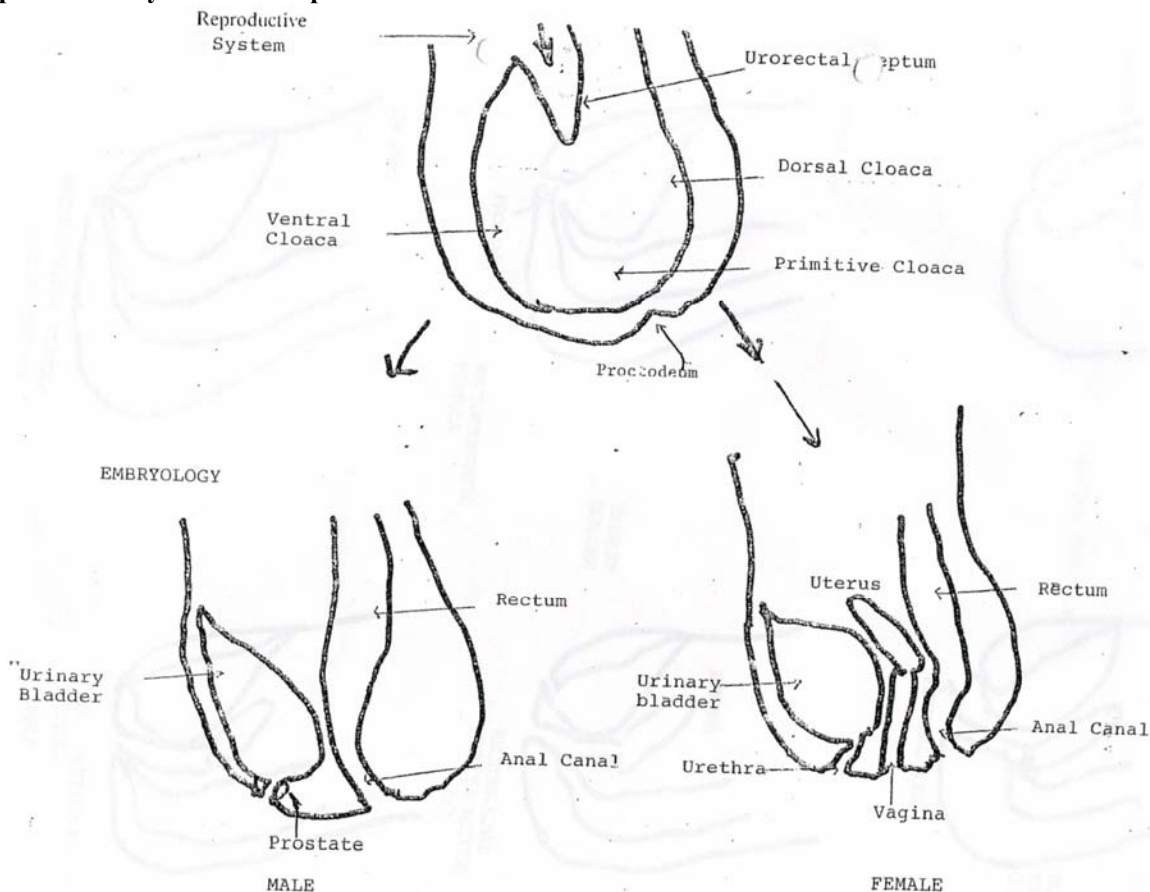
## Embryology

From the **4<sup>th</sup> to 7<sup>th</sup> weeks**, the **Primitive cloaca**, derived from the **primitive hind gut (endoderm)** is divided by the **urorectal septum** into;

- **Ventral cloaca** - gives rise to the **urinary bladder, urethra & vestibule of the vagina**
- **Dorsal cloaca** - gives rise to the **rectum & anal canal** which fuses with the **Proctodeum**, an invagination of the **ectoderm** which eventually breaks down by the **8<sup>th</sup> week** to give rise to the **anus**

While the gut tube lengthens, the **endodermal lining** proliferates, **occluding the lumen by the 6<sup>th</sup> week** of gestation. The maturation of mucosa proceeds from a proximal to distal direction as **vacuoles** form in the gut tube, so it is fully **recanalized by 9<sup>th</sup> week**.

The **reproductive system** is **interposed between** the ventral & dorsal cloaca.



## Contributing Factors;

- Genetic component
- ↓ levels of folate in diet
- Drug induced e.g. adriamycin ~*experimental in rats*

## Classification

Wing Spread Classification 1984		Alberto Pena Functional Classification (Requires colostomy)
Male	Female	
<b>Perineal fistula</b>	<b>Perineal fistula</b>	<b>No</b>
<b>High – Above levator ani (Supra levator);</b>		<b>Yes</b>
- Anorectal agenesis * + <b>Rectoprostatic urethral fistula</b>  * Without fistula - Rectovesical fistula (Bladder neck) - Rectal atresia	- Anorectal agenesis * + <b>Cloaca</b> $\geq 3\text{cm}$ common channel – poor sphincter mechanism & poor sacrum * Without fistula - - Rectal atresia	
<b>Intermediate – within the levator ani;</b>		<b>Yes</b>
- <b>Rectobulbar urethral</b> fistula - Anal agenesis (Imperforate anus) without fistula	- Rectovestibular fistula - Anal agenesis (Imperforate anus) without fistula**	**>1cm bowel skin distance
<b>Low – below the levator ani (Infralevator);</b>		<b>Yes</b>
- - Anocutaneous fistula - Anal stenosis	- <b>Anovestibular fistula (commonest)</b> - Anocutaneous fistula - Anal stenosis - <b>Cloaca;</b> * <3cm common channel – well developed sphincters & good sacrum	

## C/P

- No opening;
  - Anorectal (or anal) agenesis without fistula
  - Anal stenosis
- Failure to pass stool/meconium
- Passing **meconium/stool/air;**
  - In Urine (urethra)
  - Per vagina
  - Ectopic point in perineum
- **Single perineal opening** with **Rectovaginal & Urethral openings** immediately behind the clitoris - **Cloaca**
- Abdominal distension
- Vomiting
- Associated conditions - *oesophageal atresia, duodenal atresia, and cardiovascular defects.*

## O/E (*Clinical evidence*);

- A **piece of gauze** is placed around the tip of the penis can be used to check for particles of meconium filtered through this gauze. The presence of **meconium in the urine and a flat bottom** (flat perineum with short sacrum) are considered indications to create a *protective colostomy*.
- The presence of a **single perineal orifice** is pathognomonic of a **cloaca**. A **palpable pelvic mass (hydrocolpos)** reinforces the suspicions of a cloaca.
- The diagnosis of a **vestibular fistula** can be established by a careful **separation of the labia to see the vestibule**.

**IX;**

- i) **No Fistula - Invertogram** - X-ray in **prone** position with **head down & legs up** (*Alternative - Prone cross-table lateral view*)
  - Best done after **16-24 hr of life** - At birth the bowel is not distended; therefore, clinical and radiologic evaluations are not reliable during the **first 16–24 hr** of life.
  - To find out the **level of the rectal atresia** by viewing how far the gas has reached in relation to area where sphincter should be (**Put a coin**)
- ii) **Fistula - Colostogram** - Should be done under pressure to illustrate **any fistula**
- iii) During the **first 24 hrs of life**, all these patients need an **abdominal ultrasound** evaluation to identify an **obstructive uropathy** especially in patients with;
  - \* **Cloaca** (*Cervix faces posteriorly not downwards thus may obstruct the ureters*)
  - \* **Rectovesical** (*Bladder neck*) fistula
  - \* **Rectoprostatic urethral** fistula

**Mx;**


If **UTO** present, **divert urine first**.

**Anal Stenosis - Anoplasty & anal dilatation** until it's the size of a normal new anus (See below)

For **high & intermediate malformations**, divert the faecal stream for **4-8wks** by performing a - **Colostomy** - Irrigate distal loop of colostomy at operation & post-op to remove any faecal material to make subsequent rectum clean then;

- **PSARP + Abdominal approach**
  - Rectovesical (Bladder neck) fistulae
  - Rectoprostatic urethral fistula
  - **≥3cm** Cloaca
- **PSARP only;**
  - **Rectobulbar** urethral fistula
  - Anal Agenesis **<1cm** (*No colostomy*)
  - Perineal fistula (*No colostomy*)
  - **<3cm** Cloaca (*Rectovaginal & Rectovestibular fistula*)

### Posterior Sagittal AnoRectoPlasty (PSARP)



- \* Incision avoids nerves & blood vessels that are from the right & left & meet in the midline
- \* Look for any fistula & ligate it
- \* Trim the rectum to fit the sphincter

Post-op;

- i) **4<sup>th</sup> day - Sitz baths** to remove any bacteria
- ii) **10<sup>th</sup> day** - When the wound has healed, start **daily Hegars dilatation** - Always start the previous days dilator then increase to the next size - to prevent stenosis. Aim for a **size in keeping with the child's age (or mother's index finger)**. Once the size has been achieved, the mother is taught how to digitally dilate at home for some time.
- iii) Confirm adequacy of anus before **closure of colostomy**
- iv) If there is faecal soiling, reassess *the sphincter* by performing anal mapping under GA
  - If **rectum misplaced**, then **put a colostomy & redo PSARP**
  - If **rectum is appropriately placed**, then manage the patient **medically** - *constipating diet & high daily enema*

MALE

ARM

Perineal inspection

Clinical Evidence

No clinical Evidence (10-20%)

Perineal fistula bucket handle  
Midline rapile fistula

Flat bottom meconium in urine

Cross-table lateral film with patient in prone position

Colostomy 4-8 wks  
R/o Ass. Malfn  
Verify normal Growth

>1cm bowel-skin distance

<1cm bowel skin distance

Minimal PSARP  
No colostomy

PSARP

Minimal PSARP  
No Colostomy

FEMALE

ARM

Perineal inspection

Fistula (95%)

No fistula (5%)

Cloaca  
Emergency G.U  
Evaluation

Vestibula or vaginal

PERINEAL

Cross table lat. Film with pt in prone position

Colostomy + Vaginostomy  
Urinary diversion

colostomy

<1cm bowel skin Distance

>1cm bowel skin distance

PSARP

Limited PSARP

Minimal PSARP. NO COLOSTOMY

Colostomy

PSARP



# Appendicitis

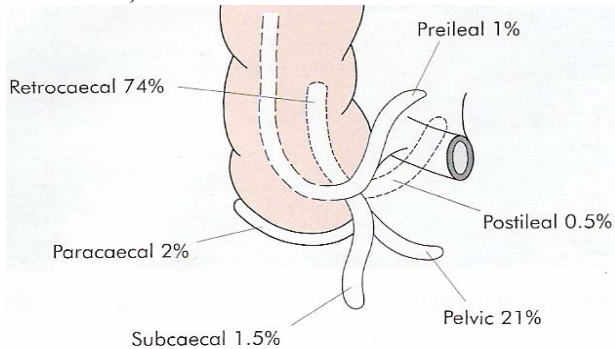
## Acute Appendicitis

- Acute inflammation of the vermiform appendix
- **Most common** acute surgical condition of abdomen

## Anatomy

The vermiform appendix is a **fixed vestigial** narrow blinded tube usually about **3-4" (7.6-10cm)** long that extends from the caecum in the RIF at the termination of the 3 taenia coli & represents an **atrophied terminal part of the caecum**. It has **much lymphoid wall tissue**, normally communicates with the cavity of the caecum,

### Variation in sites;



## Incidence

**2-6%**; Incidence is **decreasing** due to the use of **antibiotics & improved hygiene**

Highest in the **3<sup>rd</sup> - 4<sup>th</sup>** decades (15-35yrs)

- Before puberty & >30yrs - M=F
- Teenagers & young adults - M:F - **3:2**

## Risk Factors

- Adolescent males
- Familial tendency - 1/3
- Intra-abdominal tumours
- Purgative abuse

## Pathogenesis

Lumen **obstruction** 2° to;

- **Faecoliths (most common)** - Composed of;
  - Inspissated faecal material
  - Calcium phosphates
  - Bacteria
  - Epithelial debris
- Lymphoid hyperplasia
- Filarial worms
- Inspissated barium
- Vegetable, fruit seeds and other foreign bodies
- Strictures
- Tumour especially carcinoma of the caecum

Once obstruction occurs, continuous **mucous secretion & inflammatory exudation** increases intraluminal pressure, **obstructing lymphatic drainage**. **Oedema & mucosal ulceration** develop with **bacterial translocation to the submucosa**. Resolution may occur at this point either spontaneously or in response to antibiotic therapy.

If the condition progresses, further distension of the appendix may cause **venous obstruction & ischemia** of the appendix wall → **ischemic necrosis** → **gangrenous appendicitis** → **perforation** →

- a) In **neonates** (due to a *poorly developed omentum*), the **elderly** (*omentum shrinks in size*) & the **immunocompromised**, the condition is **not** controlled → free bacterial contamination of the peritoneal cavity → **Generalised peritonitis**.
- b) In the rest, *the greater omentum & loops of small bowel* become adherent to the *inflamed appendix*, walling off the spread of peritoneal contamination, resulting in a **phlegmonous mass** & eventually may form a **paracaecal abscess**

### **paracaecal abscess**

Rarely appendiceal inflammation *resolves* leaving a distended mucous-filled organ - **mucocele** of the appendix.

**Peritonitis** occurs as a result of;

- Free migration of bacteria through frank perforation of a *gangrenous appendix*
- Delayed perforation of an *appendix abscess*
- *Impaired ability to prevent invasion*, brought about by **improved hygiene** (so less exposure to gut pathogens)

## S/S

### Symptoms;

- Sequence of symptom appearance (**95%**);
  - i) *Anorexia* - Patient is **not** hungry
  - ii) *Crescendo Abdominal pain* - As inflammation begins, there is **periumbilical colicky abdominal pain** (this is *visceral pain* that is embryologically referred to the *midgut*) but once the *parietal peritoneum* becomes inflamed, the pain shifts to the **RIF** (localised *parietal pain*) & becomes **more constant**. Pain *lessened with flexion of thigh* but *exacerbated by coughing or sudden movement*.
  - iii) *Mild Nausea & Vomiting* (at the peak of the pain 2° to peritoneal irritation)
- **Obstipation** - Inability to pass **stool & flatus** (*Constipation - Inability to pass stool only*)
- Mild Diarrhoea

### O/E;

- After **6hrs** - **Low grade fever** (37.5-38.5°C) & *slight tachycardia*
- Furred tongue + Fetor oris
- **RIF**;
  - i) **Pointing sign** - Patient points to where the pain began & where it moved
  - ii) **Cutaneous hyperesthesia** at **T10-12**
  - iii) Maximal **tenderness** at "**McBurney's point**" - *Direct and referred*
  - iv) **Rebound tenderness** - ask the patient to cough or gently percuss over the point of maximum tenderness
  - v) **Muscle guarding** - *Voluntary and involuntary*
  - vi) **Rovsing's sign** - Pain more in the RIF than in the LIF when the LIF is pressed
  - vii) **Psoas sign** - Occasionally, an inflamed appendix lies on the psoas muscle & the patient often a young adult will lie **motionless** with the **right hip flexed** for pain relief **OR hyperextension of the hip joint** (*Femoral stretch test*) may induce abdominal pain when the degree of psoas spasm is insufficient to cause flexion of the hip.
  - viii) **Obturator sign** - If an inflamed appendix is in contact with the **obturator internus**, there will be pain in the hypogastrium with **internal rotation of flexed right thigh**
- DRE painful on the right
- Vaginal examination to r/o salpingitis (*+ve cervical excitation*)
- Variations in the clinical picture;
  - **Retrocecal appendix - Rigidity** is often **absent** due to distension of the caecum with gas preventing the pressure exerted by the hand from reaching the inflamed structure. However, **deep tenderness** is often present in the loin, with **rigidity** of the **quadratus lumborum**. Also **Psoas spasm**
  - **Pelvic appendix - NO abdominal rigidity; Suprapubic tenderness**. DRE - tenderness in the *rectovesical pouch or in the pouch of Douglas*, especially on the right side. Also, ± Diarrhoea, Tenesmus, Frequency
  - **Infants** - Watery diarrhoea & vomiting: Appendicitis may be a complication of simple gastroenteritis
  - **Children - The boy** with vague abdominal pain who will **not eat his favourite food & vomits**.
  - **Elderly** - *Gangrene & perforation* occur much more frequently. The **shocked, confused** octogenarian who is **not in pain**
  - **Pregnancy** - Appendicitis is **not** commoner in pregnancy, but **mortality is higher**, especially from **20wks gestation**. As pregnancy progresses, the appendix migrates, so pain is often less well localized, & signs of peritonism less obvious. **Perforation is commoner**

# DDx

**Table 70.1** Differential diagnosis of acute appendicitis

Children	Adult	Adult female	Elderly
Gastroenteritis	Regional enteritis	Mittelschmerz	Diverticulitis
Mesenteric adenitis	Ureteric colic	Pelvic inflammatory disease	Intestinal obstruction
Meckel's diverticulitis	Perforated peptic ulcer	Pylonephritis	Colonic carcinoma
Intussusception	Torsion testis	Ectopic pregnancy	Torsion appendix epiploicae
Henoch-Schönlein purpura	Pancreatitis	Torsion/rupture of ovarian cyst	Mesenteric infarction
Lobar pneumonia	Rectus sheath haematoma	Endometriosis	Leaking aortic aneurysm

## Ix

- FHG + ESR -  $\uparrow$ WBC -  $11-15 \times 10^9/L$  ( $>15$  - *Complicated appendicitis*); **75% neutrophils**
- U/E/C
- Urinalysis
- AXR
- Pregnancy test

**Table 70.2** The Alvarado (MANTRELS) score

	Score
<b>Symptoms</b>	
Migratory RIF pain	1
Anorexia	1
Nausea and vomiting	1
<b>Signs</b>	
Tenderness (RIF)	2
Rebound tenderness	1
Elevated temperature	1
<b>Laboratory</b>	
Leucocytosis	2
Shift to left	1
<b>Total</b>	<b>10</b>

MANTRELS: Migration of pain; Anorexia; Nausea or vomiting; Tenderness; Rebound pain; Elevation of temperature; Leucocytosis; Shift to left (segmented neutrophils)

**\*\*A score of  $\geq 7$  is strongly predictive of acute appendicitis**

In patients with an equivocal score (5-6);

- Abdominal/Pelvic U/S
- Contrast enhanced CT scan of abdomen
- Incidental finding of a faecolith is a relative indication for *prophylactic appendicectomy*

# Mx

## Pre-op;

- IVI fluids
- **IV Metronidazole + cefuroxime 1-3doses 1hr pre-op** - reduces wound infections
- Antipyretics for hyperpyrexia in children

## i) Surgical Appendicectomy;

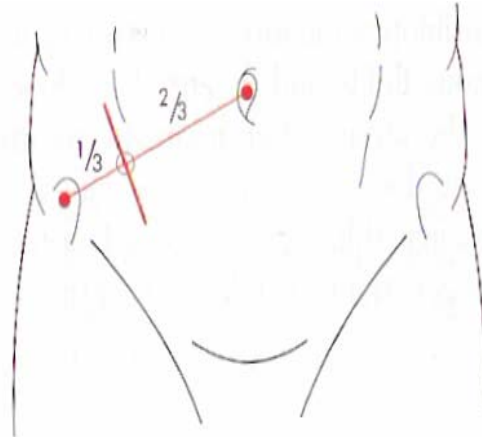
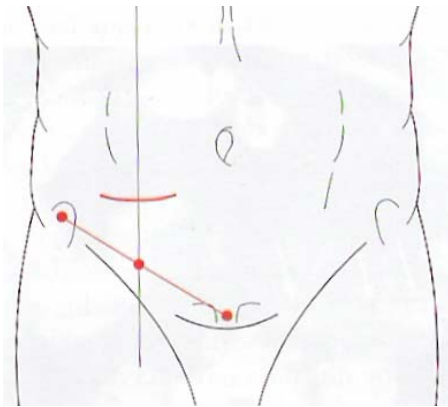
Skin & Subcutaneous tissue - an arterial twig from the *superficial circumflex iliac artery* usually requires ligation

↓  
External oblique - cut along the line of the incision

↓  
Internal oblique - split

↓  
Transverse Abdominis - split

↓  
Peritoneum



- a) Transverse or skin crease (Lanz) incision** - Centred on **midclavicular-midinguinal line**, **2cm** below the umbilicus.  
\*\* Exposure is better & extension when needed is easier especially when the diagnosis is in doubt, particularly in the presence of intestinal obstruction.
- b) Gridiron incision** - Centred on **McBurney's point** at right angles to line joining ASIS & umbilicus  
\*\* Difficult to extend, more difficult to close & provides poorer access to the pelvis & peritoneal cavity.
- c) Rutherford Morison's incision** - Useful if the appendix is **para- or retrocaecal & fixed**. It is essentially an **oblique muscle-cutting incision** with its lower end over **McBurney's point & extending obliquely upwards & laterally** as necessary (It is possible to convert the Gridiron incision to a Rutherford Morison by *cutting the internal oblique & transversus muscles* in the line of the incision)

## ii) Laparoscopic appendicectomy;

- **Unclear diagnosis** - The diagnosis can be made with certainty before treatment is rendered (e.g., patients found to have gynaecologic disorders can be treated appropriately)
- The operation is technically **easier in obese patients** when done laparoscopically
- Recommended for **females of child bearing age**
- The postoperative hospital stay averages **1 day less** than after open appendectomy & **Recuperation** and return to normal activity is **faster**.
- **Postoperative complications** (e.g., ileus, wound infection) are **less common** but **increases risk of intra-abdominal abscesses**.

\*\* The stump of the appendix is **buried** by **purse stitch method**;

- The stump is 'dirty' - contains contamination
- To prevent it from bursting due to back pressures from the rest of the colon

**\*except when;**

- Gangrenous
- Friable

# Complications

## i) Problems encountered during Appendicectomy

- Normal Appendix
- The appendix cannot be found
- An appendicular tumour is found
- An appendicular abscess is found & the appendix cannot be removed

## ii) Perforation (does **not** appear to cause later infertility in girls) - Risk factors;

- Immunosuppression
  - Extremes of age
  - Diabetes mellitus
- Pregnancy
- Faecolith obstruction of the appendix lumen
- A free-lying pelvic appendix
- Previous abdominal surgery that limits the ability of the greater omentum to wall off the spread of peritoneal contamination.

## iii) Gangrene

## iv) Appendix mass - This results when *the greater omentum & loops of small bowel* become adherent to the *inflamed appendix*, walling off the spread of peritoneal contamination.

**Ix** - U/S, Contrast-enhanced CT scan

**Rx;**

- Appendicectomy is *deferred* until the inflammation subsides as the *appendix is readily friable & surgery may lead to fistula formation.*
- **Conservative Oschner-Scherren regimen;**
  - Vitals **4hrly**
  - NBM & Antibiotics (*cefuroxime & metronidazole IV*)
  - Maintain fluids
  - Record the patient's condition & the extent of the mass - *mark the limits of the mass on the abdominal wall using a pencil*

Clinical improvement is usually evident within **24-48hrs** - Failure of the mass to resolve should raise suspicion of a **Carcinoma or Crohn's disease.**

Stop if;

- Patient gets more toxic ( $\uparrow$ Pain, T°C, Pulse, WCC)
- Increasing or spreading abdominal pain
- Increasing size of mass

- **Appendicectomy** is done after an interval of **6-8wks**

## v) Appendix abscess - This results if an *appendix mass fails to resolve.*

**S/S** - Enlargement of the mass or if the patient gets more toxic ( $\uparrow$ Pain, T°C, Pulse, WCC)

**Rx;**

- **Conservative** - Especially in **children** - **Antibiotics**
- **Drainage** - Surgical or percutaneous (under radiological guidance)
- **Elective appendicectomy** is done in **6-8wks**

## vi) Pelvic abscess;

**C/P;**

- Spiking pyrexia several days following appendicitis
- Pelvic pressure & discomfort
- Loose stool & tenesmus

**O/E** - DRE - *Boggy mass in the rectovesical pouch or the rectouterine pouch (Pouch of Douglas)*

**Ix** - Pelvic U/S or CT scan

**Mx;**

- Transrectal **drainage** under GA
- **Elective appendicectomy** is done in **6-8wks**

## vii) Appendicular stump syndrome - *S/S of acute appendicitis 2° to appendicectomy due to a retained small appendix.*

## viii) Chronic appendicitis - **TB**

## Post-op Complications

- Wound infection
- Intraabdominal abscess
- Ileus (*especially if persisting >4-5days + fever*)
- Pneumonitis or collapse
- Venous thrombosis & embolism
- Portal pyemia (***pylephlebitis***) - Complication of gangrenous appendicitis associated with ***high fever, rigors & jaundice*** caused by septicaemia in the portal venous system & leads to the development of ***intrahepatic abscess***.
- Faecal fistula
- Adhesive intestinal obstruction
- Right inguinal hernia - *more common following a gridiron incision due to injury to the iliohypogastric nerve*

# Colorectal Adenocarcinoma

## Incidence

50-70yrs old; M:F - 2:1

F > Left; M > Right

Rapidly progressing in young people.

## Predisposing factors

- Genetics (Risk) - Refer when **10yrs younger** than the youngest affected relative;
  - No close relative affected - **1:50**
  - One 1<sup>st</sup> degree relative affected - **1:17**
  - If 2 affected - **1:10**

### Familial tendencies

Colonic Manifestations	Extracolonic lesions
Familial adenomatous polyposis syndromes <ul style="list-style-type: none"> <li>a) Familial adenomatous polyposis (Mutation of APC gene on long arm of Chromosome 5 (5q21))</li> <li>b) Gardner's</li> <li>c) Oldfield's</li> <li>d) Turcot's</li> </ul>	Retinal pigmentation Osteomas, desmoids, other gastrointestinal cancers Sebaceous cysts Intracranial tumours
Harmartomas <ul style="list-style-type: none"> <li>a) Peutz Jegher's</li> <li>b) Juvenile polyps</li> </ul>	Perioral freckles

- Hereditary Non-polyposis Colorectal cancer
- Neoplastic polyps;
  - 95% polyps develop into cancer in 10-15yrs
  - Tubular or **villous** adenomas; malignant potential especially if >2cm
- Inflammatory conditions;
  - Ulcerative colitis
  - Crohn's disease
- Previous cancer - Follow up after surgery every **6months for 1yr**, then Every **2yrs** then every **3yrs**.
- Diet;
  - ↓fibre - Fibre binds oncogenic toxins
  - ↑Fat e.g. meat (cholesterol)
  - ↑proteins & calories - Digested to *nitrosoamines* that are oncogenic; Also promote *constipation* → Longer exposure to carcinogens
- Irradiation e.g. *intracavitary radiation used in the treatment of Ca cervix*
- Surgery of the colon e.g. *cholecystoenterostomy, ureterocolostomy*
- ↑Bile acids
- Bacteria - Bacterial enzymes break down harmless primary bile acids into the mutagenic secondary bile acids (**lithocholic acid and chenodeoxycholic acid**), and **Clostridia** produces enzymes which **desaturates bile acids** to produce substances that are both **tumour initiators and growth promoters**.
- Immunosuppression - Leads to **Small cell cancer of the colon**;
  - Renal transplant
  - HIV/AIDS
- Smoking
- Aflatoxin
- H. pylori

## Protective agents

- A number of dietary constituents have been found to **inhibit carcinogenesis**, including **selenium, vitamins C and E, retinoids, & β-carotene, and plant sterols**.
- NSAIDs** may be **protective**



# Pathogenesis

It is likely that all carcinomas start as a **benign adenoma**, the so called '**adenoma-carcinoma sequence**'

## Site;

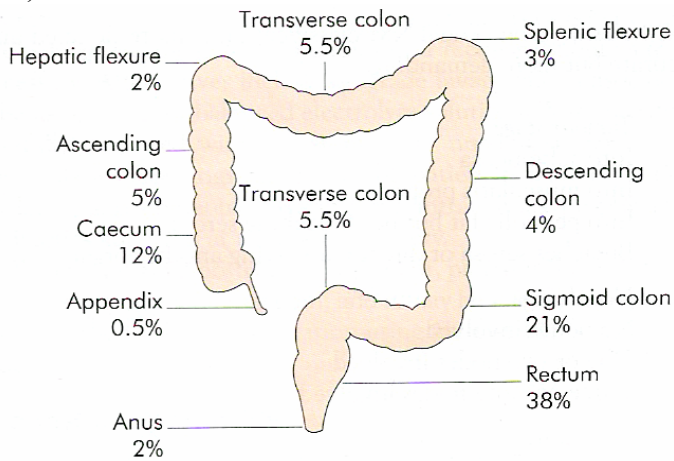


Figure 68.42 Distribution of colorectal cancer by site.

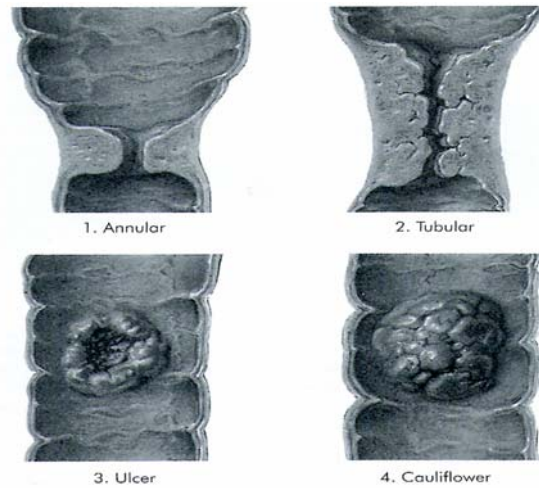


Figure 68.41 The four common macroscopic varieties of carcinoma of the colon.

\*\* More common on the **left colon & rectum**

\*\* **Cauliflower** is the **least malignant form**

\*\* The **Annular type** tends to give rise to **obstructive symptoms**, whereas the **others** more commonly will present with **bleeding**.

## Spread;

- Local spread
- Lymphatic spread - 90%;**
  - N1** - Nodes in the immediate vicinity of the bowel wall (**Epicolic**)
  - N2** - Nodes arranged along the; (**Paracolic**)
    - Ileocolic
    - Right colic
    - Midcolic
    - Left colic
    - Sigmoid arteries
  - N3** - **Apical nodes** around the **superior & inferior mesenteric vessels** where they arise from the abdominal aorta → Left supraclavicular nodes (**Virchow's node**)
- Haematogenous - 10%** - Metastasises **first** to the **Liver** via portal system, *Lung, Bone*
- Transcoelomic
- Iatrogenic

## S/S

- Emergency presentations;
  - Intestinal Obstruction - **20%**
  - Perforation/Peritonitis - **10%**
- Abdominal mass
- Haemorrhage
- Fistula - *Recovaginal, viscerocolic, to the urethra in males.*
- Metastatic disease especially 2° to **liver metastases** e.g. *Jaundice, Ascites from carcinomatosis peritonei, Hepatomegaly*; Also to the **lung, skin, bone & brain**
- Synchronous tumours** occur in about **5%** of patients & should be excluded pre-op

## + Left-sided;

- Pain - Referred to the suprapubic area; Patients will have episodes of colic
- Altered bowel habit - constipation alternating with diarrhoea (*Liquefied by bacteria*)
- Palpable lump* - Sometimes not the tumour itself but impacted faeces above it
  - DRE (60%)** in the *rectovesical pouch*
- Obstruction* due to small size (*Left splenic flexure*)
- Rectal bleeding (Poor sign)
- Tenesmus

#### + Sigmoid Colon;

- Pain - Usually colicky from outset
- Tenesmus *with passage of mucous & blood especially early in the morning*
- Bladder symptoms ± colovesical fistula
- Diverticulitis S/S - **20%**

#### +Rectum;

- Haematochezia
- Early morning diarrhoea
- Mucous discharge - *Villous adenoma*
- Urgency, Tenesmus, incomplete evacuation (involves upper/part of anus)

#### + Transverse Colon;

- Left - *Gastric pathology S/S;*
  - \* Epigastric pain
  - \* Post-prandial fullness
  - \* Dyspepsia
- Right - *Bilio-Pancreatic pathology S/S*

#### + Right-Sided (Caecum & Ascending colon);

- **IDA** (*DDx anaemia of undiagnosed origin*)
- **Mass** in the RIF - *Larger in size than left-sided tumours*
- Abdominal pain
- Mild diarrhoea & Weight ↓
- Some present as acute appendicitis (*elderly with RIF mass*)

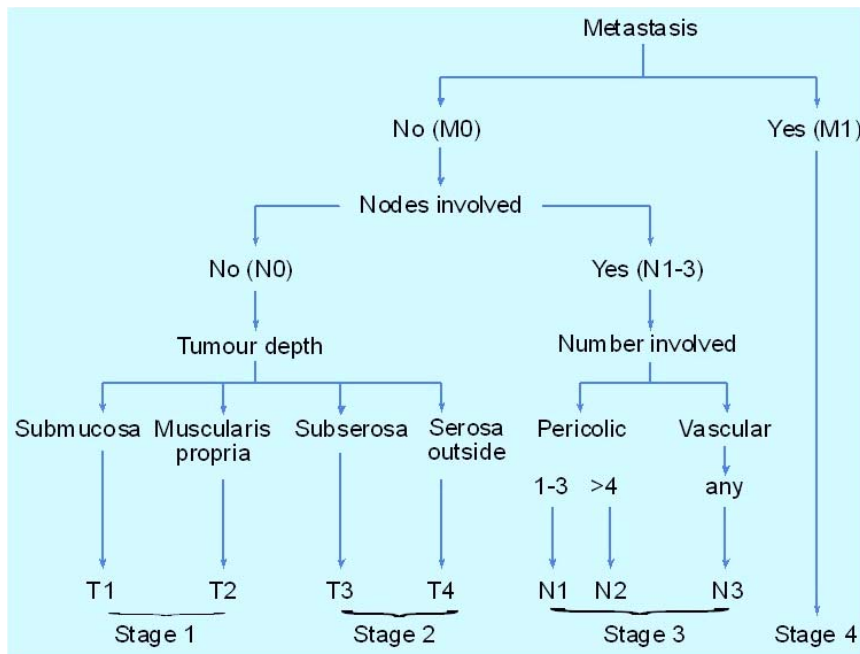
## Ix

- FBC (*Microcytic anaemia*)
- FOB
- *Double contrast Barium enema* (for location, size & relations) - Blow in air to stretch out the ruggae in the colon;
  - Constant irregular filling defect
  - *'Apple core'* Appearance i.e. A short, irregular stenosis with sharp shoulders at each end.
- *Proctoscopy/Sigmoidoscopy/Colonoscopy + Biopsy*
- LFTs
- Abdominal U/S - *For liver metastasis & ascites not malignancy*
- Contrast CT - *in patients with large palpable abdominal masses*
- MRI
- **Carcino Embryonic Antigen (CEA)** - +ve in **20-30%**; may also be used to *monitor disease & effectiveness of treatment;*
  - DDx** for ↑ CEA;
    - \* Other gastric neoplasms
    - \* Cirrhosis
    - \* Pancreatitis
    - \* Smoking
- Coeliac axis Angiography

## Staging;

- Modified Dukes' Classification
  - A** - Confined to bowel wall
  - B** - Through the bowel wall but **not** involving the free peritoneal serosal surface (**Subserosal**)
  - C** - Lymph node involvement
    - C1** - N1, N2
    - C2** - N3
  - D** - Advanced local disease or metastases to the liver (*Not part of original Dukes' Classification*)

- TNM



## Mx

Radiotherapy - *May be used in Ca Rectum;*

- Pre-op to ↓ **recurrence**; it may ↑ survival by **10%**
- Pre-op radiotherapy ± 5-FU is also used to **downstage** initially unresectable rectal tumours
- **Post-op** only in patients with **rectal tumours at high risk of local recurrence**

Surgery - *Total surgical resection of tumour;*

### Indications;

- Biopsy to stage tumour & LN spread - **Do not biopsy hepatic metastases as this may cause tumour dissemination.**
- Ideally aims to cure - **Remove 1° tumour & it's draining locoregional LN**
- Debulking
- Excision of recurrence
- Palliative - **Excise & put colostomy**
- Stop bleeding

### Types;

#### a) Hemicolectomies:

- **Right** - *Caecal tumours, ascending or proximal transverse colon (Right extended Hemicolectomy)*
- **Left** - *Distal transverse colon (Left extended Hemicolectomy) or descending colon*

b) **Transverse colon** - when there is **no obstruction**, excision of the **transverse colon & the 2 flexures** together with the **transverse mesocolon & the greater omentum**, followed by **end-end anastomosis**

c) **Sigmoid colectomy** - Tumours of the **sigmoid colon** - Done at the pelvic brim with a **5cm clean margin above pelvic diaphragm** for anastomosis

d) **Anterior resection** - For tumours **up to 10cm above pelvic floor** (low sigmoid or high rectal) tumours. **Anastomosis** is achieved at the **first** operation (stapling devices are helpful). A **temporary loop colostomy** is left in place to protect the anastomosis & **closed in 6-8wks**

e) **Abdomino-perineal (A-P) resection** - Tumours **<~5cm from anal canal** (low in the rectum): **Permanent colostomy & removal of rectum & anus**

f) **Posterior sagittal anorectoplasty (PSARP)** - **Small tumour in rectum**

g) **Metastases** - Patients with **single-lobe hepatic metastases & no extra-hepatic spread** may be suitable for **curative** surgery with **liver resection**.

h) Inoperable tumour;

- Ascending colon - A **bypass** using an **ileocolic anastomosis**
- Left colon;
  - \* Upper part of left colon - A **transverse colostomy**
  - \* Pelvic colon - **Left iliac fossa colostomy**

Chemotherapy - 5-FU, Irinotecan, Oxaliplatin;

- **5-FU ± Folinic acid (2wkly \* 6) - *Post-op* for 1yr** reduces Duke C mortality by ~25%
- Palliation of metastatic disease

## Prognosis

- Surgery has a **>98%** chance of cure
- **60%** are amenable to radical surgery - **75% 7YSR**
- Poor prognostic factors following surgery;
  - Pre-op ↑CEA ( $>5\text{ng/mL}$ )
  - Tumour penetration through the bowel wall
  - Tumour adherence to adjacent organs
  - Perforation
  - Tumour spread to regional LN
  - Number of regional LN involved
  - Venous invasion
  - Poorly differentiated histology
  - Aneuploidy
  - Specific chromosomal deletion (e.g. *allelic loss on chromosome 18q*)

# Stomas

A stoma is an **artificial union** made **between 2 conduits** (e.g. a choledochojejunostomy) or, more commonly **between a conduit & the outside** e.g. a colostomy (Mouth & anus are natural stomas)

- a) Ileostomy - Protrude from the skin & emit fluid motions which contain active enzymes (so skin needs protecting).
  - **End ileostomy** - Follows *proctocolectomy*, typically for *ulcerative colitis*
  - **Loop ileostomy** - Used instead of a colostomy for *defunctioning a low rectal anastomosis*; **Advantage** over loop colostomy - *Ease with which the bowel can be brought to the surface & the absence of odour.*
- b) Caecostomy - Indicated for **emergency situations** before definitive treatment is instituted.
- c) **Colostomy** is an *artificial opening* made in the large bowel to **divert faeces & flatus** to the exterior, where it can be collected in an external appliance.

Indications;

- **to Decompress** an obstructed colon e.g. **Sigmoid volvulus, Ca colon**
- **to Divert** the faecal stream in preparation for **resection of an inflammatory, obstructive, or perforated lesion** or following **traumatic injury** e.g. gangrenous colon
- to serve as the **Point of evacuation** of stool when the distal colon or rectum is removed e.g. **Ca rectum, Ca anus**
- **to Protect a distal anastomosis following resection**

Types;

- **Loop colostomy** - A loop of colon is exteriorized, opened & sewn to the skin. A rod under the loop prevents retraction & may be removed after **7d**. Used to **protect a distal anastomosis** or to **relieve distal obstruction** & most are made in the **transverse colon** but the **sigmoid colon** can also be suitable
- **End (Terminal) Colostomy** - The bowel is divided; the proximal end brought out as a stoma- Usually in the **LIF**; The distal end may be;
  - Resected e.g. abdominoperineal resection of the rectum
  - Closed & left in the abdomen - **Hartman's procedure**
  - Exteriorized forming a '**mucoous fistula**'
- **Double-barrelled (Paul-Mikulicz) colostomy** - A colostomy with *both ends of a colon exteriorized*. It may be closed using an enterotome.

Duration;

- **Temporary** - in which event it is subsequently closed, *usually after 6-8wks*
  - \* **Loop colostomy**
    - To defunction an anastomosis after **anterior resection**
    - To prevent faecal peritonitis developing following **traumatic injury to the rectum or colon**
    - To facilitate the operative treatment of a **high fistula in ano**
- **Permanent**;
  - **Hartman's colostomy**

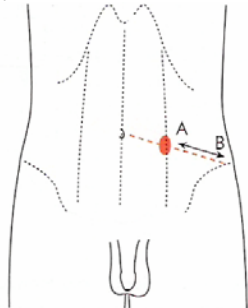


Figure 68.53 Usual site of a permanent (end) colostomy in the left iliac fossa. Note distance A-B, 2.5 cm at least.

Functionality;

- **Functioning colostomy** - *Discharges stool from normal external orifice i.e. the anus*;
  - **Loop colostomy**
- **Defunctioning colostomy** - *Stool is discharged through a stoma*
  - Double-barrelled (Paul-Mickulicz) colostomy
  - Divided colostomy
  - Hartman's colostomy



## Complications - 20% (15% require operative correction)

- **Anaesthetic complications**
- **Early;**
  - *Haemorrhage* - usually from granulomas around the margin of the colostomy
  - *Ischemia & Necrosis of the distal end* - due to technical errors in constructing the stoma.
  - *High output* (especially **ileostomies** - can lead to ↓K<sup>+</sup>)
  - *Obstruction* 2° to adhesions
  - *Stoma Retraction* - due to technical errors in constructing the stoma.
  - *Paracolostomy abscess*
- **Delayed;**
  - *Stenosis of the orifice* - largely avoided by maturing the colostomy at the operating table as with ileostomy.
  - *Stoma Prolapse*
  - *Chronic parastomal hernia* - develops because the abdominal wall aperture enlarges with time, allowing colon, omentum, or small bowel to herniate adjacent to the colostomy.
  - *Fistulae*
  - *Perforation* - avoided by putting a **de Pezzer catheter** (a self-retaining catheter with a bulbous extremity) and by maintaining the irrigation reservoir at no greater than shoulder height.
  - *Colostomy diarrhoea* - usually an infective enteritis & will respond to metronidazole.
  - Less serious complications include *faecal impaction*, and *skin irritation*.
  - *Psychological*



# Intestinal Fistula

## Small bowel fistulae

A fistula is an **abnormal communication** between a **hollow viscus and some other organ or structure**, including the skin.

### Classification

- i) According to the **sites of origin and termination** - e.g. *jejunocutaneous or ileovesical fistulas*.
- ii) According to **tissue of origin**;
  - Normal intestine
  - Associated with an abnormality such as *Crohn's disease or radiation enteritis*.
- iii) **Internal or External**
  - a) **Internal fistulae** - almost always the result of **chronic inflammation of the intestine**. Perforation and abscess formation leads to communication with an adjacent loop of bowel or viscus.
    - **Ileoileal and ileocolonic fistulae** are relatively harmless and often asymptomatic - *obstruction or sepsis* rather than the fistula itself are the usual reasons for resection.
    - **Fistulae to the bladder** or, rarely, to other parts of the urinary system, lead to recurrent bouts of urinary sepsis; for this reason they usually require resection.
    - **Duodenocholechal fistulae**, a rare complication of duodenal ulcer disease, are often asymptomatic, but may lead to episodes of biliary sepsis.
  - b) **External fistulae** include **duodenocutaneous or ileovaginal**
- iv) According to **amount of output**
  - a) **Low output fistulae** - These fistulae drain small amounts of fluid - **≤200 mL/day** which often has the appearance of *mucous or infected material* that does *not* suggest an intestinal origin.  
**Persistence** of a low output fistula usually indicates the presence of;
    - a *foreign body*, typically heavy sutures or mesh, or
    - an *intrinsic abnormality* of the intestine at the site of origin.
  - b) **High output fistulae** - These fistulae drain large amounts of fluid - **>500 mL/day** which is either from;
    - the *diversion* of a substantial part of the intestinal contents or
    - a very *proximal origin*, and many patients have partial or complete obstruction or extensive suture line dehiscence.

### Causes

- Local perforation of diseased bowel - **Internal fistulae**
- Surgery - *Almost all external fistulae*
  - Surgical *Foreign bodies* - usually mesh used in the repair of a fascial defect
  - Surgical *misadventures*
- Spontaneous - *Occur at the site of drainage of an abscess originating from a bowel perforation*
- Trauma

### Mx

#### Conservative

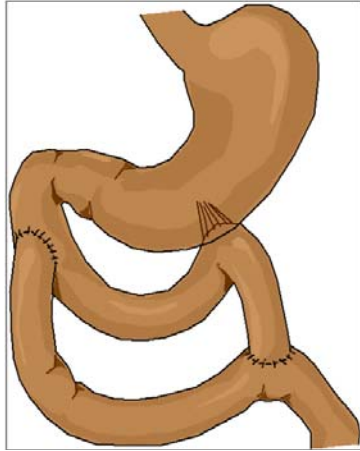
- i) **Fluid & electrolyte balance**
- ii) **Local skin care** - a collecting bag should be used as a means for protecting the skin and quantitating output.
- iii) **Ix**
  - a) **Fistulogram**, using a water soluble radio-opaque medium. If there is **no cavity**, **Barium studies** can then be used;
    - Size of the leak
    - Absence of distal obstruction
    - Presence of a tumour
    - Extent of inflammatory changes in the intestine itself
  - b) **Ultrasound study**
  - c) **CT scan**
- iv) **Decrease volume output if high**;
  - a) Placement of a **nasogastric tube** or if *long-term use* may be indicated, a **gastrostomy tube**.
  - b) **Pharmacological** means of decreasing output include the administration of **H<sub>2</sub> blockers** *without antacids* and **somatostatin analogues**.
- v) **Nutritional support**
- vi) **Control local sepsis** - Abscess cavities must be unroofed or drained and placing a catheter adjacent to or even in a fistula opening may be useful.

in a fistula opening may be useful.

## Surgical intervention

The definitive treatment of fistulae *that do not close spontaneously* is surgical resection.

- a) If **Direct closure** seems possible, *the suture line should be protected* by bringing up a loop of intact small intestine as a '**serosal patch**'. This condition meets the need of providing a normal local environment for healing.
- b) **Segmental resection & Anastomosis** - A segment of intestine is removed with anastomosis, the sutured bowel being placed in an area *not affected* by inflammation or other abnormality.
- c) A **Bypass** may be all that can be accomplished e.g. **Duodenal fistulae** - A **Roux-en-Y** limb is anastomosed over the fistula, converting it to a permanent internal fistula



## Complications

- *Acute obliterative peritonitis*

# Hernias

## Anterior Abdominal Wall Defects

### i) Omphaloceles

#### Embryology;

During development of the abdomen, **rapid growth of the gut in length** causes it to herniate into the umbilicus but then there is return of the gut into the abdominal cavity later in development failure of which an **omphalocele** is formed. Also the abdomen develops posterior → anterior bilaterally & thus most defects are in the midline due to failure of proper union.

#### Complications - Rupture;

- Pre-partum - The gut is sclerosed because of exposure to amniotic fluid
- Intra-partum
- Post-partum

#### Associated conditions - Beckwith Weidemann syndrome;

- Omphalocele
- Macroglossia
- Macrosomia
- Hypoglycaemia

### Ix - RBS

#### Mx;

- \* Start 10% dextrose drip while awaiting RBS results to prevent hypoglycaemic brain damage.

a) **Non-op** - Dress the omphalocele with sofratule every day with an aim to form granulation tissue then scar. The omphalocele becomes a hernia which can later be repaired.

#### b) Surgery;

\*\* Risk of splinting the diaphragm (& interfering with respiration) if the gut is just returned into the small abdominal cavity

#### Indications;

- Ruptured or unruptured omphalocele

#### Procedure;

- Stretch the abdominal wall & attempt to close the defect.
- If not possible, add a prosthesis. Twist the prosthesis everyday until it becomes flush with the skin. Remove the prosthesis & close the resultant defect.
- The child may need respiratory assistance in ICU

ii) Inguinal hernia - The processus vaginalis is patent allowing abdominal structures to herniate; Closes within the 1<sup>st</sup> yr of life.

iii) Umbilical hernia

iv) Prune belly syndrome - Failure of the lateral mesoderm to develop leading to;

- **MSS**
  - **Large, flaccid wrinkled abdominal wall with absent musculature**
  - Diastasis of the symphysis pubis & widely separated rectus abdominis muscle
- **GIT**
  - Malrotation of the gut
- **GUT**
  - Renal dysplasia or hypoplasia → oligohydramnios
  - **Hypertrophied, dilated collecting system (megaureters) and bladder without obstruction.**
  - Extrophy of the bladder
  - **Bilateral undescended testes (cryptorchidism)**
  - Epispadia

#### Mx;

- 1° urinary bladder closure
- No need for osteotomy before 72hrs; otherwise osteotomy so that the symphysis pubis can be approximated
- Later bladder neck reconstruction to achieve continence. Reimplantation of the ureters
- Repair of epispadias
- The child may later need bladder augmentation to increase the capacity of the bladder
- The child may also need an artificial sphincter

v) Extrophy of the cloaca - *Urinary & faecal streams* have to be managed.

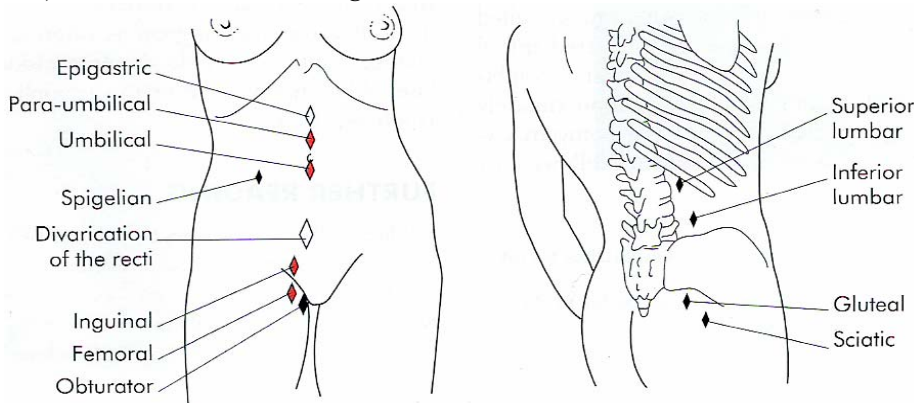
# Hernias

A hernia is a protrusion of a **viscus or part of a viscus** through an **opening** in the walls of its containing cavity.

**Commonest** cause of intestinal obstruction

## Types

- a) **Internal** - *Invisible* - *More common in children* - *Congenital*;
  - i) **Diaphragmatic hernias** e.g. Bochdalek hernias in the foramen of Bochdalek 2° to failure to close of the **left posterior part of the diaphragm**.
  - ii) **Hiatus Hernia**
- b) **External** - *Most common* - *Present with a visible swelling*
  - i) Inguinal hernia - **80%**
  - ii) Incisional hernia - **6-10%**
  - iii) Femoral hernia - **2-5%**
  - iv) Umbilical hernia - *Congenital*



**Red** - Common; **White** - Not unusual; **Black** - Rare

## Aetiology/Risk factors

1° (Congenital);

- An **indirect inguinal hernia** may occur in a congenital preformed sac - the remains of the **processus vaginalis**
- **Umbilical hernia**

2°;

- Any condition that **raises intra-abdominal pressure** e.g.
  - Chronic cough (*bronchiectasis, asthma*)
  - Powerful muscular effort
  - Straining on micturition
  - Straining on defecation (*chronic constipation*)
  - Intra-abdominal malignancy
  - Pregnancy
- **Smoking** - leads to acquired collagen deficiency
- **Obesity** - Fat;
  - Separates muscle bundles & layers
  - Weakens aponeuroses
  - Usually;
    - \* Hiatus hernia
    - \* Paraumbilical hernia
    - \* **Direct** inguinal hernia
- **Multiparity** - Causes **femoral hernias** due to stretching of the pelvic ligaments
- **Iatrogenic**;
  - Incisional hernias
  - *Peritoneal dialysis* can cause the development of a hernia from a *previously occult weakness or enlargement of a patent processus vaginalis*.
- **Trauma**

## Composition of a Hernia

- i) The sac - This is a **diverticulum of peritoneum**, consisting of;
  - Mouth
  - Neck;
    - *Well defined* - a narrow neck that could lead to strangulation of the bowel
      - \* **Indirect** inguinal hernias
      - \* Femoral hernias
      - \* Paraumbilical hernias
    - *Not well defined* (no actual neck)
      - \* **Direct** inguinal hernias
      - \* Incisional hernias
  - Body & fundus
- ii) The coverings of the Sac - Derived from layers of the abdominal wall through which the sac passes.
- iii) Contents of the Sac;
  - Omentum = *Omentocele*
  - Intestine = *Enterocoele* - **More commonly small bowel**, but may be large intestine or appendix  
A portion of the circumference of the intestine = **Richter's hernia** - Involve the **bowel wall only, not lumen.**
  - A portion of the **bladder (or a diverticulum)** - may constitute part of or be the sole contents of a;
    - **Direct** inguinal Hernia
    - Sliding inguinal hernia
    - Femoral Hernia
  - Ovary ± the corresponding fallopian tube
  - A Meckel's diverticulum = a **Littre's hernia**
  - Fluid - as part of ascites or as a residuum thereof

## Classification

- i) Reducible - contents **can be returned** to abdomen
  - The hernia either reduces itself when the **patient lies down** or can be reduced by the patient or the surgeon
  - Imparts an **expansile impulse on coughing**
  - The **intestine** usually gurgles on reduction & the **first portion** is more **difficult** to reduce than the last
  - The **omentum** in contrast, is doughy, & the **last portion** is more **difficult** to reduce than the first.
- ii) Irreducible - contents **cannot** be returned but there are **no** other complications; Usually due to **adhesions between the sac & it's contents** or from **overcrowding within the sac**  
Usually **omentocele**, especially in **femoral & umbilical hernias**  
There is a **risk of strangulation** at any time
- iii) Obstructed - **Irreducible hernia** containing intestine which is **obstructed** from without or within but there is **no interference to the blood supply to the bowel.**  
**C/P** - Colicky abdominal pain & tenderness; usually **goes on to strangulation**  
**Incarcerated hernia** - If the lumen of the portion of the colon occupying a hernial sac is blocked with faeces.
- iv) Strangulated - Blood supply of bowel is obstructed rendering the contents ischemic; **gangrene** can occur within **5-6hrs**; More common in **femoral hernias** because of the **narrowness of the neck & its rigid surrounds.**
- v) Inflamed - contents of sac have become inflamed

## Pathology

The intestine is **obstructed & it's blood supply impaired**. Initially only the **venous return is impeded**, the wall of the intestine becomes **congested & bright red** with **transudation** of serous fluid into the sac. As congestion increases, the wall of the intestine becomes **purple** in colour. The intestinal pressure increases, **distending the intestinal loop & impairing venous return further**. As venous stasis increases, the **arterial supply becomes more & more impaired**. Blood is **extravasated under the serosa & is effused into the lumen**. The fluid in the sac becomes blood-stained & the shining serosa dull due to a **fibrinous, sticky exudate**. At this stage, the walls of the intestine have lost their tone & become friable.

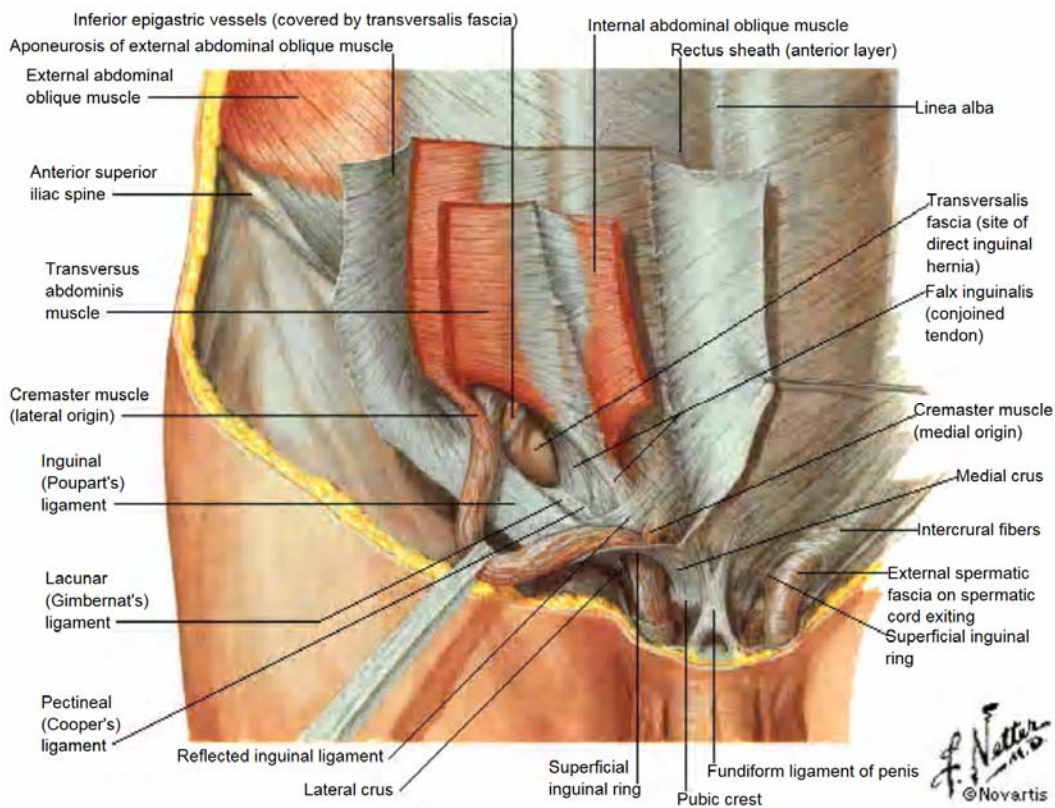
**Bacterial transudation** occurs 2° to the **lowered intestinal viability** & the sac fluid becomes infected. **Gangrene** commences at the **rings of constriction**, which become deeply indented & grey in colour, then develops in the **antimesenteric border**, the colour varying from black to green depending on the decomposition of blood in the subserosa. **The mesentery** involved by the strangulation also becomes gangrenous. If the strangulation is **unrelieved**, **perforation** of the wall of the intestine occurs, either at the **convexity of the loop** or at the **seat of constriction**. **Peritonitis** spreads from the sac to the peritoneal cavity.

C/P

- **Non-strangulated hernias** - **Soft** & exhibit **no pain**
- **Strangulated hernias** - Sudden **pain**, at first situated over the hernia, followed by generalised abdominal pain, colicky in character & often located mainly at the **umbilicus**. **Nausea &** subsequent **vomiting** ensue. Unless the strangulation is relieved by operation, the spasm of pain continue until *peristaltic contractions cease* with the onset of **ischemia**, when **paralytic ileus** (*often the result of peritonitis*) & **septicaemia** develop. **Spontaneous cessation of pain** must be viewed with caution, as this may be a **sign of perforation**
- **O/E** - The hernia is **tense, extremely tender, irreducible** & there is **no expansile cough impulse**
- Increase in hernia size

## Inguinal Hernias

### Surgical anatomy



### Abdominal incision - Pfannenstiel incision

- Skin
- Subcutaneous tissue
- Superficial fascia
  - Camper's - Fatty
  - Scarpa's - Membranous
- Rectus sheath - Aponeurosis of external oblique muscle
- Rectus abdominis
- Pyramidalis muscle
- Transversalis fascia
- Extra-peritoneal (subserous) fascia (areola tissue)/Pre-peritoneal fat
- Peritoneum



The **Superficial/External inguinal ring** is a triangular aperture in the **aponeurosis of the external oblique**. The ring is bounded by a *superomedial* & an *inferolateral crus* joined by the criss-cross *intercrural fibres*. Normally the ring will **not** admit the tip of the little finger.

The **Deep/Internal inguinal ring** is a U-shaped **condensation of the transversalis fascia above the inguinal (Poupart's) ligament**, midway between the symphysis pubis & the ASIS. The transversalis fascia is the fascial envelope of the abdomen & the competency of the deep inguinal ring depends on the integrity of this fascia.

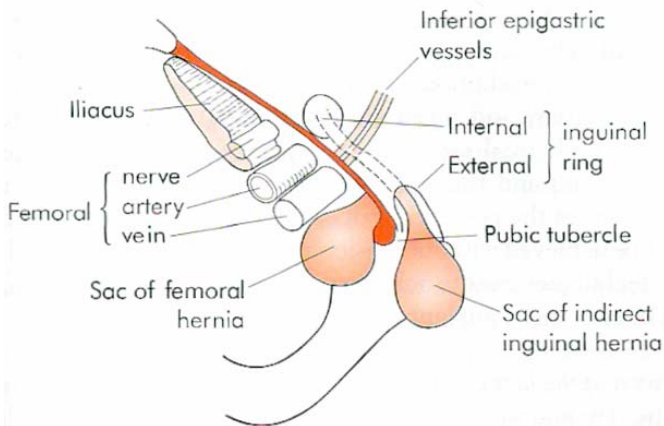
The **inferior epigastric vessels** lie **medial** to the ring. It is defined as being the **inguinal ligament's mid-point 1½ cm above the femoral pulse** (which crosses the mid-inguinal point)

The **inguinal canal** is directed **downwards & medially** from the **deep to the superficial inguinal ring**.

- Boundaries;
  - **Floor** - Inguinal ligament, cooper's.
  - **Roof** - Fibres of transversalis & internal oblique
  - **Front** - External oblique aponeurosis + Internal oblique for the lateral ½
  - **Back** - Laterally, transversalis fascia; medially, conjoined tendon (internal oblique & transversus abdominis)
- Contents;
  - Encased in cremasteric fascia;
    - \* Spermatic cord/Round ligament (in females)
    - \* Testicular vessels
    - \* Genital branch of the genitofemoral nerve
    - \* Ilioinguinal nerve
  - Spermatic fascia (Internal - Transversalis fascia; External - External oblique Aponeurosis)

An **inguinal** hernia can be differentiated from a **femoral** hernia by ascertaining the relation of the **neck of the sac to the medial end of the inguinal ligament & the pubic tubercle**, i.e. in the case of an **inguinal hernia**, the **neck is above & medial**, while that of a **femoral hernia** is **below & lateral**.

Digital control of the **internal ring** may help in distinguishing between an **indirect & a direct** inguinal hernia - The hernia is reduced & the internal ring occluded with **2 fingers**; The patient is asked to cough - if the hernia is **restrained**, it is **indirect**, if it **pops out**, it is **direct**.



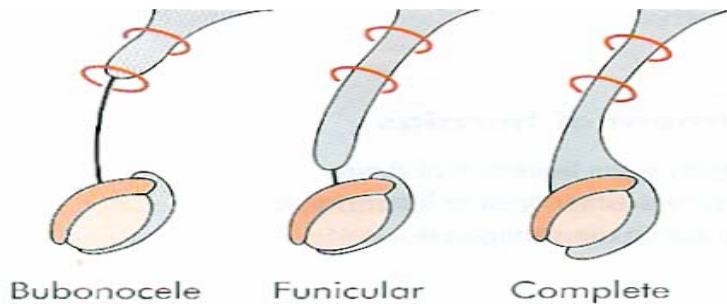
## a) Indirect (Oblique) Inguinal Hernia

### **Incidence**

- **Most common** of all forms of hernia; Most common in the **young**
- **0-10yrs** - More common on the **right** side in **males** due to the *later descent of the right testis* & a higher incidence of failure of closure of the processus vaginalis.
- **Adults;**
  - **65%** of inguinal hernias are **indirect**
  - **55%** are **right** sided; Bilateral in 12%

**Pathogenesis** - Travels **down the canal** on the outer (**lateral & anterior**) side of the spermatic cord. The neck is **lateral** to the inferior epigastric vessels

**Types;**



- i) **Bubonocele** - The hernia is limited to the inguinal canal
- ii) **Funicular** - The processus vaginalis is closed just above the epididymis. The contents of the sac can be felt separately from the testis which lies below the hernia
- iii) **Complete (scrotal)** - the testis appears to lie within the lower part of the hernia. Rarely present at birth.

**C/P;**

- Pain in the groin or pain referred to the testicle when performing heavy work or taking strenuous exercise.
- In large hernias, there is a sensation of weight & dragging on the mesentery & this may produce epigastric pain

**O/E;**

The clinician examines the patient from the front with the patient standing with the legs apart & also when lying down to check for reducibility.

Examination using finger & thumb across the neck of the scrotum will help to distinguish between a swelling of inguinal origin & one that is entirely intrascrotal.

- When asked to cough, a small transient bulging may be seen & felt together with an expansile impulse. When the sac is still limited to the inguinal canal, the bulge may be better seen by observing the inguinal region from the side or even looking down the abdominal wall while standing behind the relevant shoulder of the patient.
- In infants, the swelling appears when the child cries; it can be translucent in infancy & early childhood but never in an adult
- In girls the ovary may prolapse into the sac

**DDx;**

- Male;
  - A vaginal hydrocele
  - An encysted hydrocele of the cord
  - A lipoma of the cord
  - Spermatocele
  - A femoral hernia
  - An incomplete descended testis in the inguinal canal. An inguinal hernia is often associated with this condition
- Females;
  - A hydrocele of the canal of Nuck - **most common DDx**
  - A femoral hernia

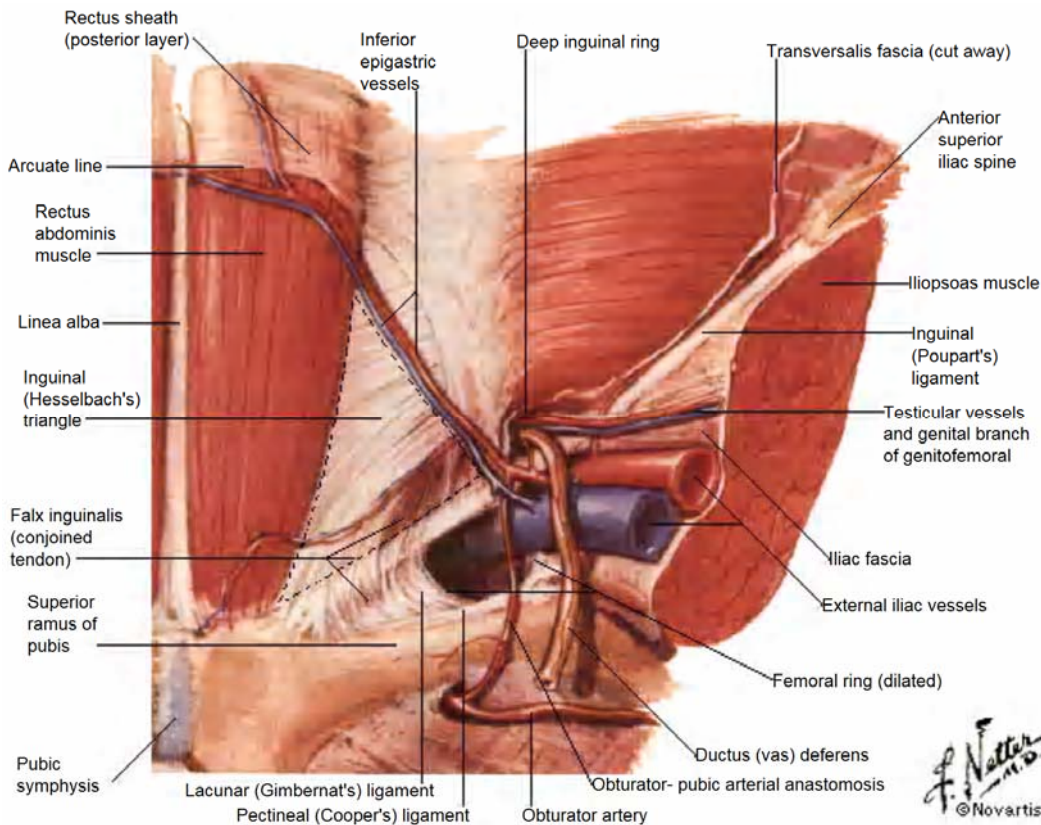
## b) Direct Hernia

**Incidence** - 35% of inguinal hernias; Most common in the **older males**. **Women** practically **never** develop a direct inguinal hernia

### Risk factors;

- Smoking
- Occupations that involve straining & heavy lifting
- Damage to the **ilioinguinal nerve** (previous appendicectomy) - due to resulting weakness of the conjoined tendon.

**Pathogenesis** - A direct inguinal hernia is **always acquired**. The sac passes through a **weakness or defect** of the **transversalis fascia in the posterior wall** of the inguinal canal usually in the **Hesselbach's triangle**. The hernia usually emerges **medial** to the inferior epigastric vessels **except** in the **saddle-bag type or pantaloon type**, which has both a lateral & medial component & lie **behind** the **spermatic cord**. They **reduce easily** & **rarely strangulate**.



### Mx

Manage causative factors

- ▶ **Inguinal herniotomy** - Dissect out & open the hernial sac, reduce any contents & then transfix the neck of the sac & remove any remainder. Recommended for **Infants**, adolescents & young adults;
- ▶ **Herniotomy & Repair (Herniorrhaphy);**
  - i) Excision of the hernial sac; plus
  - ii) Repair of the stretched *internal inguinal ring* & *the transversalis fascia*; &
    - **Shouldice operation** - This involves multilayered tension-free suturing involving both the anterior & posterior walls of the inguinal canal between the internal oblique aponeurosis arch & the inguinal ligament using monofilament materials, polypropylene, polyamide or wire
  - iii) Further reinforcement of the posterior wall of the inguinal canal - **(ii) & (iii)** must be achieved without tension resulting in the wound.
    - **Mesh techniques e.g. Lichtenstein tension-free hernioplasty** involves placement of a mesh - synthetic e.g. Dacron or Patient's own tissues e.g. fascia lata, external oblique aponeurosis) as an extra lamina, anterior to the posterior wall & overlapping it generously in all directions, including medially over the pubic tubercle.

# Femoral Hernia

## Anatomy;

- Boundaries of the femoral canal;
  - Anteriorly & Medially - The inguinal ligament
  - Laterally - The femoral vein
  - Posteriorly - The pectineal ligament
- Contents;
  - Fat
  - Cloquet's node

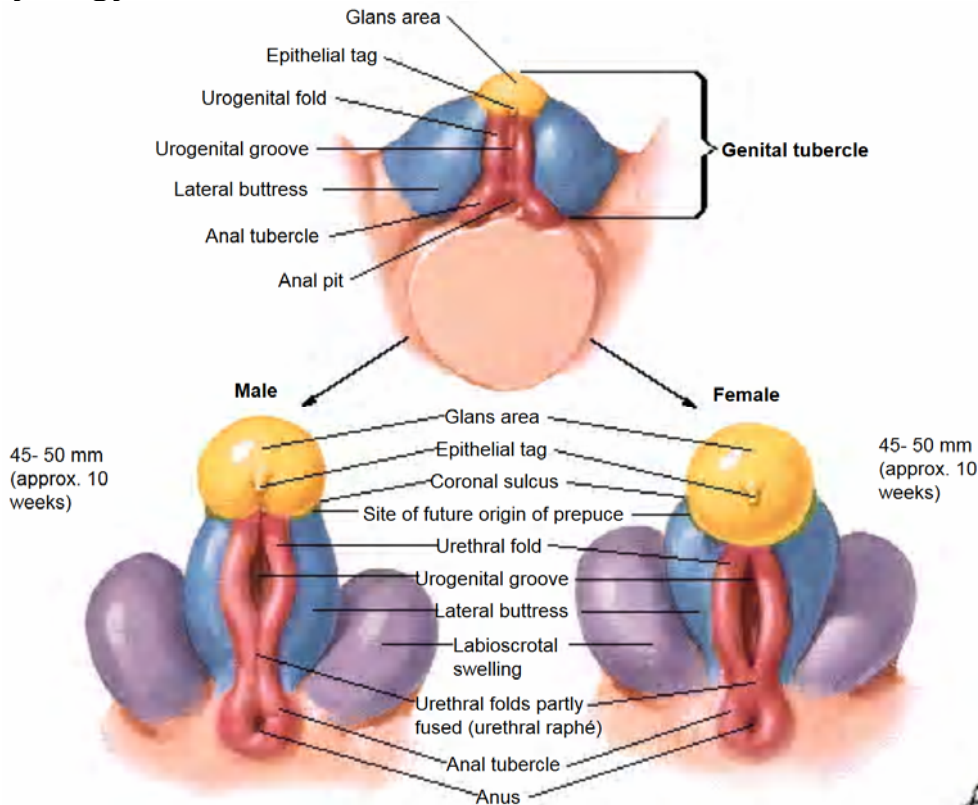
**Incidence** - Occur more often in **women**

## Pathogenesis

The neck of the hernia is felt **below & lateral to the pubic tubercle** (inguinal hernias are above & medial to this point). Bowel enters the femoral canal, presenting with a mass in the **upper medial thigh** or **above the inguinal ligament** where it points down the leg, unlike an inguinal hernia which points to the groin. They are likely to be **irreducible & to strangulate**.

# Ambiguous Genitalia

## Embryology



The **short arm of the Y chromosome** codes for the formation of **H-Y antigens** that act on the **primitive gonad** to become the **testis** which produces;

- a) **Testosterone** - Converted by *5 $\alpha$ -reductase* to **DHT** which acts on the;
  - **Paramesonephric ducts** to become the **vas deferens**
  - **Urethral folds** to form the **male urethra** &
  - **Labioscrotal swelling** to become the **scrotum**.
- b) **Mullerian inhibiting substance** - Causes Mullerian structures to regress

## Aetiology

- i) **True hermaphroditism**
- ii) **Pseudohermaphroditism**
  - a) **Female pseudohermaphroditism - Masculinization of the genetic female;**
    - Congenital Adrenal Hyperplasia
    - Androgen exposure in-utero;
      - Maternal congenital adrenal hyperplasia
      - Maternal adrenal tumour
      - Maternal drugs
      - Luteoma of pregnancy
      - Idiopathic
  - b) **Male pseudohermaphroditism - Feminization of the genetic male;**
    - Mixed gonadal dysgenesis
    - Maternal antiandrogens
    - Androgen resistance;
      - Receptor -ve
      - Receptor +ve with no response
    - Enzymatic defects of *testis* & *adrenals*;
      - *5 $\alpha$ -reductase* deficiency
      - *17-Hydroxylase* deficiency
      - *17-20 lyase* deficiency
      - *20-22 lyase* deficiency
    - Associated dysmorphic syndromes

**iii) Severe hypospadias - *not hormonally mediated***

## Associated medical problems

- Androgenital syndromes;
  - a) Salt **losing**
  - b) Salt **gaining** hence *hypertensive*

## Ix

- Barr bodies - *Buccal mucosa*
- Karyotyping - *Photographic representation of the stained preparation of chromosomes*
- Pelvic U/S - *Uterus & gonads*
- Genitograms; Put in all the perineal orifices
  - Male contrast in the urinary bladder
  - Female contrast into vagina
- Mini-laparotomy + biopsy of present gonads;
  - Look for uterus
  - What to do with ovotestis?

## Mx

- The newborn should **not** leave hospital without an assigned sex;
  - Genetic sex - XX or XY
  - Rearing sex - Based on name, clothing & schooling
- Manage associated medical problems - *Androgenital syndromes, Cortisol deficiency*
- Surgical - **Construct female (easier) external genitalia for all of them**

# Obstructive Uropathy

## OHCM - Pg 266

### Causes of Obstructive Uropathy (*Common causes in **BOLD***)

#### a) Renal causes;

- Congenital;
  - Ectopia/Crossed ectopia (*Both kidneys on one side*)
  - Malrotation
  - Horseshoe kidney - *joined at the centre*
- **Inflammatory;**
  - **Strictures**
  - **TB**
  - **Trauma**
  - **Calculi**
  - **Urinomas** (*Urine leaks out of tract & provokes an inflammatory reaction healing with scarring*)
- **Trauma;**
  - **Direct**
  - **Indirect**
- Tumours;
  - 1°;
    - \* Benign e.g. *fibroma, adenoma, lipoma*
    - \* Malignant e.g. *RCC, Wilms' tumour (in kids)*
  - 2° - From *Hepatoma, Ca colon, Lymphomas*

#### b) Ureteric causes;

- Duplex ureters (entanglement)
- Upper 1/3 - **PUJ obstruction**
  - Idiopathic
  - Aberrant blood vessel to lower pole of kidney
- Lower 1/3 + Juxtavesical portion;
  - **Surgical trauma (OBGY)**
  - **Calculi**
  - **Strictures**
  - **Retroperitoneal fibrosis**
  - **Tumours**
  - Periureteritis
- Intramural length;
  - **VUR**
  - **Ascending infection**
  - Rigid tube
- Intravesical orifice narrowing;
  - **Infections - Schistosomiasis, TB**
  - **Strictures**
  - **Calculi**
  - **Bladder tumours**
  - Granuloma, polyps, nodules, cysts

#### c) Bladder wall causes;

- Congenital e.g. *Ectopia vesicae*
- **Infections e.g. Schistosomiasis, TB**
- **Trauma**
- **Tumours - Ca bladder**

#### d) Bladder Neck;

- **PUV in boys- Membrane covering bladder neck**
- **Obstruction;**
  - **Stenosis**
  - **Calculi**
  - **Strictures**
- **Prostrate;**
  - **Prostitis**
  - **BPE**
  - **Ca prostate**

#### e) Urethral causes;

- Congenital e.g. *hypospadias, epispadias*
- **Strictures usually 2° to chlamydial infection of the membranous urethra**
- **Trauma - Fracture of the penis**
- Tumours - *Ca urethra*
- Meatal stenosis
- Phimosis

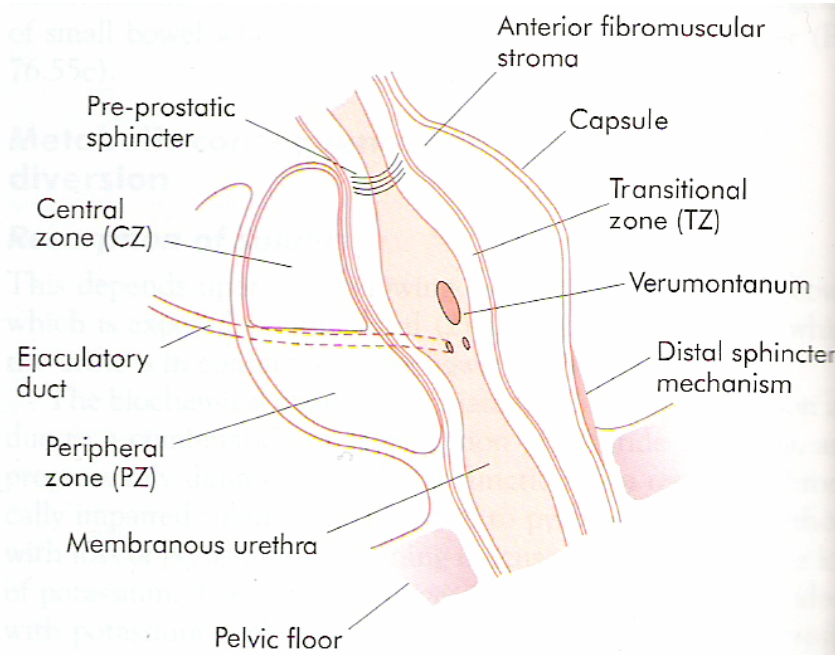


# The Prostate

## Anatomy

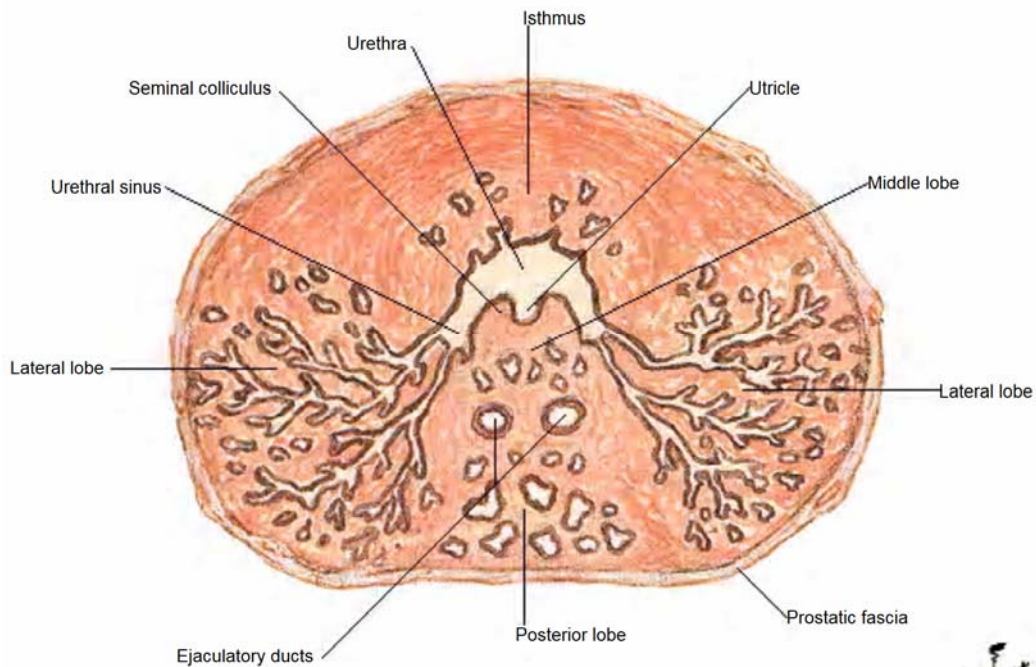
Normal weight - **25gm** but increases with age (50yrs - **35gm**)

### Divisions of the prostate;



**Figure 77.1** Sagittal diagram of prostate just lateral to the urethra showing the division into the different zones described by McNeal. The transitional zone is the area from which most benign prostatic hyperplasia (BPH) arises.

- **Periurethral transitional zone (TZ)** - From which most **Benign Prostatic Enlargement (BPE)** arises
- **Central zone (CZ)** - Lies posterior to the urethral lumen & above the ejaculatory ducts as they pass through the prostate.
- **Peripheral zone (PZ)** - Posterior & site of most **carcinomas**



# BPE (BPH is a *histological diagnosis*)

## Incidence

Occurs in men >50yrs; Peaks between **60-80yrs**; by the age of **60yrs, 50%** of men have histological evidence of BPH

## Aetiology

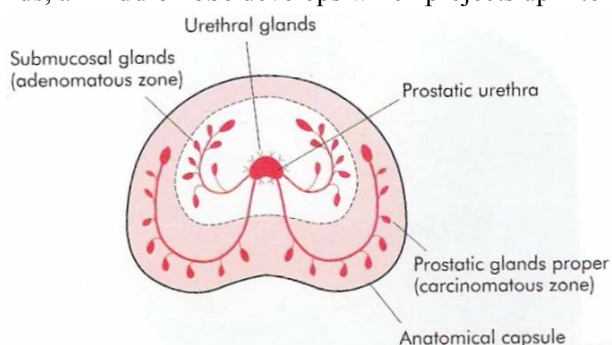
Serum **testosterone** levels **decrease** with **advancing age**; however, levels of **oestrogenic steroids** are **not decreased** equally & thus the **prostate enlarges because of oestrogenic effects** which are *hypothesised* to modulate;

- **Stromal-epithelial interactions** (stromal cells may regulate growth of *epithelial cells or other stromal cells* via a paracrine or autocrine mechanism by secreting growth factors such as **b-FGF or TGF- $\beta$** )
- **Aging** may result in *stem cells undergoing a block in the maturation process*, preventing them from entering into apoptosis.

It is likely that the secretion of **intermediate peptide growth factors** plays a part in the development of BPE.

## Pathogenesis

From **40yrs**, the prostate increases in volume by **2.4cm<sup>3</sup>/yr** on average. BPE starts in the **Periurethral transitional zone**, & the **submucosal glands & connective tissue stroma** undergo **hyperplasia** and the **smooth muscle hypertrophies** forming a nodular enlargement compressing the **outer PZ** of the prostate, which becomes the **false capsule** (surgical capsule) & causes the appearance of the typical '**lateral**' lobes. When BPE affects the **subcervical CZ glands**, a '**middle**' lobe develops which projects up into the bladder within the internal sphincter.



**Figure 77.2** A transverse section of the prostate. The peripheral zone is the area from which most prostate cancers arise. The 'adenomatous' zone comprises the central and transitional zones.

## Effects of BPE

### a) Anatomic effects;

- **Bladder** - If BPE causes **BOO**, the musculature of the **bladder hypertrophies** to overcome the obstruction & appears **trabeculated**. Significant BPE is associated with *increased blood flow*, & the resultant **veins at the base of the bladder** are apt to cause **haematuria**.
- **Urethra** - The prostatic urethra is **lengthened** (Normal length - **2cm**) but is **not narrowed** anatomically. The normal **posterior curve** may be so **exaggerated** that it requires a curved catheter to negotiate it. When **only one lateral lobe** is enlarged, **distortion** of the prostatic urethra occurs.

### b) Physiological effects;

- No symptoms, No BOO
- No symptoms, but **urodynamic evidence of BOO**.
  - \* Voiding pressures *increase*
  - \* Urinary flow rates *decrease*
  - \* Long-term effects;
    - The bladder may **decompensate** so that detrusor contraction becomes progressively *less efficient* & a residual urine develops
    - The bladder may become more irritable during filling with a *decrease in functional capacity* partly caused by *detrusor overactivity* which may also be caused by **neurological dysfunction or ageing, or be idiopathic**
- LUTS, No BOO
- LUTS & BOO
- Others (**Acute/chronic retention, haematuria, urinary infection & stone formation**)

S/S - ~2yr Hx;

a) Lower Urinary Tract Symptoms (LUTS)

- Storage; (\* 2° to bladder irritation)
  - Frequency\*
  - Nocturia\* - Urine passed  $\geq 3$  times at night 2° to  $\uparrow$  venous return &  $\uparrow$  Residual volume due to detrusor muscle weakness
  - Urgency\*
  - Urge incontinence\*
  - Nocturnal incontinence
- Voiding;
  - Hesitancy (worsened if bladder is very full) - 2° to **reduced reactivity** of the bladder to stimulation
  - Poor flow (**worsened** by straining)
  - Intermittent stream - stops & starts
  - Dribbling (including after micturition) - *Post micturition dribbling* is **not** a consequence of BOO & is **not** improved by prostatectomy.
  - Sensation of poor bladder emptying\*
  - Episodes of near retention

14.39 DETERMINING THE INTERNATIONAL PROSTATE SYMPTOM SCORE (IPSS): A WORKING EXAMPLE FOR A PATIENT WITH MODERATE SYMPTOMS							
IPSS	Not at all	Less than 1 time in 5	Less than half the time	About half the time	More than half the time	Almost always	Your score
1. Straining	0	1	②	3	4	5	
2. Weak stream	0	1	②	3	4	5	
3. Intermittency	0	1	②	3	4	5	
4. Incomplete emptying	0	1	②	3	4	5	
5. Frequency	0	1	②	3	4	5	
6. Urgency	0	1	②	3	4	5	
7. Nocturia (times per night)	0	①	2	3	4	5	
<b>Total IPSS score</b>							<b>13</b>
Quality of life	Delighted 0	Pleased 1	Satisfied 2	Mixed ③	Dissatisfied 4	Unhappy 5	Terrible 6
<b>Key Scores:</b> 0–7 = mild symptoms; 8–19 = moderate symptoms; 20–35 = severe symptoms.							

b) Bladder Outflow tract Obstruction (BOO) - (Pain is **not** a symptom of BOO)

- i) Impaired bladder emptying
- ii) Haematuria - BPE is a commoner cause of Haematuria than Ca Prostate
- iii) Retention - Means not emptying the bladder (because of obstruction or  $\downarrow$  detrusor power);
  - ▶ Acute retention - The bladder is usually tender, containing ~ 600mL of urine.

Causes - Usually prostatic obstruction in men precipitated by;

- 'Holding on'
- Alcohol
- Constipation
- Infection
- Pain
- Medication - Anticholinergics, Anaesthetics

S/S - LUTS + Pain

- O/E;
- Abdomen + DRE
  - Perineal sensation (cauda equina compression)

- Ix;
- Urinalysis
  - FBC + U/E/C
  - Renal U/S if RFTs deranged
  - RBS to r/o DM nephropathy
  - PSA

- Mx;
- Tricks to aid voiding;
    - \* Analgesia
    - \* Privacy on hospital wards
    - \* Ambulation

- \* Standing to void
- \* Voiding to the sound of *running taps* - or in a hot bath.
- If tricks fail;
  - \* Catheterize & try a prostate procedure; After e.g. **7d**, trial without catheter may work (especially <75yrs old & <1L drained or retention was triggered by a passing event, e.g. GA)

**Prevention** - *Finasteride* reduces prostate size & retention risk.

- **Chronic retention** - Is more insidious & is due to ↑ *residual volume of urine* (Normal <30mL). Bladder capacity may be >1.5L.

**C/P;**

- **Painless**
- *Overflow* incontinence - 2° to *hydrostatic pressure* on the urine with a *weak sphincter*
- Acute on chronic retention (*Painful*)
- A lower abdominal mass
- UTI or renal failure

**Causes;**

- Prostatic enlargement
- Pelvic malignancy
- Rectal surgery
- DM
- CNS disease e.g. *Transverse myelitis, MS, Zoster (S2-S4)*

**Mx;**

- Institute definitive treatment immediately.
- *Only catheterize* the patient *if* there is;
  - \* Pain
  - \* Urinary infection
  - \* Renal impairment (e.g. urea >12mmol/L)

## DRE

In BPE, the **posterior surface** of the prostate is **smooth, convex & typically elastic**, but the **fibrous element may give the prostate a firm consistency**. The **rectal mucosa** can be made to **move over the prostate**. If there is considerable amount of urine present, it pushes the prostate downwards, making it appear larger than it is. If you **cannot get to the upper margin** of the prostate, then it is assumed to be **>70gm**

\*\* Do venepuncture for PSA **before** DRE, as DRE can ↑ **total PSA** by approx. **1ng/mL (Free PSA ↑ by 10%)**

**Grading;**

- A - Normal
- B - Enlarged but can get to the upper margin **easily**
- C - Enlarged, **cant** get to the upper margin **easily**
- D - Enlarged, **cannot** get to the upper margin - Prostate assumed to be **>70gm**

## DDx;

\* **LUTS;**

- BPE
- Idiopathic detrusor overactivity
- Degeneration of bladder smooth muscle giving rise to impaired voiding & detrusor instability
- Neuropathic bladder dysfunction as a result of *Diabetes, Stroke, Alzheimer's disease or Parkinson's disease*

\* **BOO;**

- Bladder neck stenosis
  - Bladder neck hypertrophy
  - BPE
  - Prostatic cancer
  - Urethral strictures
  - PUVs
  - Functional obstruction due to neuropathic conditions
- \* **Haematuria** - OHCM Pg 258

## Ix

- Urinalysis
- Urine culture for infection
- U/E/C - Renal function
- MCU - Differentiates other causes e.g. *Strictures, Calculi*
- Pelvic U/S - *Residual volume* ↑, *Hydronephrosis*
- Urinary flow rate (*Normal - 15mL/s*) & residual volume measurement (*Normal - <30mL*)
- R/O;
  - Diabetic Neuropathy - **RBS**
  - Ca Prostate;
    - \* PSA
    - \* Transrectal U/S (TRUS) ± TruCut Biopsy
- Pressure-flow studies

## Mx;

### a) Conservative management

#### Indications;

- \* Mild symptoms
- \* Reasonable flow rates (**>10mL/s**)
- \* Good bladder emptying (**residual urine <100ml**)

#### Mx;

- Watchful waiting for **6 months** is an option but risks *incontinence, retention & renal failure*.
- Drugs may be useful in mild disease, & while awaiting TURP, e.g.;
  - **Prostate <40cm<sup>3</sup>** - Drugs of choice - **α<sub>1A</sub>-blockers e.g. Tamsulosin, alfuzosin, doxazosin, terazosin**. These ↓ **smooth muscle tone (prostate & bladder)**; S/E - Drowsiness; depression; dizziness; BP↓; dry mouth; ejaculatory failure; extrapyramidal signs; nasal congestion; weight ↑
  - **Prostate >40cm<sup>3</sup>** - **5α-reductase inhibitors e.g. finasteride, dutasteride** *Reduce testosterone's conversion to dihydrotestosterone*, the androgen which is effective. S/E - Impotence; libido↓; retrograde ejaculation.  
They can *prevent retention* but have odd effects on risk of prostate cancer - ↓*risk of indolent cancers (Gleason 2-4)*, **but ↑ risk if Gleason >7** ;  
Effects on prostate size are limited & slow, so if α-blockers fail, many try surgery next.
- **Phytotherapy** - *saw palmetto* berry, the bark of *Pygeum africanum*, the roots of *Echinacea purpurea* and *Hypoxis rooperi*, pollen extract, and the leaves of the *trembling poplar*.

### b) Prostatectomy;

#### Indications for prostatectomy;

- Complications of BOO;
  - Haemorrhage - Occasionally venous bleeding from a ruptured vein overlying the prostate
  - Acute retention in fit men with no other cause for retention
  - Chronic retention & renal impairment; **a residual urine of ≥200mL, a raised blood urea, hydroureter or hydronephrosis & uraemic manifestations**
  - Stone
  - Infection
  - Diverticulum formation
- Elective prostatectomy for severe symptoms;
  - *Increasing difficulty in micturition*, with considerable frequency (Frequency alone is **not** an indication)
  - *Delay in starting & a poor stream*
- Low maximum flow rate (**<10mL/s**)

### Pre-op Counselling on Risks of TURP;

- Haematuria/Haemorrhage
  - Infection; proctitis
  - **Incontinence** -  $\leq 10\%$
  - **Retrograde ejaculation** - **65%** - *Resection of the sphincter in the upper part of the prostate & bladder neck* that subserves a sexual function.
  - **Erectile Dysfunction** -  $\leq 14\%$  - results from *damage of the region of the neurovascular bundle supplying the autonomic innervation to the corpora of the penis* in close relationship to the *posterolateral* aspect of the prostatic capsule
  - Haematospermia
  - Urethral trauma/Stricture
  - Clot retention near strictures
  - Post **TURP syndrome** ( $\downarrow T^\circ$ ,  $\downarrow Na^+$ ) - Systemic absorption of the hypotonic bladder irrigation fluid used intraoperatively (usually **1.2% Glycine or Purisol** is used - *isosmolar & high conductance*) leads to;
    - Hypervolaemia with  $\uparrow BP$
    - Dilutional  $\downarrow Na^+$
    - Haemolysis
    - Cerebral oedema
- Mx** - Diuresis - **Furosemide + Mannitol**
- Rupture of the Denonvilliers' fascia causing a **faecal fistula**
  - $\sim 20\%$  need redoing within **10yrs**

### Procedures;

#### a) Transurethral Procedures;

- Transurethral Incision of the Prostate** - It relieves pressure on the urethra with minimal destruction & less risk of sexual dysfunction - Best surgical option for those with small glands **<30gm**
- Transurethral Resection of the Prostate (TURP)** - Indicated for small prostates - **50-70gm**;  
\*Post-op - Put a 20F or 22F Echmann's **3-way hematuria catheter** (*Balloning, irrigation & drainage*) for **5-7days**
- Transurethral Laser-Induced Prostatectomy (TULIP)**

#### b) Open procedures - Extra-peritoneal mobilization of the prostate for large glands **>100cm<sup>3</sup>; (>60gm)**.

- Transvesical prostatectomy/(Frayer's prostatectomy)**  
\*Post-op - **Twin-tube bladder irrigation** with warm saline to wash out clots till effluent is clear (**1-2days**); Remove *urethral catheter* after **8-14days**.
- Retropubic prostatectomy/(Milin's prostatectomy)**  
\*Post-op - Put a **3-way catheter** (*Balloning, irrigation & drainage*) for **5-7days**

#### Advantages of Open Procedures;

- \* *Reduced re-op rate (1.8%)*
- \* *Peak flow post-op is good*
- \* *Mortality is lower*

### Post-op Advice

- Avoid **driving** for **2wks** after the operation
- Avoid **sex** for **2wks** after surgery
- Expect to **pass blood** in the urine for the first **2wks**
- At first you may need to urinate more frequently than before. In **6wks**, things should be much better - but the operation cannot be guaranteed to work (**8% fail**, & lasting **incontinence** is a problem in **6%**)
- **12-20%** may need **repeat TURPs within 8yrs**, compared with **1.8%** of men undergoing **open prostatectomy**
- If **feverish**, or if **urination hurts**, do urinalysis, m/c/s.



# Ca (Adenocarcinoma) Prostate

## Incidence

Most common malignant tumour in men >45yrs (*BPE - Older patients - 60-80yrs*)

## Associations

- Age - >45yrs
- ↑ Testosterone
- **10-15%** of younger men who develop prostate cancer have a **+ve family history** of the disease - Thought to be defects in **Chromosome 1** inherited **AD**
- Dietary - *Fat, Meat & Alcohol*
- Environmental factors
- ? ↑ Sexual activity

## Sites

- **70% - Peripheral zone** - *'prostatectomy' for BPE confers no protection from subsequent carcinoma.*
- 20% - Transitional zone
- 10% - Central zone

## Spread

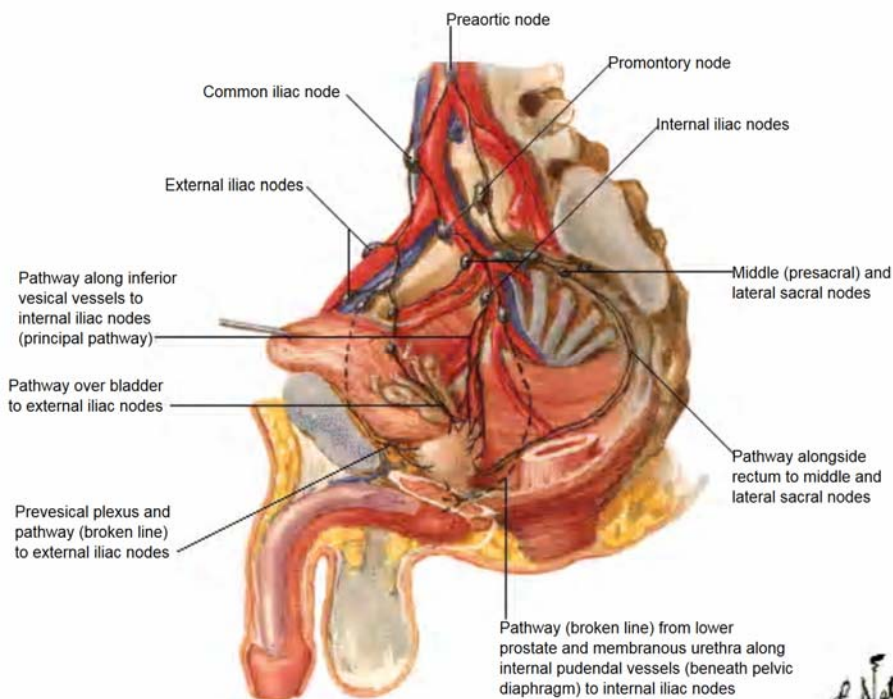
### Local;

- Seminal vesicles
- Bladder neck, trigone, & later, the tumours tend to spread distally to involve the distal sphincter mechanism
- Upwards extension obstructs the lower end of one or both ureters (anuria)
- The Rectum may become stenosed by tumour infiltrating *around it*, but **direct involvement is rare.**

**Haematogenous** - Usually **follows** direct local spread due to the presence of the **valveless veins** in the prostatic venous plexus;

- **Sclerotic & Osteolytic (10%)** bony lesions - **Pelvic bones & the lower lumbar vertebrae**; Also femoral head, rib cage & skull

### Lymphatic;



**S/S** - *Only advanced disease (T3, T4) gives rise to S/S usually within 6months*

- BOO/LUTS ± Renal failure due to Upper urinary tract obstruction
- Pelvic pain & haematuria
- Malaise, 'arthritis', anaemia or pancytopenia
- Locally advanced disease or even asymptomatic metastases, which may be found incidentally on investigation of other symptoms
- Weight loss ± Bone pain suggests metastases



## DRE

**Irregular induration**, characteristically **stony hard** in part or in the whole of the gland (with **obliteration of the median sulcus**) suggests carcinoma. **Extension beyond the capsule** up into the **bladder base & vesicles** is diagnostic, as is **deformity & projection outwards of the capsule**.

If Ca prostate can be **palpated**, then it is **not curable**.

### DDx;

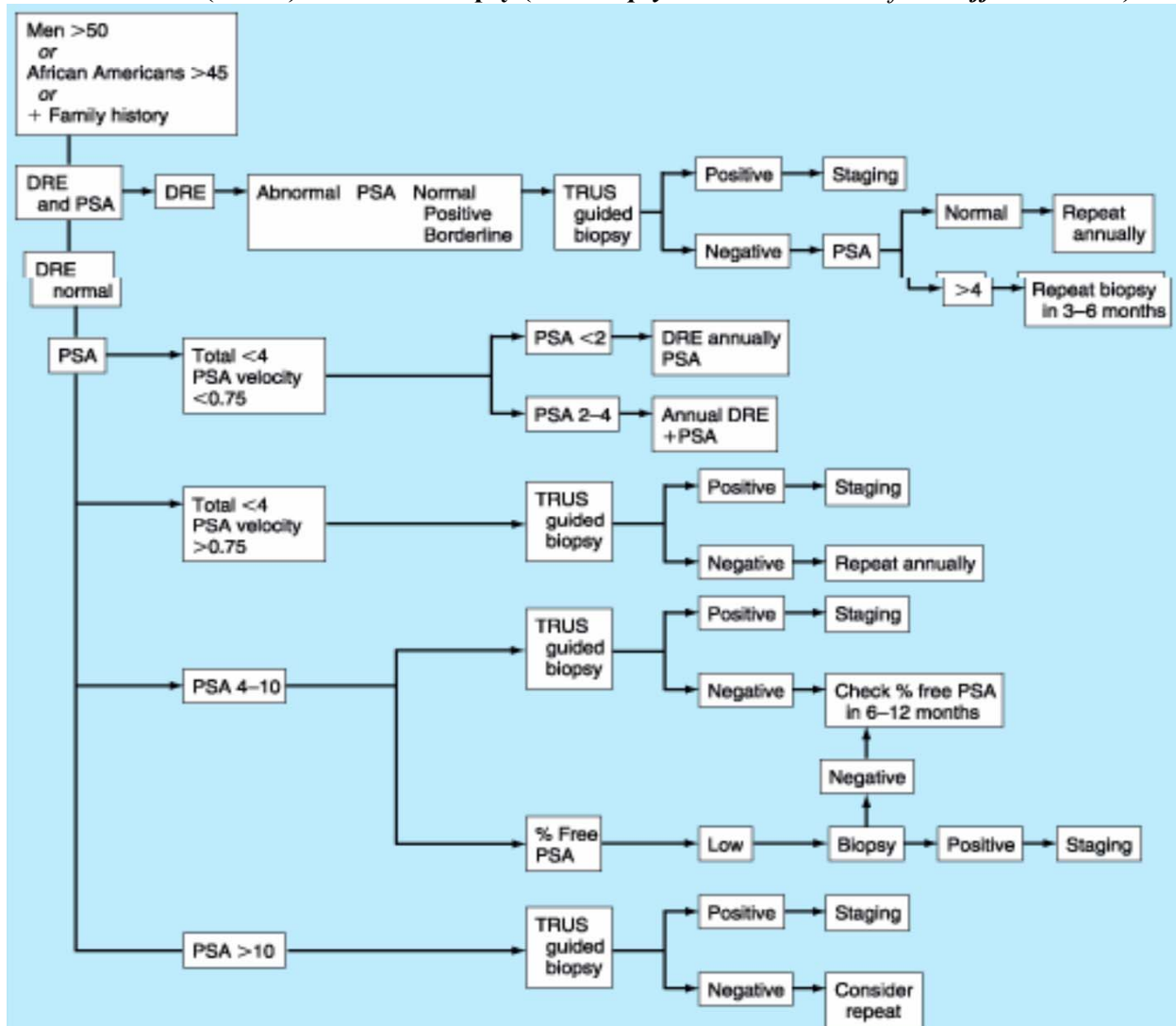
- TB prostate
- Calculous prostatitis

## Ix

- FHG + ESR - anaemia or pancytopenia due to *Marrow Infiltration*
- Coagulation screen - DIC (*Thrombocytopenia* +  $\uparrow$ FDPs)
- LFTs - Metastasis
- **PSA - 20-30%** of men with clinically significant prostate cancer have PSA values *within normal range*.
  - \* **TPSA -  $>4\text{ng/mL}$**  ( $>10\text{ng/mL}$  is highly suggestive) - **Dependent on Age**
  - \* **PSA velocity** (rate of change of serum PSA); Either;
    - $>0.75\text{ ng/mL}$
    - $\uparrow >0.2\text{ng/mL/month}$
    - **PSA doubling time -  $<3\text{months}$**
  - \* **PSA Density** (Ratio of TPSA to Prostatic volume)

### DDx $\uparrow$ PSA;

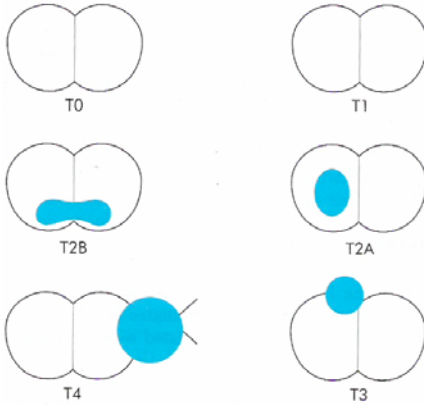
- BPE
- Trauma e.g. *recent DRE, Sex*
- Prostatitis
- UTI (*PSA levels may not return to base-line for some months after*)
- **Transrectal U/S (TRUS) & TruCut Biopsy (6-10 Biopsy cores are obtained from different zones)**



- CT/MRI - to detect local *nodal invasion*
- Bone XR & Bone scan ( $^{99\text{mTc}}$ ) - If  $\text{PSA} >20\text{ng/mL}$



## IUCC TNM Staging



T;

- **T0** - Microscopic latent cancer found at **cystoprostatectomy** or on **autopsy**
- **T1** - Tumours found incidentally in a **clinically benign gland** after histological examination of a **TURP** specimen (**T1a & T1b**) or following screening by **PSA** measurement (**T1c**);
  - **T1a** - Tumour involving **<5%** of the resected specimen - *Well or Moderately well differentiated*
  - **T1b** - Tumour involving **>5%** of the resected specimen
  - **T1c** - **Impalpable** tumours found following investigation of a **raised PSA**
- **Early**, localised prostatic cancer (**T2**);
  - **T2a** - **Suspicious nodule on DRE** confined within the prostate capsule & involving **one lobe**
  - **T2b** - Involves **both lobes**
- **Advanced** local prostate cancer (**T3 & T4**) - **Symptomatic; Incurable; 50%** progress to *bony metastases* after **3-5yrs**
  - **T3** - Extends **through the capsule**
    - **T3a** - **Uni- or Bilateral** extension
    - **T3b** - **Seminal vesicle** extension
  - **T4** - Tumour which is **fixed or invading adjacent structures** other than seminal vesicles - *rectum or pelvic sidewall*.
- **Metastatic disease** which may arise from a *clinically evident tumour (T2, T3 or T4)* or which may arise from an *apparently benign gland (T0, T1)*, i.e. occult prostate cancer; **Symptomatic; Incurable**

**N** - Regional LN (*Obturator, Internal iliac, External iliac, Pre-sacral*)

- **Nx** - Cannot be assessed
- **N0** - No regional LN metastases
- **N1** - Metastasis in a regional LN or nodes

**M** - Distant Metastasis

- **Mx** - Cannot be assessed
- **M0** - No distant Metastasis
- **M1a** - Distant metastasis to **non-regional LN**
- **M1b** - Distant metastasis to **bone**
- **M1c** - Distant metastasis to **other sites**

## Gleason Grading

A pathologist determines the Gleason grade by analysing **histology from 2 separate areas of the tumour specimen**, & based on the **degree of de-differentiation & its relation to the stroma**, gives a score between **1-5** to each area & adds them to get the total Gleason score for the tumour, from **2-10**.

- **2 - 4** - *Indolent tumour*
- **5 - 7** - *Intermediate grade*
- **8 - 10** - *Aggressive tumour*

## Mx

- ▶ **>70yrs old** - *Conservative management*;
  - \* **Watchful waiting** with serial PSA monitoring
  - \* +ve BOO - **Channel TURP ± Hormone therapy**
- ▶ **<70yrs old** (Patient with a life expectancy of **>10yrs** & consenting);
  - **T1a & T1b** - **Radical prostatectomy or Conservative management**
  - **T1c & T2** - **Radical prostatectomy (+ immediate Goserelin if node +ve) / Radiotherapy / Brachytherapy**
  - **T3 & T4** disease;
    - i) **Androgen ablation (Castration);**
      - a) **Surgical - Bilateral Subcapsular Orchiectomy**  
**or**
      - b) **Hormonal** - drugs may give benefit for **1-2yrs**;
        - **Gonadorelin (LHRH) analogues e.g. Goserelin** - These agents initially stimulate hypothalamic LHRH receptors, but because of their constant presence (*rather than the normal diurnal rhythm*) they then down-regulate them, resulting in cessation of pituitary LH production & hence a *decrease in testosterone production*  
**OR**
        - c) **Chemotherapy - Docetaxel** (mitotic spindle poison through the enhancement of tubulin polymerization) is used for **Hormone Refractory Prostate cancer**
    - ii) **Androgen receptor blockade** e.g. **Bicalutamide, Flutamide, Cyproterone acetate** - Blocks adrenal androgens (*DHEAS & Androstenedione*) (**5%**) actions.  
S/E - Androgen loss effects;
      - \* Cognitive deficit
      - \* Muscle bulk loss
      - \* Bone demineralisation leading to osteoporosis\*\* **Surgery + Androgen receptor blockade = Maximum Androgen Blockade**
    - iii) **Symptomatic treatment** (For bone metastases);
      - Analgesia e.g. Diclofenac
      - Treat Hypercalcaemia
      - Radiotherapy for bone metastases or spinal cord compression

## Complications of Radical Prostatectomy (*Prostate + Seminal Vesicles*)

### Perioperative;

- DVT
- PE
- Lymphocele formation
- Wound infection

### Late complications;

- **Urinary incontinence**
- Impotence - **Erectile dysfunction** - Preservation of *one or both neurovascular bundles* may allow maintenance of erectile function in men who are potent and sexually active before the procedure. However, **the nerve-sparing procedure** should be used selectively, for *extracapsular extension* is a common finding in patients with presumed localized Ca Prostate.

If extracapsular extension is present, preservation of the neurovascular bundle may increase the likelihood that the tumour will recur. Preservation of potency varies as a *function of age, preoperative sexual function, and preservation of one or both neurovascular bundles*

## Prognosis

- Bone scan +ve - ≤5yrs lifespan
- Bone scan -ve - >5yrs lifespan

# Posterior Urethral Valves (PUVs)

Membrane covering **bladder neck** & obstruction is as from early as **7wks gestation**.

**12%** are associated with renal dysplasia

## Ix

### Early Morning Urine (EMU) for m/c/s;

- Clean catch mid stream specimen of urine (**MSSU**) collection for **m/c/s** -  $\geq 10^5$  CFU of the same organism;
  - a) Clean periurethral area \*3 with mild soap & water - *separate the labia or retract the prepuce*;
    - \* Infants - Attach bag & hold baby upright to prevent them sitting on the urine
    - \* Older children - Direct urine into container
  - b) Catheter -  $\geq 50 \times 10^3$  CFU of the same organism
- Suprapubic tap - Aseptic technique 2cm below the umbilicus in the mid-line with a 10cc syringe when the bladder is full or **30mins** after the child has passed urine - Sterile thus **any** bacteria suggests UTI

### Imaging (In order);

- i) KUB
- ii) Renal U/S - Outlines *kidney size, ureters*
- iii) MCU - Done on **sterile urine** (<3wks presentation) to outline urethra (**PUV**) & r/o **VUR**;

#### Indications;

- **All Males**
- Females;
  - \* <5yrs with **1<sup>st</sup>** episode of UTI
  - \* >5yrs with **2<sup>nd</sup>** episode of UTI

#### Findings;

- \* Hypertrophied bladder wall with trabeculations
  - \* Dilated posterior urethra
  - \* Poor stream of urine distally
  - \*  $\pm$  Bladder diverticula
  - \*  $\pm$  reflux of contrast into the ureter  $\rightarrow$  bilateral hydronephrosis
- iv) If there is **no renal failure** - **DMSA** (Dimercaptosuccinic acid scan) -  $^{99m}\text{Tc}$  is injected IV & is taken up by renal parenchyma & a repeat scan is done after **6months** to;
    - a) Assesses individual renal tissue functional contribution;
      - \* <**12%** - Nephrectomy
      - \* >**25%** - Preserve kidney
    - b) Defects show **transient scars** & does not differentiate acute & chronic scar & a **repeat** is indicated **6months** later to determine **chronic scars**  $\rightarrow$  **HTN, CRF**.

If there is **no DMSA** - **IVU** - Done **2yrs after episode of UTI** - Shows **ureteric stenosis**

- v) DPTA

## Mx

- Catheterize (**Not balloon type catheter**) - as the valves prevent flow only in one direction
  - Manage fluid & electrolyte imbalances
  - Treat UTI
  - Monitor;
    - a) **Abnormal RFTs** - Urinary diversion - **Cutaneous ureterostomy** + **Prophylactic antibiotics until recovery of RFTs**
    - b) **Normal RFTs** - Surgery - ( $\pm$ **Re-insert ureters**) + **Transurethral Resection of the Valves with a Resectoscope**
      - \*\*In small babies where the resectoscope is bigger than the babies urethra, to divert urine to allow urethra to grow, do a **vesicostomy** on the **trigone of the bladder** (When the bladder contracts urine will be pushed out) - Possible only up to **12yrs of age**.
- Complications;
- Over-resection may cause large raw surfaces that will heal with fibrosis & **stricture formation**
  - Possible damage to the distal urinary sphincter with resultant **incontinence**

## Complications

- i) The bladder having long standing posterior urethral valves behaves like a neurogenic bladder with **incontinence or retention**
- ii) UTIs - **OHCM Pg 262**

### iii) VesicoUreteral Reflux (VUR)

Defined as reflux of urine from the bladder cavity up into the ureters and sometimes into the renal pelvis. VUR occurs during voiding or with elevation of pressure in the bladder & may result in severe **unilateral or bilateral hydroureter & hydronephrosis** (*usually more marked on the right than on the left*).

The antireflux mechanisms are;

- An *oblique posterolateral entry* of the ureter into the bladder
- Adequate muscle support of the distance that the *ureter traverses submucosally* in the bladder - Submucosal length of the ureters increases & the ureter openings close as the bladder distends
- Appropriate configuration of the *ureteral orifices*

Types;

- **1°**;
  - *Abnormal insertion* of the ureter into the bladder - **most common cause**
  - Due to *shortening* of the intravesical submucosal ureter
  - **Familial F>M**
- **2° to bladder distension**;
  - Urethral obstruction e.g. PUV
  - Neuromuscular disease e.g. *Spinal dysraphism* - Leads to bladder dysnergism - bladder & sphincter contract together
  - Abnormal voiding patterns
  - Inflammatory processes e.g. *Ureteritis*

Pathogenesis;

Reflux is harmful to the upper urinary tract for the following reasons:

- It increases postvoiding residual urine in the bladder, enhancing bacterial growth and causing risk of *infection*.
- It allows *bacteria* free access from the bladder to the kidney
- It permits the transmittal of high intravesical pressure to the kidneys, leading to interstitial *extravasation of urine* - **Urinoma or urinary ascites**.
- It functionally increases the load of urine to be transported by the *ureter*, thus leading to *stasis, dilatation, and tortuosity*
- It can result in *stone formation* or *secondary PUJ obstruction*.

Classification;

- I - Ureters only
- II - Ureters, Pelvis, Calyces
  - No dilatation**
  - Normal calyceal fornices
- III - **Mild or moderate dilatation of the pelvis**
  - No or slight blunting of the fornices
- IV - **Moderate dilatation or tortuosity of the ureter**
  - Mild dilatation of the renal pelvis & calyces**
  - Complete obliteration of the sharp angle of the fornices
  - Maintenance of papillary impressions in most calyces
- V - **Gross dilatation & tortuosity of the ureter**
  - Gross dilatation of renal pelvis & calyces**
  - Papillary impressions are **no** longer visible in most calyces.

Mx;

**Non-surgical** - Indications;

- Reflux *in the absence of UTI or BOO* usually does **not** lead to renal parenchymal damage and often resolves spontaneously as the child matures
- Reflux in infants <3yrs old
- Grade **I-III**

Mx;

- **Prophylactic antibiotics** during work-up
- Treat cause
- Follow-up;
  - **Antibiotics** + m/c/s **every 3months**; Change antibiotic for **10days** if;
    - \* +ve urinary symptoms
    - \* +ve unexplained fever
    - \* Bacteriuria,
  - Yearly - m/c/s & RFTs
  - Stop antibiotics if **no** reflux

**Surgical**;

Indications;

- UTIs recur despite chronic antimicrobial therapy.
- Persistent reflux in a child **>3yrs old**
- Grade **IV-V** reflux and unlikely to improve spontaneously
- Renal function deteriorates

Procedures;

- Reinsertion** of the ureters into the bladder **or**
- Changing of the **angle of entry** of the ureter into the bladder

**Complications**;

- Inflammation & injury → Fibrosis & Renal scarring → Ischemia → ↑ renin production → **CRF** (especially if bilateral) & **HTN** (15-30% children with bilateral scarring - especially in females during pregnancy) - Serum creatinine remains normal as you need 50% kidney loss for it to ↑ as the other kidney normally compensates if unilateral - Kidneys can recover if **<6months injury**
- **UTI**

**Prognosis**;

- **25%** - Die before **5yrs**
- **25%** - Die before **25yrs**
- **25%** - **ESRF**
- **25%** - Will need a **renal transplant**

# Urethral Strictures

This is the *narrowing of the urethral cross-sectional area* as a result of a *fixed fibrotic plaque*.

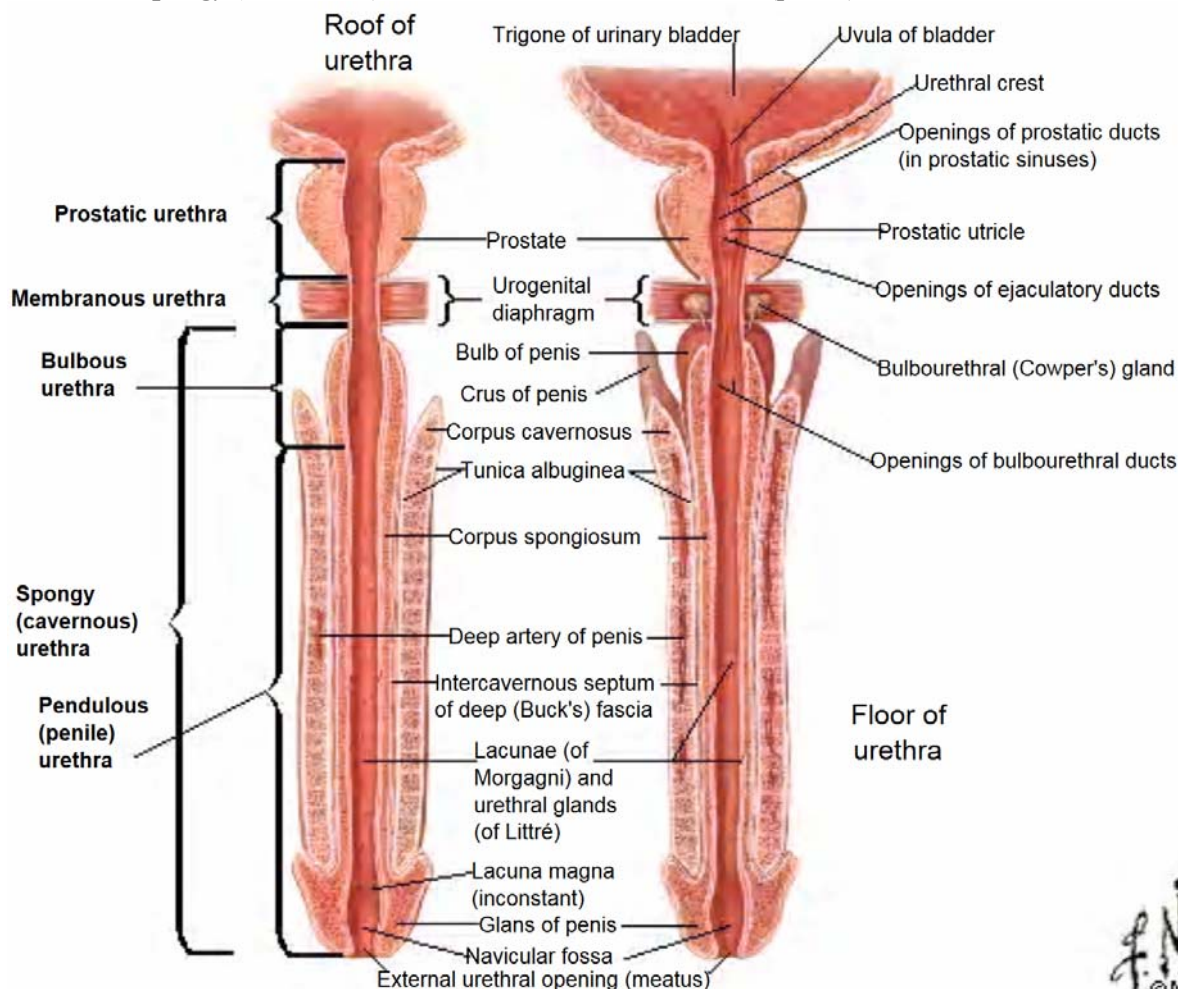
## Anatomy

### Urethral Length;

- Males - 15-17cm
- Females - 3.5-5cm

### Divisions;

- **Posterior** - *Prostatic & Membranous urethra*
- **Anterior** - *Spongy (Cavernous) urethra - Bulbous & Pendulous (penile) urethra*



## Aetiology

- *Congenital*;
  - Epi/Hypospadias
  - PUV in young boys
- *Acquired*;
  - **Traumatic (commonest cause)** e.g. **pelvic fracture** (of the *pubis & ischial rami*), saddle injury, penile fracture
  - Instrumentation - *Causes Inflammation ± trauma*;
    - \* Indwelling catheter
    - \* Urethral endoscopy
  - Inflammatory - *Post-gonorrhoea, tuberculous urethritis, chlamydial infection of the membranous urethra or schistosomiasis*
  - Postoperative;
    - \* Prostatectomy
    - \* Amputation of penis
  - Irradiation



## S/S

- **Complete** stricture - *Acute retention*
- **Incomplete** stricture;
  - **Urinary symptoms - Improve on straining;**
    - \* LUTS but **NO Hesitancy** which is a mechanism of the **median lobe of the prostate**
    - \* Dysuria
    - \* Haematuria
    - \* Forking of urine
- **Cannot pass catheter**
- Extravasation of urine
- Perineal sinuses
- Urethral stone
- Recurrence of *epididymitis or prostaticitis*

## DDx

- BPE - Mostly in old patients & *straining makes it worse*
- Ca Prostate
- Carcinoma of the urethra
- Condyloma - *Genital wart*

## Ix

- FHG
- U/E/C - *Asses renal function*
- RBS to r/o *Diabetes neuropathy*
- Renal U/S - to r/o *Hydroureter ± Hydronephrosis* - If +ve - **IVU**
- *Urethral calibration/Flow rate* - reveals the degree of narrowing
- Urethrography;
  - \* **Complete** stricture - **MCU + Retrograde CU**
  - \* **Incomplete** stricture - **MCU**
- Urethroscopy/Cystoscopy ± Biopsy

## Stricture Complications

- Retention of urine
- Infection e.g. UTI, STI
- Calculi
- Extravasation
- Urethral diverticulum
- Periurethral abscess
- Urethral fistula - Usually 2° to bursting or incision of a periurethral abscess. If the fistulae arise behind a tight stricture, there may be multiple openings - *watering-can perineum*
- Abdominal straining to void urine causes;
  - Hernia
  - Haemorrhoids
  - Rectal prolapse

## Mx

### Acute Retention Post-Trauma;

- Airway with cervical spine control, **B**reathing, **C**irculation & haemorrhage control, **D**isability & **E**xposure
- **NO** attempt should be made to pass a catheter, as this could convert a partial to a complete tear of the urethra. Instead, put a **supra-pubic catheter (cystofix) or open cystostomy (1" above pubic tubercle) if patient is unable to pass urine**
- Wait for **8-12wks** before any attempt to repair the stricture to allow;
  - \* resorption of the haematoma
  - \* proper identification & viability of the structures once inflammation has settled
- Manage renal symptoms appropriately

### Treatment options

#### ► Incomplete strictures

##### i) *Serial Dilatation;*

###### Principles;

- Dilate to stretch **not** to tear
- Do **not** try to go past **24F**; smaller than **16F** is easy to damage the urethra by perforating it.
- Dilatations are painful, & must be done with consideration of the patient to improve compliance
- Once stable, calibrate at doubling intervals (**2wks, 4wks, 8wks...**); Most common mistake is to dilate too much too quickly

###### C/I;

- Multiple strictures
- Infection
- Fistula

###### Types;

- Metal sounds
- Gum-elastic bougie
- Catheters - Filiform, follower, Nélaton catheter (Self-dilatation)

*Disadvantage* - Performed 'blind' so there is always the danger of causing a **false passage**, which will make the stricture worse.

##### ii) **Urethrotomy** - Done at **12 o'clock** to prevent damage to the vascular spaces of the corpus spongiosum that surrounds the urethra where the *stricture persists despite serial dilatation*

###### Types;

- **Direct visual urethrotomy**
- Internal Blind urethrotomy
- Perineal urethrotomy

###### Post-op;

- Catheterize with a **3-way catheter** for **irrigation** for **1-2days** (Until clear on irrigation)
- Insert urethral catheter for **2wks**
- Do a trial of catheter
- Discharge on **clean intermittent self catheterization** with **Nélaton catheter** (Filiform is better)

#### ► Complete & Persistent Incomplete Strictures

##### i) **Urethroplasty**

- **One-stage** anastomotic urethroplasty - For strictures **<2cm**;
  - \* **Bulbous urethra & 2° to Trauma - Excision & end-to-end anastomosis**
  - \* **Pendulous urethra - Patch urethroplasty** using flap or free grafts from *behind the ear, buccal mucosa, or penile shaft* (**Do not** use hairy skin e.g. scrotal skin, as it is prone to stasis → infection → calculi formation).
- **Two-stage** urethroplasty - If previous procedures are unsuccessful;
  - \* **1<sup>st</sup> stage** - Open up the urethral stricture & suture it to the surrounding skin & leave a catheter in-situ for **2wks** as the wound heals. Remove the catheter & leave open for **3months** to allow *granulation tissue formation*. Do **serial dilatation** during this interval of the entire urethra
  - \* **2<sup>nd</sup> stage** - *Refashioning of the urethra & perineum* by covering of the urethra with skin flaps from both sides.

###### Post-op;

- Catheterize with a **3-way catheter** for **irrigation** for **1-2days** (Until clear on irrigation)
- Insert urethral catheter for **2wks**
- Do trial of catheter

- *Repeat Urethral calibration/Flow rate* to determine improvement
- Discharge on **clean intermittent self catheterization** with **Nélaton catheter** (Filiform is better)

## Urinary Incontinence

Inability to prevent the discharge of urine

Types;

- **Overflow incontinence** - involuntary loss of urine associated with *overdistention of the bladder*, with or without a detrusor contraction.
- **Reflex incontinence**, in *neurogenic disorders*, loss of urine due to *detrusor hyperreflexia and/or involuntary urethral relaxation in the absence of the desire to void*.
- **Stress incontinence** - leakage of urine as a result of *coughing, straining, or some sudden voluntary movement*, due to weakness of the fascia muscles and at the neck of the bladder.
- **Urge incontinence** - urgency incontinence, leakage of urine during a strong desire to void.
- **Dribbling incontinence** - After voiding due to incomplete emptying of the bladder

# Burns

## Definition

**Coagulative destruction** of the *surface layers of the body* caused by application of **heat, cold or caustic chemicals**.

Anatomy & Functions of Skin - See *Dermatology - General Pg 1*

## Pathophysiology of Burns

**Tissue damage** → **release of vasoactive substances** *e.g. prostaglandins, histamines, oxygen radicals, leukotrienes & platelet activating factors* → **microvascular instability with increased capillary permeability for the first 24-36hrs** → **oedema & ↓right atrial filling pressures** → **↓CO** → **Shock**.

The body tries to compensate for these physiological changes by;

- Increased peripheral resistance (*sympathetic stimulation*)
- Increased cardiac output
- Decreased capacitance of great vessels

If the process goes *uncorrected*;

- Cardiac output is diverted to vital tissues **reducing** perfusion of **skin, muscle & gut** - *Skin feels cold & clammy*
- If hypovolaemia is allowed to continue, then *renal perfusion* goes down (*S/S - Reduced urine output*) which may lead to **ARF** if not corrected

**Irreversible shock** occurs as an end stage with *falling BP, CO & PR*

## Classification - According to *Cause*;

- 1) **Open flames and Hot liquid** are *most common* (heat usually  $\geq 15-45^{\circ}\text{C}$ )
- 2) **Caustic chemicals or acids** (*may show little signs or symptoms for the first few days*)
  - a) **Extravasation** - Due to drug leakage into tissues *e.g. Cytotoxics, Sulphur drugs, Potassium drugs*  
C/P - Inflammation, vesicles; **Skin necrosis** may occur within **24hrs** & **Gangrene** 2° to vascular spasm in **2-3days**.
  - b) **Contact**
    - **Paraffin** - Causes;
      - i) Local chemical reaction
      - ii) Thermal injuries
      - iii) Inhalational injuries (*pulmonary oedema & bronchospasm*)
      - iv) Systemic poisoning
    - **Acids** - Cause severe **superficial coagulative necrosis**. Burning stops within **1-2hrs** for **HCL & H<sub>2</sub>SO<sub>4</sub>** & **7-14days** for **HOCL** - Amount ingested **does not contribute** to extent of injury
    - **Alkali** - Causes **deep liquifactive necrosis** - penetrate tissue by **saponification** *i.e.* hydrolyzing structural proteins & dissolving cells along its course & Amount ingested **contributes** to extent of injury

**Mx** - Generously irrigate with fluid & Dress in gauze soaked in NS or Ice **2-3hrly**. **DO NOT** try to neutralize the chemical.

- 3) **Electricity**
  - May have significant injury due to **Myonecrosis** → Myoglobinuria → **Renal failure** with very little damage to overlying skin thus **TBSA is NOT an index for resuscitation**. IV fluids are titrated against the **volume of urine & specific gravity (1.010)**. Usually **\*2 the physiological requirements** (3L/24hrs) of the patient.
  - In *microwave injuries*, the area is normal looking but *anaesthetic* due to *depolarization of nerves*
  - *Flash burns* occur in technicians & may resemble open flame burns

**Mx** - Give plenty of fluids & *debride after 3-4days*

- 4) **Excess sun exposure**
- 5) **Frostbite**
- 6) **Mechanical** (Frictional) burns

## Quantification of Burn Severity

1) According to **Depth of Injury** which is proportional to;

- \* Temperature applied
- \* Duration of contact
- \* Thickness of the skin

The depth of injury *determines formation of scar tissue.*

a) 1<sup>st</sup> Degree Burns;

- **Epidermis only**
- Commonly caused by **UV light or very short flash or flame** exposure
- Skin is **red, dry & hypersensitive**
- No treatment except **analgesia**
- Leaves **no scarring** on healing

b) 2<sup>nd</sup> Degree Burns;

**Superficial;**

- **Epidermis + Upper  $\frac{1}{3}$  of Dermis**
- Commonly caused by **scald** (*spill or splash*)
- **Red, moist, weeping, cob blisters** that **Blanche** with pressure
- **Painful** - due to nerve exposure, & heals from **7-14days**
- Leaves **no scarring** on healing but there is **potential pigmentary changes**

**Deep;**

- **Epidermis + Upper  $\frac{2}{3}$  of Dermis**
- Commonly caused by **scald, flame, chemicals, oil & grease**
- **Cheesy white, wet or waxy dry; Do not Blanche** with pressure
- Healing takes **>21days**
- **Severe scarring & risk of contractures**

c) 3<sup>rd</sup> Degree Burns (*Full Thickness Burns*);

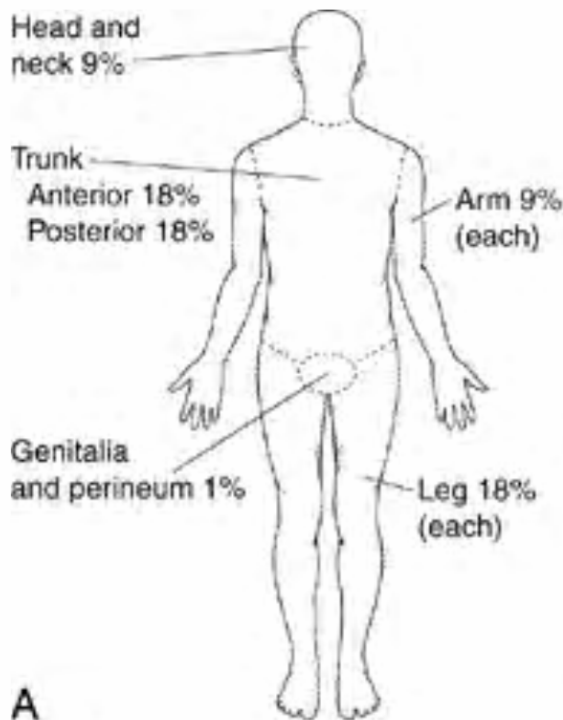
- **Full Epidermis + Dermis** are destroyed leaving *no cells to heal*
- Commonly caused by *scald, steam, flame, chemicals, oil, grease & high voltage electricity*
- **Grey to charred & black, insensate, contracted, pale, leathery** tissue
- **Severe scarring & high risk of contractures**

d) 4<sup>th</sup> Degree Burns - **Muscle** involvement

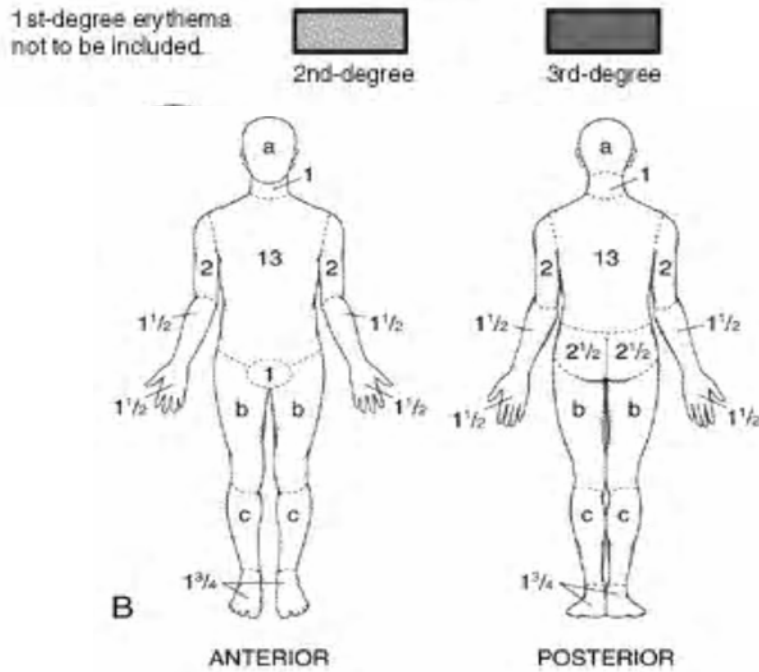
e) 5<sup>th</sup> Degree Burns - **Bone** involvement - *Especially in epileptics who convulse during burning*

2) According to **Size of Burn** - *Determines extent of fluid loss*

**Wallace Rule of Nines** - used in *Adults* to estimate BSA (Body surface Area)



**Lund-Browder Chart** for estimating the extent of burns in **Children**



Relative percentage of body surface areas (% BSA) affected by growth

	0 yr	1 yr	5 yr	10 yr	15 yr
a— 1/2 of head	9 1/2	8 1/2	6 1/2	5 1/2	4 1/2
b— 1/2 of 1 thigh	2 3/4	3 1/4	4	4 1/4	4 1/2
c— 1/2 of 1 lower leg	2 1/2	2 1/2	2 3/4	3	3 1/4

**American Burn Association Burn Severity Categorization**

	Minor Burn	Moderate Burn	Major or Severe Burn*
<b>BSA in Young or Old</b>	<10%	10-15%	>15%
<b>BSA in Adults</b>	<15%	15-25%	>25%
<b>3<sup>rd</sup> Degree Burns</b>	<2%	2-5%	>5%
<b>Treatment</b>	Outpatient	In-patient	Burn centre/ Burn Unit/ ICU

\* **Major or Severe Burns also includes;**

- i) High voltage Electrical burns
- ii) Significant burn to **face, eyes, ears, fingers, feet, joints, or genitalia**
- iii) Significant associated injuries e.g. *fractures & other major trauma*
- iv) **Inhalational Injuries**

*Pathogenesis* - Causes upper airway obstruction 2° to;

- Laryngospasm
- Oedema
- Sloughing of the mucosa → *infection & blockage* → Pneumonia

*S/S;*

- History of having been injured in an *enclosed space* e.g. house, motor vehicle
- *Physical stigmata* i.e. Facial burns, singed nasal hairs & soot in nasopharynx
- Coughing up *carbonaceous sputum/soot*
- *Stridor or new onset hoarseness of voice* (will indicate vocal cord swelling)
- *Tachypnoea* - ≥25 breaths/min

*Mx;*

- Admit
- Give 100% O<sub>2</sub> by Mask or Endotracheal tube in serious inhalational injury
- Measure *carboxyhaemoglobin*; With 100% O<sub>2</sub>, t<sub>1/2</sub> of COHb falls from 250mins to 40mins
- *Bronchoscopy + Lavage*
- Pulse oximetry - *Unreliable* (may be normal)
- CXR

# Mx

## Persons at Risk

- *Extremes of age* - the very young (<4yrs) or very old (>50yrs)
- Those whose ability to protect themselves is impaired (*Drunkards or Junkies*)
- The unlucky - Innocent bystander
- The careless - Storing petrol in the house, adding paraffin to a lit stove, smoking in bed, working close to high tension electric wires

## Rescue & First Aid

### General considerations;

- Electric burns - *turn off mains before touching patient*
- If the victims clothes are on fire - *Stop, Drop & Roll*

### 1<sup>st</sup> Degree Burns;

- Cool burned area of skin for **5-10mins** (*running water, cool compress or towel, immersion in cold water*)
- After 10mins, dry area & *keep the patient warm* to avoid hypothermia
- Drink lots of fluids - *Sweetened water with pinch of salt PRN*
- *Analgesics ± Anti-inflammatories* e.g. Ibuprofen or Acetaminophen
- Cover burn with cool sterile dressing

### 2<sup>nd</sup> Degree Burns;

- Call Emergency services
- **DO NOT** break or drain the blisters
- **DO NOT** remove stuck clothing
- Cool burned area of skin for **5-10mins** (*running water, cool compress or towel, immersion in cold water*)  
*Once immersed in cool water, carefully remove clothing & jewellery on burnt area*
- After 10mins, dry area & *keep the patient warm* to avoid hypothermia
- Evaluate for signs of shock & treat accordingly - **DO NOT** give the patient anything to drink
- Elevate burnt area if possible
- Cover burn with cool sterile dressing - **DO NOT** apply ointment, lotion or anything.

## A&E Department

### *The first 48hrs - All efforts are towards resuscitation & saving lives*

- 1<sup>o</sup> Survey** - Airway with cervical spine control (**Look out for & manage inhalational injury**), Breathing, Circulation & haemorrhage control, Disability & Exposure
- 2<sup>o</sup> Survey**
- Medical Management;**
  - **IVF** - For *Moderate & Major/Severe* Burns  
**Parkland's Formula** -  $4\text{mL} * \text{Kg BWT} * \% \text{TBSA}$  Ringers Lactate or Hartmann's solution - Give ½ within **8hrs of burns** & the rest in the **next 8hrs**; Give ~50% more in *electrical burns & inhalational injury*  
Adequate resuscitation is measured by urine output;
    - Adults - 30-50mls/hr
    - Children - 0.5-1ml/Kg/hrCauses of *inadequate* fluid resuscitation in a burns patient;
    - Inaccurate estimate of burn size
    - Undiagnosed inhalational injury
    - Concomitant traumatic injury
    - Cardiac dysfunction
    - Refractory shock
    - Mathematic miscalculation**Other formulae (surg II);**
    - **Evan's (colloid + crystalloid)**
    - **Brooke army (modification of Evan's)**
    - **Muir & Barclay (colloid)**
  - **Analgesics** - Give *opiate analgesics IV (IM is ineffective)*; NSAIDS
  - **PPI or H<sub>2</sub> Blocker** - *protection from Curling's Ulcers*
  - **Tetanus toxoid**
  - **DVT prophylaxis** in lower limb burns
  - If **≥80% TBSA** - Supervised Neglect





#### iv) Wound care;

- Remove all necrotic tissue & debris
- Rupture blisters *except those on the palms & soles of feet & those <1cm in diameter*
- Wash wound with *soap & water or saline*
- Cover wound;
  - a) **Open Dressing** - No dressing applied
  - b) **Exposure Dressing** - Apply soothant e.g. Vaseline
  - c) **Occlusive dressing** e.g. for *small superficial previously debrided wounds*;  
Indications;
    - \* If the burn is **not** oozing too much
    - \* If there is risk of infection
    - \* Children
    - \* If co-morbid conditions present
    - \* Joints
    - \* Patient's comfort
- Apply topical antibiotic e.g.
  - \* **Silver sulphadiazine** (S/E - *thrombocytopenia, leucopenia, rash*)
  - \* **0.5% Silver Nitrate** - Stains tissues & can cause *hypochloraemic alkalosis*
  - \* **Mafenide** - can penetrate tissue & *eschar*. Good for **infected wounds & eschars**. Painful on application.
  - \* **Neosporin or Bacitracin** - Good for **facial burns** as they are not toxic to the eyes
- OR** - Apply antibiotic impregnated material
  - Apply non-stick material e.g. *Bactigras*
  - Apply **3-5 layers** of dry material e.g. gauze
  - Cover with crepe bandage
  - Change **after 3days** & then **daily** up to **day 21**. *If there is no healing, consider skin grafting.*
  - *Silver sulfadiazine/transparent polythene bags for hands*
- d) **Skin grafting** e.g. for *frictional burns*

#### v) Other considerations;

- \* **Face burns** - *Intubate patient & do temporary tarsorrhaphy*
- \* In **neck burns**, a pillow is placed under the patients head to *hyperextend the neck* at the shoulders to prevent contractures
- \* **Chest wall burns** - Do a *checker-box release*
- \* **Upper limb burns** should be nursed elevated at **45°** to prevent CCF

#### vi) Nutritional support - *Curreri formula* - **25KCal/Kg + (40KCal \* %TBSA)**

#### vii) Indications for Admission

- Cause;
  - \* *Electrical burns* including lightning injuries
  - \* *Chemical burns with serious threat of function or cosmetic impairment*
  - \* *? Non-accidental injury*
- Severity;
  - \* **Moderate & Severe burns**
  - \* *3<sup>rd</sup> & 4<sup>th</sup> Degree burns* regardless of TBSA
  - \* *All inhalational injuries*
  - \* Non-healing burns after **14-21days**
- Anatomical location;
  - \* Head, neck, arms, perineum, soles
  - \* Circumferential limb burns
  - \* Burns to the back
- Patient factors;
  - \* Extremes of age (*<14yrs & >50yrs*)
  - \* *Burns of both limbs* in an *Obese patient*
  - \* Pregnancy
- Any burn with **concomitant trauma** in which the injury poses the **greatest** risk of morbidity or mortality
- Burn injuries with *pre-existing medical disorders* that could *complicate management, prolong recovery or affect mortality* e.g. **Diabetes, Epilepsy, Hypertension, Blind or Deaf, Infection, Renal problems**

## 48hrs - 6months - Management is based on complication control

- viii) **Escharotomies** - Surgical division of constricting eschars (*scab formed especially after a burn*). Indications;
- 3<sup>rd</sup> & 4<sup>th</sup> Degree Burns
  - Circumferential burns - *may compromise distal extremity blood flow*. Performed on the **midlateral or medial aspects of limbs**.

## >6months - Reconstructive surgery, Training & Rehabilitation

- ix) **Physiotherapy** - **Splint at night & Motion during the day**;
- To control pain
  - Reduce oedema & swelling
  - To protect the wound
  - To minimize cosmetic defects
  - To maximise patient's function
- x) **Occupational therapy** - *To rehabilitate the patient back into functional living*
- xi) **Psychiatric rehabilitation**

## Complications;

- a) **Wounds**;
- Haemorrhage
  - Infection;
    - \* 0-7days - *Contamination*
    - \* >7 days - *Sepsis*
  - 1month - 1yr - **Hypertrophic scars** - *Itchy, Hyperaemic, Uncomfortable*
  - >1yr;
    - \* **Keloids** - A keloid is a true tumour arising from the *connective tissue elements of the dermis*. By definition, keloids *grow beyond* the margins of the original injury or scar; in some instances, they may grow to enormous size.  
*Mx* - Local injection of *Steroids & Bleomycin, Excision & Superficial irradiation*
    - \* **Contractures**
  - 10yrs - **Marjolin's ulcer** - *SCC developing in old burn site*
- b) **GIT**;
- Burns 2° to swallowing corrosive substances → Contractures of the oesophagus → Obliteration of the angle of HIS → **GORD** → Acid irritation & burns → Scarring & contractures → ~GORD thus do **Nissen fundoplication** to break cycle.
  - **Curling's ulcers** *may cause GIT bleeding*
  - **Pseudo-intestinal obstruction** 2° to **atony** in the 3<sup>rd</sup>-4<sup>th</sup> day
  - **Diarrhoea** 2° to **Ileal atrophy** in the 7<sup>th</sup>-8<sup>th</sup> day; Diarrhoea may also be due to the **drugs**
- c) **Haematological** - **Anaemia** 2° to;
- Haemorrhage (*Wound, GIT*)
  - Thermal injury to RBCs
  - Bone marrow depression
  - Malnutrition

## Factors Affecting Burn Mortality

- Patient's age
- Pre-existing medical conditions e.g. *Cardiac, Pulmonary, Renal dysfunction*
- Presence of Inhalational injury
- Size & Depth of Burn
- Concomitant Injuries

## Preventive measures;

- Education
- Legislation
- Housing - *adherence to building code*
- Improved industrial safety measures

# Wound Management

A **wound** is a **traumatic** breach in the normal continuum of the epithelium. (*An ulcer is **not** traumatic*)

## Classification of Wounds

### a) Based on *Duration*;

- **Acute**;
  - Open e.g. *Incisional, Puncture, Abrasions, Ulcerations*
  - Closed e.g. *Bruises, contusions*
  - Complex e.g. *Crush, avulsion, internal organs, gunshot wounds*
  - Injuries to special tissues e.g. *Muscle, fat, nerves, vessels*
- **Chronic**;
  - Ulcers
  - Pressure sores

### b) Based on *Contamination*;

- **Clean** - *Atraumatic, Uninfected; No entry of GU, GI or Respiratory tracts*
- **Clean contaminated** - *Minor breaks in **sterile** technique; Entry of GU, GI or Respiratory tracts **without** significant spillage*
- **Contaminated** - *Traumatic wounds; **Gross** spillage from GI tract, Entry into *infected tissue, bone, urine or bile**
- **Dirty** - *Drainage of abscess, debridement of soft tissue infection*

## Wound Healing

This is a summation of a number of processes that follow injury;

### i) Coagulation



### ii) Lag phase - *Inflammation* - **0-48hrs**

Early Phase of Inflammation - *Accumulation of **neutrophils***



Late phase of Inflammation - *Accumulation of **macrophages***



### iii) Repair phase - *Proliferation/fibroblastic phase* - **Day 4 to 21**

Fibroplasia



Angiogenesis



Contraction



### iv) Remodelling & Scar maturation phase - **>3wks**

## Types;

- **1° Healing or 1<sup>st</sup> Intention** - The wound edges are apposed (*staples, sutures*) & healing proceeds rapidly to closure
- **Delayed 1° Healing** - Occurs in *contaminated* wounds or those with ? *viability* & the wound edges are *approximated following a delay of several days*
- **2° Healing or 2<sup>nd</sup> Intention** - The wound edges are separated as when there has been tissue loss & there is *delayed closure of 2 granulating surfaces* & the actual shrinkage of the wound area may cause a contracture.
- **3° Healing** - Wounds are closed by covering the area of the defect with *Skin Grafts* → *Local Flaps* → *Free Flaps* → *Tissue Transfer*

## Factors Impairing wound Healing

## Factors Impairing wound Healing

Local	Systemic	
Infection	Arterial disease	Immunosuppressants &
Foreign bodies	Venous Hypertension	Corticosteroids
Ischemia/hypoxia	Malnutrition	Anticoagulants
Cigarette smoking	Vitamin A & C deficiency	Obesity
Radiation	Cancer	Systemic sclerosis
Previous trauma	DM	Uraemia
Venous insufficiency	Marfan's syndrome	Alcoholism
Local toxins (e.g. spider venom)	Whole body irradiation	Jaundice
Topical corticosteroids		Old age

# Skin Grafts

A skin graft is a *piece of skin transplanted from one part of the body to another* to cover a denuded area.

## Functions;

- Wound closure
- Reduce pain from the wound
- Covers vital structures e.g. *tendons, nerves, vessels, muscle*
- Replace lost skin functions
- Prevention of contractures

## Classification;

### a) Partial-thickness skin grafts/Split thickness skin grafts (STSG)

This is a graft of portions of the skin, i.e. the *epidermis and part of the dermis*, or of *part of the mucosa and submucosa*, but **not including the periosteum**.

#### Types;

- **Thiersch graft** - a skin graft that consists of *thin strips or sheets* of epithelium with the tops of the dermal papillae
- **Postage stamp grafts** - *small pieces* cut from a sheet of STSG.
- **Mesh graft** - a skin graft in which *multiple slits* have been made, so it can be stretched to cover a large area
- **Pinch graft** - small bits of skin, of partial or full thickness, removed from a healthy area and seeded in a site to be covered - **Obsolete**

#### Harvesting;

- i) Clean *donor site*
- ii) Prepare *wound bed* - Excise granulation tissue till you get good *capillary bleeding* & achieve haemostasis with **diluted adrenaline gauzes** to *prevent non-take haematoma formation*
- iii) Apply traction to skin on both ends of donor site & use a **Humby knife** (easy to use & maintain) or an **electric dermatome** to cut out graft
- iv) Dress donor site with **diluted adrenaline gauzes**
- v) Graft can be *used immediately or refrigerated* at 4°C wrapped in **NS gauze** for up to **3wks** or in **liquid nitrogen (-100°C)** for up to **1yr**
- vi) The graft is transfixed by *Sutures/Staples/Firm Dressing + fibrin*

#### Take;

##### Phases;

- I - **Imbibition - Day 1-2** - Nutrition is by *imbibition* from the serum in between & *capillary diffusion*
- II - **Inosculation - Day 4** - *Capillaries from graft & bed align & perfusion is established*
- III - **Neo-vascularization - Day 5** - New capillaries form from *recipient site to graft* with connective tissue

##### Signs;

- Retains colour of **donor site**
- Bleeds on motion

##### Failure;

- Whitish
- No blood supply
- Moves easily
- Obvious discharge

##### Causes of failure;

- Haematomas
- Infection
- Movement
- Poor technique + other technical errors
- Immunological reaction to *Homo/Xenografts*

### b) Full thickness skin grafts

This is a graft of the *full thickness of mucosa and submucosa* or of *skin and subcutaneous tissue*.

\*\* Close of *donor site* with **advancement flaps**

\*\* **Defat** graft to prevent *non-take due to fat necrosis*

**Table 21.4** Split-skin graft vs. full-thickness graft

Split-skin grafts	Full-thickness grafts
<b>Donor site factors</b>	
Large area available	Smaller area
Donor site heals spontaneously	Donor site must be closed
Donor site reusable	Donor site scars
<b>Recipient factors</b>	
Poor colour match	Good colour match
Easily abraded	Abrasion resistant
Inferior cosmetic result	Good cosmetic result
More reliable 'take'	Less reliable 'take'
Shiny texture, inelastic	Normal texture, elastic

#### Post-op

- **Grafts** are **open on Day 5** or earlier if in doubt.
- **Donor areas** for very *thin grafts* will heal in **7-10 days**, whereas donor areas for *intermediate-thickness grafts* may require **10-18 days** and those for *thick grafts* **18-21 days** or longer.
- Monitor;
  - Clinically - *Colour, capillary refill, bleeding on pin-prick, Skin T°C & Skin turgor*
  - Doppler flow monitoring
  - Photoplethysmography
  - Surface thermometry
  - Thermocouple probes

# Flaps

A flap is a *piece of viable tissue with a blood supply* which can be used to reconstruct a tissue defect.

## Indications;

- Direct tissue closure
- Closure of complex wounds;
  - \* Chronic osteomyelitis or cartilage infection
  - \* Chronic radiation wounds
- Vascular insufficiency
- Exposed or infected prosthesis

## Classification;

### i) Based on *method of movement*;

#### a) **Local flaps** - a flap transferred to an *adjacent area*.

- **Advancement flap** - a rectangular flap raised in an *elastic area*, with its free end adjacent to a defect; the defect is covered by *stretching the flap longitudinally* until the end comes over it e.g. V-Y flap - a flap in which the incision is made in a V shape and sutured in a Y shape to gain additional tissue - around eyelids & mouth
- **Pivot flaps**;
  - **Rotation flap** - a pedicle flap that is *rotated from the donor site to an adjacent recipient area*, usually as a direct flap - *For circular defects*
  - **Transposition flap** - *Rectangular or square shaped*.

#### b) **Interpolation flaps** - a flap that is rotated into an *adjoining area* but **not immediately adjacent** hence the *pedicle must pass over or under intervening normal tissue*.

#### c) **Distant flaps** - a flap in which the *donor site is distant from the recipient area*.

- **Direct flap** - a flap raised completely and transferred at the same stage
- **Tube flap** - a flap in which the sides of the pedicle are sutured together to create a tube, with the entire surface covered by skin - *Reduces infection & contracture formation*.
- **Free flap** - island flap in which the donor vessels are severed proximally, the flap is transported as a free object to the recipient area, and the flap is revascularized by anastomosing its supplying vessels to vessels there.

### ii) Based on *blood supply*;

#### a) **Axial pattern flap** - a flap that *includes a direct specific artery* within its longitudinal axis.

#### b) **Random pattern flap** - a flap in which the *pedicle blood supply is derived randomly from the network of vessels* in the area.

### iii) Based on *tissue composition*;

#### a) **Cellulocutaneous flap** - a flap of *skin and subcutaneous tissue*.

#### b) **Myocutaneous flap** - a pedicle *skin* flap, often an island flap, with an attached *subjacent muscle* and its investments and blood supply.

#### c) **Muscle flaps**;

I - Have a *single vascular pedicle* to muscle e.g. gastrocnemius

II - Has *dominant & minor vascular pedicles* e.g. soleus

III - Has *2 dominant pedicles* from different vascular sources e.g. gluteus maximus

IV - Has *segmental pedicles*

#### d) **Composite/Compound flap** - a flap of *2 or more elements* incorporating underlying *muscle, bone, or cartilage*.

### iv) *Specialised flaps*;

#### a) **Neurovascular flap** - a flap containing *a sensory nerve*, one purpose of which is to *restore sensation to the recipient area*.

## Procedure;

- i) Pre-op assessment & preparation
- ii) Design flap & vascular pedicle
- iii) Operate & Leave a *suction* drain
- iv) Post-op monitoring - as above

## Complications;

### Anaesthetic complications

#### Pre-op;

- Poor flap design
- Underestimation of recipient requirements
- Pre-morbid conditions of the patient

#### Intra-op;

- Technical errors



Technical errors

- Design errors
- Poor choice of recipient vessels
- Errors of judgement

**Post-op;**

- Extrinsic;
  - Pedicle kinking, tension, positioning, dressing
  - Wound complications
  - Non-functioning anastomosis due to thrombosis
- Intrinsic - Distal flap ischemia - *If flap appears non-viable, return it to its bed*

# Ulcers

An ulcer is an **abnormal break in the continuity of an epithelial surface** characterized by a **progressive destruction of the surface epithelium** & a **granulating base**.

## Clinical Examination of an Ulcer

- i) Site
- ii) Size
- iii) Shape
- iv) Edges;
  - **Eroded** - *Active & spreading*
  - **Shelved/sloping** - *Healing*
  - **Punched out** - *Syphilis*
  - **Rolled/Everted** - *Malignant; Marjolin's ulcer* - This eponym is used to describe carcinomatous change occurring at the edge of *any long standing benign ulcer* e.g. *a chronic venous ulcer, burn scars, chronic osteomyelitis sinuses*. It is a **slow progressive painless SCC** that *spreads locally*.
- v) Surface;
  - Discharge
  - **Floor** - *That which can be seen by an observer*
  - **Base** - *What can be palpated;*
    - \* *Necrotic - Benign*
    - \* **Indurated** - *Malignant*
- vi) Sensation - **Decreased** sensation around the ulcer implies **neuropathy**
- vii) Lymphadenopathy - Suggest **infection or malignancy**
- viii) Symptoms (Associations)

## Signs of a Malignant Ulcer

- Cancer is more common (**10%**) in ulcers **>2 cm** in diameter
- The deepest penetration of the ulcer is **not beyond the expected border**
- **Raised & everted edge** due to rapid progression
- **Indurated** base
- **Enlarged, Hard, Fixed** Lymph nodes.
- **Rapid progression & poor healing**

# Leg Ulcers

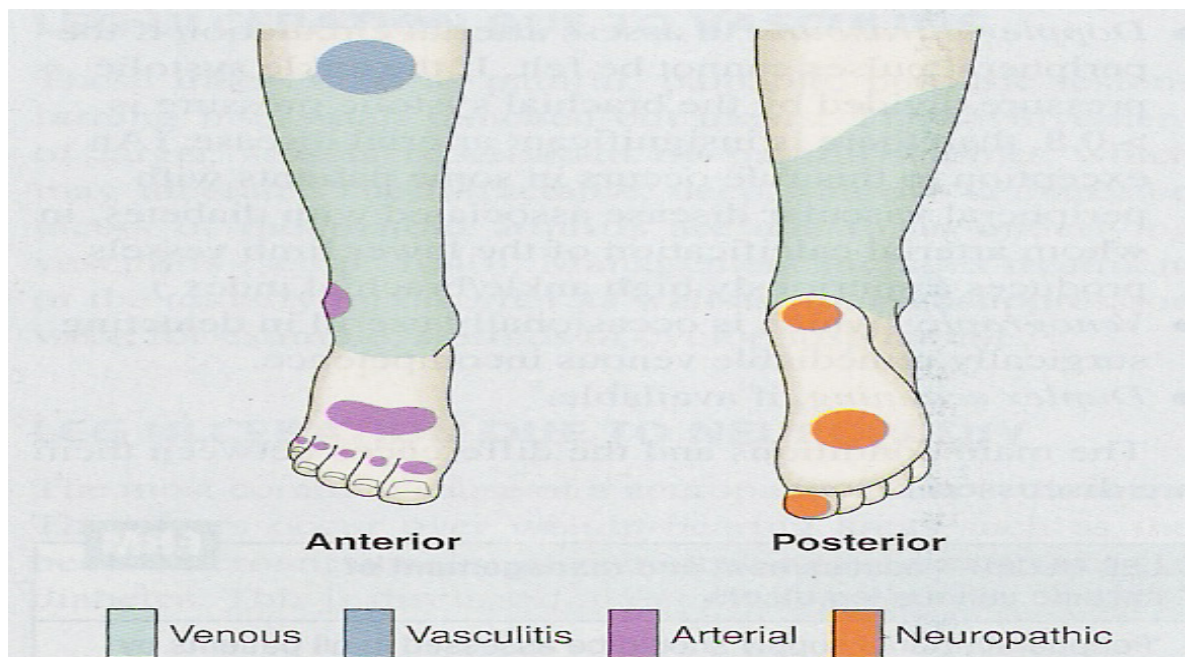


Fig. 21.8 Causes of lower leg ulceration.

## 21.15 MAIN CAUSES OF LEG ULCERATION



### Venous hypertension

- See text

### Arterial disease

- Atherosclerosis
- Vasculitis
- Buerger's disease

### Small vessel disease

- Diabetes mellitus
- Vasculitis

### Abnormalities of blood

- Sickle-cell disease
- Cryoglobulinaemia
- Spherocytosis
- Immune complex disease

### Neuropathy

- Diabetes mellitus
- Leprosy
- Syphilis

### Tumour

- Squamous cell carcinoma
- Basal cell carcinoma
- Malignant melanoma
- Kaposi's sarcoma

### Trauma

- Injury
- Artefact

## Causes of leg ulcers

- i. Vascular
  - Venous—80-85% of all leg ulcers
  - Arterial—atherosclerosis, arteriovenous malformation
  - Vasculitis—systemic lupus erythematosus, rheumatoid arthritis, scleroderma, polyarteritis nodosa, Wegener's granulomatosis
  - Lymphatic-Elephantiasis
- ii. Neuropathic- Diabetes, peripheral neuropathy—usually feet, Leprosy, nerve injury, cord lesions
- iii. Haematological- Polycythaemia rubra vera, sickle cell anaemia
- iv. Traumatic  
Burns, cold injury, pressure sore, radiation, factitious
- v. Neoplastic- Basal or squamous cell carcinoma, melanoma, Marjolin's ulcer, Bowen's disease
- vi. Others  
Sarcoidosis, tropical ulcer, pyoderma gangrenosum, Maduromycosis, Onchocerciasis, Neurofibromatosis.

## Leg Ulceration due to venous disease

Damage to the venous system of the leg results in *oedema, haemosiderin deposition, eczema, fibrosis & ulceration*.

### Pathogenesis

In the normal leg, there is a **superficial low-pressure** venous system connected to the **deep, high-pressure** veins by **perforating veins**. **Muscular activity**, aided by **valves in the veins**, pumps blood from the **superficial to the deep system & towards the heart**.

**Incompetent valves** in the **perforating & deep veins** may result from;

- Congenital or familial valve incompetence
- Prolonged standing
- Deep venous obstruction (e.g. from a *pelvic tumour, foetus*)
- Previous DVT
- Infection

This results in the **retrograde flow** of blood to the superficial system ('**venous hypertension**') causing a **rise in capillary hydrostatic pressure & stasis** leading to development of **superficial varicosities & skin changes** (*lipodermatosclerosis = induration, pigmentation, & inflammation of the skin* of the lower leg).

**Fibrinogen** is forced out through the capillary walls & fibrin is deposited as a **pericapillary cuff** which traps **growth & repair factors** so **hypoxia & necrosis due to stasis** or **minimal trauma** to the leg leads to ulceration which often takes many months to heal.

### Management

- General management includes *dietary advice for the obese & encouragement to take gentle exercise*
- Oedema should be reduced by the regular use of **graduated compression bandages** in the *absence of any evidence of compromised arterial supply*, applied from the toes to the knees enhance venous return. Also, **keeping the legs elevated** when sitting & the **judicious** use of **diuretics**
- The **exudate & slough** should be **removed** with **normal saline solution or 0.5% aqueous silver nitrate**. If the ulcer is **very purulent**, **soaking** the leg for **15mins** in **potassium permanganate** may be helpful.
- **Dressings;**
  - antibiotic-impregnated tulle dressings
  - non-adhesive absorbent dressings (*alginates, charcoals, hydrogels, or hydrocolloids*)
  - Dry non-adherent dressings.

The frequency of dressings depends on the state of the ulcer. **Very purulent & exudative ulcers** may need **daily** dressings whilst the dressing on a **clean healing ulcer** may only require changing **every week**.

- **Paste bandages**, impregnated with **zinc oxide or ichthammol**, help to keep dressings in place & provide protection.
- Surrounding **venous eczema** is treated by a *mild or moderately potent topical corticosteroid*. The steroid should **not be applied to the ulcer itself**. An anabolic steroid, stanozolol, may help lipodermatosclerosis but side effects (fluid retention, hepatotoxicity) may limit its use
- **Oral antibiotic therapy**, given in *short courses*, is only necessary for the treatment of **overt infection**.
- **Vein surgery** may help some younger patients with persistent venous ulcers. **Pinch grafts** may hasten the healing of clean ulcers *but do not influence their rate of recurrence*.