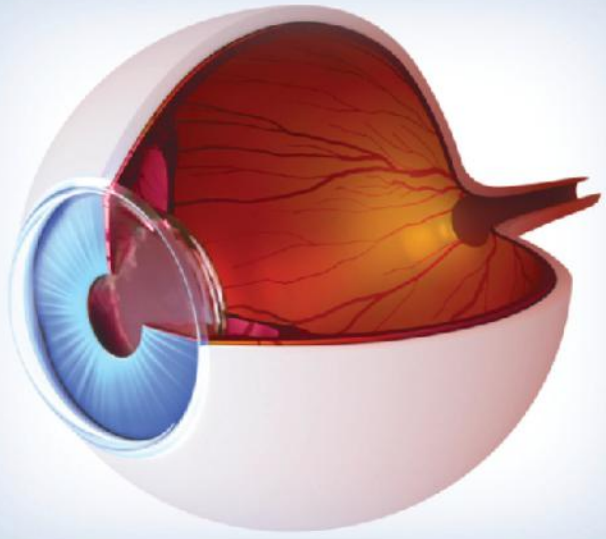


FAQs



Aravind

FAQs in

OPHTHALMOLOGY

N Venkatesh Prajna

Aravind
FAQs in
Ophthalmology

Aravind FAQs in Ophthalmology

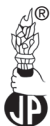N Venkatesh Prajna

DNB FRCOphth

Director-Academics

Aravind Eye Hospital

Madurai, Tamil Nadu, India



Jaypee Brothers Medical Publishers (P) Ltd

Headquarters

Jaypee Brothers Medical Publishers (P) Ltd
4838/24, Ansari Road, Daryaganj
New Delhi 110 002, India
Phone: +91-11-43574357
Fax: +91-11-43574314
Email: jaypee@jaypeebrothers.com

Overseas Offices

J.P. Medical Ltd
83 Victoria Street London
SW1H 0HW (UK)
Phone: +44-2031708910
Fax: +02-03-0086180
Email: info@jpmedpub.com

Jaypee-Highlights Medical Publishers Inc.
City of Knowledge, Bld. 237, Clayton
Panama City, Panama
Phone: +507-301-0496
Fax: +507-301-0499
Email: cservice@jphmedical.com

Jaypee Brothers Medical Publishers (P) Ltd
17/1-B Babar Road, Block-B, Shaymali
Mohammadpur, Dhaka-1207
Bangladesh
Mobile: +08801912003485
Email: jaypeedhaka@gmail.com

Jaypee Brothers Medical Publishers (P) Ltd
Shorakhute, Kathmandu
Nepal
Phone: +00977-9841528578
Email: jaypee.nepal@gmail.com

Website: www.jaypeebrothers.com
Website: www.jaypeedigital.com

© 2013, Jaypee Brothers Medical Publishers

All rights reserved. No part of this book may be reproduced in any form or by any means without the prior permission of the publisher.

Inquiries for bulk sales may be solicited at: jaypee@jaypeebrothers.com

This book has been published in good faith that the contents provided by the author contained herein are original, and is intended for educational purposes only. While every effort is made to ensure accuracy of information, the publisher and the author specifically disclaim any damage, liability, or loss incurred, directly or indirectly, from the use or application of any of the contents of this work. If not specifically stated, all figures and tables are courtesy of the author. Where appropriate, the readers should consult with a specialist or contact the manufacturer of the drug or device.

Aravind FAQs in Ophthalmology

First Edition: 2013

ISBN: 978-93-5090-183-0

Printed at

Preface

The specialty of ophthalmology has developed by leaps and bounds in the recent past. Excellent comprehensive books are being brought out at regular intervals, which helps an ophthalmologist to keep abreast with times. In my 15 years experience as a residency director, I have often found the need for a concise, examination oriented ready-reckoner, which would be of use to the postgraduates to answer specifically to the point. This book aims to fill this gap and serves as a compilation of the frequently asked questions (FAQs) and the answers expected in a postgraduate clinical ophthalmology examination. This book should not be misconstrued as a replacement to the existing standard textbooks. These questions have been painstakingly gathered over a 10-year period from the collective experience of several senior teachers at Aravind Eye Hospital, Madurai, Tamil Nadu, India. Apart from the exam-oriented questions, this book also contains examples of case sheet writing and different management scenarios, which will help the students to logically analyze and answer in a coherent manner. I do sincerely hope that this book helps the postgraduate to face his/her examination with confidence.

N Venkatesh Prajna

Contents

1. Introduction	1
1.1 <i>Visual Acuity</i>	1
1.2 <i>Color Vision</i>	10
1.3 <i>Anatomical Landmarks in Eye</i>	14
1.4 <i>Pharmacology</i>	18
1.5 <i>Slit Lamp Biomicroscope</i>	26
1.6 <i>Direct Ophthalmoscope</i>	33
1.7 <i>Indirect Ophthalmoscopy</i>	36
1.8 <i>X-rays in Ophthalmology</i>	40
1.9 <i>Computed Tomography and Magnetic Resonance Imaging</i>	48
2. Cornea	55
2.1 <i>Keratometry</i>	55
2.2 <i>Corneal Vascularization</i>	58
2.3 <i>Corneal Anesthesia</i>	60
2.4 <i>Corneal Deposits</i>	63
2.5 <i>Bacterial and Fungal Corneal Ulcer</i>	66
2.6 <i>Acanthamoeba Keratitis</i>	72
2.7 <i>Viral Keratitis</i>	77
2.8 <i>Interstitial Keratitis</i>	80
2.9 <i>Mooren's Ulcer</i>	82
2.10 <i>Band-Shaped Keratopathy</i>	88
2.11 <i>Adherent Leukoma</i>	91
2.12 <i>Bowen's Disease</i>	94
2.13 <i>Keratoconus</i>	98
2.14 <i>Stromal Dystrophies—Cornea</i>	107
2.15 <i>Fuch's Endothelial Dystrophy</i>	117
2.16 <i>Endothelial Disorders and Bullous Keratopathy</i>	121
2.17 <i>Keratoplasty</i>	125
3. Uvea	134
3.1 <i>Uveitis—History and Clinical Features</i>	134
3.2 <i>Sympathetic Ophthalmia</i>	150
3.3 <i>Fuch's Heterochromic Iridocyclitis</i>	152
3.4 <i>Vogt Koyanagi Harada Syndrome</i>	154
3.5 <i>Behcet's Disease</i>	156
3.6 <i>Investigations in Uveitis</i>	158
3.7 <i>Treatment of Uveitis</i>	172

4. Glaucoma	178
4.1 <i>Tonometry</i>	178
4.2 <i>Gonioscopy</i>	186
4.3 <i>Glaucoma Diagnostic with Variable Corneal Compensation (GDx VCC)</i>	192
4.4 <i>Glaucoma Visual Field Defects</i>	194
4.5 <i>Ultrasound Biomicroscopy in Glaucoma</i>	201
4.6 <i>Angle Closure Glaucoma</i>	203
4.7 <i>Management of an Acute Attack of Angle Closure Glaucoma</i>	212
4.8 <i>Primary Open-Angle Glaucoma</i>	213
4.9 <i>Neovascular Glaucoma</i>	220
4.10 <i>Pigmentary Glaucoma</i>	229
4.11 <i>Pseudoexfoliation Glaucoma</i>	233
4.12 <i>Uveitic Glaucoma</i>	239
4.13 <i>Steroid Induced Glaucoma</i>	242
4.14 <i>Lens Induced Glaucoma</i>	245
4.15 <i>Medical Management of Glaucoma</i>	249
4.16 <i>Newer Drugs in Glaucoma</i>	260
4.17 <i>Lasers in Glaucoma</i>	266
4.18 <i>Trabeculectomy</i>	275
4.19 <i>Modulation of Wound Healing in Glaucoma Filtering Surgery</i>	289
4.20 <i>Glaucoma Drainage Devices (GDD)</i>	293
4.21 <i>Cyclodestructive Procedures</i>	302
5. Lens and Cataract	308
6. Retina	314
6.1 <i>Fundus Fluorescein Angiography (FFA)</i>	314
6.2 <i>Ultrasonography (USG)</i>	325
6.3 <i>Diabetic Retinopathy (DR)</i>	330
6.4 <i>Lasers in Diabetic Retinopathy</i>	338
6.5 <i>Hypertensive Retinopathy (HTN Retinopathy)</i>	349
6.6 <i>Central Retinal Vein Occlusion (CRVO)</i>	355
6.7 <i>Central Retinal Artery Occlusion (CRAO)</i>	363
6.8 <i>Retinal Detachment (RD)</i>	368
6.9 <i>Endophthalmitis</i>	390
6.10 <i>Retinitis Pigmentosa</i>	398
6.11 <i>Retinoblastoma (RB)</i>	407
6.12 <i>Age-Related Macular Degeneration (ARMD)</i>	414
6.13 <i>Vitrectomy</i>	422
6.14 <i>Central Serous Chorioretinopathy (CSCR)</i>	426
6.15 <i>Angiogenesis</i>	428

7. Neuro-Ophthalmology	430
7.1 <i>The Normal Pupil</i>	430
7.2 <i>Optic Nerve Head</i>	435
7.3 <i>Optic Neuritis</i>	442
7.4 <i>Papilledema</i>	449
7.5 <i>Optic Atrophy</i>	464
7.6 <i>Optic Disk Anomalies</i>	474
7.7 <i>Anterior Ischemic Optic Neuropathy</i>	480
7.8 <i>Oculomotor Nerve</i>	485
7.9 <i>Fourth Nerve Palsy</i>	496
7.10 <i>Abducens Nerve Palsy</i>	500
7.11 <i>Myasthenia Gravis</i>	505
7.12 <i>Nystagmus</i>	513
7.13 <i>Visual Fields in Neuro-Ophthalmology</i>	519
7.14 <i>Cavernous Sinus Thrombosis</i>	523
7.15 <i>Carotico-Cavernous Fistulas</i>	530
7.16 <i>Carotid Artery Occlusion</i>	532
7.17 <i>Ophthalmoplegia</i>	537
7.18 <i>Malingering</i>	543
8. Orbit	548
8.1 <i>Ectropion</i>	548
8.2 <i>Entropion</i>	557
8.3 <i>Ptosis</i>	562
8.4 <i>Eyelid Reconstruction</i>	568
8.5 <i>Blepharophimosis Syndrome</i>	576
8.6 <i>Thyroid-Related Orbitopathy (TRO) and Proptosis</i>	577
8.7 <i>Blowout Fractures of the Orbit</i>	597
8.8 <i>Orbitotomies</i>	602
8.9 <i>Botulinum Toxin</i>	606
8.10 <i>Dacryocystorhinostomy</i>	608
9. Pediatric Ophthalmology and Strabismus.....	610
9.1 <i>Diplopia Charting</i>	619
9.2 <i>Hess Charting</i>	621
10. Miscellaneous	626
10.1 <i>Vitamin A Deficiency</i>	626
10.2 <i>Localization of Intraocular Foreign Bodies (IOFB)</i>	631
10.3 <i>Community Ophthalmology</i>	641
<i>Case Sheet Writing</i>	<i>649</i>
<i>Index</i>	<i>669</i>

1

CHAPTER

Introduction

1.1. VISUAL ACUITY

1. Define visual acuity.

Visual acuity is defined as the reciprocal of the minimum resolvable angle measured in minutes of arc for a standard test pattern.

2. Define visual angle.

It is the angle subtended at the nodal point of the eye by the physical dimensions of an object in the visual field.

3. What are the components of visual acuity?

Visual acuity has three components.

- i. **Minimum visible:** Detection of presence or absence of stimulus.
- ii. **Minimum separable:** Judgment of location of a visual target relative to another element of the same target.
- iii. **Minimum resolvable:** Ability to distinguish between more than one identifying feature in a visible target. Threshold is between 30 sec and 1 minute of arc.

4. What are the components of measurement of vision?

- i. Visual acuity
- ii. Field of vision
- iii. Color vision and
- iv. Binocular single vision.

5. Who developed classic test chart?

Professor Hermann Snellen in 1863.

6. What is the testing distance? Why do we check at that distance?

The testing is done 6 m (20 ft) away from the target. At this distance, divergence of rays that enters the pupil is so small that rays are considered parallel. Hence, accommodation is eliminated at this distance.

7. Describe about the Snellen's chart.

The letters are:

- i. It consists of series of black capital letters on a white board arranged in lines, each progressively diminishing in size.
- ii. Lines comprising letters have such a breadth that they will subtend at an angle of 1 minute at the nodal point of the eye at a particular distance.
- iii. Each letter is designed such that it fits in a square.
- iv. The sides of the letter are 5 times the breadth of constituent lines.
- v. At given distance, each letter subtends at an angle of 5 minutes at the nodal point of the eye.

8. What does normal 6/6 visual acuity represent?

It represents the ability to see 1 min of arc which is close to theoretical diffraction limits.

9. Explain LogMAR charts.

- i. Used for academic and research purposes.
- ii. This is a modification of Snellen's chart, where each subsequent line differs by 0.1 log unit in the minimum angle of resolution (MAR) required for that line.
- iii. They have equal number of letters in each line.
- iv. Used at a distance of 4 meters.

10. What is the procedure of testing visual acuity (VA) using Snellen's chart?

- i. Patient is seated at a distance of 6 m from the Snellen's chart because at this distance the rays of light are practically parallel and patient exerts minimal accommodation.
- ii. Chart should be properly illuminated (not less than 20 foot candle).
- iii. Patient is asked to read with each eye separately.
- iv. Visual acuity is recorded as a fraction.
 - Numerator: Distance of the patient from the chart.
 - Denominator: Smallest letters read accurately.
- v. When the patient is able to read upto 6 m line, the VA is recorded as 6/6 – Normal.
- vi. Depending on the smallest line patient can read from distance of 6m VA is recorded as 6/9, 6/12, 6/18, 6/24, 6/36 and 6/60.
- vii. If the patient cannot see the top line from 6 m, he/she is asked to walk towards the chart till one can read the topline.
- viii. Depending on the distance at which patient can read the topline, the VA is recorded as 5/60, 4/60, 3/60, 2/60 and 1/60.
- ix. **Finger counting:**
If patient is unable to read topline even from 1 m, he/she is asked to count fingers (CF) of the examiner, the VA is recorded as CF-3', CF-2', CF-1' or CF close to face depending on the distance (in meters) at which the patient is able to count fingers.

x. **Hand movements (HM):**

When the patient fails to count fingers, the examiner moves his/her hand close to patient's face. If the patient can appreciate the hand movements, the VA is recorded as HM positive.

xi. **Perception of light (PL):**

When the patient cannot distinguish HM, examiner notes if the patient can perceive light or not. If the patient can perceive light, then it is recorded as PL+ and if the patient cannot perceive light, then it is recorded as P.

xii. **Projection of rays (PR):**

If PL is +ve, then PR should be checked by shining light in all 4 directions and patient is asked whether he/she is able to recognize the direction of light rays that is shown and is recorded in all 4 quadrants.

11. How is a decimal notation represented?

It converts Snellen fraction to a decimal.

For example: Snellen 20/20—decimal 1.0

Snellen 20/30—decimal 0.7

Snellen 20/40—decimal 0.5

12. How is near vision tested?

- i. Near acuity testing demonstrates the ability of a patient to see clearly at a normal reading distance.
- ii. Test is usually performed at 40 cm (16") with a printed, handheld chart.
- iii. The following charts are used:
 - Jaeger's chart
 - Roman test types
 - Snellen's near vision test types

13. Explain Jaeger's chart.

- i. Jaeger, devised it in 1867.
- ii. It consisted of ordinary printed fonts of varying sizes used at that time. Various sizes of modern fonts that approximate the original chart is used.
- iii. In this chart, prints area marked from 1 to 7 and accordingly patient's acuity is labeled as J1 to J7, depending upon the print one can read.

14. What is Landolt's testing chart?

- i. It is similar to Snellen's chart, except instead of letter, broken circles are used.
- ii. Each broken ring subtends an angle of 5 min at the nodal point.
- iii. It consists of detection of orientation of the break in the circle.

15. What is Vernier acuity?

- i. It is the smallest offset of a line which can be detected.
- ii. It is measured using a square wave grating.
- iii. Offset of 3–5 sec of an arc is normally discernible.
- iv. It is less than limit of Snellen VA and is therefore called as hyperacuity.

16. What are potential acuity testing?

These tests are used to assess the visual acuity of eyes in which it is not possible to see the macula because of cataract.

- i. Pinhole test
- ii. Bluefield entopic phenomena: Ability to see moving white dots when blue light diffusely illuminates the retina. It represents light transmitted by WBCs in the perifoveal capillaries.
- iii. Interferometers: It projects laser light from two sources on to the retina. Interference occurs when two sources meet. It is seen as Sine wave Grating if macula is functioning.

17. What are Roman test types?

- i. Devised by the Faculty of ophthalmologist of Great Britain in 1952.
- ii. It consists of "Times Roman" type fonts with standard spacing.
- iii. Near vision is recorded as N5, N6, N8, N10, N12, N18, N36, and N48.

18. Explain Snellen's near vision test types.

- i. Snellen's equivalent for near vision was devised on the same principle as distant types.
- ii. Graded thickness of letters of different lines is about 1/17th of distant vision chart letters.
- iii. Letters equivalent to 6/6 line subtend an angle of 5 min at an average reading distance (35 cm/14").

19. What is the procedure of testing near vision?

- i. Patient is seated in a chair and asked to read the near vision chart kept at a distance of 25–35 cm with a good illumination thrown over his or her left shoulder.
- ii. Each eye should be tested separately.
- iii. Near vision is recorded as the smallest type that can be read completely by the patient.
- iv. A note of approximate distance at which the near vision chart is held should be made.
- v. Thus, near vision is recorded as:
 NV = J1 at 30 cm (in Jaeger's notation)
 NV = N5 at 30 cm (in Faully's notation)

Feet	Meters	LogMAR
20/20	6/6	0.00
20/30	6/9	0.18
20/40	6/12	0.30
20/60	6/18	0.48
20/80	6/24	0.60
20/120	6/36	0.80
20/200	6/60	1.00

20. What is the principle of pinhole?

Pinhole admits only central rays of light, which do not require refraction by the cornea or the lens. Patient can resolve finer detail on the acuity chart in this way, without use of glasses.

21. What do we infer from pinhole testing?

- i. If the pinhole improves VA by 2 lines or more, then there is more likely a chance of refractive error. If the pinhole does not improve vision, then other organic causes should be looked for.

22. What are the types of pinhole?

- i. Single – no more than 2.4 mm in diameter is used
- ii. Multiple – central opening surrounded by 2 rings of small perforation.

23. How is the pinhole testing performed?

- i. Position the patient and occlude the eye not being tested.
- ii. Ask the patient to hold the pinhole occluder in front of the eye that is to be tested. The habitual correction should be worn for the test.
- iii. Instruct the patient to look at the distance chart through the single pinhole.
Instruct the patient to use little hand or eye movements to align the pinhole to resolve sharpest image on the chart.
- iv. Ask the patient to begin to read the line with the smallest letters that are legible as determined on the previous vision test without the use of pinhole.

24. What are the variables used in visual acuity measurements?

The conditions that may cause variability in acuity measurements for both near and distance are:

External variables:

- i. If lighting level is not constant during testing
- ii. Variability in contrast: Charts with higher contrast will be seen more easily than those with lower contrast
- iii. If chart is not kept clean, smaller letters will become more difficult to identify
- iv. When projector chart is used, cleanliness of projector bulb and lens and condition of projecting screen will affect the contrast of letters viewed
- v. The distance between projector and chart will affect size of letters
- vi. Sharpness of focus of projected chart
- vii. Incidental glare on the screen.

Optical considerations:

- i. If patient is wearing eye glasses, be sure the lenses are clean. Dirty lenses of any kind, whether trial lenses or contact lenses will decrease visual acuity.
- ii. Effects of tear film abnormalities, such as dry eye syndromes can be minimized by generous use of artificial tear preparation.

- iii. Corneal surface abnormalities produce distortions and must be addressed medically.
- iv. Corneal or lenticular astigmatism may necessitate use of special spectacle or contact lens.

Neurologic impairments:

- i. Motility defects such as nystagmus or any other movement disorder which interferes with the ability to align the fovea will lower the acuity measurement.
- ii. Visual field defects
- iii. Optic nerve lesions
- iv. Pupil abnormalities
- v. Impairment by drugs, legal or illicit.

25. What are the causes of poor near acuity than distance acuity?

- i. Presbyopia/premature presbyopia
- ii. Undercorrected/high hyperopia
- iii. Overcorrected myopia
- iv. Small, centrally located cataracts
- v. Accommodative effort syndrome
- vi. Drugs with anticholinergic effect
- vii. Convergence insufficiency
- viii. Adie's pupil
- ix. Malingering/hysteria.

26. How to test the vision in infants?

- i. Blink response—In response to sound, bright light/touching the cornea
- ii. Pupillary reflex—After 29th week of gestation
- iii. Fixation reflex—Usually present at birth. It is well developed and well elicited by 2 weeks to 2 months
- iv. Follow movements—Following horizontally moving targets. It is seen in full term newborn and is well developed by first month. Vertical tracking is elicited by 4–8 weeks.
- v. **Catford drum test:**
 - It is based on the observation of pendular eye movement that is elicited as the child follows an oscillating drum with dots.
 - Test distance: 60 cm (2 ft)
 - Displayed dot size: 15–0.5 mm
 - Dot represent 20/600 to 20/20 vision.
 - Smallest dot that evokes pendular eye movement denotes acuity
 - Disadvantage: overestimate of vision by 2–4 times. It is unreliable for amblyopia screening.
- vi. **Preferential looking tests (PLT):**
 - The Principle is based on the behavioral pattern of an infant to prefer to fixate a pattern stimulus rather than a blank stimulus both being of the same brightness.

vii. **Teller acuity card test:**

- It is a modification based on PLT designed for a simpler and rapid testing.
- It has 17 cards, each of 25.5 x 51 cm. 15 of these contain 12.5 x 12.5 cm patches of square wave gratings.
- Cycle consists of 1 black and 1 white stripe and an octave is halving or doubling of spatial frequency.
- Testing distance: Infants upto 6 months of age – 38 cm.
7 months to 3 yr of age – 55 cm
Later – 84 cm
- Advantage: Very useful quick test for infants and preschool children upto 18 months.
- Disadvantage: It tests near acuity, not distance acuity. It measures resolution acuity not recognition acuity. It overestimates VA.

viii. **OKNOVIS:**

- Principle: Based on the principle of arresting an elicited optokinetic nystagmus by introducing optotypes of different sizes.
- Portable hand held drums moving at 12 rpm with colored pictures to elicit an optokinetic nystagmus.
- Testing distance: 60 cm
- Optotypes of different sizes are then introduced to arrest OKN.

ix. **Cardiff acuity cards:**

- Principle: Based on the principle of preferential fixation on cards which have picture optotype and a blank located vertically.
- Child identifies picture by verbalizing, pointing or fixation preference.

x. **Visually evoked response (VEP):**

- It records the change in the cortical electrical pattern detected by surface electrodes monitoring the occipital cortex following light stimulation of the retina.
- Two types of stimuli:
Pattern—Checker board or stripes
Flash—Unpatterned.
- Preferred is pattern reversal type.
- Can be recorded in two modes: Transient or steady state.

27. How do you infer visual acuity from fixation pattern?

Fixation pattern	Visual acuity
Gross eccentric fixation	<CF 1 m
Unsteady central fixation	<6/60
Steady central fixation but not maintained	6/60–6/36
Central steady fixation, can maintain but prefers other eye	6/24–6/9
Central steady fixation, free alternation or cross fixation	6/9–6/6

To call it as good fixation, it should be central, steady, and maintained. Preference of fixation in one eye denotes that poor vision in non-fixating eye.

28. How is vision tested in infants aged about 1–2 years?

- **Boeck candy test (Cake decoration test):**
 - Initially child's hand is guided to the bead and then to his mouth
 - Each eye is alternatively covered and the difference is noted.
- **Worth's ivory ball test:**
 - Ivory balls 0.5" to 1.5" of diameter are rolled on the floor in front of the child
 - Asked to retrieve each
 - Acuity is estimated on the basis of the smallest size for the test distance.
- **Sheridan's ball test:**
 - These are Styrofoam balls of different sizes rolled in front of the child
 - Quality of fixation for each size is assessed
 - Same can be used as mounted balls used at 10 ft distance against black screen. Fixation behavior for each ball is observed by the examiner hidden behind the screen.

29. How is vision tested in children of around 3 years of age?

- **Miniature toy test:**
 - A component of STYCAR test
 - Pair of miniature toys are used
 - Test distance is 10 ft
 - Child is asked to name or pick the pair from an assortment.
- **Coin test:**
 - Coins of different sizes at different distances are shown
 - Child is asked to distinguish between the two faces of the coin.
- **Dot VA test:**
 - In a darkened room, the child is shown an illuminated box with printed black dots of different diameters.
 - Then, smaller dots are shown
 - Smallest dot identified correctly twice is taken as acuity threshold.

30. How is vision tested in children aged 3–5 years?

- Vision test using pictures, symbols or even letters become applicable in this age group
- Training by mother at home is helpful
 - Illiterate E-cutout test
 - Tumbling E test
 - Isolated hand figure test
 - Sheridan-Gardiner test
 - Lipmann's HOTV test
 - Pictorial vision test
 - Broken wheel test
 - Boek Candy bead test
 - Light home picture cards

- **Illiterate E-cutout test:**
 - Child is given a cutout of an E and asked to match this with isolated E's of varying sizes
 - When child starts understanding orientation of E, VA chart consisting of E's oriented in various directions are used.
- **Tumbling E test:**
 - Preferred for mass screening in preschool children
 - Consists of different sizes of E, in one of the four positions—right, left, up or down.
 - Distance: 6 m
 - Each eye is tested separately.
- **Landolt's C:** Similar to the E test
- **Sheridan's letter test:**
 - Uses 5 letters H,O,T,V and X in 5 letter set
 - A and V are added in 7 letter set
 - C and L are also added in 9 letter set
 - Testing distance is 10 ft (3 m)
 - Child is expected to name the letters/indicate similar letter on the card in hand
- **Lippman's HOTV test:**
 - Uses only 4 letters H,O,T,V at test distance of 3 m
 - Simpler version of Sheridan test

31. What is hyperacuity?

The human eye is capable of seeing more than the ability of the retinal cones to resolve. This ability is called hyperacuity. It is due to the involvement of higher cortical centers in the parietal cortex, for example:

- Vernier acuity
- Stereo acuity

Vernier acuity:

This is the ability to discern the Vernier separation between two lines not in perfect alignment. It is in the range of 10–20 sec of an arc.

Stereoacuity:

This is the ability to perceive a separation in the three-dimension (3D) depth perception.

32. What is Stiles-Crawford effect?

Stiles and Crawford have shown that pencils of light entering the eye obliquely are less effective as stimuli, compared to those entering the pupil centrally. They pointed out that this effect is not due to aberrations in the optical system but is most likely related to the orientation of the receptors in the retina. This directional sensitivity of the retina is referred to as the Stiles-Crawford effect.

1.2. COLOR VISION

1. How will you test color vision by Ishihara chart?

- i. Room should be adequately lit by daylight
- ii. Nature of the test should be explained to the patient
- iii. Full refractive correction is worn
- iv. It is preferable to do the test before pupillary dilatation
- v. One eye is first occluded and the other eye is tested
- vi. The plates are kept at a distance of 75 cm from the subject with the plane of the paper at right angle to the line of vision.
- vii. The standard time taken to answer each plate is 3–5 seconds.

2. Explain about Ishihara chart.

- i. Designed to provide a test which gives a quick and accurate assessment of color vision deficiency of congenital origin
- ii. It consists of a total of 25 plates.

Plate number	Normal	Points with red-green defects	Inference
1	12	12	Both subjects with normal and defective color vision read plate 1 as 12.
2	8	3	
3	6	5	
4	29	17	Subjects with red-green defects read these plates as those in abnormal column. Totally color blind are unable to read.
5	57	35	
6	5	2	
7	3	5	
8	15	17	
9	74	21	
10	2	X	
11	6	X	
12	97	X	
13	45	X	
14	5	X	Subjects with normal color vision do not see any number. Those with red green deficiency read the numbers given in the abnormal column.
15	7	X	
16	16	X	
17	73	X	
18	X	5	
19	X	2	
20	X	45	
21	X	73	Subjects with protanopia read these plates as given in abnormal column(1), those with deuteranomaly read them as given in column (2).
22	26	Protan 6 Deutan 2	
23	42	2 4	
24	35	5	
25	96	6	

3. Classify color blindness.

a. Congenital b. Acquired

a. Congenital color blindness:

X-linked recessive inherited affecting predominantly males

Types:

- i. Dyschromatopsia:
 - Anomalous trichromatic color vision:
 - Protanomalous: Defective red color appreciation
 - Deutanomalous: Defective green color appreciation
 - Tritanomalous: Defective blue color appreciation
- ii. Dichromatic color vision:
 - Protanopia: Complete red color defect
 - Deutanopia: Complete green color defect
 - Tritanopia: Complete blue color defect
- iii. Achromatopsia:
 - Cone monochromatism – presence of only one primary color
 - Rod monochromatism

b. Acquired color defects

- i. Type I red green defects—similar to protan defects
 - Seen in progressive cone dystrophies
 - Stargardt's disease
 - Chloroquine toxicity
- ii. Type II Red Green Defects—similar to deutan defects
 - Seen in optic neuropathies, Leber's optic atrophy, ethambutol toxicity
- iii. Type III Tritan defects
 - Seen in progressive rod dystrophies, peripheral retinal lesions, macular edema

4. What are the difference between congenital and acquired color blindness?

Congenital	Acquired
Present at birth	Present after birth (3 months)
Type and severity constant	Can change with time
Type of deficiency can be diagnosed precisely	Can show combined color vision deficiency features
Both eyes are equally affected	Very rarely both eyes are equally affected
Visual fields and visual acuity are usually normal	Commonly there is a reduced visual acuity with field changes
Predominantly are red green defects	Most commonly are tritan defects
Higher incidence in male population	Equal incidence in both sexes

5. What are the theories of color vision?

a. Trichromatic theory of Young and Helmholtz:

It postulates the existence of 3 types of cones, each with a different photopigment maximally sensitive to either red, green or blue. The

sensation of any given color is determined by relative frequency in pulse from each of the cone systems.

b. Opponent color theory of Hering

It states that some colors appear to be mutually exclusive, for example, reddish green.

6. Mention the genes associated with color vision defects

Gene for rhodopsin—chromosome 3

Gene for red and green cones – ‘q’ arm of X chromosome

Gene for blue cone—chromosome 7.

7. Explain about the neurophysiology of color vision.

i. Genesis of visual signals in photoreceptors:

Photochemical changes in cone pigments followed by a cascade of biochemical changes produce visual signal in the form of cone receptor potential.

ii. Processing and transmission of color vision signals:

The action potential generated in photoreceptors is transmitted by electrical induction to other cells of retina across the synapses if photoreceptors, bipolar cells and horizontal cells and then across synapses of bipolar cells, ganglion cells and amacrine cells.

iii. Processing of color signals on lateral geniculate body (LGB):

All LGB neurons carry information from more than one cone cell. Color information carried by ganglion cells is relayed to parvocellular portion of LGB.

Spectrally non opponent cells (30%) give same type of response to any monochromatic light.

Spectrally opponent cells (60%) are excited by some wavelengths and inhibited by others.

Four types:

1. Cells with red/green antagonism

i. +R/-G

ii. +G/-R

2. Cells with yellow/blue antagonism

i. +B/-Y

ii. +Y/-B

iv. Analysis of color signals in visual cortex

Color information from parvocellular portion of LGB is relayed to layer IVC of striate cortex in area 17. From here it passes to blobs in Layers II and III. It is relayed to thin strips in usual association area and then to lingual and fusiform gyri of occipital lobe (specialized area concerned with color).

8. What are the tests for color vision apart from Ishihara chart?

i. Hardy-Rand-Ritter

– It is also a pseudo isochromatic chart test. Useful to identify protan, deutan and tritan defects. It consists of 24 plates with

vanishing designs containing geometric shapes. 4 plates are introductory plates, 6 are for screening (4 for protan and deutran, 2 for tritan), 10 are for grading severity of protan and deutran defect and last 4 are for grading tritan defect.

- ii. The Lantern test: The subject has to name the various colors shown to him using a lantern. He is judged based on this.
 - There are 3 types: Edrige Green, Holmes Wright Types A and B.
- iii. Farnsworth Munsell 100 hue test is a spectrographic test where colored chips are arranged in ascending order.
- iv. City University color vision test is also spectrographic test where the central colored plate is matched to its closest hue from 4 surrounding color plates.
- v. Nagels Anomaloscope test: The observer is asked to mix red and green colors in a proportion to match the given yellow color hue. It detects red-green deficiency.
- vi. Holmgren's wool test: The subject is asked to make a series of color matches from a selection of colored wools.

9. What are the causes of acquired blue-yellow defects?

Glaucoma, retinal detachment, pigmentary degeneration of retina, ARMD, vascular occlusions, diabetic, hypertensive retinopathy, pappiloedema, central serous retinopathy, chorioretinitis.

10. What are the causes of acquired red-green defects?

Optic neuritis, toxic amblyopia, Leber's optic neuropathy, Best's disease, optic nerve lesions, pappilitis, Stargardt's disease.

1.3. ANATOMICAL LANDMARKS IN EYE

CORNEA

1. Dimensions of cornea
 - Horizontal diameter – 11.75 mm
 - Vertical diameter – 11 mm
 - Posterior diameter – 11.5 mm
2. Endothelial cell count
 - At birth – 6000 cells/mm²
 - In young adults – 2400–3000 cells/mm²
 - Corneal decompensation – cell count less than 500/mm²
3. Thickness of cornea
 - Centre – about 0.52 mm
 - Periphery – about 0.67 mm
4. Refractive index of cornea – 1.37
5. Surgical limbus – 2 mm wide
 - Anterior limbal border – overlies termination of Bowman's membrane.
 - Mid limbal line – overlies termination of Schwalbe's line.
 - Posterior limbal border – overlies sclera spur
 - Preferred site for incision – mid limbal incision.

SCLERA

1. Forms posterior five-sixth of eye ball.
2. Thickness
 - Posteriorly – thickest 1 mm
 - Thinnest at insertion of extraocular muscles – 0.3 mm
3. Vortex vein – passes through middle apertures 4–7 mm posterior to equator.

UVEA

1. Average diameter of iris – 12 mm
2. Average thickness – 0.5 mm
3. Thinnest part of iris – at the root
4. Pupil diameter – 3-4 mm
5. Pars plicata – 2 to 2.5 mm wide.
6. Pars plana – 5 mm wide temporally and 3 mm wide nasally
7. Ciliary processes 70–80 in number
8. Short posterior ciliary arteries – from ophthalmic artery, 10–20 branches
9. Long posterior ciliary arteries – 2 in number
10. Anterior ciliary arteries – 7 in number

AQUEOUS HUMOR

1. Ciliary body – site of aqueous production.
2. Posterior chamber – 0.06 ml of aqueous.
3. Anterior chamber – 0.25 ml of aqueous
4. Depth of anterior chamber – 3 mm in the center.

LENS

1. Diameter of lens
 - 6.5 mm at birth
 - 9–10 mm in second decade
2. Thickness of lens
 - 3.5 mm at birth
 - 5 mm at extreme age
3. Weight of lens – 135–255 mg
4. Refractive index – 1.39
5. Lens capsule thicker anteriorly than posteriorly.

VITREOUS HUMOR

1. Weight – 4 g
2. Volume – 4 cc, 99% water
3. Anterior hyloid membrane starts from approximately 1.5 mm from ora serrata.
4. Vitreous base – 4 mm wide, 1.5 to 2 mm area of pars plana anteriorly and 2 mm of adjoining peripheral retina posterior to ora serrata.

RETINA

1. Retinal surface area – 266 mm²
2. Macula lutea – 5.5 mm in diameter
3. Fovea centralis
 - 1.85 mm in diameter
 - 5 degree of visual field
4. Foveola
 - 0.35 mm in diameter
 - Situated 3 mm from temporal edge of optic disk to 1 mm below horizontal meridian
5. Parafoveal area – 0.5 mm in diameter.
6. Perifoveal area – 1.5 mm in diameter.
7. Ora serrata – 2.1 mm wide temporally and 0.7–0.8 mm wide nasally.
8. Number of rods about – 120 million
9. Number of cones – 6.5 million
10. Highest density of cones at fovea – 199000 cones/mm²
11. Each rod – 40–60 μm long.
12. Each cone – 40–80 μm long.
13. Foveal avascular zone – 500 μm in diameter.
14. Optic disk – 1.5 mm in diameter
15. Length of optic nerve – 47–50 mm
 - Intraocular – 1 mm
 - Intraorbital – 30 mm
 - Intracanalicular – 6–9 mm
 - Intracranial – 10 mm

EXTRAOCULAR MUSCLES

1. Six extraocular muscles—4 recti and 2 oblique.
2. Origin of recti – common tendinous ring (from the limbus) attached at the apex of orbit.
3. Insertion of recti:
 - Medial rectus—5.5 mm
 - Inferior rectus—6.5 mm
 - Lateral rectus—6.9 mm
 - Superior rectus—7.7 mm
4. Superior oblique muscle – longest and thinnest of all extraocular muscles.
 - 59.5 mm long
 - Arises from body of sphenoid
 - Inserted on to the upper and outer part of sclera behind the equator.
5. Inferior oblique muscle—shortest of eye muscles.
 - 37 mm long
 - Arises from orbital plate of maxilla
 - Inserted in the lower and outer part of sclera behind the equator.

LACRIMAL APPARATUS

1. Lacrimal gland situated in lacrimal fossa formed by orbital plate of frontal bone.
2. Lateral horn of levator muscle aponeurosis divides the gland in two parts.
3. Upper and lower lacrimal puncta lie about 6 mm and 6.5 mm lateral canthus, respectively.
4. Canaliculi
 - 0.5 mm in diameter
 - 10 mm in length, vertical 2 mm and horizontal 8 mm
5. Lacrimal sac lies in lacrimal fossa formed by lacrimal bone and frontal process of maxilla.
6. Lacrimal sac is 15 mm in length and 5–6 mm in breadth.
7. Volume of sac – 20 cmm.
8. Nasolacrimal duct opens in - inferior meatus of nose
 - 18 mm in length (12–24 mm)
 - Intaosseus part 12.5 mm and intrameatal part 5.5 mm
 - 3 mm in diameter

EYELIDS

1. Upper eyelid – covers one sixth of cornea.
2. Lower eyelid – just touches the cornea.
3. Palpaberal fissure – horizontally 28–30 mm and vertically 9–11 mm.
4. Levator palpebrae superioris –
 - Origin from lesser wing of sphenoid above annulus of Zinn.
 - Inserts on to septa between orbicularis muscle, pretarsal skin of eyelid, anterior surface of tarsus.

5. Length of LPS – Fleshy part 40 mm long.
– Tendinous aponeurosis 15 mm long.
6. Tarsal plates – 29 mm long, 1 mm thick

ORBIT

1. Lateral wall of each orbit lies at an angle of 45° to the medial wall.
2. Lateral wall of two orbits are 90° to each other.
3. Depth of orbit—42 mm along medial wall, 50 mm along lateral wall.
4. Base of orbit—40 mm in width, 35 mm in height.
5. Volume of orbit—29 ml
6. Ratio between volume of orbit and eyeball is 4.5:1
7. Optic canal—length 6–11 mm, lateral wall shortest and medial wall longest.

1.4. PHARMACOLOGY

ANTI-INFECTIVES DOSAGE

ANTIBIOTICS

TOPICAL

Cefazolin	- 5%
Ceftriaxone	- 10%
Penicillin	- 1,00,000 units/ml
Ticarcillin	- 0.6%
Ciprofloxacin	- 0.3%
Ofloxacin	- 0.3%
Moxifloxacin	- 0.5%
Gatifloxacin	- 0.3%
Polymyxin B	- 50,000 units/ml
Vancomycin	- 2.5–5%
Tobramycin	- 1–1.4%
Gentamicin	- 0.3–1.4%
Amikacin	- 1–2.5%
Chloramphenicol	- 0.5%

FORTIFIED TOPICAL

Cefazolin	- 50 mg/ml or 133 mg/ml
Ceftriaxone	- 50 mg/ml
Cefamandole	- 50 mg/ml
Penicillin	- 1,00,000 units/ml
Methicillin	- 50 mg/ml
Ampicillin	- 50 mg/ml
Moxalactam	- 50 mg/ml
Carbenicillin	- 4 mg/ml
Ticarcillin	- 6 mg/ml
Bacitracin	- 10,000 units/ml
Polymyxin	- 50,000 units/ml
Vancomycin	- 50 mg/ml or 25 mg/ml
Gentamicin	- 14 mg/ml or 20 mg/ml
Tobramycin	- 14 mg/ml
Amikacin	- 10 mg/ml
Chloramphenicol	- 5 mg/ml

SUBCONJUNCTIVAL

Cefazolin	- 100 mg
Ceftriaxone	- 100 mg
Penicillin	- 0.5 million units
Polymyxin B	- 10–25 mg
Vancomycin	- 25 mg
Tobramycin	- 20–40 mg

Gentamicin	- 20–40 mg
Amikacin	- 25–50 mg
Chloramphenicol	- 100 mg

INTRAVITREAL

Cefazolin	- 2.25 mg/0.1ml
Ceftriaxone	- 3 mg
Penicillin	- 1000–5000/unit
Ciprofloxacin	- 0.1 mg
Ofloxacin	- 0.1 mg
Vancomycin	- 1 mg/0.1 ml
Tobramycin	- 0.2 mg/0.1 ml
Gentamicin	- 0.1 mg/0.1 ml
Amikacin	- 0.2–0.4 mg/0.08 ml

INTRAVITREAL INJECTION**VANCOMYCIN (1 mg in 0.1 ml)**

- 500 mg powder – Add 10 ml of Ringer lactate (RL) →50 mg/ml
- 2 ml of above – add 8 ml of RL →10 mg/ml
- Take 0.1 ml of above for injection →1 mg in 0.1 ml

CEFAZOLIN (2.25 mg in 0.1 ml)

- 500 mg powder – Add 10 ml of RL →50 mg/ml
- 1 ml of above and add 1.2 ml of RL →22.7 mg/ml
- Take 0.1 ml of above 2.27 mg

CEFTAZIDIME (2.25 mg in 0.1 ml)

- 500 mg powder – Add 10 ml of RL →50 mg/ml
- Take 1 ml of above and add 1.2 ml of RL →22.7 mg/ml
- Take 0.1 ml of above →22.7 mg

AMIKACIN (0.4 mg in 0.1 ml)

- use 100 mg vials Take 0.8 ml of drug (40 mg)
- add 9.2 ml of RL (40 mg in 10 ml)
- Take 0.1 ml 0.4 mg in 0.1 ml

AMPHOTERICIN B (0.005–0.01 mg)

- 50 mg vial Add 10 ml of water (5 mg/ml)
- take 1 ml of above Add 10 ml of water (0.5 mg/ml)
- take 1 ml of above Add 10 ml of water (0.1 mg/ml)
- Inject 0.1 ml of above (0.01 mg/ml)

ANTIFUNGAL

Amphotericin B	- 1–10 mg/ml drops, 2.5% ointment
Natamycin	- 5% suspension
Miconazole	- 1% drops, 2% ointment
Ketoconazole	- 1.5%
Fluconazole	- 0.2–2%
Flucytosine	- 1%

ANTIVIRAL

5-iodo-2-deoxyuridine	- 0.1% drops, 0.5% ointment
Trifluorothymidine	- 1% drops
Adenine arabinoside	- 3% E/o
Acyclovir	- 3% E/o

ANTI-INFLAMMATORY DRUGS**I. Nonsteroidal anti-inflammatory drugs****A. Topical**

	Generic name	Concentration (%)	Normal dosage
1.	Ketorolac tromethamine	0.5%	qid
2.	Flurbiprofen	0.03%	tid to qid
3.	Diclofenac sodium	0.1%	qid
4.	Indomethacin	1%	4 to 6 times/day
5.	Suprofen	1%	qid

B. Systemic

1.	Aspirin	300–600 mg	bd,tds,qid
2.	Acetaminophen	325 mg, 500 mg	bd,tds,qid
3.	Phenylbutazone	100 mg	tds to qid
4.	Oxyphenbutazone	100 mg	tds to qid
5.	Indomethacin	50 mg	tds
6.	Diclofenac sodium	25 mg, 50 mg	bd,tds,qid
7.	Ibuprofen	300–800 mg	tds,qid
8.	Ketoprofen	25 mg, 50 mg, 75 mg	tds,qid
9.	Flurbiprofen	500 mg	bd,tds
10.	Naproxen	250 mg, 500 mg	bd,tds,qid
11.	Etodolac	200 mg, 300 mg	bd,tds,qid
12.	Ketorolac tromethamine	10 mg	qid

II. Corticosteroids**A. Topical**

	Generic name	Concentration (%)
1.	Prednisolone acetate suspension	1%
2.	Prednisolone sodium phosphate solution	1%
3.	Fluorometholone suspension & ointment	0.1%

Contd...

Contd...

	Generic name	Concentration (%)
4.	Dexamethasone phosphate solution	0.1%
5.	Dexamethasone phosphate ointment	0.05%
6.	Hydrocortisone acetate suspension	0.5%
7.	Hydrocortisone acetate solution	0.2%
8.	Hydrocortisone acetate ointment	1.5%
9.	Betamethasone sodium phosphate solution	0.1%
10.	Betamethasone sodium phosphate ointment	0.1%
11.	Loteprednol etabonate	0.5% or 0.2%
12.	Rimexalone	1%
13.	Medrysone	1%

B. Periocular

1.	Methylprednisolone acetate (Depo-Medrol)	Depot preparation
2.	Triamcinolone acetonide (Kenalog)	Depot preparation
3.	Triamcinolone diacetate (Aristocort)	Depot preparation
4.	Hydrocortisone sodium succinate (Solu-cortef)	Solution
5.	Betamethasone (Celestone)	Solution

C. Intraocular

1.	Triamcinolone acetonide	4 mg in 0.1 ml
2.	Flucinolone acetonide	Slow release implants
3.	Dexamethasone	Slow release implants

D. Systemic

i. Oral

1.	Prednisolone (5 or 25 mg tablet)	1–2 mg/kg/day
----	----------------------------------	---------------

ii. Intravenous

1.	Prednisolone	1–1.5 mg/kg/day
2.	Triamcinolone	
3.	Dexamethasone	200 mg/day
4.	Methylprednisolone	250–1000 mg in 100 ml Normal saline for 3 days

III. Immunomodulators

A. Antimetabolites

1.	Methotrexate	7.5–25 µg/week
2.	Azathioprine	100–250 mg/day
3.	Mycophenolate mofetil	1–3 g/day

B. Inhibitors of T-cell lymphocytes:

i. Oral

1.	Cyclosporine	2.5–5 mg/kg/day
2.	Tacrolimus	0.1–0.2 mg/kg/day

ii. Intravenous

1.	Sirolimus	Loading dose 6 mg/day, Maintenance dose 4 mg/day
----	-----------	---

C. Alkylating agents

1.	Cyclophosphamide	1–2 mg/day
2.	Chlorambucil	2–12 mg/day

ANTI GLAUCOMA MEDICATIONS

I. Cholinergic drugs

A. Parasympathomimetics

	Generic name	Concentration (%)	Normal dosage
1.	Pilocarpine	2%	od to qid
2.	Carbachol	0.75%, 1.5%, 2.25%, 3%	up to tid

B. Anticholinesterases

	Generic name	Concentration (%)	Normal dosage
1.	Echothiophate iodide	0.03%, 0.06%, 0.125%, 0.25%	od to bd
2.	Physostigmine	0.25%	od to tid
3.	Demecarium	0.125%, 0.25%	bd

II. Adrenergic agents

A. Sympathomimetics

i. Nonselective

	Generic name	Concentration (%)	Normal dosage
1.	Epinephrine	0.25%, 0.5%, 1%, 2%	od to bd
2.	Dipivefrin	0.1%	bd

ii. Selective (alpha 2 agonists)

	Generic Name	Concentration (%)	Normal dosage
1.	Brimonidine	0.2%	bd
2.	Apraclonidine	1%	od

B. Beta-blockers

i. Nonselective

	Generic name	Concentration (%)	Normal dosage
1.	Timolol	0.5%	bd
2.	Carteolol	1%, 2%	bd
3.	Levobunolol	0.5%	od
4.	Metipranolol	0.1%, 0.3%	bd

ii. Selective

	Generic Name	Concentration (%)	Normal dosage
1.	Betaxolol	0.5%	bd

iii. Prostaglandin analogs

	Generic name	Concentration (%)	Normal dosage
1.	Latanoprost	0.005%	od
2.	Travoprost	0.004%	od
3.	Bimatoprost	0.03%	od
4.	Tafluprost	0.0015%	od
5.	Unoprostone	0.12%	od

iv. Carbonic anhydrase inhibitors

A. Topical

	Generic name	Concentration (%)	Normal dosage
1.	Dorzolamide	2%	bd or tid
2.	Brinzolamide	1%	bd or tid

B. Systemic

Generic name	Concentration (%)	Normal dosage
1. Acetazolamide	250 mg	bd to qid (available as tablet, sustained release capsule and powder for injection)
2. Dichlorphenamide	50 mg	bd to tid
3. Methazolamide	50 mg	bd to tid

v. Hyperosmotic agents**A. Oral:**

Generic name	Concentration (%)	Normal dosage
1. Glycerol	50%	2 ml/kg body wt
2. Isosorbide	45%	2 ml/kg body wt

B. Intravenous:

Generic name	Concentration (%)	Normal dosage
1. Mannitol	20%	5 ml/kg body wt over 30–60 min
2. Urea	45%	

vi. Neuroprotectors (Experimental)**A. NMDA receptor antagonists:**

1. Memantine

B. Nitric oxide synthase inhibitors:

1. Aminoguanidine

C. Beta 2 adrenergic agonists:

1. Brimonidine

D. Calcium channel blocker:

1. Nimodipine

E. Neurotrophic factors:

1. Neurotrophin 3

F. Apoptosis inhibitors:

1. Cytochrome C release inhibitors
2. Caspase inhibitors

G. Reactive oxygen species scavenger:

NEWER OCULAR HYPOTENSIVE AGENTS: (The dosages of these drugs have not been given since it is currently experimental in nature)

I. Natural Products**A. Cannabinoids**

- i. Topical CB1 agonists
- ii. WIN 55212-2

II. Activators of extracellular matrix hydrolysis

- A. Matrix metalloproteinases
- B. Inducers of matrix metalloproteinases
 - i. Tert-butylhydroquinone
- C. Activator of glycosaminoglycan degradation compounds
 - i. AL-3037A (Sodium ferri ethylenediamine tetra-acetate)

III. Protein kinase inhibitors

- A. Broad spectrum kinase inhibitors
 - i. H-7
- B. Inhibitors of protein kinase C
 - i. GF109203X
- C. Rho-associated coiled coil-forming kinase (ROCK) inhibitors
 - i. Y-27632
 - ii. H-1152

IV. Cytoskeleton modulator

- i. Ethacrynic acid
- ii. Latrunculin B
- iii. Swinholide A

V. Compounds that increase cyclic GMP

- A. Cyclic GMP analogs
- B. Nitric oxide donors
 - i. Nitroglycerin
 - ii. Isosorbide dinitrate
 - iii. Sodium nitrite
 - iv. Hydralazine
 - v. Minoxidil
 - vi. Sodium nitroprusside
- C. Natriuretic peptides
 - i. Atrial natriuretic peptide (ANP)
 - ii. Brain-derived natriuretic peptide (BNP)
 - ii. C-type natriuretic peptide (CNP)
- D. Compounds that increase natriuretic peptides
 - i. Candoxatril.

1.5. SLIT LAMP BIOMICROSCOPE

1. Who discovered the slit lamp?

On August 3, 1911, Alvar Gullstrand presented the first rudimentary model of slit lamp and explained its optics and refraction.

2. Who coined the term slit lamp biomicroscopy? Why is it called so?

The term biomicroscopy was coined by Mawas in 1925. We call the instrument slit lamp biomicroscope as they identify two basic components:

Slit lamp—focal narrow beam of light

Microscope—for stereoscopic magnified observation

Biomicroscopy—as it is helpful in examination of living eye

3. List the various steps for carrying out the slit lamp examination?

- i. Examination should be carried out in a semi-dark room so that the examiner's eyes are partially dark adapted.
- ii. Both the patient and the examiner must be seated in comfortable adjustable chairs.
- iii. Slit lamp table – must be stable and flat so that the slit lamp does not slide during the examination and the table should be mounted on a swinging arm or rolling table so that it is adjustable in height.
- iv. Adjust the patients chair high enough so that the patient naturally leans forward with the chin and forehead pressed firmly against the chinrest and headrest without stretching.
- v. With the patients' forehead and chin firmly in place the height of the chinrest can be raised or lowered by means of a nearby knob. In this way the patients' eye is brought level with the black demarcation line on one of the supporting rods of the patient positioning frame just below the level of forehead strap.
- vi. Adjust the settings on the slit lamp so that the patient is not initially subjected to uncomfortably bright light when the instrument is turned on. This can be accomplished by setting the instrument to provide a very narrow beam of light or by diminishing the light source if it is to provide diffuse illumination.
- vii. Oculars of the slit lamp are to be adjusted for the examiners interpupillary distance.

4. What are the basic principles of slit lamp illumination?

There are 3 specific principles of slit lamp illumination—

- i. Focal illumination
- ii. Oblique illumination
- iii. Optical section.

5. Describe the principles.

- i. Focal illumination—Achieved by narrowing the slit beam horizontally or vertically. It permits isolation of specific areas of cornea for observation without extraneous light outside area of examination.
- ii. Oblique illumination—Light beam is projected from an oblique angle. It is useful for detecting and examining findings in different layers of the cornea.
- iii. Optical section—This is the most important and unique feature of slit lamp achieved by making a narrow slit beam. Uses include determining depth or elevation of a defect in cornea, conjunctiva or locating the depth of opacity within the lens, etc.

6. What are the types of illumination used for examination?

The different illumination in the sequence in which they are used are:

- i. Diffuse illumination
- ii. Sclerotic scatter
- iii. Direct focal illumination
- iv. Broad tangential illumination
- v. Proximal (indirect) illumination
- vi. Retroillumination from the iris
 - a. direct
 - b. indirect
- vii. Retroillumination from the fundus
- viii. Specular reflection.

7. What is meant by diffuse illumination?

Diffuse illumination—also known as wide beam illumination.

- Principle—a wide un narrowed beam of light is directed at the cornea from an angle of approximately 15–45°
- Settings—Microscope is positioned directly in front of the eye and focused on the anterior surface of the cornea
 - Magnification used is low to medium
 - Illumination is kept at medium to high

USES

- i. Gross inspection of any corneal scar, irregularities of lid, tear debris, etc. —mainly for obtaining an overview of ocular surface tissues (e.g. Bulbar and palpebral conjunctiva)
- ii. It can be used with cobalt blue or red free filters.

Cobalt blue—introduction of cobalt filter without fluorescein will cause corneal iron rings to appear black, so is useful in detecting subtle fleischner's ring in early keratoconus. The cobalt blue filter produces blue light in which the fluorescent dye fluoresces with yellow green color used for evaluating fluorescein staining of ocular surface tissues or the tear film or during Goldmann applanation tonometry.

Red free filter—produces light-green light for evaluation of rose Bengal Staining. Also used to evaluate nerve fiber layer.

8. What is sclerotic scatter?

Principle: The optical principle is based on fiberoptics—the total internal reflection of light

- i. The slit beam is directed at the limbus. The opaque sclera scatters the light and some of the light is directed into the stroma where it travels through the entire cornea by repeatedly reflecting from its anterior and posterior surfaces.
- ii. In normal cornea—it creates a glowing limbal halo but no stromal opacity is visible.
- iii. When opacity is present—the internally reflected light is scattered back to the observer outlining the pattern as in Reis-Bucklers dystrophy.
Settings—slit lamp is about 15° from the microscope.
Slit beam is decentered if full view of cornea is desired.
Slit height is set at full and slit width at medium broad.

9. What is direct focal illumination?

It is of 2 types—

- A. Direct focal illumination with broad beam
- B. Direct focal slit illumination with narrow beam

A. Direct focal illumination with broad beam

- Principle—Slit lamp light is focused directly on an area of interest. Wider the slit beam, less information is presented to the examiner.
- Settings
Slit beam is approximately 30° from microscope.
Slit height is full and slit width is medium broad.

Uses: Crumb like deposits of granular stromal corneal dystrophy, stand out in direct focal illumination as they are white, reflect light, have sharp margins and are embedded in clear cornea.

B. Direct focal slit illumination with a narrow beam

- i. **Principle:** Slit lamp is placed obliquely and the slit beam is narrowed. The focused slit creates an optical cross-section of the cornea allowing the examiner to localize the level of opacities within the cornea and to determine corneal thickness.
- ii. **Settings:** Slit lamp is positioned 30–45° from microscope
Slit height is full and slit width is narrow.
- iii. **Movement:** Moving the narrow slit systematically across the cornea allows to view serial optical sections and to construct a mental picture of corneal pathology.
- iv. **Uses:** Moderately thin slit is used to identify the pigmentation of Krukenberg's spindle on the posterior surface of cornea.

The narrow slit beam localizes

- i. The net like opacity in Reis-Buckler's dystrophy to subepithelial area.
- ii. Extreme thinning in area of descemetocoele in cases of herpes simplex keratitis.
- iii. Focal central thinning of cornea in cases of post keratitis scarring, and keratoconus.

10. What is broad tangential illumination?

- i. Principle: The examiner focuses the microscope on an area of interest and swings the slit beam far to the side at an extremely oblique angle so that the light sweeps tangentially across the surface of cornea. This enhances surface details by shadowing.
- ii. Settings:
 - Slit beam is 60–90° from microscope
 - Slit height is narrow to one half and slit width is very broad.

Uses –

- Highlights irregularities on anterior corneal surface
 - i. Corneal intraepithelial neoplasia
 - ii. Sterile stromal ulcers
 - iii. Calcific band keratopathy with holes
 - iv. Diffuse punctate epithelial keratopathy
- Highlights irregularities on posterior corneal surface, e.g. folds in Descemet's membrane.

11. What is proximal (indirect) illumination?

It combines features of both sclerotic scatter and retroillumination

- Principle—A moderately wide slit beam is decentered and placed adjacent to an area of interest. Light travels through corneal stroma by internal reflection as it does in sclerotic scatter and accentuates the pattern of opacity.
- Settings—Slit lamp is about 15° from microscope
Slit height is full and slit width is moderate
- Uses—Highlights the internal structures of corneal opacity
Enables the identification of details within the opacity, e.g. small foreign body within an area of corneal inflammation
Also useful for observing iris sphincter.

12. What is retroillumination of iris? Give its uses.

Retroillumination of the iris can be of two types—

- i. Direct
- ii. Indirect

Direct retroillumination of the iris

- Principle—The slit beam reflects from the surface of the iris and illuminates the cornea from behind and accentuates the refractive properties of corneal pathology.
It allows detection of abnormalities not apparent in direct illumination. For example, epithelial basement membrane fingerprint lines
- Settings— Slit lamp is separated by 15–30° from microscope
Slit height is reduced and slit width is medium.

Indirect retroillumination of the iris

- Principle: The slit beam is decentered so that it hits the iris near the pupil adjacent to the area of interest in the cornea.
Microscope is adjusted so that the area of interest is viewed at the edge of the path of light reflected from iris (marginal retroillumination) or against the adjacent black pupil (indirect retroillumination).
- Settings
The beam can be decentered to allow viewing of object of interest over dark edge of pupil.
Slit height is reduced to eliminate background scatter and slit width is narrow to medium.

13. What is retroillumination from fundus?

- Principle: Slit beam is placed nearly co-axial with microscope and rotated slightly off axis so that it shines in through margin of pupil. This allows the red light reflected from the ocular fundus to pass through cornea to microscope.
- Settings
Slit lamp is aligned co-axial with microscope, then decentred to edge of pupil.
Slit height is reduced to one-third to avoid striking the iris
Slit width is medium and curved at one edge to fit in the pupil
- **USES**—The following abnormalities are seen:
 - i. Lattice dystrophy
 - ii. Pseudoexfoliation
 - iii. Keratic precipitates
 - iv. Corneal scars
 - v. Meesmann's dystrophy
 - vi. Map-dot fingerprint dystrophy
 - vii. Lens vacuoles
 - viii. Cataract
 - ix. Corneal rejection lines.

14. What is specular reflection?

- Principle: It is based on Snell's law. When angle of incidence of slit beam equals the angle of observation of microscope, the reflected light from epithelial and endothelial surfaces are viewed.
- Settings
Beam height is full and beam width is narrow
Microscope and slit beam are 45–60° apart
- Movement
Place the slit beam adjacent to reflection of slit lamp filament from surface of cornea (corneal light reflex).
Slit beam is moved laterally until it overlaps corneal light reflection.
Beam is moved further laterally to edge of corneal light reflection and focus on posterior corneal surface to visualize the paving stone like mosaic of endothelial cells.

15. What specialized examinations can be carried out with the help of slit lamp?

Diagnostic examinations:

- i. Gonioscopy
- ii. Fundus examination with focal illumination
- iii. Pachymetry
- iv. Applanation tonometry
- v. Ophthalmodynamometry
- vi. Slit lamp photography
- vii. Laser interferometry
- viii. Potential acuity meter test.

Therapeutic uses:

- i. Contact lens fitting.
- ii. Yag capsulotomy
- iii. Delivery system for argon, diode and YAG laser as for retinal lasers, peripheral iridotomy, ALT, synechiolysis, suturolysis.
- iv. Corneal and conjunctival foreign body removal.
- v. Corneal scrapings.
- vi. Intraoperative slit lamp illumination:

There is less risk of phototoxicity because a slit light at 5° , focused on the macula, provides a fixed illumination of 7000 lm, the same as with an intraocular fiber placed at 17 mm from the macula.

16. Describe optics of slit lamp.

Composed of two optical elements:

- Objective
- Eyepiece

Objective lens consists of two planoconvex lenses. With their convexities put together providing a composite power of +22D. Eyepiece has a lens of +10D.

For good stereopsis tubes are converged at an angle of 10° to 15°

Microscope uses a pair of prisms between objective and eye piece to re-invert the inverted image produced by compound microscope.

Most slit lamps provides a range of accommodation from X6 to X40.

Modern slit lamps use one of the following three systems to produce a range of magnification:

- i. Czapskiskope with rotating objectives:
 - a. Oldest and most frequently used.
 - b. Different objectives are placed on a turret type of arrangement that allows them to be fairly rapidly changed during examination.
 - c. Haag-Streit model, Bausch and Lomb, Thorpe model.
- ii. Littmann-Galilean telescope principle:
 - a. Developed by Littmann.

- b. Sits between objective and eyepiece lenses and does not require either of them to change.
- c. Provide range of magnification typically 5.
- d. It is called Galilean system because it utilizes Galilean telescopes to alter magnification.
- e. Two optical components are positive and negative lens
- f. Zeiss, Rodenstock, American optical slit lamp
- iii. Zoom system
 - a. Allows continuously variable degree of magnification.
 - b. Nikon slit lamp contains zoom system within objective of microscope and offers a range of magnification from X7 to X35.

17. How to evaluate tear film with evaluation with the help of slit lamp?

Examination of inferior marginal tear strip can yield information about volume of tears. The tear strip is a line just above lower lid. It is normally 0.5 mm in width and has a concave upper aspect. When thin or discontinuous, it is an evidence of deficient aqueous tear volume. The following are the parameters

- i. Beam angle 60°
- ii. Beam height maximum
- iii. Beam width parallel piped
- iv. Filter none
- v. Illumination low or ambient lighting only
- vi. Magnification 10–16X
- vii. Another feature seen in dry eye is increased debris in tear film. Bits of mucus, sloughed epithelial cells—suggestive of delayed tear clearance.
- viii. Alteration in morphology of conjunctiva—conjunctivochalasis.
- ix. Pathologic signs of Meibomian gland disease—ductal orifice pout or metaplasia (white shafts of keratin in orifices), reduced expressibility, increased turbidity and viscosity of secretions.

18. How to measure lesions with slit lamp?

- i. Brightness—lowest intensity setting
- ii. Slit lamp beam—slightly thicker than optical section
- iii. Illuminating arm directly in front of viewing arm.
- iv. Focus vertically oriented beam on the lesion to be measured.
- v. Vary height of beam till it equals height of lesion. Read the scale.
- vi. Rotate the bulb housing 90° to orient the beam horizontally and repeat measurement by varying height of beam to measure horizontal dimensions of lesion.
- vii. The bulb housing may be rotated less than 90° to perform diagonal measurement.

1.6. DIRECT OPHTHALMOSCOPE

1. Who invented direct ophthalmoscope?

- Invented by Von Helmholtz in 1850.

2. Explain the procedure for examining with a direct ophthalmoscope.

- i. It is ideally performed in a dimly lit room.
- ii. Patient is asked to look straight ahead at a distant object.
- iii. Examiner should be on the side of the eye to be examined.
- iv. Patient's right eye to be examined by the examiners right eye and scope to be held in right hand and vice versa.
- v. Examiner should first examine at an arm's distance.
- vi. Once the red reflex is appreciated, the examiner should move close to the patient's eye and focus on the structures to be examined.

3. Explain the optics of direct ophthalmoscopy.

- Principle: In emmetropic patients, the issuing rays will be parallel and will be brought into focus on the retina of the observer.
Hence, light from the bulb is condensed by a lens and reflected off a two way mirror into patient's eye. The observer views the image of patient's illuminated retina by dialling in the required focusing lens.

4. At what distance is distant direct ophthalmoscopy performed?

- Performed at 2 feet (one arm's distance)

5. What are the applications of distant direct ophthalmoscopy?

- i. To diagnose the opacities in refractive media.
 - Exact location of the opacity can be determined by parallax displacement.
 - Opacities which move in direction of movement are anterior to pupillary plane and those behind will move in opposite direction.
- ii. To differentiate between a hole and a mole of iris Mole looks black but a red reflex is seen through hole in iris as in iridodialysis.
- iii. To recognise the detached retina or a tumor arising from fundus
- iv. Bruckners test: In children, refractive error can be assessed by dialing the lens, the power of which will help us focus on the retina clearly.

6. What are the different reflexes seen on distant direct ophthalmoscopy?

- i. Red reflex: normal
- ii. Grayish reflex: retinal detachment
- iii. Black reflex: vitreous hemorrhage
- iv. Oil droplet reflex: keratoconus
- v. White reflex (leukokoria):
 - Retinoblastoma

- Retinopathy of prematurity
- Congenital cataract
- Toxocariasis
- Persistent primary hyperplastic vitreous
- Retinal dysplasias
- Coats' disease
- Choroidal coloboma

7. What are the factors determining the field of vision in direct ophthalmoscopy?

- i. Directly proportional to the size of pupil
- ii. Directly proportional to the axial length of the observed eye/ refraction of the patient. Larger area with least magnification is seen in hyperopes and smaller area with maximum magnification is noted in myopes.
- iii. Inversely proportional to distance between observed and observers eye
- iv. Smaller the sight hole of the ophthalmoscope, the better the field of vision

8. What are the parts of direct ophthalmoscope?

- i. On/off rheostat
- ii. View aperture
- iii. Lens power indicator (Rekoss disk)
- iv. Pupil size—large/small
- v. Auxillary controls—red free filter, fixation target, slit beam, etc.

9. What is the therapeutic use of direct ophthalmoscope?

- For xenon laser delivery

10. How will you quantify disk edema using direct ophthalmoscope?

The direct ophthalmoscope is first focused on the surface of the disk. The dioptric power by which the disk focusing is clearly noted. Then the ophthalmoscope is used to clearly focus on the adjacent retina. The dioptric power for this manouver is then noted. The difference between the dioptric powers gives the amount of elevation of the disk, i.e. every addition of +3D equals to 1 mm elevation of disc (phakics) 2 mm elevation of disc (aphakics).

In emmetropic eye each diopter of change of focus is equivalent to an axial length of 0.4 mm or a difference in focusing of 3D indicates a difference in level of 1 mm whereas in aphakics, 3D indicates a difference in level of 2 mm.

11. What are the characteristics of the image formed?

- i. V—vertical
- ii. E—erect
- iii. M—magnified

12. What are the drawbacks of direct ophthalmoscope?

- i. Lack of stereopsis
- ii. Small field of view
- iii. No view of retinal periphery

13. What is the magnification of direct ophthalmoscope?

Magnification is 15X.

14. What are the advantages of direct ophthalmoscope?

- i. Safe
- ii. Portable
- iii. Screening tool
- iv. Easy technique

15. What are the uses of auxillaries in direct ophthalmoscopy?

- i. Full spot-viewing through a large pupil
- ii. Small spot-viewing through a small pupil
- iii. Red free filter-change in retinal nerve fiber layer (RNFL) thickness
- iv. Identifying microaneurysms and other vascular abnormalities
- v. Slit-evaluating retinal contour
- vi. Reticule/grid-measuring vessel caliber or small retina lesions
- vii. Fixation target-identifying central/eccentric fixation.

16. How do you find patient's point of preferred fixation?

- i. Reduce illumination intensity and dial in fixation target
- ii. Ask patient to look into the light in center of target
- iii. Determine whether the test mark falls on the central foveal reflex or at an eccentric location
- iv. Ask patient whether the fixed object is seen as straight ahead off or center.

17. List the differences between Direct (DO) and Indirect (IO) ophthalmoscopes.

	Points	DO	IO
1.	Stereopsis	Absent	Present
2.	Magnification	15X	3-5X
3.	Static field of view	2 disk diameter	8 disk diameter
4.	Dynamic field of view	Upto equator	Upto ora serrata
5.	Retinal image	Virtual, erect	Real, inverted
6.	Technique	Easy	Difficult
7.	Illumination	Good	Excellent
8.	Uses	Diagnostic mostly	Diagnostic and therapeutic, e.g. PRP, barrage

1.7. INDIRECT OPHTHALMOSCOPY

1. Who invented indirect ophthalmoscope (IO)?

Nagel in 1864.

2. What is the principle behind indirect ophthalmoscopy?

Works on the principle similar to astronomical telescope.

The principle is to make the eye highly myopic by placing a strong convex lens in front of the patient's eye.

The emergent rays from an area of the fundus is brought to focus in between the lens and observer's eye as a real inverted image.

3. What are the different types of condensing lens used in indirect ophthalmoscopy?

- i. Planoconvex lens
- ii. Biconvex lens
- iii. Aspheric lens

4. What are the advantages and disadvantages of different type of lens?

i. Planoconvex lens

Advantage: causes less reflex during examination.

Disadvantage: plane surface of the lens causes troublesome reflexes when held facing the observer, so convex side should face towards the observer.

ii. Biconvex lens—both surface has +10D

Advantage: either way it can be held

Disadvantage: reflexes are more as compared to planoconvex lens

iii. Aspheric lens—lenses of greater power (30D/40D)

Advantage:

- i. Helps to obtain less magnification and greater field
- ii. Minimize aberration
- iii. Can be used with small pupil and extremely
- iv. Complicated retinal topography

5. What are the different power of the lenses which could be used as condensing lenses?

The various lenses used are:

- i. 15D (magnifies x4: field about 40°)
It is used for examination of the posterior pole.
- ii. 20D (magnifies x3: field about 45°)
It is commonly used for general examination of the fundus.
- iii. 25D (magnifies x2.5: field is about 50°)
- iv. 30D (magnifies x2: field is 60°)

It has shorter working distance and is useful when examining patients with small pupil.

- v. 40D (magnifies x2: field is 60°)
It is used mainly to examine small children.

6. What is the power of accommodation during the examination?

- i. The working distance is approximately one-third of a meter. This setup enables emmetropic observer to use only 1D of their accommodation to view the image in the condensing lens.
- ii. Myopes can increase or decrease their plus power to suit their refraction.
- iii. Presbyopes will need the equivalent of an immediate range add or their addition for near.
- iv. Hypermetropes will need their distance correction.

7. Where is the image formed in IO?

It is formed between the condensing lens and the observer.

8. Compare between different condensing power.

Features	+14D	+20D	+30D
Distance from eye (inches)	3	2	1.5
Magnification	4–5x	3x	2x
Field	30	50	60
Stereopsis	Normal	$\frac{3}{4}$ normal	$\frac{1}{2}$ normal
Illumination	Low	Medium	Bright

9. What are the advantages of indirect ophthalmoscopy?

- i. Larger field of retina can be seen
- ii. Lesser distortion of the image of the retina
- iii. Easier to examine if patient's eye movements are present or patients with high spherical or refractive power
- iv. Easy visualization of retina anterior to equator
- v. It gives a three-dimensional stereoscopic view of the retina
- vi. Useful in hazy media because of its bright light and optical property.

10. What are the disadvantages of indirect ophthalmoscopy?

- i. Magnification in IO is 5 times using a +20D lens. This is very less when compared to DO which is 15 times.
- ii. Indirect ophthalmoscopy is difficult to perform with small pupil.
- iii. Uncomfortable for the patients due to intense light and scleral indentation.
- iv. The procedure is more cumbersome, requires extensive practice both in technique and interpretation of the image visualized.
- v. Reflex sneezing can occur due to exposure to bright light.

11. Discuss the relative position of the image formed in emmetropic, myopic and hypermetropic eyes.

- i. Emmetropia—the emergent rays are parallel and thus focused at the principal focus of the lens.
- ii. Hypermetropia—the emergent rays are divergent and are therefore focused farther away from the principal focus.
- ii. Myopia the emergent rays are convergent and are therefore focused near the lens.

12. What are the color coding for fundus drawing?

For example:

- | | | |
|---------------------------|---|---------------------------------|
| i. Optic disk | — | red |
| ii. Arteries | — | red |
| iii. Veins | — | blue |
| iv. Attached retina | — | red hatching outlined in blue |
| v. Detached retina | — | blue |
| vi. Retinal tear | — | red with blue outline |
| vii. Lattice degeneration | — | blue hatchings outlined in blue |
| viii. Retinal pigment | — | black |
| ix. Retinal exudates | — | yellow |
| x. Choroidal lesions | — | brown |
| xi. Vitreous opacities | — | green |
| xii. Drusen | — | black |
| xiii. Nevus | — | black |
| xiv. Microaneurysms | — | red |

13. How to perform indirect ophthalmoscopy?

- i. Explain the procedure to the patient
- ii. Reassure him/her of the brightness of the light
- iii. The patient should be lying flat on a stretcher without flexion or extension of the neck in a dark room
- iv. The examiner throws light into patients dilated eye from an arms distance
- v. Binocular ophthalmoscope with a head band or that mounted on a spectacle frame is employed
- vi. Keeping eyes on the reflex, the examiner then interposes the condensing lens in path of the beam of light close to the patient's eyes and then slowly moves the lens away from the eye until image of the retina is clearly seen.
- vii. Use patients own hand/finger as target. Patients with sight will then use visual stimuli from his hand for fixation in addition to proprioceptive impulse. This is important in case of blind, monocular or uncooperative patients.
- viii. The examiner moves around the head of the patient to examine different quadrants of the fundus.
- ix. He has to stand opposite to the clock hour position to be examined. For example, to examine inferior quadrant (6 o'clock), the examiner should stand towards patient's head (12 o'clock).

- x. The whole peripheral retina upto the ora serrata can be examined by asking the patient to look in extremes of gaze and using a scleral indenter.

14. How to use scleral indenter?

- i. It consists of a small curved shaft with a flattened knob like tip mounted on a thimble.
- ii. It can be held between the thumb and the index finger or it can be placed upon the index or middle finger.
- iii. The examiner should move the scleral depressor in a direction opposite to that in which he wishes the depression to appear.
- iv. Should be rolled gently and longitudinally over the eye surface.

15. What is role of scleral indentation in examination of fundus?

- Make visible the part of the fundus which lies anterior to the equator.
- Making prominent the just or barely perceptible lesions of peripheral retina.

16. What are the factors affecting the field of view?

- i. Patient's pupil size
- ii. Power of the condensing lens
- iii. Size of condensing lens
- iv. Refractive error
- v. Distance of the condensing lens held from the patient's eye.

17. How to calculate the magnification of image?

$$\text{Simple magnification} = \frac{\text{Power of the eye}}{\text{Power of condensing lens}}$$

If power of the eye = 60D

If condensing lens power is = 20D

Then magnification = 60/20 = 3 times.

1.8. X-RAYS IN OPHTHALMOLOGY

1. What is the advantage of X-ray skull in ophthalmology?

The advantages of plain X-ray skull when compared to other investigations like CT scan are:

- a. Low cost
- b. Easy availability and usage
- c. Preliminary test to detect gross abnormality.

2. What are the important structures in X-ray skull to be looked for in ophthalmology?

Most important structure to be looked for is the base of the skull. In this the pituitary fossa is the most important structure. Other landmarks are the

- Anterior clinoid process
- Planum sphenoidale
- Chiasmatic sulcus
- Tuberculum sellae
- Floor of the pituitary fossa
- Dorsum sellae and
- Posterior clinoids.

Occasionally the pituitary fossa is deep and extends more in the vertical direction than in the antero-posterior direction and this has been termed the J-shaped sella and has no pathological significance.

3. When do normal vascular markings of the skull become prominent?

Arterial markings in the skull are usually visible as thin wavy lines and may become marked when the external carotid branches supply a vascular lesion like a meningioma or an arteriovenous malformation.

4. What are the abnormalities to be looked for in plain X-ray skull?

- i. Fracture
- ii. Bone erosion: *Local*, e.g. pituitary fossa; *generalized*, e.g. Paget's disease
- iii. Abnormal calcification: Tumors, e.g. meningioma, craniopharyngioma, and aneurysm
- iv. Midline shift: If pineal gland is calcified
- v. Signs of raised intracranial pressure: Erosion of posterior clinoids.

5. What are the causes of normal calcification in the X-ray skull?

A. Structures in the midline that produce calcification are:

- Pineal body
- Falx cerebri
- The pacchionian granules, and
- The labenular commissure.

- B. The normal structures away from midline that produce calcification are:
- Choroid plexus,
 - Petroclinoid ligament,
 - The lateral edge of diaphragma sellae and
 - The carotid artery.

6. What are the abnormal calcifications seen on X-ray skull?

Abnormal calcifications seen are:

- i. Tuberculomas may show calcification in 6 to 7% cases.
- ii. The shape and size of the calcification may be diagnostic as in the case of double line wavy (rail road calcification) in Sturge-Weber syndrome.
- iii. To position and shape as in the case of suprasellar area or speckled calcification (egg shell) seen in craniopharyngioma.
- iv. Meningioma
- v. Retinoblastoma
- vi. Pituitary adenoma
- vii. Mucocele
- viii. Phlebolith
- ix. Other lesions are—tuberous sclerosis, toxoplasmosis, oligodendroglioma, aneurysmal sac, subdural hematoma, dermoid, cysticercosis, etc.

7. What are the signs of raised intracranial tension (ICT) in children?

- i. There is increased separation of the sutures
- ii. Increased convolutional markings
- iii. Thinning of the bone
- iv. Silver beaten appearance—due to pressure of sulci and gyri

Sutures beyond 2 mm is suspicious of raised ICT and sometimes this may be seen even in young adults upto 20 years. Conversely premature fusion of the sutures is seen in craniosynostosis.

8. What are the signs of raised intracranial tension (ICT) in adults?

In adults, there is full ossification of the skull bones and the sutures are possibly or fully closed and so sutural separation does not occur. Similarly abnormal convolution markings are also not seen.

The changes that occur in the sella turcica, constitute the most important signs in raised ICT.

- a. In the earliest phase there is demineralization of the cortical bone leading to loss of the normal 'lamina dura' (white line of the sellar floor)
- b. This is followed by thinning of the dorsum sellae and the posterior clinoid processes. The dorsum sellae becomes shortened and pointed resulting in a shallow sella turcica.
- c. In extreme cases, the sella becomes very shallow and flattened anterior wall gets demineralized and the floor and dorsum sellae are destroyed.

- d. Alternately, the pituitary fossa may enlarge in a balloon like fashion due to internal hydrocephalus. In such cases the enlarging III ventricle acts like an expanding intra sellar lesions (empty sella syndrome).

9. How is X-ray skull lateral view taken and what are the important structures seen in it?

With the patient erect or prone the head is turned with the affected side towards the film. The head is adjusted to true lateral position with the median plane parallel to the X-ray plate and the interorbital line at right angles to the film.

The important structures seen are:

- Sella turcica
- Pterygopalatine fossa
- Hard palate
- Anterior and posterior walls of frontal sinus

10. What is Caldwell view and how is it taken?

It is a posteroanterior (occipitofrontal) view angled 15° caudal to the canthomeatal line, the nose and forehead touching the X-ray film, with orbitomeatal line perpendicular to the film. It is the best view for frontal sinus.

It shows

- Shape and size of the orbits
- Superior orbital fissure
- Floor of the sella
- Lamina papyracea.

11. What is Water's view and the structures seen on it?

It is a posteroanterior (occipitomental) view inclined with the tragocanthal line forming an angle of 37° with central ray, and the X-ray plate touching the chin.

It is the best view for maxillary sinus. It shows:

- Roof of the orbit
- Superior and inferior orbital rims
- Maxillary antrum
- Ethmoidal air cells

12. What is base view and the structures seen on it?

- Submentovertical view.
- With the patient erect or supine, the head is hyperextended touching the vertex to the couch and shoulders raised. The film is placed lengthwise with its lower border just below the occipital protuberance. The baseline and the film are parallel. The central ray passes submentally and perpendicular to the X-ray plate and the tragocanthal line.
- Structures seen on it are:
 - Anterior wall of middle cranial fossa
 - Posterior wall of maxillary antrum

- Basal foramina
- Petrous temporal bones
- Posterior wall of orbit
- Foramen ovale and spinosum.

13. What is Rheese view and the structures seen on it?

- In posteroanterior position, chin is raised till orbitomeatal line is 40° to the film. Then the head is rotated 40° away from the side to be X-rayed.
- Also called the optic foramen view as it shows
 - Optic foramen
 - Superior orbital fissure
 - Lacrimal fossa

14. What is Townes projection and the structures seen on it?

- i. In supine position the canthomeatal line and the median sagittal line is perpendicular to the film (fronto occipital/half axial)
- ii. With the patient erect or supine, and the chin well down on the chest, the head is adjusted so that the radiographic baseline is at right angles to the film. The film is placed lengthwise with its upper border 5 cm above the vertex.
- iii. This view not used commonly because of increased X-ray radiation to the eyes
- iv. Structures seen are
 - Infraorbital fissure
 - Superior orbital fissure

15. What is orbitomeatal line?

It is the line drawn from the lower margin of the orbit to the superior border of the external auditory canal.

16. What is the significance of optic foramen?

- Seen in Rheese view
- Lies in the posteroinferior quadrant of the orbit
- Average normal diameter of the optic canal is 6–7 mm (< 2 mm and > 7 mm are pathological).
- Both optic canals have to be taken always for comparison. Difference greater than 1.5 mm is significant.

17. What are the causes of small optic canal?

- Congenital
- Inflammatory—osteitis
- Dysostosis like fibrous dysplasia, Paget's disease.

18. What are the causes of optic canal expansion?

- Raised intracranial tension
- Vascular—AV malformation
- Inflammatory—arachnoiditis, sarcoid granuloma, tuberculoma.
- Tumors—meningioma, neurofibroma, retinoblastoma.

19. What are the causes of optic canal erosion?

Medial wall

- Carcinoma
- Mucocele
- Granuloma of the sphenoid sinus

Lateral wall

- Pituitary tumors
- Craniopharyngioma
- Roof—tumor of anterior cranial fossa.

20. What are the normal dimensions of the sella turcica?

Anteroposterior diameter: 4–16 mm. Average—10.5 mm.

Depth: 4–12 mm. Average—8.1 mm

21. What is the most common lesion causing enlargement of the sella?

Pituitary adenoma.

22. X-ray finding in chromophilic adenoma?

- i. Enlargement of the sella
- ii. Erosion of the floor of sella
- iii. Erosion of the under margins of the anterior clinoid process.

23. What is meant by double flooring of the sella?

Irregular and asymmetrical enlargement of the fossa mainly in posterior sellar lesions giving the appearance of double flooring on X-ray skull lateral view.

24. How is calcification in sella best seen?

- X-ray skull lateral view.

25. What is the commonest cause of calcification in midline?

Craniopharyngioma.

26. Enumerate causes of calcification in and around sella.

- i. Atheroma
- ii. Meningioma
- iii. Arterial aneurysm
- iv. TB meningitis
- v. Optic disk glioma.

27. What is empty sella syndrome?

It is an asymmetric enlargement of the sella due to downward herniation of the subarachnoid space into sella due to raised intracranial tension.

28. Enumerate causes of enlarged sella.

- i. Chromophobe adenoma and other pituitary tumors
- ii. Gliomas
- iii. Teratomas

- iv. Craniopharyngiomas
- v. Empty sella syndrome
- vi. Arachnoid cyst
- vii. Ectopic pinealomas.

29. What is the most common cause of suprasellar calcification?

- Craniopharyngioma

30. Name some common views used in orbital diseases.

- Caldwell's view—supraorbital rim and medial orbital wall
- Water's view—roof and floor of the orbit
- Lateral view—face and orbits
- PA view—paranasal sinuses
- Towne's view—supraorbital fissure

31. What is oblique orbital line?

It is a roentgenographic structure formed by junction of medial and lateral portions of the greater wing of sphenoid.

32. Enumerate the causes of small orbit.

- Anophthalmos
- Post-enucleation
- Microphthalmos
- Mucocele.

33. Enumerate the causes of large orbit.

- Pseudotumor
- Tumors in muscle cone
- Congenital serous cysts
- Dysplasia.

34. Enumerate causes of bare orbits.

This is seen in X-ray orbit PA view

- Due to hypoplasia of the lesser wing of sphenoid
- Seen in neurofibroma.

35. What is blowout fracture?

Fracture of the infraorbital plate without the fracture of the infraorbital rim.

36. What is the view used to diagnose blowout fracture?

Water's view.

37. What are the X-ray findings on Water's view in blowout fracture?

- Fragmentation of the orbital wall
- Depression of the bone fragments and prolapse of orbital soft tissue into the maxillary sinus—trap door deformity
- Opacification of the maxillary antrum due to—hemorrhage, emphysema.

38. What is the most common site of blowout fracture?

Posteromedial portion of the orbital floor medial to the inferior orbital fissure.

39. In what view can superior orbital fissure be best seen?

- Towne's projection.

40. Name some conditions in which superior orbital fissure is widened?

- Pituitary adenoma
- Intracavernous aneurysm
- Carotid-cavernous fistula
- Mucocele of the sphenoid sinus
- Backward extension of intraorbital mass
- Forward extension of intracranial mass.

41. Enumerate some causes of narrowing of superior orbital fissure.

Diseases causing increased density and thickness of bone like

- Fibrous dysplasia
- Paget's disease.

42. Enumerate some causes of hyperostosis of the orbit.

- Acromegaly
- Osteopetrosis
- Anemia in childhood
- Sphenoid ridge meningiomas
- Craniostenosis
- Paget's disease.

43. Name some causes of diffuse osteolysis of the orbit.

- Hyperparathyroidism
- Osteomyelitis
- Wegener's granulomatosis
- Malignant neoplasms invading the bone, etc.

44. What are the causes of bone destruction with clear cut margins?

- Dermoid cyst—most common
- Histiocytosis
- Meningioma.

45. Enumerate some causes of enlargement of the orbit.**i. Symmetrical**

- Congenital myopia
- Buphthalmos
- Mass in muscle cone
- Optic nerve glioma
- Optic nerve meningioma
- Neurofibroma.

ii. Asymmetrical

- Hemangioma
- Lacrimal gland tumor
- Dermoid cyst
- Schwannoma.

46. What are the causes of intraorbital calcification?**i. Ocular causes**

- Retinoblastoma—most common
- Meningioma
- Hemangioma
- Phlebolith
- Dermoid cyst
- Cataract.

ii. Ocular manifestation of systemic diseases

- Toxoplasmosis
- von Hippel-Lindau disease
- Tuberous sclerosis
- Sturge-Weber syndrome.

1.9. COMPUTED TOMOGRAPHY AND MAGNETIC RESONANCE IMAGING

1. Who invented computed tomography (CT)?

GN Hounsfield invented CT in 1972. It was initially known as EMI (electrical and musical industries) scan.

2. What is the principle of CT?

X-ray tube of CT machine emits a thin collimated beam of X-rays



Attenuated as they pass through the tissues



Detected by an array of special detectors



X-ray photons within detectors generate electrical signals



Electrical signals converted into images.

High density areas are depicted as white and low density areas as black.

3. What is the radiation dose used in CT?

The X-ray dose for a standard CT is 3 to 5 rads and for high resolution CT is 10 rads.

4. What influences the resolution of CT?

Spatial resolution of a CT scan depends on slice thickness.

Thinner the slice, higher the resolution, require higher radiation dose.

2 mm cuts are optimal for the eye and orbit. In evaluation of orbital apex 1 mm slice is more informative.

5. What are the indications of CT?

- i. Palpable orbital mass
- ii. Unexplained proptosis, ophthalmoplegia or ptosis
- iii. Pre-septal cellulitis with orbital signs
- iv. Orbital signs associated with paranasal sinus disease
- v. Unexplained afferent dysfunction
- vi. Ocular surface or lid tumor with suspected orbital spread
- vii. Intraocular tumor with proptosis
- viii. Orbital trauma
- ix. When MRI is contraindicated.

6. What is Reid's baseline?

Line extending from inferior orbital rim to upper margin of external auditory meatus.

7. What view best depicts optic canal?

The plane inclined at 30° to the orbitomeatal line depicts the optic canal and the anterior visual pathway.

8. What are Hounsfield units?

Hounsfield units represent a scale of radiation attenuation values of tissues. The number assigned is called as Hounsfield number. This number can range from -1000 to +1000 HU or above. Higher the number, greater the attenuation of X-rays and higher the tissue density.

9. What is contrast enhancement?

A contrast enhancing lesion is one which becomes bright or more intense after contrast medium infusion. An increase in its Hounsfield value is a more reliable indicator of contrast enhancement than increase in brightness.

10. What are the views for evaluation of bony orbit?

Axial view: Lateral and medial wall, superior orbital fissure, optic canal.
Coronal view: Orbit floor and roof.

11. What are the causes of enlargement of superior orbital fissure?

- Optic nerve meningioma with intracranial extension
- Carotid-cavernous fistula
- Infralaminar aneurysm.

12. What are the causes of extraocular muscle enlargement?

Type of involvement	Common causes
Unilateral, single muscle involvement	<ul style="list-style-type: none"> • Thyroid ophthalmopathy • Primary and secondary orbital tumors • Myositis
Unilateral, multiple muscle involvement	<p>Symmetrical</p> <ul style="list-style-type: none"> • AV shunts • Vascular engorgement • Thyroid ophthalmopathy <p>Asymmetrical</p> <ul style="list-style-type: none"> • Myositis • Metastatic tumors • Thyroid ophthalmopathy
Bilateral, single muscle involvement	<ul style="list-style-type: none"> • Thyroid ophthalmopathy • Metastatic tumors • Myositis
Bilateral, multiple muscle involvement	<ul style="list-style-type: none"> • Thyroid ophthalmopathy • Metastatic tumors • Cavernous sinus thrombosis

13. Which part of optic nerve is readily visualized?

Optic chiasma is readily visualized because it is surrounded by cerebrospinal fluid in the suprasellar region.

14. Which part of optic nerve is poorly visualized?

Intracanalicular portion of optic nerve is poorly imaged on CT due to absence of intrinsic contrast material and partial volume averaging from the adjacent bone.

15. What is the diameter of optic foramen?

Optic foramen is about 3 mm in diameter.

Anterior part of the optic canal—vertically oval in shape

Middle part of canal—round; Posterior part of canal—horizontally oval.

16. What are the causes of increase or decrease in size of optic foramen?

Enlargement of the optic canal—tumors of intracanalicular part of optic nerve—glioma, meningioma.

Decrease in diameter—fibrous dysplasia

- Paget's disease
- Hyperostosis secondary to meningioma

17. Differentiate between optic nerve glioma and meningioma.

	Glioma	Meningioma
Origin	Neoplasm of astrocytes	Neoplasm of meningotheial cells
Age	Children	Middle age
Sex	No prediction	More in females
Clinical features	Vision loss ↓ Proptosis	Proptosis ↓ Vision loss
CT scan	Intraconal fusiform enlargement of optic nerve	Tubular enlargement of optic nerve Tram track appearance
MRI	No calcification	Calcification may be seen
T1	Hypo- to isointense	Hypointense
T2	Variable intensity	Hyperintense

18. What are the features to be evaluated in case of orbital mass?

Following aspects should be evaluated on CT to aid diagnosis:

- i. Assessment of proptosis: using a mid-orbital scan, a straight line is drawn between the anterior margins of the zygomatic processes. Normally it intersects the globe at or behind the equator. The distance between the anterior cornea and the interzygomatic line is 21 mm normally. If greater than 21 mm or asymmetry greater than 2 mm—proptosis.

- ii. Size, shape and site of the tumor
- iii. Circumscription of the tumor
- iv. Margin of the tumor—smooth (benign) or irregular (malignant)
- v. Effect on surrounding structures—fossa formation (benign) or hyperostosis
- vi. Internal consistency—homogenous (benign) or heterogenous (malignant).

19. Which is the most common site of bony metastasis?

The greater wing of sphenoid is the most common site of bone metastasis in orbit.

20. What are the CT findings in Grave's ophthalmopathy?

Grave's ophthalmopathy typically shows unilateral or bilateral involvement of single or multiple muscles causing fusiform enlargement with smooth muscle borders, especially posteriorly. Tendons are usually spared.

21. What are the factors to be assessed in case of a orbital trauma?

- i. Evaluation of fractures.
- ii. Number, location, degree and direction of fracture fragment displacement.
- iii. Evaluation of soft tissue injury: muscle entrapment, hematoma, emphysema, etc.
- iv. Presence and location of foreign bodies.

22. Where is "empty delta sign" seen?

Sigmoid sinus thrombosis.

23. What are the causes of ring-enhancing lesions?

- i. Cysticercosis
- ii. Tuberculoma
- iii. Toxoplasmosis
- iv. Metastasis
- v. Abscess.

24. How does blood appear in CT?

Acute bleeding (< 6 hr) – hyperdense

Subacute bleeding – isodense with brain (intraparenchymal changes)

Chronic (> 2 weeks) – hypodense.

25. What are the conditions where CT is preferred over magnetic resonance imaging (MRI)?

- i. Acute trauma
- ii. Bony lesions
- iii. Metallic foreign body.

26. What is the principle of MRI?

MRI depends on the rearrangement of hydrogen nuclei when a tissue is exposed to a strong electromagnetic pulse. When the pulse subsides, the

nuclei return to their normal position, re-radiating some of the energy they have absorbed. Sensitive receivers pick up this electromagnetic echo. The signals are analyzed, computed and displayed as a cross sectional image.

27. What are the imaging parameters?

T1 → longitudinal or spin-lattice relaxation.

T2 → transverse or spin-spin relaxation.

28. What is the basis of T1 and T2 imaging?

When the radiofrequency pulse is switched off, the T1 increases and T2 decreases.

T1

- i. Depends on the tissue composition, structure and surroundings.
- ii. It is an expression of the time it takes for the energy imparted by the RF pulse to be transferred to the lattice of atoms that surround the nuclei.
- iii. T1 weighted images are good for delineating ocular anatomy.
- iv. Contrast weighted images are done with T1.

T2

- i. Comes about when the protons go out of phase due to in homogeneity of the external and internal magnetic field
- ii. T2 weighted images are best to discern pathology.

29. List some T1 and T2 characteristics of some common tissues.

	T1 signal	T2 signal
Air Bone Dense calcification	Dark (hypointense)	Dark (hypointense)
Water, edema, CSF Vitreous	Dark	Bright
High protein Paramagnetic substances (gadolinium, melanin)	Bright	Dark
Fat	Bright	Dark
Gray matter	Dark gray	Light gray
White matter	Light gray	Gray

30. What are the strengths of magnets used in MRI?

0.3 tesla, 0.5 tesla, 1 tesla, 3 tesla, and 5 tesla.

31. What is gadolinium?

Gadolinium is a paramagnetic substance (unpaired electrons) that shortens the relaxation time of T1 and T2 weighted sequences. Administered

intravenously it remains intravascular unless there is a breakdown of blood-brain barrier. It is visualized only in T1 weighted images appearing bright.

32. What are the structures that enhance with gadolinium?

Enhancement of tissues typically occurs with blood-brain barrier breakdown, which is caused by a neoplasm, infection or inflammation. The pituitary gland, extraocular muscle, choroids plexus and nasal mucosa normally lack a blood-brain barrier, hence they enhance with gadolinium.

33. What are fat suppression techniques?

Fat-suppression techniques are applied for imaging the orbit. It eliminates the bright signal of orbital fat and delineates normal structures(optic nerve and extraocular muscles), tumors, inflammatory lesions.

34. What are the types of fat suppression techniques?

- i. T1 fat saturation (used with gadolinium)
- ii. Short T1 inversion recovery.

35. What is STIR?

STIR is short T1 inversion recovery. It is considered as optimal sequence for detecting intrinsic lesions of the intraorbital optic nerve (e.g. optic neuritis). STIR images have very low signal from fat but have high signal from water.

36. What is FLAIR?

FLAIR is fluid attenuated inversion recovery. This method eliminates bright signal from fluid, allowing a strong T2 weighted image to remain, which is useful for identifying multiple sclerosis plaques and ischemia. CSF looks dark (unlike in typical T2), allowing bright MS plaques to be visualized better.

37. What is diffusion-weighted sequence (DWI)?

This sequence is used to image acute cerebral infarctions within the first hour of stroke. Ischemia looks bright on DWI. These abnormalities are not detected on other MRI sequences or CT scan.

38. List few indications of MRI.

- i. Optic nerve lesions-intraorbital part of optic nerve and intracranial extensions of optic nerve tumors.
- ii. Optic nerve sheath lesions (e.g. meningioma)
- iii. Sellar masses
- iv. Cavernous sinus pathology
- v. Intracranial lesions of the visual pathway
- vi. Intracranial aneurysm.

39. What are the contraindications of MRI?

- i. Presence of metal (aneurysm clips, cochlear implants, pacemakers)
- ii. Cardiac bypass surgery patients (upto 1 month following surgery as there may be local bleeding at the site of metallic materials)
- iii. Claustrophobic patients (difficult to perform).

40. Differentiate between CT and MRI.

CT	MRI
<ul style="list-style-type: none"> • Better for bony lesions • Sensitive to acute hemorrhage • Posterior fossa degraded by artefact • Poor resolution of demyelinating lesions • Degraded image of orbital apex because of bony artifact • Metal artifacts • Axial and coronal images • Iodinated contrast agent • Risk: ionizing radiation • Less claustrophobic • Less expensive 	<ul style="list-style-type: none"> • Better for soft tissue delineation • Insensitive to acute hemorrhage • Posterior fossa well visualized • Demyelinating lesions well seen at all stages • Good view of orbital apex • Ferromagnetic artifacts • Axial, coronal, sagittal and angled images • Paramagnetic contrast agent • Risk: magnetic field • More claustrophobic • More expensive

41. What structures are better delineated on MRI than CT?

- i. Distinction between optic nerve and its surrounding subarachnoid space.
- ii. Intracanalicular optic nerve
- iii. Contents of superior orbital fissure
- iv. Intraorbital branches of cranial nerves
- v. Lens, choroids and ciliary apparatus.

42. What is the finding in pituitary macroadenoma?

A classic “snow-man” or “figure of eight” appearance of pituitary macroadenoma is seen in gadolinium enhanced T1 weighted image as it passes through the diaphragma sella to extend into suprasellar cistern.

43. How do you differentiate optic neuritis and optic nerve meningioma in MRI?

Optic nerve enhancement (T1 with gadolinium) can differentiate between optic nerve sheath meningioma and optic neuritis. In optic neuritis, gadolinium enhancement is transient, remitting in days, whereas the optic nerve enhancement in optic nerve sheath meningioma persists.

44. What is MR angiography?

MR angiography is a noninvasive method of imaging intra and extracranial carotids and vertebrobasilar circulation to demonstrate stenosis, dissection, occlusion, arteriovenous malformations and aneurysms.

45. What are the advantages and disadvantages of MR angiography over CT angiography?

Advantage: Does not require contrast.

Disadvantage: Small aneurysms and thrombosed aneurysms may be missed.

2

CHAPTER

Cornea

2.1. KERATOMETRY

1. Define keratometry.

It is the measurement of the curvature of the anterior surface of the cornea across a fixed chord length, usually 2–3 mm, which lies in the optical spherical zone of the cornea.

2. Who first invented the keratometer?

Helmholtz in 1854. He called it ophthalmometer. His instrument was made of two glass plates.

3. Who modified Helmholtz's instrument for clinical use?

Javal and Schiotz.

4. Explain the optical principle of the keratometer.

The principle of the keratometer is based on the geometry of a spherical reflecting surface. The anterior surface of the cornea acts as a convex mirror and the size of the image formed (first Purkinje image) varies with its curvature—inversely.

An object of known size and distance is reflected off the corneal surface, and the size of the reflected image is determined with a measuring telescope. From this, the refracting power of the cornea can be calculated on the basis of an assumed index of refraction.

5. What is the principle of visible doubling? Why is it necessary to have double images?

The image formed on the corneal surface is made to double using prisms. The keratometric reading is calculated by adjustment such that the lower edge of one image coincides with the upper edge of the other. From the amount of rotation needed to coincide the edges, the image size is measured by the instrument, and thereby the corneal curvature can be calculated.

It is necessary to have double images to overcome the problem of movement of the eyes during measurements. If the eye moves, both images move together and equally.

6. How is doubling achieved in Javal-Schiotz keratometer?

In Javal-Schiotz keratometer, doubling is achieved by a Wollaston prism which is incorporated in the viewing telescope. A Wollaston prism consists of 2 rectangular quartz prisms cemented together. Quartz being a doubly refractive substance, it splits a single beam of light to form two polarized light beams.

7. Name some keratometers.

- i. Helmholtz keratometer (not used now)
- ii. Reichert (Bausch and Lomb keratometer)—constant object size, variable image size.
- iii. Javal-Schiotz keratometer—variable object size, constant image size

8. What is the relationship between the radius of curvature and dioptric power of the cornea?

$$D = (n - 1)/r$$

where D is the dioptric power of the cornea

n is the index of refraction of the cornea

r is the radius of the cornea in meters

n is usually taken as 1.3375

9. What range of corneal curvature can be measured by keratometry?

The Bausch and Lomb keratometer measures radius of curvature from 36.00D to 52.00D.

10. What are the keratometric findings in spherical cornea?

There is no difference in power between the two principal meridians. The mires are seen as a perfect sphere.

11. What are the findings in astigmatism?

In astigmatism, there is a difference in power between the two meridians. With The Rule (WTR) corneal astigmatism—Mires will be vertically oval. Against The Rule (ATR) corneal astigmatism—Mires look like a horizontal oval.

Oblique astigmatism—the principal meridians are between 30–60° and 120–50°. Irregular astigmatism—Mires are irregular or doubled.

12. What are the keratometric findings in keratoconus?

Pulsating mires are indicative of keratoconus.

i. Early signs:

Inclination and jumping of mires (while attempting to adjust the mires, the mires jump. If an attempt is made to superimpose the plus mires, they will jump above and below each other).

ii. Other signs:

Minification of mires: In advanced keratoconus ($K > 52D$), the mires begin to get smaller, due to increased amount of myopia.

Oval mires: Occur due to large amount of astigmatism, mires are normal size and distinct borders.

iii. Distortion of mires: The mire image is irregular, wavy and distorted.

13. Give some clinical uses of keratometry.

- i. Objective method for determining curvature of the cornea
- ii. To estimate the amount and direction of corneal astigmatism
- iii. The ocular biometry for the IOL power calculation
- iv. To monitor pre and post surgical astigmatism
- v. Differential diagnosis of axial versus refractive anisometropia
- vi. To diagnose and monitor keratoconus and other corneal diseases
- vii. For contact lens fitting by base curve selection
- viii. To detect rigid gas permeable lens flexure.

14. What are the sources of error in keratometry?

- i. Improper calibration
- ii. Faulty positioning of the patient
- iii. Improper fixation by patient
- iv. Accommodative fluctuation by examiner
- v. Localized corneal distortion, excessive tearing, abnormal lid position
- vi. Improper focusing of the corneal image.

15. What are the new types of keratometers?

- i. **Automated keratometer:** The reflected image is focused onto a photodetector, which measures image size, and then the radius of curvature is computed. Infrared light is used to illuminate the mires, as well as in the photodetector.
- ii. **Surgical/operating keratometer:** Keratometer attached to the operating microscope.

16. Name other methods of studying corneal curvature.

- i. Placido disk
- ii. Corneal topography.

17. What are the limitations of keratometry?

- i. The keratometer assumes that the cornea is a symmetrical spherical or spherocylindrical structure with two principal meridians separated by 90° , whereas in reality, the cornea is an aspheric structure.
- ii. The refractive status of only a very small central area of the cornea is measured, neglecting the peripheral zones.
- iii. Inaccurate for very flat or very steep corneas, i.e. effective only for a certain range of corneal curvatures.
- iv. Ineffective in irregular astigmatism, thus, cannot be used for corneal surface irregularities.

2.2. CORNEAL VASCULARIZATION

1. What are the factors that make a normal avascular cornea, vascular?

Anything that breaks the normal compactness of cornea:

- i. Trauma
- ii. Inflammatory
- iii. Toxic
- iv. Nutritional
- v. Presence of vaso-formative stimulus.

2. Classify corneal vascularization according to depth of involvement?

Superficial: originates from superficial limbal plexus.

Interstitial: derived from anterior ciliary arteries.

Deep or retrocorneal pannus: seen in syphilitic cause of interstitial keratitis.

3. What is pannus?

It is growth of fibrovascular tissue between the epithelium and Bowman's layer. It literally means cloth. It can be degenerative or inflammatory.

There are 4 types of pannus:

- i. Pannus trachomatous
- ii. Pannus leprosus
- iii. Pannus phlyctenulosus
- iv. Pannus degenerativus: associated with blind eyes like in bullous keratopathy.

4. What is micro pannus and what are the causes for the same?

When vascularization extends beyond 1–2 mm from the normal vasculature.

Causes are:

- i. Inclusion conjunctivitis
- ii. Vernal conjunctivitis
- iii. Superficial limbic keratoconjunctivitis
- iv. Staphylococcal blepharitis
- v. Childhood trachoma
- vi. Contact lens wear.

5. What is gross pannus and what are the causes for the same?

When vascularisation extends beyond >2 mm from the normal vasculature.

Causes are:

- i. Trachoma
- ii. Staphylococcal blepharitis
- iii. Atopic keratoconjunctivitis
- iv. Rosacea
- v. Herpes simplex keratitis

6. What is progressive pannus and what is regressive pannus?

- i. Progressive pannus: Infiltration is ahead of vascularization
- ii. Regressive pannus: Vascularization is ahead of infiltration.

7. How do you treat corneal vascularization?

- i. By treating acute inflammatory cause if any, vascularization decreases.
- ii. Radiation: applicable to destruction of superficial rather than deep vessels.
It acts by causing development of end arteritis resulting from trauma to endothelium.
- iii. Surgery:
 - **Peritomy**: removal of an annulus of conjunctival and subconjunctival tissue dissected outwards from limbus for 3–4 mm.
 - **Superficial keratectomy**: when vascularization is superficial or circumferential.
 - **Argon laser photocoagulation**.

8. How do you differentiate superficial and deep vessels?

- i. Superficial vessels are usually arranged in arborizing pattern, present below the epithelial layer and their continuity can be traced with the conjunctival vessels. They are dark red in color and they branch dichotomously.
- ii. Deep vessels are usually straight, lie in the stroma, not anastomosing and their continuity cannot be traced beyond the limbus. They are pink in color.

9. How are deep vessels arranged?

They may be arranged as:

- i. Terminal loops
- ii. Brush
- iii. Parasol
- iv. Umbel
- v. Network
- vi. Interstitial arcade.

10. What is the role of anti-VEGF in corneal neovascularization?

The anti-VEGF will act on newly formed endothelial buds without pericytes. These drugs are tried in diabetic neovascularization. In corneal vascularization, once the vessels become mature with pericytes, these drugs are of limited value. Subconjunctival injections are tried to prevent new vessel formation after keratoplasty in highly vascularized corneas.

2.3. CORNEAL ANESTHESIA

1. What is the nerve supply of cornea?

Long ciliary nerve, a branch of nasociliary nerve, which is a branch of ophthalmic division of trigeminal nerve, supplies the cornea.

2. What are the branches of nasociliary nerve?

Nasociliary nerve, a branch of ophthalmic division of trigeminal nerve has the following five branches:

- i. Nerve to ciliary ganglion
- ii. Long ciliary nerves
- iii. Anterior ethmoidal nerve
- iv. Posterior ethmoidal nerve
- v. Infratrochlear nerve.

3. How is the cornea innervated?

Myelinated and nonmyelinated axons distribute radially around periphery of cornea



Enter substantia propria of stroma in a radial manner and branch dichotomously (lose myelin sheath)



Preterminal fibers form a plexus in mid stroma



Subepithelial plexus formed



Epithelial plexus formed where the axons are devoid of Schwann cells.

4. Which part of cornea is more sensitive?

Innervation density is more at center and decreases five-fold toward limbus.

5. How much time does it take for nerves to regenerate?

By 4 weeks normal innervation pattern is seen, though neural density may be less. Center of the wound is devoid of sensation for more than 2 weeks.

6. With which instrument can you measure corneal sensations?

This can be tested using a wisp of cotton. In order to quantitate, one can use an instrument called esthesiometer.

Esthesiometer: Nylon monofilament of 0.08–0.12 mm diameter covers 4–10 corneal epithelial cells. Thus, it stimulates one sensitive nervous unit.

7. What are the neurotransmitters that play a role in corneal sensations?

- i. Substance P for pain
- ii. Calcitonin gene related protein

- iii. Catecholamines—Loss of this may lead to epithelial breakdown like that in neurotropic keratitis.
- iv. Acetylcholine—levels related to corneal sensations.

8. What are the physiological variations in corneal sensations?

- i. Most sensitive at apex, least at superior limbus.
- ii. Sensitivity lowest in morning and highest in evening.
- iii. Sensitivity decreases with age.

9. What are the conditions that affect corneal sensitivity?

A. CONGENITAL:

- i. Congenital trigeminal anesthesia.
- ii. Corneal dystrophies—Lattice dystrophy, Bassen-Kornzweig syndrome, Pierre-Rhomberg syndrome, iris nevus syndrome.

B. ACQUIRED:

- i. Diabetes mellitus: reduces sensitivity.
- ii. Herpes simplex keratitis.
- iii. Leprosy.
- iv. Adie's tonic pupil: lesion is in ciliary ganglion or short ciliary nerves, where the nerves serving corneal sensations and those supplying the iris sphincter run side by side.
- v. Myasthenia gravis.
- vi. Toxic corneal hypoesthesia: Carbon disulfide, hydrogen sulfide used as pesticides.

C. PHYSIOLOGICAL:

- i. Iris color—lightens the iris color, more the sensitivity.
- ii. Gender—more sensitive in males than females.
- iii. Eyelid closure: decreases sensitivity. This is due to depressed acetylcholine levels with lid close. This is the reason for low corneal sensitivity in morning after a night's sleep.

D. PHARMACOLOGICAL:

- i. Surface anesthetics like 4% lignocaine, 0.5% proparacaine.
- ii. Beta blockers—temporary decrease.
- iii. Sodium sulfacetamide—30% solution decreases sensitivity.
- iv. Atropine—decreases sensitivity after 10 minutes of instillation. This is due to decreased acetylcholine.

E. HORMONAL:

- i. Preovulatory reduction in corneal sensations due to estrogen rise.
- ii. Decreased corneal sensitivity during pregnancy.

F. MECHANICAL:

- i. Contact lens: decreases corneal sensitivity. This may be attributed to the decrease in oxygen pressure at epithelial level.

G. SURGICAL:

- i. Limbal incisions—after cataract surgery upper half of cornea may have decreased sensitivity for more than a year.
- ii. Corneal grafts: sensitivity may recover within 2 years.
- iii. Refractive surgeries: LASIK decreases sensations.
- iv. Other procedures: Photocoagulation and retinal detachment surgeries.
- v. Trigeminal denervation: decreases sensitivity.

10. When will you suspect corneal anesthesia?

- i. Persistent non-healing corneal defect
- ii. Symptoms are very less as compared to the epithelial defect.

11. How will you treat corneal anesthesia?

- i. A central tarsorrhaphy may be necessary to promote healing.
- ii. Corneal grafting will give disastrous results in the presence of corneal anesthesia.

2.4. CORNEAL DEPOSITS

1. What are the causes of superficial corneal deposits?

A. Pigmented:

- i. Iron lines
- ii. Spheroidal degeneration
- iii. Adenochrome
- iv. Pigmented (non-calcified) band keratopathy
- v. Cornea verticillata.
- vi. Epithelial melanosis
- vii. Drugs – Amiodarone, phenothiazines, epinephrine
- viii. Metals – Iron, gold, copper
- ix. Blood
- x. Bilirubin
- xi. Corneal tattooing

B. Non-pigmented:

- i. Calcific band keratopathy
- ii. Subepithelial mucinous dystrophy
- iii. Coats' white ring
- iv. Drug deposits—amiodarone

C. Refractile/crystalline:

- i. Meesmann's dystrophy
- ii. Superficial amyloid
- iii. Tyrosenemia
- iv. Intraepithelial ointment
- v. Gout.

2. What are the causes of stromal deposits?

A. Pigmented:

- i. Blood staining
- ii. Siderosis
- iii. Bilirubin
- iv. Ochronosis

B. Non-pigmented:

- i. Granular dystrophy
- ii. Macular dystrophy
- iii. Fleck dystrophy
- iv. Lipid deposition
- v. Mucopolysaccharidosis

C. Refractile/crystalline:

- i. Lattice dystrophy
- ii. Schnyder's dystrophy
- iii. Bietti's crystalline dystrophy.

3. Which are the various iron lines?

- i. **Stocker's line:** at head of pterygium.
- ii. **Hudson-Stahli's line:** in palpebral area seen in old age
- iii. **Ferry's line:** at the border of a filtering bleb.
- iv. **Fleischer's ring:** surrounding cone in keratoconus.
- v. Between radial keratotomy incisions.
- vi. Adjacent to contour changing pathology, like in Salzmann nodular degeneration.

4. What is the reason for iron staining?

Tear pooling at the site of contour change will cause iron deposition.

5. At what level of cornea is spheroidal degeneration located?

Bowman's layer and anterior stroma.

6. What are the deposits in spheroidal degeneration?

Protein rich matrix containing tryptophan, tyrosine, cystine, cysteine.

7. What kind of deposits are seen with epinephrine eye drops in glaucoma?

Adenochrome deposits.

8. When does blood staining of cornea occur?

It occurs in presence of hyphema due to two reasons:

- i. Rise in intraocular pressure
- ii. Compromised endothelium.

Initial appearance of yellow granules within the posterior stroma is sign of need of evacuation of hyphema.

9. How does blood staining in cornea clear?

It clears from the periphery to center due to the scavenging action of leucocytes which are present in perilimbal blood vessels.

10. Where is Hudson-Stahli line found?

The most common iron line, located in lower 3rd of cornea in the epithelium

- i. Usually run horizontally, higher nasally lower temporally
- ii. Typical bilateral and symmetric
- iii. Altered by various factors like corneal scar and contact lens wear
- iv. It increases in length and density with time
- v. Seen in as young as 2 years and increases with age upto 70 years

11. In which condition is Kayser-Fleischer ring seen?

- i. It is seen in Wilson's disease (hepatolenticular degeneration) which is a condition of altered copper metabolism
- ii. It's seen before any nervous symptoms develop.
- iii. It is a yellow brown or green ring seen in the peripheral cornea.
- iv. Deposit is at level of Descemet's membrane.
- v. When chelating agents are given line disappears.

12. How do you differentiate between a picture of arcus senilis and Kayser-Fleischer (KF) ring?

Arcus has a clear intervening space between the limbus and line called the clear zone of Vogt, whereas as the KF ring comes from copper from peri-limbal blood vessels. There is no intervening space between limbus and line.

13. What are causes of epithelial melanosis?

- i. **Congenital:** Nevi.
- ii. **Sequelae of trachoma and other inflammations** due to migration of conjunctival melanoblasts from limbus.
- iii. **Striate melanokeratosis of Cowen:** Normally occurs in darkly pigmented individuals. Pigmented lines located in epithelium extend from limbus to central cornea. Probably result from migration of pigmented limbal stem cells onto the cornea.

14. What are causes of endothelial melanosis?

- i. **Congenital senile degenerative:** Myopia, diabetes senile cataract, chronic glaucoma.
- ii. **Mosaic pigmentation of Vogt:** outlines the endothelial cells.
- iii. **Turk's line:** due to convection current in anterior chamber.
- iv. **Krukenburg's spindles:** accentuation of general atrophic process in which pigment derived from uveal tract is deposited on corneal endothelium and aggregated in shape of spindle. Seen in pupillary axis.

2.5. BACTERIAL AND FUNGAL CORNEAL ULCER

1. What are the organisms capable of penetrating intact cornea?

- i. *Neisseria gonorrhoeae*
- ii. *Haemophilus influenzae*
- iii. *Corynebacterium diphtheriae*.

2. What are the common bacteria causing keratitis in India?

The most common causes of bacterial keratitis in our country are:

- A. Gram-positive organism:
 - *Streptococcus pneumoniae*
- B. Gram-negative organism:
 - *Pseudomonas aeruginosa*
- C. Acid-fast organism:
 - *Nocardia*.

3. What are the common predisposing factors to keratitis?

- i. Trauma
- ii. Contact lens wear
- iii. Pre-existing corneal diseases—trauma, bullous keratopathy, and decreased corneal sensation.
- iv. Other factors—chronic blepharoconjunctivitis, dacryocystitis, tear film deficiency, topical steroid therapy, hypovitaminosis A.

4. Which is the commonest organism causing keratitis in patients with chronic dacryocystitis?

Streptococcus pneumoniae.

5. Which is the commonest organism among contact lens wearers?

Pseudomonas aeruginosa.

6. What are the typical features of bacterial keratitis?

- i. Symptoms are more than the signs and there will be lot of conjunctival congestion, discharge and chemosis
- ii. Sharp epithelial demarcation with well defined borders
- iii. Underlying dense, suppurative stromal inflammation.

7. What are the characteristic features of specific bacterial keratitis?

- i. Gram-positive cocci (such as *S. pneumoniae*) cause localized, round or oval ulcerations with distinct borders.
- ii. Ulcus serpens or serpiginous keratitis also caused by *S. pneumoniae*
- iii. Gram-negative bacilli such as *Pseudomonas* cause a rapid fulminating ulcer with lot of suppuration and discharge and produce hour glass appearance in a matter of days
- iv. *Moraxella* causes indolent ulcers in debilitated individuals
- v. *Nocardia* typically causes a wreath shaped ulcer which is superficial spreading.

8. How do you do microbiology investigations in a case of corneal ulcer?

- i. Proparacaine is used as the topical anesthetic of choice, since it has the fewest inhibitory effects on the recovery of microorganism
- ii. Corneal scraping should be performed along the edges and the base of the ulcer. For example, *S. pneumoniae* is recovered from the edges while *Moraxella* is recovered from the base
- iii. Avoid touching the conjunctiva and eyelashes
- iv. A Kimura spatula can be routinely used. A calcium alginate swab is supposed to give better recovery rates
- v. Smears can be placed on the central part of the slide in an area marked on the reverse
- vi. Culture plates are streaked using a C-shaped design.

9. Name commonly used stains.

- i. Gram stain
- ii. Acridine orange
- iii. Calcofluor white
- iv. Giemsa.

10. Which stains require fluorescence microscopy?

Acridine orange, calcofluor white.

11. What are the steps in Gram stain?

- i. Fix the slide in methyl alcohol
- ii. Flood the slide with crystal gentian violet for 1 minute
- iii. Rinse and flood with Gram's iodine for 1 minute
- iv. Rinse and decolorize with acid alcohol for 20 seconds
- v. Counterstain with dilute carbolfuschin (safranin) for 1 minute.

12. What is the principle behind Gram stain?

Gram-positive organisms have thicker peptidoglycan layer in cell wall which makes them more permeable to primary stain than gram-negative organisms. Gram-positive bacteria retain the Gentian violet-iodine complex and appear purple. Gram-negative bacteria lose the gentian violet iodine complex with the decolorization step and appear pink when counterstained with safranin.

13. What is the use of Giemsa's stain?

Apart from distinguishing between bacteria and fungi, Giemsa helps to understand the normal and abnormal cellular morphology (such as inflammatory cells).

14. Name common antibiotics active against gram-positive bacteria.

- i. Cephazolin (50 mg/ml)
- ii. Chloramphenicol (5–10 mg/ml)
- iii. Moxifloxacin
- iv. Vancomycin (15–50 mg/ml)

15. Name common antibiotics active against gram-negative bacteria.

- i. Tobramycin (3–14 mg/ml)
- ii. Gentamicin (3–14 mg/ml)
- iii. Amikacin (20 mg in 0.5 ml)
- iv. Ceftazidime
- v. Ciprofloxacin (3 mg/ml)
- vi. Levofloxacin (3 mg/ml)
- vii. Ofloxacin (3 mg/ml).

16. How do you make fortified antibiotics?

a. Gentamicin: Add 2 ml of injectable gentamycin to 5 ml of commercial topical preparation.

5 ml commercial preparation has	— 15 mg
Added drug 2 ml	— 80 mg
Total in 7 ml	— 95 mg
1 ml contains	— 13.5 mg

b. Cefazolin: Add 5 ml or 10 ml distilled water or sterile saline to 500 mg vial of cefazolin to obtain 10% or 5% solution.

c. Vancomycin: Add 10 ml of distilled water or saline to 500 mg vial of vancomycin and obtain a 5% solution.

d. Amikacin: Add 10 ml of distilled water to 100 mg of amikacin to get 1% solution.

17. What are the typical features of fungal keratitis?

- i. Signs more than symptoms
- ii. Feathery margins
- iii. Raised dry surface
- iv. Satellite lesions
- v. Endothelial plaques
- vi. Cheesy hypopyon
- vii. Gritty texture while scraping.

18. Classify fungi.

- i. **Yeast** (e.g. *Candida*, *Cryptococcus neoformans*, *Rhinosporidium*)
- ii. **Filamentous** – Septate and non-septate

Septate:

Fusarium, *Aspergillus*, *Curvularia*

Non-septate:

Mucor, *Rhizopus*

- iii. **Dimorphic:**

Histoplasmosis.

19. What are the most common fungus infecting the cornea?

- i. *Fusarium*
- ii. *Aspergillus flavus*
- iii. *Aspergillus fumigatus*.

20. How to differentiate *Nocardia* from fungal filament in KOH mount?

Nocardia is slender, branching, and thinner than fungal hyphae.

21. Name common media used for fungal culture.

- i. Sabouraud's dextrose agar
- ii. Potato dextrose agar
- iii. Brain-heart infusion
- iv. Blood agar.

22. Classify antifungals.

- i. ***Polyenes***
 - Larger molecular weight: Amphotericin, nystatin
 - Smaller molecular weight: Natamycin
- ii. ***Imidazoles***
Clotrimazole, miconazole, ketoconazole, econazole, thiobendazole.
- iii. ***Anti-metabolites***
Flucytosine.

23. What is the drug of choice in filamentous fungal infection?

Natamycin 5% suspension (especially for *Fusarium*)

24. What is the mechanism of action of amphotericin?

Amphotericin is effective against *Aspergillus*. It selectively binds to sterol present in plasma membrane of susceptible fungi and alters membrane permeability.

25. What is the dose of amphotericin?

Topical: 0.1–0.2% hourly initially

Anterior chamber irrigation: 500 µg in 0.1 ml of normal saline.

Intravitreal: 5 µg in 0.1 ml of normal saline.

26. How is amphotericin available?

It is available as 50 mg dose in vial. It has to be stored in dark colored bottles to avoid exposure to light.

27. What is the mechanism of action of imidazoles?

At lower concentration it inhibits ergosterol synthesis and at higher concentration it causes direct damage to fungal cell membrane.

28. What are the indications of oral antifungals?

- i. Deeper ulcers not responding to topical therapy
- ii. Ulcers involving the limbus and extending to the sclera

In such cases ketoconazole tablets (200 mg bd) can be used, after assessing for liver function tests.

29. What are the complications of corneal ulcer?

- i. Descemetocoele
- ii. Perforation
- iii. Anterior synechiae
- iv. Secondary glaucoma
- v. Cataract
- vi. Purulent iridocyclitis
- vii. Endophthalmitis.

30. What is the difference between hypopyon in bacterial and fungal corneal ulcer?

Hypopyon in bacterial ulcer	Hypopyon in fungal ulcer
Sterile (bacteria cannot invade intact Descemet's membrane.	Infective
Fluid, move according to head posture	Thick and immobile

31. Write briefly on voriconazole.

It is a new azole derived from fluconazole. It is active against *Aspergillus*, *Fusarium*, *Candida*. It inhibits cytochrome P450 dependent 14 sterol demethylase, an enzyme responsible for conversion of lanosterol to 14 demethyl lanosterol.

32. What are the signs to know whether the ulcer is healing?

- i. Blunting of the edges of perimeter of stromal infiltrate.
- ii. Decreased density of stromal infiltrate.
- iii. Decrease in stromal edema and endothelial plaque.
- iv. Decrease in anterior chamber reaction and reduction in the size of hypopyon.
- v. Re-epithelization.
- vi. Cessation in corneal thinning.

33. What are the indications for keratoplasty in infective keratitis?

- i. Perforated corneal ulcer
- ii. Impending perforation
- iii. Non healing corneal ulcer in spite of appropriate and adequate antimicrobial therapy.

34. What are the principles in doing therapeutic keratoplasty?

- i. The aim is to control and eliminate the infection
- ii. The infected tissue along with 1mm of uninvolved corneal tissue is removed
- iii. A peripheral iridectomy is performed

- iv. Interrupted sutures are used so that selective suture removal can be performed in indicated cases
- v. Postoperatively antibiotics are used for ulcers caused by bacteria and antifungals for fungal ulcers. Topical steroids are contraindicated in therapeutic keratoplasty done for fungal keratitis.

35. How do you treat non-healing corneal ulcers?

- i. First step is to reculture to identify/confirm the initial organism
- ii. Recheck adnexal structures, especially for dacryocystitis
- iii. Intrastromal injection of anti-microbials may be tried
- iv. Tarsorrhaphy.

2.6. ACANTHAMOEBA KERATITIS

1. What is *Acanthamoeba*?

It is a freely living protozoa commonly found in soil, dust, fresh or brackish water and upper respiratory tract in humans.

2. What are the different species of *Acanthamoeba*?

They have been classified on basis of their cyst morphology and isoenzyme into 8 species out of which two of them namely *A. castellani* and *A. polyphaga* are implicated in causing corneal infections.

3. What is different forms/life cycle of *Acanthamoeba*?

- i. Cystic (dormant) form
- ii. Trophozoite (active) form.

4. What is the cause of *Acanthamoeba* keratitis (AK)?

A. Western world: It is commonly associated with contact lens wear.

Contact lenses

- i. Contact lens users (extended wear CL users are at a greater risk)
- ii. Home-made saline as a substitute for CL solution
- iii. CL wears in contaminated waters like swimming with CL

B. Indian scenario: Commonly associated with contaminated water

Trauma

Exposure to contaminated water or soil (agricultural population)

Take food water at home, cooling towers, air filters

Surgery

Penetrating keratoplasty

Radial keratotomy.

5. Why is so much of importance given to contact lenses in evaluating a case of *Acanthamoeba* keratitis?

This is because AK can spread in numerous ways in relation to contact lenses

- i. Use of tap water in making CL solutions
- ii. Swimming in a swimming pool/sea (contaminated)
- iii. Shower while wearing lenses
- iv. Minor corneal damage or abrasion which can happen with CL use itself can cause AK.

6. What is the pathogenesis of *Acanthamoeba* keratitis?

Upon binding to the mannose glycoprotein of the corneal epithelium, *Acanthamoeba* secretes proteins which are cytolytic to the epithelium as well as proteases, which causes further penetration.

7. What is the presenting symptom in AK?

The common symptoms are disproportionate pain compared to the signs associated with blurred vision.

8. What is the reason for pain in AK?

- i. Radial keratoneuritis
- ii. Limbitis
- iii. Scleritis.

9. What are the signs of AK?

The signs mimic a viral keratitis in many ways; they are classified as early and late.

Early

- i. Epithelial irregularity (dirty looking, stippled unhealthy epithelium)
- ii. Pseudodendrites
- iii. Radial keratoneuritis
- iv. Stromal infiltration
- v. Satellite lesions
- vi. Disciform lesion

Late

- i. Ring infiltrate (oval shaped which is characteristic of this disease)
- ii. Stromal opacification
- iii. Scleritis
- iv. Descemetocele formation.

10. What are the investigations done in AK?

Noninvasive:

- i. Confocal microscopy

Invasive:

- i. Gram and Giemsa stain
- ii. Calcofluor white stain
- iii. 10% KOH mount
- iv. Acridine orange
- v. Immunofluorescent antibody stain
- vi. PAS and methenamine silver
- vii. Phase contrast microscope
- viii. PCR
- ix. Corneal biopsy.

11. How is *Acanthamoeba* grown in a microbiological environment?

The *Acanthamoeba* organism grows well on non-nutrient agar with *Escherichia coli* overlay. The organism creates a track by feeding on *E. coli*.

12. What are the extracorneal complications of AK?

- i. Scleritis
- ii. Cataract

- iii. Peripheral ulcerative keratitis
- iv. Glaucoma
- v. Iris atrophy
- vi. Chronic inflammation
- vii. Vascular thrombosis
- viii. Intraocular infection
- ix. The exact etiology of these complications is not known but likely to be due to drug toxicity (biguanides) or immune response of the body itself.

13. What are the differential diagnoses of AK?

The main differential diagnosis is herpes simplex keratitis (both epithelial and stromal keratitis) and fungal keratitis.

14. What is the treatment of AK?

It can be classified as:

Medical

- i. **Biguanides**
 - Polyhexamethylene biguanide (PHMB) (0.02 to 0.06%)
 - Chlorhexidine 0.02 to 0.2%
- ii. **Diamidines**
 - Hexamidine 0.1%
 - Propamidine 0.1%
- iii. **Imidazole and triazole antifungals**
- iv. **Aminoglycosides (AMG)**
- v. **Polymyxins.**

Surgical

- i. Epithelial debridement
- ii. Cryotherapy
- iii. Deep anterior lamellar keratoplasty
- iv. Penetrating keratoplasty.

15. What are the goals of treatment?

- i. Eradication of trophozoites and cysts
- ii. Rapid resolution of immune response
- iii. Prevent recurrence
- iv. Prevention of complications.

16. What is the mechanism of action of biguanides?

Biguanides interact with cytoplasmic membrane resulting in loss of cellular components and inhibition of respiratory enzymes.

17. What is the mechanism of action of diamidines?

It causes structural membrane changes affecting cell permeability. When the molecules enter amebic cytoplasm, denaturation of cytoplasmic proteins and enzymes occur. Hexamidine is a faster amebicidal drug than propamidine against trophozoites and cysts.

18. Which is used as first-line of treatment between the two of the above classes of drugs?

Biguanides have shown less toxicity compared to diamidines, so biguanides are used as a first line, but both can be combined in a severe case of AK. It is believed to have a additive or synergistic effect.

19. How would you prepare a 0.02% solution of PHMB?

The 20% parent solution is diluted 1000 times with saline or sterile water.

20. What is a major side effect of PHMB?

Vascularization of the cornea.

21. How would you treat a case of limbitis and scleritis in a case of AK?

Both can be a cause of significant pain. It is due to severe posterior segment inflammation. Limbitis is an early as well as a late finding. It occurs commonly. It is treated with flurbiprofen 50 to 100 mg 2–3 times a day.

Scleritis: less common. Responds well to NSAIDs. If not then systemic steroids are added.

22. How would you treat a case of persistent epithelial defect?

To exclude superficial bacterial infection which is very hard to distinguish in presence of severe AK. Topical therapy should be discontinued and non-preserved prophylactic broad spectrum antibiotic should be given to prevent bacterial super infection. After signs of improvement are seen anti amebic therapy is re-introduced.

23. How does an epithelial debridement help?

It helps in the following ways—

- i. It serves as a therapeutic and diagnostic tool
- ii. It helps in better drug penetration.

24. How is cryotherapy done?

It kills only the trophozoites but not cysts.

A retinal cryoprobe is taken and a freeze thaw method is used until a ball of ice forms near the applicator in the stroma. In this manner whole of the cornea is treated. Endothelial failure is a side effect.

25. When would you 'perform keratoplasty?

It is not required in most of the cases as medical therapy would suffice but is indicated in patients with—

- i. Non healing ulcer in spite of appropriate anti amebicidal therapy.
- ii. Corneal perforation that does not respond to corneal gluing
- iii. Fulminant corneal abscess
- iv. Intumescent cataract.

Many of these eyes will have associated limbitis and scleritis so must be started on prednisolone (1 mg/kg/day) or cyclosporine (3.5 to 7.5 mg/kg/day) which is tapered in post graft period.

26. What are the newer modes of keratoplasty useful in AK?

In the initial stages, the disease is fairly superficial and, hence, a lamellar keratoplasty or deep anterior lamellar keratoplasty can be used to considerably shorten the course of the disease.

2.7. VIRAL KERATITIS

1. What are the common viruses causing keratitis?

- i. Adenovirus
- ii. Herpes simplex virus
- iii. Herpes zoster

2. What are the types of herpes simplex keratitis?

Primary infection is extremely rare and almost all the cases which are seen are due to recurrent infections.

- i. **Epithelial keratitis:**
 - a. Superficial punctate keratitis
 - b. Dendritic keratitis
 - c. Geographic keratitis
- ii. **Subepithelial keratitis:**
 - a. Neurotrophic keratitis
- iii. **Stromal keratitis:**
 - a. Necrotizing keratitis
 - b. Nummular keratitis
 - c. Disciform keratitis
- iv. **Endothelium:**
Endothelitis.

3. What are the differential diagnosis of dendritic keratitis of herpes simplex?

- i. Herpes zoster
- ii. Healing corneal abrasion
- iii. *Acanthamoeba* keratitis
- iv. Toxic keratitis due to topical drugs
- v. Contact lens induced abrasions
- vi. Neurotrophic keratopathy.

4. What are the characteristics of a herpes simplex dendrite?

It is usually central, slender, arborizing lesion with terminal end bulbs. The base of the ulcer stains with fluorescein (due to loss of cellular integrity) while the terminal end bulbs stain by rose bengal (due to lack of mucin binding by the cells).

5. How will you treat dendritic keratitis?

- i. **Debridement:** Helps by removing viral laden cells and can be done for dendritic keratitis. It is not of any value for geographic keratitis.
- ii. **Topical acyclovir:** 3% ointment administered 5 times daily for two weeks or topical trifluridine 1% solution 8 times daily for two weeks.

6. What are the features of neurotrophic keratitis?

It is also called as metaherpetic keratitis and is characterized by:

- i. Nonhealing epithelial defect after appropriate and adequate antiviral therapy
- ii. Raised margins
- iii. Underlying gray and opaque stroma

Treatment is to stop antivirals and to use lubricants. In nonresponsive cases, it may be treated with bandage contact lenses or temporary tarsorrhaphy.

7. What are the features of disciform keratitis?

This condition causes defective vision and presents as fusiform stromal edema associated with keratic precipitates underlying the zone of the edema. Few inflammatory cells in the anterior chamber may be seen.

8. What are the features of necrotizing keratitis?

This type of viral stromal keratitis mimics a bacterial or fungal suppurative infection. A previous history of recurrence of infection and the presence of corneal vascularisation will help in the diagnosis.

9. What are the findings of HEDS (Herpetic eye disease study)?

- i. Topical corticosteroids given together with a prophylactic antiviral improves the outcome of stromal keratitis.
- ii. There is no benefit of using oral acyclovir in treating stromal keratitis.

10. What are the features of a herpes zoster dendrite?

- i. They are pseudodendrites
- ii. They are shorter, stockier and elevated
- iii. They do not stain with fluorescein, but stain with rose bengal.

11. What are the features of herpes-zoster ophthalmicus (HZO)?

- i. **Lids:**
 - a. Scarring
 - b. Trichiasis
 - c. Marginal notching
 - d. Cicatricial ectropion or entropion
- ii. **Conjunctiva:**
 - a. Ischemia with necrosis
 - b. Circumcorneal congestion
- iii. **Cornea:**
 - a. Punctate keratitis
 - b. Dendritic keratitis
 - c. Stromal keratitis
 - d. Corneal anesthesia
- iv. **Iris:**
 - Sectoral iris atrophy
- v. **Anterior chamber:**
 - Hemorrhagic hypopyon

- vi. **Retina:**
 - a. Focal choroiditis
 - b. Occlusive retinal vasculitis
 - c. Retinal detachment
- vii. **Orbit:**
 - a. Ptosis
 - b. Orbital edema
 - c. Proptosis in some cases
- viii. **Central nervous system:**
 - a. Papillitis
 - b. Cranial nerve palsies (commonly third nerve involvement).

12. What is the treatment for HZO?

- i. Oral acyclovir 800 mg 5 times daily for 10–14 days
- ii. There is no use for topical antivirals
- iii. Topical steroids can be used for stromal keratitis
- iv. Oral corticosteroids can be used to reduce zoster pain especially in older individuals
- v. Lubricants
- vi. Tarsorrhaphy in severe cases of neurophic keratitis

13. How will you treat postherpetic neuralgia?

- i. Capsaicin cream applied to the skin
- ii. Low doses of amitriptyline or carbamazepine
- iii. Oral gabapentin.

2.8. INTERSTITIAL KERATITIS

1. What is interstitial keratitis?

Vascularization and nonsuppurative infiltration affecting the corneal stroma, usually associated with a systemic disease.

2. What are the causes of interstitial keratitis (IK)?

- i. Congenital syphilis
- ii. Acquired syphilis
- iii. Tuberculosis
- iv. Leprosy
- v. Onchocerciasis
- vi. Infectious mononucleosis
- vii. LGV—segmental and highly vascularized
- viii. Cogan's syndrome
- ix. Herpes zoster
- x. Herpes simplex
- xi. Mumps—Diffuse rapid involvement of whole cornea, D/D from all others by the rapidity with it clears
- xii. Rubeola
- xiii. Vaccinia
- xiv. Variola
- xv. Leishmaniasis
- xvi. Mypanosomiasis
- xvii. Hodgkin's disease (rare)
- xviii. Kaposi's sarcoma (rare)
- xix. Mycosis fungoides (rare)
- xx. Sarcoid (rare)
- xxi. Incontinentia pigmenti
- xxii. Toxicity to drugs, such as arsenic
- xxiii. Influenza (rare).

3. What are the nonsystemic conditions that may result in interstitial keratitis?

- i. Chemical burns
- ii. Chromium deficiency.

4. What is the most common cause of interstitial keratitis?

The most important cause is syphilis. Of this, 90% is due to congenital syphilis and rest is due to acquired syphilis.

5. When does interstitial keratitis develop in congenital syphilis?

It usually occurs about the age of 5 years to early teen and is bilateral in 80%.

2.9. MOOREN'S ULCER

1. Define Mooren's ulcer.

Mooren's ulcer is an idiopathic, painful, peripheral ulcerative keratitis (PUK).

2. What are the other names of Mooren's ulcer?

- i. Chronic serpiginous ulcer
- ii. Ulcus rodens.

3. What are the symptoms of Mooren's ulcer?

- a. Severe pain out of proportion to the size of the ulcer
- b. Decreased visual acuity due to
 - i. Central corneal involvement
 - ii. Irregular astigmatism
 - iii. Associated uveitis
 - iv. Perforation.

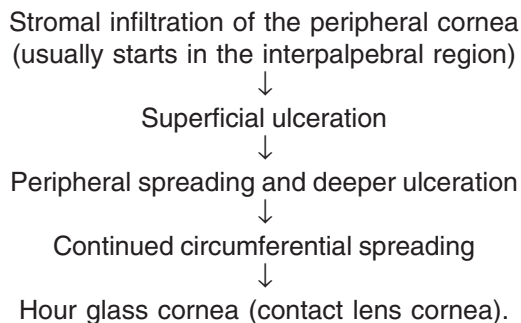
4. Who described Mooren's ulcer?

Mooren's ulcer was first described by Bowman in 1849, and then by McKenzie in 1854 as "chronic serpiginous ulcer of the cornea or *ulcus rodens*." Mooren's name, however, became attached to this rare disorder because of his publication of cases in 1863 and 1867. He was the first to clearly describe this insidious corneal problem and define it as a clinical entity.

5. Describe the clinical presentation of Mooren's ulcer.

The initial presentation is a stromal infiltration of the peripheral cornea. The limbus is involved in contrast to the other PUK's caused by rheumatoid arthritis and SLE.

The clinical course of the ulcer is as follows:



6. Describe the two clinical types of Mooren's ulcer.

Type 1:

- i.. Occurs in older individuals
- ii.. Unilateral
- iii.. Mild to moderate symptoms

Type 2:

- i. Occurs in younger individuals, usually common among the black population
- ii. Bilateral and associated with worm infestation
- iii. Generally responds poorly to therapy.

7. What are the anatomic and physiological differences between the center and the periphery of the cornea?

Central cornea	Peripheral cornea
Avascular	Close to limbal vessels
No inflammatory cells	Inflammatory cells like Langerhans' cells are present
More prone for infectious disorders	More prone for inflammatory and immune mediated disorders

8. Describe the entities associated with Mooren's ulcer.

Different entities have been described in association with Mooren's ulcer but none of the lesions have been proved to have causal relationship with Mooren's ulcer. Mooren's ulcer is seen associated with

- i. Helminthiasis
- ii. Hepatitis C infection
- iii. Herpes zoster
- iv. Herpes simplex
- v. Syphilis
- vi. Tuberculosis
- vii. Corneal trauma
- viii. Foreign bodies
- ix. Chemical trauma
- x. Surgical procedures like cataract extraction and PKP.

9. Name few differential diagnosis for Mooren's ulcer (or PUK).

- i. **Autoimmune disorders like**
 - a. Rheumatoid arthritis,
 - b. Wegener's granulomatosis,
 - c. Polyarthritits nodosa,
 - d. Inflammatory bowel disease,
 - e. Giant cell arthritis.
- ii. **Collagen vascular disorders like**
 - a. SLE
 - b. Relapsing polychondritis
 - c. Systemic sclerosis.
- iii. **Corneal degenerative conditions like**
 - a. Terrien's marginal keratitis
 - b. Pellucid marginal degeneration.
- iv. **Infectious causes like**
 - a. Herpes simplex keratitis
 - b. *Acanthamoeba* keratitis
 - c. Bacterial keratitis.

10. How do we differentiate Mooren's ulcer and PUK caused by rheumatoid arthritis?

Rheumatoid arthritis is a frequent cause of PUK. The clinical picture of PUK in RA is not characteristic to RA but frequently it is associated with scleritis. Other associated ophthalmic findings include keratoconjunctivitis sicca (the most common ophthalmic finding), episcleritis, and sclerosing keratitis. Advanced systemic involvement is usually apparent at time of ocular involvement. The patient's clinical profile and positive serologic studies, in particular rheumatoid factor, will help establish the appropriate diagnosis.

11. Describe the ophthalmic manifestations of Wegener's granulomatosis.

Wegener's granulomatosis is a rare multisystem granulomatous necrotizing vasculitis with upper and lower respiratory tract and renal involvement. Ocular involvement may be seen in upto 58% of patients, including proptosis due to orbital involvement, scleritis with or without PUK, PUK alone, uveitis, and vasculitis. Orbital involvement and scleritis are the most common ophthalmic manifestations. Prompt diagnosis is imperative because the initiation of immunosuppressive therapy, such as cyclophosphamide, can be both sight and life saving. Serum antinuclear antibody titers are raised in cases of Wegener's granulomatosis.

12. How is Terrien's marginal degeneration and other corneal degenerations differentiated from Mooren's ulcer?

Terrien's marginal degeneration differs from Mooren's ulcer in that it is typically painless, does not ulcerate and is usually noninflammatory. The disease is usually bilateral but may be asymmetrical. Terrien's degeneration usually begins in the superior cornea, in contrast to Mooren's ulcer, which typically begins in the interpalpebral region as a fine, punctate, stromal opacity. A clear zone exists between the infiltrate and the limbus, which becomes superficially vascularized. Slowly progressive thinning follows. The thin area has a sloping peripheral border and a sharp central edge that is highlighted by a white lipid line. The epithelium remains intact, although bulging of thin stroma causes significant astigmatism.

13. How is pellucid marginal degeneration differentiated from Mooren's ulcer?

Pellucid degeneration causes bilateral, inferior corneal thinning that leads to marked, irregular, against-the-rule astigmatism. Pain and inflammation are lacking and the epithelium is intact, thus differentiating it from Mooren's ulcer.

14. Describe the pathology of Mooren's ulcer.

The histopathology of Mooren's ulcer suggests an immune process. The involved limbal cornea consisted of three zones.

- i. The superficial stroma is vascularized and infiltrated with plasma cells and lymphocytes. In this region, there is destruction of the collagen matrix. Epithelium and Bowman's layer are absent.

- ii. The midstroma shows hyperactivity of fibroblasts with disorganization of the collagen lamellae.
- iii. The deep stroma is essentially intact but contains a heavy macrophage infiltrate. Descemet's membrane and the endothelium are spared.

Heavy neutrophil infiltration, as well as dissolution of the superficial stroma are present at the leading edge of the ulcer. These neutrophils show evidence of degranulation. The adjacent conjunctiva shows epithelial hyperplasia and a subconjunctival lymphocytic and plasma cell infiltration. Frank vasculitis is not present, and numerous eosinophils may present in the nearby involved conjunctiva during the course of healing.

15. Describe the pathophysiology of Mooren's ulcer.

The precise pathophysiological mechanism of Mooren's ulceration remains unknown, but there is much evidence to suggest that it is an autoimmune process, with both cell-mediated and humoral components.

On pathological examination plasma cells, neutrophils, mast cells and eosinophils have been found in the involved areas. High levels of proteolytic enzymes are found in the affected conjunctiva. Numerous activated neutrophils are found in the involved areas and these neutrophils are proposed to be the source of the proteases and collagenases that degrade the corneal stroma.

16. What are the investigations done to diagnose a case of Mooren's ulcer?

Mooren's ulcer is a diagnosis of exclusion.

Infectious etiologies should be excluded by appropriate smears and cultures.

This investigation may include a complete blood count with evaluation of the differential count, platelet count – baseline investigations done before starting immunosuppressive therapy.

- i. Erythrocyte sedimentation rate – marker of systemic inflammatory activity
- ii. Rheumatoid factor – to rule out rheumatoid associated PUK
- iii. Complement fixation, antinuclear antibodies (ANA)—to rule out SLE
- iv. Antineutrophil cytoplasmic antibody (ANCA) – to rule out Wegener's granulomatosis
- v. Circulating immune complexes, liver function tests
- vi. VDRL and fluorescent treponemal antibody absorption (FTA-ABS) tests—syphilis
- vii. Blood urea nitrogen and creatinine
- viii. Serum protein electrophoresis
- ix. Urinalysis
- x. Chest roentgenogram
- xi. Additional testing is done as indicated by the review of systems and physical examination.

17. Describe the stepwise management of Mooren's ulcer.

The overall goals of therapy are to arrest the destructive process and to promote healing and re-epithelialization of the corneal surface. Most experts agree on a stepwise approach to the management of Mooren's ulcer, which is outlined as follows:

a. Topical steroids

Controlling inflammation by topical 1% prednisolone acetate in an hourly basis and tapering it over time, depending on the clinical response. This has to be supplemented with cycloplegic agents and anti-inflammatory drugs to reduce pain and inflammation

b. Conjunctival resection**c. Systemic steroids and immunosuppressives**

Prednisolone (1mg/kg body wt) after assessing systemic factors like diabetes mellitus, tuberculosis and other immunosuppressive diseases.

d. Additional surgical procedure (tectonic grafting)**e. Rehabilitation.****18. When is conjunctival resection advocated?**

If the ulcer progresses despite the steroid regimen, conjunctival resection should be performed.

19. What is the rationale for performing conjunctival resection?

The rationale of this procedure is that the conjunctiva adjacent to the ulcer contains inflammatory cells that may be producing antibodies against the cornea and cytokines which amplify the inflammation and recruit additional inflammatory cell.

20. How is conjunctival resection performed?

Under topical and subconjunctival anesthesia, this consists of conjunctival excision to bare sclera extending at least 2 clock hours to either side of the peripheral ulcer, and approximately 4 mm posterior to the corneoscleral limbus and parallel to the ulcer. The overhanging lip of ulcerating cornea may also be removed. Postoperatively, a firm pressure dressing should be used.

21. What are other surgical procedures advocated at the second step?

Cryotherapy of limbal conjunctiva, conjunctival excision with thermo-coagulation, keratoepithelioplasty, application of isobutyl cyanoacrylate.

22. What is keratoepithelioplasty?

In this procedure, donor corneal lenticles are sutured onto the scleral bed after conjunctival excision.

23. What is the rationale of keratoepithelioplasty?

It is postulated that the lenticles form a biological barrier between host cornea and the conjunctiva and the immune components it may carry.

24. When is systemic immunosuppression indicated?

The cases of bilateral or progressive Mooren's ulcer that fail the preceding therapeutic attempts will require systemic cytotoxic chemotherapy to bring a halt to the progressive corneal destruction.

25. What are the agents commonly used for systemic immunosuppression?

The most commonly used agents are cyclophosphamide (2 mg/kg/day), methotrexate (7.5 to 15 mg once weekly), azathioprine (2 mg/kg body weight/day) and oral cyclosporine A (10 mg/kg/day).

26. When is superficial lamellar keratectomy done and how is it useful?

It is done when all the steps of management fails. It arrests the inflammatory process and allows healing of stroma. After healing, corneal grafting can be done on a later date.

27. When is PKP done in cases of Mooren's ulcer?

An initial tectonic graft is done in the peripheral cornea to strengthen the peripheral cornea. In case the central cornea is involved, a large graft can be performed.

28. How is PKP done in these patients?

In these patients, a 13 mm tectonic corneal graft is first sutured in place of interrupted 10-0 nylon or prolene sutures with the recipient bite extending into the sclera so that the suture will not pull through the thin host cornea and then a 7.5 or 8.0 mm therapeutic graft is placed.

29. What are the common complications of PKP?

Associated cystoid macular edema and glaucoma may cause defective vision in patients undergoing PKP.

2.10. BAND-SHAPED KERATOPATHY

1. What are the normal age-related changes of cornea?

- i. Flattening in the vertical meridian, leading to increased astigmatism (against the rule)
- ii. Decrease in thickness of cornea
- iii. Increase in the thickness of Descemet's membrane
- iv. Arcus senilis
- v. Decrease in the endothelial cell count and decrease in luster.

2. What is band-shaped keratopathy?

Deposits of calcium and hydroxyapatite in the basement membrane of epithelium, Bowman's and superficial stroma, usually in the interpalpebral area is called as band-shaped keratopathy (also known as band keratopathy).

3. What are the causes of band keratopathy?

I. Chronic ocular disease

- Chronic non-granulomatous uveitis—juvenile rheumatoid arthritis
- Prolonged glaucoma (absolute)
- Longstanding corneal edema
- Phthisis bulbi
- Spheroidal degeneration Norrie's disease—interstitial keratitis

II. Hypercalcemia

- Hyperparathyroidism—primary and tertiary
- Vitamin D excess
- Milk alkali syndrome
- Sarcoidosis

III. Normocalcemia—with elevated serum phosphorus

IV. Hereditary with or without other anomalies

V. Idiopathic

VI. Chronic exposure to mercury

- Vapors
- Eyedrops due to the preservative phenyl-mercuric nitrate/acetate occurs only after months or years of usage. Can be central or peripheral

VII. Hereditary

VIII. Silicon oil instillation in aphakic eye.

4. What is the pathogenesis of band-shaped keratopathy?

Deposits often begin in the periphery and extends to involve the visual axis, thus occupying the interpalpebral area. The deposits are central in cases of chronic ocular inflammation.

Precipitation of calcium salts are due to:

- i. Increase in Ca and P levels
- ii. Increase in pH due to uveitis, evaporation of tears and loss of Ca.
- iii. Concentration by evaporation and thus dry eye is a predisposing factor.

Whole process is compounded by lack of blood vessels, hence preventing the buffering ability of blood serum to inhibit variations in tissue pH.

Small holes are noticed throughout representing areas in which corneal nerves penetrate Bowman's layer giving a "swiss cheese appearance."

5. What are the histopathologic findings in a case of band keratopathy?

- i. Basophilic staining of the basement membrane of the epithelium.
- ii. Calcium deposits in the Bowman's and anterior stroma, which coalesce resulting in fragmentation and destruction of Bowman's membrane
- iii. The deposits are initially gray and flat. But with progression they become white and elevate the epithelium.
- iv. The calcium is deposited intracellularly in systemic hypercalcemia
- v. Fibrous pannus separates the Bowman's and epithelium.

6. What are the signs and symptoms of band keratopathy?

Early stages—Asymptomatic

Late stages:

a. Decrease in visual acuity due to

- ↓ In transparency
- Band across the papillary area

b. Irritation and foreign body sensation when the deposits either break or elevate the epithelium

- Tearing and photophobia
- Calcium may flake off

7. What are the differential diagnoses of band keratopathy?

- i. Calcareous degeneration of cornea is a similar process that involves all layers of cornea.
- ii. Phthisis bulbi
- iii. Intraocular neoplasm
- iv. Extensive trauma.

8. What are the indications of treatment?

- When visual acuity is decreased
- Mechanical irritation of lids
- Epithelial breakdown.

9. What are the methods of treatment?

Treat the cause of the disease, if known. In addition, the following may be done:

Method – I

- 4% cocaine applied over the cornea. Cocaine facilitates the removal of epithelium.

- EDTA (Ethylene diamine tetra-acetic acid) is dropped from a 1.5 cm syringe well, and allowed to stand for a minute.
- Cornea is then scraped with kimura spatula or scalpel blade until the band is removed

Method – II

- EDTA is placed on a small strip of cellulose sponge.
- Diamond bud is used to polish off the cornea.

If there is no EDTA just anesthetize the cornea and scrape with blade until all gritty feeling material is removed.

Patching in the form of soft contact lenses and collagen shields along with cycloplegics and mild antibiotic are used until re-epithelialization.

Excimer laser phototherapeutic keratectomy can be tried only on smoother lesions.

2.11. ADHERENT LEUKOMA

1. What are the types of corneal opacities?

- i. Nebular (Nebula) corneal opacity is slight opacification of cornea allowing the details of iris and pupil to be seen through corneal opacity
- ii. Macular (Macula) corneal opacity: It is more dense than nebular corneal opacity, through it details of iris and pupil cannot be seen but margins can be seen
- iii. Leukomatous (Leukoma) corneal opacity: It is very dense, white totally opaque obscuring view of iris and pupil totally.

2. What is adherent leukoma?

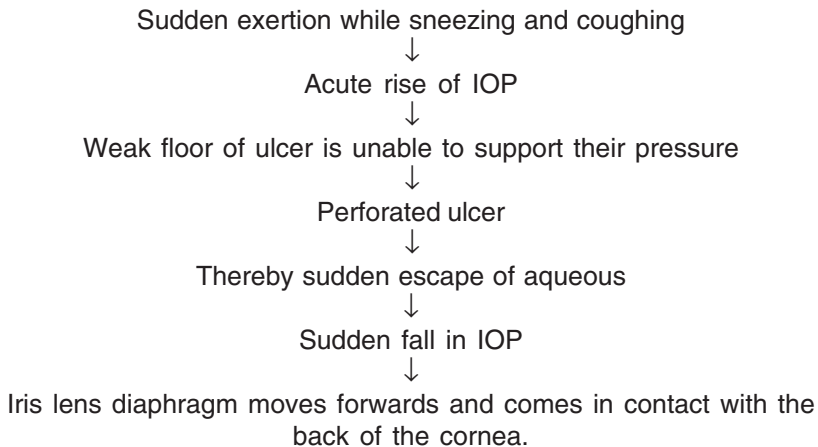
- It is a leukomatous opacity in which the iris tissue is incarcerated within the layer of cornea.

3. What are causes of adherent leukoma?

- i. Perforated corneal ulcer
- ii. Penetrating injury
- iii. Operating wound

4. What is the mechanism of development of an adherent leukoma?

In a cornea which is structurally weak, either due to acute infection or old scar with thinning, the following events might take place



5. What are signs and symptoms of adherent leukoma?

Symptoms: *Visual acuity* is decreased if the adherent leukoma affects the central visual axis. In case of peripheral lesions, there may be a chance of *astigmatism*.

Signs:

- i. Corneal surface is flat, leukomatous and has decreased corneal sensation
- ii. There may be brown pigments dispersed from the iris on the back of the cornea
- iii. The depth of the anterior chamber is irregular
- iv. The pupil is irregular in shape and drawn towards the adhesion
- v. The intraocular pressure may be raised.

6. What are the other complications associated with adherent leukoma?

- i. Perforation
- ii. Pseudocornea formation
- iii. Staphyloma formation
- iv. Ectatic cicatrix
- v. Atheromatus ulcer
- vi. Endophthalmitis
- vii. Panophthalmitis
- viii. Expulsive hemorrhage
- ix. Phthisis bulbi.

7. What are the advantages of perforation in a case of corneal ulcer?

- i. Pain is reduced due to lowering of IOP and egress of hypopyon
- ii. Rapid healing of the ulcer.

8. What are the reasons of phthisis bulbi?

- i. Large perforation may cause extrusion of the contents of the eyeball leading to shrinkage
- ii. Repeated corneal ulcer perforations may be sealed by exudates which may leak leading to fistula formation.

9. How do you do tattooing?

- i. After removing the epithelium, a piece of blotting paper of the same size as the opacity, soaked in fresh 2% platinum chloride solution, is kept over the opacity.
- ii. On removing this filter paper, few drops of fresh 2% hydrazine hydrate solution are applied over the area which in turn becomes black.
- iii. Eye is washed with saline.
- iv. A drop of parolein is instilled and a pad and bandage applied.
- v. The epithelium grows over the black colored deposit of platinum.

10. What is the treatment of choice of adherent leukoma?

- i. Optical iridectomy
- ii. Penetrating keratoplasty
- iii. Tattooing and synechotomy.

11. What is treatment for anterior staphyloma?

- i. Staphylectomy
- ii. Enucleation and prosthesis fitting.

12. What is the treatment for corneal fistula?

- i. Cyanoacrylate glue application
- ii. Bandage contact lens
- ii. Penetrating keratoplasty.

13. What is treatment of choice for panophthalmitis?

- Evisceration and prosthesis

	Anterior synechia	Leukoma	Adherent Leukoma	Anterior staphyloma
• Definition	Adhesion between iris and cornea	Dense white opacity of cornea	Adhesion between iris and leukoma	Adhesion between iris and ectatic leukoma
• Etiology	<ul style="list-style-type: none"> • Perforated corneal ulcer • Iridocyclitis • Closed angle glaucoma 	<ul style="list-style-type: none"> • Healed corneal ulcer • Healed keratitis • Penetrating injury • FB • Corneal dystrophy 	<ul style="list-style-type: none"> • Perforated corneal ulcer • Penetrating injury • Operating wound 	<ul style="list-style-type: none"> • Perforated corneal ulcer • Penetrating injury • Operating wound
• Visual acuity	Normal	Impaired	Impaired	Impaired
• Corneal surface	Flat	Flat	Flat	Ectatic
• Pigments	Nil	Fine yellowish brown lines in the epithelium,	Brown pigment from iris are present	Brown pigment from iris are present
• Anterior chamber	Normal or shallow	Normal	Irregular or shallow	Absent or very shallow
• Pupil	Normal	Normal	Drawn towards adhesion	Not seen
• Corneal Sensation	Normal	Impaired	Impaired	Impaired
• Intraocular tension	Normal or raised (Closed angle glaucoma)	Normal	Normal or raised (Secondary glaucoma)	Raised

2.12. BOWEN'S DISEASE

1. What are the old terms to describe Bowen's disease?

- i. Intraepithelial epithelioma
- ii. Bowenoid epithelioma.

2. What are the new terms?

- i. Ocular surface squamous neoplasia (OSSN)
- ii. Conjunctival intraepithelial neoplasia (CIN)
- iii. Corneal intraepithelial neoplasia.

3. What is the common site of involvement?

Interpalpebral fissure, mostly at limbus.

4. How does Bowen's disease present?

Typically, a patient presents with an isolated, slightly elevated, erythematous lesion with well demarcated borders that fail to heal. Lesion has appearance of a second degree burn, does not bleed or itch and is devoid of hairs.

5. What are the clinical forms of Bowen's disease?

- i. Gelatinous
- ii. Papilliform
- iii. Leukoplakic
- iv. Nodular
- v. Diffuse.

6. Which form masquerades as chronic conjunctivitis?

Diffuse form.

7. What are the risk factors?

- i. Exposure to sunlight
- ii. Human papilloma virus
- iii. Chronic inflammatory diseases—benign mucous membrane pemphigoid, chronic blepharoconjunctivitis
- iv. Ocular surface injury
- v. Exposure to chemicals—trifluridine, arsenic, petroleum products, cigarette smoking
- vi. HIV
- vii. Solar keratosis.

8. What is limbal transition zone/stem cell theory?

Cells in limbal area have highly proliferating and long living property. Any alteration in this area causes abnormal maturation of conjunctival and corneal epithelial cells leading to OSSN.

9. How do you differentiate squamous dysplasia from carcinoma *in situ*?

Squamous dysplasia: Atypical cells involve only part of epithelium

Carcinoma *in situ*: Atypia involves throughout epithelium, not involving the basement membrane.

10. What is the histopathological hallmark of Bowen's disease?

Histopathological hallmark of Bowen's disease is lack of penetration of cancerous cells into the dermis.

11. How does squamous cell carcinoma present?

Average age of presentation of squamous cell carcinoma between 68–73 years, but primary squamous cell carcinoma in younger patients may be seen in those who are immunosuppressed.

They may present as:

- i. Painless plaque/nodules with variable degree of scale, crust and ulceration.
- ii. Papillomatous growths/cutaneous horns/cysts along the lid margins.

12. What are various histopathological types of OSSN?

- i. Dysplastic *lesions*
- ii. Carcinoma *in situ*
- iii. Squamous cell carcinoma
- iv. Spindle cell variant
- v. Mucoepidermoid carcinoma
- vi. Adenoid squamous carcinoma.

13. Describe spindle cell variant.

It exhibits spindle shaped cells that may be difficult to distinguish from fibroblasts. Positive immunohistochemical staining for cytokeratin confirms epithelial nature.

14. Describe mucoepidermoid carcinoma.

It is a variant of conjunctival squamous cell carcinoma that in addition to squamous cells shows mucous secreting cells (stain positively with special stains for mucopolysaccharides such as muciramine, alcian blue, and colloidal iron.)

15. Describe adenoid squamous cell carcinoma.

It is an aggressive variant with extracellular hyaluronic acid but no intracellular mucin and invades eyeball. Metastasis to distant sites is common.

16. From where does corneal OSSN arise?

It is controversial. Some investigators suggest that corneal epithelium may undergo dysplastic and cancerous changes, whereas others believe that origin is in limbus.

17. When do you suspect intraocular invasion?

It is often heralded by the onset of low grade inflammation and secondary glaucoma. It is common in older patients.

18. What are the common sites of metastasis?

- i. Preauricular, submandibular, cervical lymph nodes
- ii. Parotid
- iii. Lungs
- iv. Bones
- v. Distant organs.

19. What is exfoliative cytology?

Using a platinum spatula, brush and cotton wool tip, cells are obtained from conjunctival surface, followed by Papanicolaou and Giemsa stains.

20. What are advantages and disadvantages of exfoliative cytology?***Advantages***

- i. Nature of lesion—benign or malignant
- ii. Sampling from multiple sites
- iii. DNA of cells can also be obtained.

Disadvantages

- i. Superficial nature of sample, sometimes containing only keratinized cells.

21. What is impression cytology?

It is a method of obtaining cells from conjunctival lesions in which filter paper such as cellulose acetate, millipore filter or biopore membrane are placed over ocular surface to sample superficial cells and then stained by Papanicolaou smear.

22. What is the treatment?

Localized lesion: Excision with autologous conjunctival or limbal transplantation or amniotic membrane graft (Mohs micrographic technique)

Diffuse

- i. Topical mitomycin 0.02% twice a day for 15 days followed by a relapsing period

5-FU

- ii. Interferon (alternative or adjunct to surgery)
- iii. Very large tumors—enucleation
- iv. Orbital involvement—exenteration.

23. What are the other treatment modalities available?

- i. Cryotherapy
- ii. Brachytherapy.

24. What is the mechanism of cryotherapy?

It obliterates micro circulation by lowering temperature within tissues resulting in ischemic necrosis of tumor cells.

25. What are the side effects of cryotherapy?

- i. Iritis
- ii. Increase or decrease in intraocular pressure
- iii. Inflammation
- iv. Edema and corneal scarring
- v. Sector iris atrophy
- vi. Ablation of peripheral retina
- vii. Ectropion
- viii. Superficial corneal vascularization

26. What are the commonly used radioactive materials in brachytherapy?

- i. Strontium 90
- ii. Ruthenium 106
- iii. Gamma radiation.

27. What are the complications of brachytherapy?

- i. Conjunctivitis
- ii. Dry eye
- iii. Scleral ulceration
- iv. Corneal perforation
- v. Cataract.

2.13. KERATOCONUS

1. Name a few corneal ectatic conditions.

Keratoconus, keratoglobus, pellucid marginal degeneration, Terrien's marginal degeneration.

2. What are the signs of keratoconus?

A. External signs

Munson's sign
Rizzuti phenomenon

B. Slit lamp findings

Stromal thinning
Posterior stress lines (Vogt's striae)
Iron ring (Fleischer's ring)
Scarring—epithelial or subepithelial

C. Retroillumination signs

Scissoring on retinoscopy
Oil droplet sign ("Charleaux")

D. Photokeratography signs

Compression of mires inferotemporally
("egg-shaped" mires)
Compression of mires inferiorly or centrally

E. Videokeratography signs

Curvature map
Localized increased surface power > 47D
Inferior superior dioptric asymmetry > 1.4D
Relative skewing of the steepest radial axes above and below the horizontal meridian
Elevation map
Maximum elevation difference in posterior float > 50 μ
Pachymetry map
Thinnest < 480 μ .

3. Which gender is commonly affected by keratoconus?

Keratoconus has been seen a bit more commonly in males than in females.

4. What are the biochemical alternations seen in corneas with keratoconus?

Various abnormalities suggested include:

- i. Decreased levels of glucose-6-phosphate dehydrogenase (G6PD)
- ii. Relative decrease in hydroxylation of lysine and glycosylation of hydroxylysine
- iii. Decrease in total collagen and a relative increase in structural glycoprotein
- iv. In patients with keratoconus, keratan sulfate is decreased and its structure is modified

- v. The ratio of dermatan sulfate to keratan sulfate is increased in keratoconus
- vi. Decrease in matrix metalloproteinase (MMP) inhibitors leading on to increased collagenolytic activity
- vii. There is a decreased level of α 1 proteinase inhibitor, tissue inhibitor of metalloproteinase (TIMP)-1 and α 2 macroglobin levels in keratoconus cornea
- viii. The loss of anterior stromal keratinocytes is due to apoptotic cell death
- ix. Keratinocytes have fourfold increased expression of interleukin-1 (IL1) receptors. Interleukin-1 is released from epithelial and endothelial cells and IL-1 can cause loss of keratinocytes through apoptosis and loss of corneal stroma over a period of time.

5. What is Munson's sign?

Munson's sign is a V-shaped conformation of the lower lid produced by the ectatic cornea in down gaze.

6. What is Rizzuti's sign?

Conical reflection on the nasal cornea when a penlight is shown from the temporal side.

7. What are Vogt's striae?

Vogt's striae are fine vertical lines in the deep stroma and Descemet's membrane that parallel the axis of the cone and disappear transiently on gentle digital pressure.

8. What are Fleischer's rings?

The Fleischer ring is a yellow-brown to olive-green ring of pigment, which may or may not completely surround the base of the cone. The deposition occurs at the level of basal epithelium. Locating this ring initially may be made easier by using a cobalt filter and carefully focusing on the superior half of the corneal epithelium. Once located, the ring should be viewed in white light to assess its extent.

9. What is the clinical significance of Fleischer's ring?

It delineates the extent of the base of the cone of the keratoconus, which helps to mark the recipient during the penetrating keratoplasty.

10. What is acute hydrops?

The acute hydrops is caused by breaks in Descemet's membrane with stromal imbibition of aqueous through these breaks. The edema may persist for weeks or months, usually diminishing gradually, with relief of pain and resolution of the redness and corneal edema ultimately being replaced by scarring.

11. How is acute hydrops treated?

Acute hydrops is not an ophthalmic emergency and is treated conservatively with topical hypertonic agents, patching or soft contact lens and mild cycloplegics. The edema usually resolves within a few months.

12. What is the visual prognosis following healing of acute hydrops?

Acute hydrops usually heals by scarring. The scarring can flatten the cornea and decrease the astigmatism. The flattened cornea can be fitted with a contact lens easier.

13. Describe scissoring reflex on retinoscopy.

Scissoring reflex is appreciated well with dilated pupil. The central part of the cone is hypermetropic with regards to its periphery which is myopic. The scissoring reflex is produced due to presence of two conjugate foci in pupillary axis and high astigmatism.

During retinoscopy when the neutralization point is approached, the central zone produces a hypermetropic reflex which moves with the streak and the peripheral zone produces a myopic reflex which moves against the streak which produces the appearance of scissoring reflex.

14. Describe oil droplet sign.

It is seen with a dilated fundus examination. It is an annular dark shadow separating the bright reflex of the central and peripheral areas. It occurs due to complete internal reflection of the light.

15. What is swirl staining of cornea?

Swirl staining may occur in patients who have never worn contact lenses because basal epithelial cells drop out and the epithelium slides from the periphery as the cornea regenerates. Thus, a hurricane, vortex or swirl stain may occur.

16. What is forme-fruste keratoconus?

Forme fruste-keratoconus or subclinical keratoconus is a clinical entity in which there is no frank clinical sign of keratoconus. However, the cornea is at risk of developing keratoconus at a later stage and can be diagnosed only by videokeratography. Cornea is considered suspicious when:

- i. The central keratometry is more than 47.0D
- ii. There is presence of an oblique astigmatism of $>1.5D$ and
- iii. Superior-inferior curvature disparity of $>1.4D$ on videokeratography.
- iv. The Massachusetts Eye and Ear Infirmary Keratoconus classification is currently used to detect cases of forme-fruste keratoconus and variable grades of clinical keratoconus.

17. What are the systemic disorders associated with keratoconus?

- i. Crouzon's syndrome
- ii. Down's syndrome
- iii. Laurence-Moon-Bardet-Biedl syndrome
- iv. Marfan's syndrome
- v. Nail-patella syndrome
- vi. Neurofibromatosis

- vii. Osteogenesis imperfecta
- viii. Pseudoxanthoma elasticum
- ix. Turner's syndrome
- x. Xeroderma pigmentosa.

18. What are the ocular associations of keratoconus?

Can be classified into corneal disorders and noncorneal disorders.

Corneal disorders	Noncorneal disorders
Atopic keratoconjunctivitis	Retinitis pigmentosa
Axenfeld's anomaly	Vernal conjunctivitis
Corneal amyloidosis	Congenital cataracts
Essential iris atrophy	Leber's congenital amaurosis
Fuch's corneal dystrophy	Gyrate atrophy
Microcornea	Posterior lenticonus
Lattice dystrophy	Aniridia

19. Why is keratoconus commonly associated with Leber's congenital amaurosis and Down's syndrome?

These two disorders are associated with increased incidence of eye rubbing. This is due to increased incidence of blepharitis in Down's syndrome and oculodigital sign in Leber's congenital amaurosis. Recent study by Elder suggests that the association might be due to genetic factors rather than eye rubbing.

20. What is the role of contact lens wear in causing keratoconus?

Contact lenses are suggested as a source of mechanical trauma to the cornea. It is extremely difficult to determine which came first, the contact lens wear or the keratoconus. It is possible that mechanical rubbing and hard contact lens wear can act as environmental factors that enhance the progression of the disorder in genetically predisposed individuals.

21. Describe the three types of cones seen in keratoconus.

- A. Nipple cone—small in size (< 5 mm)
 - i. Steep curvature
 - ii. Apical centre usually lies central or paracentral
 - iii. Easiest to fit with contact lens
- B. Oval cone—larger (5–6 mm) ellipsoid displaced inferotemporally.
- C. Globus cone—larger (> 6 mm) may involve more than 75% of the cornea.
 - i. Most difficult to fit with contact lenses.

22. What is posterior keratoconus?

It's a congenital corneal anomaly unrelated to keratoconus which is characterized by protrusion of posterior corneal surface into the stroma and is usually sporadic, unilateral and nonprogressive.

23. What are Rabinowitz's criteria for diagnosis of keratoconus?

- i. Keratometry value $> 47.2D$
- ii. Steepening of inferior cornea compared with the superior cornea of $> 1.2D$
- iii. Skewing of the radial axis of astigmatism by greater than $21D$
- iv. Difference in central power of more than $1D$ between the fellow eye.

24. Describe the histopathology of corneas in keratoconus.

Thinning of corneal stroma, breaks in Bowman's layer and deposition of iron in the basal layer of the corneal epithelium comprise a triad of the classic histopathologic features found in keratoconus.

A. Epithelium—Degeneration of basal cells

- Breaks accompanied by downgrowth of epithelium into Bowman's layer
- Accumulation of ferritin particles within and between basal epithelial cells

B. Bowman's layer—Breaks filled with eruptions of underlying stromal collagen

- Reticular scarring

C. Stroma—Compactions and loss of arrangement of fibrils in the anterior stroma

- Decrease in number of collagen lamellae

D. Descemet's membrane—Rarely affected except in cases with acute hydrops**E. Endothelium**—Usually normal.**25. Classify keratoconus based on keratometry.**

- i. Mild $< 45D$ in both meridians
- ii. Moderate $45\text{--}52D$ in both meridians
- iii. Advanced $> 52D$ in both meridians
- iv. Severe $> 62D$ in both meridians.

26. How is a case of keratoconus managed?

- i. Glasses
- ii. Contact lenses
- iii. Collagen cross linking
- iv. Intracorneal rings
- v. Deep anterior lamellar keratoplasty (DALK)
- vi. Penetrating keratoplasty (PKP)

27. What are the various types of contact lenses used in the management of keratoconus?

- i. Rigid gas permeable contact lens
- ii. Tricurve flex lens for nipple cone
- iii. Soper lens system
- iv. McGuire lens system
- v. Rose K design
- vi. Nicone design
- vii. Bausch and Lomb C series
- viii. Double posterior curve lenses
 - One central curve to fit the corneal apex
 - Another flatter curve peripheral to the central apical zone to fit the mid corneal periphery
- ix Piggy back lenses—gas permeable firm lens is fitted upon a soft lens or flex lens system of a hard lens fitted in to the groove of a soft lens.
Hard lens with a soft peripheral skirt.

28. What is ‘three point touch’ technique of contact lens fitting?

The lens lightly touches the peak of the cone, then a very low vault over the edges of the cone, and lastly a thin band of touching near the edge of the lens. The name “three-point touch” refers to the edge-peak-edge pattern of the lens touching the cornea. The lens is kept as small as is optically possible. Since the lens will center itself over the peak of the cone, an off-center cone needs a bigger lens than a centered cone.

29. What is the fluorescein pattern of a well-fit lens in a keratoconus patient?

- i. Slight central bearing
- ii. Intermediate pooling of tears
- iii. Peripheral bearing or touch over some portion of the lens circumference and perhaps slight peripheral lift at the steepest site of the cone.

30. What are SoftPerm lenses?

The SoftPerm lens is a hybrid lens with a rigid, gas-permeable center surrounded by a soft, hydrophilic skirt. This lens may be indicated for patients with displaced corneal apexes or for patients who cannot tolerate rigid lenses. However, in advanced keratoconus, in which a lens of larger diameter is useful, the lack of steep base curves in the SoftPerm lens (its steepest base curve is 6.5 mm) limits performance. In addition, the lens material has a low DK value (rigid lens, 14 DK; soft portion, 5.5 DK).

31. What is Soper lens system?

The objective of the Soper lens system is based on sagittal depth. The principle is that a constant base curve with an increased diameter results in increased sagittal depth and a steeper lens. The lenses included in the

fitting set are categorized as mild (7.5 mm diameter, 6.0 mm optic zone diameter), moderate (8.5 mm diameter, 7.0 mm optic zone diameter), and advanced (9.5 mm diameter, 8.0 mm optic zone diameter). The initial trial lens is selected on the basis of degree of advancement of the cone. The more advanced the cone, the larger the diameter of the recommended lens; the smaller and more centrally located the apex, the smaller the diameter of the lens.

32. What is thermokeratoplasty?

Thermokeratoplasty is corneal flattening by heat application, which may regularize the corneal surface. It is often used to flatten the cornea at the time of keratoplasty to make trephining easier.

33. What is epikeratoplasty?

A corneal lenticule is sewn over the keratoconus area, flattening the cone, reducing the myopic astigmatism and improving contact lens fit. It is preferred in conditions like Down's syndrome because of its noninvasive nature and decreased potential for corneal graft rejection.

34. What is excimer laser phototherapeutic keratectomy?

It is useful in management of patients with keratoconus who have nodular subepithelial corneal scars who are contact lens intolerant.

35. Why is prognosis of PKP good in cases of keratoconus?

- i. Absence of vascularization in the lesion
- ii. Keratoconus is a non-inflammatory ectatic condition.

36. What is collagen cross linkage?

Corneal collagen cross-linking using riboflavin is a noninvasive procedure which strengthens the weak corneal structure in keratoconus.

This technique works by increasing collagen cross-linking, which are the natural "anchors" within the cornea. Riboflavin eye drops are applied to the cornea, which is then activated by a ultraviolet (UVA) light. This increases the amount of collagen cross-linking in the cornea and strengthens the cornea. The technique uses riboflavin to create new bonds between the adjacent collagen molecules so that the cornea is about one-and-a-half times thicker and less malleable.

37. Explain the mechanism of action of collagen cross linkage.

Application of riboflavin on the cornea along with penetration for approximately 200 μm and irradiation of the riboflavin molecules through UVA leads to loss of the internal chemical balance of the riboflavin molecules, producing oxygen free radicals. The riboflavin molecule becomes unstable and stabilizes only when it is linked to two collagen fibrils. A cross bridge is created between the collagen fibrils (i.e. cross-linking) to produce a general strengthening of the cornea.

38. Compare and contrast the clinical features of keratoconus, keratoglobus and Terrien's marginal degeneration?

	Keratoconus	Keratoglobus	Terrien's	Pellucid
Age group	Progress during adolescence	Presents at at birth	Presents at 4 to 5th decade	Presents between 2–3rd decade
Appearance	Progressive thinning of central/para-central cornea	Globular deformation of entire cornea	Begins superiorly and spreads circumferentially	Causes inferior thinning of cornea
Vascularization	Absent	Absent	Forms pannus	Absent
Familial inheritance	Most cases are sporadic	Dominant inheritance with incomplete penetrance	Sporadic	Sporadic
Laterality	Bilateral, usually asymmetrical	Bilateral, usually asymmetrical	Unilateral or asymmetrically bilateral	Bilateral
Prognosis after PKP	Very favorable prognosis	Poor prognosis	Good prognosis after lamellar keratoplasty	Moderate

39. Which are surgical options for keratoconus treatment?

- i. Deep anterior lamellar keratoplasty (DALK)—Replaces only the stroma upto Descemet's membrane.
Advantages—Reduced chances for immune rejection since the endothelial layer is preserved.
Disadvantage—Technically difficult procedure.
 Visual quality may be inferior to PK because of interface irregularities and astigmatism.
- ii. Intracorneal ring segment insertion
- iii. Penetrating keratoplasty—In the presence of Descemet's scarring DALK cannot be done. A penetrating keratoplasty is the only choice for visual rehabilitation.

40. What are intracorneal rings?

Intracorneal ring segments are PMMA/silicon semicircular rings which are inserted in mid-peripheral stroma, which helps to reduce high refractive error and provides better fitting of cornea.

41. How do intracorneal rings intacs act?

Insertion of a ring of particular thickness in the mid-peripheral stroma will increase the thickness and corneal arc diameter. This will act like a hammock rod to cause central flattening. Two half ring segments are inserted on either side of the cone.

42. What are the causes of prominent corneal nerves?

Ocular causes:

- i. Keratoconus
- ii. Fuch's dystrophy
- iii. Congenital glaucoma

Systemic causes:

- i. Leprosy
- ii. Neurofibromatosis
- iii. Multiple endocrine neoplasia.

2.14. STROMAL DYSTROPHIES—CORNEA

1. What is the meaning of word dystrophy?

The word dystrophy is derived from the Greek word, *dys* = wrong, difficult; *trophe* = nourishment.

2. Define corneal dystrophy.

Corneal dystrophies are a group of inherited corneal diseases that are typically bilateral, symmetrical, and slowly progressive and without relationship to environmental or systemic factors, causing loss of clarity of one or more layers of cornea.

3. Define corneal degenerations.

Corneal degenerations may occur from physiological changes occurring from aging, or may follow an environmental insult such as exposure to ultraviolet light or secondary to a prior corneal disorder.

4. What are the differences between corneal dystrophy and degenerations?

	Dystrophy	Degenerations
1	Bilateral and symmetric	Unilateral or bilateral
2	Hereditary	Sporadic
3	Appears early in life	Occurs late in life and are considered as aging changes
4	Non-inflammatory	Inflammatory
5	Avascular and located centrally	Often eccentric and peripheral and are related to vascularity
6	Usually painless except in recurrent epithelial erosions	Mostly associated with pain
7	Systemic associations are rare	Local and systemic conditions are common association

5. Classify corneal dystrophies.

Classification according to the layers of cornea involved (anatomic) is most often used. Other classifications are based on genetic pattern, severity, histopathologic features or biochemical characteristics.

Layer	Descriptive term
Epithelium	1. Epithelial basement membrane dystrophy (EBMD) (Map-dot fingerprint, Cogan's microcystic) 2. Messman's (Juvenile epithelial) dystrophy
Bowman's layer	1. CDB I & II Reis-Bucklers dystrophy (Corneal dystrophy of Bowman's layer, type I)

Contd...

Contd...

Layer	Descriptive term
	Theil-Behnke dystrophy (Corneal dystrophy of Bowman's layer, type II)
Stroma	<ol style="list-style-type: none"> 1. Granular dystrophy Type I Type II 2. Lattice dystrophy Type I (Biber-Haab-Dimmer) Type II (Meretoja syndrome) Type III 3. Avellino corneal dystrophy (Combined granular-lattice) 4. Macular dystrophy Type I Type II 5. Gelatinous drop like dystrophy (Primary familial amyloidosis) 6. Schnyder crystalline corneal dystrophy 7. Fleck dystrophy 8. Central cloudy dystrophy of Francois 9. Congenital hereditary stromal dystrophy
Endothelium	<ol style="list-style-type: none"> 1. Posterior polymorphous dystrophy (PPMD) 2. Fuch's hereditary endothelial dystrophy 3. Congenital hereditary endothelial dystrophy (CHED I & II)

6. What is the age of presentation of the corneal dystrophies?

Most dystrophies become clinically apparent by second decade of life. There are some that may present in the first few years of life like epithelial basement membrane dystrophy and others like Fuch's dystrophy, which may not become symptomatic until very late in life.

7. What is the mechanism of decreased vision in dystrophies?

- i. Intraocular light scattering in the initial stages
- ii. Disruption of geometric image caused by the corneal deposits and by the anterior corneal surface
- iii. Recurrent corneal erosions and resultant subepithelial scarring
- iv. Opacities causing obstruction to light
- v. By affecting normal endothelial function as in CHED, Fuch's dystrophy, etc.

8. What are the types of dystrophies affecting vision?

- i. Macular dystrophy
- ii. Lattice dystrophy
- iii. Central crystalline
- iv. Congenital hereditary endothelial dystrophy
- v. Fuch's dystrophy

9. What are the types of dystrophies not affecting vision?

- i. Granular
- ii. Fleck dystrophy.

10. What are the modes of inheritance of corneal dystrophies?

Most of them are inherited as autosomal dominant except

- i. Macular (autosomal recessive)
- ii. Congenital hereditary endothelial dystrophy (type II)
- iii. Posterior polymorphous (rarely autosomal recessive)
- iv. Type III lattice (recessive).

11. What is the frequency of recurrence of stromal dystrophy in a graft?

Among the stromal dystrophies frequency of re-graft is highest in lattice dystrophy, followed by granular dystrophy, and then macular dystrophy. Of all the dystrophies the recurrence is very high for Gelatinous drop like dystrophy.

12. Why is Avellino corneal dystrophy named so?

It was originally described in a small number of families who traced their roots to a place Avellino, in Italy. It is a combination of lattice and granular dystrophies.

13. How is granular dystrophy inherited?

An autosomal dominant transmission with variable expression. Linked to chromosome 5q31, along with lattice, Avellino and Reis-Bucklers dystrophy.

14. What are the features of granular dystrophy?

- i. Bilaterally symmetric and affects the central cornea
- ii. Glare and photophobia due to light scatter by the opacities
- iii. Vision remains normal in till around 40 years. In an affected patient, a diffuse, and irregular, ground-glass haze may appear in the superficial stroma.
- iv. It is characterized by the discrete, white dense; round to oval granular opacities lie in the relatively clear stroma and form a variety of patterns, including arcuate chains and straight lines. *The intervening and peripheral areas of cornea are clear.*
- v. They are characterized by focal extracellular aggregates of eosinophilic material occupying all levels of the stroma
- vi. A mutation in the BIGH3 gene localized to chromosome 5q31 is responsible for granular corneal dystrophy.

15. What are the differential diagnoses of granular dystrophy?

Paraproteinemia A in a patient with leukemia can produce dense crystalline deposits in the cornea. Serum protein electrophoresis will show an M component spike in the patient with paraproteinemic keratopathy.

16. Classify lattice dystrophies.

Type	Predominant corneal location	Inheritance	Age of onset	Amyloid protein
Type I	Central, full thickness	Autosomal dominant	First-second decade	AA
Type II (coexisting systemic amyloidosis)	Peripheral radial pattern	Autosomal dominant	Third decade	Gelsolin
Type III	Peripheral radial pattern	Autosomal recessive	Sixth decade	AP

17. What are the characteristic features of lattice-I dystrophy?

The characteristic translucent lattice lines vary from a few small comma-shaped flecks to a dense network of large irregularropy cords that contain white dots. The white dots and lattice lines consist of amyloid. In the corneal stroma they form fusiform deposits that push aside the collagen lamellae. Lattice dystrophy results from abnormal keratocyte synthesis.

18. What are the slit lamp findings in lattice-II dystrophy?

Coarse translucent stromal lattice lines radiating centrally from the limbus sparing the central and intervening cornea.

19. What are the systemic features of lattice-II dystrophy?

- i. Slowly progressive cranial and peripheral neuropathy,
- ii. Skin changes such as lichen amyloidosis, cutis laxa, blepharochalasis, protruding lips, and mask facies, and, variably ventricular hypertrophy and polycythemia vera.

20. What are features of lattice-III dystrophy?

- i. Inherited as an autosomal recessive trait and has a late adult onset
- ii. The disorder occurs unilaterally or bilaterally
- iii. Usually, visual acuity is not greatly affected
- iv. The lattice lines are thick and ropy and extend from limbus to limbus
- v. Variably sized amyloid deposits accumulate beneath Bowman's layer and in the anterior stroma.

21. What are the components of amyloid?

Their chemical composition is unknown, but pre-albumin, transthyretin AP protein, and gelsolin (actin-modulating plasma protein, an amyloidogenic protein), are all associated with the amyloid deposits.

22. Define Avellino dystrophy.

Concurrent granular and lattice dystrophies in the same cornea.

23. What are the clinical features of combined granular-lattice dystrophy?

Exhibits an autosomal dominant inheritance pattern and appears in the first decade of life.

Granular	Lattice
The granular lesions resemble the sharply demarcated, round, focal deposits of isolated granular dystrophy, but they occur early in life and may be accompanied by a diffuse haze between the granules. The granular deposits are clustered in the anterior stroma	Whiter, and more polygonal or speculated occur later in life, and lack the classic glass-red refractile appearance in retro illumination. The lattice deposits appear in middle to posterior stroma

24. What are the characteristic features of gelatinous drop like dystrophy?

- i. Gelatinous, drop-like dystrophy is a rare, bilaterally symmetric, primary familial corneal amyloidosis.
- ii. Inherited as an autosomal recessive mapped to chromosome 1p.
- iii. The disorder manifests early in life in the first decade.
- iv. Presenting symptoms include photophobia, lacrimation, foreign body sensation, and progressive deteriorating vision.
- v. It is characterized by multiple, subepithelial, gelatinous excrescences that give the corneal surface a mulberry appearance.
- vi. The deposits appear opaque on direct illumination and translucent in retroillumination. In advanced cases, they are accompanied by neovascularization.

25. What are the characteristics of macular dystrophy?

- i. It is an autosomal recessive disease
- ii. It involves both the central and peripheral cornea, and also all the layers of cornea
- iii. It is a heterogeneous disorder, on the basis of the type of an abnormal proteoglycan present
- iv. This condition requires penetrating keratoplasty earlier than other stromal dystrophies
- v. Recurrence after graft is less common when compared to lattice and granular dystrophy. The cornea is thinner than normal.

26. Classify macular dystrophy.

Based on the immune histochemical studies macular dystrophy are classified into two types as:

Type I	Type II
Most common. The antigenic keratin sulfate are absent from both serum and cornea	Antigenic keratin sulfate is both present in serum and cornea
Deficiency of sulfo tranferase enzyme (an enzyme that catalyze the sulfation of kerato amino-glycans) leads to precipitation of less soluble keratin chains in the extracellular matrix causing loss of transparency	Dermatan sulfate proteoglycan molecule is shorter than that of normal individuals resulting in abnormal packing of collagen fibers

27. What is the substance that forms the stromal opacity in macular dystrophy?

The stromal opacities correspond to the deposition of abnormal keratin sulfate proteoglycans.

28. What are the clinical features of central crystalline dystrophy?

- i. It is a bilateral disorder with autosomal dominant inheritance.
- ii. It is characterized by deposition of subepithelial corneal crystals that appear early in life.
- iii. Local disorder of corneal lipid metabolism. Pathologically, the opacities are accumulations of unesterified and esterified cholesterol and phospholipids.
- iv. The crystals are generally deposited in an arcuate or circular pattern in the anterior, paracentral stroma). When they are relatively dense, they give the cornea a bull's eye appearance and may reduce vision.
- v. Oil red-O stains the globular neutral fats red whereas the Schultz method stains cholesterol crystals blue-green.

29. What is the Weiss classification of central crystalline dystrophy (Schnyder's crystalline dystrophy)?

Weiss has recommended that this dystrophy be reclassified into two major clinical types:

- i. With superficial stromal cholesterol crystals and
- ii. With diffuse full-thickness stromal haze alone.

30. What is Schnyder's dystrophy sine (without) crystals?

It is a rare dystrophy with diffuse stromal haze only are called Schnyder's dystrophy sine (without) crystals.

31. What are associated systemic conditions of central crystalline dystrophy?

Central crystalline dystrophy can be associated with hyperlipidemia, thyroid abnormalities and genu valgum.

32. Describe Bietti's crystalline dystrophy.

- i. Bietti's crystalline dystrophy is autosomal recessive disorder.
- ii. It is characterized by marginal depositions of numerous, small crystals in the anterior peripheral corneal stroma and in the paracentral and peripapillary retina.
- iii. Visual acuity is retained throughout its course but pigmentary changes occur at the fovea and in the retinal periphery which produce poor dark adaption and paracentral scotomata.
- iv. The demonstration of crystals resembling cholesterol and other lipids suggest a systemic abnormality of lipid metabolism.

33. What are the features of fleck dystrophy?

- i. Uncommon nonprogressive stromal dystrophy begins very early in life and may be congenital. It shows extreme asymmetry.
- ii. Affected keratocytes contain two abnormal substances: excess glycosaminoglycan, which stain with Alcian blue and colloidal iron and lipids demonstrated by Sudan black and oil red-O.
- iii. Discrete flat gray-white dandruff like opacities appear throughout the stroma to its periphery. Symptoms are minimal and vision is usually not reduced.

34. What are the features of central cloudy dystrophy of Francois?

Bilateral, symmetrical and slowly progressive stromal dystrophy. Autosomal dominant inheritance. Extracellular deposition of mucopolysaccharide and lipid like material has been described.

Clinically opacity is densest centrally and posteriorly and fades both anteriorly and peripherally. Opacities consist of multiple nebulous, polygonal, gray areas separated by crack like intervening clear zones. Vision is usually not reduced.

35. Write short notes on congenital hereditary stromal dystrophy?

- i. Autosomal dominant disorder and consists of bilaterally symmetric central anterior stromal, flaky feathery opacities that are present at birth.
- ii. Congenital hereditary stromal dystrophy is non-progressive but is often accompanied by searching nystagmus and esotropia.
- iii. Histopathologically, the stroma consists of alternating layers of tightly packed and loosely packed collagen fibrils about 15 nm in diameter.
- iv. The treatment of choice is penetrating keratoplasty, although amblyopia usually limits visually acuity to 20/200.

36. How to differentiate CHSD and CHED?

CHSD	CHED
Non-progressive condition Normal corneal thickness and absence of both epithelial edema and thickening of Descemet's membrane	Progressive in autosomal recessive condition Increased corneal thickness to about two to three times and diffuse gray-blue ground glass appearance which is the pathological hall mark of disease

37. What are the various methods of diagnosing corneal dystrophies?

- i. Transmission electron microscopy—accurate method
- ii. Immunohistochemistry—identifies composition of deposits in dystrophic corneas
- iii. Molecular genetics—Using common DNA determinants.

38. Name the substances that are found in various stromal dystrophies.

It can be remembered using the acronym.

Marilyn	— Macular
Monroe	— Mucopolysacchrides
Always	— Alcian blue
Gets	— Granular
Her	— Hyaline lipoprotein
Man	— Masson's trichrome stain
L	— Lattice
A	— Amyloid
City	— Congo red

Dystrophy	Material	Stain
Macular	Mucology	Alcian blue
Granular	Hyaline	Mucin
Lattice	Amyline	Congo red

39. What are the stains that are used in stromal dystrophies?***Stain for amyloid in lattice dystrophy:***

- i. Pink to orange by Congo red.
- ii. Alternating red and green color when viewed through a rotating polarizing filter.
- iii. Yellowish green color against black background through two rotating filters.
- iv. Periodic Acid Schiff's and Masson's trichrome staining can also be used.

Stain for granular dystrophy (Hyaline lipoprotein):

Masson's trichrome staining gives bright red color.

Stain for macular dystrophy (Glycosoaminoglycans or mucopolysaccharides):

Blue color on staining with Alcian blue, cuprolinic blue and colloidal iron.

40. How to treat a case of a stromal dystrophy?

- i. Observation and best corrected refractive correction by spectacles.
Since most of the patients are asymptomatic during their initial stages of presentation it is better to observe.
- ii. Treatment of symptoms of erosion:
Lubricants
- iii. Excimer laser phototherapeutic keratectomy (PTK):
Used to treat the superficial lesions
It can also be used to treat recurrence of granular dystrophy in a penetrating keratoplasty because the recurrences are almost always superficial.
- iv. Superficial keratectomy:
Dense superficial juvenile variety can be treated by superficial keratectomy or lamellar keratoplasty, an advantage because multiple recurrences can be treated by multiple grafts.
- v. Lamellar keratoplasty
For diseases involving the superficial stroma
- vi. Deep lamellar keratoplasty
- vii. Penetrating keratoplasty
Indications: When dense opacities and subepithelial connective tissue reduce visual function to unacceptable levels. But recurrence is common affecting within five years.
Macular dystrophy requires penetrating keratoplasty earlier than other stromal dystrophies.
Recurrence after graft is less common in macular dystrophy when compared to lattice and granular dystrophy.

41. What is the differential diagnosis of congenital corneal opacity?

Acronym for differential diagnosis of neonatal cloudy cornea—STUMPED

- | | |
|----------|---|
| S | Sclerocornea |
| T | Tears in Descemet's membrane
Infantile glaucoma—most common cause
Birth trauma |
| U | Ulcer: Herpes simplex viral keratitis, bacterial, neurotrophic |
| M | Metabolic disorders: Rare—Mucopolysaccharidosis,
mucopolipidosis, tyrosinosis |
| P | Posterior corneal defect: Posterior keratokonus, Peter's
anomaly—most common cause staphyloma |
| E | Endothelial dystrophy: Congenital hereditary endothelial dystrophy,
posterior polymorphous dystrophy, congenital hereditary stromal
dystrophy |
| D | Dermoid. |

42. What are the conditions that cause recurrent corneal epithelial erosions?

Primary epithelial dystrophies	Map-dot-fingerprint basement membrane, Franceschetti's recurrent epithelial, epithelial rosette. Meesmann's epithelial
Stromal and endothelial Dystrophies	Reis-Bucklers, gelatinous drop-like, lattice Fuch's endothelial
Systemic diseases	Epidermolysis bullosa

43. How do you manage of recurrent corneal erosions?

- i. Lubricating eye drops and ointments
- ii. Epithelial debridement
- iii. Bandage contact lenses
- iv. Anterior stromal puncture to increase adhesions
- v. Excimer laser PTK.

2.15. FUCH'S ENDOTHELIAL DYSTROPHY

1. What is Fuch's dystrophy?

Fuch's dystrophy (combined dystrophy) is defined as a bilateral, non-inflammatory progressive loss of endothelium that results in reduction of vision; the key features being guttae, folds in Descemet's membrane, stromal edema and microcystic epithelial edema.

2. Describe the epidemiology of Fuch's dystrophy.

- i. Autosomal dominant, occasionally sporadic.
- ii. Female preponderance (4:1).
- iii. Elderly; onset of symptoms > 50 years.
- iv. Increased incidence of POAG (reason unclear).

3. Describe the pathogenesis of Fuch's dystrophy.

- i. The primary cause of the dysfunctional endothelial cells is unknown.
- ii. Corneal swelling is thought to result from the loss of Na-K ATPase pump sites within the endothelium and an increase in permeability.
- iii. The deposition of aberrant collagen fibrils and basement membrane with thickening of Descemet's membrane is a result of endothelial cell transformation to fibroblast like cells.

4. Describe the various hypotheses regarding the pathogenesis of Fuch's dystrophy.

- i. Believed to be due to an embryonic defect in the terminal induction or differentiation of neural crest cells resulting in abnormal morphology of the Descemet's membrane.
- ii. Hormonal influences are suspected as the phenotypic expression is more severe in women.
- iii. Endothelial inflammation secondary to trauma, toxins or infection results in endothelial cell pleomorphism, and a thickened abnormal Descemet's membrane.

5. What are the symptoms of Fuch's dystrophy?

- i. Initially asymptomatic.
- ii. Decrease in vision (related to edema).
- iii. Pain due to ruptured epithelial bullae.
- iv. Symptoms are worse upon awakening.
- v. Painful episodes subside once subepithelial fibrosis occurs.

6. Why are symptoms worse upon awakening?

The decrease in vision and glare in Fuch's dystrophy are primarily due to varying degree of epithelial and stromal edema. Decreased evaporation of

the tears during sleep decreases their osmolarity, leading to increased edema and decreased visual acuity upon awakening.

7. Describe the clinical stages of Fuch's dystrophy.

Stage: 1

- i. Asymptomatic
- ii. Central corneal guttae
- iii. Pigments on posterior corneal surface
- iv. Gray and thickened appearance of Descemet's membrane
- v. In more advanced cases, endothelium has a 'beaten-bronze' appearance due to the associated melanin deposition.

Stage: 2

- i. Painless decrease in vision and glare, severe on awakening
- ii. Stromal edema (ground glass appearance)
- iii. Microcystic epithelial edema (occurs when stromal thickness has been increased by about 30%).

Stage: 3

- i. Episodes of pain
- ii. Formation of epithelial and subepithelial bullae, which rupture.

Stage: 4

- i. Visual acuity may be reduced to hand movements
- ii. Free of painful attacks
- iii. Appearance of subepithelial scar tissue.

8. What are the differential diagnoses of Fuch's dystrophy?

- i. Posterior polymorphous dystrophy
- ii. Congenital hereditary epithelial dystrophy
- iii. Aphakic/pseudophakic bullous keratopathy
- iv. Chandler's syndrome
- v. Interstitial keratitis
- vi. Trauma
- vii. Intraocular inflammation.

9. How is a diagnosis of Fuch's dystrophy made?

- i. Slit lamp findings of guttae, stromal edema, epithelial bullae
- ii. Increased central corneal thickness on pachymetry
- iii. Specular microscopy.

10. What are the features of Fuch's dystrophy seen on specular microscopy?

- i. Pleomorphism (increased variability in cell shape)

- ii. Polymegathism (increased variation in individual cell areas)
- iii. Decreased endothelial cell count
- iv. Guttae are seen as small dark areas with central bright spot in mild disease
- v. Later, severely disorganized endothelial mosaic is seen.

11. What are the histopathological changes in Fuch's dystrophy?

Epithelium

- i. Initially, intracellular edema in the basal cells
- ii. Later, interepithelial and subepithelial pockets of fluids develop
- iii. Map-dot and fingerprint scarring.

Bowman's membrane

- i. Usually intact
- ii. Subepithelial fibrosis, thick in advanced disease.

Stroma

- Moderate thickening and edema.

Descemet's membrane

- i. Diffusely thickened since deposition of collagen basement membrane-like material.
- ii. Anterior banded layer—relatively normal.
- iii. Posterior non-banded layer—thinned and irregular.
- iv. Followed by a thick banded layer similar to the anterior banded zone and composing the guttae.

Endothelium

- i. Lower cell density
- ii. Enlarged cells
- iii. Thinning of cells over Descemet's warts
- iv. Fibroblast like metaplasia in end stage.

12. Why does rupture of bullae cause pain?

Rupture of epithelial bullae exposes the underlying nerve ending and hence causes pain.

13. Describe the medical management of Fuch's dystrophy.

- i. Hyperosmotic eyedrops and ointment reduces the epithelial edema and improves both comfort and vision.
 - 5% NaCl drops 4–8 times/day
 - 5% NaCl ointment at night.
- ii. A hairdryer held at arm's length may help 'dry-out' the corneal surface.
- iii. Lowering of IOP is useful in some cases.
- iv. Bandage contact lens is used to alleviate discomfort from bullae formation and rupture.

14. Describe the surgical management of Fuch's dystrophy.

Indicated when diminished visual acuity impairs normal activities. If there is no corneal opacity due to subepithelial fibrosis, then DSAEK (Descemet's stripping automated endothelial keratoplasty) is done. In cases of severe corneal opacity, then penetrating keratoplasty is performed.

15. What are all the surgical measures done for Fuch's dystrophy, done for relief of pain?

- i. Anterior stromal puncture
- ii. Bowman's membrane cauterization
- iii. Conjunctival hooding
- iv. Amniotic membrane transplantation.

2.16. ENDOTHELIAL DISORDERS AND BULLOUS KERATOPATHY

1. Classify endothelial diseases.

1. *Primary endothelial diseases*

Endothelial dystrophy:

- i. Fuch's endothelial dystrophy
- ii. Posterior polymorphous dystrophy
- iii. Congenital hereditary endothelial dystrophy
- iv. Iridocorneal endothelial syndrome.

2. *Secondary endothelial diseases*

A. Mechanical trauma to the endothelium

- i. Intraocular foreign body
- ii. Corneal trauma
- iii. Cataract surgery
 - Pre-existing endothelial disease
 - Surgical trauma
 - Intraoperative mechanical trauma
 - Postoperative trauma
 - Vitreous touch
 - IOL

B. Non-mechanical damage to the endothelium

- i. Inflammation
- ii. Increased IOP
- iii. Contact lens (hypoxia).

2. What is CHED?

Congenital hereditary endothelial dystrophy (CHED) is a dystrophy in which there is bilateral corneal edema. The corneal appearance varies from a blue-grey, ground-glass appearance to total opacification.

Types: CHED 1
CHED 2

3. What are the features of CHED 1?

Autosomal dominant inheritance with the gene locus on 20p11.2–q11.2. It is less severe developing in the 1st and 2nd year of life.

Symptoms: Progressive defective vision is present. Nystagmus is absent.

4. What are the features of CHED 2?

Autosomal recessive inheritance with the gene locus on 20p13. Present at birth. Relatively nonprogressive.

Symptoms of discomfort are less prominent despite profound epithelial and stromal edema. Nystagmus is common.

5. What is pathogenesis of CHED?

The association of enlarged stromal collagen fibrils suggests some primary development abnormality of both keratocyte and endothelium quantifying this disorder as an example of mesenchymal dysgenesis.

6. Is there an association between CHED and glaucoma?

A combination of congenital glaucoma and CHED may occur and should be suspected when persistent and total corneal opacification fails to resolve after normalization of IOP.

7. How do you differentiate between CHED and congenital glaucoma?

Sl No	Congenital glaucoma	CHED
1.	Photophobia present	No photophobia
2.	Tearing and redness	Eye white
3.	Megalocornea	Normal sized cornea
4.	Epithelial edema	More of a thick cornea

8. What are corneal guttae?

Seen as a primary condition in middle age and old age. Reveals a typical beaten metal appearance of the Descemet's membrane. These warts like excrescences are abnormal elaboration of basement membrane and fibrillar collagen by distressed or dystrophied endothelial cells.

9. What are Hassall-Henle bodies?

Guttae located in the periphery of the cornea may be seen in patients as they get older. It is of no clinical significance.

10. What is posterior polymorphous dystrophy (PPMD)?

It is a rare, slowly progressive autosomal dominant or recessive dystrophy that presents early in life. It has been mapped to chromosome 20q11.

Pathogenesis: The most distinctive microscopic finding is the appearance of abnormal, multilayered endothelial cells that look and behave like epithelial cells or fibroblast.

These cells show:

- i. Microvilli
- ii. Stain positive for keratin
- iii. Show rapid and easy growth in culture
- iv. Have intercellular desmosomes
- v. Manifest proliferative tendencies

A diffuse abnormality of the Descemet's membrane (DM) is common including thickening and multilaminated appearance and polymorphous alteration.

11. What are PPMD's clinical manifestations?

The posterior corneal surface shows

- i. Isolated grouped vesicles
- ii. Geographic shaped discrete gray lesions
- iii. Broad bands with scalloped edges.

12. Association of PPMD?

- i. Iris membranes
- ii. Peripheral anterior synechiae
- iii. Ectropion uveae
- iv. Corectopia
- v. Polycoria
- vi. Glaucoma
- vii. Reminiscent of iridocorneal endothelial syndrome
- viii. Alport's disease

13. What are the investigations to detect PPMD?

- i. Specular microscopy shows typical vesicles and bands
- ii. Confocal microscopy reveals alteration in Descemet's membrane.

14. Management of PPMD?

- i. Most patients are asymptomatic
- ii. Mild corneal edema can be managed as with early Fuch's dystrophy
- iii. Stromal micropuncture to induce subthelial pannus can be done to manage localized swelling
- iv. In severe disease glaucoma must be managed and corneal transplant may be required.

15. What is iridocorneal endothelial syndrome?

It is typically unilateral occurring in middle aged women. It is a spectrum of disorders characterized by varying degrees of corneal edema, glaucoma and iris abnormalities. It consists of the following three disorders with considerable overlap in presentation.

- i. Progressive iris atrophy
- ii. Iris nevus (Cogan-Reese) syndrome
- iii. Chandler's syndrome.

16. What is the pathogenesis of ICE syndrome?

The primary abnormality lies in the endothelial cell which takes on the ultrastructural characteristics of epithelial cells. The abnormal endothelial cells proliferate and migrate across the angle and onto the surface of the iris, 'proliferative endotheliopathy'.

Glaucoma may be due to synechial angle closure secondary to contraction of the abnormal tissue. Herpes simplex virus DNA has been identified in some ICE syndrome corneal specimens.

17. What are the specific features?

Progressive iris atrophy: characterized by severe iris changes such as holes, corectopia, etc.

The iris nevus (Cogan-Reese) syndrome: is characterized by either a diffuse nevus which covers the anterior iris or iris nodules. Iris atrophy is absent in 50% of the cases although corectopia may be severe.

Chandler's syndrome:

- i. Characterized by hammered silver corneal endothelial abnormalities.
- ii. Presence of corneal edema.
- iii. Stromal atrophy is absent in 60% of cases.
- iv. Corectopia is mild to moderate.
- v. Glaucoma is usually less severe than in the other two syndromes.

18. Treatment of iridocorneal endothelial (ICE) syndrome.

Management of glaucoma:

- i. Medical treatment is usually ineffective
- ii. Trabeculectomy is frequently unsuccessful
- iii. Artificial filtering shunts is usually required
- iv. Penetrating keratoplasty for the corneal component.

2.17. KERATOPLASTY

1. What is keratoplasty?

It is a surgical procedure wherein the abnormal recipient corneal tissue is replaced by donor corneal tissue either full thickness or partial thickness.

2. Why is corneal transplant more successful than the other transplants?

Cornea is relatively immune privileged.

Three factors are:

- i. Absence of blood vessels
- ii. Absence of lymphatics
- iii. Anterior chamber associated immune deviation (ACAID).

3. Indications for keratoplasty.

a. Optical:

- i. Pseudophakic bullous keratopathy
- ii. Keratoconus
- iii. Corneal scars
- iv. Fuch's dystrophy

b. Tectonic:

- i. Stromal thinning
- ii. Descemetocoele
- iii. Ectatic disorders

c. Therapeutic:

- i. Removal of infected corneal tissue refractory to maximal medical therapy.

4. Common indications for keratoplasty in our country.

- i. Corneal scar: healed infectious keratitis or traumatic scar
- ii. Acute infectious keratitis
- iii. Re-grafting
- iv. Aphakic and pseudophakic bullous keratopathy
- v. Corneal dystrophy especially macular corneal dystrophy
- vi. Keratoconus.

5. Common indications for keratoplasty in the West?

- i. Aphakic or pseudophakic bullous keratopathy
- ii. Fuch's dystrophy
- iii. Keratoconus
- iv. Corneal scar
- v. Dystrophies.

6. What are the types of keratoplasty?

- i. Full thickness or penetrating keratoplasty
- ii. Partial thickness or lamellar keratoplasty.

7. What are the types of lamellar keratoplasty?**A. Anterior:**

- i. Anterior lamellar keratoplasty
- ii. Deep anterior lamellar keratoplasty (DALK).

B. Posterior:

- i. Posterior lamellar keratoplasty (PLK)
- ii. Deep lamellar endothelial keratoplasty (DLEK)
- iii. Descemet's stripping endothelial keratoplasty (DSEK)
- iv. Descemet's stripping automated endothelial keratoplasty (DSAEK)
- v. Descemet's membrane endothelial keratoplasty (DMEK).

8. What are the conditions having excellent prognosis with keratoplasty?

- i. Keratoconus
- ii. Central avascular corneal scars
- iii. Granular dystrophy
- iv. Macular dystrophy
- v. Pseudophakic bullous keratopathy.

9. What are the conditions having worst prognosis with keratoplasty?

- i. Stevens-Johnson syndrome
- ii. Ocular cicatricial pemphigoid
- iii. Severe chemical burns
- iv. Dry eye of any etiology like collagen vascular disorders.

10. What are the contraindications for donor's selection?

- i. Death due to an unknown cause
- ii. Rabies
- iii. Certain infectious diseases of CNS like Jacob-Creutzfeldt, subacute sclerosing panencephalitis (SSPE) and Progressive multifocal leukoencephalopathy
- iv. HIV
- v. Septicemia
- vi. Systemic infections like syphilis, viral hepatitis B and C
- vii. Leukemia and disseminated lymphoma
- viii. Intraocular tumors.

11. What is the importance of graft size and how much is it?

Usually donor cornea should be oversized by 0.5 mm from recipient cornea. In keratoconus same size can be used. Graft size is about 7.5 to 8.5 mm.

12. What are the disadvantages of larger graft?

Larger graft may cause:

- i. Increased intraocular pressure
- ii. Rejection
- iii. Anterior synechiae
- iv. Vascularization.

13. What are the disadvantages of smaller graft?

Smaller graft would give rise to astigmatism due to subsequent tissue tension.

14. Why should graft in keratoconus be same size?

Using same diameter trephines for both donor and host tissues helps by decreasing postoperative myopia.

15. What are the methods of anterior chamber entry in PKP?**I. Trephine:**

Advantages:

- i. Sharp vertical edges
- ii. Quick
- iii. Uniform entry in all 360°.

Disadvantages:

- i. Not controlled and so chance of damage to intraocular structures.

II. Blade:

Advantages:

- i. Controlled entry.

Disadvantages:

- i. May not be uniform.

16. Where are the cardinal sutures placed in PKP?

The first suture is placed at 12 o'clock. The second suture is the most important suture and is placed at 6 o'clock position. The third and fourth sutures are put at 3 o'clock and 9 o'clock position. At the end of 4 cardinal sutures, a trapezoid should be formed.

17. What are the indications for interrupted sutures?

- i. Corneas of uneven thickness.
- ii. Corneas with localized areas of inflammation.
- iii. Vascularized, inflamed or thinned corneas where uneven wound healing is expected.
- iv. Corneas in which bites on the recipient side is very close to the sclera.
- v. Pediatric keratoplasties.

18. What are the advantages of interrupted sutures?

- i. Technically less difficult.
- ii. Permits elective removal in case of children and uneven wound healing.
- iii. Individual suture bites can be adjusted.
- iv. Selective sutures can be removed in case of infection.

19. What are the disadvantages of interrupted sutures?

Stimulates more inflammation and vascularization because of more knots.

20. When can continuous sutures be used?

In absence of inflammation, vascularization or thinning, continuous sutures can be used.

21. What are the advantages of continuous sutures?

- i. They allow more even distribution of tension around the wound.
- ii. Wound healing is more uniform.
- iii. Incites less inflammation because of less knots.
- iv. If double continuous is done, the 2nd running suture can be placed in a manner that counteracts the torque induced by the 1st.

22. What are the disadvantages of continuous sutures?

Sectoral loosening or cheese wiring compromises the entire closure of the cornea.

23. What are torque and antitorque sutures?

When continuous sutures are radially arranged perpendicular to the limbus they are bound to induce some torque while tightening and so they are known as torque sutures.

When the sutures are typically placed 30 to 40° to the donor-recipient interface in the direction of suture advancement, they are known as antitorque sutures.

24. What are combined sutures?

When both types of suturing: continuous and intermittent are used to secure the graft it is called combined suture.

25. What is the advantage of combined sutures?

They have advantage of both. Interrupted sutures can be removed as early as 4 weeks later. Continuous suture can remain *in situ* to protect against wound dehiscence.

26. What are the guidelines for suture removal?

- i. Interrupted sutures can be removed before 6 to 12 months.
- ii. Combined interrupted sutures in steep meridian at 3 months.
- iii. Continuous sutures can be removed after 1 year.
- iv. Always remove suture by pulling on the recipient's side.
- v. Only loose sutures should be removed. Tight sutures may need to be cut or replaced.

27. What is lamellar keratoplasty?

Selective replacement of diseased recipient tissue wherein the partial thickness donor graft is placed in recipient corneal bed. This is prepared by lamellar dissection of abnormal corneal tissue, the donor graft being of similar size and thickness as the removed pathological host cornea.

28. What are the advantages of anterior lamellar over penetrating keratoplasty?

- i. Extraocular procedure and hence devoid of intraocular complications like hyphema, endophthalmitis, etc.
- ii. Large graft can be placed.
- iii. Less chances of rejection.
- iv. Non-viable tissue (tissue with low endothelial count) can be used.
- v. Less stringent donor selection.
- vi. Faster recovery.
- vii. Better wound strength.

29. What are the disadvantages of lamellar keratoplasty?

- i. Procedure is technically more demanding.
- ii. Visual acuity can be impaired due to uneven dissection of recipient or donor corneal tissue and interface scarring.
- iii. Particulate debris trapped in lamellar interface.
- iv. Mechanical folds in the posterior layer over the visual axis due to flattening of this layer especially in keratoconus.
- v. Vascularization and opacification at the interface.

30. What are the indications for lamellar keratoplasty?

i. Anterior:

- Localized superficial corneal scar
- Keratoconus
- Corneal and conjunctival tumors.

ii. Posterior:

- Fuch's dystrophy without corneal scarring
- Pseudophakic bullous keratopathy without scarring.

31. When do you prefer anterior lamellar keratoplasty and why?

Anterior keratoplasties are useful in treating:

- i. Keratoconus
- ii. Scars from refractive surgery or trauma
- iii. Stromal scarring from bacterial or viral infections

Healthy recipient endothelium is preserved thus decreasing graft rejection and prolonged graft survival.

32. When do you prefer posterior lamellar keratoplasty and why?

Posterior keratoplasties are used primarily for endothelial diseases like:

- i. Fuch's endothelial dystrophy
- ii. Aphakic or pseudophakic bullous keratopathy.

Advantages of posterior lamellar keratoplasty are:

- i. Posterior grafts do not require corneal surface incisions and suture so induced astigmatism is reduced and tectonic stability is greater.
- ii. Quicker visual rehabilitation.
- iii. Theoretically lesser chance of stromal rejection.

- iv. No suture related complications as no sutures.
- v. Strong wound.

33. What are inlay and onlay lamellar keratoplasties?

Inlay: Partial thickness of recipient cornea is removed by lamellar dissection and replaced by partial thickness of donor cornea.

Onlay: Partial thickness donor cornea is placed over a de-epithelized recipient cornea in which either a small peripheral keratectomy or lamellar dissection has been done (e.g. epikeratoplasty).

34. What are the techniques of deep anterior lamellar keratoplasty (DALK)?

DALK involves replacing the entire stroma barring the Descemet's membrane (DM). This can be achieved by:

- i. Dissecting with balanced salt solution, ocular viscoelastic device
- ii. Big bubble technique of Anwar where bubble is used to blow the Descemet's membrane off the rest of the cornea,
- iii. Melles' technique where a series of dissecting blades do a deep dissection to the cornea almost down to Descemet's membrane.

35. What is the difference between DLEK and DSEK?

In DLEK, manual lamellar dissection with corneal depth of 75–85% is done in the recipient. In DSEK, no lamellar dissection is necessary. Instead the DM is stripped off the central 8 mm of the cornea using a reverse Sinskey's hook followed by placement of the folded donor disk via sclero corneal tunnel.

36. What is the difference between DSEK and DSAEK?

DSEK: Donor dissection is done using a manual artificial anterior chamber.

DSAEK: Donor dissection is done using a microkeratome.

37. What is femtosecond DSEK?

In this the donor tissue is pre cut with laser. Rest of the steps continue like normal DSEK.

38. How is DSEK superior to DLEK?

DSEK:

- i. Obviates complex recipient trephination and dissection techniques. Better visual outcome.
- ii. Less potential for trauma to the anterior chamber and lens.
- iii. Ability to perform corneal refractive surgery later on to correct refractive errors.

39. What are the complications of keratoplasty?

Intraoperative complications:

- i. Improper trephination: If smaller size trephine used for donor button instead of recipient button, complications of smaller graft like increased IOP may be seen.

- ii. Damage to donor button during trephination.
- iii. Incomplete trephination in recipient cornea-retained Descemet's membrane.
- iv. Iris or lens damage.
- v. Anterior chamber hemorrhage.
- vi. Torn posterior capsule during combined keratoplasty with cataract surgery.
- vii. Expulsive choroidal hemorrhage.

Postoperative complications:

- i. Wound leaks and wound displacement
- ii. Persistent epithelial defects
- iii. Filamentary keratitis
- iv. Suture related complications:
 - Suture exposure
 - Suture related infection
 - Suture related immune infiltrate
- v. Elevated intraocular pressure
- vi. Postoperative inflammation
- vii. Anterior synechiae
- viii. Pupillary block
- ix. Choroidal detachment or hemorrhage
- x. Fixed dilated pupil
- xi. Postoperative infection: Endophthalmitis rates post PKP: 0.2–0.7%
- xii. Primary donor failure.

40. How is the donor tissue evaluated?

- i. Slit lamp appearance for lusture, presence or absence of folds
- ii. Specular microscopy data
- iii. Death to preservation time
- iv. Tissue storage time
- v. Serology—Hepatitis B and HIV.

41. What is the recommended lower limit for age of donors?

Donor corneas less than 1 year of age is not used, as these corneas are extremely flaccid and can result in high corneal astigmatism and myopia.

42. What is the recommended upper limit for age of donor?

The upper limit recommended by eye bank association of America is 70 years, but as long as the cornea is healthy, donor age does not matter.

43. What is the difference between graft rejection and failure?

Graft rejection is an immunologically mediated reversible loss of graft transparency in a graft which remained clear for at least 10–14 days following PKP.

Graft failure is irreversible loss of graft corneal transparency. It can be primary failure or late donor failure or end result of multiple rejection episodes.

44. Mention the most common types of rejection.

- i. Endothelial
- ii. Subepithelial
- iii. Epithelial
- iv. Stromal (in decreasing frequency).

45. What are the risk factors for rejection? OR Who are the high risk patients?**Host factors:**

- i. Corneal stromal vascularization.
- ii. Re-grafts: 2 or more higher chances.
- iii. Co-existing conditions like uveitis, herpes simplex keratitis, atopic dermatitis and eczema.
- iv. Active ocular inflammation at the time of surgery.
- v. Age: young patient.

Technical factors:

- i. Larger graft.
- ii. Eccentric graft.
- iii. Therapeutic keratoplasty
- iv. Suture removal
- v. Loose sutures arching vascularization

46. What is the Khodadoust line?

Linear arrangement of endothelial precipitates composed of inflammatory cells which originate at vascularized end of peripheral donor cornea or at junction of anterior synechiae with endothelium and moves towards center of cornea. It is seen in endothelial type of rejection.

47. What are the conclusions of Collaborative Corneal Transplant Study (CCTS)?

- i. Donor-recipient tissue HLA typing has no significant long term effect on success of transplantation.
- ii. ABO compatibility is more useful.
- iii. In high risk patients, high dose topical long term steroids, good patient compliance and close follow up gives successful corneal transplant.

48. What are the symptoms and signs of graft rejection?

Symptoms precede the signs.

- Symptoms:** Decreased vision
Photophobia and glare
- Signs:** Circumcorneal congestion
Keratic precipitates
Localized corneal edema
Generalized corneal edema

49. What are the types of graft failure?

1. **Primary graft failure:** The graft is irreversibly edematous, right from the immediate postoperative period. The causes are:
 - a. Poor donor tissue
 - b. Traumatic surgery destroying endothelium.
2. **Secondary graft failure:** Causes are
 - a. Irreversible rejection
 - b. Infection
 - c. Trauma

50. How do you treat endothelial rejection?

- i. Topical 1% prednisolone acetate eyedrops: Titrate according to the response
- ii. Subconjunctival injection of 0.5 mg dexamethasone
- iii. Oral prednisolone acetate 1 mg/kg body weight
- iv. Intravenous methyl prednisolone acetate
- v. If it is still irreversible, then to plan for a regraft

51. How do you treat graft failure?

Regraft.

3

CHAPTER

Uvea

3.1. UVEITIS—HISTORY AND CLINICAL FEATURES

1. Why is uvea named so?

“Uvea” is derived from the Greek word “*uva*” meaning grape. When the sclera is removed, the center of the eyeball appears like a grape and hence the name.

2. What does iris mean?

Iris is derived from a Greek word meaning rainbow/halo.

3. Why do the iris and ciliary body often get involved together?

The presence of the major arterial circle causes the involvement of both the iris and ciliary body in pathological conditions. The blood supply to the choroid is essentially segmental and hence the lesions are also isolated.

4. Definitions.

i. Anterior uveitis:

It is subdivided into:

a. Iritis: Inflammation involving iris only.

b. Iridocyclitis: Inflammation involving iris and anterior part of ciliary body (the pars plana).

ii. Intermediate uveitis: Predominant involvement of pars plana and extreme periphery of retina.

iii. Posterior uveitis: Inflammation beyond the posterior border of vitreous base.

iv. Panuveitis: Involvement of the entire uveal tract.

v. Retinochoroiditis: Primary involvement of retina with associated involvement of choroid.

vi. Chorioretinitis: Primary involvement of choroid with associated involvement of retina.

vii. Vitritis: Presence of cells in the vitreous secondary to inflammation of uvea, retina, optic nerve and blood vessels.

- viii. **Diffuse choroiditis:** Generalized inflammation of the choroid.
- ix. **Disseminated choroiditis:** Two or more scattered foci of inflammation in the choroid, retina or both.
- x. **Exogenous infection:** Infection occurring as a result of external injury to uvea, operative trauma or any other event leading to invasion of microorganisms from outside.
- xi. **Endogenous infection:** Infection occurring as a result of microorganisms or their products released from a different site within the body.
- xii. **Secondary infection:** Infection of uveal tract due to spread from other ocular tissue.

5. How do you classify uveitis?

IUSG Classification

A. Anatomical classification

Term	Primary site of inflammation	Includes
Anterior uveitis	Anterior chamber	Iritis Iridocyclitis Anterior cyclitis
Intermediate uveitis	Vitreous	Pars planitis Posterior cyclitis Hyalitis
Posterior uveitis	Retina/Choroid	Choroiditis Chorioretinitis Retinochoroiditis Retinitis Neuroretinitis
Panuveitis	AC/Vitreous/Retina/Choroid	

B. Clinical classification

a. Infectious:

- i. Bacterial
- ii. Viral
- iii. Fungal
- iv. Parasitic

b. Non-infectious:

- i. Known systemic association
- ii. No known systemic association
- iii. Masquerade:
 - Neoplastic
 - Non-neoplastic

Anatomical Classification

Tessler's classification

- i. Sclerouveitis
- ii. Keratouveitis
- iii. Anterior uveitis
- iv. Iritis
- v. Iridocyclitis
- vi. Intermediate uveitis
- vii. Cyclitis, vitritis
- viii. Pars planitis
- ix. Posterior uveitis
- x. Retinitis
- xi. Choroiditis

Pathological Classification

- i. Granulomatous and non-granulomatous
- ii. Suppurative and exudative

Aetiological Classification

Infectious

- i. **Exogenous:** *Staphylococcus, Pseudomonas, Propionibacterium acnes.*
Secondary—Iridocyclitis associated with herpetic keratitis, iridocyclitis associated with anterior and posterior scleritis.
- ii. **Endogenous:**

Bacterial	TB Syphilis Gonorrhoea
Viral	Herpes simplex CMV Measles Influenza
Fungal	Histoplasmosis Coccidioidomycosis Candidiasis
Parasitic	<i>Toxoplasmosis</i> <i>Toxocariasis</i> <i>Onchocerciasis</i> <i>Pneumocystis carinii</i>

Hypersensitivity/autoimmune

- i. Lens induced—autoimmune reaction to lens protein
- ii. Sympathetic ophthalmia—autoimmunity to uveal pigment.

- iii. VKH
 - iv. Behcet's
- } suspected autoimmune origin.

Toxic

- i. Systemic toxins—onchocercal uveitis.
- ii. Endocular uveitis—atrophic uveitis in degenerating eyes.
- iii. Iridocyclitis in RD due to unusual proteins reaching through retinal tear.
- iv. Chemical irritants—miotics and cytotoxic agents.

Associated with Systemic Conditions

- i. Associated with arthritis
- ii. Ankylosing spondylitis (AS)
- iii. Rheumatoid arthritis (RA)
- iv. Juvenile rheumatoid arthritis (JRA)
- v. Psoriatic arthritis
- vi. Associated with GIT disorders: Ulcerative colitis
- vii. Associated with anergy: Sarcoidosis, leprosy, TB.

Associated with Neoplasms

- i. Retinoblastoma, choroidal melanoma.

Idiopathic

- i. Specific—Fuch's
- ii. Nonspecific—Account for 25% of all uveitis.

Occurrence of Uveitis

- i. Most common type of uveitis:
Anterior uveitis is the most common type, followed by intermediate, posterior and panuveitis.
- ii. Commonest age group affected, i.e. 20–40 years.
- iii. Common causes of uveitis in young adults:
 - Behcet's
 - Sarcoidosis
 - Fuch's heterochromic iridocyclitis
 - Herpes simplex
 - Toxoplasmosis
- iv. Causes of uveitis in middle ages
 - Reiter's
 - Ankylosing spondylitis
 - Vogt Koyanagi Harada (VKH) syndrome

- White dot syndrome
- Toxoplasmosis
- v. Uveitic entities with sex predilection

Males	Females
Ankylosing spondylitis	RA
Reiter's syndrome	JRA
Behcet's	
- vi. Racial influence on uveitis

Caucasians	– Ankylosing spondylitis, Reiter's syndrome
Black	– Sarcoidosis
Orientals	– VKH, Behcet's
Phillipino	– Coccidioidomycosis
- vii. Geographic influence on uveitis
 - “Histoplasmosis belt” of Ohio, Missouri and Mississippi—Histoplasmosis
 - Japan and Mediterranean countries—Behcet's and VKH
 - San Jaoguin Valley of California—Coccidioidomycosis
- viii. Genetic/familial influence on uveitis
 - RA and Collagen disease
 - Syphilis
 - HIV and CMV
 - TB
 - Pars planitis

SUN (Standardization of Uveitis Nomenclature) Working Group 'Activity of Uveitis' Terminology:

Inactive: Grade 0 cells in AC

Worsening activity: 2 step increase in level of inflammation

Improving activity: 2 step decrease in level of inflammation

Remission: Inactive disease for > 3 months after discontinuing all treatment for eye disease.

SUN Working Group 'Descriptors in Uveitis':

Onset: Sudden/Insidious

Duration:

Limited: < 3 months duration

Persistent: > 3 months duration

Courses:

Acute: sudden onset and limited duration

Recurrent: repeated episodes separated by periods of inactivity without treatment 3 months duration

Chronic: persistent uveitis with relapse in < 3 months after discontinuing treatment

Remission: inactive disease for at least 3 months after discontinuing treatment.

6. Name causes of acute and chronic posterior uveitis.

- i. **Acute posterior uveitis** occurs in toxoplasmosis
- ii. **Chronic posterior uveitis** occurs in pars planitis and toxocariasis.

7. Name causes of acute generalized uveitis.

- i. Endophthalmitis
- ii. Sympathetic ophthalmia.

8. What are the causes of acute suppurative uveitis?

- i. Panophthalmitis
- ii. Endophthalmitis
- iii. Suppurative iridocyclitis.

9. Name causes of unilateral non-granulomatous uveitis.

- i. Fuch's
- ii. Ankylosing spondylitis.

10. What are the causes of unilateral granulomatous uveitis?

- i. Viral
- ii. Lens induced.

11. What are the causes of bilateral granulomatous uveitis?***Infectious***

Tuberculosis
Leprosy
Syphilis

Non-infectious

Sarcoidosis
Vogt Koyanagi Harada (VKH) syndrome
Sympathetic ophthalmia (SO)

12. What is Fuch's heterochromic uveitis? What are the gonioscopic findings in Fuch's? What are its sequelae?

Fuch's uveitis is an unilateral idiopathic non-granulomatous anterior uveitis occurring in young adults. It is associated with heterochromia of the iris. Gonioscopic finding in Fuch's—fine filamentous vessels bridging angle sequelae in Fuch's

- Cataract
- Glaucoma

13. What are the causes of uveitis associated with vitritis?

- i. Pars planitis
- ii. Irvine Gass syndrome
- iii. Active retinitis
- iv. Trauma.

14. What is the relevance of eliciting the following history in uveitis?

- i. Trauma/eye surgery—Sympathetic ophthalmia
- ii. Vitiligo, alopecia, poliosis—Vogt Koyanagi Harada (VKH) syndrome
- iii. Rashes: Hyper/Hypopigmentation—Leprosy
- iv. Low back pain/Joint pain—Ankylosing spondylitis (AS), rheumatoid arthritis (RA), psoriatic arthritis
- v. Painful mouth ulcers—Behcet's syndrome
- vi. Dysentery, altered bowel habits—Ulcerative colitis
- vii. Ringing in the ears, hearing loss, headache—VKH.

15. Why is history of fever important in uveitis?

It is present in the following conditions:

- i. Tuberculosis
- ii. Syphilis
- iii. Leprosy
- iv. Collagen vascular disorders (also associated with purpuric rashes).

16. What are the systemic findings associated with uveitis?***Skin:***

- i. Rash of secondary syphilis
- ii. Erythema nodosum, sarcoidosis, Behcet's
- iii. Psoriasis—plaques, arthritis
- iv. Keratoderma blenorrhagica, Reiter's syndrome
- v. Kaposi sarcoma
- vi. Leprosy.

Hair:

- i. Alopecia: VKH, secondary syphilis
- ii. Poliosis: VKH.

Nails:

- i. Pitting
- ii. Psoriasis.

Dysentery

- i. Reiter's syndrome

Mouth ulcers

- i. Painful: Behcet's syndrome
- ii. Painless: Reiter's syndrome.

Arthritis

- i. RA
- ii. Juvenile RA
- iii. AS.

Gut involvement

- i. Ulcerative colitis
- ii. Crohns disease.

Lungs

- i. TB
- ii. Sarcoidosis.

Urethritis/urethral ulcers

- i. VKH
- ii. Cytomegalovirus (CMV) infections
- iii. Congenital toxoplasmosis
- iv. Syphilis.

CNS involvement

- i. VKH
- ii. CMV
- iii. Behcet's
- iv. Congenital toxoplasmosis.

17. What is the mechanism of pain in uveitis?

The pain is an acute spasmodic ciliary neuralgia superimposed on a dull ache. Since the iris is richly supplied with sensory nerves from the ophthalmic division of the fifth nerve, pain is very common. It is typically worse in the night. It is worse in the acute stage when there is tissue swelling hyperemia and release of high concentration of toxic materials.

18. What are the symptoms in cyclitis/choroiditis?

Cyclitis:

- i. Floaters
- ii. Redness due to ciliary congestion
- iii. Tenderness over pars plana
- iv. Defective vision, in chronic cyclitis due to vitreous opacities.

Choroiditis:

- i. Asymptomatic, unless posterior pole is involved.
- ii. Photopsia, due to irritation of rods and cones at the periphery of the lesion.
- iii. Floaters—due to outpouring of exudate
- iv. Metamorphopsia due to irregular elevation in the retina. Initially a positive scotoma develops following which a negative scotoma develops. Hiatus or negative scotoma is sector shaped in severe lesions due to destruction of nerve fibers and blockage of retinal vessels causing damage to RPE in periphery.

19. Differentiate circumcorneal/ciliary and conjunctival congestion.

	Conjunctival	Circumcorneal
Site	In fornices	Circumcorneal
Color	Bright red	Pale red/violaceous
Type of discharge	Mucus	Serous
Branching of vessels	Dichotomous	Radially arranged around the cornea without branching
Origin	Posterior conjunctival vessels	Anterior ciliary vessels
Movement of vessels	Can be moved on moving conjunctiva	Cannot be moved
On pressure	Fill from fornix	Fill from limbus

20. What are the keratic precipitates? What is the importance of detecting them? What is their fate?

Keratic precipitates (KPs) comprise of lymphocytes, plasma cells and phagocytes enmeshed in a network of fibrin. Mononuclear phagocytes are common in non-granulomatous KPs. Epithelial and giant cells are common in granulomatous KPs.

Significance of KPs:

- i. Gives clue to diagnosis
- ii. Evidence of inflammatory activity
- iii. It signifies involvement of ciliary body.

Fate of KPs:

- i. Hyalinization
- ii. May disappear after resolution of inflammation
- iii. May reduce in size
- iv. May become pigmented
- v. May get washed away during surgery.

Sometimes, if inflammation becomes chronic then non-granulomatous KPs may become larger and granulomatous.

21. Describe distribution of KPs.

von Arlt's triangle: A base down triangle on the inferior aspect of the corneal endothelium, where KPs aggregate due to convection currents of aqueous humor and gravity.

Ehrlich Tuck's line: Vertical line along the centre of the endothelium

Central: Viral

Diffuse: Fuch's heterochromic iridocyclitis

In the angle: Sarcoidosis.

22. What are the prerequisites for a keratic precipitate to occur?

- i. Defective nutrition of the corneal endothelium so that the cells become sticky and may desquamate in places.
- ii. The convection currents in the anterior chamber (due to the difference of the temperature between the warm iris and the cool cornea)
- iii. Gravity.

23. Differentiate fresh/old and granulomatous/non-granulomatous KPs.**Fresh**

White
Round
Fully hydrated
Smooth edges

Old

Pigmented
Flat
Dehydrated
Crenated edges

	Granulomatous	Non-granulomatous
Size	Large	Small to medium
Shape	Oval or Oblong	Usually circular
Color and Appearance	Yellow and greasy Mashed potato appearance	White—hydrated
Confluence	Often confluent	Usually non-confluent
Changes	Cause alteration of endothelium leading to prelucid haloes May get pigmented	Pigmentation, dehydration, flattening

24. What is flare? What is its significance? How is it examined and graded?

The visualization of the path of the slit lamp when aimed obliquely across the anterior chamber (AC) is called flare.

Breakdown of blood ocular barrier and damage to iris blood vessels cause proteins to leak into AC. This causes flare.

Flare in the absence of cells does not indicate active inflammation as damaged blood vessels leak for a long time after inflammation has resolved. Steroids are not indicated in the absence of cells.

Flare is examined at the slit lamp with maximum light intensity and magnification 1 mm long, 1 mm wide beam is directed at 45° to 60° to ocular surface.

Grading of flare:

Hogan’s grading:

- Faint—just detectable = 1 +
- Moderate—iris details clear = 2 +
- Marked—iris details hazy = 3 +
- Intense—fibrinous exudates = 4 +

SUN Working Group Grading for AC flare:

Grade	Description
0	None
+1	Faint
+2	Moderate (Iris and lens details clear)
+3	Marked (Iris and lens details hazy)
+4	Intense (Fibrin/plasmoid aqueous)

25. What are the types of AC reaction?

Serous: Flare due to protein exudation.

Purulent: PMNs and necrotic debris causing hypopyon.

Fibrinous/plastic: Intense fibrinous exudates, hypopyon.

Sanguinoid: Inflammatory cells with RBCs, hypopyon.

26. What are the types of cells in AC? How are they graded?

- i. Inflammatory cells (lymphocytes and PMN)
- ii. Red Blood cells (RBCs)
- iii. Iris pigment cells
- iv. Malignant cells, e.g. lymphoma.

Grading of cells

Hogan’s grading:

- None = 0
- 5–10/field = 1 +
- 10–20/field = 2 +
- 20–50/field = 3 +
- 50/field = 4 +

SUN Working Group Grading of AC cells:

<i>Grade</i>	<i>Cells in Fields</i>
0	None
+0.5	1–5
+1	6–15
+2	16–25
+3	26–50
+4	>50

27. How is hypopyon formed in uveitis?

Hypopyon is a collection of leucocytes. Sufficient fibrin content in the anterior chamber causes cells to clump and settle down as hypopyon.

28. When is hyphema seen in uveitis?

- i. Viral uveitis (especially zoster)
- ii. Syphilis
- iii. Ophthalmia nodosum
- iv. Trauma
- v. Masquerade syndrome.

29. What are the iris changes in uveitis?

- i. Pattern change: Iris crypts and furrows are obliterated
- ii. Iris atrophy
- iii. Heterochromia—Fuch's, Viral
- iv. Rubeosis
- v. Synechiae
- vi. Seclusio pupillae
- vii. Occlusion pupillae
- viii. Ectropion uveae
- ix. Nodules—Koeppel's and Busaca's
- x. Granulomas and lepra pearls.

30. What are the nodules seen in a case of uveitis? What are Leprotic pearls?

There are two types of nodules seen in uveitis:

	Koeppel's	Busaca's
Location	At pupillary margin	Usually seen along collarette
Pathology	Ectodermal nodules	Mesodermal floccules
Color	Small usually white, but may be pigmented	Greenish white and larger than Koeppel's nodules
Conditions	Usually seen in granulomatous but may occur in non-granulomatous	Only in granulomatous never in non-granulomatous uveitis

Leprotic pearls:

They are iris nodules, pathognomonic of leprosy and are situated between collarette and ciliary margin.

31. What is seclusio pupillae?

It is also called as annular or ring synechia. In this condition, the whole circle of the pupillary margin may become tied down to the lens capsule.

32. What is oclusio pupillae?

When the exudate becomes more extensive, it may cover the entire pupillary area, which then becomes filled by a film of opaque fibrous tissue and this condition is called as oclusio pupillae.

33. What is the differential diagnosis for iris nodules?

- i. Down's syndrome (Brushfield spots)
- ii. Epithelial invasion, serous cyst
- iii. Foreign body (retained)
- iv. Fungal endophthalmitis
- v. Iridocyclitis
- vi. Iris freckle
- vii. Iris nevus syndrome (Cogan-Reese)
- viii. Iris pigment epithelial cyst
- ix. Juvenile xanthogranuloma
- x. Leiomyoma
- xi. Malignant melanoma
- xii. Melanocytosis (ocular and oculodermal)
- xiii. Neurofibromatosis
- xiv. Retinoblastoma.

34. What are the pupil changes in uveitis?

In the acute stage: Miosis.

In the chronic stage: Posterior synechiae

Miosis is due to:

- i. Irritants causing muscle fibres to contract; sphincter effect overcomes dilator leading to constriction.
- ii. Vascularity allows unusual amounts of exudation, causing iris to become waterlogged and the pupil to become sluggish.
- iii. Radial nature of the vessels.

35. What are the vitreous changes in uveitis?

Vitreous changes:

- i. Opacities—fine, coarse, stinky snowball.
- ii. Posterior vitreous detachment (PVD).
- iii. Cellular precipitation posterior wall of vitreous, flare and cells, fluid in retrovitreal space.
- iv. Late shrinkage of vitreous may cause vitreal holes and retinal detachment (RD).
- v. Vitreous hemorrhage.

SUN Working Group Grading for vitreous cells:

Grade	No. of cells
0	None
+0.5	1–10
+1	10–20
+2	20–30
+3	30–100
+4	>100

36. What are the fundus changes in uveitis?**A. Optic disk:**

- i. Papillitis (VKH)
- ii. Granuloma (Sarcoid)
- iii. Optic atrophy secondary to retinal damage
- iv. Disk hyperemia/edema.

B. Macula:

- i. Edema (pars planitis, bird shot chorioretinopathy)
- ii. Scar—toxoplasmosis.

C. Peripheral retina:

- i. Healed retinitis/choroiditis/retinochoroiditis
- ii. Retinal detachment
 - Serous (VKH)
 - Rhegmatogenous
 - Tractional
- iii. Vascular occlusion
- iv. Perivascular exudates
- v. Candle wax drippings, e.g. sarcoid
- vi. Sheathing, e.g. Eales' disease
- vii. Pars plana exudates—snow banking
- viii. Neovascularization
 - Peripheral—pars planitis
 - Macular—toxoplasmosis
 - Periphery and ONH sarcoidosis

37. Differentiate choroiditis from retinitis.

Choroiditis	Retinitis
i. Yellow patch	White cloudy appearance
ii. Distinct with defined borders	Indistinct borders
iii. Involvement of vessels and	Abundant vitreous cells
iv. vitreous minimal or absent	Sheathing of adjacent vessels
v. Subretinal hemorrhage	Surrounding retinal edema

38. What is the difference between active and healed choroiditis?

Active	Healed
<ul style="list-style-type: none"> i. Elevated lesion ii. Ill-defined margins iii. Associated with vascular sheathing, hemorrhage and vitreous inflammation 	<ul style="list-style-type: none"> Flat Distinct pigmented margins No associated features

39. What are the intraocular pressure (IOP) changes that can occur in uveitis?

Low IOP:

- i. Inflammation of Ciliary body and failure to produce sufficient amount of aqueous
- ii. Choroidal detachment
- iii. Retinal detachment.

High IOP:

- i. Trabeculitis
- ii. Neovascular glaucoma (NVG)
- iii. Clogging of trabecular meshwork by inflammatory debris
- iv. Possner-Schlossman syndrome
- v. Sclerosis of trabecular meshwork
- vi. Peripheral anterior synechiae
- vii. Iris bombe
- viii. Steroid induced glaucoma.

40. What are the uveitic conditions associated with increased IOP?

- i. Viral
- ii. Toxoplasmosis
- iii. Sarcoidosis
- iv. Fuch’s heterochromic iridocyclitis
- v. Possner-Schlossman syndrome
- vi. Steroid induced uveitis
- vii. Lens induced uveitis.

41. What are the characteristic features of Posner-Schlossman syndrome?

It is also known as hypertensive iridocyclitis crises. The features are:

- i. Quiet eye
- ii. Periodic raised intraocular pressure with flare and cells
- iii. Reduced vision during these attacks and mimics angle closure glaucoma
- iv. Treatment is by using atropine ointment.

42. What are the complications of iridocyclitis?

Corneal conditions:

- i. Band keratopathy

Anterior chamber:

- Posterior synechiae,
- Iris bombe
- Seclusio pupillae,
- Occlusio pupillae.

Secondary glaucoma (described above) .

Complicated cataract.

Cystoid macular edema.

Tractional RD.

Phthisis bulbi.

43. How does phthisis occur in uveitis?

Organization of vitreous forms a cyclitic membrane, contraction of which leads to a retinal detachment with base toward lens and apex toward optic disc. As the cyclitic membrane consolidates, the ciliary processes are drawn inwards, so that the ciliary body detaches leading to phthisis bulbi.

44. What are the causes of cystoids macular edema in uveitis?

- i. Acute severe iridocyclitis
- ii. Behcet's syndrome
- iii. Pars planitis
- iv. Endophthalmitis
- v. Birdshot chorioretinopathy.

45. What are the causes of macular chorioretinitis?

- i. Toxoplasmosis
- ii. Tuberculosis
- iii. Syphilis
- iv. Cytomegalovirus (CMV) retinitis
- v. Herpes simplex.

46. What are the causes of retinochoroiditis?

- i. Toxoplasmosis
- ii. Toxocara granuloma of retina/choroid
- iii. Septic (subacute bacterial endophthalmitis)
- iv. CMV retinitis
- v. Candida retinitis.

47. What are the causes of chorioretinitis?

- i. Tuberculosis
- ii. AMPPE
- iii. Geographical helical polypoidal choroidopathy
- iv. Birdshot choroidopathy
- v. Sympathetic ophthalmia
- vi. Presumed ocular histoplasmosis.

48. What is the characteristic description of active toxoplasmic retinochoroiditis?

- 'Headlight in fog' appearances.

49. What are the preoperative concerns while performing cataract surgery in an eye with uveitis?

- i. The eye should remain quiet for a minimum of 3 months before contemplating surgery under the cover of steroids.
- ii. In phacolytic and other lens induced uveitis the above does not apply and cataract surgery could be done immediately.

50. What are the intraoperative steps to be taken while performing cataract surgery in a uveitic eye?

- i. Inadequate pupillary dilatation (to do sphincterotomy, iris hooks, sector iridectomy).
- ii. Complete cortical removal.
- iii. Minimal manipulation of Iris.
- iv. To perform a prophylactic peripheral iridotomy.
- v. Perform capsulorhexis and facilitate in the bag intraocular lens placement.
- vi. To preferably use a heparin coated or an acrylic lens.

51. What are the indications of explantation of IOL's in a uveitic eye?

- i. Propionobacterium gene endophthalmitis
- ii. Persistent postoperative uveitis with haptic rubbing the iris due to "in sulcus" placement.

52. Name an uveitic entity in which intraocular placement of IOL is contra indicated? Why?

JIA (juvenile idiopathic arthritis) due to persistent severe uveitis causing cyclitic membrane leading to phthisis bulbi.

52. What are the uses of atropine in a case of uveitis?

- i. It keeps the iris and ciliary body at rest
- ii. It breaks the preexisting synechia and prevents new synechia from occurring
- iii. It decreases hyperemia.

53. What is mydracaine?

It is a powerful mydriatic agent and is a combination of procaine, atropine and adrenaline. 0.3 ml is given through the subconjunctival route.

3.2. SYMPATHETIC OPHTHALMIA

1. Define sympathetic ophthalmia.

A specific bilateral inflammation of the entire uveal tract of unknown aetiology, characterized clinically by insidious onset and progressive course with exacerbations and pathologically by a nodular or diffuse infiltration of the uveal tract with lymphocytes and epithelioid cells; almost universally follows a perforating injury involving the uveal tissue.

Exciting eye—Injured eye developing the disease at a variable time after the injury.

Sympathizing eye—The other eye which develops the disease synchronously or shortly afterwards.

2. What are the predisposing causes for sympathetic ophthalmia?

A. Perforating injuries—65%

- I. Perforating injury involving the uveal tissue and in the vast majority of cases rapid and reaction less wound healing is interfered by iris, ciliary body incarceration or foreign body retention.
- II. Subacute inflammation in a soft shrunken eye in which delayed or incomplete wound healing is present.
- III. Wounds in the ciliary region are most dangerous but not very common.

B. Operative wounds—25%

- I. Incarceration of iris in the wound
- II. Iridectomy, iridencleisis.

C. Non-perforating contusions (subconjunctival scleral rupture)—10%

D. Intraocular malignant melanomata—rare

- I. Complicated by perforation of the globe by invading tumor.
- II. Necrotic tumors.

3. Discuss the pathology of sympathetic ophthalmia.

- I. Sympathetic ophthalmia is a clinicopathologic diagnosis and never a histological diagnosis alone.
- II. Focal lymphocytic and plasma cell infiltration around large veins of choroid → coalesce to form multinucleated giant cells → formation of nodules of epithelioid cells with central giant cells surrounded by lymphocytes → infiltration of iris (posterior part) and diffuse infiltration of choroid (esp. outer layers).
- III. Four characteristic histological findings in the sympathizing and exciting eye include:
 - Diffuse granulomatous uveal inflammation composed predominantly of epithelioid cells and lymphocytes; eosinophil and plasma cells may be present—neutrophils are absent.
 - Sparing of choriocapillaries

- Epithelioid cells containing phagocytosed uveal pigment
- Dalen Fuchs, nodules:
Collections of epithelioid cells between Bruch's membrane and the retinal pigment epithelium (RPE) with no involvement of the overlying neural retina and sparing of the underlying choriocapillaries. Some cells may come from transformation of the RPE.

4. What are the clinical features of sympathetic ophthalmia?

In sympathizing eye:

- i. Mild pain
- ii. Photophobia
- iii. Increased lacrimation
- iv. Blurring of vision
- v. Visual fatigue.

In exciting eye:

Decrease in vision and photophobia.

Signs in both eyes:

- i. Ciliary injection
- ii. Development of keratic precipitates on corneal endothelium
- iii. Partially dilated and poorly responsive pupil
- iv. Thickened iris
- v. Clouding of vitreous.

Posterior segment findings:

- i. Papillitis
- ii. Generalized retinal edema
- iii. Perivasculitis
- iv. Small yellow white exudate beneath RPE (Dalen-Fuchs' nodule)
- v. Areas of choroiditis
- vi. Exudative retinal detachment.

3.3. FUCH'S HETEROCHROMIC IRIDOCYCLITIS

1. What are the signs and symptoms of Fuch's heterochromic iridocyclitis?

Symptoms:

- i. Decreased vision—due to cataract formation
- ii. Floaters—due to vitreous opacities
- iii. Discomfort—due to ciliary spasm
- iv. Conjunctival injection
- v. Asymptomatic
- vi. Symptoms due to elevated IOP
- vii. Change in iris color
- viii. Hyphema
- ix. Strabismus from juvenile cataract.

Signs:

Triad of:

- i. Heterochromia
- ii. Cataract
- iii. Keratic precipitates.

Heterochromia:

- i. Iris pigments present in all three layers:
 - Anterior border layer
 - Stroma
 - Posterior pigment epithelium
- ii. There is atrophy of all the three layers.
- iii. Atrophy of anterior border layer and stroma—**hypochromia** in many cases and **hyperchromia** in a few due to revealing of the posterior pigment epithelium.
- iv. Blue irides—affected eye looks more bluer or lighter than the other eye due to loss of orange brown pigment of the anterior border layer concentrated around the collarete. Rarely show hyperchromia
- v. Brown—usually affected eyes are hypochromic may appear normal also.
- vi. Subtle heterochromia—best observed by naked unaided eye under natural day light or bright overhead light. Most sensitive method to identify heterochromia is to compare anterior segment photographs taken under standard conditions.
- vii. May be congenital/acquired later in life.
- viii. Bilateral cases—no heterochromia.

Iris characteristics:

- i. Anterior border layer: depigmentation → lighter, translucent, whitish hazy appearance.

- ii. Stroma—depigmentation and loss of volume → smooth iris surface → prominent radial vessels → visualization of the sphincter.
- iii. Pigment epithelium affected: transillumination defects and abnormalities of the pupillary ruff.
- iv. Iris nodules: rare, translucent near the pupillary margin.
- v. Posterior synechiae is rare.
- vi. Iris vessels:
 - Due to atrophy—normal iris vessels become conspicuous.
 - Radial and orderly dichotomous branching.
 - New vessels—fine, filamentous, sinuous, arborising with anomalous branching pattern.
 - Seen on the surface of iris and anterior chamber angle.
 - Rarely may form fibrovascular membrane over trabecular meshwork—neovascular glaucoma occasional.
 - Incidence of rubeosis: 6–22%; more when iris fluorescein angiography is used.
 - May cause filiform hemorrhage arising as a fine stream of blood arising in or near the angle usually opposite to the site of puncture during paracentesis—**Amsler's sign**
 - Considered to be diagnostic and confirmatory test—but now its clinical utility is questioned.
 - Applanation tonometry and cataract surgery may cause bleeding.

Iridocyclitis:

Characteristic KPs –

Stellate or round, whitish translucent with interspersed wispy filaments precipitated over the entire corneal endothelium diffusely.

Minimal anterior chamber cellular activity.

Cataract:

- i. Posterior subcapsular cataracts
- ii. Rapid advance to maturation.

Vitreous cells:

Individual cells, aggregates, stinging filaments and occasional dense vitreous veils.

Glaucoma: 26–59%

Mechanism of glaucoma:

- i. Rubeosis
- ii. Peripheral anterior synechiae
- iii. Lens induced angle closure
- iv. Recurrent spontaneous hyphema
- v. Steroid response

3.4. VOGT KOYANAGI HARADA SYNDROME

1. What is Vogt Koyanagi Harada (VKH) syndrome?

VKH syndrome or uveomeningitic syndrome is a systemic disorder involving many organ systems, including the eye, ear, integumentary and nervous system.

2. What are the clinical manifestations of VKH?

The American Uveitis Society adopted the criteria for the diagnosis of VKH syndrome in 1978 as follows:

- No history of ocular trauma or surgery.
- At least three of four of the following signs:
 - i. Bilateral chronic iridocyclitis.
 - ii. Posterior uveitis, including exudative retinal detachment, disk hyperemia or edema, and sunset glow fundus.
 - iii. Neurologic signs of tinnitus, neck stiffness, cranial nerve or CNS problems or CSF pleocytosis.
 - iv. Cutaneous findings of alopecia, poliosis or vitiligo.

3. What are the clinical manifestations of VKH?

Typical clinical manifestations of VKH syndrome:

- i. Bilateral panuveitis in association with multifocal serous retinal detachment.
- ii. Central nervous system manifestations—Meningismus, headache, CSF pleocytosis
- iii. Auditory manifestations—Hearing loss, tinnitus
- iv. Cutaneous manifestations—Vitiligo, alopecia, poliosis.

Most patients, present with severe bilateral uveitis associated with exudative retinal detachment and signs of meningismus.

4. What are the differential diagnosis of VKH?

- i. Idiopathic central serous choroidopathy
- ii. Nanophthalmos (axial length <19 mm)
- iii. Uveal effusion syndrome
- iv. Bilateral diffuse melanocytic hyperplasia
- v. Toxemia of pregnancy, renal disease
- vi. Posterior scleritis
- vii. Acute retinal necrosis syndrome
- viii. Primary B-cell intraocular lymphoma
- ix. Syphilis, tuberculosis and sarcoidosis
- x. Sympathetic ophthalmia
- xi. Lupus choroidopathy.

5. How will you investigate a case of VKH?

Fluorescein angiography (FA)

- i. Characteristic FA in acute stage of VKH demonstrates multiple punctate hyperfluorescent dots at the level of RPE.

- ii. These hyperfluorescent dots gradually enlarge and stain the subretinal fluid.
- iii. 70% of the patients have disc leakage.
- iv. In chronic stage, the angiogram shows multiple hyperfluorescent RPE window defects without progressive staining.
- v. Alternating hyper and hypofluorescence from RPE alteration causing “moth eaten” appearance can be found.

Ultrasonography:

Echographic manifestations of VKH are described by:

- i. Diffuse thickening of the posterior choroid with low to medium reflectivity.
- ii. Serous RD around posterior pole or inferiorly.
- iii. Vitreous opacities without PVD.
- iv. Posterior thickening of the sclera or episclera.

Lumbar puncture:

Lumbar puncture (LP) has not been used routinely in most recent studies. In a study by Ohno et al, more than 80% of the patients had CSF pleocytosis consisting mostly of lymphocytes. CSF pleocytosis occurs in 80% of the case within one week and resolves within eight weeks.

MRI discriminates the sclera from the choroid, which is not possible with computerized tomography and allows the detection of subclinical ocular and CNS disease. Choroidal thickening can be demonstrated even when the fundus and fluorescein angiogram appear normal.

3.5. BEHCET'S DISEASE

1. Definition of Bechet's disease.

It is relapsing and remitting systemic vasculitis of unknown etiology characterized by oral and genital ulcers and ocular inflammation.

With the triad of:

- i. Recurrent hypopyon—iritis
- ii. Oral ulceration
- iii. Genital ulceration.

2. What is the etiology?

- i. Viral agent—Herpes simplex
- ii. Bacterial—Streptococcal species
- iii. Genetic:

HLA B5	–	Ocular type
HLA B12	–	Mucocutaneous
HLA B27	–	Arthritic

3. What is Behcet's Disease Research Committee Criteria?

Major Criteria:

- i. Oral aphthous ulceration
- ii. Skin lesions:
 - Erythema nodosum like skin eruption
 - Subcutaneous thrombophlebitis
 - Cutaneous hypersensitivity
- iii. Ocular lesions
- iv. Recurrent hypopyon iritis or iridocyclitis
- v. Chorioretinitis
- vi. Genital aphthous ulceration.

Minor Criteria

- i. Arthritic symptoms and signs (arthralgia, swelling, redness in large joints).
- ii. Gastrointestinal lesions (appendicitis like pain, malena, diarrhea and so on).
- iii. Epididymitis.
- iv. Vascular lesions (Obliterative vasculitis, occlusions, aneurysms).
- v. CNS involvement:
 - Brain stem syndrome
 - Meningoencephalomyelitic syndrome
 - Psychiatric symptoms.

4. What are the anterior segment findings?

- Iridocyclitis with hypopyon—19–31%.
- Periorbital pain, redness, photophobia and blurred vision.
- Ciliary injection, fine KPs.

Hypopyon, does not coagulate—changes position with head movement

Attack lasts for 2–3 weeks and then subsides, recurrences are the rule with subsequent iris atrophy and posterior synechiae formation.

5. What are the posterior segment findings?

- i. Vitritis
- ii. Retinal vasculitis
- iii. Patchy perivascular sheathing and inflammatory exudates surrounding retinal hemorrhages
- iv. Retinal Edema
- v. Severe vasculitis—thrombosis—ischemic retinal changes. BRVO/CRVO
- vi. Neovascularization—bleeding—fibrosis—RD (Very rare)
- vii. Optic neuritis in acute phase
- viii. Progressive optic atrophy.

3.6. INVESTIGATIONS IN UVEITIS

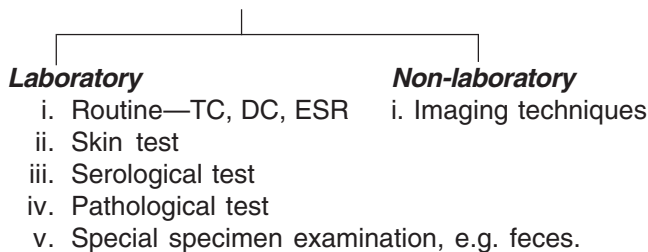
1. What are the indications for Investigations in Uveitis?

- i. To arrive at a specific diagnosis.
- ii. To choose a correct therapeutic approach.
- iii. To rule out infection (steroids are used in majority of uveitic cases; they may exacerbate existing diseases like TB and toxoplasmosis).
- iv. To rule out tumors—because many tumors like leukemias and retinoblastomas masquerade as uveitis.
- v. To rule out presumed autoimmune disease.
- vi. To rule out associated systemic conditions, e.g. HLA-B27+ JRA may present as uveitis initially. HLA-B27 positivity forewarns the patient about the systemic nature of the disease and its prognosis.
- vii. To evaluate why vision has not improved non-responders, poor responses and early recurrences.
- viii. To assess the side effects of treatment, e.g. in Behcet's disease, immunosuppressants are used.
- ix. For academic and research purposes.

2. Which uveitic entities do not need laboratory investigations for diagnosis?

- i. Pars planitis
- ii. Fuch's heterochromic iridocyclitis
- iii. Traumatic uveitis
- iv. Postoperative uveitis.

3. Classify investigations used in uveitis.



4. What are the hematological investigations done in uveitis? What is their significance? What is the normal value?

WBC (Total count):

Normal count: 4,500–11,000 cell/ml

Conditions where total count is raised:

- i. Exercise
- ii. Stress
- iii. Infections
- iv. Tissue necrosis (e.g. myocardial infarction, pulmonary infarction)
- v. Chronic inflammatory disorder (e.g. vasculitis)
- vi. Drugs (e.g. glucocorticoids, epinephrine, lithium)

Conditions where total count is decreased

- i. Infections—viral (e.g. influenza, HIV, hepatitis)
Bacterial (e.g. typhoid, TB)
- ii. Nutritional—B12 and folate deficiency
- iii. Autoimmune, e.g. SLE

5. What are the clinical conditions which can cause raised neutrophils (Neutrophilia)?

- i. Inflammatory states
- ii. Nonspecific infections
- iii. Eclampsia
- iv. Hemolytic anemia
- v. Corticosteroids.

6. What are the causes of decreased neutrophils (Neutropenia)?

- i. Congenital
- ii. Leukemia
- iii. Chemotherapy
- iv. Steroids
- v. Radiation
- vi. Vitamin B12/Folate deficiency
- vii. Hemodialysis
- viii. Viral infections.

7. What are the causes of raised eosinophils (Eosinophilia)?

- i. Parasitic infestation
- ii. Allergic disorders
- iii. Churg-Strauss syndrome
- iv. Cholesterol embolization
- v. Hodgkin's lymphoma
- vi. Addison's disease.

8. What are the causes of decreased eosinophils (Eosinopenia)?

- i. Congenital
- ii. Leukemia
- iii. Chemotherapy
- iv. Steroids.

9. What are the causes of raised basophils (Basophilia)?

- i. Stress
- ii. Inflammatory states
- iii. Leukemia.

10. What are the causes of decreased basophils (Basopenia)?

- i. Urticaria
- ii. Agranulocytosis
- iii. Ovulation

11. What are the causes of increased lymphocytes (Lymphocytosis)?

- i. Acute viral infections
- ii. Infectious mononucleosis
- iii. Acute pertussis
- iv. Protozoal—Toxoplasmic infections
- v. Tuberculosis
- vi. Brucellosis
- vii. Chronic lymphocytic leukemia
- viii. Acute lymphocytic leukemia
- ix. Connective tissue disorders
- x. Thyrotoxicosis
- xi. Addison's disease
- xii. Splenomegaly with sequestration of granulocytes.

12. What are the causes of decreased lymphocytes (Lymphocytopenia)?

- i. Common cold
- ii. Corticosteroids
- iii. HIV/viral/bacterial/fungal infections
- iv. Malnutrition
- v. Systemic lupus erythematosus
- vi. Stress
- vii. Prolonged physical exertion
- viii. Rheumatoid arthritis
- ix. Iatrogenic—radiation.

13. What are the causes of increased monocytes (Monocytosis)?

- i. Infections—Tuberculosis, syphilis, brucellosis, listeria, subacute bacterial endocarditis
- ii. Protozoal infections
- iii. Rickettsial infections
- iv. Myeloproliferative disorders
- v. Auto immune diseases
- vi. Malignancies: Hodgkin's, leukemia
- vii. Sarcoid
- viii. Lipid storage diseases.

14. What are the causes of decreased monocytes (Monocytopenia)?

- i. Immunosuppressed states
- ii. Bone marrow suppression
- iii. Radiation states
- iv. Increased destruction: autoimmune states, carcinoma of hematopoietic system
- v. Hemodialysis.

15. What is erythrocyte sedimentation rate (ESR)?

Erythrocyte sedimentation rate or Biernacki reaction is defined as the rate at which erythrocytes precipitates in an hour.

16. What are the principles of ESR?

Erythrocyte sedimentation rate (ESR) is principally determined by the balance between pro-sedimentary factors and factors that resist sedimentation. The main pro-sedimentary factor is fibrinogen. The negative charge on the surface of RBCs called as potential is responsible for resisting the sedimentation of erythrocytes.

In inflammatory states, increase in fibrinogen causes the erythrocytes to stick to each other thereby causing 'Rouleaux' formation and raised ESR.

17. What are the causes of raised ESR?**A. Physiological:**

- i. Pregnancy
- ii. Exercise
- iii. Menstruation

B. Pathological:

- i. Anemia
- ii. Endocarditis
- iii. Renal disorders
- iv. Osteomyelitis
- v. Rheumatic fever
- vi. Rheumatoid arthritis
- vii. Thyroid disorder
- viii. Tuberculosis
- ix. Syphilis
- x. HIV.

Causes of very high raised ESR:

- i. Giant cell arthritis
- ii. Hyperfibrinogenemia
- iii. Multiple myeloma
- iv. Macroglobulinemia
- v. Necrotising vasculitis
- vi. Polymygia rheumatic.

18. What are the drugs which can cause increased ESR?

- i. Dextran
- ii. Methyl dopa
- iii. Oral contraceptives
- iv. Penicillamines
- v. Theophylline
- vi. Vitamin A.

19. What are the causes of decreased ESR?

- i. Congestive cardiac failure
- ii. Hyperviscosity syndrome
- iii. Hypofibrinogenemia
- iv. Low plasma protein states

- v. Polycythemia
- vi. Sickle cell anemia
- vii. Very high blood sugar levels
- viii. Severe liver diseases
- ix. Drugs—aspirin, cortisone, quinine.

20. What are the common methods to estimate ESR?

- i. Westergren's method
- ii. Wintrobe's method

21. What is tuberculin skin testing (TST)?

The mantoux tuberculin test is the standard method of determining whether a person is infected with *Mycobacterium tuberculosis*. Reliable administration and reading of the TST requires standardization of procedures, training, supervision and practice.

22. How is the TST Administered?

The TST is performed by injecting 0.1 ml of tuberculin purified protein derivative (PPD) into the inner surface of the forearm. The injection should be made with a tuberculin syringe, with the needle bevel facing upward. The TST is an intradermal injection. When placed correctly, the injection should produce a pale elevation of the skin (a wheal) 6 to 10 mm in diameter.

23. How is the TST read?

The skin test reaction should be read between 48 and 72 hours after administration. A patient who does not return within 72 hours will need to be rescheduled for another skin test.

The reaction should be measured in millimeters of the induration (palpable, raised, hardened area or swelling). The reader should not measure erythema (redness). The diameter of the indurated area should be measured across the forearm (perpendicular to the long axis).

24. How are TST reactions interpreted?

Skin test interpretation depends on two factors:

- i. Measurement in millimeters of the induration
- ii. Person's risk of being infected with TB and of progression to disease if infected.

25. What are false-positive reaction?

Some persons may react to the TST even though they are not infected with *Mycobacterium tuberculosis*. The causes of these false-positive reactions may include, but are not limited to, the following:

- i. Infection with nontuberculosis mycobacteria
- ii. Previous BCG vaccination
- iii. Incorrect method of TST administration
- iv. Incorrect interpretation of reaction
- v. Incorrect bottle of antigen used.

26. What are false-negative reactions?

Some persons may not react to the TST even though they are infected with *Mycobacterium tuberculosis*. The reasons for these false-negative reactions may include, but are not limited to, the following:

- i. Cutaneous anergy (anergy is the inability to react to skin tests because of a weakened immune system).
- ii. Recent TB infection (within 8–10 weeks of exposure).
- iii. Very old TB infection (many years).
- iv. Very young age (less than 6 months old).
- v. Recent live-virus vaccination (e.g. measles and small pox).
- vi. Overwhelming TB disease.
- vii. Some viral illnesses (e.g. measles and small pox).
- viii. Incorrect method of TST administration.
- ix. Incorrect interpretation of reaction.

26. Who can receive a TST?

Most persons can receive a TST. Tuberculin skin testing is contraindicated only for persons who have had a severe reaction (e.g. necrosis, blistering, anaphylactic shock, or ulcerations) to a previous TST. It is not contraindicated for any other persons, including infants, children, pregnant women, persons who are HIV infected, or persons who have been vaccinated with BCG.

28. How often can TST be repeated?

In general, there is no risk associated with repeated tuberculin skin test placements. If a person does not return within 48–72 hours for a tuberculin skin test reading, a second test can be placed as soon as possible. There is no contraindication to repeating the TST, unless a previous TST was associated with a severe reaction.

29. What is boosted reaction?

In some persons who are infected with *Mycobacterium tuberculosis*, the ability to react to tuberculin may wane over time. When given a TST, years after infection, these persons may have a false-negative reaction. However, the TST may stimulate the immune system, causing a positive, or boosted reaction to subsequent tests. Giving a second TST after an initial negative TST reaction is called two-step testing.

30. Why is two-step testing conducted?

Two-step testing is useful for the initial skin testing of adults who are going to be retested periodically, such as health care workers or nursing home residents. This two-step approach can reduce the likelihood that a boosted reaction to a subsequent TST will be misinterpreted as a recent infection.

31. Can TST be given to persons receiving vaccinations?

Vaccination with live viruses may interfere with TST reactions. For persons scheduled to receive a TST, testing should be done as follows:

- Either on the same day as vaccination with live-virus vaccine or 4–6 weeks after the administration of live-virus vaccine.
- At least one month after smallpox vaccination.

32. Classification of the tuberculin skin test reaction.

Classification of the tuberculin skin test reaction		
<p>An induration of 5 or more millimeters is considered positive in</p> <ul style="list-style-type: none"> • HIV infected persons • A recent contact of a person with TB disease • Persons with fibrotic changes on chest radiograph consistent with prior TB • Patients with organ transplants • Persons who are immunosuppressed for other reasons (e.g. taking the equivalent of >15 mg/day of prednisone for 1 month or longer, taking TNF alpha antagonists) 	<p>An induration of 10 or more millimeters is considered positive in</p> <ul style="list-style-type: none"> • Recent immigrants (<5 years) from high-prevalence countries • Injection drug users • Residents and employees of high-risk congregate settings • Mycobacteriology laboratory personnel • Personnel • Persons with clinical conditions that place them at high-risk • Children <4 years of age • Infants, children, and adolescents exposed to adults in high-risk categories 	<p>An induration of 15 or more millimeters is considered positive in any person, including persons with no known risk factors for TB. However, targeted skin testing programs should only be conducted among high-risk groups.</p>

33. What is the role chest X-ray in uveitis cases?

- i. To rule out active pulmonary TB
- ii. To look for sarcoidosis
- iii. To look for secondaries.

34. What is the basis of skin tests and what is the role of skin tests in uveitis?

The basis of all skin tests is delayed hypersensitivity type IV.

Uses of skin tests:

In diagnosis of

- i. Tuberculosis
- ii. Histoplasmosis
- iii. Coccidiomycosis
- iv. To indicate anergy—sarcoidosis.

Pathergy test—Behcet's disease

35. What is Kveim test? How is it done?

- i. Kveim test—A skin test for sarcoidosis
- ii. Suspension of antigenic preparation of human sarcoid tissue prepared from spleen of sarcoidosis patients is injected intradermally
- iii. At the end of 6 weeks—a papule develops
- iv. Papule is biopsied for evidence of granuloma and giant cells
- v. Well formed epithelial tubercles indicate a positive reaction
- vi. Sensitivity—Positive in 80% patients of sarcoidosis.

Disadvantages:

- i. Requires standardization by testing in patients with sarcoidosis
- ii. It is usually negative in patients on steroid treatment.

36. How is Behcet's skin test done?

- i. The skin test for Behcet's disease is called Pathergy test.
- ii. Intradermal injection of 0.1 ml of sterile saline solution
- iii. A pustule develops within 18–24 hours
- iv. Patient shows increased sensitivity to needle trauma.
- v. *Disadvantage:* Only rarely positive in the absence of systemic activity.

37. What are the conditions associated with elevated antinuclear antibodies (ANA)?

- i. Systemic lupus erythematosus (SLE)
- ii. Juvenile rheumatoid arthritis (JRA)
- iii. Scleroderma
- iv. Hepatitis
- v. Lymphoma
- vi. Polyarteritis nodosa.

38. List the conditions in uveitis which are associated with HLA.

- i. HLA B27 – Acute anterior uveitis, reiter syndrome
- ii. HLA B51 – Japanese with Behcet's disease
- iii. HLA DR4 – VKH
- iv. HLA B7 – Macular histoplasmosis
- v. HLA A29 – Birdshot chorioretinopathy
- vi. HLA B8 – Sarcoidosis

39. What is ELISA?

ELISA is enzyme-linked immunosorbent assay. It is very sensitive and specific.

40. What are uses of ELISA in uveitis?

Used to detect antibodies of toxoplasma, toxocara and herpes simples.

Apart from blood, the test can also be done on aqueous and vitreous sample.

Patients antibodies are bound to solid phase antigen and then incubated with enzyme tagged antibody. Measurement of enzyme activity provides measurement of specific antibody concentration.

41. What are the serological tests for toxoplasmosis?

- i. Toxoplasma dye test/Sabin Feldman test
- ii. Hemagglutination test
- iii. Indirect fluorescent test
- iv. ELISA
- v. PCR.

42. What serological tests for syphilis are commonly done in uveitis?

- i. Non-treponemal test: VDRL
- ii. Treponemal test: FTA-ABS, TPHA.

43. What is the role of VDRL and FTA-ABS in case of suspected syphilis?

- i. FTA-ABS is done in syphilis because of its high sensitivity and specificity.
- ii. VDRL is done to determine state of activity of disease and adequacy of treatment.

44. What are the two new specific tests for syphilis?

MHA-TP, i.e. microhemagglutination assay for antibodies to *Treponema pallidum*.

HATTS, i.e. hemagglutination treponemal test for syphilis as 90% positive for ANA fillies. IgG titer more confirmatory than IgM titer.

45. What is the importance of negative ANA?

Negative result is more important as it excludes the diagnosis.

46. When is ANA considered positive?

ANA is considered positive when titers are 1:10 or 1:20

47. Where is Angiotensin converting enzyme (ACE) produced?

By normal capillary endothelium cells and monocytes.

48. What is normal value of ACE?

Normal value

Males	→	12–55	mole mm/ml
Females	→	11–29	mole mm/ml

49. What conditions are associated with elevated ACE?

- i. Increased in active sarcoidosis (falls to normal if there is systemic remission even if ocular inflammation is active; i.e. normal ACE does not rule out sarcoidosis)
- ii. Also increased in untreated TB, leprosy, toxoplasmosis (thereby not specific for sarcoidosis).

50. What is human leukocyte antigen (HLA)?

Human leukocyte antigen (HLA) includes histocompatibility antigens present on the surfaces of most nucleated cells.

51. Where are genes for HLA antigens located?

HLA genes are located on short arm of chromosome 6.

Two classes are present

- i. Class I — A, B, C
- ii. Class II — D

52. What is the most important HLA in Uveitis?

Most important is HLA-B 27

HLA-B 27: 58% of normal population
 85% in ankylosing spondylitis
 70–85% in Reiter's syndrome.

In patients with ankylosing spondylitis, HLA-B27 positivity implies 35% chance of developing acute uveitis, vis-a-vis 7% if negative.

53. What is the importance of serum calcium in uveitis?

Serum calcium—hypercalcemia occurs in 25% of patients with sarcoidosis but only rarely positive in isolated ocular sarcoidosis with systemic remission.

54. What is normal A:G ratio? Name conditions where it is reversed.

- i. Normal A:G ratio is 1.5:1 to 2.5:1
- ii. Decreased A:G ratio—conditions with elevated antibody concentration, e.g. chronic infections, SLE, RA, malignancy, collagen diseases
- iii. Serum globulin is elevated in sarcoidosis.

55. What is significance of urine culture in cytomegalovirus (CMV) infection?

It is recovered from urine specimens from 100% patients with acute CMV infection.

56. What is PCR?

Polymerase chain reaction (PCR) works on the principle of amplification of a segment of DNA. It is used to identify infectious agents—bacteria, viruses and parasites.

57. What are the uses of PCR in uveitis?

Currently used to detect viral DNA in eyes with ARN and to diagnosis ocular toxoplasmosis, TB.

58. What is the importance of serum lactate dehydrogenase (LDH) in uveitis?

Serum LDH is useful in the diagnosis of retinoblastoma, which can present as uveitis (masquerade syndrome).

59. Serum lysozyme—what is its importance in uveitis?

- Increased in TB, sarcoidosis, leprosy
- Normal levels 1–2 µg/dl

60. What is Rheumatoid factor composed of?

- i. 7S IgG
- ii. 7S IgM
- iii. 19S IgM.

61. What are the conditions, in which rheumatoid factor is positive?

- i. Rheumatoid arthritis
- ii. Juvenile rheumatoid arthritis
- iii. SLE
- iv. Sjogren's syndrome
- v. Scleroderma
- vi. Infections, e.g. syphilis, infectious mononucleosis, hepatitis.

62. What are the conditions, in which rheumatoid factor is negative?

- i. JRA (pauciarticular variety)
- ii. Seronegative spondyloarthropathies like psoriasis, ulcerative colitis, Crohn's disease and Reiter's syndrome
- iii. Ankylosing spondylitis.

63. What antibody testing methods are used in uveitis?

- i. ELISA
- ii. IFA
- iii. Complicated fixation test
- iv. Hemagglutination test.

64. How is anterior chamber (AC) paracentesis done?

It is done with a 26 gauge needle attached to 1 cc tuberculin syringe. At the limbus a gutter is made with a blade; care taken to be parallel to plane of iris with bevel up.

It provides small amount of fluid (200–250 µg).

65. Who proposed AC paracentesis first?

Desmont.

66. What are the uses of AC tap?

- i. Detection of organisms by direct exam/culture
- ii. Microscopic study to rule out malignancy
- iii. Assessment of non-specific biological enzyme, e.g. aqueous ACE
- iv. Immunological test for infection agent, e.g. ELISA to show herpes simplex in ARN
- v. Cell cytology.

67. How is cell cytology of aqueous sample done?

Small drop of aqueous is placed on the slide-fixed in absolute methanol for 10 minutes, air dried, stained with Giemsa for 1 hour, rinsed with 95% ethanol and let to dry.

68. What are the therapeutic investigations done in uveitis?

- i. Vitrectomy
- ii. Trial of anti-tuberculous treatment
- iii. Trial of steroids.

69. What are the cells found in AH in different condition?***Type of cells Condition***

Neutrophils—Bacterial infection

Eosinophils—Parasitic infection

Lymphocytes—Viral, fungal, autoimmune and hypersensitivity uveitis

Macrophages—Phacoanaphylactic/Sympathetic ophthalmia

Tumor cells—Foreign Body/Masquerade syndrome

70. How is vitreous aspiration done?

- Done with 18–20 gauge needle
- The aspirate is sent for cytology, antibodies and culture.

71. Why is vitrectomy preferred over vitreous aspiration?

- i. Collection of more material
- ii. Apart from diagnostic use, it may also prove therapeutic, e.g. in phacoanaphylactic uveitis
- iii. Less complications due to controlled traction on vitreous base
- iv. Avoids long-term hypotony
- v. Chorioretinal biopsy can also be taken with vitrectomy.

72. What are the indications and techniques for chorioretinal biopsy in uveitis?

The main indication is bilateral vision threatening disease not responding to treatment, in which etiology cannot be established.

Can be done by:

- i. Making scleral flap at site of lesion by microblade and vannas scissor.
- ii. Can be also done endoretinally while doing vitrectomy with vitrectomy scissors and forceps.

73. What are the contraindications of chorioretinal biopsy?

Infections of retina and choroid.

74. What are the complications of chorioretinal biopsy?

- i. Choroidal hemorrhage
- ii. Retinal detachment
- iii. Infection
- iv. Proliferative vitreoretinopathy.

75. When is lacrimal gland biopsy done in uveitis?

Lacrimal gland biopsy is done in suspected sarcoidosis, but only if lacrimal glands are clinically enlarged or show increased uptake on gallium scan.

76. What are the indications for invasive procedures in uveitis?

- i. Uncontrolled uveitis
- ii. Endophthalmitis
- iii. Threatened vision
- iv. Doubtful malignancy
- v. Viral retinitis
- vi. Research tool.

77. How is feces examination useful in uveitis?

It is useful to diagnose the following organisms:

- i. *E. coli*
- ii. *E. histolytica*
- iii. *Ascariasis*
- iv. *Giardiasis* (can cause CME).

78. What X-rays are taken in uveitis?**A. X-ray chest:** TB, Sarcoidosis, histoplasmosis

In TB—X-ray chest may show fibrocavitary lesions or miliary lesions.

In sarcoidosis—Findings can be divided into 4 stages.

Stage 1: Bilateral Lymphadenopathy and normal parenchyma.

Stage 2: Bilateral Lymphadenopathy and reticulonodular parenchymal infiltrates.

Stage 3: Reticulonodular infiltrates alone.

Stage 4: Progressive pulmonary fibrosis.

B. X-ray sacroiliac joint: In all young patients with acute unilateral iritis irrespective of presence or absence of low backache. This is because X-ray may be positive before patient is symptomatic in cases of ankylosing spondylitis.**C. X-ray hands and feet:** Sarcoidosis

CT/MRI brain is indicated in lymphoma.

D. X-ray skull: Cerebral calcifications in congenital toxoplasmosis, CMV.**79. What is the importance of gallium scan?**

- i. Gallium is taken up by mitotically active liposomes of granulocytes.
- ii. Scanning is done 48 hours after intravenous injection of labelled gallium citrate.

80. What is the importance of gallium scan in the diagnosis of sarcoidosis?

- i. In acute systemic sarcoidosis, gallium scan of head, neck and chest shows increased uptake.
- ii. This increased uptake + increased aqueous ACE – highly suggestive of sarcoidosis.

81. In which condition is iris angiography done?

Fuch's heterochromic iridocyclitis—new vessels—in the angle.

82. What are the indications of FFA in uveitis?

- i. Vogt Koyanagi Harada syndrome
- ii. Acute polypoidal multifocal PPE
- iii. Multiple evanescent white dot syndrome (MEWDS)
- iv. Serpinginous choroiditis.

83. What are the major FFA findings in uveitis?

- i. Cystoid macular edema
- ii. Sub retinal neovascular membrane
- iii. Disc leakage
- iv. Late staining of retinal vessels
- iv. Neovascularization of retina
- v. Retina vascular capillary drop out and reorganization
- vi. RPE perturbation.

84. What are the uses of USG (ultrasonography) in uveitis?

- i. To diagnosis masquerade syndromes like lymphoma, benign lymphoid hyperplasia and diffuse melanoma.
- ii. To plan surgery in hazy media due to complicated cataract.
- iii. Vitreal disorders like hemorrhage, inflammation, pars planitis, retained lens fragments.
- iv. Optic disc edema and cupping.
- v. Macular edema and exudative detachment.
- vi. Choroidal thickening, uveal effusion, scleritis, Harada's disease, sympathetic ophthalmia hypotony.
- vii. To rule out Coat's disease and intraocular tumors.
- viii. Useful in VKH and toxocariasis.

85. What is the importance of visual fields in uveitis?

- i. Association with secondary glaucoma—glaucoma damage can be estimated.
- ii. Behcet's syndrome
- iii. Uveitis syndromes are associated with neurologic disorders VF may be helpful in differentiating papillitis from juxtapapillary uveitis
- iv. Differentiating uveitis from heredodegenerative diseases, e.g. RP from bone spicule pigmentation seen in luetic uveitis
- v. In the early diagnosis and follow-up.

86. What are the indications for lumbar puncture in uveitis?

- i. VKH
- ii. Reticulum cell sarcoma
- iii. Intraocular lymphoma.

3.7. TREATMENT OF UVEITIS

1. What are the aims of therapy?

- i. To prevent vision threatening complications
- ii. To relieve the patient's discomfort
- iii. To treat the underlying cause if possible.

2. What are the surgeries done in uveitis?

- i. Cataract extraction
- ii. Pupillary reconstruction
- iii. Glaucoma surgery
- iv. Peeling of ERM
- v. Scleral buckling
- vi. Vitrectomy.

3. What is the purpose of using mydriatics/cycloplegics?

- i. Give comfort by relieving the spasm of ciliary body and sphincter of pupil.
- ii. Prevent the formation of posterior synechiae by using a short acting mydriatic to keep the pupil mobile.
- iii. Breakdown posterior synechiae.
- iv. Reduce exudation from the iris:
1% atropine—most powerful and longest acting cycloplegic in severe acute inflammation. It is changed to a short acting agent, once inflammation subsides.

4. Which short acting cycloplegics are used and what is their role?

Short acting cycloplegics are used as they keep the pupil mobile, which is the best mechanism to prevent synechiae formation.

These agents include:

- i. Tropicamide 0.5%, 1.0%
- ii. Cyclopentolate 0.5%, 1.0%, 2.0%

(Note: Side effect of cyclopentolate—chemoattractant for leukocytes and so it may prove bad for uveitis)

When long acting cycloplegics are continued posterior synechiae occurs in dilated state thereby ill serving the very purpose of it.

5. What are the preparations commonly used topically?

- | | |
|--|--------------|
| i. Prednisolone acetate | 0.12% and 1% |
| Suspension (Pred Forte) | |
| ii. Prednisolone sodium phosphate solution | 0.12% and 1% |
| iii. Dexamethasone phosphate solution | 0.1% |
| iv. Fluoromethalone | 0.1% and 1% |

Duration and frequency of application depends upon severity of inflammation. Initially applied more frequently and tapered slowly over weeks as inflammation subsides.

Steroids should not be used topically more than 2–3 times/day without concomitant antibiotic drops applied once/twice daily. Antibiotic-steroid combinations are usually used.

6. What are the indications for periocular steroids?

- i. Severe acute anterior uveitis, especially ankylosing spondylitis with severe fibrin membrane/hypopyon.
- ii. Adjunct to topical/systemic treatment in resistant cases of chronic anterior uveitis.
- iii. Intermediate uveitis.
- iv. Poor patient compliance.

7. What are the advantages of periocular steroids over drops?

- i. To achieve therapeutic concentration behind lens.
- ii. Drugs not capable of penetrating corneas are able to enter the eye by penetrating sclera.
- iii. Long lasting effect achieved when a depot preparation is used.

8. What are the types of periocular preparations used?

- i. Anterior subtenon—Persistent severe anterior uveitis.
- ii. Posterior subtenon—Intermediate uveitis, posterior uveitis.
- iii. Sub-conjunctival and retrobulbar injections.

9. What are the types of periocular preparation used?

- i. Triamcinolone acetonide 40 mg
- ii. Depo-medral (methylprednisolone acetate) 40 mg.

10. What are complications of periocular steroids?

Topical complication + extraocular muscle fibrosis, scleromalacia and conjunctival necrosis.

11. Why is posterior sub-Tenon (PST) injection given temporally and in what frequency?

Because it reaches macula, when given temporally. It is given every 4–10 weeks. The injection site is close to insertion of inferior oblique, which corresponds to anatomical macula.

12. What are indications for systemic treatment with oral steroids?

- i. Intractable anterior uveitis (that has not responded to topical medications and anterior sub-Tenon's injections)
- ii. Intractable intermediate and posterior uveitis (that has not responded to PST).

13. What are contraindications to steroid treatment?

- i. Inactive disease with chronic flare
- ii. Very mild anterior uveitis
- iii. Intermediate uveitis with normal vision
- iv. Fuch's uveitis
- v. When anti-microbial treatment is more appropriate, e.g. candidiasis.

14. What are indications and dose of IV steroids?

- i. IV pulse methylpredniolone 1 g over 1–2 hour can be employed in cases of severe inflammatory process that needs to be treated as rapidly as possible.
- ii. IV methylprednisolone 1 g every day 3 days.

15. What are the indications for immunosuppressants?

- i. Vision threatening intraocular inflammation
- ii. Reversibility of the disease process
- iii. No response to steroids
- iv. Intolerable side effects of steroids.

16. Clinical conditions needing immunosuppressants according to IUSG?

- A. Absolute
 - Behcet's
 - Rheumatoid arthritis
 - Sympathetic ophthalmia
 - VKH
 - Serpiginous choroidopathy
- B. Relative
 - Intermediate uveitis in adults
 - Preretinal vasulitis
 - Chronic cyclitis

17. What are the classes of immunosuppressives?

- i. Antimetabolites
 - Methotrexate
 - Azathioprine
- ii. Alkylating agents
 - Cyclophosphamide
- iii. Antibiotics
 - Cyclosporine
- iv. Ergot alkaloid
 - Bromocriptine
- v. Dapsone
- vi. Colchicine
 - Anti-inflammatory

18. What are indications and side effects of different immunosuppressants?

		Indications	Side effects
1	Cyclophosphamide	Behcet's RA SO	Marrow suppression Hemorrhagic cystitis Sec. Malignancy
2	Chlorambucil	Behcet's SO	Marrow suppression Gonadal malignancy Sec. Malignancy Hepatotoxicity
3	Methotrexate	SO Scleritis	Marrow suppression Ulcerative stomatitis Diarrhea

Contd...

		Indications	Side effects
4	Azathioprine	Behcet's SLE Pemphigoid	Marrow suppression Secondary infection
5	Cyclosporine	Behcet's Birdshot chorioretinopathy Corneat graft rejection	Hepatotoxicity Nephrotoxicity Hyperuricemia
6	Bromocriptine	Adjunct to cyclosporine in anterior idiopathic uveitis	Nausea, vomiting Postural hypotension
7	Dapsone	Cicatrical pemphigoid	Hemolytic anemia Nausea
8	Colchicine	Behcet's	Nausea, vomiting Marrow suspension

19. What are indications for PKP in uveitis?

Corneal scarring caused by herpes simplex keratouveitis.

20. What are indications for vitrectomy?

- i. Diagnostic—endophthalmitis of suspected infective etiology
- ii. Therapeutic—progressive disease (hypotony) complications needing surgery, e.g. RD iris bombe with hypotony.

21. Ocular complications of steroids.

- i. Increased IOP
- ii. Decreased resistance to infection
- iii. Delayed healing of corneal/shear wounds
- iv. Mydriasis—may precipitate angle closure glaucoma
- v. Ptosis
- vi. Complicated cataract
- vii. Blurred vision
- viii. Enhances lytic action of collagenase
- ix. Paralysis of accommodation
- x. Visual field changes
 - scotoma
 - constriction
 - enlarged blind spot
 - glaucoma field defect
- xi. Problems with color vision
 - color vision defect
 - colored haloes around lights
- xii. Eyelids and conjunctiva
 - Allergic reactions
 - Persisted erythema
 - Jelangiectasion

- Depigmentation
- Poliosis
- scarring
- Fat atrophy
- Skin atrophy
- xiii. Cornea
 - SPK
 - Superficial corneal defects
- xiv. Irritation
 - Lacrimation
 - Photophobia
 - Ocular Pain
 - Burning sensation
 - Anterior uveitis
- xv. Corneal/scleral thickness
 - Increased—initial
 - Decreased
- xvi. Toxic amblyopia
- xvii. Optic atrophy
- xviii. May aggravate the following diseases:
 - Scleromalacia perforans
 - Corneal melting disease
 - Behcet's disease
 - Eales disease
 - Presumptive ocular
- xix. Retinal embolic phenomena

22. What are the systemic complications of steroids?

- A. Endocrine
 - i. Adrenal insufficiency
 - ii. Cushing's syndrome
 - iii. Growth failure
 - iv. Menstrual disorders
- B. Neuro psychiatric
 - i. Pseudotumor cerebri
 - ii. Insomnia
 - iii. Mood swings
 - iv. Psychosis
- C. Gastrointestinal
 - i. Peptic ulcer
 - ii. Gastric hemorrhage
 - iii. Intestinal perforation
 - iv. Pancreatitis
- D. Musculoskeletal
 - i. Osteoporosis
 - ii. Vertebral compression fracture

- iii. Aseptic necrosis of femur
- iv. Myopathy
- E. Cardiovascular
 - i. Hypertension
 - ii. Sodium and fluid retention
- F. Metabolic
 - i. Secondary diabetes mellitus
 - ii. Hyperosmotic ketoacidosis
 - iii. Centripetal obesity
 - iv. Hypelipidemia
- G. Dermatologic
 - i. Acne
 - ii. Hirsutism
 - iii. Subcutaneous tissue atrophy
- H. Immunologic
 - i. Impaired inflammatory response
 - ii. Delayed tissue healing.

4

Glaucoma

CHAPTER

4.1. TONOMETRY

1. What is the normal intraocular pressure (IOP)?

The normal intraocular pressure is between 10 mm Hg and 21 mm Hg.

2. Why is 21 considered as upper limit?

Intraocular pressure (IOP) distribution in general population resembles a Gaussian curve but skewed toward right. Mean IOP is considered to be 15.5 ± 2.57 mm Hg. Two standard deviation above the mean is approximately 20.5 mm Hg as approximately 95% of the area under a Gaussian curve lies between the mean ± 2 SD. The concept of normal IOP limits is viewed as only a rough approximation.

3. What are the two ways by which aqueous is secreted?

- i. Active secretion by non-pigmentary ciliary epithelium—80%
- ii. Passive secretion by ultrafiltration and diffusion—20%.

4. What are the factors that determine the level of IOP?

- i. Rate of aqueous secretion
- ii. Resistance encountered in outflow channels
- iii. Level of episcleral venous pressure.

5. What is normal episcleral venous pressure?

The normal is 8–10 mm of Hg.

6. What are the causes of elevated episcleral venous pressure?

1. Obstruction of venous drainage

- i. Thyroid eye disease
- ii. Radiation
- iii. Pseudotumor
- iv. Cavernous sinus thrombosis
- v. Jugular vein obstruction

- vi. Superior vena cava obstruction
- vii. Pulmonary venous obstruction

II. Arteriovenous fistulas

- i. Carotid-cavernous fistula
- ii. Sturge-Weber syndrome
- iii. Dural fistula
- iv. Venous varix.

7. What are the conditions which influence IOP?

- i. Diurnal variation
- ii. Postural variation
- iii. Exertional influences
- iv. Lid and eye movement
- v. Intraocular conditions
- vi. Systemic conditions
- vii. Environmental conditions
- viii. General anesthesia
- ix. Food and drugs.

8. How does the intraocular pressure vary diurnally?

The most common pattern is that the IOP is maximum in the morning and decreases as day progresses and becomes minimum in the evening. It once again starts to rise as the night progresses. The variation is about 3 to 6 mm Hg in normal individuals. The variation is about 10 mm Hg or more in a glaucomatous eye.

9. Why is this diurnal variation due to?

It is due to cyclic fluctuation of blood levels of adrenocortical steroids. Maximum IOP is reached 3 to 4 hours after the peak of plasma cortisol. The night time elevated IOP is due to the supine position along with the fluctuating cortisol levels.

10. What are the types of diurnal variation curves?

There are four types of diurnal variation curves.

They are:

- i. **Falling type:** maximal at 6–8 am followed by a continuous decline
- ii. **Rising type:** maximal at 4–6 pm
- iii. **Double variation type:** with 2 peaks 9–11 am and 6 pm
- iv. **Flat type** of curve.

11. How does IOP vary with posture?

The IOP rises (0.3–6 mm Hg) when the person is lying down. This may be because of increase in the episcleral venous pressure in the supine posture.

12. How does IOP vary with exertion?

Valsalva maneuvers increases IOP (by increasing episcleral venous pressure) while prolonged exercise decreases IOP (by metabolic acidosis and increased colloid osmotic pressure).

13. How does IOP vary with lid and eye movement?

Hard lid squeezing increases IOP because of increased orbicularis tone.

14. How does IOP vary with intraocular conditions?

Acute anterior uveitis causes a slight reduction in IOP because of decreased aqueous humor production. Rhegmatogenous retinal detachment also causes a reduction because of reduced aqueous humor production as well as shunting of aqueous humour from the posterior chamber through the vitreous and retinal hole into the subretinal space.

15. How does IOP vary with systemic conditions?***Systemic factors causing increased IOP:***

- i. Systemic hypertension
- ii. Systemic hyperthermia
- iii. ACTH and growth hormone stimulation
- iv. Hypothyroidism
- v. Diabetes.

Systemic factors causing decreased IOP:

- i. Pregnancy
- ii. Hyperthyroidism
- iii. Myotonic dystrophy.

16. How does IOP vary with environmental conditions?

Exposure to cold decreases IOP (because of lowered episcleral venous pressure) while reduced gravity increases IOP.

17. How does IOP vary with anesthetic agents?

In general, general anesthetic agents reduce IOP. However, trichloroethylene, ketamine succinylcholine and suxamethonium increase IOP.

18. How does IOP vary with food and drugs?***Factors increasing IOP:***

- i. Caffeine
- ii. Tobacco smoking.

Factors decreasing IOP:

- i. Alcohol
- ii. Heroin and marijuana.

19. Does heredity influence IOP?

Intraocular pressure (IOP) tends to be higher in individuals with enlarged cup-disk ratio and in relatives of open-angle glaucoma.

20. What is tonography?

Tonography is a method used to measure the facility of aqueous outflow. The facility of outflow is called as the C value and it ranges from 0.22–0.30 $\mu\text{L}/\text{min}/\text{mm}$ of Hg.

21. How is tonography performed?

The clinician first takes the IOP measurement by using a schiottz tonometer. The tonometer is placed on the cornea, acutely elevating the IOP. The rate at which the pressure declines with time is related to the ease with which the aqueous leaves the eye. The decline in IOP over time can be used to determine outflow facility.

Tonography technique:

- i. Patient in supine position
- ii. Topical anesthetic instilled on cornea
- iii. IOP measured with 2 brief application of electronic tonometers
- iv. 4 minute tracing of pressure at this position till a smooth tracing is obtained for full 4 minutes
- v. Slope is estimated by placing free hand line through middle of oscillations (readings at beginning and end noted)
- vi. P_0 and change in readings used to obtain C value from special tonographic tables.

$$F = C (P_0 - P_v)$$

F—Aqueous outflow rate (ml/min), P_0 —IOP

C—Coefficient of outflow facility, P_v —episcleral nervous pressure

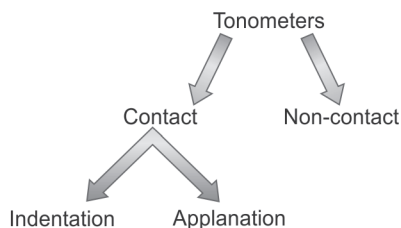
22. What is the principle of digital tonometry?

Compressibility of ocular coats is estimated by sense of fluctuation perceived on palpation.

23. How is IOP measured digitally?

After asking the patient to look down, the sclera is palpated through the upper lid above the tarsal plate using the tip of 2 fingers. One finger is kept still and the other indents the globe lightly.

24. What are the types of tonometers?



25. What are the types of weights used in Schiottz tonometry?

A 5.5 g weight is permanently fixed to the plunger, which can be increased to 7.5 or 10 and 15 g by adding additional weights.

26. What are the advantages of Schiötz tonometry?

- i. Easy to use
- ii. Portable
- iii. Useful for screening
- iv. Cost effective.

27. What are the disadvantages of Schiötz tonometry?

- i. **Ocular rigidity:** The more the scleral rigidity, the higher is the reading. Conversely, in conditions like high myopia, where the scleral rigidity is low, the IOP is underestimated.
- ii. **Corneal influences:** A steeper or thicker cornea causes a greater displacement of fluid during indentation tonometry, which leads to a falsely high tonometry reading.
- iii. **Blood volume alteration:** The variable expulsion of the intraocular blood during indentation tonometry may also influence IOP measurement.
- iv. **Moses effect:** The hole in the tonometer foot plate can be a source of error.

28. What are the precautions to be taken before using Schiötz tonometry?

- i. Touch the artificial cornea till the reading is at zero
- ii. Avoid pressure over the eyelids
- iii. Sterilize before using.

29. What are the other types of indentation tonometers?

- i. Herrington
- ii. Grants
- iii. Maurice.

30. What are the types of applanation tonometers?

They are of two types:

- | Variable force | Variable area |
|-----------------------|----------------------|
| i. Goldmann | i. Maklakov-Kalfa |
| ii. Perkins | ii. Applanometer |
| iii. Draeger | iii. Tonomat |
| iv. Mackay-Marg | iv. Halberg |

31. What is the principle of applanation tonometer?

It is based on Imbert-Fick law, which states that the pressure inside an ideal dry, thin walled sphere equals the force necessary to flatten its surface divided by the area of the flattening.

$$P = F/A$$

32. What is the most common applanation tonometer used?

The one designed by Goldmann for use with Haag-Streit slit lamp.

33. How much volume of aqueous is displaced?

Approximately 0.5 mm volume of aqueous is displaced.

34. How much of the anesthetized cornea does the circular plate flatten?

3.06 mm of corneal diameter is flattened, which is always constant. Hence, it is called constant area applanation tonometer.

35. How is the pressure calculated?

When the area is made constant (3.06 mm) then 0.1 g, reading corresponds to a pressure of 1 mm Hg.

36. What is the rationale behind using a circular plate of a particular (3.06 mm) diameter?

At this diameter, the resistance of the cornea to flattening is counter-balanced by the capillary attraction of the tear film meniscus for the tonometer head.

37. What dye is used under what illumination?

Fluorescein dye (0.25%) is used and viewed under cobalt blue light.

38. What should be the angle between the source of illumination and microscope?

The angle should be approximately 60°.

39. What mark is the knob set before the procedure?

The knob is set at 1. If placed at zero, microvibrations are produced which can cause corneal erosions.

40. What is observed when viewed through the eye piece?

The fluorescence of the stained tear facilitates visualization of the tear meniscus at the margin of the contact between cornea and bi-prism. A central blue circle, which is the flattened cornea, surrounded by 2 yellow semi-circles which is the tear meniscus is seen.

41. What is the desired end point of an applanation tonometer?

The bi-prism which contacts the cornea produces 2 semicircles which should be equal in size and inner sides of the two should coincide.

42. What are the advantages of applanation tonometers over indentation tonometry?

- i. Reliable and accurate
- ii. Reproducible
- iii. Not influenced by scleral rigidity.

43. What are the disadvantages or source of errors of applanation tonometry?

- i. **Central corneal thickness:** Thicker corneas produce falsely higher reading while thinner corneas produce falsely lower readings. However, corneal thickening due to edema causes a falsely lower reading. An average error is 0.7 mm Hg per 10 microns of deviation from the mean of 520 microns.
- ii. **Semicircles:** Wider meniscus and improper vertical alignment causes falsely higher reading.
- iii. **Corneal astigmatism:** Since astigmatism produces an elliptical area of contact, there is an error in measurement. IOP is underestimated in cases of with the rule astigmatism and over-estimated in cases with against the rule with approximately 1 mm Hg for every 4D of astigmatism.
- iv. **Design:** It has a complex design and can be done only in sitting position.
- v. **Corneal irregularity:** It is not useful in case of corneal irregularity.
- vi. **Errors following corneal refractive surgery:** It will not be accurate following Lasik surgery.

44. How can errors due to astigmatism be minimized?

The tonometer prisms should be rotated so that the axis of the least corneal curvature is opposite the red line on the prism holder.

45. What are the methods of disinfection of tonometers?

The following chemicals can be used to sterilize the tip of applanation tonometers:

- i. 3% hydrogen peroxide
- ii. 70% isopropyl alcohol
- iii. Diluted sodium hypochlorite solution (1:10)
- iv. Schiotz tonometer can be heat sterilized.

46. What are the infections likely to be transmitted?

- i. Adenovirus of epidemic keratoconjunctivitis (EKC)
- ii. HSV—type 1
- iii. HIV
- iv. Hepatitis B.

47. How is IOP measured in conditions of corneal scarring?

The following tonometers can be used:

- i. Non-contact tonometers
- ii. Mackay-Marg
- iii. Tonopen
- iv. Pneumatic tonometers.

48. What are the advantages of tonopen?

- i. Used in cases of corneal epithelial irregularities
- ii. Measurement of IOP over bandage contact lens
- iii. Useful in edematous and scarred corneas
- iv. Useful in patients with nystagmus and head tremors
- v. Used in operation theatre
- vi. Portable.

49. What is the principle of non-contact tonometers?

A puff of air creates constant force which deforms the central cornea. The time from an internal reference point to the moment of maximum light detection is measured and converted to IOP.

50. What are the disadvantages of NCT?

- i. Tear film damage
- ii. False positive and false negatives.

51. What are the newer modalities of IOP measurement?

- i. Optical response analyzer
- ii. Dynamic contact tonometer (pascal)
- iii. Rebound tonometer
- iv. Preview phosphene tonometer.

52. What is the principle behind dynamic contact tonometer (DCT)?

Pressure applied to an enclosed fluid is transmitted undiminished to every part of closed system including walls of container. By applying DCT cornea is placed in a neutral shape so that pressure on interior surface equals pressure on exterior surface.

53. Advantages of DCT over GAT (Goldmann applanation tonometer).

- i. No mechanical calibration
- ii. No fluorescein staining
- iii. Direct display of pressure as numerical values
- iv. Pressure reading independent of corneal thickness.

4.2. GONIOSCOPY

1. What is gonioscopy?

It is a clinical technique that is used to examine structures in the anterior chamber angle, using the principle of total internal refraction.

2. What is cycloscopy?

This is a technique of direct visualization of ciliary processes under special circumstances such as the presence of an iridectomy, wide iris retraction, aniridia and some cases of aphakia. Main value is in conjunction with laser therapy to ciliary processes (transpupillary cyclophotocoagulation).

3. What is the principle of gonioscopy?

Under normal conditions, light reflected from the angle structures undergoes total internal reflection at the tear-air interface. All gonioscopy lenses eliminate the tear-air interface by placing a plastic or glass surface adjacent to the front surface of the eye.

4. What are commonly used contact lenses for gonioscopy?

I. *Direct gonioscopy (Gonio lens):*

- i. Koeppe
- ii. Barkan
- iii. Worst
- iv. Swan-Jacob
- v. Richardson.

II. *Indirect gonioscopy (Gonio prism):*

- i. Goldmann
- ii. Zeiss
- iii. Posner
- iv. Sussman.

5. Describe direct gonioscopy.

This is performed with a binocular microscope, a fibreoptic illuminator or a pen light and a direct gonioscopy lens. It is mostly performed with the patient in a supine position, (example in an operating room for infants under anesthesia). With direct gonioscopy lenses, an erect view of the angle structures are obtained.

6. Describe indirect gonioscopy.

Instruments:

1. Goldmann single mirror	Mirror in this lens has a height of 12 mm tilt of 62 degrees from the plano front surface. Central well has a diameter of 12 mm posterior radius of curvature—7.38 mm
---------------------------	---

Contd...

Contd...

2. Goldmann three mirror	<p>Has two mirrors for examination of the fundus and one for the anterior chamber angle.</p> <p>Equatorial Mirror: It is largest and oblong shaped enables visualization from posterior pole to equator.</p> <p>Peripheral Mirror: Intermediate in size, square shaped enables visualization from equator to ora serrata.</p> <p>Gonioscopy Mirror: Smallest and dome shaped used to visualize extreme periphery and the angle.</p>
3. Zeiss four mirror (can be used for indentation gonioscopy)	<p>All four mirrors are tilted at 64 degrees. Original 4 mirror lens is mounted on a holding fork called unger or holder. Posners lens has permanently attached holder rod. Sussmans lens are held directly. Patient's own tears are useful as fluid bridge.</p>
4. Ritch trabeculoplasty	<p>Two mirrors are titled at 59 degrees. Two are titled at 62 degrees convex lens is present over one mirror of each set.</p>
5. Trabeculens	<p>Has a 30D convex lens in a hollow funnel, with four mirrors at 62 degrees angles. It can be used as a diagnostic gonioprism, as well as for laser trabeculoplasty and iridotomy.</p>

Techniques:

The cornea is anesthetized and with the patient positioned at the slit lamp, the gonioprism is placed against the cornea with or without a fluid bridge. The lens is then rotated to allow visualization of 360 degree of the angle.

Visualization into a narrow angle can be enhanced by manipulating the gonioprism, by asking the patient to look in the direction of the mirror being used.

7. Comparison of direct and indirect gonioscopy.

SI No	Advantages	Disadvantages
Indirect		
1. 2. 3. 4.	<p>Equipment easily available</p> <p>Quicker procedure</p> <p>Compression can be done</p> <p>Slit lamp provides light and optics</p>	<p>Orientation is confusing initially</p> <p>Difficult in narrow angles</p>

Contd...

Contd...

Sl No	Advantages	Disadvantages
Direct		
1.	Binocular Comparison	Special equipment
2.	Simple orientation	Time consuming
3.	Can see over convex iris	Expensive, Uncomfortable to the patient due to the supine position

8. What is compression gonioscopy?

This is also called as dynamic gonioscopy or indentation gonioscopy. By varying, the amount of pressure applied to the cornea by a Zeiss contact lens the physician can observe the effects, since this will cause the aqueous humor to be forced into the angle. This is used to differentiate appositional versus synechial angle closure.

9. Describe normal structures of the angle seen in gonioscopy.

Starting at the root of the iris and progressing anteriorly toward the cornea, the following structures can be identified by gonioscopy (from behind forward):

- i. **Ciliary body band:** This is a gray or dark brown band and is the portion of ciliary body, which is visible in the anterior chamber as a result of the iris insertion into the ciliary body.
- ii. **Scleral spur:** This is usually seen as a prominent white line between the ciliary body band and functional trabecular mesh work. This is the posterior lip of the scleral sulcus.
- iii. **Trabecular meshwork:** This is seen as a pigmented band just anterior to the scleral spur. It has an anterior and posterior part. The posterior part is the primary site of aqueous outflow.
- iv. **Schwalbe's line:** This is the junction between the angle structures and the cornea.

10. Mention the clinical uses of gonioscopy.

A. Diagnostic:

- i. Differentiate between open angle and angle closure glaucoma
- ii. Early detection of narrow angles
- iii. Helps in diagnosing secondary glaucomas like trauma (angle recession), neovascular (new vessels in the angle) and pseudoexfoliative (deposition of pseudoexfoliation material), and pigmentary glaucoma
- iv. Helps in identifying tumor, cysts, foreign bodies or blood in the angle
- v. Assess K-F ring (Wilson's disease).
- vi. Postoperative evaluation:
 - a. Ostium
 - b. Cyclodialysis
 - c. Iridotomy.

B. Therapeutic:

- i. Indentation gonioscopy can be used to break an attack of acute angle closure.
- ii. Useful to do goniotomy and gonio photocoagulation.

11. How do you differentiate iris processes and peripheral anterior synechiae (PAS)?

Iris process	PAS
Lacy, Fenestrated	Solid, not fenestrated
Underlying angle structures visible through spacer between strands	Preclude any view of underlying structures

12. How do you differentiate between the normal blood vessel in angle and the pathological angle vessels?

Normal blood vessel in angle	Pathological angle vessels
Broad	Fine
It will not cross the scleral spur	Cross the scleral spur
Do not arborize	Branch, arborize in Trabecular Meshwork

13. How do you differentiate between Sampaolesi's line and pigmented trabecular meshwork?

Sampaolesi's line	Pigmented trabecular meshwork
Salt and pepper appearance	Brown sugar
Dark and granular	Fine
Discontinuous	Continuous

14. Mention the causes of trabecular meshwork pigmentation.

- i. Pigmentary glaucoma/pigment dispersion syndrome
- ii. Pseudoexfoliation
- iii. Pseudophakic pigment dispersion
- iv. Trauma
- v. Following YAG—laser iridotomy
- vi. Following acute angle closure glaucoma
- vii. Anterior uveitis
- viii. Iris melanoma
- ix. Epithelial cysts
- x. Nevus of ota
- xi. Darkly pigmented iris.

15. What are the causes of blood in the angle?

- i. Post traumatic
- ii. Post surgical
- iii. Post laser
- iv. Ghost cells recognized as candy stripe pattern.

16. What are the causes of blood in schlemm canal?

A. Due to increased episcleral venous pressure

- i. Carotid-cavernous fistula
- ii. Dural shunt

- iii. Sturge-Weber syndrome
- iv. Obstruction of superior vena cava
- v. Ocular hypotony
- vi. Post gonioscopy.

B. Due to low intraocular pressure

- i. Following trabeculectomy
- ii. Hypotony.

17. What are the causes of peripheral anterior synechiae?

- i. Primary angle-closure glaucoma
- ii. Anterior Uveitis
- iii. Iridocorneal endothelial (ICE) syndrome
- iv. Secondary glaucoma following intraocular surgery (like wound leak, etc.)
- v. Trauma.

18. What are the findings one can expect in gonioscopy following trauma?

- i. Angle recession
- ii. Trabecular dialysis
- iii. Cyclodialysis
- iv. Foreign bodies.

GONIOSCOPIC GRADING OF ANGLES STRUCTURE

A. Shaffer's grading system

S.No	Angle Grade	Numeric Grade	Degrees	Clinical Interpretation	Structure visible
1.	Wide open angle	4	35–40 degree	Closure impossible	Upto ciliary body
2.	Open	3	25–35 degree	Closure impossible	Upto ciliary body
3.	Moderately narrow	2	20 degree	Eventual Closure possible. But unlikely	Trabecular Meshwork (Pigmented)
4.	Extremely narrow	1	10 degree	Closure possible	Only Schwalbe line. May be anterior TM (Non pigmented) seen
5.	Slit angle	S	< 10 degree	Portions appear closed	No angle structures seen. But no obvious iridocorneal contact
6.	Closed angle	0	-	Closure complete	Iridocorneal contact

In Grade O—Indentation gonioscopy with zeiss goniolens in necessary to differentiate appositional from synechial angle closure.

1. Define occludable angle.

This is a condition in which pigmented trabecular meshwork is not visible (shaffer grade 1 or 0) without indentation or manipulation in atleast three quadrants.

2. Scheie's Gonioscopic Classification.

S.No	Grade	Structure visible
1.	Wide open	All structure visible
2.	Grade 1 narrow	Hard to see the root of iris
3.	Grade 2 narrow	Ciliary body band obscured
4.	Grade 3 narrow	Posterior trabecular meshwork obscured
5.	Grade 4 narrow	Only Schwalbe's line visible

3. Spaeth Classification.

Takes four parameters into consideration.

a. Site of iris root insertion

A	Anterior to TM (i.e. schwalbe's line)
B	Behind schwalbe's line (at the level of TM)
C	Centred at the level of scleral spur
D	Deep to scleral spur (i.e. anterior to CB)
E	Extremely deep Inserted into CB

b. Width or geometric angle of iris insertion

The angle between the intersection of imaginary tangents formed by peripheral third of iris and the inner wall of corneoscleral junction. It is graded as 10, 20, 30 degree and 40 degree.

c. Contour of peripheral iris near the angle

S	Steep or convex configuration
R	Regular or flat
Q	Queer—deeply concave

d. Intensity of trabecular meshwork pigmentation minimal or no pigment—grade—to dense pigment deposition grade 4.

4.3. GLAUCOMA DIAGNOSTIC WITH VARIABLE CORNEAL COMPENSATION (GDx VCC)

1. What are the key elements of the printout?

A. The thickness map

Retinal nerve fiber layer (RNFL) thickness represented on color coded map

Thick RNFL—yellow, orange, red

Thin RNFL—dark blue, light blue and green.

B. The deviation map

Location and magnitude of RNFL defects over the map.

C. The TSNIT map

Displays RNFL thickness over the calculation circle

Normal TSNIT—Map follows a double hump pattern, i.e.

Thick RNFL—superior, inferior

Thin RNFL—nasal, temporal

shows actual values along with shaded area representing normal range for that age.

D. The parameters

- i. TSNIT average
- ii. Superior average
- iii. Inferior average
- iv. TSNIT standard deviation
- v. Inter eye a symmetry.

2. How is the measurement done? What area is measured and at how many points?

It is performed with an undilated pupil of at least 2 mm diameter. As the scanner has two mirrors that oscillate at 4000/sec, there is a high-pitched noise emitted.

65,536 points are measured in a full 15 × 150 grid centered at the optic nerve head.

The central ellipse denotes an area of 1.75 disk diameter in size.

The reproducibility of images is 5–8 micron per measured pixel.

Image quality check: A warning is given if image fails to meet criteria.

The quality of image is affected by cataracts and poor media clarity.

3. What are the abnormal patterns on the thickness map?

Abnormal patterns include:

- i. Diffuse loss of NFL, causing areas that should be yellow to fade to red
- ii. Focal defects are seen as concentrated dark areas (Should be visible on fundus image as well)
- iii. Asymmetry between superior and inferior quadrants

- iv. Asymmetry between the two eyes
- v. Higher than normal nasal and temporal thickness (red and yellow where blue should be).

4. What is the sensitivity and specificity of GDx VCC?

- i. Sensitivity—96%
- ii. Specificity—93%.

5. What are advantages of GDx VCC?

Advantages of GDx VCC:

- i. Easy to operate
- ii. Does not require pupillary dilatation
- iii. Good reproducibility
- iv. Does not require a reference plane
- v. Can detect glaucoma on the first exam
- vi. Early detection before standard visual field
- vii. Comparison with age matched normative data base

6. What are limitations of GDx VCC?

Limitations of GDx VCC:

- i. It does not provide optic nerve head analysis
- ii. Limited use in moderate/advanced glaucoma
- iii. Does not measure actual RNFL thickness (inferred Value)
- iv. No clinical studies on detection of progression using this technology
- v. No database from the Indian population
- vi. Affected by anterior and posterior segment.

Pathology such as:

- i. Ocular surface disorders
- ii. Macular pathology
- iii. Cataract and refractive surgery
- iv. Refractive errors (false positive in myopes)
- v. Peripapillary atrophy (scleral birefringence interferes with RNFL measurement).

7. What is scanning laser polarimetry?

Scanning laser polarimetry is an imaging technology that is utilized to measure peripapillary RNFL thickness. It is based on the principle of birefringence. GDx is the trade name which uses this technology.

8. What is VCC?

VCC stands for variable corneal compensator, which has been created to account for the variable corneal birefringence in patients.

4.4. GLAUCOMA VISUAL FIELD DEFECTS

1. What is visual field?

Traquair defined visual field as an island hill of vision in a sea of darkness. The island of vision is usually described as a three-dimensional graphic representation of differential light sensitivity at different positions of space.

2. What is the extent of the normal visual field?

Superior	: 60 degrees
Inferior	: 75 degrees
Nasally	: 60 degrees
Temporally	: 120 degrees

3. What is blind spot?

This region corresponds to the optic nerve head, and because there are no photoreceptors in the area, it creates a deep depression within the boundaries of the normal visual field.

4. What is kinetic perimetry?

Kinetic perimetry is one in which a target is moved from an area where it is not seen to an area where it is just seen, e.g. Goldmann perimetry.

5. What is static perimetry?

A stationary stimulus is presented at various locations, e.g. Humphrey's perimetry.

6. What are the variables that can influence perimetry?

- i. Alertness of the patient
- ii. Fixation must be constant and centered
- iii. Background luminance: should be maintained between 4 and 31 apostilbs
- iv. Brighter the stimulus, more visible it will be
- v. Patient refraction should be fully corrected
- vi. Pupil size should be constant (2–4 mm)
- vii. Increasing age is associated with a reduction in retinal threshold sensitivity
- viii. High cheekbones and sunken socket
- ix. Media clarity.

7. What are the causes of generalized decrease in sensitivity of the visual field?

- i. Glaucoma
- ii. Cataracts
- iii. Use of miotics
- iv. Gross uncorrected refractive errors
- v. Other media opacities

8. What is an isopter?

A line on a visual field representation connecting points with the same threshold. It is usually done on a two-dimensional sheet of paper.

9. What is a scotoma?

An area of decreased retinal sensitivity within the visual field surrounded by an area of greater sensitivity.

10. What is a depression?

Depression is a decrease in retinal sensitivity.

11. What are the sequential progression of visual field defects in glaucoma?

- i. Generalized depression
- ii. Paracentral scotoma
- iii. Siedel's scotoma
- iv. Arcuate or Bjerrum scotoma
- v. Double arcuate or ring scotoma
- vi. Nasal step
- vii. Progressive contraction
- viii. Central island and temporal island with or without split fixation.

12. What are angioscotomas?

Angioscotomas are long branching scotomas above and below the blind spot, which are presumed to result from shadows created by the large retinal blood vessels.

13. What is Bjerrum's area?

It is an arcuate area extending above and below the blind spot between 10 and 20 of fixation point.

14. What is Arcuate (or) Bjerrum's Scotoma?

The arcuate scotoma starts from the blind spot and arches above or below fixation, or both, to the horizontal median raphe, corresponding to arcuate retinal nerve fibres. Visual loss in glaucoma commonly occurs within this arcuate area, especially in the superior half, which correlates with the predilection of the inferior and superior poles.

15. What are the differential diagnosis for arcuate scotoma?**A. Chorioretinal lesions:**

- i. Juxtapapillary choroiditis
- ii. Myopia with peripapillary atrophy
- ii. Panretinal photocoagulation.

B. Optic nerve head lesions:

- i. Drusen
- ii. Retinal artery plaques
- iii. Chronic papilledema

- iv. Colobomas
- v. Optic pit.

C. Anterior optic nerve head lesion:

- i. Electric shock
- ii. Retrobulbar neuritis
- iii. Cerebral arteritis
- iv. Ischemic optic neuropathy.

D. Posterior lesions of the visual pathway:

- i. Pituitary adenoma
- ii. Optochiasmatic archnoiditis
- iii. Meningiomas of dorsum sellae.

16. What is paracentral scotoma?

It is the earliest clinically significant field defect. It may appear either below or above the blind spot in Bjerrum area.

17. What is Seidel's scotoma?

When the disease progresses, paracentral scotoma joins with the blindspot to form a sickle shaped scotoma known as Seidel's scotoma.

18. What is ring (or) double arcuate scotoma?

It develops when the two arcuate scotomas join together.

19. What is Roenne's central nasal step?

It is created when the two arcuate scotomas run in different arcs and meet to form a sharp right angled defect at the horizontal meridian.

20. What is true baring of blindspot and false baring of blindspot?

When a small isopter is being studied, a patient with Seidel's scotoma may demonstrate a connection between the blindspot and non-seeing area outside the 25 degree radius. This is true baring of blind spot. A normal patient may exhibit false baring of blindspot, when the isopter is just outside blindspot.

21. What are the differences between neurological and glaucomatous field defects?

Neurological field defects

- i. It follows the vertical meridian
- ii. Absolute field defect
- iii. Field defects are mostly congruous.

Glaucomatous field defects

- i. It follows horizontal meridian
- ii. Relative field defect
- iii. Field defects are incongruous.

22. What is standard automated perimetry (SAP)?

It is also called as achromatic automated perimetry. With this procedure, threshold sensitivity measurements are usually performed at a number of test locations using white stimuli on a white background.

23. What is short wavelength automated perimetry (SWAP)?

This is also known as blue yellow perimetry. Standard perimeters are available that can project a blue stimulus onto a yellow background.

Sensitivity to blue stimuli is believed to be mediated by small bi-stratified ganglion cells that typically have large receptive fields. This method is more sensitive to detect early stages of glaucoma.

24. What are the advantages and disadvantages of SWAP?

Advantages

- i. Detects glaucoma early
- ii. Can track progression.

Disadvantages

- i. Tedious and time consuming
- ii. Affected by refractive error and media opacities.

25. What is frequency doubling technology (FDT) perimetry?

The FDT perimeter was developed to measure contrast detection thresholds for frequency doubled test targets. This test uses a low spatial frequency sinusoidal grating undergoing rapid phase reversal flicker. The instruments employ a 0.25 cycle per degree grating phase reversed at a rapid 25 Hz. It is believed that this stimuli employed in this test preferentially activate the M cells and are most sensitive in the detection of early glaucomatous loss.

26. What are the advantages and disadvantages of FDT perimetry?

Advantages

- i. Portable
- ii. Can be used in ambient illumination
- iii. Relatively insensitive to refractive error
- iv. Shorter learning curve.

Disadvantages

- i. Affected by media opacity
- ii. False positives possible.

27. What is false positivity?

When a patient responds at a time when no test stimulus is being presented, a false positive response is recorded. False positives more than 33% suggests an unreliable test.

28. What is false negativity?

When a patient fails to respond to a stimulus presented in a location where a dimmer stimulus was previously seen, a false negative response is recorded. False negativities more than 33% suggest an unreliable test.

29. What is threshold?

The differential light sensitivity at which a stimulus of a given size and duration of presentation is seen 50% of the time.

30. What is a decibel (dB)?

The measured light sensitivity is expressed in logarithmic units referred to as decibels. It is a 0.1 log unit. It is a relative term used both in static and

kinetic perimetry. It refers to log units of attenuation of the maximum light intensity available in the perimeter. The standard staircase strategy used by automated perimeters employs an initial 4 dB step size that decreases to 2 dB on first reversal and continues until a second reversal occurs.

31. What are the testing strategies in automated perimetry?

- i. Suprathreshold strategy : For screening purposes
- ii. Threshold related strategy : For moderate to severe defects
- iii. Threshold strategy : Current standard for automated perimetry
- iv. Efficient threshold strategies : This is a shorter threshold testing typified by Swedish interactive thresholding algorithm (SITA) and takes only 50% of regular threshold strategy.

32. What are the common programs for glaucoma testing using automated perimetry?

- i. Octopus 32 : Central 24 degree and 30 degree programs
- ii. Humphrey field analyzer (HFA) : 24-2 and 30-2 programs.

These programs test the central field using a 6 degree grid. For patients with advanced visual field loss that threatens fixation, serial 10-2 should be used.

33. What are test programs of HFA?

- i. Central field test : Central 30-2 test
Central 24-2 test
Central 10-2 test
Macula test
- ii. Peripheral field test : Peripheral 30/60-1
Peripheral 30/60-2
Nasal step
Temporal crescent
- iii. Speciality test : Neurological-20
Neurological-50
Central 10-12
Macular test

34. What is central 30-2 tests?

It is the most comprehensive form of visual field assessment of the central 30 degrees. It consists of 76 points at 6 degrees apart on either side of the vertical and horizontal axes. The inner most points are three degrees from the fixation point.

35. What is mean deviation?

It is the mean difference between the normative data for that age compared with that of collected data. It is more an indicator of the general depression.

36. What is pattern standard deviation?

It is a measure of variability between two different points within the field, i.e. it measures the difference between a given point and adjacent point. It determines localized field effect.

37. What is glaucoma Hemifield test?

It compares the five clusters of points in the upper field (above the horizontal midline) with the five mirror images in the lower field. These clusters of points are specific to the detection of glaucoma outside normal limits.

38. What are the indicators in automated perimetry which indicates glaucomatous progression?

- i. Average fluctuations between two determinations of visual field will be more than 3 dB
- ii. Deepening of an existing scotoma is suggested by the reproducible depression of a point in an existing scotoma by >7 dB.
- iii. Enlargement of an existing scotoma is suggested by the reproducible depression of a point adjacent to an existing scotoma by >9 dB.
- iv. Development of a new scotoma is suggested by the reproducible depression of a previously normal point in the visual field by >11 dB, or of 2 adjacent, previously normal points by >5 dB.

39. What is the criteria to grade glaucomatous field defects?

Parameters	Early defects	Moderate defects	Severe defects
Mean Deviation	<-6 dB	- 6 dB — -12 dB	>-12 dB
Corrected pattern standard deviation	Depressed to the P < 5%	Depressed to the P < 5%	Depressed to the P < 5%
Pattern deviation plot			
1. Points depressed below P < 5%	<18 (25%)	<37 (50%)	>37 (>50%)
2. Points depressed below P < 1%	<10	<20	>20
Glaucoma Hemifield test	Outside normal limits	Outside normal Limits	Outside normal limits
Sensitivity in central 5 degree	No point <15 dB	One hemifield may have point with sensitivity <15 dB	Both hemifields have points with sensitivity <15 dB

40. What are Anderson's criteria?

- i. Glaucoma hemifield test (GHT): Outside normal limits on at least two consecutive occasions.
- ii. Three or more nonedge points in a location typical of glaucoma all of which are depressed at $P < 5\%$ and one of which is depressed at $P < 1\%$ level on two consecutive occasions.

- iii. Corrected pattern standard deviation (CPSD), (it takes into account the short term fluctuations; thereby highlighting the localized defects. It accounts for intra observer variations), at $P < 5\%$ level.

41. What are the features of tangent screen?

- i. It may be used at 1 or 2 meters
- ii. It should have a uniform illumination of 7 foot candles
- iii. Should be large enough to allow testing of the full 30° of central field.

42. What are the features of Goldman perimetry?

- i. It is a type of bowl perimetry
- ii. The maximum stimulus should be 1000 apostilbs
- iii. The background illumination should be 31.5 apostilbs
- iv. A threshold target is initially identified. Careful investigation of the 5° , 10° and 15° isopters is necessary to detect early glaucoma.

43. What are the other psychophysical tests useful in glaucoma?

- i. High pass resolution perimetry
- ii. Motion detection perimetry
- iii. ERG
- iv. Pattern ERG
- v. Multifocal visual evoked potential.

4.5. ULTRASOUND BIOMICROSCOPY IN GLAUCOMA

1. What is UBM?

The ultrasound biomicroscope (UBM) is a high frequency ultrasound machine with 50–100 MHz transducers. It is used to image ocular structures anterior to the pars plana region of the eye in living patients.

2. Give characteristics of the UBM image.

It produces cross sectional images of anterior segment structures providing

- i. Lateral resolution of 50 μ
- ii. Axial resolution of 25 μ
- iii. Depth of penetration of approximately 4–5 mm
- iv. Field of view is 5 \times 5 mm
- v. Vertical image lines 256
- vi. Scan rate is 8 frames/second

3. What are qualitative uses of UBM?

I. GLAUCOMA

a. Angle closure glaucoma

Angle closure can occur in four anatomic sites, the iris (pupillary block), the ciliary body (plateau iris), the lens (phacomorphic glaucoma) and behind the iris by a combination of various forces (malignant glaucoma and other posterior pushing glaucoma types). Differentiating these sites is the key to provide effective treatment. UBM is extremely useful in achieving this goal.

i. Angle occludability

Dark room provocative testing can be done generating objective results using UBM.

ii. Pupillary block

Unbalanced relative pressure gradient between anterior and posterior chamber results in anterior iris bowing, angle narrowing and acute or chronic angle closure, seen on UBM.

iii. Plateau iris

Indentation UBM shows double-hump sign (as seen on indentation gonioscopy).

iv. Malignant glaucoma

UBM clearly shows that all anterior segment structures are displaced and pressed tightly against the cornea with or without fluid in the supraciliary space.

v. Other causes of angle closure

Iridociliary tumor, enlargement of ciliary body due to inflammation or tumor infiltration, air or gas bubble after intraocular surgery, can be diagnosed on UBM.

b. Open-angle glaucoma

The only type of open-angle glaucoma showing typical finding on UBM is pigment dispersion syndrome. UBM shows widely open angle, posterior bowing of the peripheral iris and increased iridolenticular contact.

II. OCULAR TRAUMA**i. Detection of foreign body**

Wood and concrete: Shadowing artifact

Metal and glass: Cosmetic artifact

Detection of location of intraocular lens for research purposes

ii. Angle recession

Ultrasound biomicroscopy (UBM) shows the separation between the longitudinal and circular ciliary muscles

iii. Cyclodialysis

Cyclodialysis cleft confirmed on UBM as an echoluscent streak between the sclera and ciliary body, just posterior to the scleral spur.

4. What are quantitative uses of UBM in biometry of anterior chamber?

Quantitative uses in biometry of anterior chamber

Determination of:

- i. Corneal thickness
- ii. Anterior chamber depth
- iii. Posterior chamber depth
- iv. IOL thickness
- v. Scleral thickness.

5. Advantages and disadvantages of UBM.**Advantages**

- i. Quick
- ii. Convenient
- iii. Minimally invasive investigative tool
- iv. Imaging of the anterior segment structures is possible even in eyes with corneal edema or corneal opacification that precludes gonioscopic assessment.

Disadvantages

- i. Bulky instrumentation
- ii. Limited penetration into the eye.

4.6. ANGLE CLOSURE GLAUCOMA

1. Classify angle closure glaucoma.

1. *Primary:*

A. With pupillary block

- i. Primary angle closure (acute/subacute/chronic)

B. Without pupillary block

- i. Plateau iris syndrome
- ii. Plateau iris configuration

2. *Secondary:*

A. With pupillary block

- i. Miotic induced
- ii. Swollen lens
- iii. Mobile lens syndromes (ectopia lentis/microspherophakia)

B. Without pupillary block

- i. Synechiae to lens/vitreous/PCIOL
- ii. Anterior "PULLING" mechanisms (iris is pulled forward by some membrane)
 - 1. Neovascular glaucoma
 - 2. Iridocorneal endothelial syndromes
 - 3. Post PKP
 - 4. Aniridia
- iii. Posterior "PUSHING" mechanisms (iris is pushed forward by some posterior segment pathology with anterior rotation of the ciliary body)
 - 1. Ciliary block glaucoma
 - 2. Cysts of iris/ciliary body
 - 3. Nanophthalmos
 - 4. Intraocular tumors
 - 5. Intravitreal air (pneumoretinopexy)
 - 6. Suprachoroidal hemorrhage.

2. What are the modern consensus classifications?

i. Primary angle closure suspect:

- Greater than 270° of iridotrabecular contact
- Absence of PAS
- Normal IOP, disk and visual fields

ii. Primary angle closure (PAC)

- Greater than 270° of iridotrabecular contact
- Either elevated IOP and/or PAS
- Normal disk and fields

iii. Primary angle closure glaucoma (PACG)

- Greater than 270° of iridotrabecular contact
- Elevated IOP plus optic nerve and visual field damage.

3. What are the predisposing factors for angle closure glaucoma?

The predisposing factors for ACG include:

a. Anatomical factors

- i. Eyes with small axial length (hypermetropia, nanophthalmos)
- ii. Smaller corneal diameter
- iii. Decreased corneal height
- iv. Shallow anterior chamber
- v. Plateau iris configuration
- vi. Anteriorly placed iris lens diaphragm
- vii. Thicker and more curved lens (e.g. microspherophakia)
- viii. More anterior insertion of the iris into the ciliary body.

b. Physiological factors

- i. Mid dilated pupil
- ii. Dim illumination
- iii. Near work
- iv. Prone position.

c. Demographic factors

- i. Gender: More common in females
- ii. Race: Indians, Eskimos and other Asian groups.

d. Psychosomatic factors

- i. Type-I personality.

4. What are the two forms of iridotrabecular contact?

- i. Appositional
- ii. Synechial.

5. How does the risk of PACG increase with age?

- i. Continuing growth of the lens thickness
- ii. More anterior position of the lens
- iii. Pupil becomes increasingly miotic.

6. Why is the mid dilated pupil a significant cause of increased pupillary block?

- i. Posterior vector of force of the iris sphincter muscle reaches its maximum during the mid-dilated time
- ii. Peripheral iris is under less tension and is more easily pushed forward into contact with the trabecular meshwork
- iii. Dilation also causes thickening and bunching of the peripheral iris. With full dilation, there is no contact between the lens and iris and hence there is no pupillary block.

7. What is plateau iris syndrome?

The plateau iris syndrome is a form of PACG. It is less common than pupillary block and is observed most commonly in young adults. Plateau

iris syndrome is caused by forward displacement of the ciliary body with corresponding ciliary processes, which hold the peripheral iris in an anterior position overlying the trabecular meshwork. The iris is commonly located on the same plane as Schwalbe's line and a recess is present in the peripheral angle.

8. How do you diagnose plateau iris syndrome?

Patients with plateau iris syndrome are characteristically asymptomatic until they experience an attack of acute angle closure or develop chronic angle closure. They demonstrate deep axial anterior chambers but narrow peripheral anterior chambers when examined with a slit lamp.

On gonioscopic examination, the iris is flat instead of convex with a corresponding narrow anterior chamber angle. If indentation gonioscopy is used, the trabecular meshwork is visible with a sine wave appearance of the peripheral iris due to the iris hanging over the anterior ciliary processes.

To definitively diagnose plateau iris syndrome, a peripheral iridotomy must be performed; an anterior chamber angle that remains occludable confirms plateau iris syndrome.

9. What is plateau iris configuration?

Plateau iris configuration occurs when the typical iris configuration is present but without angle closure.

10. How is plateau iris syndrome treated?

Most cases of suspected plateau iris syndrome have at least some component of pupillary block and patients are treated with peripheral iridotomy.

If the diagnosis of plateau iris syndrome is confirmed, argon laser iridoplasty may be used to shrink the peripheral iris and relieve the closed angle.

11. What are the drugs capable of precipitating angle closure glaucoma?

- a. Antipsychotic agents
 - i. Antidepressants : Phenothiazines
 - ii. Monoamine oxidase inhibitors : Amitriptyline
- b. Antiparkinsonian agents
 - i. Sympathomimetic agents : Phenylzine
 - ii. Mydriatic agents : Adrenaline

12. Why is the eye pain more in PACG than in POAG, even with the same IOP?

The eye pain appears to be related more to the rapid rate of the rise in IOP than the actual pressure.

13. What is the cause of defective vision in PACG initially?

The blurred vision occurs first as a result of distortion of the corneal lamellae and later as a result of corneal epithelial edema.

14. What is colored haloes due to?

Haloes is due to corneal epithelial edema, which acts as a diffraction grating that breaks white light into its component colors.

15. How does the colored haloes present?

It presents with blue-green color in the center and yellow-red color in the periphery.

16. What are the other conditions which can cause colored haloes?

- i. Mucus on the cornea due to conjunctivitis
- ii. Incipient stage of cataract
- iii. Vitreous opacities
- iv. Snow blindness
- v. Tilt of IOL.

17. What is Fincham test?

Fincham or the staenopic test is a test used to distinguish between the haloes seen in incipient cataract and angle closure glaucoma. A staenopic slit is placed in front of the eye and moved from one end of the pupillary aperture to the other. In glaucoma the halo remains intact while the halo in incipient cataract breaks into component colors.

18. What is the incidence of developing angle closure in the fellow eye?

About 50% within 5 years.

19. Describe the clinical features of the various stages of angle closure glaucoma.**I. Prodromal stage:**

- i. Presence of haloes
- ii. White eye
- iii. Intermittent attacks of mild pain
- iv. IOP may rise to 40–60 mm Hg.

II. Phase of constant instability:

- i. Intermittency is replaced by regularity
- ii. Increase in diurnal fluctuations.

III. Acute congestive attack:

- i. Circumcorneal congestion
- ii. Corneal edema
- iii. Pain and vomiting
- iv. Shallow AC
- v. Pupil moderately dilated and vertically oval
- vi. Very high IOP.

iv. Chronic closed-angle glaucoma:

- i. Presence of PAS
- ii. IOP remains high between attacks
- iii. Decreased vision and fields.

v. Absolute glaucoma:

- i. Vision is no PL
- ii. Corneal sensation absent
- iii. Dilated circum corneal vessels
- iv. Atrophic iris and ectropion uvea
- v. Optic disk cupped
- vi. Stony hard eye
- vii. Scleral staphyloma.

20. What are the differential diagnosis of acute angle closure glaucoma?**A. Evidence of compromised angle on gonioscopy or shallow anterior chamber**

- i. Ciliary block glaucoma
- ii. Neovascular glaucoma
- iii. Iridocorneo endothelial (ECE) syndrome
- iv. Plateau iris syndrome with angle closure
- v. Secondary angle closure with pupillary block (phacomorphic glaucoma).

B. High pressure open-angle glaucomas masquerading as acute angle closure

- i. Glaucomatocyclytic crisis
- ii. Herpes simplex keratouveitis
- iii. Herpes zoster ophthalmicus
- iv. Pigmentary glaucoma
- v. Exfoliative glaucoma
- vi. Phacolytic glaucoma.

21. Why is the pupil in angle closure glaucoma vertically mid dilated and nonreacting?

It is due to iris sphincter ischemia and paresis due to high IOP.

22. What is inverse glaucoma?

In conditions like spherophakia, miotics increase the iris lens contact area due to slackening of the zonules (due to ciliary muscle contraction) leading to forward displacement of the lens thus precipitating or aggravating the pupillary block.

23. What are the gonioscopic findings in angle closure glaucoma?

In chronic angle closure, peripheral anterior synechiae is seen late in the course. In the subacute/acute congestive stages the angle shows an occludable configuration.

24. How do you do gonioscopy in the presence of corneal edema?

After application of one or two drops of anhydrous glycerin.

25. What are the signs suggestive of previous attacks angle closure?

- i. Iris pigments on the back of cornea and endothelial loss
- ii. Peripheral anterior synechiae

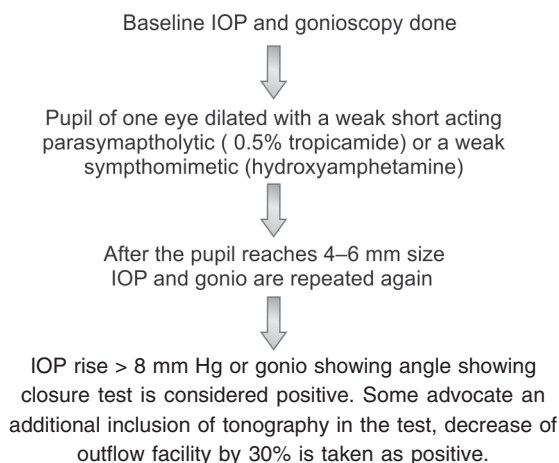
- iii. Sectoral iris atrophy
- iv. Posterior synechiae
- v. Mid-dilated sluggishly reacting pupil
- vi. Glaukomflecken
- vii. Visual field loss
- viii. Diminished outflow facility
- ix. Optic nerve cupping.

26. What are the various provocative tests used to diagnose angle closure glaucoma?

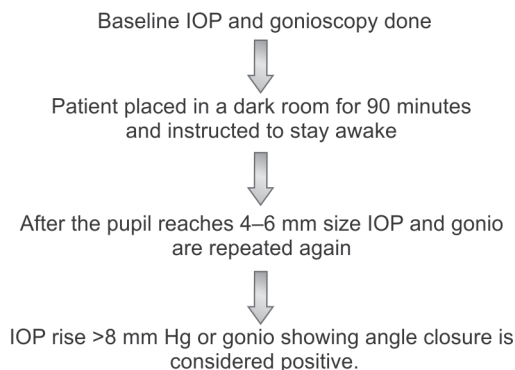
The various provocative tests include:

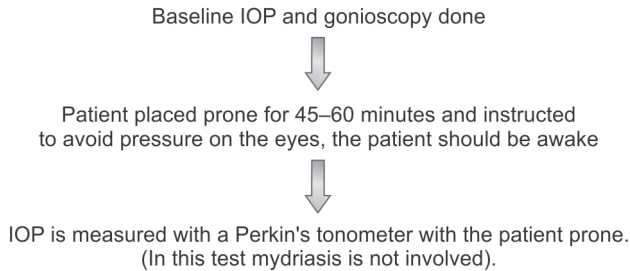
- i. Mydriatic test
- ii. Dark room test
- iii. Prone test
- iv. Prone dark room test
- v. Phenylephrine-pilocarpine test
- vi. Triple test.

Mydriatic test:



Dark room test:

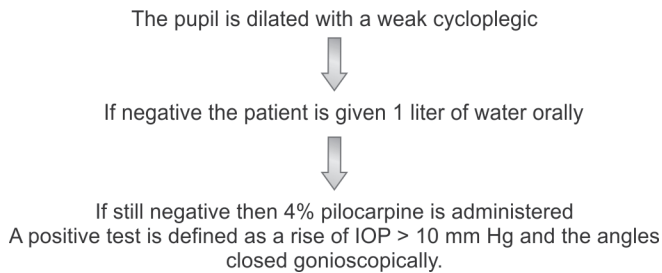


Prone test:**Dark room prone test:**

This test combines the features of dark room test and prone test.

Phenylephrine-pilocarpine test:

This test uses 10% phenylephrine and 2% pilocarpine to produce a pupillary block by creating a mid dilated pupillary state.

Triple test:**27. What are the optic nerve head changes seen in angle closure glaucoma?**

- i. In the acute stage the view is obscured by the corneal edema, but after the corneal edema clears out, the disk is seen to be congested with or without multiple hemorrhages. In chronic angle closure, the disk changes are similar to the changes seen in POAG.
- ii. In chronic congestive stage, the disk will be pale.

28. What are the field defects in angle closure glaucoma, during an attack?

There is generalized constriction of the fields.

29. Indications of trabeculectomy in angle closure glaucoma.

- i. Documented progression of glaucoma after maximal tolerable medical therapy
- ii. Synechial angle closure (>270°)

30. What is the role of nonpenetrating glaucoma surgeries in angle closure glaucoma?

Angle closure glaucoma serves as a relative contraindication to non-penetrating glaucoma surgeries. Since the trabecular meshwork is very close to the root of iris, effective filtration may not occur.

31. What is Vogt's triad?

A triad of symptoms usually seen in post congestive glaucoma or any treated case of angle closure glaucoma. It includes:

- i. Glaukomflecken
- ii. Patches of iris atrophy
- iii. Slightly dilated non reacting pupil.

32. How do we manage the terminal stage of primary angle closure glaucoma?

The terminal stage of PACG, i.e. absolute glaucoma is characterized by

- i. Painful blind eye
- ii. Ciliary congestion and caput medusa appearance of limbal vessels
- iii. Shallow AC
- iv. Atrophic iris
- v. Band keratopathy
- vi. Very high IOP (stony hard eyeball)
- vii. Optic atrophy.

Management

- i. Topical antiglaucoma medications
- ii. Topical steroids
- iii. Cycloplegics (preferably atropine).

If pain still persists

- i. Cryophotocoagulation/cyclophotocoagulation
- ii. Retrobulbar alcohol injection
- iii. Evisceration/enucleation.

33. How is retrobulbar alcohol given (technique)?

Initially about 2–3 ml of lignocaine is injected in the retrobulbar region. The needle is then held in place while the syringe is replaced with a 1 ml syringe containing 95–100% alcohol. (some prefer to use 50% alcohol). The alcohol is then injected into the retrobulbar space. This is effective for 3–6 months.

34. What do you anticipate following a retrobulbar alcohol injection?

- i. Transient ptosis
- ii. Eyelid swelling
- iii. Ocular movement restriction
- iv. Anesthesia (periocular)
- v. Necrosis of ocular tissue.

35. What is combined mechanism glaucoma?

This diagnosis is typically made in a patient who experienced an acute attack of angle closure that was treated with a peripheral iridotomy. In these patients, IOP remains elevated despite the presence of an open angle. Ensuing treatment is aimed at the open-angle component of the patient's glaucoma.

36. What are the newer imaging technologies useful in diagnosis angle closure?

- i. UBM
- ii. Anterior segment OCT.

4.7. MANAGEMENT OF AN ACUTE ATTACK OF ANGLE CLOSURE GLAUCOMA

(This narrative is given intentionally in active tense to familiarize the resident in the art of presentation in a viva)

Management of angle closure glaucoma is essentially surgical. However, I would like to control the intraocular pressure as much as possible, by medical means before planning surgery.

If the intraocular pressure is very high (above 50 mm Hg), pressure induced ischemia of the iris leads to paralysis of sphincter muscle and hence miotic therapy does not help. For this reason, the first line of defense is to administer drugs which will promptly reduce the intraocular pressure.

I will start him on 20% intravenous mannitol in a dose of 1–2 g/kg/body wt. over a period of 20–30 minutes.

In the absence of nausea or vomiting, I would like to use oral acetazolamide tablets, 250 mg, 4 times a day or oral hyperosmotic agents like 50% oral glycerol in a dose of 1–1.5 g/kg body weight, after ruling out diabetes mellitus. Apraclonidine 0.5% can be used to reduce the IOP quickly.

After bringing the intraocular pressure below 40 mm Hg, I will start my patient on 2% topical pilocarpine hydrochloride 4 times over 30 minutes and then once every 6 hours, (which by causing pupillary miosis, tightens the peripheral iris pulls it away from the trabecular meshwork and relieves the pupillary block). Additionally, I will also use a combination therapy of topical beta blockers like 0.5% timolol maleate, twice a day with alpha 2 adrenergic agonist like 0.2% brimonidine tartrate, thrice a day with a time interval of 10 minutes. I would like to use topical steroids like 1% prednisolone acetate, 4 times a day, to control the associated intraocular inflammation. Additionally, I would like to give analgesics like oral Ibuprofen 500 mg twice a day to control the pain.

I shall review the patient on an hourly basis. I will record the intraocular pressure and if the cornea is clear I will do gonioscopy of both the affected eye and fellow eye.

Besides the medications, I will perform some maneuvers like axially depressing the central cornea, which may force open the angle temporarily. If the eye is uninfamed and cornea clear with reduced intraocular pressure, I will do primary peripheral iridotomies using Nd:YAG in both the affected and the fellow eye prophylactically.

If the cornea is not clear and if the gonioscopy reveals angle closure of less than 2/3rd. I will perform a surgical iridectomy for the affected eye and do a YAG iridotomy for the fellow eye.

If the angle closure is more than 2/3rd or if there is persistent inflammation with edematous cornea and high intraocular pressure, then I will contemplate primary trabeculectomy.

Repeat or serial gonioscopy is essential for follow-up of the patient to be certain that the angle has adequately opened.

4.8. PRIMARY OPEN-ANGLE GLAUCOMA

1. What are the risk factors for POAG?

- i. High IOP
- ii. Myopia
- iii. Relatively thin central corneal thickness increases the risk of progression
- iv. Systemic vascular disease—diastolic perfusion pressure < 55 mm Hg
- v. Advanced age (prevalence roughly doubled for each decade over 40 years)
- vi. Race, (Blacks) and first degree relatives
- vii. There is no gender predisposition.

2. What percentage of risk is associated in family history?

First degree relatives are at increased risk.

- Siblings (10%)
- Off springs (4%).

3. What is the prevalence of POAG?

1–2% in persons older than 40.

4. What is phasing?

The measurement of IOP at various times of day and night to record diurnal variation is known as phasing. This is being done since POAG patients manifest greater diurnal variation.

5. What is the cause of diurnal variations/fluctuation?

Fluctuation in aqueous humor production cause mean diurnal IOP measurement variation.

6. What is the usefulness of diurnal variation measurement?

- i. For diagnosing glaucoma
- ii. Explaining progressive damage despite apparent good pressure control
- iii. Evaluating the efficacy of therapy
- iv. Distinguishing normal tension glaucoma from POAG.

7. What is the pathogenesis of glaucoma damage in POAG patients?

- i. Ischemic theory secondary to raised intraocular pressure
- ii. Mechanical theory of raised pressure gradient
- iii. Susceptibility of ganglion cells
- iv. Loss of architecture of the connective tissue structures within the ONH.

8. What are the genes associated with the development of POAG?

Two genes have been identified.

- i. Myocilin gene at chromosome 1
- ii. Optineurin gene at chromosome 10p.

9. What is the normal rate of loss of ganglion cells per year?

5000 ganglion cells are lost every year in normal individuals by apoptosis.

10. How do ganglion cells die?

They die by a process called as apoptosis (preprogrammed genetic mode for individual cellular suicide).

11. What are the studies done in POAG patients to define systemic risk factors?

- i. Beaver Dam eye study
- ii. Baltimore eye study
- iii. Blue mountains eye study.

12. What is the importance of performing gonioscopy every year in open-angle glaucoma patients?

With advancing age, angle closure component may develop because of increasing thickness of lens which may warrant peripheral iridotomy to prevent pupillary block.

13. Define target pressure.

It is the pressure at or below which further damage/loss of ganglion cells is unlikely. It depends on the IOP at the time of presentation, severity of damage, extent of damage and rapidity of progression of visual fields deterioration.

14. How does normal tension glaucoma (NTG) differ from POAG?

NTG is a disease of exclusion. Mean IOP will always be less than 21 mm Hg on diurnal testing while optic nerve head damage and glaucomatous field loss are present. The cup is often shallow with pallor. Disk hemorrhages are more frequent. History of migraine and chronic blood loss may be reported. The angle is open and there is absence of any secondary cause for glaucomatous disk damage.

15. What are the sites of maximum resistance to outflow in POAG patients?

- i. Juxtacanalicular part of trabecular meshwork offers maximum resistance to outflow.
- ii. Schlemm's canal.

16. What are the reasons for this maximum resistance?

- i. Altered corticosteroid metabolism
- ii. Dysfunctional adrenergic control
- iii. Abnormal immunologic process
- iv. Oxidative damage.

17. What is the other reason besides trabecular outflow resistance for elevated IOP in patients with POAG?

Obstruction of collector channels by deposition of glycosaminoglycans.

18. What are the histopathological findings in the anterior chamber angles of POAG patients?

- i. Alteration in trabecular beams in the form of fragmentation of collagen.
- ii. Thickened basement membrane
- iii. Fused trabecular beams
- iv. Narrow intertrabecular spaces
- v. Narrow collector channels
- vi. Decreased number of giant vacuoles.

19. What are the ONH changes in POAG?

A. Papillary changes (actual changes in the optic disk)

- i. Concentric enlargement of cup
- ii. Focal narrowing of the neuroretinal rim
- iii. Asymmetric cupping
- iv. Saucerization

B. Peripapillary changes (changes immediately surrounding the optic disk)

- i. Optic disk hemorrhages
- ii. Changes in the nerve fiber layer
- iii. Variation in the diameter of retinal arterioles
- iv. Peripapillary choroidal atrophy

C. Vascular changes

- i. Nasalization
- ii. Baring of the circumlinear vessel

20. What is the best method of evaluating the optic disk changes in glaucoma?

The best method is slit lamp combined with a Hruby lens, or a 60, 78 or 90D lenses.

21. What is the best method of documenting the optic disk changes in glaucoma?

Photographic documentation of optic nerve head.

22. Why does increased cupping occur?

It is due to

- i. Backward bowing of the lamina cribrosa
- ii. Elongation of the laminar beams
- iii. Loss of the ganglion cell axons in the rim of neural tissue

23. Where does the increase in cupping start?

Large physiological cups are round in shape while vertical elongation occurs in glaucoma. The process frequently starts segmentally often in the lower temporal quadrant. This often causes an early appearance of an upper arcuate scotoma.

24. What is the main site of glaucomatous optic nerve damage?

Lamina cribrosa.

25. What is the shape of the normal neuroretinal rim (NRR)?

The NRR is broadest in the inferior disk, then the superior disk, then the nasal disk and thinnest in the temporal disk.

26. What is the shape of the normal cup disk ratio?

Because of the vertically oval optic disk and the horizontally oval optic cup, cup disk ratios are usually larger horizontally than vertically in normal eyes.

27. Why are the superior and inferior poles of optic disk affected first in glaucoma?

The superior and inferior poles have larger laminar pores and hence, the axon bundles traversing have less support by glial tissue. Thus they are more prone to damage.

28. Can cupping reverse?

Reversal of cupping can happen in children and young patients following lowering of intraocular pressure, probably because the sclera is more elastic.

29. What are the parapapillary changes in glaucoma?

The normal optic nerve head may be surrounded by zones that vary in width, circumference and pigmentation. There are two zones – alpha and beta Zone; alpha is characterized by irregular hypopigmentation and by thinning of the overlying chorioretinal layers. Zone beta is located closer to the optic disk border and is usually more distinctive because of the visible sclera.

30. What is baring of circumlinear vessels?

Vessels that pass circumferentially across the temporal aspect of the cup have been called as circumlinear vessels. If they pass the exposed depths of the cup, they are bared. Baring of the circumlinear vessels is seen because, as the cup recedes, it exposes the vessel.

31. What is nasalization?

As the cup enlarges, the retinal vessels are displaced nasally. This can be an indicator for the progression of glaucoma.

32. What is the significance of disk hemorrhage?

It is a sign of active disease and they occur more frequently in normal tension glaucoma and precede visual field defects by several months. They occur most commonly inferotemporally and are flame shaped.

33. What is saucerization of the optic disk?

Occasionally, the glaucomatous damage to the optic disk produces a shallower background bowing of the disk rather than excavation. This is called saucerization.

34. How many ganglion cell loss should be there before visual field defects become manifest on white on white perimetry?

25–30% of ganglion cell loss occurs before visual field loss becomes apparent on white on white perimetry.

35. What are the modalities to detect preperimetric glaucoma?

- i. Optical coherence tomography (OCT)
- ii. GDx-VCC nerve fiber layer (NFL) analyzer
- iii. Frequency doubling perimetry (FDP)
- iv. Short wavelength automated perimetry (SWAP)
- v. Heidelberg retinal tomography (HRT)

36. What is the role of corneal thickness in POAG?

The Goldmann's applanation tonometer is accurate only for a central corneal thickness measuring 520 μ . Thin corneas have falsely low measured IOP because force required to applanate is less. Thick corneas have falsely high reading.

37. What is the differential diagnosis of POAG?

- i. Pseudoexfoliative glaucoma
- ii. Pigmentary glaucoma
- iii. Elevated episcleral venous pressure
- iv. Post inflammatory glaucoma
- v. Steroid induced glaucoma
- vi. Arteritic and non-arteritic anterior ischemic optic neuropathy (AAION and NAAION).

38. What is SLT?

It is selective laser trabeculoplasty wherein double frequency Nd:YAG 532 nm is used selectively to target melanin cells in trabecular meshwork.

39. Why miotics are ineffective in angle recession glaucoma?

Due to trabecular scarring, the miotics are ineffective while prostaglandin analogues are the drug of choice.

40. What are the types of disk damage in glaucoma?

- i. Type I (focal ischemic)
- ii. Type II (myopic glaucomatous)
- iii. Type III (senile sclerotic)
- iv. Type IV (concentrically enlarging)
- v. Mixed.

41. What is the concept of corneal hysteresis?

It measures the elasticity and the biomechanical properties of cornea hence IOP is measured more accurately by ocular response analyzer (ORA).

42. When will you suspect an intracranial lesion in a patient with visual field defects?

- i. Pallor more than cupping
- ii. Asymmetric dyschromatopsia
- iii. Fields respecting vertical meridian
- iv. Contralateral ONH normal.

43. Non-glaucomatous conditions mimicking POAG?

- i. Chiasmal compression
- ii. AAION
- iii. Toxic optic neuropathies
- iv. Hypotension (shock optic neuropathy).

44. How do you approach in diagnosis and treatment of open-angle glaucoma?

- i. Identify the risk factors
- ii. Careful optic nerve evaluation and documentation
- iii. Confirm visual field loss with automated perimetry
- iv. Reserve advanced imaging techniques for selected patients
- v. Differentiate ocular hypertension from POAG (may need follow-up for certain period)
- vi. Educate the patient regarding glaucoma and side effects of therapy.
- vii. Institute therapy—single medication with less side effects and adequate follow-up
- viii. Ensure compliance each time
- ix. Switch over therapy to better drugs than addition
- x. Think of filtering surgery—if maximal tolerable medical therapy fails or in a non-compliant patient

45. What are the problems associated with myopia and glaucoma?

- i. Faulty measurement of IOP due to decreased scleral rigidity
- ii. Increased chances of POAG due to
 - Increasing ovality of the disk due to stretching or tractional vectors not evenly distributed across the myopic optic disk
- iii. Altered scleral rigidity and deformation of the posterior scleral structures can act as contributory factors.

46. What is Grants syndrome?

Inflammatory precipitates in trabecular meshwork, obstructing the angle. It occurs in rheumatoid arthritis and other connective tissue disorders. It is generally associated with mild aqueous flare/cells in the anterior chamber contributory factors.

47. What are the most common imaging techniques used for the diagnosis and evaluation of glaucoma?

They are:

- i. Heidelberg retina tomography (HRT) or confocal scanning laser ophthalmoscope (CSLO)

- ii. Optical coherence tomography (OCT)
- iii. Scanning laser polarimetry (also called as GDX).

48. What is the HRT or CSLO?

It obtains three-dimensional images of the optic disk by acquiring high resolution images, by using a 670 μ diode laser.

49. What are the components of the HRT report?

- i. Patient demographic data
- ii. Topographic image (on the left upper corner of the printout)
- iii. Reflectance image (right upper corner)
- iv. Retinal surface height variation graph
- v. Vertical and horizontal interactive analysis
- vi. Stereometric analysis
- vii. Moorfields regression analysis
- viii. Glaucoma probability score.

50. What are the advantages and disadvantages of HRT?

Advantages:

- i. Rapid
- ii. Simple
- iii. No need for pupillary dilatation

Disadvantages:

- i. Not useful for RNFL or macula
- ii. Operator dependent and hence high inter observer variability
- iii. Tends to overestimate rim area in small optic nerves.

4.9. NEOVASCULAR GLAUCOMA

1. What are the other terminologies for neovascular glaucoma (NVG)?

- i. Hemorrhagic glaucoma
- ii. Thrombotic glaucoma
- iii. Rubeotic glaucoma
- iv. Congestive glaucoma
- v. 100th day glaucoma.

2. Who coined the term 'neovascular glaucoma'?

Weiss, et al.

3. Describe the first sign of NVG.

- i. Clinically new vessel tufts at pupillary margin.
- ii. By using investigative modalities, the first sign is increased permeability of the blood vessels at the pupillary margin as detected by fluorescein angiography or fluorophotometry.

4. Why does ectropion uveae occur?

Radial traction of the fibrovascular membrane in the angle and the iris pulls the posterior layer of the iris around the pupillary margin onto the anterior iris surface.

5. Etiology of neovascular glaucoma.

A. Ocular vascular diseases:

- i. Diabetic retinopathy
- ii. Ischemic CRVO
- iii. CRAO
- iv. BRVO
- v. BRAO
- vi. Leber's miliary aneurysm
- vii. Sickle cell retinopathy
- viii. Coats' disease
- ix. Eales' disease
- x. Retinopathy of prematurity
- xi. Persistent fetal vasculature

B. Ocular inflammation:

- i. Chronic uveitis
- ii. Chronic retinal detachment
- iii. Sympathetic ophthalmia
- iv. Endophthalmitis
- v. Syphilitic retinitis
- vi. VKH
- vii. Leber's congenital amaurosis

C. Neoplasms:

- i. Malignant melanoma
- ii. Retinoblastoma
- iii. Optic nerve glioma with venous stasis retinopathy
- iv. Metastatic carcinoma
- v. Retinaocular cell sarcoma

D. Systemic diseases:

- i. Diabetes mellitus
- ii. Sickle cell disease
- iii. SLE

E. Extraocular vascular disorders:

- i. Carotid artery obstruction
- ii. Congestive heart failure
- iii. Giant cell arthritis
- iv. Carotid cavernous fistula
- v. Takayasu (pulseless) disease

F. Miscellaneous:

- i. ROP
- ii. PHPV
- iii. Eales' disease
- iv. Coats' disease
- v. RRD with PVR
- vi. Retinoschisis

G. Precipitating ocular surgical causes

- i. RD surgery
- ii. Cataract extraction
- iii. Vitrectomy
- iv. Radiation
- v. Nd:YAG capsulotomy

6. Difference between new vessels and normal iris vessels.

	New vessels	Normal vessels
Location	Pupillary margin, angles	Iris stroma
Arrangement	Irregular	Regular
Appearance	Thin	Tortuous
Course	Arborising	Radial
Character	Fenestrated	Non-fenestrated
Scleral spur	Crosses	Does not cross
Fluorescein	Leakage	No leakage
Histology	Endothelial tube	Has all three coats
Blood-aqueous barrier	Poor	Intact

7. Theories of neovasculogenesis?

- A. **Retinal hypoxia:** Vascular endothelial cells of blood vessels in retina release proangiogenic factors like FGF, VEGF, TGF α , TNF α , angiogenin which incites a cascade leading to activation, proliferation, migration of endothelial cells—new vessel formation, (e.g. PDR, ischemic CRVO).

- B. Angiogenesis factors:** 'Tumor angiogenesis factor' released by tumors into the aqueous and vitreous, increases vasoproliferative activity.
- C. Chronic dilatation of ocular vessels:** Hypoxia of iris causes dilatation of its vasculature which is a stimulus for new vessel formation
- D. Vasoinhibitory factors from vitreous and lens:** Loss of these factors such as in pars plana vitrectomy and pars plana lensectomy increase rubeosis.

8. What are the most commonly encountered proangiogenesis factors?

VEGF, FGF, TNF- α , IGF, IL-6, PDGF, Transforming growth factor- β , angiogenin.

9. What are the clinicopathological stages of NVG?

- i. **Prerubeosis stage:** Patients may have arteriolar/capillary non-perfusion or optic disk neovascularization or retinal neovascularization. FFA shows leaking iris vessels and extensive retinal capillary closure. Vitreous fluorophotometry detects increased fluorescein appearance in the vitreous.
- ii. **Preglaucoma stage:** Also called rubeosis stage. IOP is normal. Slit lamp examination reveals dilated tufts of pre-existing capillaries and new vessels over iris, especially at peripupillary area. NVA may also be present.
- iii. **Open-angle glaucoma stage:** Rubeosis more florid with anterior chamber (AC) reaction, high IOP and open angles on gonioscopy. Angles are covered by translucent fibrovascular membrane extending to posterior iris.
- iv. **Angle closure glaucoma stage:** Raised IOP with florid NVI/NVA, ectropion uveae, and contracture of membrane in angles causing peripheral anterior synechiae which will lead to eventual total synechial angle closure.
- v. **Burnt out stage**

10. What is Wands classification of the stages of NVG?

- i. Stage 1: Vessels at the pupillary margin
- ii. Stage 2: Vessels upto collarete
- iii. Stage 3: Vessels upto angle
- iv. Stage 4: Vessels crosses scleral spur.

11. What are the types of glaucoma occurring in NVG?

Open angle (pretrabecular type) and secondary angle closure glaucoma.

12. Histopathological feature of open-angle glaucoma stage?

The new vessels appear first as endothelial buds from capillaries of the minor arterial circle. The buds then become vascular tufts. The new vessels have thin walls with irregular endothelia and pericytes. A clinically invisible fibrous membrane develops along the vessels which then covers the angle and iris, obstructing trabecular meshwork.

13. What is the cause of angle closure?

Contraction of myofibroblasts present in fibrovascular membrane causes PAS and flattening of iris surface.

14. Where do the new vessels arise from?

They arise from microvasculature (capillaries, venules) of the vascular endothelial cell.

15. In ischemic CRVO when does NVG occur?

Usually between 3–5 months (100 day glaucoma) but anywhere from 2 months to 2 years (17–80%).

16. What are the risk factors in diabetes that cause NVG?

In an eye with diabetic retinopathy

- i. Cataract extraction and vitrectomy
- ii. Cataract extraction with PCIOL implantation (increases anterior segment inflammation and disrupts blood retinal barrier)
- iii. Chronic RD
(Lens and vitreous provide vasoconstrictive factors and serve as a diffusion barrier for angiogenic factors)
- iv. Longer duration of diabetes, associated hypertension, hypercholesterolemia
- v. In extracapsular cataract extraction with capsule rupture, or loss of zonular support with exposure of vitreous.

17. Name some occlusive vascular diseases causing NVI/NVG.

- i. Carotid artery ligation
- ii. ICA obstruction, giant cell arteritis, Takayasu's disease

18. What are the differential diagnosis of NVG?

- i. **Acute congestive stage of primary angle closure glaucoma** (does not have rubeosis of iris and angles, no fibrovascular membrane over iris and angles, no ectropion uveae)
- ii. **Uveitic glaucoma** (Keratic precipitates on endothelium, aqueous flare and cells; may have posterior synechiae, complicated cataract, band shaped keratopathy in chronic cases; acute attack due to pupillary block)
- iii. **Fuch's heterochromic iridocyclitis** (Eye is white and quiet, stellate KP's present, new vessels seen at angle but NVI and NVG rare, open angle glaucoma may be present due to trabecular sclerosis)
- iv. **ICE syndromes** (Corneal decompensation, corectopia, pseudopolyopia, iris atrophy)
- v. **Old trauma** (Recession of angle, pigment clumps in trabecular meshwork; no NVI)
- vi. **Lens induced glaucoma.**

19. How is Fuch's heterochromic iridocyclitis different from NVG?

Fuch's heterochromic iridocyclitis has the following features:

- i. Eye is white and quiet
- ii. New vessels seen at angle but new vessels on iris (NVI) and NVG rare (filiform vessels)
- iii. Spontaneous hyphemas common
- iv. Open-angle glaucoma may be present due to trabecular sclerosis
- v. Stellate KPs present
- vi. Iris heterochromia present.

20. What are the late complications of NVG?

- i. Painful bullous keratopathy (due to corneal decompensation or due to high intraocular pressure)
- ii. Complete synechial angle closure (due to extensive synechial angle closure or due to the fibrovascular membrane contraction)
- iii. Intractable glaucoma.

21. Name other conditions in which fluorescein leaks from the pupillary margin.

- i. Exfoliation syndrome (at the site of pupillary ruff defects)
- ii. Fuch's heterochromic iridocyclitis.

22. Why does fluorescein leak?

- i. In NVI, gap junctions between the endothelial cells and fenestrations within basement membrane are present allowing leakage.

23. Drugs contraindicated in NVG.

- i. Miotics—may increase inflammation and pain
- ii. Epinephrine
- iii. Prostaglandins (relative contraindication as membrane prevents uveoscleral outflow, may cause mild anterior uveitis).

24. Treatment of choice in NVG.

Panretinal photocoagulation.

25. Mechanism of PRP influencing NVG.

Causes destruction of RPE and photoreceptor cells in posterior segment
 Reduces oxygen requirement of posterior segment → Stimulus for release of angiogenesis factors reduced → Decreased proangiogenesis factors → Decreased anterior segment neovascularization.

26. Indications of prophylactic PRP.

- i. In diabetic retinopathy with peripupillary fluorescein leakage undergoing lensectomy or vitrectomy
- ii. Ischemic CRVO with risk factors for developing NVI or NVA (extensive retinal hemorrhage or ischemia) where frequent ophthalmologic follow up is not possible
- iii. Proliferative diabetic retinopathy.

27. LASER treatment options in NVG.

Anterior segment

Goniophotocoagulation: is inadequate treatment for neovascular glaucoma by itself, it may be useful adjunct to panretinal photocoagulation in certain situation.

- i. Argon laser
- ii. Eliminates vessels at the angle by direct photocoagulation
- iii. Exposure time: 0.2 sec
- iv. Spot size: 50–100 μm
- v. Power 100–200 mW; sufficient to blanch and constrict vessels.

Posterior segment

A. Panretinal photocoagulation:

- i. Parameters: Blue-green-argon laser
- ii. Spot size: 500 μm
- iii. Exposure time: 0.1 sec
- iv. Power: 300 mW clear media; 500 mW—lenticular sclerosis
- v. End point: Moderate intense white burns
- vi. Inter burn distance—one half burn width apart
- vii. Placement: 2 DD above, temporal and below center of macula
- viii. 500 μm from the nasal margin of disk extending to or beyond equator
- ix. Number: 1800–2200 burns in 2–3 divided sittings over 3–6 weeks period.

B. Cyclophotocoagulation:

1. Transcleral:

Nd:YAG (1064 nm)

i. *Non-contact*

- 1–1.5 mm behind limbus
- Power: 4–8 J
- Exposure time: 20 ms
- 30–40 evenly spaced spots for 360° (8 spots per quadrant)
- 3 and 9 o'clock positions not treated
- Spot size: 0.9 mm

ii. *Contact*

- 1.5–2 mm behind limbus
- Power: 5–9 watts
- Exposure time: 0.5–0.7 sec
- 30–40 burns for 360° sparing 3 o'clock and 9 o'clock
- Spot size: 0.9 mm

Diode laser (810 nm):

i. *Non-contact:*

- 0.5–1 mm behind limbus
- Power: Initial 1500–2500 mW for 1.5–2.5 seconds → pop sound heard → 250 mW reduced from that level for 9.9 sec
- 30–40 spots for 360°
- Spot size: 100–400 μm

ii. **Contact:**

- 1.2 mm behind limbus
- Power: 1.5–2.5 watt
- Exposure time: 1.5–2 sec
- Spot size: 100–400 μm
- 16–18 spots for 360°; 180° or 270° treated at a time

2. **Transpupillary:** Argon laser

- Exposure time: 0.1–0.2 sec
- Spot size: 50–100 μm
- Power: 700–1500 mW
- White discoloration and brown concave burn
- 180° treated

3. **Intraocular:**

i. **Transpupillary visualization:** Argon laser

- Exposure time: 0.1–0.2 sec
- Power: 1000 mW
- 3–5 per quadrant
- White reaction with shallow tissue disruption

ii. **Endoscopic visualization:** Argon laser

- Illumination: 20 G probe (670 nm aiming beam)
- Power of illumination: 1.2 watt
- 3.2 mm at/inside limbus
- Power: 300 mW
- 7–8 clock hours treated
- Whitening and shrinkage of ciliary epithelium.

28. Glaucoma surgical procedures in NVG?

Filtering surgery: Trab with 5-FU (50 mg/ml-5 min) or MMC (0.2–0.4 mg/ml-2 min)

- i. **Modified trabeculectomy** with intraocular bipolar cautery of peripheral iris and ciliary processes
- ii. Trabeculectomy after intravitreal/intracameral injection bevacizumab 1.25 mg in 0.05 ml
- iii. **Drainage devices** or valves

Cyclodestructive procedure (cyclophotocoagulation/cyclocryotherapy).

29. How will you manage a case of NVG?

- i. The main therapeutic goals will be to:
- ii. Control the intraocular pressure
- iii. Prevent further progression of neovascularization
- iv. Treat the underlying cause of neovascularization
- v. Provide symptomatic relief
- vi. If the IOP is less than 40 mm of Hg, the patient can be started on a combination of aqueous suppressants like topical β -blockers like timolol maleate 0.5% eye drops bid, α_2 adrenergic agonists like 0.2% brimonidine tartarate eye drops tds, or carbonic anhydrase inhibitors like dorzolamide hydrochloride 2% eye drops tds.

- If the IOP is above 40 mm of Hg, for initial control of IOP by starting the patient on 100 ml of 20% intravenous mannitol in a dose of 2 g/kg body weight over a period of 20–30 min after ruling out systemic hypotension or cardiac disease.
- In the absence of history of sulpha allergy, nausea and vomiting tab. acetazolamide 250 mg bd or hyperosmotic agents like 50% oral glycerol at 1–1.5 g/kg body weight can be advised after ruling out diabetes mellitus. For symptomatic pain relief, atropine eye ointment 4% and topical prednisolone acetate 1% qid can be instilled.
- Once epithelial edema subsides gonioscopic examination and fundus examination will be performed. If synechial angle closure does not extend for more than 270° and the patient has definite posterior segment ischemic pathology like PDR or ischemic CRVO, the patient can be advised for PRP in 3–4 sittings.
- Once rubeosis regresses, glaucoma filtering surgery like trabeculectomy using wound modulators like 5-FU (50 mg/ml-5 min) or MMC (0.2–0.4 mg/ml-2 min) or a glaucoma drainage device like Ahmed valve will be done.
- If IOP is still not controlled, with hazy media, the patient can undergo panretinal cryotherapy with a cyclodestructive procedure like cyclocryotherapy or transcleral Nd:YAG cyclophotocoagulation.
- If the IOP is still not controlled and the patient has severe pain in the blind eye, the patient can be advised retrobulbar alcohol injection for pain relief or enucleation after thorough and extensive counseling.

30. Indication for transscleral panretinal cryoablation with cryotherapy?

Hazy media.

31. What is express shunt?

3 mm long stainless steel tube with diameter of 400 μ having a 50 μ diameter lumen, implanted through limbus.

32. Indication for cyclodestructive procedures in NVG?

NVG with pain and poor visual potential with uncontrollable rubeosis and glaucoma.

33. Newer treatments for NVG?

- i. Anti-VEGF antibodies, e.g. bevacizumab
- ii. Alpha-interferon therapy
- iii. Troxerutin
- iv. Gene transfer of PEDF gene.

34. Probe sizes.

- i. Retinal cryotherapy: 2.5 mm (-70°C)
- ii. Cyclocryotherapy: 3.5 mm (-60° to -80°C).

35. Define rubeosis iridis.

Rubeosis iridis refers to new vessels on the surface of the iris regardless of the state of the angle or the presence of glaucoma.

36. What is the role of bevacizumab (avastin) in neovascular glaucoma?

In neovascular glaucoma, intravitreal bevacizumab (1.25 mg/0.05 ml) (avastin) can be administered through the pars plana route, 24–78 hours preceding surgery, with near total regression of iris neovascularization within 48 hours and some IOP lowering, an effect lasting for some weeks.

The rapid regression of new vessels allows both for panretinal photocoagulation and glaucoma surgery with reduced risk of bleeding.

4.10. PIGMENTARY GLAUCOMA

1. What is the typical profile of a patient typically presenting with pigmentary glaucoma (PG)?

Young (3rd decade), myopic, male, white race.

2. Mention the chromosome related to pigment dispersion syndrome (PDS)?

Chromosome 7q

3. What are the ocular findings in PG?

A. Cornea:

- i. Krukenberg spindle
- ii. Increased corneal diameter
- iii. Corneal endothelial pleomorphism and polymegathism

B. Iris:

- i. Iris transillumination defects (TID): seen in mid-periphery in contrast to PXF glaucoma, where it is seen at the pupillary margins
- ii. Pigment granules
- iii. Heterochromia
- iv. Anisocoria
- v. Concave iris configuration

C. Deep anterior chamber

D. Lens: Pigment deposits on zonules, posterior lens surface (Zentmayer's ring or Scheie's line).

4. What is the characteristic gonioscopic finding in PG?

- i. The angle is wide open.
- ii. Dense, homogenous dark brown pigment in the full circumference of the trabecular meshwork and pigmented Schwalbe's line is present.
- iii. The pigment can cover the entire width of the angle from the ciliary face to the peripheral cornea; a pigment line anterior to Schwalbe's line is often referred to as Sampaolesi's line is seen.

5. What are the differential diagnosis of pigmentation at the angles?

- i. Aging
- ii. Pigmentary glaucoma
- iii. PXF glaucoma
- iv. Post trauma
- v. Post intraocular surgery
- vi. Post laser iridotomy
- vii. Uveitic glaucoma
- viii. Previous attack of angle closure glaucoma
- ix. Ocular melanosis
- x. IOL placement in sulcus.

6. What are the associated possible fundus findings in PG?

- i. Retinal detachments
- ii. Lattice degenerations
- iii. RPE dystrophy.

7. What are the theories of mechanism of PG?

A. Inherited defect:

- i. Focal atrophy/hypopigmentation of iris pigment epithelium
- ii. Delay in melanogenesis
- iii. Hyperplasia of dilator muscle
- iv. Hypovascularity of the iris

B. **Mechanical theory (Campbell's theory):** Rubbing of lens zonules against mid peripheral iris due to iris concavity which release the pigments

C. Anderson, et al. postulate that pigment production and mutant melanosomal protein genes may contribute to pigmentary glaucoma.

8. What is the mechanism of IOP rise in PG?

Two phenomena:

- i. Pigment release and
- ii. Diminished outflow facility.

9. Histopathology of angle structures in PG.

Demonstrates pigment and debris in the trabecular meshwork cells. With advanced disease, the trabecular cell degenerate and wander from their beams, allowing sclerosis and eventual fusion of the trabecular meshwork.

10. What are the differential diagnosis of PG?

PXF glaucoma (PXF material on endothelium, anterior lens capsule angles)

Chronic uveitis (Keratic precipitates on endothelium, aqueous flare and cells; may have posterior synechiae, complicated cataract, band shaped keratopathy in chronic cases; acute attack due to pupillary block)

- i. Angle recession glaucoma
- ii. Ocular melanosis
- iii. Trauma
- iv. Herpes zoster
- v. Siderosis
- vi. Hemosiderosis
- vii. Pigmented intraocular tumors
- viii. Previous surgery (including laser surgery)
- ix. Cysts of iris and ciliary body
- x. Radiations

11. What are the differences between PXF and pigmentary glaucoma?

Feature	Pseudoexfoliative glaucoma	Pigmentary glaucoma
Profile	5th decade and older	3rd decade
Severity	Increases with age	Decreases/disappears in later life
Gender	Equal	Males(2:1)
Types of glaucoma	Open angle and angle closure	Open-angle glaucoma
Clinical features	Cornea: PXF, pigments on endothelium, guttatae	Krukenberg spindle
	Iris: Iris transillumination defects (peripupillary), moth eaten appearance	Iris transillumination defects (mid-periphery), heterochromia, reverse pupillary block
	Pupil: PXF, poor mydriasis	Anisocoria
	Lens: Cataract, phacodonesis, zonular distribution of PXF	May be normal
Gonioscopy	Sampaolesi line	Increased trabecular pigmentation
Progression	40% with PXF develop glaucoma	35% with PDS develop glaucoma
Management	Surgical in most cases	Medical in most cases
Extraocular involvement	Systemic findings present—amyloid like material (CNS, CVS, kidney, liver)	No systemic association

12. What is the treatment of PG?

Medical:

- i. Pilocarpine 1% eye drops (miosis restricting pupillary movement and pigment release, direct effect on aqueous outflow)
- ii. Carbonic anhydrase inhibitor—Dorzolamide 2% eye drops tds,
- iii. Beta blockers—Timolol maleate 0.5% eye drops bd.
- iv. Pilocarpine is poorly tolerated by these young patients and also chances of higher incidence of retinal detachment.

Laser:

Nd:YAG laser iridotomy (Relieves the posterior bowing of iris in pigmentary glaucoma) to cure reverse pupillary block

- i. Power: 4–8 mJ
- ii. 1–3 pulses per burst
- iii. Minimum size 60 μ m

Argon laser trabeculoplasty:

- i. Power: 800–1200 mW increased till blanch/bubble is seen
- ii. Spot size: 50 μ m
- iii. Duration: 0.1 sec
- iv. 50 burns over 180°
- v. Burn site: Junction of anterior 1/3rd and posterior 2/3rd of trabecular meshwork.

Selective laser trabeculoplasty:

- i. Frequency doubled Q switched Nd:YAG laser (532 nm)
- ii. Pulse duration: 3 ns
- iii. Energy: 0.3–2.0 mJ
- iv. Spot size: 400 μm
- v. 50–100 adjacent laser spots over 180°

Surgery:

- i. **Filtering surgery**—Modified trabeculectomy with 5-FU(50 mg/ml-5 min) or MMC (0.2–0.4 mg/ml-2 min)
- ii. **Drainage devices** or valves.

4.11. PSEUDOEXFOLIATION GLAUCOMA

1. What is true exfoliation of lens capsule?

It is a delamination of anterior capsule. There is separation of superficial layers of lens capsule from the deeper layers to form a scroll like margin, which occasionally float in the anterior chamber as thin, clear membranes. It was first described in glassblowers hence called glassblower's cataract.

2. What is the risk factor associated with capsular delamination?

- Extended exposure to infrared radiation (prophylactic measure—use of protective goggles).

3. What are the differential diagnosis of capsular delamination?

- i. Trauma
- ii. Intraocular inflammation
- iii. Idiopathically with advanced age.

4. What is pseudoexfoliation (PXF)?

PXF is a gray white fibrillogranular extracellular matrix material composed of a protein core (10–12 fibrils) surrounded by glycosaminoglycans. It's a sticky "Christmas tree" type of protein, aggregating a large number of elastic tissue and basement membrane proteins.

5. What is glaucoma capsulare?

Occurrence of glaucoma in an eye with pseudoexfoliation syndrome is called glaucoma capsulare. It is usually unilateral.

6. What is the origin of PXF?

It is thought to be produced by abnormal basement membranes of ageing epithelial cells in the trabeculum, equatorial lens capsule, iris, ciliary body, conjunctiva and then deposited on the anterior lens capsule, zonules, ciliary body, iris, trabeculum, anterior vitreous phase and conjunctiva.

7. What are the epidemiological factors of significance?

- i. ↑ Age → ↑ PXF
- ii. Mostly bilateral but unilateral cases are also present
- iii. More common between 60–70 years
- iv. Mostly seen in Scandinavian population

8. Difference between glaucoma capsulare and PXF glaucoma.

Glaucoma capsulare is usually unilateral while PXF glaucoma tends to be bilateral.

9. What is the incidence of glaucoma in patients with pseudoexfoliation syndrome?

Glaucoma is found to occur in 40% of patients with pseudoexfoliation.

10. List the clinical features of PXF.**A. Corneal changes**

- i. PXF material deposited on the back of cornea
- ii. Associated with corneal guttata
- iii. Associated with spheroidal degeneration
- iv. Decrease in the endothelial density, polymegathism and endothelial decompensation

B. Anterior chamber angle

- i. Increased trabecular meshwork pigmentation (uneven): Sampolesi's line

C. Iris changes

- i. Material deposited on iris tissue (anterior stroma)
- ii. Mid-peripheral iris transillumination defects (moth eaten appearance)

D. Pupil

- i. PXF material deposited on pupillary margin
- ii. Poor mydriasis (secondary to atrophy of muscle cells)

E. Lenticular changes

PXF on anterior lens capsule has 3 distinct zones:

- i. Translucent, central disk with occasional curled edges (absent in 20% of cases)
- ii. Central clear zone→corresponds to contact with moving iris
- iii. Peripheral granular zone→radial striations

F. Zonules and ciliary body changes

- i. PXF may be detected earliest in the ciliary body or zonules
- ii. Involvement of zonules



Subluxation or phacodonesis

11. What is the mechanism by which PXF causes zonular weakness?

- i. PXF material erupt through the basement membrane and invade the zonules creating areas of weakness (esp. in its origin—nonpigmented ciliary epithelium and insertion—pre-equatorial region of lens)
- ii. Proteolytic enzymes within the PXF material may facilitate zonular disintegration.

12. What are the findings in iris fluorescein angiography in case of PXF syndrome?

- i. Hypoperfusion
- ii. Peripupillary leakage.

13. What are the specular microscopy findings in PXF syndrome?

- i. Decreased cell density of corneal endothelium
- ii. Altered size of endothelial cells
- iii. Altered shape of endothelial cells

14. Describe the clinical classification of PXF based on morphologic alterations of anterior lens capsule.

- i. Preclinical stage (clinically invisible)
- ii. Suspected PXF (precapsular layer)
- iii. Mini PXF (focal defect starts superonasally)
- iv. Classic PXF.

15. What are the differences in gonioscopic findings in PXF and pigmentary glaucoma?

PXF glaucoma	Pigmentary glaucoma
↓	↓
i. Uniform pigmentation in trabecular meshwork	i. More thicker pigmentation in an irregular manner
ii. Pigmentation doesn't extend upto the Schwalbe's line	ii. Pigmentation extends anterior to Schwalbe's line

16. What are the intraocular complications of PXF syndrome?

A. Trabecular meshwork	<ol style="list-style-type: none"> a. Open-angle glaucoma b. Angle closure glaucoma c. Acute pressure rises
B. Lens or Zonules	<ol style="list-style-type: none"> a. Phacodonesis b. Subluxation/dislocation c. Nuclear cataract d. Zonular dialysis
C. Iris	<ol style="list-style-type: none"> a. Posterior synechiae b. Uveitis c. Sphincter muscle degeneration d. Melanin dispersion e. Poor mydriasis
D. Cornea	<ol style="list-style-type: none"> a. Early endothelial decompensation
Retina	<ol style="list-style-type: none"> b. CRVO c. Retinal detachment

17. How does open-angle glaucoma in PXF differ from primary open-angle glaucoma?

- i. Greater diurnal fluctuation of IOP in PXF glaucoma.
- ii. IOP in PXF glaucoma tends to run higher and more difficult to control
- iii. Glaucomatous neuroretinal rim damage tends to be more diffuse in PXF cases (sectoral preference → primary open-angle glaucoma)
- iv. PXF cases show ↑ tendency for glaucomatous optic atrophy.

18. What are the ways in which pseudoexfoliation causes glaucoma?

Pseudoexfoliation causes open angle and angle closure glaucoma.

A. Open-angle glaucoma is caused by the following mechanisms:

- a. Blockage of trabecular meshwork by PXF material by
 - Active pseudoexfoliation material production within the trabecular meshwork, Schlemm's canal and collector channels
 - Passive pseudoexfoliation material deposition in intertrabecular spaces

Progressive accumulation → Swelling of juxtacanalicular meshwork



Gradual narrowing of Schlemm's canal

- b. Blockage of meshwork by liberated iris pigment
- c. Trabecular cell dysfunction
- d. Associated open-angle glaucoma

B. PXF causes angle closure by the following mechanisms:

- i. Zonular weakness → anterior movement of lens
- ii. Lens thickening from cataract formation
- iii. Increased adhesiveness of the iris to the lens due to PXF material, sphincter muscle degeneration and uveitis.

19. Why do a high percentage of PXF cases have occludable angles?

Presence of shallower central and peripheral anterior chamber depths due to:

- i. Zonular weakness and forward movement of lens iris diaphragm
- ii. Lens thickening from cataract formation.

20. What are the pathogenesis of pseudoexfoliation?

- i. **Myofibril theory:** Elastic microfibril hypothesis which states that it's a type of elastosis with elastic microfibrils being secreted abnormally by local ocular cells.
- ii. **Basement membrane theory:** Pseudoexfoliation may be a basement membrane proteoglycan
- iii. **Glycosaminoglycan theory:** Abnormal metabolism of glycosaminoglycans in the iris
- iv. **Amyloid theory:** Protein of PXF material may be of amyloid group.

21. What are the ocular and systemic sites of PXF deposition?**Ocular**

- i. Lens capsule epithelium and zonules
- ii. Iris epithelium
- iii. Vascular endothelium
- iv. Corneal endothelium
- v. Schlemm's canal endothelium
- vi. Conjunctiva

- vii. Extraocular muscles
- viii. Orbital septa
- ix. Anterior hyaloids face of the vitreous
- x. Posterior ciliary arteries
- xi. Vortex veins
- xii. Central retinal vessels

Systemic

- i. Lungs
- ii. Heart
- iii. Liver
- iv. Kidneys
- v. Skin
- vi. Gall bladder
- vii. Cerebral meninges

22. What are the differential diagnoses of pseudoexfoliation?

- i. Uveitis
- ii. Capsular delamination
- iii. Primary amyloidosis
- iv. Pigment dispersion syndrome and pigmentary glaucoma
- v. Melanosis and melanoma

23. What are the important points to be kept in mind while medically managing PXF glaucoma?

- i. Tends to respond less well with medical therapy than POAG
- ii. Treat aggressively with frequent follow-up
- iii. Higher diurnal variation of IOP in PXF to be kept in mind while deciding the target pressure for an individual
- iv. Consider argon laser trabeculoplasty/selective laser trabeculoplasty which has a higher success rate in PXF glaucoma than in POAG but shorter duration of effectiveness.

24. What is trabecular aspiration?

Surgical modality to remove intertrabecular and pretrabecular debris.

25. What are the important findings to be looked for during pre operative evaluation in PXF syndrome patients undergoing cataract surgery?

- i. Corneal endothelial compromise
- ii. Evidence of zonular dialysis → Phacodonesis



Asymmetric anterior chamber depth

Ultrasound biomicroscopy to confirm the extent of zonular dialysis

- iii. Poor pupillary dilatation
- iv. Posterior synechiae
- v. Lens subluxation

26. What the special features to be adopted in PXF cases undergoing cataract surgery to maximize postoperative outcome?

- a. Use corneal endothelium friendly viscoelastics (chondroitin sulfate)
- b. Expand the pupil
 - Kuglen hooks
 - Iris hooks
 - Minisphincterotomies
 - Sector iridectomy
- c. Use of heparin surface modified intraocular lens (to minimize postoperative iritis which is common, in pseudoexfoliation cases postoperatively)
- d. Capsular tension ring to manage zonular dialysis and stabilize the bag.

27. Which gene is associated with exfoliation syndrome?

A polymorphism in exon 1 of the loxl 1 gene.

4.12. UVEITIC GLAUCOMA

1. What are the mechanisms of uveitic glaucoma?

I. Open angle mechanisms

- i. Trabeculitis: Clogging of trabecular meshwork by inflammatory cells.
- ii. Increased viscosity of aqueous: Due to fibrinous exudates.
- iii. Raised episcleral venous pressure: Due to perivascular inflammatory cuffing
- iv. Increased aqueous secretion: Due to inflammatory prostaglandin secretion.
- v. Steroid induced glaucoma.

II. Closed angle mechanism

Broadly classified as pupillary block and non-pupillary block mechanisms

A. Pupillary block

- i. Inflammatory cells, fibrin and debris collect in the angle
- ii. The peripheral iris adheres to the trabecular meshwork which leads to the formation of peripheral anterior synechiae
- iii. Chronic inflammation may be associated with angle neovascularization, which causes synechiae to develop.
- iv. Anterior segment inflammation causes posterior synechiae formation.

B. Non-pupillary block

- i. The ciliary body edema can cause the anterolateral rotation of the ciliary body about its attachment to the scleral spur, which relaxes the lens zonules and causes the forward movement of a rounder lens.
- ii. The anterior face of the ciliary body and peripheral iris are then brought into contact with the trabecular meshwork, causing angle closure.

2. Describe the development of glaucoma in an acquired immune deficiency syndrome (AIDS) patient.

- i. Bilateral acute angle closure glaucoma have been reported in these patients which is due to choroidal effusion with anterior rotation of the ciliary body
- ii. B-scan echography is helpful in establishing the diagnosis by demonstrating diffuse choroidal thickening with ciliochoroidal effusion
- iii. These cases do not respond to miotics or iridotomy
- iv. Treatment with aqueous suppressants, cycloplegics, and topical steroids reported to achieve complete resolution of the angle closure.

3. What is Posner-Schlosman syndrome?

It is otherwise called as glaucomatocyclitic crisis. It is characterized by:

- i. Recurrent attacks of mild anterior uveitis with marked elevation of IOP.
- ii. Associated with gastrointestinal disorders especially with peptic ulcers
- iii. White eye with minimal congestion

- iv. Open-angle with occasional debris and characteristic absence of synechiae.
- v. Apraclonidine is especially useful.

4. Describe the management of uveitic glaucoma.

There are two components:

I. Control of inflammation:

Topical administration of corticosteroids is preferred for anterior segment and commonly used steroids include 1.0% prednisolone acetate or 0.1% dexamethasone. The drops are titrated depending on the response.

When the response is insufficient, periocular injections (e.g. dexamethasone phosphate, prednisolone succinate, triamcinolone acetate, or methylprednisolone acetate) or a systemic corticosteroid (e.g. prednisone) may be required.

Children with uveitis may have unique dosing requirements and drug-associated risks such as growth retardation with systemic corticosteroids.

Non-steroidal anti-inflammatory agents

Used when the use of corticosteroids are contraindicated or inadequate, other anti-inflammatory drugs may be helpful.

Prostaglandin synthetase inhibitors such as aspirin, imidazole, indoxyl, indomethacin and dipyridamole have been effective.

In severe cases, **immunosuppressive agents** such as methotrexate, azathioprine or chlorambucil are used. These patients must be monitored closely for hematologic reactions.

Newer cyclooxygenase inhibitors like → flurbiprofen, ketorolac, suprofen and diclofenac may provide useful anti-inflammatory effects without the risk of steroid-induced IOP elevation.

Mydriatic cycloplegics → atropine (1%), homatropine (1 to 5%), or cyclopentolate (0.5 to 1%) is used to avoid posterior synechiae and to relieve the discomfort of ciliary muscle spasm.

II. Control of glaucoma

Medical management

- i. Topical β -blocker, α_2 -agonist or carbonic anhydrase inhibitor are the first line antiglaucoma drugs in uveitic glaucoma
- ii. An oral carbonic anhydrase inhibitor may be added, and a hyperosmotic agent is used for a short-term emergency measure.
- iii. In eyes with acute fibrinous anterior uveitis and impending pupillary block with or without peripheral anterior synechiae, it may be reasonable to consider use of intracameral tissue plasminogen activator (6.25 to 12.5 μ g).
- iv. Miotics and prostaglandins are contraindicated in the inflamed eye.

Surgical management

- i. Intraocular surgery should be avoided in active inflammation.
- ii. When medical therapy is inadequate, surgery may be required.
- iii. Laser iridotomy is safer than an incisional iridectomy but fails usually due to iris inflammation, fibrin exudates or late neovascularization
- iv. Filtering surgery with heavy steroid therapy is indicated in open-angle cases that are uncontrolled with medical therapy. Additional use of subconjunctival 5-fluorouracil (5-FU) significantly improves the success rate in these cases
- v. Laser trabeculoplasty is not effective in eyes with uveitis and open-angle glaucoma and it may cause an additional, significant rise in IOP and is generally contraindicated in these cases.
- vi. Surgical iridectomy during cataract surgery in uveitic cases can be performed to prevent post operative angle closure due to pupillary block
- vii. Cyclodestructive surgery like transscleral Nd:YAG cyclophotocoagulation can be done in aphakic and pseudophakic eyes with limited visual potential.
- viii. Filtering devices like Ahmed valve may be placed when the inflammation is under control but steroid cover is important to reduce inflammatory exudates from blocking the lumen during early postoperative period.

4.13. STEROID INDUCED GLAUCOMA

1. Define steroid induced glaucoma.

Corticosteroid induced glaucoma is a secondary glaucoma of the open angle type caused by prolonged use of topical, periocular, intravitreal, inhaled or systemic corticosteroids.

- i. 25% of general population develop increase in IOP after 4 weeks of QID topical steroids
- ii. 5% of the population are super responders – they develop > 10–15 mm Hg rise in IOP within 2 weeks
- iii. Approximately 15% of super responders developing glaucoma require filtering surgery
- iv. There is no racial or sexual predilection for steroid induced glaucoma.

2. What is steroid responsiveness?

The normal population can be divided into 3 groups on the basis of IOP response to a 6 week course of topical betamethasone

- i. High – marked elevation of IOP > 30 mm Hg
- ii. Moderate – moderated elevation of IOP 22–30 mm Hg
- iii. Non-responders – no change in IOP.

3. What is the mechanism of steroid induced glaucoma?

Steroids decrease aqueous outflow by the following mechanisms

- i. Accumulation of polymerized glycosaminoglycans (GAG) in the trabecular meshwork which become hydrated producing “*biologic edema*”—leading to increased resistance to outflow.
- ii. Stabilizing the lysosomal membranes and inhibiting release of catabolic enzymes
- iii. Accumulation of acid mucopolysaccharides (AMPs) in outflow channels, thus reducing outflow
- iv. Decreased synthesis of prostaglandins that regulate aqueous outflow.

4. Who are the people at risk of developing steroid induced glaucoma?

- i. Prolonged use of steroid drops for conditions like vernal conjunctivitis, uveitis, chronic blepharitis
- ii. Long term systemic steroid use in conditions like SLE, rheumatoid arthritis
- iii. Use of steroid drops in patients with strong family history of glaucoma
- iv. 50% of patients with progressive AMD or diffuse macular edema treated with intravitreal injection of 25 mg of triamcinolone acetonide
- v. Subtenon depot triamcinolone in treatment of patients with pars planitis
- vi. Diabetic patients
- vii. High myopes
- viii. Post refractive surgeries
- ix. Asthmatics using inhaled steroids.

5. Example of a systemic condition causing steroid induced glaucoma.

Excessive secretion of endogenous corticosteroids associated with adrenal hyperplasia or adenoma can cause steroid induced glaucoma.

6. Clinical picture of steroid induced glaucoma in adults.

- i. Resembles chronic open-angle glaucoma with an open, normal appearing angle and absence of symptoms
- ii. May have acute presentation and IOP rises have been observed within hours after steroid administration
- iii. May mimic low tension glaucoma when IOP increase has damaged the optic nerve head.

7. Clinical picture of steroid induced glaucoma in children.

- i. Children in general have lower incidence of positive steroid responses than adults
- ii. Infants treated with steroids develop a condition resembling congenital glaucoma
- iii. Increase in IOP has been reported in infants using steroid for
 1. nasal and inhalational steroids
 2. Eye drops after strabismus surgery.

8. Diagnosis of steroid induced glaucoma.

Diagnosis requires a high index of suspicion and questioning of patients specifically about steroids eye drops, ointments and pills.

9. Mention a few alternative drugs which have a lesser tendency to cause glaucoma?

- i. Medrysone
- ii. Loteprednol etabonate

These drugs have a lesser tendency to raise IOP.

10. Are there any genetic influences in the causation of steroid induced glaucoma?

Experiments have revealed multiple genes involved in protective and damaging mechanisms with IOP elevation that are upregulated with dexamethasone

- i. Alpha-1 antichymotrypsin
- ii. Pigment epithelium derived factor
- iii. Cornea derived transcript 6
- iv. Prostaglandin D2 synthase

11. Prevention of steroid induced glaucoma.

Patient selection

- i. Good history and systemic conditions
- ii. Avoid steroids when safer drugs are available
- iii. Use least amount of steroid necessary

- iv. Establish baseline IOP before initiating therapy
- v. Monitoring IOP for duration if steroid therapy

Drug selection—choose a drug that can achieve desired response by safest route in lowest concentration and with fewest potential side effects

- i. Topical drops are often associated with raised IOP
- ii. Periocular injection of longacting steroid—most dangerous
- iii. Systemic steroids—least likely to induce glaucoma.

12. Mention a few words about the relative pressure effects of anti-inflammatory drugs.

- 1. Corticosteroids—pressure inducing effect is proportional to its anti-inflammatory potency. Hence betamethasone, dexamethasone and prednisolone have increased tendency to induce glaucoma.
- ii. Non-adrenal steroids—closely related to progesterone with less pressure inducing effects. For example—medrysone—used for treatment of extraocular disorders but has poor corneal penetration. Fluorometholone (0.1%) is more effective than medrysone.
- iii. NSAIDs
 - Act as COX inhibitors
 - May be effective in anterior segment inflammation
 - Acts by reducing breakdown of blood aqueous barrier
 - Do not cause increase in IOP
 - For examples—oxyphenbutazone, flurbiprofen, diclofenac
 - Other drugs in this class are suprofen and ketorolac.

13. Management of steroid induced glaucoma.

- i. The first step is to discontinue the drug—IOP returns to normal in a few weeks or replace with a milder anti-inflammatory drug
- ii. Excision of depot steroid if present
- iii. Anti-glaucoma drugs can be used to control IOP
- iv. If unsuccessful filtering surgery should be considered after confirming progression in glaucomatous damages
- v. Patients with steroid induced glaucoma respond poorly to argon laser trabeculoplasty.

4.14. LENS INDUCED GLAUCOMA

1. What are lens induced glaucoma?

Lens induced glaucoma are a group of secondary glaucoma that share the lens as a common pathogenic cause.

2. How will you classify lens induced glaucoma?

Open-angle	Closed-angle
Phacolytic glaucoma Lens particle glaucoma Phacoanaphylaxis glaucoma	Phacomorphic glaucoma Ectopia lentis

3. What is the mode of presentation in phacolytic glaucoma?

Elderly patient with history of poor vision and sudden, rapid onset of pain and redness.

4. What are the clinical features of phacolytic glaucoma?

- i. Conjunctiva: Hyperemia
- ii. Cornea: Microcystic corneal edema
- iii. Anterior chamber: Deep
 - Prominent cell and flare reaction
 - No keratic precipitates
 - White flocculent material floating in the anterior chamber with or without pseudohypopyon
- iv. Iridocorneal angle: Open
- v. Lens: Mature, hypermature/morgagnian cataract
 1. Wrinkling of anterior lens capsule
- vi. IOP: High, > 35 mm Hg

5. Mechanism of phacolytic glaucoma.

As lens ages, its protein composition alters into high molecular weight lens protein



These proteins released through microscopic openings in the lens capsule



Precipitate an inflammatory reaction and engulfed by large phagocytes



Swept into trabecular space by normal current of aqueous



Block the normal exit of aqueous causing open-angle glaucoma

6. How will you treat phacolytic glaucoma?

The ultimate treatment is lens removal after control of IOP.

- Medical: Reduction of IOP by
 β -blockers
 Apraclonidine
 Carbonic anhydrase inhibitor
 Osmotic agents
- Surgical: Cataract extraction.

7. What are the precipitating events for lens particle glaucoma?

- i. Remnants of cortical or epinuclear material after cataract surgery
- ii. Nd:YAG laser posterior capsulotomy.

8. Describe the clinical features of lens particle glaucoma.

- i. Cornea : Microcystic corneal edema
- ii. Anterior chamber : Free cortical material in the anterior chamber
 Dense flare and cells
- iii. Pupil : Posterior and peripheral anterior synechiae
- iv. IOP : Elevated

9. What is the treatment for lens particle glaucoma?

- Medical : Aqueous suppressants (decrease aqueous production)
 Topical steroids (reduce inflammation)
 Cycloplegics (inhibit posterior synechiae)
- Surgical : Removal of lens debris

10. Define phacoanaphylactic glaucoma.

It is a rare entity in which patients become sensitized to their own lens protein following surgery or penetrating trauma resulting in granulomatous inflammation.

11. Name two criteria to suspect phacoanaphylactic glaucoma.

- i. Polymorphonuclear leucocytes must be present within the aqueous or vitreous
- ii. Circulating lens protein or particle content of aqueous must be insufficient to explain glaucoma.

12. What is the clinical feature of phacoanaphylactic glaucoma?

Anterior chamber : Moderate reaction
 KPs present both on the corneal endothelium and anterior lens surface
 Low grade vitritis
 Synechial formation
 Residual lens material in the anterior chamber.

13. What is phacomorphic glaucoma?

Secondary angle closure glaucoma due to lens intumescence is called phacomorphic glaucoma.

14. What is the differential diagnosis for phacomorphic glaucoma?

Primary angle closure glaucoma.

15. How to differentiate phacomorphic glaucoma from primary angle closure glaucoma?

Phacomorphic glaucoma	PACG
Rapid swelling of lens	Normal lens growth
Occur in senile cataract, traumatic cataract	Occur in hypermetropic individual
Asymmetric central shallowing of AC	BE – shallow AC
Unilateral mature intumescent cataract	Normal lens

16. Describe pathogenesis of phacomorphic glaucoma.

Lens become intumescent (rapid development of cataract/traumatic cataract)



Swollen lens obliterate the drainage (forcing root of iris against cornea)



Resulting in angle closure glaucoma.

17. Treatment for phacomorphic glaucoma.

The definitive treatment is surgery after controlling IOP.

Reduction of IOP by

- Beta blockers, alpha adrenergic agonist, topical or systemic carbonic anhydrase
- Topical steroids and cycloplegics.
- Surgical
 - i. YAG peripheral iridotomy (PI)
 - ii. Lens extraction

18. What is ectopia lentis?

Displacement of the lens from its normal anatomic position.

19. How does ectopia lentis cause secondary glaucoma?

Anterior displacement of lens → Pupillary block
by itself or in combination with vitreous



Iris bombe



Shallowing of AC



Secondary angle-closure glaucoma

20. What are the causes of ectopia lentis?

Without systemic associations

- i. Familial ectopia lentis
- ii. Ectopia lentis pupillae
- iii. Aniridia

With systemic associations

- i. Marfan syndrome
- ii. Homocystinuria
- iii. Weil-Marchesani syndrome
- iv. Hyperlysinemia
- v. Sulfite oxidase deficiency
- vi. Stickler syndrome
- vii. Ehlers-Danlos syndrome.

21. What is the treatment of choice?

Laser iridectomy—since it is primary angle closure glaucoma with pupillary block.

22. Medical management of ectopia lentis.

- i. Cyclopegics and mydriatics
- ii. Cycloplegic act by flattening the lens and pull it posteriorly and break pupillary block
- iii. Miotics – should be avoided since it may exaggerate pupillary block and make the glaucoma worse.

23. Surgical treatment of ectopia lentis?

- i. Lens removal is not indicated unless lens is in the AC or there is evidence of lens induced uveitis.
- ii. Pars plana lensectomy is preferable if posterior lens displacement is present.

4.15. MEDICAL MANAGEMENT OF GLAUCOMA

1. What is the goal of therapy in glaucoma?

To achieve a target intraocular pressure which will arrest or prevent optic nerve head damage and progression of field defects.

2. What are the advantages of medical therapy of glaucoma?

- i. Serious side effects are rare
- ii. Most patients are easily controlled with one or two drugs.

3. What are the disadvantages of medical therapy?

- i. Less effective than surgery to lower the IOP than surgery
- ii. Costly
- iii. Effects tend to wear away with time
- iv. Prolonged use may interfere with the success of surgery
- v. Difficulty in compliance

4. Classify drugs used in glaucoma.

I. Cholinergic drugs

- a. **Parasympathomimetics:** Pilocarpine, carbachol
- b. **Anticholinesterases:** Echothiophate iodide, phospholine iodide, physostigmine and demecarium

II. Adrenergic agents

- a. **Sympathomimetics:**
 - Nonselective:** Epinephrine, dipivefrine
 - Selective (α -agonists):** Clonidine, apraclonidine, brimonidine
- b. **Adrenergic blocking agents:**
 - Non-selective:** Timolol, levobunolol, Metipranolol, carteolol
 - Selective (β_1 antagonists):** Betaxolol

III. Carbonic anhydrase inhibitors:

- Oral:** Acetazolamide, methazolamide
- Topical:** Dorzolamide, brinzolamide

IV. Hyperosmotic agents:

- Oral:** Glycerol, isosorbide
- Intravenous:** Mannitol, urea

V. Prostaglandins:

Latanoprost, bimatoprost, travoprost, unoprostone

VI. Neuroprotective agents:

- a. NMDA receptor antagonists
- b. Calcium channel blockers
- c. NO synthetase inhibitors
- d. Antioxidants
- e. Vasodilators

5. What is the mechanism of action of pilocarpine?

It is a directly acting parasympathomimetic.

In POAG: Pilocarpine acts by causing contraction of the longitudinal ciliary muscle, which pulls the scleral spur to tighten the trabecular meshwork, thereby increasing aqueous outflow.

In PACG: Pilocarpine constricts the pupil and pulls the peripheral iris from the trabecular meshwork there by relieving the pupillary block.

6. What are the contraindications to the use of pilocarpine?

- i. Neovascular glaucoma
- ii. Uveitic glaucoma
- iii. Phacolytic glaucoma

7. What are the adverse effects of pilocarpine?**A. Functional side effects:**

- i. Browache
- ii. Decreased vision in low illumination due to miosis
- iii. Induced myopia (due to ciliary body contraction)
- iv. Lacrimation due to punctal stenosis

B. Anatomical side effects:

- i. Conjunctival congestion
- ii. Corneal epithelial staining
- iii. Increased inflammation
- iv. Cataract
- v. Iris pigment cysts
- vi. Retinal holes and detachment
- vii. Increased vascular permeability and postoperative inflammation.

8. What are the types of adrenergic receptors?

α_1 , α_2 , β_1 , β_2

9. Where are they located?

- α_1 : arterioles, dilator pupillae
 α_2 : ciliary epithelium
 β_1 : heart
 β_2 : bronchi, ciliary epithelium.

10. Which is the only cardioselective β -blocker?

Betaxolol.

11. What are the contraindications for β -blockers?

- i. Congestive cardiac failure
- ii. Second or third degree heart block
- iii. Bradycardia
- iv. Asthma
- v. COPD

12. What are the β -blockers used as antiglaucoma medication?

- i. Timolol 0.5% bd
- ii. Betaxolol 0.5% bd
- iii. Levobunolol 0.5% bd
- iv. Carteolol 1%, 2%
- v. Metipranolol 0.1%, 0.3% bd

13. What is the mechanism of action of β -blocker?

Topical β -blockers inhibit cyclic adenosine monophosphate (cAMP) production in ciliary epithelium thereby decreasing aqueous production (20–50%) and hence reducing the intraocular pressure (20–30%).

14. Which is the ideal time to use timolol?

Timolol reduces aqueous production more, while taken in the morning. Because of this reason and because there is a normal physiologic decrease in aqueous flow at night, timolol is more effective when used in the morning.

15. How is β -blockers classified?

Nonselective : Timolol
 Carteolol
 Levobunolol
 Metipranolol
 Selective : Betaxolol

16. What are the types of decrease in efficacy associated with timolol application?

- i. Short term escape
- ii. Long term drift

This decrease in efficacy may be due to the response of beta receptors to constant exposure to an antagonist.

17. What are the ocular side effects of β -blockers?

- i. Allergy
- ii. Punctate epithelial erosions
- iii. Decreases tear secretion.

18. What are the systemic side effects?

CVS: Bradycardia, hypotension, heart failure.

RS: Bronchospasm, aggravating asthma, emphysema, bronchitis.

CNS: Sleep disorders, depression, forgetfulness, rarely hallucinations.

19. What are the ways to decrease systemic absorption of topically administered drug?

- i. Lacrimal occlusion following instillation
- ii. Closing the eyes for 3 minutes

20. Which antiglaucoma drug is contraindicated in children?

Alpha-2 agonists are contraindicated in children because they cross blood-brain barrier.

21. What are the advantages of gel forming solution?

- i. Stays longer
- ii. Absorption is better
- iii. Day long IOP control
- iv. Improves compliance.

22. What is 0.5% levobunolol equivalent to?

0.5% timolol.

23. What is the advantage of betaxolol?

It is the only cardioselective β -blocker. It has minimal respiratory side effects.

24. What are the dosages in which brimonidine is available?

- i. 0.2% brimonidine tartate
- ii. 0.15% brimonidine purite.

25. What is the action of highly selective α_2 adrenergic agonist (brimonidine)?

- i. Decreases aqueous formation
- ii. Increases uveoscleral outflow
- iii. Neuroprotection.

26. What is the mechanism of action of sympathomimetics?

They decrease aqueous production by the net inhibition of adenylate cyclase and the reduction of intracellular cyclic adenosine monophosphate.

27. What are the side effects of epinephrine and dipivefrine?**Ocular:**

- i. Black deposits (adrenochrome deposits in conjunctiva and cornea)
- ii. CME
- iii. Pupillary dilatation and hence contraindicated in angle closure glaucoma

Systemic:

- i. Tachycardia
- ii. Extra systoles
- iii. Systemic hypertension
- iv. Palpitation.

28. What is dipivefrine?

Dipivefrine is a derivative prodrug of epinephrine.

29. Why is clonidine not used widely?

- i. Narrow therapeutic index
- ii. Causes systemic hypotension
- iii. Causes sedation.

30. How does apraclonidine work?

Apraclonidine reduces IOP by:

- i. Reduced aqueous production
- ii. Improved trabecular outflow
- iii. Reduced episcleral venous pressure.

31. What is the advantage of apraclonidine over clonidine?

Apraclonidine achieves the substantial IOP reduction of clonidine without causing the centrally mediated side effects of systemic hypotension and drowsiness.

32. What are the side effects of α agonists (brimonidine)?

- i. Allergic blepharoconjunctivitis
- ii. Dry mouth
- iii. Somnolence
- iv. Should be avoided in children and infants because of the increased risk of somnolence, hypotension, seizures, apnea and serious derangements of neurotransmitters in the CNS.

33. What is apraclonidine?

Apraclonidine is a paraamino derivative of clonidine and it is a potent α_2 adrenergic agonist. Clonidine is believed to reduce aqueous humor production, which may be caused by constriction of afferent vessels in the ciliary processes.

34. What is the indication of 1% apraclonidine?

It has the advantage over clonidine in that it has minimal blood brain barrier penetration and rapidly brings down the IOP in cases with short term IOP elevations, such as following laser iridotomies.

35. What are the systemic side effects of α_2 agonists?

CVS: Bradycardia, vasovagal attack, palpitation, postural hypotension

GIT: Abdominal pain, nausea, vomiting, diarrhea.

36. What is the mechanism of action of carbonic acid inhibitors (CAI)?

They cause lowering of intraocular pressure by decreasing aqueous humor production, by inhibition of carbonic anhydrase II isoenzyme in ciliary epithelium.

37. What are the forms in which CAI are available?

Oral: Acetazolamide, methazolamide

Topical: Dorzolamide and brinzolamide

38. What is the dosage of oral CAI?

Acetazolamide, 250 mg tablets, over 6 hours or 500 mg sustained release capsules twice a day.

39. What are the side effects of CAI?

A. Ocular: Transient myopic shift.

B. Systemic:**a. Electrolyte imbalance:**

Metabolic acidosis
Potassium and chloride depletion
Uric acid retention

b. Gastrointestinal disturbances:

Abdominal discomfort
Metallic taste
Nausea
Diarrhea
Anorexia

c. Genitourinary disturbances:

Nocturia
Urolithiasis associated with dysurea
Impotence

d. Central nervous system disturbances:

Drowsiness, headache, fatigue, paresthesias and tingling sensations
Irritability
Vertigo
Insomnia

e. Blood dyscrasias:

Agranulocytosis
Neutropenia
Aplastic anemia

f. Dermatological side effects:

Exfoliative dermatitis
Hair loss
Pruritis
Stevens-Johnson syndrome

40. What are the topical CAI available?

2% dorzolamide hydrochloride eye drops used three times a day and 1% brinzolamide used twice a day.

41. What are the side effects of topical CAI eye drops?**A. Ocular:**

- i. Ocular burning
- ii. Stinging and discomfort
- iii. Hypersensitivity reactions like periorbital dermatitis
- iv. Superficial punctate keratitis.

B. Systemic:

Thrombocytopenia.

42. When should the CAI be avoided?

Renal transplant patients, renal failure patients and those patients with known allergy to sulfa drugs and patients with chronic liver disease.

43. What is the mechanism of action of prostaglandins?

They cause increased uveo scleral outflow by two possible mechanisms namely:

- i. The relaxation of the ciliary muscle
- ii. Remodeling the extracellular matrix of the ciliary muscle.

44. What are the various prostaglandins available?

- i. Latanoprost (0.005%)
- ii. Travoprost (0.004%)
- iii. Unoprostone (0.12%)
- iv. Bimatoprost (0.03%)

45. What are the side effects of prostaglandins?

- i. Increased pigmentation of eyelid skin.
- ii. Alterations in eyelid cilia, like hypertrichosis and increased pigmentation
- iii. Conjunctival hyperemia
- iv. Reactivation of dendritic keratitis
- v. Increased iris pigmentation due to upregulation of tyrosinase activity in melanocytes
- vi. Uveitis
- vii. Cystoid macular edema
- viii. There is no systemic side effects.

46. Why is prostaglandin analogues used at bed time?

Because they have a peak effect 10–14 hours after administration, bedtime application is recommended:

- i. To maximize efficacy
- ii. Decrease patient symptoms related to vascular dilatation.

47. What is the specific advantage of travoprost?

It has a good effect over the diurnal variation of IOP.

48. What is the mechanism of action of hyperosmotic agents?

Increases the osmolarity of plasma and thereby water from the eye (mainly from the vitreous) moves to the hyperosmotic plasma. This movement of water reduced vitreous volume and causes lowering of IOP.

49. What are the indications for hyperosmotics?

- i. Any form of acute glaucoma
- ii. To prepare the patient for surgery
- iii. Malignant glaucoma

50. What is the contraindication for hyperosmotics?

- i. Anuria
- ii. Severe dehydration
- iii. Severe cardiac decompensation
- iv. Pulmonary edema

51. What are the side effects of hyperosmotic agents?**A. Ocular:**

- i. Rebound of IOP.
- ii. Intraocular hemorrhage

B. Systemic:**GIT:**

- i. Nausea
- ii. Vomiting
- iii. Abdominal cramps
- iv. Diarrhea

CNS:

Hyperosmolality and electrolyte imbalance causes:

- i. Thirst
- ii. Chills
- iii. Fever
- iv. Confusion
- v. Disorientation

C. Genitourinary system:

- i. Diuresis
- ii. Electrolyte imbalance
- iii. Dehydration
- iv. Hypovolemia

D. Cardiovascular system:

- i. Angina
- ii. Pulmonary edema
- iii. Congestive cardiac failure

E. Others:

- i. Hyperglycemia
- ii. Hypersensitivity.

52. What is the most common instruction given to patients after IV mannitol?

Not to get up immediately after the injection, since it may lead to hypotension and rarely, even coning of the brain.

53. What is the dosage of hyperosmotic agents?

Glycerol 50%	oral route	1–1.5 g/kg
Isosorbide 45%	oral route	1–2 g/kg
Mannitol 20%	IV	1–2 g/kg

54. What is the advantage of isosorbide over glycerol?

It can be safely given to diabetics unlike glycerol.

55. Why is mannitol the drug of choice for IV use?

- i. Less irritating to blood vessels
- ii. Can be used in diabetic patients
- iii. Can be used in renal failure.

56. What are the disadvantages of mannitol?

- i. Large volume
- ii. Dehydration
- iii. Diuresis.

57. What are the advantages of urea?

- i. Less cellular hydration
- ii. No caloric value
- iii. Penetrates eye readily.

58. What are the disadvantages of urea?

- i. Unstable
- ii. Thrombophelbitis and sloughing of skin at injection site, if extravasation occurs.

59. What is the percentage reduction of IOP in each class of drugs?

- i. Prostaglandin analogs : 25–32%
- ii. β -blockers : 20–30%
- iii. Adrenergic agonists : 15–20%
- iv. Parasympathomimetics : 15–20%
- v. Carbonic anhydrase inhibitors : 15–20%

60. What are the disadvantages of using 2 or more drugs separately?

- i. Nonadherence to treatment
- ii. Poor compliance
- iii. Difficult scheduling
- iv. Washout effect
- v. Preservative toxicity
- vi. Cost

61. What are the parameters which need to be addressed when going in for fixed combination (FC)?

- i. Need
- ii. Is IOP lowering effect superior?
- iii. Pharmacologically complementing mechanism of action
- iv. Similar dosing schedule

62. What are advantages of timolol 0.5% + dorzolamide 2% combination?

- i. Reduces IOP more than either drug alone
- ii. Produces maximal or near maximal efficacy
- iii. Additive in their effect in spite of being aqueous suppressants
- iv. No electrolyte imbalance.

63. What is the advantage of timolol and prostaglandin combination?

Prostaglandin ↑ uveoscleral outflow
 Timolol ↓ aqueous inflow
 13–37% IOP reduction.

64. Why should we not combine prostaglandins with pilocarpine?

Pilocarpine :	contracts ciliary muscle
	↓ uveoscleral outflow
	↑ trabecular outflow
Prostaglandins:	relaxes ciliary muscle
	↑ uveoscleral outflow.

65. What are the fixed combination of prostaglandins?

Prostaglandins with brimonidine
 Prostaglandins with topical CAI.

66. What are the advantages of fixed combination?

- i. Simple dosing and easy scheduling
- ii. More patient adherence
- iii. Maintains IOP at a lower level
- iv. Less preservative toxicity
- v. Less systemic toxicity
- vi. Economical.

67. What are the disadvantages of fixed combination?

1. a. Formulation of both drug in single bottle → a. time of action. For example, for timolol, dosing first thing in the morning is preferred in order to effectively blunt an early morning pressure rise while minimizing the risk of systemic hypotension during sleep, when aqueous production is diminished. But prostaglandin analogues reach the peak effect 10–14 hours after administration. Hence bed time application is recommended to maximize efficacy and decrease patient

symptoms related to vascular dilatation. Therefore when both these drugs are combined, dosage becomes an issue.

b. Alters the individual potency of medication.

2. Without confirming the efficacy of individual components, so unnecessary exposure to drugs which will not be beneficial.

68. What are the choices of drugs in POAG/PACG post YAG PI?

Prostaglandins + timolol

Dorzolamide + timolol

Brimonidine + timolol

Pilocarpine + timolol

69. What are the choices of drugs in uveitic glaucoma?

i. Dorzolamide + timolol

ii. Brimonidine + timolol.

70. What are prostamides?

Prostamides are COX-2 derived oxidation products of the endocannabinoids/ endovanilloid anandamide.

71. What are neuroprotective drugs?

These drugs are thought to protect the optic nerve and include:

i. Memantine

ii. Nitric oxide synthetase inhibitors

iii. Peptides

iv. Cannabinoids

v. Calcium channel blockers.

72. Which anti-glaucoma medications are contraindicated in uveitis?

Miotics and prostaglandin analogues are contraindicated because they increase blood-aqueous barrier breakdown thereby increasing inflammation.

73. What are prostamides closely related to?

PGF2 alpha is related to bimatoprost.

4.16. NEWER DRUGS IN GLAUCOMA

1. Classify new ocular hypotensive agents.

- i. Natural products: Cannabinoids
- ii. Activators of extracellular matrix hydrolysis: Matrix metalloproteinases (MMPs)
- iii. Cytoskeleton modulator: Ethacrynic acid
- iv. Protein kinase inhibitors
- v. Compounds that increase cyclic GMP.

2. What are cannabinoids?

Mechanism of action:

- i. Vasodilatation of the efferent vessels in the anterior uvea
- ii. Modification of the surface membrane glycoprotein residues on the ciliary epithelium
- iii. Increased facility of outflow.

Side effects:

Tachycardia, hypotension, euphoria and hyperemia of the conjunctiva. Pulmonary fibrosis and impaired neurologic behavior.

Disadvantages:

Systemic hypotension, which may be associated with reduced perfusion of the optic nerve head. These side effects of the cannabinoids thus far tested in humans seriously limit their usefulness in the treatment of glaucoma.

3. What are the activators of extracellular matrix (ECM) hydrolysis group?

Mechanism of action:

An excessive accumulation of ECM material in the TM of glaucomatous eyes likely contributes to decreased aqueous outflow. Therefore, therapeutic manipulations that eliminate the excessive extracellular matrix should theoretically improve outflow facility and consequently lower IOP.

Current drug under study from this group:

- i. Matrix metalloproteinases
Activation of these enzymes reduces the excessive accumulation of ECM molecules, such as proteoglycans, collagens, fibronectins and laminin, in the glaucomatous eye and in turn decreases hydrodynamic resistance of the outflow pathway.

Disadvantages:

MMPs, being proteins of large molecular mass, are not practical as medical treatment.

- ii. Inducers of matrix metalloproteinases
Tert-butylhydroquinone, can upregulate MMP-3 expression in the TM cells and increase aqueous outflow facility in glaucoma and nonglaucoma eyes.
- iii. Activator of glycosaminoglycan degradation compounds:
Products that catalyze the hydrolysis of glycosaminoglycans (GAGs) stimulate the degradation of ECM in the TM and increase the outflow. GAG-degrading enzymes, hyaluronidase and chondroitinase, consistently increase outflow facility and decrease IOP in study models. Similar to MMPs, these GAG-degrading enzymes are not practical for clinical use. AL-3037A (sodium ferri ethylenediamine tetraacetate), a small molecule with a chelated ferric ion, accelerates the ascorbate mediated hydrolysis of GAGs and enhances outflow facility by 15–20%. Future studies may discover other small molecules that stimulate the production or activation of these enzymes, which are more suitable as clinically useful therapeutic agents.

4. What are protein kinase inhibitors?

Mechanism of action: Exact mechanism of action is not fully understood. They likely increase aqueous outflow by affecting cytoskeleton of the TM or Schlemm's canal endothelial cells.

Current drug under study from this group:

- i. Broad spectrum kinase inhibitors—H-7
- ii. Inhibitors of protein kinase C—GF109203X
- iii. Rho-associated coiled coil-forming kinase (ROCK) inhibitors—Y-27632 and H-1152.

Advantages:

Topically active and have great IOP-lowering efficacy.

Disadvantages:

Since kinases are involved in many cellular functions in most tissues, vigilance is needed for the potential local and systemic side effects of prolonged use of these compounds.

5. What are cytoskeleton acting agents?

Mechanism of action:

Compounds that disrupt the cytoskeleton (microfilaments, microtubules, intermediate filaments) can affect the cell shape, contractility and motility, and these changes may be sufficient to alter the local geometry of the outflow pathway and consequently aqueous outflow.

Current drug under study from this group:

- i. Ethacrynic acid
- ii. Latrunculin B
- iii. Swinholide A

Disadvantages:

- i. Poor corneal penetration
- ii. Corneal toxicity
- iii. Trabecular meshwork toxicity.

These side effects have limited its clinical utility as a glaucoma therapeutic agent.

6. What are compounds that increase cyclic GMP?**Mechanism of action:**

Cyclic GMP affects both aqueous production and outflow.

Activation of cyclic GMP-dependent protein kinases, which, by phosphorylation, leads to functional changes of various proteins, e.g. an inhibition of Na-K ATPase, leads to decrease in aqueous production.

Current drug under study from this group:

- i. Cyclic GMP analogs:
Cell permeable analogs of cyclic GMP
- ii. Nitric oxide donors:
Nitroglycerin, isosorbide dinitrate, sodium nitrite, hydralazine, minoxidil, sodium nitroprusside.
- iii. Natriuretic peptides:
Atrial natriuretic peptide (ANP)
Brain-derived natriuretic peptide (BNP)
C-type natriuretic peptide (CNP).

Intracellular cyclic GMP levels can also be increased by the activation of guanylyl cyclases. Nitric oxide (NO) and compounds that release NO by hydrolysis (NO donors) are activators of the soluble guanylyl cyclases. Natriuretic peptides are activators of the membrane-bound guanylyl cyclases. Both NO donors and natriuretic peptides are effective IOP-lowering compounds.

Disadvantages: Since they are peptides, cornea penetration and degradation by peptidases can be prohibitive hurdles for their clinical usefulness.

- iv. Compounds that increase natriuretic peptides:
Candoxatril natriuretic peptides are degraded partly by a neutral endopeptidase NEP 24.11. Thus, inhibition of this enzyme increases tissue concentration of natriuretic peptides. Oral administration of candoxatril, a prodrug that is metabolized to an NEP 24.11 inhibitor, increases atrial natriuretic peptide (ANP) level and significantly lowers IOP by 2–3 mm Hg.

7. Neuroprotection:**Rationale for using neuroprotection:**

It has been hypothesized that intraretinal or intravitreal glutamate levels that are neurotoxic to ganglion cells play a role in glaucoma and hence drugs which work against these agents can help in glaucoma management.

They are also supposed to enhance the vascular supply and decrease pro-apoptotic factors.

Methods for neuroprotection

A. Pharmacologic

- i. Glutamate receptor antagonists
NMDA receptors: Memantine
AMPA/kainate antagonists
- ii. Calcium channel blocker
Nimodipine
- iii. β 2-adrenergic agonists like brimonidine
- iv. Neurotrophic factors
Neurotrophin 3
- v. Nitric oxide synthase inhibitors
Aminoguanidine
- vi. Reactive oxygen species scavengers
- vii. Apoptosis inhibitors
Cytochrome C release inhibitors
Caspase inhibitors.

B. Immune modulation

Focal activation of the immune system in the optic nerve or retina as a way of preserving retinal ganglion cells and their functions. (Activated T lymphocytes primed to optic nerve constituents, e.g. myelin basic protein, would home to sites of injury and release factors that are neuroprotective).

C. Preconditioning

Concept: An injury insufficient to cause irreversible damage often may result in increased resistance to future injury. This type of neuroprotection is difficult to translate directly into clinical use, as it requires a series of injuries insufficient to kill retinal ganglion cells and it may not be tolerated by the patient.

Neurorepair and regeneration

Neurorepair is the name given to the production and differentiation of new neurons. Regeneration is the name given to the extension of axons to their appropriate targets. Neurorepair focuses on the use of stem cells (embryonic stem cells, adult stem cells or more differentiated neural progenitor cells) to repopulate and repair damaged neuronal tissues.

8. Neuroprotectors.

A. Memantine

It is an N-methyl-D-aspartate (NMDA) receptor antagonist.

Mechanism of action:

The NMDA receptor is an ion channel that is activated by glutamate, allowing extracellular calcium to enter the cell. In normal physiologic conditions, the NMDA receptor has an important role in neurophysiologic processes, such as memory. However, excessive activation of the

NMDA signaling cascade leads to “excitotoxicity” wherein intracellular calcium overloads neurons and causes cell death through apoptosis. Memantine blocks the excessive glutamate stimulation of the NMDA receptor of the regional ganglion cell and protects it from calcium mediated apoptosis.

Uses: To treat CNS disorders like—Parkinson, Alzheimer’s disease. Currently being studied as a neuroprotective agent in glaucoma.

B. Nitric oxide synthase inhibitors:

Aminoguanidine:

Mechanism of action:

Nitric oxide is a gaseous second messenger molecule. It has both physiologic and pathologic functions in blood flow, immune response and neuronal communication.

The expression of nitric oxide is regulated by three different forms of nitric oxide synthase (NOS) — endothelial NOS (eNOS), neuronal NOS (nNOS) and inducible NOS (iNOS).

Role of nitric oxide in the eye:

Aqueous humor dynamics, maintaining a clear cornea, ocular blood flow, retinal function and optic nerve function. Excessive nitric oxide generated by iNOS in optic nerve astrocytes and microglia is associated with optic nerve damage. Aminoguanidine by inhibiting inducible nitric oxide (iNOS) synthase was shown to prevent retinal ganglion cell loss.

C. Calcium channel blockers

Nimodipine

Mechanism of action:

Produce vasodilatation by inhibiting the entrance of calcium ions into vascular smooth muscle cells. Hence may protect the optic nerve head by improving vascular perfusion.

They have also been shown to have ocular hypotensive activity.

Current status: The level of evidence at this time, as well as the systemic side effects of calcium channel blockers, does not support the use of this class of drugs for the routine management of glaucoma.

D. Neurotrophic factors

Neurotrophins are peptides that have an important role in the development and maintenance of various neuronal populations. Brain-derived neurotrophic factor, neurotrophin 3 and nerve growth factor have differential effects on the cell survival promotion, differentiation or demise. The role for these biologically active peptides and their receptors in relation to the survival and death of ganglion cells is under study.

E. Apoptosis inhibitors

Caspases are a family of proteases that execute the dismantling and demolition of cells undergoing apoptosis. Caspases 8 and 9 have been shown to be activated in experimental glaucoma. Suppression of apoptosis using caspase inhibitors is an approach that has been explored with modest success.

9. Other agents.

- i. **Tetrahydrocortisol:** A metabolite of cortisol, shown to lower the dexamethasone-induced ocular hypertension.
- ii. **Mifepristone:** A specific glucocorticoid receptor antagonist lowers IOP, possibly by blocking the glucocorticoid receptor-mediated effects in ocular tissues.
- iii. **Spirolactone:** A synthetic steroidal aldosterone antagonist with potassium-sparing diuretic-antihypertensive activity produced significant IOP reduction in glaucoma patients, which persisted 2 weeks after termination of the treatment.
- iv. **Antazoline:** An antihistamine of the ethylenediamine class, shown to lower the IOP following topical administration apparently by decreasing aqueous production. Angiotensin-converting enzyme inhibitor: In a topical formulation has been shown to lower the IOP in dogs and humans with ocular hypertension or open-angle glaucoma.
- v. **Organic nitrates:** Intravenous nitroglycerin or oral isosorbide dinitrate have been reported to lower IOP in glaucoma and nonglaucoma patients.
- vi. **Melatonin:** A hormone produced by the pineal gland, was shown to lower the IOP in normal subjects. Demeclocycline, tetracycline and other tetracycline derivatives: Lower the IOP in rabbits, which appears to be related to reduce aqueous humor production. Acepromazine, an analog of chlorpromazine that is used as a tranquilizer in veterinary medicine, had no effect on IOP when given topically to normotensive rabbits, but reduced the pressure for at least 32 hours in rabbits with chronic IOP elevation produced by argon laser applications to the trabecular meshwork.
- vii. **Alternative medicine:**
Ginkgo biloba extract (GBE): Leaf extracts of the ginkgo tree have many neuroprotective properties applicable to the treatment of non-IOP-dependent risk factors for glaucomatous damage. GBE exerts significant protective effects against free radical damage and lipid peroxidation. It preserves mitochondrial metabolism and ATP production. It partially prevents morphologic changes and indices of oxidative damage associated with mitochondrial aging. It can scavenge nitric oxide and possibly inhibit its production. It can reduce glutamate-induced elevation of calcium concentrations and can reduce oxidative metabolism in resting and calcium-loaded neurons and inhibits apoptosis. GBE has been reported to be neuroprotective for retinal ganglion cells in a rat model of chronic glaucoma.

4.17. LASERS IN GLAUCOMA

1. What are the applications of laser in glaucoma?

A. Therapeutic

i. To treat internal block:

Iridotomy (both argon and Nd:YAG and diode)

ii. To treat outflow obstruction:

Trabeculoplasty (argon)

Trabeculopuncture (argon)

Gonioplasty/iridoplasty (argon)

iii. Miscellaneous uses:

Cyclophotocoagulation (Nd:YAG)

Cyclodialysis (Nd:YAG)

Pupilloplasty (argon)

Sphincterotomy (both)

To rupture cysts of iris and ciliary body (both):

Goniophotocoagulation (argon)

Laser suturolysis

Anterior hyaloidotomy

B. Diagnostic

i. Confocal scanning laser ophthalmoscope (optic nerve head evaluation)

ii. Laser retinal Doppler flowmetry (optic nerve head perfusions).

2. Mention commonly used lasers and their wavelengths.

Laser	Wavelength (in nm)
Excimer	193
Argon blue-green	488–514
Nd:YAG	1064
Diode	810
CO ₂	10600

3. What are the principles used in lasers to treat glaucoma?

a. Photodisruption:

When ultra short pulses of laser are targeted at tissue, the latter is reduced to a form of matter called 'plasma'. This generates fluid forces (both hemodynamic waves and acoustic pulses) which propagate in all directions. This propagating force incises tissue. This forms the basis of Nd:YAG capsulotomies and iridotomies.

b. Photocoagulation:

Any chromophore including iris and trabecular meshwork absorbs laser light and converts to heat energy. This causes coagulation of tissue. When collagen is warmed during this process, it contracts and changes

the microanatomy of tissues (trabeculoplasty). Likewise, the leaking blood vessels are sealed in neovascular glaucoma.

4. What are the indications of laser iridotomy?

- i. Acute angle closure glaucoma
- ii. Prodromal stage of angle closure glaucoma
- iii. Chronic angle closure glaucoma
- iv. Aphakic or pseudophakic pupillary block
- v. Malignant glaucoma
- vi. Prophylactic laser iridotomy in fellow eye of angle closure
- vii. Nanophthalmos
- viii. Traumatic secondary angle closure
- ix. Microspherophakia
- x. Pigment dispersion syndrome
- xi. To penetrate nonfunctioning peripheral iridectomy
- xii. Combined mechanism glaucoma
- xiii. Alteration in angle structure due to lens like phacomorphic glaucoma.

5. What are the contraindications of laser peripheral iridotomy?

- i. Corneal edema
- ii. Corneal opacification
- iii. Flat anterior chamber
- iv. A completely sealed angle resulting in angle closure
- v. Primary synechial closure of the angle
- vi. Uveitis
- vii. Neovascular glaucoma
- viii. Iridocorneal endothelial syndrome.

6. What is the mechanism by which argon produces peripheral iridotomy?

Argon laser requires uptake of light energy by the pigment (thermal effect) and coagulates tissues. However, it requires more energy for iridotomy and is associated with more late closures compared to Nd:YAG laser.

7. What are the conditions where argon laser is preferred over Nd:YAG in producing peripheral iridotomy?

- i. Brown irides (it is used in sequential contribution with Nd:YAG)
- ii. Patients on chronic anticoagulant therapies
- iii. Angle closure stage of neovascular glaucoma
- iv. Patients with blood dyscrasias like hemophilia.

8. What is the mechanism by which Nd:YAG laser produces a peripheral iridotomy?

Nd:YAG works on the principle of photodisruption and is effective on all iris colors. Laser wavelength is near infrared range (1064 nm). It is always preferred over argon laser.

9. Describe the technique of Nd:YAG PI.

i. Preoperative preparation:

Pilocarpine 2%—3 times (5 minutes apart), is used to constrict the pupil.

Brimonidine or apraclonidine 0.2%—Half hour before procedure.

ii. **Role of using a contact lens:** The lens provides firm control over eyeball and reduces saccades and extraneous eye movements that interfere with accurate superimposition of burns. The lens assists in keeping the lids separated, focuses the laser beam and minimizes loss of laser power caused by reflection. The Abraham lens which is used, consists of a fundus lens with a +66D planoconvex lens with a button placed on its anterior surface. The button provides magnification without loss of depth of focus.

iii. **The gonioscopy solution:** Absorbs excess heat delivered to the cornea thus decreasing the incidence of corneal burns.

iv. **Site:** Iridotomy spot may be placed in the upper nasal iris to avoid diplopia and macular burns. The laser is targeted at the crypts to ensure easy penetration. The red helium neon laser aiming beam is brought to focus when the multiple beams are brought into a single spot aimed through center of the contact lens.

Energy: 3–8 mJ

1–3 pulses per shot

PI size should be 300–500 μ

v. Immediate post treatment:

Prednisolone acetate 1% is used every 2 hours for 1 day and then tapered over a week. The intraocular pressure is checked regularly at 1 hour, 1 day, 1 week and 4 weeks. Gonioscopy is done at 1 week and dilation at 2 weeks. Intraocular pressure, status of the overlying corneal endothelium, anterior chamber reaction and iridotomy patency are evaluated. Gonioscopy is always performed to be sure that pupillary block has been relieved and to determine the extent of PAS. Smallest size iris opening that is acceptable following laser iridotomy is 60 μ or greater. More importantly, one must be able to see the lens capsule through the iridotomy to document relief of pupillary block by gonioscopy. Failing this, repeat treatment is indicated.

10. What are the signs of iridotomy penetration?

- i. Sudden gush of aqueous
- ii. Retroillumination shows a patent PI
- iii. Deepening of AC
- iv. Plomb of iris pigments.

11. What are the various techniques used in argon laser PI?

Hump, drumhead and chipping are the techniques advocated for producing peripheral iridotomy with continuous wave argon laser.

Hump technique: Involves creating a localized elevation of iris with large diameter low energy burns and then penetrating the hump with a small intense burn.

Drumhead technique: Involves placing a large diameter low energy burn around the intended treatment site to put the iris on stretch and the area is penetrated with small high energy burns.

Chipping technique: Especially useful in dark brown iris where standard settings may produce black char in iris stroma making it difficult to penetrate the tissue. This is circumvented by using multiple short duration burns. This is called the chipping technique.

12. Common complications of laser peripheral iridotomy.

- i. Corneal burn
- ii. Uveitis
- iii. Elevated intraocular pressure
- iv. Hemorrhage
- v. Pigment dissemination and iris atrophy
- vi. Lens injury
- vii. Posterior synechia
- viii. Retinal damage
- ix. Corectopia
- x. Monocular diplopia
- xi. Malignant glaucoma
- xii. Glare.

13. Difference between surgical iridectomy and laser iridotomy.

	Surgical iridectomy	Laser iridotomy
Margins	Clean cut, triangular	Ragged, irregular
Site	Near limbal incision site (mostly 12 o'clock)	Any clock hour on the iris surface
Closure	Not possible	Possible
Surrounding iris tissue	Not altered	May be associated with pigment dispersions

14. What are the indications for argon laser trabeculoplasty?

- i. Primary open-angle glaucoma
- ii. Exfoliative glaucoma
- iii. Pigmentary glaucoma
- iv. Glaucoma in pseudophakia
- v. Combined mechanism glaucoma
- vi. Normal tension glaucoma
- vii. Noncompliance with medications
- viii. Inadequate medical control.

15. What are the contraindications for argon laser trabeculoplasty?

- i. Inflammatory glaucoma
- ii. Iridocorneal endothelial syndrome
- iii. Neovascular glaucoma
- iv. Synechial angle closure
- v. Developmental glaucoma.

16. Describe the technique of argon laser trabeculoplasty.

- i. Preoperatively: Pilocarpine is used to constrict the pupil. 0.5% apraclonidine and topical xylocaine are instilled.
- ii. Contact lens: Ritch trabeculoplasty/Goldmann 3 mirror can be used.
- iii. Site: Equally spaced burns are applied to anterior half of trabecular meshwork at the junction of pigmented functional and nonfunctional trabecular meshwork.
- iv. Laser parameters: 180–360° of angle treated with argon blue green of 800–1200 mW; 0.1 sec exposure, 50 µmm spot size, 24 shots per quadrant.
- v. End point: Blanching of trabecular meshwork or appearance of an air bubble.

17. What is the mechanism of action of argon laser trabeculoplasty?

Explained by 2 theories:

Mechanical theory: Collagen shrinkage is produced at site of burns. There is stretching of trabecular meshwork between the burns which opens the meshwork pores and allows aqueous to flow better. Laser burns attract phagocytes that clean up the debris within the meshwork and allow aqueous to flow better.

Biological theory: It causes activation of macrophages to ingest and clear the debris thereby increasing the outflow facility.

18. What are the complications of argon laser trabeculoplasty?

- i. Pressure rise
- ii. Visual loss
- iii. Peripheral anterior synechiae
- iv. Uveitis
- v. Hyphema
- vi. Increased incidence of Tenon's cyst following trabeculectomy.

19. What is the percentage decrease in IOP following argon laser trabeculoplasty in POAG?

Average reduction is about 30%. About 50% of eyes remain well controlled after 5 years of treatment.

20. What is the effect on success of trabeculectomy following ALT versus an eyes in which no laser was done previously?

The risk of encapsulated blebs following filtration surgery is upto 3 times more in eyes previously treated by ALT.

21. What are the indications for selective laser trabeculoplasty?

- i. Open-angle glaucoma
- ii. Failed argon laser trabeculoplasty
- iii. Pseudoexfoliation glaucoma
- iv. Pigmentary glaucoma
- v. Juvenile glaucoma
- vi. Inflammatory glaucoma
- vii. Poorly compliant patient
- viii. End stage treatment.

22. What is the mechanism of action of selective laser trabeculoplasty?

Selective laser trabeculoplasty therapy targets the pigmented melanin containing cells (yellow) in the trabecular meshwork preventing thermal transfer to the surrounding tissue.

A cellular and biochemical model has been proposed.

Macrophages are recruited to the laser treatment zones which stimulate release of cytokines. These cytokines upregulate synthetic matrix metalloproteinase (MMP), which increase the porosity of endothelial layers of trabecular meshwork and Schlemm's canal and increases aqueous outflow.

23. What are the laser parameters used in selective laser trabeculoplasty?

Frequency doubled Q switched Nd:YAG laser is used.

532 nm, pulse duration 3 ms

Spot size 400 μ

Energy 0.2–1.7 mW, 50–100 adjacent laser spots are applied.

24. What is laser iridoplasty?

It is also called gonioplasty and is a technique to deepen the angle. It is an iris flattening procedure done in:

Plateau iris

Nanophthalmos

POAG in anatomically narrow angle.

25. What are the settings used for laser iridoplasty?

Settings—100–200 mm spot size

—200–400 mW power

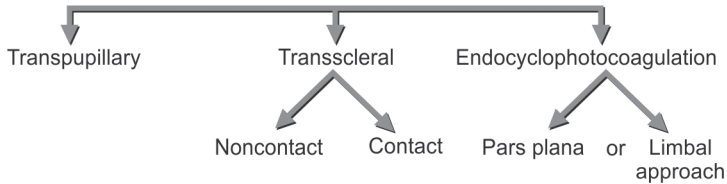
—0.1 second

—20–24 spots over 360°

26. What is the role of lasers in cyclodestructive procedures?

Involves cyclophotocoagulation – A thermal method of destroying part of ciliary body.

Approaches can be



Transpupillary procedures are unpredictable and give disappointing results. Transscleral route is the preferred modality.

In noncontact: There is slit lamp delivery of laser energy through air.

Contact method: Involves fiberoptic probe delivery directly to ocular surface.

Endocyclophotocoagulation: Involves use of intraocular laser probe to treat ciliary processes. Two options are available.

Pars plana route: Particularly useful in neovascular glaucoma in diabetic patients in whom vitrectomy is also needed.

Limb route: Procedure is carried out through limbal incision. Useful in phakic, pseudophakic and aphakic patients. It can be combined with cataract extraction.

27. How is laser useful in malignant glaucoma?

Laser hyaloidectomy/hyaloidotomy or vitreolysis is done. In malignant glaucoma anterior hyaloid acts as a barrier to fluid movement into anterior chamber. Laser (by Nd:YAG) is used to photodisrupt the anterior hyaloid face and relieve ciliovitreal compression.

Laser parameters: 100–200 μm

Spot size 1–11 mm

28. What is laser suturolysis?

Technique by which scleral flap sutures applied for closing flap in trabeculectomy can be lysed or cut using lasers.

29. Describe the technique of laser suturolysis.

Lasers used : Solid Nd:YAG laser or argon green

Timing : Within few days to 6 months after trabeculectomy

Indications : When the target intraocular pressure is not reached.

Lenses used : Zeiss gonioprism or Hoskins laser suturolysis lens

Duration : 0.02 to 0.15 seconds

Spot size : 50–100 μm

Power : 300 mW

Gentle pressure over conjunctiva makes sutures more visible.

30. What are the complications of laser suturolysis?

- i. Conjunctival burns
- ii. Flat anterior chamber
- iii. Conjunctival flap leak

- iv. Hypotonous maculopathy
- v. Iris incarceration, hyphema
- vi. Blebitis, endophthalmitis.

31. Describe technique of digital pressure.

Constant and firm digital compression is applied over inferior aspect of globe through the patient's lower lid while the eye is upturned. Duration of each compression shouldn't last for more than 10 seconds.

32. What is goniophotocoagulation?

Used to ablate vessels which cross scleral spur.

Argon laser of 150–500 mW

100 μ spot size is used for 0.2 sec for this procedure.

33. What are the indications for transscleral cyclophotocoagulation?

- i. In refractory glaucoma when intraocular pressure is uncontrolled despite maximum tolerated medical treatment and failed filtration or high risk of failure of the same like in aphakic, pseudophakic or neovascular glaucomas.
- ii. Glaucoma associated with inflammation
- iii. Eyes with previous failed filtering procedure or following penetrating keratoplasty.

34. Describe diode laser transscleral cyclophotocoagulation.

Anesthesia: Administer local anesthetic. Supplement with retro or peribulbar injections. Can be done in supine position or sitting at the slit lamp.

Treatment quadrants: Over a 270° area involving inferior, nasal and superior quadrants. Temporal quadrant is spared to allow for some ciliary production of aqueous humor.

Treatment parameters:

Pigmentation	Starting power	Starting duration
Dark	1500 mW	2000 ms
Light	1750 mW	2000 ms

Pops may be heard during treatment indicating tissue disruption but they are not a prerequisite for effective treatment.

The G probe tip and eye surface is kept moist by methylcellulose or artificial tears.

Postoperative care: The eye is patched for 4 to 6 hours. Topical cycloplegics BD or more, topical steroids QID is given and tapered as inflammation subsides. All preoperative glaucoma medications except miotics are to be continued. Monitor patients at 1, 3, 6 weeks after treatment.

35. What are the complications of diode cyclophotocoagulation?

Commonly:

- i. Pain

- ii. Inflammation
- iii. Reduced visual acuity due to cystoid macular edema
- iv. Hypotony

Uncommon complications:

- i. Hypopyon
- ii. Corneal epithelial defect
- iii. Scleral thinning
- iv. Graft failure
- v. Malignant glaucoma
- vi. Suprachoroidal hemorrhage
- vii. Hyphema
- viii. Sympathetic ophthalmitis
- ix. Phthisis bulbi.

4.18. TRABECULECTOMY

1. What are the types of filtering surgeries?

Filtering surgeries are of 3 types:

- i. Full thickness
- ii. Partial thickness
- iii. Nonpenetrating

Full thickness (Example):

- i. Sclerectomy
- ii. Trephination
- iii. Thermal sclerostomy (Scheie's procedure)
- iv. Laser sclerostomy (ab externo/interno)
- v. Iridencleisis
- vi. Goniopuncture

Partial thickness:

- Trabeculectomy

Nonpenetrating:

- i. Visco canalostomy
- ii. Canaloplasty
- iii. Deep sclerectomy.

2. What are “full thickness” operations?

These are filtering operations without a sclera flap. Entire thickness of the wall from the corneoscleral surface to the anterior chamber is removed.

3. What is a “partial thickness” operation?

An operation with a partial thickness flap of sclera overlying the opening between the anterior chamber and the subconjunctival space, e.g. trabeculectomy.

4. What is the advantage of partial thickness flap over full thickness?

- i. Uniform control of IOP
- ii. Decrease risk of postoperative hypotony thus decrease risk of hypotonous maculopathy
- iii. Decreased risk of postoperative complication like hyphema, iris prolapse, shallow anterior chamber
- iv. Decreased risk of postoperative infection, endophthalmitis.

5. Is the term trabeculectomy a misnomer?

Yes, because the block of tissue removed does not need to include trabecular meshwork to be successful. The procedure involves a peripheral posterior keratectomy more than removal of trabecular meshwork.

6. What is the principle?

Trabeculectomy works mainly because of filtration. The basic mechanism is by creating a fistula at the limbus, which allows aqueous humor to drain

from the anterior chamber, around the edges of the sclera flap and into the subconjunctival space from where it leaves by transconjunctival filtration or by absorption into the lymphatics and vessels of subconjunctival tissue.

7. What are the indications for trabeculectomy in primary open-angle glaucoma?

Failed maximal tolerated medical therapy and failed laser surgery or poor candidates of laser with any of the following:

- i. Progressive glaucomatous optic nerve head damage
- ii. Progressive glaucomatous field loss
- iii. Anticipated optic nerve head damage or as a result of excessive IOP
- iv. Anticipated visual field damage
- v. Lack of compliance with anticipated progressive glaucomatous damage.

8. What are the features of a good filtering bleb?

The blebs which are associated with good IOP control are:

- i. Avascular
- ii. Numerous microcysts in the epithelium
- iii. Either low and diffuse or more circumscribed and elevated.

9. What are the signs of a failing bleb?

The signs of a failing bleb are:

- i. Reduced bleb height
- ii. Increased bleb wall thickness
- iii. Vascularization of the bleb
- iv. Loss of conjunctival microcysts
- v. Raised IOP.

10. What are the types of blebs following trabeculectomy?

There are 4 types:

- i. **Type 1 bleb:** Thin and polycystic appearance due to transconjunctival flow of aqueous. It is associated with good filtration.
- ii. **Type 2 bleb:** Flat, thin and diffuse with a relatively avascular appearance, associated with good filtration. Conjunctival microcysts are usually visible with high magnification.
- iii. **Type 3 bleb:** Flat, not associated with microcystic spaces, contains engorged blood vessels on its surface. This bleb does not filter and hence the intraocular pressure is elevated.
- iv. **Type 4 bleb/encapsulated bleb/Tenon's cyst:** Localized, highly elevated, dome shaped, cyst like cavity of hypertrophied Tenon's capsule with engorged surface blood vessels. This bleb does not filter and hence the intraocular pressure is elevated.
- v. Risk factors for Tenon's cyst:
 - Young individuals
 - Previous conjunctival surgery
 - Secondary glaucoma
 - Laser trabeculoplasty

- Topical sympathomimetic therapy
- Tenon cyst in the fellow eye.

11. What is the preoperative care?

- i. If IOP is very high then it is reduced to a safe level
- ii. Treat any ocular inflammation (reduced chances of establishing a lasting bleb)
- iii. Discontinue epinephrine/anticholinesterase to reduce vascular congestion and reduce intraoperative bleedings
- iv. Discontinue aqueous suppressant timolol (2 weeks prior) and carbonic anhydrase inhibitors (1–2 days prior)) to prevent ocular hypotony and establish a filtering bleb
- v. Avoid gentamicin, which can irritate conjunctiva and produce congestion of eyes
- vi. Constrict pupil with pilocarpine 1% 3 times, 1 hour before the operation. It prevents iris prolapse
- vii. If aspirin had been used, it is discontinued for 5 days before surgery
- viii. If eyes have new vessels, preoperative panretinal laser photocoagulation should be done first to induce regression of vessels and improve prognosis.

12. What are the steps of trabeculectomy?

- i. A bridle suture is inserted
- ii. A conjunctival flap is fashioned superonasally. The flap may be based either at the limbus or at the fornix
- iii. A triangle or rectangle based at the limbus is outlined on the sclera measuring 3 mm radially and 4 mm circumferentially by a wet field cautery. One may make a square/triangular flap. With a sharp pointed knife, incisions are made along the cautery marks through 2/3rd of the sclera thickness starting as anteriorly as possible behind the reflected flap.
- iv. One of the corners of the flap is held up with toolkit colibri forceps and dissection is started. A natural tissue plane will become apparent at about 1/3rd of scleral thickness. The dissection is done in an anti-direction in the same plane keeping the blade flat until the color turns from white to grey
- v. The dissection is continued until clear cornea has been reached
- vi. Paracentesis is done at this stage
- vii. The fistula is begun by entering the anterior chamber with a knife just behind the hinge of scleral flap
- viii. This deep block is excised using Kelly Descemet's membrane punch
- ix. Internal ostium should be 1.5 x 2 mm
 - x. A peripheral iridectomy is performed to prevent blockage of the internal ostium by the peripheral iris
- xi. The superficial sclera flap is sutured with interrupted 10-0 nylon so that it is apposed lightly to the underlying bed

- xii. If necessary, AC can be reformed by injecting BSS through the paracentesis with a Rycroft cannula.
- xiii. The conjunctival flap is sutured with 8-0 vicryl
- xiv. At the completion of surgery, one drop of 1% atropine eye drop is instilled and a mixture of betamethasone and gentamicin (0.8 ml gentamycin, 0.3 ml betamethasone) is injected inferiorly under the conjunctiva

13. What are the structures removed in trabeculectomy?

From outside to inside:

- i. Block of scleral tissue
- ii. Schlemm's canal
- iii. Trabecular meshwork
- iv. Schwalbe's line
- v. Block of peripheral cornea
- vi. Iris.

(Tenon's removal is optional. Some surgeons prefer to remove it, as it is source for fibroblasts).

14. What are the advantages of fornix based flap?

- i. Easier to create
- ii. Good surgical exposure
- iii. Easier to identify surgical landmarks
- iv. Avoids postconjunctival scarring.

15. What are the disadvantages of fornix based flap?

- i. Harder to excise Tenon's tissue
- ii. Spontaneous aqueous leak at limbus in early postoperative period
- iii. Caution when doing argon laser lysis of sclera flap sutures subconjunctival 5-FU injections and digital pressure in the early postoperative period
- iv. Late postoperative IOP not as low as limbus based flap.

16. What are the advantages of limbus based flap?

- i. Easier to excise Tenon's tissue
- ii. Argon laser lysis of sclera flap sutures, subconjunctival 5-FU injections and digital pressure can be done with more safety in the early postoperative period
- iii. Late postoperative IOP lower

17. What are the disadvantages of limbus based flap?

- i. Anterior dissection of the conjunctival flap is difficult as incision in conjunctiva is made posterior to the fornix
- ii. Poor surgical exposure
- iii. More conjunctival manipulation.

18. Which are more preferred limbus/fornix based flaps?

Studies comparing fornix—based on limbus based trabeculectomies have demonstrated equivalent success in intraocular pressure control both with and without antimetabolites.

19. What is the problem with sclerostomy at 12 o'clock?

Bleeding from perforating branch of an anterior ciliary vessel that passes through the sclera to enter the ciliary body 2–4 mm from the limbus.

20. What are the preferred sites of sclerostomy for limbus and fornix based flap?

Limbus based—superotemporal quadrant as conjunctival incision can be made farther back in the fornix.

Fornix based—superonasal quadrant is adequate.

21. What is the purpose of a corneal incision?

Provides an entry for fluid into the AC at any stage of the operation.

22. What needles can one use for the corneal incision?

A dull needle. Because the top of a sharp needle will get caught in the corneal stroma.

23. What is the disadvantage of bridle suture under the superior rectus tendon?

Subconjunctival hemorrhage may occur.

24. What are the reasons for doing an iridectomy with trabeculectomy?

- i. To prevent iris incarceration in the sclerostomy with blockage of aqueous outflow if it shallows postoperatively.
- ii. To prevent pupillary block if posterior synechiae or a pupillary membrane develops secondary to postoperative intraocular inflammation.

25. What should be the size of iridectomy?

It should be basal and wider than the opening in the anterior chamber so that iris tissue does not block the opening.

26. When should the sclera flap be sutured more tightly?

- i. Eyes with primary angle closure glaucoma and those with a history of malignant glaucoma
- ii. Aphakic/highly myopic eyes prone to choroidal hemorrhage
- iii. Nanophthalmic eye and eyes with elevated episcleral venous pressure prone to suprachoroidal infusion and flat anterior chamber.

27. Why should a tenonectomy be done?

- i. Improves visibility of the nylon sutures in the postoperative period.
- ii. Partially determines the effectiveness of suture lysis, which determines the final postoperative pressure.

28. What should be used to reform the AC?

Usually done with balanced salt solution

Healon (sodium hyaluronate) can maintain anterior chamber depth, prevent choroidal effusion or suprachoroidal hemorrhage, decrease the rate of postoperative hyphaema, and delay scarring of the bleb. However, IOP may be higher in the early postoperative period.

29. Why is hemostasis essential in trabeculectomy surgery?

Because blood in the anterior chamber under the conjunctival flap can produce scarring of the bleb and cause failure of filtration.

30. How can it be prevented?

- i. The internal sclerostomy is made as far anteriorly as possible
- ii. Ensure effective hemostasis by proper cautery during the operation, over cautery should not be done as scleral flap will be thin.

31. What should be the postoperative evaluation of the eye?

- i. Extent of height of the bleb
- ii. Presence/absence of microcysts
- iii. Presence/absence of aqueous leak
- iv. Visibility of sclera flap sutures through overlaying conjunctival flap
- v. IOP
- vi. Clarity of cornea
- vii. AC depth
- viii. AC inflammation
- ix. Hyphema
- x. Choroidal detachment/suprachoroidal hemorrhage
- xi. Optic disk and macular appearance.

32. What is the role of atropine 1% scopolamine 0.25% postoperative?

By paralyzing the ciliary muscles they:

- i. Tighten the zonular lens – iris diaphragm – maximally deepening the anterior chamber
- ii. Maintain blood aqueous barrier
- iii. Relief from ciliary spasm
- iv. Dilate the pupil
- v. Prevent the formation of posterior synechiae.

33. What are the factors contributing to poor prognosis in filtering surgery?

- i. Age < 40 years of age
- ii. Previous failed filter
- iii. Aphakia/pseudophakia
- iv. Neovascular glaucoma
- v. Active uveitis
- vi. Congenital glaucoma
- vii. Congenital disease, e.g. Steven-Johnson, ocular pemphigoid.

- viii. Previous penetrating keratoplasty
- ix. Previous scleral buckle for retinal reattachment
- x. Previous topical medications
- xi. Chronic conjunctival inflammation
- xii. Previous conjunctival surgery.

34. What is the most common problem after trabeculectomy?

Shallowing of the AC postoperatively.

35. What are the main causes of a shallow AC for trabeculectomy?

Shallow AC can be associated with:

i. Hypotony:

- a. Wound leak
- b. Excessive filtration
- c. Serous choroidal detachment

ii. Raised IOP:

- a. Malignant glaucoma
- b. Incomplete peripheral iridectomy with pupillary block
- c. Delayed suprachoroidal hemorrhage.

36. What are the characteristics and treatment of wound leak?

Characteristics:

- i. Soft eye
- ii. Poor bleb
- iii. Positive Seidel's test

Treatment:

- i. Immediate pressure dressing
- ii. Simmons scleral shell tamponade
- iii. Therapeutic soft contact lenses
- iv. Cyanoacrylate tissue adhesive covered with collagen shield.

If the defect is large, suturing of the defect, construction of new conjunctival flap created posterior to original flap or a conjunctival autograft can be considered.

37. What are the characteristics and treatment of excessive filtration?

Characteristics:

- i. Very low IOP
- ii. A good bleb
- iii. A negative Seidel's test
- iv. Choroidal detachment may be present

Treatment:

- i. First step is firm patching
- ii. Simmons scleral shell
- iii. Therapeutic soft contact lenses
- iv. Aqueous suppressants (to promote spontaneous healing by temporarily reducing aqueous flow through the fistula)

- v. Atropine (to prevent pupillary block)
- vi. Steroids

Surgical: Reformation of the anterior chamber with air, sodium hyaluronate or SF6 and drainage of choroidal detachment if they are very deep. Scleral flap and conjunctiva are resutured.

38. What are the characteristic features, cause and treatment of ciliary block glaucoma?

Features:

- i. Hard eye
- ii. No bleb
- iii. Negative Seidel's test

Cause:

- Blockage of aqueous flow at the secreting portion of the ciliary body, so that aqueous is forced backwards into the vitreous

Treatment:

- i. Strong topical mydriatics
- ii. If this fails, osmotic agents – IV mannitol
- iii. If osmotic agent fails, the anterior hyaloid phase is disrupted through a patent iridectomy with an Nd:YAG laser.
- iv. Needling of aqueous pockets in vitreous
- v. Removal of aqueous pockets from vitreous through sclerostomy and formation of anterior chamber by air through paracentesis
- vi. If laser therapy fails, an anterior vitrectomy via the pars plana should be performed with a vitreous cutter and the entrapped fluid removed.

39. What are the complications of postoperative shallowing of the AC?

- i. Peripheral anterior synechiae
- ii. Corneal endothelial damage
- iii. Cataract.

40. What are the causes of failure of filtration?

A. Intraocular factors:

- i. Obstruction of fistula by clot, iris, ciliary body, lens, vitreous
- ii. Bleb failure
- iii. Poor surgical techniques which prevent exit of aqueous from the anterior chamber

B. Extraocular factors:

- i. Subconjunctival fibrosis
- ii. Individual racial and genetic factors.

41. What is the most common cause for bleb failure?

Subconjunctival fibrosis.

42. What is the management of failure of filtration?

Two causes for failure of filtration:

- i. Obstruction of fistula by iris/ciliary body/lens or vitreous
- ii. Failing filtering bleb

If there is obstruction:

- i. Low energy argon laser therapy can be done surrounding the obstruction
- ii. Internal bleb revision

If failing bleb:

- i. Increase the steroids to hourly dosing
- ii. Digital pressure
- iii. Argon laser suturolysin: 50 μ spot size, 0.02–0.1 sec, 250–1000 mW power.
- iv. If fibrin or clot is obstructing, intracameral tissue plasminogen activator (6–12.5 μ g)
- v. Restart antiglaucoma medications
- vi. Repeat filtering procedure with antimetabolites or drainage implants.

43. How can the success rate of trabeculectomy be improved?

1. Preoperative techniques:

- i. Treat surface infections
- ii. Discontinue use of pilocarpine, aqueous suppressants, carbonic anhydrase inhibitor and aspirin.

2. Intraoperative techniques:

- i. Constriction of pupil
- ii. Prevent conjunctival button hole or scleral flap disinsertion
- iii. Internal ostium should be 1.5 x 2 mm. Iridectomy should be larger than this ostium to prevent blockage
- iv. Tight wound closure.

3. Postoperative techniques:

By the use of antimetabolites which inhibit the wound healing.

Antimetabolites used are:

- i. Corticosteroids
- ii. 5-fluorouracil
- iii. Mitomycin C
- iv. Suramin
- v. Beta radiation
- vi. Tissue plasminogen activator
- vii. Gamma interferon
- viii. Calcium ionophores.

44. What are the complications of antimetabolites?

Complications are more with MMC than 5-FU.

Most important complications are:

- i. Early or late hypotony
- ii. Bleb leak
- iii. Bleb related infection

Others are:

Lids:

- i. Punctal occlusion (more with 5-FU)
- ii. Cicatricial ectropion

Conjunctiva:

- i. Wound and suture track leaks
- ii. Disintegration of vicryl sutures

Cornea:

- i. Erosion
- ii. Ulcer

Endothelial toxicity is common with mitomycin and epithelial toxicity is common with 5-FU

- i. Pupillary block
- ii. Cataracts
- iii. Hypotonous maculopathy
- iv. Choroidal hemorrhage
- v. Malignant glaucoma.

45. What are the advantages of argon laser suture lysis?

- i. Scleral flap can be closed tightly intraoperatively
- ii. Decreases hypotony
- iii. Decreases choroidal separation
- iv. Decreases suprachoroidal hemorrhage
- v. Decreases the hospital stay.

46. What is the role of aqueous humor in wound modulation?

It decreases stimulation of fibroblasts as aqueous humor contains lots of factors to inhibit active inflammation. The bleb is formed permanently without fibrosis.

47. What is the role of postoperative digital pressure?

- i. Encourages flow of fluid through the sclerostomy
- ii. Expands the filtering bleb
- iii. Prevents anatomic obstructions to filtration from becoming unalterable.

48. When should digital pressure be applied?

Rather than waiting for a bleb to fail, if the IOP rises above 12 mm Hg or if the target pressure is not achieved, digital pressure should be applied.

49. What are the problems due to digital pressure?

- i. Small subconjunctival hemorrhages
- ii. Hyphema
- iii. Rupture of a filtering wound
- iv. Dehiscence of an incisional wound.

50. What are the complications of trabeculectomy?

- i. Intraoperative
- ii. Early postoperative
- iii. Late postoperative

I. *Intraoperative*

- i. Conjunctival buttonhole/perforation
- ii. Amputation of sclera flap
- iii. Flap related—Thick, thin, irregular and buttonholing
- iv. Hemorrhage
- v. Damage of lens
- vi. Vitreous loss
- vii. Choroidal effusion
- viii. Cyclodialysis cleft
- ix. Malignant glaucoma

II. *Early postoperative*

- A. Hypotony and flat AC:
 - i. Conjunctival defect
 - ii. Excessive filtration
 - iii. Serous choroidal detachment
- B. Hypotony and formed AC:
 - i. Hypotony maculopathy
- C. Raised IOP and flat AC:
 - i. Delayed suprachoroidal hemorrhage
 - ii. Malignant glaucoma
 - iii. Incomplete PI with pupillary block
- D. Raised IOP with deep AC:
 - i. Obstruction of fistula
 - ii. Failing bleb
- E. Uveitis
- F. Hyphema
- G. Dellen
- H. Loss of central vision
- I. Ocular decompression retinopathy

III. *Late postoperative*

- i. Bleb infection/endophthalmitis
- ii. Cataract
- iii. Dissection of filtering bleb into cornea
- iv. Leaking filtering bleb
- v. Cyst of Tenon's capsule
- vi. Hyphema
- vii. Pupillary membrane
- viii. Corneal edema
- ix. Failure of filtration
- x. Malignant glaucoma
- xi. Upper eyelid retraction

- xii. Scleral staphyloma
- xiii. Sympathetic ophthalmia.

51. What are the methods for repairing a conjunctival buttonhole?

- i. Small pinpoint leaks can be sealed with cyanoacrylate glues or fibrin glues
- ii. Direct microsurgical repair.
- iii. Wing suture technique
- iv. Glaucoma (Simmond) shell technique
- v. Purse string suture.

52. What care should be taken during trabeculectomy surgery in aphakic/highly myopic eyes?

Such eyes are hypotonous and can develop intra/suprachoroidal hemorrhage.

53. How can a leaking filtering bleb be detected?

Many can be detected with 0.25% fluorescein; subtle leaks are seen with 2% fluorescein.

54. How is a leaking bleb managed?

- i. If the leak is minimal, chamber is of good depth, bleb is pale and elevated, then conservative treatment is done.
- ii. Aqueous flow with blockers and carbonic anhydrase inhibitors
- iii. Topical antibiotic – gentamicin which irritates the conjunctiva and facilitates healing of the conjunctival defect
- iv. Patching of the eye to lid movement
- v. If associated with flat AC, glaucoma shells
- vi. If not effective, then surgical repair is done.

55. What is the earliest evidence of a bleb infection?

Mild conjunctival hyperemia around the filtering bleb is the first sign. If treatment is delayed, there is a risk of endophthalmitis.

56. What is the treatment of bleb infection?

- i. Initial treatment is empirical
- ii. Topical antibiotics frequently
- iii. Topical steroids 12–24 hours after starting antibiotics.

57. What are the common organisms involved in bleb related endophthalmitis?

- i. *Haemophilus influenzae*
- ii. *Staphylococcus*
- iii. *Streptococcus*.

58. What is the treatment of Tenon's cyst?

- i. Usually resolve spontaneously within 2–4 months
- ii. However medical therapy may be needed to control IOP during this time.

59. How are corneal dellen formed and what is the treatment?

Localized disruption of the precorneal tear film → corneal dehydration causes stromal thinning and dellen formation

- i. Usually occur in the horizontal plane within the lid fissure.
- ii. Treatment—Artificial tears and patching

If ineffective, steroid drops are decreased.

60. Why is trabeculectomy more successful in older patients?

- i. Atrophic Tenon's capsule
- ii. Decreased capacity for fibroblastic proliferation.

61. What are the indicators for combined glaucoma and cataract surgery?

May be considered in patients with visually significant cataracts and:

- i. Inadequate control of IOP
- ii. Medication intolerance/poor compliance
- iii. Advanced glaucoma
- iv. Eyes requiring epinephrine compound
- v. Marginally functioning filter.

62. What are the advantages of combined cataract surgery?

- i. Earlier visual rehabilitation owing to cataract extraction
- ii. Reduces risk of early postoperative IOP spikes which is detrimental in eyes with severely excavated ONH
- iii. A one time single intervention eliminates need for further surgery
- iv. Patient compliance is better.

63. What are the disadvantages of combined approach?

- i. Long term IOP control seems questionable owing to loss of bleb function from enhanced episcleral scarring.
- ii. Increased incidence of postoperative complications hyphema, uveitis, shallow chambers, hypotony.

64. What are the advantages of 2 stage procedure over combined procedure?

More decrease in intraocular pressure (IOP) as plain trabeculectomy decreases IOP by 41%.

Lesser risk of postoperative complication like hyphema, inflammation, hypotony and shallow anterior chamber.

65. What are the antimetabolites used routinely?

MMC and 5-FU.

Dosage: MMC: 0.2 to 0.5 mg/ml for 1–5 min

5-FU: 30 mg/ml for 5 min, subconjunctival dose is 5 mg.

66. What are the indications for adjuvant antimetabolite therapy?**High risk factors:**

- i. Neovascular glaucoma
- ii. Previous failed trabeculectomy or artificial filtering devices
- iii. Certain secondary glaucomas (e.g. inflammatory, post traumatic angle recession, iridocorneal endothelial syndrome)

Intermediate risk factors:

- i. Patients on topical antiglaucoma medications (sympathomimetics) for 3 years
- ii. Previous conjunctival surgery
- iii. Previous cataract surgery

Low risk factors:

- i. Black patients
- ii. Patients under age of 40 years

67. Mechanism of action of 5-FU.

It inhibits DNA synthesis and is active on the 'S' phase of the cell cycle. Fibroblastic proliferation is inhibited, but fibroblastic attachment and migration are unaffected.

68. Mechanism of action of MMC.

It is an alkylating agent which selectively inhibits DNA replication, mitosis and protein synthesis. The drug inhibits proliferation of fibroblasts, suppresses vascular ingrowth and is much more potent than 5-FU.

69. Where are the antimetabolites placed?

They are placed in the sub-Tenon's space, as the most common cause for failure is subconjunctival fibrosis.

70. Why does previous long term use of medications is associated with failure of trabeculectomy?

- i. Increased fibroblastic proliferation in conjunctiva
- ii. Reduced goblet cells
- iii. Infiltration of conjunctiva with inflammatory cells.

71. What are the advantages of Releasable sutures and laser suturolysis?

- i. Can leave eye with firm pressure
- ii. Can protect eye against low pressure and complications associated with low pressure
- iii. Can titrate eye pressure postoperatively.

4.19. MODULATION OF WOUND HEALING IN GLAUCOMA FILTERING SURGERY

1. What are the pharmacological techniques that interfere with wound healing to maintain success of trabeculectomy?

- i. The preoperative and postoperative administration of glucocorticosteroids to control inflammation and thereby scarring
- ii. The local intraoperative and postoperative administration of antineoplastic agents such as mitomycin C and 5-fluorouracil to reduce fibroblast proliferation
- ii. The use of agents to interfere with the synthesis of normal collagen such as β -aminopropionitrile and penicillamine.

2. What is the role of corticosteroids in glaucoma filtering surgeries?

- i. They control inflammation and immune response at multiple points.
- ii. Anti-inflammatory mechanisms of corticosteroids include constriction of blood vessels, stabilization of lysosomes, inhibition of degranulation, impairment of leucocyte chemotaxis, reduction of lymphocyte proliferation, suppression of fibroplasia, inhibition of phospholipase A2 production, which subsequently prevents cyclooxygenase and lipoxygenase from producing prostaglandins, prostacyclins, thromboxanes and leukotrienes.

3. What is the role of NSAIDs in glaucoma filtering surgeries?

- i. NSAIDs are heterogeneous group of agents that inhibit the enzyme cyclooxygenase from converting arachidonic acid into prostaglandins and thromboxanes.
- ii. They have been demonstrated to inhibit proliferation of human Tenon fibroblasts in culture.

4. What is the role of mitomycin C in glaucoma filtering surgeries?

- i. Mitomycin C is an alkylating agent isolated from the fermentation filtrate of *Streptomyces caespitosus*.
- ii. It inhibits DNA dependent RNA synthesis and binds to cellular DNA sites on cell membranes, forming free radicals and chelating metal ions.
- iii. Like 5-FU, mitomycin inhibits fibroblast proliferation, but unlike 5-FU, it affects cells in all phases.

5. Describe the methods of administration of mitomycin C.

- i. After outlining and partially dissecting the scleral flap to ensure integrity of the scleral tissues, the conjunctiva is inspected to rule out the presence of any tears or button holes.
- ii. An amputated tip of 4.5 mm \times 4.5 mm sized methylcellulose sponge soaked in a 0.2 to 0.5 mg/ml solution of MMC is then placed between the conjunctiva/Tenon's capsule and episclera for 1 to 5 minutes.

- iii. During this time, the edges of the conjunctival flap are pulled over the sponge so that the tissue edges are not exposed to the drug.
- iv. The area is then rinsed with copious amounts of balanced salt solution.
- v. A relatively tight scleral flap is prudent to reduce the likelihood of prolonged postoperative hypotony.

6. What are the side effects of MMC?

Irritation

- i. Lacrimation
- ii. Hyperemia
- iii. Photophobia
- iv. Ocular pain

Eyelids and conjunctiva

- i. Allergic or irritative reactions
- ii. Erythema
- iii. Conjunctivitis
- iv. Avascularity
- v. Hyperemia
- vi. Blepharitis
- vii. Granuloma
- viii. Symblepharon

Cornea

- i. Corneal melting
- ii. Edema
- iii. Erosion
- iv. Crystalline epithelial deposits
- v. Endothelial decompensation
- vi. Punctate keratitis
- vii. Delayed wound healing
- viii. Perforation
- ix. Recurrence of herpes simplex

Sclera

- i. Scleral melting (necrotizing scleritis)
- ii. Delayed wound healing
- iii. Avascularity
- iv. Erosion
- v. Perforation
- vi. Calcium deposits

Uvea

- i. Iridocyclitis
- ii. Hyperemia
- iii. Hypopigmentation of iris

Glaucoma

Punctal occlusion

Hypotony

7. What is the role of 5-fluorouracil in glaucoma filtering surgeries?

- i. 5-fluorouracil is a pyrimidine analogue
- ii. It is a folic acid antagonist.
- iii. It is active on the 'S' phase (synthesis phase) of the cell cycle
- iv. Mechanism of action is to prevent the reduction of folic acid to tetrahydrofolic acid by noncompetitive enzyme inhibition. This results in inhibition of DNA and RNA synthesis and eventual cell death.
- v. Inhibition of fibroblast proliferation has been regarded as the primary mechanism by which 5-FU enhances and maintains bleb function.

8. Describe the methods of administration of 5-FU.

It can be given as subconjunctival injections or as an intraoperative application.

1. Subconjunctival injection of 5-FU

- i. Subconjunctival injection of 5-FU may be administered in an undiluted concentration (50 mg/ml), although many prefer to dilute it to 10 mg/ml.

2. Dilution

- i. Five milligram of the agent is drawn into a tuberculin syringe, after which the tuberculin needle is replaced with a 0.5 inch 30 gauge needle.
- ii. After administration of a topical anesthetic, at least 2 cotton-tipped applicators soaked in 4% topical lidocaine are used to swab and further anesthetize the tissues at the proposed injection site.
- iii. The injection is then given 90° to 180° from the trabeculectomy site.

3. Dosage

- i. Twice daily for 1 week and once daily for the second week for a total of 21 injections (105 mg).

9. What are the side effects of subconjunctival or intradermal 5-FU?

Irritation

- i. Lacrimation
- ii. Ocular pain
- iii. Edema
- iv. Burning sensation

Eyelids or conjunctiva

- i. Cicatricial ectropion
- ii. Allergic reactions
- iii. Erythema
- iv. Hyperpigmentation
- v. Keratinization
- vi. Urticaria
- vii. Subconjunctival hemorrhages
- viii. Periorbital edema

Cornea

- i. Superficial punctate keratitis
- ii. Ulceration
- iii. Scarring stromal
- iv. Keratinized plaques
- v. Delayed wound healing
- vi. Endothelial damage.

10. How to choose an agent: 5-FU versus MMC?

- i. Currently intraoperative 5-FU with supplementary postoperative 5% FU injections are used in most primary filtering surgeries.
- ii. 5% FU is also used in selected higher risk case, particularly those with MMC complications in a previous surgery or those at risk for hypotonous maculopathy.
- iii. MMC is used in most high risk cases including aphakic or pseudophakic eyes, eyes with previous filtration failure surgery, eyes with a history of anterior segment neovascularization, and eyes with uveitis.
- iv. MMC is also used in selected cases of primary filtering surgery (e.g. when trabeculectomy with 5-FU has failed in the fellow eye).

11. What is the latest advancement in glaucoma filtering surgery?

Photodynamic therapy with diffuse blue light coupled with a photosensitizing agent to kill fibroblasts may be another way to control the surface area of treatment and modulate healing. It will be important to determine the effect of these agents on the overlying epithelium, because differentiated stable epithelium may have a suppressive effect on fibroblasts in the wound.

12. What are the indications for antimetabolites in glaucoma filtering surgery?**1. Patient factors:**

- a. Young patients
- b. Previous failed trabeculectomy
- c. Previous conjunctival surgery (e.g. pterygium surgery)

2. Ocular factors:

- a. Secondary glaucomas (neovascular, uveitic, traumatic and pseudophakic glaucoma)
- b. Congenital/pediatric glaucoma

13. What are the measures to be taken to prevent antimetabolite toxicity?

- i. Thorough irrigation after the prescribed time of applications
- ii. Water tight wound closure
- iii. Careful dissection to prevent button hole formation.

4.20. GLAUCOMA DRAINAGE DEVICES (GDD)

1. Define glaucoma drainage devices (aqueous shunt devices).

Consists of an alloplastic tube leading to a large equatorial reservoir that drains aqueous humor from the anterior chamber.

2. Define setons.

Nonlumened devices in which aqueous flows along the surface of the implant through the subconjunctival space.

3. Define shunts.

Hollow tubular structure that allows bidirectional flow.

4. Define valves.

Allows unidirectional flow which needs an activating pressure to open it.

5. What are the common features of all GDDs?

- i. Manufacturing drainage tube and explant portions of the devices from materials to which fibroblasts cannot firmly adhere.
- ii. Equatorial placement of explant portion of the device.
- iii. Similar diameter of all drainage tubes.
- iv. Ridge along edge of the explant plate where drainage tube inserts ensures.

Physical separation of
enveloping capsule from
posterior tube orifice

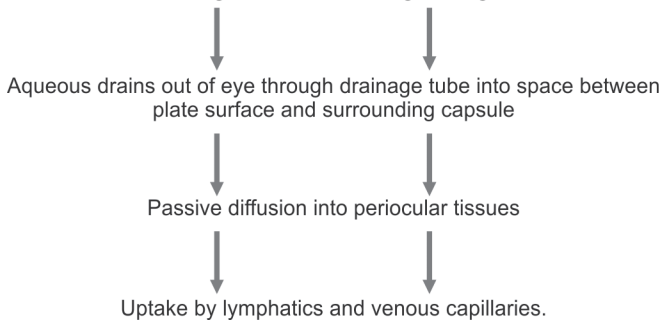
Directs the flow
onto explant's
upper surface



Preventing occlusion.

6. What is the principle of GDD?

Explant portion of device stimulates a fibrous enveloping capsule, which becomes the delimiting wall of the resulting filtering bleb.



7. What are the factors which decide hydraulic conductivity of GDD?

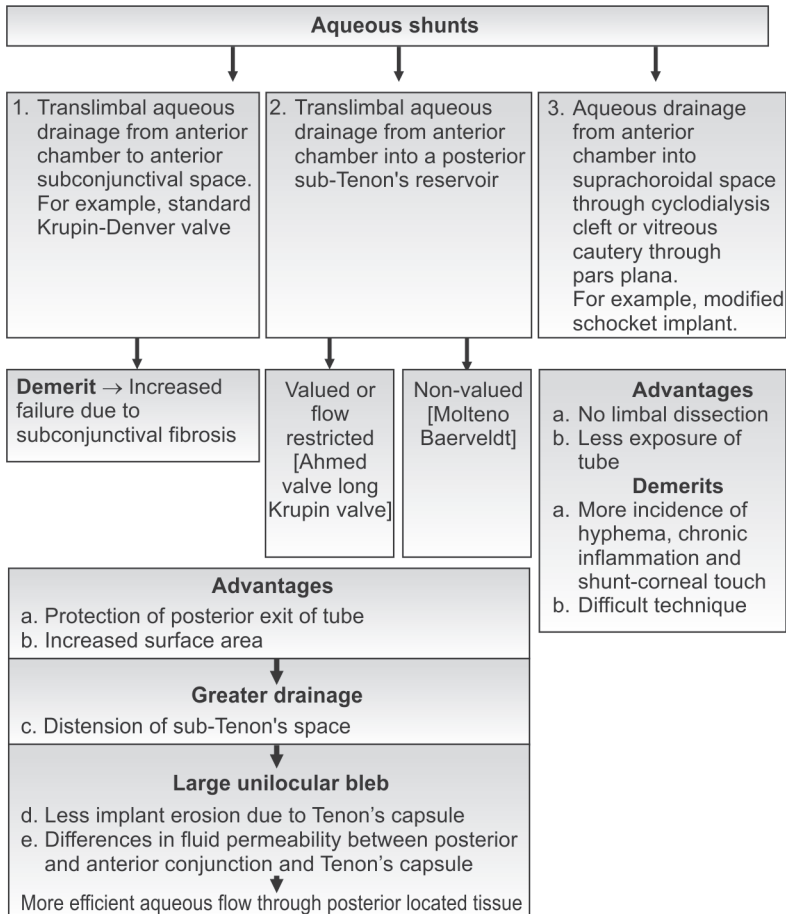
Drainage capacity of bleb is directly proportional to surface area of capsule around explants. Resistance of capsule to flow is directly proportional to its thickness.

8. What are the indications of GDD?

A. All refractory glaucomas like:

- i. Uveitic glaucoma
- ii. Neovascular glaucoma
- iii. Congenital glaucoma
- iv. Refractory juvenile glaucoma
- v. Multiple failed trabeculectomy
- vi. Extensive conjunctival scarring
- vii. Post PKP
- viii. Aniridia
- ix. Posttraumatic glaucoma

B. Failed primary glaucomas

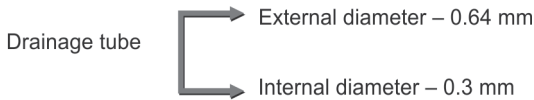

9. Describe Molteno implant.

- i. First implant with a nonvalved device
- ii. Material—polypropylene
- iii. Consists of a circular plate with a drainage tube
- iv. Outer diameter of drainage tube—0.63 mm
- v. Inner diameter of drainage tube—0.3 mm
- vi. Types—Single plate, double plate and triple plate.

10. Describe Baerveldt implant.

- i. Nonvalved
- ii. Material—silicone



Types: Single plate, double plate

11. Advantages of Baerveldt GDD.

- Ease of implantation
 - Larger surface area
- ↓
- Greater drainage
- ↓
- Flexible silicone composition facilitates confirmation to globe
 - Presence of fenestration hole in explant
- ↓
- Allows fibrous tissue ingrowth
- ↓
- Helps to reduce bleb height
- ↓
- Less risk of postoperative diplopia
- } Compared to molteno implant

12. What is the mechanism of action of Ahmed glaucoma valve?

- i. Oval shaped polypropylene plate 184 mm² (double plate – 364 mm²) surface area is connected to a silicone drainage tube via 2 layers of silicone elastomer membrane that functions as a one way valve by venturi effect (Bernoulli's principle)
- ii. Goal of keeping IOP between 8–10 mm Hg
- iii. Venturi design (Bernoulli's principle)

The tension on the silicone membranes is designed to only allow outflow when the IOP is above 8–10 mm Hg. When the initial pressure in the anterior chamber is high, the valve fully opens. As the pressure is reduced, the membrane opening automatically reduces in size, diminishing the flow.

13. Describe the optimized glaucoma pressure regulator.

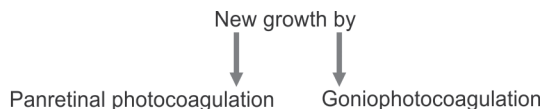Silicone tube attached to a polymethyl methacrylate matrix of conductive resistors that regulate the flow of aqueous through capillary action.

14. Preoperative evaluation in a case of glaucoma drainage devices.

- i. Potential for useful vision is a must
- ii. Preoperative IOP
- iii. Upper lid position
- iv. Scleral exposure
- v. Tear film stability
- vi. Blepharitis (risk of late postoperative infection)
- vii. Corneal clarity— especially peripheral cornea
For intraoperative
Confirmation of tube location
- viii. Eyes with PCIOL
 - Shallow AC
 - Post PKP eyes
 - Endothelial cell function

All the above-mentioned risk factors are the indications for glaucoma drainage device with pars plana tube insertion into vitreous cavity

- ix. Presence of vitreous strands in anterior chamber → may occlude the tube tip.
- x. Cataract—for concurrent cataract surgery and glaucoma drainage device
- xi. Gonioscopy
Assess PAS → areas to be avoided for tube insertion (peripheral anterior synechiae)
Neovascularisation of angle
Preoperative treat to halt the

**15. What are the drugs to be stopped preoperatively?**

- i. Pilocarpine or echothiophate
(To reduce postoperative inflammation)
Continue all other glaucoma drugs till surgery
- ii. Warfarin.

16. Types of surgical techniques for GDD implantation.

- | | |
|---|--|
| <p>i. Limbal based conjunctival flap
Two layer closure securing Tenon's capsule and conjunctiva with separate running layers of absorbable sutures</p> | <p>Fornix based conjunctival flap
If tissue coverage over the device is adequate
↓
Suturing only at lateral corners of flap</p> |
|---|--|
- ii. One stage installation**
- i. One stage complete surgical installation with immediate function, done with devices that have flow restrictors or valves
- iii. Two stage installation**
- i. Temporary ligature of tube on nonvalved device for 2–3 weeks
 - ii. Time for development of capsule and acceptable resistance to outflow.

17. What are the types of temporary ligature sutures?

- i. Rip cord—intraluminal occluding sutures left beneath the conjunctiva for pulling (4-0 chromic catgut)
- ii. Absorbable 8-0 polyglactin or 10-0 prolene tied around the tube (Released by argon laser suturolysis)
- iii. 5-0 nylon tied to side of tube and to an adjacent occluding structure like a spacer which is removed after 2–3 weeks.

18. What is the cause of hypotony in both single and double stage techniques?

Due to leakage around the surface of the tube, where it penetrates the eye wall.

19. What is the difference between glaucoma drainage device bleb and trabeculectomy bleb?

Features of GDD bleb:

- i. More posterior filtering bleb
- ii. More consistently organized surrounding capsule which is distinct and separable from overlying Tenon's capsule
- iii. Absence of conjunctival microcysts as seen in trabeculectomy.

20. What is the preferred positioning of GDD?

- i. Superotemporal quadrant
- ii. Centered at the equator and equally spaced between adjacent rectus muscles
- iii. Anterior edge of explant
↓
8–10 mm posterior to corneoscleral junction
- iv. Explant plates are sutured to episclera
↓
Complication encountered
↓
Perforation of sclera.

21. How to manage/identify perforation of sclera?

- i. Identification → Gush of vitreous gel is seen
- ii. Management → Apply cryotherapy to the area
Under direct observation by indirect ophthalmoscope.

22. When do you suture the explant to the avascular insertion of superior rectus (instead of episclera)?

- i. Staphyloma
- ii. Quiescent scleritis.

23. What are the complications in superonasal placement of GDD?

- i. Vertical strabismus—Pseudo-Brown's syndrome
- ii. Impact on optic nerve.

24. What are the instances where the GDD can migrate?

a. Inadequate suturing



Posterior migration of explant



Extrusion of tube from anterior chamber

b. Postoperative hypotony



Drainage tube migrates anteriorly and impacts on cornea, lens or iris.

25. Where do you place the 2nd plate in an explant with 2 plates?

The second plate and its interconnecting tube placed either above or below superior rectus muscle and attached by suturing in a similar manner to the first plate.

26. How to install the drainage tube?

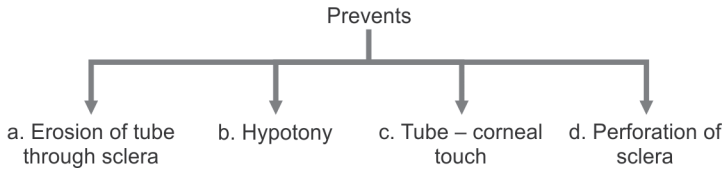
Anterior chamber installation	Pars plana installation
<ul style="list-style-type: none"> • Tube shortened to the appropriate length with a sharp level to facilitate passage through a 23 gauge needle tract • Tip → Beveled up surface • Site of insertion ↓ Posterior edge of blue limbus • Preparation of site of insertion ↓ Use wet field cautery • 1.5 – 2 mm of tube should extend through the endothelium parallel to the plane of iris (prevents migration) 	<ul style="list-style-type: none"> • Indications <ol style="list-style-type: none"> a. Aphakia & PCIOL eyes b. Post PKP eyes c. Eyes with shallow anterior chamber d. Decreased endothelial cell function • Tip → Beveled down • Needle tract oriented perpendicularly to scleral surface, 3–4 mm posterior to limbus • Verify tube tip by direct visualization that it is free of vitreous • Precautions — <ol style="list-style-type: none"> 1. Complete pars plana vitrectomy ↓ 2. Clearance of vitreous base in the quadrant of tube insertion

27. What are the advantages of installation of drainage tube through 21 or 23 gauge needle tract compared to the traditional sclerectomy?

- i. Ensures tight fit
- ii. Prevents aqueous leak around the tube.

28. What are the advantages of scleral patch graft?

- a. Covering the portion of tube exposed to lid contact (usually 3–5 mm of tube)



29. How is the technique of scleral patch graft performed?

Full thickness scleral patch graft taken according to the size required.



Nonoccluding mattress suture is usually placed over the tube near its insertion.

30. What is the complication of scleral patch graft?

- i. Abrupt elevation of limbal conjunctiva



Corneal Dellen formation

- ii. Scleral melt

31. What is the role of intracameral hyaluronic acid (Healon)?

Reforming the anterior chamber with intracameral hyaluronic acid at the end of the procedure through a paracentesis entry helps in:

- i. Decreasing postoperative hypotony and flat anterior chamber
- ii. Intraoperative evaluation of tube position
- iii. Slows the process of aqueous drainage in the immediate postoperative period.

32. Compare valved and nonvalved GDD.

- i. Advantage of valved → Simple one step procedure
- ii. Advantages regarding clinical safety and efficacy not clear over a short term/long term follow-up appear to be equal.

33. What is the principle behind sizing of nonvalved devices?

- i. Larger devices → Younger, healthier eyes
- ii. Smaller devices → Older, sicker eyes.

34. How do you implant a modified schocket device?

Bent 18 gauge needle is inserted into a sharp buckle capsule incision



Segment of side perforated tubing fed into needle bore of 18 gauge needle and pulled into buckle capsule. (Segmented of side perforated tubing later becomes intracapsular portion)



A tube segment placed between buckle capsule and anterior chamber



Tight closure of buckle capsule incision



Anchoring suture of 10° prolene is placed to prevent tube from slipping.

35. What is the level of IOP reduction as compared to trabeculectomy?

Percentage of IOP reduction achieved in GDD is less compared to trabeculectomy.

36. What are the contraindicated postoperative medications?

Increases vascularization of bleb capsule

- i. Miotics
- ii. Alpha agonists

37. Complications of aqueous shunt surgery.**Intraoperative**

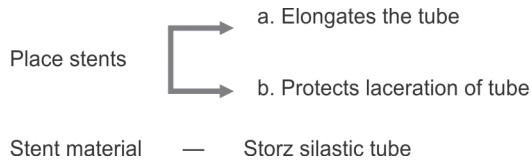
- i. Hyphema: Injury to iris root with tube insertion
- ii. Lens damage: Improper tube length or direction
- iii. Lens or corneal endothelial damage: Needle tip trauma
- iv. Scleral perforation and retinal tear; needle injury while suturing plate to globe
- v. Hypotony: Sclerotomy site too wide for tube, incomplete tube occlusion

Early postoperative

- i. Intraocular pressure elevation before occluding suture absorbs: Risk for nerves with advanced damage
- ii. Dellen: Elevated conjunctiva over patch graft causing poor tear lubrication
- iii. Hypotony: Excessive aqueous run off with flat anterior chamber and choroidal effusion
- iv. Intraocular inflammation: Marked in eyes with chronic uveitis
- v. Suprachoroidal hemorrhage: Postoperative hypotony and high preoperative IOP
- vi. Transient diplopia: Edema within the orbit and rectus muscles
- vii. Endophthalmitis: Direct intraoperative contamination
- viii. Aqueous misdirection: Initial postoperative hypotony and choroidal swelling

Late postoperative

- i. Cataract progression: With or without direct mechanical injury, prolonged hypotony
- ii. Chorioretinal folds: Prolonged hypotony
- iii. Chronic iritis: History of uveitis or neovascularization
- iv. Corneal edema and graft failure; with or without cornea touch
- v. Persistent elevated IOP after tube open; thick fibrous capsule
- vi. Hypotony maculopathy: Excessive aqueous fluid runoff
- vii. Inadequate IOP control with properly functioning Baerveldt glaucoma drainage device: Hypertensive phase
- viii. Motility disturbance, strabismus, diplopia: Bleb displacement of globe, muscle fibrosis
- ix. Patch graft melting: Tube or plate erosion associated with poor lid closure, dry eye
- x. Retinal detachment: Scleral perforation, underlying disease such as diabetic retinopathy
- xi. Tube occlusion; blood, fibrin, iris or vitreous
- xii. Tube migration: Poor fixation of plate to sclera
- xiii. Endophthalmitis: Associated with tube exposure.

38. How do you manage erosion of tube?**39. What are the phases of GDD surgery postoperatively?**

Hypertensive phase Hypotensive phase
 Transient \uparrow IOP
 in immediate postoperative

4.21. CYCLODESTRUCTIVE PROCEDURES

1. Classify cyclodestructive procedures.

Based on the destructive energy source

- i. Diathermy
- ii. β -irradiation
- iii. Electrolysis
- iv. Cryotherapy
- v. Laser photocoagulation
- vi. Therapeutic ultrasound
- vii. Microwave cyclodestruction

Based on the route by which the energy reaches the ciliary process

- i. Transscleral
- ii. Transpupillary
- iii. Intraocular

2. Describe the technique of penetrating cyclotherapy.

Penetration of sclera (with or without preparation of conjunctival flap)

Site: 2.5 mm to 5 mm from corneolimbus junction

1–1.5 mm electrode is used

Current – 40–45 mA

Duration – 10–20 second

One or two rows of lesions placed several mm apart for approximately 180°.

3. What is the mechanism of action in cyclotherapy?

- i. Cell death within the ciliary body
- ii. More posteriorly placed lesions create a draining fistula in the area of pars plana.

4. What are the demerits of diathermy?

- i. Low success rate
- ii. Hypotony
- iii. Phthisical eye.

5. What is the newer diathermy?

One pole diathermy unit.

6. Describe the mechanism of action of cyclocryotherapy.

Ability of ciliary process to produce aqueous humor is destroyed by two mechanisms

- i. Intracellular ice crystal formation
- ii. Ischemic necrosis

7. What is the additional effect of cyclocryotherapy other than ↓ IOP?

It also causes destruction of corneal nerves and thus causes relief of pain.

8. Describe the technique of cyclocryotherapy.**Instruments**

- i. Nitrous oxide or carbon dioxide gas cryosurgical units
- ii. Cryoprobe tips ranging from 1.5 to 4 mm. Commonly 2.5 mm is suggested for cyclocryotherapy.

Cryoprobe placement

- i. Placement of the anterior edge of probe, firmly on the sclera, 1 mm from corneolimbic junction temporally, inferiorly and nasally and 1 mm superiorly.

Number of cryoapplications

- i. 2–3 quadrants → 3–4 applications per quadrant
- ii. Rule of thumb → Treat less than 180° or 6 applications in each treatment session.

Freezing technique

- i. Temperature—60–80°C
- ii. Duration—60 seconds

Postoperative management

- i. Systemic analgesics
- ii. Topical corticosteroids—frequently
- iii. Cycloplegics
- iv. Preoperative glaucoma medications except miotics.

9. What is the minimum time interval between repeated cyclotherapy?

1 month.

10. What is the additional measure taken for proper cryoprobe placement over ciliary process in cases of distorted anatomic landmarks, e.g. buphthalmos?

Transillumination (for delineating the pars plicata).

11. List the complications of cyclocryotherapy.

- i. Transient rise of IOP
- ii. Uveitis
- iii. Pain
- iv. Hyphema
- v. Hypotony and sometimes phthisis—Best avoided by treating a limited area each time

- vi. Choroidal detachment
- vii. Intravitreal neovascularization causing vitreous hemorrhage.
- viii. Anterior segment ischemia
- ix. Lens subluxation
- x. Sympathetic ophthalmia

12. List the indications for cyclocryotherapy/transscleral photocoagulation.

- i. Relief for refractory ocular pain secondary to \uparrow IOP in blind eyes
- ii. Repeated failure of other glaucoma surgeries
- iii. Glaucoma following PKP
- iv. Chronic open-angle glaucoma in aphakia
- v. Congenital glaucoma
- vi. High risk cases in which medical and other glaucoma surgical procedures have failed or not felt to be feasible
- vii. Patient who requires urgent IOP reduction but who is too sick to undergo incisional surgery.

13. Describe the mechanism of action of transscleral cyclophotocoagulation.

- i. **Reduced aqueous production:** Due to damage of pars plicata due to direct destruction of ciliary epithelium and reduced vascular perfusion.
- ii. **Increased aqueous outflow:** Due to increased pars plana or transscleral outflow.

14. What are the types of lasers used in transcleral cyclophotocoagulation?

- i. Nd:YAG lasers (yttrium-aluminum-garnet): 1064 nm
- ii. Semiconductor diode lasers: 750–810 nm
- iii. Krypton lasers

15. What is the advantage of diode laser over Nd:YAG laser in cyclophotocoagulation?

- i. The energy needed to produce comparable lesions is less with the diode laser than that required with the Nd:YAG laser.
- ii. Primarily because of the smaller size and greater durability of diode lasers, transscleral diode cyclophotocoagulation is currently most commonly performed cyclodestructive procedure.
- iii. Transcleral diode cyclophotocoagulation has the advantage of being quick and easy to perform.

16. What are the advantages of semi-conductor diode lasers?

- i. Greater absorption by uveal melanin

- ii. Solid state construction with compact size (portable)
- iii. Low maintenance requirements

17. What are the types of cryoprobes?

Diameter	Indications
1 mm	— ICCE
2 mm	— Retinal cryotherapy
2.5–4 mm	— Cyclocryotherapy
> 4 mm	— Hammerhead probe – Treatment of malignant melanoma

18. Describe the preoperative preparation of the patient in laser cycloablation.

- i. Retrobulbar anesthesia usually preferred over peribulbar
- ii. Contralateral eye patched to prevent entry of stray laser light

19. What is the role of contact lens in Nd:YAG noncontact thermal mode?

- i. Maintains lid separation
- ii. Compress and blanch the conjunctiva. Allows more energy to reach ciliary body
- iii. Provide measurement from the limbus. (applying laser 0.5–1.5 mm behind limbus is optimum)
- iv. Reduces laser back scatter at the air-tissue interface
- v. Higher incidence of phthisis is observed when laser is applied with contact lens.

20. What is the protocol commonly followed for noncontact transscleral cyclophotocoagulation (Nd:YAG)?

- i. 30–40 evenly spaced lesions for 360°.
- ii. Approximately 8 applications per quadrant.
- iii. Spare the 3 and 9 o'clock positions from laser applications due to long posterior ciliary vessels underneath.

21. What is the minimum time interval before retreatment in transcleral laser cyclophotocoagulation?

- i. 1 month
- ii. 2/3rd of cases do not require retreatments.

22. In which condition is a contact Nd:YAG transscleral cyclophotocoagulation indicated over a noncontact laser.

- i. Pediatric patients with refractory glaucoma.

23. Describe complication of transscleral cyclophotocoagulation?

- i. Conjunctival hyperemia

- ii. Uveitis
- iii. Malignant glaucoma
- iv. Sympathetic ophthalmia
- v. Ocular hypotony

24. What are the measures taken to prevent full thickness sclerostomies?

- i. Use of well rounded, polished tips.
- ii. Prior to treatment inspect the probes to make sure they are free of mucus and other debris.
- iii. Constantly keep the eyeball moist

25. What are the factors that influence the variability of tissue response in contact delivery systems?

- i. Probe pressure
- ii. Probe diameter
- iii. Time of probe contact

26. What is the prerequisite for transpupillary cyclophotocoagulation?

- i. A sufficient number of ciliary processes (at least a quarter) must be visualized gonioscopically.

27. Describe the technique of transpupillary cyclophotocoagulation?

- i. Argon laser
- ii. Spot size – 100–200 μ
- iii. Duration – 0.1–0.2 sec
- iv. Energy level – 700–1000 mW
- v. Desired effect – Produce a white discoloration as well as a brown concave burn with pigment dispersion or gas bubbles
- vi. All the visible portions of ciliary processes are treated
- vii. 3–5 applications for each process
- viii. All visible processes treated upto a total of 180°.

28. What are the factors that decide the outcome of transpupillary cyclophotocoagulation?

- i. Number of ciliary processes that can be visualized and treated
- ii. Intensity of laser burns to each process
- iii. Angle at which ciliary processes are visualised gonioscopically.

29. What are different types of intraocular photocoagulation?

- i. With transpupillary visualization
- ii. With endoscopic visualization (argon or diode laser)

30. Describe the technique of therapeutic ultrasound?

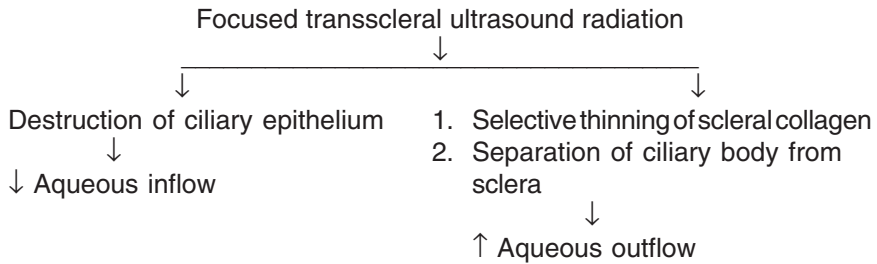
- i. Immersion applicator or contact ultrasound (contains a distensible rubber membrane that can be inflated)

- ii. 6–7 exposures of ultrasound delivered at an intensity level of 10 kW/cm² for 5 seconds each to scleral sites near the limbus.

31. What is transscleral microwave cyclodestruction?

Direct application of high frequency electromagnetic radiation over conjunctiva causes heat induced damage to the ciliary body and causes a decreased production of aqueous humor.

32. Describe the mechanism of action by which an ultrasound works in ↓ IOP.



5

Lens and Cataract

CHAPTER

1. What is the size of the adult human lens?

It measures 9 mm equatorially and 5 mm anteroposteriorly. It weighs approximately 255 mg.

2. What are the changes in the eye during accommodation?

- i. Contraction of the ciliary muscle
- ii. Decrease in ciliary ring diameter
- iii. Decrease in zonular tension
- iv. More spherical shape of the lens
- v. Decrease in lens equatorial diameter
- vi. Increased axial lens thickness
- vii. Steepening of the central anterior lens curvature
- viii. Increased lens dioptric power.

3. What is the level of amplitude of accommodation?

- i. Adolescents have 12–16D of accommodation
- ii. Adults at 40 have 4–8D
- iii. After 50, accommodation reduces to 2D.

4. What is lenticonus?

- i. It is a congenital, localized cone shape deformation of the anterior or posterior lens surface.
- ii. Anterior lenticonus is uncommon, bilateral and associated with Alport's syndrome.
- iii. Posterior lenticonus is more common, unilateral and axial.

5. What are the types of lens coloboma?

- i. **Primary coloboma:** Isolated wedge shaped defect or indentation
- ii. **Secondary coloboma:** Defect or indentation of the lens periphery caused by the lack of ciliary body or zonular development.

6. What is Mittendorf's dot?

It is a remnant of the posterior pupillary membrane of the tunica vasculosa lentis and is located inferonasal to the posterior pole of the lens.

7. What are the common causes of microspherophakia?

- i. Weil-Marchesani syndrome
- ii. Marfan's syndrome
- iii. Peter's anomaly
- iv. Alport's syndrome
- v. Lowe syndrome

8. What are the common causes of cataracts in children?**A. Bilateral cataracts:**

- i. Idiopathic
- ii. Hereditary cataracts
- iii. Maternal infections like rubella, CMV, varicella and syphilis
- iv. Ocular anomalies like aniridia and anterior segment dysgenesis syndrome

B. Unilateral cataracts:

- i. Idiopathic
- ii. Trauma
- iii. Persistent fetal vasculature
- iv. Posterior pole tumors.

9. What are the conditions which can cause poorer visual result following cataract surgery in children?

- i. Unilateral cataracts carry a poorer prognosis than bilateral cataracts
- ii. Patients with nystagmus
- iii. If adequate visual rehabilitation or treatment of amblyopia is not carried out.

10. What are the causes of ectopia lentis?

- i. Marfan's syndrome
- ii. Homocystinuria
- iii. Aniridia
- iv. Congenital glaucoma
- v. Trauma
- vi. Ehlers-Danlos syndrome
- vii. Sulfite oxidase deficiency
- viii. Hyperlysinemia
- ix. Ectopia lentis at papillae

11. What are the features of Marfan's syndrome?**Systemic:**

- i. Arachnodactyly
- ii. Long arm span
- iii. Chest deformities
- iv. Mitral valve prolapse
- v. Dilated aortic root
- vi. High arched palate

Ocular:

- i. Axial myopia
- ii. Hypoplasia of dilator pupillae (difficulty in dilatation)
- iii. Superotemporal subluxation of lens
- iv. Pupillary block glaucoma
- v. Retinal detachment.

12. How is the lens status in various syndromes?

- i. **Marfan's syndrome:** Superotemporal subluxation with the presence of zonules
- ii. **Homocystinuria:** Iblens subluxation inferiorly with absent zonules
- iii. **Weil-Marchesani:** Iblens subluxation inferiorly along with microspherophakia.

13. What are the drugs which can cause cataracts?

- i. Corticosteroids
- ii. Phenothiazines and other antipsychotics
- iii. Topical miotics
- iv. Amiodarone
- v. Statins

14. What is Vossius ring?

The imprinting of the pupillary ruff onto the anterior surface of the lens due to blunt trauma is termed as Vossius ring.

15. What are the characteristic types of cataract in specific situations?

- i. Trauma: Rosette cataract
- ii. Infrared rays (glassblowers cataract): Exfoliative cataract
- iii. Chalcosis: Sunflower cataract
- iv. Diabetes: Snow-flake cataract
- v. Myotonic dystrophy: Polychromatic crystals in a Christmas tree pattern.

16. What are the experimental medical agents tried for reversal of cataracts?

- i. Aldose reductase inhibitors
- ii. Aspirin
- iii. Glutathione-raising agents

17. What are the tests by which postoperative acuity can be estimated in the presence of a dense cataract?

- i. Laser interferometry
- ii. Potential acuity meter.

18. What are the tests to assess macular function in the presence of cataract?

- i. Maddox rod test
- ii. Photostress recovery time: normal is less than 50 seconds
- iii. Blue-light endoscopy

- iv. Purkinje's entoptic phenomenon
- v. ERG and
- vi. VEP

19. What are cohesive viscoelastics?

They are high molecular weight agents with high surface tensions and high pseudoplasticity. They tend to be easily aspirated from the eye. Examples include Healon, Amvisc, Healon GV.

20. What are dispersive viscoelastics?

They are substances with low molecular weight and good coating abilities. They tend to be removed less rapidly. Examples include Viscoat and Vitrax.

21. What are the advantages of peribulbar anesthesia as compared to retrobulbar anesthesia?

- i. Lower risk of optic nerve damage
- ii. Lower risk of systemic neurological effects.

22. What are the disadvantages of peribulbar anesthesia?

- i. Need more anesthetic
- ii. More chemosis and congestion
- iii. May need more number of injections.

23. What are the complications of retrobulbar and peribulbar anesthesia?

- i. Retrobulbar hemorrhage
- ii. Globe penetration
- iii. Optic nerve damage
- iv. Extraocular muscle damage
- v. Neurological damage due to intrathecal penetration of drugs
- vi. Death.

24. What are the different pump designs in phacoemulsification machines?

- i. Peristaltic
- ii. Diaphragm
- iii. Venturi.

25. What are the steps which can be taken to modify astigmatism following phacoemulsification?

- i. Toric intraocular lenses
- ii. Limbal relaxing incisions
- iii. Astigmatic keratotomy

26. What is SRK formula?

It was developed by Sanders, Retzlaff and Kraff and is useful for calculating the required IOL power. IOL power $P = A - (2.5L) - 0.9K$

Where “A” is the constant specific to the lens implant, “L” is the axial length and “K” is the average keratometry reading.

27. How will you suspect a posterior capsular tear during cataract surgery?

- i. Deepening of the anterior chamber
- ii. Difficulty in aspiration of the residual cortical material
- iii. Peaking of pupil.

28. What are the steps to be taken in a case of intraoperative posterior capsular tear?

- i. Stop infusion of irrigating fluid
- ii. Avoid anterior chamber collapse by refilling viscoelastics
- iii. Mechanical anterior vitrectomy to take care of vitreous in the anterior chamber or in the wound
- iv. Attempt retrieval of fragments only if they are accessible
- v. If a significant amount of cortex or nucleus falls into the vitreous, then pars plana vitrectomy is performed.
- vi. The IOL is placed in the bag in the event of a small well defined tear. In case of a big tear, but with an associated intact peripheral capsular rim, then the lens can be placed in the ciliary sulcus
- vii. Plan a peripheral iridectomy after IOL implantation
- viii. The incision is closed in a watertight manner
- ix. In the postoperative period, frequent use of topical steroidal drops and topical NSAIDs may be used.

29. What are the conditions which can cause shallow anterior chamber following cataract surgery?

- A. Conditions associated with increased intraocular pressure:
 - i. Pupillary block glaucoma
 - ii. Suprachoroidal hemorrhage
 - iii. Malignant glaucoma (ciliary block glaucoma)
- B. Conditions associated with decreased intraocular pressure
 - i. Leaking incision
 - ii. Choroidal detachment

30. What are the potential risk factors for the development of posterior capsular opacification (PCO)?

- i. Younger age at surgery
- ii. Intraocular inflammation
- iii. Round edged intraocular lenses are more prone to develop PCO than square edged IOLs
- iv. Smaller capsulorhexis
- v. Residual cortical material and anterior capsular opacity
- vi. Presence of intraocular silicon oil
- vii. PMMA IOLs are more likely to develop PCO than acrylic IOLs.

31. What are the signs of expulsive suprachoroidal hemorrhage?

- i. Sudden increase of intraocular pressure
- ii. Darkening of the red reflex
- iii. Wound gape
- iv. Expulsion of the lens, vitreous and bright red blood
- v. Severe pain.

32. What are the risk factors for expulsive hemorrhage?

- i. Uncontrolled glaucoma
- ii. Arterial hypertension
- iii. Patients on anticoagulant therapy
- iv. Bleeding diathesis
- v. Prolonged hypotony.

33. How will you manage expulsive hemorrhage?

- i. Attempt to close the wound as quickly as possible
- ii. Posterior sclerotomies (5–7 mm posterior to the limbus).

6

CHAPTER

Retina

6.1. FUNDUS FLUORESCEIN ANGIOGRAPHY (FFA)

1. What is luminescence, fluorescence and phosphorescence?

- i. Luminescence is the emission of light from any source other than high temperature. This occurs when there is absorption of electromagnetic radiation, the electrons are elevated to higher energy states and then the energy is re-emitted by spontaneous decay of the electrons to lower energy levels. When this decay occurs in visible spectrum, it is called luminescence.
- ii. Fluorescence is luminescence that is maintained only by continuous excitation, thus emission stops when excitation stops.
- iii. Phosphorescence is luminescence where the emission continues long after the excitation has stopped.

2. What are the dyes used in ocular angiography?

- i. Fluorescein sodium
- ii. Indocyanine green.

3. Describe the chemical properties of fluorescein.

- i. Orange-red crystalline hydrocarbon, related to phenolphthalein, resulting from the interaction of phthalic acid anhydride and resorcinol.
- ii. The chemical name is resorcinophthalein sodium, $C_{20}H_{10}Na_2O_5$
- iii. It has low molecular weight (376 dalton) and high solubility in water allows rapid diffusion.

4. Describe the biophysical properties of fluorescein.

- i. Maximum fluorescence at pH 7.4
- ii. Upto 80% protein bound (mainly albumin)
- iii. Only the remaining 20% is available for fluorescence
- iv. Rapid diffusion through intra and extracellular spaces
- v. Elimination rapidly through liver and kidney in 24–36 hours

5. Describe the absorption and emission peaks of fluorescein.

Sodium fluorescein gets excited by a light energy between 465 nm and 490 nm which is a blue spectrum and will fluoresce at a wavelength of 520 nm and 530 nm which is green yellow.

6. What are the other uses of fluorescein in ophthalmology?

- i. Applanation tonometry
- ii. To identify corneal epithelial defects
- iii. Contact lens fitting
- iv. Seidel's test
- v. Fluorescein dye disappearance test
- vi. ear film breakup time testing
- vii. For nasolacrimal duct obstruction evaluation
- viii. Fluorophotometry.

7. What is the common bacterial contaminant of fluorescein solution?

Pseudomonas aeruginosa.

8. What is fluorescein angiography?

It is a fundal photography, performed in rapid sequence following intravenous injection of fluorescein dye.

It provides three main information:

- i. the flow characteristics in the blood vessels as the dye reaches and circulates through the retina
- ii. it records fine details of the pigment epithelium and retinal circulation that may not otherwise be visible
- iii. Gives a clear picture of the retinal vessels and assessment of their functional integrity.

9. Describe the history of FFA.

- i. Ehrlich introduced fluorescein into investigative ophthalmology in 1882
- ii. Chao and Flocks gave earliest description of FFA in 1958
- iii. Novotony and Alvis introduced this into clinical use in 1961.

10. Describe the principle of FFA.

Inner and outer blood retinal barrier are the key to understand FFA. Both barriers control movement of fluid, ions and electrolytes from intravascular to extravascular space in retina.

i. **Inner blood retinal barrier**

- At the level of retinal capillary endothelium and basement membrane
- Prevents all leaks of fluorescein and albumin-bound fluorescein
- Thus, a clear picture of retinal blood vessels is seen in a normal angiogram.

ii. **Outer blood retinal barrier**

- Composed of intact retinal pigment epithelium (RPE) which is impermeable to fluorescein
- RPE acts as an optical barrier to fluorescein and masks choroidal circulation.

11. What are the requirements to perform a FFA?

- i. Fundus camera with two camera backs, timer, filters and barrier.
- ii. 35 mm black and white film
- iii. 35 mm color film
- iv. 23 gauge scalp vein needle
- v. 5 ml syringe with 1.5 inch needle
- vi. 5 ml of 10% fluorescein solution
- vii. Tourniquet
- viii. Emergency tray with medicines to counter anaphylaxis.

12. Describe the filters used in FFA.

- i. **A blue excitation filter** through which white light passes from the camera. The emerging blue light excites the fluorescein molecules in the retinal and choroidal circulations, which then emit light of a longer wavelength (yellow-green)
- ii. **A yellow-green barrier filter** then blocks any reflected blue light from the eye allowing only yellow-green light to pass through unimpaired to be recorded.

13. What is the dosage of fluorescein used for FFA?

Solutions containing 500–1000 mg of fluorescein available in vials of

- i. 5 ml of 10% fluorescein (most commonly used)
- ii. 10 ml of 5% fluorescein
- iii. 3 ml of 25% fluorescein (preferred in opaque media).

14. Describe the technique employed in FFA.

A good quality angiogram requires adequate pupillary dilatation and a clear media.

- i. The patient is seated in front of the fundus camera
- ii. Fluorescein, usually 5 ml of a 10% solution is drawn up into a syringe.
- iii. A red-free image is captured
- iv. Fluorescein is injected intravenously over a few seconds.
- v. Images are taken at approximately 1 second intervals, 5–25 seconds after injection.
- vi. After the transit phase has been photographed in one eye, control pictures are taken of the opposite eye.
- vii. If appropriate, late photographs may also be taken after 10 minutes and, occasionally, 20 minutes if leakage is anticipated.

15. List some of the *main indications* for fluorescein angiography.

Fluorescein angiography is used mainly for the study of abnormal ocular vasculature. The following are the main indications for fluorescein angiography:

i. Diabetic retinopathy

- Detecting any significant macular Oedema which is not clinically obvious
- Locating the area of Oedema for laser treatment

- Differentiating ischaemic from exudative diabetic maculopathy
- Differentiating between IRMA and new blood vessels if clinical differentiation is difficult
- In the presence of dense asteroid hyalosis to detect occult NVE and NVD

ii. Retinal vein occlusion

- Determining the integrity of the foveal capillary bed and the extent of macular edema following branch retinal vein occlusion
- Differentiating collaterals from neovascularization
- To determine capillary non-perfusion areas.

iii. Age-related macular degeneration

- Locate the subretinal neovascularization and determine its suitability for laser treatment.

Other indications

- Locating subretinal neovascular membrane in various conditions (*high myopia, angioid streaks, choroidal rupture and chorioretinitis*)
- Locating abnormal blood vessels (*e.g. idiopathic retinal telangiectasia, etc.*)
- Looking for break down of RPE tight junctions (*central serous retinal retinopathy*) or the blood retinal barrier (*cystoid macular edema*)
- Help with diagnosis of retinal conditions (*e.g. Stargardt's disease gives a characteristic dark choroid*).

16. What are the contraindications of FFA?

- i. Pregnancy
- ii. Juvenile asthmatics
- iii. Renal failure
- iv. Recent cardiac illness
- v. Previous adverse reactions

Caution required in:

- i. Elderly patients
- ii. Blood dyscrasias
- iii. Impaired lymphatic system.

17. What are the phases described in an angiogram?

- i. Choroidal (pre-arterial)
- ii. Arterial
- iii. Arteriovenous (capillary)
- iv. Venous
- v. Late (elimination).

18. Describe the phases of a normal fluorescein angiography.

Normally 10–15 seconds elapse between dye injection and arrival of dye in the short ciliary arteries (arm to retina time). Choroidal circulation precedes retinal circulation by 1 second. Transit of dye through the retinal circulation takes approximately 15–20 seconds.

i. **Choroidal phase**

Choroidal filling via the short ciliary arteries results in initial patchy filling of lobules, very quickly followed by a diffuse (blush) as dye leaks out of the choroidocapillaris. Cilioretinal vessels and prelaminar optic disc capillaries fill during this phase.

ii. **Arterial phase**

The central retinal artery fills about 1 second later than choroidal filling.

iii. **Capillary phase**

The capillaries quickly fill following the arterial phase. The perifoveal capillary network is particularly prominent as the underlying choroidal circulation is masked by luteal pigment in the retina and melanin pigment in the RPE. (At the center of this capillary ring is the foveal avascular zone (500 μ m in diameter).

iv. **Venous phase**

Early filling of the veins is from tributaries joining their margins, resulting in a tramline effect. Later, the whole diameter of the veins is filled.

v. **Late phase**

After 10 to 15 minutes little dye remains within the blood circulation. Dye which has left the blood to ocular structures is particularly visible during this phase.

19. What is A-V transit time?

- i. It is the time from the appearance of dye in the retinal arteries to complete filling of the retinal veins
- ii. Normal—10 to 12 seconds.

20. Why does the fovea appear dark on FFA?

- i. Absence of blood vessels in the foveal avascular zone
- ii. Blockage of background choroidal fluorescence due to increased density of xanthophyll at the fovea.
- iii. Blockage of background choroidal fluorescence by the RPE cells at the fovea, which are larger and contain more melanin than elsewhere.

21. What are the sideeffects of FFA?

They are transient and do not require treatment.

- i. Staining of skin, sclera, tears, saliva and urine (lasting 24–36 hr)
- ii. Flushy sensation, tingling of lips, metallic taste.

22. What are the adverse reactions of FFA?

These require medical intervention.

Mild

- i. Nausea and vomiting
- ii. Vasovagal responses—dizziness, light-headedness

Moderate

- i. Urticaria
- ii. Syncope

- iii. Phlebitis
- iv. Local tissue necrosis and nerve palsies (due to extravasation)

Severe

- i. Respiratory—Laryngeal edema, bronchospasm, anaphylaxis
- ii. Neurologic—Tonic clonic seizures
- iii. Cardiac—Arrest, Death

23. What are the abnormal fluorescein patterns?

i. Hypofluorescence

Reduction or absence of normal fluorescence. It is any normally dark area on the positive print of any angiogram.

It is seen in major two patterns:

- Blocked fluorescence
- Vascular filling defects

ii. Hyperfluorescence

Appearance of areas that are more fluorescent which may be due to enhanced visualization of a normal density of fluorescein in the fundus or an absolute increase in the fluorescein content of the tissues.

It is seen in several major patterns:

- Window defect
- Pooling of dye
- Leakage
- Staining of tissue

24. Describe the causes of hypofluorescence.

It can be because of blocked fluorescence or vascular filling defects

i. Blocked fluorescence

a. Pigments

- RPE hypertrophy
- Melanin, xanthophyll at macula
- Hemoglobin

b. Exudates

c. Edema and transudates

- Disciform degeneration
- Central serous retinopathy
- Detachment

d. Hemorrhage, e.g. choroidal, retinal, sub-hyaloid

ii. Vascular filling defects

- a. Vascular occlusions of retinal, artery, vein and capillary bed
- b. Choriocapillaries—Non-perfusion, choroidal sclerosis.

25. How to differentiate blocked fluorescence and vascular filling defects?

Blocked fluorescence is most easily differentiated from hypofluorescence due to hypoperfusion by evaluating the ophthalmoscopic view where a lesion is usually visible that corresponds to the area of blocked

fluorescence. If no corresponding area is visible clinically, then it is likely an area of vascular filling defect and not blocked fluorescence.

26. Describe the causes of hyperfluorescence.

A. Preinjection phase

Autofluorescence

Pseudofluorescence

B. Increased transmission (window defect)

- i. Atrophic pigment—Drusen, RPE atrophy, albino epithelial window defect
- ii. Leak
- iii. Pooling (in space)
 - New vessels
 - Retinal
 - Subretinal—choroidal neovascular membrane (CNVM), central serous retinopathy (CSR)
- iv. Staining (in tissue)
 - Retinal, e.g. soft exudate
 - Subretinal, e.g. drusen, scar tissue.

C. Abnormal vessels

- i. Neovascularization
- ii. Occlusions
- iii. Micro and macroaneurysms
- iv. Telangiectasia, e.g. Coat's, angiomatosis
- v. Shunts and Collaterals subretinal
- vi. Neovascular membrane tumors
- vii. Retinal—Retinoblastoma
- viii. Subretinal—Malignant melanoma, choroidal hemangioma.

27. What is autofluorescence and pseudofluorescence?

- *Autofluorescence* occurs when certain structures in the eye naturally fluoresce.
 - i. optic nerve head drusen
 - ii. scar tissue
 - iii. astrocytic hamartoma
 - iv. cataractous lens.
- *Pseudofluorescence* is a false fluorescence indicating an inefficient filter system.
 - i. old filters
 - ii. brand new filters
 - iii. high humidity
 - iv. exposure to light.

28. What is leakage?

Leakage refers to the gradual, marked increase in fluorescence throughout the angiogram when

- i. fluorescein molecules seep through the pigment epithelium into the subretinal space or neurosensory retina,
- ii. out of retinal blood vessels into the retinal interstitium, or
- iii. from retinal neovascularization into the vitreous.

The borders of hyperfluorescence become increasingly blurred, and the greatest intensity of hyperfluorescence is appreciated in the late phases of the study, when the only significant fluorescein dye remaining in the eye is extravascular.

Examples include

- i. choroidal neovascularization,
- ii. microaneurysms,
- iii. telangiectatic capillaries in diabetic macular edema, or
- iv. neovascularization of the disk.

29. Describe staining.

Staining refers to a pattern of hyperfluorescence where the fluorescence gradually increases in intensity through transit views and persists in late views, but its borders remain fixed throughout the angiogram process. Staining results from fluorescein entry into solid tissue or similar material that retains the fluorescein such as

- i. scar,
- ii. drusen,
- iii. optic nerve tissue or sclera.

30. Describe pooling.

Pooling refers to accumulation of fluorescein in a fluid filled space in the retina or choroid. The margins of the space trapping the fluorescein are usually distinct, as seen in an RPE detachment in central serous chorioretinopathy.

31. Explain transmission defect or window defect.

It refers to a view of the normal choroidal fluorescence through a defect in the pigment or loss of pigment in the RPE. In this pattern hyperfluorescence occurs early, corresponding to filling of the choroidal circulation, and reaches its greatest intensity with the peak of choroidal filling. The fluorescence does not increase in size or shape and usually fades in the late phases of the angiogram.

32. What are the angiographic findings in diabetic retinopathy?

A. Indications of FFA in DR

- i. Clinically significant macular edema
- ii. Macular ischemia
- iii. Fellow eye of high risk/severe PDR (asymmetric DR)
- iv. Suspected severe NPDR/PDR—to differentiate IRMA and NVE
- v. Asteroid hyalosis
- vi. Featureless retina
- vii. To differentiate diabetic papillopathy from AION and NVD.

B. Salient findings

The two most important phases of FFA in a diabetic eye are the mid arteriovenous phase and the late venous phase.

AV Phase

- i. The most important observations are capillary non-perfusion (CNP) areas outside the arcades and foveal avascular zone.
 - ii. Foveal avascular zone changes in DR
 - Irregularity of FAZ margins
 - Capillary budding into FAZ
 - Widening of intercapillary spaces in perifoveal capillary bed
 - Enlargement of FAZ (normal diameter is 500 μ)
- Leaking microaneurysms—many more than clinically evident are seen, and can be differentiated from dot hemorrhages
 - IRMA and new vessels are seen at the borders of CNP areas. The former leak minimally and the latter profusely.

Late Phase

- Emphasizes leakage

A. Mild non-proliferative diabetic retinopathy (NPDR)

- a. Microaneurysms—hyperfluorescent dots that may leak in later phases.
- b. Superficial and deep retinal hemorrhages causing blocked choroidal fluorescence.

B. Severe NPDR:

- a. All features as in mild NPDR.
- b. CNP areas—seen as areas of hypofluorescence and usually outlined by dilated capillaries unlike hypofluorescence caused by hemorrhages.
- c. IRMAs—are segmental and irregular dilatation of capillary channels lying within CNP areas.
- d. Venous abnormalities—such as dilatation, beading, looping and reduplication.
- e. Soft exudates cause blockage of choroidal fluorescence like retinal hemorrhages.

C. Proliferative diabetic retinopathy

- i. Neovascularization of disk (NVD) or Neovascularization elsewhere (NVE) on retinal surface or elevated into vitreous—these leak the dye profusely which increases in later phase.
- ii. Preretinal (subhyaloid) hemorrhages are well outlined and these block both retinal and choroidal fluorescence.

D. Focal diabetic maculopathy:

- a. Focal leaks from microaneurysms in macular area.
- b. Hard exudates cause blocked choroidal fluorescence.

E. Diffuse diabetic maculopathy (cystoid).

- a. Dilated retinal capillaries are seen leaking diffusely in the macular area.
- b. Typical petalloid or honeycomb pattern of CME, may be seen in late phases.
- c. Hard exudates typically are not seen.

33. Describe the characteristic features of FFA in other common retinal pathologies.

A. Cystoid macular edema

- Petalloid pattern of staining of cysts in macula
- Disc may leak or stain
- Leak into vitreous in late phases

B. Central serous retinopathy

- i. 95% have one or more typical leakage points
- ii. Arteriovenous phase shows the leakage point
- iii. In late phases
 - It spreads in all directions, i.e. ink-blot type of leakage
 - It first ascends forming smoke stack and then spreads like a mushroom or umbrella (7–20%)
- iv. Scar will show hyperfluorescence with hypofluorescent patches
- v. Optic pit shows hyperfluorescence.

C. Macular hole

- i. Pseudohole shows no abnormal fluorescence except for traction induced retinal vascular leakage
- ii. Outer lamellar hole—Variable degree of window defect
- iii. Inner lamellar hole—No transmitted fluorescence or minimal window defect
- iv. Full thickness hole—Granular hyperfluorescent window defects in arteriovenous phase. Surrounding elevation produces blockage of choroidal fluorescence which increase the contrast.

D. Branch retinal vein occlusion (BRVO)

- i. Early arteriovenous phase shows delayed filling of involved vein
- ii. Hemorrhages and cotton-wool spots produce blocked fluorescence
- iii. NVD, NVE, capillary non-perfusion areas are seen
- iv. Macular edema (perifoveal capillary leakage) and macular ischemia (broken FAZ)

E. Central retinal vein occlusion (CRVO)

- i. Delayed central venous filling and emptying
- ii. Engorged and tortuous retinal veins
- iii. NVD, NVE, capillary non-perfusion areas are seen
- iv. Blocked fluorescence
- v. New vessels (early leakage) and collaterals (no leakage)

F. Anterior ischemic optic neuropathy (AION)

- i. Early arteriovenous phase—Hypofluorescence of the disc
- ii. Mid-arteriovenous phase—patient capillaries leak and show edema
- iii. Hypofluorescent areas remain as such due to capillary non-perfusion.

G. subretinal neovascular membrane (SRNVM)

- i. Early arteriovenous phase shows lacy irregular nodular hyperfluorescence
- ii. Late phase shows leakage and pooling.

34. Describe indocyanine green (ICG) angiography.

Indocyanine green angiography is of particular value in delineating the choroidal circulation and can be a useful adjunct to FA in the investigation of macular disease in certain circumstances. About 98% of the ICG molecules bind to serum protein reducing the passage of ICG through the fenestrations of the choriocapillaries, which are impermeable to the larger protein molecules.

Indications:

- i. Exudative age related macular degeneration
 - Occult CNV
 - CNV associated with PED
 - Recurrent CNV adjacent to laser scars
 - Identification of feeder vessels
- ii. Polypoidal choroidal vasculopathy
- iii. Chronic central serous retinopathy
- iv. Lacquer cracks and angiod streaks

35. Describe anterior segment angiography.

Abnormal blood vessels in the conjunctiva, cornea, and iris may be identified with fluorescein angiography.

Mainly iris angiography is done to diagnose

- i. Iris neovascularization
- ii. Iris tumors

Findings:

- i. Normal iris vessels follow a fairly straight pattern from the iris root to the pupillary border with anastomotic connection between the vessels near the iris root and those of the collarete.
- ii. Rubeosis leak of fluorescein dye is extensive and occurs early in the angiography.

6.2. ULTRASONOGRAPHY (USG)

1. What is an ultrasound?

Ultrasound is an acoustic wave that consists of oscillation of particles with a frequency greater than 20,000 Hz and hence inaudible.

2. What is the audible range?

20–20,000 Hz.

3. What is the frequency of diagnostic ophthalmic USG?

8–20 MHz.

4. What is an A-scan?

A—Amplitude.

A-scan is one-dimensional acoustic display in which echoes are represented as vertical spikes. The spacing of spikes depends on the time it takes for the sound to reach an interface and the height indicates the strength of the returning echoes (i.e. amplitude).

5. What is B-scan?

B—Brightness.

B-scan produces two-dimensional acoustic sections. This requires focused beam with the frequency of 10 MHz. The echo is represented by a dot and the strength of the echo is depicted by brightness of the dot.

6. What is standardized echography?

Combined use of standardized A-scan and contact B-scan is called standardized echography.

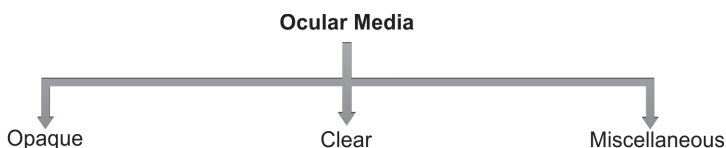
7. What is M-mode?

M-mode (also called time motion (TM)) systems will examine temporal variations in tissue dimension, thus providing data concerning accommodation and vascular pulsations in tumors.

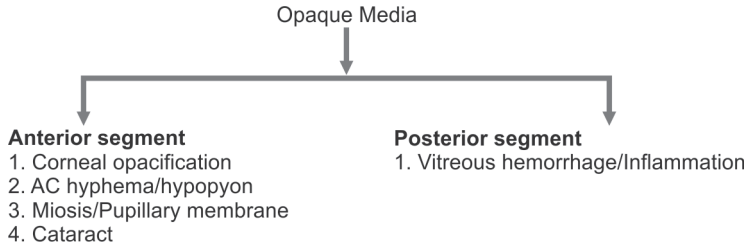
8. What are the basic probe orientations?

- Transverse
- Longitudinal
- Axial.

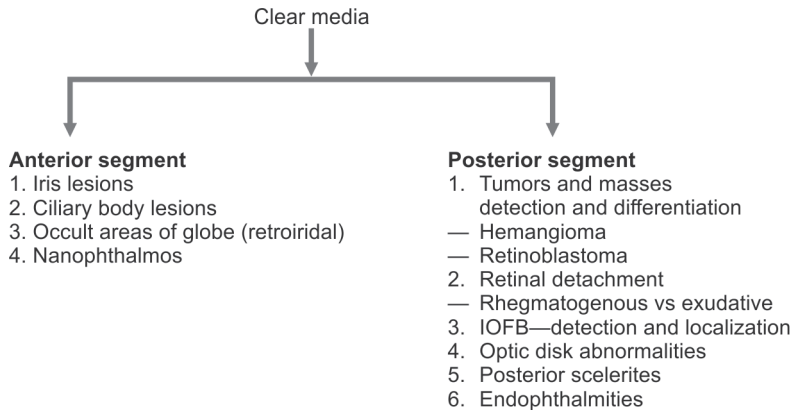
9. What are the indications for echography?



I.



II.



III. Miscellaneous

a. Biometry:

- Axial eye length
- AC depth
- Lens thickness
- Tumor measurement

b. Orbital indications:

- Pseudotumor
- Thyroid myopathy
- Orbital tumors.

10. How does asteroid hyalosis show up in USG?

B-scan

- Bright point like echo which is either diffuse or focal.
- Clear area of vitreous between the posterior boundary of the opacities and the posterior hyaloid.

A-scan

- Medium to high reflective spikes.

11. How does vitreous hemorrhage (VH) show up in USG?

Aim:

To establish the density and location of the hemorrhage and the cause of an unexplained hemorrhage.

Mild VH:

B-scan: Dots and short lines

A-scan: Chain of low amplitude spikes.

More dense hemorrhage

More opacities on B-scan and higher reflectivity on A-scan.

If blood organizes, larger interfaces are formed, resulting in membranous surfaces on B-scan and higher reflectivity on A-scan.

Because of gravity, blood may layer inferiorly, resulting in highly reflective pseudomembranes that may be confused with RD.

12. How is USG useful in Intraocular foreign body (IOFB)?

- i. For more precise localization and to determine the extent of intraocular damage.
- ii. For determining, if a FB which is located next to the scleral wall, lies just within or just outside the globe.

Metallic FB

A-scan → Very high reflective spikes

B-scan → Very bright signal that persists at low sensitivity and marked shadowing (Gain lowest).

- i. Standardized echography can monitor the response of FB to pulsed magnet, to determine if it can be removed magnetically.
- ii. Spherical FB (gun pellets/bullets)
 - Reduplication/multiple signals due to reverberation of sound
 - A-scan: Series of spikes of decreasing amplitude.
 - B-scan: Multiple short bright echoes in decreasing brightness.
- iii. Glass FB: Produces extremely high reflection signal, only if the sound wave is perpendicular to the surface. If non-perpendicular, sound is reflected away from probe and hence, can be missed.

13. How is USG useful in endophthalmitis?

- I. **A-scan:** Chain of low amplitude spikes from vitreous cavity.
- II. **B-scan:**
 - Diffuse low intensity vitreous echoes
 - Diffuse thickening of RCS complex
 - Serous/tractional RD may be seen.

14. What is the normal RCS complex thickness?

- 1 mm.

15. What are the conditions with increased RCS thickness?

- May be diffuse or focal
 - I. Choroidal edema (high reflective)

- Uveitis
- Endophthalmitis
- Macular edema
- Vascular congestion
- Hypotony
- II. Inflammatory infiltration (low reflective)
 - VKH syndrome
 - Sympathetic ophthalmia
 - Lymphoid hyperplasia of uvea
- III. Choroidal tumors
 - Primary
 - Metastatic
- IV. Nanophthalmos

16. How does PVD look in USG?

- i. It can be focal or extensive and may be completely separated or remain attached to disk or at other sites (like NVE/tears/impact sites in trauma/arcades)
- ii. B-scan—smooth, thick membranous with fluid undulating after movements.
- iii. Scan—low (normal eye) to high (as in dense hemorrhage) reflectivity with marked horizontal and vertical spike after movements.

17. How does retinal detachment (RD) look in USG?

- i. B-scan—Bright, continuous folded membrane with more tethered restricted after movement—Total RD is attached usually at disk and ora.
- ii. A-scan—100% tall single spike at tissue sensitivity
- iii. Less than 100% spike is seen if retina is atrophic, severely folded or disrupted.
- iv. Very mobile RD is seen if it is bullous.
- v. Hemorrhagic RD produces echoes in the subretinal space.
- vi. Configuration of RD should be determined which vary from very shallow, flat and smooth membrane to a bullous folded and funnel shaped membrane. The funnel shape may be open/closed and may be concave, triangular or T-shaped.
- vii. Longstanding RD may develop cyst with cholesterol crystals that produce bright echoes and RD may echolucent.
- viii. Tractional RD
 - Tent like if there is point adherence
 - Table top RD

18. USG findings in nanophthalmos.

- i. Short axial length (14–20.5 mm)
- ii. Shallow AC
- iii. Diffuse RCS thickening (>2 mm)
- iv. Normal sized lens

19. USG in choroidal melanoma.

- i. Collar button or mushroom shaped appearance
- ii. Regular structure with low to medium reflectivity
- iii. Marked sound attenuation on A-scan
- iv. High vascularity indicated by marked spontaneous motion
- v. Choroidal excavation which is seen in the base of the mass where the low reflective tumor replaces the normally high reflective choroidal layer
- vi. Hemorrhage into globe and serous RD also seen
- vii. Extrascleral extension detected by well circumscribed area of homogeneity that is situated mostly adjacent to lesion.
- viii. Treated tumours—more irregular in structure, more highly reflective and decreases in elevation.

20. USG in retinoblastoma.

A-scan—extremely high reflectivity

B-scan:

- i. Large bright mass at high sensitivity
- ii. At low sensitivity shows multiple bright echoes corresponding to calcium deposits
- iii. Shadowing of sclera and orbit
- iv. Diffuse tumor may not have calcification

21. USG in choroidal hemangioma.

- i. Solid, regularly structured, highly reflective.
- ii. Internal vascularity—less pronounced than in melanoma.
- iii. Lesions—mildly to moderately elevated with a dome shaped configuration and are normally located posteriorly.

22. How will you differentiate between thyroid myopathy and pseudotumor?

In thyroid myopathy, tendons are spared, with enlargement of muscle belly, whereas in pseudotumor, there will be diffuse enlargement of muscles (involving tendons) seen. Typical beer belly pattern is seen in thyroid related myopathy.

23. What are the limitations of orbital ultrasonography?

- i. Tumors located at the orbital apex are difficult to recognize because of the attenuation of sound and confluence of optic nerve and muscles that are inseparable ultrasonically.
- ii. Tumors < 2 mm are not seen.
- iii. Tumors originating/extending along the bony wall of the orbit do not present a reflecting surface perpendicular to the ultrasonic beam, and consequently do not produce distinct echoes. (e.g. meningioma, osteoma, pseudotumor)
- iv. Floor fractures, surgical defects of the orbital wall, as well as hyperostosis of bone, are not reliably detectable.

6.3. DIABETIC RETINOPATHY (DR)

1. What are the characteristic features of retinal arteries?

Retinal arteries are end arteries.

2. What are the various anatomical layers of retinal artery?

- i. **Intima:** the innermost layer is composed of a single layer of endothelium.
- ii. **Internal elastic lamina:** separates the intima from the media.
- iii. **Media:** consists mainly of smooth muscle
- iv. **Adventitia:** is the outermost and is composed of loose connective tissue.

3. What are the outer and inner blood retinal barriers?

- i. **Outer blood retinal barrier:** consists of basal lamina of the Bruch and zonal occludens between the retinal pigment epithelium (RPE)
- ii. **Inner blood retinal barrier:** The endothelial cells of the capillaries linked by the tight junctions form the inner blood retinal barrier.

4. How do the RPE and the photoreceptors derive their nutrition?

RPE and layer of rods and cones are avascular and derive their nourishment from the choroidal circulation.

5. What are the characteristics of retinal capillaries?

- i. They supply the inner two thirds of the retina while the outer third is supplied by choriocapillaries
- ii. There are two capillary networks—the inner (located in the ganglion cell layer) and the outer (in the inner nuclear layer).

6. Why is proliferative diabetic retinopathy (PDR) more prevalent in Insulin dependent diabetes mellitus (IDDM) than in NIDDM?

PDR is the result of prolonged, very high average blood glucose levels and such levels are seen more in patients with IDDM

7. What are the risk factors for developing DR in patients with DM?

- i. Longer duration of the disease
- ii. Metabolic control—worsening of retinopathy occurs with poor control of hyperglycemia.

8. What are the systemic factors which have an adverse effect on DR?

- i. Duration of diabetes
- ii. Poor metabolic control of diabetes
- iii. Pregnancy
- iv. Hypertension
- v. Nephropathy
- vi. Anemia
- vii. Hyperlipidemia

9. What are the ocular conditions which decrease the progression of DR?

- i. Chorioretinal scarring
- ii. Retinitis pigmentosa
- iii. High myopia
- iv. Optic atrophy
(It is due to decreased retinal metabolic demand).

10. What are the causes of vision loss in diabetic retinopathy?

- i. Macular Oedema
- ii. Macular ischemia
- iii. Vitreous hemorrhage
- iv. Tractional retinal detachment
- v. Optic atrophy due to direct papillopathy or following extensive PRP

11. Explain the pathogenesis of diabetic microangiopathy.

Diabetic microangiopathy occurs at the level of capillaries and comprise of:

a. Capillaropathy

- i. Degeneration and loss of pericytes
- ii. Proliferation of endothelial cells
- iii. Thickening of basement membrane and occlusion

b. Hematological changes

- i. Deformation of erythrocytes and rouleaux formation
- ii. Changes in RBC leading to defective oxygen transport
- iii. Increased plasma viscosity
- iv. Increased stickiness and aggregation of platelets.

These changes result in microvascular occlusion and leakage.

12. Mention the retinal vascular changes in DR.

- i. **Capillaries:**
 - a. Occlusion
 - b. Dilatation
 - c. Microaneurysms
 - d. Abnormal permeability
- ii. **Arterioles:**
 - a. Narrowing of terminal arterioles
 - b. Occlusion
 - c. Sheathing
- iii. **Veins:**
 - a. Tortuosity
 - b. Looping
 - c. Beading
 - d. Sausage like segmentation.

13. What are the functions of basement membrane?

- i. Structural integrity to blood vessels

- ii. Filtration barrier for molecules of various sizes and charges
- iii. Regulate cell proliferation and differentiation.

14. What is the ratio of endothelium cells to pericytes?

Normal endothelial cell: pericyte ratio is 1:1 and there is loss of intramural pericytes in DM.

15. What are the causes of breakdown of blood retinal barrier?

- i. Opening of tight junction between adjacent endothelial cell processes
- ii. Fenestration of the endothelial cell cytoplasm (normally—absent)
- iii. Increased in foldings of plasma membrane at the basal surface of RPE cells
- iv. Increased transport by endocytic vessels.

16. How does microvascular leakage occur?

Loss of pericyte results in distention of capillary walls which leads to breakdown in blood retinal barrier and leakage of plasma.

17. What is the cause of endothelial cell damage in DR?

It is due to increased sorbitol level in endothelial cells.

18. What are the causes of RBC changes in DR?

It is due to increased growth hormone.

19. What is the cause of increased platelet stickiness in DR?

Due to increased factor VIII.

20. What are the features of non proliferative diabetic retinopathy (NPDR)?

- i. Retinal microvascular changes are limited to the confines of the retina and do not extend beyond the internal limiting membrane.
- ii. Findings include microaneurysms, areas of capillary non perfusion, dot and blot retinal hemorrhages, and vascular abnormalities.

21. What are microaneurysms?

They are localized saccular outpouchings of the capillary wall, often caused by pericyte loss. They are continuous with the blood vessels. They appear as red round intraretinal lesions of 30–120 μ in size and are located in the inner nuclear layer of the retina. However, clinically they are indistinguishable from dot hemorrhages. Fluorescein angiogram reveals hyperfluorescence. They are saccular outpouchings of the capillary wall probably arising at the weak points due to loss of pericytes.

22. What are hard exudates and where are they located?

They are caused by chronic localized retinal edema and appear at the junction of the normal and edematous retina. They are composed of lipoproteins and lipid filled macrophages and are located mainly in the outer plexiform layer of the retina. FFA shows hypofluorescence.

23. How do you differentiate drusen and hard exudates?

Drusen:

- i. Oval or round
- ii. Whitish or yellowish in color
- iii. Punched out areas of choroid or pigment epithelial atrophy

Hard exudates:

- i. Waxy yellow lesions with distinct margin
- ii. Other features of DR like microaneurysms and hemorrhages will be present.

24. Why are the retinal superficial hemorrhages flame shaped?

These hemorrhages occur at the nerve fiber layer and they are flame shaped since they follow the architecture of the nerve fiber layer. They arise from superficial precapillary arterioles.

25. Why are the inner retinal hemorrhages dot shaped?

This is because the inner retinal structures are perpendicular to the retinal surface.

26. What are cotton wool spots?

Cotton wool spots are due to the ischemic infarction of the nerve fiber layer. Because of the ischemia, interruption of axoplasmic flow happens and build up of transported material within axons occurs.

27. Describe IRMA.

Intraretinal microvascular abnormality (IRMA) is frequently seen adjacent to capillary closure and they resemble focal areas of flat retinal neovascularization clinically. These are arteriovenous shunts that run from arterioles to venules. IRMA indicates severe NPDR and may herald the onset of the preproliferative stage of diabetic retinopathy (PPDR).

28. Explain the pathological changes of diabetic maculopathy.

They are classified into

a. Intraretinal

- i. Macular edema
- ii. Macular ischemia

b. Preretinal

- i. Thickened posterior hyaloid
- ii. Thickened preretinal membrane
- iii. Macular traction
- iv. Macular ectopia

29. What are the reasons for focal and diffuse macular edema?

This is the most common cause of visual impairment in the diabetic patients.

Focal edema: Due to localized leakage from microaneurysm leading to hard exudates ring formation and retinal thickening.

Diffuse edema (> 2 DD size): Due to generalized leakage from decompensated capillaries throughout the posterior pole.

30. What is clinical significant macular edema (CSME)?

- i. Retinal thickening at or within 500 μ of the center of macula
- ii. Hard exudates at or within 500 μ of the center of macula with adjacent retinal thickening
- iii. Retinal thickening of 1 disk diameter (DD) or larger, any part of which is within 1 DD of the center of the fovea.

31. How does macular ischemia look clinically?

- i. Signs are variable: Multiple cotton wool spots and attenuated arterioles may be seen.
- ii. Macula may look relatively normal despite reduced visual acuity

32. What are the FFA characteristics of macular ischemia?

- i. Focal capillary dropout
- ii. Enlargement of foveal avascular zone (FAZ)
- iii. Occlusion of arterioles of the macula.

33. How do you manage diabetic macular edema (DME)?

- i. **Medical:**
 - a. In patients with refractory macular edema, a posterior sub-tenon injection of triamcinolone acetonide is useful.
 - b. Intravitreal triamcinolone
 - c. Intravitreal anti-VEGF agents
- ii. **Laser:** (given in later chapters)
- iii. **Surgery:**
In cases with posterior hyaloid traction, pars plana vitrectomy and detachment of posterior hyaloid may be useful for treating DME.

34. What are the characteristic features of preproliferative diabetic retinopathy?

a. Clinical features:

- i. Presence of cotton wool spots
- ii. Presence of IRMA
- iii. Venous beading
- iv. Narrowing of vessels
- v. Dark blot hemorrhages

b. Fluorescein angiogram features:

- i. Extension of papillary non perfusion areas

35. What is the 4:2:1 rule?

ETDRS investigators developed the 4:2:1 rule to help clinicians identify patients at greater risk of progression.

- i. Diffuse intraretinal hemorrhages and microaneurysms in **4** quadrants
- ii. Venous beading in **2** quadrants
- iii. IRMAs in **1** quadrant.

36. What is the incidence of proliferative diabetic retinopathy in diabetic population?

5–10%. Type I patients are typically at risk.

37. What is the cause of neovascularization?

- i. Liberation of vasoformative angiogenic growth factors (VEGF, placental growth factor, pigment epithelial factor) elaborated by the hypoxic retina in an attempt to revascularize hypoxic areas are thought to produce neovascularization.
- ii. Inhibition of endogenous inhibitors like endostatin and angiostatin.

38. What is the common site for neovascularization?

It is mainly along major temporal arcade at the posterior pole and over the disc, arising most frequently from veins. Predilection of neovascularization over the disc to bleed is due to absence of internal limiting membrane and hence NVD is more dangerous than NVE.

39. What is high risk PDR?

- i. Mild NVD with vitreous hemorrhage
- ii. Moderate to severe NVD with or without vitreous haemorrhage
- iii. Moderate NVE with vitreous hemorrhage

40. What is the appearance of vitreous hemorrhage on ophthalmoscopic examination?

Black in color.

41. What are the various stages in the development of PDR?

- i. Fine new vessels with minimal fibrous tissue cross and extend beyond the ILM.
- ii. New vessels increase in size and extent with an increased fibrous component.
- iii. New vessels regress, leaving residual fibrovascular proliferation along the posterior hyaloid.

42. What is the most common type of RD that occurs in diabetes?

- i. Tractional RD
- ii. Combined RD and rhegmatogenous RD also occur.

43. What are the current indications for pars plana vitrectomy in PDR?

- i. Dense, non clearing vitreous hemorrhage (VH).
- ii. Tractional retinal detachment involving or threatening macula
- iii. Combined tractional and rhegmatogenous retinal detachment.
- iv. Diffuse diabetic macular edema associated with posterior hyaloid traction
- v. Significant recurrent vitreous hemorrhage despite maximal PRP.

44. What are the complications of PDR?

- i. Persistent VH
- ii. Tractional RD

- iii. Development of opaque membranes on posterior surface of detached hyaloid
- iv. Rubeosis iridis and NVG.

45. What are the landmark studies in DR?

- i. **Studies which measured the efficacy of photocoagulation:**
 - a. DRS—proved the use of photocoagulation in the treatment
 - b. ETDRS—gave data regarding when to do photocoagulation
- ii. **Study which measured the efficacy of vitrectomy:**
DRVS—proved the advantage of early vitrectomy in VH complicating PDR
- iii. **Studies which measured the efficacy of metabolic control:**
 - a. DCCT—showed the advantage of intensive insulin therapy in the treatment of DM
 - b. UKPDS—United Kingdom prospective diabetes study

46. What was the main study objective of diabetic retinopathy study (DRS)?

If photocoagulation reduced the risk of severe visual loss in proliferative diabetic retinopathy.

47. What were the major methodology aspects of DRS?

- i. Randomization
- ii. One eye of each patient was assigned randomly to PHC (argon or xenon) and other eye for follow up. Eye on treatment was randomly assigned to argon or xenon arc.

48. What was the inference of DRS?

- i. Photocoagulation reduced risk of severe visual loss by 50% or more
- ii. Modest risks of decrease in visual acuity and constriction of visual fields (more for xenon)
- iii. Treatment benefit outweighs risks for eyes with high risk PDR.

49. What were the main study questions of early treatment diabetic retinopathy study (ETDRS)?

- i. Is photocoagulation effective in treating diabetic macular edema?
- ii. Is photocoagulation effective for treating diabetic retinopathy?
- iii. Is aspirin effective for preventing progression of diabetic retinopathy?

50. What were the results of ETDRS?

- i. **Aspirin use results:**
 - a. Aspirin use did not alter progression of diabetic retinopathy but reduced risk of cardiovascular morbidity and mortality.
- ii. **Early scatter photocoagulation results:**
 - a. Early scatter photocoagulation resulted in a small reduction in the risk of severe visual loss.
 - b. Early scatter photocoagulation is not indicated for eyes with mild to moderate diabetic retinopathy

- c. Early scatter photocoagulation may be most effective in patients with type 2 diabetes.
- iii. **Macular edema results:**
 - a. Focal photocoagulation for DME decreased risk of moderate visual loss, reduced retinal thickening and increased the chance of moderate visual gain.

51. What was the main study question of diabetic retinopathy vitrectomy study (DRVS)?

To evaluate the natural course and effect of surgical intervention on severe PDR and its complications.

52. What were the clinical recommendations?

1. Early vitrectomy is advantageous for severe vitreous hemorrhage causing significant decrease in vision especially in type I diabetics.
2. Greater urgency for early surgery in uncontrolled fibrovascular proliferation or when proliferation has been treated partially by scatter photocoagulation.
3. Eyes with traction detachment not involving the fovea and producing visual loss do not need surgery until there is detachment of fovea, provided proliferation process is not severe.

53. What were the main study questions of diabetes control and complication trial (DCCT)?

- a. **Primary prevention study:** Will intensive control of blood glucose slow development and subsequent progression of diabetic retinopathy?
- b. **Secondary prevention study:** Will intensive control of blood glucose slow progression of diabetic retinopathy?

54. What were the main study outcomes of DCCT?

- i. Intensive control reduced the risk of developing retinopathy and also slowed the progression of retinopathy.
- ii. Intensive control also reduced the risk of clinical neuropathy and albuminuria.

55. What were the study questions of United Kingdom prospective diabetes study (UKPDS)?

Will intensive control of blood glucose and intensive control of blood pressure reduce the risk of microvascular complications of DR?

56. What were the main study outcomes of UKPDS?

Intensive control of diabetes and blood pressure slowed the progression of diabetic retinopathy and reduced the risk of other microvascular complications of DR.

6.4. LASERS IN DIABETIC RETINOPATHY

1. What does the word LASER stand for and what is its basic principle?

LASER stands for **L**ight **A**mplification by **S**timulated **E**mission of **R**adiation.

Principle: Electrons in lasing medium are excited to higher energy level, which then decay to a lower energy state with the release of a photon, which may be spontaneous or stimulated emission. This photon is then to target the tissue of interest.

2. What are the types of laser tissue interaction in the eye?

- i. **Photochemical effects:**
 - a. Photoradiation (dye laser)
 - b. Photoablation (excimer lasers)
- ii. **Thermal effects:** Photocoagulation (argon, krypton laser)
- iii. **Ionizing effect:** Photodisruption (Nd:YAG laser)

3. How does laser work?

The lasing material is placed in a resonant cavity, which has a mirror at each end. When a photon encounters an excited electron and stimulated emission occurs, the light emitted travels to and fro in the cavity and reinforces itself, producing coherent, monochromatic and collimated light.

4. What are the different types of lasers used?

A. Based on types of laser media, lasers are classified as:

A. Solid state lasers

- Ruby laser
- Nd:YAG laser

B. Gas lasers

- Argon laser
- Krypton laser
- CO₂ laser

C. Liquid lasers

Dye laser (not much popular)

D. Semiconductor lasers

Diode lasers

B. Based on types of output modes:

A. **Continuous wave:** Coherent, monochromatic, and collimated light are produced continuously, eg. argon lasers.

B. Pulsed mode

- **Mode locked:** Pulses in Q switched mode are separated from each other by a specific time interval and all the wavelengths are in phase.
- **Q switched mode:** Single, brief and very high power pulsed, e.g. Nd:YAG, CO₂.
- **Re running mode:** The pulses are not separated by specific time interval and the wavelengths are not in place.

5. What does solid state laser use?

Solid state lasers are ruby laser, Nd:YAG laser. The active element in Ruby laser is chromium ion incorporated in sapphire crystal. In the Nd:YAG, the yttrium-aluminiumgarnet is doped with neodymium ions.

6. What does gas laser use?

The gas lasers have an ionized rare gas as their active medium. For example argon and krypton lasers are ion lasers.

7. What does tunable dye laser mean?

It is a fluorescent organic compound dissolved in liquid solvent which when optically pumped by laser/flash lamp laser, can emit laser radiation over a wide range of wavelength. The output wavelength can be changed over the possible lasing band by varying the tuning element.

8. What is phototherapy?

Necrosis of tumor/neovascularization using locally/systematically administered photosensitizer.

9. Mechanism by which photo therapy works?

Photochemically sensitized target tissue, when exposed to laser of proper wavelength, releases singlet oxygen. This damages the lesion by lipid per-oxidation. For example photodynamic therapy—verteporfin.

10. Few important lasers and their properties?

Laser type	Wavelength (nm)	Active medium	Primary damage mechanism	Applications
1. Argon	488–514	Gas	Photothermal Photochemical	Trabeculoplasty Iridotomy Iridoplasty PRP/PDT Laser Suturolysis Sclerotomy
2. CO ₂	10,600 (Far IR)	Gas	Photothermal	<ul style="list-style-type: none"> • Oculoplastic surgery • Laser Phacolysis • Sclerostomy
3. Excimer	193 (UV)	Gas (Ar/F)	Photochemical	LASIK LASEK PRK/PTK Trabeculoplasty Sclerostomy
4. Nd:YAG	532 (green) 1064 (near IR)	Solid neodymium ion in yttrium	Photo disruption Photothermal	Capsulotomy Iridotomy Trabeculoplasty Phacolysis

Contd...

Contd...

Laser type	Wavelength (nm)	Active medium	Primary damage mechanism	Applications
		aluminum sarnet matrix		Sclerostomy PRP Cyclophotocoagulation Oculoplastic Surgery
5. Diode	(620–895) Red & IR	Solid sassium aluminum	Photothermal	PRP Iridotomy Iridoplasty Sclerostomy Suturolysis Trabeculoplasty Cyclophotocoagulation
6. Dye	310–1200 (UV-visible IR)	Fluorescent dye	Photothermal Photochemical	PKP PDT Iridotomy Sclerostomy Suturolysis

11. How can you increase the burn intensity?

$$\text{Burn intensity} = \frac{(\text{burn duration}) \times (\text{power setting})}{\text{spot size}}$$

So intensity can be increased by

↑ duration

↑ power

↓ spot size.

12. How does Nd:YAG laser work?

It uses a trivalent neodymium ion, which is excited in YAG matrix by an external exciting source (flash lamp/other laser diode).

13. What is the special property of Nd:YAG?

Nd ion laser works at 1064 nm (near infrared) and can be used as a continuous wave laser. Because of longer wavelength, it would penetrate tissue which would otherwise scatter shorter wavelength.

14. How can it be frequency doubled?

Bypassing through KTP crystal (potassium titanium phosphate). The emitted wavelength is 532 nm.

15. What is the use of frequency doubling?

At this wavelength, it is well absorbed by hemoglobin and RPE and hardly any by xanthophyll. This property makes it excellent for use in retina and vitreous disorders.

16. What is Q-switching?

Q-switching causes giant pulse formation.

In this technique a laser can be made to produce a pulsed output beam. Because the pulse duration is so short, the total power delivered per pulse is not very high but the peak power per pulse is very high.

17. What are the uses of Q switched Nd:YAG laser?

- i. Capsulotomy
- ii. Iridotomy

Hyaloidotomy—Release of loculated pre-retinal blood into vitreous cavity.

18. What are the properties of laser light?

- i. **Coherence:** The photons are in phase with each other in time and space.
- ii. **Collimation:** Light amplification of photons produced in parallel beam.
- iii. **Monochromatic:** Photons are emitted in a single wavelength.
- iv. **High intensity.**

19. What is the difference between photocoagulation and photoablation?

Photocoagulation: Process, by which light energy is converted into heat energy, resulting in coagulation of tissue proteins and producing a burn.

Photoablation: High energy photons are able to break the intra molecular bonds of the corneal surface tissue enabling a fine layer to be removed with each pulse without thermal damage to remaining cornea.

20. What are the fundus pigments?

- i. Melanin—in RPE and choroids
- ii. Xanthophyll—in macula (ganglion cells)
- iii. Hemoglobin—in blood vessels.

21. What is the wavelength absorption of each pigment?**a. Melanin**

- Argon blue green
- Green
- Krypton red

b. Xanthophyll

- Blue
- Minimally absorbs yellow/red

c. Hemoglobin

- Blue
- Green
- Yellow
- Red

22. What are the various parameters used in laser photocoagulation?

- i. Spot size—ranges from 50 μ –1000 μ
- ii. Exposure time—0.01–5 sec
- iii. Power—0–3000 mW

23. What is the relationship between spot size and energy requirements in laser?

To decrease energy, spot size is increased except in xenon arc where a decrease of energy is caused by decreasing spot size.

24. What are the factors, which determine the effectiveness of any photocoagulation?

- i. Penetration of light through ocular media.
- ii. Amount of light absorbed by the pigment and converted to heat.

25. What are the indications of photocoagulation in eye?

- i. Diabetic retinopathy
- ii. Retinal vascular abnormalities
 - BRVO (grid, sector)
 - ICRVO with NVG
- iii. Subretinal neovascularization
- iv. Retinal break
- v. Vascular tumors
- vi. Iridectomy
- vii. Trabeculoplasty
- viii. Vasculitis
- ix. Coloboma
- x. Optic nerve pit.

26. What are the indications of laser photocoagulation in diabetic retinopathy?

- a. Clinically significant macular edema.
- b. Paramacular edema.
- c. Proliferative diabetic retinopathy:
 - High risk PDR
 - Early PDR
 - i. in patients with poor compliance
 - ii. During pregnancy
 - iii. Patients with systemic diseases
 - iv. Pending cataract surgery
 - v. Rubeosis
 - vi. Severe/very severe NPDR (irregular follow-up)

27. What are the laser types used in the treatment of macular edema?

- Direct/focal
- Grid.

28. What are the laser parameters of direct and grid laser treatment?

	Direct	Grid
a. Type	Green/red	Green/red
b. Spot size	100–200 μ	100–200 μ
c. Duration	0.10–0.15 sec	0.10 sec
d. End point	Whitening/darkening of microaneurysm at minimal power	Inter burn width is one or two burn width apart subtle whitening of RPE

29. What is the intensity of photocoagulation burns?

- a. Grade I(light) faint retinal blanching
- b. Grade II(mild) hazy translucent retinal burn
- c. Grade III(moderate) opaque grey/dirty white
- d. Grade IV(heavy) dense chalky white

30. How does laser work in clinically significant macular edema (CSME)?

- i. Direct closure of leaking vascular microaneurysms due to laser induced endovascular thrombosis and heat induced contraction at the vessel wall. It acts by increasing filtration by RPE.
- ii. Thermally damaged RPE alters outer retinal blood barrier thereby favoring fluid movement from retina to choroid
- iii. Photoreceptor destruction increases inner retinal oxygenation, which results in vasoconstriction decreased blood flow and therefore decreased vascular leakage.
- iv. RPE damage causes retinal capillary and venule endothelial proliferation, which restores inner blood retinal barrier.
- v. Decreases the amount of retinal leakage by decreasing total surface area of leaking retinal vessels.

31. What are the side effects of focal photocoagulation?

- i. Paracentral scotoma
- ii. Transient increased edema/decreased vision
- iii. Choroidal neovascularization
- iv. Subretinal fibrosis
- v. Photocoagulation scar expansion
- vi. Inadvertent foveal burn.

32. How long should we wait for macular edema to resolve following laser before deciding on retreatment?

Upto 4 months.

33. What is the minimal level of visual acuity to give focal treatment in macular edema?

Focal treatment has to be given even if vision is 6/6 or better if the edema is clinically significant.

34. What are the indicators of poor prognosis in CSME for laser photocoagulation?

- i. Extensive macular capillary non-perfusion (ischemic maculopathy)
- ii. Diffuse disease
- iii. Cystoid macular edema (long)
- iv. Lamellar macular hole
- v. Foveal hard exudates plaque

35. What are the indications for PRP?

- High risk PDR

Others

- i. Rubeosis with/without NVG
- ii. PDR developing in pregnancy
- iii. Early PDR or severe NPDR with increased risk for progression (poor compliance, fulminant course in fellow eye, uncontrolled systemic diseases like hypertension, nephropathy, anemia etc.
- iv. Widespread retinal ischemia/capillary drop outs on FFA of > 10 DD area.

36. What is the mechanism of action of pan retinal photocoagulation (PRP)?

- i. Conversion of hypoxic areas to anoxic areas
- ii. Greater perfusion from the choroidal circulation by achieving a closer approximation of the inner layer of the retina with choriocapillaries.
- iii. Destruction of badly perfused capillaries and grossly hypoxic retina thus diverting available blood to a healthier retina.
- iv. Destruction of leaking blood vessels which create abnormal hemodynamic situation in the diabetic retina thereby normalizing the vascular supply of the macular region.

37. What are the parameters of PRP?

Blue green argon/Fd Nd:YAG lasers

Spot size:	200–500 μ
Exposure time:	0.1–0.2 sec
Power:	200–500 mW
End point:	Moderately intense white burns
Inter burn distance:	one burn width apart
Placement:	2 DD above, temporal and below center of macula.

500 μ from nasal margin of the optic disk and extends to or beyond the equator.

To avoid direct treatment of:

- i. Major retinal vessels
- ii. Macula
- iii. Papillomacular area
- iv. Area of gliosis
- v. Retinal hemorrhage
- vi. Chorioretinal scars

38. What are the approximate number of burns required for completing PRP?

1,800–2,200 burns in 2–3 divided sittings over 3–6 weeks period.

Multiple sessions decrease the risk of

- i. Macular edema
- ii. Exudative RD
- iii. Choroidal detachment
- iv. Angle closure glaucoma

39. What are the indications of additional laser treatment after initial PRP?

For recurrent or persisting neovascularization.

40. What is the placement or number for additional burns in PRP?

- i. In between prior treatment scars
- ii. Anterior to previous scars
- iii. Posterior pole—2 DD away from the macula.

Number at least 500–700.

41. What are the complications of PRP?

Functional complications:

- i. Decreased night vision
- ii. Decreased color vision
- iii. Decreased peripheral vision
- iv. Loss of 1 or 2 lines of visual acuity
- v. Glare, photopsia.

Anatomical complications:

Anterior segment:

- a. Cornea burns
 - Erosion
 - SPK'S
- b. Shallowing of AC
- c. Iris
 - Iritis
 - Atrophy
 - Damage to sphincter
 - Posterior synechiae
- d. Lens
 - Lens opacities

Posterior segment:

- Foveal burn
- Occlusion of vein/artery
- Retinal hemorrhage
- Choroidal hemorrhage—due to rupture of Bruch's membrane/choroidal detachment
- Macular edema following extensive PRP
- Macular pucker
- Contraction of fibrous tissue leading to tractional RD
- CNVM
- Subretinal Fibrosis
- Scar expansion

42. What are the differences between choroiditis pigmentation marks and old laser marks?

Choroiditis pigmentation	Old laser marks
<ul style="list-style-type: none"> i. Irregular ii. Pigmentation is peripheral iii. Anywhere 	<ul style="list-style-type: none"> Regular with equal spacing Pigmentation is in the center Spare the macular regions and Immediately surrounding the disk

43. What is the goal of PRP?

- i. To cause regression of existing neovascular tissue.
- ii. To prevent new vessel formation.

44. What is the wavelength of argon laser?

Argon blue green emits both blue (488 nm) and green (514 nm)

45. What are the advantages of argon laser?

- i. Coherent radiation—more efficient delivery
- ii. High monochromacity
- iii. Very small spot size

46. What are the disadvantages of Argon laser?

- i. Absorption by cataract lens
- ii. Poor penetration through vitreous hemorrhage
- iii. Uptake by macular xanthophyll (blue green)—cannot be used for treatment around macula.
- iv. High intraocular scattering leads to less precise retinal focusing.

47. What is the wavelength of krypton red?

Krypton red—647 nm

48. What are the advantages of krypton?

- i. Useful in treatment of lesions within foveal avascular zone and papillomacular bundle (as not absorbed by xanthophylls)
- ii. Better penetration through nuclear sclerotic cataracts (decreased absorption by lens) and through moderate vitreous hemorrhage (decreased absorption by hemoglobin) because of decreased intraocular scattering.

49. What are the disadvantages of krypton laser?

Red light must have melanin for its absorption

- i. Less effective for treating vascular abnormalities because of poor absorption by hemoglobin.
- ii. Less effective for pale fundus.
- iii. Increased pain and hemorrhage due to deeper choroid penetration.

50. What are the modes of delivery of lasers?

- i. Slit lamp
- ii. Indirect ophthalmoscopy
- iii. Endolaser

51. What are the various lenses used?

- a. All purpose fundus contact lens.
 - i. Goldmann contact lens
 - ii. Karickhoff lens
- b. Contact lens for macular photocoagulation
 - Volk super macula
 - Mainstar high magnification
 - Volk area centralis Real inverted
 - Mainstar standard lens
- c. For peripheral photocoagulation
 - Rodenstock panfundoscopic
 - Volk trans equator
 - Mainster widefield Inverted real magnified
 - Mainster ultrafield
- d. Non-contact lenses
 - 60D
 - 78D
 - 90D

52. What are the indications of laser PHC through indirect ophthalmoscopy delivery?

- i. PRP in patients with hazy media, patients unable to sit, early anterior segment post operative period
- ii. Retinopathy of prematurity
- iii. Peripheral proliferative lesions as in pars planitis, Eales', sickle cell retinopathy, Coat's disease
- iv. Peripheral retinal breaks
- v. Retinal PHC following pneumatic retinopexy
- vi. Retinal and choroidal tumors: Choroidal malignant melanoma, retinoblastoma.

53. What are the advantages of laser PHC through indirect ophthalmoscope delivery?

Treatment of patients with

- i. Hazy media
- ii. Poorly dilated pupils
- iii. In presence of intraocular gas bubbles
- iv. For patients unable to sit at a slit lamp
- v. For peripheral lesions

54. Which is more responsive to treatment, flat or elevated new vessels?

- i. Flat vessels
- ii. Because absorption of laser energy by elevated lesions is less.

55. Which is more likely to bleed, NVD or NVE? Why?

NVD. Because of the absence of internal limiting membrane over the disk.

56. What is to be done when bleeding occurs during photocoagulation?

- i. Bleeding can be stopped by increasing the pressure of the contact lens on the globe.
- ii. By increasing the laser energy and hitting the bleeding point repeatedly.

57. What are the relative indications for retrobulbar anesthesia in photocoagulation procedures?

- i. Significant ocular pain
- ii. Significant eye movement
- iii. Treatment near the foveal center to avoid incidental foveal burns.

58. What are the indications of anterior retinal cryotherapy?

- i. Progressive proliferative diseases (NVD, NVE or NVI) despite full PRP
- ii. When media opacities (cataract, VH) preclude PRP.

59. What are the diameters of various cryoprobes used in ophthalmology?

Endocryopexy—1 mm

ICCE—1.5 mm

Retina—2–2.5 mm

6.5. HYPERTENSIVE RETINOPATHY (HTN RETINOPATHY)

1. What are the different classifications of HTN retinopathy?

There are two main classifications:

- i. Keith-Wagener-Barker classification
- ii. Scheie's classification

2. What is the Keith-Wagener-Barker classification?

It is divided into 4 groups:

Group 1—Minimal constriction of the arterioles with some tortuosity.

Group 2—Abnormalities in Group 1 with definite focal narrowing and arteriovenous nicking

Group 3—Group 1 and 2 abnormalities and hemorrhages, exudates, cotton wool spots.

Group 4—Above findings along with optic disc edema.

3. What is Scheie's classification?

Scheie classified changes of hypertension and arteriosclerosis separately.

Scheie's classification of hypertensive retinopathy:

Stage 0—No visible retinal vascular abnormalities

Stage 1—Diffuse arteriolar narrowing

Stage 2—Arteriolar narrowing with areas of focal arteriolar constriction.

Stage 3—Diffuse and focal arteriolar narrowing with retinal hemorrhages

Stage 4—All above findings with retinal edema, hard exudates and optic disc edema.

Scheie's classification of arteriolosclerosis:

Stage 0—Normal

Stage 1—Broadening of arteriolar light reflex

Stage 2—Light reflex changes and arteriovenous crossing changes

Stage 3—Copper wiring of arterioles

Stage 4—Silver wiring of arterioles

4. What is Salus's sign?

Deflection of vein as it crosses the arteriole.

5. What is Gunn's sign?

Tapering of veins on either side of arteriovenous (AV) crossing.

6. What is Bonnet's sign?

Banking of veins distal to arteriovenous (AV) crossings.

7. What is the cause of arteriolar light reflex?

It is the light reflected from the convex surface of normal arteriolar wall.

8. What is copper wiring?

When the light reflex from the vessel wall takes on a reddish brown hue due to increase in arteriolosclerosis it is called copper wiring.

9. What is silver wiring?

When there is severe arteriolosclerosis and no blood is seen inside the vessel wall it is called silver wiring.

10. What is the reason for arteriolar narrowing?

When there is rise in blood pressure, it excites the pliable and non-sclerotic retinal vessels to increase their vascular tone by autoregulation.

11. What is a cotton wool spot?

It is an area of focal ischemic infarct of the nerve fiber layer as a result of axon disruption.

12. What are causes of cotton wool spots?

They are:

i. Systemic diseases

- Diabetes
- Hypertension
- Collagen vascular diseases

ii. Vascular

- CRVO
- BRVO

iii. Infections

- HIV retinopathy
- Toxoplasmosis

iv. Hematological

- Leukemias
- Anemia
- Hypercoagulable states

v. Others

- Radiation retinopathy
- Purtschers retinopathy
- Interferon therapy

13. What are flames shaped hemorrhages?

These are the hemorrhages present in nerve fiber layer from superficial precapillary arterioles and hence assuming the architecture of nerve fiber layer.

14. What are the differential diagnoses of flame shaped hemorrhages?

They are:

- i. HTN retinopathy
- ii. Diabetic retinopathy
- iii. CRVO
- iv. BRVO
- v. Ocular ischemic syndrome
- vi. Eales, disease
- vii. Hemoglobinopathies

15. What are hard exudates?

They are caused by chronic retinal edema. They develop at the junction of the normal and edematous retina and are composed of lipoprotein and lipid rich macrophages located within the outer plexiform layer.

16. What are the differential diagnoses of hard exudates?

They are:

- i. Diabetic retinopathy
- ii. HTN retinopathy
- iii. BRVO
- iv. CRVO
- v. Coats' disease
- vi. Retinal artery macroaneurysm
- vii. Radiation retinopathy
- viii. Eales' disease

17. What is macular star?

It is the deposition of hard exudates in a star shaped pattern around the fovea. This is due to chronic macular edema in hypertensive retinopathy.

18. What are the differential diagnoses of macular star?

They are:

- i. HTN retinopathy
- ii. Neuroretinitis
- iii. Papilledema
- iv. CRVO
- v. BRVO

19. What is the hallmark of accelerated hypertension?

Optic disk swelling.

20. How is hypertensive eye disease divided on the basis of ocular tissue involved?

It is divided into:

- i. HTN retinopathy
- ii. HTN choroidopathy
- iii. HTN optic neuropathy

21. What are different phases of HTN retinopathy?

It is divided into:

- i. Vasoconstrictive phase
- ii. Exudative phase
- iii. Sclerotic phase

22. What are the changes in vasoconstrictive phase?

Fundus changes:

- i. Diffuse arteriolar narrowing
- ii. Focal arteriolar narrowing
- iii. Reduction of arteriole to venule ratio (Normal—2:3)

23. What are the changes in exudative phase?

Fundus changes:

- i. Flame shaped hemorrhages
- ii. Cotton wool spots
- iii. Hard exudates

24. What is the finding in sclerotic phase?

Fundus changes:

- i. Sclerosis of vessel wall (copper wiring and silver wiring)
- ii. Arteriovenous crossing changes (Salus's sign, Bonnet's sign, Gunn's sign)

25. What are the complications of HTN retinopathy?

They are:

- i. Microaneurysms
- ii. Macroaneurysms
- iii. Central retinal artery or vein occlusion
- iv. Branch retinal artery or vein occlusion
- v. Epiretinal membrane formation
- vi. Macular edema
- vii. Retinal neovascularization
- viii. Vitreous hemorrhage

26. What is HTN arteriolosclerosis?

It is progressive increase in the elastic and muscular component in the walls of the arterioles.

27. What is onion skin appearance of the vessel wall?

In longstanding hypertension elastic tissue forms multiple concentric layers. Muscular layer is replaced by collagen fibers and the intima is replaced by hyaline thickening. These give the appearance of onion skin.

28. What are the risk factors for HTN choroidopathy?

It's commonly seen in acute HTN and young patients. Risk factors are:

- i. Toxemia of pregnancy
- ii. Malignant HTN
- iii. Renal disease
- iv. Pheochromocytoma
- v. Acquired diseases of connective tissue

29. What are the fundus changes in HTN choroidopathy?

Fundus changes are:

- i. Elsching's spots and Siegrist's streaks
- ii. Serous retinal detachments
- iii. Macular star
- iv. RPE depigmentation
- v. Subretinal exudates
- vi. Choroidal sclerosis

30. What are Elsching's spots?

They are small black spots surrounded by yellow halos representing RPE infarct due to focal occlusion of choriocapillaries.

31. What are Siegrist's streaks?

They are flecks arranged linearly along the choroidal vessels; indicative of fibrinoid necrosis.

32. How is choroidal circulation different from retinal circulation?

Choroidal circulation has got following peculiarities:

- i. Profuse sympathetic nerve supply
- ii. No autoregulation of blood flow
- iii. No blood ocular barrier

Hence increased blood pressure is directly transferred to choroidal choriocapillaries which initially constrict but further increase in blood pressure overcomes the compensatory tone, resulting in damage to the muscle layer and endothelium.

33. What is HTN optic neuropathy?

It is characterized by:

- i. Swelling of the optic nerve head (ONH)
- ii. Blurring of the disk margins
- iii. Hemorrhages over the ONH
- iv. Ischemia and pallor of the disc

34. What are the differential diagnosis of HTN optic neuropathy?

They are:

- i. CRVO
- ii. AION
- iii. Radiation retinopathy
- iv. Diabetic papillopathy
- v. Neuroretinitis

35. What is malignant hypertension?

Diastolic blood pressure of >120 mm Hg

It is characterized by fibrinoid necrosis of the arterioles. Choroidopathy and optic neuropathy are more common but retinopathy also occurs in malignant hypertension.

36. What are ocular manifestations in pregnancy induced HTN (PIH)?

They are divided as:

Conjunctiva—

- i. Capillary tortuosity
- ii. Conjunctival hemorrhages
- iii. Ischemic necrosis of conjunctiva

Hypertensive retinopathy changes

Choroid—Serous detachments

Optic nerve—Disk edema and rarely optic atrophy.

37. How do you manage PIH?

The fundus findings that occur generally return to normal in response to appropriate medical management or upon spontaneous or elective delivery. The role of ophthalmologist is limited.

38. What is the management of HTN retinopathy?

Control of the hypertension is the key step. An ophthalmologist mainly plays a supportive role to a primary care physician in the diagnosis and management of systemic hypertension with prompt referral.

6.6. CENTRAL RETINAL VEIN OCCLUSION (CRVO)

1. What are the main types of CRVO?

- i. **Ischemic** (nonperfused/ hemorrhagic/complete (ICRVO))
- ii. **Non-ischemic** (perfused/partial/incomplete (NICRVO))

2. What is indeterminate CRVO?

A CRVO is categorized as indeterminate when there is sufficient intraretinal hemorrhage to prevent angiographic determination of perfusion status.

3. Which type of CRVO is more prevalent in younger age group?

Non-ischemic CRVO.

4. Which type of CRVO more prevalent in older age group?

Ischemic CRVO.

5. Which type of CRVO is known to recur in the same eye again?

Non-ischemic CRVO.

6. What is the crucial period for the development of neovascularization after the ischemic insult?

First 7 months. (The risk period may span upto 2 years).

7. What percentage of patients with neovascularization develops NVG?

33% of patients with iris neovascularization develop NVG.

8. What is the need for distinction between two types of CRVO?

- i. Prediction of the risk of subsequent ocular neovascularization.
- ii. Identification of patients who will have poor visual prognosis.
- iii. Determination of the likelihood of spontaneous visual improvement.
- iv. Decision as to appropriate follow up interval.

9. Mention the causes for CRVO.

i. **Systemic vascular disease:**

- a. Hypertension (artery compresses the vein)
- b. Thrombosis of the central retinal vein
- c. Diabetes
- d. Hyperlipidemia
- e. Hematological alterations like hyperviscosity syndrome, blood dyscrasias
- f. Leukemia

ii. **Ocular disease:**

- a. Primary open angle glaucoma.
- b. Ischemic optic neuropathy
- c. Events compressing the proximal part of the optic nerve like retrobulbar hemorrhage, orbital pseudotumor, optic nerve tumors

iii. **Inflammatory/autoimmune vasculitis:**

- a. Systemic lupus erythematosus
- b. Behcet's disease
- c. Sarcoidosis

iv. **Infectious vasculitis:**

- a. HIV
- b. Syphilis
- c. Herpes zoster

v. **Medications:**

- a. Oral contraceptives
- b. Diuretics
- c. Hepatitis B vaccine.

vi. **Others:**

- After retrobulbar block, dehydration, pregnancy.

10. Where is the common site of occlusion in non-ischemic CRVO?

6 mm behind lamina cribrosa.

11. What is the common site of occlusion in ischemic CRVO?

At the region of lamina cribrosa or immediately posterior it.

12. Why does ischemic CRVO present with a more malignant picture?

In ischemic CRVO, the site of occlusion is closer to the disk, i.e. it is at lamina cribrosa or immediately posterior to it, where only a few collaterals are present to drain the blood. So there is a marked increase in venous pressure with a more malignant picture at presentation. Non-ischemic CRVO has occlusion more proximally with plenty of collaterals to drain the blood.

13. How does glaucoma cause CRVO?

- i. The pressure in CRV at optic disk depends upon the IOP, the former being always higher than the latter to maintain blood flow. A rise of IOP would produce retinal venous stasis and sluggish venous outflow—one of the factors in Virchow's triad for thrombus formation.
- ii. The central retinal artery and veins are subjected to compression from mechanical stretching of lamina cribrosa, while passing through rigid sieve like openings especially in POAG.
- iii. Nasalization and compression of vessels

14. How does CRVO cause glaucoma?

- i. Neovascular glaucoma (open-angle and closed-angle types).
- ii. In the management of macular edema in CRVO, intravitreal steroid may cause steroid induced glaucoma.

15. What are the risk factors for the conversion of non-ischemic CRVO to ischemic CRVO?

A. **Ocular risk factors:**

- i. Non-ischemic CRVO with V/A at presentation of < 6/60
- ii. Presence of 5–9 disk areas of non-perfusion on angiography

B. Systemic risk factors:

- i. Elderly individuals (> 60 years)
- ii. Associated cardiovascular disease
- iii. Blood dyscrasias
- iv. Nocturnal hypotension

16. What are the pathological changes in CRVO?

- i. Hemorrhagic infarction of inner layer of retina
- ii. Neovascularization of disk, retina, iris, angle
- iii. Thickening of retina, reactive gliosis
- iv. Intraretinal Oedema

17. What is the most common cause of visual loss in CRVO?

Macular edema.

18. Why do patients of CRVO complain of defective vision in the early morning?

The fall in the blood pressure during sleep (nocturnal hypotension) alters the perfusion pressure and so the venous circulation is further slowed down, converting partial thrombosis to complete thrombosis.

19. Why do patients with CRVO have amaurosis fugax?

The thrombosis formation in central retinal vein completely cuts off the retinal vascular blood flow resulting in transient obscuration of vision with field defects. However, due to the sudden rise in the blood pressure at the arterial end of the retinal vascular blood flow, the freshly formed thrombus is pushed out of the site of block and relieves the ischemia, resulting in the return of vision and field normality.

20. Which type of CRVO is usually asymptomatic?

Non-ischemic CRVO.

21. Which type of CRVO presents with amaurosis fugax?

Non-ischemic CRVO.

22. Which type of CRVO presents with sudden loss of vision?

Ischemic CRVO.

23. What is the commonest field defect in CRVO?

Central scotoma.

24. What are the clinical tests used in the evaluation of CRVO?

Clinical tests can be classified into two categories:

MORPHOLOGICAL

- a. Ophthalmoscopy
- b. FFA

FUNCTIONAL

- a. Visual acuity
- b. RAPD
- c. Visual fields
- d. ERG

25. Differentiate between non-ischemic and ischemic CRVO.

	Non-ischemic CRVO	Ischemic CRVO
1. V/A	Better than 6/60	Worse than 6/60(3/60-HM)
2. Anterior segment	Normal RAPD +/-	RAPD++ NVI, NVA +/- NVG features
3. Fundus	Less retinal hemorrhage at posterior pole Cotton wool spot +	Abundant and extensive retinal superficial hemorrhage Cotton wool spot + + +
4. Field defects	50–75%	100%
5. ERG changes	+/-	+ +
6. FFA changes	Few non perfusion areas	Non perfusion areas > 10 DD
7. Course	Majority resolve completely (48%)	Majority do not resolve, leading to ocular morbidity

26. What is the importance of relative afferent pupillary defect (RAPD) in the setting of CRVO?**Uses:**

- i. Higher sensitivity at earliest stages
- ii. It gives reliable information in spite of hazy media.
- iii. It can detect conversion of non-ischemic to ischemic CRVO.
- iv. It is a noninvasive and inexpensive diagnostic tool.

Limitations:

- i. To test for RAPD, it is essential to have a normal fellow eye and normal optic disk and pupil in both eyes. For example, not useful in pharmacologically miotic or mydriatic pupil, glaucomatous disc damage or optic neuropathy.
- ii. The amount of RAPD is influenced by the size of the central scotoma because it is modified more by the number of retinal ganglion cell involved than by the area of the retina. For example, NICRVO with central large, dense, macular edema may show a RAPD.

27. What will be the fundus picture in ischemic CRVO?

- i. Widespread retinal hemorrhages (Tomato ketchup fundus)
- ii. Retinal venous engorgement and tortuosity
- iii. Cotton wool spots
- iv. Macular edema
- v. Optic disk edema.

28. What is the footprint of asymptomatic NICRVO?

Retinocapillary venous collaterals on optic disk.

29. What is the importance of ocular neovascularization in CRVO?

- a. Ocular neovascularization is seen in 2/3 of ischemic CRVO.
- b. Ocular neovascularization if seen in non-ischemic CRVO, should raise the suspicion of other associated conditions like
 - i. DM and other proliferative retinopathy
 - ii. Carotid artery disease.

30. Which is the commonest site of neovascularization in ischemic CRVO?

Iris.

31. What is the importance of ischemic index in CRVO?

$$\text{Ischemic index} = \frac{\text{Non-perfusion area}}{\text{Total area of retina}}$$

The risk of developing neovascularization is directly proportional to the degree of ischemic index.

Ischemic index:

- 0–10% — < 1% develop NVG
- 10–50% — 7% develop NVG
- > 50% — 45% develop NVG.

32. What are the indications of FFA in CRVO?

FFA should be performed after the acute phase is over since the hemorrhages during the acute phase will not provide accurate information.

- i. To look for any macular ischemia before treatment
- ii. To evaluate the extent of capillary non-perfusion (CNP)
- iii. In cases of non-ischemic CRVO, follow-up changes can be identified such as conversion to ischemic type.

33. FFA findings in ischemic CRVO and non-ischemic CRVO.

Ischemic CRVO:

- i. Hypofluorescence due to retinal capillary non-perfusion, blockage from retinal hemorrhages
- ii. Increased arteriovenous transit time
- iii. Macular area shows pooling due to edema and non-perfusion areas suggestive of macular ischemia
- iv. NVD and NVE show leakage
- v. Vessel wall staining.

Non-ischemic CRVO:

- i. Delayed AV transit time
- ii. Blockage by hemorrhages
- iii. Non-perfusion areas are minimal
- iv. Late leakage
- v. FFA may become normal after NICRVO resolves.

34. How do you differentiate between ischemic CRVO and non-ischemic CRVO by FFA?

Ischemic CRVO	> 10 DD of CNP area
Non-ischemic CRVO	< 10 DD of CNP area

35. Is ERG useful in differentiating ICRVO from NICRVO?

- i. Amplitude reduction of 'b' wave has 80% sensitivity and specificity in differentiating ICRVO from NICRVO. It does not require normal fellow

eye and can be done in patients with optic nerve and pupil abnormalities also. In ischemic CRVO

- ii. 'b' wave amplitude decreased to less than 60% of normal
- iii. 'b' wave amplitude reduced by 1 standard deviation or more, below the normal mean value.

36. What are the investigations to be done in patients with CRVO?

History:

Age
Sex
Occupation/lifestyle
DM/HTN

Ocular:

Slit lamp examination
Direct/indirect ophthalmoscopy
Field charting
FFA
ERG

General:

BP, pulse rate
Systemic examination

Specific investigations:

BP
ECG
Full blood count and ESR
FBS and lipids
Urine albumin and serum creatinine
Plasma protein electrophoresis

Young patients have to be specifically screened for

Thrombophilia screening

Autoantibodies (anticardiolipin, lupus anticoagulant, ANA, DNA, ACE.)

Homocysteine.

37. How will you manage CRVO?

- i. Treat the associated cause like hypertension, diabetes, elevated cholesterol.
- ii. Intravitreal triamcinolone acetonide for treating macular edema
- iii. Intravitreal anti-VEGF agents to reduce macular edema
- iv. Surgical decompression of CRVO via radial optic neurotomy which involves sectioning the posterior scleral ring and retinal vein cannulation with an infusion of tissue plasminogen activators have been reported.

38. What are the findings of central vein occlusion study group (CVOS)?

The CVOS findings were the following:

- i. Even though grid laser treatment in the macula reduced angiographic evidence of macular edema, it yielded no benefit in improved visual acuity

- ii. The most important risk factor predictive of iris neovascularization in CRVO is poor visual acuity. Scatter PRP failed to decrease the incidence of iris neovascularization. CVOS recommended waiting for at least 2 clock hours of iris neovascularization to show on undialted gonioscopy before performing photocoagulation.

39. What is significant anterior segment neovascularization?

More than 2 clock hour neovascularisation of iris (NVI) and/or angle (NVA).

40. When is PRP indicated in CRVO?

- i. Patient presenting with NVI or NVA
- ii. Patient presenting with NVD or NVE, even without NVA or NVI.

Focal retinal laser can be performed if macular edema persists for 3 to 6 month duration and visual acuity is below 6/12 with macular capillary perfusion.

41. When is prophylactic PRP indicated in CRVO?

Patient with **ischemic CRVO** where regular follow-up is not possible.

42. Is grid photocoagulation useful in macular edema due to CRVO?

No.

43. Why is there no improvement of visual acuity after grid in CRVO as against that seen in BRVO or early stages of DME? (CVOS).

- i. Difference in the pathophysiology of the diseases
- ii. CRVO usually results in the diffuse capillary leakage involving all the macular area, unlikely in BRVO or background DR.
- iii. In BRVO, macular edema may have more angiographically normal parafoveal capillaries.
- iv. Also in BRVO, collateral channels typically develop temporal to the macula crossing the horizontal raphe. This may permit a greater normalization of venous circulation in the recovery phase (as opposed to CVO, where collaterals channels develop at the optic nerve).
- v. In CRVO—Macular edema involves the center of the fovea and additionally includes all four quadrants in the parafoveal region. May adversely affect the recuperative process in the macula.

44. What is the role of steroids in management of CRVO?

Decreases macular edema in non-ischemic CRVO.

Treatment of CRVO in young is especially secondary to phlebitis.

45. What is the role of cyclocryotherapy?

Procedure:

- i. 180° of the ciliary body is treated at one time, employing six spots of freezing, 2.5 mm posterior to the limbus.
- ii. The 3.5 mm probe is allowed to reach -60° to -80°C and is left in place for 1 minute each.

46. What is anterior retinal cryotherapy (ARC)?

Indication in NVG: In cases in which the cornea, lens and vitreous is hazy to allow adequate PRP.

Procedure:

- i. A 2.5 mm retinal cryoprobe is used. The first row of application is performed 8 mm posterior to limbus, three spots between each rectus muscle.
- ii. Second row of application is performed 11 mm behind the limbus, four spots between each rectus muscle.
- iii. Probe is applied for approximately 10 seconds.

47. Complications of ARC.

- i. Tractional and exudative RD
- ii. Vitreous hemorrhage.

48. What is the visual outcome in patients with CRVO?

Depends on the vision on presentation

Non-ischemic CRVO—final V/A is better than 6/60 in 50% patients.

Ischemic CRVO—final V/A is worse than 6/60 in 93%, worse than 3/60 in 10%.

49. Why is visual prognosis in young patients good?

- i. Due to absence of significant retinal ischemia
- ii. Young patients with healthy blood vessels may be able to tolerate brief periods of CRVO better than older individuals.

50. What is the differential diagnosis of CRVO?

- i. Ocular ischemic syndrome
- ii. Hyperviscosity retinopathy
- iii. Diabetic retinopathy
- iv. Papilledema.

6.7. CENTRAL RETINAL ARTERY OCCLUSION (CRAO)

1. What does central retinal artery supply?

Central retinal artery is a branch of ophthalmic artery that enters the eye within the optic nerve and supplies the blood to the inner layers of the retina, extending from the inner aspect of the inner nuclear layer to the nerve fiber layer. Therefore CRAO leads to damage predominantly to the inner layers of the retina.

2. What are the causes of CRAO?

- i. Atherosclerosis-related thrombosis
- ii. Carotid embolism
- iii. Giant cell arteritis
- iv. Cardiac embolism which may be calcific emboli or vegetations or thrombus or myxomatous material
- v. Periarteritis
- vi. Thrombophilic disorders
- vii. Sickling hemoglobinopathies
- viii. Retinal migraine.

3. Where is the occlusion present in CRAO?

Occlusion is most commonly present at the level of lamina cribrosa (80%).

4. What are the features of atherosclerosis?

Atherosclerosis is characterized by focal intimal thickening comprising cells of smooth muscle origin, connective tissue and lipid containing foam cells.

5. What are the risk factors of atherosclerosis-related thrombosis?

Risk factors are:

- i. Aging
- ii. Hypertension
- iii. Diabetes
- iv. Hyperhomocysteinemia
- v. Increased LDL cholesterol
- vi. Obesity
- vii. Smoking
- viii. Sedentary life style.

6. Where does carotid embolism originate from and what are the types of emboli?

Carotid embolism mostly originates from an atheromatous plaque at the carotid bifurcation and less commonly from the aortic arch. The emboli may be of

- a. **Cholesterol (Hollenhorst plaques):** appear as intermittent showers of minute, bright, refractile, golden to yellow-orange crystals. They rarely cause significant obstruction to the retinal arterioles and are frequently asymptomatic.

- b. **Calcific emboli:** single, white nonscintillating and are often on or close to the disk. Calcific emboli are more dangerous than the others as they cause permanent occlusion of the central retinal artery or its branches.
- c. **Fibrin-platelet emboli:** are dull, gray, multiple elongated particles that occasionally fill the entire lumen. They may cause retinal transient-ischemic attacks with resultant amaurosis fugax and occasionally complete obstruction.

7. What is the incidence of CRAO?

- i. 1 per 10,000 outpatients
- ii. Above the age of 60 years
- iii. Bilateral in 2–3% of cases—To rule out cardiac valvular diseases, giant cell arteries and vascular inflammations.

8. Describe the clinical features of CRAO.

Symptoms

- i. Sudden painless loss of vision.
- ii. In a few cases, visual loss is preceded by amaurosis fugax.
- iii. Visual acuity—counting fingers to PL+ve in 90% of cases.
 - In case of PL-ve—suspect associated ophthalmic artery occlusion or optic nerve damage.

Signs

- i. RAPD—within seconds after CRAO.
 - will be present even when fundus appears normal during the early phases of CRAO.
- ii. Anterior segment is usually normal initially.
- iii. Rubeosis iridis at the time of obstruction is rare.
 - if present, suspect concomitant carotid artery obstruction.
 - rubeosis iridis in CRAO develops at a mean of 4–5 weeks after obstruction, with a range of 1 to 15 weeks and seen in 18% of eyes.
- iv. Yellowish white opacification of superficial retina in the posterior pole except fovea. This loss of retinal transparency is due to ischemia of inner half of retina. This usually resolves in 4–6 weeks.
- v. Cherry-red spot in the foveal area due to extremely thin retina, allowing view of underlying retinal pigment epithelium and choroids.
- vi. In early stages, the retinal arteries are attenuated. The retinal veins are thin, dilated or normal.
 - In severe cases, segmentation or “box caring” of blood vessels in arteries and veins are seen.
- vii. In 20% of CRAO, Hollenhorst plaque—(glistening, yellow cholesterol embolous) that arises from atherosclerotic, deposits in the carotid artery.
- viii. NVD in 2–3%.
- ix. Late fundus picture:
 - Consecutive optic atrophy
 - Attenuated blood vessels to a relatively normal fundus picture
 - When present, pigmentary changes may indicate carotid or ophthalmic artery occlusion.

9. Mention the differential diagnosis of CRAO.

- i. Acute ophthalmic artery occlusion (usually no cherry-red spot)
- ii. Other causes of cherry-red spot like Tay-Sachs diseases, Neiman-Pick disease, some cone dystrophies, etc.
- iii. Berlin's edema
- iv. Anterior ischemic optic neuropathy
- v. Inadvertent intraretinal injection of gentamycin.

10. What is cherry-red spot?

Cherry-red spot at the macula is a clinical sign seen in the context of thickening and loss of transparency of the retina at the posterior pole. The fovea being the thinnest part of the retina and devoid of ganglion cells, retains relative transparency, due to which the color of the choroids shines through.

In case of lipid storage diseases, the lipids are stored in the ganglion cell layer of the retina, giving the retina a white appearance. As ganglion cells are absent at the foveola, this area retains relative transparency and contrasts with the surrounding retina.

11. What are the causes of cherry-red spot?

- i. CRAO
- ii. Sphingolipidoses like Gaucher's disease, Neimann-Pick disease, Tay-Sachs disease, Goldberg syndrome, Faber syndrome, gangliosidosis GM1-type 2, Sandoff's disease
- iii. Berlin edema/comotio retinae
- iv. Macular retinal hole with surrounding retinal detachment
- v. Quinine toxicity
- vi. Hollenhorst syndrome (chorioretinal artery infarction syndrome)
- vii. Cardiac myxomas
- viii. Severe hypertension
- ix. Temporal arteritis
- x. Myotonic dystrophy syndrome.

12. What are the systemic diseases associated with CRAO?

- i. Atheromatous vascular diseases
- ii. Diabetes mellitus
- iii. Hypertension
- iv. Cardiac valvular/occlusive disease
- v. Carotid occlusive disease
- vi. Compressive vascular disease
- vii. Blood dyscrasias
- viii. Embolic disease
- ix. Vasculitis
- x. Spasm following retrobulbar injection.

13. What are the ocular diseases associated with CRAO?

- i. Precapillary arterial loops
- ii. Optic disk drusen
- iii. Increased IOP

- iv. Toxoplasmosis
- v. Optic neuritis.

14. How do you treat a case of CRAO?

CRAO is an ophthalmic emergency. Treatment has to be instituted as soon as the diagnosis of CRAO is made even before work up of the case.

a. BRINGING DOWN THE IOP

- dislodges the embolus.
- produces retinal arterial dilation and increases retinal perfusion
 - a. Ocular massage
 - b. Paracentesis of anterior chamber
 - c. IOP lowering drugs.

b. VASODILATION

- a. Carbogen inhalation
- b. Retrobulbar or systemic administration of vasodilators.
- c. Sublingual nitroglycerin.

c. FIBRINOLYSIS

Mode and Effects of Treatment

i. OCULAR MASSAGE

- Done digitally or by direct visualization of the artery by using a contact lens (Goldmann lens)
- Compression of globe for approximate 10 seconds to obtain retinal arterial pulsation or flow cessation followed by 5 seconds of release which is continued for approximately 20 minutes
- Improvement of retinal blood flow is seen as re-establishment of continuous laminar flow and increase in width of blood column and disappearance of fragmented flow.

ii. ANTERIOR CHAMBER PARACENTESIS

- Causes sudden decrease in IOP. As a result the perfusion pressure behind the obstruction will push on an obstructing embolus.
Technique: Performed at the slit lamp using topical anesthesia with a twentyfive gauge needle.
Generally 0.1 to 0.2 ml of aqueous is removed.

iii. IOP LOWERING AGENTS

Act in the same mechanism as AC paracentesis.

- 500 mg of IV. acetazolamide
- 20% IV mannitol
- Oral 50% glycerol.

iv. VASODILATORS

- Carbogen(95% of O₂ + 5% CO₂ mixture).
Inhalation of 100% O₂ in the presence of CRAO produces a normal pO₂ at the surface of the retina via diffusion from the choroids.
CO₂ is a vasodilator and can produce increased retinal blood flow.
– In the absence of CO₂-O₂ mixture, rebreathing into a paper bag can be considered.
- Retrobulbar or systemic papavarine or tolazoline.
- Sublingual nitroglycerin.

v. FIBRINOLYTIC AGENTS

- Administered through supra orbital artery. This produces 100 times higher doses of fibrinolytic agent at the central retinal artery than IV administration due to retrograde flow into ophthalmic artery.
- Injection of urokinase into the internal carotid artery through femoral artery catheterization has been tried.
- Systemic thrombolysis using plasminogen has also shown improvement in CRAO patients.

WORK UP/INVESTIGATIONS

- i. A detailed history regarding hypertension, diabetes, cardiac diseases and other systemic vascular diseases, e.g. giant cell arteritis.
- ii. Check pulse (to rule out atrial fibrillation) and BP
- iii. ESR, FBS < glycosylated Hb < TC, DC, PT and APTT).
 - In young patients (< 50 yr) consider lipid profile, ANA, RF, FTA-ABS, serum electrophoresis, Hb electrophoresis and antiphospholipids antibodies.
- iv. Carotid artery evaluation digital palpation/duplex USG
- v. ECG, echo
- vi. FFA and ERG.

15. What is the FFA picture in CRAO?

- i. Delay in arterial filling.
- ii. Prolonged A-V transit time.
- iii. Complete lack of filling of arteries is unusual.
- iv. Choroidal vascular filling is usually normal in eyes with CRAO.
- v. If there is marked delay in choroidal filling in the presence of cherry-red spot—suspect ophthalmic artery occlusion or carotid artery occlusion.
- vi. Though the arterial narrowing and visual loss persists, the fluorescein angiogram can become normal after varying time following CRAO.

16. What is the ERG picture in CRAO?

- i. “b” wave diminution—due to inner retinal ischemia.
- ii. “a” wave is generally normal.

17. What are the causes of sudden visual loss?

A. Painless loss of vision:

- i. CRAO
- ii. Retinal detachment
- iii. Retrobulbar neuritis
- iv. Methyl alcohol poisoning
- v. Vitreous hemorrhage

B. Painful loss of vision:

- i. Acute congestive glaucoma
- ii. Optic neuritis
- iii. Traumatic avulsion of optic nerve
- iv. Meningeal carcinomatosis

6.8. RETINAL DETACHMENT (RD)

1. What are the layers of retina?

From outer to inner:

- i. Retinal pigment epithelium (RPE)
- ii. Layers of rods and cones
- iii. External limiting membrane
- iv. Outer nuclear
- v. Outer plexiform
- vi. Inner nuclear
- vii. Inner plexiform
- viii. Ganglion cell layer
- ix. Nerve fiber layer
- x. Internal limiting membrane.

2. Define macula.

It is an area of 4500 μ in size between the temporal around where the ganglion cells are 2 or more in layers.

3. Define fovea and foveola.

Fovea: is a depression in the inner retinal surface at the center of the macula with a diameter of 1.5 mm. Ophthalmoscopically it gives rise to an oval light reflex because of the increased thickness of the retina and internal limiting membrane at its border.

Foveola: forms the central floor of the fovea and has a diameter of 0.35 mm. It is the thinnest part of the retina, is devoid of ganglion cells and consists only of cones and their nuclei.

4. What are the layers of Bruch's membrane?

- i. Basement membrane of RPE
- ii. Inner loose collagenous zone
- iii. Middle layer of elastic fibers
- iv. Outer loose collagenous zone
- v. Basement membrane of the endothelium of the choriocapillaries

5. What are the layers of choroid?

Four layers from without inwards:

1. Suprachoroidal lamina(lamina fusca).
2. Stroma of choroids:
 - Outer layer of choroidal vessels → (Haller's layer)
 - Inner layer of choroidal vessels → (Sattler's layer)
3. Choriocapillaries
4. Bruch's membrane or lamina vitrae.

6. What is the blood supply of choroid?

Posterior choroid upto the equator: Short posterior ciliary arteries. These arise as 2 trunks from the ophthalmic artery. Each trunk divides into 10–20 branches which pierce the sclera around the optic nerve and supply the choroid in a segmental manner.

Anterior choroid: Recurrent ciliary arteries, long posterior ciliary artery and anterior ciliary artery.

7. What is the blood supply of retina?

Outer four layers (pigment epithelium, layer of rods and cones, external limiting membrane and outer nuclear layer) get their nutrition from choriocapillaries.

Inner six layer (outer plexiform layer, inner nuclear layer, inner plexiform layer, layer of ganglion cells, nerve fiber layer and internal limiting membrane) get their blood supply from central retinal artery.

8. What is vitreous base?

Vitreous base straddles ora serrata, extending 1.5–2mm anteriorly and 1–3 mm posteriorly.

9. What are the normal attachments of vitreous to retina?

- i. Around vitreous base
- ii. Around the optic disk
- iii. Around the fovea
- iv. Around the peripheral blood vessels.

10. What is the composition of vitreous?

99% water with volume of 4 cc. Liquid phase contains hyaluronic acid. Collagen types—II, IX and XI.

11. What are the landmarks of vortex vein?

Vortex ampulae are located just posterior to the equator in the 1, 5, 7 and 11 o'clock meridian.

12. What are the landmarks of long posterior ciliary artery?

Yellow lines that start behind the equator and runs forward at 3 and 9 o'clock position with accompanying nerves.

13. How does a normal retina remain attached?

- i. An interphotoreceptor matrix between the cells forms a 'glue' that helps to maintain cellular apposition.
- ii. RPE function as a cellular pump, to remove ions and water from the interphotoreceptor matrix providing a 'suction force' that keeps the retina attached.
- iii. Vitreous acts as a tamponade.

14. What is syneresis?

Contraction of gel, which separates its liquid from solid component.

15. What is synchysis?

Liquefaction of gel.

16. What is a retinal break?

A retinal break is a full thickness defect in the sensory retina connecting the vitreous cavity and the potential or actual subretinal space.

They can be tears or holes.

- i. **Tears:** are caused by dynamic vitreoretinal traction.
- ii. **Holes:** caused by chronic atrophy of sensory retina and are less dangerous than tears.

Operculated holes: When a piece of retina has been pulled away from the rest of the retina and when this piece of retina attached to the detached vitreous face floats internal and anterior to the hole, the piece of retina is called operculum and the hole, an operculated hole.

17. What are the factors responsible for break?

- i. Dynamic vitreoretinal traction
- ii. Underlying weakness on peripheral retina due to predisposing degeneration.

18. Name the most common site of breaks.

Upper temporal quadrant (60%).

19. What is primary and secondary break?

Primary — break responsible for RD

Secondary— break not responsible for RD.

20. What is dialysis?

Dialysis is a circumferential tear along the ora serrata with vitreous gel attached to their posterior margin.

21. What is the most common site for dialysis in blunt trauma?

Upper nasal quadrant.

22. What are giant tear and horseshoe tear?

Giant tear: A tear involving 90° or more of the circumference of the globe. They have vitreous gel attached to the anterior margin of the break. Common site—immediate post-oral retina.

Horseshoe tear: is a retinal tear which takes the shape of a horseshoe with the ends pointing towards the ora. The tongue of retina inside the horseshoe is called a flap.

23. What are the peripheral retinal degenerations not associated with RD?

Benign peripheral retinal degenerations are:

- i. Peripheral cystoid degenerations
- ii. Snowflakes
- iii. Pavingstone degenerations
- iv. Honeycomb degenerations
- v. Drusen.

24. Which are the peripheral retinal degenerations which predispose to RD?

- i. Lattice degeneration
- ii. Snail track degeneration
- iii. Retinoschisis
- iv. White without pressure
- v. Diffuse chorioretinal atrophy.

25. What is lattice degeneration?

Lattice degeneration is sharply demarcated, circumferentially oriented, spindle shaped areas of retinal thinning. There is discontinuity of internal limiting membrane with variable atrophy of underlying sensory retina. It is present in 8% of normal population and 40% of patients with RD and commonly associated with myopia.

Commonest location: Between equator and posterior border of vitreous base, more in the superotemporal quadrant. Lattice may be complicated by retinal tears or atrophic holes. It should be treated prophylactically in those with past history of detachment in the fellow eye, family history of detachment, recently acquired horseshoe tears and aphakic patients.

26. What is snail track degeneration?

These are sharply demarcated bands of tightly packed snowflakes which gives the peripheral retina a white frost like appearance. Round holes may be seen in the snail track and overlying vitreous liquefaction may be present. Snail track degeneration is a predisposing condition for RD.

27. What is retinoschisis?

Horizontal splitting of the peripheral sensory retina into 2 layers, namely an

- i. Outer (choroidal layer) and
- ii. Inner (vitreous layer)

There are two main types:

A. Typical:

- a. Split is at the outer plexiform layer
- b. Does not extend posterior to the equator
- c. Outer layer is uniform
- d. Less transparent inner layer.

B. Reticular:

- a. Split is at the nerve fiber layer
- b. Extends posterior to the equator more often, may involve the fovea.
- c. Outer layer is not homogenous and may have dark areas
- d. Greater transparency of the inner layer

Seen in 5% normal population above 20 years, and common among hypermetropes. This is a predisposing condition for RD.

28. What is white with pressure (WWP)?

Translucent gray appearance of retina induced by indenting it.

29. What is white without pressure?

It is a gray appearance of retina even without indenting it.

30. What is posterior vitreous detachment (PVD)?

It is a separation of cortical vitreous from the internal limiting membrane (ILM). It may be complete or incomplete. Acute PVD may cause retinal tears, rhegmatogenous retinal detachment, avulsion of blood vessel in the periphery and vitreous hemorrhage.

31. What is Weiss ring?

Weiss ring is a solitary floater consisting of the detached annular attachment of vitreous to the margin of the optic disk.

32. What are the standard color codes used in fundus drawings?

- i. Detached retina —*blue*
- ii. Attached retina —*red*
- iii. Retinal veins —*blue*
- iv. Retinal breaks —*red with blue outlines*
- v. Flap of retinal tear —*blue*
- vi. Thinned retina —*red hatches outlined in blue*
- vii. Lattice degeneration —*blue hatches outlined in blue*
- viii. Retinal pigment —*black*
- ix. Exudates —*yellow*
- x. Vitreous opacities —*green*

33. What is retinal detachment (RD)?

Retinal detachment is defined as the separation of neurosensory retina (NSR) from the retinal pigment epithelium (RPE) with accumulation of fluid in the potential space between NSR and RPE.

34. What are the types of RD?

- i. Rhegmatogenous
- ii. Tractional
- iii. Exudative
- iv. Combined tractional and rhegmatogenous.

35. What is rhegmatogenous RD (RRD)?

Rhegma—break

RRD occurs secondary to a full thickness defect in the sensory retina which permits the fluid from synchitic (liquefied) vitreous to enter the subretinal space. There are two types of rhegmatogenous RD—primary and secondary.

Primary: retinal break has not been preceded by an antecedent condition (e.g. degenerations) and is usually preceded by PVD.

Secondary: retinal break has been preceded by an antecedent condition like lattice, etc.

36. What are the symptoms of RRD?

- i. **Flashes or photopsia:** due to vitreoretinal traction
- ii. **Floater:** due to microbleeding from retinal tear
- iii. **Field defects:** due to spread of subretinal fluid (SRF) posterior to equator.

37. What are flashes due to?

The perception of flashes or photopsia is due to the production of phosphenes by pathophysiologic stimulation of retina. During PVD, as the vitreous separates from the retinal surface, the retina is disturbed mechanically stimulating a sensation of light. Ocular migraine is a differential diagnosis.

38. What is the significance of floaters?

- i. Sudden appearance of one large floater near the visual axis is mostly due to PVD (Weiss ring)
- ii. Appearance of numerous curvilinear opacities within the visual field indicates vitreous degeneration
- iii. Floaters due to vitreous hemorrhage is characterized by numerous tiny black dots, followed by cobwebs as the blood forms clots.

39. What is the significance of visual field?

The quadrant of visual field in which field defect first appears is useful in predicting the location of primary retinal break (which will be in opposite quadrant). Patients tend to be less aware of superior field defects and hence patients with inferior RD may not be symptomatically aware. High bullous detachments cause dense field defects, while flat detachments produce relative field defects.

40. What are the symptoms perceived by a patient with acute vitreous hemorrhage?

Shower of floaters/reddish smoke.

41. What are the signs of fresh signs of RRD?

- i. Marcus Gunn pupil
- ii. IOP lowers by about 5 mm Hg than the other eye
- iii. Mild anterior uveitis.

- iv. Tobacco dusting in the vitreous
- v. Retinal breaks
- vi. Detached retina has a convex configuration and a slightly opaque and corrugated appearance with loss of underlying choroidal pattern.

42. Why is the intraocular pressure (IOP) decreased in certain RDs?

An eye with rhegmatogenous RD typically has decrease IOP and is due to the following factors:

- i. **Early transient pressure drop** may result from inflammation and reduced aqueous production.
- ii. **Prolonged hypotony** may be caused by posterior flow, presumably through a break in the RPE.

43. What is Schwartz syndrome?

RRD is typically associated with decreased IOP. Schwartz described a condition in which patient presents with unilateral intraocular pressure elevation, retinal detachment and open anterior chamber angle.

44. Why is IOP raised in certain RD's?

- Chronic low grade uveitis in RDs damage the trabecular meshwork
In long standing RDs
↓
Rubeosis iridis (NVI)
↓
Increased IOP.

45. What is “tobacco dusting”?

- Pathognomonic of RRD
- Present in the anterior vitreous phase
- The cells represent macrophages containing shed RPE.

46. What is the incidence of retinal detachment in myopes?

40% of all RDs occur in myopes.

47. What are the reasons for high myopes to have RRD?

- i. Increased stretch of the retina over the bigger eye ball
- ii. Incidence of lattice generation is higher
- iii. Incidence of PVD is higher
- iv. Macular hole
- v. Vitreous loss during cataract surgery
- vi. Diffuse chorioretinal atrophy.

48. Which are the systemic conditions associated with rhegmatogenous RD?

- i. Marfan's syndrome
- ii. Ehlers-Danlos syndrome
- iii. Stickler syndrome

- iv. Goldmann-Favre syndrome
- v. Homocystinuria

49. Why is detached retina gray?

Retina is transparent normally and the normal color of retina is due to the underlying choriocapillaries showing through the transparent retina. However, in detachment, the following factors make the retina look gray.

- i. Detached retina is away from capillaries
- ii. Presence of subretinal fluid
- iii. Retinal edema.

50. Why is configuration of SRF important?

Because SRF spreads in gravitational fashion and its shape is governed by anatomic limits (ora and optic nerve), it can be used to locate primary break.

51. What are the factors promoting SRF into the break?

- i. Ocular movements
- ii. Gravity
- iii. Vitreous traction, at the edge of the break.
- iv. PVD

52. What is Lincoff's rule?

SRF usually spreads in gravitational fashion and its shape is governed by anatomical limits and location of the primary retinal break. If the primary break is located superiorly, SRF first spreads inferiorly on the same side of the break and then spreads superiorly on the opposite side of the fundus.

- i. A shallow inferior RD in which SRF is slightly higher on the temporal side points to a primary break on that side.
- ii. A primary break at 6 o'clock will cause inferior RD with equal fluid levels.
- iii. In a bullous inferior RD, the primary break usually lies above the horizontal meridian.
- iv. If a primary break is in the upper nasal quadrant, the SRF will revolve around the optic disk and then rise on the temporal side until it is level with the primary break.
- v. A subtotal RD with a superior wedge of attached retina points to a 1° break located in the periphery nearest its highest borders.
- vi. When the SRF crosses the vertical midline above the primary break is near to 12 o'clock the lower edge of the RD corresponding to the side of the break.

53. How does a RD progress?

They can go through any of the following patterns:

- i. Usually most detachments progress to total detachments
- ii. 'Stable detachment' form demarcation lines and does not settle (commonly in inferior breaks)

- iii. Settling of retinal break spontaneously, [only superior retinal breaks] as RD settles inferiorly the site of original break flattens
- iv. Rarely by scarring, spontaneous closure of retinal hole may occur resulting in reattachment.

54. What are late secondary changes in RD?

- i. Retinal thinning.
- ii. proliferative vitreoretinopathy (PVR) changes
- iii. subretinal demarcation line (3 months)
- iv. Intraretinal cyst formation (1 year)
- v. Pigmentation

55. What are demarcation lines?

Demarcation line is formed due to pigment epithelial proliferation and migration at the boundary of the detached and attached retina and is a sign of the chronicity of the condition. It takes about 3 months for the demarcation lines to develop.

56. What is vitreoretinal traction?

It is the force exerted on the retina by structures originating in the vitreous.
Types:

- i. Dynamic—It is induced by rapid eye movement, where there is a centripetal force towards the vitreous cavity. Responsible for retinal tears and rhegmatogenous RD.
- ii. Static—Independent of ocular movements and plays an important role in pathogenesis of tractional RD and proliferative vitreoretinopathy.

It may be:

- i. Tangential → epiretinal fibrovascular membranes
- ii. Anteroposterior traction → contraction of fibrovascular membranes
- iii. Bridging (trampoline) traction → contraction of fibrovascular membranes which stretch from one part of the posterior retina to another or between vascular arcades which tends to pull the 2 involved points together.

57. What is tractional retinal detachment (TRD)?

Tractional RD occurs when the neurosensory retina is pulled away from the RPE by contracting vitreoretinal membranes in the absence of a retinal break.

58. What are the conditions causing tractional RD?

- i. Diabetes
- ii. Trauma
- iii. Vascular occlusions
- iv. Cataract extraction with vitreous incarceration
- v. Perforating or penetrating injury to the globe
- vi. Sickle cell hemoglobinopathies
- vii. Retrolental fibroplasia
- viii. Persistent hyperplastic primary vitreous (PHPV)
- ix. Pars planitis

- x. Eales' disease
- xi. Toxoplasma, toxocara infections.

59. What is the pathogenesis of exudative RD?

Diseases of choroids and retina



Damages RPE



Allow passage of fluid (transudate) from choroids into subretinal space.

60. What are the causes of exudative RD?

- a. **Inflammatory:**
 - VKH
 - Peripheral uveitis
 - Excessive cryopexy
 - Extensive photocoagulation
 - Choroidal effusion
- b. **Systemic:**
 - Renal failure
 - Hypertension
 - Dysproteinemia and macroglobulinemia
- c. **RPE defect:**
 - RPE detachment
 - CSR
- d. **SRNV:**
 - ARM
 - Presumed histoplasmosis
 - Angioid streaks
 - Choroidal rupture.
- e. **Tumors:**
 - Malignant melanoma
 - Metastasis
 - Retinoblastoma

61. How do you differentiate between the three types of RD?

Rhegmatogenous, tractional and exudative.

	Rhegmatogenous	Exudative	Tractional
History	Photopsia visual field defects	Systemic factors such as malignant hypertension, eclampsia, and renal failure	Diabetes, penetrating trauma, sickle cell disease,
Retinal break	Present	No break or coincidental	No primary break May develop secondary break
Extent of detachment	Extends to ora early	Gravity dependent, extension to ora is variable	Frequently does not extend to ora

Contd...

Contd...

	Rhegmatogenous	Exudative	Tractional
Retinal motility	Undulating bulla or folds	Smoothly elevated bullae, usually without folds	Taut retina, concave surface. Peaks to traction points.
Retinal elevation and Shape	Low to moderate; Convex sometimes;	Varies—may be extremely high Concave Convex	Elevated to level of focal traction;
Evidence of chronicity	Demarcation lines, intraretinal macrocysts, atrophic retina	Usually none	Demarcation lines.
Pigment in vitreous	Present in 70% of cases	Not present	Present in trauma cases
Vitreous changes	Frequently synergetic, posterior vitreous detachment, traction on flap of tear	Usually clear, except uveitis	Vitreoretinal traction
Subretinal fluid	Clear	May be turbid and shift rapidly to dependent location with changes in head position	Clear, no shift
Choroidal mass	None	May be present	None
Intraocular pressure	Frequently low	Varies	Usually normal
Transillumination	Normal	Blocked transillumination if pigmented choroidal mass is present	Normal
Examples of conditions causing detachment	Peripheral retinal degeneration, PVD, CMV retinitis, Stickler syndrome, Marfan's syndrome, Ehlers-Danlos syndrome	Uveitis, metastatic tumor, malignant melanoma, Coat's disease, Vogt-Koyanagi-Harada syndrome, Retinoblastoma	Proliferative diabetic retinopathy, retinopathy of prematurity, toxocara, sickle cell retinopathy, posttraumatic vitreous traction

62. What is the differential diagnosis of leukokoria?**I. Congenital:**

- a. Norrie's disease
- b. Incontinentia pigmenti
- c. Autosomal dominant exudative vitreoretinopathy

II. Developmental:

- a. Retinopathy of prematurity
- b. Myelinated nerve fiber layer
- c. Coloboma
- d. Persistent hyperplastic primary vitreous (PHPV)
- e. Congenital cataract

III. Inflammatory:

- a. CMV retinitis
- b. Toxoplasma
- c. Toxocara

IV. Tumor:

- a. Retinoblastoma

V. Vasculitis:

- a. Coat's disease

VI. Others:

- a. Retinal detachment
- b. Vitreous hemorrhage

63. What are the conditions exhibiting abnormal retinal embryogenesis?

- i. Retinal dysplasia
- ii. Norrie's disease
- iii. Fundus coloboma
- iv. Optic nerve pits
- v. Persistent fetal vasculature

64. What are the diseases which simulate retinal detachment?

- i. Retinoschisis
- ii. Choroidal detachment
- iii. Vitreous hemorrhage
- iv. Endophthalmitis
- v. Melanoma of choroid with exudative detachment
- vi. Intraocular cysticercosis
- vii. Uveal effusion syndrome
- viii. Severe vitritis

65. What are the complications of long standing RD?

- i. Uveitis
- ii. Complicated cataract
- iii. Rubeosis iridis
- iv. Glaucoma
- v. Band keratopathy
- vi. Phthisis

66. What are the types of traumatic RD?

- i. Tractional
- ii. Rhegmatogenous
- iii. Combined.

67. What is the pathogenesis of traumatic RD?

Penetrating trauma → vitreous incarceration at the site of penetration injuries



Vitreoretinal traction

The weakest area is in the temporal periphery.

Blunt trauma → compression of AP diameter of globe and simultaneous expansion at equatorial plane. It can cause retinal dialysis (frequent in the upper nasal quadrant) or can cause macular or equatorial holes.



Causes



Dialysis, tears (equatorial), macular holes

68. How to differentiate between rhegmatogenous retinal detachment and retinoschisis?

	Rhegmatogenous retinal detachment	Retinoschisis
Symptoms	Photopsia and floaters are present	Photopsia and floaters are absent as no vitreoretinal traction
Visual field defect	Relative scotoma	Absolute scotoma
Detachment	Convex with undulated appearance with mobility	Convex, smooth, thin and immobile, localized
	Presence of tobacco dusting, demarcation and intraretinal cysts	Absence of such findings
Laser photocoagulation	Does not create burn due to underlying SRF	Will create a burn

69. Differentiate between retinal detachment and choroidal detachment clinically.

	RD	CD
Symptoms	Photopsia and floaters are present	Absent (no vitreoretinal traction)
Appearance	Convex, undulated, mobile on eye movements. Lighter in color	Brown, convex, smooth, bullous detachment which is relatively immobile. Darker in color.

Contd...

Contd...

	RD	CD
Macula	May be involved	Elevations do not extend to the posterior pole because they are limited by the firm adhesion between the suprachoroidal lamellae and sclera where the vortex veins enter the scleral canals
IOP	Normal/low	Very low.
Periphery examinations	Scleral indentation required for periphery examination	Peripheral retina and ora serrata may be seen without scleral indentation
Anterior chamber	Normal depth	Shallow

70. How do you classify proliferative vitreoretinopathy (PVR) changes associated with RD?

Modified Retina Society Classification/Silicone Study Classification		
Grade	Name	Clinical sign
A	Minimal	Vitreous haze, vitreous pigment clumps
B	Moderate	Wrinkling of inner retinal surface, rolled edge of retinal break, retinal stiffness, tortuosity, ↓ motility of vitreous
CP 1–12 (clock hours)	Marked	Posterior to equator focal, diffuse or circumferential full thickness folds, subretinal strands
CA 1–12 (clock hours)	Marked	Anterior to equator focal, diffuse, circumferential full thickness folds, subretinal strands, anterior displacement, anterior condensed vitreous strands
D	Massive	Fixed retinal folds in 4 quadrants; D-1 wide funnel shape; D-2 narrow funnel shape; D-3 closed funnel (optic nerve head, not visible)

71. What are the factors governing visual function following surgical reattachment?

If the macula has been involved the prognosis is poorer. It is especially more poorer if

- i. The time of involvement is more than 2 months
- ii. Height of macular detachment and age > 60 years negatively affect visual restoration.

72. What is the principle of retinal detachment surgery?

- i. Identify all the breaks (See the break)
- ii. Create a controlled injury to the retinal pigment epithelium and retina to produce a chorioretinal adhesion at the site of all retinal breaks (Seal the break).

- iii. Employing an appropriate technique such as scleral buckling and/or intravitreal gas to approximate the retinal breaks to the underlying treated retinal pigment epithelium.

73. What is an explant?

Buckling element (silicon) sutured directly onto the sclera to create a buckle height.

74. What is an implant?

Buckling element placed within the sclera to create a buckle height.

75. What are the types of buckles used?

- i. Radial explant: placed at right angles to limbus
- ii. Sequential circumferential explants: placed circumferentially to limbus to create a sequential buckle.
- iii. Encircling circumferential explants: 360° buckle
- iv. Soft silicon sponges for radial or circumferential buckling.
- v. Hard silicon straps: used for 360° buckling
- vi. Hard silicon tyres.

76. What are the indications for radial buckling?

- i. Large U shaped tears, particularly when 'fish mouthing' is anticipated (especially if it is a single break)
- ii. Posterior retinal breaks.

77. What are the indications for segmental circumferential buckling?

- i. Multiple breaks located in one or 2 quadrants and varying distance from ora serrata
- ii. Anterior breaks
- iii. Wide breaks, dialysis and giant tears.

78. What are the indications for encircling buckle (360°)?

- i. Break involving 3 or more quadrants
- ii. Extensive RD without detectable breaks particularly in eyes with hazy media
- iii. Lattice degeneration, snail track degeneration involving 3 or more quadrants
- iv. Along with vitrectomy.

79. What are the preliminary examinations to be done before surgery?

- i. Check all clinically important lesions to see if it is correctly indicated in drawing.
- ii. Assess retinal mobility by moving eye with squint hook. Good retinal motility indicates absence of significant PVR and hence carries a good prognosis.
- iii. Try to appose the retinal break, to the RPE by indenting the sclera with squint hook; if this can be done with ease, drainage of SRF may not be necessary.

- iv. Assess the dimensions of retinal breaks, by comparing them with the diameter of optic nerve head (1.5 mm)
- v. Assess whether the break is anterior or posterior to the equator.

80. What are the steps in scleral bucking surgery?

- i. Preliminary examination
- ii. 360° peritomy
- iii. Traction (bridle) sutures around the recti
- iv. Inspection of sclera
- v. Localization of the break
- vi. Cryotherapy
- vii. Scleral buckling
- viii. Drainage of SRF
- ix. Intravitreal air or BSS injection
- x. Closure of the peritomy

81. What precautions should be taken during peritomy?

Care should be taken not to damage the plica semilunaris, tears in conjunctiva and muscle.

82. What is the purpose of bridle sutures?

- i. To stabilize the globe
- ii. To manipulate it into optimal position during surgery.

83. How do you take bridle sutures?

- i. Insert a squint hook under rectus muscle
- ii. Pass a reverse mounted needle with a 4-0 black silk suture under the muscle tendon
- iii. Secure the suture by twisting it around the forceps and cut externally

84. What are the complications associated with taking bridle suture?

- i. Damage to vortex veins
The inferior vortex veins are more anteriorly placed, and can be damaged by a posterior insertion of squint hook under inferior rectus. If vein is damaged, do not cauterize, wait for bleeding to stop.
- ii. Rupture of muscle belly due to excessive traction on the sutures
- iii. Muscle disinsertion.

85. What is the purpose of examining sclera?

A. To detect scleral thinning:

It is characterized by gray color due to underlying choroids. Complications due to it are:

- a. Penetration of the needle into choroid and retina while the scleral bite is taken.
- b. Sutures may cut through the thin sclera after the sutures are tied.

B. To detect anomalous vortex veins:

As it can be damaged during cryotherapy, scleral buckling and SRF drainage.

86. What are the 3 modalities used for prophylaxis of retinal detachment?

- i. Cryotherapy
- ii. Laser photocoagulation
- iii. Scleral buckling for large tears.

87. What are the principles in the prophylactic management of retinal breaks?

- i. **Breaks needing treatment:** Aphakic eyes, symptomatic tear, any break with SRF more than 1 DD, any break greater than one clock hour, family history of RD
- ii. **Breaks needing only observation:** Asymptomatic holes, asymptomatic tears.

88. What is the principle of cryotherapy?

Cryotherapy causes freezing of the intracellular and extracellular water to ice. This leads to tissue death and sterile inflammatory reaction. Scarring will result in stronger than normal bond between the sensory retina, RPE and choroids. This permanently seals the break.

89. What are the indications for cryotherapy of retinal breaks? What is the temperature generated by cryoprobe and what is the probe size?

Indications:

- i. Hazy ocular media
- ii. Peripherally located tears near the ora
- iii. Tears at the region of vortex veins and at the large ciliary vessels
- iv. Small pupils

Temperature of probe: -80°

Probe size: Standard size of 2.5 mm

90. What is the technique of cryotherapy?

- i. Using indirect ophthalmoscope locate the break
- ii. Indent the sclera gently with cryoprobe and bring the RPE as close as possible to the break
- iii. Start freezing until sensory retina has returned 'white'
- iv. Repeat cryo until the entire break has been surrounded.

Cryoprobe position is changed only after complete thawing.

91. How is laser retinopexy done?

- i. Laser source: Double frequency Nd:YAG, diode.
- ii. Instruments: Slit lamp or indirect ophthalmoscope, Goldmann 3 mirror lens or wide angle fundoscopic lens.
- iii. Spot size: 200–500 μ

- iv. Duration: 0.1–0.2 sec
- v. Power: 150–400 mW
- vi. Burn placement: ½ burn width apart for at least three rows. Lesion should be surrounded 360° or if closer to the ora, should be treated in U shaped pattern around the posterior edge of the lesion.

92. What are the indications for subretinal fluid (SRF) drainage?

- i. Difficulty in localization of retinal breaks in bullous detachments
- ii. Long standing RD as SRF is viscous
- iii. Bullous RD
- iv. Ganglion RD
- v. Glaucomatous cyclitis
- vi. Resurgeries

93. What are the methods of SRF drainage?

1. Prang: Here digital pressure is applied till central retinal artery is occluded and choroidal vasculature is blanched. Then full thickness perforation is made with 27 gauge hypodermic needle to drain SRF. Air is injected to form the globe.
2. Cut down: Radial sclerotomy is made beneath the area of deepest SRF. Mattress suture may be placed across the lips of the sclerotomy. Prolapsed choroidal knuckle is examined with +20D lens for large choroidal vessels. After ruling this out, light cautery is applied to knuckle to avoid bleeding and knuckle is perforated with 25 gauge hypodermic needle.

94. What are the advantages of SRF drainage?

It provides immediate contact between sensory retina and RPE with flattening of the fovea. If this contact is delayed, the stickiness of RPE wears off and adequate adhesion may not occur, resulting in nonattachment of retina.

95. What are the precautions taken before drainage of SRF?

- i. Examine the fundus to make sure, SRF has not shifted
- ii. Avoid vortex vein
- iii. IOP should not be elevated (it may cause retinal incarceration).

96. How do you know that SRF drainage is completed?

By the presence of pigments.

97. What are the complications of SRF drainage?

- i. Choroidal hemorrhage
- ii. Ocular hypotony
- iii. Iatrogenic break
- iv. Retinal incarceration
- v. Vitreous prolapse
- vi. Damage to long posterior ciliary arteries and nerves
- vii. Endophthalmitis.

98. What are the indications for internal tamponade in scleral buckling?

- i. Superior break
- ii. Hypotony
- iii. Retinal folds
- iv. Fish mouthing
- v. Posterior breaks

99. What are the causes of failed scleral buckling surgery?

- i. Improper positioning of buckle
- ii. Missed holes and iatrogenic inadvertent retinal perforations
- iii. Residual vitreous traction
- iv. PVR
- v. Infection and extrusion of buckle

100. What are the complications of scleral buckling and retinal detachment surgery?***Immediate***

- i. Failure to reattach retina
- ii. Iatrogenic break
- iii. CRAO
- iv. Anterior segment ischemia
- v. Excessive cryo resulting in exudative RD

Early

- i. Choroidal detachment
- ii. Vitritis
- iii. Bacterial endophthalmitis
- iv. Acute orbital cellulitis

Late

- i. Extraocular muscle (EOM) imbalance
- ii. Exposure of implant
- iii. Infection
- iv. Ptosis
- v. Maculopathy
- vi. Cataract
- vii. Proliferative vitreoretinopathy
- viii. Macular pucker

101. Who are the best candidates for pneumatic retinopexy?

- i. A detachment caused by a single break, in superior 8 clock hours
- ii. The break should not be more than 1 clock hour.
- iii. Multiple breaks but in 1–2 clock hours of each other
- iv. Free of systemic disease (rheumatoid arthritis) (who can maintain position)
- v. Phakic patients
- vi. Total PVD

102. Which are the cases not suitable for pneumoretinopexy?

- i. Breaks larger than one clock hour or multiple breaks extending over more than 1 clock hour of retina
- ii. Breaks in the inferior part of the retina
- iii. Presence of PVR, grade C and D, since this surgery does not relieve vitreoretinal traction.
- iv. Physical disability
- v. Severe uncontrolled glaucoma cloudy media.

103. How is this procedure done?

The eye to be treated is massaged well to reduce the IOP. Selected gas is drawn through a 0.22 μ Millipore filter. Injection is given, 4 mm posterior to the limbus in the region of pars plana temporally. The 30 gauge needle is directed towards the center of the vitreous to ensure penetration of the pars plana epithelium and the anterior hyaloid face. With the injection side uppermost and the needle is vertical, the gas is injected moderately. To prevent leakage, from the injection site, the head is turned to the opposite side.

104. What are the principles of pneumoretinopexy?

Intraocular gases keep the retinal break closed by the following properties:

- i. Mechanical closure and thus RPE pump removes excessive SRF.
- ii. Surface tension
- iii. Buoyancy

105. What are the complications of pneumoretinopexy?

- i. Subretinal migration of gas
- ii. Gas entrapment at the injection site
- iii. Iatrogenic macular detachment
- iv. New retinal breaks
- v. Vitreous incarceration in the paracentesis site
- vi. Subconjunctival gas
- vii. Cataract and glaucoma

106. What are the advantages and disadvantages of pneumatic retinopexy with that of scleral buckling?***Advantages of pneumoretinopexy:***

- i. Post operative vision is better
- ii. Morbidity is less
- iii. Attachment results are similar
- iv. Incidence of cataract is less
- v. Economical

Disadvantages:

- i. Need for post operative positioning
- ii. Needs closer monitoring.

107. What are the indications for vitrectomy in RD?

- i. PVR grade C2 or more
- ii. Giant retinal tear and dialysis
- iii. Posterior break
- iv. Associated with vitreous hemorrhage
- v. Combined RRD with TRD
- vi. Colobomatous detachment
- vii. Inadequate pupillary size
- viii. Associated cataract surgery
- ix. Associated intraocular foreign bodies.

108. What are the substances used as vitreous substitutes in RD surgery?**I. INTRAOCULAR GASES:**

<i>Nonexpansile</i>	<i>Expansile</i>
a. Air	a. SF6
b. SF6: Air mixture	b. C3F8
c. C3F8: Air mixture	

II. SILICON OIL**III. PERFLUOROCARBON LIQUIDS (PFCL)****109. What are the characteristics of intraocular gases?**

- a. **Air:** Average duration of action: 3 days.

Maximum size	: Immediate
Average expansion	: No expansion
Advantages	: Low cost and universal availability
Disadvantage	: Shorter time of action.
- b. **SF6:** Average duration of action: 12 days

Maximum size	: 36 hours
Average expansion	: Doubles
Advantages	: S-maller amount of gas required. No need for reinjecting the gas in case a new break develops.
Disadvantages	: Air travel contraindicated for a prolonged time
- c. **C3F8:** Average duration of action: 38 days

Maximum size	: 3 days
Average expansion	: Quadruples
Advantages and disadvantages	: Similar to SF6

110. What are the common silicon oils used?

- i. Polydimethyl siloxane (PDMS)
- ii. Trifluoromethyl siloxane.

111. What is the mechanism of action of silicon oils?

Silicon oils provide retinal tamponade for a larger period more than the intraocular gases. Since it is heavier than water, it allows subretinal fluid to drain through peripheral retinal break. It can act as a mechanical instrument to cleave planes and also acts as an internal tamponade.

112. What are the indications for the use of silicon oil?

- i. Retinal detachment complicated by PVR changes
- ii. Traumatic RD
- iii. Giant retinal tears
- iv. Tractional and combined retinal detachments
- v. RD associated with choroidal colobomas
- vi. RD associated with infectious retinitis.

113. What are the complications of silicon oil?

- i. Silicon oil migration under the retina
- ii. Suprachoroidal silicon oil
- iii. Silicon oil keratopathy
- iv. Inverse hypopyon
- v. Glaucoma
- vi. Vitreous floaters.

114. What are perfluorocarbon liquids (PFCL)?

They are fully fluorinated synthetic analogs of hydrocarbons containing carbon-fluoride bonds.

115. What are the characteristic of PFCL that enables them to be used as a vitreous substitute?

- i. Optical clarity
- ii. Similar refractive index that of water.
- iii. High density
- iv. Biologically inert
- v. High cohesive force.

116. What are the commonly used PFCL materials?

- i. Perfluor-n-octane
- ii. Perfluorotributylamine
- iii. Perfluorodecalin

117. What are the indications of PFCL?

- i. RD with PVR
- ii. RD with giant retinal tear
- iii. Traumatic RD
- iv. Lens/IOL dislocation into vitreous.
- v. Management of suprachoroidal hemorrhage.

118. Who is the father of RD surgery?

Jules Gonin—1923 treated retinal break by ignipuncture.

119. Who invented scleral buckling?

Custodis.

120. Who invented vitrectomy?

Machemer in 1971.

6.9. ENDOPTHALMITIS

1. Define endophthalmitis.

Endophthalmitis is an inflammation of the internal layers of the eye resulting from intraocular colonization of infection agents and manifesting with an exudation into vitreous cavity.

2. Classify endophthalmitis.

A. Based on route of entry:

- I. Exogenous: Pathogen is introduced from outside
 - a. Postoperative
 - b. Post-traumatic
- II. Endogenous: Pathogen is introduced from ocular circulation

B. Based on microorganisms:

I. Bacterial

a. Gram-positive

- *Staphylococcus epidermidis*
- *Staphylococcus aureus*
- *Streptococcus pneumoniae*
- *Streptococcus viridans*
- *Peptostreptococci*
- *Corynebacterium*
- *Propionibacterium acnes*
- *Actinomyces*

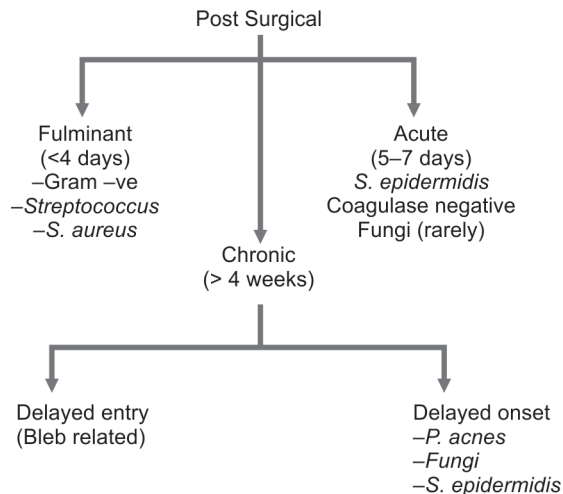
b. Gram-negative

- Pseudomonas aeruginosa*
- Proteus mirabilis*
- Klebsiella*
- Haemophilus influenzae*
- Escherichia coli*

II. Fungal

- *Aspergillus*
- *Candida*
- *Cephalosporium*
- *Penicillium*
- *Paecilomyces*

C. Based on duration:



3. What are the symptoms of endophthalmitis?

- i. Decrease in vision (94% in EVS study)
- ii. Pain
- iii. Tearing
- iv. Photophobia
- v. Redness
- vi. Blepharospasm

4. What are the signs of endophthalmitis?

- i. Lids: Edema
- ii. Conjunctiva: Chemosis, circumcorneal congestion
- iii. Cornea: May be clear or
Gross edema
Limbal ring abscess
Wound dehiscence
Suture abscess
- iv. Anterior chamber: Flare and cells
Hypopyon
Exudate
- v. Iris: Posterior synechiae
- vi. Pupil: Sluggish or absent pupillary reflexes
- vii. Vitreous: Cells and exudates.

Fundal glow

Grading of media clarity (based on EVS)

- i. >20/40 (6/12) view of retina
- ii. 2° order retinal vessel visible
- iii. Some vessels visible but not second order
- iv. No vessels visible
- v. No red reflex

5. What are the differential diagnosis of endophthalmitis?

Surgical

- i. Fibrinous reactions
- ii. Dislocated lens
- iii. Chemical response
- iv. Complicated surgery (manipulation)
- v. Microscopic hyphema
- vi. Phacoanaphylaxis

Nonsurgical

- i. Retained IOFB
- ii. Pars planitis
- iii. Old vitreous hemorrhage
- iv. Toxoplasmosis/toxocara
- v. Necrotic retinoblastoma

6. What is the role of USG in endophthalmitis?

To diagnose:

- i. Vitritis
- ii. Choroidal detachment
- iii. Retinal detachment
- iv. Dislocated lens/nucleus
- v. Radiolucent IOFB
- vi. Parasitic infestation

7. What are the common organisms implicated in traumatic endophthalmitis?

- i. *Bacillus* species
- ii. Gram-negative species (pseudomonas)
- iii. Fungi.

8. What are the common organisms implicated in endogenous endophthalmitis?

- i. *Candida*
- ii. *Neisseria*
- iii. *Bacillus*

9. What are the common organisms implicated in postoperative endophthalmitis?

- i. *Pseudomonas*
- ii. *Nocardia*
- iii. *S. epidermidis*
- iv. *Haemophilus influenza* (associated with bleb-related endophthalmitis).

9. Define “laboratory confirmed growth.”

- i. At least semiconfluent growth on solid media.
- ii. Any growth on more than or equal to 2 media
- iii. Growth on one media supported by gram-positive stain.

10. What are the objectives in endophthalmitis treatment?

Primary

- i. Control/eradicate infection
- ii. Manage complication
- iii. Restoration of vision

Secondary

- i. Symptomatic relief
- ii. Prevent panophthalmitis
- iii. Maintain globe integrity.

11. What are the important determinants in outcome?

- i. Time duration between onset of infection and presentation
- ii. Virulence and load of organism
- iii. Pharmacokinetics and spectrum of drug activity.

12. Modalities of treatment

Medical

- Antimicrobial
- Anti-inflammatory
- Supportive

Surgical

- Vitreotomy

13. What are the steps taken before intravitreal injection?

- i. Informed consent

- ii. Check if vision is at least perception of light
- iii. Echography
- iv. To check for wound integrity
- v. Suture abscess
- vi. Lens status
- vii. IOP

14. What are the materials for intravitreal injection?

- i. Clean glass slides
- ii. Culture places
- iii. Tuberculin syringe
- iv. 26 gauge half inch, 23 gauge 1 inch needle
- v. Antimicrobial vials
- vi. Lid speculum, sterile cotton tipped applicator
- vii. Topical xylocaine hydrochloride 4%.

15. What are the steps in intravitreal injection?

- i. Paint periocular region with povidone iodine and wash cul-de-sac with solution of same
- ii. Apply topical xylocaine hydrochloride 4% adequately
- iii. Visualize injection site from limbus (3.0 mm if aphakic, 3.5 mm if pseudophakic, 4 mm if phakic)
- iv. Stabilize globe and insert 26–30 gauge needle with bevel up towards anterior or mid vitreous.
- v. Inject drug drop by drop
- vi. If multiple drugs are to be given, replace syringe but not needle
- vii. Check IOP at end
- viii. Subcutaneous antibiotic is given and eye is patched.

16. What are the advantages of vitrectomy?

- i. Decrease infection and inflammatory load
- ii. Provides undiluted specimen for culture
- iii. Increases antimicrobial drug concentration within the eye
- iv. Enables rapid visual recovery by removing media opacities.

17. What are the cardinal principles in vitrectomy?

- i. Maximum cutting rate
- ii. Minimum suction
- iii. Do not attempt to induce PVD
- iv. Do not attempt to go close to retina.

18. What are the indications for vitrectomy in infectious endophthalmitis?

- i. Severe cases at manifestation defined as loss of red reflex, loss of light reflex, afferent pupillary defect and corneal ring infiltrate, etc.
- ii. All cases demonstrating gram negative bacteria in microbiology
- iii. Cases where vitreous infection precludes retinal examination
- iv. Vitreous abscess
- v. Cases not responding to initial medical therapy.

19. What are the causes of treatment failure?

- i. Late presentation/delayed diagnosis
- ii. Highly virulent organism
- iii. Drug resistance
- iv. Inadequate drug concentration
- v. Complications (RD)
- vi. Poor visibility for pars plana vitrectomy
- vii. Faulty diagnosis
- viii. Failure to recognize a nidus of infection, e.g. dacryocystitis.

Endophthalmitis Vitrectomy Study (EVS)**20. What was the main objective of the EVS?**

To determine role of early pars plana vitrectomy (PPV) in comparison to intravitreal injection in patients with postoperative endophthalmitis and also identify the role of systemic antibiotic treatment in these cases.

21. What were the outcome measures of this study?

Visual acuity and media clarity at the end of 3–9 month follow up.

22. Mention the inclusion and exclusion criteria for this study.**Inclusion criteria**

- i. Bacterial endophthalmitis within 6 weeks of cataract surgery or secondary IOL implantation.
- ii. Visual acuity of PL or better, but worse than 20/50 with relatively clear cornea and anterior chamber view.

Exclusion criteria

- i. H/O of other intraocular surgery
- ii. Presentation after 6 weeks
- iii. Fungal infection
- iv. Previous intraocular antibiotic
- v. Retinal and choroidal detachments
- vi. Drug sensitivity to lactams.

23. What were the drugs used in the study?**A. Intravitreal**

- i. Vancomycin (1000 µg in 0.1 ml)
 - ii. Amikacin (400 µg in 0.1ml)
- (No intravitreal corticosteroids were used)

B. Systemic

- i. Ceftazidime (2 g, 8 hourly)
 - ii. Amikacin (7–5 mg/kg BD)
- If allergic to lactams, oral ciprofloxacin 750 mg BD was used

C. Subconjunctival

- i. Vancomycin (25 mg/0.5 ml)
- ii. Ceftazidime (100 mg/0.5 ml)
- iii. Dexamethasone (6 mg/0.25 ml)

D. Topical

- i. Vancomycin (50 mg/ml) every 4 hr
- ii. Amikacin (20 mg/ml) every 4 hr

24. What were the major conclusions of study?

- i. There was no difference in final visual acuity or media clarity with or without the use of systemic antibiotics.
- ii. In patients whose initial visual acuity was hand motions or better, there was no difference in visual outcome whether or not an immediate vitrectomy was performed.
- iii. In patients with only light perception vision, vitrectomy was much better than intravitreal injections alone.

25. What is sterile post operative endophthalmitis?

This is caused by the following:

- i. Postoperative inflammation to retained lens matter
- ii. residual chemicals
- iii. toxicity of residual monomers on PMMA
- iv. mechanical irritation of iris and ciliary body

26. Most common organism in bleb-related endophthalmitis.

- i. *Streptococcus*
- ii. *Haemophilus influenzae*.

27. What is the mode of treatment in severe *P. acnes* infection?

- i. Vitrectomy
- ii. Total capsulectomy
- iii. IOL explantation combined with intraocular and systemic antibiotics

28. What are the organisms common in endogenous endophthalmitis?

Fungal	Bacteria
<i>Candida</i>	<i>Bacillus cereus</i>
<i>Aspergillus</i>	

29. What are the organisms common in post-traumatic endophthalmitis?

Bacterial	Fungal
<i>S. epidermidis</i>	<i>Fusarium</i>
<i>Bacillus cereus</i>	
In children	
<i>Streptococcal</i> species	

30. How does treatment of endogenous endophthalmitis differ from other types?

- i. Both bacterial and fungal in the initial phase are treated with intensive intravenous therapy.
- ii. Only if infection is not responding to medical intravenous therapy then intravitreal is considered.

31. What drug is contraindicated in endogenous endophthalmitis?

Corticosteroids.

32. How to prepare the commonly recommended intravitreal drugs in post operative endophthalmitis?**Antibacterial****A. Vancomycin hydrochloride (1000 µg in 0.1 ml)**

- i. The drug is available as a powder in strength of 500 mg.
- ii. Reconstitute this with 10 ml of sterile solution for injection or saline.
- iii. This gives a strength of 50 mg in 1 ml and hence 10 mg in 0.2 ml.
- iv. 0.2 ml of this drug is drawn into a tuberculin syringe and this is further diluted with 0.8 ml of sterile saline to give a strength of 10 mg in 1 ml and hence 1000 µg (1 mg) in 0.1 ml.

B. Ceftazidime hydrochloride (2.25 mg in 0.1 ml)

- i. The drug is available as a powder in a strength of 500 mg powder.
- ii. Reconstitute this with 2 ml of sterile saline solution for injection to give a strength of 250 mg in 1 ml (225 mg of active ingredient) and 25 mg (22.5 mg) in 0.1 ml.
- iii. 0.1 ml of the drug is drawn into a tuberculin syringe and diluted further with 0.9 ml of sterile solution to give a strength of 25 mg (22.5 mg) in 1 ml and hence 2.25 mg in 0.1 ml.

C. Cefazolin hydrochloride (2.25 mg in 0.1 ml)

Same as for ceftazidime.

D. Amikacin sulfate (400 µg in 0.1 ml)

- i. The drug is available as a solution in a strength of 100 mg in 2 ml vial (50 mg in 1 ml) and 10 mg in 0.2 ml.
- ii. 0.2 ml of the drug is drawn into a tuberculin syringe and diluted further with 2.3 ml of sterile solution to give a strength of 10 mg in 2.5 ml and hence 4000 µg in 0.1 ml.

E. Gentamicin sulfate (200 µg in 0.1 ml)

- i. The drug is available as a solution of 80 mg in 2 ml vial (40 mg in 1 ml) and 4 mg in 0.1 ml.
- ii. 0.1 ml of the drug is drawn into a tuberculin syringe and diluted further with 1.9 ml of solution to give a strength of 4 mg in 2 ml (2 mg in 1ml) and hence 200 µg in 0.1 ml.

Antifungal**A. Amphotericin B (5 μ g in 0.1 ml)**

- i. The drug is available as a 50 mg powder vial.
- ii. Reconstitute this with 10 ml of dextrose 5% to give a concentration of 5 mg per ml and 500 μ g in 0.1 ml.
- iii. Take 0.1 ml into a tuberculin syringe and dilute further with 9.9 ml of dextrose 5% to give a concentration of 500 μ g in 10 ml and 50 μ g per ml and 5 μ g in 0.1 ml.

Corticosteroids**A. Intravitreal dexamethasone (400 μ g in 0.1 ml)**

- i. The drug is available as a solution in strength of 8 mg in 2 ml vial (4 mg in 1 ml) and hence 0.4 mg (400 μ g) in 0.1 ml.
- ii. 0.1 ml of the drug may be withdrawn directly into a tuberculin syringe without any further dilution.

33. What are the recommended doses of systemic antibiotics in endogenous endophthalmitis?

Chloramphenicol—1–1.5 mg IV 6 hrly	Ceftaxime—2 g IV 4 hrly
Cefuroxime—3 g IV 8 hrly	Moxalactam—2–4 g IV 6–8 hrly
Ampicillin—2–4 g IV 4 hrly	Ceftizoxime—2 g IV 6 hrly
Vancomycin—500 mg IV 6 hrly	Penicillin G—2 mU IV 2 hrly.
Gentamicin—8 mg/kg/day IV	

Intravenous treatment should continue at least for a period of 10–14 days.

6.10. RETINITIS PIGMENTOSA

1. Define retinitis pigmentosa.

Retinitis pigmentosa is a clinically and genetically heterogeneous group of progressive hereditary disorders that diffusely and primarily affect photoreceptor and pigment epithelial function, and that are associated with progressive cell loss and eventually atrophy of several retinal layers.

2. What are synonyms of RP?

- i. Tapetoretinal degeneration
- ii. Primary pigmentary retinal degeneration
- iii. Pigmentary retinopathy
- iv. Rod-cone dystrophy
- v. Retinal dystrophy.

3. What is the prevalence rate of RP?

Between 1/3000 and 1/5000.

4. What is the earliest presentation of RP?

Nyctalopia (night blindness) and progressive visual field disturbances. By the age of 30 years more than 75% of the patients become symptomatic.

5. What are the causes of nyctalopia (night blindness)?

- i. ***Congenital stationary night blindness***
 - Presenting with normal fundus—AD, AR, X-linked forms
 - Presenting with abnormal fundus—Fundus albipunctatus, Oguchi's disease
- ii. ***Progressive night blindness***
 - Retinitis pigmentosa
 - Choroidal diseases like choroideremia, gyrate dystrophy, diffuse choroidal atrophy
 - High myopia
 - Progressive glaucoma
 - Retinitis punctata albescens
 - Vitamin A deficiency
 - Liver cirrhosis (alcoholic)
 - Tapetoretinal degenerations
- iii. ***Spurious night blindness***
 - Nuclear cataract
 - Postrefractive surgery

6. What is day blindness (hemeralopia)?

- i. Posterior subcapsular cataract
- ii. Hereditary retinoschisis
- iii. Intraocular iron

7. What are the causes of central vision loss in RP?

- i. Posterior subcapsular cataract
- ii. Cystoid macular edema
- iii. Cellophane maculopathy
- iv. Diffuse vascular leakage
- v. Macular preretinal fibrosis
- vi. RPE defects

8. What are the visual field defects in RP?

- i. **Paracentral scotoma:** starts 20° from fixation
- ii. **Ring scotoma:** Outer edge of the ring expands rapidly to the periphery while the inner ring contracts towards fixation.
- iii. **Constricted tunnel field of vision (tubular vision).**

9. What is the cause of ring like scotomas in the visual field?

The pigmentary changes extend both posteriorly and anteriorly giving rise to ring like scotoma in the visual field.

10. What are the conditions which can cause tubular vision?

- i. Retinitis pigmentosa
- ii. Glaucoma
- iii. High myopia
- iv. Aphakic glasses
- v. Extensive choroiditis
- vi. Extensive panretinal photocoagulation
- vii. Chronic atrophic papilloedema
- viii. Hysteria and malingering
- ix. Alcohol poisoning.

11. What are the diagnostic criteria for RP?

- i. Bilateral involvement
- ii. Loss of peripheral vision and night vision
- iii. Rod dysfunction
 - a. dark adaptation
 - b. ERG
- iv. Progressive loss in photoreceptor function.

12. Which photoreceptors are involved?

Both cones and rods involved, but rod is predominantly involved.

13. What is the mode of inheritance/genetic type?

- i. Sporadic 60%
- ii. Inherited 40%
 - AD—most common 43%
 - AR—20%
 - X-linked—uncommon 8%
 - Uncertain family history 6–8%
 - Digenic mode in some families.

14. Discuss the prognosis of inheritance pattern of RP.

- i. Best prognosis—AD
- ii. Worst prognosis—X-linked

15. What is the triad of RP?

- i. Arteriolar attenuation
- ii. Retinal bone spicule pigmentation
- iii. Waxy disk pallor.

16. What are the causes of retinal vessel attenuation?

The exact cause is unknown but it is thought to be a secondary change. It is thought to be the result of

- i. Increased intravascular oxygen tension due to decreased oxygen consumption by degenerating outer retinal layers
- ii. Closer proximity of retinal vascular network to the choroidal circulations as a result of retinal thinning.

17. What are the differential diagnosis of retinal vessel narrowing?

- i. Arteriosclerosis
- ii. Hypertensive retinopathy
- iii. Coarctation of aorta
- iv. Hyperbaric oxygen therapy
- v. Apparent narrowing (hypermetropia, aphakia)
- vi. Inflammatory disorders like temporal arteritis, polyarteritis nodosa.

18. What is the cause of 'bone spicule pigment deposits'?

Pigments getting released from the degenerating retinal pigment epithelium migrates into the inner retina and accumulates in the inner retina around the blood vessels, especially at the vessel branchings producing a perivascular cuffing and bone spicule pigment formation.

19. What are the conditions causing pigmentation in retina?

- i. Retinitis pigmentosa
- ii. Senile changes (degenerative pigmentation)
- iii. Inflammatory conditions like rubella, congenital syphilis (salt and pepper fundus), toxoplasmosis.
- iv. CMV retinitis
- v. Toxic: Chloroquine, phenothiazines, clofazamine
- vi. Iatrogenic: Photocoagulation, cryotherapy
- vii. Trauma
- viii. Spontaneously settled retinal detachment
- ix. Hereditary chorioretinal dystrophies like fundus flavimaculatus, pigmented paravenous chorioretinal atrophy
- x. Choroideremia
- xi. Peripheral retinal pigment degeneration.

20. What is the site of pigmentary deposition in the initial stages of RP?

It is found at the midperipheral, equatorial region of the fundus. This part of the retina is the one to develop first and according to the principle of abiotrophy undergoes degeneration first as well.

21. What are the conditions which cause consecutive optic atrophy (waxy disc pallor)?

- i. Retinitis pigmentosa
- ii. High myopia
- iii. Extensive photocoagulation
- iv. Diffuse chorioretinitis
- v. CRAO

22. What is the cause of waxy disc pallor in RP?

The waxy disk pallor is due to a thick preretinal membrane centered on the disc that extends over the retina in all quadrants. The preretinal membrane appears to originate from fibrous astroglial cells in the optic nerve. The reorganization of fibrous astrocytes into the thickened retinal membrane over the optic nerve could contribute to the appearance of waxy pallor of the optic disk.

23. What are the classic fundus appearance in a case of RP?

- I. Optic nerve changes
 - i. Variable waxy pallor disk
 - ii. Consecutive optic atrophy
- II. Vessel changes
 - Arteriolar narrowing
- III. General retinal changes
 - i. Pigment within the retina—generalized granularity or discrete
 - ii. Pigment clumps or bone spicule appearing pigment deposits
 - iii. A generalized mottling or moth-eaten pattern of the RPE
 - iv. A refractile appearance to the retina
- IV. Macular changes
 - Loss of foveal reflex
 - Maculopathy (3 types)
 - i. Atropic
 - ii. Cellophane
 - iii. CME
- V. Vitreous changes
 - Stage 1: Fine colorless dust particles
 - Stage 2: Posterior vitreous detachment
 - Stage 3: Vitreous condensation
 - Stage 4: Collapse

24. What are the changes in macula?

Three types of macular lesions

- i. Atrophy of the macular area with thinning of RPE and mottled transmission defects of fluorescein angiography
- ii. Cystic lesion or partial thickness holes within the macula with radial, inner retinal traction lines and or various degrees of preretinal membranes causing a 'surface wrinkling phenomenon' (cellophane maculopathy)
- iii. Cystoid macular edema and increased capillary permeability.

25. What are the vitreous particles seen in RP?

Fine melanin pigment granules, pigment granules, uveal melanocytes, retinal astrocytes and macrophages like cells.

26. What are the associated ocular features?

- i. Myopia
- ii. Keratoconus
- iii. Open-angle glaucoma
- iv. Posterior subcapsular cataract
- v. Optic disk drusen
- vi. Microphthalmus

27. What are the causes of cataract formation in RP?

It is possibly caused by pseudoinflammatory pigmental cells in the vitreous and is of the central posterior subcapsular variety. Ultrastructurally the cataracts of RP are not unique expect for focal epithelial degeneration, which may cause osmotic instability.

28. Discuss the theories of RP.

- i. Vascular theory
 - a. Sclerosis of choroid and choriocapillaries
 - b. Sclerosis of retinal vessels
- ii. Pigmentary theory
 - a. Changes in neuroepithelium and pigmentary epithelium
- iii. Abiotrophy
- iv. Premature seniling and death of cells of specified tissues—equatorial parts are affected first because it is the first to attain full development.

29. What are the variants of RP?

- i. **Inverse RP or central RP:**
Pigments are more seen centrally and the equatorial and peripheral retina may be spared.
- ii. **Sectoral RP:**
Pigmentary changes are confined to one quadrant. Visual function remains good for many years.
- iii. **RP with exudative vasculopathy:**
It is bilateral and consists of vascular anomalies, serous RD and lipid deposits in retinal periphery.

iv. **Unilateral RP:**

These are patients with unilateral pigmentary degeneration.

v. **RP sine pigmento:**

Typical symptoms and the presence of signs except pigmentary deposition.

vi. **Retinitis punctata albescens:**

Fine white punctate lesions in the mid periphery at the level of pigment epithelium with symptoms of RP.

30. What are the tests of visual function done in patients with RP?

i. **Electroretinogram (ERG)**

a. Very useful to determine early loss of photoreceptor function

b. Prognostic information in some cases of RP

c. Useful in evaluating therapeutic modalities of retinal dystrophies

ii. **Dark adaptations and visual sensitivity:**

To measure visual sensitivity, a test light positioned on a given area of the retina is dimmed to a sub-threshold level and is then made gradually brighter. The intensity at which it is perceived is defined as visual threshold and may be expressed in log units.

Dark adaptation involves the measurement of the absolute thresholds at given time intervals as the retina adapts to the dark. The Goldmann-Weekers adaptometer is the most commonly used.

iii. **Visual fields**

iv. **Fundus reflectometry**

Useful technique for quantitative assessment of photopigment regeneration

v. **Contrast sensitivity:**

It is a more sensitive test of macular function

vi. **Electro-oculogram (EOG):**

The EOG is thought to measure the functions of both the photoreceptors and retinal pigment epithelium. Although EOG is abnormal in RP even in early stages, ERG is more preferred.

vii. **Visually evoked response**

viii. **Fluorescein angiography:**

It is useful in patients with exudative vasculopathy and cystoid macular edema.

ix. **Vitreous fluorophotometry:**

It is a method of evaluating the blood retinal barrier by quantifying the leakage of fluorescein from retinal vessels into the posterior vitreous. It is useful to detect abnormality of the blood retinal barrier. Patients with RP have a marked elevation of the dye concentration in the vitreous.

31. How is ERG useful in RP?

- i. Patients with advanced RP have non-detectable rod and cone responses

- ii. In patients with early disease, a and b waves generated by the photoreceptors in response to white light under dark-adapted conditions are reduced in amplitude
- iii. In all genetic subtypes of RP, the pure rod responses have “b” wave amplitudes which are non- detectable or reduced with either prolonged or normal implicit times.

32. What is non-detectable ERG?

Defined as less than 10 micro volts.

33. What are the conditions which can cause nonrecordable ERG?

- i. Leber’s congenital amaurosis
- ii. Retinal aplasia
- iii. Retinitis pigmentosa
- iv. Total retinal detachment.

34. What are histopathological changes of RP?

- i. Rod and cone outer segments—shortened and disorganized (but inner segment remains (normal)
- ii. In the area of visual loss from RP, there is total loss and decrease in photoreceptor number
- iii. Pigmented cells invade the retina.
- Typical RPE cells away from the RPE layer and macrophage like cells that contain melanin also found in retina.

35. What are the systemic associations with RP?

- i. ***Usher’s syndrome:***
Congenital sensory neural deafness with RP
- ii. ***Lawrence-Moon-Biedel syndrome:*** components are
 - Retinal dystrophy
 - Mental retardation
 - Truncal obesity
 - Hypogonadism
 - Polydactyly
- iii. ***Cockayne syndrome:***
RP with infantile onset of growth failure, cutaneous photosensitivity to UV light, cachexia, dementia, cerebellar dysfunction and joint contractures
- iv. ***Alstrom syndrome:***
Cone-rod dystrophy, interstitial nephropathy, progressive sensory neural deafness.
- v. ***RP with neurological disorders:***
These are lysosomal storage diseases with accumulation of insoluble autofluorescent lipopigments in a variety of tissues. They are characterized by symptoms of RP along with cerebellar degeneration and extrapyramidal signs. They are of the following types:
 - Infantile form: Haltia-Santavuori syndrome

- Late infantile form: Jansky-Bielschowsky syndrome
- Juvenile form: Batten-Spielmeyer-Vogt's syndrome
- Hallervorden-Spatz syndrome
- vi. ***Spinocerebellar degenerations (Pierre-Marie's hereditary cerebellar ataxia)***
- vii. ***Kearns-Sayre syndrome (mitochondrial myopathy)***
Pigmentary degeneration of the retina, external ophthalmoplegia and complete heart block.
- viii. ***Refsum's syndrome (phytanic acid storage disease)***
RP with peripheral neuropathy, cranial neuropathy, cerebellar involvement, cardiomyopathy and sudden death.
- ix. ***Mucopolysaccharidosis: Sanfilippo's and Schie's syndrome***
- x. ***Abetalipoproteinemia Bassen-Kronzweig syndrome***
RP with infantile steatorrhea and failure to thrive.

36. What are the types of Usher's syndrome?

Type I: Congenital, bilateral sensorineural deafness and no intelligible speech.

Type II: Nonprogressive moderate to profound congenital sensory neural hearing impairment and late manifestation of RP

Type III: Type I patients with ataxia.

37. How do you manage a case of RP?

- i. Clinical evaluation and investigation
- ii. Treatment of allied conditions
- iii. Low vision aids
- iv. Genetic counseling
- v. Psychological and vocational counseling

38. Discuss the treatment of RP.

- ***Surgical procedures***
 - i. To increase retinal blood flow
 - ii. Injections of vitamins and minerals, vasodilators, penicillamine, tissue therapy with placental extract, cortisone, transfer factor, muscle transplant.
- ***Topical therapy***
Dimethyl sulfoxide
- ***Injections***
 - i. Yeast RNA and subretinal injections to fetal retinal cells
 - ii. Beneficial effects of 15,000 IU/day of vit A has been reported
- ***Light deprivation***
Dark glasses during outdoor activities—CPF (corning photochromatic filter)
- ***Optical aids***
 - a. ***Mirrors and prisms*** mounted on spectacles for peripheral field expansion

b. *Field expanders*

- Drawbacks like distortion of depth perception

c. *Reverse Gallilean telescopes*

- Diminish central visual acuity to an unacceptably low level

d. *Low vision aid*

- Magnifiers and closed circuit television

e. *Image intensifiers***f. *High intensity lantern*****39. What are the recent treatment modalities in RP?**

- Retinal chip research
- Stem cell
- Gene therapy
- Analysis of leukocyte DNA
- Hormone estrogen injection

6.11. RETINOBLASTOMA (RB)

1. What is the most common intraocular malignancy of childhood?

Retinoblastoma.

2. What are the other common childhood malignancies?

- i. Rhabdomyosarcoma
- ii. Neuroblastoma
- iii. Ewing's sarcoma
- iv. Wilms' tumor.

3. What is the incidence of retinoblastoma?

- i. 1 in 17,000 live births in western countries.

4. What are the modes of presentations?

- i. Heritable—40%
- ii. Non-heritable—60%

5. What is the pathogenesis?

RB1 tumor suppressor gene is located on long arm of chromosome 13 at region 14. It codes for RB nucleoprotein, which normally suppresses cell division. Any mutation in RB gene will cause retinoblastoma.

6. What are the non-ocular cancers common in heritable retinoblastoma?

- i. Pinealoma
- ii. Osteosarcoma
- iii. Melanoma
- iv. Malignancies of brain, lungs.

7. From where does it arise?

It arises from primitive retinal cells before differentiation.

8. What is the common age of presentation?

First year of life in bilateral cases

Second year of life in unilateral cases.

9. Why is retinoblastoma seldom seen after 3 years of age?

Primitive retinal cells disappear within first few years of life.

10. What are the patterns of tumor spread?

- i. Endophytic (vitreous): Retina is not detached
- ii. Exophytic(subretinal space): Retina is detached
- iii. Optic nerve invasion
- iv. Diffuse infiltration of retina
- v. Metastasis.

11. What is the histopathological hallmark of differentiated retinoblastoma?

Rosettes formation.

12. Describe Flexner-Wintersteiner rosette.

It is an expression of retinal differentiation. Cells surround a central lumen lined by refractile structure. Refractile lining corresponds to external limiting membrane of retina. It is characterized by single row of columnar cells with eosinophilic cytoplasm and peripherally situated nuclei.

13. Describe Homer-Wright rosette.

It consists of cells which form around a mass of neural fibers. No lumen is present.

14. What are the differences between Flexner-Wintersteiner and Homer Wright rosettes?

Flexner-Wintersteiner rosette	Homer-Wright rosette
It consists of columnar cells around central lumen	It consists of cells around a mass of neural fibers. No lumen is present.
Hyaluronidase is present	Hyaluronidase is absent
It is also seen in medulloepithelioma	It is also seen in neuroblastoma, medulloblastoma, medulloepithelioma

15. What are fleurettes?

Cluster of tumor cells with long cytoplasmic processes project through a fenestrated membrane and resembles a bouquet of flowers. It represents photoreceptor differentiation.

16. What are the presenting features of retinoblastoma?

- i. Leukokoria (white reflex in the pupillary area)
- ii. Strabismus
- iii. Vitreous opacity
- iv. Pseudohypopyon
- v. Iris heterochromia
- vi. Spontaneous hyphema
- vii. Inflammation mimicking orbital cellulitis
- viii. Vitreous hemorrhage
- ix. Glaucoma
- x. Corneal edema
- xi. Proptosis

17. What is the differential diagnosis of leucocoria?

- i. Persistent hyperplastic primary vitreous (PHPV)
- ii. Coats' disease
- iii. Toxocariasis
- iv. Retinopathy of prematurity (ROP)

- v. Coloboma of choroid
- vi. Cataract
- vii. Vitreous hemorrhage (VH)
- viii. Retinal detachment (RD)
- ix. Retinal dysplasia

18. What are the signs of regression in case of endophytic retinoblastoma?

- i. Pigmented atrophic ring at the circumference of tumor
- ii. Translucency of tumor

19. What are the predictive factors of metastasis?

- i. Orbital invasion
- ii. Optic nerve invasion
- iii. Massive choroidal invasion
- iv. Tumor volume $>1 \text{ cm}^3$

20. What are the investigations useful in diagnosis of retinoblastoma?

- i. X-ray skull
- ii. USG
- iii. MRI
- iv. Specular microscopy (seeding of tumour cells in the endothelium).

21. What are the features of retinoblastoma in X-ray?

- i. Expansion of optic canal
- ii. Diffuse or finely stippled calcification.

22. How does USG help in cases of retinoblastoma?

- i. Tumor dimension
- ii. Orbital shadowing
- iii. Calcification
- iv. Helpful in hazy media.

23. How does CT help?

- i. To determine the size, extraocular extent of tumor
- ii. Calcification
- iii. Optic nerve evaluation.

24. How does retinoblastoma present in MRI?

- i. Hyperintense in T1 weighted images
- ii. Hypointense in T2 weighted images.

25. What are the investigations contraindicated in retinoblastoma?

FNAC and incisional biopsy are contraindicated. It may lead to tumor seeding into orbit.

26. Describe the types of retinoblastoma based on USG.

- i. Solid—early lesion
- ii. Cystic—advanced tumor cells floating in vitreous.

27. What are the inflammatory conditions that mimic retinoblastoma?

- i. Toxocariasis
- ii. Posterior uveitis
- iii. Orbital cellulitis
- iv. Congenital toxoplasmosis.

28. What are the neoplastic conditions that mimic RB?

- i. Retinal astrocytic hamartoma
- ii. Medulloepithelioma
- iii. Leukemia
- iv. Rhabdomyosarcoma

29. Name a few diseases having intra-ocular calcification.

- i. Retinoblastoma
- ii. Toxoplasmosis
- iii. Tuberculosis
- iv. Cysticercosis
- v. Syphilis
- vi. Toxocaral endophthalmitis
- vii. Coats' disease.

30. What are the classification systems used in retinoblastoma?

- i. Reese-Ellsworth classification
- ii. International classification system.

31. What is international classification?

Group A (Very low risk)	Small tumor <3 mm confined to retina; 3 mm from fovea, 1.5 mm from optic disk
Group B (Low risk)	Tumor > 3 mm confined to retina in any location with clear SRF <6 mm from tumor margin
Group C (Moderate risk)	Localized vitreous subretinal seeding (> 6 mm in total from tumor margin). If there is more than 1 site of subretinal/vitreous seeding, then total of these sites must < 6 mm.
Group D (High risk)	Diffuse vitreous and/or subretinal seeding (>6 mm in total from tumor margin). If there is more than 1 site of subretinal/vitreous seeding, then total of these sites must > 6 mm SRF > 6 mm from tumor margin
Group E (Very high risk)	No visual potential or any one of the following: <ol style="list-style-type: none"> 1. tumor in anterior segment 2. tumor in ciliary body 3. NVG 4. VH obscuring tumor of significant hyphema 5. phthisical or pre-phthisical 6. orbital cellulitis like presentation.

32. What are the various treatment modalities available for RB?

- i. Enucleation
- ii. Chemotherapy
- iii. Radiotherapy
- iv. Cryotherapy
- v. Transpupillary thermotherapy
- vi. Photocoagulation.

33. How do you plan to treat retinoblastoma?

- i. Unilateral nonheritable retinoblastoma:
 - Group A: Photocoagulation and cryotherapy
 - Group B: 3–4 cycles of chemotherapy. Solitary lesion can be treated using a radioactive plaque
 - Group C: 6 cycles of chemotherapy
 - Group D: Enucleation
- ii. Bilateral retinoblastoma: Symmetrical disease
 - Group A: Photocoagulation and cryotherapy
 - Group B to C: Same treatment like unilateral disease
 - Group D: 6 cycles of three drug chemotherapy
- iii. Bilateral retinoblastoma: Asymmetrical disease.
 - If the worst eye is in group E, then primary enucleation is recommended.

34. What are the precautions to be taken while enucleating retinoblastic eye?

Technique must be gentle, avoiding use of clamps, snares or cautery. The surgeon must obtain as long section of optic nerve as possible. This is best achieved via temporal approach with slightly curved enucleation scissors.

35. What is the role of chemotherapy in management of retinoblastoma?

- i. Chemo reduction of tumor in association with local therapy
- ii. To reduce the possibility of orbital recurrence
- iii. Suspected/documentated metastasis

36. What are the common chemotherapeutic agents used in management of retinoblastoma?

- i. Day 1—vincristine + etoposide + carboplatin
- ii. Day 2—etoposide
 - Standard dose (3 weekly, 6 cycles):
 - Vincristine—1.5 mg/m² (0.05 mg/kg for children < 36 months and maximum dose <2 mg)
 - Etoposide—150 mg/m² (5 mg/kg for children < 36 months)
 - Carboplatin—560 mg/m² (18.6 mg/kg for children < 36 months)
 - High dose (3 weekly, 6–12 cycles)
 - Vincristine—0.025 mg/kg
 - Etoposide—12 mg/kg
 - Carboplatin—28 mg/kg

37. What is periocular chemotherapy?

Subtenon carboplatin had been tried. 2 ml of 10 mg/ml solution is injected.

38. What are the side effects of periocular chemotherapy?

Orbital myositis, optic atrophy.

39. What are the indications of focal therapy?

- i. Small tumor < 3 mm in diameter and height located in visually non crucial areas.
- ii. As an adjuvant in large tumors/vitreous/subretinal seeding.

40. What are the lasers used in the management of retinoblastoma?

Xenon arc, argon laser. Focal consolidation is most often accomplished with transpupillary therapy.

41. Where do you prefer cryoablation and laser photoablation?

Laser photoablation is preferred for posteriorly located tumors and cryoablation for anteriorly located tumors because of the risk of optic nerve and macular damage. RD can occur in cryo scar.

42. What is the indicator of satisfactory freezing during cryotherapy in retinoblastoma?

Vitreous overlying tumor must be frozen.

43. What is the aim of modern treatment?

To save life as well as salvage vision.

44. What are the absolute indications for enucleation?

- i. Tumor > 50% of globe
- ii. Orbital or optic nerve involvement
- iii. Anterior segment involvement with or without neovascular glaucoma.

45. What are the types of radiation therapy?

- i. External beam therapy
- ii. Intensity modulated radiation therapy
- iii. Brachytherapy.

46. What are the limitations of external beam radiotherapy?

- i. Increased risk of second independent primary malignancy, e.g. osteosarcoma
- ii. Radiation related sequelae like mid face hypoplasia, cataract, optic neuropathy, vasculopathy.

47. What are factors that influence the prognosis of retinoblastoma?

- i. Tumor size.
- ii. Amount of vitreous/anterior chamber seeding
- iii. Presence/absence of choroidal invasion
- iv. Degree of tumor invasion of optic nerve or subarachnoid space.

48. Name the cryotherapy technique followed in treatment of retinoblastoma.

Triple freeze thaw technique.

49. What is the new gene therapy used in the treatment of retinoblastoma?

Targeted therapy uses adenoviral mediated transfection of tumor cells with thymidine kinase renders tumor cells susceptible to systemically administered ganciclovir.

50. What is trilateral RB?

Bilateral retinoblastoma with pinealoblastoma.

6.12. AGE-RELATED MACULAR DEGENERATION (ARMD)

1. Definition of ARMD.

- i. It is a spectrum of disease.
- ii. Associated with visual loss, RPE changes, drusens, geographical atrophy of the retina, SRNVM (subretinal neovascular membrane),
- iii. Usually in person aged above 50 years
- iv. Drusen alone without visual loss not considered as ARMD.

2. Definition of early ARMD (according to the International Epidemiological Age-related Maculopathy Study Group).

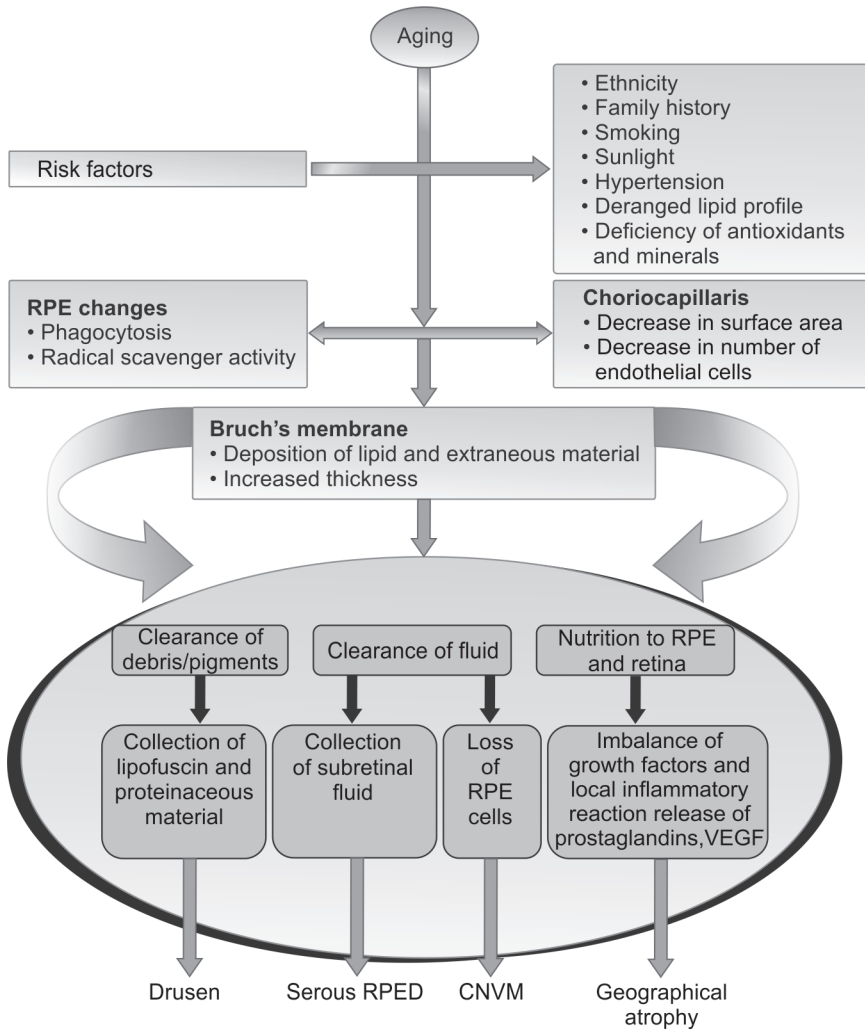
- i. Degenerative disorder in persons > 50 years characterized by presence of any of the following:
- ii. Soft drusen > 63 μ
- iii. Area of hyperpigmentation and/or hypopigmentation associated with drusen but excluding pigment surrounding small, hard drusen
- iv. VA is not a criterion for diagnosis.

3. What are the risk factors for AMD?

- i. Age—Incidence, prevalence and progression all increases with age.
- ii. Gender—Female > Male: 2:1 (Blue Mountains Eye Study)
- iii. Race—More in Whites
- iv. Ocular risk factor—Hyperopia
- v. Family history: 4 times higher risk
- vi. Oxidative stress: Accumulation of prooxidant melanin oligomers in RPE are responsible.
- vii. Systemic hypertension
- viii. Smoking—increases the risk
- ix. Light exposure—photooxidative damage mediated by reactive O_2 intermediates. Dietary and medication factor—Very high doses of zinc, vit C, vit E, and β -carotene provide a modest protective effect on progression to advanced neovascular AMD.
- x. Genetic factors—1q 25—31 and 10q26 increases risk
- xi. Cataract surgery.

4. What are the clinical features of ARMD?

- i. Blurred Vision—Dry ARMD—Asymptomatic or gradual loss of central vision, Wet ARMD—Rapid onset of vision loss
- ii. Difficulty in night vision
- iii. Decreased contrast sensitivity
- iv. Decrease saturation of colors
- v. Distorted vision (metamorphopsia)
- vi. Central scotomas
- vii. Slow recovery of visual function after exposure to bright light.



5. What is the classification of AMD?

AREDS (Age-related eye disease study) classification

- No AMD—Category 1—Control group—No or few small drusen $<63 \mu$
- Early AMD—Category 2—Combination of multiple small drusen, few intermediate drusen (63 to 124μ), or RPE abnormalities
- Intermediate AMD—Category 3—Extensive intermediate drusen, at least 1 large drusen (125μ) or geographic atrophy not involving the center of the fovea.
- Advanced AMD—Category 4—Characterized by 1 or more of the following in 1 eye:

- i. Geographic atrophy of the RPE and choriocapillaries involving the center of fovea
- ii. Choroidal neovascularization (CNV)
- iii. Serous and/or hemorrhagic detachment of sensory retina or RPE
- iv. Retinal hard exudates
- v. Subretinal and sub-RPE fibrovascular proliferation
- vi. Disciform scar

6. What are drusens?

Drusens are aggregation of hyaline material located between Bruch's membrane and the RPE.

Types:

A. Small, hard drusen: Referred simply as drusen < 63 μm

B. Large, soft drusen: > 63 μm , ill defined borders and vary in size and shape. They have a tendency towards confluence.

3 types (on basis of pathogenesis)

- Granular soft drusen: About 250 μm (2x vein width) with a yellow solid appearance, there confluence resulting in sinuous shapes.
- Soft serous drusen and drusenoid pigment epithelial detachments (PEDs): > 500 μm , may have pooled serous fluid, appearing blister like.
- Soft membranous drusen: Clinically between 63–175 μm (0.5–1.5 vein width), appear paler and shallower than the granular drusens.

C. Regressing drusens: Drusens begin to regress when the overlying RPE fails. They become whiter and harder due to inspissation of contents. Hypo- and hyper-pigmentation develops over the surface, margins become irregular and foci of calcification appear.

7. Classify CNV/SRNVM.

Histologically CNV is growth of abnormal, fragile new vessels between the Bruch's membrane and RPE or between the RPE and neurosensory retina. These vessels sprout from the choriocapillaries and proceed inwards through the defects in the Bruch's membrane.

A. Topographic classification:

- i. Extrafoveal (> 200 μm from foveal center)
- ii. Juxtafoveal (1–199 μm from foveal center)
- iii. Subfoveal—Under the fovea.

B. Angiographic classification:

- i. **Classic CNV**—reveals fairly discrete hyperfluorescence in early phase of angiogram that progressively intensifies throughout the transit phase, with intense late leakage of dye into the overlying neurosensory retinal detachment.
- ii. **Occult CNV** is of two forms:
 - FVPED (Fibrovascular PED)—Appears 1–2 min after dye injection. It appears as an irregular elevation of RPE with stippled leakage into overlying neurosensory detachment in early and late phase.

- Late leakage of undetermined source: Regions of stippled or ill-defined leakage into overlying neurosensory detachment without a distinct source focus that can be identified in the early frames of angiogram.

8. What is pigment epithelium detachment and how to identify PED in fluorescein angiography?

Pigment epithelium detachment (PED): Appears as sharply demarcated, dome shaped elevations of RPE. If filled with serous fluid they transilluminate. Four types of PED (on basis of angiographic pattern):

- FVPED (Fibrovacular PED)**—Appears 1–2 min after dye injection. It appears as an irregular elevation of RPE with stippled leakage into overlying neurosensory detachment in early and late phase.
- Serous PED**—Uniform bright smooth and sharp hyperfluorescence with rapid homogenous filling that starts in early phase without leakage in late phase of angiogram. May or may not overlie CNVM.
- Drusenoid PED**—Reveals hyperfluorescence in mid phase which increases in late phase with faint hyperfluorescence of drusen and late staining. Does not have CNVM.
- Hemorrhagic PED**—Dark sub RPE blood, which blocks choroidal fluorescence on angiography.

9. What is RPE rip/tear?

Occurs as a complication in serous or fibrovacular PED at the border of attached and detached RPE due to stretching forces of the underlying fluid or from the contractile forces of the fibrovacular tissue. Clinically, it is seen as area of hypopigmentation with hyperpigmented wavy border on one side due to rolling in of the free edge of torn RPE.

10. What is disciform scar?

It is the last stage in the evolution of neovascular AMD just as geographic atrophy as in dry AMD. Clinically apparent white to yellow subretinal scar with intervening areas of hyperpigmentation composed of fibrovacular complex is called disciform scar.

11. How do you differentiate dry ARMD and wet ARMD?

Dry or nonexudative ARMD	Wet or exudative ARMD
More common	Less common
Atrophic and hypertrophic changes in the RPE underlying the central retina (macula) as well as deposits (drusen) on the RPE	Abnormal blood vessels called choroidal neovascular membranes develop under the retina
May progress to the exudative form of ARMD	Leak fluid and blood, and ultimately cause a blinding disciform scar in and under the retina

Contd...

Contd...

Dry or nonexudative ARMD	Wet or exudative ARMD
Visual loss can occur particularly when geographic atrophy of the RPE develops in the fovea and causes a central scotoma.	Causes severe visual loss as a result of leaky CNVMs

12. What are the investigations for ARMD?

- i. Fundus fluorescein angiography (FFA)
 - ii. Indocyanine green (ICG) angiography
 - iii. Optical coherence tomogram (OCT)
 - iv. Multifocal electroretinography (MERG)
- i. **Fundus fluorescein angiography (FFA)**
 - a. **Classic CNV**—Reveals fairly discrete hyperfluorescence in early phase of angiogram that progressively intensifies throughout the transit phase, with intense late leakage of dye into the overlying neurosensory retinal detachment.
 - b. **Occult CNV** is of two forms:
 - FVPED (Fibrovascular PED)—Appears 1–2 min after dye injection. It appears as an irregular elevation of RPE with stippled leakage into overlying neurosensory detachment in early and late phase.
 - Late leakage of undetermined source—Regions of stippled or ill-defined leakage into overlying neurosensory detachment without a distinct source focus that can be identified in the early frames of angiogram.
 - ii. **Indocyanine green (ICG) angiography**—Can facilitate visualization of choroidal vasculature and CNVM through hemorrhage. ICG angiography can show CNVM as localized hot spots or as diffuse hyperfluorescent plaques.
 - iii. **Optical coherence tomogram (OCT)**—High reflective thickened Bruch's/RPE complex that is characteristic of CNV in AMD. For monitoring the therapeutic response to photodynamic therapy (PDT) and anti-VEGF therapy.

13. What are the differential diagnosis for CNVM?

- i. Idiopathic Polypoidal Chorioidal Vasculopathy (IPCV)
- ii. Myopia
- iii. Angioid streaks
- iv. Presumed ocular histoplasmosis syndrome.

14. What are the treatment options available for ARMD?

- a. **Early AMD**—No proven treatment
- b. **Intermediate AMD**—The combination treatment of antioxidant, vitamins and minerals causes significant reduction in both the development of advanced AMD and vision loss.

Supplement	Dose (daily)
Vitamin C	500 mg
Vitamin E	400 IU
β -carotene	15 mg
Zinc oxide	80 mg
Cupric oxide	2 mg

c. Neovascular ARMD

- i. The VEGF inhibitors have become the first-line therapy for treating neovascular AMD.
 - Ranibizumab (Lucentis)**—Dose—0.3–0.5 mg in 0.03/0.05 ml every month intravitreally or as needed.
- ii. **Bevacizumab (Avastin)**—Dosage between 1.25 and 2–5 mg monthly or as needed.
- iii. **Pegaptanib sodium (Macugen)**—Dose—0.3 mg injected every 6 weeks intravitreally.
- iv. **Cortisone**—Triamcinolone in dosages of 4, 8 and 25 mg was used intravitreally, mainly as an adjunct to PDT. Side effects—Raised IOP and rapid cataract development.

Treatment according to location of CNVM:

- **Subfoveal CNV**—Anti-VEGFs, verteporfin PDT and thermal laser photocoagulation.
- **Juxtafoveal CNV**—Anti-VEGF is the primary therapy. PDT with verteporfin can also be used.
- **Extrafoveal CNV**—Anti-VEGFs, still a role for thermal laser treatment (as defined by the MPS).

Photodynamic therapy (PDT)

Mechanism of action: Initially, a drug (verteporfin) is administered. The drug gets concentrated in the immature endothelium of CNVM, and light-activation induces a photochemical reaction in the target area that causes immunologic and cellular damage, including endothelial damage of new vessels causing subsequent thrombosis and occlusion of the vasculature.

Procedure:

- i. Intravenous infusion of verteporfin (a benzoporphyrin derivative monoacid)—light-activated drug.
- ii. After 15 minutes the laser light (689 nm) is applied for 90 seconds. Avoid direct sunlight for about 2 to 5 days after treatment. Follow-up every 3 months.

Contraindicated in porphyria.

Transpupillary thermotherapy (TTT)

Modified infrared diode laser (810 nm) attached to the slit lamp is used. Used in treatment of subfoveal CNVM (classic, occult or mixed).

15. What are the newer modalities of treatments for ARMD?

- i. **VEGF-trap**—Regeneron-recombinant soluble VEGF receptor protein.
- ii. **Anecortave acetate**—15 mg every 6 months delivered by periocular posterior juxtасcleral delivery.
- iii. **Small interfering RNA (siRNA)**—
 - C and-5 therapy—It silences the gene that promotes the overgrowth of blood vessels that lead to vision loss by shutting down the production of VEGF.
 - Sirna-027 therapy—Modified siRNA that specifically targets VEGF receptor 1, a component of the angiogenic pathway found on endothelial cells.

16. What surgical treatment options are available for ARMD?

- i. **Macular translocation**—The aim of the surgery is to relocate the central neurosensory retina (fovea) away from the CNV, to an area of healthier RPE, Bruch's membrane, and choroid.
- ii. **Iris/retinal pigment epithelium transplantation**—Fetal or mature RPE transplanted.
- iii. **Surgical removal**—Failed to show a beneficial effect on vision in elderly patients with AMD.
- iv. **Retinal rotation**—Extrafoveal RPE can maintain foveal function. Surgery has not been widely adopted.
- v. **Transplantation**—Transplantation of the autologous RPE. It is performed in two different ways—the transplantation of a freshly harvested RPE suspension immediately after membrane removal and transplantation of a full thickness RPE-choroidal patch excised from the midperiphery of the retina and translocated subfoveally.

17. What are the rehabilitation measures for ARMD patients?

- i. Provision of low vision aids.
- ii. Visual handicap registration.
- iii. Training and coping strategies
- iv. Statutory and voluntary support services in the community.

18. Name the studies for ARMD.

- i. **MARINA** (Minimally Classic/Occult Trial of the Anti-VEGF Antibody Ranibizumab in the treatment of Neovascular AMD)
- ii. **ANCHOR** (Anti-VEGF Antibody for the treatment of Predominantly Classic CNV in AMD)
- iii. **VISION** (VEGF inhibition Study in Ocular Neovascularization)
- iv. **VIP** (Verteporfin in PDT)
- v. **TAP** (Treatment of Age-Related Macular Degeneration with Photodynamic therapy)
- vi. **PIER** (A Phase IIIb, Multicenter, Randomized, Double-Masked Degeneration with photodynamic therapy)

19. What is MARINA trial?

- i. Done for minimally classic and occult with no classic lesion
- ii. Divided into three groups—i) Sham injection ii) Ranibizumab 0.3 mg every 4 week for 24 month. iii) Ranibizumab 0.5 every 4 week for 24 month.
- iii. After 2 years, mean visual acuity was better in Ranibizumab group versus placebo.

20. What is ANCHOR trial?

- i. This study was done for predominantly classic CNVM
- ii. Divided into three groups:
 - a. Verteporfin PDT + Sham injection
 - b. Sham injection + Lucentis 0.3 mg every 4 week for 24 months
 - c. Sham + Verteporfin PDT + Lucentis 0.5 mg every 4 week for 24 months
- iii. Result—visual gain of 15 letters or more in 6% in group (i)
36% in group (ii),
40%in group (iii).

6.13. VITRECTOMY

A. Instrumentation:

1. What are all the instruments used in vitrectomy?

- i. The cutter
- ii. The intraocular illumination source
- iii. The infusion cannula
- iv. Accessory instruments like scissors, forceps, flute needle, endodiathermy and endolaser delivery system.

2. What is the number of oscillations in the guillotine blade?

- i. Usually 1500 times/min
- ii. Latest—over 2500 times/min

3. What is the normal length of the infusion cannula? In which circumstances longer cannula is used?

Normal length is 4 mm. In special conditions like choroidal detachment or eyes with opaque media, 6 mm cannula is used.

4. What are all the expanding agents? Why are they used?

- i. Air
- ii. Sulfur hexafluoride which lasts for 10–14 days
- iii. Perfluoroethane which lasts for 30–35 days
- iv. Perfluoropropane which lasts for 55–65 days
- v. Expanding agents are used to achieve prolonged intraocular tamponade.

5. Indications for vitrectomy.

A. Anterior segment indications

- i. Glaucoma—Ghost cell glaucoma due to vitreous hemorrhage
- ii. Cataract
 - a. Lensectomy in eyes which need vitrectomy
 - b. Dislocated lens fragments
- iii. Pupillary membranes

B. Posterior segment indications

I. Indications for vitrectomy in diabetic retinopathy

- i. **Vitreous hemorrhage, especially if**
 - a. Long standing
 - b. Bilateral
 - c. Disabling because of frequent recurrences
 - d. Retinal neovascularization is inactive
- ii. **Traction retinal detachment, especially if**
 - a. The macula is detached
 - b. It is of recent onset
- iii. **Combined traction/rhegmatogenous detachment**
- iv. **Macular heterotopia of recent onset**
- v. **Macular epiretinal membranes**
- vi. **Florid retinal neovascularization—(controversial)**

C. Other posterior segment indications

- i. Retinal detachment with proliferative vitreoretinopathy
- ii. Giant tears
- iii. Opaque media
- iv. Trauma
- v. Macular pucker
- vi. Endophthalmitis
- vii. Uveitis
- viii. Acute retinal necrosis
- ix. Massive suprachoroidal hemorrhage
- x. Macular hole
- xi. Retinopathy of prematurity
- xii. Sick cell retinopathy
- xiii. Dislocated intraocular lenses
- xiv. Choroidal neovascular membrane
- xv. Diagnostic vitrectomy and retinal biopsy

6. What are the types of vitrectomy?

- A. Open sky
- B. Closed
 - i. Single port
 - ii. Two port
 - iii. Three port
 - iv. Four port

7. What is the technique of 3 port pars plana vitrectomy?

- i. A hand support is essential for intravitreal surgery. The surgeon rests both hands throughout the operation, avoiding fatigue and achieving fine control of the intravitreal manipulations.
- ii. Under aseptic precautions, plastic drape is pushed down into the space between the patient's head and the hand support, forming a trough to collect fluid that would otherwise spill onto the floor.
- iii. Small radial incisions through the conjunctiva and Tenon's capsule are made superonasally, superotemporally and inferotemporally.
- iv. The sclerotomy incisions in the standard threeport vitrectomy technique are typically placed at the 10 and 2 o'clock positions at the same distance from the limbus as the infusion cannula.
- v. The entry incisions of size only to allow passage of instrument are parallel to the corneoscleral limbus and are 4 mm from it in phakic eyes and 3.5 mm in aphakic and pseudophakic eyes.
The first incision is for the infusion cannula, which is placed in the inferotemporal quadrant, just inferior to the lateral rectus.
A mattress suture which will secure the 4 mm diameter cannula infusion line is preplaced prior to entering the eye.
- vi. After the infusion cannula is secured by its mattress suture, incisions are made in the superonasal and superotemporal quadrants for the vitrectomy instrument and the fiberoptics light pipe.

Before entering the eye, the surgeon must be certain that the instrument is functioning properly.

vii. If the pupil will not dilate, the iris must be retracted using pupillary stretching techniques or iris pins.

viii. **Vitrectomy**

The safest removal of vitreous is achieved using low suction (100 to 150 mm Hg) and a high cutting rate (400 cpm). This permits removal of small quantities of vitreous with each “bite” and reduces the risk of pulling on the vitreous base and of suddenly aspirating and cutting a detached retina.

After the vitreous has been removed and blood on the retinal surface has been aspirated, supplementary panretinal photocoagulation is given with the endolaser or with the laser indirect ophthalmoscope to diabetics who require it.

ix. Once the media have been cleared and the intraocular portion of the surgery has been completed, the cornea is covered to prevent foveal burns by the operating microscope. The scleral incisions are closed with 8-0 nylon sutures and the conjunctival incisions with 6-0 plain catgut.

The surgeon must carefully examine the peripheral retina for iatrogenic breaks.

8. Mention the intraoperative complications of vitrectomy.

i. Cornea

Avoid corneal trauma especially in diabetic patients as they are vulnerable to recurrent erosion.

Do not perform corneal contact procedures such as tonometry, ERG, contact lens examinations.

Moisten cornea repeatedly throughout the procedure.

Endothelial damage during instrumentation and infusion; intraocular irrigating solutions are toxic to the corneal endothelium.

ii. Cataract

Surgeon may inadvertently cause a break in the lens capsule with an instrument.

iii. Choroidal hemorrhage

iv. Choroidal detachment

v. Retina

a. Iatrogenic tears, the worst operative complication of vitrectomy, have been reported to occur in approximately 20–25% of cases.

b. One-third of all iatrogenic breaks are in the region of the sclerostomies, which must be carefully inspected by indirect ophthalmoscopy and scleral depression at the end of the procedure.

c. If there is no vitreoretinal traction, cryotherapy of a peripheral tear with an intraocular gas tamponade will seal the tear.

9. What are all the postoperative complications?

- i. Cornea
 - a. Persistent stromal edema is twice as common in diabetics as in non-diabetics.
 - b. Formerly, as many as 15% of diabetic patients had significant postoperative corneal decompensation, and as many as 3% required a corneal transplant. More recent studies show a marked decrease in corneal complications.
- ii. Glaucoma
 - a. Neovascular glaucoma—11 to 26% of diabetic eyes go on to neovascular glaucoma.
 - b. Erythroclastic glaucoma
 - c. Chronic open-angle glaucoma the incidence of chronic open angle glaucoma after vitrectomy has been reported to be as high as 22% with most of the cases developing 5 or more years postoperatively.
- iii. Hypotony
- iv. Cataract

Inadvertent touch by the vitrectomy instruments, toxicity of the intraocular irrigating solutions, and prolonged contact between the lens and long-lasting intraocular gases may all cause cataract.
- v. Vitreous hemorrhage
- vi. Anterior hyaloid fibrovascular proliferation
- vii. Retinal detachment

Rhegmatogenous retinal detachment has been reported to occur in approximately 5 to 15% of cases.
- viii. Endophthalmitis
- ix. Sympathetic ophthalmia
 - x. In association with vitrectomy, therefore, the placement or alteration of buckling material or manipulation of the extraocular muscles may produce
 - a. Strabismus,
 - b. Anterior segment necrosis,
 - c. Postoperative infection
- xi. Extrusion of scleral buckling materials

10. What are the factors contributing to neovascular glaucoma?

- A. Preoperative factors
 - i. Neovascularization of the iris
 - ii. Florid retinal neovascularization
 - iii. Panretinal photocoagulation
 - iv. Aphakia
- B. Operative factors
 - i. Removal of the lens
 - ii. Failure to reattach the retina (50% cases).

11. What are the contraindications of vitrectomy?

- i. If the eye has no light perception
- ii. In the presence of suspected or active retinoblastoma
- iii. Active choroidal melanoma

6.14. CENTRAL SEROUS CHORIORETINOPATHY (CSCR)

1. Define central serous chorioretinopathy.

It is a sporadic disorder of the outer blood retinal barrier, characterized by a localized detachment of sensory retina at the macula secondary to focal RPE defect, usually affecting only one eye .

2. List out the risk factors that cause CSCR.

- i. Type A personality.
- ii. Emotional stress
- iii. Untreated hypertension
- iv. Alcohol use
- v. Systemic lupus erythematosus
- vi. Organ transplantation
- vii. Gastro-oesophageal reflux
- viii. Cushing's disease
- ix. Pregnancy

3. Age in which CSCR is common?

- i. Common among young or middle aged men, 30 to 50 years of age.
- ii. Men typically outnumber women with a ratio of at least 6:1.
- iii. In patients older than 50 years the ratio is changed to 2:1.

4. Classify CSCR.

CSCR are generally classified as:

- i. Typical CSCR
- ii. Atypical CSCR.
 Histologically CSCR (Spitznagel classification) has been classified as
 Type 1—Detachment of sensory retina
 Type 2—RPE detachment
 Type 3—intermediate type—both sensory retina and RPE are elevated.

5. What are the clinical features of typical CSCR?

- i. Best corrected visual acuity of 6/60 or better.
- ii. Macular detachment greater than 3 DD
- iii. Pin point ink blot, smoke stack leakage in FFA
- iv. Spontaneous resolution.

6. What are the common clinical features in CSCR?

At presentation:

1. Unilateral blurred vision.
2. Micropsia
3. metamorphopsia
4. Loss of color saturation.

Signs

- i. A round or oval detachment of the sensory retina is present at the macula.
- ii. Yellowish subretinal deposits forming a spot pattern.

7. What are the FFA findings in CSCR?

1. Smoke stack:
 - i. Most common
 - ii. Early phase—small hyperfluorescent spot due to leakage of dye through RPE.
 - iii. Late phase—fluorescein passes into the subretinal space and ascends vertically to the upper border of detachment, and then spreads laterally until the entire area is filled with dye.
2. Ink-blot:
 - i. Is less common
 - ii. EARLY PHASE—shows hyperfluorescent spot.
 - iii. LATE PHASE—spot gradually enlarges centrifugally until the area is filled with dye.

8. What are the conditions during which management of CSCR becomes important?

Laser photocoagulation is carried out only when the following guidelines are met

- i. Unresolving CSCR of 4 months or more duration.
- ii. If spontaneous recovery does not occur within a month in a patient with or without a history of recurrent CSCR in the same eye or if the other eye associated with visual loss due to previous episodes of CSCR.
- iii. For patients with occupational needs for binocular vision (pilot, surgeons).
- iv. In the acute stage, photocoagulation at the site of leakage can result in resolution of subretinal fluid in 3 to 4 weeks.

9. What are the settings for laser therapy in CSCR?

Two or three moderate intensity burns are applied to the leakage sites to produce mild greying of the RPE.

Spot size of 200 μ for 0.2 sec and power of 80 MW titrated to 30 MW once the blanching signs are seen in RPE.

10. What are all the differential diagnosis of CSCR?

- i. Choroidal neovascular membrane
- ii. VKH
- iii. Optic disk pit
- iv. Posterior scleritis
- v. Rhegmatogenous retinal detachment

6.15. ANGIOGENESIS

1. Name the angiogenic molecules.

- i. VEGF (Vascular endothelial growth factor)
- ii. Fibroblast growth factor
- iii. Integrins
- iv. Angioprotein
- v. Protein kinase C
- vi. Ephrins

2. Name antiangiogenic factors.

- i. Pigment epithelial derived factor
- ii. Matrix metalloproteinases
- iii. Angiostatin
- iv. Endostatin
- v. Thrombospondin
- vi. Steroids

3. How many types of VEGF are present?

- i. VEGF A
- ii. VEGF B
- iii. VEGF C
- iv. VEGF D
- v. VEGF E

4. How many isoforms of VEGF A are present?

- i. VEGF 206
- ii. VEGF 189
- iii. VEGF 165
- iv. VEGF 145
- v. VEGF 121

5. Which is the main isoform of VEGF?

- i. VEGF A 165 is the predominantly expressed isoform. It is critical for both developmental and pathological neovascularization.

6. What is the role of other VEGF?

- i. VEGF B,C, D—play role in tumor angiogenesis and development of the lymphatic system
- ii. VEGF E—has similar angiogenic activity to VEGF A.

7. Where are the VEGF receptors found?

- i. Endothelial cells
- ii. Retinal epithelial cells
- iii. Bone marrow derived epithelial cells

8. What are the factors upregulating VEGF?

- i. Hypoxia
- ii. Hypoglycemia
- iii. β -estradiol
- iv. Epidermal growth factor
- v. Insulin-like growth factor
- vi. Pigment derived growth factor
- vii. Fibroblast growth factor.

9. What is the source of VEGF?

- i. Muller cells
- ii. Endothelial cells of vessels.

10. What are the properties of VEGF?

- i. Stimulates angiogenesis
- ii. Increases vascular permeability
- iii. Proinflammatory action
- iv. Endothelial survival factor and fenestration factor
- v. Neuroprotective factor.

11. What are the pathologic role of VEGF?

- i. Neovascular AMD
- ii. Diabetic retinopathy
- iii. Retinal vein occlusion
- iv. Retinopathy of prematurity
- v. Corneal neovascularization
- vi. Iris neovascularization
- vii. Systemically, it has a role in cancer, psoriasis, rheumatoid arthritis.

7

CHAPTER

Neuro-ophthalmology

7.1. THE NORMAL PUPIL

1. Define pupil.

The pupil is an opening present in the center of the iris that controls the amount of light passing to the retina.

2. What are the muscles involved in pupillary action and where are they derived from?

- i. Sphincter
- ii. Dilator

Both are derived from neuro-ectoderm.

3. What is the normal shape and size of the pupil and how does it vary with age?

- i. Normal pupil is approximately circular and usually placed slightly eccentrically towards the nasal side (inferonasal)
- ii. Average size (2.4–4 mm)
- iii. Larger in myopes
- iv. Smaller in hypermetropes
- v. Constantly smaller in very young and very aged because of decreasing sympathetic activity
- vi. Largest in adolescence.

4. What is the size of pupil when maximally dilated and maximally constricted?

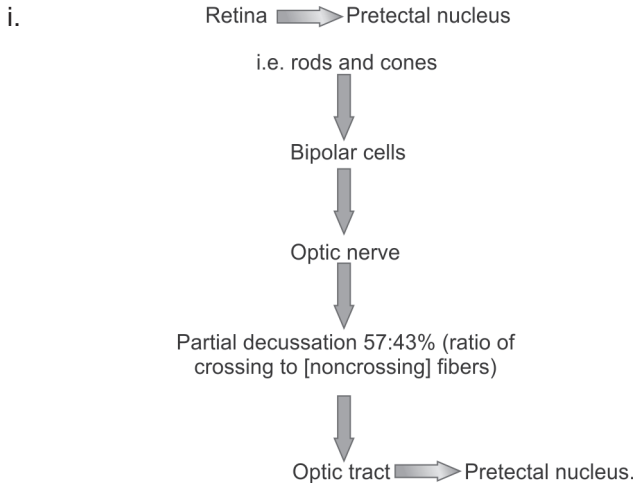
Dilated pupil: 10 mm

Constricted pupil: 1–1.5 mm.

5. At what age does the pupillary light reaction start and what is the range at birth?

- i. Premature baby has no pupillary light reaction until 3 weeks of gestational age
- ii. Gradually increases upto 2 mm at birth.

6. Trace the light reflex pathway.



- ii. Intercalated neurons from the pretectal complex to parasympathetic motor pool

(Edinger-Westphal of oculomotor nuclear complex)

Parasympathetic outflow from Edinger-Westphal nucleus



Ciliary ganglion



Pupillary sphincter.

7. How do you test the light reflex pathway?

A. Direct response:

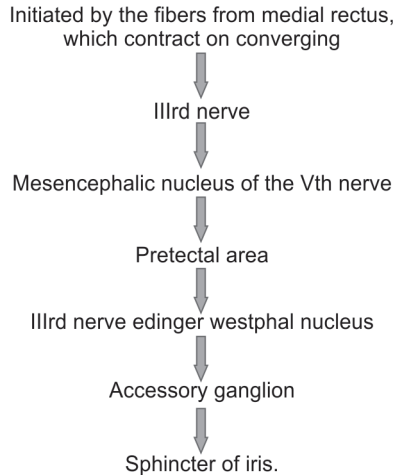
- i. The person testing should cover both eyes of the patient with palms of his hands or with two cards.
One eye is then uncovered. Pupil should contract briskly and contraction should be maintained.
Similar response should be noted in the other eye.
- ii. Patient should be asked to sit in a dimly lit room.
Person testing should use a point light source or a pen torch.
Patient should be asked to look into a distance (to avoid accommodation reflex).
Light should be brought from temporal side focusing onto the nasal side.

B. Indirect response:

- i. Criteria similar to that done in card test.
It is obtained by uncovering one eye in such a way that it is not exposed to direct light while the other is alternately covered and exposed.
- ii. Criteria are
 - Dim light

- Point light source
- Patient looking into distance
- Light should be brought from temporal side focusing onto the nasal side, so that it does not fall on the other eye and the reflex is observed in the unstimulated eye.

8. Trace the near reflex pathway.



9. How do you test pupillary reactions for accommodation?

Normal light

- i. Ask the patient to look into the distance
- ii. Suddenly ask the patient to fixate to a close object at 6 inches from the patient's nose.

Most accurately

- i. Patient is facing a wall between two windows and a small object is fixated for about half a minute 50 cm from his eye
- ii. This is gradually moved towards his eyes as it approaches a distance of 40 cm, slight contraction should be noted, which becomes stronger when the distance is 20–15 cm.

10. Describe other pupillary reactions.

- i. **Hemianopic pupillary reaction of Wernicke's syndrome:** It is a crude method to estimate the function of nasal and temporal half of retina. Point pencil of light is used.
- ii. **Orbicularis (lid) reflex:** Is elicited by observing the pupillary contraction which occurs when a forcible attempt is made to close the lid while they are held apart by fingers or speculum
- iii. **Oculosensory reflex:** It is elicited by touching the cornea or the conjunctiva lightly with a cotton wisp the pupil responds by dilating and then contracting. The reaction of the pupil will be sluggish, when light is thrown on the non-functioning part of retina.

11. How do you measure the size of the pupil?

Pupillometer.

12. Name some pupillometers.

- i. **Haabs:** It is a rough method of examination of the pupil size measurement by direct comparison of the aperture of the pupil with a series of circular disks of graduated sizes
- ii. Similar method with ophthalmoscope is used in Mortons ophthalmoscope
- iii. **Projection pupillometer:** Depends on the projection of the scale on the eye of the subject
 - a. Priestley's Smiths keratometer and pupillometer
 - b. Bumke's
- iv. **Sanders:** It is a device attached to the corneal microscope of Zeiss. The light is reflected into the eye through a movable glass plate, which is graded in tint, in such a way that different parts transmit a different proportion of incident light. The degree of contraction can be accurately decided at different illumination and the least intensity at which the pupillary reaction starts can be noted
- v. **Hemi Akinesia Meter:** This instrument is helpful in eliciting hemianopic pupillary response. This is possible because the illuminating system is duplicated. This provides for momentary stimulation of the peripheral retinal element, both in horizontal and oblique meridians.

13. What are the other methods of pupillometry?

- i. Photographic
- ii. Cinematographic
- iii. Electronic.

14. What is normal pupillary cycle time?

It is measured in slit lamp in dimly lit room.

A stopwatch is needed; time taken from the time the light is on to the constant contraction of pupil without any oscillation is noted. Normal 900 msec/cycle.

Abnormal Pupils**1. What are the characteristics of Marcus Gunn pupil?**

Afferent pupillary defect

- Causes:**
- i. Optic neuropathy
 - ii. Extensive retinal damage
 - iii. Amaurotic pupil

2. What are the characteristics of Adie's tonic pupil?

- i. Idiopathic
- ii. Female predilection
- iii. Dilated pupil with poor to absent light reaction
- iv. Slow constriction to prolonged near effort and slow redilatation after near effort

- v. Vermiform constriction of the iris sphincter on slit lamp examination.
- vi. Demonstrates cholinergic supersensitivity to weak (0.125%) pilocarpine solution
- vii. It may be associated with diminished deep tender reflexes.

3. What are the characteristics of Argyll Robertson pupil?

- i. Miotic, irregular pupils
- ii. Light reflex absent
- iii. Accommodation reflex present
- iv. **Etiology:** Neurosyphilis, diabetics mellitus, chronic alcoholism, multiple sclerosis, sarcoidosis
- v. Site of lesion: Most likely in the region of Sylvian aqueduct (dorsal midbrain)

4. What are the characteristics of Hutchinson pupil?

- i. Seen in comatose patient
- ii. Unilateral dilated poorly reactive pupil
- iii. **Etiology:** Due to expanding intracranial supratentorial mass that is causing downward displacement of hippocampal gyrus and uncus herniation compressing the third cranial nerve.

5. What are the characteristics of Horner's pupil?

- i. Miosis
- ii. Anhidrosis of the affected side of the face
- iii. Apparent enophthalmos due to narrow palpebral fissure
- iv. Ptosis of the upper lid.

6. What are the characteristics of Horner's syndrome?

- i. Cocaine test
- ii. Paredrine test

Causes of Horner's syndrome

- A. First order neuron lesion
 - i. Cerebrovascular accident
 - ii. Demyelinating disease
 - iii. Neck trauma
 - iv. Neoplasm
- B. Second order neuron lesion (preganglionic)
 - i. Chest lesions—Pancoast tumor, mediastinal mass, cervical rib
 - ii. Neck lesions—Trauma, thyroid lesion
 - iii. Third order neuron lesion (postganglionic)
 - a. Migraine
 - b. Otitis media
 - c. Cavernous sinus lesion
 - d. Carotid-cavernous fistula

7.2. OPTIC NERVE HEAD

1. What are the dimensions of the optic nerve?

The optic nerve extends from the eye ball to the optic chiasma. It measures about 3.5 to 5.5 cm in length. The diameter ranges from 3 mm in orbit to 7 mm near the chiasma.

2. Define optic nerve head (ONH).

- i. It is the part of the optic nerve that extends from the retinal surface to the myelinated portion of the optic nerve just behind sclera
- ii. In reference to glaucoma, the ONH is defined as the distal portion of optic nerve that is directly susceptible to elevated IOP.
- iii. The terms 'disk' and 'papilla' refers to the portion of the ONH that is clinically visible by ophthalmoscopy.

3. What are the dimensions of ONH?

- i. It is 1 mm long (anterior-posterior)
- ii. Diameter—1.5 mm horizontally and 1.75 mm vertically
- iii. Mean area of disk—2.7 sq mm.

4. Describe the parts of ONH.

- i. Superficial nerve fiber layer—the prelaminar zone anterior to the level of Bruch's membrane (pars retinalis)
- ii. The pre-laminar zone—level with the choroids (pars choroidalis)
- iii. The lamina cribrosa (pars scleralis)
- iv. The retro-laminar portion, immediately behind the lamina.

5. What is physiological cup?

- i. Central depression of optic disk is known as physiological cup
- ii. It is slightly pushed to the temporal side of the disk due to heaping of nasal fibers
- iii. From the center of this depression, vessels emerge, usually hugging the nasal side
- iv. Usually symmetrical in the two eyes.

6. What are the dimensions of the physiological cup?

- i. Median cup volume 0.28 sq mm
- ii. Median cup depth 0.63 sq mm
- iii. Mean cup area 0.72 sq mm.

7. What is neuroretinal rim (NRR)?

- i. The tissue outside the cup is termed the NRR and contains the retinal nerve axons as they enter the ONH
- ii. Rim area ranges from 0.8–4.66 sq mm
- iii. It is widest inferotemporally.

8. What is the normal shape of cup?

- i. Cup is 8% wider in the horizontal so that NRR is wider above and below
- ii. Cup area correlates with disk area and hence is large in large disks and small in small disks.

10. What is cup/disk ratio?

- i. Ratio of the cup and disk width measured in the same meridian. Its median value is 0.3
- ii. An asymmetry between both eyes of greater than 0.2 has been taken to signify enlargement and to be of diagnostic importance in glaucoma
- iii. The vertical ratio is used as simple index of rim integrity in chronic glaucoma.

11. Why is the ONH considered a major zone of transition?

- i. Nerve fibers pass from an area of high tissue pressure within the eye to a zone of low pressure that correlates with intracranial pressure
- ii. Transition from an area supplied by central retinal artery alone to an area supplied by other branches of ophthalmic artery
- iii. The axons become myelinated immediately at the posterior end of ONH.

12. What is scleral ring?

- i. The layers of the retina abruptly cease before the optic nerve is reached. The pigment epithelium and the underlying choroid may not extend right up to the nerve, thus leaving a white scleral ring-surrounding disk.

13. What are conus?

- i. If the scleral ring is accentuated it is termed as conus—a crescent shaped configuration usually seen on the temporal side.
- ii. Large inferior conus are frequently associated with other abnormalities and approximately to a staphyloma.

14. What is crescent?

- i. The pigment epithelium may stop short some distance from the disk and the remaining space upto the margin of the optic nerve is covered by the choroid. It is usually crescent shaped and situated temporally (also known as choroidal ring).

15. What is parapapillary chorioretinal atrophy?

- i. A crescent-shaped region of chorioretinal atrophy at temporal margin of normal disks and may be exaggerated in chronic glaucoma or high myopia. There are 2 types of zone:
 - Zone alpha
 - Zone beta

16. What are zone alpha and zone beta?**i. Zone beta**

- Inner zone
- Exhibits chorioretinal atrophy with visibility of sclera and large choroidal blood vessels
- Seen more frequently in patients with POAG
- Contributes to absolute scotoma

ii. Zone alpha

- More peripheral zone
- Displays variable irregular hyper and hypopigmentation of RPE
- Larger in patients with POAG, but frequency is similar in glaucoma and normal subjects
- Contributes to relative scotoma

17. What is the site of emergence of retinal vessels?

- The retinal vessels emerge on the medial side of the cup, slightly decentered superonasally.

18. What is the significance of venous pulsation?

- i. Absence of spontaneous venous pulsation is an early sign of papilledema
- ii. 20% of normal population have venous pulsation
- iii. Pulsations cease when intracranial pressure exceeds 200 mm of water.

19. What is the significance of retinal arterial pulsation?

- i. Visible retinal arterial pulsations are rare and usually pathological implying for example
 - Aortic incompetence
 - High intraocular pressure.

20. What is microdisk and macrodisk?

- i. Macrodisk, whose area lies greater than 2 standard deviations above the mean ($> 4.09 \text{ mm}^2$)
 - Primary macrodisk: May be associated with optic nerve pit, morning glory syndrome
 - Secondary macrodisk: Seen with acquired globe enlargement such as high myopia and buphthalmos
- ii. Microdisk, whose area is less than 2 standard deviations below mean ($< 1.29 \text{ mm}^2$).

21. What is the relationship between size of optic disk and certain ONH diseases?

- i. Small optic disks have a smaller number of optic nerve fibers and a smaller anatomical reserve.
 - Nonarteritic ION is commoner in small ONH due to problems of vascular perfusion and of limited space
 - Same is true for ONH drusen

- Pseudopapilledema is also encountered with smaller ONH, particularly in highly hypermetropic eyes.

22. Are there any racial differences in disk?

- i. There is a racial difference in disk diameter. Blacks have larger disks and hence larger cups.

23. What is the meniscus of Kuhnt?

- i. It refers to the central connective tissue that covers the non-myelinated fibers of the optic disk on the vitreal side.

24. What is the limiting tissue of Elschnig?

- i. This is the border tissue or limiting tissue that separates the fibers of ONH from the retina and choroids
- ii. It is essentially a derivative of the connective tissue of the choroids and sclera.

25. How many nerve fibers converge to form the disk?

- i. There are approximately 1.2 million retinal nerve fibers.

26. Why is there a blind spot corresponding to the area of the ONH?

- i. Because there are no rods or cones at the ONH, there is a physiological blind spot in the visual field.

27. What is the arrangement of retinal fibers at ONH?

- i. Those from the peripheral part of the retina lie deep in the retina but occupy the most peripheral part of optic disk; while fibers originating closer to ONH lie superficially and occupy a more deeper portion of the disk
- ii. The arcuate nerve fibers occupy the superior and inferior temporal portion of ONH and are most sensitive to glaucomatous damage accounting for early loss in corresponding region of visual field
- iii. The papillomacular fibers spread over approximately one-third of distal optic nerve, primarily inferotemporally where axonal density is higher. They intermingle with extramacular fibers which might explain the retention of central visual field.

28. What do you mean by medullated nerve fibers at ONH?

- i. Normally optic nerve fibers become medullated beyond lamina cribrosa. Occasionally myelin sheathing extends anterior to the lamina reaching a variable distance on the surface of the retina.

29. What is the composition of ONH?

Four types of cells:

- i. Ganglion cell axons
- ii. Astrocytes
- iii. Capillary associated cells
- iv. Fibroblasts

30. What type of glial element is present at the disk?

- i. The prominent glial element is astrocyte
- ii. It supports the bundles of nerve fibers
- iii. Provides cohesiveness to the neural compartment by arranging themselves to form an interface with all mesodermal structures (like vitreous, choroids, sclera, etc.)
- iv. Also serves to moderate the conditions of neuronal functions. For example:
 - By absorbing extracellular potassium ions released by depolarizing axons
 - Storing glycogen for use during transient oligemia.

31. What is the vascular supply of ONH?

- i. Mainly posterior ciliary arterial circulations
- ii. Central retinal arterial circulations

32. Describe the vascular supply to the different parts of the ONH.

- i. Surface nerve fiber layer—supplied by capillaries derived from retinal arterioles
- ii. Prelaminar region—supplied mainly from centripetal branches of peripapillary choroidal vessels
- iii. Lamina cribrosa region—supplied by centripetal branches of the short posterior ciliary arteries. Some also delivered via the circle of Zinn-Haller, which encircles the prelaminar region and is fed via the short posterior ciliary arteries
- iv. Retro-laminar region—supplied by centrifugal branches from central retinal artery and centripetal branches from pial plexus formed by branches of choroidal artery, circle of Zinn, central retinal artery and ophthalmic artery.

33. What is the venous drainage of ONH?

- i. Primarily via the central retinal venous system
- ii. Under conditions of chronic compression or CRVO, pre-existing connections between superficial disk veins and choroidal veins—*Optociliary veins*, enlarge and shunt blood to choroids.

34. What are the features of microvascular bed of ONH?

- i. It resembles the retinal and CNS vessels anatomically
 - Pericytes (mural cells) engulf the capillaries
 - Nonfenestrated endothelium has tight junctions
- ii. The optic nerve vessels share with those of the retina and CNS the following physiological properties of
 - Autoregulation
 - Presence of blood-brain barrier.

35. What is the significance of autoregulation?

- i. Because of autoregulation the rate of blood flow in the optic nerve is not much affected by intraocular pressure
- ii. In optic nerve the flow level is not affected by increase in BP because vascular tone is increased by autoregulation thus increasing the resistance to flow.

36. What is the main control of flow in optic nerve vessels?

- i. Anterior to lamina cribrosa, autoregulation controls flow.

37. Why does fluorescein diffuse towards the center of the optic disk from its boundary during FFA?

- i. The choroid is not separated from the ONH by a cellular layer that has tight junctions. Hence extracellular materials may diffuse into the extracellular space of the ONH.

38. How do you examine the ONH?

- a. Direct ophthalmoscope
 - i. For disk examination
 - ii. Nerve fiber layer (NFL) through red free filter
- b. Indirect ophthalmoscope
 - i. Young children
 - ii. Uncooperative patients
 - iii. High myopes
 - iv. Substantial media opacities
- c. Slit lamp using posterior pole lens such as Hruby lens, 60, 78, 90 diopter lens.

39. What is the location of ONH with respect to foveola?

- i. The center of ONH is approximately 4 mm superonasal to the foveola.

40. In what percentage of eyes is cilioretinal artery seen?

- 32%.

41. What is the difference between congenital and myopic crescents?

- i. Most temporal crescents are myopic and are acquired during life due to continuous growth process
- ii. True congenital crescents are present at birth and remain unchanged throughout life.

42. What are the congenital anomalies of ONH?

- a. Coloboma of ONH
 - i. Results from a defective closure of fetal fistula
 - ii. It may be confined to the ONH or may include choroids, retina, iris and lens
 - iii. Ophthalmoscopic appearance—the nerve is surrounded by peripapillary atrophy and shows extensive cupping and pallor
- b. Optic pit—usually located near the disk margin and often associated with serous detachment of the macula

- c. Situs inversus of the vessels: The right eye's ONH vascular pattern appears like that of the left eye.
- d. Situs inversus of the disk: The scleral canal is directed nasally and the vessel divisions sweep nasally for a considerable distance before assuming their usual course.
- e. Bergmeister's papilla:
 - i. A large stalk like vascularized tissue extending into the vitreal cavity from ONH
 - ii. It is due to persistence of remnants of fetal vasculature extending from ONH to the lens.

43. What is corpora amylacea?

- i. They are small hyaline masses, of unknown pathologic significance and occurring more commonly with advancing age, derived from degenerate cells
- ii. They are oval, highly refractile, either homogenous or showing concentric lamination and are enclosed in a definite capsule
- iii. They occur normally in the optic nerve as in other parts of the CNS.

44. Why in papilledema does the disk swell easily but not the adjacent retina?

- i. This is because in the prelaminar region loose glial tissue does not bind the axon bundle together as do the Muller cells of the retina.

45. What are the ocular signs of head injury?

1. Torchlight signs: Subconjunctival hemorrhage (with no clear posterior demarcation)
2. Fundus signs:
 - i. Papilledema
 - ii. Traumatic optic neuropathy (normal fundus with afferent pupillary defect)
 - iii. Purtscher's retinopathy
3. Field signs
 - Homonymous hemianopia
4. Pupillary signs:
 - I. Fixed dilated pupil due to
 - i. Transtentorial herniation (Hutchinson's pupil)
 - ii. Traumatic III N palsy
 - iii. Traumatic mydriasis
 - iv. Orbital blowout fracture
 - II. Small pupil
 - i. Horner's syndrome
 - ii. Pontine hemorrhage
5. Motor signs
 - i. Cranial nerve palsies
 - ii. Internuclear ophthalmoplegia

7.3. OPTIC NEURITIS

1. Define optic neuritis.

Literally means “Inflammation of the optic nerve” but it is defined as a demyelinating disorder of the optic nerve characterized by sudden monocular loss of vision, ipsilateral eye pain and dyschromatopsia.

2. Classification of optic nerve inflammation.

A. Ophthalmoscopically

- i. Papillitis
- ii. Retrobulbar neuritis
- iii. Neuroretinitis

B. Etiologically

- i. Demyelinating
- ii. Parainfectious
- iii. Infectious

C. Structurally

- i. Perineuritis or peripheral optic neuritis
- ii. Inflammation of optic nerve substance.

3. What are the causes of optic neuritis?

- i. Etiology is numerous, most cases are idiopathic
- ii. 90% cases are demyelinating diseases of optic nerve
- iii. 20–40% cases develop signs and symptoms of multiple sclerosis (MS) in optic neuritis.

I. Infectious diseases

- i. Bacterial—Bacterial endocarditis, syphilis, meningitis, chronic mastoiditis (lateral sinus thrombosis), brucellosis, endogenous septic foci.
- ii. Viral diseases poliomyelitis, acute lymphocyte meningitis, Coxsackie B virus encephalitis, recurrent polyneuritis, Guillain-Barré syndrome
- iii. Parasitic diseases sandfly fever, trypanosomiasis, neurocysticercosis.

II. Ischemic diseases

- i. Atherosclerosis
- ii. Diabetes mellitus
- iii. Takayasu’s disease
- iv. Carotid vascular insufficiency.

III. Inflammatory diseases

- i. Collagen vascular diseases
- ii. Giant cell arteritis

4. What are the triad of symptoms of optic neuritis?

- i. Loss of vision
- ii. Ipsilateral eye pain and
- iii. Dyschromatopsia.

5. What are the other symptoms of optic neuritis?

The associated visual symptoms are movement phosphenes, sound-induced phosphenes, and visual obscurations in bright light, and Uhthoff's symptom.

6. What is the cause of pain in optic neuritis?

According to Whitnall's hypothesis, pain of optic nerve inflammation is caused by traction of the origins of the superior and medial recti on the optic nerve sheath at the orbital apex.

7. Describe dyschromatopsia in optic neuritis.

Impaired color vision (dyschromatopsia) is always present in optic neuritis. In the absence of a macular lesion, color desaturation is a highly sensitive indicator of optic nerve disease. Color vision, a parvocellular-ganglion cell function, is abnormal in patients with acute and recovered optic neuritis. The localized loss of red and green perception to be the most sensitive test of interference with optic nerve function.

Color vision defects are highly sensitive indicators of a previous attack of optic neuritis. Color vision defects can be detected clinically using Hardy-Rand-Ritter or Ishihara pseudoisochromatic plates. More sensitive testing can be achieved with the Farnsworth Munsell 100 Hue test.

Typically the patient observes a reduced vividness of saturated colors. In color terminology saturation refers to the purity of color, and desaturation is the degree to which a color is mixed with white.

Some patients who are shown a red target characterize the sensation as darker (i.e. red is shifted toward amber), whereas others say the color is bleached or lighter (i.e. red is shifted towards orange).

8. Describe Uhthoff's phenomenon.

Uhthoff's symptom, episodic transient obscuration of vision with exertion, occurs in isolated optic neuritis and in MS.

However, exertion is not the only provoking factor for Uhthoff's symptom.

Typically, the patient has blurring of vision in the affected eye after 5 to 20 min of exposure to the provoking factor. Color desaturation may also occur. After resting or moving away from heat, vision recovers to its previous level within 5 to 60 min.

In optic neuritis, Uhthoff's symptom correlates significantly with multifocal white matter lesions on brain MRI ($P < 0.025$).

Conversion to MS in patients followed for a mean of 3.5 year is significantly greater in patient with Uhthoff's symptom ($P < 0.01$).

Uhthoff's symptom also correlates with a higher incidence of recurrent optic neuritis.

Uhthoff's symptom in MS can be detected by Farnsworth Munsell 100 Hue testing and Octopus perimetry, as well as by fluctuations of VEP amplitudes and contrast sensitivity.

9. What are the clinical signs of optic neuritis?

The clinical signs of optic neuritis are those of optic nerve disease. They include:

- i. Visual acuity (distance and near) — reduced
- ii. Dyschromatopsia
- iii. Contrast sensitivity — impaired
- iv. Stereoacuity — reduced
- v. Visual field — generalized depression, particularly pronounced centrally
- vi. Afferent pupillary defect
- vii. Optic disk(s) — hyperemia and acute swelling.

10. What is the name of the chart used to test contrast sensitivity?

Pelli-Robson chart.

11. How is stereoacuity checked?

Titmus polaroid 3-D vectograph stereoacuity test.

12. What is Pulfrich effect?

Patients notice reduced brightness and difficulty in depth perception. Because optic nerve damage results in delayed transmission of impulses to the visual cortex, patients with unilateral or markedly asymmetric optic neuritis will experience the Pulfrich effect, a stereo illusion.

13. What are the visual field defects in optic neuritis?

- i. Involvement of the visual field during an attack of optic neuritis, as well as following recovery, can be extremely variable.
- ii. In acute optic neuritis, the cardinal field defect is a widespread depression of sensitivity, particularly pronounced centrally as a centrocecal scotoma.
- iii. When acuity is severely impaired perimetric field charting is unreliable and confrontation testing is recommended.
- iv. As vision improves multiisopter kinetic Goldmann perimetry or computer-assisted automated static perimetry using a Humphrey Field Analyzer or Octopus perimeter are sensitive techniques for serial testing.
- v. A finding of generalized depression, paracentral scotomas, or scattered nerve fiber bundle-related defect(s) between 5° and 20° from fixation, may indicate sequelae of prior demyelinating optic neuropathy.

14. What are the optic disk finding in optic neuritis?

The appearance of the optic disk may be normal.

Swollen (papillitis) in 23%, blurred or hyperemic in 18%, and blurred with peripapillary hemorrhages around the disk in 2%.

Temporal pallor suggests a preceding attack of optic neuritis.

In recovered optic neuritis, 6 months after the first attack, a normal disk can be present in 42% of eyes; temporal pallor present in 28%; and total disk pallor evident in 18%.

In MS in remission, optic pallor is present in 38% of cases.

15. What are the retinal findings in optic neuritis?

- i. Two retinal signs are associated with optic neuritis and multiple sclerosis:
 - ii. Retinal venous sheathing due to periphlebitis retinae and
 - iii. Defects in the retinal nerve fiber layer.

16. What are the investigations in optic neuritis?

There is usually no need for investigative studies in a healthy adult presenting with typical acute, monosymptomatic, unilateral optic neuritis and an unremarkable medical history. However the following tests may be performed.

- A. Complete blood counts
- B. ESR
- C. Rule out diabetes
- D. Rule out infectious disease etiology like
 - i. Tuberculosis—chest X-ray, Mantoux (important as steroids will be used in treatment of optic neuritis)
 - ii. Syphilis
 - iii. HIV 1 & 2
 - iv. Hepatitis B
- E. Any other suspected infectious disease serology
- F. Rule out inflammatory disease conditions like
 - i. SLE, collagen vascular diseases—ANA, RA, ANCA, anti ds DNA
 - ii. Giant cell arteritis—temporal artery biopsy.

17. What are the neuroimaging in optic neuritis?

CT, MRI, VEP, pattern electroretinogram.

18. What are the MRI finding in optic neuritis?

- i. Enhancing optic nerve on T1 contrast fat saturated
 - Best seen on coronal images
 - On axial images, may have 'train-track' enhancement pattern simulating optic nerve sheath meningioma
- ii. On T2 with fat saturation (or STIR images) - mildly enlarged hyperintense optic nerve
- iii. Acute and chronic MS lesions appear bright in T2 images.
 - Lesions are round or ovoid in periventricular white matter, internal capsule and corpus callosum (perpendicular to ventricles, at calloseseptal interface)
 - They may also be linear with finger like appearance (Dawson's fingers) on sagittal or coronal scanning periventricular region.

19. What are the VEP finding in optic neuritis?

Prolongation of p₁₀₀ latency is seen optic neuritis.

20. What are the differential diagnosis of optic neuritis?**Unilateral optic neuritis**

- i. Ischemic optic neuropathy
- ii. Rhinogenous optic neuritis
- iii. Syphilis
- iv. HIV-associated optic neuropathies
- v. Infectious optic neuropathy
- vi. Nonorganic factitious visual loss

Simultaneous or sequential bilateral optic neuritis

When optic neuritis strikes both eyes, simultaneously or sequentially, the disorder must be distinguished from the following:

- i. Devic's disease
- ii. Immune-mediated optic neuropathy
- iii. Nutritional amblyopia
- iv. Jamaican optic neuropathy
- v. Leber's hereditary optic neuropathy and
- vi. Functional blindness.

21. What is Devic's disease?

Devic's disease (Neuromyelitis optica) is an inflammatory CNS-demyelinating disease that is considered to be a variant of MS. Affects both eyes simultaneously or sequentially in children, in young adults, and in the elderly and is accompanied by transverse myelitis within days or weeks.

Neuromyelitis optica has also been reported in association with SLE and pulmonary tuberculosis.

Familial cases of acute optic neuropathy and myelopathy may be linked to an inherited mutation in mitochondrial DNA (mtDNA), possibly a cytochromic oxidase subunit 2 mutation at nucleotide position 7706.

22. Treatment of optic neuritis.

Optic Neuritis Treatment Trial (ONTT) and Longitudinal Optic Neuritis Study (LONS).

Purpose

- i. To assess the beneficial and adverse effects of corticosteroid treatment for optic neuritis
- ii. To determine the natural history of vision in patients who suffer optic neuritis.
- iii. To identify risk factors for the development of multiple sclerosis in patients with optic neuritis.

The treatment phase of the study was called the Optic Neuritis Treatment Trial (ONTT), whereas the current long term follow-up phase is called the Longitudinal Optic Neuritis Study (LONS).

Prior to the Optic Neuritis Treatment Trial (ONTT), well-established guidelines for treating optic neuritis did not exist. Although corticosteroids had been used to treat this disease, studies to demonstrate their effectiveness had not been satisfactory.

Patients were randomized to one of the three following treatment groups at 15 clinical centers:

- i. Oral prednisone (1 mg/kg/day) for 14 days
- ii. Intravenous methylprednisolone (250 mg every 6 hours) for 3 days, followed by oral prednisone (1 mg/kg/day) for 11 days
- iii. Oral placebo for 14 days

Each regimen was followed by a short oral taper. The oral prednisone and placebo groups were double masked, whereas the intravenous methylprednisolone group was single masked.

The rate of visual recovery and the long term visual outcome were both assessed by measures of visual acuity, contrast sensitivity, color vision and visual field at baseline, at seven follow-up visits during the first 6 months, and then yearly. A standardized neurologic examination with an assessment of multiple sclerosis status was made at baseline, after 6 months, and then yearly.

Patient eligibility

The major eligibility criteria for enrollment into the ONTT included the following:

- i. Age range of 18 to 46 years
- ii. Acute unilateral optic neuritis with visual symptoms for 8 days or less
- iii. A relative afferent pupillary defect and a visual field defect in the affected eye
- iv. No previous episodes of optic neuritis in the affected eye
- v. No previous corticosteroid treatment for optic neuritis or multiple sclerosis
- vi. No systemic disease other than multiple sclerosis that might be the cause of the optic neuritis.

Results

The study has defined the value of baseline ancillary testing, the typical course of visual recovery with and without corticosteroid treatment, the risks and benefits of corticosteroid treatment, and the 5-year risk of the development of multiple sclerosis after optic neuritis.

These results are briefly summarized below:

- i. Routine blood tests, chest X-ray, brain MRI, and lumbar puncture are of limited value for diagnosing optic neuritis in a patient with typical features of optic neuritis.
- ii. Brain MRI is a powerful predictor of the early risk of multiple sclerosis after optic neuritis.

- iii. In optic neuritis patients with no brain MRI lesions, the following features of the optic neuritis are associated with a low 5-year risk of multiple sclerosis: lack of pain, optic disk edema (particularly if severe), peripapillary hemorrhage, retinal exudates and mild visual loss.
- iv. Visual recovery begins rapidly (within 2 weeks) in most optic neuritis patients without any treatment, and then improvement continues for upto 1 year. Although most patients recover to 20/20 or near 20/20 acuity, many still have symptomatic deficits in vision.
- v. The probability of a recurrence of optic neuritis in either eye within 5 years is 28 percent. Visual recovery after a second episode in the same eye is generally very good.
- vi. Treatment with high dose, intravenous corticosteroids followed by oral corticosteroids accelerated visual recovery but provided no long term benefit to vision.
- vii. Treatment with standard-dose oral prednisone alone did not improve the visual outcome and was associated with an increased rate of new attacks of optic neuritis.
- viii. Treatment with the intravenous followed by oral corticosteroid regimen provided a short term reduction in the rate of development of multiple sclerosis, particularly in patients with brain MRI changes consistent with demyelination. However, by 3 years of follow-up, this treatment effect had subsided.

The treatments were generally well-tolerated, and side effects during the treatment period were mild.

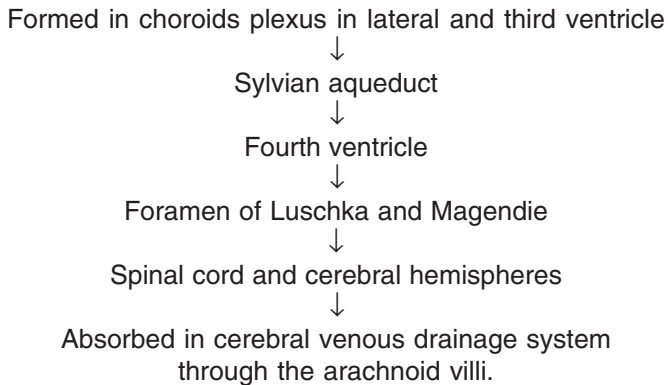
7.4. PAPILLEDEMA

CLINICAL FEATURES AND CAUSES

1. Definition of papilledema.

Passive hydrostatic, noninflammatory edema of the optic disk or nerve head due to raised intracranial pressure.

2. What is the place of production and pathway of CSF?



3. What is normal CSF pressure?

Normal CSF pressure in adults = 80–200 mm H₂O

Pressure > 250 mm H₂O elevated.

4. What is meant by the term “axoplasmic transport”?

- i. Optic nerve axoplasmic transport, transports material (proteins and organelles) from the retinal ganglion cells to the entire axons and to its termination in the lateral geniculate body where some of the material is degraded and returned to the cell body via the retrograde transport system.
- ii. Orthograde axoplasmic transport (from eye to the brain) has a slow component (proteins and enzymes) that progress at 0.5–3.0 mm/day an intermediate component (mainly mitochondria) and a rapid component (subcellular organelles) that moves at 200–1,000 mm/day.
- iii. Retrograde axoplasmic transport of lysosomes and mitochondria (from the brain to the eye) also occurs at an intermediate rate.

5. What is the relationship between IOP and papilledema?

- i. Normally the IOP (14–20 mm Hg) is higher than the tissue pressure in the optic nerve (6–8 mm Hg). This pressure differential is the force driving the axoplasm in the region of the lamina cribrosa.

Hence, a fall in the IOP or an increase in the optic nerve tissue pressure following a rise in the CSF pressure will interfere in the axoplasmic flow, leading to stasis and accumulation of the axoplasm.

6. What are the theories of papilledema?

- i. Inflammatory theory by Gowers and Leber—Edematous inflammation was set up by toxic material associated with intracranial disease
- ii. Vasomotor theories by Kornder—Papilledema caused by venous stasis which was part of a generalized increase in systemic venous pressure due to an accentuated inhibitory action of vagus resulting from central stimulation of increased intracranial pressure
- iii. Axoplasmic stasis theory by Hayreh.

The most accepted theory is Hayreh's theory of axoplasmic stasis.

7. What is Hayreh's theory of pathogenesis of papilledema?

- i. Patency of the meningeal spaces surrounding the optic nerve and intracranial structures and transmission of increased CSF pressure, to the region posterior to the optic nerve sheath is the first step
- ii. There is free diffusion of substances from the CSF to the optic nerve and thereby increases the optic nerve tissue pressure in the setting of increased intracranial tension
- iii. Increased optic nerve tissue pressure causes alteration of pressure gradient across lamina cribrosa which causes blockage of axoplasmic flow from retinal ganglion cells to lateral geniculate body
- iv. Venous changes are secondary due to compression of fine vessels lying in the prelaminar region and in the surface layers by the swollen axons.

8. How frequent is the occurrence of papilledema in children?

- i. Infants: Uncommon due to open fontanelles
- ii. Children age 2–10 years common due to increased infratentorial tumors.

9. What are the causes of papilledema?

A. Space occupying lesions

- i. Neoplasms—Infratentorial tumors (common)
- ii. Abscess—Temporal lobe
- iii. Inflammatory mass
- iv. Subarachnoid hemorrhage
- v. Infarction
- vi. A-V malformations

B. Focal or diffuse cerebral edema

- i. Trauma
- ii. Toxic
- iii. Anoxia

C. Reduction in size of cranial vault

Craniosynostosis

D. Blockage of CSF flow

Noncommunicating hydrocephalus

E. Vitamin A toxicity

F. Reduction in CSF resorption

- i. Communicating hydrocephalus
- ii. Infectious meningitis
- iii. Elevated CSF proteins (meningitis)
- iv. Spinal cord tumor, Guillain-Barre syndrome (GBS)

G. Increased CSF production**H. Idiopathic intracranial hypertension (pseudotumor cerebri)****10. Which tumors are more prone to develop papilledema and why?**

Tumors of the midbrain, parietooccipital and cerebellum mostly cause papilledema

Tumors → Infratentorial (more common)
→ Supratentorial

- i. Infratentorial tumors—Produce papilledema by obstruction of the aqueduct or by compression of vein of galen or the posterior superior sagittal sinus.
- ii. Supratentorial tumors—Produce papilledema by deflection of the falx and pressure upon the great vein of Galen.

Others—Intracranial masses—Metastatic tumors, brain tumors.

11. Which intracranial tumor is least likely to cause papilledema?

- i. Medulla oblongata tumors
- ii. Tumor of the anterior fossa

12. What are the common causes of papilledema in children?

- Posterior fossa tumors—medulloblastoma.

13. What are the stages of papilledema?

- i. Early
- ii. Established
- iii. Chronic
- iv. Atrophic

(As suggested by Hughlings Jackson in 1871)

14. What are the clinical features of early papilledema?

- i. Visual symptoms are mild or absent
- ii. Optic disk shows hyperemia and blurring of superior and inferior margins and blurring of retinal nerve fiber layer.

15. How does the edema progress?

The edema (blurring of the optic nerve) starts at the superior and inferior margins and extends around the nasal side and finally the temporal side (SINT).

16. What are the pathological features of papilledema?

- i. Signs of passive edema without evidence of inflammation
- ii. Edematous changes are located in front of the lamina cribrosa
- iii. Axoplasmic stasis is seen

- iv. Nerve fibers become swollen and varicose and ultimately degenerate
- v. Proliferation of neuralgia and mesoblastic tissue around the vessels becomes thickened.

17. What are the clinical features of established papilledema?

- i. Transient visual obscuration—5 seconds, rarely exceeds 30 seconds at irregular intervals
- ii. Visual acuity normal or decreased
- iii. Enlargement of blind spots
- iv. Gross elevation of the disk surface with blurred margins
- v. Venous pulsation absent
- vi. Microaneurysm formation and capillary dilatation on disk margin
- vii. Flame shaped hemorrhages, cotton wool spots
- viii. Circumferential retinal folds (Paton's lines)
- ix. Hard exudates on hemorrhages and macula (macular fan).

18. Why do transient visual obscurations occur in papilledema?

Transient visual obscurations of vision may occur in one or both eyes simultaneously with rapid recovery usually lasting seconds but sometimes lasting hours.

Patients may experience upto 20–30 attacks per day, with obscurations precipitated by change of posture or from the lying down to sitting or standing position.

The cause of these transient obscurations is related to transient compression or ischemia of the optic nerve.

19. What is the usual duration of the transient obscuration of vision in papilledema and its precipitating factors?

- i. 5 seconds. It rarely exceeds 30 seconds at irregular interval.
- ii. Precipitated by
 - standing up from a sitting position
 - stooping
 - turning the head abruptly.

20. Name other conditions causing transient obscuration of vision.

- i. Amaurosis fugax
 - usual duration 5–15 min
 - Fundi may show emboli
- ii. Retinal migraine
 - Duration 15–20 min
 - Frequently accompanied or followed by headache
- iii. Acute glaucoma
 - Several hours
- iv. Hemicrania
 - 15–45 min
- v. Epileptic fits (partial)
 - Few seconds

21. In how many percentages of normal individuals can we see pulsations over the optic nerve head?

Absence of spontaneous venous pulsations—occurs when the intracranial pressure rises above 200 mm H₂O. This can be misleading if seen during the times of fluctuation of increased intracranial pressure when it may be below 200 mm H₂O. Absence of spontaneous venous pulsations may be a finding in 20% of normal population.

22. What is macular fan?

The nerve fibers in the macula are arranged in a radial fashion. Hence hard exudates and hemorrhages are arranged in a radial manner in the macula, which are more prominent on the nasal side of the fovea due to the vascular compromise in and around the disk.

23. What are the clinical features of chronic (vintage) papilledema?

- Visual acuity is variable with constricted visual field
- Optic disk changes
 - i. Champagne-cork appearance with no exudates and hemorrhages
 - ii. Central cup obliterated but peripapillary retinal edema absorbs
 - iii. Small white opacities on the disk—corpora amyloacea
 - iv. Pigmentary changes in macula

24. What are the clinical features of atrophic papilledema?

- i. Visual acuity is severely impaired with constriction of visual field
- ii. Optic disk grayish-white with indistinct margins as a result of gliosis
- iii. Narrow retinal vessels due to sheathing of vessels, which are extension of gliosis
- iv. Reduced disk elevation—flat disk

25. What are the causes of optic atrophy in papilledema?

- i. Increased intracranial pressure compromises the vascular supply (focal infarct, ischemia, axon damage) which cause nerve fiber atrophy. Decreased vascularity of the disk causes pale gray color leading to secondary optic atrophy
- ii. Appearance depends on the fact that absorption of exudates causes organization and formation of fibrous tissue on the disk. This fibrous tissue obscures the lamina cribrosa and fills in atrophic cup, then extends over the edges which are thus ill-defined along vessels and perivascular sheath
- iii. Number of vessels also decreases (Kestenbaum's sign)

26. What is the other staging system of papilloedema?

Frisen's grading system

A. Stage 0

- i. Mild nasal elevations of the nerve fiber layer
- ii. A portion of major vessels may be obscured in upper pole

B. Stage 1—Very early papilledema

- i. Obscuration of the nasal border of the disk
- ii. No elevation
- iii. Disruption of normal retinal nerve fiber layer
- iv. Concentric or radial retino choroidal folds

C. Stage 2—Early papilledema

- i. Obscuration of all the borders
- ii. Elevation of nasal border
- iii. Complete peripapillary halo

D. Stage 3—Moderate papilledema

- i. Obscuration of all the borders
- ii. Increased diameter of optic nerve head
- iii. Obscuration of one or more segments of major blood vessels leaving the disk
- iv. Peripapillary halo, irregular outer fringe with finger-like extensions

E. Stage 4—Marked papilledema

- i. Elevation of the entire nerve head
- ii. Obscuration of all the borders
- iii. Peripapillary halo
- iv. Total obscuration on the disk of a segment of major blood vessels

F. Stage 5—Severe papilledema

- i. Dome shaped protrusions representing anterior expansion of optic nerve head
- ii. Peripapillary halo
- iii. Total obscuration of a segment of major blood vessels
- iv. Obliteration of optic cup
- v. Obscuration of all the borders

27. How does the blurring of disk margins appear in papilledema?

- i. It usually appears first in the upper and lower margins. Usually at the upper nasal quadrant, spreading then round the nasal margin and appearing last at the temporal margin (SINT).

28. Why are the upper and lower quadrants affected first?

- i. The distribution depends on the density of capillaries, with the papillomacular bundle occupying the greater part of the outer aspect of the disk. The upper and lower quadrants are the most heavily crowded with nerve fibers.

29. Why is there an enlargement of blind spot?

It is due to separation of the retina around the disk by the edema.

- i. Due to compression, detachment and lateral displacement of the peripapillary retina and due to generalized decrease in sensitivity of the peripapillary retina. The outer layer of the neural retina may buckle, and rods and cones are displaced away from the end of the Bruch's membrane

- ii. **Stiles-Crawford effect:** This phenomenon proposes that the wrinkles and the folds in the peripapillary retina cause light to fall obliquely on the photoreceptors thus making the light a less effective stimulus.

30. What are the visual field defects common in cases of papilledema?

- i. Enlargement of blind spots
 - ii. Concentric contractions
 - iii. Relative scotoma first to green and red
 - iv. Complete blindness
 - v. Homonymous hemianopia
 - vi. Central and arcuate scotomas
 - vii. Most commonly involves inferior nasal quadrant.
- } more common

31. What are the systemic features of increased intracranial pressure?

- i. Headache—more severe in the morning, worsening progressively. Intensifies with head movement
- ii. Sudden nausea—projectile vomiting
- iii. Horizontal diplopia caused by stretching of the VI nerve over the petrous tip (false localizing sign). Sometimes IV nerve palsy
- iv. Loss of consciousness/generalized motor rigidity
- v. Bilaterally dilated pupil (rare).

32. What are the causes of headache, loss of consciousness and generalized motor rigidity?

Headache: associated with increased intracranial pressure is due to stretching of the meninges while sharply localized pains can be due to involvement of sensory nerve at the base of the skull or localized involvement of the meningeal nerves.

Loss of consciousness: occurs from compression of the cerebral cortex and the reduction of its blood supply.

Generalized motor rigidity: Herniation of the hippocampal gyrus through the tentorium from increased intracranial pressure results in crowding of the temporal lobe into the incisura of each side.

Tentorial herniation thus places pressure on the crura cerebri, resulting in generalized motor rigidity. Finally direct pressure on the nerves and dorsal midbrain produces bilaterally dilated pupils that do not respond to light stimulation.

34. How is the elevation of the disk seen on direct ophthalmoscopy?

First with a direct ophthalmoscope retinal vessels below the disk are focused and then the vessels above the disk are seen.

A difference of 2–6D may be found between the focus of the vessels on the top of the disk and those on the retina.

A difference of 3D is equivalent to approximately 1 mm difference of level at the fundus.

35. Which refractive error may mimic papilledema?

- i. Astigmatism and hypermetropia (pseudoneuritis): It is a condition usually occurring in hypermetropic eyes when the lamina is small and the nerve fibers are heaped up as they debouch upon the retina.

36. What are the earliest features of resolution in papilledema?

- i. Retinal venous dilatation and disk capillary dilatation regression
- ii. Disappearance of disk hyperemia.

37. What are the last abnormalities which usually resolve after treatment of papilledema?

- i. Blurring of disk margins
- ii. Abnormalities of the peripapillary retinal nerve fiber layer.

38. What are the poor prognostic factors for papilledema?

- i. Rapidity—The more rapid the onset, the greater the danger of permanent visual loss
- ii. Duration of papilledema
- iii. Papilledema of more than 5D, extensive retinal hemorrhages and exudates and macular scar
- iv. Early pallor of the disk and attenuated arterioles
- v. Gliosis of the disk
- vi. Obscurations of vision and presence of opticociliary shunts.

39. Mention the criteria for idiopathic intracranial hypertension?

(Modified from criteria established by WE Dandy)

- i. Signs and symptoms of increased intracranial pressure.
- ii. Absence of localizing findings on neurologic examination.
- iii. Absence of deformity, displacement and obstruction of ventricular system and otherwise normal neurodiagnostic studies except for increased cerebrospinal fluid pressure (> 200 mm H₂O in nonobese patient and >250 mm H₂O in obese patient).
- iv. Awake and alert patient.
- v. No other cause of increased intracranial pressure present.

40. What are the diagnostic criteria of pseudotumor cerebri?

- i. Symptoms and signs solely attributable to increased intracranial pressure.
- ii. Elevated CSF pressure
- iii. Normal CSF composition
- iv. Normal neuroimaging studies
- v. No other etiology of intracranial hypertension identified
- vi. Treated with diuretics and lumbar puncture.

41. What are the drugs that may produce a secondary pseudotumor cerebri?

- i. Nalidixic acid
- ii. Penicillin

- iii. Tetracycline
- iv. Minocycline
- v. Ciprofloxacin
- vi. Nitrofurantoin

42. Why are pupillary reactions normal in cases of early and established papilledema?

Because neuronal conduction is not dependant on axonal transport but rather on the myelin sheath.

43. What is the differential diagnosis of papilledema?

- A. Papillitis
- B. Pseudopapilledema due to
 - i. High hypermetropia
 - ii. AION (nonarteritic)
 - iii. Drusens of optic nerve
- C. Optic neuritis
- D. Tilted optic disk
- E. Hypoplastic disk
- F. Myelinated nerve fiber

44. How can one differentiate between pseudopapilledema and papilledema?

Pseudopapilledema—

- i. Swelling never more than 2D
- ii. No venous engorgement, edema or exudates
- iii. Blind spot is not enlarged
- iv. FFA—no leaking

45. How can one differentiate between optic neuritis (papillitis) and papilledema?

Optic neuritis

- i. Relative apparent pupillary defect
- ii. Moderate swelling; 2–3D shelving gradually into the surrounding retina
- iii. Central scotoma with field loss of color discrimination
- iv. Visual symptoms are marked
- v. Acute depression of central vision
- vi. Usually unocular
- vii. Associated vitreous opacities.

46. How can one differentiate crowded disk and tilted disk from papilledema?

- i. Peripapillary nerve fiber layer and retinal vessels that traverse it remain normal
- ii. Venous pulsations are usually present
- iii. No vascular engorgement/hemorrhages
- iv. No cottonwool spots

- v. An oval disk with one side displaced posteriorly, usually at the inferior margin and the other side elevated anteriorly, usually at the superior margin
- vi. Oblique direction of retinal vessels
- vii. High myopia/moderate oblique myopic astigmatism is usually present.

47. Differentiate between nonarteritic AION from papilledema.

- i. Associated with hypertension—40%, diabetes mellitus—24%
- ii. Visual acuity decreased > 6/60
- iii. Color vision defective
- iv. Altitudinal field defects

48. Differentiate between papilledema and optic disk drusen.

- i. Drusen—Common in children and young
- ii. Familial and very slow growing
- iii. Visual defects do not correspond to location of the drusen
- iv. Small optic nerve head
- v. Calcified laminated globular aggregates on the disk
- vi. FFA is normal.

49. Differentiate between hypertensive retinopathy and papilledema.

Hypertensive retinopathy—is characterized by

- i. Less venous dilatation
- ii. More marked arterial narrowing
- iii. Abnormalities of arteriovenous crossings with
- iv. Retinal hemorrhages and exudates more scattered than confined to the proximity of the disk.

50. Differentiate between optic neuritis, papilledema, ischemic neuropathy.

	Optic neuritis	Papilledema	Ischemic neuropathy
Symptoms			
Visual	Rapidly progressive loss of central vision	No visual loss +/- transient obscuration	Acute field defect (common altitudinal)
Others	Tender globe, pain on motion, orbit or browache	Headache, nausea, vomiting	None (headache in cranial arteritis)
Bilaterality	Rare	Always	Unilateral in acute stage. Second eye involved subsequently with picture of Foster Kennedy syndrome
Signs			
Pupil	No anisocoria	No anisocoria	No anisocoria

Contd...

Contd...

	Optic neuritis	Papilledema	Ischemic neuropathy
	↓ light reaction on side of neuritis	Normal reaction unless asymmetric atrophy	↓ light reaction on side of disk infarct
Visual acuity	Decreased	Normal	Variable (Severe loss common in arteritis)
Fundus	Variable degrees of disk swelling with few flame hemorrhages, cells in vitreous	Variable degrees of disk swelling, hemorrhages, cystoids infarcts	Usually segmental disk edema with few flame hemorrhages
Visual prognosis	Vision usually returns to normal or functional levels	Good	Poor prognosis

51. What are the causes of unilateral optic disk edema?

A. Oculoorbital

- i. Papillitis
- ii. Drusen
- iii. Ischemic optic neuropathy
- iv. Central retinal venous occlusion
- v. Optic nerve glioma/meningioma
- vi. Ocular hypotony

B. Mixed intracranial

- i. Unilateral optic atrophy and true papilledema (Foster Kennedy syndrome)
- ii. Pre-existing atrophy before development of increased ICP (pseudo-Foster Kennedy syndrome)
- iii. Unilateral high myopia and true papilloedema
- iv. Cavernous sinus thrombosis
- v. Carotid-cavernous fistula

C. Pure intracranial

- i. Posterior fossa tumour
- ii. Pseudo tumor cerebri
- iii. Sub-arachnoid hemorrhage
- iv. Brain abscess
- v. Optochiasmatic arachnoiditis

52. What are the causes of bilateral optic disk edema with normal visual function?

- i. Hypertensive retinopathy
- ii. Spinal cord tumors
- iii. Guillain-Barre syndrome
- iv. Hypoxemia and anemia
- v. Cyanotic congenital heart disease

INVESTIGATIONS

1. What is the investigation of choice in papilledema?

- A. MRI with or without contrast is the best investigation of choice
 - a. MRI angiography
 - b. MRI venography
 - i. to rule out arterial disease and venous obstruction (thrombosis)
 - ii. Arnold-Chiari malformations
 - iii. to see structured lesions (mainly posterior fossa lesions)
 - iv. to see hydrocephalus
- B. Fascial resolution is better in MRI which provides three-dimensional image
- C. Soft tissue lesions are well appreciated.

2. What is the role of CT scan in papilledema?

- A. To rule out intracranial lesions that would produce increased intracranial pressure and rule out obstructive hydrocephalus.
 - i. Acute vascular causes—like subarachnoid, epidural, subdural, intracranial hemorrhages, acute infarctions
 - ii. After head injury—cerebral edema
- B. Patient with contraindication to MRI like pacemaker, metallic clip, metallic foreign body.

3. What is the role of lumbar puncture (LP) in papilledema?

- i. Diagnostic—to evaluate for intracranial hypertension by recording the opening pressure
- ii. To send CSF for microbial/infectious studies like—TLC, DC, glucose, protein, cytology, VDRL
- iii. Therapeutic—pseudotumor cerebri.

4. What is the main hazardous disadvantage of LP?

- i. It is usually contraindicated because of the danger of herniation of the brain into the foramen magnum which causes pressure on medulla leading to sudden death in cases with intracranial space occupying lesions with midline shift.

5. What are the complications of lumbar puncture?

- i. Poor compliance
- ii. Painful to the patient
- iii. Difficult in obese patients
- iv. May produce a remission of PTC by creating a permanent fistula through the duramater
- v. Spinal epidermoid tumors
- vi. Infection.

6. How does CT scan help in diagnostic of disk edema due to Graves disease?

- It shows marked enlargement of extraocular muscle with compression of optic nerve leading to disk edema.

7. What are the X-ray findings in papilledema in children and adults?

Adults

- i. Demineralization of subcortical bone leading to loss of 'lamina dura' (white line) of sellar floor followed by thinning of dorsum sella and the posterior clinoid process.
- ii. In extreme cases the sella becomes very shallow and flattened with its floor and anterior wall demineralized and the posterior clinoid process and dorsum sella destroyed.
- iii. Increased intracranial tension causes enlargement of the emissary veins in occipital region.
- iv. Congenital cyst or chronic subdural hematoma may show localized thinning or bulge.

Children

- i. Presents with sutural diastasis, i.e. sutural widening
- ii. Increased convolutional markings with thinning of the bone
- iii. Any separation beyond 2 mm is suspicious of increased tension.

8. What are the FFA findings in papilledema?

Early phase

- i. Disk capillary dilatation
- ii. Dye leakage spots
- iii. Microaneurysm over the disk.

Late phase

- i. Leakage of dye beyond disk margin
- ii. Pooling of dye around the disk as vertically oval pooling.

TREATMENT OF PAPILLEDEMA

1. What is the medical and surgical treatment for benign intracranial hypertension?

- A. Medical treatment
 - a. Acetazolamide 500 mg BD
 - b. Dehydrating agent—oral glycerol
 - c. Corticosteroids
 - d. Weight reduction
- B. Surgical
 - a. Repeated LP
 - b. Decompression
 - c. Shunting procedure—Lumboperitoneal shunt.

2. How many times lumbar puncture can be done before subjecting the patient for decompression?

Multiple lumbar punctures can be done to relieve the increased intracranial tension. LP needle creates a sieve that allows sufficient regress egress of CSF, so that ICT is normalized.

3. How long does it take for regression of papilledema following treatment?

Fully developed papilledema may disappear completely within hours, days or weeks depending on the way in which intracranial tension is lowered.

Brain tumor—Papilledema can resolve 6–8 weeks after successful craniotomy to remove a brain tumor.

Pseudotumor cerebri—Resolution of papilledema within 2–3 weeks after lumboperitoneal shunts in Idiopathic intracranial hypertension and several days after optic nerve sheath fenestration.

4. During treatment of papilledema, how is therapeutic success determined?

- i. Relief of headache
- ii. Diminished frequency of transient visual obscuration
- iii. Regression of papilledema
- iv. Stability or improvement of field defects
- v. Weight reduction

5. Indications of decompression.

- i. Failure of medical treatment as evidenced by clinical signs
 - Marked degree of swelling ($> 5D$)
 - Great engorgement of veins
 - Presence of extensive hemorrhage
 - Early appearance of exudate spots
- ii. Progressive headaches unrelieved with medical treatment
- iii. Progressive optic neuropathy evidenced by early contraction of visual field.

6. Which patient of pseudotumor cerebri should be treated? And how?

- i. Those patients who develop
 - Signs of visual loss from chronic papilledema (optic neuropathy)
 - Intractable headaches
 - Persistent diplopia
- ii. Treatment
 - Repeated LP
 - Decompression
 - Shunting procedure

7. How do you manage a case of pregnancy induced hypertension (PIH) presenting with papilledema?

- i. General—bed rest
- ii. Diet—only fluids
- iii. Sedative—phenobarbitone/diazepam
- iv. Control of BP
- v. Control edema—proteinurea/diuretic/frusemide, hypertonic glucose
- vi. Finally if patient doesn't respond to treatment, pregnancy has to be terminated.

8. What are the operative disk decompression done to relieve papilledema?

- i. Subtemporal decompression
- ii. Suboccipital craniectomy
- iii. Direct fenestration of optic nerve sheath (ONSD) via medial or lateral orbitotomy.

9. What is the procedure of ONSD?

- i. The surgeon makes a window or multiple incisions in the normally bellowed anterior dural covering of the optic nerve sheath using either a lateral or a medial approach (the latter preferred).

10. What are the features and treatment of fulminant IIH (idiopathic intracranial hypertension)?

- i. Features
 - Rapid onset of symptoms
 - Significant visual loss
 - Macular edema
 - Cerebral venous thrombosis and meningeal process should be considered
 - Malignant cause requires rapid treatment
- ii. Treatment
 - IV corticosteroids and insertion of lumbar drain used while waiting for definitive treatment.

11. How do you manage a patient with PTC?

- i. No symptoms of papilledema
 - Periodic monthly review
 - If vision is normal for 3 months, then 2-monthly review
- ii. With transient obscuration of vision/signs of optic nerve dysfunction
 - T. acetazolamide–1 g daily depending on patient's tolerance
 - Re-examine the patient every 2–3 weeks for signs of compromise
- iii. With progressive optic neuropathy
 - T. acetazolamide–corticosteroid (80–100 mg/day)
- iv. Other treatment modalities
 - Repeated LP
 - Lumboperitoneal shunt
 - Optic nerve sheath decompression

12. If the patient has visual symptoms only, what is the treatment of choice?

- i. Bilateral optic nerve sheath decompression.

13. If the patient has headache only with no visual symptoms, what is the treatment of choice?

Lumboperitoneal shunt.

7.5. OPTIC ATROPHY

1. Define optic atrophy.

Optic atrophy describes a group of clinical conditions which have abnormal pallor of the disk as a common physical sign. It is not a disease but a pathological end point of any disease that causes damage to the ganglion cells and axons with overall diminution of the optic nerve and visual acuity.

2. What are the features of optic atrophy?

- i. Loss of conducting function
- ii. Abnormal pallor of the disk
- iii. Proliferation of glial tissue
- iv. Reduction in number of capillaries
- v. Destruction of nerve fibers
- vi. Diminished volume of nerve fiber bundle
- vii. Increased excavation

3. What are the clinical features of optic atrophy?

- i. Reduced visual acuity
- ii. RAPD/APD
- iii. Defective color vision
- iv. Visual field loss central, paracentral, altitudinal scotomas

4. What is the normal color of disk and why?

The disk is reddish pink in color with a mild pale physiological cup in the center.

The normal color of the disk depends on following factors:

- i. **Composition of the optic disk**
 - axons of retinal ganglion cells
 - blood capillaries
 - astrocytes
 - connective tissue
- ii. **Relationship of these structures to each other**
- iii. **Behavior of light on falling on the disk**
- iv. **Vascularity of the disk**

5. What is the pathology of optic atrophy?

There are two main factors:

- i. Degeneration of optic nerve fibers
- ii. Proliferation of astrocytes and glial tissue

The disease may be focal, multifocal or diffuse causing axonal interruption and their destruction by

- direct effect
- investing glial tissue

- decreasing capillary blood supply—gross shrinkage and atrophy of optic nerve.

6. What are the causes of pallor in optic atrophy?

Optic nerve degeneration causes:

- reduced blood supply and disappearance of smaller vessels from view
- glial tissue formation occurs which is opaque
- loss of tissue causes visibility of opaque scleral lamina.

7. What is Kestenbaum capillary number?

Capillaries on normal disk were counted by Kestenbaum to be 10–12. In optic atrophy it was reduced to 6 or less.

8. What is Wallerian degeneration (ascending or antegrade optic atrophy)?

Primary lesion is in the optic nerve head, retina or choroid, which proceeds towards the brain. Visual axons are severed and their ascending segment disintegrates.

There is swelling and degeneration of terminal buttons of axons within the lateral geniculate body.

9. Which fibers are first to be affected in ascending optic atrophy?

Rate of degeneration is proportional to thickness of nerve fibers. Hence, larger axons degenerate faster than small caliber axons.

10. Causes of ascending optic atrophy?

- Retinitis pigmentosa
- CRAO
- Glaucoma
- Traumatic optic atrophy
- Papilledema
- Toxic amblyopia
- Extensive panretinal photocoagulation

11. How soon can ascending optic atrophy set in and completed?

The process can be identified within 24 hours and completed within 7 days.

12. What pathological process occurs in lateral geniculate body (LGB) in optic atrophy?

Transsynaptic changes occur in layer 1, 2, 3 and 5. Axons are reduced in size and not in number. Shrinkage and reduction of cytoplasm especially, endoplasmic reticulum—reduced Nissl granule staining is seen.

13. Examples of transsynaptic antegrade atrophy.

- Glaucoma
- After trauma
- After enucleation.

14. What is the earliest sign of optic atrophy?

Retinal nerve fiber layer changes are seen even before the onset of disk pallor or field defect. This defect can be slit like wedge shaped/diffuse loss.

15. What is descending optic atrophy?

Refers to retrograde degeneration of axons. The primary lesion is in the brain or optic nerve. The atrophic process proceeds towards the eye leading to secondary effects on the optic disk and the retina.

16. What is the time span of completion of descending optic atrophy?

Approximately 6–8 weeks. The time course of this descending degeneration is independent of the distance of the injury from the ganglion cell body.

17. What are the histopathological hallmarks of optic atrophy?

- i. Loss of myelin and axon fibers
- ii. Loss of the parallel architecture of the glial columns
- iii. Gliosis
- iv. Widening of the space separating the optic nerve and meninges
- v. Thickening of the pial septa of the nerve to occupy space lost by nerve fiber loss.

18. Define primary optic atrophy (POA).

There is orderly degeneration of optic nerve fibers and is replaced by columns of glial tissue without any alteration in the architecture of the optic nerve head. This reflects a chronic process that has not been preceded by swelling or congestion of optic disk.

19. Describe the features of primary optic atrophy.

- i. Chalky white disk
- ii. Sharply defined margins
- iii. Lamina cribrosa is well seen
- iv. Surrounding retina and retinal vessels and periphery are normal
- v. Shallow, saucer shaped cup seen

20. What are the common causes of primary optic atrophy?

- i. ***Retrobulbar neuritis***
- ii. ***Compressive lesions of optic nerve, e.g.***
 - pituitary tumors
 - meningiomas
 - gliomas
- iii. ***Traumatic optic atrophy***
- iv. ***Demyelinating diseases, e.g. tabes dorsalis, multiple sclerosis.***

21. What is secondary optic atrophy (SOA)?

It is characterized by marked degeneration of optic nerve fibers with excessive proliferation of glial tissue resulting in loss of entire architecture of optic nerve head.

It is preceded by swelling or congestion of the optic nerve head.

22. What are the causes of secondary optic atrophy?

- i. Papillitis
- ii. Papilledema

23. Describe features of secondary optic atrophy.

- i. Gray or dirty gray pallor of the disk
- ii. Poorly defined margins
- iii. Physiological cup is obliterated and is filled with proliferating fibroglial tissue
- iv. Peripapillary sheathing and narrowing of arteries
- v. Veins are tortuous and sometimes narrowed
- vi. Hyaline bodies and drusens in and around the disk

24. What is the commonest cause of altitudinal pallor?

Acute ischemic optic neuropathy.

25. What is the commonest cause of segmental optic atrophy?

Temporal pallor: This is due to degeneration of axial fibers of the retrobulbar optic nerve resulting in atrophy of papillomacular bundle.

26. What are the types of field defects occurring due to temporal pallor?

Centrocecal scotoma or central scotoma due to loss of papillomacular bundle.

27. How does wedge-shaped pallor occur?

Branch retinal artery occlusion leads to degeneration of infarcted ganglion cells causing atrophy of the corresponding wedge of the disk.

28. What is the commonest cause of consecutive optic atrophy (COA)?

Central retinal artery occlusion. It is an ascending type of optic atrophy. Other causes are:

- i. Degenerative—RP, cerebromacular degeneration, myopia
- ii. Post inflammatory—Choroiditis, chorioretinitis
- iii. Extensive PRP
- iv. Long standing RD

29. What are the clinical features of consecutive optic atrophy?

- i. Disk has a waxy pallor
- ii. Normal disk margin
- iii. Marked attenuation of arteries
- iv. Associated retinal pathology may be seen
- v. Normal physiologic cup

30. What is cavernous optic atrophy?

This is nothing but glaucomatous optic atrophy (Schnabel's). This is characterized by axonal degeneration without any proliferation of glial tissue resulting in formation of caverns with marked excavation of the optic disk. The caverns are filled with hyaluronic acid.

31. What is the mechanism of ischemic optic atrophy?

Occurs when perfusion pressure of the ciliary system falls below the IOP.

32. Causes of ischemic optic atrophy?

- i. Systemic hypertension
- ii. Temporal arteritis
- iii. Atherosclerosis
- iv. Diabetes
- v. Collagen disorders

33. When does optic atrophy manifests in CRAO?

2–3 weeks.

34. Name some chemicals causing optic atrophy.

- i. Arsenic
- ii. Lead
- iii. Benzene
- iv. Chromium
- v. Nitro and dinitro benzene

35. What are the drugs which can cause optic atrophy?

- i. Quinine (total blindness in small doses in susceptible persons)
- ii. Ethambutol
- iii. Streptomycin
- iv. INH
- v. Chloroquine (Bull's eye maculopathy)
- vi. Oral contraceptives

36. What is the commonest cause of toxic amblyopia?

Tobacco—in cigar and pipe smokers.

37. What is the pathogenesis and features of tobacco induced optic atrophy?

Cyanide is the normal constituent of tobacco which is detoxified by sulfur metabolism to harmless thiocyanate. In tobacco users sulfur metabolism is deranged. There is degeneration of the axial portion of retrobulbar optic nerve due to demyelination. The resulting toxic degenerative neuritis leads to secondary fibrosis and gliosis within papillomacular bundle. It is associated with a deficiency of vitamin B12.

38. What is the treatment of tobacco amblyopia?

- i. Abstention from tobacco and alcohol
- ii. Injections of hydroxocobalamine 1000 µg intramuscularly. The dose should be repeated five times at intervals of 4 days.

39. Name some metabolic disorders causing optic atrophy.

- i. Diabetes
- ii. Thyroid ophthalmopathy

- iii. Cystic fibrosis
- iv. Nutritional amblyopia
- v. Hypophosphatasia
- vi. G-6-PD deficiency
- vii. Mucopolysaccharidosis
- viii. Acute intermittent porphyria—Menkes disease

40. What is nutritional amblyopia?

It is due to atrophy of papillomacular nerve fibers caused by deficiency of vitamin B12, B6, B1, B2 and niacin.

Characterized by—

- i. progressive bilateral visual loss
- ii. centrocecal scotoma
- iii. temporal pallor

41. What is the pathogenesis of tropical amblyopia?

Common in people eating cassava. Occurs due to reduced levels of serum cyanocobalamin and absence of sulfur containing amino acids.

42. What are the features of tropical amblyopia?

- i. Bilateral blurred disk
- ii. Temporal pallor
- iii. General features like—ataxia, paresthesia of lower extremities, tinnitus, deafness, absence of deep tendon reflexes, posterior column sensory loss.

43. Which variants of diabetes cause optic atrophy?

- i. Juvenile diabetes mellitus
 - autosomal recessive
 - pronounced rod and less severe cone dystrophy (Wolfram syndrome)
- ii. DIDMOAD syndrome—diabetes mellitus, diabetes insipidus, optic atrophy, deafness.

44. Specify the types of mucopolysaccharidosis causing optic atrophy.

- i. Hurlers syndrome
- ii. Sanfilippo's syndrome.

45. What is the mechanism of traumatic optic atrophy?

- i. Tears in the nerve substance
- ii. Perforation of nerve by fractured bone spicules
- iii. Hemorrhage into nerve sheath
- iv. Contusion necrosis
- v. Avulsion of optic nerve

46. What is the commonest site of injury leading to traumatic optic atrophy?

A blow to the lateral wall of the orbit.

47. What is the time span after which the optic atrophic process manifest clinically first as temporal pallor in traumatic optic neuropathy?

2–4 weeks.

48. What could be the pathophysiology of reversible loss of vision in traumatic optic neuropathy?

Compression of the intracanalicular portion of the optic nerve due to edema.

49. What is the cause of intermittent visual claudication?

Takayasu disease—loss of vision may occur during exercise and improves at rest.

50. What percent of foveal fibers must be present for normal visual acuity?

44% of foveal fibers.

51. Name some hereditary causes of optic atrophy.

- i. Congenital/infantile optic atrophy—recessive and dominant form
- ii. Leber's optic atrophy
- iii. Behr's optic atrophy

52. What are the differential diagnoses of optic atrophy?

- i. Coloboma of disk
- ii. Optic pit
- iii. Morning glory syndrome
- iv. Medullated nerve fibers
- v. Myopic disk
- vi. Optic disk hypoplasia
- vii. Drusens of the disk

53. Name histopathological techniques to highlight demyelination of optic nerve.

- i. Special myelinophilic stains
 - Luxol fast blue
 - Weigert stain
- ii. Paraphenylenediamine—stains remnants of optic nerve myelin long after the degeneration/atrophy has occurred
- iii. Demyelination is indicated in a hematoxylin and eosin tissue section by the more compact nature of the nerve parenchyma.

54. What is the specific color vision loss in optic nerve disorders?

Optic nerve disorders manifest a relative red-green deficiency.

55. How can color vision loss due to retinal and optic nerve pathology be differentiated?

Retinal diseases manifest a relative blue-yellow deficiency whereas optic nerve disorders show a relative red-green deficiency.

56. Name some causes of traction optic atrophy.

- i. Glaucoma
- ii. Post papilledema
- iii. Sclerosed calcified arteries
- iv. Aneurysm of internal carotid artery
- v. Bony pressure at the optic foramen
- vi. Tumors of optic nerve sheath, pituitary, frontal temporal or sphenoidal lobes
- vii. Swelling of optic nerve which may get strangulated at the optic foramen
- viii. Inflammatory adhesion in basal arachnoiditis

57. What are the types of segmental or partial optic atrophy?

- i. Temporal pallor
- ii. Altitudinal pallor
- iii. Wedge shaped pallor

58. Classify optic atrophy.**A. Pathological**

- i. Ascending
- ii. Descending

B. Ophthalmoscopic

- i. POA
- ii. SOA
- iii. COA

C. Etiological

- i. Consecutive
- ii. Post inflammatory
- iii. Pressure/traction
- iv. Toxic
- v. Metabolic
- vi. Traumatic
- vii. Hereditary
- viii. Circulatory

59. How is optic atrophy classified ophthalmoscopically?

- i. Primary
- ii. Secondary
- iii. Consecutive
- iv. Cavernous or glaucomatous
- v. Segmental or partial

60. How can methyl alcohol poisoning occur commonly?

Methanol (methyl alcohol) is found in cleaning materials, solvents, paints, varnishes, Sterno fuel, formaldehyde solutions, antifreeze, gasohol, "moonshine," Windshield washer fluid (30–40% methanol), and duplicating fluids. It is consumed as local liquor (wood alcohol).

61. What are the features of methyl alcohol poisoning?

- i. Nonspecific symptoms such as headache, dizziness, nausea, lack of coordination, confusion, drowsiness
- ii. Central nervous system (CNS) involvement in the form of unconsciousness, semiconsciousness, giddiness
- iii. Visual symptoms are the predominant presenting features
- iv. Shock may occur as a late event
- v. unconsciousness and death with sufficiently large doses.

62. How does methyl alcohol poisoning affect the optic nerve?

The symptoms of methanol poisoning are nonspecific except for the visual disturbances. Ocular changes consists of:

- i. Retinal edema
- ii. Blurring of the disk margins
- iii. Hyperemia of the disks and
- iv. Optic atrophy as a late sequelae

Metabolic acidosis is the most striking disturbance seen in methanol poisoning. It is probably due to the accumulation of formic acid and lactic acid.

Formic acid inhibits cytochrome oxidase in the fundus of the eye. Disruption of the axoplasm is due to impaired mitochondrial function and decreased ATP production. Swelling of axons in the optic disk and edema result in visual impairment.

The ocular changes correlate to the degree of acidosis. Retinal damage is due to the inhibition of retinal hexokinase by formaldehyde, an intermediate metabolite of methanol.

63. What is the treatment of methyl alcohol poisoning?

The essential therapy of methanol poisoning is adequate alkalization and ethanol administration. Ethanol competes with methanol for the enzyme alcohol dehydrogenase in the liver, thereby preventing the accumulation of toxic metabolites of methanol in the body. The recommended dose of ethanol is 0.6 g/kg body weight (a loading dose) followed by an infusion of 66 mg/kg/hour in nondrinkers and 154 mg/kg/hour in chronic drinkers.

Dialysis is recommended in those patients who have visual disturbances, blood methanol of 50 mg% or more, ingestion of more than 60 ml of methanol and severe acidosis not corrected by sodium bicarbonate administration.

64. What are the features of excessive use of artificial sweeteners containing aspartame (NutraSweet)?

- i. Decreased vision — including blindness in one or both eyes
- ii. Blurring, “bright-flashes”, tunnel vision, “black spots”
- iii. Double vision
- iv. Pain in one or both eyes
- v. Decreased tears
- vi. Difficulty in wearing contact lens
- vii. Unexplained retinal detachment and bleeding

65. How do artificial sweetening agents affect the optic nerve?

Each of the components of aspartame—phenylalanine (50%); aspartic acid (40%); the methyl ester, are converted to methyl alcohol or methanol (10%) and further to formaldehyde which is toxic to the retina and optic nerves. Methanol causes swelling of the optic nerve and degeneration of ganglion cells in the retina.

66. Fundus portraits of different types of optic atrophy.

Primary	Secondary	Consecutive	Cavernous	Temporal
Disk	Disk	Disk	Disk	Disk
Chalky white in color	Grey dirty grey pallor	Waxy pallor of the disk	-Vertical pallor of cup-notching of NRR -Pallor of rim	Disk is pale on the temporal side
Sharply defined margins	Poorly defined margins	Normal disk margin	-Visibility of lamina pores -laminar dot sign -Backward bowing of lamina cribrosa	Clear disk margin
Lamina cribrosa well seen	Physiological cup obliterated and filled with fibroglial tissue obscuring view of lamina cribrosa	Normal physiological cup	-Bayoneting and nasalization of retinal vaessels -Splinter hemorrhages at the disk margin -Saucerisation of optic disk	
Vessels	Vessels	Vessels	Vessels	Vessels
Retinal vessels normal	Peripapillary sheathing of arteries and narrowing of arteries Veins are tortuous and narrowed; occasionally sclerosed or hyaluronised	Marked attenuation of arteries	Baring of cicumlinear vessels Peripapillary halo and atrophy	Vesels are normal
Surrounding retina normal	Hyaline bodies or drusen seen in and around the disk		Nerve fiber layer defect	

67. How is optic atrophy treated?

There is no real cure or treatment for optic atrophy. Therefore, it is important to have regular eye exams (especially if there is a family history of eye diseases), and to see an ophthalmologist immediately if any changes in vision are noted.

7.6. OPTIC DISK ANOMALIES

1. What are congenital optic disk anomalies?

Definition: Unusual configuration of the disk(s) typically present since birth.

Key features: Small, pale or unusual shaped disk may reflect mere curiosities or significant anomalies associated with visual field defects.

Associated features: Abnormalities of the surrounding retina (e.g. in morning glory syndrome, anterior segment (e.g. in iris coloboma), face or brain occasionally may be seen.

Congenital optic nerve head (ONH) anomalies are important because:

- i. Relatively common
- ii. Some may be mistaken for papilledema
- iii. Some may give rise to visual field defects
- iv. Some are associated with CNS malformation
- v. Some may be associated with other ocular abnormalities.

2. What are the features of congenital optic nerve head (ONH) anomalies?

Following are the general concepts useful in evaluating and managing children with congenital optic disk anomalies:

- i. Children with bilateral optic disk anomaly generally present in infancy with poor vision and nystagmus; those with unilateral anomaly present during preschool years with sensory esotropia.
- ii. CNS malformations are common in patients with malformed optic disks.

Small optic disk is associated with malformations of cerebral hemisphere, pituitary infundibulum and midline intracranial structures (septum pellucidum, corpus callosum)

Large optic disks of morning glory configuration are associated with the trans-sphenoidal form of basal encephalocele.

Large optic disks of colobomatous configuration may be associated with systemic anomalies.

MRI is advisable in infants with small optic disks (unilateral or bilateral) and in infants with large optic disks who have either neuro-developmental deficits or mid facial anomalies suggestive of basal encephalocele.

- iii. Color vision is relatively preserved in an eye with a congenitally anomalous optic disk in contrast to the severe dyschromatopsia in acquired optic neuropathies.
- iv. Any structural ocular abnormality that reduces visual acuity in infancy may lead to superimposed amblyopia. Occlusion therapy therefore should be tried in patients with unilateral optic disk anomalies and decreased vision.

3. What are the features of optic nerve hypoplasia?

The most common optic disk anomaly encountered in ophthalmologic practice.

Incidence has increased in recent times because of maternal alcohol and drug abuse.

Pathogenesis:

Primary failure of retinal ganglion cell differentiation at the 13 to 15 mm stage of embryonic life.

Ophthalmoscopic appearance:

- i. Abnormally small optic nerve head.
- ii. Gray in color and is often surrounded by a yellowish mottled peripapillary halo, bordered by a ring of increased or decreased pigmentation (double ring sign)
- iii. Major retinal blood vessels are tortuous.
- iv. Histopathologically, subnormal number of optic nerve axons with normal mesodermal elements and glial supporting tissue.
- v. Double ring sign
 - a. Outer ring—normal junction between the sclera and lamina cribrosa.
 - b. Inner ring—abnormal extension of retina and RPE over the outer portion of lamina cribrosa.

Visual acuity

- i. Ranges from 6/6 to no PL
- ii. Localized visual field defects
- iii. Generalized constriction of visual fields.

Systemic associations

- i. Superior segmental ONH—type 1 DM.
- ii. Growth hormone deficiency is most common.
- iii. Neonatal hypoglycemia or seizures with ONH—congenital pan hypopituitarism.

Investigation

Magnetic resonance imaging (MRI) demonstrates thinning and attenuation of prechiasmatic intracranial optic nerve.

4. What are excavated optic disk anomalies?

- i. Morning glory disk anomaly
- ii. Optic disk coloboma
- iii. Peripapillary staphyloma

5. What are the features of morning glory disk anomaly?

It is a congenital, funnel shaped excavation of the posterior fundus that incorporates the optic disk.

Ophthalmoscopically

- i. The disk is markedly enlarged, orange or pink in color, and it may appear to be recessed or elevated centrally within the confines of a funnel shaped peripapillary excavation.
- ii. A wide annulus of chorioretinal pigmentary disturbance surrounds the disk within the excavation.
- iii. A white tuft of glial tissue overlies the central portion of the disk.
- iv. Blood vessels appear increased in number and often arise from the disk periphery; have a straight course.
- v. Macula may be incorporated in the excavation (macular capture).

Features

- i. Morning glory anomaly is usually a unilateral condition.
- ii. Visual acuity 6/60 to finger counting.
- iii. Females > males
- iv. Rare in blacks
- v. Associated with transsphenoidal form of basal encephalocele.
- vi. Patient with transsphenoidal encephalocele usually display a characteristic malformation complex consisting of midfacial anomalies, hypertelorism, widened bitemporal diameter, depressed nasal root and V-shaped fusion line involving the upper lip.
- vii. A transsphenoidal encephalocele may appear clinically as a pulsatile posterior nasal mass or a "nasal polyp" high in the nose.
- viii. Morning glory disk anomaly patients are at risk of acquired visual loss.
- ix. In 30% serous retinal detachment starts in the peripapillary area and extends to the posterior pole.

6. What are the features of optic disk coloboma?

- i. Coloboma means mutilated.
- ii. Coloboma of the optic disk results from incomplete or abnormal coaptation of the proximal end of the embryonic fissure.
- iii. In optic disk coloboma, a sharply defined, glistening white, bowl-shaped excavation occupies an enlarged optic disk.
- iv. Excavation is decentered inferiorly, reflecting the position of the embryonic fissure.
- v. Inferior neuroretinal rim is thin or absent while superior is spared.
- vi. Iris and ciliary coloboma often co-exist.
- vii. Axial scan show crater like excavation of the posterior globe at its junction with optic nerve.
- viii. Visual acuity may be decreased.
- ix. Optic disk coloboma may arise sporadically or inherited in an autosomal dominant fashion.
- x. Eyes with isolated optic disk coloboma are prone to develop serous macular detachments.

7. What are the features of peripapillary staphyloma?

It is a rare, unilateral, deep fundus excavation which surrounds the disk.

Peripapillary staphyloma	Morning glory disk
Deep, cup shaped excavation. Optic disk: Relatively normal and well defined Absence of glial and vascular anomalies	Less deep, funnel shaped excavation Optic disk: Grossly anomalous and poorly defined Central glial bouquet; anomalous vascular pattern

8. How do you differentiate morning glory syndrome from optic disk coloboma?

Ophthalmoscopic findings

Morning glory disk	Optic disk coloboma
<ol style="list-style-type: none"> 1. Optic disk lies within the excavation 2. Symmetrical defect 3. Central glial tuft 4. Severe peripapillary pigmentary disturbance 5. Anomalous retinal vasculature 	<ol style="list-style-type: none"> 1. Excavation lies within the optic disk 2. Asymmetrical defect 3. No central glial tuft 4. Minimal peripapillary pigmentary disturbance 5. Normal retinal vasculature

Systemic and ocular findings

Morning glory disk	Optic disk coloboma
Females > males Rarely familial Rarely bilateral No iris, ciliary body or retinal colobomas Rarely associated multisystem genetic disorder Basal encephalocele common	No sex or racial predilection Often familial Often bilateral Iris, ciliary and retinal colobomas common Often associated multisystem genetic disorder Rare

9. What are the features of megalopapilla?

Features:

2 phenotypic variants

- i. First is a common variant in which abnormally large optic disk (>2.1 mm in diameter)
 - Frequently bilateral with large cup-to-disk ratio where the cup is round or horizontally oval with no vertical notching differentiating it from a normal tension glaucoma
- ii. Second phenotypic variant, the normal optic cup is replaced by grossly anomalous non-inferior excavation that obliterates the adjacent neuroretinal rim.

10. What are the features of optic pit?

- i. Round or oval, gray, white or yellowish depression in the optic disk.
- ii. Commonly involve the temporal optic disk but may be situated in any sector.

- iii. Temporally located pits are often accompanied by adjacent peripapillary pigment epithelial changes.
- iv. One or two cilioretinal arteries are seen to emerge from the bottom or margin of the pit in 50% cases.
- v. Typically unilateral; disk is larger than in the fellow eye.
- vi. Serous macular elevation develops in 25–75% cases.
- vii. Maculopathy become symptomatic in third to fourth decade of life.

11. What are the sources of fluid in an optic disk pit?

- i. Vitreous cavity via the pit
- ii. Subarachnoid space
- iii. Blood vessels at the base of pit
- iv. Orbital space surrounding the dura.

12. What are the features of congenital tilted disk syndrome?

Fairly common, non-hereditary, bilateral condition in which the superotemporal optic disk is elevated and the inferonasal disk is posteriorly displaced, resulting in an oval-appearing disk, with its long axis obliquely oriented.

Accompanying features:

- i. Situs inversus of retinal vessels
- ii. Congenital inferonasal conus
- iii. Thinning of inferonasal RPE and choroid
- iv. Bitemporal hemianopia
- v. Affected patient may have myopic astigmatism
- vi. Disk is small, oval or d-shaped with axis oblique.
- vii. Visual field defects involving the upper temporal quadrants may be present as a result of inferonasal fundus changes.

13. What are the features of Aicardi syndrome?

Cerebroretinal disorder of unknown etiology.

Clinical features:

- i. Infantile spasms
- ii. Agenesis of corpus callosum
- iii. A characteristic EEG pattern termed as ‘hypsarrhythmia’
- iv. A pathognomonic optic disk appearance consisting of multiple depigmented “chorioretinal lacunae” clustered around the disk.
- v. Histopathologically these lacunae are well circumscribed, full thickness defects, limited to the RPE and the choroids.
- vi. Other congenital optic disk anomaly may accompany the chorioretinal lacunae.

Ocular associations:

- i. Microphthalmos
- ii. Retrobulbar cyst
- iii. Pseudoglioma
- iv. Retinal detachment, macular scars
- v. Cataract
- vi. Pupillary membrane, etc.

Systemic associations:

- i. Vertebral malformations (fused vertebra, scoliosis, spina bifida)
- ii. Costal malformations (absent ribs, fused ribs or bifurcated ribs)
- iii. CNS anomalies include:

Aggenesis of corpus callosum, cortical migration anomalies and malformations.

14. What are the features of optic disk drusen?

- i. Intrapapillary drusen are crystalloid, acellular refractile bodies that often appear in long standing anomalously elevated disk.
- ii. Incidence in general population is 0.3–2%.
- iii. Bilateral and familial “emerge” over time.
- iv. Patients with retinitis pigmentosa and angoid streak show increase incidence.
- v. Thought to develop from stagnant axoplasm dammed up by a small disc, a tight cribriform plate, or a narrow scleral canal.
- vi. May be small or large; superficial or deep.
- vii. Produce field loss, sparing 10° of visual field.

Investigations

- i. Fluorescein angiography: Drusen shows late staining with fluorescein (hyperfluorescence); whereas in papilledema the staining disk often shows feathery leakage into the adjacent nerve fiber layer.
- ii. Autofluorescence: Drusen shows autofluorescence when viewed with 430 nm wavelength (blue) light source using a yellow filter.
- iii. CT scan: Drusen show mineralization.
- iv. Ultrasonography: Drusen reflect sound waves.

Differentiating drusen from early *papilledema* pose a diagnostic challenge. Drusens have the following features:

- i. Absent optic cup
- ii. Disk has a pink/yellow color and margin has a “lumpy” appearance
- iii. Emerging vessels show anomalous premature branching
- iv. Autofluorescence.

15. What are the features of myelinated nerve fibers?

- i. Myelination of the optic nerve begins in the fetus, approaching the optic chiasm by about 7 months of gestation.
- ii. Myelination stops usually at lamina cribrosa at about 1 month of age, and is complete by about 10 months after birth.
- iii. In approximately 0.5% of population myelination continue past the optic disk and into the nerve fiber layer of the retina.
- iv. Characteristically, myelinated nerve fibers are white, and feathered at the edges and
- v. Do not have any effect on visual fields but the blind spot may be enlarged.

7.7. ANTERIOR ISCHEMIC OPTIC NEUROPATHY

1. Define anterior ischemic optic neuropathy.

Anterior ischemic optic neuropathy (AION)—defined as the segmental or generalized infarction within the prelaminar or laminar portion of the optic nerve. Caused by occlusion of the short posterior ciliary arteries.

2. Give the clinical classification of anterior ischemic optic neuropathy.

1. Arteritic AION
2. Nonarteritic AION

3. What are the risk factors for nonarteritic anterior ischemic optic neuropathy?

Risk factors

- i. Nicotine smokers
- ii. Diabetes (diabetic papillopathy—common in juvenile diabetics)
- iii. Hypertensives and patients with migraine—long standing HTN is thought to affect the autoregulation of blood flow to the optic nerve head
- iv. Hypercholesterolemia
- v. Cerebrovascular disease
- vi. Carotid artery disease
- vii. Acute severe blood loss
- viii. Uremia
- ix. Favism resulting in an acute hemolytic anemia
- x. Nocturnal hypotension
- xi. Elevated IOP
- xii. Uncomplicated cataract extraction
- xiii. Rarely associated with cavernous sinus thrombosis and radiation optic neuropathy.

4. What is the pathogenesis of nonarteritic anterior ischemic optic neuropathy?

Nonarteritic anterior ischemic optic neuropathy is thought to be caused by vascular insufficiency. This hypothesis is supported by the following facts.

Abrupt onset of visual loss which is typical of a vascular disease:

- i. Common in older patients with systemic vasculopathies
- ii. Closure of small blood vessels in histopathology specimens
- iii. Lack of evidence of inflammation and

The prelaminar and laminar portions of the optic nerve is supplied by an elliptical arterial circle called Zinn's corona or Haller's circle formed by the anastomosis around the optic nerve between medial and lateral paroptic short posterior ciliary arteries. The ellipse is divided into superior and inferior parts by the entry points of the lateral and medial short posterior ciliary

arteries, providing an altitudinal blood supply to the anterior optic nerve. Reduced perfusion pressure within the territory of the paraoptic branches of the short posterior ciliary arteries results in an altitudinal visual field loss.

Optic disks of patients with AION are usually small with little or no physiologic cupping. A small cup-to-disk ratio implies a small optic disk diameter and small scleral canal resulting in crowding of nerve fibers through a restricted space in the lamina cribrosa. The ischemia in AION causes axoplasmic flow stasis, which causes compression of the capillaries within this crowded disk resulting in further ischemia.

Hence the 'disk at risk' is one with:

- i. Small physiologic cup.
- ii. Elevation of disk margins by a thick nerve fiber layer.
- iii. Anomalies of blood vessel branching.
- iv. Crowded and small optic nerve head.

Blood flow to the optic nerve head is directly proportional to the perfusion pressure and is inversely proportional to the vascular resistance in the blood vessels. Vascular resistance is influenced by the blood vessel wall changes, which are affected in disease states such as hypertension, diabetes mellitus, arteriosclerosis and vasospasm.

5. What are the clinical features of nonarteritic anterior ischemic optic neuropathy?

- i. Affects patients between 45–70 years of age.
- ii. Patients present with monocular sudden painless visual loss. 2/3rd of cases have a moderate to severe impairment and 1/3rd of cases are spared or have minimal visual impairment.
- iii. Diminished color perception. The degree of color vision loss is directly related to the amount of visual acuity loss (as opposed to patients with optic neuritis where color vision is significantly impaired despite minimal loss of visual acuity).
- iv. Visual field defects most often in the form of inferior altitudinal defects which spare fixation. Other field defects such as central scotomas, arcuate defects, quadrantic defects and generalized constriction may also occur.
- v. Relative afferent pupillary defect.
- vi. On ophthalmoscopic examination, there may be:
 - Focal or diffuse disk swelling
 - Disc may be pale or hyperemic and
 - May have splinter hemorrhages at the disk margin.

7% of cases have associated with hard exudates in a star pattern at the macula which may be misdiagnosed as neuroretinitis.

Focal hyperemic telangiectatic vessels may appear on the optic disk of an eye with NAION within day or weeks of onset of symptoms. This phenomenon is called luxury perfusion—a vascular autoregulatory response to ischemia.

Disk swelling resolves in 1–2 months with the development of optic atrophy but with no cupping and attenuated vessels.

6. What are the investigations used in nonarteritic anterior ischemic optic neuropathy?

- i. ESR
- ii. C-reactive protein
- iii. Serum lipids
- iv. Blood glucose
- v. Packed cell volume and
- vi. Fibrinogen levels.

7. What is the treatment for nonarteritic anterior ischemic optic neuropathy ?

No therapy is of significant benefit.

Medical therapy

- i. Underlying systemic conditions should be treated.
- ii. Patients should discontinue smoking.
- iii. Antiplatelet agents and anticoagulants have been tried.
- iv. Steroids—its role is controversial.

Surgical therapy

- i. Stellate ganglion block.
- ii. Optic nerve sheath decompression.

The ischemic optic neuropathy decompression trial:

- i. It is a multicenter prospective study of nonarteritic anterior ischemic optic neuropathy.
- ii. The primary objective of this study was to assess the safety and efficacy of optic nerve sheath decompression (ONSD) versus careful observation of patient with NAION. The secondary objectives were documentation of the natural history of the disease, identification of risk factors and assessment of the contralateral eye risk as well as other nonocular vaso-occlusive events.
- iii. The study found that 42.7% of patients on careful observation, at 6 months, showed an improvement in visual acuity by 3 lines or more while in 45% little or no change occurred.
- iv. In the patients who underwent ONSD, only 32.6% of patient had an improved visual acuity of 3 lines or more while 43.5% experienced little or no change.
- v. Hence, optic nerve sheath decompression ONSD did not appear to be effective in the management of nonarteritic anterior ischemic optic neuropathy.
- vi. Optic nerve sheath decompression group also studied the role of aspirin in nonarteritic anterior ischemic optic neuropathy and concluded that its role in prevention of NAION is still unclear.

8. What are the causes of arteritic anterior ischemic optic neuropathy (AAION)?

- i. Giant cell arteritis or temporal arteritis (most common cause type of AAION)
- ii. Rheumatoid arthritis
- iii. HZV infection
- iv. Relapsing polychondritis
- v. Takayasu's arteritis
- vi. Behcet's disease
- vii. Polyarteritis nodosa
- viii. Systemic lupus erythematosus
- ix. Churg-Strauss angitis

9. What are the clinical features of AAION?

- i. Sudden monocular profound loss of vision which is preceded by transient visual obscurations and flashes of light
- ii. Bilateral involvement may occur
- iii. Periocular pain may or may not occur
- iv. Patients have pale swollen disks with splinter hemorrhages. The disks typically look chalky white. The disk edema resolves leaving behind a markedly cupped disk.

10. What are the ocular features of giant cell arteritis?

- i. Amaurosis fugax
- ii. CRAO
- iii. AION
- iv. Choroidal infarcts
- v. Cotton wool spots
- vi. Anterior segment ischemia
- vii. Hypotony
- viii. Conjunctival and episcleral congestion
- ix. Corneal edema
- x. Extraocular muscle ischemia
- xi. Oculomotor nerve palsy
- xii. Ophthalmic artery occlusion
- xiii. Cortical blindness.

11. What are the systemic manifestations of giant cell arteritis (GCA)?

- i. Malaise
- ii. Weight loss, depression, fever
- iii. Polymyalgia rheumatica—stiffness and pain of proximal muscle groups in the morning and after exertion
- iv. Jaw claudication
- v. Headache
- vi. Palpable, nodular and non-pulsatile temporal artery
- vii. Anemia

- viii. Myocardial infarction
- ix. Stroke
- x. Renal failure

12. How do you diagnose arteritic anterior ischemic optic neuropathy (AAION)?

- i. ESR—normal in 20% of cases
usually > 50 mm/hr (by Westergren's method)
age related normal for males is $\frac{\text{age}}{2}$ mm/hr
and for females is $\frac{\text{age} + 10}{2}$ mm/hr
 - ii. C-reactive protein—raised
 - iii. Fluorescein angiography—delayed or absent filling of the choroidal circulation
 - iv. Alkaline phosphate level in serum—raised
 - v. ANA—positive
 - vi. Temporal artery biopsy
 - gives a definitive diagnosis
 - a 3 cm long specimen should be taken as skip lesions are evident
- Occult GCA: Ocular involvement without associated signs and symptoms but with raised ESR and temporal artery biopsy positive for GCA.

13. How do you treat arteritic anterior ischemic optic neuropathy (AAION)?

Systemic steroids is the main stay. The treatment protocol is as follows:

IV methyl prednisolone 1–2 g/day
+
Tab prednisolone 80 mg/day } for 3 days

Then,

Tab prednisolone 60 mg x 3 days
 40 mg x 4 days

Taper by 5 mg/week till 10 mg/day

Maintenance dose of 10 mg/day for 12 months

Throughout the treatment the signs, symptoms and ESR is monitored.

7.8. OCULOMOTOR NERVE

1. Enumerate the salient features in the embryology of 3rd nerve.

- i. 3rd nerve develops in the cranial portion of the neural tube from the most medial row of neuroblasts, the somatic efferent column.
- ii. 3rd nerve nucleus becomes visible at the 8–9 mm stage.

2. What are the functional components of third nerve?

- i. Somatic efferent—fibers to extraocular muscles
- ii. General somatic afferent—Carries proprioceptive impulses from these muscles
- iii. General visceral efferent—Parasympathetic supply to eye.

3. Describe the anatomy of third nerve nucleus.

Location: Midbrain at the level of superior colliculus

Dimension: Longitudinal column of large multipolar neurons, 10 mm in length, in the floor of cerebral aqueduct

Relations: Above it extends as far as the floor of the third ventricle. Below it is related to the nucleus of trochlear nerve.

Blood supply: Nuclei and the fascicles are supplied by median group of arteries that arises from the bifurcation of basilar artery at the origin of superior cerebellar and posterior cerebral arteries.

4. What are the components of third nerve nucleus?

- i. Principal nucleus
- ii. Edinger-Westphal nucleus dorsal to the principal nucleus.

5. What is Warwick's classification of principal nucleus?

Nucleus	Muscle supplied
i. Dorsolateral	Inferior rectus
ii. Intermediate	Inferior oblique
iii. Ventro median	Medial rectus
iv. Paramedian	Superior rectus
v. Caudal central	Levator palpebrae superioris

6. Which nucleus has a contralateral innervation and what is its significance in diagnosis?

Fibers from paramedian group nucleus are partly crossed and supply the contralateral superior rectus. Therefore, a nuclear third nerve palsy of one side causes a paresis of contralateral superior rectus.

7. Which nucleus is unpaired and has a bilateral supply?

Both levator palpebrae superioris muscles are supplied by a single midline caudal subnucleus. Lesion that damages this region thus produces a bilateral symmetric ptosis.

Some lesions of the oculomotor nuclear complex may spare this region causing a fixed dilated pupil and ophthalmoparesis but no ptosis.

8. Describe the anatomy of Edinger-Westphal (EW) nucleus.

- i. The E-W nucleus is made up of small multipolar neurons.
- ii. It consists of two lateral components and a medial component united anteriorly.
- iii. Anterior part of median component and lateral components are parasympathetic.
- iv. Cranial half of this is concerned with light reflexes.
- v. Caudal half is concerned with accommodation reflex.
- vi. Posterior part of E-W nucleus is forked and previously was erroneously termed as convergence nucleus of perlia.

The nucleus for the proprioceptive fibers is situated in the trigeminal nerve nuclear complex. They reach the nucleus either through the communication to ophthalmic nerve in the cavernous sinus or through the connections between oculomotor nucleus and mesencephalic nucleus of trigeminal nerve.

9. Describe the blood supply of third nerve.

- i. In the subarachnoid space, the nerve receives vascular twigs from the posterior cerebral artery, superior cerebellar artery and the tentorial and dorsal meningeal branches of the meningohypophyseal trunk of the internal carotid artery.
- ii. In cavernous sinus, the tentorial, dorsal meningeal and inferior hypophyseal branches of the meningohypophyseal trunk supply the nerve along with branches from ophthalmic artery.

10. Describe the topographic arrangement of fibers within the third nerve.

- i. Within the subarachnoid space, pupillomotor fibers appear to be located superficially in the superior portion of the nerve. The fibers in this portion of the third nerve are arranged in a superior and inferior division.
- ii. Within the cavernous sinus and orbit, the pupillary fibers are located in the inferior division of the nerve. The position of the fibers going to the specific EOM is unknown.

11. What are the muscles supplied by the third nerve?

- A. The superior division innervates the
 - i. Superior rectus
 - ii. Levator palpebrae superioris
- B. The inferior division innervates the
 - i. Inferior rectus
 - ii. Medial rectus
 - iii. Inferior oblique
 - iv. Sphincter muscle of the iris (pupil)
 - v. Ciliary muscle (accommodation).

12. What is ciliary ganglion?

It is a peripheral parasympathetic pinhead size ganglion situated at the apex of the orbit, between the optic nerve medially and the lateral rectus laterally, in the central surgical space.

13. What are the various roots of the ciliary ganglion?

- i. Parasympathetic root is a branch from the nerve to inferior oblique, carrying preganglionic fibers from Edinger-Westphal nucleus
- ii. Sympathetic root carries postganglionic fibers from the superior cervical sympathetic ganglion
- iii. Sensory root is a twig from nasociliary nerve.

14. What are types of third nerve palsies?

- i. Congenital
- ii. Acquired.

15. What are the causes of congenital third nerve palsies?

A. Aplasia or hypoplasia of the third nerve nucleus.

B. Birth trauma. It is due to the damage to the subarachnoid portion of the 3rd nerve, either at its exit from the brainstem or just before it enters the cavernous sinus.

C. Syndromes associated with congenital 3rd nerve palsy.

- i. ***Congenital adduction palsy with synergistic divergence:*** Patients with this syndrome have congenital unilateral paralysis of adduction associated with simultaneous bilateral adduction on attempted gaze into the field of action of the paretic medial rectus muscle.
- ii. ***Vertical retraction syndrome:*** Main features are limitation of movement of the affected eye on elevation or depression associated with a retraction of the globe and narrowing of the palpebral fissure.
- iii. Oculomotor nerve paresis with cyclic spasms.

16. What are the various levels at which third nerve can be affected in an acquired palsy?

At the level of

- i. Oculomotor nucleus
- ii. Oculomotor nerve fascicle
- iii. In the subarachnoid space
- iv. At or near the entrance to the cavernous sinus
- v. Within the cavernous sinus
- vi. Within the supraorbital fissure
- vii. Within the orbit
- viii. Uncertain or variable location

17. What are the causes of III nerve palsy?

Any focally destructive lesion along the course of the third cranial nerve can cause oculomotor nerve palsy or dysfunction. Some of the most frequent causes include the following:

- A. Nuclear portion
 - i. Infarction
 - ii. Hemorrhage
 - iii. Neoplasm
 - iv. Abscess
- B. Fascicular midbrain portion
 - i. Infarction
 - ii. Hemorrhage
 - iii. Neoplasm
 - iv. Abscess
- C. Fascicular subarachnoid portion
 - i. Aneurysm
 - ii. Infectious meningitis—Bacterial, fungal/parasitic, viral
 - iii. Meningeal infiltrative
 - iv. Carcinomatous/lymphomatous/leukemic infiltration, granulomatous inflammation (sarcoidosis, lymphomatoid granulomatosis, Wegener granulomatosis)
- D. Fascicular cavernous sinus portion
 - a. Tumor—Pituitary adenoma, meningioma, craniopharyngioma, metastatic carcinoma
 - b. Vascular
 - c. Giant intracavernous aneurysm
 - d. Carotid artery-cavernous sinus fistula
 - e. Carotid dural branch-cavernous sinus fistula
 - f. Cavernous sinus thrombosis
 - g. Ischemia from microvascular disease in vasa nervosa
 - h. Inflammatory—Tolosa-Hunt syndrome (idiopathic or granulomatous inflammation).
- E. Fascicular orbital portion
 - i. Inflammatory—Orbital inflammatory pseudotumor, orbital myositis
 - ii. Endocrine (thyroid orbitopathy)
 - iii. Tumor (e.g. hemangioma, lymphangioma, meningioma).

18. What is the commonest cause of isolated III nerve palsy with pupillary involvement?

Intracranial aneurysms

19. What are the investigations for a III nerve palsy?

A. Basic investigations

- i. Blood sugar
- ii. Blood pressure
- iii. Lipid profile
- iv. ESR—to rule out giant cell arteritis

B. X-ray skull lateral view—to rule out sellar lesions involving the cavernous sinus

- C. In complicated third nerve palsies where other neural structures are involved, have the patient undergo an MRI/MRA.
- D. In isolated third nerve palsies with no pupillary involvement where the patient is over 50, MRI scanning, an ischemic vascular evaluation, and daily pupil evaluation is indicated.
- E. If the patient is under 50 and has a non-pupillary involved isolated third nerve palsy, intracranial angiography is indicated since ischemic vasculopathy is less likely to occur in this age group than is aneurysm. In majority of cases it can pick aneurysms >3 mm in size.
- F. **Cerebral angiography**—Angiography is the definitive test for berry aneurysm in all intracranial locations. If the adult patient of any age presents with a complete or incomplete isolated third nerve palsy with pupillary involvement, consider this to be a medical emergency and have the patient undergo intracranial angiography immediately (CT angiography or MR angiography). In these cases, the cause is likely subarachnoid aneurysm and the patient may die if the aneurysm ruptures.
- G. Children under the age of 14 rarely have aneurysms; the majority of third nerve palsies in this age group are traumatic or congenital.
- H. **Lumbar puncture**—The main purpose of lumbar puncture is to demonstrate the presence of blood in cerebrospinal fluid, an inflammatory reaction, neoplastic infiltration, or infection.
- I. **Cytologic examination** of cerebrospinal fluid is used to diagnose meningeal carcinomatosis and lymphomatous or leukemic infiltration.

20. How does aneurysms affect the III nerve and what is its commonest site?

- A. Aneurysms usually arise from the junction of internal carotid and posterior communicating arteries.
- B. In its course towards the cavernous sinus, the III nerve travels lateral to the posterior communicating artery and may be injured by
 - i. Direct compression
 - ii. Hemorrhage
 - iii. Major rupture
 - iv. During aneurysm surgery.

21. Why are pupillary fibers spared in ischemic lesions and more commonly affected in compressive lesions?

The pupillomotor fibers are arranged in outer layers of the III nerve and are therefore closer to the nutrient blood supply enveloping the nerve. So they are spared in 80% of ischemic lesions but being outer, are affected in 95% of compressive lesions.

22. Why is III nerve more commonly affected in cavernous sinus lesions?

The III nerve is firmly attached to the dura adjacent to the posterior clinoid process just posterior to the cavernous sinus, so is more vulnerable to

- i. Stretch
- ii. Contusion injuries
- iii. Frontal head trauma
- iv. Aneurysms
- v. Surgery in the perisellar region.

23. What are the causes of painful III nerve palsy with pupil involvement?

- i. Posteriorly draining, low flow carotid-cavernous fistula
- ii. Tumors
- iii. Compressive lesions—Aneurysms of posterior cerebral and basilar vessels
- iv. Intrinsic lesions of the III nerve—Schwannomas and cavernous angiomas

24. How can you demonstrate whether fourth nerve is involved, in the situation of a third nerve palsy?

The patient is asked to abduct the eye and then look down. If the fourth nerve is functioning the eye should intort.

25. Localization of 3rd nerve lesions and clinical manifestations.

Structure involved	Clinical manifestations
<p>Lesions affecting OM nucleus:</p> <ol style="list-style-type: none"> 1. Oculomotor nucleus 2. Oculomotor subnucleus 3. Isolated levator subnucleus 4. Paramedian mesencephalon 	<p>Ipsilateral complete third palsy Contralateral ptosis and superior rectus paresis.</p> <p>Isolated muscle palsy (inferior rectus) Isolated bilateral ptosis Plus minus syndrome (ipsilateral ptosis and contralateral eyelid retraction)</p>
<p>Lesions affecting OM fascicles:</p> <ol style="list-style-type: none"> 1. Isolated fascicle 2. Fascicle and superior cerebellar peduncle 3. Fascicle and cerebral peduncle 4. Fascicle and red nucleus/substantia nigra 	<p>Partial or complete third nerve palsy with or without pupillary involvement.</p> <p>Ipsilateral 3rd nerve palsy with contralateral ataxia and tremor (Claude's syndrome)</p> <p>Ipsilateral 3rd nerve palsy with contralateral hemiparesis</p> <p>Ipsilateral 3rd nerve palsy with contralateral choriform movements (Benedicts syndrome)</p>

26. What are the features of nuclear III nerve palsy?

- i. Ptosis—always bilateral
- ii. Mydriasis and cycloplegia—always bilateral
- iii. Contralateral superior rectus paresis or bilateral superior rectus paresis
- iv. Incomplete involvement of different subnuclei
- v. Bilateral total III nerve palsy can happen without ptosis

27. How does fascicular III nerve palsy present?

Damage to fascicular or subarachnoid portion of the III nerve presents as

- i. Isolated pupillary dilation with reduced light reaction
- ii. Ophthalmoplegia with or without pupillary involvement.

28. What are the factors responsible for III nerve palsy in hippocampal gyrus herniation?

- i. Direct compression of the III nerve
- ii. Mechanical stretching of III nerve
- iii. Shifting of basal arteries with herniating brainstem—posterior cerebral arteries drawn tightly across the dorsal surface of III nerves.

29. What is Hutchinson's pupil?

Dilation of one pupil when the other is contracted, resulting from compression of the third nerve due to

- i. Meningeal hemorrhage at the base of the brain
- ii. Herniation of the uncus of the temporal lobe through the tentorial notch.

The effect is caused by pressure of the posterior cerebral artery on the superior surface of the oculomotor nerve where the pupillary fibers are concentrated.

30. What is sphenocavernous syndrome?

Characterized by paralysis or paresis of the III, IV and VI nerves within the cavernous sinus or the superior orbital fissure.

- i. Associated with involvement of the first division of the V nerve.
- ii. Optic nerve involvement can cause visual loss
- iii. Oculosympathetic paresis may lead to proptosis and edema of eyelids and conjunctiva.

31. What is pseudo-orbital apex syndrome?

Large intracranial masses may expand to such a degree that they compress the intracranial optic nerve or cavernous portion of the III nerve and prevent adequate venous drainage from the orbit, resulting in pseudo-orbital apex syndrome.

32. Enumerate some common lesions causing sphenocavernous syndrome.

- i. Aneurysms
- ii. Meningiomas
- iii. Pituitary tumors
- iv. Craniopharyngiomas
- v. Nasopharyngeal tumors
- vi. Metastatic tumors
- vii. Infectious/inflammatory

33. What are the common causes of pupil sparing III nerve palsy?

The most important cause is ischemia, due to

- A. Diabetes
- B. Hypertension
- C. Atherosclerosis
 - i. Migraine
 - ii. Systemic lupus erythematosus
 - iii. Giant cell arteritis.

34. How can a pupil sparing isolated III nerve palsy be investigated?

Ischemia lab work up

- i. Blood pressure
- ii. Complete blood count
- iii. ESR
- iv. Blood sugar, glycosylated Hb
- v. VDRL, FTA-ABS (TPHA)

35. How long does it take for pupil sparing palsy to recover?

Ischemic III nerve palsies resolve within 4 to 16 weeks without treatment and the resolution is almost complete.

36. What is aberrant regeneration of the III nerve or oculomotor synkinesis or misdirection syndrome?

Aberrant regeneration occurs as a consequence of complete III nerve palsy in which there is gross limitation of ocular movement amounting to virtual paralysis. The regenerating autonomic and voluntary nerve fibers grow along the wrong myelin tubes that contained functioning neurons before degeneration.

37. Why is aberrant degeneration seen commonly in III nerve palsy?

The III nerve supplies a number of different muscles. The regenerating sprouts from axons that previously innervated one muscle group may ultimately innervate a different muscle group with a different function.

38. What are the clinical presentations of aberrant regeneration of III nerve?

1. Lid-gaze dyskinesia

- a. **Pseudo von Graefe sign:** Some of the nerve fibers to the inferior rectus may end up innervating the elevator so that the lid retracts when the patient looks down.
- b. **Inverse Duane's syndrome:** Some of the medial rectus fibers may end up supplying some of the innervation to the levator so that the lid retracts when the patient adducts his eye.

2. Pupil-gaze dyskinesia:

Pseudo-Argyll Robertson pupil: Some of the medial rectus fibers may end up innervating the pupillary sphincter muscle so that there is more pupil constriction during convergence than as a response to light.

39. What are the two forms of aberrant regeneration?

- i. Primary: No preceding III N palsy
- ii. Secondary aberrant regeneration: After III N palsy

40. What are the syndromes associated with III nerve palsy?

- i. **Benedict's syndrome**—Involves the fasciculus as it passes through the red nucleus. It causes ipsilateral III nerve palsy and contralateral extrapyramidal signs.
Level of lesion: Red nucleus.
- ii. **Weber's syndrome**—Involves fasciculus as it passes through the cerebral peduncle. Causes ipsilateral third nerve palsy and contralateral hemiparesis.
- iii. **Nothnagel's syndrome**—involves fasciculus at the level of superior cerebellar peduncle. Causes ipsilateral III nerve palsy and cerebellar ataxia.
- iv. **Claude's syndrome**—Combination of Benedict and Nothnagel syndrome
- v. **Uncal herniation syndrome**—A supratentorial space occupying mass causes downward displacement and herniation of the uncus across tentorial edge compressing the III nerve. A dilated and fixed pupil (Hutchinson's pupil) in a patient with altered consciousness may be the presenting feature.
- vi. **Orbital syndrome**—While crossing the superior orbital fissure any division of the III nerve may be affected causing paresis of structures innervated by them.
- vii. **Cavernous sinus syndrome**—Occurs in association with IV, V, VI nerves and oculosympathetic paralysis. III nerve cavernous palsy is usually partial and pupil sparing .

41. What is primary oculomotor nerve synkinesis?

Acquired oculomotor synkinesis may occur as a primary phenomenon, without a pre-existing acute III nerve palsy. Common causes are slowly growing tumors of:

- i. Cavernous sinus-meningioma, aneurysms, trigeminal Schwannomas
- ii. Subarachnoid space.

42. What are the indications of neurological imaging in III nerve palsy?

- i. All children <10 years irrespective of pupillary findings
- ii. Children >10 years with pupil involvement
- iii. If pupil becomes dilated after 5–7 days of onset
- iv. Multiple cranial nerves affected
- v. No improvement is seen within 3 months
- vi. Signs of aberrant degeneration of the nerve develop
- vii. Other neurological signs.

43. How can III nerve palsy be managed?

A. Medical management

- i. Medical management is watchful waiting, since there is no direct medical treatment that alters the course of the disease. Nearly all patients undergo spontaneous remission of the palsy, usually within 6–8 weeks.

- ii. Treatment during the symptomatic interval is directed at alleviating symptoms, mainly pain and diplopia.
- iii. Non-steroidal anti-inflammatory drugs (NSAIDs) are the first-line treatment of choice for the pain. Diplopia is not a problem when ptosis occludes the involved eye.
- iv. When diplopia is from large-angle divergence of the visual axes, patching one eye is the only practical short-term solution.
- v. When the angle of deviation is smaller, fusion in primary position often can be achieved using horizontal or vertical prism or both.
- vi. Since the condition is expected to resolve spontaneously within a few weeks, most physicians would prescribe the Fresnel prism.

B. Surgical management

- i. For practical purposes, surgical care of third cranial nerve palsy includes clipping, gluing, coiling or wrapping of the berry aneurysm by a neurosurgeon in the acute stage.
- ii. Patients who do not recover from third cranial nerve palsy after 6–12 months may become candidates for eye muscle resection or recession to treat persistent and stable-angle diplopia.
- iii. Some of these patients also may require some form of lid-lift surgery for persistent ptosis that restricts vision or is cosmetically unacceptable to the patient.
- iv. Neurosurgery: Third cranial nerve palsy due to berry aneurysm, with or without concomitant subarachnoid hemorrhage, requires neurosurgical management in most cases.
- v. Ophthalmology: The ophthalmologist provides symptomatic treatment for diplopia using
 - Occlusion
 - Prism
 - Eye muscle surgery
 - Lid-lift procedures for ptosis
 - Botulinum toxin into the lateral rectus muscle.

46. What are the indications of follow-up in III nerve palsy?

- i. Truly isolated palsy—which may be still evolving. Review within 2 weeks
- ii. Age >40 years
- iii. H/O diabetes or hypertension.

47. For how long is surgical intervention deferred in III nerve palsy?

- i. Strabismus and lid surgeries can be considered after six months. Most ischemic palsies have complete recovery by 3 months (maximum 6 months).
- ii. In complete traumatic palsies, recovery is usually not complete and surgical correction of squint is quite difficult.

48. What are the differential diagnosis of III nerve palsy?

- i. Neuromuscular disease—myasthenia
- ii. Orbital diseases—myositis

- iii. Cavernous sinus lesions
- iv. Chronic meningitis
- v. Midbrain pathology.

49. What are the differentiating features between concomitant/non-paralytic and nonconcomitant/paralytic squint?

Features	Paralytic squint	Nonparalytic squint
1. Onset	Usually sudden	Usually slow
2. Diplopia	Usually present	Usually absent
3. Ocular movements	Limited in the direction of paralysed muscle	Full
4. False projection	It is positive: the patient cannot correctly locate the object in space when seeing in the direction of the paralyzed muscle, in early stages	Negative
5. Head posture	Particular head posture depending on the muscle paralyzed, may be present	Normal
6. Nausea and vertigo	Present	Absent
7. Secondary deviation	More than primary deviation	Equal to primary deviation
8. Pathological sequelae in muscles	Present	Absent

7.9. FOURTH NERVE PALSY

1. What are the peculiarities of the fourth nerve?

Trochlear nerve palsy is the most common cause of acquired vertical strabismus in the general population.

- i. It is the only cranial nerve to have a dorsal emergence
- ii. It has all the fibers crossed
- iii. It is the most slender cranial nerve
- iv. It has the longest intracranial course of all the cranial nerves (75 mm).

2. Where is the nucleus of the fourth nerve located?

It is situated in the midbrain at the level of the inferior colliculus anterolateral to cerebral aqueduct and dorsal to medial longitudinal bundle.

3. What are the symptoms of fourth nerve palsy?

These are due to superior oblique palsy, which leads to:

- i. **Diplopia:** It can be vertical, some degree of horizontal and torsional. The last one is more pronounced on down gaze, i.e. in the field of action of superior oblique muscle. This in turn leads to symptoms like **asthenopia**, difficulty in walking down the stairs.
- ii. **Image tilting:** The image is tilted in the direction of affected side. This symptom is rare in congenital palsy.
- iii. **Anomalous head posture:** To prevent diplopia, the face is turned and head is tilted toward uninvolved side and the chin is depressed. This position places the eyes in a position where cooperation of affected muscle is not required.

4. How does one test involvement of the fourth nerve?

Bielschowsky's head tilt test: It is employed to diagnose paretic superior oblique as well as vertical rectus muscle in hypertropia.

The three steps are:

Step 1: Identify the type of hypertropia (RHT or LHT)

Step 2: Identify whether vertical deviation increases on dextroversion or levoversion.

Step 3: Determine whether vertical deviation increases on tilting the head toward the right or left. If the hypertropia is due to weakness of one of the 8 vertically acting muscles, the paretic muscle is identified by answering these questions. Each step cuts possible number of muscles in half. After the last step only one muscle remains.

In a superior oblique paralysis, there is ipsilateral hypertropia, which increases on contralateral gaze and ipsilateral head tilt.

5. How does one test involvement of the fourth nerve in the presence of 3rd nerve palsy?

- i. In presence of 3rd nerve palsy, fourth nerve function is tested by asking the patient to depress the abducted eye and watching for intorsion.
- ii. Isolated fourth nerve palsy can occur in ischemic conditions, e.g. diabetes mellitus and herpes zoster.

6. How does one test the torsional component of the fourth nerve?

- i. Double Maddox rod test:
 - done to quantify the torsional component of diplopia
 - $>10^\circ$ of torsion is suggestive of bilateral fourth nerve palsy
- ii. Landcaster's Red Green test
- iii. Ophthalmoscopic examination
- iv. Hess's charting.

7. What are the differential diagnosis of vertical diplopia?

A. Skew deviation:

- i. It is a vertical misalignment of visual axis
- ii. It may be transient, constant or alternating, concomitant or incomitant
- iii. Due to imbalance of supranuclear inputs
- iv. Associated with brainstem and cerebellar signs and symptoms
- v. Not associated with torsional diplopia or cyclodeviation

B. Myasthenia gravis:

- i. Can involve isolated superior oblique and mimic fourth nerve palsy
- ii. Shows diurnal variation
- iii. Can involve other extraocular muscles
- iv. Tensilon test positive
- v. EMG and ACh receptor antibodies positive

C. Thyroid ophthalmopathy:

- i. Other signs of hyperthyroidism are present
 T_3, T_4 levels suggestive
 In superior oblique palsy the hypertropia is worse on **down gaze**, while in thyroid ophthalmopathy it is worse in **up gaze**.

8. What are the causes of superior oblique paresis?

- i. Fourth nerve palsy
- ii. Traumatic (may be bilateral)
- iii. Vascular mononeuropathy
- iv. Diabetic
- v. Decompensated congenital paresis
- vi. Posterior fossa tumor (rare)
- vii. Cavernous sinus/superior orbital fissure syndromes
- viii. Neurosurgical procedures
- ix. Herpes zoster
- x. Myasthenia gravis
- xi. Graves' myopathy (fibrotic inferior oblique, superior rectus)*

- xii. Orbital inflammatory pseudotumor
- xiii. Orbital injury to trochlea.

9. What are the syndromes associated with fourth nerve palsy?

A. Nuclear-fascicular syndrome: Distinguishing nuclear from fascicular lesions is virtually impossible due to short course of fascicles within the midbrain.

Common etiologies are:

- i. Hemorrhage
- ii. Infarction
- iii. Demyelination
- iv. Trauma.

B. Subarachnoid space syndrome:

Causes:

- 1. Trauma
- 2. Basal meningitis
- 3. Neoplasms like pinealomas and tentorial meningiomas and aneurysms.

When bilateral-site-anterior medullary velum.

Associated signs and symptoms of the condition are present.

C. Cavernous sinus syndrome: Associated with other cranial nerve palsies like third, sixth, fifth and ocular sympathetic paralysis.

D. Orbital syndrome: It occurs due to trauma, inflammation and tumors.

Seen in association with other cranial nerve palsies, e.g. 3rd, 5th, 6th.

Associated orbital signs are proptosis, chemosis and conjunctival injection.

E. Isolated fourth nerve palsy

Congenital:

Diagnostic keys: large vertical fusion amplitude (10 to 15 prism diopters)

FAT (family album tomography) scan.

Acquired:

In ischemic conditions, e.g. diabetes mellitus and in herpes zoster.

10. Describe the management of superior oblique paresis.

Medical management:

- i. Primary aim is to **prevent diplopia** while waiting for spontaneous improvement
- ii. Occlusion of one eye with a patch or opaque contact lens can be done
- iii. Fresnel's prism can be used for vertical displacement
- iv. Treatment of diabetes and hypertension is done appropriately
- v. Evaluations at frequent intervals during waiting period
- vi. Role of botulinum toxin is controversial.

With this treatment superior oblique function may:

- i. **Recover completely**, e.g. in cases of ischemia, closed injury, after relief of compression from tumor or aneurysm.
- ii. **Recover incompletely** leaving the patient with mild but persistent vertical diplopia, torsional diplopia or both.
- iii. **No recovery**, e.g. mesencephalic injury or transection of trochlear nerve

Chances of further improvement after 6 months are rare.

Surgical management:

- i. About 50% of patients require re-surgery in future
- ii. The available options are:
 - Weaken the antagonist, i.e. weakening of ipsilateral inferior oblique
 - Weaken the yoke muscle, i.e. weakening of the contralateral inferior rectus
 - Weakening of ipsilateral superior rectus
 - Strengthening of superior oblique
 - More than one muscle surgery.

11. What is Knapp's classification?

The choice of surgery is decided by **Knapp's classification**. It depends on magnitude of hypertropia in the diagnostic positions of gaze. There are 7 classes. For every class a specific surgery is recommended.

1. Class 1:

- Hypertropia is greatest in adduction and elevation
- Ipsilateral inferior oblique overaction is present. Treatment is inferior oblique myomectomy.

2. Class 2:

- Hypertropia is greatest in adduction and depression
- Treatment is superior oblique tuck (8–12 mm) with recession of contralateral inferior rectus as second procedure.

3. Class 3:

- Hypertropia is of equal magnitude in entire paralyzed field of gaze
- Treatment is ipsilateral inferior oblique myotomy.
- But if hypertropia is more than 25 prism diopters, it is combined with superior oblique tuck.

4. Class 4:

- Hypertropia is more in entire paralyzed field of gaze and in down gaze also
- Contracture of ipsilateral superior rectus or contralateral inferior rectus
- Forced duction test is done.
- Treatment is as in class 3 plus recession of ipsilateral superior rectus or contralateral inferior rectus.

5. Class 5:

- Hypertropia is more in all down gazes
- Treatment is superior oblique tuck, recession of ipsilateral superior rectus or contralateral inferior rectus.

6. Class 6:

- Bilateral fourth nerve palsy
- Treatment is as in classes 1 to 5, but bilateral surgery.

7. Class 7:

- Classic superior oblique paralysis associated with restriction of elevation in adduction (pseudo Brown's syndrome)
- Cause is direct trochlear trauma.

7.10. ABDUCENS NERVE PALSY

1. Location of the nucleus.

Its nucleus is located in the pons in the floor of the fourth ventricle, at the level of the facial colliculi.

2. What are the causes of 6th nerve palsy?

A. Nonlocalizing:

- i. Increased intracranial pressure
- ii. Intracranial hypotension
- iii. Head trauma
- iv. Lumbar puncture or spinal anesthesia
- v. Vascular, hypertension
- vi. Diabetes/microvascular
- vii. Parainfectious processes (postviral; middle ear infections in children)
- viii. Basal meningitis

B. Localizing:

- i. Pontine syndromes (infarction, demyelination, tumor); contralateral hemiplegia; ipsilateral facial palsy, ipsilateral horizontal gaze palsy (\pm ipsilateral internuclear ophthalmoplegia); ipsilateral facial analgesia.
- ii. Cerebellopontine angle lesions (acoustic neuroma, meningioma): in combination with disorders of the eighth, seventh and ophthalmic trigeminal nerves (especially corneal hypoesthesia), nystagmus, and cerebellar signs.
- iii. Clivus lesions (nasopharyngeal carcinoma, clivus chordoma).
- iv. Middle fossa disorders (tumor, inflammation of medial aspect of petrous): facial pain/numbness, \pm facial palsy.
- v. Cavernous sinus or superior orbital fissure (tumor, inflammation, aneurysm): in combination with disorders of the third, fourth, and ophthalmic trigeminal nerves (pain/numbness).
- vi. Carotid-cavernous or dural arteriovenous fistula.

Common causes of sixth nerve palsy:

- i. Collier's sphenoidal palsy
- ii. Superior orbital fissure syndrome
- iii. Arteriosclerosis
- iv. Hypertension
- v. Diabetes
- vi. Trauma and raised ICT.

3. What are the clinical features of 6th nerve palsy?

Symptoms:

Horizontal diplopia—Uniocular, painless and increases on looking toward lateral side.

An abnormality of the abducens nerve is the most likely cause of strictly horizontal double vision, especially if it is worse at a distance than near, and worse on lateral gaze.

Signs

- i. Limitation of abduction
- ii. Esotropia in primary position
- iii. Uncrossed diplopia
- iv. Slight face turn toward side of diplopia.

All other ocular movements are normal.

In early cases, secondary deviation is greater than primary deviation (non-concomitant).

Later due to contractures developing in the ipsilateral antagonist they become equal (concomitant).

Still later with the development of contractures in contralateral synergist (with secondary underaction of antagonist of contralateral synergist) the primary deviation increases.

Uncrossed horizontal diplopia

- i. Increases towards paralyzed side
- ii. Horizontal displacement of image
- iii. Vertical displacement also occurs due to increased effectiveness of obliques in adduction
- iv. Field of binocular vision constricted towards the affected side.

4. What are the features seen on Hess charting?

- I. Enlargement towards the direction of action of ipsilateral antagonist MR and opposite MR (contralateral synergist)
- II. Contraction away from the direction of action of LR muscle of opposite eye (antagonist of contralateral synergist)
- III. False projection outwards towards the paralyzed side.

5. What are the conditions that mimic the sixth nerve palsy?

- i. Thyroid ophthalmopathy
- ii. Myasthenia gravis
- iii. Medial wall orbital blowout fracture
- iv. Duane's syndrome (type 1)
- v. Mobius syndrome
- vi. Spasm of the near reflex
- vii. Essential infantile esotropia
- viii. Divergence paralysis.

6. What are the syndromes associated with abducens nerve palsy?**I. Brainstem syndrome:**

- i. Brainstem lesion affecting 6th nerve also affects 5th, 7th, 8th nerves.
- ii. Structures in the lower pons affected by a lesion of 6th nerve:
 - Oculomotor sympathetic central neuron: ipsilateral Horner's syndrome
 - Para pontine reticular fiber (PPRF): ipsilateral horizontal conjugate gaze palsy.
 - Medial longitudinal fascicle (MLF): ipsilateral internuclear ophthalmoplegia
 - Pyramidal tract: contralateral hemiparesis.

a. Millard-Gubler syndrome:

Due to the lesion in the ventral paramedian pons.

Clinical features:

- i. Ipsilateral 7th nerve paresis
- ii. Ipsilateral 6th nerve paresis
- iii. Contralateral hemiparesis.

b. Raymond's syndrome:

- i. Ipsilateral 6th nerve paresis
- ii. Contralateral hemiparesis.

c. Foville's syndrome:

Due to the lesion in the pontine tegmentum.

- i. Horizontal conjugate gaze palsy.
- ii. Ipsilateral Horner's syndrome.
- iii. Ipsilateral 5,6,7 cranial nerve palsies
- iv. Ipsilateral paralysis of the abduction.

II. The subarachnoid space syndrome:

- i. Vascular: compression of the nerve by atherosclerosis and aneurysm of the anterior inferior cerebellar artery or posterior inferior cerebellar artery or the basillar artery.
- ii. Posterior fossa causes: Space occupying lesion (SOL) above the tentorium, posterior fossa tumors, structural anomalies, head trauma. Mechanism: All these causes leads to increased intracranial pressure (ICP) which leads to the downward displacement of the brainstem. This may cause stretching of the 6th nerve, which is tethered at its exit from the pons and in Dorello's canal. This gives rise to the "nonlocalizing" 6th nerve palsies of raised ICP.
- iii. Other causes: Meningitis—often bilateral palsy
Basal tumors: like meningioma, chordoma and Schwannoma.
After lumbar puncture—with or without raised ICP

III. Petrous apex syndromes:

Contact with the petrous pyramid makes the portion of the 6th nerve within the Dorello's canal susceptible to pathologic processes affecting the petrous bone.

A. Gradenigo's syndrome:

At the Dorello's canal the 6th nerve lies adjacent to mastoid air cells. So severe mastoiditis leading to inflammation of tip of the petrous bone causes inflammation of the 6th nerve. Mechanism is by the inflammatory involvement of the inferior petrosal sinus or pseudotumor cerebri leading to raised ICP with 6th nerve paresis.

In addition the Gasserian ganglion and facial nerve are also nearby to the petrous apex leads to involvement of the 5th and 7th cranial nerves.

Features:

- i. Ipsilateral 6th nerve palsy
- ii. Ipsilateral decreased hearing

- iii. Ipsilateral facial pain in the distribution of the 5th nerve
- iv. Ipsilateral facial paralysis.

B. Petrous bone fracture:

Basal skull fractures following head trauma may involve the 5th, 6th, 7th and 8th cranial nerves.

Associated findings—hemotympanum, Battle's sign, CSF otorrhea

C. Pseudo-Gadenigo's syndrome:

Lesions other than inflammation can involve petrous apex and produce symptoms suggestive of Gradenigo's syndrome.

Causes:

- i. Tumors/aneurysms of the intrapetrous segment of the internal carotid artery (ICA)
- ii. Nasopharyngeal carcinoma.
- iii. Cerebellopontine angle tumor like acoustic neuroma.

Mechanism: The nasopharyngeal carcinoma extends through foramina at the base of the skull, spreading beneath the dura to damage the extradural portions of the 5th and 6th nerves.

The cerebellopontine angle tumor can cause:

- 5th, 6th, 7th and 8th cranial nerves paralysis
- Ataxia
- Papilledema.

D. Lateral sinus thrombosis or phlebitis:

Leads to involvement of the inferior petrosal sinus causing 6th nerve palsy.

IV. The cavernous sinus syndrome:

The nerve runs within the body of the sinus, in close relation to the ICA. Some oculosympathetic fibers within the cavernous sinus which leave the ICA and join briefly with 6th nerve before joining the ophthalmic division of 5th nerve. This is responsible for the isolated 6th nerve palsy with ipsilateral Horner's syndrome.

Causes of the 6th nerve palsy in cavernous sinus lesion:

- i. Vascular: ICA aneurysm, direct carotid—cavernous fistula, dural carotid-cavernous fistula.
- ii. Neoplastic: meningioma, metastasis, pituitary adenoma, Burkitt's lymphoma.
- iii. Inflammatory: Granulomatous: TB, sarcoid.
Non-granulomatous: Sphenoid sinus abscess

V. The orbital syndrome:

The nerve enters the orbit through the superior orbital fissure within the annulus of Zinn. The nerve supplies the lateral rectus muscle only a few mm from the superior orbital fissure. For this reason, isolated 6th nerve within the orbit is rare.

Causes:

- Intraorbital tumor
- Orbital trauma
- Inflammatory pseudotumor
- Orbital cellulitis

VI. Isolated 6th nerve palsy:

- i. **Benign transient isolated 6th nerve palsy:** occurs rarely. In children, it is caused most often by viral illness and recent vaccination. In adults, it is caused most often by vascular lesion like HT, DM, IHD.
- ii. **Chronic isolated 6th nerve palsy:** some patients don't recover spontaneously and have no obvious lesion despite an extensive evaluation.

7. How will you manage 6th nerve palsy?

- i. Usually will recover spontaneously within 3–4 months, but sometimes recovery may take upto 1 year, in case of traumatic etiology.
- ii. If it does not recover then some serious pathology like tumor, aneurysm, stroke are often present. If the nerve palsy has not shown much improvement over 3 to 4 months, or if other cranial nerve involvement appears then further evaluation is needed.
- iii. Correction of the strabismus: should not be considered until 8–10 months have passed without improvement unless it is known that 6th nerve is no longer intact.
- iv. During this period one can do occlusion of one eye either by patching or by using opaque contact lens. Children < 8 years should undergo alternate patching of the eyes to prevent amblyopia.
- v. Prisms can be used for the correction of diplopia.
- vi. Chemodenervation of the antagonist medial rectus muscle with botulinum toxin can be used. Strabismus surgery whenever required usually consists of either weakening of the ipsilateral medial rectus combined with strengthening of the ipsilateral lateral rectus or some type of transposition procedure.

7.11. MYASTHENIA GRAVIS

1. What is myasthenia gravis (MG)?

Myasthenia gravis is an acquired autoimmune disorder of neuromuscular transmission.

2. What is the literal meaning of myasthenia gravis?

From greek *Mys* = muscle and *asthenia* = weakness and latin *gravis* = heavy or weighty.

3. What is the pathophysiology of myasthenia gravis?

Myasthenia gravis is an autoimmune disease in which antibodies are directed against postsynaptic acetylcholine receptors. There is a slight genetic predisposition: particular HLA types seem to be predisposed for MG (B8 and DR3 more specific for ocular myasthenia).

4. What is the recent thought on the pathophysiology of myasthenia gravis?

It has recently been realized that a second category of gravis is due to auto-antibodies against the MuSK protein (muscle specific kinase), a tyrosine kinase receptor which is required for the formation of the neuromuscular junction. Antibodies against MuSK inhibit the signaling of MuSK normally induced by its nerve-derived ligand, agrin. The result is a decrease in patency of the neuromuscular junction, and the consequent symptoms of myasthenia.

5. What is the source of antibody in myasthenia?

The antibodies are produced by plasma cells that have been derived from B cells. These plasma cells are activated by T helper cells. The thymus plays an important role in the development of T cells, which is why myasthenia gravis may be associated with thymoma.

6. What is the role of the thymus gland in myasthenia gravis?

T helper cells which have been activated in the thymus probably stimulate the production of the acetylcholine receptor auto-antibodies. Upto 65–70% myasthenics have thymic hyperplasia with 5–20% incidence of thymoma.

7. Does the level of acetylcholine receptor antibody titer correlate with the severity of the disease?

No. The level of the acetylcholine receptor antibody titer does not correlate well with the severity of the disorder.

8. What are the symptoms of myasthenia gravis?

Ocular symptoms:

- i. Drooping of upper lid
- ii. Diplopia.

Systemic symptoms:

- i. Weakness and fatigability of skeletal muscles
- ii. Mild generalized disease: facial and bulbar muscles affected
- iii. Severe generalized disease: impairment of respiration.

9. Classify myasthenia gravis.

The most widely followed classification of myasthenia gravis is that of Osserman which is as follows:

- i. Ocular myasthenia
- ii. (a) Mild generalized myasthenia: Slow progression, no crisis, responds well to drugs.
(b) Moderately severe generalized myasthenia. Severe skeletal or bulbar involvement but no crisis, response to drugs is less than satisfactory.
- iii. Acute fulminant myasthenia: Rapid progression of clinical symptoms with respiratory crisis, poor response to drugs, high incidence of thymoma and high mortality.
- iv. Late severe myasthenia: Symptoms same as in acute fulminating type. The difference is that the progression from class 1 to class 2 has occurred slowly, i.e. over two years.

10. What are the commonly involved muscles in myasthenia?

Muscles that control eye and eyelid movement, facial expression, chewing, talking and swallowing are especially susceptible. The muscles that control breathing and neck and limb movements can also be affected. Often the physical examination is within normal limits.

11. What is the reason for predilection for eye muscle?

There are several lines of thought:

- i. Slight weakness in a limb may be tolerated, but slight weakness in the extraocular muscles would lead to misalignment of the two eyes, even a small degree of which could lead to diplopia. Eyes may also be less able to adapt to variable weakness, because extraocular muscles use visual rather than proprioceptive (body position sensing) cues for fine-tuning.
- ii. Compared to extremity muscles, extraocular muscles are smaller, served by more nerve fibers, and are among the fastest contracting muscles in the body. This higher level of activity may predispose them to fatigue in MG.

12. Which extraocular muscle is most commonly involved?

Medial recti are most commonly affected.

Myasthenic ophthalmoparesis can mimic any pupil sparing ocular motility disorder.

13. Why is the pupil and ciliary muscle unaffected?

Myasthenia involves skeletal and not visceral musculature and therefore the pupil and ciliary muscle are unaffected.

14. How do you examine a case of suspected ocular myasthenia?

Muscle fatigability can be tested for many muscles. A thorough investigation includes:

- i. Looking upward and sideways for 30 seconds: ptosis and diplopia.
- ii. "Peek sign": after complete initial apposition of the lid margins, they quickly (within 30 seconds) start to separate and the sclera starts to show.

15. What is ice pack test?

- i. Cooling may improve neuromuscular transmission. In a patient with myasthenia gravis who has ptosis, placing ice (wrapped over a towel) over an eyelid will lead to cooling of the lid, which leads to improvement of the ptosis
- ii. A positive test is clear resolution of the ptosis, with at least more than 2 mm of improvement
- iii. The test is thought to be positive in about 80% of patients with ocular myasthenia.

16. What is lid fatigue test?

In this test, the patient is asked to keep looking up for several minutes and then observed for the appearance of worsening of ptosis.

17. What is sleep test?

Resolution of ptosis or ophthalmoparesis after 30-minute period of sleep, with reappearance of the sign 30 seconds to 5 minutes after awakening.

18. What is enhanced ptosis?

With bilateral ptosis, enhanced ptosis may be seen, where one upper eyelid becomes more ptotic when the other upper eyelid is manually elevated. This phenomenon is explained by Hering's law of equal innervation to yoke muscles.

19. What is Cogan's eye lid twitch?

When the patient looks down for at least 10–20 seconds and then makes an upward saccade back to primary gaze, a transient overshoot of the upper eyelid may be seen. This may be followed by nystagmoid twitches of the upper eyelid and then downward drifting of the eyelid to a normal or ptotic position. This is caused by rapid recovery on resting in down gaze and easy fatigability in up gaze of the myasthenic levator muscle.

20. What are the blood tests done to diagnose myasthenia gravis?

If the diagnosis is suspected, serology can be performed in a blood test to identify antibodies against the acetylcholine receptor.

21. What is repetitive nerve stimulation test?

- i. Muscle fibers of patients with myasthenia gravis are easily fatigued. By repeatedly stimulating a muscle with electrical impulses, the fatigability of the muscle can be measured. This is called the repetitive nerve stimulation test.

- ii. In single fiber electromyography, which is considered to be the most sensitive (although not the most specific) test for myasthenia, a thin needle electrode is inserted into a muscle to record the electric potentials of individual muscle fibers. By finding two muscle fibers belonging to the same motor unit and measuring the temporal variability in their firing patterns (i.e. their 'jitter'), the diagnosis can be made.

22. What is edrophonium test?

Edrophonium inhibits enzyme acetylcholinesterase (which destroys acetylcholine in the neuromuscular junction) thereby increasing the available acetylcholine.

Before test, ptosis, ocular motility eye alignment should be assessed. Initially atropine sulfate (0.6 mg) is given.

Dose of edrophonium: 0.5 to 1.0 mg/kg

In adults—1–2 mg test dose given watch for positive response. If there is no improvement remaining 8–9 mg given in increments of 0.1–0.2 cc waiting for 45–60 seconds between increments.

Onset of action: 30–60 seconds after IV injection.

Effect resolves within 5 minutes.

23. What is neostigmine test?

Neostigmine is a longer acting antiacetylcholinesterase that can also be used similarly.

Dose: 0.03 mg/kg or 1.0–1.5 mg intramuscularly, preceded by atropine 1 cc (0.6 mg) intramuscular (IM).

24. What is the role of atropine in edrophonium test?

It serves two purposes in the test—

- i. First, it counters the muscarinic side effects of edrophonium, especially cardiac arrhythmias.
- ii. Second, placebo responders may improve with this alone.

25. What are the conditions which can give false positive responses in edrophonium test?

- i. Intracranial mass lesions
- ii. Orbital apex syndrome from metastasis
- iii. Multiple sclerosis
- iv. Amyotrophic lateral sclerosis
- v. Eaton-Lambert syndrome
- vi. Guillain-Barre syndrome.

26. What are the imaging tests done in myasthenia gravis?

A. Chest X-ray is frequently performed to diagnose:

- i. Lambert-Eaton syndrome
- ii. Widening of the mediastinum suggestive of thymoma

B. Computed tomography (CT) or magnetic resonance imaging (MRI) are more sensitive ways to identify thymomas, and are generally done for this reason.

27. How does the pulmonary function test help in monitoring of myasthenia gravis progression?

Spirometry (lung function testing) is done to assess respiratory function (FEV1) or the peak expiratory flow rate (PEFR) may be monitored at intervals in order not to miss a gradual worsening of muscular weakness.

28. What is transient neonatal myasthenia?

In the long term, pregnancy does not affect myasthenia gravis. Upto 10% of infants with parents affected by the condition are born with transient (periodic) neonatal myasthenia (TNM) which generally produces feeding and respiratory difficulties. A child with TNM typically responds very well to acetylcholinesterase inhibitors. Immunosuppressive therapy should be maintained throughout pregnancy as this reduces the chance of neonatal muscle weakness, as well as controlling the mother's myasthenia.

29. What are the myasthenic symptoms in children?

Three types of myasthenic symptoms in children can be distinguished:

- i. **Neonatal:** In 12% of the pregnancies with a mother with MG, she passes the antibodies to the infant through the placenta causing neonatal myasthenia gravis. The symptoms will start in the first two days and disappear within a few weeks after birth. With the mother it is not uncommon for the symptoms to even improve during pregnancy, but they might worsen after labor.
- ii. **Congenital:** Children of a healthy mother can, very rarely, develop myasthenic symptoms beginning at birth. This is called congenital myasthenic syndrome or CMS. CMS is not caused by an autoimmune process, but due to synaptic malformation, which in turn is caused by genetic mutations. Thus, CMS is a hereditary disease. More than 11 different mutations have been identified and the inheritance pattern is typically autosomal recessive.
- iii. **Juvenile:** Myasthenia occurring in childhood but after the peripartum period.

The congenital myasthenias cause muscle weakness and fatigability similar to those of MG. The symptoms of CMS usually begin within the first two years of life, although in a few forms, patients can develop their first symptoms as late as the seventh decade of life. A diagnosis of CMS is suggested by the following:

- Onset of symptoms in infancy or childhood
- Weakness which increases as muscles tire
- A decremental EMG response, on low frequency, of the compound muscle action potential (CMAP)
- No anti-AChR or MuSK antibodies
- No response to immunosuppressant therapy
- Family history of symptoms which resemble CMS.

30. What are the various autoimmune diseases associated with myasthenia gravis?

Myasthenia gravis is associated with various autoimmune diseases, including:

- i. Thyroid diseases, including Hashimoto's thyroiditis and Graves' disease
- ii. Diabetes mellitus type 1
- iii. Rheumatoid arthritis
- iv. Lupus and demyelinating CNS diseases

Seropositive and "double-seronegative" patients often have thymoma or thymic hyperplasia. However, anti-MuSK positive patients do not have evidence of thymus pathology.

31. What is the management of myasthenia gravis?

A. Symptomatic therapy

Acetylcholinesterase inhibitors: neostigmine and pyridostigmine can improve muscle function by slowing the natural enzyme cholinesterase that degrades acetylcholine in the motor end plate; the neurotransmitter is therefore around longer to stimulate its receptor. Usually one can start with a low dose, e.g. 3 x 20 mg pyridostigmine, and increase until the desired result is achieved. If taken 30 minutes before a meal, symptoms will be mild during eating. Side effects, like perspiration and diarrhea can be countered by adding atropine. Pyridostigmine is a short-lived drug with a half-life of about 4 hours.

B. Disease modifying therapy

i. *Medical*

- Immunosuppressive drugs: prednisone, cyclosporine, mycophenolate mofetil and azathioprine may be used.
- Treatments with some immunosuppressives take weeks to months before effects are noticed.

ii. *Surgical*

Thymectomy, the surgical removal of the thymus, is essential in cases of thymoma in view of the potential neoplastic effects of the tumor. It is usually indicated in all patients with myasthenia.

32. What is the role of steroids in the treatment of myasthenia gravis?

Steroids are useful in inducing remission. However, because of the possible side effects, the treatment with steroids is reserved for severe cases.

33. What are the drugs exacerbating the symptoms of myasthenia?

The adverse effects of many medications may provoke exacerbations; therefore, carefully obtaining a medication history is important. Some of the medications reported to cause exacerbations of myasthenia include the following:

- i. **Antibiotics**—Macrolides, fluoroquinolones, aminoglycosides, tetracycline and chloroquine
- ii. **Antidysrhythmic agents**— β -blockers, calcium channel blockers, quinidine, lidocaine, procainamide and trimethaphan

- iii. **Miscellaneous**—Diphenylhydantoin, lithium, chlorpromazine, muscle relaxants, levothyroxine, adrenocorticotrophic hormone (ACTH) and paradoxically, corticosteroids.

34. What is cholinergic crisis?

- i. One of the confusing factors in treating patients with MG is that insufficient medication (i.e. myasthenic crisis) and excessive medication (i.e. cholinergic crisis) can present in similar ways.
- ii. Cholinergic crisis results from an excess of cholinesterase inhibitors (i.e. neostigmine, pyridostigmine, physostigmine) and resembles organophosphate poisoning. In this case, excessive ACh stimulation of striated muscle at nicotinic junctions produces flaccid muscle paralysis that is clinically indistinguishable from weakness due to myasthenia.
- iii. Myasthenic crisis or cholinergic crisis may cause bronchospasm with wheezing, bronchorrhea, respiratory failure, diaphoresis and cyanosis.
- iv. Miosis and the SLUDGE syndrome (i.e. salivation, lacrimation, urinary incontinence, diarrhea, GI upset and hypermotility, emesis) also may mark cholinergic crisis. However, these findings are not inevitably present.
- v. Despite muscle weakness, deep tendon reflexes are preserved.

35. How is myasthenic crisis treated?

A myasthenic crisis occurs when the muscles that control breathing weaken to the point that ventilation is inadequate, creating a medical emergency and requiring a respirator for assisted ventilation. In patients whose respiratory muscles are weak, crises—which generally call for immediate medical attention—may be triggered by infection, fever, an adverse reaction to medication or emotional stress.

If the myasthenia is serious (myasthenic crisis), plasmapheresis can be used to remove the putative antibody from the circulation. Also, intravenous immunoglobulins (IVIG) can be used to bind the circulating antibodies. Both of these treatments have relatively short-lived benefits, typically measured in weeks.

36. What are the complications in a patient with myasthenia?

- i. Respiratory crisis
- ii. Pulmonary aspiration
- iii. Permanent muscle weakness
- iv. Side effects related to medication used and surgery related complications.

37. What are the other ancillary treatment modalities for reducing ocular disabilities in other myasthenia?

Ptosis—can be corrected with placement of crutches on eyeglasses ptosis tape to elevate eyelid droop.

Diplopia—can be addressed by occlusion with eye patching, frosted lens, occluding contact lens or by simply placing opaque tape over a portion of eyeglasses, plastic prisms (Fresnel prisms).

38. What are the differences between myasthenia gravis and myopathy?

Myasthenia gravis	Myopathy
Ptosis is asymmetrical	Ptosis is symmetrical
Diplopia is present	Diplopia may or may not be present
Diurnal variation present	Absent
Fatigability—present	Absent
Response to the stigmine—positive	Negative
Clinical course—variable characteristics	Slowly progressive
Other eye signs—absent	Retinal pigment disturbance may be present
Age—any age	Any age—under 20 suspect heart block

39. Differential diagnosis of myasthenia gravis.

A. Prominent ocular signs

- i. Mitochondrial myopathy: Progressive external ophthalmoplegia
- ii. Oculopharyngeal muscular dystrophy
- iii. Intracranial mass lesion
- iv. Senile ptosis

B. Bulbar dysfunction

- i. Motor neuron syndromes
- ii. Polymyositis
- iii. Thyroid disorders
- iv. Oculopharyngeal dystrophy

C. Generalized myasthenia gravis

- i. Lambert-Eaton syndrome (LES)
- ii. Botulism
- iii. Congenital myasthenic syndromes
- iv. Myopathies or muscular dystrophies.

7.12. NYSTAGMUS

1. Define nystagmus.

It is defined as a regular, rhythmic, involuntary, repetitive, to-and-fro movement of the eye.

2. Classification of nystagmus.

- I.a. **Physiological**
 - i. End gaze
 - ii. Optokinetic
 - iii. Vestibulo-ocular reflexes (VOR)
- b. **Pathological**
 - i. Sensory deprivation (ocular)
 - ii. Motor imbalance nystagmus
 - Congenital nystagmus
 - Spasmus nutans
 - Latent nystagmus
 - Ataxic nystagmus
 - Downbeat nystagmus
 - Upbeat nystagmus
 - Convergent refraction nystagmus
 - See-saw nystagmus of maddox
 - Periodic alternating nystagmus
- II. **Based on the type of nystagmus**
 - i. Pendular
 - ii. Jerk
- III. **Based on direction of movement**
 - i. Horizontal
 - ii. Vertical
 - iii. Rotatory
- IV. **Congenital/infantile**
 - i. Acquired
 - ii. Toxic/drug/metabolic
 - iii. Neurological
 - iv. Functional/voluntary.

3. What are the types of nystagmus?

There are different types depending upon

- a. **Rate:** The number of to-and-fro movements in one second. It is described in hertz (Hz).
 - I. Slow (1–2 Hz)
 - II. Medium (3–4 Hz)
 - III. Fast (5 Hz or more)
- b. **Amplitude**
 - I. Fine (<5°)
 - II. Moderate (5°–15°)
 - III. Large (>15°)

c. Direction

- I. Horizontal
- II. Vertical
- III. Rotational

d. Movement

- I. Pendular
- II. Jerk.

4. What is the anatomic basis of nystagmus?

The goal of the eye movement control system is to maintain images of objects steady on the retina to preserve visual acuity. The slow eye movement systems that provide this stability of images are

- i. Visual fixation
- ii. Vestibular system
- iii. Optokinetic system
- iv. Neural integrator
- v. Smooth pursuit system
- vi. Vergence eye movement system.

5. What are the main points in history-taking in nystagmus?

Following points should be asked in history

- i. Present from birth or not
- ii. Oscillopsia
- iii. Vertigo
- iv. Visual loss
- v. Diplopia.

6. What are the other movement disorders which can mimic a nystagmus?

- i. **Nystagmoid movements** are those which are not regular and rhythmic in nature.
- ii. **Ocular bobbing**: Fast downward movement of both eyes followed by a slow drift back towards mid position. It is usually seen in patients with severe brainstem dysfunction.
- iii. **Ocular dipping**: Slow downward movement of eyeball followed by delayed rapid upward movement and spontaneous roving horizontal eye movements.
- iv. **Ping pong gaze**: Slow roving horizontal conjugate movement from one extreme to the other occurring regularly or irregularly every few seconds. It is seen in acute diffused bilateral cerebral disease with intact brainstem.
- v. **Ocular dysmetria**: Seen in cerebral disease.
- vi. **Ocular flutter**: Brief, horizontal, bilateral ocular oscillation occurring intermittently when the patient looks straight or changes his gaze. Seen in certain cerebellar diseases.
- vii. **Opsoclonus**: Consists of large amplitude, involuntary, repetitive unpredictable conjugate chaotic saccades in horizontal, vertical and

torsional planes. Causes include organophosphorus poisoning, Epstein-Barr virus infection and hypertension.

- viii. **Superior oblique/myokymia:** It consists of intermittent monocular torsional movement of one eyeball. Associated with torsional diplopia. It responds to carbamazepine. Causes midbrain tectal tumors.

7. What are the two components of jerk nystagmus and how is the direction defined?

The two components are slow component in one direction and a fast one in the opposite direction. The direction is defined by direction of the fast component as viewed by the patient.

8. What is Alexander's law?

It states that the amplitude of jerk nystagmus is largest in the gaze of the direction of its fast component.

9. What is null point?

It is the position of gaze in which the nystagmus is lessened or totally absent.

10. What are the causes of monocular nystagmus?

- i. Strabismus
- ii. Amblyopia
- iii. Internuclear ophthalmoplegia

11. What are the features of congenital nystagmus (manifest)?

- i. Most common type (80%)
- ii. Presence from birth
- iii. Binocular
- iv. Horizontal and pendular
- v. Remains horizontal even in vertical gaze
- vi. Disappears at one position—null point
- vii. Decreases on convergence, eye closure
- viii. Absent during sleep
- ix. No oscillopsia, normal vision
- x. Particular head posture
- xi. Associated head oscillations may be there
- xii. Inversion of optokinetic nystagmus.

12. What are the features of pendular nystagmus?

- i. May have horizontal, vertical, torsional component
- ii. May be congenital or acquired
- iii. Associated with visual problems
- iv. Most common cause being demyelination of the neural circuit known as the myoclonic triangle (the dentato-rubro-olivary pathways—associated with visual loss oscillopsia, palatal myoclonus).

13. What are the features of gaze evoked nystagmus?

- i. Fast phase is towards the direction of gaze (up on looking up, down on looking down)
- ii. Amplitude may be greater towards the side of lesion
- iii. Drug-induced nystagmus tends to be minimal in down gaze.

14. What are the features of vestibular nystagmus?

- i. Seen in primary position
- ii. Purely horizontal or horizontal rotatory
- iii. Fast component opposite to the side of lesion
- iv. Suppressed by visual fixation, increased when fixation is removed
- v. Intensity increases in the direction of fast phase (**Alexander's law**)
- vi. Associated vertigo, tinnitus.

15. What are the features of downbeat nystagmus?

- i. Primary position nystagmus
- ii. Fast component downwards
- iii. Oscillopsia often present and may precede
- iv. Best elicited by looking down and out
- v. Craniocervical junction lesions, e.g. Arnold-Chiari malformations and certain drugs.

16. What are the features of upbeat nystagmus?

- i. Fast phase beats upwards.
- ii. Lesion in the posterior fossa—either brainstem or cerebellar vermis or some drugs.

17. What are the features of seesaw nystagmus (of Maddox)?

- i. Primary position nystagmus worsens on down gaze
- ii. One eye elevates as well as intorts while the other eye descends and extorts
- iii. Site of lesion is parasellar, parachiasmal.

18. What are the features of Bruns nystagmus?

- i. A combination of large amplitude, low frequency horizontal nystagmus on looking to the ipsilateral side (due to cerebellar component) and small amplitude, high frequency nystagmus on looking contralaterally and in primary position (due to vestibular component)
- ii. Often seen in tumors of cerebellopontine angle.

19. What are the features of optokinetic nystagmus?

It is a normal nystagmus which results when a person gazes at a succession of objects moving past in one direction. For example, gazing from a fast moving train. The nystagmus is always in the direction opposite to the direction of movement of the object.

20. What is the significance of eliciting optokinetic nystagmus?

- i. To test presence of some vision (in malingering and children)
- ii. To test integrity of the horizontal and vertical gaze centers for saccadic and pursuit movements
- iii. To differentiate homonymous hemianopia of occipital cortical lesion from that of a lesion of optic radiation and adjacent opticomotor pathway (parietal lobe lesion). (In parietal lobe lesions, it will be lost due to disruption of the smooth pursuit pathways).

21. How will you detect the side of the parietal lobe lesion by demonstrating optokinetic nystagmus?

Nystagmus will be absent or defective when the targets are moved towards the side of the lesion, i.e. away from hemianopia. This is called positive optokinetic nystagmus sign (OKN) and suggests a parietal lobe lesion, usually a neoplasm.

22. What is latent nystagmus?

It is a type of congenital jerk nystagmus that occurs during fixation when one eye is covered. This is frequently associated with strabismus.

23. What is spasmus mutans?

- i. It is a triad of nystagmus, head nodding and torticollis.
- ii. Onset is between 4 months and 1 year and lasts for 1–4 years.
- iii. Indicates serious neurological problem.
- iv. Has vertical and torsional components.

24. How do you clinically differentiate congenital nystagmus from others?

A good rule is that horizontal nystagmus which remains horizontal even on vertical gaze is always congenital nystagmus until proved otherwise.

25. How do you induce caloric nystagmus?

Cold or warm water is irrigated into the external auditory canal. With cold water, the fast phase will be in opposite direction while with warm water, the fast phase will be in the same direction. “COWS” (Cold Opposite Warm Same).

26. What should be the position of the patient to show caloric induced nystagmus?

Patient should be supine with the head bent forward by 30° so that the horizontal semicircular canals are almost horizontal in position.

27. What is the significance of demonstrating caloric nystagmus?

- i. To test the integrity of vestibular-ocular system
- ii. To induce eye movement in patients who are incapable of moving them in response to command—either because of their state of consciousness or because of their orientation.

28. What are the degrees of nystagmus?

- i. 1st degree: Nystagmus only in the direction of fast component.
- ii. 2nd degree: Nystagmus also in primary position gaze.
- iii. 3rd degree: Nystagmus in addition to the above two gazes is also present in the direction of slow component.

29. What is the role of perinatal history in nystagmus?

History of intrauterine infection (rubella, toxoplasma), maternal alcohol abuse or anticonvulsion drugs (optic nerve hypoplasia), neonatal asphyxia or neonatal seizures (cerebral damage) are very helpful in case of nystagmus.

30. What is the role of family history in nystagmus?

- i. Most common X-linked
- ii. Autosomal dominant is also likely but autosomal recessive is rare.

31. What are the treatment modalities in nystagmus?**i. Optical aids**

- a. Prisms—to shift gaze into the null point.
- b. Soft contact lens—helps probably by stimulating trigeminal afferent—especially in congenital nystagmus.

ii. Biofeedback

- a. Training mechanism to decrease nystagmus—visual and auditory

iii. Medical modalities

Baclofen in acquired periodic alternating nystagmus

Clonazepam, anticholinergic in downbeat nystagmus

Menantine and gabapentene help in acquired pendular nystagmus

Botulinum toxin

Injected into the retrobulbar space or into the extraocular muscles in the better eye especially in pendular nystagmus. There may be transient improvement in the visual acuity and oscillopsia. However, the side effects override the small and transient improvements.

iv. Surgery

This helps correct the head posture by shifting the null point from an eccentric location to a straight ahead position in visually disabling nystagmus.

- i. Kestenbaum-Anderson procedure

By recession of horizontal muscles, the versions are blocked

- ii. Faden operation

Acts like a recession by creation of a more posterior attachment, first reducing the area of contact.

7.13. VISUAL FIELDS IN NEURO-OPHTHALMOLOGY

1. What is the purpose of perimetry in neuro-ophthalmology?

- i. To detect generalized or focal defects in the island of vision that may identify the location of pathology affecting the visual pathways.
- ii. To aid in differential diagnosis since different pathologies may produce different kinds of field defects.
- iii. To quantitate severity of defects in order to detect any progression, recovery or response to therapy.
- iv. To reveal hidden visual loss in patients who may be totally unaware of such defects.

2. What are the types of visual field testing?

- i. Confrontation
- ii. Amsler grid
- iii. Tangent screen
- iv. Goldmann perimetry
- v. Static perimetry—octopus/humphrey visual analyzer
- vi. Newer tests—swap, high pass resolution, flicker, motion and displacement.

3. What are the field defects in lesions of the optic chiasma?

- i. Bitemporal (heteronymous) hemianopia
- ii. Traquair's junctional scotoma
- iii. Incongruous contralateral homonymous hemianopia (very rare)
- iv. Posterior involvement affects crossing macular fibers—bitemporal hemiscotomas.

Compression of chiasma:

- i. From below, e.g. pituitary adenoma—defects start superiorly and progress inferiorly in the temporal hemifields.
- ii. From above, e.g. craniopharyngioma, suprasellar meningioma—defects start inferiorly and progress superiorly in the temporal hemifields.
- iii. Binasal hemianopia: rare. A rare neuro-ophthalmic cause is aneurysm of internal carotid artery producing compression of temporal fibers ipsilaterally and also contralaterally by displacing chiasma against opposite internal carotid artery.

4. What are the field defects in optic tract lesions?

- Homonymous contralateral, incongruous hemianopia.

5. What are the field defects in lesions of the lateral geniculate body?

Such defects are generally rare.

- i. Incongruous homonymous hemianopia
- ii. Quadruple sectoranopia

- a. Homonymous hemianopia with sparing of a horizontal sector
- b. Occurs with infarction of anterior choroidal artery.
- iii. Relatively congruous, homonymous, horizontal sectoranopia
- iv. Only a horizontal sector involved
- v. Occurs with infarction of lateral choroidal artery.

6. What are the field defects in temporal lobe lesions?

- Mid peripheral/peripheral contralateral homonymous superior quadrantanopia (pie in the sky).

7. What are the field defects in parietal lobe lesions?

- i. Contralateral inferior homonymous quadrantanopia (pie on the floor)
- ii. Homonymous hemianopia, denser inferiorly.

8. What are the field defects in occipital lobe lesions?

- i. Exquisitely congruous contralateral, homonymous hemianopia
- ii. Macular 'sparing'
- iii. Macular 'splitting'
- iv. Central, macular homonymous hemianopia
- v. Temporal crescent sparing.

Homonymous Hemianopia

1. What are the characteristics of optic tract hemianopia?

- i. Reduction in ipsilateral visual acuity, defects with both bitemporal and hemianopic character
- ii. Incongruity
- iii. Associated bow-tie optic atrophy (from selective involvement of decussated axons)
- iv. A contralateral relative afferent pupillary defect.

2. What are the causes of homonymous hemianopia?

A. Optic tract lesions—visual conduction system posterior to optic chiasma and anterior to lateral geniculate body.

- i. Saccular aneurysms of internal carotid artery.
- ii. Pituitary tumors—pituitary adenomas—chromophobe (commonest), basophil, acidophil, mixed, adenocarcinoma,
- iii. Metastases
- iv. Demyelinating diseases
- v. Trauma
- vi. Migraine.

B. Temporoparietal lesions—temporal lobe lesions—pie in the sky and later pie on the floor if parietal lobe is involved.

- i. Vascular accidents thromboembolism, vasospasm, subdural hematoma, fracture skull
- ii. Tumors—meningioma, glioma, retinoblastoma, pinealoma, ependymoma, metastases

- iii. Demyelinating diseases—Schilder's disease, Krabbe's leukodystrophy, PMLE, migraine.

C. Occipital lesions

- i. Vascular accidents thromboembolism, vasospasm, subdural hematoma, fracture skull, subclavian steal phenomenon
- ii. Vertebrobasilar insufficiency
- iii. Tumors—meningioma, glioma, retinoblastoma, pinealoma, ependymoma, metastases
- iv. Demyelinating diseases—Schilder's disease, Krabbe's leukodystrophy, PMLE, migraine
- v. Trauma
- vi. Poisons—digitalis, LSD, mescaline, opium, carbon monoxide
- vii. Migraine.

Bitemporal Hemianopia

1. What are the causes of bitemporal hemianopia?

A. Chiasmal lesions

- i. Aneurysm of internal carotid artery, intrasellar, syphilitic, septic
- ii. Vascular—arteriosclerosis, arterial compression
- iii. Chiasmal basal arachnoiditis, chiasmal neuritis—tuberculosis, syphilis, cysticercosis
- iv. Tumors—meningioma, glioma, retinoblastoma, pinealoma, ependymoma

B. Pituitary lesions

- i. Hyper/hypo pituitarism
- ii. Pituitary tumors
- iii. Pituitary adenomas—chromophobe (commonest), basophil, acidophil, mixed, adenocarcinoma
- iv. Metastases

C. Perisellar lesions

- i. Suprasellar tumors—craniopharyngioma, meningioma, frontal lobe tumors, ependymoma
- ii. Chordoma
- iii. Presellar tumors—meningioma of olfactory groove, neuroblastoma
- iv. Parasellar tumors—sphenoid bone meningioma, metastases, disseminated sclerosis.

D. Injury.

Commonest causes include:

- i. In children—craniopharyngioma and chiasmal glioma
- ii. In 20–40 years age—pituitary tumors
- iii. Above 40 years—meningioma, basal arachnoiditis, aneurysms.

2. What are the clinical features of bitemporal hemianopia?

- i. Monocular/binocular visual field defects that respect vertical meridian.

- ii. Asymmetry of field loss is the rule, such that one eye may show advanced deficits, including reduced acuity, whereas only relative temporal field depression is found in the contralateral field.
- iii. With few exceptions, these slow-growing tumors produce insidiously progressive visual deficits in the form of variations on a bitemporal theme.
- iv. Most tumors are slow growing and so are the progress of visual symptoms.
- v. Aneurysms may provoke sudden worsening or fluctuations in vision that mimic optic neuritis, at times with confounding improvement during corticosteroid therapy.
- vi. Without temporal fields, objects beyond the point of binocular fixation fall on non seeing nasal retina, so that a blind area exists, with extinction of objects beyond the fixation point.
- vii. Suprasellar tumors of presumed prenatal origin, such as optic gliomas or craniopharyngiomas, may be associated with congenitally dysplastic optic disks.

3. What are the conditions that can mimic chiasmal field defects?

- i. Tilted disks (inferior crescents, nasal fundus ectasia)
- ii. Nasal sector retinitis pigmentosa
- iii. Bilateral cecocentral scotomas
- iv. Papilledema with greatly enlarged blind spots
- v. Overhanging redundant upper lid tissue
- vi. Dominant optic atrophy
- vii. Ethambutol toxic optic neuropathy.

4. What is the treatment of visual field defects?

- i. Visual field defects, particularly of the homonymous variety or those present in one-eyed patients, frequently pose unique problems of eye movement. Such patients typically experience difficulty in moving the eye very far into a large "blind" area.
- ii. A prism with the base oriented toward the blind area and covering only the portion of the spectacle lens corresponding to the blind area can produce a favorable result. For example, a patient with sight in only the left eye and a left hemianopia would be helped in "seeing" objects in his left field with a base-out Fresnel prism applied to the temporal portion of the left lens.
- iii. With a small eye movement from the primary position (no prism) to the left (into the prism), the visual field would be shifted by the amount of the eye movement plus the power of the prism. Thus, a small flick of the eye to the left would provide the subject with a large view of the visual scene normally lying in his "blind" area.

7.14. CAVERNOUS SINUS THROMBOSIS

1. Describe briefly anatomy of cavernous sinus.

- i. The cavernous sinuses are irregularly shaped, trabeculated and consists of incompletely fused venous channels located at the base of the skull in the middle cranial fossa.
- ii. They lie on either side of the sella turcica, are just lateral and superior to the sphenoid sinus and are immediately posterior to the optic chiasma.
- iii. Each cavernous sinus is formed between layers of the dura mater, and multiple connections between the 2 sinuses exist.
- iv. The cavernous sinuses receive venous blood from the facial veins (via the superior and inferior ophthalmic veins) as well as the sphenoid and middle cerebral veins. They, in turn, empty into the inferior petrosal sinuses, then into the internal jugular veins and the sigmoid sinuses via the superior petrosal sinuses.
- v. There are no valves, however, in this complex web of veins, blood can flow in any direction depending on the prevailing pressure gradients.
- vi. The internal carotid artery with its surrounding sympathetic plexus passes through the cavernous sinus.
- vii. The third, fourth and sixth cranial nerves are attached to the lateral wall of the sinus.
- viii. The ophthalmic and maxillary divisions of the fifth cranial nerve are embedded in the wall.

This intimate juxtaposition of veins, arteries, nerves, meninges and paranasal sinuses accounts for the characteristic etiology and presentation of cavernous sinus thrombosis.

2. What are the causes of cavernous sinus thrombosis?

Causes can be divided into:

A. Septic or infective:

- i. Most cases of septic cavernous sinus thrombosis are due to an acute infection in an otherwise normal individual. However, patients with chronic sinusitis or diabetes mellitus may be at a slightly higher risk.
- ii. The causative agent is generally *Staphylococcus aureus*, although *streptococci*, *pneumococci*, and fungi may be implicated in rare cases.
 - a. Infection of the face
 - especially the middle 1/3rd,
 - causative organism: *Staphylococcus aureus*
 - bacteria → facial vein and pterygoid plexus → ophthalmic vein → cavernous sinus
 - b. Sinusitis
 - It can be involving the sphenoid or the ethmoid sinuses

- It can be
 - a. Acute: caused by gram positive organisms viz. *S. aureus*, *pneumococci*
 - b. Chronic: caused by gram negative organisms, coagulase negative *staphylococci*, fungi, e.g. *Aspergillus*, *Mucoraceae*
- c. Dental infections: (10%)
 - common with maxillary teeth
 - common pathogens involved in odontogenic septic cavernous sinus thrombosis are
 - *Streptococci*
 - Fusobacteria
 - Bacteriodes
- d. Otitis media:
 - Cavernous sinus thrombosis is rare complication
 - seen in untreated, incompletely treated, incorrectly treated disease
- e. Orbital cellulitis:
 - rare

B. Aseptic or non-infective:

- i. Polycythemia
- ii. Sickle cell disease or trait
- iii. Paroxysmal nocturnal hemoglobinuria
- iv. Arterio-venous malformations
- v. Trauma
- vi. Intracranial surgery
- vii. Vasculitis
- viii. Pregnancy
- ix. Oral contraceptive pills
- x. Congenital heart disease
- xi. Dehydration
- xii. Marasmus
- xiii. Compression or obstruction due to expanding mass (e.g. pituitary adenoma, meningioma) → sterile thrombosis part of the paraneoplastic hypercoagulability syndrome.

3. What are the clinical features of cavernous sinus thrombosis?

History:

- i. Patients generally have sinusitis or a midface infection (most commonly a furuncle) for 5–10 days. In upto 25% of cases where a furuncle is the precipitant, it will have been manipulated in some fashion (e.g. squeezing, surgical incision).
- ii. Headache, fever and malaise typically precede the development of ocular findings. As the infection tracks posteriorly, patients complain of orbital pain and fullness accompanied by periorbital edema and visual disturbances.
- iii. In some patients, periorbital findings will not develop early on and the clinical picture is subtle.

- iv. Without effective therapy, signs will appear in the contralateral eye by spreading through the communicating veins to the contralateral cavernous sinus. This is pathognomonic for cavernous sinus thrombosis. The patient rapidly develops mental status changes from CNS involvement and/or sepsis. Death will follow shortly thereafter.

Ocular and Physical examination:

Other than the findings associated with the primary infection, the following signs are typical:

- i. Initially, signs of venous congestion may present.
 - Chemosis
 - Eyelid edema
 - Periorbital edema
- ii. Manifestations of increased retrobulbar pressure follow.
 - Exophthalmos
 - Ophthalmoplegia
- iii. Increased intraocular pressure (IOP)
 - Sluggish pupillary responses
 - Decreased visual acuity is common due to increased IOP and traction on the optic nerve and central retinal artery.
- iv. Cranial nerve palsies are found regularly.
 - Isolated sixth nerve dysfunction may be noted before there are obvious orbital findings.
 - Impaired extraocular movements
- v. Depressed corneal reflex is possible.
- vi. Appearance of signs and symptoms in the contralateral eye is diagnostic of cavernous sinus thrombosis, although the process may remain confined to one eye.
- vii. Meningeal signs may be noted, including nuchal rigidity, Kernig's and Brudzinski's signs.
- viii. Systemic signs indicative of sepsis are late findings. They include chills, fever, shock, delirium and coma.

Ocular features depend on the origin of the infection.

- i. Anterior infection (facial, dental, orbital) → acute presentation in the following order:
 - Deep seated pain around the eye
 - ↑ temperature
 - Orbital congestion
 - Lacrimation
 - Conjunctival edema
 - Eyelid swelling
 - Ptosis
 - Proptosis
 - Ophthalmoparesis

Such patients are usually toxic with +ve blood cultures.
- ii. Sphenoid sinusitis/pharyngitis →
 - Delayed presentation of signs

- Subacute or chronic
 - Isolated abducens nerve paresis is the most consistent early neurologic sign
- iii. Secondary to otitis media →
- Signs and symptoms are slow
 - Protracted course.

Visual loss is common and causes are: ischemic oculopathy, ischemic optic neuropathy, neurotrophic keratopathy (corneal ulceration).

Aseptic: Signs and symptoms are similar to the septic type but without any laboratory or clinical evidence of infection.

- No fever, chills, leukocytosis, or signs and symptoms suggestive of meningitis
- Pain around and behind the eye
- Loss of corneal sensations, decreased facial sensations
- Ophthalmoparesis
- Proptosis, chemosis are less severe
- Sympathetic dysfunction
- Increased intraocular pressure
- Stasis retinopathy

Visual loss is usually uncommon regardless of the severity.

4. What are the differential diagnosis of cavernous sinus thrombosis?

Differential diagnosis of cavernous sinus thrombosis	
Diagnosis	Signs/Symptoms
Traumatic retrobulbar hemorrhage	<ul style="list-style-type: none"> • Accumulation of blood within the orbit • History of trauma or surgery • Bullous subconjunctival hemorrhage • Pain, decreased vision, lid ecchymosis, increased IOP, proptosis
Orbital cellulitis	<ul style="list-style-type: none"> • Lid edema, erythema and tenderness • Pain and fever but normal vision
Orbital fracture and ruptured globe	<ul style="list-style-type: none"> • History of trauma • Periocular bruising, enophthalmos • Pain, decreased vision, lid edema, restricted eye movements
Conjunctivitis	<ul style="list-style-type: none"> • Conjunctival follicles and/or papillae • Red eye, decreased vision, lid edema, discharge • Corneal neovascularization • Itching and/or pain
Thyroid-related orbitopathy	<ul style="list-style-type: none"> • Lid retraction, lid lag, scleral show • Foreign body sensation, decreased tearing

Contd...

Contd...

Differential diagnosis of cavernous sinus thrombosis	
Diagnosis	Signs/Symptoms
	<ul style="list-style-type: none"> • Dyschromatopsia, diplopia, proptosis, decreased vision
Cavernous sinus thrombosis	<ul style="list-style-type: none"> • Altered level of consciousness • Dilated and sluggish pupils; CN III, IV, and/or VI palsies • Fever, nausea, vomiting • Chemosis and lid edema, proptosis
Lacrimal gland neoplasia	<ul style="list-style-type: none"> • Temporal upper eyelid swelling • Inferonasal globe displacement • Tearing, pain, diplopia • Palpable mass under superotemporal orbital rim
Orbital inflammation—idiopathic (orbital pseudotumor)	<ul style="list-style-type: none"> • Acute onset of orbital pain, headaches • Binocular diplopia, decreased vision, proptosis, lid edema • Induced hyperopia, decreased corneal sensation, increased IOP
Orbital vasculitis	<ul style="list-style-type: none"> • Systemic signs and symptoms (sinus, renal, pulmonary, skin) • Fever, increased ESR (erythrocyte sedimentation rate)

5. How do you investigate a case of cavernous sinus thrombosis?

- i. Cavernous sinus thrombosis is a clinical diagnosis and lab studies are seldom specific.
- ii. Hematological investigation:
 - a. Most patients exhibit a polymorphonuclear leukocytosis, often marked with a shift towards immature forms.
 - b. Complete blood count is done to look for polycythemia as an etiologic factor.
 - c. Decreased platelet count would support thrombotic thrombocytopenic purpura; leukocytosis might be seen in sepsis. In addition, if heparin is used as treatment, platelet counts should be monitored for thrombocytopenia.
 - d. Blood cultures generally are positive for the offending organism.
- iii. Immunological tests:
 - a. Antiphospholipid and anticardiolipin antibodies should be obtained to evaluate for antiphospholipid syndrome.
 - b. Tests that may indicate hypercoagulable states include protein S, protein C, antithrombin III, lupus anticoagulant and leiden factor V mutation. These evaluations should not be made while the patient is on anticoagulant therapy.
- iv. Electrophoresis—sickle cell preparation or hemoglobin electrophoresis
- v. Cerebrospinal fluid examination—examination of the cerebrospinal fluid is consistent with either a parameningeal inflammation or Frank meningitis.

6. What are the imaging studies done in cavernous sinus thrombosis?

A. Computed tomography (CT) is the investigation of choice to confirm the diagnosis.

- i. On noncontrast study—thrombosis of the cavernous sinus can be appreciated as increased density.
- ii. Contrast scan reveal filling defects within the cavernous sinus. Empty delta sign appears on contrast scans as enhancement of the collateral veins in the superior sagittal sinus walls surrounding a non-enhanced thrombus in the sinus
- iii. Negative CT cannot reliably rule out cavernous sinus thrombosis when the clinical suspicion is high.
- iv. Useful in ruling out other conditions such as neoplasm and in evaluating coexistent lesions such as subdural empyema. CT of the sinuses is useful in evaluating sinusitis; CT of the mastoids may be helpful in lateral sinus thrombosis.

B. Magnetic resonance imaging (MRI)

- i. Magnetic resonance imaging shows the pattern of an infarct that does not follow the distribution of an expected arterial occlusion. It may show absence of flow void in the normal venous channels.
- ii. Magnetic resonance venography (MRV) is an excellent method of visualizing the dural venous sinuses and larger cerebral veins.
- iii. Single-slice phase-contrast angiography (SSPCA) takes less than 30 seconds and provides rapid and reliable information.
- iv. If magnetic resonance studies are not diagnostic, conventional angiography should be considered.

C. Contrast studies

- i. Carotid arteriography is an invasive procedure and is therefore associated with a small risk.
- ii. Direct venography can be performed by passing a catheter from the jugular vein into the transverse sinus with injection outlining the venous sinuses.

7. How do you treat a case of cavernous sinus thrombosis?

A. Emergency department care:

- i. The mainstay of therapy is early and aggressive antibiotic administration. Although *S. aureus* is the usual cause, broad-spectrum coverage for gram-positive, gram-negative and anaerobic organisms should be instituted pending the outcome of cultures.
- ii. Anticoagulation with heparin may be considered. The goal is to prevent further thrombosis and reduces the incidence of septic emboli. Heparin is contraindicated in the presence of intracerebral hemorrhage or other bleeding diathesis.
- iii. Corticosteroids may help to reduce inflammation and edema and should be considered as an adjunctive therapy. When the course of cavernous sinus thrombosis leads to pituitary insufficiency, however, corticosteroids definitely are indicated to prevent adrenal crisis.

- iv. Surgery on the cavernous sinus is technically difficult. The primary source of infection should be drained, if feasible (e.g. sphenoid sinusitis, facial abscess).

Medical treatment

Antibiotic therapy ideally is started after appropriate cultures but should not be delayed if there are difficulties in obtaining specimens. Antibiotics selected should be broad-spectrum, particularly active against *S. aureus*, and capable of achieving high levels in the cerebrospinal fluid.

Drug categories:

- i. Antibiotics
 - ii. Anticoagulants
 - iii. Corticosteroids.
1. **Antibiotics**—empiric broad-spectrum coverage for gram-positive, gram-negative, and anaerobic organisms. Therapy must be comprehensive and should cover all likely pathogens in the context of the clinical setting. The common antibiotics are:
 - i. Oxacillin (2 g IV q4h)
 - ii. Ceftriaxone (2 g IV 112h)
 - iii. Metronidazole (500 mg IV q6h)
 2. **Anticoagulants**—unfractionated IV heparin and fractionated low molecular weight subcutaneous heparins are the 2 options in anticoagulation therapy. Dose: 80 mg/kg IV bolus; then 18 mg/kg IV infusion; titrate
 3. **Corticosteroids**—these agents have anti-inflammatory properties and cause profound and varied metabolic effects. In addition, these agents modify the body's immune response to diverse stimuli.

Complications of cavernous sinus thrombosis:

- i. Meningitis
- ii. Septic emboli
- iii. Blindness
- iv. Cranial nerve palsies
- v. Sepsis and shock.

Prognosis:

Septic cavernous sinus thrombosis:

- i. Mortality is upto 30%, with the majority of survivors suffering permanent sequelae and neurological deficit.
- ii. Full recovery is seen in < 40%
- iii. Rarely Frohlich's syndrome has been reported.

Aseptic cavernous sinus thrombosis:

- i. Variable
- ii. Depends on the underlying cause
- iii. Extent and severity of neurologic dysfunction
- iv. Mortality rate is much low
- v. Damage to the cranial nerves → persistent pareses, trigeminal neuralgia
- vi. Permanent visual loss is rare but can occur.

7.15. CAROTICO-CAVERNOUS FISTULAS

1. Define carotico-cavernous fistula.

It is an abnormal communications between the cavernous sinus and dural veins and the carotid arterial system.

2. Classify carotico-cavernous fistula.

Cause	Velocity of blood flow	Anatomy
Traumatic	High flow	Direct and dural
Spontaneous	Low flow	Internal carotid and external carotid, or both.

A. **High flow**—Carotid-cavernous fistulas, characterized by direct flow into the cavernous sinus from the intracavernous carotid artery.

Causes—These usually are traumatic and most often diagnosed in young men.

B. **Low flow**—Spontaneous shunts occur between the cavernous sinus and one or more meningeal branches of the internal carotid artery (usually the meningohypophyseal trunk), the external carotid artery, or both. These shunts have a low amount of arterial flow and almost always produce signs and symptoms spontaneously.

Causes:

- i. Spontaneously
- ii. In the setting of atherosclerosis, hypertension,
- iii. Collagen vascular disease,
- iv. During or after childbirth
- v. Elderly, especially women.

3. Describe dural shunts.

- i. Dural shunts between the arterial and venous systems have lower flow.
- ii. They may produce symptoms in younger patients spontaneously or in older patients due to hypertension, diabetes, atherosclerosis or other vascular disorders.
- iii. Anatomically, these shunts arise between the meningeal arterial branches and the dural veins.
- iv. The meningohypophyseal trunk and the artery of the inferior cavernous sinus provide the arterial supply to most dural shunts.
- v. Such shunts may be due to an expansion of congenital arteriovenous malformation, or due to spontaneous rupture of one of the thin-walled dural arteries that transverse the sinus.

4. What are the ocular manifestations of carotico-cavernous fistulas?

Ocular signs of carotico-cavernous fistulas are related to venous congestion and reduced arterial blood flow to the orbit. These abnormalities usually are unilateral, but can be bilateral or even contralateral to the fistula.

- A. **Conjunctiva**—Chemosis of the conjunctiva and arterIALIZATION of the episcleral vessels occurs in most patients. ArterIALIZATION of episcleral veins is the hallmark of all carotico-cavernous fistulas or dural shunts
- B. **Glaucoma**—Stasis of venous and arterial circulation within the eye and orbit may cause ocular ischemia and increased episcleral venous pressure may cause glaucoma.
- C. **Orbit**
- i. Exophthalmos is a common sign that occurs in almost all patients who have carotico-cavernous fistulas. Rapid-flow fistulas may develop exophthalmos within hours or several days.
 - ii. The orbit can become ‘frozen’, with no ocular motor function; usually, this is accompanied by conjunctival chemosis and hemorrhage. Vision may be reduced markedly as a result of optic nerve ischemia.
 - iii. ‘Pulsating exophthalmos’ is uncommon in carotico-cavernous fistula. Usually, the orbit is rigid from hemorrhage and edema and incapable of ‘pulsation’.
- D. **Bruits**—Bruits associated with fistulas and dural shunts can be appreciated both subjectively and objectively. A bruit can be heard best when the examiner uses a ‘bell stethoscope’ over the closed eye, over the superior orbital vein, or the temple. A subjective bruit (heard by the patient) almost always can be obtained from the history; however, an objective bruit heard over the orbit or temple by auscultation is relatively uncommon. A bruit is not pathognomonic of carotico-cavernous fistula. It also can be heard in normal infants, in young children, and in severe anemia.
- E. **Optic nerve**—Immediate or delayed visual loss occurs frequently in direct carotico-cavernous fistulas, due to optic nerve ischemia from apical orbital compression.
Long-standing fistulas can lead to loss of vision as a result of distention of the cavernous sinus or of retrobulbar ischemia.
- F. **Cranial nerve palsy**
- i. Diminished arterial flow to cranial nerves within the cavernous sinus may cause diplopia.
 - ii. The abducens nerve is affected most often as it lies in the cavernous sinus itself.
 - iii. Since the third and fourth nerves are encased in the superior internal dural wall of the sinus, they may be protected from changes caused by the fistula.
 - iv. Mechanical restriction from venous congestion and orbital edema also may contribute to limitation of eye movements.
- G. **Fundus picture**
- i. Ophthalmoscopic findings due to venous stasis and impaired retinal blood flow include retinal venous engorgement and dot and blot retinal hemorrhages.
 - ii. Central retinal vein occlusion may be observed in high-velocity carotico-cavernous fistulas with arterIALIZED venous channels.
 - iii. High episcleral and intraocular pressures rarely results in damage to the optic nerve.
 - iv. In the unusual cases of central vein occlusion, neovascular glaucoma can occur.

7.16. CAROTID ARTERY OCCLUSION

1. What are the common modes of presentation of carotid artery occlusion to an ophthalmologist?

- A. **Transient ischemic attack.** If the transient ischaemic attack involves the carotid system, the symptoms include hemiparesis, hemisensory loss, aphasia and transient monocular blindness (amaurosis fugax).
- B. **Purely ocular symptoms**, such as
1. Paratransient ischemic attack or complete visual loss due to an artery obstruction
 2. Decreased visual acuity
 3. Pain resulting from the ocular ischemic syndrome.
- C. Other patients are asymptomatic and any ocular findings consistent with carotid artery disease are incidental.

2. What is amaurosis fugax?

Amaurosis fugax (“fleeting darkness or blindness”; ocular transient ischemic episode).

- i. Most common symptom of carotid artery disease.
- ii. This phenomenon may be defined as a painless unilateral, transient loss of vision that usually progresses from the periphery toward the center of the field.
- iii. Often, the visual deficit takes the pattern of a dark curtain descending from above or ascending from below.
- iv. Complete or subtotal blindness follows in seconds and lasts from 1 to 5 minutes (rarely longer).
- v. Vision returns to normal within 10 to 20 minutes, at times by reversal of the pattern of progression.
- vi. The return of vision can be sectorial or altitudinal and is occasionally described as a “curtain rising.”
- vii. Generally, the vision returns to normal immediately after an attack. The frequency of these attacks varies from one or two attacks per month to 10 or 20 per day.
- viii. The retina—if observed during an amaurotic attack—may be normal or it may show obstruction (such as in central retinal artery obstruction).
- ix. It may exhibit migratory white retinal emboli (within the retinal arterioles and in association with disruption of the arterial circulation) or it may show cholesterol emboli moving through the arterial system.
- x. It is important to recognize amaurosis fugax as a transient ischemic attack because it is frequently caused by microembolization from an atheromatous ulcerative lesion in the ipsilateral extracranial carotid artery, at least in older patients.
- xi. About a third of all patients with an untreated transient ischemic attack can be expected to have a stroke; this rate is about four times greater than that of an age-matched population.

3. What are causes of amaurosis fugax?

- i. Migraine
- ii. Hematology disorders
- iii. Ocular hypertension
- iv. Arterial hypotension
- v. Vasospasm
- vi. Temporal arteritis
- vii. Pseudotumor cerebri
- viii. Structural cardiac defects
- ix. Ophthalmic artery stenosis
- x. Ophthalmic artery aneurysms.

4. What is ocular ischemic syndrome?

Ocular ischemic syndrome refers to the constellation of ophthalmic features that result from chronic hypoperfusion of the entire arterial supply to the eye, including the central retinal, posterior ciliary and anterior ciliary arteries.

The occlusion is at the level of:

- i. The carotid artery
- ii. Proximal to the point where the central retinal and ciliary arteries branch from the ophthalmic artery.

5. What is the clinical presentation of ocular ischemic syndrome?

- i. Patient, typically more than 50 years old, is more likely to be male than female.
- ii. Patient reports having a loss of vision in one or both eyes over a period of weeks to months.
- iii. Ocular or periocular pain here may or may not be associated, it is found in approximately 40% of persons with ocular ischemic syndrome. Typically, the pain is described as a dull ache over the eye or brow.
- iv. Ischemia to the anterior segment structures, or ocular angina, is thought to be the cause of this pain in some cases.
- v. History of difficulty adjusting from bright light to relative darkness represents inability of ocular circulation to supply enough oxygen to sustain increases retinal circulation.
- vi. Similar complaints occur after exertion, change in posture and postprandial period.
- vii. Additionally, the patient may relate a history of transient focal neurologic deficits.

Ocular symptoms and signs of carotid artery occlusion

Symptoms

- i. Visual loss
- ii. Pain—'ocular angina' (40% case)
- iii. Prolonged recovery after light exposure
- vi. Amaurosis fugax (10% cases)
- v. Associated with transient focal neurologic deficits.

Signs

- i. Spontaneous retinal arterial pulsations
- ii. Midperipheral retinal hemorrhage
- iii. Cholesterol emboli
- iv. Disk edema—AION
- v. Neovascularization of disk, retina, iris
- vi. Narrowed retinal arterioles
- vii. Dilated retinal veins
- viii. Arteriovenous communications.

Other peculiar presentations

- i. Ipsilateral Horner's syndrome
- ii. Carotid dissection
- iii. Ischemic anterior uveitis
- iv. Neovascular glaucoma

Systemic associations—most patients will have already been diagnosed with diabetes mellitus, hypertension, ischemic heart disease, cerebrovascular disease.

Differential diagnosis

1. Diabetic retinopathy
2. Non-ischemic CRVO

Diagnostic Workup

Prompt noninvasive vascular workup is mandatory

- i. To confirm carotid vascular disease
- ii. Establish cause (atheroma, emboli, dissection, vasculitis, compression, etc.)
- iii. Ocular and cerebral tolerance of carotid occlusion

Investigations

- i. Carotid color doppler
- ii. Cerebral angiography and arteriography (Gold standard)
- iii. Digital subtraction angiography.
- iv. Ultrasonography
- v. MRI angiography
- vi. Spiral CT angiography
- vii. Fundus fluorescein angiography.

6. What are the features of ocular ischemic syndrome on fluorescein angiogram?

Characteristic fluorescein angiographic features reflect the chronic hypoperfusion of the retinal and choroidal circulations, as well as ischemic damage to the neurosensory retina and retinal vessels.

- i. Prolonged arteriovenous transit time
- ii. Prolonged arm-to-retina circulation times (over 20 seconds)
- iii. Retinal vascular staining

- iv. Retinal capillary nonperfusion
- v. Delayed or patchy choroidal filling
- vi. Macular edema

7. What are the other tests that can be done for diagnosing ocular ischemic syndrome?

i. Photopic stress test

A marked difference in photopic stress recovery times between the two eyes is suggestive of macular disease, such as ocular ischemic syndrome; diseases of the optic nerve would be less affected.

ii. Electroretinography

Eyes with ocular ischemic syndrome show a decreased amplitude of both the a- and b-waves. The b-wave, which corresponds to the inner retinal layer, probably reflects the function of the bipolar and/or Müller cells, and it is diminished by compromised perfusion of the central retinal artery.

The a-wave correlates with photoreceptor function and is affected by choroidal ischemia.

iii. Orbital color Doppler imaging

Central retinal and posterior ciliary artery peak systolic velocities markedly reduced.

iv. Ophthalmodynamometry and oculoplethysmography

The normal ophthalmic artery has a systolic pressure of approximately 100 mm Hg and a diastolic pressure of approximately 60 mm Hg. In ocular ischemic syndrome, the systolic pressure is often less than 40 mm Hg, and the diastolic pressure may be less than 10 mm Hg. It is often useful to measure an unaffected contralateral eye for comparison.

v. Carotid duplex (b-mode and Doppler) scanning

Although safe and inexpensive, has limitations, less reliable than carotid angiography in distinguishing between a completely occluded artery and one that is nearly occluded, used as screening techniques for atherosclerotic disease.

vi. Carotid angiography (digital subtraction aortogram)

Despite its expense and low but definite morbidity rate, carotid angiography remains the most reliable method of assessing atherosclerotic carotid disease, and it serves as the “gold standard” in the evaluation of all other tests of the carotid arteries.

8. What is the treatment of ocular ischemic syndrome?

Treatment directed primarily at

- i. Treating ocular neovascularization and neovascular glaucoma.
- ii. Restoring blood flow into the eye with surgery.

Treatment of ocular neovascularization

- i. Fundus fluorescein angiography to determine cause of NVD/NVE.

- ii. Retinal ablative procedures—PRP/anterior retinal cryoablation still remains the first modality of treatment.

Systemic antiplatelet therapy

- i. Aspirin
- ii. Ticlopidine
- iii. Pentoxifylline
- iv. Dipyridamole
- v. Clopidrogel

Indications for medical management

- i. Inoperable carotid disease
- ii. Nonstenotic carotid disease
- iii. Medical contraindication to surgery.

Surgical management—In most cases, carotid endarterectomy remains the treatment of choice for symptomatic patients with severe stenotic atherosclerotic disease of the internal carotid artery.

7.17. OPHTHALMOPLEGIA

1. What are the types of ophthalmoplegia?

- i. **Total ophthalmoplegia**—if all the extrinsic and intrinsic muscle of one or both eyes are paralyzed.
- ii. **External ophthalmoplegia**—if only the extrinsic muscle of one or both the eyes are paralyzed.
- iii. **Internal ophthalmoplegia**—if only the intrinsic muscles (sphincter pupillae and ciliary muscle) of one or both eyes are paralyzed.
- iv. **Painful ophthalmoplegia**—the syndrome of painful ophthalmoplegia consists of periorbital pain or hemicranial pain combined with ipsilateral ocular motor palsies, oculosympathetic paralysis, and sensory loss in the distribution of ophthalmic and occasionally maxillary division of trigeminal nerve. The etiology of painful ophthalmoplegia may be divided into those with the involvement of cavernous sinus/superior orbital fissure and those without the involvement of the same.

2. Describe briefly anatomy of the superior orbital fissure.

Superior orbital fissure connects the middle cranial fossa with the orbit. It lies between the roof and lateral wall of the orbit and is a gap between greater wing and lesser wing of sphenoid, and is bounded by

- i. Body of sphenoid medially
- ii. Lesser wing of sphenoid above
- iii. Greater wing of sphenoid below
- iv. A part of frontal bone may complete the fissure laterally

Subdivisions—a common tendinous ring (tendon of Zinn) encircles the optic foramen and middle of superior orbital fissure and gives origin to recti muscles of the eye ball. The central part of the fissure within the ring is called oculomotor foramen.

3. What are the structures passing through the superior orbital fissure?

The various structures transmitted are:

A. Above the common tendinous ring

- i. Trochlear nerve medially
- ii. Frontal nerve laterally
- iii. Superior ophthalmic vein
- iv. Rarely recurrent lacrimal artery.

B. Through the oculomotor foramen

- i. Superior division of 3rd cranial nerve
- ii. Inferior division of the 3rd cranial nerve
- iii. Nasociliary nerve
- iv. Sympathetic root of ciliary ganglion
- v. Abducent nerve inferonasally.

C. Below the tendinous ring—inferior ophthalmic vein.

4. What are the causes of parasellar syndrome producing painful ophthalmoplegia?

- A. Trauma
- B. Vascular
 - i. Intracavernous sinus carotid artery aneurysm
 - ii. Posterior carotid artery aneurysm
 - iii. Carotid artery fistula
 - iv. Cavernous sinus thrombosis
- C. Neoplasm
 - i. Primary intracranial neoplasm—pituitary adenoma, meningioma, sarcoma, craniopharyngioma, neurofibroma, Gasserian ganglion neuroma and epidermoid
 - ii. Primary cranial tumor—chondroma, chordoma, giant cell tumor
 - iii. Local metastasis—nasopharyngeal tumor, cylindroma, chordoma, squamous cell carcinoma
 - iv. Distant metastasis—lymphoma, multiple myeloma
 - v. Inflammation
 - i. Bacterial—sinusitis, mucocele
 - ii. Viral—herpes zoster
 - iii. Fungal—mucormycosis
 - iv. Spirochaetal—*Treponema pallidum*
 - v. Mycobacterium
 - vi. Unknown causes—sarcoidosis, Wegner's granulomatosis, Tolosa-Hunt syndrome.

5. What are the causes of painful ophthalmoplegia with no involvement of the cavernous sinus/superior orbital fissure?

- A. Orbital disease
 - i. Idiopathic orbital inflammation (pseudotumor)
 - ii. Contiguous sinusitis
 - iii. Mucormycosis or other fungal infection
 - iv. Metastatic tumor
 - v. Lymphoma/leukemia.
- B. Diabetic ophthalmoplegia
 - i. Mononeuropathy
 - ii. Multiple cranial nerve palsy
- C. Posterior fossa aneurysm
 - i. Posterior communicating artery
 - ii. Basilar artery
- D. Cranial arteritis
- E. Migrainous ophthalmoplegia
- F. Gradenigo's syndrome
- G. Reader's syndrome
- H. Trauma.

6. What are the ways in which trauma can produce ophthalmoplegia?

Cranio-cerebral trauma may produce painful ophthalmoplegia in various ways namely

- i. Basilar skull fracture with ocular motor damage
- ii. Intracavernous carotid artery injury with subsequent aneurysm formation
- iii. Carotico-cavernous fistula
- iv. Painful ophthalmoplegia may occur as an acute phenomenon or as delayed phenomenon.

a. Acute painful ophthalmoplegia

- i. **Cranial nerve involvement**—immediate paralysis of III, IV, VI cranial nerves is a well known complication of closed head trauma.
- ii. **Orbit involvement**—the direct injury to the orbit can cause immediate impairment of ocular motility due to trauma to the ocular muscles, orbital hemorrhage and edema, or entrapment of the muscle or fasciae in the fracture site.

b. Delayed painful ophthalmoplegia

This may be due to various reasons

- i. Progression of the local edema after injury to the ocular motor nerve or to the orbit which tends to produce maximal impairment within few days after injury and manifestation itself as a worsening of the immediate impairment.
- ii. Progressive brainstem edema which becomes maximal within few days after the injury and is generally accompanied by other brainstem signs. This may be due to the injury to the blood vessels outside the brainstem rather than direct brainstem injury.
- iii. Sixth nerve and rarely fourth nerve paresis due to increased intracranial pressure without herniation, and third nerve paresis due to transtentorial herniation can all result from verity of mass lesions secondary to head injury.
- iv. Post traumatic sphenoid mucocele can cause painful ophthalmoplegia usually after delay of months or years.
- v. Sudden severe exophthalmos and painful ophthalmoplegia due to an orbital meningocele occurring one month after a frontal fracture has been reported.

7. What are the features of ophthalmoplegia due to intracavernous carotid artery aneurysm?

- i. Compromise about 3% of all intracranial aneurysm.
- ii. Most of these syndromes occur in middle aged individuals, without the history of incident head trauma.
- iii. The onset of signs and symptoms may be abrupt but may be slow and insidious.
- iv. Pain in and around the eye and face is the prominent symptom.

- v. The sixth nerve being the close relation of the internal carotid artery is affected first and in most cases third and fourth nerve are involved subsequently.
- vi. Trigeminal sensory loss is regarded as the classical manifestation of this disease.
- vii. Aneurysmal expansion can produce additional findings that vary with its directions.
 - a. Anterior expansion—can produce exophthalmos and ipsilateral and ipsilateral visual failure due to optic nerve compression.
 - b. Posterior expansion—may extend as far as petrous part of temporal bone and give rise to ipsilateral hearing loss
 - c. Inferior expansion—into the sphenoid sinus with subsequent rupture explains the massive and sometimes fatal epistaxis suffered by the patients.
 - d. Medial erosion of the aneurysm into the sella turcica can produce signs and symptoms which mimic a pituitary tumor.

8. Why is pupil spared in intracavernous carotid artery aneurysm causing third cranial nerve paresis?

- a. The small pupil may be due to simultaneous involvement of the both the third nerve and the sympathetic fibers surrounding the internal carotid artery (ICA).
- b. The absence of large pupil in the cavernous sinus lesion may sometimes reflect sparing of the inferior division of the third nerves.

9. Where do you ligate the carotid artery?

- a. Ligation of the carotid in the neck with or without intracranial clipping distal to the aneurysm
- b. Occlusion of the carotid artery by the detachable balloon catheter.

10. What are the features of ophthalmoplegia due to carotico-cavernous fistula?

- i. This represents the direct communication between the intracavernous carotid artery and the surrounding cavernous sinus.
- ii. The large majority arises traumatically.
- iii. Spontaneous fistula may develop. Causes:
 - a. Pre-existing aneurysm.
 - b. Angiodysplasias, such as Ehler-Danlos or pseudo-xanthoma elasticum.
- iv. The clinical features usually develop immediately although there may be a delay. The degree of the external symptom depends on the amount of the anterior drainage of the shunted blood.

11. What are the clinical features of carotico-cavernous fistula?

- i. **Conjunctiva**—There is arterialization of the bulbar conjunctiva often with marked proptosis and chemosis. Conjunctival prolapse with inversion of the fornix may occur.

- ii. **Cornea**—exposure keratitis. And possible corneal anesthesia from the fifth nerve damage.
- iii. **Orbit**—severe proptosis with limitation of the eyelid closure.
- iv. **Glaucoma** is usually due to increased episcleral venous pressure with open angles. Neovascular glaucoma may develop secondary to hypoxic retinopathy. Blood in the trabecular meshwork is the common finding on gonioscopy.
- v. **Bruit** may accompany these finding.
- vi. **Cranial nerves**—any of the cranial nerves may be involved.
- vii. **Vision**—visual loss may be due to
 - a. Traumatic optic neuropathy
 - b. Ocular steal phenomenon
 - c. Hypoxic retinopathy due to decreased ocular blood flow.

Management: The treatment of choice is balloon immobilization.

12. What are the features of ophthalmoplegia due to pituitary apoplexy?

- A. Pituitary tumors frequently invade the cavernous sinus and cause cavernous sinus syndrome
- B. Pituitary apoplexy, which occurs as a result of infarction of the pituitary adenoma, which has outgrown its blood supply.
 - i. It can be precipitated by radiation therapy, trauma and pregnancy.
 - ii. The condition is characterized by acute onset of headache, painful ophthalmoplegia, bilateral amaurosis, drowsiness or coma and subarachnoid hemorrhage.
 - iii. Headache is usually of sudden onset, generalized or only retrobulbar.
 - iv. Unilateral or bilateral ophthalmoplegia is due to involvement of III, IV and VI cranial nerve in the cavernous sinus.
 - v. The CSF shows xanthochromia, pleocytosis and elevated protein levels.
 - vi. CT scan often shows infarction of the tumor with hemorrhage in and above enlarged sella.

Treatment

It is a life threatening condition and needs prompt treatment.

Corticosteroids are the mainstay of treatment.

If there no improvement, surgical transnasal decompression is done.

13. What are the classical triad of pituitary apoplexy?

- i. Headache
- ii. Diplopia
- iii. Subarachnoid hemorrhage

14. What are the features of cavernous sinus meningiomas?

- i. Manifest as slowly progressive, painless lesion occurring in older women, they may occasionally present as sudden painful ophthalmoplegia.

- ii. Presents with ptosis, diplopia and parasympathetic pupillary involvement.
- iii. The demonstration of primary aberrant regeneration of the third nerve without a preceding neuropathy is exceedingly suggestive meningioma.
- iv. Management includes observation, radiation, surgical therapy or combination of all the three. They are extremely radiosensitive.

15. What are the features of nasopharyngeal tumors?

Ophthalmic signs and symptoms	Otolaryngeal symptoms
<ol style="list-style-type: none"> 1. Proptosis 2. Facial pain 3. Eye pain 4. Visual loss 5. Epiphora 6. Globe displacement 7. Limitation of extraocular movements 8. Diplopia 9. Photophobia 10. Conjunctival chemosis 11. Palpebral mass within the orbit 12. Bony erosion 13. Dacrocystitis 14. Horner's syndrome 	<ol style="list-style-type: none"> 1. Nasal congestion 2. Facial discomfort 3. Sinusitis 4. Facial swelling 5. Erythema 6. Headache 7. Epistaxis 8. Nasal mass 9. Difficulty in chewing and 10. Facial numbness

16. What are the features of Tolosa-Hunt syndrome?

This is a variant of acute inflammatory pseudotumor affecting the cavernous sinus or superior orbital fissure.

The diagnostic criteria are:

- i. Steady boring retro orbital pain which may precede ophthalmoplegia.
- ii. Second, third or fourth cranial palsy with or without Horner's syndrome.
- iii. Symptoms lasting for days to weeks
- iv. Occasional spontaneous remission, although neurological defect may persist.
- v. Recurrent attacks in the intervals of months to years.
- vi. No evidence of disease outside cavernous sinus.

Pathology—orbital periostitis with granulomatous vasculitis in the cavernous sinus.

Investigations:

- i. Hematological tests are nonspecific.
- ii. CSF analysis is unremarkable.
- iii. Carotid angiography shows abnormalities in the configuration of intracavernous carotid artery in the form of irregular narrowing or constriction. These changes resolved with steroid therapy.
- iv. Orbital venography shows occlusion of superior ophthalmic vein on the affected side. There may be partial or absent filling of cavernous sinus. Follow-up venography shows persistent filling defects, suggestive of fibrosis in the involved areas.

Treatment: Corticosteroids are the mainstay of the treatment.

7.18. MALINGERING

1. What are the tests to detect malingering?

A. Total binocular blindness

a. Observation

- i. Truly blind moves cautiously, bumps into things naturally; hysterics avoids objects, “seeing unconsciously”, malingerer goes out of his or her way to bump into objects.
- ii. Patients who are truly blind in both eyes tend to look directly at the person with whom they are speaking, whereas patients with nonorganic blindness, particularly patients who are malingering, often look in some other direction.
- iii. Similarly, patients claiming complete or near complete blindness often wear sunglasses, even though they do not have photophobia, and external appearance of eyes is perfectly normal.

b. **Pupillary response**—earliest and single most important test.

- i. Intact direct and consensual response excludes anterior visual pathway disease.
- ii. In patients with better than NPL, there is no consistent relationship between amount of visual loss and pupillary deficit.

c. **Menace reflex**—blinking to visual threat.

d. **Reflex tearing**—sudden strong illumination thrown into eyes difficult to suppress reflex tearing in a patient with good visual acuity.

e. **Signature**—Truly blind patients have no difficulty in doing signature. While functionally blind patients sign their name with exaggerated illegibility.

f. Another way to detect nonorganic visual loss in a patient who claims to be unable to see shapes and objects in one or both eyes is to ask patient to touch the tips of index fingers of both hands together. If the patient claims loss of vision in one eye only, opposite eye is patched before test is performed.

As physician knows, the ability to touch the fingers of both hands together is based not on vision but on proprioception. Thus patient with organic blindness can easily bring the tips of the fingers of two hands together, whereas patients with nonorganic blindness, particularly malingerer will not do so. As the patient’s hand is held up in front of him, and he is asked to look at his hand, the malingerer tends to look to the right or left, anywhere but not at his hand.

g. **Optokinetic nystagmus (OKN)**—If patient claims no perception of light, light perception only, or perception of hand movements in one or both eyes. Rotating optokinetic drum or horizontally moving tape can be used to produce a horizontal jerk nystagmus that indicates intact vision of at least 3/60. It is important in this regard that the images on the tape or drum be sufficiently large that the patient is not able to look around them. When testing a patient who claims complete loss of

vision in one eye only, we begin test in rotating the drum or moving the tape in front of the patient while he/she has both eyes open. Once we elicit good OKN, cover the unaffected eye with palm of our hand or a hand held occluded. The patient with nonorganic loss of vision is one eye will continue to slow jerk nystagmus.

- h. **Mirror Test**—A large mirror held in front of patient's face, and patient is asked to look directly ahead. Mirror is then rotated and twisted back and forth, causing image in mirror to move. Patients with vision better than NPL show nystagmoid movement of the eyes, because they cannot avoid following the moving mirror.
- i. **Visual evoked potential (VEP)**—Flash and pattern reversal stimuli correlation exists between check size and level of acuity. Although difficult, it is possible to consciously alter response to pattern reversal stimulation with convergence, meditation, intense concentration.
P300 component of VEP is suggestive of conscious stimulation of the cerebral tissue even though the patient says that he does not view the pattern stimulus.

B. Total monocular blindness

More common than binocular blindness, tends to occur with malingering. Can use any of the above tests with unaffected eye occluded.

a. Diplopia tests

- i. Suspected eye occluded while strong prism held with apex bisecting pupil of good eye. Patient admits monocular diplopia. As suspected eye uncovered, the entire prism is placed before good eye, producing binocular diplopia. If patient still reports diplopia, functional blindness is revealed.
- ii. Make patient walk up and down stairs with vertical prism over allegedly blind eye.
- iii. Prism dissociation tests

Can be used to detect mild degrees of nonorganic monocular visual loss. In these tests patient is first asked if he or she has experienced double vision in addition to loss of vision in affected eye. If answer is negative, the patient is told that the examiner will test, the alignment of both eyes and that test should produce vertical double vision.

A 4 prism diopter loose prism is then placed base down in front of unaffected eye at the same time that 0.5 prism diopter loose prism is simultaneously placed with base in any direction over the eye with decreased vision.

In this way the patient does not become suspicious that examiner is paying specific attention to one or the other eye.

A 6/6 or larger letter projected at a distance, the patient is asked if he/she has double vision.

When patient admits diplopia, she/he is then asked whether the two letters are of equal quality or sharpness, and an assessment of visual acuity can be made.

b. Fixation tests

- i. 10 prism base out test
 - relies upon refixation movement to avoid diplopia
 - 10D base out prism in front of normal eye produces shift of both eyes with refixation movement of the other eye

- ii. Vertical bar (reading)

A ruler is held 5 inches from nose in between eyes while patient reads at near. Overlap of visual fields allow a binocular person to read across the bar. If patient reads without interruption, functional blindness confirmed. Can also use prism in front of suspect eye, resulting in diplopia, which should interrupt reading.

c. Fogging tests

- i. With both eyes open on the phoropter, patient starts reading eye chart. Examiner progressively adds more plus to the good eye while patient keeps reading.

Final line read is patient's visual acuity in suspected eye.

- ii. Crossed cylinder technique

A variation of this test is the use of paired cylinders. A plus cylinder and minus cylinder of same power (usually from 2 to 6 diopters) are placed at parallel axes in front of the normal eye in a trial frame. The patient's normal correction is placed in front of the affected eye. The patient is asked to read with both eyes open, a line that previously has been read with the normal eye but not with the affected eye.

As patient begins to read, the axis of one of the cylinders rotated through 10° to 15° . The axes of two cylinders thus will no longer be parallel due to blurring of vision in normal eye.

If patient continues to read the line or can read it again when asked to do so, he/she must be using affected eye.

- iii. Instill cycloplegic agent into unaffected eye while doing applanation tension, have patient read at near.

d. Color tests

- i. Red/green duochrome in projector, red/green glasses worn such that red lens covers suspected eye. Eye behind red lens sees letters on red and not on green side of chart. And eye behind the green lens sees only letters on the green side.

If patient reads the entire line, the suspected eye is being used.

- ii. Red/green glasses and worth four dot test—Patient should see appropriate number of dots.

- iii. Ishihara color testing

In this test, use of red and green filter in front of each eye, while subject views Ishihara's color plates. The numbers and lines on Ishihara plates are visible only through red filter while plates 1 and 36 are seen by all persons even if color blind, and are more distinctly seen through this filter. Even with visual acuity of 3/60, all color plates are can be seen through red filter.

The test for detecting functionally impaired vision is performed as follows:

After testing visual acuity of each eye, the patient is given the red and green goggles with red filter over the eye with alleged impaired vision. With sound eye, patient will not see plates through green filter. If the patient sees the plates, the visual acuity must be 3/60 or better. If there is no response the goggles should be switched so that the red filter will be over the sound eye, and if the patient does not respond even 1 and 36, then test should be done without any goggles to prove wrong answers.

iv. Polaroid glasses and vectorgraphic slides

Polarizing lenses can be used in several ways to detect nonorganic visual loss in patients with decreased vision in one eye only.

In American Optical Polarizing Test, the patient wears polarizing glasses, and the test object, a project-o-chart slide projects letters alternately so that one letter is seen by both eyes, the next by the left eye, the next by right eye and so on.

Another test uses polarizing lens placed before a projector. The patient is asked to read the chart while wearing polarizing lenses, with one eye or the other being allowed to see the whole projected image at a time, with vertical polarizer in one eye and horizontal polarizer in the other eye.

v. Red Amsler grid test

Using red-green filters, red Amsler grid test is useful in cases with unilateral field loss when the professed visual field defect extends to within 10° of fixation. A paracentral scotoma must be demonstrated monocularly with Amsler grid. The patient is then asked to look at red Amsler grid on black background, using red filter in front of eye with scotoma and green filter in front of normal eye. The red on black can be seen only through red filter.

A positive response indicates a credibility problem and proves functional visual loss.

vi. Stereoscopic tests

Stereoacuity is directly proportional to Snellen's acuity. Test plates used are Titmus fly or Randot test.

40 seconds of arc stereoacuity compatible with not worse than 20/20 or 6/6 Snellen's acuity OU.

Relationship of Visual Acuity and Stereopsis

Visual Acuity	Stereopsis
6/6	40 seconds
6/9	52 seconds
6/12	61 seconds
6/18	78 seconds
6/24	94 seconds
6/36	124 seconds
6/60	160 seconds

C. Diminished vision

Simulation of visual acuity less than 6/6 is more difficult to detect.

Binocular or monocular can use most of the tests above plus the following:

- i. DKR (Doctor killing refraction) or toothpaste refraction
Start with 6/5 line and express disbelief the patient could not see big letters on the 6/6 line then proceed up chart until patient reads.
- ii. Visual Angle—varying test distance with eye chart, Landolt's C rings or Tumbling E block such that patient sees a smaller visual angle or demonstrates inconsistencies. For example, reading 6/6 letter at 10 feet is equivalent to 6/12 acuity.
- iii. Move patient back and forth slightly in the chair, helping them get into focus or place combinations of lenses adding upto plano in a trial frame to help magnify their image.

D. Field defects

1. **Constricted field (On kinetic perimetry)**

- These field defects show steep margins
- Remains same regardless of size of object and test distance from screen (tunnel vision).
- The degree of functional constriction may vary in the same patient from one examination to the next. This may be demonstrated in malingering using tangent screen.
- Marks used to outline the patient's visual field are moved to new positions closer to fixation when the patient is absent.
- When the test is repeated, the new field will confirm to new pin arrangement.

2. **Monocular hemianopias**

Field testing monocularly and binocularly—fields overlap.

3. **Paracentral field defect**

In this malingering can be detected with the help of red Amsler grid test.

8

Orbit

CHAPTER

8.1. ECTROPION

1. What is ectropion?

Ectropion is an eyelid malposition characterized by an outward turning of the eyelid margin away from the globe accompanied by separation between the eyelid and the globe.

2. What is the surgical anatomy of the eyelid?

Eyelid is a bilamellar structure.

Anterior lamella consists of:

- i. Skin
- ii. Thin areolar subcutaneous connective tissue.
- iii. Orbicularis oculi: It is a striated muscle, which is anatomically divided into 3 parts, viz. orbital, preseptal and the pretarsal.

Posterior lamella consists of:

- i. Tarsal plate
 - a. Dense fibrous tissue
 - b. 25–29 mm long
 - c. 1–1.5 mm thick
 - d. Upper tarsus: 8–12 mm in height
 - e. Lower tarsus: 4–5 mm in height
- ii. Conjunctiva

3. What are the upper lid and lower lid retractors?

- i. These lie between the anterior and the posterior lamella
- ii. **Upper lid retractors:**
 - levator palpebrae superioris
 - Muller's muscle
- iii. **Lower lid retractors:**
 - Capsulopalpebral fascia
 - Sympathetically innervated inferior tarsal muscle

4. What is capsulopalpebral fascia?

- i. **Origin:** as capsulopalpebral head from delicate attachments to inferior rectus muscle
- ii. Extends anteriorly and splits into two and surrounds the inferior oblique muscle
- iii. Again rejoins to form the Lockwood's ligament and fascial tissue anterior to this forms the capsule palpebral fascia
- iv. **Insertion:** on the inferior fornix along with inferior tarsal muscle and on inferior border of tarsus.

5. How are the eyelids attached to the bony orbit?

Eyelids are attached to bony orbit via the medial and lateral tendons.

Medial canthal tendon: 2 limbs

- i. Anterior (superficial)—attached to the anterior lacrimal crest
- ii. Posterior (deep)—attached to the posterior lacrimal crest
- iii. Lacrimal sac is enclosed between the two
- iv. Common canaliculus lies immediately posterior to the anterior limb.

Lateral canthal tendon:

- i. Laterally the tarsal plate becomes fibrous strands that form the crura of lateral canthal tendon.
- ii. The crura of upper and lower lid fuse to form common lateral canthal tendon.
- iii. It is about 1–3 mm thick and 5–7 mm long.
- iv. Insertion is 1.5 mm inside the lateral orbital rim on the Whitnall's tubercle as a part of the lateral retinaculum.

Laxity of lateral canthal tendon is due to stretching and redundancy of the free portion of tendon between the tarsal plate and the tubercle.

6. How is ectropion classified?

Classification:

- A. Upper lid ectropion
 - Lower lid ectropion—more common
- B. i. Medial
 - ii. Lateral
 - iii. Total
- C. Etiologically
 - i. Involutional
 - ii. Cicatricial
 - iii. Paralytic
 - iv. Mechanical
 - v. Congenital

7. How do we stage the severity of ectropion?

Staging

- i. **Mild:** posterior lid margin just falls away from contact with globe
- ii. **Moderate:** complete eversion of lid margin exposing the conjunctiva
- iii. **Severe:** complete eversion of lid (tarsal ectropion)

8. What are the clinical features of ectropion?

Clinical features:

Can be asymptomatic

- i. **Punctal eversion:** This leads to decrease tear drainage and disuse punctal atrophy → epiphora → constant wiping → eczematous changes in the skin → further aggravation of the ectropion.
- ii. **Conjunctival exposure:** This leads to keratinization, hyperemia, xerosis → punctal stenosis and chronic conjunctivitis → chronic irritation and foreign body sensation.
- iii. **Corneal exposure:** It is due to improper closure of the lids → keratitis → pain, photophobia and decreased vision.

9. How to clinically evaluate ectropion?

Clinical evaluation: Aim is → find type,

- i. Underlying mechanism and
- ii. Decide the appropriate treatment.

It is done in 3 parts:

A. OCULAR:

B. LOCAL: look for

- i. Herpes zoster dermatitis
- ii. Surgical scars
- iii. Traumatic scars
- iv. Facial anatomy and symmetry
- v. Facial function

C. SYSTEMIC: look for

- i. Skin disorders, e.g. lamellar ichthyosis
- ii. Actinic dermatitis
- iii. Parkinsonism

10. How do you test for the following?

i. **Lid laxity:** 2 tests

- a. **Pinch/retraction/distraction test:** If central portion of lower lid can be pinched (between index finger and the thumb) and is able to be pulled >6 mm from the globe, significant lid laxity is present.
- b. **Snap back test:** Central portion of lid is pulled and released; failure to snap back in its original position indicates lid laxity.

ii. **Canthal tendon integrity:**

a. Lateral tendon:

- Rounding of the lateral canthal angle
- Horizontal shortening of the palpebral fissure
- Decrease in distance between temporal limbus and lateral canthal angle
- Direct palpation of inferior crus of the lateral canthal tendon with simultaneous medial traction.

b. Medial tendon:

- Look for position of the punctum during lateral traction of the lid. Movement of punctum lateral to nasal limbus or displacement > 3 mm indicates partial dehiscence
- Rounding of the medial canthal angle
- Direct palpation of the medial canthal tendon with simultaneous lateral traction.

iii. **Orbicularis muscle tone:** Ask the patient to squeeze the eyes tightly and try and open the eyes against resistance.

iv. **Lower lid retractor disinsertion:**

- Inferior fornix deeper than the normal
- Higher resting position of the lower lid
- Diminished excursion of lower lid in the downgaze.
- Disinserted edge of the retractors may be seen as a whitish band in the inferior fornix below the inferior edge of the tarsus.

v. **Lacrimal apparatus:** Look for

- Direction of the punctum
- Stenosis of the punctum
- Patency of lacrimal drainage system

vi. **Cicatricial component:** Grasp the lower lid margin and pull superiorly; if it does not reach 2 mm above the inferior limbus → vertical deficiency present.

vii. **Inferior scleral show:** This is seen if associated with lid retraction. In such cases mere lid shortening procedures will aggravate the retraction and have to be combined with free full thickness skin graft.

viii. **Orbitotarsal disparity:** When contact and thereby pressure is inadequate between orbital contents and eyelid, there is lid instability.

ix. **Corneal sensations:** decreased sensations esp. in case of paralytic ectropion indicates early surgical intervention.

x. **Lagophthalmos**

11. What is involitional ectropion and the mechanisms of it?

a. Involitional ectropion

- i. Most common
- ii. Gradual onset
- iii. Commonest in lower lid
- iv. Earliest symptom: tearing
- v. Earliest sign: inferior punctal eversion

b. Mechanisms:

- i. Laxity of both medial and lateral canthal tendon
- ii. Partial dehiscence of the canthal tendon
- iii. Orbicularis muscle undergoes ischemic changes due to microinfarcts → laxity
- iv. Fragmentation of elastic and collagenous tissue within the tarsus leads to thinning and instability.
- v. Dehiscence of lower lid retractors

12. What is the management of involutional ectropion?

a. Medical management:

- i. To relieve tearing and inflammation, lubricating antibiotic ointment can be used.
- ii. Antibiotic—Steroid combination can be used preoperatively for 2–3 weeks to decrease eyelid edema and hyperemia.

b. Punctal ectropion: Following procedures can be done

i. Suture technique:

- a. 2 double armed 5-0 chromic sutures are taken
- b. The first suture is taken at the inferior border of tarsus at junction of nasal and medial 1/3 of lid
- c. The second is taken at similar position at junction of medial and lateral 1/3 of lid
- d. Both emerge through skin at level of infraorbital rim

Advantage:

Useful in debilitated patients

Disadvantage:

- i. Temporary method
- ii. Recurrence
- iii. Foreshortening of the inferior fornix

ii. Medial spindle procedure: Also called as the tarso conjunctival excision

- i. The lower punctum is inverted by vertically shortening the posterior lamella and tightening the lower lid retractors.
- ii. Diamond shaped area (6 mm x 3 mm) of tarso conjunctiva is excised below the punctum.
Closed with absorbable sutures from upper apex to lower apex including the lower lid retractors.

iii. Electrocautery:

- i. Several deep burns placed 2 mm apart along the entire lower lid at the junction of conjunctiva and the lower margin of the tarsus
- ii. Effect can be titrated by depth and duration of cauterization
- iii. Recurrence is common

iv. Punctoplasty:

- i. Done in combination with ectropion, if associated with punctal stenosis
- ii. One snip, two snip procedures can be employed

v. Otis Lee procedure:

- i. Done in case of severe punctal ectropion or in atonic medial ectropion involving both upper and lower puncta
- ii. Horizontal incision at the junction of skin and conjunctiva medial to the puncta
- iii. Lids joined with nonabsorbable suture
- iv. Excess of skin is removed.

vi. Smith's lazy-T procedure:

- i. Done when medial ectropion is associated with horizontal lid laxity.
- ii. Done when medial canthal tendon is firm
- iii. Pentagonal wedge of excess horizontal eyelid tissue is resected 4 mm lateral to the punctum.
- iv. This is coupled with excision of diamond of tarso conjunctiva below the punctum to invert it.
- v. Conjunctiva is closed horizontally with interrupted catgut sutures
- vi. Eyelid is closed.

vii. Medial canthal tendon plication:

- i. Indicated in excess medial tendon laxity
- ii. Canalicular part of medial canthal tendon is shortened by suturing the medial end of lower tarsal plate to the main part of medial canthal tendon with nonabsorbable suture.

viii. Pentagonal wedge resection:

- i. Generalized ectropion with horizontal lid laxity
- ii. No excess of skin is seen
- iii. A full thickness pentagon is resected to correct the excess of horizontal lid laxity
- iv. Done usually 5 mm from the lateral canthus or at the maximum lid laxity
- v. Lid defect is repaired

ix. Smith's modification of Kuhnt-Szymanowski procedure:

- i. Done when medial canthal tendon is firm
- ii. Associated with horizontal lid laxity and excess of skin
- iii. Subciliary blepharoplasty incision is made
- iv. Pentagonal wedge resection is done to correct horizontal lid laxity
- v. Excess of skin is removed as a triangular flap
- vi. Both skin and lid are closed.

x. Lateral tarsal strip procedure:

- i. Done when ectropion is associated with horizontal lid laxity and lateral tendon laxity
- ii. A subciliary incision is made from the lateral 2/5 of eyelid upto the lateral canthus and extending posteriorly
- iii. Lateral canthotomy is done
- iv. Inferior crux of lateral tendon is incised
- v. Tarsal strip is made by excising the mucosa cilia orbicularis and skin at the lateral end
- vi. Lid is shortened by removing the excess tarsus
- vii. Tarsal strip is sutured to lateral orbital tubercle
- viii. Excess of skin is removed

xi. Edelstein-Dryden procedure:

- i. Done when ectropion is associated with mid facial trauma involving the lacrimal system
- ii. Associated with detached posterior horn of medial tendon

- iii. Periosteal flap is made from nasal bone and everted and hinged medially to lacrimal sac fossa and sutured to nasal margin of the tendon
- iv. Thus, a new posterior horn is created.

13. What is cicatricial ectropion?

- i. Seen in both upper and lower lid.
- ii. Associated with vertical shortening within the anterior lamella of lid.

Etiology:

- i. Trauma—mechanical, thermal, chemical, radiation
- ii. Actinic dermatitis
- iii. Herpes zoster dermatitis
- iv. Basal cell carcinoma
- v. Lamellar ichthyosis
- vi. Iatrogenic, e.g. post blepharoplasty.

Management:

- A. Medical:** Ocular lubricants, soft contact lens, air humidification, Digital massage of the scar
Steroids injection in the scar
Wait for 6 months post trauma for scar to soften before surgery.

B. Surgical:

a. Z-plasty:

- i. Done for localized vertical scar crossing the skin tension lines
- ii. Initial incision made along the scar and another incision at each end of the central line at an angle of 60°
- iii. Scar tissue is excised
- iv. Two flaps of skin are transposed which increase the length of the skin in the line of scar contraction at the expense of shortening the skin at right angles to it
- v. It also alters the line of the scar

b. V-Y plasty:

- i. Done for localized vertical scar but with minimal skin shortening
- ii. V shaped incision with apex of V at the base of scar
- iii. Scar tissue is excised and V is closed as Y thereby lengthening the lid vertically

c. Skin replacement:

- i. Indicated in generalized shortage of the skin
- ii. Can be a transposition flap from the upper lid (if excess skin is present) or a thin full thickness skin graft (in case of extensive scarring)
- iii. Skin graft can be taken from upper eyelid, retroauricular skin, supraclavicular area.

14. What is paralytic ectropion?

- i. Due to facial nerve palsy, a loss of orbicularis tone → tarsal instability and an ectropion

- ii. Pre-existing involutional changes make the condition more pronounced
- iii. Associated with failure of lacrimal pump function
- iv. Other features of facial nerve palsy are seen.

15. What is the management of paralytic ectropion?

A. Management: Primary goal is to protect cornea.

- i. **Medical:** apart from lubricants, moisture chambers, Donaldson's Patch can be used.
- ii. **Surgical:** indications are
 - i. Progressive corneal deterioration
 - ii. Permanent facial paralysis
 - iii. Corneal anesthesia
 - iv. Dry eye
 - v. Lack of good Bell's phenomenon
 - vi. Monocular vision on the paralytic side

B. Medial canthoplasty:

- i. Indicated in paralytic medial ectropion
- ii. Eyelids are sutured together medial to lacrimal puncta to reduce the increased vertical interpalpebral distance at the medial canthus caused by the unopposed action of the lid retractors and to bring the lacrimal puncta into the tear film
- iii. Excess of skin is cut

C. Lateral canthal sling:

- i. Usually combined with medial canthoplasty
- ii. Indicated in generalized lid laxity

D. Temporary suture tarsorrhaphy:

E. Facial sling:

- Used to support the lid when large bulk of atonic midfacial tissue continues to drag down the lower lid. Commonly fascia lata is used.

F. Temporalis transfer:

- Reserved for most severe cases that have recurred after previous surgery and in permanent facial nerve damage.

16. What is mechanical ectropion?

- i. Secondary to mechanical factor which either displaces the lid or pulls the lid out of its normal position against the globe
- ii. For example, large lid tumors, conjunctival chemosis from orbital inflammatory conditions, severe lid edema
- iii. **Management:** treat the cause.

17. What is congenital ectropion?

- i. Rare, familial, but no Mendelian inheritance
- ii. Due to deficiency of eyelid skin → vertical shortening → ectropion
- iii. Associated with blepharophimosis syndrome
- iv. At rest the lids are apposed, but on attempt to look up or close the lids → eversion
- v. Treatment is horizontal lid tightening with free full thickness skin grafting.

18. What are the features of upper lid ectropion?

- i. Rare, congenital, common in black male infants, associated with trisomy-21
- ii. Usually bilateral
- iii. Can also be seen in cicatricial conditions, e.g. lamellar ichthyosis
- iv. Mechanisms: vertical shortening of anterior lamella, vertical lengthening of posterior lamella, failure of fusion between septum and levator aponeurosis and spasm of orbicularis.
- v. **Treatment:** Pressure patch over re-inverted lids
Lid reconstruction procedures.

8.2. ENTROPION

1. Define entropion.

Inward rotation of the eyelid margin such that the cilia brush against the globe.

2. How do you classify entropion?

- i. Involutional entropion (senile entropion)
- ii. Cicatricial entropion
- iii. Congenital entropion
- iv. Spastic

3. What is the pathophysiology of involutional entropion?

It affects mainly lower lid because upper lid has a wider tarsus and is more stable.

Pathogenesis:

- i. Horizontal lid laxity/medial and lateral tendon laxity.
- ii. Over riding of preseptal over pretarsal orbicularis during lid closure.
- iii. Lower lid retractor weakness (excursion decreased of lower lid in downgaze).

4. What are the causes of cicatricial entropion?

Caused by severe scarring of the palpebral conjunctiva which pulls the lid margin towards the globe.

Causes:

A. Infection

- i. Trachoma
- ii. Chronic blepharoconjunctivitis
- iii. Herpes zoster ophthalmicus

B. Trauma

- i. Chemical
- ii. Mechanical
- iii. Radiation

C. Immunological

- i. Erythema multiforme
- ii. Ocular cicatricial pemphigoid
- iii. Cicatricial vernal conjunctivitis
- iv. Dysthyroid.

5. What is congenital entropion?

- i. It is caused by the improper development of retractor aponeurosis insertion into inferior border of the tarsal plate
- ii. It is extremely rare
- iii. Inversion of entire tarsus and lid margin
- iv. Epiblepharon and horizontal tarsal kink are to be differentiated.

6. How is congenital entropion classified?

Classification is based on severity.

Kemp and Collin Classification

A. Minimal

- i. Apparent migration of meibomian glands
- ii. Conjunctivalization of lid margin
- iii. Lash globe contact on upgaze.

B. Moderate

Same features plus

- i. Lid retraction
- ii. Thickening of tarsal plate.

C. Severe

Lid retraction (incomplete closure)

- i. Gross lid retraction
- ii. Metaplastic lashes
- iii. Presence of keratin plaques.

7. What are the examinations to be done in a case of entropion?

- i. **Lid margin and ocular surface**—look for signs of punctate keratopathy due to blepharitis, meibomianitis, trichiasis, foreign bodies, dry eyes, corneal disease
- ii. **Lid instability**—forceful lid closure
Excursion of the lower lid in downgaze usually 3–4 mm—loss of movement indicates retractor weakness/disinsertion
- iii. **Lid laxity**—pinch test
- iv. **Lid elasticity**—snap test
- v. **Medial canthal tendon (MCT) laxity**
- vi. **Cicatricial component**—see directly by everting the lids. It can also be ascertained by pulling the lid superiorly. If it does not reach 2 mm above the lower limbus, lid is vertically deficient.
- vii. Syringing
- viii. Jones dye test
- ix. Schirmer's test

8. What are the preoperative evaluation tests to be done in a case of entropion?

Preoperative evaluation/testing

A. Assessment of capsulopalpebral fascia

- i. Higher eyelid resting position in primary gaze
- ii. Presence of white infratarsal band
- iii. Increased depth of inferior conjunctival fornix
- iv. Reduction in vertical eyelid excursion from upgaze to down gaze.

B. Assessment of horizontal eyelid laxity

- i. Passive horizontal eyelid distraction.
- ii. Hills test—central eyelid pulled > 6 mm between eyelid and cornea—abnormal.

C. Enophthalmos

- a. Assessment of relative enophthalmos—exophthalmometry.

D. Assessment of preseptal orbicularis muscle override

- i. Subjective assessment—done in primary gaze/forceful eyelid closure/spontaneous blink.
- ii. Thick appearance of eyelid.

E. Assessment of posterior lamellar support

- i. Height of tarsal plate

F. Presence of cicatrizing conjunctival disease

- i. Trachoma
- ii. Stevens-Johnson syndrome
- iii. Ocular cicatricial pemphigoid
- iv. Chronic meibomian gland dysfunction
- v. Chemical injury/topical medication

G. Corneal/conjunctival status**H. Lash position/lacrimal and meibomian gland function.****9. What are the nonsurgical management of entropion?**

- i. Taping
- ii. Treatment of associated blepharitis, meibomianitis, corneal disease
- iii. Lubricants
- iv. Botulinum toxin injection
- v. Bandage contact lenses

10. What are the temporary surgical measures in involutional entropion?

- i. **Transverse sutures** are placed through the lid to prevent the upward movement of the preseptal orbicularis muscle.
- ii. **Everting sutures** are placed obliquely to shorten the lower lid retractors and transfer their pull to the upper border of the tarsus.
- iii. **Transverse sutures**—3 doubled armed 4-0 catgut sutures are taken through the lid from the conjunctiva to the skin in the lateral two thirds of the lid. Start below tarsus and make each needle emerge through the skin about 2 mm apart, just below the level at which they entered the conjunctiva .
- iv. **Everting sutures**—They are similar but start lower in the fornix and emerge nearer to the lashes.
- v. Sutures are removed after 10–14 days

11. What are the principles of permanent treatment in involutional entropion?

Strengthening the lid retractors as in Jones, Reeh, Wobigs and modified Jones procedure where the inferior lid retractors are plicated or attached to the tarsus.

Shortening the anterior lamina by suturing the preseptal orbicularis to pretarsal orbicularis so as to prevent migration of orbicularis, forming a cicatrix between the two parts of orbicularis.

Removal of horizontal lid laxity if present by tarsal strip procedure, where small strip of lid margin, conjunctiva and skin are removed to create a free end of the tarsal plate that functions as the canthal ligament.

12. What is Weiss procedure?

- i. Transverse lid split + everting sutures.
- ii. This is indicated in cases with minimum horizontal lid laxity when long term results are required.

13. What is Quickert procedure?

- i. Transverse lid split + everting sutures + horizontal lid shortening.
- ii. This is a long term procedure for cases where horizontal lid laxity also presents.

14. What is Jones procedure?

Plication of lower lid retractors.

Indication: Recurrence after Quickert's procedure

15. What are the steps of modified Jones procedure?

- i. Mark a subciliary incision along the length of the lid. If there is lengthening the amount of shortening required should be marked.
- ii. Incision is made into the skin—muscle upto the tarsal plate. The tarsal plate is exposed.
- iii. Blunt dissection is continued at inferior margin of tarsus. The stretched is dehiscd. Retractors will be visible.
- iv. Three double armed 6-0 vicryl sutures are passed; the retractors may be plicated or simply reattached. The 3 sutures are tightened and correction observed. The straightening of margin is immediately seen. The end point is when the posterior margin is just apposed to the globe.
- v. The skin and muscle lamina usually needs to be shortened and is excised in a spindle manner.
- vi. Associated lengthening—by excising the lid in full thickness pentagonal shape (Bick's procedure)
- vii. Sutures are removed in 6–7 days

16. What is the surgical procedure for congenital entropion?

Hotz procedure

Minimal ellipse of skin and orbicularis is excised from medial two thirds of the lower lid.

Skin is fixed to lower edge of the tarsus.

17. What is the management of cicatricial entropion?

Marginal incision and grafting

Tarsal fracture and margin rotation—Tenzel procedure—indicated when lid retraction is <1.5 mm from the limbus.

Posterior lamellar grafting in cases of posterior lamellar shortening—indicated when lid retraction is > 1.5 mm from the limbus.

Tarsal wedge resection—common procedure used in cases with trichomatous scarring (especially if tylosis is present).

18. What are the various materials used as posterior lamellar grafts?

- i. Conchal cartilage
- ii. Nasal chondromucosa
- iii. Palatal mucoperichondrium
- iv. Buccal mucosa
- v. Tarsconjunctival composite graft
- vi. Mucus membrane graft
- vii. Amniotic membrane transplant—now becoming more popular

19. What are the complications after surgery for entropion?

- i. **Recurrence**—it is the most common complication of surgical correction of entropion.
- ii. **Ectropion**—possible mechanisms include excessive skin removal, over advancement of the retractors onto the anterior face of the tarsal plate. Shortening of the septum, hematoma and excessive scar formation.
- iii. **Lagophthalmos**—shortened septum—warm compresses and massage with corticosteroid ointment may correct mild cases.
- iv. **Lid necrosis**—margin rotation techniques commoner.
- v. **Lid infection, wound dehiscence**
- vi. **Graft complications**—symblepharon, corneal injury induced by rough posterior eyelid surface.

8.3. PTOSIS

1. What is the definition of blepharoptosis?

Drooping or infero displacement of upper eye lid.

2. How will you classify blephroptosis?

Two classification systems.

A. According to onset:

- i. Congenital
- ii. Acquired

B. According to cause:

- a. Neurogenic
 - i. Third nerve palsy
 - ii. Third nerve misdirection
 - iii. Horner's syndrome
 - iv. Marcus Gunn jaw-winking syndrome
- b. Myogenic
 - i. Myasthenia gravis
 - ii. Myotonic dystrophy
 - iii. Ocular myopathies
 - iv. Simple congenital
 - v. Blepharophimosis syndrome
- c. Aponeurotic
 - i. Involutional attenuation
 - ii. Repetitive traction like rigid contact lenses
- d. Mechanical
 - i. Plexiform neuroma
 - ii. Hemangioma
 - iii. Acquired neoplasm

3. How to classify amount of blephroptosis?

The difference in marginal reflex distance (MRD) 1 of the two sides in unilateral cases

Or

The difference from normal in bilateral cases gives the amount of ptosis.

Amount of ptosis may be classified as:

- Mild ptosis - 2 mm or less
- Moderate ptosis - 3 mm
- Severe ptosis - 4 mm or more

4. What is MRD1 and its significance?

Margin reflex distance (MRD)

The distance between the center of the lid margin of the upper lid and the light reflex on the cornea in primary position would give the MRD1.

- i. If the margin is above the light reflex, the MRD1 has a **positive value**.
- ii. If the lid margin is below the corneal reflex in cases of very severe ptosis the MRD1 would have a **negative value**. The latter would be calculated by keeping the scale at the middle of upper lid margin and elevating the lid till the corneal light reflex is visible. The distance between the reflex and the marked original upper lid margin would be the MRD1.
- iii. MRD1 is the single most effective measurement in describing the amount of ptosis.

Margin reflex distance 1 (MRD1): Normal 4–5 mm

The mean measurement in Indian eyes is 4.1 ± 0.5

It must be remembered that ptotic lid in unilateral congenital ptosis is usually higher in down gaze due to the failure of levator to relax.

The ptotic lid in acquired ptosis is invariably lower than the normal lid in down gaze.

5. What is margin reflex distance 2 (MRD2)?

MRD2 is the distance from corneal light reflex to lower eye lid margin.

6. What are various methods to evaluate Levator function?

i. Berke's method (lid excursion)

Measures the excursion of the upper lid from extreme down gaze to extreme upgaze with action of frontalis muscle blocked.

The patient is positioned against a wall while the surgeon's hands press the forehead above the eyebrows ensuring that there is no downward or upward push. The patient is then asked to look at extreme downgaze and then in extreme upgaze and the readings are recorded in millimeters. Crowell Beard reported normal eyelid excursion to be between 12–17 mm.

ii. The levator function is classified as:

8 mm or more	— Good
5–7 mm	— Fair
4 mm	— Poor

iii. Putterman's method

This is carried out by the measurement of distance between the middle of upper lid margin to the 6 'o clock limbus in extreme upgaze. This is also known as the margin limbal distance (MLD). Normal is about 9.0 mm.

The difference in MLD of two sides in unilateral cases

(Or)

The difference with normal in bilateral cases multiplied by three would give the amount of levator resection required.

iv. **Assessment in children**

Measurement of levator function in small children is a difficult task. The presence of lid fold and increase or decrease on its size on movement of the eyelid gives us a clue to the levator action. Presence of anomalous head posture like the child throwing his head back suggests a poor levator action.

v. **Iliff test**

This is another indicator of levator action. It is applicable in first year of life. The upper eyelid of the child is everted as the child looks down. If the levator action is good, the eyelid reverts back on its own.

7. **What is margin crease distance (MCD)?**

i. **Margin crease distance (MCD)**

The height of the crease on the normal side should be measured and compared to the ptotic eyelid in downgaze.

In case of a very faint lid crease, it can be made prominent by using a cotton tipped applicator below the lid margin. In patients, when more than one lid crease is present, the most prominent one should be considered.

ii. **MCD in normal eyes is 5–7 mm.**

The distance of the lid crease from the margin is measured as it helps in planning the surgical incision. Also presence of a distant lid fold in a case of moderate to severe ptosis with good levator action indicates a levator aponeurotic dehiscence.

8. **What is Bell's phenomenon?**

It is the upward rotation of eyeball on closure of the eye. This is referred to as Bell's phenomenon.

Confirmation of presence of Bell's phenomenon is important before undertaking any surgical procedure to avoid risk of postoperative exposure keratopathy.

9. **What is pseudoptosis?**

Pseudoptosis is false impression of eye lid drooping. It may be caused by:

- i. *Lack of support* of lids by the globe as in artificial eye, microphthalmos, phthisis bulbi or enophthalmos.
- ii. *Contralateral lid retraction*
- iii. *Ipsilateral hypotropia*. The pseudoptosis will disappear when hypotropic eye assumes fixation on covering the normal eye.
- iv. *Brow ptosis* due to excessive skin on brow or seventh nerve palsy.
- v. *Dermatochalasis* in which excessive upper lid skin overhangs the eye lid margin.

10. What is Marcus Gunn jaw winking syndrome?

It is the most common type of congenital synkinetic neurogenic ptosis. About 5% of congenital ptosis manifests this phenomenon.

This synkinesis is thought to be caused by aberrant connection between motor division of cranial nerve 5 and levator muscle.

Signs:

Retraction of ptotic lid in conjunction with stimulation of the ipsilateral pterygoid muscles by chewing, sucking, opening the mouth or contralateral jaw movement.

Jaw winking does not improve with age, although patient may learn to mask it.

Treatment:

No surgical treatment is entirely satisfactory.

Management depends on the cosmetic significance of the jaw winking, where jaw winking is not significant the choice of procedure depends on the amount of ptosis and the levator action is carried out as in any case of congenital simple ptosis. A larger levator resection is necessary and under correction is common. In case with significant jaw winking bilateral levator excision with a fascia lata, sling surgery is the procedure of choice.

11. What are various options for ptosis repair?

Ptosis repair is a challenging oculoplastic surgical procedure.

Nonsurgical treatment: are unusual but may include devices called eyelid crutches that are attached to eyeglass frames. They are occasionally useful in patients with neurogenic or myogenic ptosis in whom surgical correction can lead to severe, exposure related corneal problems.

It is advisable to wait till 3–4 years of age for surgical correction when the tissues are mature enough to withstand the surgical trauma and a better assessment and postoperative care is possible due to improved patient cooperation. There should be no delay in surgical management in cases of severe ptosis where pupil is obstructed and the possibility of the development of amblyopia is high.

Surgical approach depends on whether

- a. Ptosis is unilateral or bilateral
- b. Severity of ptosis
- c. Levator action
- d. Presence of abnormal ocular movements, jaw winking phenomena or blepharophimosis syndrome.

The choice of surgical procedure is as follows:

Fasanella-Servat operation

- a. Mild ptosis (<2 mm or less)
- b. Levator action >10 mm
- c. Well defined lid fold—no excess skin

Levator resection

- a. Mild/moderate/severe ptosis
- b. Levator action ≥ 4 mm

Brow suspension ptosis repair

- a. Severe ptosis
- b. Levator action <4 mm
- c. Jaw-winking ptosis or blepharophimosis syndrome

Bilateral ptosis

In cases of bilateral ptosis, simultaneous bilateral surgery is preferred to ensure a similar surgical intervention in the two eyes. However in cases where gross asymmetry exists between the two eyes, the eye with a greater ptosis is operated first and the other eye is operated after 6–8 weeks when the final correction of the operated.

12. What are the various surgical steps in the different techniques for ptosis correction?**A. Modified Fasanella-Servat surgery:**

It's done for

- i. Mild ptosis (<2 mm or less)
- ii. Levator action >10 mm

It is the excision of tarso conjunctiva, Muller's muscle and levator.

Xylocaine with adrenaline is used for local anesthesia in adults but general anesthesia is necessary for children.

Surgical steps

- i. Three sutures are passed close to the folded superior margin of the tarsal plate at the junction of middle, lateral and medial one-third of the lid.
- ii. Three corresponding sutures are placed close to the everted lid margin starting from conjunctival aspect near the superior fornix in positions corresponding to the first 3 sutures.
- iii. Proposed incision is marked on the tarsal plate such that a uniform piece of tarsus, decreasing gradually towards the periphery is excised.
- iv. A groove is made on the marked line of incision and the incision is completed with a scissor. The first set of sutures help in lifting the tarsal plate for excision.
- v. The tarsal plate not more than 3 mm in width is excised.

B. Levator resection

This is the most commonly practiced surgery for ptosis correction. It may be performed through skin or conjunctival route.

Surgical steps

- i. The proposed lid crease is marked to match the normal eye considering the margin crease

- ii. Incision through the skin and orbicularis is made along the crease marking.
- iii. The inferior skin and orbicularis are dissected away from the tarsal plate.
- iv. The upper edge is separated from the orbital septum.
- v. The fibers of the aponeurosis are cut from their insertion in the inferior half of the anterior surface of the tarsus.
- vi. The levator is freed from the adjoining structures.
- vii. The lateral and the medial horn are cut whenever a large resection is planned.
- viii. Care should be taken that Whitnall's ligament is not damaged.
- ix. A double armed 5-0 vicryl is passed through the center of the tarsal plate by a partial thickness bite.
- x. It is then passed through the levator aponeurosis at height judged by the preoperative evaluation. Intraoperative assessment is made.
- xi. Two more double armed vicryl 5-0 sutures are passed through the tarsus about 2 mm from the upper border in the center and at the junction of central third with the medial and lateral thirds.
- xii. These sutures are then placed in the levator and intraoperative assessment made.
- xiii. Excess levator is excised.
- xiv. Four to five lid fold forming sutures are placed.

C. Brow suspension repair

This surgery is the procedure of choice in simple congenital ptosis with a poor levator action. A number of materials like nonabsorbable sutures, extended polytetrafluoroethylene (ePTFE), muscle strips, banked or fresh fascia lata strips have been used for suspension.

D. Temporary sling

Thread sling is carried out in very young children with severe ptosis where prevention of amblyopia and uncovering the pupil is the main aim. The suture sling procedures have a relatively higher recurrence rate of or may show formation of suture granuloma. Definitive surgery may be performed at a later date when a fascia lata sling is carried out.

E. Fascia lata sling

It is considered in children above four years of age having severe congenital simple ptosis with poor levator action. Even in cases of unilateral severe ptosis a bilateral procedure is preferred because a unilateral surgery causes marked asymmetry in downgaze. Results of bilateral surgery are more acceptable.

8.4. EYELID RECONSTRUCTION

1. What are the common causes of eyelid defects?

Eyelid tissue loss is usually the result of trauma or resection of a pathologic process such as tumor or segmental trichiasis.

i. Defects due to trauma

Eyelid wounds, especially those resulting from trauma, tend to gape widely giving the unnerving appearance of a large amount of tissue loss. Fortunately, the eyelid is quite elastic and a large majority of these defects can be repaired with direct closure.

ii. Defects due to surgical resection of tumor

Reconstruction of the eyelid is simplified by the technique of resection. Resection of a lesion of the eyelid should be made with full thickness incisions.

2. What are the principles of eyelid reconstruction?

- I. The repair depends on its size and position and the state of surrounding tissues.
- II. Components which require consideration include the posterior lamella, the anterior lamella, both lamella or a full-thickness defect, the medial and lateral canthi and the lacrimal drainage system.
- III. The approach should proceed by considering direct repair first, followed by lateral cantholysis and then a tissue transfer procedure using either a flap and/or a graft.

3. What is the anesthesia required?

- I. Local anesthesia for repair of eyelid lacerations is best obtained by performing a regional block. Anesthesia of most of the lower eyelid can be obtained by injecting 1cc of anesthetic into the infraorbital foramen.
- II. Anesthesia of the upper lid is obtained by blocking the supraorbital nerve. Again, additional anesthesia may be necessary laterally because of the lacrimal nerve. Anesthesia to the medial canthal area and lacrimal sac is obtained by blocking the infratrochlear nerve.

4. What are the preoperative preparations?

- I. The eye should be anesthetized with xylocaine eye drops. A corneal shield lubricated with antibiotic ointment is useful. The surrounding skin should be prepped with betadine but the solution should not be used to cleanse the wound. The wound should be irrigated profusely with warmed saline. All dirt and foreign particles should be cleansed, especially embedded dirt which can cause permanent discoloration and tattooing.
- II. Wound edges should be minimally debrided of all necrotic tissue. Irregular edges should be freshened to allow for straight surgical margins to suture together. Identifiable landmarks such as eyebrows or eyelid margins should be sutured first.

5. Classify common reconstruction options of periocular defects.

Region and defect	Closure option	Indication
Eyelids		
Partial thickness (anterior lamellar)	Primary closure Local skin and myocutaneous flap Full-thickness skin graft	
Full-thickness	Primary closure	Defects < 15 mm or < 25% of lid margin
	Primary closure + lateral canthotomy + cantholysis	Defects 25–50% of lid margin
	Tenzel semicircular flap	Defects of 50–75% of lid margin
	Hughes tarsoconjunctival flap + full-thickness skin graft or local flap	Lower eyelid defects >75% of lid margin
	Cutler-Beard technique	Upper eyelid defects >75% of lid margin
	Free graft for posterior lamella + local flap for anterior lamella	Defects >75% of lid margin
	Mustarde rotating cheek and opposing lid flaps	Large lid defects >75%
	Composite lid grafts	Defects <8 mm of lid margin
Medial canthus		
	Local flaps (e.g. nasoglabellar transposition flap)	
	Paramedian forehead flap	
	Full-thickness skin grafts	
	Combination of above	
Lateral canthus		
	Local flaps	
	Full-thickness skin grafts	

6. What are the procedures for repairing anterior lamellar defects?

- i. Direct skin closure
- ii. Skin flaps
- iii. Skin graft: (a) full thickness (b) partial thickness

7. How is direct skin repair done?

Wounds involving a small loss of partial thickness eyelid skin with an intact eyelid margin can usually be closed primarily. Skin can be closed with 6-0 or 7-0 silk in adults and 7-0 chromic gut in children. If tissue closure results in some tension, the wound should be closed with horizontal tension rather than vertical tension to try avoiding ectropion. Sutures can be removed at 5–7 days and scar massage beginning in one week after suture removal.

8. What are the various types of skin flaps used?

- i. **V-Y plasty**—to lengthen structures, e.g. telecanthus repair and close defects. Glabellar flap is its variant.
- ii. **Rhomboid flap**—used in closure of medial and lateral periorbital defects. The rhombic flap is useful for non-marginal lesions where vertical tension on the eyelids can be avoided.
- iii. **Z-plasty**—to increase the length of skin and to change the direction of scar.

9. What are the various type of skin grafts used for anterior lamellar repair?

i. Full-thickness skin grafts

A full-thickness skin graft contains both epidermal and dermal components. For eyelid reconstruction, the contralateral eyelid is the best donor site. If not enough tissue can be obtained from there, the postauricular region and supraclavicular region are also good choices. All donor sites should be hairless to avoid trichiasis.

After harvesting the full-thickness graft in the standard way, the graft is sewn into place. A standard bolster is then placed. The dressing may be removed in five days.

ii. Split-thickness skin grafts

A split-thickness skin graft (STSG) is composed of epidermal components only. STSGs have a poor texture and color match with eyelid skin and tend to contract more than full-thickness grafts. They, therefore, are not used very much in eyelid reconstruction unless there is no other alternative (e.g. a badly burned patient without full-thickness skin to harvest). Usually taken from inner arm or thigh.

10. What are the various procedures for posterior lamellar reconstruction?

Posterior lamellar graft

- i. Tarsal rotation
- ii. Hughes procedure
- iii. Ear cartilage graft
- iv. Mucous membrane graft
- v. Tarsosconjunctival graft

11. What is the principle of posterior lamellar graft?

The posterior lamella consists of tarsus and conjunctiva. In cases of posterior lamellar shortening grafts like sclera, cartilage, mucosa graft can be used to lengthen posterior lamella. In upper lid, grafts are placed between tarsus and LPs. In lower lid grafts are placed between tarsus and lower lid retractors.

12. What is free tarsoconjunctival graft?

For full-thickness defects that are too large to close primarily, a graft taken from the posterior surface of the ipsilateral or contralateral upper eyelid will provide both conjunctiva and tarsus to reconstruct the posterior lamella. The donor site is left to granulate. The graft is sutured to the residual tarsus or canthal tendons in the recipient site and then covered by a sliding myocutaneous flap to reconstruct the anterior lamella. This technique works equally well for the lower or upper eyelid.

13. What is Hughes tarsoconjunctival flap and skin graft procedure?

The Hughes procedure is a two-staged operation for reconstruction of total or near total lower eyelid defects. As with the free tarsoconjunctival graft, a block of tarsus and conjunctiva is marked out on the ipsilateral upper lid. However, the upper border is left attached superiorly and a conjunctival flap is dissected off of the underlying Müller's muscle to the superior fornix. The tarsal flap is advanced down into the lower lid defect and sutured to residual tarsus or canthal tendons and the lower lid retractors. The anterior lamella is reconstructed with a skin graft or myocutaneous flap. After three weeks the conjunctival flap is cut off along the new lower lid margin.

14. How to repair eye lid defects with eye lid margin involvement?

- i. The wound edges should be sharply trimmed (minimally). A 6-0 or 7-0 silk is first placed through a Meibomian gland 3 mm from eyelid margin to depth of 3 mm. The suture is brought out of the laceration and into the other side 3 mm deep to the lid margin emerging 3 mm from the laceration. The second suture is placed in a similar fashion through the posterior lash line. The third is placed between these in the gray line. They are tied anteriorly and left long.
- ii. The tarsus is then closed by placing absorbable suture through 3/4 to 7/8 of the tarsal thickness. Full thickness bites of the tarsus in the upper lid would expose to the conjunctival surface and most likely cause a corneal abrasion. Heavier suture should be used for the lower lid tarsus (5-0 chromic) than the upper lid tarsus (6-0 chromic) because there is greater tension on the lower lid.
- iii. The skin can then be closed with 6-0 or 7-0 interrupted silks with the eyelid margin sutures tucked under the eyelash margin sutures to keep from touching the cornea. Skin sutures can be removed in 5–7 days, while the eyelid margin sutures should remain for 10–14 days.

15. What is lateral cantholysis?

For full-thickness defects with moderate loss of tissue, closure may be obtained by performing a lateral canthotomy with cantholysis. The lateral canthotomy is performed by making a horizontal cut from the lateral canthus to the orbital margin using a straight Stevens scissors. This maneuver splits the tendon into an upper and lower limb. An additional 3–5 mm of length can be obtained by cutting either limb (depending on which eyelid is involved). The eyelid margin can then be closed. The skin of the lateral canthotomy can be closed with 6-0 silk.

16. How will you classify full thickness lid defect repair?

1. *Horizontal extent of defect*

Can be classified as

- i. less than 30%
- ii. 30–50% defect
- iii. >50% defect

2. *Assess the vertical extent of the defect*

- i. Vertically shallow (5–10 mm)
 - Skin mobilization and posterior lamellar reconstruction
- ii. Intermediate (10–15 mm)
 - Skin flap & posterior lamellar reconstruction
- iii. Large vertical (>15 mm)
 - Rotation flap + posterior lamellar reconstruction

17. How is the procedure of semicircular flap of Tenzel done?

- i. This flap is a variation of the lateral cantholysis. It adds rotation to the lateral advancement. A full thickness semicircular flap of skin and orbicularis muscle which is high arched, (i.e. vertical diameter (22 mm) is more than horizontal diameter (19 mm)) is fashioned superior to the lateral canthal angle for lower eyelid defects and inferior to the lateral canthal angle for upper eyelid defects.
- ii. After cantholysis and wide undermining is performed, the flap is rotated to close the defect with minimal tension. Again, it is important to secure the deep orbicularis musculature to the periosteum to prevent drooping of the lateral canthal angle.

18. What are the various skin muscle flaps used for full thickness eyelid reconstruction?

- I. Temporal advancement flap
- II. Semicircular flap of Tenzel
- III. Mustarde cheek rotation flap
- IV. Median forehead flap
- V. Temporal forehead or friddle flap
- VI. Cutler-Beard flap
- VII. Glabellar flap

19. What is Cutler-Beard or bridge procedure?

- i. The Cutler-Beard procedure is used for repair of large full-thickness defects of the upper lid.
- ii. The true width of the defect should be determined by grasping the cut tarsal edges with a forceps.
- iii. The horizontal width of the defect is then marked on the lower lid 1–2 mm below the inferior tarsal border. This avoids compromising the marginal artery of the lower eyelid.
- iv. The horizontal incision is placed through skin and conjunctiva. Vertical incisions (usually 1–2 cm) are made full-thickness into the lower fornix until enough laxity exists to allow the flap to advance.
- v. The flap is then brought beneath the bridge of the lower eyelid margin and tarsus to cover the globe. It is then sutured into the upper lid defect.
- vi. The dressing is important for the success of this flap. It is important to avoid any pressure on the inferior margin bridge of tissue. A protective shield should be worn until the flap is taken down 6–8 weeks later. This is accomplished by severing the flap about 2 mm from the desired lid margin. Again, the conjunctival side should be longer than the skin side so that it can wrap around and create a new lid margin.

20. What is the Mustarde cheek rotation flap?

- i. It is useful for reconstruction of very large lower eyelid defects, especially if the defect extends into the cheek tissue.
- ii. The flap is created by making an incision at the lateral canthus which extends superolaterally then curving inferiorly to just in front of the ear. Wide undermining is then done (beware of facial nerve branches) to allow the flap to rotate.
- iii. This flap is not used as much anymore because the thick cheek skin does not make a good match with the eyelid skin. Additionally, it has the potential for numerous complications including facial nerve paralysis, sagging of the lateral canthal angle, ectropion, pseudotrachiasis from facial skin hairs and cheek flap necrosis.

21. What is glabellar flap?

- i. It is used for repair of defects involving medial canthus and medial part of upper lid. In it, a V-Y flap is advanced and rotated from glabellar region.
- ii. An inverted V incision is made in midline of the brow. The flap is undermined and is sutured into the defect.

22. What are the precautions to be employed before closure of wounds?

- i. Ensure complete hemostasis and remove all blood clots
- ii. Eliminate tension in wound edges by adequate undermining
- iii. There should be no dead space

- iv. Meticulous wound closure in layers. Adequate closure of deeper tissues using inverted mattress suture.
- v. Ensure eversion of wound edges and no overlapping.

23. What are the important points to be kept in mind while suturing non marginal lid defects?

- i. Smaller defects can be sutured without undermining
- ii. Round defect should be converted into elliptical shape
- iii. All vertical tension on lid margins should be eliminated by adequate undermining
- iv. Incisions should be parallel to lines of tension/lid margin
- v. Defect should be sutured in three layers
- vi. For larger defects local skin flaps/grafts indicated

24. What are the basic differences between upper and lower lid reconstruction?

Upper eyelid reconstruction	Lower eyelid reconstruction
1. More important than LL due to cornea closure	Less important for corneal protection.
2. Should be done on priority if both lids are missing	Can wait
3. Incision should be parallel to lines of tension and lid margin, preferably at lid crease	Wound parallel to lines of tension and lid margin would result in scleral show/ectropion. Hence wound should be converted perpendicular to lid margin
4. Gravitational effect and lid laxity does not cause adverse effects	Can cause ectropion, retraction, scleral show
5. Thinner skin	Thicker
6. Height of tarsus: 8–9 mm	Ht : 5 mm
7. Less important for tear drainage	More important for tear drainage

25. How is the full thickness lid margin defects managed?

A. Less than 30% defect

- i. direct closure
- ii. direct closure with canthotomy and cantholysis

B. 30–50% defect

- i. direct closure with canthotomy and cantholysis
- ii. Rotational flaps like Tenzy semicircular flap

C. Greater than 50% defect

- i. Cutler-Beard technique - for upper lid
- ii. Reverse Culter-Beard technique for lower lid
- iii. Hughes tarsoconjunctival flap
- iv. Mustarde's cheek rotational flap

D. Total loss of upper lid

- i. Mustarde's switch flap
- ii. Transposition cheek flap

- iii. Fricke temporal forehead transposition flap
Posterior lamellar graft is necessary for lining all these flaps.

E. Total loss of upper lid and partial loss of lower lid

- ***If total loss of lower lid is associated with presence of lateral part of lower lid:*** This part of lower lid is used as a switch flap for upper lid (Mustarde operation). Remaining part of lower lid is reconstructed with temporal frontal pedicle flap lined by mucus membrane.
- ***If total loss of UL is associated with presence of medial part of LL:*** This need not be transferred to UL. UL is formed by supraorbital/forehead flap and LL formed by cheek rotation flap is lined by mucus membrane.

F. Absence of both lids with intact eyeball:

- Protection of cornea: By suturing the remnants of conjunctiva over it.
By free mucosal grafts

26. What are the techniques for upper eyelid reconstruction?

- i. Direct closure
- ii. Tenzel's lateral semicircular rotation flap
- iii. Cutler-Beard bridge flap
- iv. Tarsoconjunctival flap
- v. Free tarsoconjunctival graft
- vi. Mustarde's marginal pedicle rotation flap
- vii. Composite eyelid graft
- viii. Local myocutaneous flap with post.lamellar graft
- ix. Periorbital flaps with posterior lamellar grafts.
Inclusion of few fibers of LPS while forming lid crease is essential.

27. What are the techniques for lower eyelid reconstruction?

- i. Direct closure
- ii. Lateral semicircular rotation flap
- iii. Reverse Cutler-Beard operation
- iv. Free tarsoconjunctival graft with myocutaneous advancement flap
- v. Hughes tarsoconjunctival advancement flap
- vi. Mustarde's cheek rotation flap
- vii. Temporal forehead flap with posterior lamellar grafts
- viii. Composite eyelid graft

8.5. BLEPHAROPHIMOSIS SYNDROME

1. What is blepharophimosis syndrome?

Approximately 6% of children with congenital ptosis demonstrate the typical findings of blepharophimosis syndrome.

Clinical features commonly seen are:

- i. There is severe bilateral ptosis with poor levator function.
- ii. The palpebral fissures are horizontally shortened (blepharophimosis)
- iii. Epicanthus inversus
- iv. Telecanthus—the intercanthal distance is more than half the interpupillary distance. It occurs due to increase length of medial canthal tendons.
- v. True hypertelorism is occasionally present.
- vi. Lateral ectropion of lower lids.
- vii. High arching of eyebrows.

Associated features may include tarsal plate hypoplasia and poorly developed nasal bridge. Some patients demonstrate low-set, “lop” ears.

Blepharophimosis is a dominantly inherited condition, although the severity of findings varies among affected family members. Sporadic cases also occur.

Blepharophimosis is associated with primary amenorrhea in some family lines.

Treatment of blepharophimosis usually requires a staged approach.

Mustarde’s double “Z” plasty or Y-V plasty with transnasal wiring is done as a primary procedure. This gives a good surgical result both in terms of correction of telecanthus as well as deep placement of the medial canthus. The results are long lasting.

Brow suspension is carried out 6 months after the first procedure for correction of ptosis.

8.6. THYROID-RELATED ORBITOPATHY (TRO) AND PROPTOSIS

1. What is the volume of the orbit?

30 ml.

2. Why is the new terminology of thyroid orbitopathy preferred over the older thyroid-related ophthalmopathy?

It is a disease in which orbit is the primary site of involvement in which the following changes take place:

- i. Increase in the volume of extraocular muscles.
- ii. Increased fat synthesis.
- iii. Associated primary lacrimal gland dysfunction.
- iv. Compression of the orbital part of the optic nerve.

3. What is the difference in the terminology of exophthalmos and proptosis?

- i. **Exophthalmos** is an active or a dynamic disease characterized by the forward protrusion of the eyeball, classically seen in thyroid-related orbitopathy and hence usually bilateral.
- ii. **Proptosis** is a passive protrusion of the eyeball classically seen in retro-orbital space occupying lesions and hence usually unilateral.

4. What is physiological proptosis?

It is seen in infants, owing to the fact that orbital cavities do not attain their full volume as rapidly as the eyeball. It is also seen in conditions such as bending forwards or during straining/strangulation.

5. What are the accepted exophthalmometry values to determine proptosis or enophthalmos?

Proptosis > 21 mm
Enophthalmos < 10–12 mm

6. Mention few causes of acute proptosis.

- i. Orbital emphysema
- ii. Orbital hemorrhage
- iii. Orbital cellulitis.

7. Mention a few causes of intermittent proptosis.

- I. Orbital varices (90%)
- II. Highly vascular neoplasms like hemangioma or lymphangioma
- III. Recurrent orbital hemorrhages
- IV. Due to vascular congestions such as
 - a. strangulation, suffocation
 - b. intense muscular efforts
 - c. constriction of jugular veins in cases of cavernous sinus thrombosis.
- V. Periodic orbital edema (particularly angioneurotic edema)

- VI. Intermittent ethmoiditis
- VII. Recurrent emphysema.

8. Mention causes of pulsating proptosis.

It may be vascular or cerebral in origin.

A. Vascular pulsations

- a. Aneurysm of carotid or ophthalmic artery
 - I. A-V aneurysms (commonest—carotid-cavernous communications 90%)
 - II. Saccular aneurysms
 - III. Cirroid aneurysm of orbit
- b. Venous dilatations
 - Orbital varix—rarely pulsates
- c. Thrombosis of cavernous sinus
- d. Vascular tumors in orbit—hemangioma, lymphangioma (rarely).

B. Cerebral pulsations

Transmission pulsation present when there is orbital wall defect.

- a. Orbital root defect associated with meningocele or encephalocele
- b. Neurofibromatosis associated with large dehiscence in orbital wall
- c. Traumatic hiatus.

9. What is the anatomical basis for increase in proptosis with straining or internal jugular venous or carotid artery compression?

- i. Acutely raised pulmonary artery pressure may be transmitted to the veins of the head and neck including facial vein.
- ii. The facial vein lacks valves, so that raised facial venous pressure may in turn be transmitted to orbit through its anastomosis with superior ophthalmic vein (principal venous drainage of orbit). This is the probable anatomical basis for congestive expansion of the orbit.

10. What are the causes of unilateral proptosis?

The causes can be divided into following causes:

- i. Thyroid related orbitopathy
- ii. Deformities of the cranium and asymmetric orbital size
- iii. Inflammatory lesions
 - a. Acute inflammations
 - i. Inflammation of orbital tissue
 - ii. Lacrimal gland
 - iii. Whole globe (panophthalmitis)
 - iv. Para nasal sinuses
 - v. Eyelids
 - vi. Cavernous sinus
 - b. Chronic inflammations
 - i. Granulomas
 - ii. Tuberculoma

- iii. Gummas
 - iv. Sarcoidosis
 - v. Chronic dacryoadenitis.
- iv. Circulatory disturbances
 - a. Varicoceles
 - b. Retrobulbar hemorrhage
 - i. Trauma
 - ii. Hemophilia
 - c. Aneurysms
- v. Cysts
 - a. Dermoid cyst
 - b. Parasitic cyst
 - c. Implantation cyst
 - d. Cyst of optic nerve
 - e. Cyst of lacrimal gland
 - f. Congenital cystic eyeball
- vi. Tumors
 - a. Primary orbital tumors
 - b. Lacrimal gland tumors
 - c. Optic nerve tumors
 - d. Secondaries
- vii. Traumatic
 - a. Retrobulbar hemorrhage
 - b. Retained intraocular foreign body
 - c. Emphysema
- viii. Associated with general disorders
 - a. Lymphatic deposits in leukemia
 - b. Lipogranulomatous deposits as in histiocytosis
 - c. Localized amyloidosis.

11. What do you mean by orbitometry or piezometry?

Assessment of compressibility of orbital contents or the 'tension of orbit' is called piezometry.

- i. It is of diagnostic value
- ii. It gives idea of effectivity of treatment. For example, orbitometer of Cooper.

12. What are the different types of exophthalmometry?

They are:

- i. Clinical exophthalmometry
- ii. Stereo photographic method of exophthalmometry
- iii. Radiographic exophthalmometry.

Clinical methods are:

- I. Zehender's exophthalmometer
- II. Gormaz exophthalmometer
- III. Luedde exophthalmometer (used in children)

- IV. Hertel's exophthalmometer (used for axial proptosis)
- V. Davenger's exophthalmometer
- VI. Watson's ocular topometer (in eccentric proptosis)
- VII. Measurement of displacement of globe with perspex ruler.

13. What are the causes of bilateral proptosis?

- A. Thyroid orbitopathy
- B. Developmental anomalies of the skull
 - a. craniofacial dysostosis
 - b. generalized osteodysplasia
- C. Osteopathies
 - a. infantile cortical hyperostosis
 - b. fibrous dysplasia
 - c. osteoporosis
 - d. rickets
 - e. acromegaly
- D. Encephalocele in the ethmoidal region
- E. Edema
 - a. angioneurotic edema
 - b. cavernous sinus thrombosis
- F. Neoplasms
 - a. symmetric lymphoma
 - b. choromas
 - c. malignancy of nasopharynx
 - d. metastatic neuroblastoma

14. What is the most common cause unilateral proptosis in adults?

Thyroid orbitopathy.

15. What is the most common cause of bilateral proptosis in adults?

Thyroid orbitopathy.

16. What is the most common cause of unilateral proptosis in children?

Orbital cellulitis.

17. What do you mean by pseudoproptosis?

It is the clinical appearance of proptosis where in no real forward displacement of the globe takes place.

18. What are the causes of pseudoproptosis?

It can be classified as:

A. When globe is enlarged

- a. Congenital buphthalmos/congenital cystic eye ball
- b. High axial myopia
- c. Staphyloma
- d. Unilateral secondary glaucoma in childhood

B. Retracting lids

- a. Microblepharon
- b. Dermatitis or ichthyosis or from scarring
- c. Sympathetic overaction such as Graves' disease or Parkinson's disease

C. Lower lid sagging

- a. Facial palsy
- b. Retraction of inferior rectus
- c. Following recession of inferior oblique

D. Deformation of orbit or facial asymmetry

- a. Asymmetry of bony orbit
- b. Progressive facial hemiatrophy (Parry-Romberg's syndrome)
- c. Harlequin orbit
- d. Hypoplastic supraorbital ridges as in trisomy 18
- e. Shallow orbit as in Crouzon's disease (craniofacial dysostosis)

F. Opposite eye enophthalmos.**19. What are the causes of enophthalmos?**

Causes of enophthalmos are:

- i. Microphthalmos
- ii. Phthisis bulbi
- iii. Blowout fracture
- iv. Subluxation of the globe
- v. Age-related absorption of the fat

20. Classify proptosis.

Proptosis can be classified based on different criteria:

1. Unilateral or bilateral
2. Axial or eccentric
3. Acute, chronic, recurrent, intermittent
4. Pulsatile or nonpulsatile.

21. What do you mean by axial proptosis?

Axial proptosis is caused by any space occupying lesion in the muscle cone or any diffuse orbital inflammatory or neoplastic lesions. For example, optic nerve glioma, cavernous hemangioma, meningioma, Schwannoma, metastatic tumors from CA—breast, lung or prostate.

22. What do you mean by eccentric proptosis?

Proptosis caused by any extraconal lesion or fracture displacement of orbital bones protruding inwardly.

23. Give a few causes of non-axial proptosis.**A. Lateral displacement of globe/down & out:**

- a. Ethmoidal mucocele
- b. Frontal mucocele
- c. Lacrimal sac tumors

- d. Nasopharyngeal tumors
- e. Rhabdomyosarcoma

B. Down & in:

- a. Lacrimal gland tumors
- b. Sphenoid wing meningoma

C. Upwards:

- a. Tumors of floor of orbit
- b. Maxillary tumors
- c. Lymphoma
- d. Lacrimal sac tumors

D. Downwards:

- a. Fibrous dysplasia
- b. Fibrous mucocele
- c. Lymphoma
- d. Neuroblastoma
- e. Neurofibroma
- f. Schwannoma
- g. Subperiosteal hematoma

24. What are the important causes of proptosis in the following age group?

It can be divided into following categories:

a. **Newborn**

- i. Orbital sepsis
- ii. Orbital neoplasm

b. **Neonates**

Osteomyelitis of maxilla

c. **Infants**

- i. Dermoid cyst
- ii. Dermolipoma
- iii. Hemangioma
- iv. Histiocytosis X
- v. Orbital extension of retinoblastoma

d. **Children**

- i. Dermoid cyst
- ii. Teratoma
- iii. Capillary hemangioma
- iv. Lymphangioma
- v. Orbital nerve glioma
- vi. Plexiform neurofibroma
- vii. Rhabdomyosarcoma
- viii. Acute myeloid leukemia
- ix. Histiocytosis
- x. Neuroblastoma
- xi. Wilms' tumor
- xii. Ewing's tumor

e. **Adults**

- i. Thyroid orbitopathy
- ii. Cavernous hemangioma
- iii. Orbital varices
- iv. Optic nerve meningoma
- v. Schwannoma
- vi. Fibrous histiocytoma
- vii. Lymphoma
- viii. Secondaries from breast, lung, prostate carcinoma.

25. What is proptometry?

It is the measurement of the distance between apex of the cornea and the bony point usually taken as deepest portion of the lateral orbital rim with the eye looking in primary gaze.

26. Which instruments are used for measuring eccentric proptosis?

- i. Topometer of Watson
- ii. Persplex ruler
- iii. Luedde exophthalmometer

27. What are the types of exophthalmometry?

Types of exophthalmometry are:

- i. Absolute exophthalmometry: The amount of proptosis is compared with a known normal value.
- ii. Comparative exophthalmometry: The reading is compared from time to time in the same eye.
- iii. Relative exophthalmometry: The reading is compared between two eyes.

28. Which age group is commonly affected and what is the sex preponderance in TRO?

- i. Average age of onset is in 40s
- ii. Females are 3–6 times more affected than males

29. What refractive errors are associated with TRO?

- i. Astigmatism due to lid retraction
- ii. Induced hyperopia as a result of flattening of posterior pole due to retrobulbar mass.

30. What is the reason of dilated vessels over muscles?

With increasing inflammation of muscles, the anterior radials of the muscular vessels become engorged, producing characteristic dilated and visible vessels subconjunctivally over the insertions.

31. What is the sequence of muscle involvement in TRO?

- i. Inferior rectus
- ii. Medial rectus

- iii. Superior rectus
- iv. Lateral rectus

32. Why inferior rectus is most commonly involved in TRO?

- i. Inferior rectus involvement occurs due to well developed connective tissue system around inferior oblique and inferior rectus muscles, which also have good septal connections with adjacent periorbita.
- ii. Also inferior rectus contains high concentration of macrophages (CD4+ memory T cells, CD8 T cells) which may account for disease activity in muscles.

33. What are the reasons for restricted ocular movements in TRO?

It can be divided into causes due to:

- i. Edematous muscle—this occurs in active stage caused by imbibitions of fluid into the muscle belly, which causes increase in size of the muscle. This causes restriction of contraction of the muscle.
- ii. Fibrosed muscle—this occurs following chronic disease.
- iii. Fibrosis causes contracture and restriction of the muscle movements.

34. What are systemic associations of TRO?

Autoimmune or immunoregulatory diseases

- i. Myasthenia gravis
- ii. Pernicious anemia
- iii. Vitiligo

35. What is Braley's test?

- i. Also known as differential tonometry or positional tonometry
- ii. It refers to an increase in IOP measured during upgaze
- iii. An increase in IOP of more than 6 mm Hg is significant
- iv. Normal—2 mm Hg
- v. Increase in IOP more than 9–10 mm Hg suggests optic neuropathy.

36. What is the reason of increase in IOP in TRO?

- i. Enlargement of recti interferes with uveoscleral drainage in various positions of gaze.
- ii. Increased tension due to resistance of inferior rectus opposing supraduction, provoking compression of eye and elevation in IOP in upgaze.

37. What are the causes of increase in IOP in upgaze?

- i. TRO
- ii. Fractures
- iii. Myositis
- iv. Irradiation
- v. Orbital metastasis.

38. Are all patients with TRO hyperthyroid?

Approximately 80% of the patients with TRO are hyperthyroid at the time of diagnosis or develop hyperthyroid status within 6 months of the disease. 10% are hypothyroid and the rest 10% are euthyroid.

39. What is the most significant environmental factor causing TRO?

Smoking:

Smokers with TRO have more severe disease than non smokers.

40. What are the causes of upper lid retraction in TRO?

The causes of upper lid retraction in TRO are:

- I. Fibrotic contracture of the levator associated with adhesion with overlying orbital tissue.
- II. Sympathetic overstimulation of Muller's muscle.
- III. Secondary overaction of levator superior rectus complex in response to hypophoria produced by fibrosis of inferior rectus muscle.

41. What are the causes of lower lid retraction?

Fibrosis of the inferior lid retractors (capsulopalpebral head).

42. How do you grade lid retraction?

- I. Mild—intersection of lid at superior limbus, 1–2 mm of superior sclera show, MRD 1: 6 mm
- II. Moderate—2–4 mm of superior sclera show, MRD 1: 6–10 mm
- III. Severe—> 4 mm of superior sclera show, MRD 1: >10 mm

43. What is the importance of measuring lid retraction?

If surgical correction is mandatory for lid retraction, size of spacer graft depends on amount of lid retraction.

1 mm of lid retraction = 3 mm of spacer graft.

44. When does one get ptosis instead of lid retraction in TRO?

- i. When there is apical compression and congestion of orbit as in tight orbit syndrome
- ii. Severe proptosis may cause disinsertion of aponeurosis of elevators of lids leading to ptosis
- iii. Ptosis may be associated with myasthenia gravis.

45. What are the causes of vision loss in TRO?

- i. Exposure keratopathy
- ii. Diplopia due to involvement of extraocular muscles
- iii. Optic nerve traction
- iv. Optic nerve compression (by enlarged EOM)
- v. Macular edema
- vi. Macular scar
- vii. Glaucomatous optic neuropathy (systemic steroid induced).
- viii. Posterior subcapsular cataract secondary to steroids used in the treatment of TRO.

46. Where is the site of compression of optic nerve by enlarged extraocular muscles?

Orbital apex caused by the crowding of the enlarged muscles.

47. What is the earliest and most sensitive indicator of optic nerve damage and why?

- i. Color vision: pseudoisochromatic plates and Farnsworth Munsell Hue test.
- ii. Color vision is affected earlier because axons that precede macula are most sensitive to damage.
- iii. Pattern reversal visual evoked potential: also sensitive for detecting early damage

48. What are the visual field defects seen in optic neuropathy due to TRO?

- i. Central scotoma
- ii. Inferior altitudinal defect.

Less commonly

- i. Enlarged blind spot
- ii. Paracentral scotoma
- iii. Nerve fiber bundle defect
- iv. Generalized constriction

49. What are the causes of exposure keratopathy in TRO?

- i. Severe proptosis preventing mechanical closure of eyelids.
- ii. Retraction of the upper and lower eyelids.
- iii. Decreased secretion of tears due to primary lacrimal gland dysfunction.

50. What are Sallmann's folds?

These are choroidal folds seen in macula in case of retrobulbar mass. Seen in TRO.

Other conditions where choroidal folds may be seen are:

- i. Idiopathic
- ii. Retrobulbar tumors
- iii. Choroidal melanomas
- iv. Ocular hypotony
- v. Posterior scleritis
- vi. Post scleral buckling

51. What are racoon eyes? Where it is seen in context of orbit?

Dark purple discoloration/periorbital ecchymoses giving an appearance similar to that of a racoon/panda.

Otherwise seen in following conditions:

- Bilateral proptosis due to metastatic neuroblastoma.
- Fracture of base of skull.

Amyloidosis.
Kaposi's sarcoma.
Multiple myeloma.

52. What do you mean by temporal flare in a patient with TRO?

The upper eyelid retraction in Graves' disease has a characteristic temporal flare, with a greater amount of sclera visible laterally as compared with medially.

53. What is the cause of temporal flare in TRO?

The results of inflammation, resultant adhesions and fibrosis clearly affect the lateral horn of the levator aponeurosis.

- i. The lateral horn of the levator aponeurosis is much stronger than the medial horn, and its insertion through the lateral orbital retinaculum at the lateral orbital tubercle is much more defined than its medial insertion. The lateral fibers of the muscular portion of the levator muscle, proximal to Whitnall's ligament, blend with the superior transverse ligament as it courses to the lateral orbital attachment, exerting a strong pull on the lateral aspect of the eyelid through the aponeurosis, the suspensory ligament of the fornix and the conjunctiva.
- ii. Müller's muscle, an involuntary muscle, may develop over reaction or be enlarged secondary to a direct inflammatory infiltrate in thyroid-related orbitopathy. An involved Müller's muscle, with its substantial lateral extensions, contributes to and may cause more temporal flare than in those patients with thyroid-related orbitopathy but without this muscle involvement.

54. Which is the most common extraocular muscle involved in TRO and why?

Inferior rectus (Second most common muscle involved is medial rectus). Inferior rectus involvement occurs due to well developed connective tissue system around it and also because it has the greatest number of septal connections with adjacent periorbita.

55. Mention a few conditions which are associated with extraocular muscle enlargement.

It can be classified as:

A. Inflammatory:

- i. Graves' orbitopathy
- ii. Myositis
- iii. Orbital cellulitis
- iv. Sarcoidosis
- v. Vasculitides

B. Neoplastic:

- i. Rhabdomyosarcoma
- ii. Metastasis
- iii. Lymphoid tumors

C. Vascular:

- i. Carotid-cavernous fistula
- ii. A-V malformation
- iii. Lymphoid tumors

D. Miscellaneous:

- i. Acromegaly
- ii. Amyloidosis
- iii. POEMS syndrome
- iv. Trichinosis
- v. Lithium therapy

56. What is differential tonometry?

It refers to an increase in the intraocular pressure measured during upgaze. This is caused by the compression of the globe by fibrosed inferior rectus. An increase in IOP of >6 mm of Hg is significant.

57. What is the significance of retinoscopy in a case of proptosis?

- i. To identify any high axial myopia which manifests as pseudoproptosis.
- ii. Axial length may be decreased in a case of retrobulbar mass causing hyperopic shift due to compression of the posterior pole.

58. What is the difference between von Graefe's sign and pseudo von Graefe's sign?

von Graefe's sign: It is seen in thyroid orbitopathy due to retarded descent of the globe on downgaze.

Pseudo von Graefe's sign: It is seen in III cranial nerve palsy with aberrant regeneration of the nerve where there is lid retraction on attempted downgaze.

59. What is the cause of increase in the volume of extraocular muscles?

In a patient with TRO there is a 100 fold increase in the synthesis of GAGs (glycosaminoglycans) by the pre-adipocyte fibroblasts, which causes imbibition of water into the muscles causing the thickness to increase.

60. What is the type of hypersensitivity reaction in thyroid orbitopathy?

Type V hypersensitivity reaction.

61. What is the significance of ultrasonography in a patient with suspected TRO?

It can detect early thyroid disease in a case with unequivocal laboratory tests.

- I. It helps to differentiate TRO from pseudotumor.
- II. It can predict whether the disease is active or inactive. The amount of internal reflectivity is less in a patient with active disease.

62. What is the frequency of orbital ultrasound?

8–15 MHz.

63. How do you differentiate between enlarged muscles in myositis from that of TRO on USG?

In myositis there is a typical enlargement of the tendinous insertion of the muscles whereas in TRO there is a fusiform enlargement of the muscle belly.

64. How do you clinically differentiate active and an inactive disease?

	Active disease	Inactive disease
Accompanying signs of inflammation like chemosis and congestion	More	Less (usually eye will be quiet)
Amount of proptosis	Severe	Less
Restriction of extraocular movements	1 or 2 gazes	May be in all gazes

Inflammatory score (Activity of the disease)		
1.	ORBITAL PAIN	
	No pain	0
	At gaze	1
	At rest	2
2.	CHEMOSIS	
	Not beyond gray line	1
	Beyond gray line	2
3.	EYELID EDEMA	
	Present but no overhanging of tissues	1
	Roll in eyelid skin like festoons	2
4.	CONJUNCTIVAL INJECTION	
	Absent	1
	Present	2
5.	EYELID INJECTION	
	Absent	1
	Present	2
	Total	0-8

If the score is < 3/8 and there is no deterioration then management is conservative with cool compresses, head elevation and NSAIDs.

If the score is > 4/8 or if there is evidence of progression then the management is oral or IV steroids, radiotherapy or immunosuppressive agents.

65. What do you mean by VISA?

It is a new classification of TRO which helps in grading and planning management at all the levels of TRO, where VISA stands for:

V: Vision

I: Inflammation

S: Strabismus

A: Appearance

66. What is the best investigation for early diagnosis of compressive optic neuropathy in Graves' disease?

MRI.

67. What are the indications of orbital imaging in a patient with TRO?

- I. Suspicion of optic nerve compression
- II. Evaluation before orbital decompression surgery
- III. Orbital irradiation
- IV. To rule out pseudotumor.

68. What is the significance of CT scanning in a patient of TRO?

- I. CT scan allows reliable identification of even minimally enlarged recti muscles.
- II. In patients with unilateral proptosis, it can detect subclinical enlargement of extraocular muscles EOM in contralateral eye.
- III. Can detect patients with risk of developing optic neuropathy as depicted by
 - a. Severe apical crowding
 - b. Dilated superior ophthalmic vein.

69. What are the characteristic findings of CT scan in TRO?

Fusiform enlargement of extraocular muscles which is usually bilateral and symmetric with sharply defined borders and sparing the tendinous insertions.

70. What is the best cross-sectional view in CT scan to visualize enlarged muscle?

Coronal section.

71. What are the indications of orbital decompression surgery?

- I. Compressive optic neuropathy
- II. Exposure keratopathy
- III. Cosmetically unacceptable proptosis.

72. What is the most common site of orbital wall decompression?

Deep lateral wall.

73. What are principles/goal of orbital decompression?

- i. Expanding orbital volume (bony expansion)
- ii. Reducing orbital soft tissue (fat decompression).

74. What is approach for orbital decompression?

- i. For exophthalmometry < 22 mm
Lateral wall + fat decompression

- ii. For exophthalmometry—22–25 mm
Lateral wall + fat + medial wall decompression
- iii. For exophthalmometry > 25 mm
Lateral wall + fat + medial wall decompression + posterior orbital floor decompression + lateral rim advancement.

75. What are the complications of orbital decompression?

Most common is worsening of diplopia or new double vision.
Infraorbital hyperesthesia.
Risk of visual loss.
Bleeding and infection.

76. What are the indications of extraocular muscle surgery and which surgery is preferred for the same?

- i. Diplopia in primary gaze
- ii. Quiescent disease and stable angle of deviation for a minimum of 6 months.
The preferred surgery to correct diplopia is recession of inferior oblique muscle with adjustable sutures.

77. How long will you wait for strabismus surgery in TRO and why?

We wait for 6 months as diplopia tends to get resolved with prisms and/or systemic corticosteroids in the acute phase. Also TRO tend to be progressive, and hence we wait for 6 months so that strabismus measurement stabilizes.

78. How does strabismus surgery affect eyelid retraction?

Recession of tight inferior rectus often improves upper eyelid retraction. Superior rectus had to work against tight inferior rectus, thus associated levator muscles was overactive, causing eyelid retraction. When inferior rectus is recessed, overactivity ends.

79. What should be the sequence of surgery in patients with thyroid orbitopathy?

The evaluation and treatment of thyroid-related orbitopathy may require one or multiple stages of surgery, depending on the severity and manifestation of the disease process. Each stage will affect the decision making for subsequent stages, and therefore the surgery should be staged in a specific sequence, with orbital decompression, then strabismus surgery if indicated, and finally eyelid repositioning and removal of excess fat and skin.

Any of the stages may be skipped when deemed unnecessary or not indicated, but maintaining the correct order reduces the number of procedures to a minimum.

Orbital decompression can result in a change in the extraocular muscle position and function relative to the globe, displacement of the muscle cone, and alteration of the muscle pulley system, which may result in postoperative phorias or diplopia.

Recession or resection of the vertical extraocular muscles for the correction of hypertrophies, especially large deviations, may increase the retraction of the eyelids secondary to alterations of the anatomical connectivity between the retractor complex and the vertical extraocular muscles. This is avoidable by careful and meticulous dissection of the extraocular muscles. Orbital decompression can also change the position of the eyelids.

80. Differentiate between orbital pseudotumor and graves orbitopathy.

	Idiopathic pseudotumor	Graves orbitopathy
Sex – F:M ratio	Equal	3:1
Mode of onset	Acute, subacute or chronic	Chronic
Pain	Often present. May be severe	Painless (unless keratitis or orbital congestion present)
Laterality	Usually unilateral	Usually bilateral
Lid signs	Lid edema, lid erythema, ptosis	Lid and periorbital edema, lid retraction, lid lag and lagophthalmos
Systemic symptoms	Malaise	Generally well. Associated symptoms of thyroid disease
Laboratory findings	Elevated ESR	Abnormal thyroid functions
Radiography	<ul style="list-style-type: none"> • Infiltrate or a mass • Uveoscleral enhancement • Extraocular muscle enlargement including tendon 	<ul style="list-style-type: none"> • Spindle shaped extraocular muscle enlargement • Sparing tendon • Inferior and medial recti most commonly involved
Ultrasonography	<ul style="list-style-type: none"> • Uveoscleral thickening • Sub tenons effusion 	<ul style="list-style-type: none"> • Extraocular muscle enlargement detected before CT scan

81. Which neuroimaging test is best to evaluate the etiology of proptosis?

CT scan is superior in most cases.

MRI may be desirable in certain cases when optic nerve dysfunction is present.

82. What are the indications for CT scan in proptosis?

- i. Acute proptosis
- ii. Progressive proptosis
- iii. When there is RAPD
- iv. Orbital fracture
- v. Orbital foreign body

83. What is Coca-Cola sign?

It is CT scan finding seen in coronal section where there is bilateral bowing of lamina papyracea/medial wall of the orbit due to bilateral medial rectus enlargement in TRO.

84. What are the indications of biopsy in proptosis?

- i. Pseudotumor refractory to medical treatment.
- ii. Suspected lymphoma or other malignancies

85. How is orbital bruit best examined?

Place the stethoscope bell over the closed eyelids and ask the patient to gently open the eye lids.

86. What are the bones comprising the walls of the orbit?**I. Medial wall (weakest wall)**

(from front to back)

- i. Frontal process of maxilla
- ii. Lacrimal bone
- iii. Orbital plate of ethmoid
- iv. Body of sphenoid

II. Inferior wall

- i. Orbital surface of maxilla (medially)
- ii. Orbital surface of zygomatic (laterally)
- iii. Palatine bone (posteriorly)

III. Lateral wall (strongest wall)

- i. Zygomatic bone (anteriorly)
- ii. Greater wing of sphenoid (posteriorly)

IV. Roof

- i. Orbital plate of frontal bone (anteriorly)
- ii. Lesser wing of sphenoid (posteriorly)

87. What are the approaches to the orbital surgery?

Surgical approaches can be

- i. Superior orbitotomy
- ii. Medial orbitotomy
- iii. Lateral orbitotomy
- iv. Inferior orbitotomy
- v. Transcranial approach
- vi. Transnasal endoscopic approach
- vii. Transantral approach

Anterior can also be divided as:

A. Inferior orbitotomy

- i. Extraperiosteal approach—subciliary incision
- ii. Conjunctival incision in inferior fornix for orbital floor fracture repair

B. Superior orbitotomy

- i. Coronal approach
- ii. Conjunctival incision
- iii. Subbrow incision
- iv. Eyelid crease incision

C. Anterior orbitotomy—Superomedial lesion—lid split incision**D. Medial orbitotomy**

- i. Inferomedial lesion—DCR like incision
- ii. Medial orbitotomy—Conjunctival approach for central and peripheral space
- iii. Endoscopic approach
- iv. Lateral orbitotomy
- v. Transfrontal orbitotomy

88. What is lateral orbitotomy?

Lateral approach is used for deeper orbital lesions that cannot be reached through an anterior incision. The type of skin incisions include:

- i. S-shaped (Stallard-Wright)
- ii. Horizontal canthal crease
- iii. Eyelid crease incision.

The skin is cut with a scalpel blade, and dissection is extended through orbicularis muscle



Periosteum is cut elevated from the lateral orbital wall till zygomatic bone and greater wing of sphenoid is exposed



The bone is cut with oscillating saw or small holes can be drilled, and the bone is fractured out.



Thin bone of greater wing of sphenoid is removed to provide adequate retrobulbar exposure



Periorbita is opened with scissors by making a cut just inferior to lateral rectus muscle.



The orbital fat dissected, the lesion identified and dissected out, hemostasis achieved



Periorbita closed with interrupted 6-0 vicryl, lateral orbital rim replaced, sutured with 4-0 prolene



Periosteum closed with 4-0 vicryl, orbicularis with 6-0 chromic catgut and the skin with 6-0 nylon or silk vertical mattress sutures.

89. What are the surgical spaces of the orbit?

These spaces include:

- i. Central surgical space (intraconal space)
- ii. Peripheral surgical space (extraconal space)
- iii. Subperiosteal space
- iv. Preaponeurotic space
- v. Tenon's space
- vi. Periorbital tissues

90. What are the TRO signs?

The signs of TRO were given by Werner's classification and grading of thyroid orbitopathy.

Class	Grade	Mnemonic	Suggestions for grading
0		N	No physical signs or symptoms
1		O	Signs only
2		S	Soft tissue involvement
	0		Absent
	A		Minimal
	B		Moderate
	C		Marked
3		P	Proptosis of 3 mm or more
	0		Absent
	A		3–4 mm
	B		5–7 mm
	C		8 mm or more
4		E	Extraocular muscle involvement
	0		Absent
	A		Limitation of motion at extremes of gaze
	B		Evident restriction of motion
	C		Fixation of globe
5		C	Corneal involvement
	0		Absent
	A		Punctate lesions
	B		Ulceration
	C		Necrosis or perforation
6		S	Sight loss (due to optic nerve)
	0		Absent
	A		20/20–20/60
	B		20/70–20/200
	C		Worse than 20/200

91. What are the differences between optic nerve glioma and optic nerve sheath meningioma?

Optic nerve glioma	Optic nerve sheath meningioma
<ol style="list-style-type: none"> 1. Age: children and young girls 2. Arise from astrocytes of the optic nerve 3. Visual loss followed by proptosis 4. CT: fusiform enlargement of optic nerve 5. X-ray shows regular enlargement of optic foramen 	<ol style="list-style-type: none"> 1. Middle aged adults, mostly women 2. Arise from meningoendothelial cells of arachnoid villi 3. Proptosis presents first followed by visual loss 4. Tubular thickening of optic nerve ("Tram-tracking") 5. Irregular enlargement

8.7. BLOWOUT FRACTURES OF THE ORBIT

1. Who were the first to describe orbital blowout fractures?

Smith and Regan in 1957.

2. What is the mechanism of a blowout fracture?

A blowout fracture of the orbital floor is typically caused by a sudden increase in the orbital pressure by an impacting object which is greater in diameter than the orbital aperture (about 5 cm), such as a fist or tennis ball so that the eyeball itself is displaced and transmits rather than absorbs the impact. Since the bones of the lateral wall and the roof are usually able to withstand such trauma, the fracture most frequently involves the floor of the orbit along the thin bone covering the infraorbital canal.

3. What are the theories explaining the mechanism of the blowout fracture?

Two theories have been proposed to explain the mechanism of the blowout fracture:

- i. Hydraulic theory
- ii. Buckling theory

4. What is the hydraulic theory?

In hydraulic theory the external injury is supposed to cause an increase in the intraorbital pressure which causes the thin orbital floor medial to the infraorbital groove and the medial wall to give way and help in absorbing the impact of the injury and thereby protect the globe from injury.

5. What is the buckling theory?

In the buckling theory the stress of the initial injury is transmitted directly from the orbital rim to the orbital floor and results in the fracture.

6. How are blowout fractures classified?

The blowout fractures is classified into two types:

- A. Pure blowout fracture
- B. Impure or complex blowout fracture
 - i. A **pure blowout** fracture is fracture of the orbital wall without involvement of the orbital rim.
 - ii. **Impure blowout** fracture is a variety in which the orbital rim and the adjacent facial bones are involved.

7. How are pure blowout fractures classified?

- i. Trapdoor refers to cases in which either edge of the inferior orbital wall is attached to its original position.
- ii. Nontrapdoor refers to cases in which the inferior orbital wall is completely separated from its original position and the periorbital tissue has escaped into the maxillary sinus.

8. What are the clinical signs seen in a patient with blowout fracture?

Eyelid signs: Ecchymosis and edema of eyelids, occasionally subcutaneous emphysema

Infraorbital nerve anesthesia involving the lower lid, cheek, side of nose, upper lip, upper teeth and gums is very common because the fracture frequently involves the infraorbital canal.

Diplopia with limitation of upgaze, downgaze or both:

Diplopia may be caused by one of the following mechanisms:

- i. Hemorrhage and edema in the orbit may cause the septa connecting the inferior rectus and inferior oblique muscles to the periorbita to become taut and thus restrict movement of the globe. Ocular motility usually improves as the hemorrhage and edema resolve.
- ii. Mechanical entrapment within the fracture of the inferior rectus or inferior oblique muscle, or adjacent connective tissue and fat. Diplopia typically occurs in both upgaze and downgaze (double diplopia).
- iii. In these cases forced duction and the differential intraocular pressure tests are positive. Diplopia may subsequently improve if it is mainly due to entrapment of connective tissue and fat, but usually persists if there is significant involvement of the muscles themselves.
- iv. Direct injury to an extraocular muscle is associated with a negative forced duction test. The muscle fibers usually regenerate and normal function returns within about 2 months.

Enophthalmos may be present if the fracture is severe, although it tends to manifest only after a few days as the initial edema resolves. In the absence of surgical intervention, enophthalmos may continue to increase for about 6 months as post-traumatic orbital degeneration and fibrosis develop.

9. What is 'white eyed blowout fracture'?

It is a well described entity especially in the pediatric group which presents with signs of entrapment of the extra ocular muscles with a relatively white eye which reveals minimal signs of inflammation. These patients can also have symptoms suggestive of oculocardiac reflex with resultant bradycardia and nausea.

10. What are the causes of vision loss following a blowout fracture?

In patients with orbital floor fractures, vision loss can result from injury to the optic nerve or increased orbital pressure causing a compartment syndrome.

11. What is the initial management of blowout fractures?

The majority of blowout fractures do not require surgical intervention. Initial treatment is conservative with antibiotics; ice packs and nasal decongestants may be helpful. The patient should be instructed not to

blow the nose, because of the possibility of forcing infected sinus contents into the orbit. Systemic steroids are occasionally required for severe orbital edema, particularly if this is compromising the optic nerve.

12. What are the indications of surgery in cases of blowout fracture?

- i. Diplopia with limitation of upgaze and/or downgaze within 30 degrees of the primary position with a positive traction test result 7–10 days after injury and with radiologic confirmation of a fracture of the orbital floor.
- ii. Enophthalmos that exceeds 2 mm and that is cosmetically unacceptable to the patient.
- iii. Large fractures involving at least half of the orbital floor, particularly when associated with large medial wall fractures.

13. How do we manage white eyed blowout fracture?

The 'white-eyed' fracture requires urgent repair to avoid permanent neuromuscular damage. Release of the entrapped muscle should be done to avoid restriction and fibrosis.

14. What are the preoperative investigations done?

- i. Visual acuity testing, papillary reflex
- ii. Ocular motility evaluation using Hess chart/Lees screen
- iii. Hertels exophthalmometry
- iv. Slit lamp biomicroscopy
- v. Applanation tonometry
- vi. Fundus ophthalmoscopy
- vii. Evaluation of sensitivity in the distribution of infraorbital nerve
- viii. Forced duction test (FDT)—to confirm mechanical restriction
- ix. Imaging—CT scan of the orbit (2 mm slice) in axial, coronal and sagittal planes to identify the extent of fracture.
- x. Determining the nature of maxillary antral soft tissue densities which may represent prolapsed orbital fat, extraocular muscles, hematoma or unrelated antral polyps.

CT scan is the imaging of choice in orbital fractures.

15. What are the various approaches to orbital floor during surgical management?

For orbital floor fractures, surgical procedures are routinely performed via:

- i. Transorbital approach
- ii. Transantral approach
- iii. Endoscopic endonasal approach

16. Explain about the transorbital approach.

Most anterior fractures are managed by the transorbital route which can be via:

- A. Transcutaneous incision
- B. Transconjunctival incision

- i. Inferior forniceal (to approach floor)
- ii. Transcaruncular (to approach medial wall)

17. What are the approaches to posterior and medial fractures?

The transantral approach is used to approach posteriorly placed fractures which might be difficult to approach through anterior approach.

The endoscopic approach is in managing medial wall fractures.

18. What are the steps done in surgical management of blowout fractures?

- i. Open reduction of the fracture
- ii. Release of entrapped tissues
- iii. Repositioning of the herniated orbital soft tissue within the orbit
- iv. Repair of the post traumatic defect with an orbital implant as needed.

19. Describe about the transcutaneous approach.

- i. In transcutaneous approach the skin incision is made in the lower eyelid at 3–4 mm below the subciliary fold following the natural curve of the lid.
- ii. A dissection is then carried down until the periosteum is reached at the level of the orbital rim.
- iii. The incision is then carried through the periosteum just below the orbital rim.
- iv. The reflection of the periosteum is made over the rim using a periosteal elevator until the fracture is visualized.
- v. To relieve any orbital structure entrapment and to restore the orbital contents to their original place, a forced traction of the globe is made.
- vi. The implant is then cut to the appropriate size and then placed to bridge the fracture site and is anchored anteriorly with screws in case there is no posterior support.
- vii. The periosteum is closed with 5-0 chromic catgut and the subcutaneous tissue approximated.
- viii. The 6-0 silk is used to close the skin.

20. What is the transconjunctival approach?

In transconjunctival approach the orbital rim periosteum is reached via the inferior fornix incision in case of floor fractures and transcaruncular incision for medial wall fractures.

21. What are orbital implants?

The orbital implant restores the structural integrity of the orbital wall by bridging the defect and preventing orbital contents from herniating into the adjacent periorbital sinuses. The implant also prevents extraocular motility limitations by minimizing scar tissue adhesions with orbital contents. These implants can also serve to augment the orbital volume by compressing the intraorbital contents to correct enophthalmos.

22. What are the current orbital implants?

They include:

- i. Autogenous bone grafts
- ii. Human donor grafts
- iii. Xenografts
- iv. Alloplastic implants

23. What are the properties of an ideal alloplastic implant?

The ideal alloplastic implant should be readily sizeable, sterilizeable, strong, inert, non-allergenic, durable, noncarcinogenic, easily manipulated, shaped and suitable for single stage reconstruction.

Also the implant should be accepted and well integrated into the surrounding tissues with minimal inflammatory response, foreign body reaction, or risk of infection.

The implant should provide mechanical support strong enough to hold up the orbital contents, and have the stability to be easily anchored to the surrounding bone to prevent migration and extrusion.

Finally, it should be readily available in larger quantities if necessary at reasonable cost.

24. What are the various materials used as orbital implants?

- i. Autogenous bone grafts (iliac crest/rib)
- ii. Silastic sheets
- iii. Porous polyethylene (MEDPOR)—the porous polyethylene implants are available as sheets which can be cut, channel implants which have provisions for inserting a plate which can be fixed to the orbital rim with screws and with titanium sheets (TITAN)
- iv. Titanium implant—these are available as titanium sheets which can be cut or preshaped models.

25. What are the complications of blowout fracture surgery?

- i. Decreased visual acuity
- ii. Diplopia
- iii. Undercorrection/overcorrection of enophthalmos
- iv. Lower eyelid retraction
- v. Infraorbital nerve hypoesthesia
- vi. Infection
- vii. Extrusion of implant
- viii. Chronic sinusitis
- ix. Dacryocystitis
- x. Chronic skin orbital floor fistulas/maxillary sinus orbital fistulas
- xi. Loss of lacrimal pump mechanism
- xii. Intraorbital hemorrhage

8.8. ORBITOTOMIES

1. What are the walls of the orbit?

- i. Medial Wall
- ii. Inferior wall (floor)
- iii. Lateral wall
- iv. Roof

2. What are the contents of medial wall?

It is quadrilateral in shape, and the thinnest wall of the orbit and consists of:

- i. The frontal process of maxilla
- ii. Lacrimal bone
- iii. Orbital plate of ethmoid bone
- iv. Body of sphenoid.

3. What is the most common complication in these surgeries?

Hemorrhage is the most common due to injury of ethmoid vessels, medial-palpebral, frontal and dorsal-nasal arteries.

4. What are the contents of floor of the orbit?

It is triangular in shape; consists of

- i. Orbital surface of the maxillary bone medially
- ii. Orbital surface of the zygomatic bone laterally
- iii. Palatine bone posteriorly.

5. What are the contents passing through the infraorbital foramen?

Infraorbital nerve, artery and the vein.

6. What are the contents of the lateral wall of the orbit?

It is triangular in shape and consists of

- i. Zygomatic bone anteriorly
- ii. Greater wing of sphenoid posteriorly.
Posterior part of the wall there is a small projection called spina recti lateralis, which gives origin to a part of lateral rectus muscle.

7. What is the importance of the lateral wall?

- i. It protects the posterior part of the eyeball.
- ii. Palpation of retro-orbital tumors is easier.
- iii. Lateral orbital surgeries are more popular.
- iv. It is devoid of foramina, so hemorrhage is less.
- v. It is the strongest portion of orbit.
- vi. Once sawed open has direct access to superolateral, inferolateral and retrobulbar contents.

8. What are the contents of the roof?

It is triangular and consists of:

Orbital plate of frontal bone,
behind this is lesser wing of sphenoid.

The anterolateral part has a depression called fossa for lacrimal gland.

9. What are the surgical approaches?

- i. Superior approach
- ii. Inferior approach
- iii. Medial approach
- iv. Lateral approach

10. What are the incisions for the superior approach?

- i. Transcutaneous
- ii. Transconjunctival
- iii. Vertical eyelid splitting

11. How is transcutaneous incision made?

- i. Upper eyelid crease incision is made.
- ii. Access to superior orbital rim by dissecting superiorly in the postorbicularis fascial plane anterior to the orbital septum.
- iii. Incision is made in the arcus marginalis of the rim, and a periosteal elevator is then used to separate the periosteum from the frontal bone of the orbital roof.
- iv. The periorbita is kept intact to prevent orbital fat from obscuring the vision.

12. How is transconjunctival incision made?

Incision in the superior conjunctiva can be used to reach the superonasal, episcleral, intra-or extra-conal spaces; but dissection must be performed medial to the levator muscle to prevent postoperative ptosis.

13. How is vertical eyelid splitting made?

Incise the eyelid and levator aponeurosis vertically to expose the superomedial intraconal spaces.

It allows extended transconjunctival exposure for the removal of superomedial intraconal tumors.

14. What are the types of inferior approach and how are they made?

It is suitable for masses that are visible or palpable in the inferior conjunctival fornix of the lower eyelid, as well for deeper inferior extraconal masses.

Transcutaneous incisions

- i. Infraciliary blepharoplasty incision is made in the lower eyelid and dissection beneath the orbicularis muscle to expose the inferior orbital septum and inferior orbital rim.
- ii. For access to the inferior subperiosteal space, an extended subciliary incision or an incision in the lower eyelid crease with downward reflection of the skin and orbicularis muscle allows exposure of the rim.

Transconjunctival incision

- i. To reach the extraconal surgical space and the orbital floor, incision is made through the inferior conjunctiva and the lower eyelid retractors.
- ii. Exposure to the globe is optimized when this incision is combined with a lateral canthotomy and cantholysis.
- iii. The intra conal-space may be reached by opening the reflected periosteum and the retracting the muscle and intraconal fat.

15. What are the types of medial approach and how are they made?

While dissecting the medial orbit care should be taken to avoid damaging,

- i. Medial canthal tendon
- ii. Lacrimal canaliculi and sac
- iii. Trochlea
- iv. Superior oblique tendon
- v. Inferior oblique muscle
- vi. Sensory nerves and vessels

Types of incision

Transcutaneous incisions (Lynch or frontoethmoidal incision)

- i. Tumors within or near the lacrimal sac, the frontal or ethmoidal sinus, and the medial rectus muscle can be approached.
- ii. Skin incision is placed vertically just medial to the incision of the medial canthal tendon.
- iii. Mainly used to enter the subperiosteal space.

Transconjunctival incision

- i. An incision in the bulbar conjunctiva allows entry into the extraconal or episcleral surgical space.
- ii. If the medial rectus is detached, one can enter the intraconal surgical space to expose the region of the anterior optic nerve for examination biopsy or sheath fenestration.
- iii. If the posterior optic nerve or muscle cone needs to be seen, combined lateral/medial orbitotomies can be performed.
- iv. Lateral orbitotomy with removal of lateral orbital wall displaces the globe temporally, maximizing medial access to deeper orbit.

Transcaruncular incision

- a. An incision through the posterior third of the caruncle or the conjunctiva immediately lateral to it allows excellent exposure of the medial periosteum.
- b. Medial dissection just posterior to the lacrimal sac allows access to the subperiosteal space along the medial orbital wall.
- c. Incision and elevation of the medial periorbita has advantage of providing better cosmetic results than the traditional Lynch incision.
- d. The combination of transcaruncular route with an inferior transconjunctival incision allows extensive exposure of the inferior and medial orbit.
- e. This approach provides access for repair of medial wall fractures, for medial orbital bone decompression, for drainage of medial subperiosteal abscess.

16. How is the lateral approach done?

- i. It is used when a lesion is located within the lateral intraconal space, behind the equator of the globe or in the lacrimal gland fossa.
- ii. The traditional 'S' shaped Stallard-Wright skin incision extending from beneath the eyebrow laterally and curving down along the zygomatic arch allows good exposure of the lateral rim.
- iii. It has been replaced by upper eyelid crease incision or lateral canthotomy incision.
- iv. Dissecting through the periorbita and then the intermuscular septum, either above or below the lateral rectus and posterior to equator provides access to retrobulbar space.
- v. If the lesion is too big, the bone of the lateral rim is removed.
- vi. Tumors can be prolapsed by application of gentle pressure of the eyelid.

17. What are the complications?

- i. Hemorrhage
- ii. Optic nerve injury
- iii. Damage to vessels and nerves
- iv. Damage to muscles and tendons
- v. Injury to lacrimal gland

8.9. BOTULINUM TOXIN

1. What is botulinum toxin (Botox) ?

Botulinum toxin is a protein produced by the bacterium *Clostridium botulinum*, and is considered the most powerful neurotoxin.

2. When was it discovered and by whom?

The German physician and poet **Justinus Kerner (1786-1862)** first developed the idea of a possible therapeutic use of botulinum toxin, which he called “**sausage poison.**”

3. What is the mechanism of action of Botox?

Botulinum toxin acts by binding presynaptically to high-affinity recognition sites on the cholinergic nerve terminals and decreasing the release of acetylcholine, causing a neuromuscular blocking effect.

4. What is the structure of Botox?

- i. They are proteins that are produced by several different clostridial bacterial species and are related to tetanus toxin.
- ii. The neurotoxin proteins are synthesized along with hemagglutinin and non-toxin hemagglutinin proteins that together form a protein complex progenitor toxin.

5. What is the concern with the use of Botox?

The formation of blocking antibodies leading to non-response of subsequent botox injections, called as “**secondary non-responders.**”

6. What are the preparations used?

- i. Botox (Allergan Irvine, USA)
- ii. Dysport (Ipsen, France)
- iii. Myobloc (Elan Pharma, USA)

7. Contents of 1 vial.

Each vial contains 100 Units (U) of *C. botulinum* neurotoxin complex,

- i. 0.5 mg human albumin,
- ii. 0.9 mg sodium chloride.

All these in sterile vacuum dried solid without preservatives.

8. Botulinum toxin concentration with various amount of diluents used.

Diluent added (0.9% NaCl) (ml)	Botox used (U/0.1 ml) (U)	Dysport dose (U/0.1) (U)
1	10	50
2	5	25
4	2.5	12.5
8	1.25	6.25

9. Dose recommendations for common therapeutic indications of botulinum toxin in ophthalmic plastic surgery?

Clinical condition	Approx dose of Botox required (U)
Benign essential blepharospasm	30–40
Hemifacial spasm	15–20
Chemo-tarsorrhaphy	5–10
Upper eyelid retraction	5–25
Lower eyelid senile entropion	10–20
Injection to the lacrimal gland	2.5–5

10. What are the common complications?

- i. Upper eyelid ptosis
- ii. Lagophthalmos
- iii. Entropion
- iv. Ectropion
- v. Functional epiphora due to lacrimal pump failure
- vi. Diplopia
- vii. Eyelid hematoma

8.10. DACRYOCYSTORHINOSTOMY

1. What is dacryocystorhinostomy (DCR)?

Dacryocystorhinostomy surgery consists of making a permanent opening from the lacrimal sac into the nasal space through which tears will drain freely, resulting in the relief of epiphora and discharge.

2. What are the indications for performing DCR?

- i. Primary acquired nasolacrimal duct obstruction
- ii. Secondary acquired nasolacrimal duct obstruction, e.g. postmaxillary surgery
- iii. Recurrent dacryocystitis
- iv. Chronic mucoïd reflux
- v. Painful distension of lacrimal sac.

3. What are the types of DCR?

- i. Conventional
- ii. Endonasal

4. What are the surgical steps of external DCR?

- i. General anesthesia
- ii. Skin incision 8 mm medial to medial canthus
- iii. Expose ascending process of anterior lacrimal crest and medial palpebral ligament
- iv. Dissection of lacrimal sac
- v. Exposure of nasal mucosa
- vi. Preparation of flaps of sac
- vii. Fashioning of nasal mucosa flap
- viii. Suturing of flaps using 6-0 vicryl chromic catgut
- ix. Closure

5. What are the surgical steps of endonasal DCR?

- i. Preparation and anesthesia
- ii. Identification of sac area
- iii. Creation of nasal mucosa opening and bones forming the lacrimal fossa and posterior medial wall
- iv. Stenting rhinostomy opening
- v. Postoperative care and removal of silastic lacrimal stents

6. What are the advantages and disadvantages of endoscopic surgery?

Advantages

- i. No scar
- ii. Less bleed
- iii. Less chances of injury
- iv. Less time consuming
- v. Less postoperative morbidity

Disadvantages

- i. Less success rate
- ii. Experience required is more
- iii. Expensive equipment

7. What are the complications of dacryocystorhinostomy surgery?***A. Early complications***

- i. Wound infection
- ii. Bleeding
- iii. Tube lateral displacement
- iv. Infranasal synechia
- v. Delayed healing

B. Intermediate complications

- i. Rhinostomy fibrosis
- ii. Granulomas
- iii. Corneal erosions from tube

C. Late complications

- i. Webbed facial scar
- ii. Chronic fistula
- iii. Persistent intranasal synechia

8. What is sump syndrome?

The surgical opening in the lacrimal bone is too small and too high. Thus there is a dilated lacrimal sac lateral to and below the level of inferior margin of the ostium in which the secretions collect and are unable to gain access to the ostium and thence the nasal cavity.

9. What are the bones that are broken during DCR?

- i. Lacrimal fossa
- ii. Lacrimal bone
- iii. Frontal process of maxillary bone
- iv. Part of ethmoid bone
- v. Part of the nasal bone

9

CHAPTER

Pediatric Ophthalmology and Strabismus

1. What is the visual acuity during infancy?

1 month of age	: 6/120
6 months	: 6/30
12–18 months	: 6/48–6/12
36 months	: 6/12–6/6

2. How can we estimate visual acuity by examining the fixation of a child?

- Central steady fixation : 6/9–6/6
- Central fixation but unsteady : 6/60–6/30
- Unsteady central fixation : Less than 6/60
- Gross eccentric fixation : Finger counting close to face

3. What are the drugs used in refraction for children?

- Cyclopentolate (0.5 to 2%)
- Atropine 0.5% or 1% (used three times daily for three days prior to retinoscopy to produce complete cycloplegia).

4. What is the amount to be subtracted from retinoscopy findings to take into account the working distance?

<i>Working distance</i>	<i>Diopters to be subtracted</i>
1.0	1.00
0.75	1.33
0.66	1.50

5. What are the general principles with regard to prescription of spectacles in various refractive errors?

Hypermetropia: In general hypermetropia should be corrected fully and totally.

Myopia: The weakest concave spherical lens giving good distance vision should be prescribed.

6. What are phorias and tropias?

- i. **Phoria:** A latent deviation in which fusional control is always present
- ii. **Tropia:** A manifest deviation in which fusional control is not present.

7. Why does surgery (recession or resection) performed on the inferior rectus muscle associated with alteration in the palpebral fissure width?

Recession of the inferior rectus causes widening of the palpebral fissure while resection causes narrowing. This is because the inferior rectus is bound to the lower eyelid by fascia.

8. What are synergists?

They are muscles in the same eye which moves the eye in the same direction. (Example, left superior rectus and left superior oblique acts as synergists during elevation).

9. What are yoke muscles?

These are otherwise called as contralateral synergists. They are pairs of muscles, one in each eye, that produces conjugate ocular movements. For example, lateral rectus is the yoke muscle for right medial rectus in levoversion.

10. What is Sherrington's law?

This law (also called as the law of reciprocal innervation) states that the increased innervation and contraction of an extraocular muscle (e.g. right lateral rectus) is accompanied by a reciprocal decrease in innervation and contraction of its antagonist (right medial rectus).

11. What is Hering's law?

This law (also called as the law of motor correspondence) states that equal and simultaneous innervations flows to the yoke muscles concerned with the direction of gaze.

12. What are the effects of muscle sequelae following strabismus?

- i. Primary underaction of the involved muscle
- ii. Secondary contracture of the unopposed direct antagonist
- iii. Secondary contracture of the yoke muscle
- iv. Secondary inhibitional palsy.

13. What are the various supranuclear control systems for eye movement?

- i. Saccadic system
- ii. Smooth pursuit system
- iii. Vergence system
- iv. Position maintenance system
- v. Non-optic reflex system including labyrinthine system

14. What is amblyopia?

It is a reduction of best corrected visual acuity that cannot be attributed directly to the structural abnormality of the eye. It is often unilateral and can very rarely be bilateral.

15. What are the most common causes of amblyopia?

- i. Strabismus
- ii. Anisometropia
- iii. Visual deprivation

16. How do you manage a case of amblyopia?

- i. Exclude other causes of poor vision by performing a comprehensive eye exam.
- ii. Correct refractive errors fully
- iii. Occlusion therapy
- iv. Penalization (atropine to the better eye, optical penalization of the better eye)
- v. Visual stimulation using grating lines, CAM stimulator

17. What are the tests used in the assessment of a squint?**A. Light reflection tests:**

- i. Hirschberg test
- ii. Krimsky test
- iii. Bruckner's test

B. Cover tests:

- i. Cover and uncover test
- ii. Alternate cover test
- iii. Simultaneous prism cover test
- iv. Alternate prism cover test.

C. Dissimilar image test:

- i. Maddox wing
- ii. Maddox rod
- iii. Hess/Lees test

D. Binocular single vision tests:

- i. Base out prism test
- ii. Worth four dot test
- iii. Stereopsis
- iv. Bagolini striated glasses
- v. Synoptophore

18. What are the tests based on light reflex to test for ocular alignment?

- i. **Hirschberg test:** This test is based on the principle of the corneal light reflex (Purkinje image 1). Normal light reflex is just nasal to the center of the pupil. 1 mm of decentration of the corneal light reflex corresponds to about 7° or 15 prism of ocular deviation. If the light

reflex is seen at the border of the pupil, it is a 15° or a 30 prism D deviation. If the light reflex is seen in the mid-iris region which is about 4 mm from the center of the pupil, corresponds to 30° or 60 prisms of ocular deviation.

- ii. **Krimsky test:** It involves placing prisms before the deviated eye. The prisms are adjusted to center the corneal reflection in the deviated eye and the amount of prism required is taken as a quantitative measure.
- iii. **Bruckner test:** The direct ophthalmoscope is used to obtain a red reflex simultaneously in both the eyes. The deviated eye will have a brighter reflex.

19. What are the various cover tests?

- i. **Cover-uncover test:** The cover test is to detect tropia while the uncover test is to detect phorias. The patient is asked to fix a distant target. The fixing eye is closed and the eye suspected of deviation is observed. No movement indicates that the eye is orthotropic. Now, the cover is removed and the movement of the eye behind the cover is looked for movement. No movement indicates that the eyes are orthophoric.
- ii. **Alternate cover test:** It is a test to assess deviation when the fusion mechanisms are suspended.
- iii. **Prism cover test:** It is a test to quantitatively measure the angle of deviation. After performing the alternate cover test, prisms of increasing strength are placed in front of an eye with the base opposite the direction of the deviation. The alternate test is continuously performed and the strength of the prism is increased till no movement is seen.

20. What does the Maddox rod test do?

- i. It can be used to test for horizontal and vertical deviations (phorias). Used in addition with another Maddox rod (double Maddox rod test), it can be used to test for cyclodeviations.
- ii. It dissociates both the eyes for distance fixation
- iii. Phorias and tropias cannot be differentiated.

21. What is the use of Maddox wing?

It dissociates both the eyes for near fixation and is used to measure phorias.

22. What is Worth four dot test?

- i. It is a test used for estimating binocular single vision.
- ii. It dissociates both eyes for distance fixation.
- iii. The patient wears a glass with red lens in the right eye and green lens in the left and sees a box consisting of 4 dots (1 red, 1 white and 2 green).

iv. The following is the interpretation.

Normal fusion: All 4 lights are seen

Anomalous retinal correspondence: All 4 lights are seen in the presence of a manifest squint.

Left suppression: 2 lights are seen

Right suppression: 3 lights are seen

Diplopia: 5 lights are seen

23. What are the uses of synoptophore?

- i. To determine the grades of binocular single vision (BSV)
- ii. To measure the objective and subjective angle of deviation
- iii. To measure angle kappa
- iv. To measure primary and secondary deviation
- v. Used to treat suppression and intermittent tropias and phorias

24. What is a horopter?

It is an imaginary plane in space in which all corresponding retinal points are seen singly.

25. What are the factors which are required for the presence of BSV?

- i. Clear visual axis in both eyes
- ii. Eyes in orthopic position (straight)
- iii. Ability of the cerebral cortex to fuse the images.

26. What are the three grades of BSV?

- i. Simultaneous perception
- ii. Fusion
- iii. Stereopsis

27. What are the compensatory mechanisms which happen when BSV is interrupted?

- i. Abnormal head posture
- ii. Closing one eye and seeing with the other.
- iii. Suppression
- iv. Anomalous retinal correspondence
- v. Blindspot syndrome

28. What are the causes of pseudosquint?

- i. Flat, broad nasal bridge
- ii. Prominent epicanthal folds
- iii. Narrow or very wide interpupillary distance
- iv. Positive angle kappa
- v. Asymmetry of face
- vi. Deep set eyes

29. What are the reasons for abnormal head postures?**A. Nonocular causes:**

- i. Torticollis
- ii. Deafness
- iii. Disorders of the cervical spine
- iv. Habit

B. Ocular causes:

- i. Diplopia
- ii. Limitation of ocular movements
- iii. Nystagmus

30. What are the components of a head posture?

- i. Head tilt to the right or left shoulder
- ii. Face turn to right or left side.
- iii. Chin elevation or depression

31. What are the reasons for a head tilt in a case of strabismus?

The head is tilted for two reasons:

- a. Vertical deviation:** The head is tilted to the side of the lower eye to elevate the diplopic images and make fusion possible.
- b. Torsional deviation:** Normally, if the head is tilted to the right shoulder, the right eye will intort and the left eye will extort. However in case like a IV nerve palsy, where the left eye is already extorted, the head is tilted to the right and the left extorsion is compensated.

32. What is the reason for a face turn in a case of squint?

The face turn is performed to place the eyes away from the field of main action of the paralyzed muscle and into the position of least deviation. For example in a case of right sixth nerve palsy, the face is turned to the right.

33. What is the reason for the chin movement in a case of squint?

The chin is elevated or depressed for the following reason:

- i. To place the eyes away from the field of action of the paretic muscle.
- ii. To place the eyes in a position in which the deviation can be controlled
- iii. To avoid discomfort.

34. What is angle kappa?

It is the angle between the visual and optical axis.

35. What are the different types of esodeviation?

- i. Infantile esotropia
- ii. Accommodative esotropia:
 - a. Refractive (normal AC/A ratio)
 - b. Nonrefractive (high AC/A ratio)
- iii. Non-accommodative acquired esotropia
- iv. Incomitant esotropia

36. What are the characteristics of infantile esotropia?

- i. A family history of esotropia is present
- ii. Equal visual acuity with cross-fixation may be a feature
- iii. Correction of refractive errors after cycloplegic refraction has to be performed first before contemplating surgery.

37. What are the characteristics of refractive accommodative esotropia?

- i. Three factors, namely uncorrected hypermetropia, insufficient fusional divergence and accommodative convergence are involved
- ii. Treatment consists of fully correcting hypermetropia
- iii. Surgery is to be considered if fusion is not obtained.

38. What are the causes of exotropia?

A. Congenital: including Duane's type 2

B. Acquired:

- i. Concomitant exotropia
 - a. Intermittent exotropia
 - b. Consecutive exotropia
 - c. Sensory exotropia
 - d. Convergence insufficiency
- ii. Incomitant exotropia
 - a. Oculomotor nerve palsy
 - b. Myasthenia gravis
 - c. Internuclear ophthalmoplegia
 - d. Thyroid eye disease

39. What is Duane's syndrome?

- i. It is a disorder of ocular motility, in which there is retraction of globe during attempted adduction.
- ii. It is of three types:
 - a. Type I: Limitation in abduction
 - b. Type II: Limitation in adduction
 - c. Type III: Limitation in abduction and adduction

40. What are the disorders associated with Duane's syndrome?

- i. Systemic association:
 - a. Epilepsy
 - b. Deafness
 - c. Maldevelopment of the genitourinary system
- ii. Ocular association:
 - a. Ptosis
 - b. Dermoids
 - c. Nystagmus
 - d. Myelinated nerve fibers.

41. What is Brown's syndrome?

It is also called as superior oblique tendon sheath syndrome. The characteristic features are:

- i. Limitation of the active and passive elevation in adduction.
- ii. Downdrift of the affected eye on contralateral version.
- iii. Predominance of a V pattern
- iv. There may be a clicking sound on ocular movements
- v. Hess chart shows a limitation of movement but with a normal lower field.

42. What are the types of Brown's syndrome?

- i. Congenital:
 - a. Idiopathic
 - b. Congenital click syndrome
- ii. Acquired:
 - a. Trauma to the trochlea or superior oblique tendon
 - b. Inflammation of the tendon due to inflammatory conditions such as rheumatoid arthritis, scleritis, etc.

43. What is Mobius syndrome?

It is a congenital disorder characterized by bilateral facial weakness, bilateral VI nerve palsies and horizontal gaze palsies.

44. What are the indications for squint surgeries?

- i. Cosmetic
- ii. To restore BSV
- iii. To correct abnormal head posture
- iv. To treat diplopia and confusion

45. What are the surgical procedures which cause weakening of the recti muscles?

- i. Recession
- ii. Retroequatorial myopexy (Faden's procedure)
- iii. Marginal myotomy
- iv. Myectomy
- v. Free tenotomy

46. What is the principle of recession?

In this procedure, the muscle is disinserted and reinserted to a point closer to its origin, which induces a laxity in the muscle action.

47. What are the maximal limits of recession?

- i. Adults: 6 mm for medial rectus and 8 mm for lateral rectus
- ii. Children: 5.5 mm for medial rectus and 7 mm for lateral rectus.

48. What is Faden's procedure?

It is a retroequatorial myopexy. In this surgery, the muscle is sutured well posterior to its insertion, thus considerably weakening its action. The indications are:

- i. Non-accommodative esotropia
- ii. Nystagmus blockade syndrome
- iii. Dissociated vertical deviations
- iv. Paralytic strabismus
- v. Duane's retraction syndrome.

49. What is the principle of resection?

In this procedure, the muscle length is shortened, by making it more taut. It involves excision of the tendinous part only.

9.1. DIPLOPIA CHARTING

1. What is diplopia charting?

It gives a pictorial record of diplopia in cases where there is separation of 2 images, changing with the position of gaze.

2. What is the principle of diplopia charting?

Each retinal point has its own value of direction in gazes.

3. What are the indications for diplopia charting?

In patients with incomitant deviation, it can be an aid for diagnosis or for follow-up.

4. What are the data derived from diplopia charting?

- i. The areas of single vision and diplopia
- ii. The distance between the two images in the areas of diplopia
- iii. Whether the images are on the same level or not
- iv. Whether one image is inclined or both are erect
- v. Whether the diplopia is homonymous or crossed.

5. What are the prerequisites for doing diplopia charting?

- i. Patient should have binocular single vision.
- ii. Good visual acuity.
- iii. Patient should be cooperative.

6. What are the materials required for diplopia charting?

- i. A pair of red and green glasses.
- ii. Linear light source.

7. Why linear light?

Linear light is preferable since it allows the patient to see a tilted image in the presence of cyclotropia.

8. Explain the procedure.

- i. The patient is seated comfortably.
- ii. The procedure is explained to the patient in detail.
- iii. It is made sure that the head is held straight for the whole procedure.
- iv. Goggles are fitted such that the red glass is in front of the right eye.
- v. The linear light is held vertically in the primary position at a distance of about 50 cm and is asked about the diplopia.
- vi. Patient is asked which colored image appears straight in front of him and on which side does he see the second image.
- vii. Ask if the image higher/lower and is it straight/tilted.
- viii. If the patient is cooperative he can be given 2 pencils and asked to hold them exactly as he sees the 2 lights.

9. What are the precautions to be followed during the procedure?

- i. Patient must not be allowed to turn his head to look in any position of gaze.
- ii. The light source must be moved as far as possible in each direction of gaze checking that it is visible to both the eyes.
- iii. If the patient says that he sees only one light indicating possible binocular single vision the examiner must make sure that the line image has not moved out of the visual field.

10. How do we record the results?

- i. Patient's right and left side to be clearly labeled
- ii. Which eye projects the red image and green image to be noted
- iii. Record the separation of images and tilted images as described by the patient.

11. How do we interpret the charting?

- i. If two images are joined together—no diplopia
- ii. If images are separated—confirms diplopia.
- iii. Maximum separation is in the quadrant in which (the muscle moves the eye) the muscle is restricted.
- iv. The image is displaced towards the field of action of the paralyzed muscle.
- v. If horizontal separation with uncrossed images—esodeviation.
- vi. If horizontal separation with crossed images—exodeviation.
- vii. If vertical separation with uncrossed images—oblique muscles involved.
- viii. If vertical separation with crossed image—vertical recti muscle involved.

12. What are the disadvantages of diplopia charting?

- i. It is mainly a subjective test.
- ii. Needs a well cooperative patient.
- iii. Test is not reproducible.
- iv. In many cases the patients are uncooperative or their intelligence is obscured by intracranial disease or contracture of the antagonistic muscles may have set in.
- v. The test may give false interpretations if the paresis unmasks a latent squint or the patient starts fixing with the paralyzed eye, especially if this eye has the greater visual acuity.

9.2. HESS CHARTING

1. What is the clinical significance of Hess charting?

- i. The Hess screen test is an important diagnostic modality that helps in the diagnosis and prognostication of incomitant strabismus.
- ii. It provides an accurate clinical method of determining the position of each visual axis in different directions of gaze.
- iii. It provides a permanent and accurate record which may be compared with the results of subsequent examinations.
- iv. May help to differentiate recent onset paralysis from long standing one.
- v. May enable to differentiate parietic squint caused by neurological pathology from restrictive myopathy like thyroid eye disease or blowout fracture of the orbit.

2. Describe in detail about Hess chart.

The electrically operated Hess screen has largely replaced the original Hess screen.

It has a wooden screen with small red lights forming fixation points and a movable illuminated green indicator.

- i. A light source is present behind each red light aperture, the illumination of which is controlled from a control unit.
- ii. Each of the red fixation spot lights can be switched on in turn by the insertion of a plug into the switch board, the apertures of which correspond to the circular apertures of the Hess screen.
- iii. The patient holds a green spotlight color, the color of which is identical with that of the green eyepiece of red green glasses.
- iv. Each eye has to be tested separately. This can be done by red-green glasses which dissociate both eyes.
- v. The eye behind the green glass is the testing eye. The patient tries to place a green light tip pointer on each of the red points in turns. The place indicated by the patient is recorded on a chart printed with similar marking. The recorded points are joined to form an inner and outer square.
- vi. For interpreting the results of the Hess test, it is important to be aware of the muscle sequelae that follow paralytic strabismus and the laws that govern them.

3. What are the principles of Hess chart?

- i. Foveal projection
- ii. Hering's law
- iii. Dissociation of eyes

4. What are the indications of Hess chart?

- i. Patient with incomitant squint.
- ii. Patients with divergence weakness type of esotropia to exclude mild sixth nerve palsy.
- iii. To differentiate divergence palsy from sixth nerve palsy.

5. What is Sherrington's law?

It states that increased innervation and contraction of a muscle is associated with a reciprocal decrease in innervation (relaxation) of its antagonist.

6. What are the stages in the development of muscle sequelae?

- i. Overaction of contralateral synergist according to Hering's law.
- ii. Overaction of ipsilateral antagonist as its action is unopposed by the parallel muscle.
- iii. Secondary underaction of the contralateral antagonist. However, in long standing palsies, there is the spread of comitance and these stages cannot be easily discerned.

7. What are the prerequisites for Hess charting?

There are certain prerequisites required before conducting a Hess charting.

- i. Full understanding of the procedure.
- ii. Good vision in both eyes.
- iii. Central fixation.
- iv. Normal retinal correspondence.

8. Describe the procedure.

- i. The patient is seated at 50 cm facing the screen being plotted.
- ii. Head erect and eyes in primary position with the head centered on the fixation spot.
- iii. The patient wears red and green glasses.
- iv. Patient instructed to shine spotlight upon each red fixation light as it is illuminated.
- v. With green glasses in front of left eye he fixes red dots with his right eye, indicator shows deviation of left eye and then glasses are reversed.

9. What are the features of the Hess chart used for interpretation?**General guidelines**

- i. The central dot in each field indicates the deviation in the primary position.
- ii. Smaller field belongs to the paretic eye.
- iii. Inward displacement of the dots indicates underaction. The eye cannot move far enough to plot in normal position.
- iv. Outward displacement of dot indicates overaction (or contracture). Excessive movement of eye causes dots to be plotted beyond the normal position.

- v. Equal sized fields indicate that muscle sequelae have developed. Underaction of the affected muscle, overaction of the contralateral synergist, contracture of ipsilateral antagonist of paretic muscle, secondary underaction of the contralateral synergist of contracted muscle. The paresis is therefore long standing or congenital.
- vi. The outer fields should be examined for small under and overactions which may not be apparent on inner fields.
- vii. If the outer field is very close to the inner field, a mechanical cause for the limited movement is likely.
- viii. Each small square subtends 5° . The inner square therefore measures 15° movement from the primary position to each position of gaze. The outer square measures 30° of movement.
- ix. When the right eye fixes the red dots, the field of movement of the left eye is plotted and vice versa. The fixing eye determines the amount of innervation sent to non-fixing eye.

Interpretation of Hess chart.

- i. Compare the size of the two fields.
- ii. Examine the smaller field (paretic eye) and note position of maximum inward displacement which will be in the direction of main action of paretic muscle.
- iii. In the side with smaller field, note if there is outward displacement in the direction of action of the ipsilateral antagonist of the affected muscle. Outward displacement indicates contracture shown as overaction.
- iv. Examine the larger field and note position of maximum outward displacement, indicating overaction of contralateral synergist of paretic muscle.
- v. In the side with larger field, note if there is inward displacement of the antagonist of the overacting muscle, indicating secondary underaction (this muscle is contralateral synergist of the contracted muscle).
- vi. Look at the relationship between the inner and outer field.
- vii. Look at the position of center dots inward displacement indicating esotropia.
- viii. Equal sized fields indicate either symmetrical limitation of movement in both eyes or a concomitant strabismus.
- ix. Sloping fields denote A or V pattern.

10. What are the features of neurogenic defects?

- i. The smaller field has a proportional spacing between the outer and inner fields.
- ii. Muscle sequelae is common.
- iii. The Hess chart between the two eyes tend to become more similar in size with time.

11. What are the features of mechanical defects?

- i. Compressed field either vertically or horizontally
- ii. The most obvious feature of a mechanical defect is normally the marked overaction of the contralateral synergist.
- iii. There is not normally an obvious overaction of the direct antagonist, nor underaction of the contralateral antagonist.

12. What are the uses of the Hess chart?

- i. Diagnosis of a muscle palsy.
- ii. Assessing progress.
- iii. Planning muscle surgery.
- iv. Evaluating results of incomitant strabismus.
- v. Provides a permanent and accurate record which may be compared with the results of subsequent examinations.

Right eye has a smaller field—affected eye

Right hypertropia of less than 5°

Proportional spacing between inner and outer squares

Limitation of right depression in adduction (right superior oblique underaction)

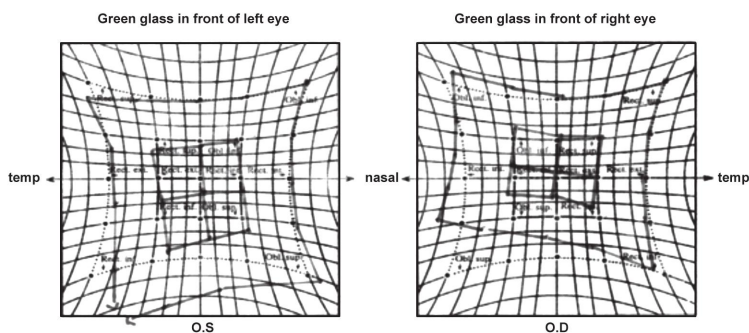
Extorsion of field of the right eye

Above point to right superior oblique palsy

Overaction of right inferior oblique and left inferior rectus (muscle sequel).

NAME _____

No. _____



Diagnosis: _____

Diagnosis—Right lateral rectus palsy

Right eye has a smaller field—affected eye

Right esotropia of 5° in primary position (one small square)

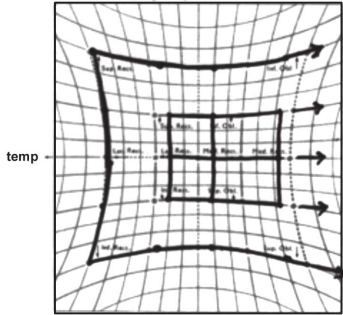
Right abduction restriction

Proportional spacing between inner and outer squares

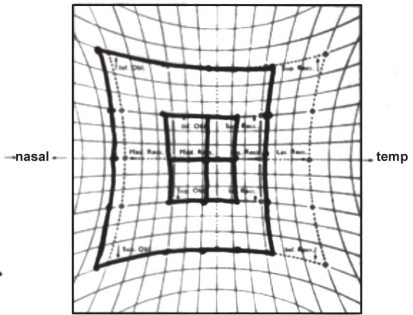
Left medial rectus overaction (muscle sequelae)

Points 4 and 5 indicate a paralytic strabismus.

HESS SCREEN CHART
Field of Left Eye (fixing with right eye)



Name No
Field of Right Eye (fixing with left eye)



10

CHAPTER

Miscellaneous

10.1. VITAMIN A DEFICIENCY

1. What is vitamin A?

It is a fat soluble vitamin stored in the liver. Vitamin A, in strictest sense refers to retinol. However the oxidized metabolites, retinaldehyde and retinoic acid are also biologically active compounds.

2. What are available forms of vitamin A?

There are four forms:

- i. Acid—retinoic acid
- ii. Aldehyde—retinaldehyde
- iii. Alcohol—retinal
- iv. Ester—retinyl ester

3. What is role of retinaldehyde and retinoic acid in normal body?

Retinaldehyde—it is required for normal vision.

Retinoic acid—it is necessary for normal morphogenesis, growth and cell differentiation.

4. What are sources of vitamin A?

Vitamin A is available from both plant and animal sources as retinyl palmitate and carotene respectively.

Animal sources—meat, milk, liver, fish, cod liver oil.

Plant sources—green leafy vegetable, carrots, fruits especially yellow fruits (mango and papaya).

5. What are requirement of vitamin A?

Adults	300–750 µg/day
Lactating female	1150–4600 µg/day.

6. What is the role of vitamin A in the body?

A. Role in general:

- i. Maintenance of mucus secreting cells of epithelia of body.
- ii. Normal morphogenesis, growth and cell differentiation.
- iii. Role in iron utilization.
- iv. Role in humoral immunity, T-cell mediated immunity, natural cell killer activity and phagocytosis.

B. Role in eye:

- i. Precursor of photosensitive visual pigment (rhodopsin)
- ii. Maintain conjunctival mucosa and corneal stroma.
- iii. Outer segment turnover epithelium.

7. What is the blood level of vitamin A?

It is made by measurement of serum retinol.

Normal range— 30–65 µg/dl or
150–300 IU/dl.

8. What is etiology of vitamin A deficiency?

- I. Primary vitamin A deficiency: This is due to deficient dietary intake of vitamin A and other micronutrients.
- II. Secondary vitamin A deficiency: It is due to defect in absorptions and utilization. It occurs in the following conditions.

For example:

- i. Malabsorbtion syndrome
- ii. Chronic liver disease
- iii. Severe infection
- iv. Chronic pancreatitis

9. What are the risk factors of vitamin A deficiency?

- i. Age: preschool children (2 to 3 years of age)
- ii. Sex: males > females
- iii. Social economic status: low social class
- iv. Physiological status: pregnant and lactating women are vulnerable to low vitamin A content in breast milk
- v. Diet: rice dependent communities in most tropics
- vi. Seasons: dry summer
- vii. Breast feeding: highly protective, weaning diet highly crucial
- viii. Cultural: dietary habits in some communities
- ix. Infectious diseases: some diseases predispose to vitamin A deficiencies.

For example: diarrhea, intestinal parasites, AIDS, measles.

10. What is WHO classification of xerophthalmia?

XN Night blindness

X1A Conjunctival xerosis

X1B Conjunctival xerosis ± Bitot's spot

X2 Corneal xerosis

X3A Corneal ulceration/keratomalacia/involving <1/3 of corneal surface

X3B Corneal ulceration/keratomalacia/involving >1/3 of corneal surface

- XS Corneal scars
 XF Xerophthalmia fundus.

11. What is xerophthalmia?

The term used to describe irregular, lusterless, and poorly wettable surface of the conjunctiva and cornea associated with vitamin A deficiency.

12. Describe night blindness.

One of the most common and earliest manifestation.

- It is reversible.
- It is due to inadequate or slow recovery of rhodopsin in retina after exposure to bright light.
- Occurs because retinol is essential for production of rhodopsin by rod photoreceptor.
- With oral replacement night blindness may disappear in 48 hours.

13. Describe conjunctival xerosis.

Characteristic changes are usually confined to bulbar conjunctiva.

- Changes are dryness, lack of wettability, loss of transparency, thickening, wrinkling and pigmentation.
- Histopathology
 - i. Metaplasia of normal columnar cells to stratified squamous.
 - ii. Prominent granular layer.
 - iii. Formation of metaplastic, keratinized surface.

14. What is Bitot's spot?

It is a classic sign of xerophthalmia.

- It is described as a paralingual grayish plaques of keratinized conjunctival debris, frothy foamy cheese in appearance and not wetted by tear.
- Pathologically it is a tangle of keratinizing epithelial cells mixed with saprophytic bacteria and sometimes fungi, fatty debris over edema of mucosa and submucosa.

15. What is site of occurrence of Bitot's spot?

Site in decreasing order of frequency,
 Temporal → nasal → inferior → superior.

- More significant diagnostically if nasal in position.

16. Describe corneal xerosis.

Usually associated with conjunctival xerosis.

Torch light examination shows

- i. Roughened and lusterless surface.
- ii. Peau 'd' Orange appearance.

Slit lamp examination.

- i. Stromal edema.
- ii. Superficial punctate keratitis.

- iii. Keratinization.
- iv. Fluorescein shows pooling between plaques and keratinized epithelia—Tree bark appearance.

17. What are the subclinical signs of vitamin A deficiency?

- i. Dark adaptometry—Abnormal rod threshold
- ii. Vision restoration test—Delayed response after blanching
- iii. Pupil constriction—Failure to constrict in low illumination
- iv. Conjunctival impression cytology—Abnormal epithelial and goblet cell pattern.

18. Describe corneal ulceration in vitamin A deficiency.

They occur mostly in inferior or nasal part.

- i. Ulcer has very sharp margin as if cut with a trephine.
- ii. More severe lesions results in frank necrosis or sloughing of stroma known as keratomalacia.
- iii. It is generally not reversed with treatment.

19. Describe xerophthalmic fundus.

Whitish yellow changes in pigment epithelium.

- i. Both eyes are affected.
- ii. Corresponds to areas of temporary visual field loss.
- iii. Appear to be window defect in fundus fluorescein angiogram (FFA).
- iv. Known as Uyemura's syndrome.

20. How do you diagnose vitamin A deficiency?

Diagnosis depends on:

- i. Clinical signs, symptoms
- ii. Serum vitamin A level
- iii. Conjunctival impression cytology for mucin secreting cells, goblet cells and epithelial cells.

21. How do you treat a patient with vitamin A deficiency?

Children— < 1 yr of age or	1,00,000 IU—immediately
< 8 kg in wt	1,00,000 IU—next day
	1,00,000 IU—after 4 months.
Children 1–6 yr of age	2,00,000 IU—immediately
	—next day
	—after 4 months.

- It will take care of acute manifestation of vitamin A deficiency.
- They should also be treated with both vitamin and protein calorie supplement.
- Maintenance of adequate corneal lubrication and prevention of infection and corneal melting is essential.

10.2. LOCALIZATION OF INTRAOCULAR FOREIGN BODIES (IOFB)

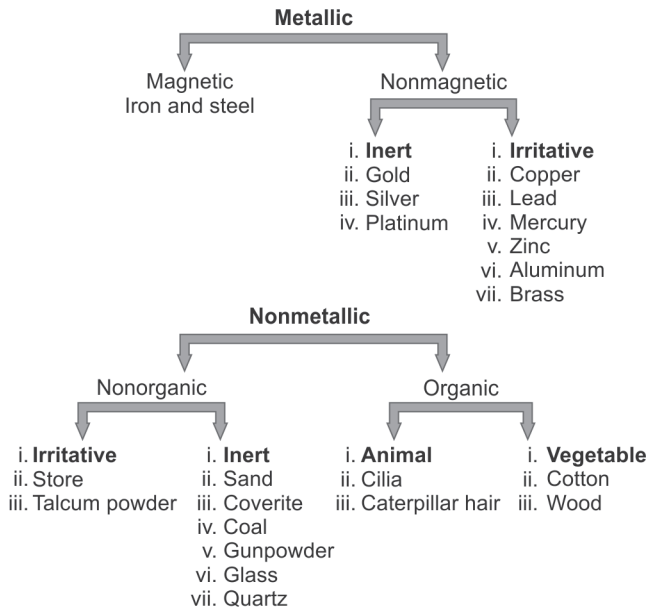
1. Intraocular foreign body occurs more commonly in:

- i. Males
- ii. Age 20–40 years
- iii. In the work setting
- iv. Mostly are the results of hammering metal on metal.

2. What history should be elicited from the patient having IOFB?

- i. Circumstance and mechanism of injury
- ii. Nature of material
- iii. Any likelihood of contamination
- iv. Force with which it hit the eye.

3. Classify the different types of foreign bodies.



4. How does the entrance of the foreign body into the eye cause damage?

- i. By mechanical effects

- ii. By introduction of infection
- iii. By specific action (chemical & otherwise) on the tissue.

5. Where can the foreign body be embedded in the anterior chamber?

- i. It can either fall to the bottom and if very small embedded in the angle.
- ii. It can get embedded in the iris.

6. How can the foreign body pass into the vitreous?

- i. Through the cornea, iris and lens when there will be a hole in the iris and traumatic cataract.
- ii. Through the cornea, pupil and lens
- iii. Through the cornea, iris and zonule
- iv. Through the sclera directly.

7. What changes does the foreign body cause in the vitreous?

The foreign body may be suspended for sometime and ultimately sinks to the bottom of the vitreous cavity due to degenerative changes in the gel, which lead to liquefaction partial or complete. The track of the foreign body through the vitreous is seen as a gray line.

8. How can the foreign body penetrate the retina?

Mostly the particle has enough energy to carry it directly into the retina where it may ricochet once or even twice before it comes to rest. Occasionally, it pierces the coats of the eye to rest in the orbital tissues (double perforation).

9. How does the foreign body look if lodged in the sclera?

The foreign body often appears black with a metallic lustre. It is surrounded by white exudates and red blood clot. Eventually fibrous issue usually encapsulates it and retina in the neighborhood becomes heavily pigmented.

10. What degenerative changes does the foreign body cause in the posterior segment?

- i. There may be widespread degeneration but most frequently fine pigmentary disturbances at the macula → often the result of concussion.
- ii. Vitreous turns fluid usually
- iii. Bands of fibrous tissue may traverse along the path of the foreign body
- iv. Hemorrhage may be extensive
- v. Retinal detachment may follow.

11. What is the reaction of the ocular tissue to the nonorganic materials?

- i. They are inert.
- ii. Excite a local irritative response, which leads to formation of fibrous tissue and results in encapsulation.

- iii. Produce a suppurative reaction.
- iv. Cause specific degenerative changes.

12. What do organic materials produce?

They cause a proliferation reaction characterized by formation of granulation tissue.

13. What is siderosis?

Iron contamination of intraocular tissues causes a characteristic picture called siderosis (so does steel in proportion to its ferrous content). The condition is due to electrolytic dissociation of the metal, especially trivalent iron by the current of rest in the eye, which disseminates the material throughout the tissues and enables it to combine with the cellular proteins, thus killing cell causing atrophy.

14. What are the features of siderosis?

- i. A rusty staining of cornea—Coats' white ring when deposits are at the level of Bowman's membrane.
- ii. Brown colored iris, mid dilated pupil, non-reactive due to damage to dilator muscle.
- iii. Deposition of iron in the anterior capsules of the lens as a rusty deposit, arranged radially corresponding with the dilated pupil.
- iv. The ring becomes stained first greenish and then reddish brown.
- v. Eventually this leads to development of cataract.
- vi. Retinal degeneration with attenuation of vessels.
- vii. Secondary glaucoma of chronic type is a complication due to iron deposition in trabecular meshwork.
- viii. Powerful oxidants like superoxide, hydrogen peroxide, which causes lipid peroxidation, leading to enzyme inactivation and cell membrane damage.

15. How are the deposits of iron revealed pathologically?

They are revealed by the Prussian blue reaction with Perl's microchemical stain. The characteristic blue pigmentation is found particularly in the corneal corpuscles, in the trabecular meshwork, on the inner surface of the ciliary body and in the retina where the whole retinal vasculature system is clearly marked out.

16. What is the reaction of copper?

If the metal is pure, a profuse formation of fibrous tissue occurs which is followed by a suppurative reaction and eventually shrinkage of globe. If the metal is alloyed (bronze/brass), a milder reaction occurs called chalcosis. It gets deposited where resistance to its migration is offered by a continuous membrane. So it has a tendency to get deposited on basement membranes like Descemet's membrane, anterior lens capsule and internal limiting membrane. The typical sites are:

1. Deep parts of cornea more in the periphery causing the appearance of golden brown Kayser-Fleischer ring.

2. Under the lens capsule where it is deposited to form a brilliant golden green sheen aggregated in radiating formations like petals of a flower → sunflower cataract.
3. On the retina at the posterior pole where lustrous golden plaques reflect the light with a metallic sheen.
4. Greenish discoloration of iris.
5. Impregnation on zonular fibers.
6. Brownish red vitreous opacities.

17. What is the reaction of lead?

One of the commonest form of foreign body.

It is rapidly covered by layer of insoluble carbonate, which prevents its diffusion. It produces few changes in the anterior chamber, and liquefaction and opacification of vitreous gel can occur. If the metal lies on retina or choroid, it causes an exudative reaction, partly purulent and partly fibrinous.

18. What is ophthalmia nodosa?

Caterpillar hair may penetrate the eye inciting a severe iridocyclitis characterized by the formation of granulomatous nodules.

19. What are the methods for localization of foreign body?

- i. Clinical methods for direct visualization.
- ii. Special methods for indirect visualization.

20. What will you look for in direct visualization?

- i. Wound of entry
- ii. Associated corneal, scleral, iris tear
- iii. Penetrating tract in iris, vitreous
- iv. Gonioscopy for angle recession
- v. Any signs of siderosis or chalcosis.

21. What are the clinical signs of importance?

- i. Localized tenderness
- ii. Mydriasis 3 to 6 weeks after an accident
- iii. Undue persistence of irritation
- iv. Delayed occurrence of unexplained uveitis.

22. What are the special methods for investigation?

- i. Those depending on magnetic property of the foreign body
- ii. Those depending on electrical conductivity and induction.
- iii. Those depending on chemical analysis.
- iv. Radiology including X-ray, CT, MRI.
- v. USG
- vi. ERG

23. What are the instruments used for detection of foreign body based on electrical conduction?

- i. Bermann's locator: The detecting range for magnetic foreign body is ten times the diameter of the foreign body. For nonmetallic foreign body it ranges between 1–2 times. Nonmagnetic foreign body can be detected only if they are more than 3 mm in diameter.
- ii. Roper Hall's locator: Also called electroacoustic foreign body detector, metallic foreign body is continuous while nonmetallic foreign body is intermittent.
- iii. Carnays locator.
- iv. Ophthalmometalloscope of Hale.

24. What is the sensitivity for foreign body in radiographic methods?

- i. 0.5 mm diameter will be evident in X-rays. (All metals except aluminum, which has an equal bone density. So bone free method is used).
- ii. Only 40% are located with plain films and they can be difficult to locate accurately.

25. What are the views most suitable for demonstration of foreign body?

- i. **True lateral**—affected side towards the film.
- ii. **Posteroanterior**—face against the film.
 - Nose and chin in contact with film.
 - Tube is centered to middle of orbit.

26. What are the different radiological methods used?

- i. Direct methods
- ii. Methods depending on relational movements of eye
- iii. Methods on geometric projection
- iv. Bone free methods
- v. Stereoscopic methods
- vi. Methods based on delineation of globe using contrast media.

27. What is the direct radiographic method?

- i. Two exposures—posteroanterior and lateral are taken
- ii. The foreign body is located in relation to a marker bearing a known relation to the globe.

28. What are the limitations of direct radiographic method?

- i. Errors may arise from movement of marker
- ii. Markers cannot be kept in a badly damaged eye.
- iii. Eyeball is thought to be 24 mm which is not always true.

29. What are the principle of methods, which depend on rotation of globe?

- i. Head and X-ray tube remain fixed.
- ii. Several exposures with eye moving in different directions.

- iii. 3 exposures in lateral view with eye looking straight upward and downward.
- iv. Position of foreign body calculated with amount and direction of displacement with reference to center of rotation of globe.

30. What are its limitations?

- i. There is no true center of rotation of the globe.
- ii. The calculations are made in reference to a schematic eye 24 mm.

31. What is the principle of methods depending on geometric construction?

Sweet's Method:

- i. Eye and head remain fixed.
- ii. 2 X-rays are taken with X-ray tube in known position.
- iii. Two metal indicators are used.
- iv. Foreign body position localized with reference to fixed indicators.

32. Different methods based on geometric construction are

- i. Mackenzie Davidson
- ii. Sweet's method (ingenious and very accurate)
Indicators: 1. Center of cornea
 2. Temporal side

iii. Dixon's method



Modified by Bromley



Modified by McGregor.

33. What are its limitations?

- i. Measurements are incorrect if the patient does not fix properly.
- ii. Measurements on schematic eye of 24 mm axial length.

34. What is the principle in stereoscope methods?

- i. Two X-ray are positioned at 2 fixed angles with markers attached to globe eye in different position.
- ii. Foreign body is calculated with reference to displacement of its shadow from the radiopaque marker.

35. How do you delineate the globe by using contrast media?

- Injecting air or dye (thorotrast, lipiodol, diodrast) in the Tenon's space.

36. What are the disadvantages?

- i. Air embolism if air is used.
- ii. Tissue reaction to eye.

37. What is the principle in bone free or Vogt's method?

Dental film is held over and perpendicular to inner canthus of eye and the ray are directed from the side so that a shadow of the profile of the anterior segment of the eye (8–12 mm) is recorded on the film.

38. What are the indicators for Vogt's method?

- i. Useful when a small foreign body is in anterior segment of eye.
- ii. Foreign body density equals to that of bone.

39. How is the limbal ring used to detect foreign body?

- i. This was introduced by Stallard and Somerset.
- ii. In this method, a metallic ring 11–14 mm in diameter half the diameter of the schematic eye, is sutured to limbus and X-ray. PA view and lateral view are taken.
- iii. Precaution:
 - Image of the ring on PA view should be circular
 - Image of ring on lateral view should be vertical.
- iv. On PA view:
 - The center of the ring formed by the limbal ring is marked.
 - A schematic eye of 24 mm is drawn from center.
 - If the foreign body falls within the schematic eye it is intraocular, otherwise it is extraocular.
 - A vertical corneal axis is drawn passing through the center of the ring and the distance of the foreign body nasal or temporal to this axis is noted and measured.
- v. On lateral view:
 - A horizontal corneal axis is drawn.
 - Distance of the foreign body above or below this axis is also noted and the distance of foreign body from behind limbal ring is also noted. To measure the AP measurement from the front of cornea, 3 mm should be added to the measurement from the limbal ring.
 - Finally the position of the foreign body is charted on a Bromley's chart or cridland graticule.

40. What are the limitations of the limbal ring test?

- i. Errors may arise from movement of ring and its inaccuracy of its fit.
- ii. Inaccurate orientation of globe can occur.
- iii. The ring cannot be sutured to a badly damaged eye.
- iv. Standard eye ball size is taken as 24 mm which is not always true.

41. What is the contact lens method?**A. Comberg's method:**

It utilizes a contact lens with radiopaque markers (lead) in all 4 quadrants.

A PA exposure is taken with the central ray focused on the anterior pole of the eye and lateral exposure where central ray passes through the limbus.

From the frontal X-ray the anterior pole of the eye is indicated by intersection of the diagonals joining the markers and the distance of the foreign body from this point is determined. Its position in the sagittal plane is obtained from lateral view by measurement of the distance of the foreign body behind the markers.

Worst Lovac contact lens: This contact lens is held in constant position during filming by a partial vacuum produced between the contact lens and cornea. It has a central opening which is connected to a metal tube which is attached to a rubber suction bulb. PA and lateral view are taken.

42. What are the disadvantages of contact lens method?

- i. It is assumed that the eyeball size is 24 mm
- ii. The marker may superimpose on the foreign body
- iii. It is an additional trauma to the eye.
- iv. Improper positioning of lens can occur due to chemosis and AC deformation.
- v. Sometimes a poor contact lens fit will allow movement of lens and so false limbal reference points may be identified.

43. What is the frequency of ultrasonogram used to detect foreign bodies?

8–10 MHz. In the presence of severe inflammation, then 5 MHz is used.

44. What are the two modes used?

i. A-scan

- one-dimensional method
- It may reveal orbital foreign body posterior to sclera
- Foreign body appears as steeply rising echospike.

ii. B-scan two-dimensional, more valuable than A-scan

- Foreign body appears as acoustically white (opaque).

45. What is quantitative echography used in the detection of a foreign body?

- i. The reflectivity of a foreign body echospike is extremely high reaching 100% with lowest gain.
- ii. This allows a comparison with scleral signal.

46. What are the advantages of USG?

- i. Can detect foreign body even in opaque medium.
- ii. Can detect the presence of retinal detachment or vitreous hemorrhage
- iii. Gives axial length of eyeball.
- iv. Can localize non-metallic foreign body
- v. Can precisely localize intraocular or extraocular foreign body.

47. What are the disadvantages of USG?

- i. Hazardous in open globe.
- ii. Information only in two dimensions
- iii. More anterior part of globe may not be directed in USG.

48. What is the relevance of ERG in the detection of foreign bodies?

- i. In siderosis bulbi—early ERG changes include an increased amplitude of the “a” wave and a normal b wave. Late changes include a diminished b wave and ultimately an extinguished ERG.

- ii. In chalcosis, ERG shows initial a wave amplitude and later a decreased “a” wave and a “b” wave amplitude.

49. What are the advantages of CT scan?

- i. It is extremely sensitive
- ii. No globe manipulation is required.
- iii. Multiple foreign bodies can be localized.
- iv. Little patient cooperation is required.
- v. Allows detection of smaller foreign body 0.5 mm or more
- vi. Distinguish metallic from nonmetallic and identifies composition of nonmetallic.

50. What are the suggested cuts for CT scan?

Thin axial cuts (≥ 1.5 mm) and direct coronal cuts are used.

51. What are the limitations of MRI?

- i. If there is a magnetic foreign body, they have been shown to move on exposure to the magnetic field.
- ii. Visual loss and vitreous hemorrhage have been attributed to movement of occult foreign body after MRI and hence they are contraindicated for magnetic foreign bodies.

52. Management of intraocular foreign bodies.

Intravitreal	Well-visualized	Poorly visualized
a. Magnetic	External magnet	Vitrectomy, forceps/REM
b. Non-magnetic intraretinal	Vitrectomy/forceps	Vitrectomy/forceps
a. Magnetic	Transcleral "trapdoor" or vitrectomy forceps/REM	Vitrectomy forceps/REM
b. Non-magnetic	Transcleral "trapdoor" or vitrectomy forceps/REM	Vitrectomy forceps/REM

53. What are the types of magnets?

- i. Hand held magnet
 - It is small and low powered. Applicable only when the foreign body is within 1 mm of its tip.
- ii. Giant magnet or Bronson’s electromagnet
 - This magnet has a strong magnetic field.
 - It is of 2 types
 - a. The Haab’s type of electromagnet.
 - b. The ring method.
- iii. Intraocular magnet

54. What is the “Lancaster’s working criteria for a magnet?”

The rule states that to be effective, a giant magnet should pull steel ball of 1 mm diameter with a force of over 50 times its weight at a distance of 20 mm.

55. What can be the associated complication with foreign bodies?

- i. Vitreous hemorrhage
- ii. Retinal tears
- iii. Retinal detachment
- iv. Endophthalmitis
- v. Traumatic cataract
- vi. Iridocyclitis
- vii. Subluxated lens with zonular dialysis, etc.

56. What is the treatment of siderosis?

- i. First remove the foreign body
- ii. Galvanic deactivation
- iii. Administration of IV EDTA.
- iv. Subconjunctival injection of adenosine triphosphate
- v. Administration of desferrioxamine, which traps the free ions and converts it non-toxic chelate.

57. What is the treatment of chalcosis?

- i. Sodium thiosulfate
- ii. Sodium hyposulfate
- iii. BAL (British anti-Lewisite)

10.3. COMMUNITY OPHTHALMOLOGY

1. What is the WHO definition of blindness?

i. Based on visual acuity

WHO defined blindness as visual acuity less than 3/60 or its equivalent in the better eye with best possible refractive correction (best corrected visual acuity < 3/60).

ii. Based on visual field

Visual field less than 10° in the better eye, irrespective of the level of visual acuity.

2. How will you categorize visual impairment and blindness?

WHO classification (1992)

CATEGORY	BCVA
0—normal	6/6 to 6/18
1—visual impairment	6/24 to 6/60
2—severe visual impairment	< 6/60 to 3/60 (economic blindness)
3—blind	< 3/60 to 1/60 (social blindness)
4—blind	< 1/60 to PL+ (legal blindness)
5—blind	NO PL (complete/total blindness)

3. What is the Indian definition of blindness?

Best Corrected Visual Acuity (BCVA) less than 6/60 or its equivalent in the better eye.

4. What is avoidable blindness?

- i. **Preventable** blindness which can be easily prevented by attacking the causative factor at an appropriate time, e.g. corneal blindness due to vitamin A deficiency and trachoma.
- ii. **Curable** blindness which vision can be restored by timely intervention, e.g. cataract blindness.

5. What is the magnitude of blindness?

Global— 45 million blind and 180 million visually disabled.

India— 9 million blind (1/5th of the world)

Prevalence of blindness in India is 1.1% (NPCB 2001–2002)

6. What are the causes of blindness in Indian scenario?

The causes of blindness in Indian scenario:

NPCB survey (2001–02), presenting vision < 6/60

Cataract	— 62.6%
Refractive error	— 19.7%
Glaucoma	— 5.8%
Posterior segment pathology	— 4.7%
Corneal opacity	— 0.9%
Surgical complications	— 1.2%
Others	— 4.1%

7. What is cataract surgery rate (CSR)?

$$\text{CSR} = \frac{\text{Total number of cataract surgeries performed}}{\text{Total population}} \times 1,000,000$$

According to 2005 statistics, CSR for India was 4500 per million populations.

8. What is the management of ophthalmia neonatorum?

I. Prophylaxis

Antenatal—Treat genital infection

Intranatal—Hygienic delivery

Postnatal—1% tetracycline eye ointment (or) 1% silver nitrate (Crede's method) (or) 2.5% povidone-iodine immediately into the eyes of the babies after birth.

II. Curative

Conjunctival swab for culture sensitivity and cytology taken. Patient is started on broad spectrum antibiotic like topical fluoroquinolone till the reports arrive, following which specific treatment is started.

Neonatal conjunctivitis (Ophthalmia neonatorum)	
Infection	Treatment
Chlamydiae trachomatis	Oral erythromycin 50 mg/kg in four divided dose for 14 days
Gram-positive bacteria	Erythromycin 0.5% e/o QID
Gram-negative bacteria (gonococcal)	Systemic: Inj. ceftriaxone 25–50 mg/kg IV or IM single dose X 7 days OR Inj. cefotaxime 100 mg/kg IV or IM single dose X 7 days Topical: saline lavage hourly, bacitracin eye ointment qid, or penicillin drops 5000 10,000 U/ml
Others	Topical gentamycin or tobramycin
HSV	Topical and systemic antivirals

9. What are the prophylaxis and treatment options in vitamin A deficiency?

Prophylaxis

- i. Immunization (e.g. measles)
- ii. Vitamin A supplements
- iii. Nutritional education to mothers
- iv. Fortified foods

These prophylactic measures can be observed under following strategies:

Short-term strategies:

- i. WHO recommendation: 6 monthly supplementation of high dose of vitamin A

Children (age—1 to 6 years)—2 lakh IU orally every 6 months.

Infants 6 to 12 months old—1 lakh IU orally every 6 months.

Infants < 6 months—50,000 IU orally

- ii. Indian recommendation: CSSM (Child survival and safe motherhood)
 - First dose (1 lakh IU)—at 9 months along with measles vaccine
 - Second dose (2 lakhs IU)—at 18 months along with booster dose of DPT/OPV
 - Third dose (2 lakhs IU)—at 2 years of age.

Medium-term strategies:

- i. Food fortification (salt, dalda)
- ii. Food supplementation

Long-term strategies:

- i. Improve intake of vitamin A in daily diet.
- ii. Nutritional health education to school children.

Treatment:

keratomalacia reflects very severe vitamin A deficiency and should be treated as medical emergency to reduce child mortality

1. Systemic:

Systemic treatment of xerophthalmia involve oral or intramuscular vitamin A

Multivitamin supplements and dietary sources of vitamin A are also administered.

Vitamin A doses:

Age > 1 year	—2 lakh IU on days 0,1,14.
Age 6 months to 1 year	—1 lakh IU on days 0,1,14.
Age < 6 months	—50,000 IU on days 0,1,14.

2. Local:

- i. Intense lubrication
- ii. Topical retinoic acid may promote healing but is not sufficient without systemic supplements
- iii. Emergency surgery for corneal perforation may be necessary.

10. What are the objectives of vision 2020? What are eye diseases covered under the same?

Vision 2020: The right to sight

It is a global initiative launched by WHO, in Geneva on February 18, 1999 in a broad coalition with the international NGOs to combat the problem of blindness.

Objectives:

To intensify and accelerate present prevention of blindness activities so as to achieve the goal of eliminating avoidable blindness by the year 2020.

Implementation:

Through four phases of five year plans, the first one started in 2000.

Strategic approaches:

The five basic strategies of this initiative are:

- i. Effective disease prevention and control
- ii. Training of eye health personnel
- iii. Strengthening of existing eye care infrastructure
- iv. Use of appropriate and affordable technology
- v. Mobilization of resources

Priority diseases:

Globally five conditions have been identified for immediate attention for achieving goals of vision 2020. They are:

- i. Cataract
- ii. Trachoma
- iii. Onchocerciasis
- iv. Childhood blindness
- v. Refractive error and low vision

In Indian scenario in addition to aforementioned conditions, emphasis to be laid on

- glaucoma
- diabetic retinopathy
- corneal blindness.

11. Comment briefly upon National Programme for Control of Blindness (NPCB).

National Programme for Control of Blindness (NPCB) was launched in the year 1976. It is a 100% centrally sponsored scheme with the goal of reducing the prevalence of blindness to 0.3% by 2020. Rapid Survey on Avoidable Blindness conducted under NPCB during 2006–07 showed reduction in the prevalence rate of blindness from 1.1% (2001–02) to 1% (2006–07).

The main objectives of the program are:

- i. To reduce the backlog of blindness through identification and treatment of blind;
- ii. To develop comprehensive eye care facilities in every district;
- iii. To develop human resources for providing eye care services;
- iv. To improve quality of service delivery;
- v. To secure participation of voluntary organizations/private practitioners in eye care;
- vi. To enhance community awareness on eye care.

The program objectives are to be achieved by adopting the following strategy:

- i. Decentralized implementation of the scheme through District Health Societies (NPCB);
- ii. Reduction in the backlog of blind persons by active screening of population above 50 years, organizing screening eye camps and transporting operable cases to eye care facilities;

- iii. Involvement of voluntary organization in various eye care activities;
- iv. Participation of community and Panchayat Raj institutions in organizing services in rural areas;
- v. Development of eye care services and improvement in quality of eye care by training of personnel, supply of high-tech ophthalmic equipments, strengthening follow-up services and regular monitoring of services;
- vi. Screening of school age group children for identification and treatment of refractive errors, with special attention in under-served areas;
- vii. Public awareness about prevention and timely treatment of eye ailments;
- viii. Special focus on illiterate women in rural areas. For this purpose, there should be convergence with various ongoing schemes for development of women and children;
- ix. To make eye care comprehensive, besides cataract surgery, provision of assistance for other eye diseases like diabetic retinopathy, glaucoma management, laser techniques, corneal transplantation, vitreoretinal surgery, treatment of childhood blindness, etc.
- x. Construction of dedicated eye wards and eye OTs in District Hospitals in NE states and few other states as per need;
- xi. Development of mobile ophthalmic units in NE states and other hilly states linked with tele-ophthalmic network and few fixed models;
- xii. Involvement of private practitioners in sub-district, blocks and village levels.

12. What is the prevalence of corneal blindness? How much is the requirement of cornea?

Corneal blindness prevalence in

- i. India—6.8 million (out of which 1 million have bilateral corneal blindness) (i.e. vision < 6/60)
- ii. World—4.9 million
- iii. Corneal requirement in India is 3.5 million as against annual collection of donor corneas—20,000. 40,000 new cases of corneal blindness are added to this existing backlog.

Causes of corneal blindness:

Infective

- i. Trachoma
- ii. Infective keratitis
- iii. Onchocerciasis
- iv. Ophthalmia neonatorum
- v. Leprosy

Nutritional

- Vitamin A deficiency

Trauma

- Penetrating trauma
- Chemical injury

Inflammatory

- Mooren's ulcer
- Sjogren's syndrome

Inherited

- Stromal dystrophies
- Fuch's endothelial dystrophy
- CHED

Degenerative

- Keratoconus

Traditional eye medicines

- Milk, blood, saliva, dried plant powder.

13. Prevalence and causes of childhood blindness?

It is estimated that 1.5 million children suffer from severe visual impairment and blindness and, of these 1 million live in Asia.

Causes of childhood blindness

Hereditary : Chromosomal disorders, single-gene defects

Intrauterine : Congenital rubella, fetal alcohol syndrome

Perinatal : Ophthalmia neonatorum, retinopathy of prematurity, birth trauma

Childhood : Vitamin A deficiency, measles, trauma

Unclassified : Impossible to determine the underlying cause

14. Recommendations for screening of children for eye diseases.*At birth*

- i. Buphthalmos
- ii. Cataract
- iii. Ophthalmia neonatorum
- iv. Microphthalmia or anophthalmos
- v. Nystagmus
- vi. Squint
- vii. Retinopathy of prematurity

Pre-school

- i. Squint and amblyopia
- ii. Retinoblastoma
- iii. Vitamin A deficiency

School

- Refractive error

15. What is trachoma? How does it cause blindness?

Trachoma is a leading cause for blindness in developing countries in Africa. 6 million people are blind.

Trachoma is caused by *Chlamydia trachomatis*. Spread by fomites, house and flies.

It results in conjunctival scarring leading to entropion, trichiasis, secondary corneal infections and scarring.

Treatment:

- i. Tetracycline eye ointment BD for 6 weeks
- ii. Oral erythromycin, azithromycin

Prevention:

SAFE strategy:

- i. **S**urgery to correct lid deformity and prevent blindness
- ii. **A**ntibiotics to acute infections and community control
- iii. **F**acial hygiene
- iv. **E**nvironmental change

16. How does onchocerciasis spread? Its treatment?

Onchocerciasis is a parasitic infestation by *Onchocerca volvulus*, a filarial worm. Endemic in Africa, central America, Yemen.

Definitive host—man

Intermediate host—blackfly *Simulium*.

Blindness results from corneal scar, glaucoma, retinopathy and optic atrophy.

Treatment: Oral ivermectin 150 µg/kg body weight
Available as Mectizan 6 mg per tablet in market.

17. Functions of an eye bank?

- i. Promotion of eye donation
- ii. Registration of the pledger for eye donation
- iii. Collection of the donated eyes from the deceased
- iv. Receiving and processing the donor eyes
- v. Preservation of the tissue for short, intermediate, long or very long term
- vi. Distribution of the donor tissue to the corneal surgeons
- vii. Research activities

18. Contraindications to the use of donor cornea?

A. *Systemic:*

Conditions potentially hazardous to eye bank personnel and fatal, if transmitted

- a. AIDS or HIV seropositivity
- b. Rabies
- c. Active viral hepatitis
- d. Creutzfeldt-Jacob disease

Other contraindications

- i. Subacute sclerosing panencephalitis
- ii. Progressive multifocal leukoencephalopathy

- iii. Reye's syndrome
- iv. Death from unknown cause including unknown encephalitis
- v. Congenital rubella
- vi. Active septicemia including endocarditis
- vii. Intravenous drug abusers
- viii. Leukemia
- ix. Lymphoma and lymphosarcoma

B. Ocular:

- a. Intrinsic eye disease
 - Retinoblastoma,
 - Active inflammatory diseases
 - Congenital abnormalities
 - Central opacities
 - Pterygium
- b. Prior refractive procedures
 - Radial keratotomy scars
 - Lamellar inserts
 - Laser photoablation
- c. Anterior segment surgical procedures

Case Sheet Writing

The following description attempts to train a resident in describing various abnormalities of the fundus in a case of diabetic retinopathy.

Fundus of Mr C aged 70 years.

High risk PDR with CSME (Right eye)

Fundus examination of the right eye:

Distant direct ophthalmoscopy at one arms distance showed a good red glow.

Direct ophthalmoscopy close to face revealed a clear media.

Disk was, vertically oval, normal in size, pink in color, with well-defined margins and having a cup disk ratio of 0.3 with a healthy neuroretinal rim.

Vessels arise from the center of the disk, branching dichotomously maintaining an arterio-venous ratio of 2:3.

Fine, lacy frond of vessels occupying one clock hour area of the disk superiorly and 3 o'clock hours inferonasally suggestive of neovascularization of the disk are noted.

A whitish, elevated semilunar shaped fibrous band about 1 disk diameter inferonasal to the disk containing fine tufts of vessels suggestive of neovascularization elsewhere is seen.

Background retina shows numerous red pinhead shaped lesions not continuous with the blood vessels suggestive of dot hemorrhages in all four quadrants.

A single streak shaped red lesion at the inferotemporal margin of the disk suggestive of a flame shaped hemorrhage is seen.

A tortuosity of the vein in the superotemporal arcade suggestive of venous looping is seen.

Localized caliber changes of the veins in the superonasal and superotemporal arcades suggestive of venous beading is seen.

Yellowish, waxy lesions with distinct margins suggestive of hard exudates arranged in clumps at the posterior pole, inferior, nasal and temporal to the fovea with adjacent retinal thickening are seen.

A dark red, well defined accumulation of blood in the inferior retina obscuring the view of the underlying retinal vasculature suggestive of a vitreous hemorrhage is seen.

On slit lamp biomicroscopy with a +90D lens retinal thickening is seen at the macular area and the above findings are confirmed. Indirect ophthalmoscopy showed the peripheries to be normal.

Fundus examination of the left eye:

Diagnosis: Severe NPDR with CSME

Distant direct ophthalmoscopy at one arms distance showed a good red glow.

Direct ophthalmoscopy close to face revealed a clear media.

Disk was normal in size, vertically oval, pink in color, with well-defined margins and having a cup disk ratio of 0.3 with a healthy neuroretinal rim.

Vessels arise from the center of the disk, branching dichotomously maintaining an arterio-venous ratio of 2:3.

Background retina shows numerous pinhead shaped red lesions suggestive of dot and blot hemorrhages in all four quadrants.

A streak shaped red lesion inferior to the fovea suggestive of a flame shaped hemorrhage is seen.

Yellowish, waxy lesions with distinct margins arranged in clumps along the superior and inferior temporal arcades suggestive of hard exudates are seen.

A yellowish lesion with distinct margins, 2 disk diameter (DD) from the temporal disk margin, surrounded by an area of retinal thickening suggestive of a hard exudates plaque is seen.

A yellowish fluffy lesion with indistinct margins inferior to the disk suggestive of a cotton wool spot is seen.

A few atrophic hypopigmented chorioretinal scars along the inferotemporal arcade suggestive of old laser marks are seen.

On slit lamp biomicroscopy with a +90D lens, the above findings are confirmed. Indirect ophthalmoscopy showed the peripheries to be normal.

Examination of a long case: Proptosis

Guidelines

1. Duration of the complaints should be in chronological order.
2. Elaboration of the complaint should have an onset (insidious, sudden, etc.) and a progress mode (rapid, slow, etc.) and any relieving nature (e.g. pain relieved with closing the eyes).

Mr M, a 57-year-old male, farmer by occupation, hailing from Madurai presented to us with complaints of:

- Prominence of right eye of 4 months duration.
- Swelling and pain of right eye of 1 month duration.

History of present illness

The patient was asymptomatic till 4 months back when he noticed prominence of right eye which was insidious in onset, progressive in nature and more worse in the morning. The prominence was associated with mild discomfort and dryness of the right eye. He consulted a local ophthalmologist and was prescribed some eye drops which provided some symptomatic relief.

The patient then developed swelling of right eye of both upper and lower lid associated with pain and redness of the right eye which was progressive in nature and worse in the morning. The pain was dull aching in nature more of retrobulbar discomfort, typically described by the patient as something pushing behind the eye. The pain was non-radiating, present both at rest and with movements of the eye.

The above symptoms were associated with gritty foreign body sensation of both eyes.

H/o loss of weight with good appetite associated with increased sweating, tremors and palpitations since past 2 years.

He gives h/o swelling in the neck for past two years.

No h/o diplopia.

No h/o defective vision or blackouts or transient loss of vision or defective color perception.

No h/o hyperpigmentation of lids/eyes.

No h/o postural variation (bending forwards).

No h/o variation with sneezing or coughing or straining.

No h/o photophobia, discharge or colored halos.

No h/o any other swelling in the body.

No h/o dysphagia, dysphonia, easy fatigability, drooping of eyelids.

No h/o radiation therapy or chemotherapy in the past.

No h/o skin discoloration in the past.

No h/o fever, headache, nausea, vomiting.

No h/o nasal block, frequent respiratory tract infection, epistaxis.

No h/o trauma.

Past history

H/o taking tablet Carbimazole 5 mg BD for past 2 years.

No h/o diabetes mellitus, hypertension, cardiac disease.

Personal history

Patient consumes mixed diet.

He is a chronic smoker, consumes average of 6–7 cigarettes per day.

He occasionally consumes alcohol.

Family history

No h/o similar complaints in the family.

General examination

Patient is averagely built and nourished.

Pulse—90/minute, regular in rhythm and volume.

Respiratory rate was 18/minute.

Blood pressure was 130/80 mm Hg taken in left upper arm in the supine position.

Higher functions are normal.

No pallor, cyanosis, icterus and clubbing.

No evidence of any regional or generalized lymphadenopathy.

No evidence of any skin changes or dryness.

Examination of the neck revealed small midline swelling 3 × 5 cm which moved with deglutition and did not move with protrusion of the tongue suggestive of a thyroid swelling.

Fine tremors were noted when the patient was asked to stretch his arms and spread out his fingers.

Tremors were not present at rest.

There was no evidence of dysdiadochokinesia and finger.

Nose past pointing test was negative.

Central nervous system was within normal limits. There was no signs of confusion or dementia, lethargy.

Cardiovascular system was normal without any murmurs.

Respiratory system examination revealed normal vesicular breath sounds in both lungs on auscultation.

Per abdominal examination was normal with no evidence of any palpable intra-abdominal mass.

ENT examination—anterior rhinoscopy was normal with no evidence of sinus tenderness.

Ocular examination

Visual acuity in both eyes is 6/12p improving to 6/6 with +1.50D sphere with 2.50D sphere for near vision.

	Right eye	Left eye
	Axial proptosis	Normal
Lids	Periorbital edema	Normal
Conjunctiva	Congestion nasally and temporally, mild chemosis, decreased tear film height, decreased tear film breakup height (<10 seconds)	Normal
Cornea	Few punctate epithelial erosions	Clear
Anterior chamber	Normal depth	Normal depth
Iris	Normal color and pattern	Normal color and pattern
Pupil	4 mm, briskly reacting to both direct and consensual light reflex	4 mm, briskly reacting to both direct and consensual light reflex
Lens	Clear	Clear
EOM	Full	full
Fundus	Normal	Normal

The above findings were confirmed with slit lamp biomicroscopy and fundus examination with 90D examination revealed normal findings with no evidence of Sallmann macular folds.

EVALUATION OF PROPTOSIS

- Head posture is normal
- Facial asymmetry is present
- Corneal reflex: Eyes are orthophoric.

Inspection

- Axial proptosis of the right eye is noted
- Nafziger's sign (protrusion of the eye beyond the orbital rim when examined from above and behind the patient) was positive on the right side.
- On inspection, eyebrows were normal with no evidence of madarosis.
- Lids revealed periorbital edema of both upper and lower lids.

Right eye:

Inspection:

- In the right eye, lid margins were 3 mm from the superior and inferior limbus suggestive of moderate lid retraction
- Temporal flare was present

- Lid lag was present on downgaze.
- There was minimal lagophthalmos with good Bell's phenomenon in the right eye.
- No variation of proptosis was observed in the right eye with posture especially on bending forwards and with Valsalva's maneuver.
- The proptosis was nonpulsatile.
- There was no evidence of engorged veins/corkscrew vessels in the right eye.

Palpation

- Orbital margins were intact
- Insinuation with fingers was possible in all four margins
- Resistance to retropulsion was present
- Proptosis was noncompressible and nonreducible
- No thrills or pulsations felt
- There was no evidence of warmth or tenderness over the right eye
- No change in the size of the proptosis with jugular vein compression or carotid artery compression.

Left eye

Inspection

- Temporal flare was present
- Lid margins were 1 mm from superior limbus and 2 mm from inferior limbus respectively suggestive of mild lid retraction.
- Lid lag was present on downgaze.
- There was minimal lagophthalmos with good Bell's phenomenon.

Palpation

- Orbital margins were intact.
- Resistance to retropulsion was present.

Auscultation

- No bruits were heard in both eyes.

MEASUREMENTS

Hertel's exophthalmometry (base at 105)

- Right eye — 22 mm
- Left eye — 18 mm

Applanation tonometry

- Tension by applanation tonometry was 16 mm Hg in the right eye and 18 mm Hg in the left eye in primary gaze.
- Tension by applanation tonometry was 26 mm Hg in the right eye and 24 mm Hg in the left eye in upgaze.
- **Schirmer's test:** At the end of 5 minutes revealed 12 mm of Whatmann's strip wetting in the right eye and 15 mm in the left eye suggestive of mild dry eye.

- Color vision testing with Ishihara's pseudoisochromatic plate was normal in both eyes.
- Central fields testing with Bjerrum's screen was normal in both eyes.
- Anterior rhinoscopy was within normal limits. Sinus examination was normal.

PROVISIONAL DIAGNOSIS

Right eye unilateral axial proptosis due to acute inflammatory stage of thyroid related orbitopathy.

DIFFERENTIAL DIAGNOSIS

1. Thyroid related orbitopathy
2. Cavernous hemangioma
3. Idiopathic inflammatory pseudotumor
4. Orbital cellulitis

Frequently Asked Questions during Presentation

1. What is the rationale for asking history of radiation therapy or chemotherapy in the past?

To rule out any neoplasm elsewhere in the body which might have metastasized to the orbit.

2. What is the rationale for asking history of skin discoloration in the past?

To rule out thyroid related skin changes (thyroid myxedema) and also eurofibromatosis (pigmented birthmarks).

3. What is the rationale for asking history of hyperpigmentation of lids/eyes?

To rule out metastatic neuroblastoma (raccoon eyes).

4. What is the rationale for asking history of fever, headache, nausea, vomiting?

To rule out orbital cellulitis, cavernous sinus thrombosis .

5. What is the rationale for asking history of nasal block, frequent respiratory tract infection, epistaxis?

To rule out sinusitis and nasopharyngeal carcinoma.

6. What is the rationale for asking history of trauma?

To rule out orbital hematoma and retrobulbar hemorrhage in cases of acute proptosis.

7. What is the rationale for asking history of dysphonia, dysphasia, easy fatigability in a patient with proptosis?

To rule out associated myasthenia gravis.

THIRD NERVE PALSY—MODEL CASE SHEET

Mr G, a 52-year-old male came with the chief complaints of double vision for the past 5 days.

History of present illness:

- He was asymptomatic till 5 days ago, when he experienced sudden double vision when he was leaving for work. It was acute in onset, present binocularly, with progressive and horizontal separation of images.
- There was no diurnal variation and, not increasing in any particular gaze.
- He noticed some restricted movement of the right eye, but was not associated with pain.
- He was also able to appreciate that while occluding either eye the diplopia subsided.

No drooping of eyelids/defective vision or any history suggestive of defective field of vision.

- No h/o headache/vomiting
- No h/o fever/trauma/surgery
- No h/o diurnal variation
- No h/o weakness of one side of face/limb weakness/tremors
- No h/o mental/sleep disturbances
- No h/o anosmia/hard of hearing/nasal regurgitation/nasal twang
- No h/o altered bowel/bladder habit
- No h/o scalp tenderness/jaw claudication
- (In children—rule out post vaccination)

PAST HISTORY:

No similar episodes in the past.

Medical treatment history:

- He gives history of diabetes mellitus for the past 8 years, and is on irregular medications.
- He also gives history of systemic hypertension for the past 5 years and on irregular medications.
- No h/o surgeries in the past.

PERSONAL HISTORY:

- Non-smoker/non-alcoholic
- Normal bowel and bladder habits
- Consuming a balanced diet.

GENERAL EXAMINATION:

- Conscious, oriented to place and time
- Moderately built and nourished
- No pallor
 - Icterus
 - Cyanosis

Clubbing
Lymphadenopathy
Pedal edema

VITALS:

- Afebrile
- Pulse—80 beats/min—regular rhythm, with normal volume and character.
- Blood pressure—140/90 mm Hg recorded in supine position over the left arm.
- Respiratory rate—18 mm times/min.

SYSTEMIC EXAMINATION:

- CVS—S1 S2 + heard. No murmurs
- RS—Normal vesicular breath sounds heard. No added sounds.
- Abdomen—soft. No organomegaly.

OCULAR EXAMINATION:

1. Best corrected visual acuity 6/9 in both eyes
(Distance)
(Near) N6 at 33 cms with +2.0 DS.
2. No characteristic head posture noted
3. Hirschberg's test revealed 30' exotropia in the (RE)
4. On torchlight examination:

	Right eye	Left eye
Lids/Adnexa	Normal	Normal
Conjunctiva	Normal	Normal
Cornea	Clear	Clear
Anterior chamber	Normal depth	Normal depth
Iris	Normal color pattern	Normal color pattern
Pupil	3 mm round-D+-C+	3 mm round-D+-C+
Accommodation reflex present		
Lens	Early lens changes	Early lens changes

5. Extraocular movements: RE
Restricted adduction, elevation and depression.
Abduction is present
Intorsion is present
The movements of the left eye are normal.
6. The above findings were confirmed using a slit-lamp biomicroscopy with additional inference of
(BE) - lens—Grade I nuclear sclerosis

7. Fundus examination
 - i. Using a direct ophthalmoscope:
Revealed a clear media, with normal disk and vessels, with a healthy macula FR +/-
The above findings were confirmed using a slit-lamp biomicroscopy and 90D lens
The peripheries were examined using an indirect ophthalmoscope and 20D lens were found to be normal.
8. Corneal sensations (BE)—normal
9. Color vision (BE)—Normal (using Ishihara's chart)
10. Tension (BE) by non-contact tonometer—16 mm of Hg
11. No signs of aberrant regeneration.
12. Examination of other cranial nerves:
 - i. Olfactory nerve
 - ii. Optic nerve
 - iii. Trigeminal nerve
 - iv. Facial nerve
 - v. Vestibule cochlear nerve
 - vi. Glossopharyngeal nerve
 - vii. Vagus nerve
 - viii. Accessory nerve
 - ix. Hypoglossal nerve
13. Motor system examination—normal
14. Sensory system examination—normal
15. Reflexes
 - i. Superficial
 - ii. Deep normal
16. Gait—Normal
17. Cerebellar function tests—Normal

DIAGNOSIS:

Right eye, pupil sparing, infranuclear incomplete 3rd nerve palsy, due to an ischemic microangiopathy with probable etiology being DM/HM.

Explanation to the history taking and examination of the model case sheet

1. Diplopia:

- Onset—acute, subacute, insidious in onset
- Progression—progressive/or regressive
Progressive—all neoplasms, myasthenia, TRO
Regressive—inflammatory, infection causes.
- Horizontal/Vertical –
Horizontal diplopia—lateral rectus/medial rectus involved
Vertical diplopia—elevators/depressors involved.
- Diplopia for near or far –
Near: Trochlear nerve is involved.
Far: Abducent nerve is involved.

- Increases in which gaze—diplopia increases on looking towards the side of paralyzed muscle
- Diurnal variation—to rule out myasthenia gravis
- Diplopia worsens in the evening: Myasthenia gravis
- Diplopia worsens in the morning: Thyroid orbitopathy due to venous stasis and accumulation of glycosaminoglycans.

2. Conditions causing ophthalmoplegia + pain

- Tolosa-Hunt syndrome
- Giant cell arteritis
- Retrobulbar neuritis
- Migraine
- Carotico-cavernous fistula
- Intrinsic lesions of 3rd nerve—Schwannomas/cavernous hemangiomas.

3. History of drooping of lids

To know the involvement of LPS—to differentiate a nuclear from an infranuclear palsy.

4. History of defective vision

Orbital apex syndrome—optic nerve is affected.

5. History of defective field of vision

To know the status of cortical function.

6. Negative history:

- H/o headache/vomiting signs of raised intracranial tension.
- H/o fever/fits to rule out typhoid/tick fever/glandular fever.
- H/o trauma/surgery lumbar puncture can predispose to uncal herniation syndrome/other FESS and neurosurgeries too.
- H/o diurnal variation myasthenia/TRO.
- H/o weakness at one side of face/limb weakness/tremors (to rule out involvement of other cranial nerves and the syndromes associated with 3rd nerve palsy)
- H/o epistaxis (raised blood pressure)
- H/o vesicular eruption on one side of face—herpetic ophthalmoplegia can predispose to 3rd nerve palsy.
h/o anosmia/nasal regurgitation/nasal twang—to rule out involvement of other cranial nerves.
- H/o altered bowel/bladder habits—(involvement of autonomic nervous system).
- H/o scalp tenderness/jaw claudication—giant cell arteritis
- For children—can cause post vaccination neuritis (R/o past vaccination).

7. Significance of medical treatment history?

- Diabetes mellitus and systemic hypertension are the most common causes of pupil sparing 3rd nerve palsy.

8. History of smoking and alcoholism?

Smoker—Predisposed to thromboembolism

Alcoholic—Wernicke's encephalopathy/trauma

9. Importance of contact to tuberculosis?

Tuberculous meningitis can predispose to 3rd nerve palsy.

10. Relevance of fundus examination?

- Look for papilledema

11. Causes of decreased corneal sensations?

- Herpes simplex keratitis
- Neuroparalytic keratitis
- Leprosy
- Herpes zoster ophthalmicus
- Absolute glaucoma
- Acoustic neuroma
- Neurofibroma.

12. Examination of other cranial nerves:

- i. **Olfactory**—Using asafetida, coffee, beans, check each nostril separately.

Optic nerve—Visual acuity

Pupil examination

Visual fields

Color vision

- ii. **Trigeminal nerve**—motor muscles of mastication/jaw deviates towards paralyzed side

Sensory—Corneal sensations

Sensations over face.

- iii. **Facial nerve**—motor—orbicularis oculi

Wrinkling of forehead orbicularis oris (whistling) smile and dense (mouth deviated to healthy side) inflate mouth with air.

Sensory—test in anterior 2/3 of tongue.

- iv. **Vestibule cochlear:**

For cochlear function use 512 Hz because higher frequency—less accurate in finding difference between air/bone conduction.

Lower frequency—vibrations produced may be misinterpreted as sound.

Rinne's test: Normal sensory neural hearing loss—lateralized to normal ear conductive loss—lateralized to deaf ear.

For vestibular functions we check:

- Nystagmus
- Positional vertigo
- Romberg's test.

- x. **Glossopharyngeal nerve**—taste in post 1/3rd of tongue palatal reflex.

- xi. **Vagus**—Gag reflex

- xii. **Spinal accessory nerve**—sternomastoid/trapezius muscle

- xiii. **Hypoglossal nerve**—tongue deviates to paralyzed side.

GLAUCOMA—MODEL CASE SHEET

A fifty-six-year-old gentleman came to us for complaints of:

Defective vision of the right eye (RE)—1 year duration and left eye (LE) of 6 months duration.

History of present illness:

On elaboration, he revealed he had been suffering from defective vision for the past 1 year. He had consulted an ophthalmologist at his place who said he had raised pressures in both his eyes, and put him on topical medications, twice a day regime for both his eyes. He was not compliant to his medicines, and on his follow-up visit, his doctor had advised surgery for his right eye. He underwent the surgery to reduce his eye pressures. He feels that vision is unsatisfactory in both his eyes and has come for a second opinion.

No history of night blindness

No h/o frequent change of glasses

No h/o headache

No h/o colored haloes

No h/o redness/watering/pain

No h/o injury/trauma

Past history:

Known diabetic for the past 15 years on oral hypoglycemic agents and an asthmatic on inhalational therapy whenever symptomatic.

Apart from the medications which he has been using for both his eyes, twice daily for the past 1 year and surgery to lower pressure in his right eye 6 months back, there is no other medical or surgical history.

Personal history:

Smoker, smokes 2–3 beedis per day for the past 30 years.

Not an alcoholic.

Family history:

No history of diabetes or ocular diseases amongst/among the family members.

GENERAL EXAMINATION:

Well built and nourished.

Pulse rate—76/minute, regular in rhythm and volume.

Blood pressure—130/70 mm of Hg

Cardiovascular, respiratory and central nervous system examination within normal limits.

OCULAR EXAMINATION

	Right eye	Left eye
Distance		
Unaided vision	6/60	6/24
With pin hole	6/12	6/9
Near vision	N8 at 33 cm with +2D	N6 at 33 cm with +2D

No facial asymmetry

	Right eye	Left eye
Lids and adnexa	Normal	Normal
Conjunctiva	A flat, diffuse translucent bleb, extending from 11 o'clock to 2 o'clock position superiorly above the limbus, with dilated tortuous vessels over its surface and subconjunctival fibrosis obscuring the underlying details was seen	Normal
Cornea	Clear	Clear
Anterior chamber	Normal in depth centrally and in the periphery	Normal in depth centrally and in the periphery
Iris	A single, peripheral triangular defect measuring 2 mm in size seen superiorly at the 12 o'clock position close to the limbus, suggestive of a surgical iridectomy is seen. Retroillumination was positive.	Normal in color and pattern
Pupil	4 mm, round and reacting sluggishly to light, with grade 3 RAPD	Normal in size and shape, reacting well to direct, indirect being slightly sluggish
Lens	Nuclear sclerosis, grade 2	Nuclear sclerosis, grade 2
EOM	Full	Full

FUNDUS EXAMINATION

	Right eye	Left eye
Media	Clear	Clear
Disk	Vertically oval disk with well-defined margins. Cup disk ratio was 0.9 with a diffuse, circumferential loss of neuroretinal rim. Bayonetting of vessels and laminar dot sign was present. Surrounding nerve fiber layer seen with the help of a red free filter showed a diffuse loss of RNFL	Vertically oval disk with well-defined margins. Cup disk ratio being 0.75 with a focal notching superior and corresponding thinning of neuroretinal rim was seen. An arcuate defect was seen superiorly in the nerve fiber layer with the help of a red free filter corresponding to the superior notch
Posterior pole	Foveal reflex present and background retina was normal	Foveal reflex was present and background retina was normal

GONIOSCOPY:

Right eye	Left eye
Trabecular meshwork seen in all four quadrants with a patent ostium and peripheral iridectomy seen superiorly	Trabecular meshwork seen in all four quadrants

INTRAOCULAR PRESSURES:

Recorded with Goldmann's applanation tonometer showed

Right eye	Left eye
26 mm of Hg	24 mm of Hg

DIAGNOSIS:

Right eye: Primary open angle glaucoma status post trabeculectomy with failed bleb and grade 2 nuclear sclerosis.

Left eye: Primary open angle glaucoma and grade 2 nuclear sclerosis.

1. Why do we ask for history of night blindness?

- i. Defective dark adaptation is a feature of open angle glaucoma
- ii. Use of miotics will accentuate night blindness.

2. What is the cause for frequent change of glasses?

- i. Patients experience more difficulty for near vision since constant high pressure over zonules and ciliary body impairs accommodation
- ii. Patients tend to confuse defective field of vision with defective vision and hence repeatedly change glasses

3. What can cause sudden loss of vision in a glaucoma patient?

- i. Acute IOP rise resulting in corneal edema
- ii. Central retinal vein occlusion
- iii. Post trabeculectomy in advanced glaucoma—snuff out phenomena

4. What are the structural abnormalities you will look for in a case of glaucoma?**i. Lids and Adnexa:**

- i. Hemangioma (Sturge-Weber)
- ii. Hypertrichosis (Use of latanoprost)
- iii. Periocular pigmentation (Use of epinephrine)

ii. Conjunctiva:

- i. Dilated tortuous episcleral vessels (Sturge-Weber)
- ii. Bleb (Location, extent, presence of microcysts, vascularity, visibility of scleral flaps, infection, presence of aqueous leak, subconjunctival fibrosis)
- iii. Circumcorneal congestion (In acute congestive glaucoma)

iii. Cornea:

- i. Edema
- ii. Descemet's folds
- iii. Keratic precipitates
- iv. Pigments on the endothelium (Krukenberg's spindle in pigmentary glaucoma)
- v. Pseudoexfoliation on the endothelium
- vi. Prominent Schwalbe's line—congenital glaucoma
- vii. Peripheral anterior synechiae
- viii. Megalocornea
- ix. Cornea plana
- x. Sclerocornea
- xi. Congenital corneal opacity (Peter's anomaly)
- xii. Prominent corneal nerves (Neurofibromatosis)

iv. Anterior chamber

- i. Depth—peripheral and central
- ii. Reactions—flare and cells
- iii. Hyphema
- iv. Hypopyon

v. Iris

- i. Aniridia
- ii. Atrophic patches (following acute attack)
- iii. Nodules
- iv. Holes
- v. Pseudoexfoliation material
- vi. Transillumination defects
- vii. Peripheral iridectomy (number, position, patency, surgical/laser)
- viii. Iris cysts
- ix. Nevus
- x. Ectropion uvea

vi. Pupil:

- i. Size
- ii. Shape
- iii. Number
- iv. Reaction to light—direct and indirect
- v. Resistant to dilatation
- vi. Seclusion or occlusion papillae

vii. Lens

- i. Pseudoexfoliation on anterior lens capsule
- ii. Glaucomflecken
- iii. Cataract—intumescent/dislocated/subluxated
- iv. Zonular dialysis
- v. Spherophakia

5. What are the management strategies for the following scenarios?**1. PRIMARY OPEN-ANGLE SUSPECT***Baseline investigations:*

1. Tension applanation
2. Central corneal thickness
3. Baseline fundus photo
4. Nerve fiber analysis-GDx
5. HFA-SITA SWAP—glaucoma progression analysis
6. OCT-macular thickness analysis, i.e. ganglion cell complex

Treatment:

- i. Observe the patient if no risk factors.
- ii. Follow-up after two months. If progression is documented, start antiglaucoma therapy.

2. ESTABLISHED PRIMARY OPEN-ANGLE GLAUCOMA*Baseline investigations:*

1. Tension applanation
2. Central corneal thickness
3. Baseline fundus photo
4. Nerve fiber analysis—GDx (role controversial in established glaucoma)
5. HFA-24-2
6. OCT—macular thickness analysis, i.e. ganglion cell complex

Treatment:

- i. Calculate the target pressure: This is done using the following formula

$$TP = IP (1 - IP/100) - Z \pm 2$$

where: TP = target pressure

IP = initial pressure

Z = functional status

(disk damage/field changes)

Z-0 Glaucoma suspect (Low risk)

Z-0 Glaucoma suspect (High risk)

- Z-1 *Early glaucoma*
- Z-3 *Moderate glaucoma*
- Z-5 *Severe glaucoma*
- Z-7 *End-stage glaucoma*

- ii. Start on single drug therapy (Prostaglandin analogs are the first choice or else beta-blockers, alpha adrenergic agonists can be started).
- ii. Review after 2 months and see if target pressure is maintained. If not consider substituting or adding another drug.
- iii. Follow-up, and in spite of maximal tolerated medical therapy if the pressures are still not under control, then consider trabeculectomy.

3. POAG WITH SIGNIFICANT CATARACT

The following considerations should be taken into account while performing surgery in a glaucoma patient:

- Miotic pupils
- Posterior synechiae
- Exfoliation—zonular weakness
- Congested eyes—bleeding
- Prior surgery—scarring/filtering bleb
- Systemic diseases—diabetes, hypertension
- Ocular conditions—myopia, shallow chamber
- Increased incidence of postoperative IOP rise
- Suprachoroidal hemorrhage

A. Cataract alone can be performed in the following scenario:

- Acceptable IOP control with one or two medications
- No significant visual field loss or disk damage
- Older age
- Conditions where compliance and drug intolerance are not an issue
- Higher target IOP

Advantages of doing cataract alone:

- Single procedure
- Technically easier
- Short surgical time
- Reduced operative and postoperative complications
- Temporal clear corneal approach enables preserving viable conjunctiva

Disadvantages of doing cataract alone:

- Early postoperative spike of intraocular pressure
- Long term IOP control questionable
- Subsequent filtering surgery prone for failure

B. Combined surgery (Cataract and filtering surgery) can be performed in the following scenario:

- Multiple medications required to control IOP
- Use of glaucoma medications restricted by cost, intolerance, compliance issues

- Significant glaucomatous visual loss
- Presence of ocular risk factors—exfoliation, pigment dispersion, angle recession
- Monocular status—earlier visual recovery
- Two separate procedures not feasible

Advantages of combined surgery:

- Restore vision promptly
- Single procedure
- Reduced glaucoma medications
- Early postoperative IOP control
- Long term IOP control
- Antimetabolite use possible to enhance success
- Facilitate assessment of disk and visual fields

Disadvantages of combined surgery:

- More complications—shallow chamber, bleb leak, choroidal effusion/hemorrhage, hypotony, infection, astigmatism
- Visual recovery longer than in cataract alone
- Intensive postoperative care requirements than cataract alone
- Less IOP control than filtering surgery alone—success of filtering compromised by filtering surgery
- Glaucoma medications postoperative

Index

A

- Abdominal
 - cramps 256
 - discomfort 254
- Abducens nerve palsy 500
- Abetalipoproteinemia Bassen-Kronzweig syndrome 405
- Abiotrophy 402
- Ablation of peripheral retina 97
- Abrupt elevation of limbal conjunctiva 299
- Absence of
 - blood vessels 125
 - lymphatics 125
- Absolute glaucoma 207
- Acanthamoeba* keratitis 72, 77, 83
- Acetaminophen 20
- Acetazolamide 24
- Achromatopsia 11
- Acid-fast organism 66
- Acquired
 - diseases of connective tissue 352
 - neoplasm 562
 - syphilis 80
- Acridine orange 67, 73
- Actinic dermatitis 550, 554
- Actinomyces 390
- Action of
 - amphotericin 69
 - biguanides 74
 - diamidines 74
 - imidazoles 69
- Active retinitis 139
- Acute
 - angle closure glaucoma 267
 - anterior uveitis 165
 - congestive
 - attack 206
 - glaucoma 367
 - stage of primary angle closure glaucoma 223
 - generalized uveitis 139
 - hemolytic anemia 480
 - hydrops 99
 - infectious keratitis 125
 - intermittent porphyria 469
 - lymphocytic leukemia 160
 - myeloid leukemia 582
 - orbital cellulitis 386
 - pertussis 160
 - posterior uveitis 138
 - retinal necrosis syndrome 154
 - rise of IOP 91
 - severe
 - blood loss 480
 - iridocyclitis 148
 - trauma 51
 - viral infections 160
- Acyclovir 20
- Addison's disease 159, 160
- Adenine arabinoside 20
- Adenochrome 63, 64
- Adenoid squamous carcinoma 95
- cell carcinoma 95
- Adenovirus 77
- Adherent leukoma 91
- Adie's
 - pupil 6
 - tonic pupil 61
- Adrenal insufficiency 176
- Advantages of
 - direct ophthalmoscope 35
 - indirect ophthalmoscopy 37
- Age-related macular degeneration 317, 414
- Agranulocytosis 254
- Alexander's law 516
- Alkylating agents 22
- Allergic disorders 159
- Allergic
 - blepharoconjunctivitis 253
 - reactions 291
- Allergy 251
- Alopecia 140
- Alpha-interferon therapy 227

- Alport's
 - disease 123
 - syndrome 309
- Alstrom syndrome 404
- Altered corticosteroid metabolism 214
- Alternate cover test 613
- Altitudinal pallor 471
- Amaurosis fugax 483, 532
- Amikacin 18, 19, 68
 - sulfate 396
- Aminoglycosides 74
- Aminoguanidine 24, 263, 264
- Amiodarone 63, 310
- Amniotic membrane transplantation 120
- Amount of ptosis 562
- Amphotericin 69
 - B 19
- Ampicillin 18, 397
- Amputation of sclera flap 285
- Amyloidosis 587
- Amyloid theory 236
- Amyotrophic lateral sclerosis 508
- Analysis of color signals in visual cortex 12
- Anamalous trichromatic color vision 11
- Anecortave acetate 420
- Anemia 459, 483
 - in childhood 46
- Angina 256
- Angiographic classification 416
- Angioid streaks 377, 418
- Angioneurotic edema 580
- Angioprotein 428
- Angle
 - closure glaucoma 201, 203, 222, 235
 - recession 190, 202
 - glaucoma 230
- Aniridia 101, 247, 309
- Anisocoria 229
- Ankylosing spondylitis 137-139
- Anomalous head posture 496
- Anophthalmos 45
- Antazoline 265
- Anterior
 - and posterior walls of frontal sinus 42
 - border layer 152
 - chamber 14, 391
 - depth 202
 - hemorrhage 131
 - installation 298
 - paracentesis 366
 - choroid 369
 - clinoid process 40
 - ethmoidal nerve 60
 - hyaloidotomy 266
 - hyaloids face of vitreous 237
 - ischemic optic neuropathy 323, 480
 - lamella 548
 - lamellar keratoplasty 126
 - limbal border 14
 - orbitotomy 594
 - segment
 - angiography 324
 - indications 422
 - ischemia 304, 386, 483
 - OCT 211
 - staphyloma 92
 - stromal puncture 116, 120
 - subTenon 173
 - synechiae 70, 126, 131
 - uveitis 134-136, 189, 190
 - wall of middle cranial fossa 42
- Antibiotics 18
- Anticholinesterases 249
- Antiglaucoma medications 22
- Anti-infectives dosage 18
- Anti-inflammatory drugs 20
- Antineutrophil cytoplasmic antibody 85
- Antinuclear antibodies 85
- Anuria 256
- Aphakic glasses 399
- Aplasia 487
- Aplastic anemia 254
- Apoptosis inhibitors 263
- Applanation tonometry 31
- Application of distant direct ophthalmoscopy 33
- Apraclonidine 23
- Aqueous
 - humor 14
 - suppressants 246
- Acquired color blindness 11
- Arachnodactyly 309

- Arachnoid cyst 45
 - Arachnoiditis 43
 - Arcus senilis 88
 - Argon laser
 - photocoagulation 59
 - trabeculoplasty 231
 - Arterial
 - aneurysm 44
 - hypertension 313
 - Arteriolar
 - attenuation 400
 - narrowing 401
 - Arteriosclerosis 400, 500
 - Arteriovenous crossing changes 352
 - Artery compresses vein 355
 - Arthritis 140
 - Aseptic
 - cavernous sinus thrombosis 529
 - necrosis of femur 177
 - Aspergillus*
 - flavus* 69
 - fumigatus* 69
 - Aspheric lens 36
 - Aspirin 20, 310
 - Assessment of
 - capsulopalpebral fascia 558
 - horizontal eyelid laxity 558
 - preseptal orbicularis muscle override 559
 - Asteroid hyalosis 321
 - Asthma 250
 - Astigmatic keratotomy 311
 - Astrocytic hamartoma 320
 - Asymmetric dyschromatopsia 218
 - Ataxic nystagmus 513
 - Atheroma 44
 - Atheromatous
 - ulcer 92
 - vascular diseases 365
 - Atherosclerosis 468
 - related thrombosis 363
 - Atopic keratoconjunctivitis 58, 101
 - Atrial natriuretic peptide 25, 262
 - Atrophic
 - iris 210
 - Tenon's capsule 287
 - Atropine 61
 - Autoimmune
 - diseases 160
 - disorders 83
 - Automated keratometer 57
 - Avellino
 - corneal dystrophy 108, 109
 - dystrophy 110
 - Axenfeld's anomaly 101
 - Axial myopia 310
 - Azathioprine 22
- B**
- Bacitracin 18
 - Backward extension of intraorbital mass 46
 - Bacterial
 - and fungal corneal ulcer 66
 - endophthalmitis 386
 - keratitis 83
 - Band
 - keratopathy 147, 210, 379
 - keratoplasty 81
 - shaped keratopathy 88
 - Bandage contact lens 93, 116
 - Basal
 - cell carcinoma 554
 - foramina 43
 - Basement membrane
 - of RPE 368
 - theory 236
 - Bausch and Lomb C series 103
 - Beam
 - angle 32
 - height 32
 - Behcet's
 - disease 156, 165, 356, 483
 - skin test 165
 - syndrome 148, 171
 - Behind Schwalbe's line 191
 - Behr's optic atrophy 470
 - Benedict's syndrome 490, 493
 - Benign
 - peripheral retinal degenerations 371
 - transient isolated 6th nerve palsy 504
 - Berke's method 563
 - Best depicts optic canal 48
 - Betamethasone 21
 - sodium phosphate ointment 21
 - solution 21

- Betaxolol 23, 251
 - Bevacizumab 419
 - Biconvex lens 36
 - Bielschowsky's head tilt test 496
 - Bietti's crystalline dystrophy 63, 113
 - Bilateral ptosis 566
 - Bilirubin 63
 - Bimatoprost 23, 255
 - Binocular single vision 1
 - tests 612
 - Birdshot
 - chorioretinopathy 148, 165, 175
 - choroidopathy 148
 - Birth trauma 115, 487
 - Bitemporal hemianopia 521
 - Bjerrum scotoma 195
 - Black reflex 33
 - Bleb infection/endophthalmitis 285
 - Blebitis 273
 - Bleeding diathesis 313
 - Blepharitis 290
 - Blepharophimosis syndrome 562, 576
 - Block of scleral tissue 278
 - Blockage of CSF flow 450
 - Blocked fluorescence 319
 - Blood 63
 - agar 69
 - aqueous barrier 221
 - dyscrasias 254, 357, 365
 - pressure 488, 492
 - staining 63
 - sugar 488
 - volume alteration 182
 - Blowout fracture 45
 - of orbit 597
 - Blue-field entopic phenomena 4
 - Blue-light endoscopy 310
 - Blunt trauma 380
 - Blurring of
 - disk margins 353, 472
 - vision 151
 - Boeck candy test 8
 - Bone
 - erosion 40
 - marrow suppression 160
 - Bony
 - lesions 51
 - pressure 471
 - Botulinum toxin 518, 606
 - Bowen's disease 94
 - Bowenoid epithelioma 94
 - Bowman's
 - layer 64, 102, 107
 - membrane 119
 - cauterization 120
 - Brachytherapy 97
 - Bradycardia 250
 - Brain
 - derived natriuretic peptide 25, 262
 - heart infusion 69
 - tumor 462
 - Brainstem syndrome 501
 - Branch retinal
 - artery 352
 - vein occlusion 323
 - Branches of nasociliary nerve 60
 - Branching of vessels 141
 - Brimonidine 23, 24, 259
 - Brinzolamide 23
 - Broad
 - spectrum kinase inhibitors 25
 - tangential illumination 27
 - Broken wheel test 8
 - Brow
 - ptosis 564
 - suspension ptosis repair 566
 - Browache 250
 - Brucellosis 160
 - Bruckner's test 612, 613
 - Buccal mucosa 561
 - Bulbar dysfunction 512
 - Bulky instrumentation 202
 - Bull's eye maculopathy 468
 - Bullous keratopathy 121
 - Buphthalmos 46
 - Burnt out stage 222
- C**
- Cake decoration test 8
 - Calcific band keratopathy 29, 63
 - Calcium
 - channel blocker 24, 259, 264
 - ionophores 283
 - Calcofluor white stain 73
 - Calculate magnification of image 39
 - Campbell's theory 230
 - Candida retinitis 148
 - Candidiasis 136
 - Candle wax drippings 146

- Cannabinoids 24, 259
 Canthal tendon integrity 550
 Capillary
 hemangioma 582
 tortuosity 353
 Capsaicin cream 79
 Capsular delamination 237
 Carbachol 22
 Carbenicillin 18
 Carbogen inhalation 366
 Carbon disulfide 61
 Carbonic anhydrase inhibitor 246,
 249, 257
 Carcinoma 44
 in situ 95
 Cardiac
 myxomas 365
 valvular 365
 Cardiff acuity cards 7
 Cardiovascular
 disease 357
 system 256
 Carotico-cavernous fistula 530
 Carotid
 angiography 535
 artery 41, 488
 disease 358, 480
 ligation 223
 obstruction 221
 occlusion 532
 cavernous fistula 46, 49, 179, 434,
 588
 duplex scanning 535
 dural branch-cavernous sinus
 fistula 488
 embolism 363
 occlusive disease 365
 Carteolol 23, 251
 Caspase inhibitors 24, 263
 Cataract 30, 47, 70, 73, 97, 152,
 153, 194, 250, 282, 285, 386,
 387, 409, 425, 666
 extraction 172, 221
 and vitrectomy 223
 with PCIOL implantation 223
 with vitreous incarceration 376
 surgery 121
 Cataractous lens 320
 Catford drum test 6
- Causes of
 6th nerve palsy in cavernous sinus
 503
 Acanthamoeba keratitis 72
 acquired
 blue-yellow defects 13
 red-green defects 13
 acute suppurative uveitis 139
 adherent leukoma 91
 angle closure 223
 glaucoma 201
 band keratopathy 88
 bare orbits 45
 chorioretinitis 148
 corneal blindness 645
 cystoids macular edema 148
 decreased
 basophils 159
 eosinophils 159
 ESR 161
 lymphocytes 160
 monocytes 160
 neutrophils 159
 diffuse osteolysis of orbit 46
 endothelial melanosis 65
 enlargement of orbit 46
 epithelial melanosis 65
 extraocular muscle enlargement
 49
 eyelid defects 568
 Horner's syndrome 434
 increased
 lymphocytes 160
 monocytes 160
 interstitial keratitis 80
 intraorbital calcification 47
 large orbit 45
 macular chorioretinitis 148
 normal calcification in X-ray skull
 40
 prominent corneal nerves 106
 raised
 basophils 159
 eosinophils 159
 ESR 161
 retinochoroiditis 148
 ring-enhancing lesions 51
 small orbit 45
 stromal deposits 63

- Cavernous
 - hemangioma 583
 - sinus 500
 - fistula 488
 - lesions 495
 - pathology 53
 - syndrome 493, 498, 503
 - thrombosis 49, 178, 488, 523, 527, 580
- Cefamandole 18
- Cefazolin 18, 19, 68
 - hydrochloride 396
- Ceftazidime 19, 68
 - hydrochloride 396
- Ceftriaxone 18, 19
- Cefuroxime 397
- Cellophane 401
- Central
 - avascular corneal scars 126
 - cloudy dystrophy 113
 - cornea 83
 - corneal
 - guttae 118
 - thickness 184
 - crystalline 108
 - field test 198
 - nervous system 79, 254, 472
 - retinal
 - artery 352
 - vein occlusion 323
 - vessels 237
 - scotoma 586
 - serous
 - chorioretinopathy 426
 - retinopathy 323
- Centripetal obesity 177
- Cephazolin 67
- Cerebellopontine angle lesions 500
- Cerebral
 - angiography 489
 - arteritis 196
 - meninges 237
 - pulsations 578
- Cerebrovascular
 - accident 434
 - disease 480
- Certain secondary glaucomas 288
- Chandler's syndrome 118, 123, 124
- Cheesy hypopyon 68
- Chemical
 - burns 80
 - irritants 137
- Chemosis 589
- Chemotherapy 411
- Chest
 - deformities 309
 - roentgenogram 85
- Chiasmal
 - compression 218
 - lesions 521
- Chiasmatic sulcus 40
- Childhood trachoma 58
- Chipping technique 269
- Chlorambucil 22
- Chloramphenicol 18, 19, 67, 397
- Chlorhexidine 74
- Chloromas 580
- Chloroquine 468
 - toxicity 11
- Cholesterol embolization 159
- Cholinergic drugs 22, 249
- Chorioretinal
 - biopsy 169
 - scarring 331
- Chorioretinitis 134, 156, 401
- Choroid plexus 41
- Choroidal
 - coloboma 34
 - detachment 131, 147, 304, 312, 379, 386, 391
 - hemorrhage 169, 345, 385
 - infarcts 483
 - lesions 38
 - melanoma 137, 586
 - neovascular membrane 320
 - neovascularization 343, 416
 - rupture 377
 - sclerosis 352
- Choroideremia 400
- Choroiditis 135, 136, 141
- Chromium deficiency 80
- Chromophilic adenoma 44
- Chronic
 - angle closure glaucoma 267
 - atrophic papilledema 399
 - blepharoconjunctivitis 557
 - closed-angle glaucoma 207
 - conjunctival inflammation 281

- conjunctivitis 94
- cyclitis 174
- dilatation of ocular vessels 222
- fistula 609
- inflammation 74
- inflammatory diseases 94
- isolated 6th nerve palsy 504
- lymphocytic leukemia 160
- meningitis 495
- non-granulomatous uveitis 88
- ocular disease 88
- open-angle glaucoma 304, 425
- papilledema 195
- posterior uveitis 138
- retinal detachment 220
- serpiginous ulcer 82
- uveitis 220
- Churg-Strauss
 - angitis 483
 - syndrome 159
- Cicatrical
 - component 551, 558
 - ectropion 78, 291
 - vernal conjunctivitis 557
- Cicatrizing conjunctival disease 559
- Ciliary
 - block glaucoma 207, 312
 - body 14
 - band 188
 - ganglion 61, 487
 - injection 151
 - muscle 486
 - ring diameter 308
- Ciprofloxacin 18, 19, 68
- Circumcorneal congestion 78, 206
- Classification of
 - nystagmus 513
 - tuberculin skin test 164
- Classify proptosis 581
- Claude's syndrome 490, 493
- Clean glass slides 393
- Clivus lesions 500
- Clogging of trabecular meshwork 147
- Closed angle mechanism 239
- Clouding of vitreous 151
- CMV retinitis 148, 379
- Coarctation of aorta 400
- Coats'
 - disease 34, 221, 351, 379, 408, 410
 - white ring 63
- Cobalt blue 27
- Cocaine test 434
- Coccidioidomycosis 136
- Cockayne syndrome 404
- Cogan's
 - microcystic 107
 - Reese syndrome 123
 - syndrome 80, 81
- Coin test 8
- Collagen
 - disorders 468
 - vascular
 - diseases 350
 - disorders 83, 140
- Collier's sphenoidal palsy 500
- Coloboma 196, 342, 379
 - of choroid 409
 - of disk 470
- Color
 - blindness 11
 - tests 545
 - vision 1, 10, 11
- Comberg's method 637
- Combined
 - mechanism glaucoma 267, 269
 - traction 422
- Community ophthalmology 641
- Complement fixation 85
- Complete
 - blood count 492
 - cortical removal 149
- Complicated
 - cataract 148, 379
 - fixation test 168
- Complications of
 - cavernous sinus thrombosis 529
 - iridocyclitis 147
 - keratoplasty 130
- Components of
 - measurement of vision 1
 - visual acuity 1
- Composite eyelid graft 575
- Composition of
 - optic disk 464
- Compression of
 - mires inferotemporally 98
- Compressive
 - optic neuropathy 590
 - vascular disease 365
- Computed tomography 48, 528
- Concave iris configuration 229

- Conchal cartilage 561
- Cone monochromatism 11
- Confocal microscopy 73
- Congenital
 - adduction palsy 487
 - cataract 34, 101, 379
 - color blindness 11
 - deafness 81
 - glaucoma 106, 122, 294, 309
 - hereditary
 - endothelial dystrophy 108, 109, 121
 - epithelial dystrophy 118
 - stromal dystrophy 108
 - myasthenic syndromes 512
 - myopia 46
 - nystagmus 513
 - optic nerve head 474
 - senile degenerative 65
 - serous cysts 45
 - stationary night blindness 398
 - syphilis 80
 - toxoplasmosis 140, 141, 410
 - trigeminal anesthesia 61
- Congestive
 - cardiac failure 161, 250, 256
 - glaucoma 220
 - heart failure 221
- Conjunctiva 78, 245, 284, 531, 540
- Conjunctival
 - and episcleral congestion 483
 - burns 272
 - buttonhole/perforation 285
 - congestion 250
 - defect 285
 - exposure 550
 - flap 297
 - leak 272
 - hemorrhages 353
 - hooding 120
 - hyperemia 255, 305
 - incision 594
 - injection 589
 - intraepithelial neoplasia 94
 - resection 86
- Conjunctivitis 97, 290
- Connective tissue disorders 160
- Consecutive optic atrophy 401
- Constricted tunnel field of vision 399
- Contact 226
 - lens 61, 72, 102, 121
 - cornea 82
 - fitting 31
 - induced abrasions 77
 - users 72
 - wear 58, 66
 - method 272
- Contents of superior orbital fissure 54
- Continued circumferential spreading 82
- Continuous
 - sutures 128
 - wave 338
- Contraction of
 - ciliary muscle 308
 - fibrous tissue leading 345
- Contrast
 - sensitivity 403, 444
 - studies 528
- Control of
 - glaucoma 240
 - inflammation 240
- Convergence insufficiency 6
- Corectopia 123, 169
- Cornea 14, 55, 78, 245, 246, 284, 425, 541
 - burns 345
 - of uneven thickness 127
 - verticillata 63
- Corneal
 - amyloidosis 101
 - anesthesia 60, 62, 78, 555
 - astigmatism 184
 - blindness 645
 - burn 269
 - decompensation 14
 - degenerations 107
 - Dellen formation 299
 - deposits 63
 - diameter 229
 - disorders 101
 - dystrophy 61, 107
 - of Bowman's layer 107, 108
 - edema 206, 267, 285, 483
 - endothelial
 - damage 282
 - pleomorphism and polymegathism 229

- endothelium 236
 - epithelial
 - defect 274
 - staining 250
 - erosions from tube 609
 - exposure 550
 - fistula 93
 - graft rejection 104
 - guttae 122
 - influences 182
 - intraepithelial neoplasia 29, 94
 - melting 290
 - opacification 267
 - perforation 75, 97
 - refractive surgery 184
 - rejection lines 30
 - scars 30, 125
 - scrapings 31
 - sensations 551
 - stromal vascularization 132
 - tattooing 63
 - thickness 202
 - thinning 81
 - topography 57
 - toxicity 262
 - transplant 125
 - trauma 83, 121
 - ulcer 70
 - vascularization 58, 59
 - Cortical blindness 483
 - Corticosteroids 159, 310
 - Corynebacterium* 390
 - diphtheriae* 66
 - Cosmetically unacceptable proptosis 590
 - Cotton wool spots 352, 358, 483
 - Cover
 - tests 612
 - uncover test 613
 - Cranial nerve 541
 - involvement 539
 - palsies 79, 441, 531
 - Craniopharyngioma 44, 45, 491
 - Craniostenosis 46
 - Crohn's disease 140
 - Crouzon's syndrome 100
 - Cryotherapy 74, 96, 97, 384
 - C-type natriuretic peptide 25, 262
 - Cupric oxide 419
 - Curvature map 98
 - Cushing's
 - disease 426
 - syndrome 176
 - Cutaneous hypersensitivity 156
 - Cutler-Beard bridge flap 575
 - Cyanoacrylate glue application 93
 - Cyanotic congenital heart disease 459
 - Cyclic adenosine monophosphate 251
 - Cyclitis 141
 - Cyclocryotherapy 227
 - Cyclodestructive procedure 227
 - Cyclodialysis 190, 202, 266
 - cleft 285
 - Cyclopentolate 172
 - Cyclophosphamide 22, 174
 - Cyclophotocoagulation 225, 266
 - Cyclosporine 22
 - Cyst of Tenon's capsule 285
 - Cystic fibrosis 469
 - Cysticercosis 51, 410
 - Cystoid macular edema 148, 171, 255, 323, 343
 - Cytochrome C release inhibitors 24
 - Cytomegalovirus
 - infections 140
 - retinitis 148
 - Cytoskeleton modulator 25
- D**
- Dacryocystorhinostomy 608
 - Damage of lens 285
 - Dark room test 208
 - Darkly pigmented iris 189
 - Davenger's exophthalmometer 580
 - Decreased endothelial cell count 119
 - Deep
 - anterior
 - chamber 229
 - lamellar keratoplasty 74, 102, 126
 - lamellar endothelial keratoplasty 126
 - sclerectomy 275
 - Degenerative pigmentation 400
 - Dehiscence of incisional wound 284
 - Dehydration 256, 257
 - Delay in melanogenesis 230

- Delayed
 - painful ophthalmoplegia 539
 - tissue healing 177
 - wound healing 290, 292
 - Delivery system for argon 31
 - Demecarium 22
 - Demyelinating disease 434, 466
 - Demyelination 498
 - Dendritic keratitis 77, 78
 - Depth of anterior chamber 14
 - Dermatochalasis 564
 - Dermoid cyst 46, 47, 582
 - Descemet's
 - membrane 64, 81, 102, 119
 - endothelial keratoplasty 126
 - stripping endothelial keratoplasty 126
 - Deutranopia 11
 - Developmental glaucoma 270
 - Deviation map 192
 - Devic's disease 446
 - Dexamethasone
 - phosphate ointment 21
 - solution 21, 172
 - Diabetes mellitus 61, 221, 365, 510
 - Diabetic
 - maculopathy 322
 - papillopathy 353, 480
 - retinopathy 220, 223, 316, 330, 342, 350, 351, 362
 - Diameter of
 - lens 15
 - optic foramen 50
 - Diarrhea 256
 - Dichlorphenamide 24
 - Dichromatic color vision 11
 - Diclofenac sodium 20
 - DIDMOAD syndrome 469
 - Digital subtraction aortogram 535
 - Dilated aortic root 309
 - Dimensions of cornea 14
 - Dimethyl sulfoxide 405
 - Diode laser 225
 - Dipivefrin 23
 - Diplopia 496, 512, 598, 614, 658
 - charting 619
 - tests 544
 - Direct
 - fenestration of optic nerve sheath 463
 - focal illumination 27, 28
 - gonioscopy 186
 - ophthalmoscope 33-35
 - retroillumination of iris 29
 - Disadvantages of indirect ophthalmoscopy 37
 - Disciform
 - keratitis 77, 78
 - scar 416
 - Dislodges embolus 366
 - Disseminated choroiditis 135
 - Dissimilar image test 612
 - Distant direct ophthalmoscopy 33
 - Distortion of mires 57
 - Distraction test 550
 - Diuresis 256, 257
 - Diurnal variation 179
 - Dorsum sellae 40
 - Dorzolamide 23, 259
 - Dot VA test 8
 - Double posterior curve lenses 103
 - Down's syndrome 100, 145
 - Drainage devices 226, 232
 - Drumhead technique 269
 - Drusens of disk 470
 - Dry
 - eye 97
 - mouth 253
 - Duane's syndrome 501
 - Dural arteriovenous fistula 500
 - Dyschromatopsia 11, 444
 - Dysplasia 45
 - Dystrophies 107, 116, 125
- E**
- Eales' disease 146, 221, 351, 377
 - Eaton-Lambert syndrome 508
 - Echothiophate iodide 22
 - Eclampsia 159
 - Ectatic
 - cicatrix 92
 - disorders 125
 - Ectopia lentis pupillae 247
 - Ectopic pinealomas 45
 - Ectropion 97, 548, 607
 - uveae 123, 144
 - Edelstein-Dryden procedure 553
 - Edematous muscle 584
 - Edinger-Westphal nucleus dorsal 485
 - Ehlers-Danlos syndrome 248, 309, 374

- Ehrlich Tuck's line 142
 Electric shock 196
 Electro-oculogram 403
 Electroretinogram 403
 Electroretinography 535
 Elevated
 episcleral venous pressure 217
 intraocular pressure 131, 269
 ELISA 166
 Elsching's spots 353
 Embolic disease 365
 Emmetropia 38
 Empty sella syndrome 45
 Endocyclophotocoagulation 272
 Endogenous infection 135
 Endolaser 346
 Endocular uveitis 137
 Endophthalmitis 70, 92, 139, 148,
 170, 220, 273, 379, 385, 390,
 425
 vitrectomy study 394
 Endothelial
 cell count 14
 damage 292
 decompensation 290
 diseases 121
 disorders 121
 dystrophy 115, 121
 plaques 68
 rejection 133
 Endothelitis 77
 Endothelium 102, 119
 Enlarged
 blind spot 586
 cells 119
 sella 44
 Enlargement of sella 44
 Exophthalmos 559, 598
 Epidemiology of Fuch's dystrophy
 117
 Epidermolysis bullosa 116
 Epikeratoplasty 104
 Epinephrine 23, 63, 224
 Epiretinal membrane formation 352
 Episodes of pain 118
 Epithelial
 basement membrane dystrophy
 107
 cysts 189
 debridement 74, 116
 edema 122
 invasion 145
 keratitis 77
 melanosis 63
 Epithelium 102, 107, 119
 Equatorial mirror 187
 Erosion of floor of sella 44
 Erythema 290, 291
 multiforme 557
 nodosum 156
 Erythroclastic glaucoma 425
 Erythrocyte sedimentation rate 160
Escherichia coli 390
 Essential iris atrophy 101
 Ethambutol 468
 Ethmoidal
 air cells 42
 mucocele 581
 Etodolac 20
 Evaluation of
 bony orbit 49
 fractures 51
 proptosis 653
 Ewing's
 sarcoma 407
 tumor 582
 Excimer laser phototherapeutic
 keratectomy 104
 Exfoliative
 dermatitis 254
 glaucoma 207, 269
 Exogenous infection 135
 Exophthalmometry 579
 Exophthalmos 577
 Expansion of optic canal 409
 Explain
 logMAR charts 2
 optical principle of keratometer 55
 Exposure keratopathy 590
 Expulsive hemorrhage 92
 Extensive
 choroiditis 399
 conjunctival scarring 294
 panretinal photocoagulation 399,
 465
 trauma 89
 External
 limiting membrane 368
 ophthalmoplegia 537
 Extrafoveal CNV 419

- Extraocular muscle 16, 237
 damage 311
 ischemia 483
- Exudative retinal detachment 151
- Eyelid 16
 crease incision 594
 edema 589
 hematoma 607
 injection 589
 reconstruction 568
 swelling 210
- F**
- Facial
 anatomy and symmetry 550
 function 550
- Failed argon laser trabeculoplasty 271
- Failing bleb 285
- Failure of filtration 285
- Falx cerebri 40
- Familial ectopia lentis 247
- Fasanella-Servat operation 565
- Fascia lata sling 567
- Fat suppression techniques 53
- Features of lattice-III dystrophy 110
- Femtosecond DSEK 130
- Ferry's line 64
- Fibrin platelet emboli 364
- Fibrinolysis 366
- Fibroblast growth factor 428
- Fibrosed muscle 584
- Fibrotic inferior oblique 497
- Fibrous
 dysplasia 46, 582
 histocytoma 583
 mucocele 582
- Field
 expanders 406
 of vision 1
- Filamentary keratitis 131
- Filtering surgery 226, 232
- Finger counting 2
- Fish mouthing 386
- Fixation
 reflex 6
 tests 545
- Fixed dilated pupil 131
- Flame shaped hemorrhages 352
- Flap of retinal tear 372
- Flat anterior chamber 267, 272
- Fleck dystrophy 63, 108, 109, 113
- Fleischer's ring 64, 98, 99
- Floor of
 pituitary fossa 40
 sella 42
- Florid retinal neovascularization 422, 425
- Flucinolone acetonide 21
- Fluconazole 19
- Flucytosine 19
- Fluorescein
 angiography 403
 dye disappearance test 315
- Fluoromethalone 172
- Fluorophotometry 405
- Flurbiprofen 20
- Focal
 arteriolar narrowing 351
 choroiditis 79
 diabetic maculopathy 322
 edema 333
 illumination 26, 27
- Fogging tests 545
- Folate deficiency 159
- Foramen ovale and spinosum 43
- Foreign bodies 83, 145, 190
- Forme-fruste keratoconus 100
- Forward extension of intracranial mass 46
- Fourth
 nerve palsy 496
 ventricle 449
- Fovea centralis 15
- Foveal
 burn 345
 hard exudates plaque 343
- Foveola 15
- Foville's syndrome 502
- Fracture 40, 585
 of base of skull 586
- Free tarsoconjunctival graft 575
- Frisen's grading system 453
- Frontal
 mucocele 581
 process of maxillary bone 609
- Fuch's
 corneal dystrophy 101
 dystrophy 106, 108, 117, 118, 125

- endothelial dystrophy 117, 121, 129
- hereditary endothelial dystrophy 108
- heterochromic
 - iritidocyclitis 137, 147, 152, 158, 224
 - uveitis 139
- Fulminant corneal abscess 75
- Functional blindness 446
- Fundus
 - coloboma 379
 - examination
 - of left eye 650
 - with focal illumination 31
 - fluorescein angiography 314, 418
 - reflectometry 403
- Fungal
 - endophthalmitis 145
 - keratitis 68
- G**
- Gadolinium 52
- Gallium scan 170
- Gamma
 - interferon 283
 - radiation 97
- Ganglion cell
 - axons 438
 - layer 368
- Gastric hemorrhage 176
- Gastrointestinal disturbances 254
- Gatifloxacin 18
- Gastroesophageal reflux 426
- Genital aphthous ulceration 156
- Genitourinary
 - disturbances 254
 - system 256
- Gentamicin 18, 19, 68, 397
 - sulfate 396
- Geographic keratitis 77
- Geographical helical polypoidal choroidopathy 148
- Giant
 - cell arthritis 83, 161, 221, 363, 492
 - intracavernous aneurysm 488
 - retinal tears 389
- Giemsa's stain 67
- Ginkgo biloba* extract 265
- Glaucoma 74, 81, 123, 153, 178, 192, 194, 201, 290, 379, 387, 389, 399, 425, 465, 531, 541, 661
 - drainage devices 293
 - Hemifield test 199
 - probability score 220
 - surgery 172
 - visual field defects 194
- Glaucomatocyclytic crisis 207
- Glaucomatous optic neuropathy 585
- Glaukomflecken 208, 210
- Gliomas 44, 466
- Glycosaminoglycan theory 236
- Goldmann
 - contact lens 347
 - Favre syndrome 375
 - perimetry 519
 - single mirror 186
 - three mirror 187
- Gonadal malignancy 174
- Gonio
 - lens 186
 - prism 186
- Gonioplasty 266
- Goniopuncture 275
- Gonioscopic grading of angles
 - structure 190
- Gonioscopy 31, 663
 - mirror 187
 - solution 268
- Gormaz exophthalmometer 579
- Gradenigo's syndrome 502
- Grading of
 - cells 143
 - flare 143
- Graft
 - failure 131, 274
 - rejection 131
- Gram-negative organism 66
- Gram-positive organism 66
- Gram stain 67
- Granular dystrophy 63, 108, 109, 126
- Granuloma 290, 609
 - and lepra pearls 144
 - of sphenoid sinus 44
- Graves'
 - myopathy 497

- ophthalmopathy 51
- orbitopathy 587
- Grayish reflex 33
- Gross
 - eccentric fixation 7
 - uncorrected refractive errors 194
- Guillain-Barre syndrome 459, 508
- Gyrate atrophy 101
- H**
- Haag-Streit model 31
- Haemophilus influenzae* 66, 286, 390, 392
- Hard
 - exudates 352
 - palate 42
- Hassall-Henle bodies 122
- Headache 455, 483
- Headlight in fog appearances 149
- Healing corneal abrasion 77
- Heidelberg retina tomography 217, 219
- Helmholtz keratometer 56
- Hemagglutination test 166, 168
- Hemangioma 47, 562
- Hemi akinesia meter 433
- Hemianopic pupillary reaction of
 - Wernicke's syndrome 432
- Hemifacial spasm 607
- Hemolytic anemia 159
- Hemorrhage 269, 285, 488, 489, 498
- Hemorrhagic
 - cystitis 174
 - glaucoma 220
 - hypopyon 78
- Hepatitis 165
 - B vaccine 356
 - C infection 83
- Hereditary cataracts 309
- Herpes
 - simplex 58, 80, 83, 136, 137, 148
 - keratitis 58, 61, 83
 - keratouveitis 207
 - viral keratitis 115
 - virus 77
 - zoster 77, 80, 83, 230, 356, 497
 - dendrite 78
 - dermatitis 550, 554
 - ophthalmicus 207, 557
- Hertel's exoptthalmometer 580
- Hess
 - charting 621
 - test 612
- Heterochromia 152, 229
- Hexamidine 74
- High
 - arched palate 309
 - axial myopia 580
 - myopia 331, 399, 401
- Hirschberg test 612
- HIV 94, 126, 161
- Hodgkin's
 - disease 80
 - lymphoma 159
- Hogan's grading 143
- Homocystinuria 248, 309, 310, 375
- Homonymous hemianopia 441, 520
- Honeycomb degenerations 371
- Horizontal
 - diameter 14
 - diplopia 501
- Horner's syndrome 441, 562
- Horseshoe tear 370
- Hour glass cornea 82
- Hudson-Stahli's line 64
- Hughes tarsoconjunctival
 - advancement flap 575
- Human
 - leukocyte antigen 166
 - papilloma virus 94
- Hump technique 269
- Hurlers syndrome 469
- Hutchinson's
 - teeth 81
 - triad 81
- Hyaline lipoprotein 114
- Hydralazine 25
- Hydrocortisone
 - acetate
 - ointment 21
 - solution 21
 - suspension 21
 - sodium succinate 21
- Hyperbaric oxygen therapy 400
- Hypercalcemia 88
- Hypercholesterolemia 480
- Hyperemia 245, 290
- Hyperfibrinogenemia 161
- Hyperfluorescence 319
- Hyperglycemia 256

- Hyperhomocysteinemia 363
 - Hyperlipidemia 177, 356
 - Hyperlysinemia 248, 309
 - Hypermetropia 38
 - Hyperosmotic ketoacidosis 177
 - Hyperparathyroidism 46, 88
 - Hyperplasia of dilator muscle 230
 - Hypersensitivity 136, 256
 - Hypertension 177, 363, 365, 377, 500
 - Hypertensive retinopathy 400, 459
 - Hyperthyroidism 180
 - Hyperviscosity
 - retinopathy 362
 - syndrome 161
 - Hyphema 274, 284, 285, 300
 - Hypofibrinogenemia 161
 - Hypofluorescence 319
 - Hypogonadism 404
 - Hypoperfusion 234
 - Hypophosphatasia 469
 - Hypopyon 274
 - in bacterial ulcer 70
 - in fungal ulcer 70
 - Hypothyroidism 180
 - Hypotonous maculopathy 273, 284
 - Hypotony 290, 300, 386, 425
 - maculopathy 285
 - Hypovascularity of iris 230
 - Hypovolemia 256
 - Hypoxemia 459
 - HZV infection 483
- I**
- Iatrogenic
 - break 385
 - macular detachment 387
 - Ibuprofen 20
 - Ice syndromes 223
 - Idiopathic intracranial hypertension 451
 - Ilyff test 564
 - Illiterate E-cutout test 8, 9
 - Imidazoles 69
 - Immune mediated optic neuropathy 446
 - Immunofluorescent antibody stain 73
 - Incongruous homonymous hemianopia 519
 - Incontinentia pigmenti 80, 379
 - Indications for
 - keratoplasty 125
 - medical management 536
 - systemic treatment with oral steroids 173
 - vitrectomy in diabetic retinopathy 422
 - Indirect
 - fluorescent test 166
 - gonioscopy 186
 - ophthalmoscopy 36, 346
 - retroillumination of iris 30
 - Indocyanine green angiography 324, 418
 - Indomethacin 20
 - Infantile
 - cortical hyperostosis 580
 - glaucoma 115
 - optic atrophy 470
 - Infectious
 - diseases 442
 - meningitis 488
 - mononucleosis 80, 160
 - Inferior
 - oblique 487
 - muscle 16
 - orbitotomy 593
 - rectus 486, 583, 587
 - scleral show 551
 - Inflammation of ciliary body 147
 - Inflammatory
 - bowel disease 83
 - cells 143
 - diseases 442
 - glaucoma 270, 271
 - pseudotumor 504
 - Infraclinoid aneurysm 49
 - Infraorbital
 - fissure 43
 - hyperesthesia 591
 - nerve anesthesia 598
 - Infratrochlear nerve 60
 - Inhibit posterior synechiae 246
 - Inhibitors of
 - protein kinase C 25
 - T-cell lymphocytes 22
 - Inlay and onlay lamellar keratoplasties 130

- Inner
 - blood retinal barrier 315, 330
 - nuclear 368
 - plexiform 368
 - Insertion of recti 16
 - Insomnia 176
 - Intermediate
 - pooling of tears 103
 - uveitis 134, 135, 136, 173, 174
 - Intermittent ethmoiditis 578
 - Internal
 - elastic lamina 330
 - ophthalmoplegia 537
 - Internuclear ophthalmoplegia 441
 - Interpretation of Hess chart 623
 - Interrupted sutures 127
 - Interstitial keratitis 80, 81, 118
 - Intestinal perforation 176
 - Intracanalicular optic nerve 54
 - Intracavernous aneurysm 46
 - Intracorneal rings 102, 105
 - Intracranial
 - aneurysm 53
 - mass lesions 508
 - tension 43
 - Intraepithelial
 - epithelioma 94
 - ointment 63
 - Intraocular
 - cysticercosis 379
 - foreign body 121
 - gases 388
 - hemorrhage 256
 - infection 74
 - inflammation 118, 233, 312
 - lymphoma 171
 - malignant melanomata 150
 - neoplasm 89
 - pressure 126, 180, 287, 663
 - tumors 126, 203
 - Intraoperative
 - mechanical trauma 121
 - slit lamp illumination 31
 - Intraorbital
 - branches of cranial nerves 54
 - tumor 504
 - Intraretinal
 - microvascular abnormality 333
 - edema 357
 - Intravitreal
 - dexamethasone 397
 - injection 19
 - Intumescent cataract 75
 - Inverse
 - Duane's syndrome 492
 - hypopyon 389
 - Ipsilateral hypotropia 564
 - Iridenceleisis 275
 - Iridocorneal endothelial syndrome
 - 121, 123, 190, 207, 267, 270
 - Iridocyclitis 134, 136, 145, 153, 290
 - Iridoplasty 266
 - Iris 78, 279
 - angiography 170
 - atrophy 74
 - bombe 147, 148
 - color 61
 - freckle 145
 - hooks 238
 - incarceration 273
 - melanoma 189
 - membranes 123
 - nevus syndrome 123, 124, 145
 - pigment
 - cells 143
 - cysts 250
 - epithelial cyst 145
 - transillumination defects 229
 - Iritis 97, 134, 136
 - Iron ring 98
 - Irregular astigmatism 82
 - Irvine Gass syndrome 139
 - Ischemia with necrosis 78
 - Ischemic
 - diseases 442
 - necrosis of conjunctiva 353
 - optic neuropathy 196, 355, 446
 - Ishihara chart 10, 12
 - Isolated
 - 6th nerve palsy 504
 - fourth nerve palsy 78
 - grouped vesicles 123
 - hand figure test 8
 - Isosorbide dinitrate 25
- J**
- Jaeger's chart 3
 - Jamaican optic neuropathy 446

- Javal-Schiotz keratometer 56
 Jaw claudication 483
 Jones dye test 558
 Jugular vein obstruction 178
 Juvenile
 asthmatics 317
 diabetes mellitus 469
 epithelial dystrophy 107
 glaucoma 271
 rheumatoid arthritis 165, 168
 xanthogranuloma 145
 Juxtacanalicular part of trabecular meshwork 214
 Juxtafoveal CNV 419
 Juxtapapillary choroiditis 195
- K**
 Kaposi's sarcoma 80, 140, 587
 Karickhoff lens 347
 Kayser-Fleischer ring 64
 Kearns-Sayre syndrome 405
 Keith-Wagener-Barker classification 349
 Keratinization 291
 Keratinized plaques 292
 Keratoconus 98, 105, 106, 125, 126, 129, 402
 Keratoderma blenorrhagica 140
 Keratoepithelioplasty 86
 Keratoglobus 105
 Keratometry 55
 Keratoplasty 125
 Keratouveitis 136
 Ketoconazole 19
 Ketoprofen 20
 Ketorolac tromethamine 20
 Khodadoust line 132
 Knapp's classification 499
 Krimsky test 612, 613
 Krukenburg's spindles 65, 229
 Kuglen hooks 238
 Kveim test 165
- L**
 Labenular commissure 40
 Lack of stereopsis 35
 Lacrimal
 apparatus 16, 551
 bone 609
 fossa 43, 609
 gland
 neoplasia 527
 tumors 47, 582
 sac tumors 581, 582
 Lacrimation 151
 Lagophthalmos 551, 561, 607
 Lambert-Eaton syndrome 508, 512
 Lamellar
 ichthyosis 554
 keratoplasty 128, 129
 macular hole 343
 Lamina papyracea 42
 Landolt's testing chart 3
 Lantern test 13
 Larger molecular weight 69
 Laser
 in diabetic retinopathy 338
 in glaucoma 266
 interferometry 31, 310
 photocoagulation 384
 sclerostomy 275
 suturolysis 266
 Latanoprost 23, 255
 Latent nystagmus 513
 Lateral
 canthal tendon 549
 orbitotomy 594
 rectus 584
 semicircular rotation flap 575
 sinus thrombosis 503
 Latrunculin B 25, 261
 Lattice
 degeneration 230, 371, 372
 dystrophy 30, 61, 63, 101, 108
 Laurence-Moon-Bardet
 Biedl syndrome 100
 syndrome 404
 Layers of rods and cones 368
 Leber's
 congenital amaurosis 101, 220, 404
 hereditary optic neuropathy 446
 miliary aneurysm 220
 optic atrophy 470
 Lees test 612
 Leiomyoma 145
 Leishmaniasis 80
 Lens 15, 229
 damage 131
 extraction 247

- induced
 - glaucoma 223, 245
 - uveitis 147
- injury 269
- subluxation 304
- vacuoles 30
- Leprosy 80, 81, 106, 140
- Less cellular hydration 257
- Leukemia 355, 410
 - and disseminated lymphoma 126
- Levator
 - function 563
 - palpebrae superioris 16, 486
 - resection 566
- Levobunolol 23, 251
- Levofloxacin 68
- Lid
 - elasticity 558
 - excursion 563
 - infection 561
 - laxity 558
 - necrosis 561
- Light
 - home picture cards 8
 - reflection tests 612
- Limbal
 - based conjunctival flap 297
 - incisions 62
 - relaxing incisions 311
 - transition zone 94
- Limbitis 73
- Lipid
 - deposition 63
 - keratoplasty 81
 - storage diseases 160
- Lithium therapy 588
- Littmann-Galilean telescope
 - principle 31
- Localization of intraocular foreign
 - bodies 631
- Long
 - arm span 309
 - ciliary nerves 60
- Longstanding corneal edema 88
- Loss of
 - central vision 285
 - consciousness 455
 - foveal reflex 401
- Loteprednol etabonate 21, 243
- Low
 - grade vitritis 246
 - intraocular pressure 190
 - plasma protein states 161
 - vision aid 406
- Lowe syndrome 309
- Lower
 - cell density 119
 - eyelid 16
 - reconstruction 574
 - senile entropion 607
 - lid
 - retractor disinsertion 551
 - sagging 581
- Luedde exophthalmometer 579, 583
- Lumbar puncture 155, 489
- Lupus choroidopathy 154
- Lymphangioma 582
- Lymphoid tumors 587
- Lymphoma 165, 582, 583
- M**
- Macroglobulinemia 161
- Macula lutea 15
- Macular
 - dystrophy 63, 108, 111, 126
 - ectopia 333
 - edema 321, 333, 337, 345, 352, 358, 463, 585
 - epiretinal membranes 422
 - histoplasmosis 165
 - hole 323
 - ischemia 321, 333
 - pucker 345, 386
 - scar 585
 - traction 333
 - translocation 420
- Maddox
 - rod 612
 - test 310
 - wing 612
- Magnetic resonance imaging 48, 528
- Magnification of direct
 - ophthalmoscope 35
- Malignancies of
 - brain 407
 - nasopharynx 580
- Malignant
 - cells 143

- glaucoma 201, 255, 267, 269, 274,
 285, 306, 312
 melanoma 145, 221, 377
 Management of
 Fuch's dystrophy 119, 120
 glaucoma 124
 Mooren's ulcer 86
 PPMD 123
 Map-dot fingerprint dystrophy 30
 Marcus Gunn jaw-winking syndrome
 562
 Marfan's syndrome 100, 248, 309,
 310, 374
 Margin
 crease distance 564
 limbal distance 563
 of tumor 51
 reflex distance 563
 Massive choroidal invasion 409
 Masson's trichrome stain 114
 Matrix metalloproteinases 25, 260
 Maxillary
 antrum 42
 tumors 582
 McGuire lens system 103
 Medial
 canthal tendon 549, 553, 558
 orbitotomy 594
 rectus 486, 583
 spindle procedure 552
 Medryson 21, 243
 Medullated nerve fibers 470
 Medulloepithelioma 410
 Meesmann's dystrophy 30, 63
 Megalocornea 122
 Melanin dispersion 235
 Melanocytic hyperplasia 154
 Melanocytosis 145
 Melanoma 407
 of choroid with exudative
 detachment 379
 Melatonin 265
 Menace reflex 543
 Meningeal carcinomatosis 367
 Meningioma 40, 41, 44, 46, 47, 445,
 491
 of dorsum sella 196
 Menkes disease 469
 Menstrual disorders 176
 Mental retardation 404
 Meretoja syndrome 108
 Metabolic
 acidosis 254
 disorders 115
 Metallic
 foreign body 51
 taste 254
 Metastatic
 carcinoma 221
 neuroblastoma 580
 tumors 49, 491
 Methazolamide 24
 Methicillin 18
 Methotrexate 22
 Methyl alcohol poisoning 367
 Methylprednisolone 21
 Metipranolol 23, 251
 Miconazole 19
 Microblepharon 581
 Microcornea 101
 Microcystic corneal edema 245
 Microspherophakia 267
 Mid limbal line 14
 Midbrain pathology 495
 Middle
 fossa disorders 500
 layer of elastic fibers 368
 Mifepristone 265
 Mild
 non-proliferative diabetic
 retinopathy 322
 pain 151
 Milk alkali syndrome 88
 Millard-Gubler syndrome 502
 Miniature toy test 8
 Minimal manipulation of iris 149
 Minimum angle of resolution 2
 Minisphincterotomies 238
 Minoxidil 25
 Mirror test 544
 Mitochondrial myopathy 405
 Mitral valve prolapse 309
 Mobile lens syndromes 203
 Mobius syndrome 501
 Modified
 Fasanella-Servat surgery 566
 Retina Society Classification 381
 Monocular
 diplopia 269
 hemianopias 547

- Mood swings 176
 Mooren's ulcer 82-84, 87
 Morning glory
 disk 477
 syndrome 470
 Mosaic pigmentation of Vogt 65
 Motion detection perimetry 200
 Motor neuron syndromes 512
 Mouth ulcers 140
 Movement of vessels 141
 Moxalactam 18
 Moxifloxacin 18, 67
 Mucocele of sphenoid sinus 46
 Mucoepidermoid carcinoma 95
 Mucopolysaccharidosis 63, 405, 469
 Mucous membrane graft 561
 Multifocal
 electroretinography 418
 visual evoked potential 200
 Multiple
 endocrine neoplasia 106
 evanescent white dot syndrome 171
 failed trabeculectomy 294
 myeloma 161, 587
 sclerosis 508
 Munson's sign 98, 99
 Muscular dystrophies 512
 Mustarde's
 cheek rotation flap 575
 double Z plasty or Y-V plasty 576
 marginal pedicle rotation flap 575
 Myasthenia gravis 61, 497, 501, 505, 506, 512, 562, 584
Mycobacterium tuberculosis 162
 Mycophenolate mofetil 22
 Mycosis fungoides 80
 Mydriatic
 cycloplegics 240
 test 208
 Mydracaine 149
 Myelinated nerve fiber layer 379
 Myeloproliferative disorders 160
 Myocardial infarction 484
 Myofibril theory 236
 Myopathy 177
 Myopia 38, 195, 402, 418
 Myopic disk 470
 Myotonic dystrophy 180, 562
 syndrome 365
- N**
 Nail-patella syndrome 100
 Nanophthalmos 154, 203, 267
 Naproxen 20
 Nasal chondromucosa 561
 Nasopharyngeal tumors 491, 582
 Natamycin 19, 69
 Natriuretic peptides 25, 262
 Nd:YAG
 capsulotomy 221
 laser 340
 iridotomy 231
 Near vision 3
 Necrosis of ocular tissue 210
 Necrotizing
 keratitis 77, 78
 vasculitis 161
Neisseria gonorrhoeae 66
 Neonatal conjunctivitis 642
 Neovascular glaucoma 147, 207, 250, 267, 270, 288, 294
 Neovascularization of
 disk, retina, iris angle 357
 iris 425
 Nerve fiber bundle defect 586
 Neuroblastoma 407, 582
 Neurofibroma 46, 582
 Neurofibromatosis 100, 106, 145
 Neuromuscular disease 494
 Neuro-ophthalmology 430
 Neuroretinitis 351
 Neurotrophic
 keratitis 77
 keratopathy 77
 Neurotrophin-3 24
 Neutropenia 254
 Nevus of Ota 189
 Nicotine smokers 480
 Nimodipine 24, 264
 Nitric oxide
 donors 262
 synthase inhibitors 24, 264
 Nitroglycerin 25
 Nocturnal hypotension 357, 480
 Noncorneal disorders 101
 Non-healing corneal ulcers 70
 Non-pupillary block 239
 Non-steroidal anti-inflammatory agents 240
 drugs 20

- Normal
 - dimensions of sella turcica 44
 - intraocular pressure 178
 - tension glaucoma 269
- Normocalcemia 88
- Norrie's disease 88, 379
- Nothnagel's syndrome 493
- Nuclear
 - cataract 235
 - fascicular syndrome 498
- Number of
 - cones 15
 - rods 15
- Nummular keratitis 77
- Nutritional amblyopia 446, 469
- Nystagmoid movements 514
- Nystagmus 513
- Nystatin 69

- O**
- Oblique
 - illumination 26, 27
 - orbital line 45
- Obstruction of fistula 285
- Occlusio pupillae 145
- Occlusion
 - of vein/artery 345
- Occlusive
 - disease 365
 - retinal vasculitis 79
- Occurrence of uveitis 137
- Ocular
 - bobbing 514
 - burning 254
 - cicatricial pemphigoid 126, 557
 - complications of steroids 175
 - decompression retinopathy 285
 - dipping 514
 - dysmetria 514
 - flutter 514
 - hypotony 190, 306, 385, 586
 - ischemic syndrome 350, 362
 - manifestation of systemic diseases 47
 - massage 366
 - melanosis 229, 230
 - movement restriction 210
 - myopathies 562
 - pain 290
 - rigidity 182
 - surface
 - injury 94
 - squamous neoplasia 94
 - trauma 202
- Oculomotor
 - nerve 485
 - fascicle 487
 - palsy 483
 - nucleus 487
- Oculopharyngeal dystrophy 512
- Oculoplethysmography 535
- Oculosensory reflex 432
- Ofloxacin 18, 19, 68
- Oil
 - droplet reflex 33
 - droplet sign 100
- Onchocerciasis 80
- Open angle
 - glaucoma 202, 271, 402
 - stage 222
 - mechanisms 239
- Ophthalmia neonatorum 642
- Ophthalmic artery occlusion 483
- Ophthalmodynamometry 31, 535
- Ophthalmoplegia 537
- Ophthalmoscopic appearance 475
- Opponent color theory of Hering 12
- Opposite eye enophthalmos 581
- Opsoclonus 514
- Optic
 - atrophy 210, 464, 472
 - canal 17
 - disk 146
 - anomalies 474
 - coloboma 477
 - drusen 365, 402
 - edema 358
 - glioma 44
 - hypoplasia 470
 - foramen 43, 471
 - nerve 531
 - compression 585
 - cupping 208
 - damage 311
 - enhancement 54
 - evaluation 409
 - glioma 46
 - head 435
 - invasion 407, 409
 - lesions 6, 53

- meningioma 46, 49, 54, 583
- pit 342, 379
- sheath lesions 53
- traction 585
- neuritis 157, 366, 442, 446, 457, 459
- pit 196, 470
- tract lesions 520
- Optical
 - coherence tomography 217, 219
 - section 26, 27
- Optochiasmatic archnoiditis 196
- Optokinetic
 - nystagmus 543
 - system 514
- Ora serrata 15
- Oral
 - acyclovir 79
 - aphthous ulceration 156
 - contraceptives 161, 356, 468
 - gabapentin 79
- Orbicularis
 - muscle tone 551
 - reflex 432
- Orbit 17, 79, 541, 548
- Orbital
 - apex syndrome 508
 - cellulitis 410, 504, 577, 587
 - color doppler imaging 535
 - diseases 45, 494
 - edema 79
 - emphysema 577
 - extension of retinoblastoma 582
 - foreign body 592
 - fracture 592
 - hemorrhage 577
 - inflammatory pseudotumor 498
 - invasion 409
 - metastasis 584
 - neoplasm 582
 - nerve glioma 582
 - pain 589
 - sepsis 582
 - septa 237
 - syndrome 493, 498, 503
 - trauma 48, 51, 504
 - varices 583
 - vasculitis 527
- Orbitotarsal disparity 551
- Organ transplantation 426
- Organic nitrates 265
- Osteodysplasia 580
- Osteogenesis imperfecta 101
- Osteomyelitis 46, 161
 - of maxilla 582
- Osteopetrosis 46
- Osteoporosis 177
- Osteosarcoma 407
- Otis Lee procedure 552
- Outer blood retinal barrier 315, 330
- Overcorrected myopia 6
- Oxyphenbutazone 20
- P**
- Pacchionian granules 40
- Pachymetry 31
 - map 98
- Paget's disease 46, 50
- Painful
 - blind eye 210
 - ophthalmoplegia 537
- Painless loss of vision 367
- Palatal mucoperichondrium 561
- Palpaberal fissure 16
- Palpable orbital mass 48
- Pancreatitis 176
- Pannus
 - degenerativus 58
 - leprosus 58
 - phlyctenulosis 58
 - trachomatous 58
- Panophthalmitis 92, 139
- Panretinal photocoagulation 195, 225, 425
- Panuveitis 134, 135
- Papilledema 351, 362, 449, 465, 467
- Papillitis 79, 467
- Paracentral
 - field defect 547
 - scotoma 195, 343, 399, 586
- Parasitic infestation 159
- Parasympathomimetics 22, 249, 257
- Paredrine test 434
- Pars
 - plana
 - installation 298
 - route 273
 - planitis 136, 138, 139, 148, 158, 376

- Part of
 - direct ophthalmoscope 34
 - ethmoid bone 609
 - nasal bone 609
 - optic nerve 49, 50
- Patches of iris atrophy 210
- Pathogenesis of
 - Acanthamoeba* keratitis 72
 - band-shaped keratopathy 88
 - Fuch's dystrophy 117
 - ICE syndrome 123
- Pathology of Mooren's ulcer 84
- Pathophysiology of Mooren's ulcer 85
- Pavingstone degenerations 371
- Pediatric ophthalmology and strabismus 610
- Pegaptanib sodium 419
- Pellucid marginal degeneration 83
- Penetrating
 - injury 91
 - keratoplasty 72, 74, 93, 102
- Penicillin 18, 19
- Peptic ulcer 176
- Perception of light 3
- Perfluoro-n-octane 389
- Perfluorocarbon liquids 388
- Perfluorodecalin 389
- Perfluorotributylamine 389
- Perforated
 - corneal ulcer 70, 91
 - ulcer 91
- Perforating injuries 150
- Perform indirect ophthalmoscopy 38
- Periorbital
 - edema 291
 - tissues 595
- Peripapillary
 - atrophy 195
 - staphyloma 477
- Peripheral
 - anterior synechiae 123, 147, 153, 207, 282
 - cornea 83
 - cystoid degenerations 371
 - field test 198
 - mirror 187
 - retina 146
 - retinal pigment degeneration 400
 - ulcerative keratitis 74
 - uveitis 377
- Perivascular exudates 146
- Perivasculitis 151
- Permanent
 - facial paralysis 555
 - muscle weakness 511
- Pernicious anemia 584
- Persistent
 - epithelial defects 131
 - fetal vasculature 220, 309, 379
 - hyperplastic primary vitreous 376, 379, 408
 - intranasal synechiae 609
 - primary hyperplastic vitreous 34
- Persplex ruler 583
- Peter's anomaly 309
- Petroclinoid ligament 41
- Petrous
 - apex syndromes 502
 - bone fracture 503
 - temporal bones 43
- Pseudotumor cerebri 462
- Phacolytic glaucoma 207, 250
- Phenothiazine 63, 310
- Phenylbutazone 20
- Phenylephrine pilocarpine test 208
- Pheochromocytoma 352
- Phlebolith 47
- Photocoagulation scar expansion 343
- Photokeratoscopy signs 98
- Photophobia 151, 290
- Photopic stress test 535
- Photostress recovery time 310
- Phthisis 379
 - bulbi 88, 89, 92, 148, 274
- Physostigmine 22
- Phytanic acid storage disease 405
- Pictorial vision test 8
- Piggy back lenses 103
- Pigment
 - dispersion syndrome 237, 267
 - dissemination and iris atrophy 269
 - epithelium detachment 417
 - granules 229
- Pigmentary
 - glaucoma 207, 217, 230, 269, 271
 - retinopathy 398
 - theory 402
- Pigmented
 - band keratopathy 63
 - intraocular tumors 230
 - trabecular meshwork 189

- Pilocarpine 22, 258, 259
- Pineal body 40
- Pinealoma 407
- Ping-pong gaze 514
- Pinhole test 4
- Pituitary
 - adenoma 41, 46, 196
 - fossa 40
 - lesions 521
 - macroadenoma 54
 - tumors 44, 466, 491
- Placido disk 57
- Planoconvex lens 36
- Planum sphenoidale 40
- Plateau iris 201
 - configuration 203
 - syndrome 203, 207
- Plexiform
 - neurofibroma 582
 - neuroma 562
- Pneumocystis carinii* 136
- POEMS syndrome 588
- Polyarteritis nodosa 83, 165, 483
- Polycoria 123
- Polycythemia 162
- Polydimethyl siloxane 388
- Polyhexamethylene biguanide 74
- Polymerase chain reaction 167
- Polymyalgia rheumatica 483
- Polymyxin 18, 74
- Pontine
 - hemorrhage 441
 - syndromes 500
- Poor corneal penetration 262
- Position maintenance system 611
- Possner-Schlossman syndrome 147
- Posterior
 - chamber depth 202
 - ciliary arteries 237
 - clinoids 40
 - corneal
 - defect 115
 - surface 118
 - diameter 14
 - ethmoidal nerve 60
 - fossa tumor 497
 - keratoconus 101
 - lamella 126, 548, 561
 - limbal border 14
 - pigment epithelium 152
 - pole tumors 309
 - polymorphous 109
 - dystrophy 108, 118, 121, 122
 - scleritis 154, 586
 - segment
 - findings 151
 - indications 422
 - stress lines 98
 - subcapsular cataract 402, 585
 - sub-Tenon injection 173
 - synechiae 148, 208, 235, 345
 - uveitis 134, 135, 136, 410
 - vitreous detachment 145
 - wall of
 - maxillary antrum 42
 - orbit 43
- Post-inflammatory glaucoma 217
- Post-intraocular surgery 229
- Post-laser iridotomy 230
- Postoperative
 - inflammation 131
 - trauma 121
 - uveitis 158
- Post-traumatic glaucoma 294
- Potato dextrose agar 69
- Potential acuity
 - meter test 31
 - testing 4
- Precapillary arterial loops 365
- Prednisolone 21
 - acetate 172
- Preferential looking tests 6
- Premature presbyopia 6
- Prednisolone
 - acetate suspension 20
 - sodium phosphate solution 20
- Preretinal vasculitis 174
- Presumed ocular histoplasmosis 148
- Previous
 - cataract surgery 288
 - conjunctival surgery 281, 288
 - penetrating keratoplasty 281
- Primary
 - amyloidosis 237
 - angle closure 203
 - glaucoma 190, 203
 - suspect 203
 - B-cell intraocular lymphoma 154
 - endothelial diseases 121

- epithelial dystrophies 116
 - familial amyloidosis 108
 - open-angle glaucoma 213, 269, 276, 665
 - pigmentary retinal degeneration 398
 - position nystagmus 516
 - Principle
 - behind
 - Gram stain 67
 - indirect ophthalmoscopy 36
 - of MRI 51
 - of pinhole 5
 - of slit lamp illumination 26
 - Prism cover test 613
 - Procedure of testing near vision 4
 - Prodromal stage of angle closure glaucoma 267
 - Progressive
 - corneal deterioration 555
 - iris atrophy 123, 124
 - night blindness 398
 - optic atrophy 157
 - proptosis 592
 - Proliferative
 - diabetic retinopathy 322
 - vitreoretinopathy 169, 376, 386
 - Prolonged
 - glaucoma 88
 - hypotony 313, 374
 - Prominent
 - cell and flare reaction 245
 - ocular signs 512
 - Prone
 - dark room test 208
 - test 208
 - Propionibacterium*
 - acnes* 390
 - gene endophthalmitis 149
 - Proptosis 79, 577
 - Prostaglandin 249, 258, 259
 - analogs 257
 - synthetase inhibitors 240
 - Protanopia 11
 - Protein kinase inhibitors 25
 - Proteus mirabilis* 390
 - Protozoal infections 160
 - Pruritis 254
 - Pseudo-Argyll Robertson pupil 492
 - Pseudocornea formation 92
 - Pseudoexfoliation glaucoma 233, 271
 - Pseudoexfoliative glaucoma 217, 231
 - Pseudo-Gadenigo's syndrome 503
 - Pseudomonas aeruginosa* 66, 315, 390
 - Pseudophakic
 - bullous keratopathy 118, 125, 126, 129
 - pupillary block 267
 - Pseudotumor 45, 178
 - cerebri 176
 - Pseudo-von Graefe sign 492
 - Pseudoxanthoma elasticum 101
 - Psoriasis 140
 - Psoriatic arthritis 137
 - Psychosis 176
 - Pterygopalatine fossa 42
 - Ptosis 79, 562
 - Pulmonary
 - aspiration 511
 - edema 256
 - venous obstruction 179
 - Punctal
 - eversion 550
 - occlusion 290
 - Punctate
 - epithelial
 - erosions 251
 - keratopathy 29
 - keratitis 78, 290
 - Pupil-gaze dyskinesia 492
 - Pupillary
 - block 131, 201, 239, 285
 - glaucoma 310, 312
 - membrane 285
 - reconstruction 172
 - reflex 6
 - Pupilloplasty 266
 - Purkinje's entoptic phenomenon 311
 - Purtscher's retinopathy 350, 441
 - Purulent iridocyclitis 70
 - Putterman's method 563
- Q**
- Q switched mode 338
 - Quadruple sectoranopia 519
 - Quicker visual rehabilitation 129

- Quiescent
 disease 591
 scleritis 298
 Quinine 468
- R**
- Rabies 126
 Radial
 keratoneuritis 73
 keratotomy 72
 Radiation retinopathy 350, 351, 353
 Radiographic exophthalmometry 579
 Ranibizumab 419
 Rash of secondary syphilis 140
 Raymond's syndrome 502
 Reactivation of dendritic keratitis 255
 Recent cardiac illness 317
 Recurrence of herpes simplex 290
 Recurrent
 corneal erosions 116
 emphysema 578
 Red
 blood cells 143
 reflex 33
 Reduced aqueous production 304
 Reese-Ellsworth classification 410
 Reflex tearing 543
 Refractive
 index 15
 of cornea 14
 surgeries 62
 Refractory juvenile glaucoma 294
 Refsum's syndrome 405
 Regressing drusens 416
 Reid's baseline 48
 Reis-Bucklers dystrophy 107
 Reiter's syndrome 138, 140, 167
 Relapsing polychondritis 83, 483
 Removal of lens 425
 debris 246
 Renal
 disease 154, 352
 disorders 161
 failure 317, 484
 Residual lens material in anterior chamber 246
 Respiratory crisis 511
 Restoration of vision 392
 Reticulum cell sarcoma 171
 Retina 79, 314
 Retinal
 aplasia 404
 artery
 macroaneurysm 351
 plaques 195
 astrocytic hamartoma 410
 breaks 372, 374
 cryotherapy 227
 detachment 33, 79, 146, 147, 169, 230, 310, 367, 379, 389, 391, 409, 425
 dysplasia 34, 379, 409
 dystrophy 398, 404
 edema 157, 375, 472
 exudates 38
 folds 386
 hard exudates 416
 hemorrhage 344, 345
 hypoxia 221
 incarceration 385
 migraine 363
 neovascularization 352
 pigment epithelium 315, 368
 transplantation 420
 rotation 420
 tear 38
 vasculitis 157
 vein 372
 occlusion 317
 Retinaocular cell sarcoma 221
 Retinitis 136
 pigmentosa 101, 331, 398-401, 404, 465
 punctata albescens 403
 Retinoblastoma 33, 41, 47, 137, 145, 221, 377, 379, 407, 410
 Retinochoroiditis 134
 Retinoic acid 626
 Retinopathy of prematurity 34, 220, 379, 408
 Retinoschisis 221, 371, 379
 Retrobulbar
 alcohol injection 210
 hemorrhage 311
 neuritis 196, 367, 466
 tumors 586
 Retroillumination of iris 29
 Retrolental fibroplasia 376

- Reverse Galilean telescopes 406
 Rhabdomyosarcoma 407, 410, 582, 587
 Rhegmatogenous 372, 380
 detachment 422
 Rheumatic fever 161
 Rheumatoid arthritis 83, 84, 137, 160, 161, 168, 174, 483, 510
 Rhinogenous optic neuritis 446
 Rhinostomy fibrosis 609
 Rhomboid flap 570
 Rickettsial infections 160
 Rigid gas permeable contact lens 103
 Rimexalone 21
 Ring scotoma 399
 Ritch trabeculoplasty 187
 Rizzuti
 phenomenon 98
 sign 99
 Rod-cone dystrophy 398
 Rodenstock panfundoscopic 347
 Role of
 nitric oxide in eye 264
 scleral indentation in examination of fundus 39
 using contact lens 268
 Roman test types 3, 4
 Roof of orbit 42
 Rose K design 103
 RPE
 depigmentation 353
 dystrophy 230
 Rubeola 80
 Rubeosis 144, 153
 iris 379
 Rubeotic glaucoma 220
- S**
- Sabin Feldman test 166
 Sabouraud's dextrose agar 69
 Saccadic system 611
 Salus's sign 352
 Salzmann degeneration 81
 Sampaolesi's line 189
 Sanfilippo's syndrome 469
 Sarcoid granuloma 43
 Sarcoidosis 88, 140, 165, 356, 587
 Sausage poison 606
 Scanning laser polarimetry 193, 219
 Scar
 expansion 345
 tissue 320
 Scarring stromal 292
 Scheie's
 classification 349
 of arteriolosclerosis 349
 procedure 275
 Schirmer's test 558
 Schlemm's canal 214, 278
 endothelium 236
 Schnyder's
 crystalline corneal dystrophy 108
 dystrophy 63, 112
 Schwalbe's
 line 188, 191, 278
 Scissoring reflex on retinoscopy 100
 Sclera 14, 290
 Scleral
 buckling 172
 for large tears 384
 melt 299
 spur 188, 191
 staphyloma 286
 thickness 202
 thinning 274
 ulceration 97
 Sclerectomy 275
 Scleritis 73, 75
 Sclerocornea 115
 Scleroderma 165, 168
 Sclerosed calcified arteries 471
 Sclerosis of
 choroid and choriocapillaries 402
 retinal vessels 402
 trabecular meshwork 147
 vessel wall 352
 Sclerotic scatter 27, 28
 Sclerouveitis 136
 Seclusio pupillae 144, 145, 148
 Secondary
 angle closure with pupillary block 207
 diabetes mellitus 177
 endothelial diseases 121
 glaucoma 70, 148, 190
 graft failure 133
 infection 135, 175
 Sector iridectomy 238
 Sectoral iris atrophy 78, 208
 Seidel's test 282, 315

- Selective laser trabeculoplasty 232
- Sella
 - syndrome 44
 - turcica 42
- Sellar masses 53
- Semiconductor lasers 338
- Septic cavernous sinus thrombosis 529
- Septicemia 126
- Sequelae of trachoma 65
- Serous
 - choroidal detachment 285
 - cyst 145
- Serum
 - lactate dehydrogen 167
 - protein electrophoresis 85
- Severe
 - acute anterior uveitis 173
 - cardiac decompensation 256
 - chemical burns 126
 - dehydration 256
 - hypertension 365
 - liver diseases 162
 - ptosis 566
 - vasculitis 157
 - vitreitis 379
- Severity of ptosis 565
- Shaffer's grading system 190
- Shape and size of orbits 42
- Sheridan's
 - ball test 8
 - Gardiner test 8
 - letter test 9
- Shock optic neuropathy 218
- Short wavelength automated perimetry 217
- Sickle cell
 - anemia 162
 - disease 221
 - hemoglobinopathies 376
 - retinopathy 220
- Sickling hemoglobinopathies 363
- Siedel's scotoma 195
- Siegrist's streaks 353
- Significant visual loss 463
- Signs of
 - keratoconus 98
 - raised intracranial tension 41
- Silicon oil 388
 - keratopathy 389
 - migration under retina 389
- Site of aqueous production 14
- Sjogren's syndrome 168
- Slight central bearing 103
- Slightly dilated non reacting pupil 210
- Slit lamp 26, 346
 - beam 32
 - biomicroscope 26
 - examination 26, 628
 - findings of guttae 118
 - photography 31
- Small
 - interfering RNA 420
 - subconjunctival hemorrhages 286
- Smaller
 - capsulorhexis 312
 - molecular weight 69
- Smith's
 - lazy-T procedure 553
 - modification of Kuhnt-Szymanowski procedure 553
- Smooth pursuit system 611
- Snail track degeneration 371
- Snap back test 550
- Snellen's
 - chart 2
 - near vision test 3, 4
- Snow blindness 206
- Sodium
 - and fluid retention 177
 - nitrite 25
 - nitroprusside 25
 - sulfacetamide 61
- SoftPerm lens 103
- Solar keratosis 94
- Solid state lasers 338
- Soper lens system 103
- Spaeth classification 191
- Sparing of choriocapillaries 150
- Spasm of near reflex 501
- Spasmus nutans 513
- Specular
 - microscopy 118, 131
 - reflection 27, 30
- Sphenoid
 - ridge meningiomas 46
 - wing meningoma 582
- Spheroidal degeneration 63, 64, 88
- Sphincter
 - muscle degeneration 235
 - muscle of iris 487

- Sphincterotomy 266
 Spinal cord tumors 459
 Spindle cell variant 95
 Spinocerebellar degenerations 405
 Spironolactone 265
 Split-thickness skin grafts 570
 Spurious night blindness 398
 Squamous
 cell carcinoma 95
 dysplasia 95
 Staphylectomy 92
 Staphylococcal blepharitis 58
Staphylococcus
 aureus 390
 epidermidis 390
 Staphyloma 298
 formation 92
 Stargardt's disease 11
 Stem cell theory 94
 Sterile stromal ulcers 29
 Steroid
 induced glaucoma 147, 217, 242
 induced uveitis 147
 Stevens-Johnson syndrome 126,
 254
 Stickler syndrome 248, 374
 Stiles-Crawford effect 9, 455
 Stocker's line 64
Streptococcus
 pneumoniae 66, 390
 viridans 390
 Streptomycin 468
 Stroma 102, 119
 Stromal
 dystrophies 107, 115
 infiltration 73
 keratitis 77, 78
 thinning 98, 125
 Sturge-Weber syndrome 47, 179,
 190
 Subacute bacterial endophthalmitis
 148
 Subarachnoid space syndrome 498,
 502
 Subbrow incision 594
 Subconjunctival
 and retrobulbar injections 173
 fibrosis 282
 hemorrhages 291
 Subcutaneous
 thrombophlebitis 156
 tissue atrophy 177
 Subepithelial
 keratitis 77
 mucinous dystrophy 63
 Subfoveal CNV 419
 Subperiosteal hematoma 582
 Subretinal
 exudates 352
 fibrosis 343, 345
 fluid 375
 migration of gas 387
 neovascular membrane 171, 323
 Sulfite oxidase deficiency 248, 309
 Superficial
 amyloid 63
 corneal vascularization 97
 keratectomy 59
 lamellar keratectomy 87
 limbic keratoconjunctivitis 58
 punctate keratitis 77, 254, 292
 ulceration 82
 Superior
 oblique muscle 16
 orbital fissure 42, 43
 syndrome 500
 orbitotomy 593, 594
 rectus 486, 584
 vena cava obstruction 179
 Superotemporal subluxation of lens
 310
 Suppurative iridocyclitis 139
 Suprachoroidal
 hemorrhage 203, 274, 312
 lamina 368
 silicon oil 389
 Surgical
 keratometer 57
 limbus 14
 scars 550
 trauma 121
 Suture
 removal 132
 technique 552
 Swelling of optic nerve head 353
 Swirl staining of cornea 100
 Swollen lens 203
 Sylvian aqueduct 449

- Symblepharon 290
 Symmetric lymphoma 580
 Sympathetic
 ophthalmia 136, 139, 148, 150,
 154, 174, 221, 286, 306, 425
 ophthalmitis 274
 Symptomatic therapy 510
 Symptoms of Moore's ulcer 82
 Synechial angle closure 270
 Syphilis 83, 140, 161, 410
 Syphilitic retinitis 220
 Systemic
 antiplatelet therapy 536
 complications of steroids 176
 diseases 116
 hypertension 180, 252, 468
 hyperthermia 180
 infections 126
 lupus erythematosus 160, 165,
 356, 426, 483, 492
 sclerosis 83
 toxins 137
 vascular disease 355
- T**
- Tabes dorsalis 466
 Tachycardia 252
 Tacrolimus 22
 Takayasu's
 arteritis 483
 disease 221
 Tapetoretinal degeneration 398
 Tarsal
 plates 17
 wedge resection 561
 Tarsoconjunctival
 composite graft 561
 flap 575
 Tears in Descemet's membrane 115
 Tectonic grafting 86
 Teller acuity card test 7
 Temporal
 arteritis 365, 468
 pallor 471
 Temporalis transfer 555
 Tenon's
 capsule and conjunctiva 297
 cyst 277
 space 595
 Tenzel's lateral semicircular rotation
 flap 575
- Teratoma 44, 582
 Terrien's marginal
 degeneration 84
 keratitis 83
 Tessler's classification 136
 Testing visual acuity 2
 Theil-Behnke dystrophy 108
 Theophylline 161
 Theories of neovascuogenesis 221
 Therapeutic keratoplasty 132
 Thermal sclerostomy 275
 Thermokeratoplasty 104
 Thickened
 iris 151
 posterior hyaloid 333
 preretinal membrane 333
 Thickening of retina 357
 Thickness
 map 192
 of cornea 14
 Thinned retina 372
 Thinning of cells over Descemet's
 warts 119
 Third nerve
 misdirection 562
 palsy 562, 656
 Threatened vision 170
 Thrombocytopenia 255
 Thrombophilic disorders 363
 Thrombosis of central retinal vein
 355
 Thrombotic glaucoma 220
 Thyroid
 disorder 161, 512
 eye disease 178
 ophthalmopathy 49, 468, 497
 orbitopathy 583
 related orbitopathy 526, 577
 Timolol 23, 251
 Tissue
 plasminogen activator 283
 storage time 131
 Tobramycin 18, 19, 68
 Topical
 acyclovir 77
 antiglaucoma medications 210
 miotics 310
 steroids 86, 210, 246
 Topometer of Watson 583
 Toric intraocular lenses 311
 Torsional deviation 615

- Total
 - binocular blindness 543
 - monocular blindness 544
 - ophthalmoplegia 537
 - retinal detachment 404
 - Toxemia of pregnancy 154, 352
 - Toxic
 - amblyopia 465
 - corneal hypoesthesia 61
 - optic neuropathies 218
 - Toxocara granuloma of retina/
choroid 148
 - Toxocariasis 34, 408
 - Toxoplasma 379
 - dye test 166
 - Toxoplasmosis 47, 51, 137, 138,
148, 166, 366, 410
 - Trabecular
 - dialysis 190
 - meshwork 188, 235, 278
 - toxicity 262
 - Trabeculectomy 275, 276
 - Trabeculens 187
 - Trabeculitis 147
 - Trabeculoplasty 266
 - Trabeculopuncture 266
 - Trachoma 58
 - Traction retinal detachment 422
 - Transcaruncular incision 604
 - Transconjunctival incision 604
 - Transcutaneous incisions 603
 - Transient
 - ischemic attack 532
 - ptosis 210
 - Translucency of tumor 409
 - Transpupillary thermotherapy 411,
419
 - Transverse sutures 559
 - Traquair's junctional scotoma 519
 - Traumatic
 - avulsion of optic nerve 367
 - optic atrophy 465, 466
 - scars 550
 - secondary angle closure 267
 - uveitis 158
 - Treatment of
 - iridocorneal endothelial syndrome
124
 - malignant melanoma 305
 - ocular neovascularization 535
 - uveitis 172
 - Trial of anti-tuberculous treatment
169
 - Triamcinolone 21
 - acetonide 21, 173
 - diacetate 21
 - Trichromatic theory of Young and
Helmholtz 11
 - Tricurve flex lens for nipple cone
103
 - Trifluoromethyl siloxane 388
 - Trifluorothymidine 20
 - Triple test 208
 - Tritanomalous 11
 - Tritanopia 11
 - Tropicamide 172
 - Truncal obesity 404
 - Tuberculin skin testing 162
 - Tuberculoma 51
 - Tuberculosis 80, 81, 83, 140, 148,
160, 161, 410
 - Tuberculum sellae 40
 - Tuberous sclerosis 47
 - Tubular vision 399
 - Tumbling E test 8, 9
 - Tumors
 - in muscle cone 45
 - of anterior cranial fossa 44
 - of floor of orbit 582
 - Turk's line 65
 - Turner's syndrome 101
 - Two stage installation 297
 - Types of
 - contact lenses 103
 - corneal opacities 91
 - glaucoma 222
 - graft failure 133
 - herpes simplex keratitis 77
 - incision 604
 - keratometers 57
 - keratoplasty 125
 - lamellar keratoplasty 126
 - pinhole 5
 - Tyrosenemia 63
- U**
- Ulcer 115
 - Ulcerative
 - colitis 137, 140
 - stomatitis 174
 - Ulcus rodens 82
 - Ultrasonography 155

- Ultrasound biomicroscope 201
 - Uncal herniation syndrome 493
 - Uncomplicated cataract extraction 480
 - Uncontrolled
 - glaucoma 313
 - uveitis 170
 - Uncrossed horizontal diplopia 501
 - Unexplained proptosis 48
 - Unilateral optic neuritis 446
 - Unoprostone 23, 255
 - Unsteady central fixation 7
 - Untreated hypertension 426
 - Upper
 - eyelid 16
 - ptosis 607
 - reconstruction 574
 - retraction 285, 607
 - lid retractors 548
 - Uremia 480
 - Urethral ulcers 140
 - Urethritis 140
 - Uric acid retention 254
 - Uses of
 - auxillaries in direct ophthalmoscopy 35
 - skin tests 164
 - Usher's syndrome 404
 - Urticaria 291
 - Uvea 14, 290
 - Uveal effusion syndrome 154, 379
 - Uveitic glaucoma 223, 229, 239, 250, 294
 - Uveitis 82, 134, 235, 237, 255, 267, 270, 306, 379
 - syndromes 171
- V**
- Vaccinia 80
 - Vancomycin 18, 19, 67, 68, 397
 - Vascular
 - endothelium 236
 - engorgement 49
 - filling defects 319
 - mononeuropathy 497
 - occlusions 146, 376
 - pulsations 578
 - theory 402
 - thrombosis 74
 - Vasculitis 342
 - Venous varix 179
 - Vergence system 611
 - Vernal conjunctivitis 58, 101
 - Vernier acuity 3, 9
 - Vertebral compression fracture 176
 - Vertical
 - deviation 615
 - diameter 14
 - retraction syndrome 487
 - strabismus 298
 - Vestibular system 514
 - Vestibulo-ocular reflexes 513
 - Videokeratography signs 98
 - Viral
 - infections 159
 - keratitis 77
 - retinitis 170
 - Viscocanalostomy 275
 - Vision 541
 - in infants 6
 - Visual
 - acuity 1, 7, 93, 475
 - measurements 5
 - angle 1
 - evoked potential 544
 - fatigue 151
 - field 403
 - in neuro-ophthalmology 519
 - loss 208
 - fixation 514
 - Vitamin
 - A 161
 - deficiency 626
 - toxicity 450
 - B12 159
 - C 419
 - D 88
 - E 419
 - Vitreotomy 169, 172, 221, 422, 424
 - Vitreous
 - cells 153
 - floaters 389
 - fluorophotometry 403
 - hemorrhage 33, 145, 352, 367, 379, 409, 422, 425
 - humor 15
 - loss 285
 - opacities 38, 206
 - touch 121
 - Vitritis 134, 157, 391

Vogt's
 Koyanagi Harada syndrome 137,
 154, 171
 striae 98, 99
 Volk
 super macula 347
 trans equator 347
 Volume of orbit 17
 Vomiting 256
 von Art's triangle 142
 von Hippel-Lindau disease 47
 Vortex vein 14, 237
 V-Y plasty 554, 570

W

Watson's ocular topometer
 580
 Webbed facial scar 609
 Weber's syndrome 493
 Wegener's granulomatosis 46, 83,
 84
 Weight of lens 15
 Weil-Marchesani syndrome 248,
 309
 Westergren's method 162
 White dot syndrome 138
 Wilms' tumor 407, 582
 Wilson's disease 64
 Wintrobe's method 162

Without pupillary block 203
 Worth's Ivory ball test 8

X

Xeroderma pigmentosa 101
 X-ray
 chest 170
 hands and feet 170
 in ophthalmology 40
 sacroiliac joint 170
 skull 170
 in ophthalmology 40

Y

YAG
 capsulotomy 31
 peripheral iridotomy 247

Z

Zehender's exophthalmometer 579
 Zeiss four mirror 187
 Zinc oxide 419
 Zonular
 dialysis 235
 tension 308
 weakness 236
 Zoom system 32
 Z-plasty 554, 570
 Zygomatic bone 593