

Outline of Fractures

A fracture is a **complete or incomplete break or crack** in the continuity of a bone.

Classification - By quality of bone in relation to load

- a) **Traumatic fractures** - Occurs when excessive force is applied to *normal bone* either **directly** or **indirectly**
- b) **Fatigue/Stress fractures** - This occurs if bones are subjected to *chronic repetitive forces*, none of which alone would be enough to break the bone but which mean that the *mechanical structure of the bone is gradually fatigued*

Examples (in order of frequency);

- March fracture of the 2nd & 3rd metatarsal heads
- Mid & Distal Tibia & Fibula fractures in *long distance runners & dancers*
- Neck of femur
- Fractures of the **pubic rami** in severely *osteoporotic or osteomalacic* patients

Detected early by **Scintigraphy** or **MRI** as radiographic changes appear after **2-4wks.**

- c) **Pathological fractures** - Produced when the *strength of bone is reduced by disease*

Table 1.1 The more important causes of pathological fracture.

LOCAL DISEASE OF BONE

Infections

Pyogenic osteomyelitis (usually in chronic form)

Benign tumours

Chondroma (enchondroma)

Giant-cell tumour (osteoclastoma)

Haemangioma (spine)

Malignant tumours

Osteosarcoma (osteogenic sarcoma)

Ewing's tumour

Solitary myeloma

Metastatic carcinoma (especially from lung, breast, prostate, thyroid or kidney)

Metastatic sarcoma (from primary in another bone)

Miscellaneous

Simple bone cyst

Monostotic fibrous dysplasia

Eosinophilic granuloma

Bone atrophy in paralytic conditions such as poliomyelitis

Tabes dorsalis

Osteonecrosis after irradiation

GENERAL AFFECTIONS OF THE SKELETON

Congenital disorders

Osteogenesis imperfecta (fragilitas ossium)

Diffuse rarefaction of bone

Senile osteoporosis

Parathyroid osteodystrophy

Cushing's syndrome

Infantile rickets

Coeliac (gluten-induced) rickets

Uraemic osteodystrophy (renal rickets)

Cystinosis (renal tubular rickets; Fanconi syndrome)

Nutritional osteomalacia

Idiopathic steatorrhoea

Disseminated tumours

Multiple myeloma (myelomatosis)

Diffuse metastatic carcinoma

Miscellaneous

Paget's disease (osteitis deformans)

Polyostotic fibrous dysplasia

Gaucher's disease

Hand-Schüller-Christian disease

d) **Partial/Green-stick fractures** - Occur because bones in children especially <10 years are very flexible. Longitudinal compression force leads to **crumpling** whereas an **angulation force** tends to **bend** the bone at one cortex & to **buckle or break it** at the other producing an **incomplete fracture**. They are **not** mobile due to the **thick periosteum**.

Open & Closed Fractures

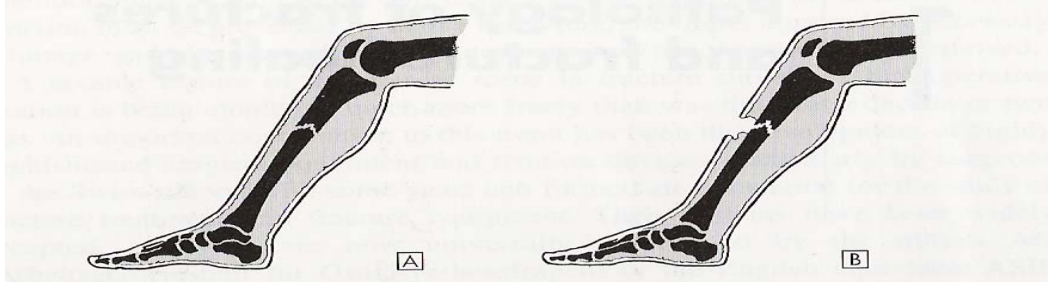


Fig. 1.1 [A] Closed or simple fracture. There is no communication between the fractured bone and the body surface. [B] Open or compound fracture. There is a wound leading down to the site of fracture. Organisms may gain access through the wound and infect the bone.

Open/Compound fractures

Open/Compound fractures can communicate with the outside in 3 ways;

- i) Trauma directly damaging skin & breaks bone - **outside-in injury**
- ii) Bone breaks & pierces through skin - **inside-out injury**
- iii) Injury to skin which becomes necrotic & sloughs off exposing bone

Classification

A. Gustilo and Anderson Classification:

- **Type 1 fracture** is a low-energy injury with a wound <1 cm in length, often from an **inside-out injury**.
- **Type 2 fracture** involves a wound >1 cm long and significantly more injury, caused by more energy absorption during the production of the fracture.
- **Type 3 fracture** has extensive wounds >10 cm in length, significant **fracture fragment comminution**, and a great deal of **soft tissue damage & periosteal stripping**. It is usually a high-energy injury. This type of injury results typically from **high-velocity gun shots, motorcycle accidents, or injuries with contamination from outdoor sites** such as with tornado disasters or farming accidents.
 - * **Type 3A fractures do not require major reconstructive surgery** to provide **skin coverage**.
 - * **Type 3B fractures**, in contrast, usually **require reconstructive procedures** because of soft tissue defects that provide either *poor coverage for bone or no coverage*.
 - * **Type 3C injuries involve vascular compromise** requiring surgical repair or reconstruction.

B. Mangled Extremity Severity Score (MESS) Scoring:

Table 3-1. Factors in evaluation of the mangled extremity severity score (MESS) variables.¹

	Points
A. Skeletal and soft tissue injury	
Low energy (stab; simple fracture; "civilian" gunshot wound)	1
Medium energy (open or multiple fractures, dislocation)	2
High energy (close-range shotgun or "military" gunshot wound, crush injury)	3
Very high energy (above plus gross contamination, soft tissue avulsion)	4
B. Limb ischemia²	
Pulse reduced or absent but perfusion normal	1
Pulseless; paresthesia, diminished capillary refilling	2
Cool, paralyzed, insensate, numb	3
C. Shock	
Systolic blood pressure almost more than 90 mm Hg	0
Hypotensive transiently	1
Persistent hypotension	2
D. Age	
<30 years	0
30-50 years	1
>50 years	2

¹Adapted and reproduced, with permission, from Johansen K et al: Objective criteria accurately predict amputation following lower extremity trauma. J Trauma 1990;30:369.
²Score doubled for ischemia more than 6 hours.

Mx of Open Fractures

Principles of Mx;

- Wound debridement
- Antibiotic prophylaxis
- Stabilization of the fracture
- Early wound cover

i) First-Aid

i) Airway with cervical spine control, **B**reathing, **C**irculation & haemorrhage control, **D**isability & **E**xposure - 30% of patients with an open fracture have other life threatening injuries

- Assess **neurovascular status** of the limb
- Relieve pain
- IV antibiotics - 70% of open fractures are contaminated with bacteria at the time of injury
Give antibiotics for **48-72Hrs** post injury & for **48-72Hrs** each time a further procedure is performed;
* **Cephalosporins** (+ **Aminoglycoside** - Type II/III) (+ **Penicillin** - if a farmyard injury to cover for *Clostridium perfringens*)

- Tetanus prophylaxis - *Toxoid* for those previously immunised, *human antiserum* if not.
- Swab wound
- Photograph - *to prevent reopening for examination*
- Cover wound
- Splint
- X-ray

ii) Surgical debridement - Principles;

- **Wound extension** - Small wounds should be extended & excised to allow adequate exposure.
- **Wound excision** - The wound margins are excised, but only enough to leave healthy skin edges.
- **Removal of devitalized tissue** - Dead muscle can be recognised by;
 - * Purplish colour
 - * Mushy consistency
 - * Failure to contract when stimulated
 - * Failure to bleed when cut
- **Wound cleansing** - All foreign material & tissue debris must be carefully removed. **Type II/III** - Irrigate with **5-10L NS** ± *Water & Hydrogen peroxide*
- Unattached bone should be discarded
- Nerves & Tendons - It is best to leave cut nerves & tendons alone, though if the wound is absolutely clean & no dissection is required, they can be sutured.
- Repeat debridement at **48Hr** intervals until the wound is clean

Amputation

Indications;

- Congenital anomalies especially of **lower limbs** so as to enable weight bearing
- Traumatic (*Patient specific*)
 - A MESS score ≥ 7
 - Massive loss of bone
 - Extensive neurovascular damage
 - Frost bite
- Vascular conditions e.g. *Diabetes, Arteriosclerosis, Raynaud's Disease, SLE, Berger's Disease*
- Infective conditions e.g. *Gas gangrene, Madura foot, Chronic osteomyelitis*
- Neoplastic conditions

Ix;

- Clinical Evaluation - **T°C, Capillary refill & Pulse**
- **FHG, ECG**
- **Ischemic-Brachial Pressure Index** - Use *doppler pressure probe*. Ratio between **pressure at amputation** level with **SBP of brachial artery** - Has to be **>0.45** or no healing will occur.
 - Normal - **1**
 - Intermittent claudication - **0.6-0.9**
 - Resting pain - **0.3-0.6**
 - Impending gangrene - **≤ 0.3 or Ankle SBP <50mmHg**
- **Angiography** to check if there is an indication for reconstruction
- **Transcutaneous oximetry** - Determines the *capacity of the vascular system to deliver oxygen to level of proposed surgery* (**20-30mmHg**)

Surgical Principles;

- **Metabolic Cost of Amputation** is *inversely proportional* to the **length of the residual limb & number of joints involved** thus amputations should be **as low as possible** to *reduce oxygen consumption & increase walking speed of the stump*
- Design flaps
- Vessels are ligated - *The stump is usually supplied by collaterals.*
- Retract & cut nerves & cushion them in muscles or fat to prevent formation of a painful neuroma. **Exception - Sciatic nerve** that has a companion artery from the inferior gluteal artery that must be ligated.
- Cut & suture **antagonistic** muscles together (**myoplasty**); also **myodesis** - suture muscles to bone e.g. after disarticulation
- Cut bone
- Suture skin flaps together

Types;

- a) **Syme's Amputation** - of tibia & fibula; Removal of both malleoli & avoid flaring of metaphysis
- b) **Guillotine Amputation;**

Types;

- **Transfemoral** - **12cm** above knee
- **Transtibial** - **12-15cm** below knee - *Especially in kids - Cut fibula at higher level*

Can go longer if adequate muscle cover; if not, prosthesis won't fit

Indications;

- Massive trauma with very contaminated bones
- Severe infection - *the wound is **not** closed to prevent post-op infection*
- Peripheral vascular disease e.g. *Diabetes*

Complications;

- Psychological
- Pain;
 - Phantom limb pain/sensation - Managed by;
 - * Counselling
 - * Early & ↑ use of prosthesis
 - * Physiotherapy
 - * Intermittent compression
 - * Transcutaneous electrical nerve stimulation
 - Painful neuroma - *prevented retracting the nerve before cutting, then cushioning stump.*
 - Recurrence of disease
 - Incompetent soft tissue envelope with bony projection - *need to bevel & smooth edges*
- Bone overgrowth especially in kids - **disarticulation** can prevent this
- Non-healing of stump
- Stump breakdown - *due to oedema (too much soft tissue/dressing above stump)*
- Joint contractures - Occur between *amputation & fitting* of prosthesis. Controlled by;
 - Proper surgical technique (*don't suture antagonistic muscles **in tension***)
 - Early physiotherapy & mobilization
 - **Transfemoral** amputation - The patient should **avoid sitting with the hip in flexion**
 - **Transtibial** amputations - " " **legs hanging over the bed.**
- Dermatological problems - *Epidermal cysts, folliculitis, Verrucous hyperplasia* - due to prosthesis with *socket that constricts stump* producing a wart-like hyperplasia with darkening of skin, serous discharge etc
- Thromboembolism

iii) Stabilize fracture;

If there is **no obvious contamination** & the time lapse is **<8hrs**, open fractures of all grades up to **Type IIIA** can be treated as for closed injuries, i.e.

- * External fixation - *for not more than 2wks*
- * Splints, casts & traction - *Can be used in stable **Type I** fracture*
- * Intramedullary nailing - **Type I** fracture
- * Plates & screws - useful in *displaced metaphyseal or intraarticular fractures & fractures of smaller tubular bones.*

iv) **After care;**

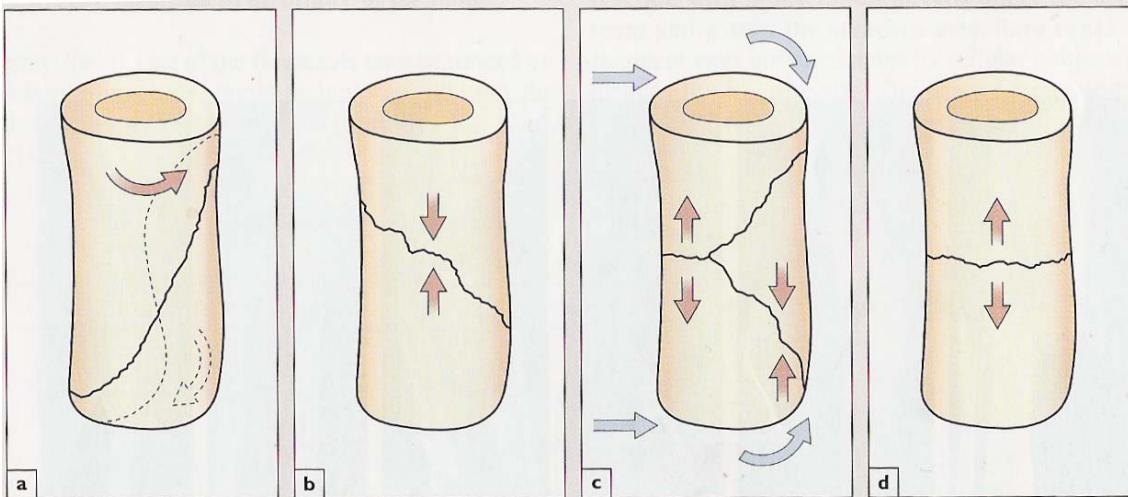
- The limb is elevated & it's circulation carefully monitored
- Antibiotic cover
- If the wound has been left open, it is inspected at **2-3days** & covered appropriately

v) **Coverage & closure of the wound;**

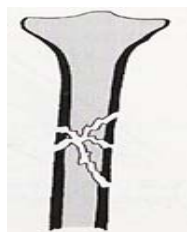
- * A small, uncontaminated **Type I** wound may (after debridement) be sutured, provided this can be done *without tension*.
- * All other wounds must be left open until the dangers of *tension & infection* have passed. The wound is lightly packed with sterile gauze & is inspected **after 2 days**; if it is clean, it is sutured (delayed 1° closure) or skin grafted - *The wound must be covered in 5-7days unless there is infection.*
 - Suturing skin directly - *Type I* wound.
 - 1° delayed closure
 - Skin grafting/Flaps

vi) **Physiotherapy & Rehabilitation**

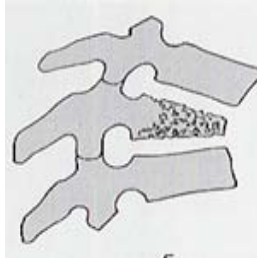
Patterns Of Fractures



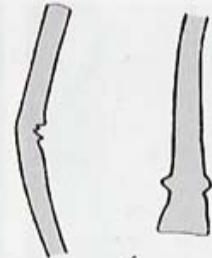
23.1 Mechanisms of injury Some fracture patterns suggest the causal mechanism: (a) spiral pattern (twisting); (b) short oblique pattern (compression); (c) triangular 'butterfly' fragment (bending); and (d) transverse pattern (tension). Spiral and some (long) oblique patterns are usually due to low energy indirect injuries; bending and transverse patterns are caused by high energy direct trauma.



e) **Comminuted fracture**



f) **Compression fracture**



g) **Greenstick fracture**

h) **Segmental fracture** - a fracture in two parts of the same bone.

i) **Avulsion/Distracton fractures** - a fracture that occurs when a joint capsule, muscle, or ligament insertion or origin is pulled from the bone as a result of a *sprain dislocation or strong contracture of the muscle against resistance*; as the soft tissue is pulled away from the bone, a fragment or fragments of the bone may come away with it.

Examples;

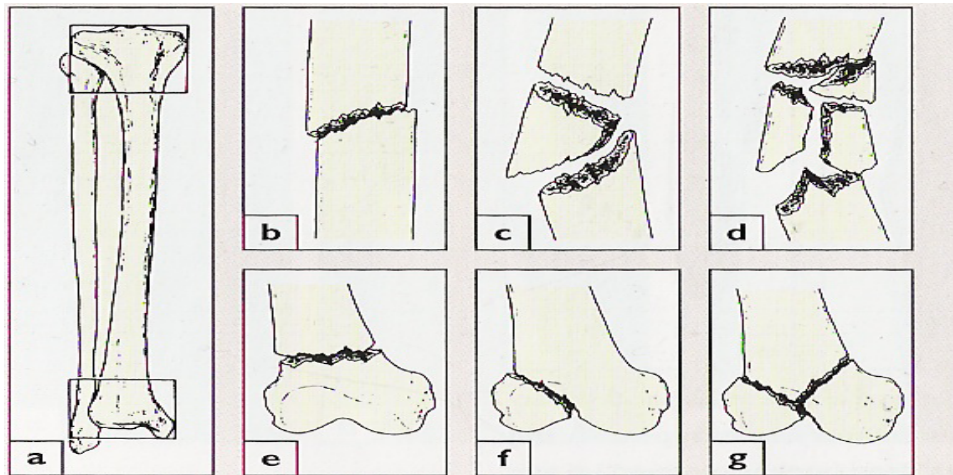
- Patella - The quadriceps muscle
- The Olecranon - Triceps
- The 5th Metatarsal head - Peroneus tertius
- Inferior boarder of ischium - Hamstrings
- Anterior Inferior Iliac Spine - Rectus femoris
- Lesser trochanter - Iliopsoas

Controversial;

- Tibial apophyseal stress lesion of Osgood-Schlatter disease
- Sinding-Larson-Johansson syndrome

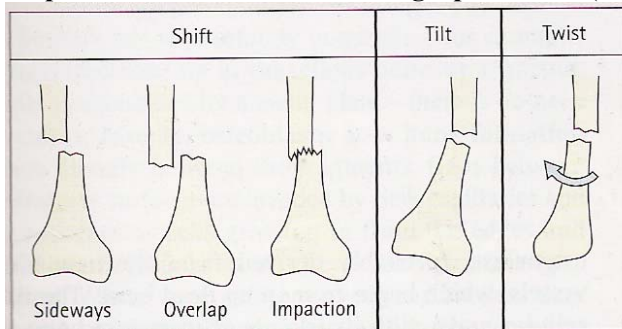
Describing a fracture

- i) Bone
- ii) Segment - *Proximal, Diaphyseal or Distal*
- iii) Type of fracture
 - Proximal & Distal fractures may be **extra-articular, peri-articular or complete articular**
 - Diaphyseal fractures may be **Simple, Wedge or Complex**



23.3 Müller's classification (a) Each long bone has three segments – proximal, diaphyseal and distal; the proximal and distal segments are each defined by a square based on the widest part of the bone. (b, c, d). Diaphyseal fractures may be simple, wedge or complex. (e, f, g) Proximal and distal fractures may be extra-articular, partial articular or complete articular.

iv) Displacement - Based on 2 roentgenographic views (*AP & Lateral*)



23.4 Fracture displacements The different types of fracture displacement.

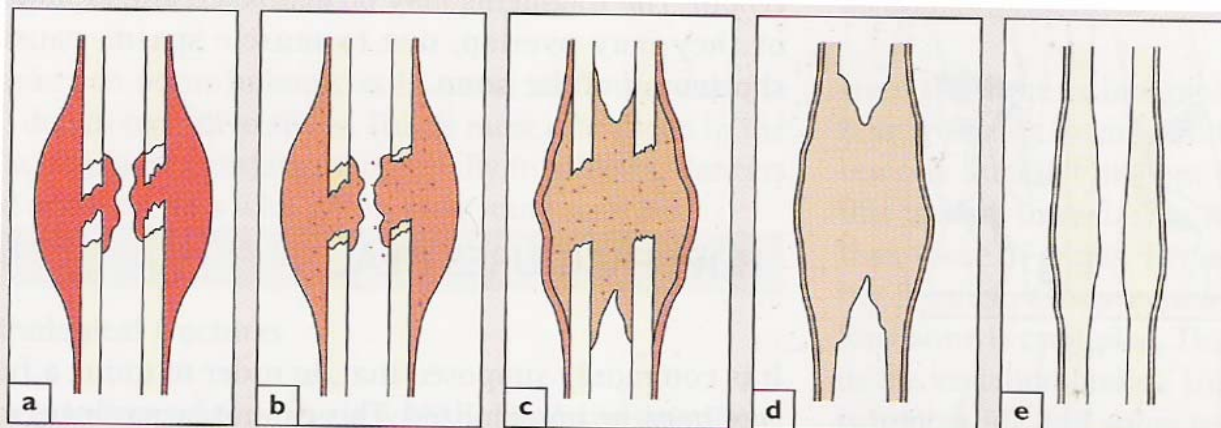
- a) **Translation (Shift)** - Expressed as a *percentage of the diameter of the proximal fragment* (e.g. 25%, 50% or 100%)
- b) **Alignment (Angulation/Tilt)** - This is the relationship of the *distal to the proximal fragment* along their axis. The terms *Anterior, Posterior, Varus or Valgus* are used.
- c) **Rotation (Twist)**
- d) **Length**
 - a) ***Distracted*** - Excessive separation of fracture fragments
 - b) ***Apposition*** - Overlapping due to muscle spasm

Pathophysiology of Fracture Healing

The pattern of healing in a given bone is influenced by;

- Rigidity of fixation of the fragments
- Closeness of their coaptation

Standard stages of bone healing;



23.5 Fracture healing Five stages of healing. (a) *Haematoma*: there is tissue damage and bleeding at the fracture site; the bone ends die back for a few millimetres. (b) *Inflammation*: inflammatory cells appear in the haematoma. (c) *Callus*: the cell population changes to osteoblasts and osteoclasts; dead bone is mopped up and woven bone appears in the fracture callus. (d) *Consolidation*: woven bone is replaced by lamellar bone and the fracture is solidly united. (e) *Remodelling*: the new-formed bone is remodelled to resemble the normal structure.

a) Haematoma (24-48Hrs)

Injury (fracture) leads to haematoma formation from the damaged blood vessels of the *periosteum, endosteum, and surrounding tissues* & there is necrosis of bone immediately adjacent to the fracture.

b) Inflammation & Cellular proliferation

There is immediate release of cytokines that;

- Within hours attract an inflammatory infiltrate of **neutrophils and macrophages** into the haematoma that debride and digest necrotic tissue and debris, including bone, on the fracture surface.
- Attract **undifferentiated stem cells** - probably from the periosteum & the endosteum, which migrate in & start differentiating into **fibroblasts & bone-producing cells (chondroblasts, osteoblasts)**. *Low-oxygen tension, low pH, and movement* favour the differentiation of **chondrocytes**; *high-oxygen tension, high pH, and stability* predispose to **osteoblasts**.

c) Callus formation (4-6wks)

During the reparative stage, the haematoma is gradually replaced by *specialized granulation tissue with the power to form bone - callus*, from both sides of the fracture. Callus is composed of **fibroblasts, chondroblasts, osteoblasts and endothelial cells**.

The extent to which callus forms from the *periosteum, cortical bone or medulla*, depends upon;

- the site of fracture
- the degree of immobilization
- the type of bone injured

As macrophages phagocytose the haematoma and injured tissue, **fibroblasts** deposit a *collagenous matrix*, and **chondroblasts** deposit *mucopeptisaccharides* in a process called **endochondral bone formation**.

The collagenous matrix is then converted to bone as **osteoblasts condense hydroxyapatite crystals** on specific points on the collagen fibres, and **endothelial cells form a vasculature** characteristic of bone with an end result analogous to reinforced concrete.

Eventually the **fibrovascular callus** becomes **calcified** - This is termed as **Union**.

Clinical Union - A bone is clinically united when putting load on the fracture produces *no detectable movement & no pain*. The fracture site will not yet be as strong as the bone around it, but it is united.

Radiological union - Occurs when the callus around the fracture can be seen to pass from one broken bone end to the other *without a gap between*. The fracture across the medulla of the bone **may still be visible**

d) Consolidation

This final phase, involving the replacement of **woven bone** (Immature bone or **osteoid** which is **calcified callus**) by **lamellar bone** in various shapes and arrangements, is necessary to restore the bone to optimal function. This process - **consolidation** - involves the simultaneous meticulously coordinated removal of bone from one site (**osteoclasts**) and deposition in another (**osteoblasts**) & **Ossification** - the process of deposition of **inorganic bone substance** by **osteoblasts** about themselves - starts at the **centre** of the fracture cleft, where oxygen levels may be low.

Osteoclasts are derived from **monocytes** and are large multinucleated cells that remove bone. They are located on the resorption surfaces of the bone. **Osteoblasts** are **mononuclear** and are responsible for the accretion of bone.

e) Remodelling

Bone is strengthened in the lines of stress & resorbed elsewhere

Healing of various bones

- Humerus - 3-6wks
- Radius/Ulna;
 - * Children - 3-6wks
 - * Adults - 6-8wks
- Femur - 12wks (Older patients up to 16wks)
- Tibia/Fibula -16-18wks
- Spine - 4-6wks (*Has good blood supply*)
- Hand & Foot - 3wks

X-Ray changes in Bone Healing

In young children, union is nearly always rapid, callus often being visible radiologically within **2wks** & the bone being consolidated in **4-6wks**.

In adults, new bone visible within **4-6wks** & consolidation is in **16-24wks**

Principles of # Mx

- To obtain & hold fracture alignment
- To limit soft-tissue damage & preserve skin cover
- To prevent-or at least recognize-compartment swelling
- To start early weight bearing (loading promotes healing)
- To start joint movements as soon as possible

i) Reduction

Reducing a fracture involves trying to return the bones to as near to their original position as possible

Acceptable reduction;

- **Lateral shift** of up to **50%**
- **5°** for **varus or valgus** angulation
- **10°** for **anterior or posterior** angulation
- **≤10°** for **rotation** in reference to the **opposite** extremity
- **≤1cm** for **length discrepancy**; *No distraction* should be tolerated

Methods

- a) **Closed reduction** - This is the standard initial method of reducing most common fractures. It is usually carried out under **GA**, but **LA** or **Regional anaesthesia** is sometimes appropriate. The technique is to simply grasp the fragments through the soft tissues, to disimpact them if necessary, & then to adjust them as nearly as possible to their correct position.

Advantages;

- Minimises damage to blood supply & soft tissues

Disadvantages;

- Relies on soft-tissue attachments to reduce the fragments
- Is rarely adequate for intra-articular fractures
- In children, *lack of ossification* makes checking closed reduction *impossible*.

- b) **Open Reduction** - The fracture is exposed surgically so that the fragments can be reduced under direct vision; **Fixation** is usually applied to ensure that the position is maintained.

Indications;

- Some fractures involving *articular surfaces* - Important to achieve perfect reduction to avoid *arthritis*
- When the fracture is complicated by *damage to a nerve or artery*
- *Open fractures* - The wound needs opening up & washing out
- *Grossly unstable* - Internal fixation provides stability, allowing the patient to mobilise

Advantages;

- Allows wounds to be cleaned & fragments to be reduced exactly

Disadvantages;

- Risks damage to the blood supply of the bone
- Incision must be extensile - *able to be extended if necessary*
- Soft tissue cover must be possible

- c) **Reduction by Mechanical traction** - When the contraction of large muscles exerts a strong displacing force, some mechanical aid may be necessary to draw the fragments out to the normal length of the bone. The aim may be to gain full reduction rapidly at one sitting with anaesthesia, or to rely upon gradual reduction by prolonged traction without anaesthesia.

Indications;

- Fractures of the **shaft** of the femur
- Certain types of fracture or displacement of the **cervical spine** e.g. *odontoid peg fractures*

ii) Immobilisation

Indications;

- To *relieve pain*
- To *prevent movement* that might interfere with union
- To prevent *displacement or angulation of the fragments* - Especially fractures of the shafts of the major long bones

Advantages;

- Reduces rates of infection
- Facilitates wound care
- Promotes soft tissue healing
- Allows immobilisation of the limb, *particularly important in multiply injured patients*

Methods;

a) Plaster of Paris (POP)

POP is **hemihydrated CaSO₄** which reacts with water to form **hydrated CaSO₄** and **heat**, evidenced by noticeable warming of the plaster during setting. A thin lining of **stockinet or cellulose bandage** is applied to *prevent the plaster from sticking to the hairs & skin*. If marked swelling is expected, as after an operation upon the limb, a more bulky padding of **surgical cotton wool** should be used.

Plaster bandages are applied in 2 forms;

- Round-&-round bandages
- Longitudinal strips or 'slabs' to reinforce a particular area of weakness or stress

A plaster is best dried by exposure to air.

The plaster is removed by;

- Electrically powered oscillating plaster saws - useful for removing a very thick plaster & for cutting a window through a plaster
- Plaster-cutting shears

Precautions;

- Monitor for possible impairment of circulation 2° to undue swelling within a closely fitting plaster or splint- **Severe pain** within the plaster & **marked swelling of the digits** are warning signs - The period of greatest danger is **12-36hrs** after injury or operation

b) External splint




Fig. 3.11 Thomas's splint with Pearson knee flexion attachment, used mainly for fractures of the shaft of the femur. Note the canvas strips slung between the two bars to support the limb.

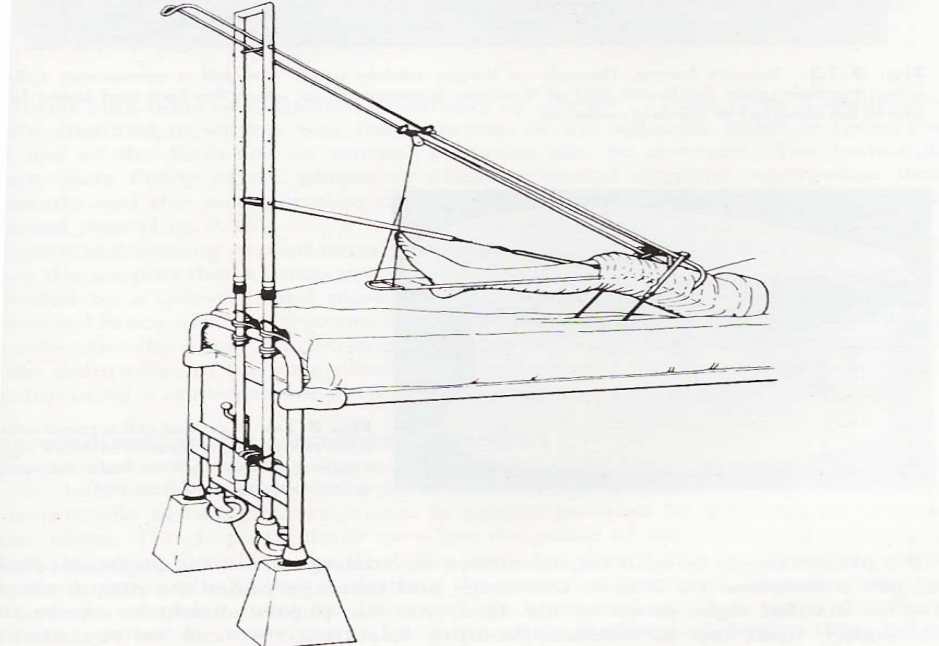


Fig. 3.12 The Povey splint: a modern development of the Thomas's splint. The drawing shows tibial traction applied by a constant force spring. The end of the bed is raised to provide countertraction. (Reproduced by courtesy of Messrs John Drew (London) Ltd.)

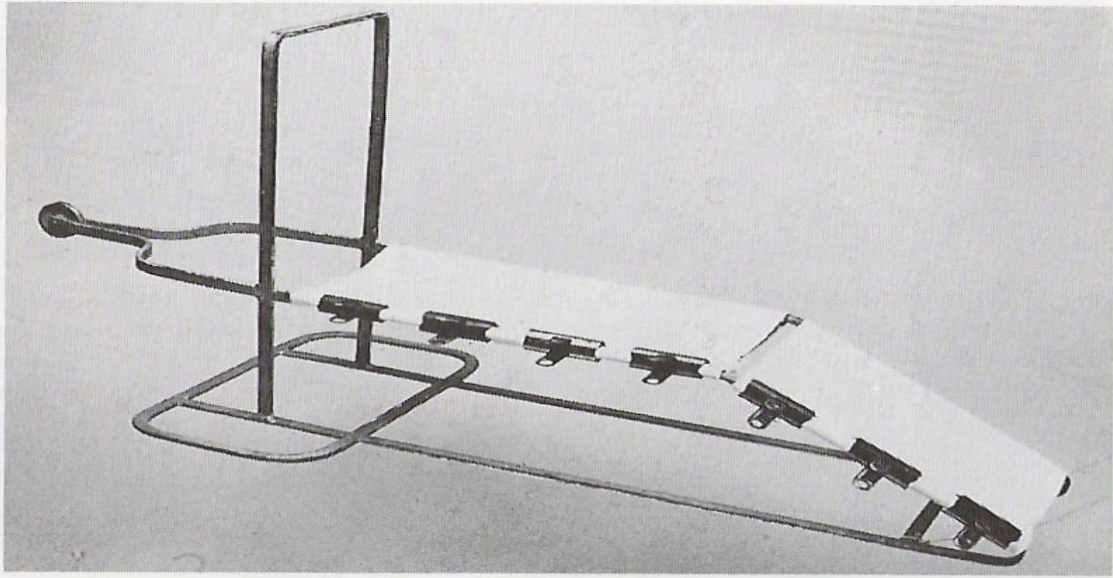


Fig. 3.13 Braun's frame. Though no longer widely used, it is still a convenient splint when traction upon the lower end of the tibia is required, or when the foot and lower leg are to be elevated to combat oedema.

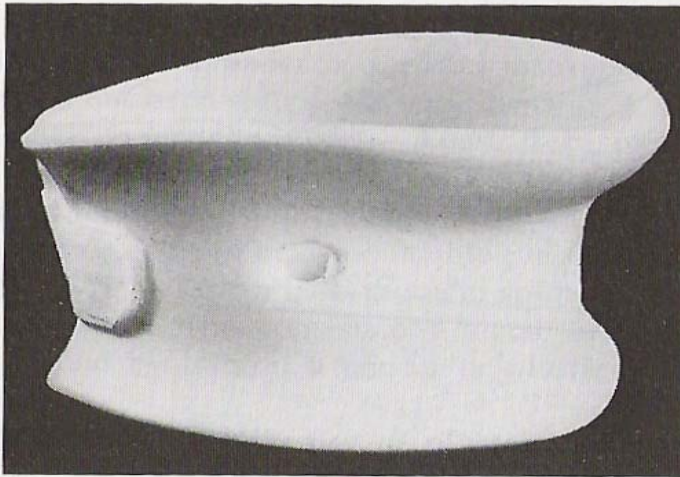


Fig. 3.14 Cervical collar constructed from polyethylene foam. For more rigid support of the neck a 'halo-thoracic' splint may be used (see text).

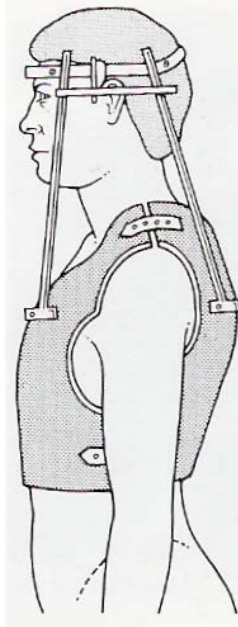


Fig. 7.11 Halo-thoracic support. The halo—a metal ring—is screwed to the skull, and vertical struts unite it to a plastic thoracic vest or to a body plaster. This device gives better immobilisation of the cervical spine than any other splint.

c) **Functional Bracing (Cast Bracing)**

This is a technique in which fractured long bone is supported externally by POP in such a way that function of the adjacent joints is preserved by incorporation of metal or plastic hinges at the level of the adjacent joints & use of the limb for its normal purposes can be resumed. This is normally applied when the fracture is already becoming 'sticky' - **5-6wks** after the injury.

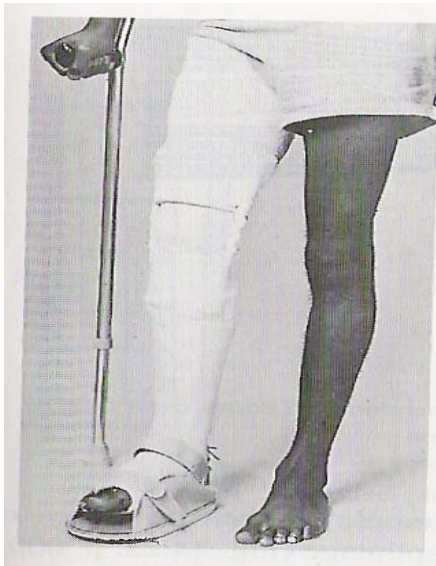

Fig. 3.15 Functional brace (cast brace) suitable for certain fractures of the femoral shaft or tibia. Note the plastic hinges incorporated at the knee. Hinges may also be fitted at the ankle.

d) **Continuous traction**

This is useful when the plane of the fracture is **oblique or spiral**, because the elastic pull of the muscles then tends to draw the distal fragment proximally so that it overlaps the proximal fragment. In such a case, the pull of the muscles must be balanced by sustained traction upon the distal fragment in the long axis of the bone, either by a weight or by some other mechanical device with counterforce in the opposite direction (to prevent the patient being merely dragged along the bed).

Sustained traction of this type is usually combined with some form of *splintage* to give support to the limb against angular deformity;

- **Thomas' splint** or modified version of it in case of a *femoral shaft fracture*
- **Braun's splint** in the case of the *tibia*

Indications;

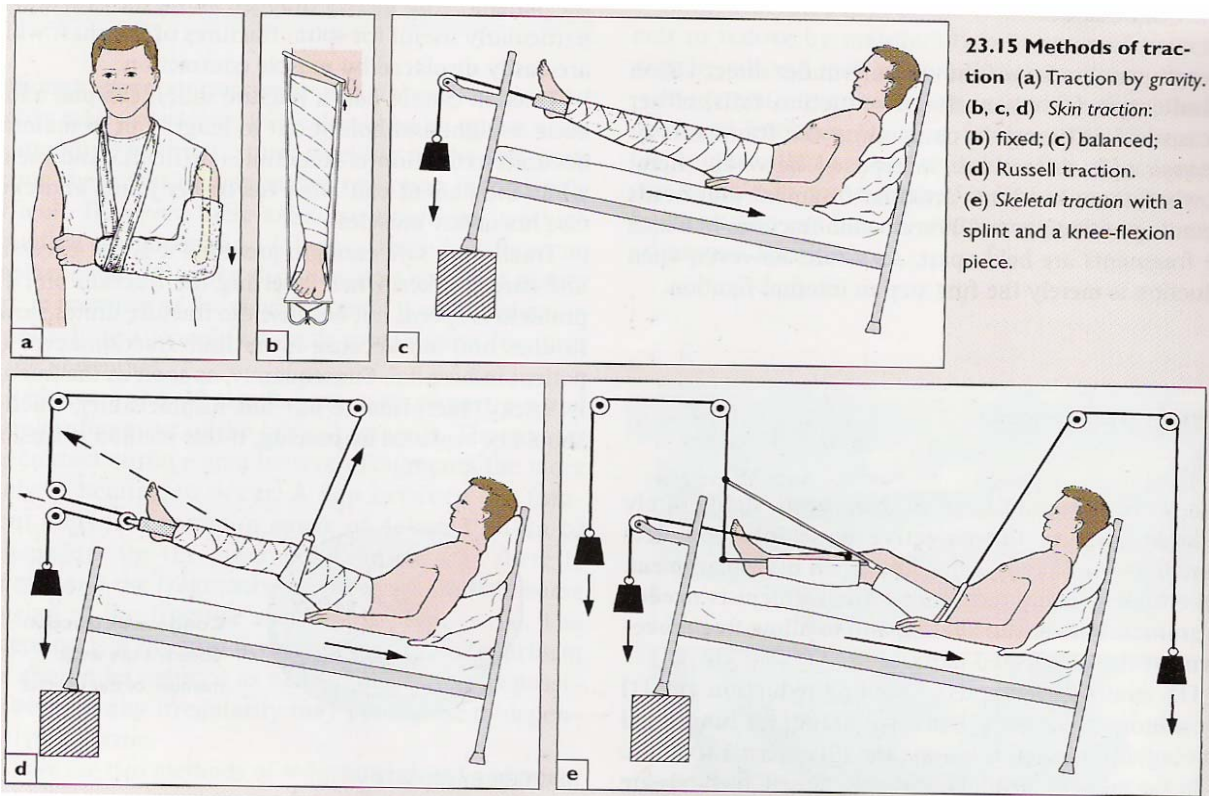
- Fracture of the shaft of the femur
- Certain fractures of the shaft of the tibia
- Certain Fractures of the distal shaft of the humerus
- Traction upon the skull for **cervical spine** injury

Types;

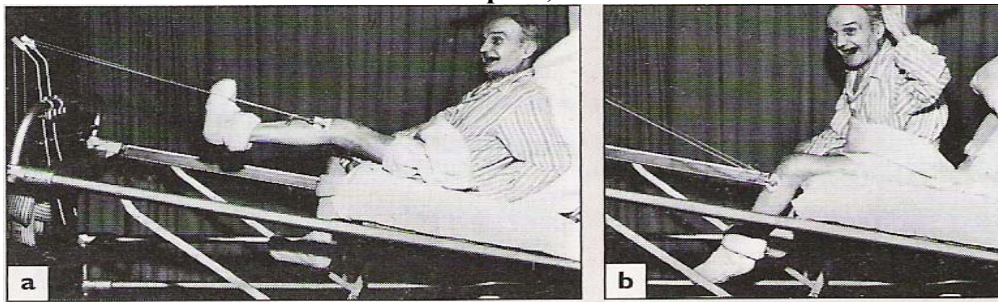
- **Traction by gravity** - Applies only to **upper limb injuries**
- **Skin traction** - will sustain a pull of no more than **4-5Kg**

Parts - *Spreader, cord, pulley, weights*

- a) **Russell traction** - In this method, a splint is **not** used. The traction grip on the leg may be obtained by **Adhesive skin strapping (Spreader)** or a **Steinmann pin** through the tibia. A canvas sling gives support under the knee from the overhead beam. Because of the system of pulleys the **distalward pull is twice the upward pull**, so the resultant pull is approximately in the line of the femur. The foot of the bed is raised on **wooden blocks** so that the patient's own weight provides counter-traction. It is **suitable for** any condition about the **hip or trochanteric region** but is **not suitable for fractures of the shaft of the femur** because there is nothing to give support under the fracture to prevent sagging.
- b) **Fixed traction**
- c) **Balanced traction**
- d) **Combined traction - Fixed + Balanced traction**



Perkins Traction - Skeletal traction without a splint;



- **Skeletal traction** - A *Stiff wire, Steinmann pin or Deinmann pin* (threaded at the centre) is inserted;
 - * **1" below the tibial tuberosity** - For **hip, thigh & knee injuries** - Inserted from **lateral to medial** to avoid injuring the *common peroneal nerve* that goes round the head of the fibula
 - * **Calcaneum** - For **tibial fractures**
 - * **Olecranon** for **supracondylar fractures** of the humerus
 - * Traction upon the skull for **cervical spine** injury - Use weights up to $\frac{1}{3}^{rd}$ patients weight
 - * Distal femur - *If there is concurrent ligamentous injury to the knee*
 - * Distal Tibia
 - * Greater trochanter - *For sideways traction in hip dislocation*

Parts - *Stirrup, cord, pulley, weights*

Use weights $\frac{1}{10}^{th}$ - $\frac{1}{7}^{th}$ the patient's body weight

Complications;

- *Pin-site infection* (S/S - Local tenderness & a loose pin) - Reduced by using **aseptic technique** & maintaining pin for a **maximum of ≤ 3 wks** & the use of **prophylactic antibiotics** usually **2nd generation cephalosporins** given at **induction** (*applies for any prosthetic implantation*)
- *Circulatory embarrassment*
- Nerve injury - leg traction may predispose to *common peroneal nerve injury* & a resultant *drop-foot*

C/I in osteoporosis

e) Fixation

i) External Fixation e.g. Orthofix

This is rigid anchorage of the bone fragments to an external device such as a metal bar through the medium of pins inserted into the proximal & distal fragments of a long bone fracture.

Advantages;

- Minimally invasive
- Can be used when soft-tissue cover is compromised
- Allows early mobilisation
- Can be adjusted later

Types;

- *Unipolar/Bipolar + Uniplanar/Multiplanar*

Indications;

- Management of *open or infected fractures*, where the use of internal fixation devices is undesirable because of the risk that it carries of promoting or exacerbating infection.
- Fractures associated with *severe soft-tissue damage* for which the wound can be left open for inspection, dressing or skin grafting.
- Fractures associated with *nerve or vessel damage*
- *Severe comminuted & unstable fractures*, which can be held out to length until healing commences
- *Un-united fractures*, which can be excised & compressed; sometimes this is combined with elongation (*Callostasis*) & correction of deformity
- Severe multiple injuries, in which early stabilization reduces the risk of serious complications.
- Emergency indications;
 - To stabilise an *unstable pelvic fracture* to try & reduce life-threatening haemorrhage from the pelvic veins
 - To stabilise *a limb with an unstable fracture that has lost its blood supply* so that the vascular surgeon can start work with minimum delay.

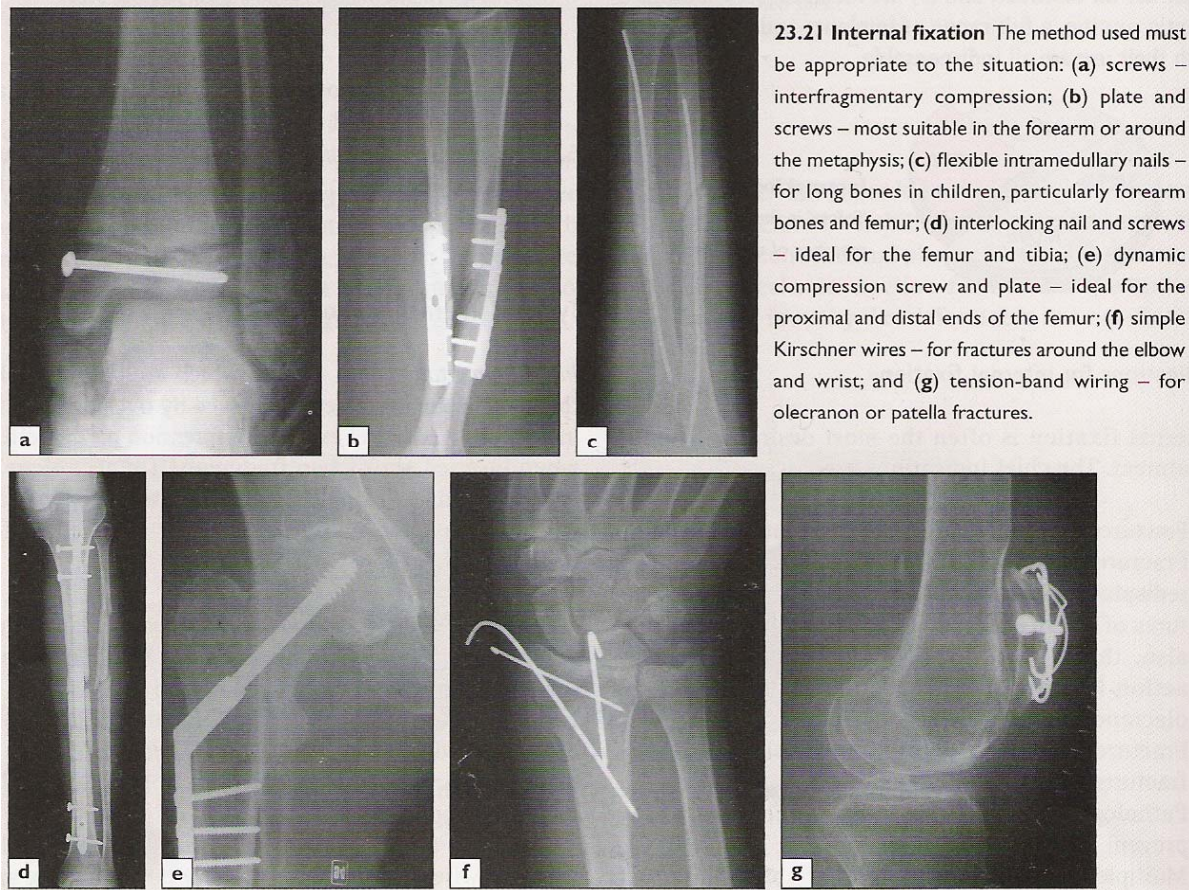
Maintained for a maximum of **2wks** to prevent infection.

ii) Internal Fixation

Indications;

- *Open Reduction*
- *Fractures that are inherently unstable & prone to redisplacement after reduction* (e.g. mid-shaft fractures of the forearm & displaced ankle fractures); also, those liable to be pulled apart by muscle action (e.g. transverse fracture of the patella or olecranon)
- Fractures that *unite poorly & slowly*, principally fractures of the *femoral neck*.
- *Pathological fractures*, in which bone disease may prevent healing.
- *Multiple fractures*, in which early fixation (by either internal or external fixation) reduces the risk of general complications & late multisystem organ failure.
- Fractures in patients who present nursing difficulties (*paraplegics, those with multiple injuries & the very elderly*)

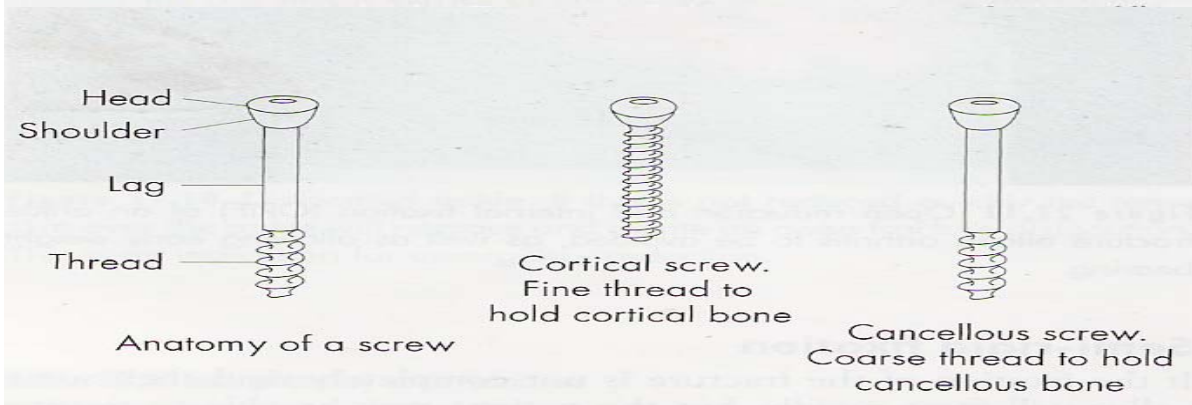
Types;



23.21 Internal fixation The method used must be appropriate to the situation: (a) screws – interfragmentary compression; (b) plate and screws – most suitable in the forearm or around the metaphysis; (c) flexible intramedullary nails – for long bones in children, particularly forearm bones and femur; (d) interlocking nail and screws – ideal for the femur and tibia; (e) dynamic compression screw and plate – ideal for the proximal and distal ends of the femur; (f) simple Kirschner wires – for fractures around the elbow and wrist; and (g) tension-band wiring – for olecranon or patella fractures.

a) Screws

Transfixion screws. The use of a transfixion screw has wide application in the fixation of small detached fragments—for instance the capitulum of the humerus, the olecranon process of the ulna or the medial malleolus of the tibia. A single screw usually suffices. Transfixion screws directed obliquely as in Fig. 3.18 (5) are also appropriate for the fixation of long oblique or spiral fractures of the shaft of a long bone—especially the tibia. In this case at least two screws should be inserted to ensure stable fixation.



If a screw is used to compress two bone fragments together, it is important that the thread of the screw should grip **only the distal fragment** in which the tip of the screw is embedded. If the thread of the screw engages with the proximal fragment, the screw can actually hold the fragments apart. This can be prevented by;

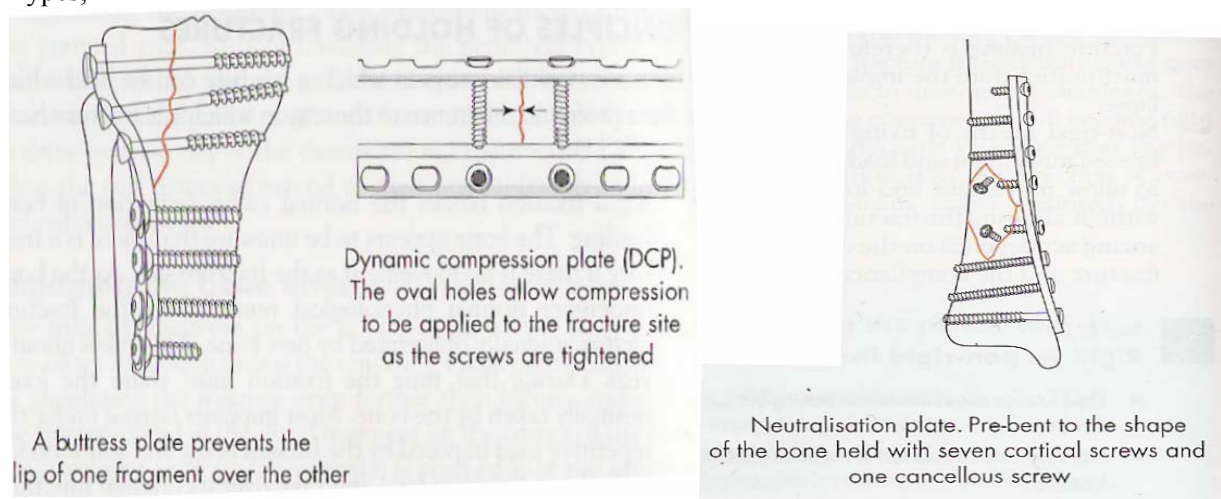
- Using a 'lag' screw
- Drilling the hole in the proximal fragment to a slightly larger size so that the screw threads cannot engage with the wall of the hole i.e. **Lagging the drill hole**

- b) **Plate & screws** - This method is applicable to long bones. Usually a single 4-Hole plate suffices, but a 6-Hole or 8-Hole plate may be preferred for the femur, & occasionally there is a place for double plates, one on each side of the bone.

Disadvantages;

- The bone fragments are not forcibly pressed into close contact; indeed if there is any absorption of the fracture surfaces the plate tends to hold the fragments apart & this may sometimes be a factor in the causation of delayed union. In order to counter this disadvantage of simple plates & to improve coaptation at the time of plating, special compression devices are available by which the fragments are forced together before the plate is finally screwed home (*compression plating*)
- The need to expose the fracture site
- Stripping of soft tissues around the fracture
- An increased risk of introducing infection
- Less secure fixation & delayed weight bearing

Types;



d) **Intramedullary Nailing**

This technique is excellent for many fractures of the long bones, especially when the fracture is near the **middle of the shaft**. It is used regularly for fractures of the *Femur, Tibia, Humerus, Ulna*

i) Indications for **K-Nail - hollow & of clover leaf section;**

- Fractures around the **isthmus of the femur**

Proper size is determined by measuring the *diameter of the isthmus* & the *length from the greater trochanter to the top of the patella*.

Reaming is important;

- * For better grip of the nail
- * Bone spicules act as grafts to patch up the fracture site

ii) Indications for **Interlocking nail** - Has transverse perforations at the ends to allow the insertion of transfixing ('locking') screw through bone & nail.;

- Fractures near the **middle of the shaft**
- Fractures *prone to rotational forces*
- Fractures of bones with a **wide medullary cavity**

Complications of Internal fixation;

- Infection
- Non-union
 - Callus formation is inhibited
 - Damage to soft tissues & blood supply
 - Rigid fixing with a gap between the ends
- Implant failure
- Refracture

Bone grafting

Cancellous bone e.g. from ASIS, is used as the airspaces *promote neovascularization* which delivers to the site *osteoprogenitor cells* that *synthesize osteoid*.

Bone morphogenic proteins are *inductive proteins* that *induce the proliferation of osteoprogenitor cells* to form **osteoid**.

Rehabilitation Equipment

- Walking frames e.g. *Zimmer frame* - used to teach patients to walk before the use of crutches
- Types of crutches;
 - *Axillary crutches* - **Not recommended** due to damage to the *brachial plexus & axillary vessels*.
 - *Elbow crutches*

Complications of Fractures

Early complications

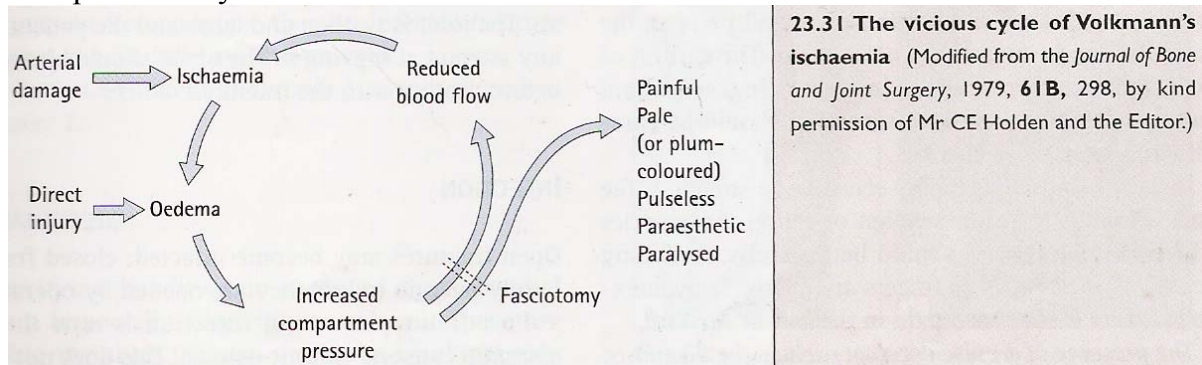
- a) Infection
- b) Vascular injury

Common vascular injuries	
Injury	Vessel
First rib fracture	Subclavian
Shoulder dislocation	Axillary
Humeral supracondylar fracture	Brachial
Elbow dislocation	Brachial
Pelvic fracture	Presacral and internal iliac
Femoral supracondylar fracture	Femoral
Knee dislocation	Popliteal
Proximal tibial	Popliteal or its branches

S/S;

- Paraesthesia or numbness in the toes or the fingers
- Injured limb is cold & pale, or slightly cyanosed
- The pulse is weak or absent

c) Compartment Syndrome



The vicious cycle ends after **12Hrs** or less, in **necrosis of nerve & muscle** within the compartment. *Nerve is capable of regeneration* but **muscle**, once infarcted, can **never** recover & is replaced by **inelastic fibrous tissue** - **Volkmann's ischemic contracture**.

Causes;

- High-risk fractures;
 - Elbow
 - Forearm bones
 - Multiple fractures of the hand or foot
 - **Proximal** 1/3 of tibia
- Swelling of a limb inside a tight plaster cast
- Crush injuries
- Circumferential burns

S/S of Ischemia (**5Ps** - in order of appearance)

- Pain
- Paraesthesia
- Pallor or Plum coloured
- Paralysis
- Pulselessness

d) Nerve injury

Common nerve injuries	
Injury	Vessel
Shoulder dislocation	Axillary
Humeral shaft fracture	Radial
Humeral supracondylar fracture	Radial or median
Elbow medial condyle	Ulnar
Monteggia fracture-dislocation	Posterior interosseous
Hip dislocation	Sciatic
Knee dislocation	Peroneal

S/S;

- **Neurapraxia** - The mildest type of focal nerve lesion - **Demyelination without Axon degeneration** - followed by a complete recovery usually within **6wks earliest**.
- **Axonotmesis** - **Axon degeneration without Demyelination** - The **endoneurium is intact** so regeneration can take place; such a lesion may result from *pinching, crushing, or prolonged pressure*.
- **Neurotmesis** - **Demyelination & Axon degeneration** - with the most severe neurotmesis lesions, the gross continuity of the nerve is disrupted.

Ix;

- **Nerve conduction studies**

e) Haemarthrosis

f) Visceral injury

g) Gas Gangrene

This is a condition produced by **Clostridium perfringens** within **24Hrs** of the injury characterized by **myonecrosis**; The patient complains of **intense pain & swelling around the wound & a brownish discharge** may be seen. There is *little or no pyrexia* but the **pulse rate is increased & a characteristic smell** becomes evident.

h) Fracture blisters

i) Plaster sores & Pressure sores

Late Complications

a) Malunion

When the *fragments join in an unsatisfactory position* (unacceptable angulation, rotation or shortening)

Causes;

- Failure to reduce a fracture adequately
- Failure to immobilise while healing proceeds
- Gradual collapse of *comminuted or osteoporotic* bone

Guidelines for re-manipulation or correction;

- Mal-alignment of **>10-15°** in any plane may cause *asymmetrical loading* of the joint above or below & the late development of 2° *osteoarthritis*.
- Noticeable rotational deformity, may need correction by *remanipulation*, or by *osteotomy & internal fixation*
- In **children, angular deformities** near the **bone ends** will **usually remodel** with time; **rotational deformities will NOT**.
- In the lower limb, shortening of **>2cm** is seldom acceptable to the patient & a limb lengthening procedure may be indicated - *Use of Ilizarov method*

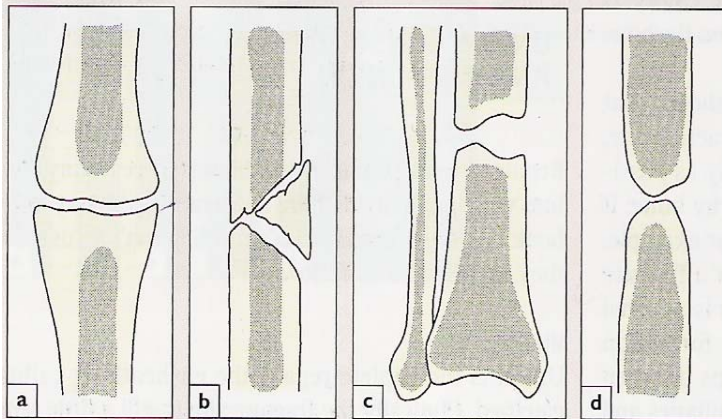
b) Delayed Union & Non-union

Failure of the fragments of a broken bone to knit together in time or at all

Causes of non-union	
The injury	The bone
Soft-tissue loss	Poor blood supply
Bone loss	Poor haematoma
Intact fellow bone	Infection
Soft-tissue interposition	Pathological lesion
The surgeon	The patient
Distraction	Immense
Poor splintage	Immoderate
Poor fixation	Immovable
Impatience	Impossible

DDx - Pseudoarthrosis - Is **NOT** painful *cf* Non-union

Types;



23.9 Non-unions These are generally divided into hypertrophic and atrophic types. Hypertrophic non-unions often have florid streams of callus around the fracture gap – the result of insufficient stability. They are sometimes given colourful names, like (a) elephant's foot. In contrast, atrophic non-unions usually arise from an impaired repair process; they are classified, according to the x-ray appearance, as (b) necrotic, (c) gap and (d) atrophic.

c) Avascular necrosis

Common sites;

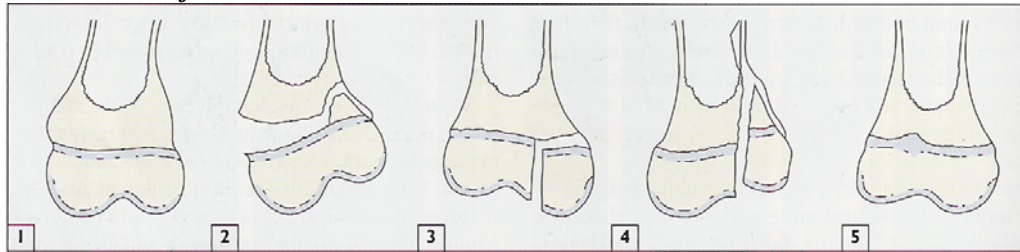
- Head of the femur (*after fracture of the femoral neck or dislocation of the hip*)
- **Proximal** part of the scaphoid (*after fracture through it's waist*)
- Lunate (*following dislocation*)
- **Body** of the talus (*after fracture of it's neck*)

d) Growth disturbance

Shortening due to;

- *Mal-union*, the fragments being united with overlap or with marked angulation
- *Crushing or actual loss of bone*, as in severely comminuted compression fractures or in gunshot wounds when a piece of bone is shot away
- In children, fractures that split the epiphysis traversing the growing portions of the growth plate may lead to asymmetrical growth & the bone ends characteristically angulated.

Salter & Harris Classification



1. A **transverse fracture** through the **hypertrophic or calcified zone** of the plate - usually occurs in *infants* but also seen at *puberty* as a **slipped upper femoral epiphysis**
2. Type 1 + fracture of the metaphysis (*Metaphyseal spike*) - Is the **commonest**; it occurs in older children & **seldom** results in abnormal growth.
3. An intra-articular fracture that **splits the epiphysis** - needs accurate reduction to restore the joint surface. It damages the 'reproductive' layers of the growth plate & **may result in growth disturbance**
4. Type 3 + extends into the metaphysis - **Causes asymmetrical growth**
5. A **longitudinal compression** injury of the epiphysis - there is **no visible fracture** but the growth plate is crushed & this **may result in growth arrest**.

C/P

- Boys > Girls; Infancy or between **10-12yrs**

Ix

- X-ray - There is **widening of the epiphyseal 'gap', incongruity of the joint or tilting of the epiphyseal axis**. A repeat x-ray may be done **4-5days** later if in doubt

Mx

Undisplaced;

- **Type 1&2** - **Splint** the part in a **cast or a close-fitting plaster slab** for **2-4wks** (depending on the site of injury & the age of the child)
- **Type 3&4** - **As above** + a check x-ray after **4days** & again at about **10days** is mandatory *in order not to miss late displacement*.

Displaced;

- **Type 1&2** - **Closed reduction** + the part is then **splinted** securely for **3-6wks**
- **Type 3&4;**
 - a) **Closed reduction** + the part is then **splinted** securely for **4-8wks**; If unsuccessful
 - b) **ORIF** with smooth **Kirschner wires** + **splinting** for **4-6wks**

e) Bed sores

f) Myositis ossificans - Heterotrophic bone formation or deposition of calcium in muscles with fibrosis, causing pain and swelling in muscles usually *due to excessive manipulation of fractures*.

g) Tendon lesions

h) Nerve compression

i) Muscle contracture

j) Joint instability/stiffness

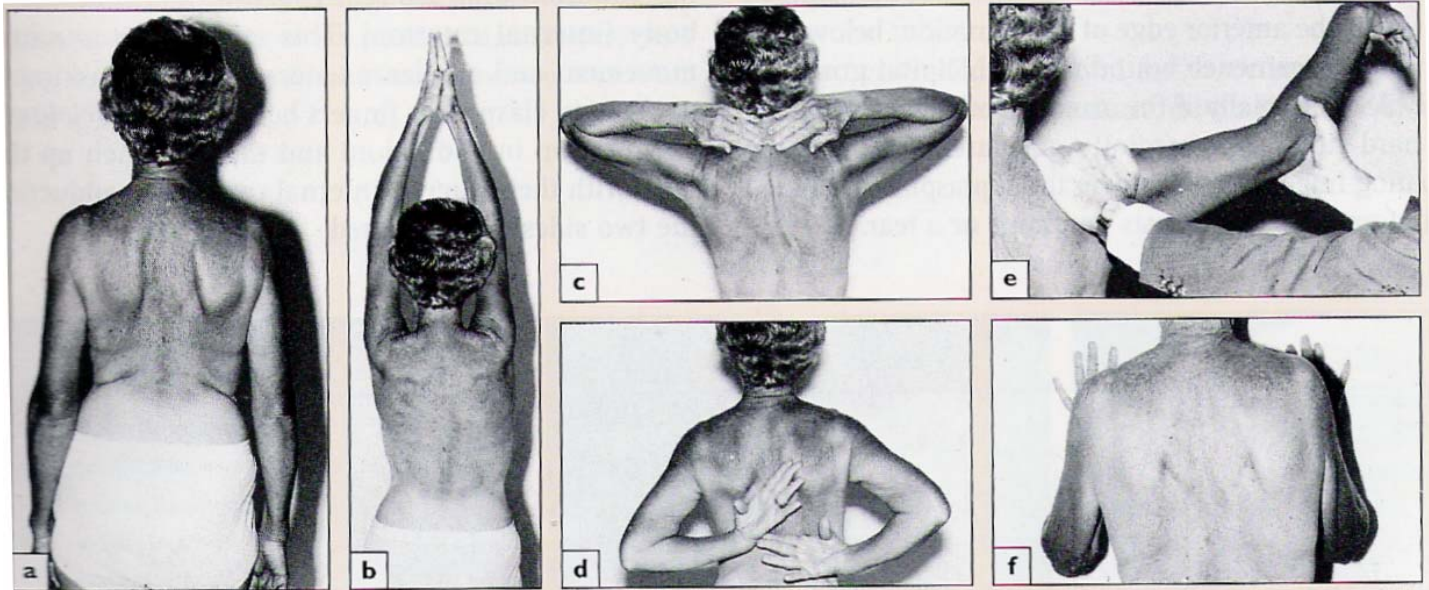
k) Osteoarthritis

l) Fat embolism syndrome - Mainly after severe fractures of the *pelvis & lower limbs*, particularly those of the *femur & tibia*.

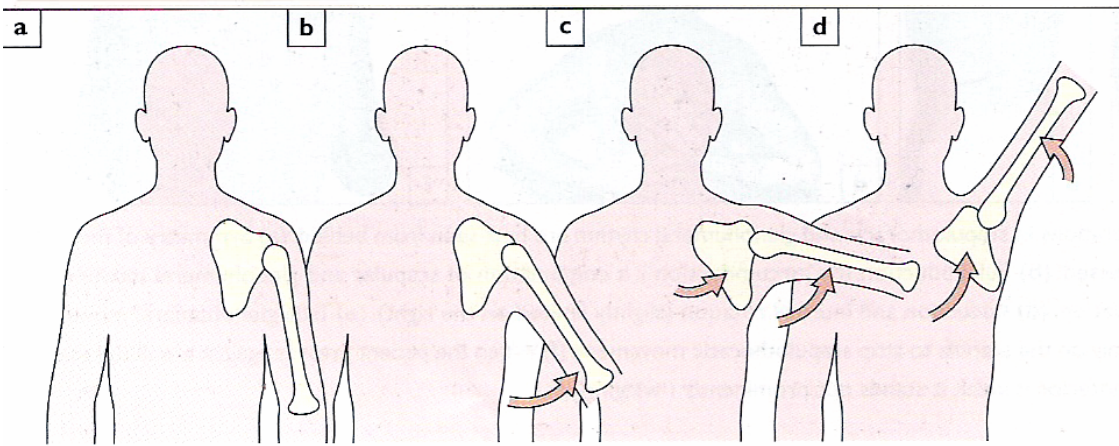
m) Algodystrophy - This is a syndrome comprising **pain, vasomotor instability, trophic skin changes, functional impairment & osteoporosis**. Follows trauma to the *hand & foot & sometimes the knee, hip or shoulder*.

Humerus

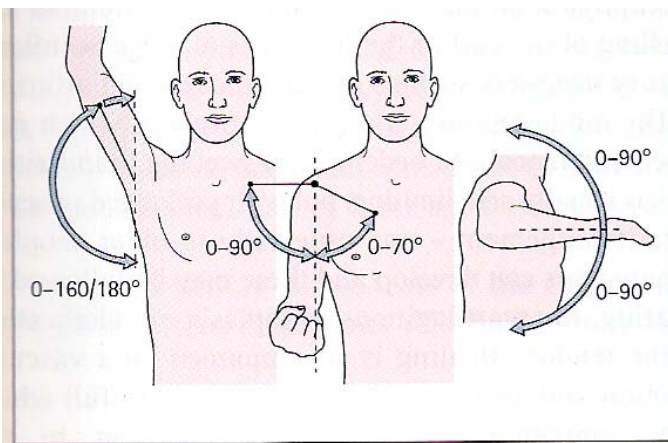
Examination of the Shoulder



13.1 Examination Small alterations in scapulothoracic and glenohumeral rhythm are best seen from behind. (a) Symmetry of the neck, shoulders and scapulae is assessed. (b) Full abduction (or 'circumduction'), a combination of scapular and glenohumeral movements. (c) Abduction and external rotation. (d) Adduction and internal rotation (slightly limited on the right). (e) True glenohumeral movement is gauged by pressing down firmly on the scapula to stop scapulothoracic movement. (f) When the patient presses against a wall the scapula should remain flat; if serratus anterior is weak it stands out prominently ('winging').



13.2 Scapulohumeral rhythm (a-c) During the early phase of abduction, most of the movement takes place at the glenohumeral joint. As the arm rises, the scapula begins to rotate on the thorax (c). In the last phase of abduction, movement is almost entirely scapulothoracic (d).



13.3 Normal range of movement (a) Abduction is from 0° to 160° (or even 180°), but only 90° of this takes place at the glenohumeral joint (in the plane of the scapula, 20° anterior to the coronal plane); the remainder is scapular movement. (b) External rotation is usually about 80° , but internal is rather less because the trunk gets in the way. (c) With the arm abducted to a right angle, internal rotation can be assessed without the trunk getting in the way.

Instability of the Shoulder

The humeral head is held in the shallow glenoid socket by the;

- Glenoid labrum
- Glenohumeral ligaments
- Coracohumeral ligament
- Overlying canopy of the coracoacromial arch
- Surrounding muscles

Anterior instability is the **commonest** cause;

- Lax capsule anteriorly
- Glenoid labrum is often torn
- The joint was designed for a wide range of movements

C/P;

- Acute Dislocation;
 - The arm is forced into **abduction, external rotation & extension**
 - Indentation on the **posterolateral** aspect of the humeral head (**Hill-Sachs lesion**) - A compression fracture due to the humeral head being forced against the anterior glenoid rim each time it dislocates.
- Recurrent subluxation - Develops in 1/3 patients **<30yrs & 20% older patients**;
 - Patient describes a 'catching' sensation followed by 'numbness' or 'weakness' - **Dead arm syndrome** - whenever the shoulder is used with the arm in the overhead position

O/E;

- Recurrent subluxation;
 - **Apprehension test** - With the patient seated or lying, the examiner cautiously lifts the arm into abduction, external rotation & then extension; at the crucial moment the patient senses that the humeral head is about to slip out anteriorly & his body tautens in apprehension.
 - **Fulcrum test** - With the patient lying supine, arm abducted at 90°, the examiner places one hand behind the patient's shoulder to act as a fulcrum over which the humeral head is levered forward by extending & laterally rotating the arm; the patient immediately becomes apprehensive.

Ix;

- **Axillary view XR**
- CT angiography for labral tears
- Recurrent subluxation - The *labrum & capsule are often detached from the anterior rim of the glenoid* (**Bankart lesion**)

Mx;

- Closed reduction & immobilization for **3wks** in a **collar & cuff** then start physiotherapy & remove at **6wks**
 - Hanging method - Patient lies on the bed sedated with the arm hanging on the edge of the bed
 - Hypocritic method - Gentle traction & counter-traction
 - Cock's manoeuvre
- Sx - Indications;
 - Frequent dislocation, *especially if this is painful*
 - Recurrent subluxation or a fear of dislocation sufficient to *prevent participation in everyday activities* including sports
- Neglected shoulder dislocation;
 - Children - **ORIF**
 - Elderly - **Physiotherapy** to increase motion

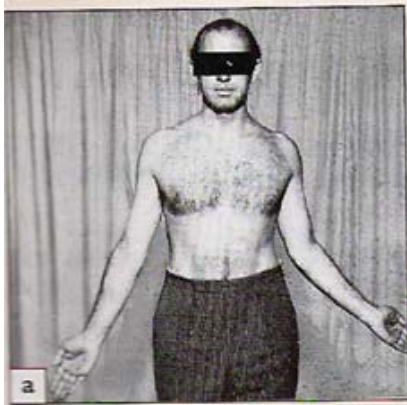Complications;

- Rotator cuff tear
- Axillary nerve & artery injury
- Shoulder stiffness

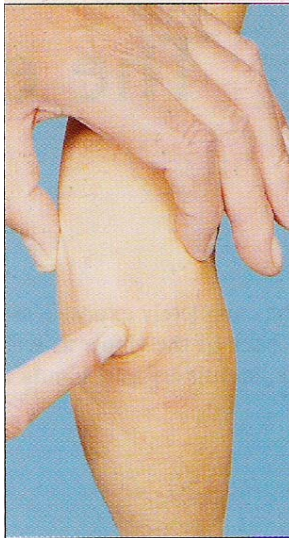Examination of the Elbow Joint

Often the **neck & shoulders** (which are sources of referred pain to the elbow) & the **hand** (for signs of nerve dysfunction) also need to be examined.

- a) **Inspection** - Both limbs should be completely exposed, & is essential to look at the back of the elbow as well as the front.

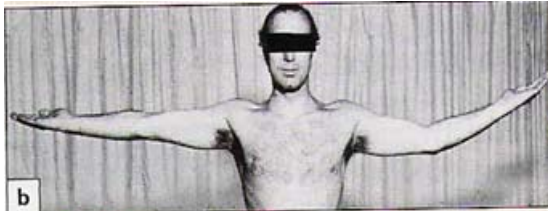

- b) **Palpation**



14.2 Examination
 Feeling begins with the skin. Is there undue warmth? Next, feel the bony landmarks. With the elbow flexed, the tips of the medial and lateral epicondyles and the olecranon process form an isosceles triangle. With the elbow extended, they lie transversely in line with each other. These relationships are disturbed in post-traumatic deformities of the elbow.

- c) **Movement**

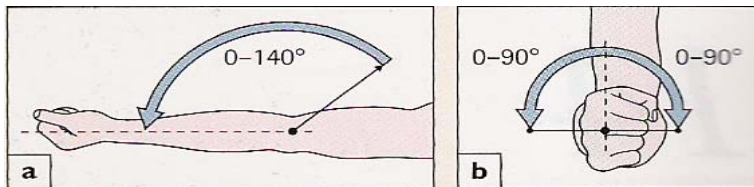


Extension



Flexion

With the elbows tucked into the sides & flexed to a right angle, the radioulnar joints are tested for **pronation & supination**.



14.3 Normal range of movement (a) The extended position is recorded as 0° and any hyperextension as a minus quantity; flexion is full when the arm and forearm make contact. (b) From the neutral position the radioulnar joint rotates 90° into pronation and 90° into supination.

- d) **Muscle Bulk, Tone & Power**

Shaft of Humerus

C/P

- # **Above deltoid insertion** - The proximal fragment is **adducted by pectoralis major**
- # **Lower down** - The proximal fragment is **adducted by the deltoid**
- Injury to the **radial nerve** in the radial groove is common but recovery is usual

Mx

- **Closed Reduction** - A **hanging cast** is applied from shoulder to wrist with the **elbow flexed at 90°**, & the forearm section is suspended in a sling around the patient's neck. This cast is replaced after **2-3wks** by a *short (shoulder to elbow) cast or a functional brace* for a further **6wks (union)** after which only a sling is needed until the fracture is consolidated.
- Indications for **ORIF**
 - Fractures in the **upper 1/3 or Muller's fractures**
 - Displaced intra-articular extension of the fracture
 - Severe multiple injuries
 - An open fracture
 - Segmental fractures
 - A pathological fracture
 - A '*floating elbow*' - simultaneous unstable humeral & forearm fractures
 - Radial nerve palsy *after manipulation*
 - Non-union

Fixation can be achieved by;

- a) A **Dynamic compression plate & screws - 2 tubular plates at 90°** are used to control rotation
- b) An **interlocking intramedullary nail**
- c) In **KNH - flexible pins (Rash pins)**

Complications

- **Vascular injury - Brachial artery damage**
- **Nerve injury - Radial nerve palsy** (*wrist drop & paralysis of the MCP extensors*) may occur particularly *displaced oblique fractures* at the junction of the **middle & distal 1/3s** of the bone. Tested by **active extension of the MCP joints**; active extension of the wrist can be misleading because *extensor carpi radialis longus* is sometimes supplied by a branch arising proximal to the injury.

Supracondylar

Most common fracture in childhood.

Mechanism of Injury

Posterior angulation & displacement (95% cases) suggests **hyperextension injury**, usually due to a fall on the outstretched hand. The humerus breaks just above the condyles. The **distal fragment** is pushed **backwards &** (because the forearm is usually in pronation) **twisted inwards**. The jagged end of the **proximal fragment** pokes into the soft tissues **anteriorly**, sometimes injuring the **brachial artery ± radial ± median nerve**.

Anterior displacement is due **direct violence with the joint in flexion**.

Classification - *Garland's classification*

According to the severity & degree of displacement.

Type I - Undisplaced fracture

Type II - Angulated fracture with the posterior cortex still in continuity

A - Less severe & merely angulated

B - More severe & both angulated & malrotated

Type III - Completely displaced fracture with no cortical contact

A - Posteromedial

B - Posterolateral

C/P

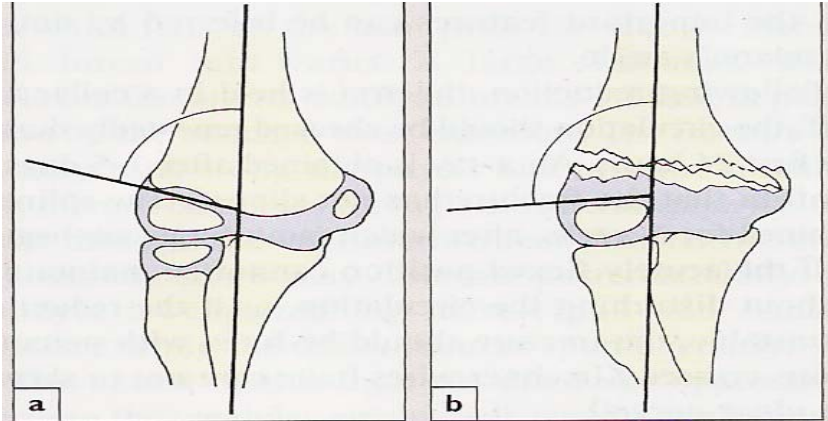
- Following a fall, the child is in **pain & the elbow is swollen**; with a posteriorly displaced fracture the **S-deformity** of the elbow is obvious & the bony landmarks are abnormal - Differentiated from elbow injuries by the **retention of the isosceles triangle** formed when the elbow is flexed between the medial + lateral epicondyles & the olecranon process.
- It is essential to check the neurovascular status of the limb
- **Passive extension** of the **flexor muscles** should be **pain free**.

Ix

X-ray of Distal humerus - *Jones view, AP & Lateral view;*

The elbow is gently splinted in **30° flexion** to *prevent movement & possible neurovascular injury* during the x-ray examination.

- **Type I - 'Fat pad sign'** - There is a triangular lucency in front of the distal humerus, due to the *fat pad being pushed forwards by a haematoma*.
- **Posteriorly displaced fracture** - the fracture line runs *obliquely downwards & forwards & the distal fragment is tilted &/or shifted backwards*.



24.17 Baumann's angle In a child it is sometimes difficult to be sure that the distal fragment is reduced. Baumann's angle is subtended by the longitudinal axis of the humeral shaft and a line through the coronal axis of the capitellar physis. This is normally less than 80 degrees (a). If the distal fragment is tilted in varus, the increased angle is readily detected (b).

Mx

Dunlop's skin traction with the arm out to the side can be used;

- Severe oedema inhibiting reduction of the fracture
- If the fracture is severely displaced & cannot be reduced by manipulation
- If, with the elbow flexed 100°, the pulse is obliterated & image intensification is not available to allow pinning & then straightening of the elbow.
- Severe open injuries or multiple injuries of the limb

Type I - The elbow is immobilised at **90° & neutral rotation** in a **posterior slab** up to the wrist & the arm is supported by a **sling**. It is essential to obtain an **x-ray 5-7days** later to check that there has been no displacement. The splint is retained for **3wks** then removed & then **guided active range of movements exercises** are done while the patient still retains the sling until full recovery - around **6wks**.

Type IIA - If the posterior cortices are in continuity, the fracture can be reduced under GA & the arm is held in a **collar & cuff**; the circulation should be checked repeatedly during the first 24Hrs.

An x-ray is obtained after **3-5days** to confirm that the fracture has not slipped. The splint is retained for **3wks**, after which movements are begun as above up to **6wks**

Indications for **ORIF - Percutaneous crossed Kirschner wires** (*take care not to skewer the ulnar nerve!*) -

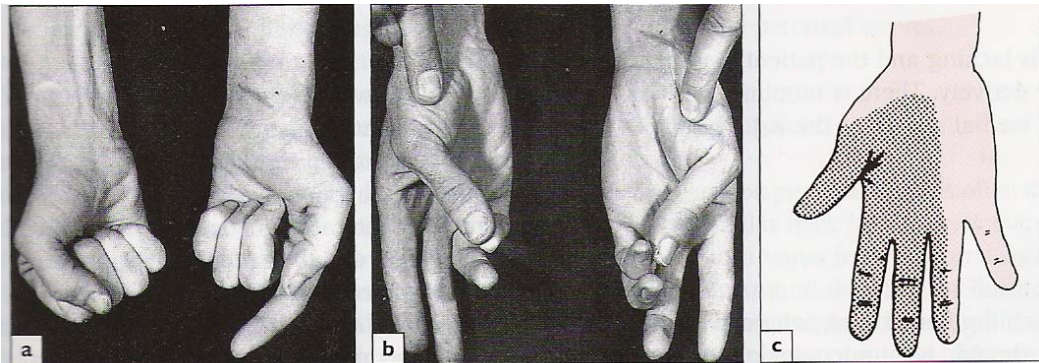
Removed after **3wks**;

- **Type IIB & III**
- Neurovascular compromise
- If the acutely flexed position cannot be maintained without disturbing the circulation
- If the reduction is unstable
- Old injuries
- Open fractures
- Floating elbow

Anteriorly displaced Fractures - The fracture is reduced & a **posterior slab** is bandaged on & retained for **3 weeks**. Thereafter the child is allowed to regain flexion gradually while still in a sling as above.

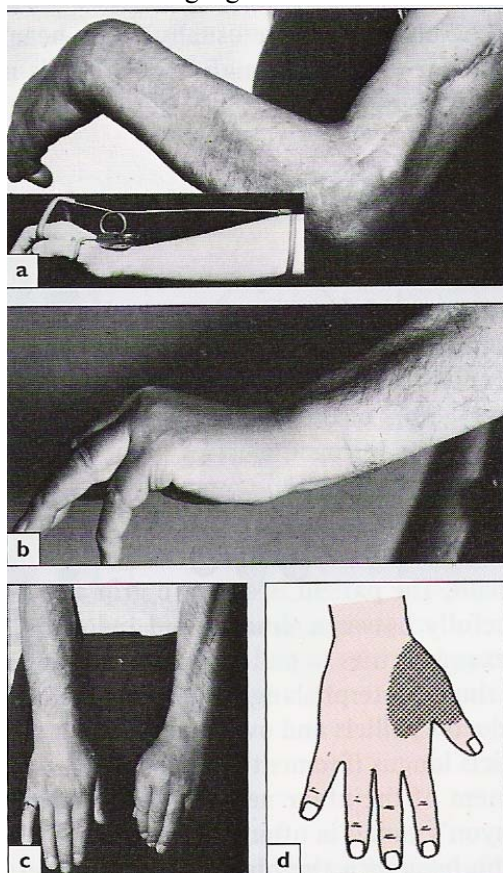
Complications

- **Vascular injury** - Injury to the **brachial artery** ± **compartment syndrome** ± **Volkmann's ischemic contracture**
- **Nerve injury** - All 3 nerves can be tested by the '**Thumb sign**'
 - **Median nerve** (Ask patient to **snap fingers**) particularly the **anterior interosseous branch**; the patient is unable to **abduct the thumb**, & sensation is lost over the palmar **radial 3½ digits**. In **long standing** cases, the **thenar eminence is wasted** & trophic changes may be seen. Loss of function is usually temporary & recovery can be expected in **6-8wks**.



11.14 Cut median nerve (a) The pointing index when trying to clench the fist. (b) Abductor pollicis brevis wasting. (c) Sensory loss.

- **Radial nerve** - Pointing sign



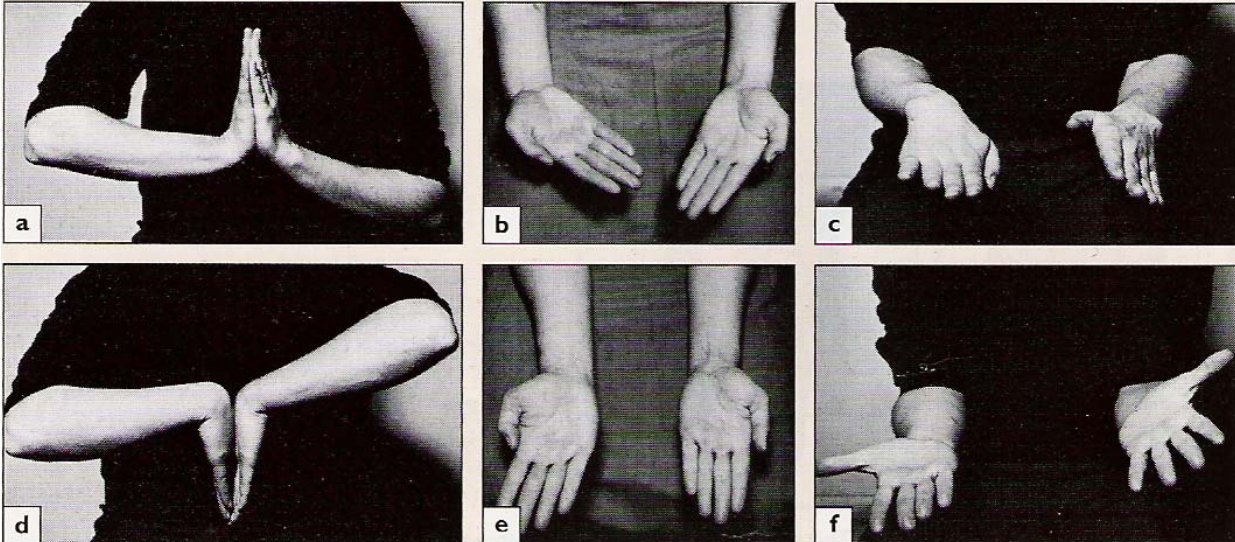
11.12 Radial nerve lesions (a) High lesion, producing a drop wrist. The inset shows a type of drop wrist splint. (b) Low lesion: the wrist extensors are spared but the patient cannot extend his metacarpophalangeal joints. (c) Muscle wasting due to a long-standing posterior interosseous nerve lesion. (d) Area of sensory loss.

- **Cubitus**

Ulna & Radius

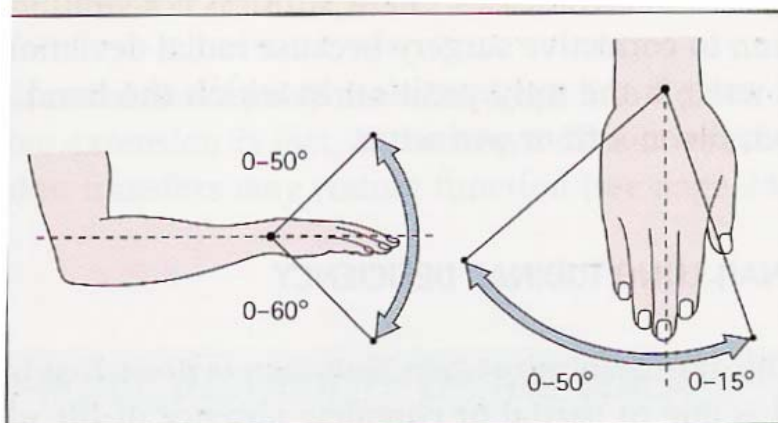
Examination of the Wrist

- i) Inspection - Look at the elbow, forearm & hand
- ii) Palpation
- iii) Movement



15.3 Examination All movements of the left wrist are limited: (a) dorsiflexion, (b) palmarflexion, (c) ulnar deviation, (d) radial deviation, (e) pronation, (f) supination.

- a) To compare **passive dorsiflexion** of the wrists the patient places his or her palms together in the position of prayer, then elevates his or her elbow
- b) , e) **Radial & ulnar deviation** are measured in either the palms-up or the palms-down position



15.4 Normal range of movement From the neutral position dorsiflexion is slightly less than palmarflexion. Most hand functions are performed with the wrist in ulnar deviation; normal radial deviation is only about 15°.

- d) **Palmar flexion** is examined in a similar way as dorsiflexion
- c) , f) With the elbows at right angles & tucked in to the sides, **pronation & supination** are assessed.

- iv) **Muscle Bulk, Tone & Power**

Proximal Radius & Ulna

Mechanism of Injury

Additional **rotational deformity** may be produced by the pull of muscles attached to the **radius**;

- # **Upper** 1/3 - Biceps & supinator muscles
- # **Middle** 1/3 - Pronator teres
- # **Lower** 1/3 - Pronator quadratus

Mx

• Children

Closed treatment is usually successful because the **tough periosteum** tends to guide & then control the reduction. The fragments are held in a well-moulded **full-length cast, from axilla to metacarpal shafts** (to control rotation). The cast is applied with the **elbow at 90°**. If the fracture is **proximal to the pronator teres** - The **forearm is supinated**; if it is **distal** to pronator teres, then the forearm is held in **neutral**. The position is checked by x-ray after **a week** &, if it is satisfactory, splintage is retained until both fractures are united (usually **6-8wks**)

Indications for surgery;

- If the fracture cannot be reduced
- If the fragments are very unstable

Fixation with a **small plate, Kirschner wires** or **flexible intramedullary nails** is then needed.

• Adults

ORIF - The fragments are held by **interfragmentary compression** with **plates & screws**. **Bone grafting** is advisable if there is comminution of **>1/3 of the circumference**. The **deep fascia** is **left open** to prevent build-up of pressure in the muscle compartments, & only the skin & subcutaneous tissue are sutured.

After the operation, the arm is kept elevated until the swelling subsides, & during this period active exercises of the hand are encouraged.

Immobilize with **comminuted fractures** or **unreliable patients**.

It takes **8-12wks** for the bones to unite.

Complications

- **Nerve injury** - Rarely caused by the fracture but may be caused by the surgeon. Exposure of the **radius in it's proximal** 1/3 risks damage to the **posterior interosseous nerve** where it is covered by the superficial part of the supinator muscle. The patient complains of clumsiness &, on testing, **cannot extend the MCP joints** of the hand. In the **thumb** there is also **weakness of abduction & IP extension**.
- **Vascular injury** - Injury to the radial or ulnar artery seldom presents any problem as the collateral circulation is excellent.
- **Compartment syndrome** - A distal pulse **does not exclude** compartment syndrome.

Monteggia Fracture - Dislocation of the Ulna

This is any **fracture of the ulna** associated with **subluxation or dislocation of the radiocapitellar joint**.

- * Fracture of the **shaft** of the ulna is associated with **dislocation of the proximal radioulnar joint**
- * In **Trans-Olecranon** fractures, the **proximal radioulnar joint remains intact**.

If the **fracture apex** is **posterior**, then the **radial dislocation** is **posterior**; & if the **fracture apex** is **lateral** then the **radial head** will be **laterally displaced**.

In children the ulnar injury may be an incomplete fracture (green stick or plastic deformation of the shaft)

Mechanism of Injury

- Usually the cause is a fall on the hand; if at the moment of impact the body is twisting, it's momentum may forcibly pronate the forearm. The **upper 1/3 of the ulnar fractures & bows forwards & the radial head** usually **dislocates forwards**.

Mx

- **ORIF** with **plates & screws** of the ulnar; bone grafts may be added for safety. The radial head usually reduces once the ulna has been fixed but if it fails - ORIF.

If the elbow is completely **stable**, then flexion/extension & rotation can be started after **10 days**. If there is doubt, then the arm should be immobilized in plaster with the elbow flexed for **6wks**.

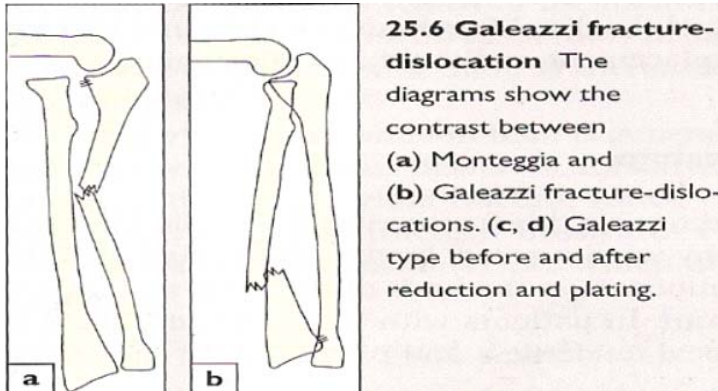
• In children;

- * **Incomplete** ulnar fractures can often be **reduced closed**. The arm is then **immobilized in a cast** with the **elbow in flexion & supination** for **3wks**.
- * **Complete** fractures - **ORIF**

Complications

- **Nerve Injury** - The wrist & hand should be examined for signs of injury to the **radial nerve (Posterior interosseous branch)**, usually a neuropraxia which will recover by itself.

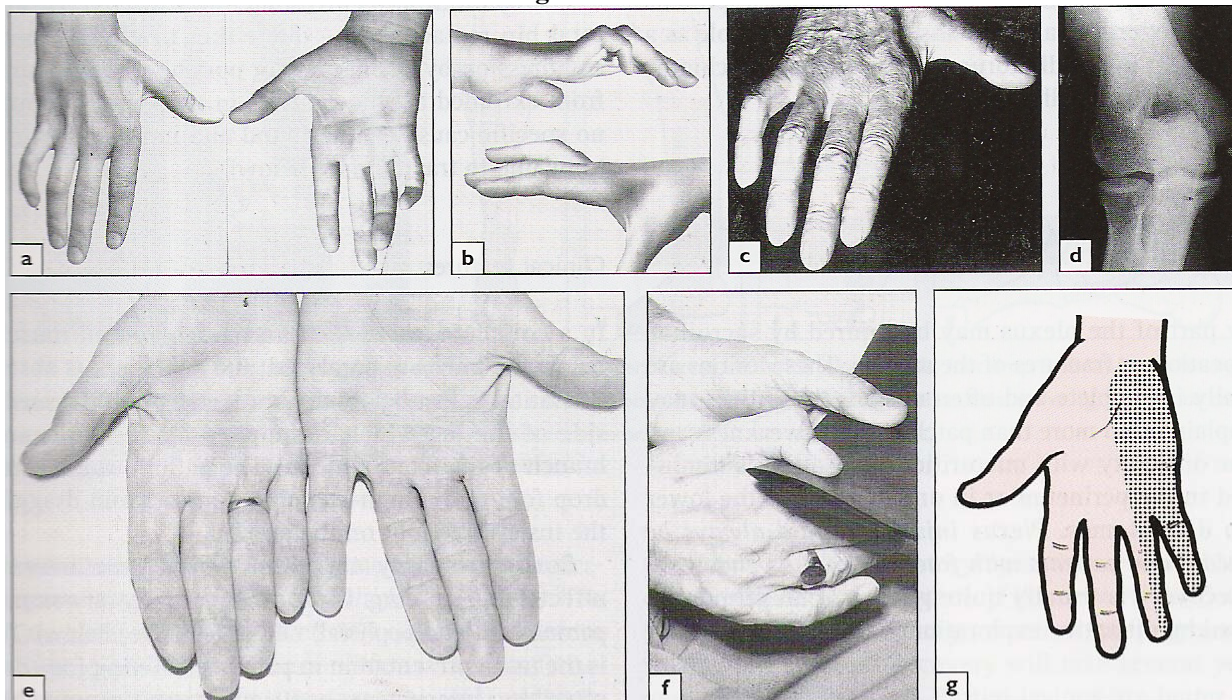
Galeazzi Fracture - Dislocation of the Radius



Fracture of the Distal 1/3 of Radius & subluxation or dislocation of the Inferior Radioulnar joint More common than the Monteggia.

C/P

- Prominence or tenderness over the lower end of the ulna
- Instability of the radioulnar joint demonstrable by 'balloting' the distal end of the ulna (the '**piano-key sign**') or by rotating the wrist.
- Test for an **ulnar nerve lesion** which is common;
 - * **Claw-hand deformity** - with **Hyperextension** of the MCP (*Paralysed Lumbricals*) & **Flexion** of the IP joints (*Paralysed Interossei*) of the ring & little finger
 - * Ask patient to **cross fingers - PAD + DAB** - Finger abduction is weak + loss of thumb adduction = Pinch difficult
 - * **Hypothenar & interosseous wasting** may be obvious.
 - * **Numbness of the ulnar 1½ fingers.**



11.13 Ulnar nerve lesions (a, b) Low ulnar palsy: intrinsic muscle wasting; in the ring and little fingers the knuckle joints are hyperextended (paralysed lumbricals) and the interphalangeal joints are flexed (paralysed interossei). (c) High ulnar palsy: profundus action is lost, so the terminal interphalangeal joints are not flexed (ulnar paradox). He had cut his elbow on some glass. (d) The x-ray shows the glass fragment. (e) When the patient tries to push his little fingers apart, weakness of one abductor digiti minimi is displayed. (f) Froment's sign - because adductor pollicis is weak, the flexor pollicis longus is being used. (g) Sensory loss.

Mx

- **Children - Closed reduction**
- **Adults - ORIF with compression plating** of the radius

If the **distal radioulnar joint remains unstable** after reduction, the forearm should be immobilized in the position of stability (usually **supination**), supplemented if required by a **transverse K-wire**. The forearm is splinted in an **above elbow cast** for **6wks**

Fractures of the Distal Radius

Classification;

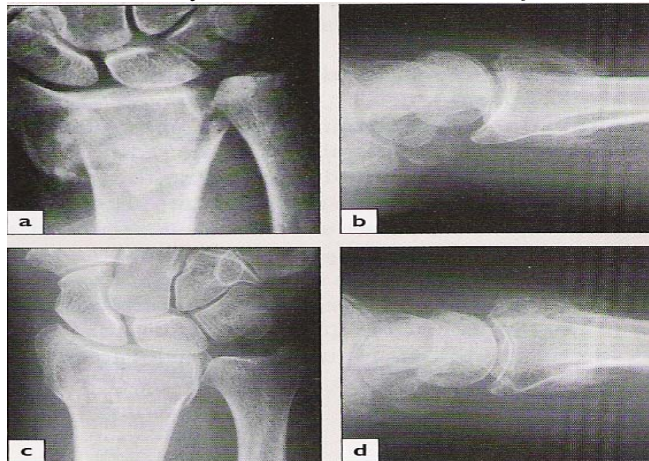
- I - Pure bending - Includes all Fernande's Classification;**
 - a) Colles' Fracture - Low-energy osteoporotic fracture in postmenopausal women
 - b) Smith's fracture - cf Colles' but displaced **anteriorly** rather than posteriorly ('*garden spade*' deformity)
 - c) Distal forearm fracture in children
 - d) Radial styloid fracture
 - e) Barton's fracture
 - f) Comminuted intra-articular fractures in young adults
- II - Shearing**
- III - Impaction**
- IV - Distraction**
- V - Gross disorganization**

a) Colles' Fracture

Transverse fracture of the **radius** just above the wrist at the **corticocancellous junction**, with **extension, dorsal displacement, radial tilt & shortening** of the **distal** fragment. Often the **ulnar styloid process** is **broken off**.

C/P

- **'Dinner-fork'** deformity - **Prominence in the back of the wrist & a depression in front**



25.7 Colles' fracture (a, b) The typical Colles fracture is both displaced and angulated towards the dorsum and towards the radial side of the wrist. (c, d) Note how, after successful reduction, the radial articular surface faces correctly both distally and slightly volarwards.

Mx

- **Undisplaced (or only very slightly displaced)** - A dorsal **splint** is applied for **1-2days** until the swelling has resolved, then the **cast** is completed & removed after **4wks** to allow mobilization.
- **Displaced - Closed reduction + a dorsal plaster slab** extending from just below the elbow to the metacarpal necks & $\frac{2}{3}$ of the way round the circumference of the wrist. It is held in position by a crepe bandage.
- **Comminuted - Percutaneous K-wire fixation;** If severe, **External fixation**

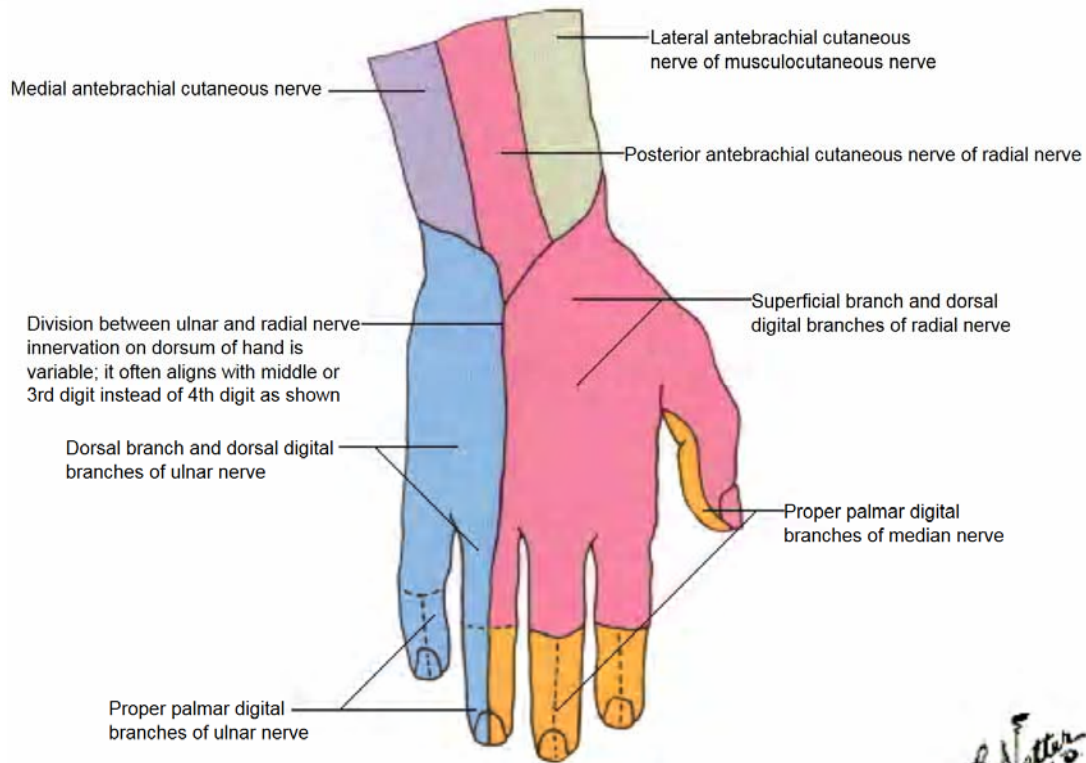
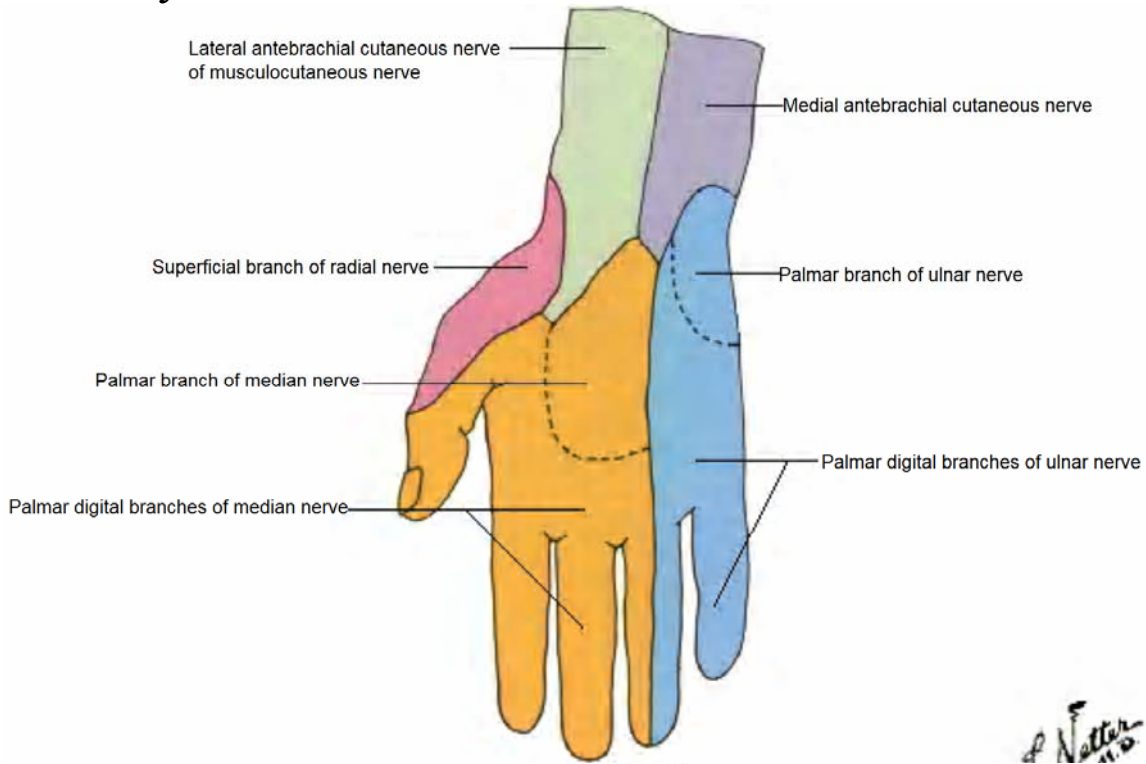
The fracture unites in about **6wks**

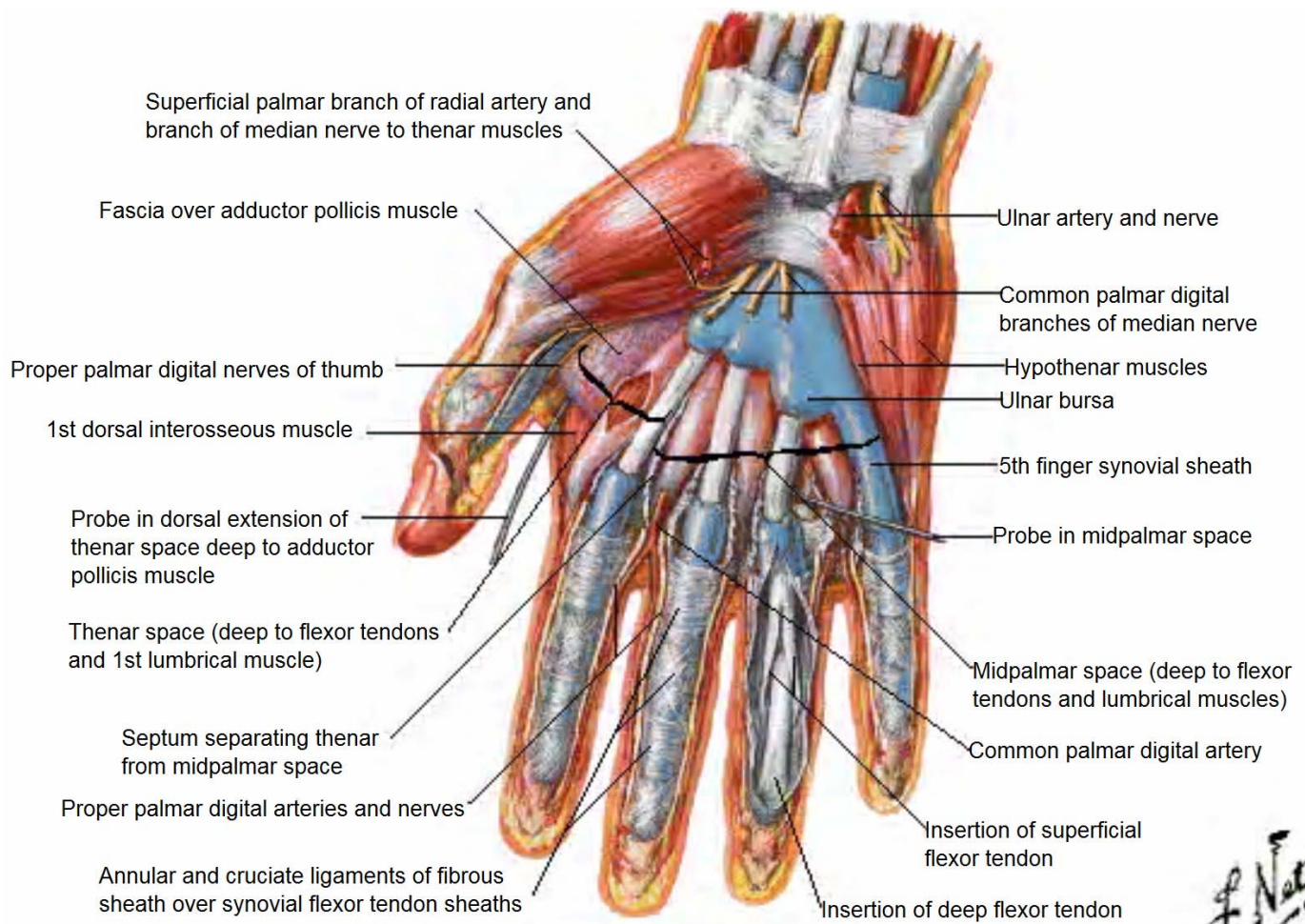
Complications

- **Nerve injury** - Compression of the **median nerve** in the carpal tunnel - **wasting of the thenar eminence & diminished sensibility** on the **palmar aspect of the radial 3½ fingers**.
- Reflex sympathetic dystrophy/Algodystrophy
- Tendon rupture (of extensor pollicis longus)

Hand Injuries

Anatomy

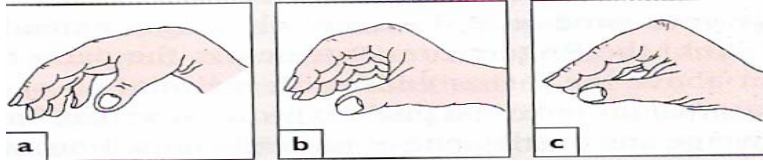




- ** The Ulnar bursa contains the superficialis & profundus flexor tendons
- ** The Radial bursa contains the flexor pollicis longus tendon

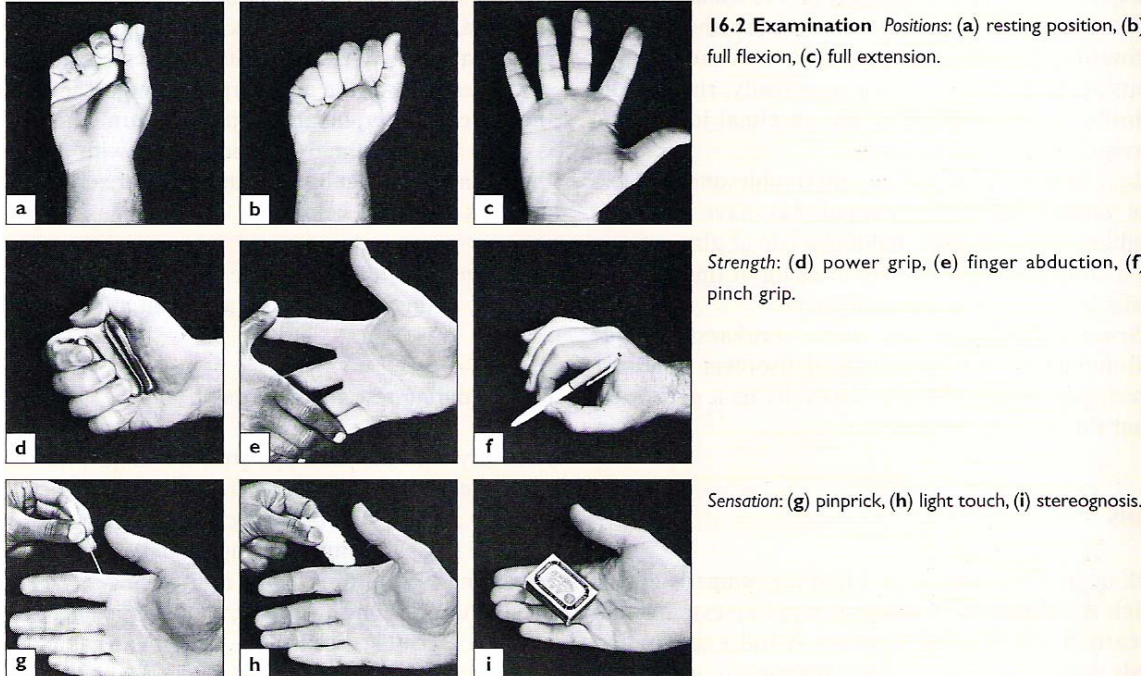
Examination of the Hand

- **Inspection** - Skin damage



Position of: a) **Relaxation** b) **Function** c) **Safe Immobilization**

- **Circulation** - *Allen test* to the hand as a whole or to individual fingers
- **Sensation**
- **Palpation**



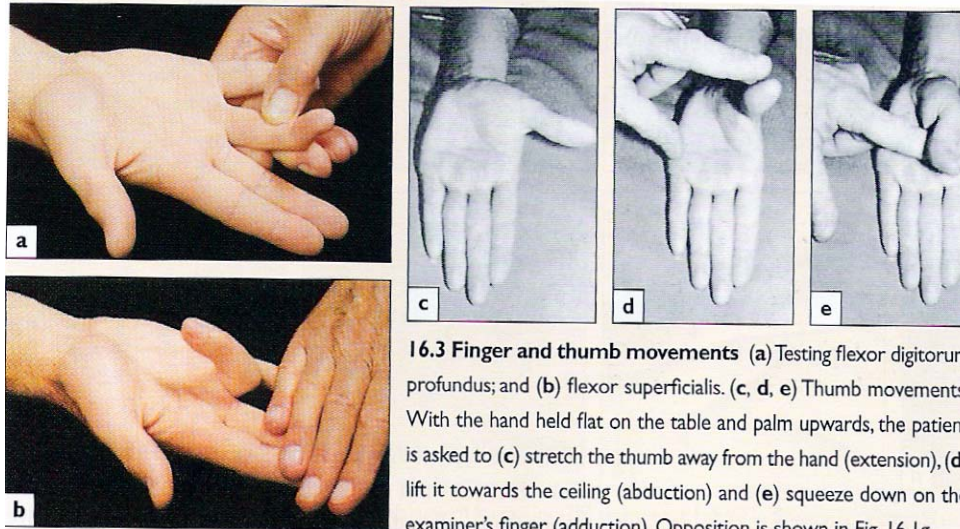
16.2 Examination Positions: (a) resting position, (b) full flexion, (c) full extension.

Strength: (d) power grip, (e) finger abduction, (f) pinch grip.

Sensation: (g) pinprick, (h) light touch, (i) stereognosis.

- **Tendons**

- **Passive tenodesis** - When the **wrist is extended** passively, the **fingers automatically flex** & when the **wrist is flexed**, the **fingers fall into extension**.
- **Active movements;**
 - Flexor digitorum profundus** - hold the proximal finger joint straight & ask the patient to bend the distal joint
 - Flexor digitorum superficialis** - The examiner holds all the fingers together out straight (immobilises all the deep flexors), then releases one & asks the patient to bend the proximal joint.



16.3 Finger and thumb movements (a) Testing flexor digitorum profundus; and (b) flexor superficialis. (c, d, e) Thumb movements. With the hand held flat on the table and palm upwards, the patient is asked to (c) stretch the thumb away from the hand (extension), (d) lift it towards the ceiling (abduction) and (e) squeeze down on the examiner's finger (adduction). Opposition is shown in Fig. 16.1g.

General Principles of Management

Important history;

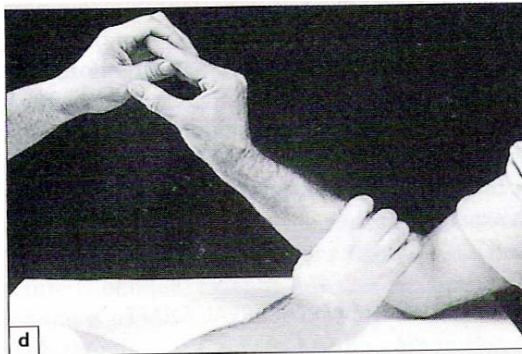
- Mechanism of injury;
 - Sharp or blunt instrument?
 - Clean or dirty?
 - Position of the fingers at the time of injury - Flexed or Extended?
 - High pressure injection - predicts major soft tissue damage no matter how innocuous the wound may seem.
- Patient's occupation, hobbies & aspirations?
- Handedness?

Ix;

- Hand X-Ray

Mx;

- **Circulation** - Restore by direct repair or vein grafting
- **Swelling** - Control by elevating the hand + early & repeated active exercises
- **Splintage;**
 - Single finger - Tape to neighbouring finger or alone
 - Entire hand - **Position of Safe Immobilization (POSI)** - In this position the *tendons are at their longest* & splintage is least likely to result in stiffness & contractures.
 - * Wrist extended
 - * MCP joints flexed at 90°
 - * IP joints - straight
 - * Thumb - Abducted



Also Position of function (Splint while holding a ball)

- Internal fixation;
 - * Percutaneous Kirschner wires
 - * Screws, plates & wire loops
- **Skin cover** - Treatment of the skin takes precedence over treatment of the fracture
- **Nerve & tendon injury**

Management of Open Injuries of the Hand

i) Pre-op;

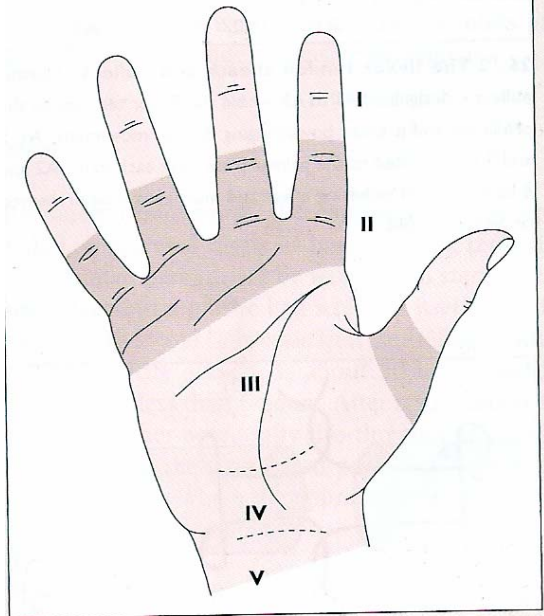
- Wash wound
- Give analgesics & antibiotics
- Prophylaxis against tetanus & gas gangrene
- The hand is lightly splinted
- The wound is covered with an iodine-soaked dressing

ii) Wound exploration;

- Under GA or Regional anaesthesia
- A pneumatic tourniquet (250mmHg (+50mmHg SBP Upper limbs)) is essential **unless** there is a crush injury in which muscle viability is in doubt.
- Any incision must **not cross a skin crease or an interdigital web** or else scarring may cause *contracture & deformity*
- Debride wound
- Irrigate with isotonic crystalliod solution

iii) **Tissue Repair;**

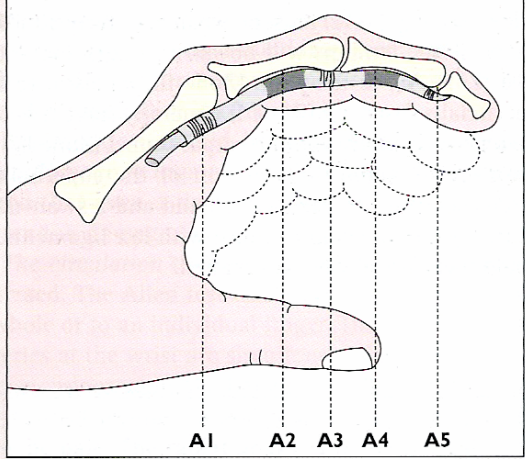
- Fractures - *Reduce & fix with percutaneous K-wires*
- Joint capsule & ligaments - *Fine sutures*
- Artery & vein - Repaired if hand is ischemic
- Severed nerves - Repaired **without tension** or if not possible, a **nerve graft** (e.g. *posterior interosseous nerve at the wrist or from the sural nerve*)
- **Extensor** tendon repair;
- **Flexor** tendon repair;
 - Division of the **superficialis tendon** noticeably weakens the hand & a **swan-neck deformity** can develop in those with lax ligaments & should therefore always be repaired



26.11 The zones of injury I – Distal to the insertion of flexor digitorum superficialis. II – Between the opening of the flexor sheath (the distal palmar crease) and the insertion of flexor superficialis. III – Between the end of the carpal tunnel and the beginning of the flexor sheath. IV – Within the carpal tunnel. V – Proximal to the carpal tunnel.

**** Cuts above the wrist (Zone V), in the palm (Zone III) or distal to the superficialis insertion (Zone I) generally have a better outcome.**

- The **A2 & A4** pulleys must be repaired or reconstructed otherwise the tendons will **bowstring**.



26.12 The flexor tendon sheath and pulleys Fibrous pulleys – designated A1 to A5 – hold the flexor tendons to the phalanges and prevent bowstringing during movement. A1, 3 and 5 are attached to the palmar plate near each joint; A2 and 4 have a crucial tethering effect and must always be preserved or reconstructed.

iv) Replantation;

Indications;

- **The thumb** even if it functions only as a *perfused 'post' with protective sensation*
- **Multiple digits**
- **In a child**, even a **single digit**
- Proximal amputation through the **palm, wrist or forearm**

Relative contraindications;

- **Single digits** - do badly if replanted with a high complication rate, including stiffness, non-union, poor sensation & cold intolerance; a replanted single finger is likely to be excluded from use. The **exception** is an amputation *beyond* the insertion of flexor digitorum superficialis, when a cosmetic, functioning finger tip can be retrieved.
- Severely **crushed, mangled or avulsed parts**
- Parts with **long ischemic time**
- **General medical disorders or other injuries** that may engender unacceptable risks from prolonged anaesthesia needed for replantation.

v) Amputation indications;

- If the finger remains **painful or unhealed**, or if it is a **nuisance** (i.e. if the patient cannot bend it, straighten it or feel with it)
- If repair is **impossible or uneconomical**

vi) Closure

vii) Splintage

- In POSI
- Modifications;
 - After **1° flexor tendon** suture;
 - * Wrist - **20° of flexion** to take the tension off the repair (too much wrist flexion invites wrist stiffness & carpal tunnel symptoms)
 - * IP joints - Straight
 - After **extensor tendon** repair;
 - * Wrist - **30° extension**
 - * MCP joints - **30° flexed** so that there is less tension on the repair
 - * IP joints - Straight

viii) Post-op;

- The hand is kept elevated in a roller towel or high sling (latter must be removed several times a day to exercise the elbow & shoulder - Too much elbow flexion can stop venous return & make swelling worse)
- Antibiotics

ix) Rehabilitation - Occupational therapy

Acute Infections of the Hand

Infection of the hand is usually by **Staphylococcus spp.** & is frequently limited to one of several well-defined compartments;

- Under the nail fold (Paronychia)
- The pulp space (Felon)
- Subcutaneous tissues
- Also;
 - Tendon sheaths
 - The deep fascial spaces - *Thenar space & Mid-palmar space*
 - Joints

Pathology;

- Acute inflammation → Oedema, suppuration & increased tissue tension, which in closed compartments pressures may rise to levels where the *local blood supply is threatened*, with the risk of tissue necrosis. In neglected cases, infection can spread from one compartment to another & the end result may be a permanently stiff & useless hand. Also *lymphangitis & septicaemia*

O/E;

- With **superficial infection**, the patient can usually be persuaded to **flex** an affected finger; with **deep infection** *active flexion is not possible*

DDx;

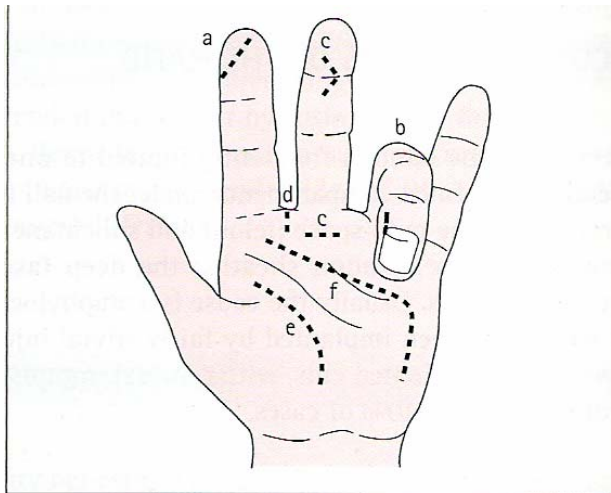
- Thorn prick (can closely mimic subcutaneous infection)
- Acute tendon rupture (may resemble a septic tenosynovitis)
- Acute gout (easily mistaken for septic arthritis)

Ix;

- HXR - Initially **not** helpful but a **few weeks** later there may be features of *osteomyelitis or septic arthritis*, & later still of *bone necrosis*.

Principles of treatment;

- Antibiotics;
 - **Flucloxacillin or a cephalosporin**
 - If bone infection is suspected, **fusidic acid** may be added
 - **Human Bites** - Common organisms - *Staph. Aureus, Strep. Group A & Eikenella corrodens* - Treated with *broad-spectrum penicillins (e.g. augmentin)*
 - Agricultural injuries - Add **metronidazole**
 - **Herpetic Whitlow** - HSV may enter the finger-tip, possibly by auto-inoculation. Small vesicles form on the finger-tip, then coalesce & ulcerate. The condition is self-limiting & usually subsides after about **10days**, but may recur from time to time. **Acyclovir** may be effective in the early stages.
- Rest, splintage & elevation
 - Analgesics
 - Splintage - In a position of safe immobilization (POSI)
 - * Mild cases - Sling
 - * Severe case - Admit & splint in an overhead sling
- Drainage;
 - If signs of abscess - **Throbbing pain, marked tenderness & toxæmia**
 - Done under GA or regional block & a tourniquet (250mmHg (+50mmHg SBP Upper limbs)) is essential; The hand is **exsanguinated by elevation only**; *an exsanguinating bandage can spread the sepsis.*



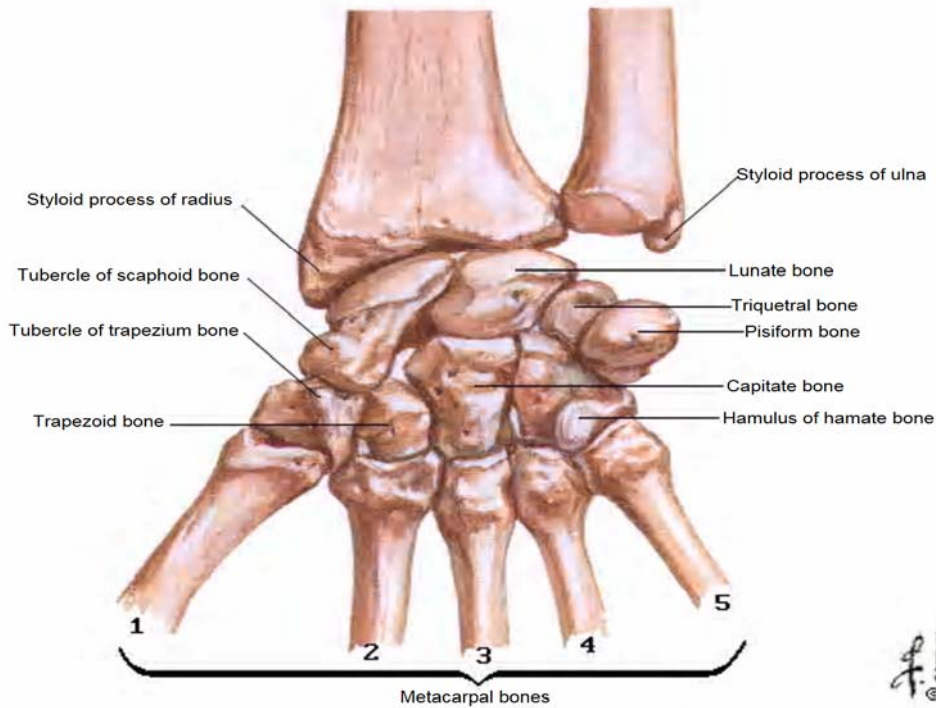
16.22 Infections The incisions for surgical drainage are shown here: (a) pulp space (directly over the abscess); (b) nail-fold (it may also be necessary to excise the edge of the nail); (c) tendon sheath; (d) web space; (e) thenar space; (f) mid-palmar space.

- The area is thoroughly washed out & in some cases, a catheter may be left in place for further, post-op irrigation (e.g. in cases of **flexor tenosynovitis**)
- The wound is either *left open or lightly sutured*, & then covered with a non-stick dressing & betadine soaked gauze
- After the operation, the hand is splinted in POSI & elevated in a suitable sling

Rehabilitation is started as soon as signs of acute inflammation have settled.

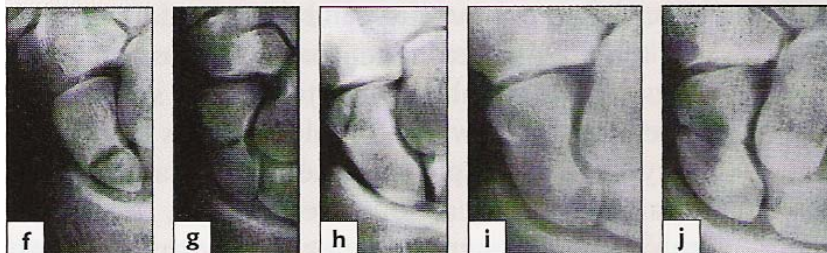
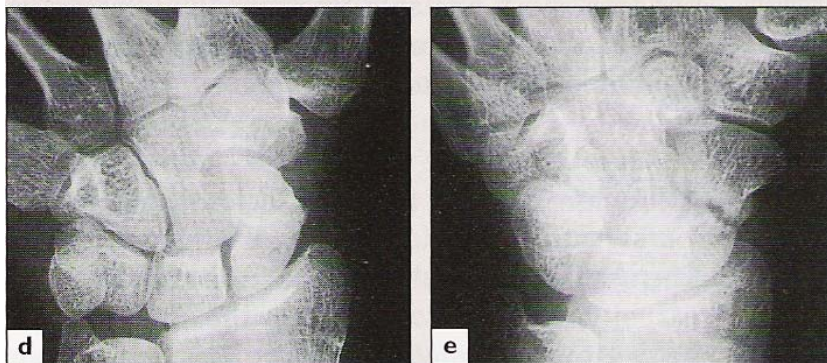
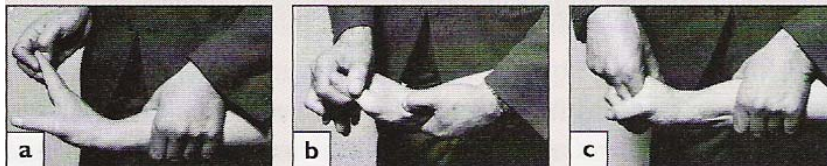Scaphoid

Carpal Bones Anterior [Palmar] View



Mechanism of Injury

- Fall on the *dorsiflexed hand*



25.19 Scaphoid fractures – diagnosis

Clinical signs: (a) pain on dorsiflexion, (b) localized tenderness, (c) pain on gripping.

X-ray signs: the anteroposterior view (d) often fails to show the fracture; always ask for an oblique, 'scaphoid' view (e). Fracture may be through (f) the proximal pole, (g) the waist or (h) the tubercle. If the clinical features are suggestive and no fracture is seen on x-ray (i), a repeat film at 2 weeks (j) should be obtained.

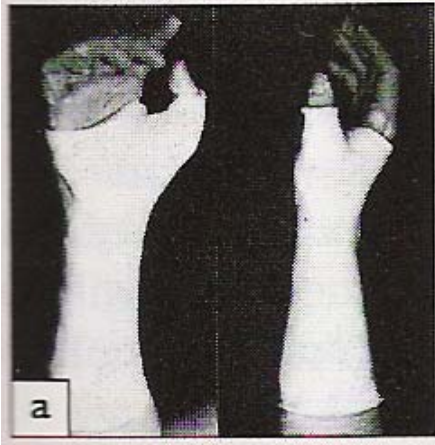
** Anatomical snuff box - Contains the *radial artery*

- Medially - Extensor pollicis longus
- Laterally - Extensor pollicis brevis & Abductor pollicis longus

- Base - Styloid process of the radius

Mx

- **Fracture of the scaphoid tubercle** needs no splintage & should be treated as a wrist sprain; a crepe bandage is applied & movement is encouraged.
- **Undisplaced fractures** - No reduction; Casting from the upper forearm to just short of the MCP joints of the fingers, but incorporating the proximal phalanx of the thumb. The wrist is held dorsiflexed & the thumb forwards in the '**glass-holding**' position (Position of Function) - It is retained for **6wks**.



- **Displaced fractures** - **ORIF** with a **compression screw**

Complications

- **Avascular necrosis** - The **proximal fragment** may die especially with *proximal pole fractures*.

The Back

Examination of the Back

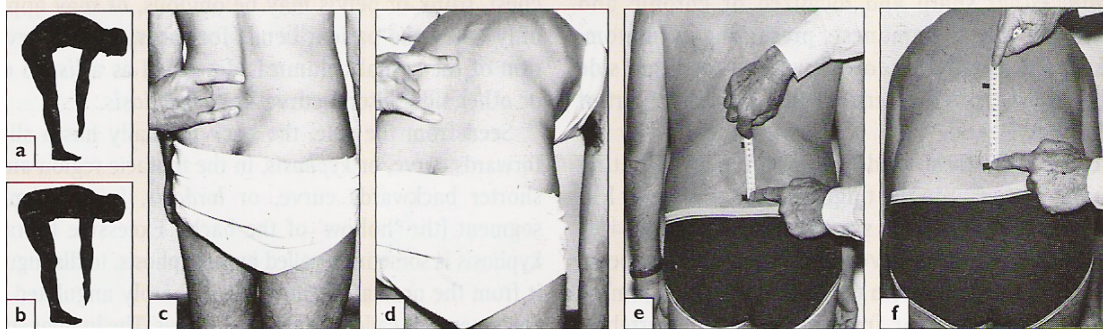
i) Inspection

- Lateral **deviation** of the spinal column is described as a **list** to one or other side; lateral **curvature** is **scoliosis**
- Seen from the side, the back normally has a slight **forwards curve - Kyphosis** (Excessive - **Hyperkyphosis**) in the **thoracic** region; If the spine is sharply angulated - **Kyphos** or **Gibbus**; & a shorter **backwards curve - Lordosis**, in the **lumbar segment** (the 'hollow' of the back)
- Undue or asymmetrical prominence of the paravertebral muscles may be due to spasm, an important sign in acute back disorders.

ii) Palpation

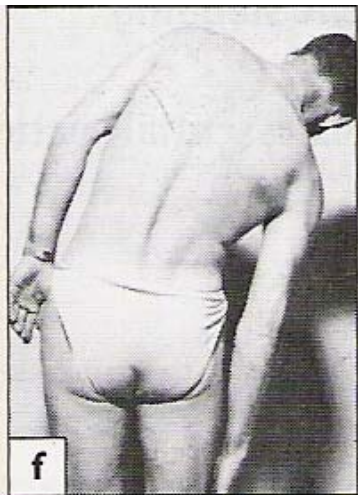iii) Movement

a) Forward Flexion

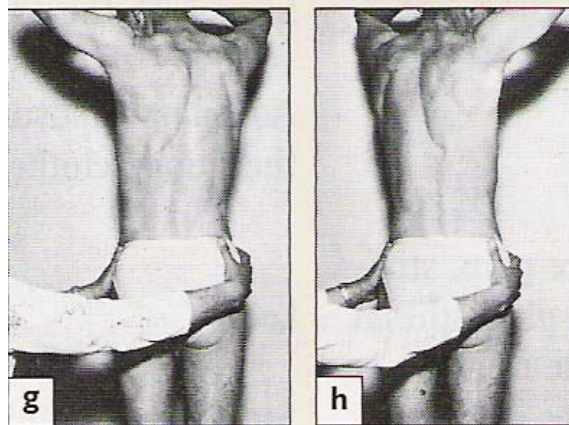


18.2 Examination (2) In both diagrams the hands nearly reach the toes; to distinguish spine flexion (a) from hip flexion (b), watch the lumbar lordosis undoing as the patient bends. Alternatively (c, d), note the separation of fingers placed on the spinous processes. Better still (e, f), measure the lumbar excursion; with the patient upright, two bony points 10cm apart are selected – in full flexion they should separate by at least a further 5cm.

b) Lateral flexion



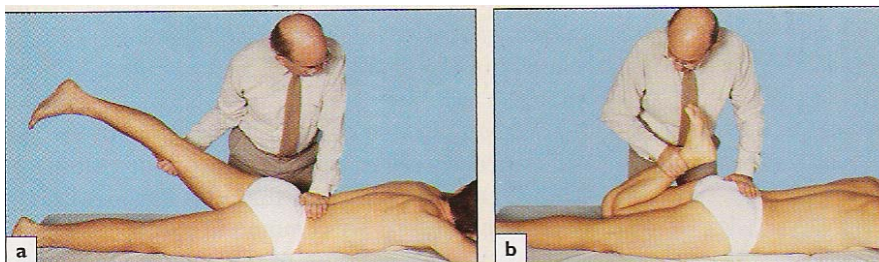
c) Rotation - This is essentially a thoracic movement & should not be limited in lumbosacral disease.



iv) Chest circumference - Measured in full expiration & then in full inspiration; the normal difference is about 7cm

v) Muscle Bulk, Tone & Power in the legs

vi) Femoral stretch test



18.3 Femoral stretch test

Lumbar root sensitivity can be detected by applying tension to the femoral nerve. This is done either by (a) hyperextending the hip or (b) acutely flexing the knee with the hip held in the neutral position.

Approach to diagnosis in patients with low back pain

Terminology:

- **Lumbago** - Pain in the lumbar spine
- **Sciatica** - Pain in the lower back and hip *radiating down the back of the thigh into the leg*, initially attributed to sciatic nerve dysfunction, but now known to usually be due to **herniated lumbar disk** compromising the **L5 or S1** root.
- **Pain;**
 - * **Acute** - 0-7days
 - * **Acute-on-chronic** - Recurrence of acute pain
 - * **Sub-acute** - 7days - 3months
 - * **Chronic** - >3months

Backache may be from;

- Idiopathic
- Bony structures
- Intervertebral tissues
- Paravertebral muscles

a) **Transient backache following muscular activity;**

- *Back strain* - will respond to a short period of rest followed by gradually increasing exercise; People with thoracic kyphosis (of whatever origin), or fixed flexion of the hip, are particularly prone to back strain because they tend to compensate for the deformity by holding the lumbosacral spine in *hyperlordosis*.

b) **Sudden, Acute Pain & Sciatica;**

- **<20 yrs** - *Infection & Spondylolisthesis* (slipping forward of one vertebra upon another)
- **20-40yrs** - *Acute disc prolapse* - Diagnostic features;
 - * History of a lifting strain
 - * Unequivocal sciatic tension
 - * Neurological symptoms & signs
- **>40yrs** - *Osteoporotic compression fractures*
 - *Metastatic disease* from **Prostate**, Thyroid, Breast, Bronchus, Adrenals, Kidney, GIT, Uterus

c) **Intermittent Low Back pain after Exertion;**

- Facet joint dysfunction; **>50yrs** - *Osteoarthritis of the facet joints*
- Intervertebral disc degeneration &/or segmental instability
- Ankylosing spondylitis
- Chronic infection *e.g. TB spine*
- Myelomatosis
- Bone disease

d) **Back pain + Pseudoclaudication** (Numbness & paraesthesia in the thighs & legs; it comes on after *standing upright or walking for 5-10minutes*, & is consistently relieved by *sitting, squatting or leaning against a wall to flex the spine*);

- **>50yrs** - *Spinal stenosis* - Usually **L4-S2**

e) **Severe & constant pain localised to a particular site;**

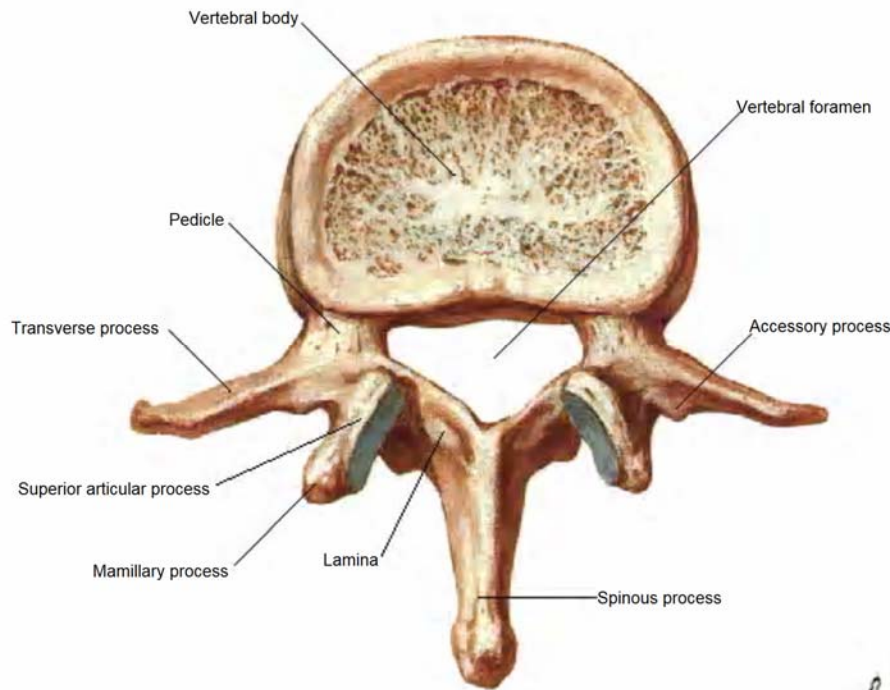
- Compression fracture
- Paget's disease
- Tumour
- Infection
- Spinal osteoarthritis; *If in middle-aged men, exclude;*
 - * Myelomatosis
 - * Carcinomatosis
 - * Hyperthyroidism
 - * Gonadal insufficiency
 - * Alcoholism
 - * Corticosteroid usage

Mx

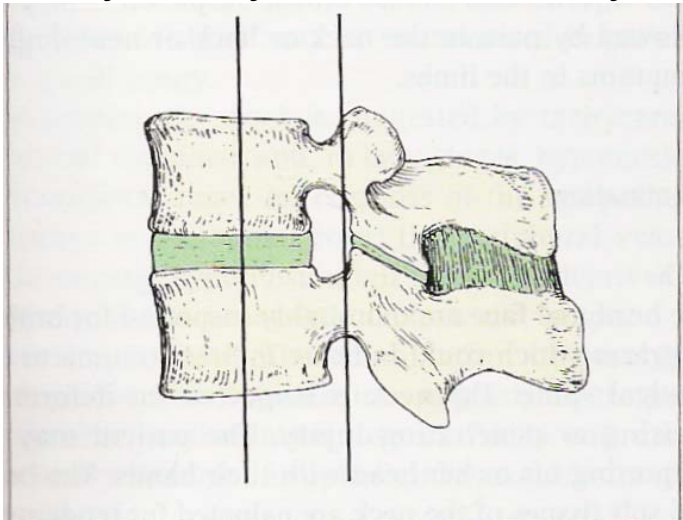
- Conservative - *NSAIDs + Physiotherapy*
- Surgery

Injuries to the spine

Anatomy



Denis' Classification of Structural Elements of the Spine



27.1 Structural elements of the spine The vertical lines show Denis' classification of the structural elements of the spine. The three elements are: the posterior complex, the middle component and the anterior column. This concept is particularly useful in assessing the stability of lumbar injuries.

- Posterior Osseoligamentous Complex (or Posterior column);
 - * Supraspinous, Interspinous ligaments & Ligamentum flavum
 - * Pedicles, Facet, Posterior Bony Arch
- Middle column;
 - * Posterior longitudinal ligament
 - * Posterior ½ of the vertebral body
 - * Posterior part of the intervertebral disc
- Anterior column;
 - * Anterior ½ of the vertebral body
 - * The anterior part of the intervertebral disc
 - * Anterior longitudinal ligament

Stability of Fractures

- A **stable** injury is one in which *the vertebral components will not be displaced by normal movements*; if the **neural elements** are undamaged, *there is little or no risk of them becoming damaged*.
- An **unstable** injury is one in which *there is a significant risk of displacement & consequent damage to the neural tissues*;
 - a) Fractures involving the **middle column** & at least **one other column**
 - b) Injuries involving at least **3 vertebrae**
 - c) **Facet dislocation** - usually in the *cervical spine*
 - <50% shift - *One facet joint involved* - Relatively stable
 - >50% shift - *Both facet joints involved* - **Unstable**
 - d) **Spondylolisthesis** - Forward displacement of a **lumbar vertebrae** on the one below it & especially of **L5 on the sacrum** producing pain by compression of nerve roots.
 - e) >40% wedge compression

Mechanism of Injury

- Traction Injury;
 - In the **cervical spine**, the **7th spinous process** can be avulsed - '**Clay-shoveller's fracture**'
 - In the **lumbar spine**, resisted muscle effort may avulse **transverse processes**
- Direct injury
- Indirect injury

Management

- i) Airway with cervical spine control, **Breathing**, **Circulation** & haemorrhage control, **Disability** & **Exposure**
- ii) Spinal immobilization;
 - **In-line immobilization** - The head & neck are supported in neutral position
 - **Quadruple immobilization** - A backboard, sandbags, forehead tape & a semi-rigid collar are applied
 - **Thoracolumbar spine** - Scoop stretcher or spinal board & if the back is to be examined, the log-rolling technique should be used

O/E

- Neck
- Back - *Tenderness, a haematoma, a gap or a step* between the interspinous ligaments, suggest instability due to posterior column failure.
- Shock;
 - **Hypovolaemic** - *Tachycardia, peripheral shut down & in later stages, hypotension*
 - **Neurogenic** - *Paralysis, Bradycardia & hypotension*. Reflects loss of the **sympathetic pathways** in the spinal cord; the peripheral vessels dilate causing hypotension but the heart, deprived of its sympathetic innervation, does not respond by increasing its rate. Use **atropine & vasopressors**. IVI may cause pulmonary oedema.
 - **Spinal** - Occurs when the spinal cord fails temporarily following injury. **Below** the level of the injury, the **muscles are flaccid**, the **reflexes absent & sensation is lost**. Lasts for **≤48Hrs** during which it's difficult to tell whether the neurological lesion is complete or incomplete. Return of the **primitive reflexes** (*anal wink & bulbocavernosus reflex*) signifies spinal shock has ended; the residual motor & sensory loss reflects the true state of affairs.
- Neurological examination
 - Each dermatome, myotome & reflex is tested
 - Cord longitudinal column functions are assessed (*Corticospinal, Dorsal, Spinothalamic tracts*)
 - **Sacral sparing** - Preservation of **active great toe flexion, anal tone** (on digital examination) & **intact perianal sensation** suggest a **partial** rather than complete lesion. Further recovery may occur.

Frankel Grading of functional deficit after an incomplete spinal injury;

Grade A - Absent Motor & Sensory function

Grade B - Sensation present, motor power **absent**

Grade C - Sensation present, motor power present but **not useful**

Grade D - Sensation present, motor power present & **useful (grade 4 or 5)**

Grade E - Normal motor & sensory function

60% - Grade **B, C, or D** - Improve (spontaneously) by one grade regardless of the treatment type.

- Clues of spinal cord injury in the unconscious patient;
 - History of a fall or rapid deceleration
 - Head injury
 - Diaphragmatic breathing
 - Flaccid anal sphincter
 - Hypotension with bradycardia
 - Pain response **above but not below** the clavicle

Ix

- Spinal x-ray;
 - a) AP & lateral
 - b) Open mouth views - C₁ & C₂ (**False +ves** - *Superimposition of the teeth & If the epiphyseal plate is not fused (usually <16yrs)*)
 - c) Oblique views - Thoracolumbar
- CT scan - Ideal for showing *structural damage to individual vertebrae & displacement of bone fragments into the vertebral canal*
- MRI - Method of choice for showing *intervertebral discs, ligmentum flavum & neural structures*

Palliative Treatment

- 2 hourly turning
- Toilet care - *Catheterize & Diapers*
- Skin care - Keep skin dry
- Repo mattress or padding of pressure points
- Active management of bedsores with *regular dressing & debridement of devitalized tissue*
- Physiotherapy

Definitive Treatment

Objectives;

- i) To preserve neurological function
- ii) To relieve any reversible neurological compression
- iii) To restore alignment of the spine
- iv) To stabilize the spine
- v) To rehabilitate the patient

- **IV Methyl prednisolone** is given within **8hrs (Up to 24-48Hrs is practical)** ; if given later, may interfere with surgery;
 - Orthostatic pneumonia
 - Poor wound healing
- **No Neurological injury;**
 - Stable injury - *Collar or lumbar brace + bed rest till the pain & muscle spasm subside*
 - Unstable injury - immobilisation until the tissues heal & the spine becomes stable
 - * Cervical spine - *traction using tongs or a halo device attached to the skull*
 - * Thoracolumbar spine - *ORIF*
 - Dislocations & Subluxations must be reduced
- **Neurological injury;**
 - Stable (rare) - *Conservative + Rehabilitation*
 - Unstable;
 - * High thoracic injuries with *no associated rib or sternal fractures* - *Conservative + Physiotherapy & Occupational therapy*
 - * Others - *Operative reduction or decompression & stabilization* is needed if neurological loss is **incomplete or is progressive**
- Urgent **decompression & surgical stabilization;**
 - An unstable fracture with *progressive neurological deficit*
 - An unstable fracture in a patient with multiple injuries
- Modes of stabilization;
 - Pedicular screws
 - Rods & sublaminar wires
 - Plates anteriorly on the vertebral bodies

Compression Injury

Mechanism of injury

- **Spinal flexion** - In osteoporotic patients, fracture may occur with minimal trauma. The posterior ligaments usually remain intact, although they may be damaged by distraction
- Neurological injury is rare

Ix

- CT-scan - *Posterior part of the vertebral body (middle column) is **unbroken***

Mx

- <10% wedge - **Conservative** - *Bed rest for 1-2wks until pain subsides then mobilisation*
- 10-40% wedge - **Thoracolumbar brace**. At 12wks, flexion-extension views are taken out of the brace; if there is no instability, the brace is gradually discarded
- >40% wedge - **Unstable #** - It is likely that the posterior ligaments have been damaged by distraction & will be unable to resist further collapse & deformity. **ORIF**

Burst Injury

Mechanism of injury

- Severe axial compression may 'explode' the vertebral body causing failure of both the **anterior & middle columns**
- The posterior part of the vertebral body is shattered & fragments of bone & disc may be displaced into the spinal canal
- **Neurological Instability** - Refers specifically to burst fractures where a *neurological deficit develops when the patient is mobilized* because of bone protrusion from the vertebral body into the spinal canal.
- **Unstable #**

Ix

- X-ray - AP - *Spreading of the vertebral body with an **increase of the interpedicular distance***
- CT scan - *Posterior displacement of bone into the spinal canal (**retropulsion**)*

Mx

- If there is minimal retropulsion of bone, no neurological damage & minimal anterior wedging - Bed rest until the acute symptoms settle **3-6wks** & is then mobilised in a **thoracolumbar brace** which is discarded at about **12wks**
- If neurological symptoms - **Anterior decompression & stabilization**

Mx Metastatic deposits (*thyroid, breast, lung, suprarenals, kidney, **prostate**, ovaries*)

- * Conservative management;
 - Prolonged paraplegia
 - Wide spread metastases
- * If the 1° tumour is known;
 - **NO** motor weakness - *Steroids + Radiotherapy*
 - Motor signs +ve - *Decompressive laminectomy + Radiotherapy or Steroids*

READ

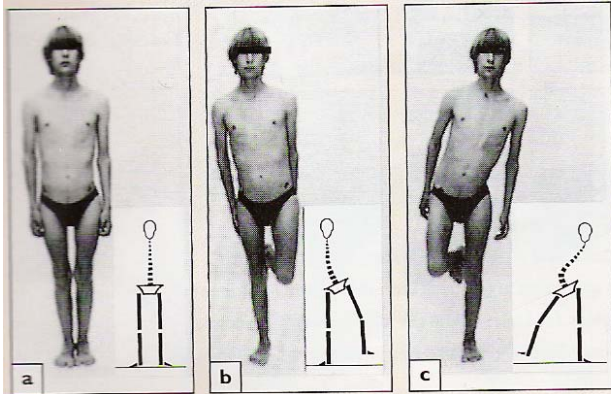
- The Spine
- TB bone
- Multiple myeloma

Pelvis

Examination of the Hip

Patient Upright

- a) **Inspection** - Start by standing face-to-face with the patient & note his or her general build & **symmetry of the lower limbs**. While the patient is upright, take the opportunity to **examine the spine** for deformity or limitation of movement
- b) **Trendelenburg's sign**



19.1 Trendelenburg's sign (a) Standing normally on two legs. (b) Standing on the right leg which has a normal hip whose abductor muscles ensure correct weight transference. (c) Standing on the left leg whose hip is faulty, and so abduction cannot be achieved; the pelvis drops on the unsupported side and the shoulder swings over to the left.

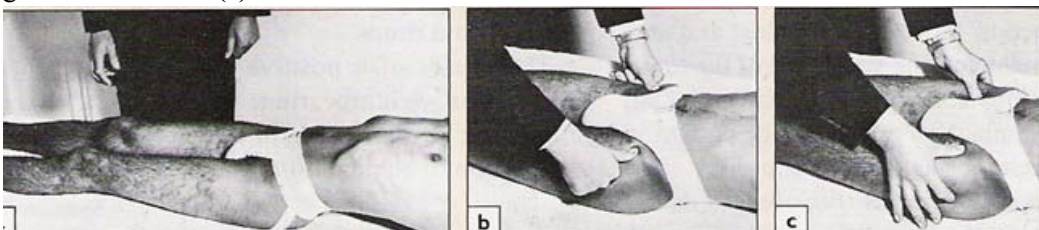
Causes of a positive Trendelenburg's sign;

- Pain on weight bearing
 - Weakness of the hip abductors
 - Shortening of the femoral neck
 - Dislocation or subluxation of the hip
- c) **Gait** - Observed from the patient walking
- Abnormalities;
- **Short-leg limp** - a regular, even dip on the short side
 - **Antalgic gait** - An irregular limp, with the patient moving more quickly off the painful side
 - **Trendelenburg lurch** - A variant of Trendelenburg's sign

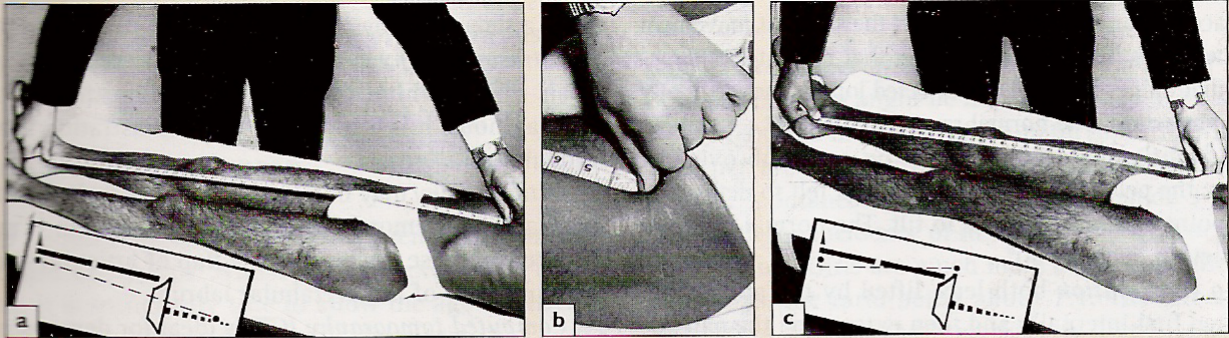
Patient sitting - This is the best way to test the *iliopsoas* function. The patient sits on the edge of the examination couch. Place a hand firmly on his thigh & ask him to lift the thigh (flex the hip) against resistance. Pain or weakness suggests a local disorder e.g. tendinitis or psoas bursitis

Patient Lying Down

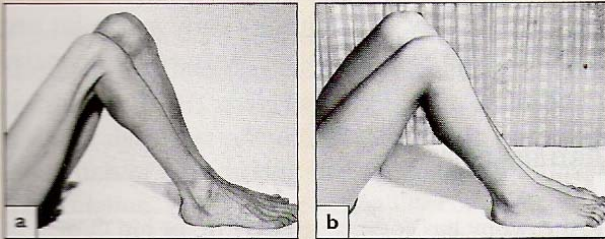
- a) **Inspection** - Check for signs of muscle wasting & swelling. Check that the pelvis is horizontal (Both ASIS at the same level) & the legs & pelvis are square with the couch (a). Feel for the ASIS (b) & the top of the greater trochanter (c)



b) Limb length can be gauged by looking at the ankle & heels, but measurement is more accurate

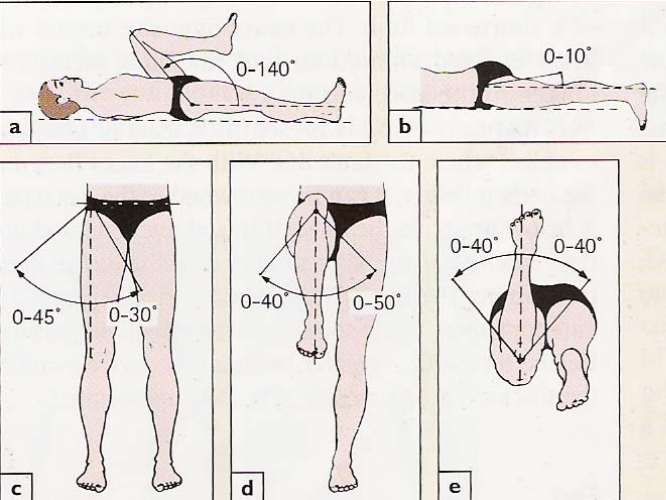


19.5 Shortening (2) – measurements Apparent length (a) is measured from a fixed point in the midline (e.g. the xiphisternum) to the bottom of the medial malleolus. Real length is measured from the anterior superior iliac spine; note how the thumb is pressed hard up against it (b) – also to the medial malleolus (c).



19.6 Shortening (3) Provided the backs of both heels are exactly level, bending the knees immediately shows whether the shortening is (a) above the knee or (b) below it.

c) Movement



19.7 Normal range of movements (a) The hip should flex until the thigh meets the abdomen, but (b) extends only a few degrees. (c) Abduction is usually greater than adduction. The relative amounts of internal and external rotation may vary according to whether the hip is in (d) flexion or (e) extension.

To test rotation both legs, lifted by the ankles, are rotated first internally & then externally; the patella are watched to estimate the amount of rotation.

d) Muscle Bulk, Tone & Power

Dislocation of the Hip

Often small fragments of bone are chipped off as the joint dislocates; if there is a *major fragment, or comminution*, it is regarded as a **fracture-dislocation**.

a) Posterior Dislocation

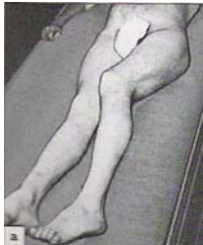Commonest Variety

Mechanism of Injury

Usually occurs when someone seated in a vehicle is thrown forwards, *striking the knee against the dashboard*. The femur is thrust upwards & the femoral head is forced out of its socket; often a piece of bone at the back of the acetabulum (the posterior wall of the socket) is sheared off making it a fracture-dislocation.

C/P

The leg is **short & lies adducted, internally rotated & slightly flexed**



DDx for shortening

- Fracture femur
- Acetabular fracture

Mx

- **Skin traction**
- **Reduction under GA** - An assistant steadies the pelvis; the surgeon starts by applying **traction in the line of the femur** as it lies (usually in **adduction & internal rotation**) & then gradually **flexes the patient's hip & knee to 90°**, maintaining traction throughout. At 90° flexion, traction is increased & sometimes a little rotation (both internal & external) is required to accomplish reduction. A satisfying 'clunk' terminates the manoeuvre. X-rays are essential to confirm reduction & exclude a fracture.

Complications

Early;

- **Sciatic nerve injury**
- Vascular injury - *the superior gluteal artery may be torn*
- Associated fractured femoral shaft

Late;

- Avascular necrosis of the femoral head
- Myositis ossificans
- Unreduced dislocation
- 2° Osteoarthritis due to:
 - * Cartilage damage at the time of the dislocation
 - * The presence of retained fragments in the joint
 - * Ischemic necrosis of the femoral head

b) Anterior Dislocation

Mechanism of injury

A **posteriorly** directed force on an **abducted & externally rotated** hip will cause the neck to impinge on the acetabular rim & lever the femoral head out in front.

The femoral head will lie **superiorly (Type I)** or **inferiorly (Type II)**

C/P

The leg lies **externally rotated, abducted** (occasionally almost to a right angle) & **slightly flexed**. It is **not short**, because of the *attachment of the rectus femoris on the AIIS & superior aspect of the acetabulum* thus prevents the head from displacing upwards.

O/E

- The prominent head is easy to feel, either *anteriorly (superior type)* or in the *groin (inferior type)*
- Hip movements are impossible

Mx

The manoeuvres employed are similar to those used to reduce posterior dislocation, except that while the hip is gently flexed upwards, it should be kept **abducted**; an assistant then helps by applying **lateral traction** to the thigh.

Pelvis

Injuries to the pelvis are associated with;

- *Shock/Risk of severe blood loss* - The **major branches of the common iliac arteries** arise within the pelvis between the level of the *sacroiliac joint & the greater sciatic notch*. With their accompanying veins, they are particularly vulnerable in fractures through the **posterior** part of the **pelvic ring**.
- The nerves of the **lumbar & sacral plexuses**, likewise, are at risk with **posterior pelvic injuries**.
- In severe pelvic injuries, the **membranous urethra** is damaged when the prostate which lies between the bladder & the pelvic floor is forced **backwards** whilst the urethra remains static. When the **puboprostatic ligament** is torn, *the prostate & base of the bladder can be grossly dislocated from the membranous urethra*
- Soft-tissue injuries
- Sepsis
- ARDS

C/P

- Severe pain & patient feels like he/she has fallen apart
- Swelling or bruising of the *lower abdomen, the thighs, the perineum, the scrotum or the vulva*
- Gross haematuria

Examination

- Airway with cervical spine control, **B**reathing, **C**irculation & haemorrhage control, **D**isability & **E**xposure
- The abdomen is carefully palpated - signs of irritation suggest the possibility of intraperitoneal bleeding - **Do immediate DPL** in haemodynamically unstable patients with suspect intraperitoneal haemorrhage - up to **IL** of blood may be lost.
- The pelvic ring is compressed from side to side & back to front - Tenderness over the sacroiliac region may signify disruption of the posterior bridge.
- Examine the external urethral meatus - An **inability to void & blood at the external meatus** are the classic features of a **ruptured urethra**; However the absence of blood at the meatus does **NOT** exclude urethral injury, because *the external sphincter may be in spasm*.
- A **DRE** - The coccyx & sacrum can be felt & tested for tenderness. If the prostate can be felt, which is often difficult due to pain & swelling, it's position should be gauged; an abnormally high prostate suggests a urethral injury
- Vaginal examination
- Neurological examination

Ix

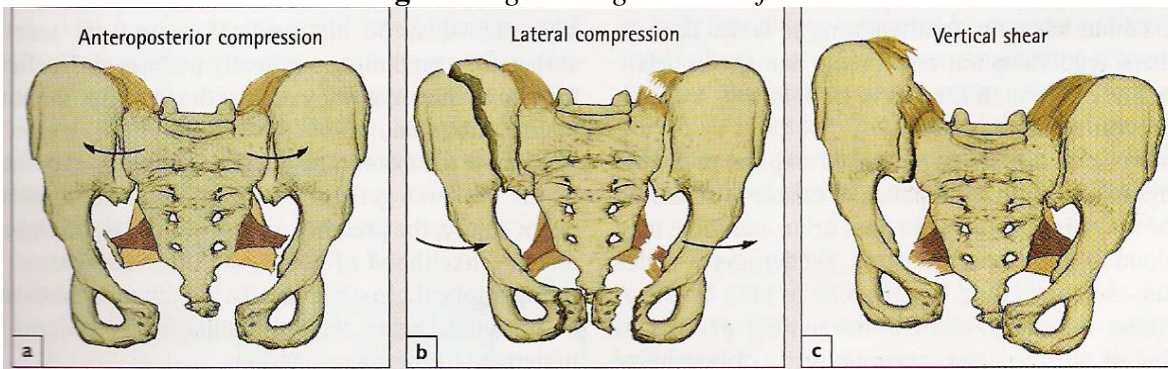
- X-Rays;
 - * Pelvis;
 - AP
 - **Inlet view** - Tube **cephalad** to the pelvis & tilted **30° downwards**
 - **Outlet view** - Tube **caudad** to the pelvis & tilted **40° upwards**
 - **Right & left Oblique views** - Helpful for defining the *ilium & acetabulum* on each side
 - * CXR - **PE & ARDS**
- CT scan - Especially for *posterior pelvic ring disruptions & for complex acetabular fractures*
- IVU - *to exclude renal injury*
- Retrograde urethrography - *for urethral tears*

Types

1. Isolated fractures with an intact pelvic ring

- a) **Avulsion fractures** - *managed by rest for a few days & reassurance* - Heal in **4-6wks**
 - ASIS - Satorius
 - AHS - Rectus femoris
 - Pubis - Adductor longus
 - Ischium - Hamstrings - *Avulsion of the ischial apophysis may need ORIF*
- b) **Stress fractures** - Fractures of the **pubic rami** in *severely osteoporotic or osteomalacic patients*
- c) **Direct fractures**

2. Fractures with a broken ring - Young & Burgess Classification



28.7 Types of pelvic ring fracture The three important types of injury are shown. (a) Anteroposterior compression with lateral rotation may cause the 'open book' injury, the hallmark of which is diastasis of the pubic symphysis. Widening of the anterior portion of the sacroiliac joint is best seen on an inlet view. (b) Lateral compression causing the ring to buckle and break; the pubic rami are fractured, sometimes on both sides. Posteriorly the iliac blade may break or the sacrum is crushed. (c) Vertical shear, with disruption of both the sacroiliac and symphyseal regions on one side.

- a) **APC-I** - Slight diastasis (<2cm) of the symphysis - **Stable**
APC-II - Diastasis is more marked & the **anterior sacroiliac ligaments** are torn (*often also the sacrotuberous & sacrospinous ligaments*) - **Stable**
APC-III - **Anterior & posterior sacroiliac ligaments** are torn. Shift/separation of the sacroiliac joint; the one hemipelvis is disconnected from the other anteriorly & from the sacrum posteriorly - **Unstable**
- b) **LC-I** - Transverse fracture of the **pubic ramus (or rami)** ± compression fracture of the sacrum - **Stable**
LC-II - LC-I + Fracture of the **iliac wing** on the side of impact - **Stable**
LC-III - LC on **one iliac wing** & an opening APC on the **opposite ilium** - **Unstable**
- c) **Vertical Shear** - The hemipelvis is totally disconnected - **Unstable**
- d) **Combination injuries**

C/P

- Stable fractures;
 - * Patient is **not** severely shocked
 - * Pain on attempting to walk
 - * Localised tenderness but seldom any damage to pelvic viscera (*except a severe LC-II injury*)
- Unstable Fractures;
 - * Patient is **severely shocked**
 - * In great pain & **unable to stand**
 - * Unable to pass urine ± blood at the external meatus

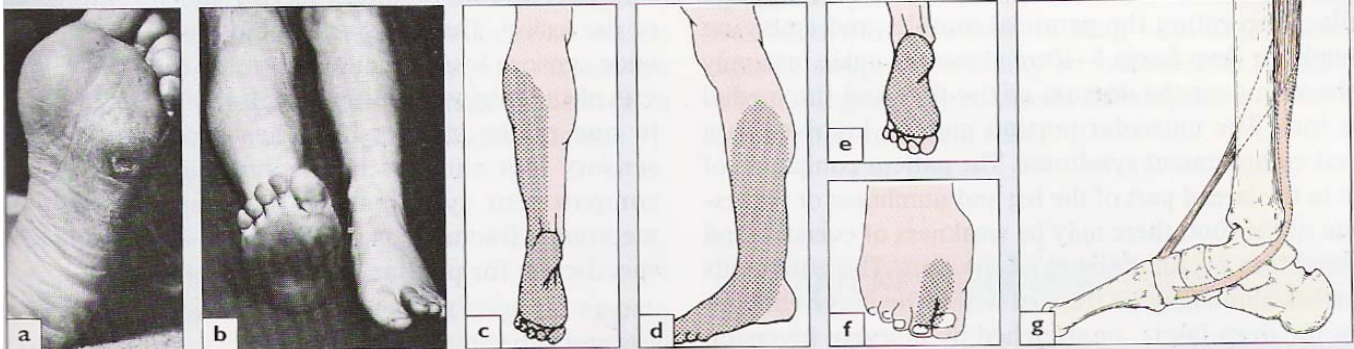
Mx

- Airway with cervical spine control, **Breathing**, **Circulation** & haemorrhage control, **Disability** & **Exposure**
- **NO attempt should be made to pass a catheter**, as this could convert a partial to a complete tear of the urethra. Instead, put a **supra-pubic catheter** if patient is unable to pass urine
- **Conservative** - **Early external fixation** - *Reduces haemorrhage & counteracts shock*
- **Definitive**;
 - **Isolated fractures** & minimally displaced fractures - **Bed rest + Lower limb traction**. Heals within 4-6wks & the patient may be allowed up on crutches
 - **Open-book injuries**;
 - * **APC-I** - **Bed rest + a posterior ring, elastic girdle or Hammock** to help close the book
 - * Others - **External fixation**
 - * Fractures of the iliac blade only - **Bed rest**
 - * + Marked displacement or associated anterior ring fracture or symphysis separation - **ORIF with plates & screws**
 - * **APC-II & VS** - **Skeletal traction + External fixator for 10wks**
 - a) **Anterior external fixation or Plating** & Posterior stabilization using **screws** across the sacroiliac joint or
 - **Open pelvic fractures** - **External fixation**

- DVT prophylaxis

Secondary complications

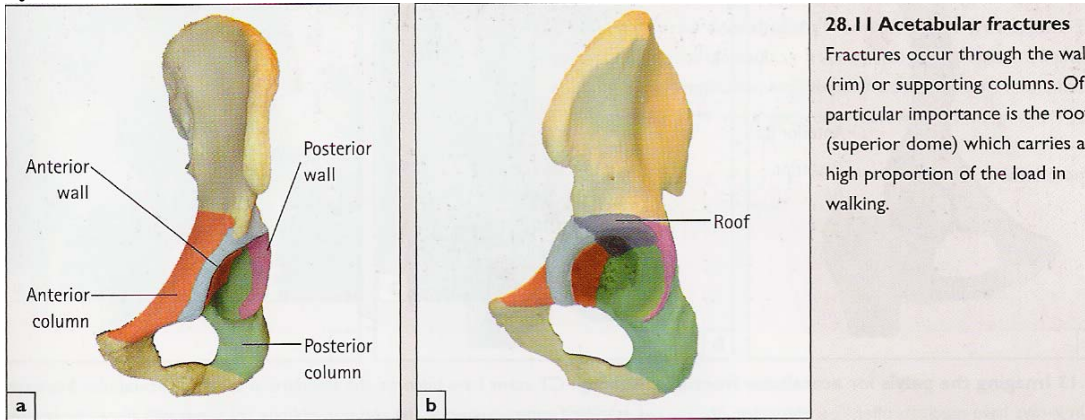
- *Sciatic nerve injury* - usually a neuropraxia & resolves in 6wks



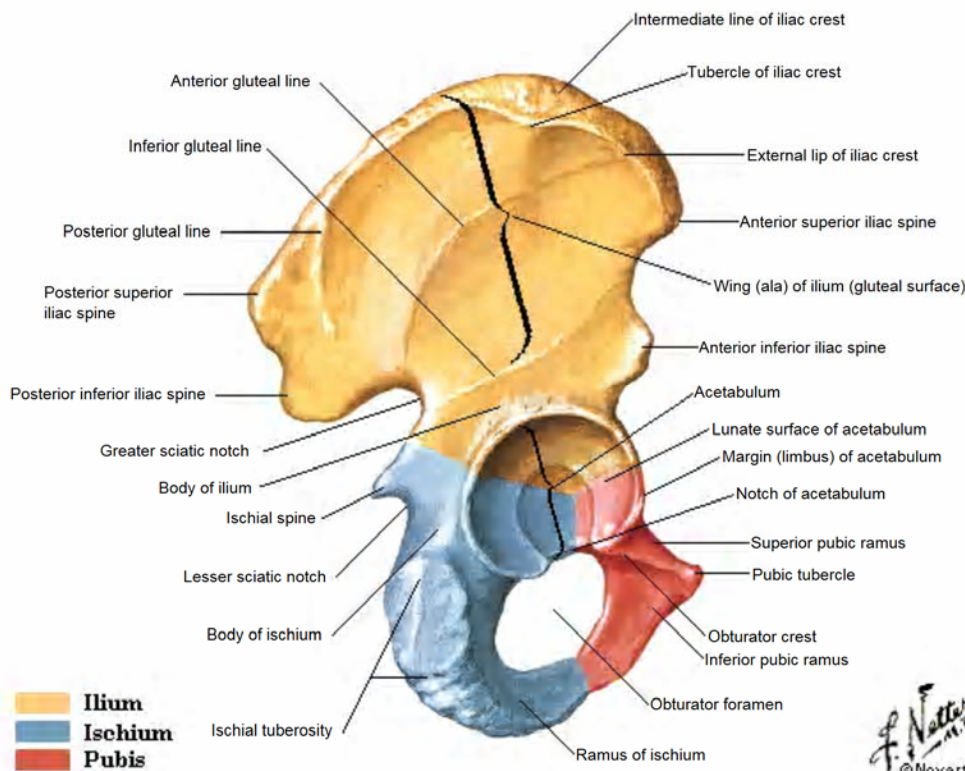
11.15 Two problems in sciatic nerve lesions are (a) trophic ulcers because of sensory loss and (b) foot drop. Sensory loss following division of (c) complete sciatic nerve, (d) lateral popliteal nerve, (e) posterior tibial nerve and (f) anterior tibial nerve. (g) Drop foot can be treated by rerouting tibialis posterior so that it acts as a dorsiflexor.

- *Urogenital problems* - Stricture, incontinence or impotence (especially if surgery involves the pubic symphysis)
- *Persistent sacroiliac pain*

3. Acetabular # Anatomy



28.11 Acetabular fractures
Fractures occur through the wall (rim) or supporting columns. Of particular importance is the roof (superior dome) which carries a high proportion of the load in walking.



F. Netter M.D.
©Novartis

Mechanism of injury

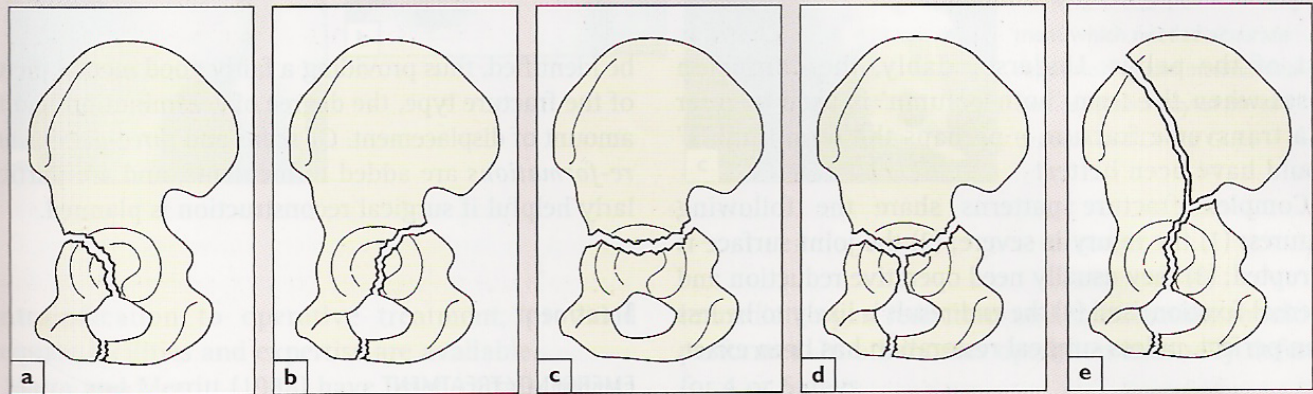
Occur when the head of the femur is driven into the pelvis as a result of;

- A blow on the side (as in a fall from a height)
- A blow on the front of the knee, usually in a *dashboard injury* when the femur also may be fractured

C/P

- Bruising & abrasions on the thigh or buttock
- Degloving of skin in the area - *Morel-Lavallé lesion*
- **Posterior column fracture** is usually associated with a **posterior dislocation of the hip** & may injure the *sciatic nerve*

Tile's Classification

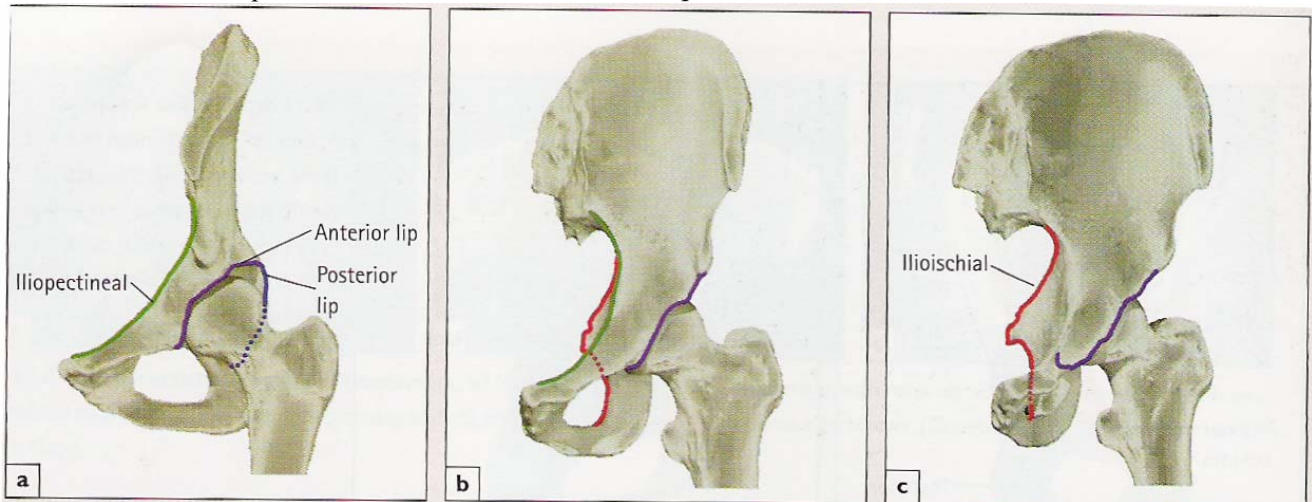


28.12 Tile's classification of acetabular fractures There are four types of injury: (a, b) a simple fracture involving either the anterior or the posterior wall or column; (c) a transverse or (d) a T-type fracture involving two columns; (e) the both-column fracture, resulting in a 'floating' acetabulum with no part of the socket attached to the ilium (compare this with the transverse or T-type fractures).

Ix

At least 4 x-ray views should be obtained in every case;

- AP
- Pelvic Inlet view
- Two 45° oblique views i.e. *Iliac & Obturator oblique views*



28.13 Imaging the pelvis for acetabular fractures Although CT scans have become the standard in assessing acetabular fractures, plain x-rays have much to offer. The obturator oblique (a), standard anteroposterior (b) and iliac oblique (c) views will allow the trained eye to picture the structures involved in the injury. The iliopectineal line represents a profile of the anterior column whereas the ilioischial line defines the posterior column. The margins of the anterior and posterior walls are usually seen in all three views.

Mx

Emergency;

- Counteract shock
- Reduce a dislocation
- Apply **traction** to the distal femur & during the next 3-4days the patient's general condition is brought under control

Conservative Mx;

Indications;

- Acetabular fractures with minimal displacement (in the weight-bearing zone, <3mm)
- Displaced fractures that do **not** involve the **superomedial** weight-bearing segment (roof) of the acetabulum or only <20% is lost- usually **distal anterior column & distal transverse fractures**
- A both-column fracture that retains the ball & socket congruence of the hip by virtue of the fracture line lying in the **coronal plane** & displacement being limited by an intact labrum
- Fractures in elderly patients, where closed reduction seems feasible
- Patient's with 'medical' contraindications to operative treatment (including local sepsis)

The following criteria (*Matta & Merritt*) should be met if conservative Mx is expected to succeed;

- When traction is released, the hip should remain congruent
- The weight-bearing portion of the acetabular roof should be intact
- Associated fractures of the posterior wall should be excluded by CT

Closed reduction & Longitudinal traction, if necessary supplemented by **lateral traction**, is maintained for **6-8wks**; This will unload the articular cartilage allowing it to heal & will help prevent further displacement of the fracture. During this period, hip movement & exercises are encouraged. The patient is then allowed up, using crutches for a **further 6wks**

Operative Mx;

Indications - *surgery can be deferred for 4-5days*;

- Unstable hips
- Fractures resulting in significant distortion of the ball & socket congruence
- Associated fractures of the femoral head &/or retained bone fragments in the joint

Immediate operations;

- If stable closed reduction cannot be achieved
- If the joint redislocates

ORIF with **lag screws** or special **butressing plates** which can be shaped in the operating theatre.

Post-op hip movements are started as soon as possible & the patient is allowed up, partial weight-bearing with crutches, after **7days**. Exercises are continued for **3-6months**; it may take **a year** or longer for full function to return.

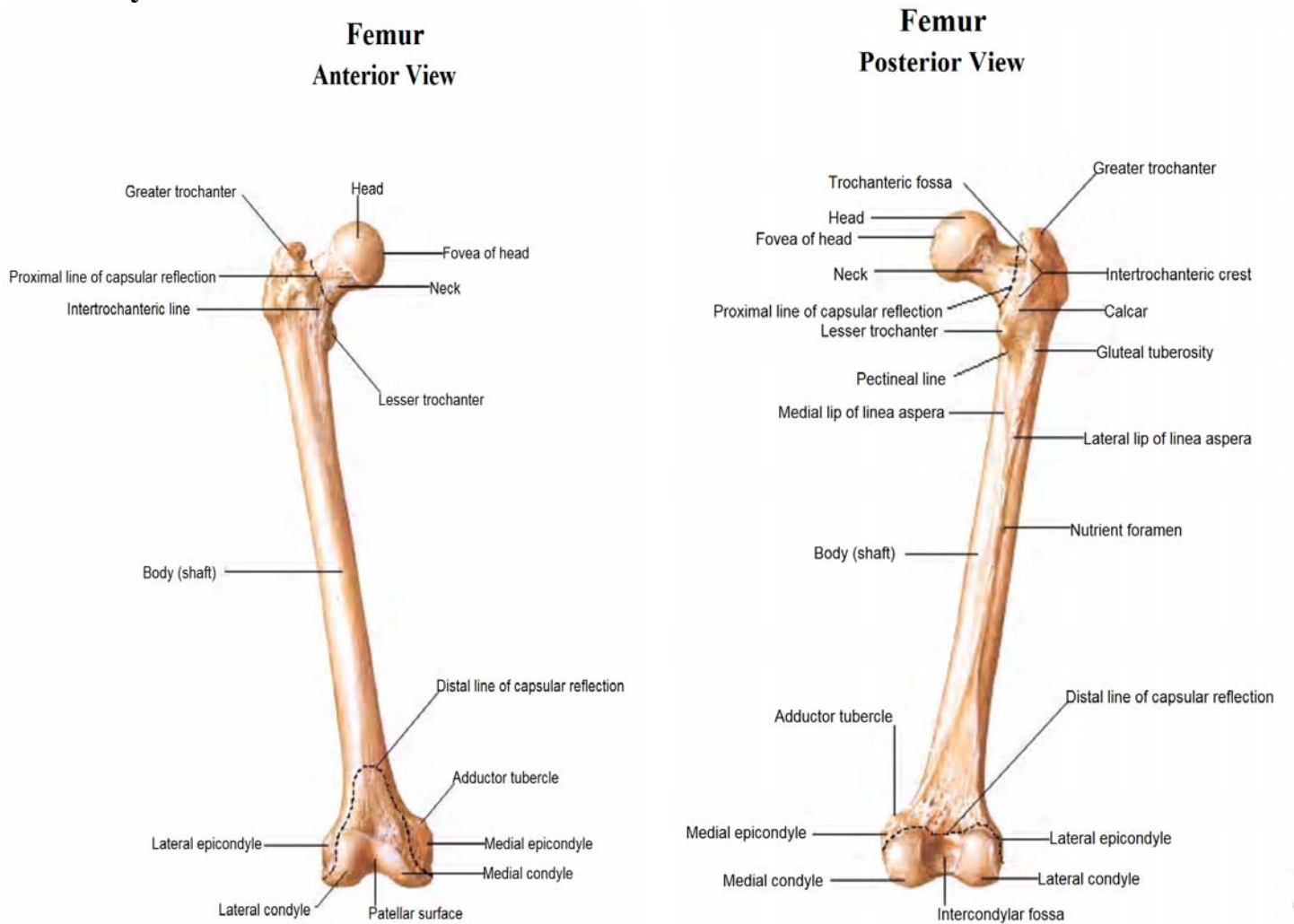
DVT prophylaxis

Complications

- Iliofemoral venous thrombosis
- Sciatic nerve injury - Recovery is complete in **50%**, partial in **40%** & No recovery in **10%**
- Myositis ossificans - In cases where it is anticipated, prophylactic **indomethacin** is used
- Avascular necrosis of the femoral head
- Loss of joint movement & 2° osteoarthritis

Femur

Anatomy



Anatomic Classification

- a) Intracapsular - *Fracture of the femoral neck proper*
 - i) Subcapital
 - ii) Transcervical
 - iii) Basal
- b) Extracapsular
 - i) Intertrochanteric - Trochanteric fracture
 - ii) Subtrochanteric - Up to **5cm** below the lesser trochanter

a) Intracapsular Fractures - Fracture of the Neck of the Femur

Common in **women >60years** in whom there is a tendency for the bone to become increasingly fragile as a consequence of generalised osteoporosis due to post-menopausal bone loss.

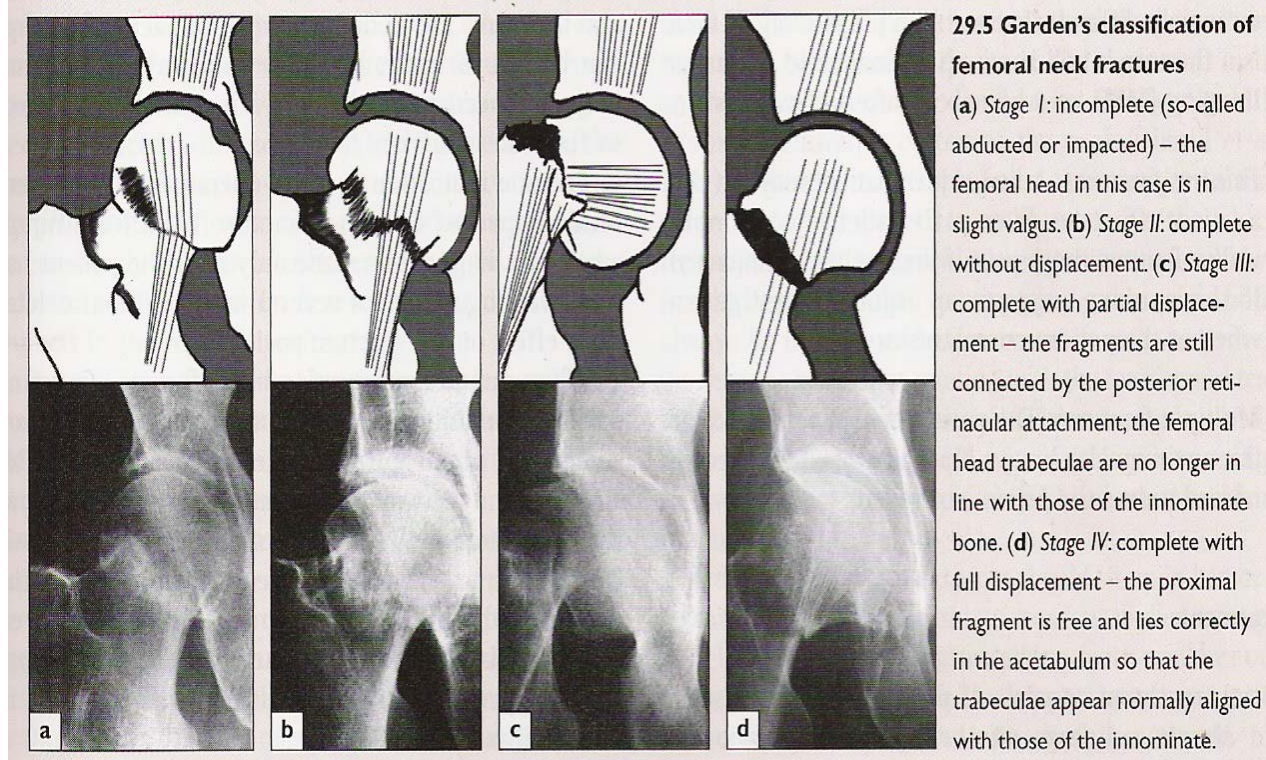
Risk Factors

- *Osteoporosis*
- Bone-losing or bone-weakening disorders e.g. *osteomalacia, diabetes, stroke (disuse), alcoholism & chronic debilitating disease.*

Ix

Garden's Classification

This classification is based on the **amount of displacement** apparent in the pre-reduction x-rays which is judged by the abnormal shape of the bone outlines & the degree of mismatch of the **trabecular lines** in the **femoral head, neck & the supra-acetabular (innominate) part of the pelvis.**



The femoral neck fracture may be missed in;

- i) Stress fractures - The elderly patient with unexplained pain in the hip; X-Ray is usually normal, but a bone scan will show the 'hot' lesion.
- ii) Undisplaced fractures - Shows up on an MRI or Bone scan after a few days.
- iii) Painless fractures
- iv) Multiple fractures e.g. Femoral shaft fracture

C/P

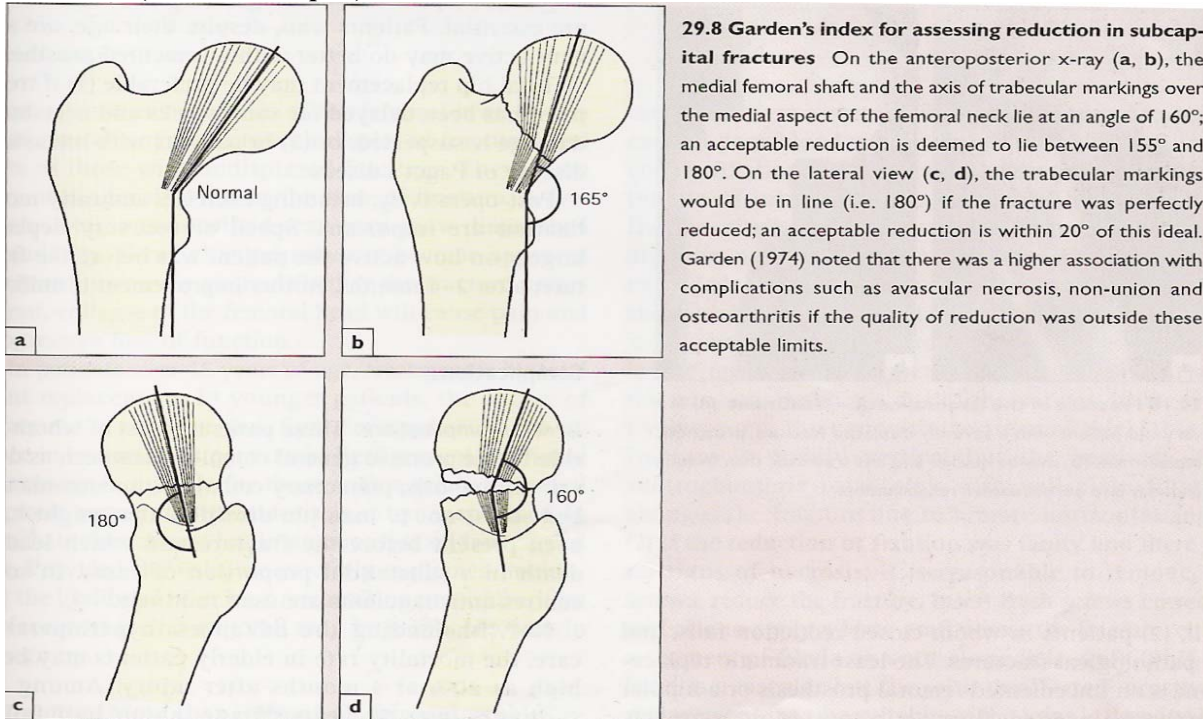
- **Garden's Stage I** - A typical history is that the elderly patient tripped & fell & was **able** to pick herself up after falling & may have walked perhaps with assistance & **remained mobile** despite pain. On examination, there is **no detectable abnormality** & the patient is able to move the hip through a moderate range **without severe pain.**
- **Displaced fractures** - the elderly patient tripped & fell, & was **unable** to get up again unaided & she was subsequently **unable to take weight on the injured limb.** On examination, there was marked **hip flexion, abduction & external rotation** of the limb because of **gluteus medius & iliopsoas** (inserted at the greater & lesser trochanter respectively) causing **shortening** by 2-3cm & movement of the hip causes severe **pain.**

DDx - of external rotation;

- Congenital dislocation
- Intracapsular & Extracapsular & shaft of femur fractures
- Herpes osteoarthritis

Mx

- **Pre-op;**
 - Pain relief
 - Splintage
- **Conservative Mx** - An '*old*' **Garden's I fracture** where the diagnosis is made only after the patient has been walking about for several weeks without deleterious effect on the fracture position.
- **Surgical Mx** - *Best if done within 12hrs.*
- **Reduction (Closed then Open)**- Under GA.



- ♦ **Children** - Closed reduction followed by *immobilisation in plaster*
- ♦ **Young patients**
 - **Garden's I** - ORIF - *Multiple parallel cannulated screws (usually 3)*
 - **Displaced** - ORIF with a *Dynamic Hip Screw*

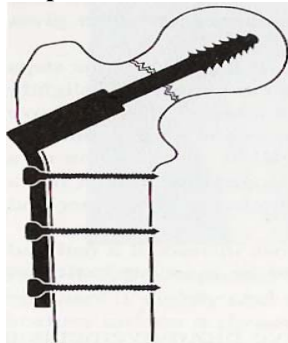


Fig. 14.3 Compression screw-plate (dynamic hip screw) used for some fractures of the femoral neck and for trochanteric fractures. The lag screw gripping the head fragment is drawn into the barrel by tightening the end screw, thus compressing the fragments together.

- ♦ **Elderly**
 - **Garden's I** - ORIF with a *Dynamic Hip Screw*
 - **Displaced**
 - ORIF with a *Dynamic Hip Screw*
 - **Hemiarthroplasty** - consists in removal of the **head & neck** of the femur & replacement by a **metal prosthesis**;
 - * In very old patients with a limited lifespan ± comorbidity
 - * If ≥ 2 closed reduction attempts fail in an elderly patient
 - * Comminution of either fragment
 - * Pathological fractures
 - **Total Hip replacement**;
 - * If treatment has been delayed for some weeks & *acetabular damage is suspected (Garden I)*
 - * In patients with *metastatic disease or Paget's disease.*

Post-op;

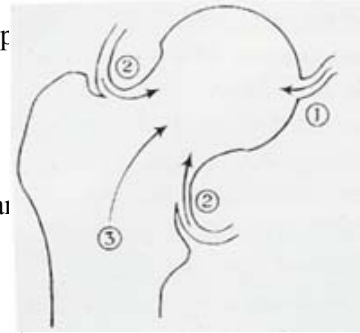
- Patient should sit-up in bed or in a chair
- Breathing exercises
- Active hip movements are encouraged
- Early mobilisation - with crutches or a walker

Complications

a) Avascular necrosis

Blood supply to the femoral head is through;

- (1) Vessels in ligamentum teres from the *obturator artery* - **15-20%** supply
- (2) Retinacular vessels
- (3) Nutrient vessels from the femoral shaft
- (4) *Trochanteric anastomosis* in the trochanteric fossa;
 - Descending branch of superior gluteal artery
 - Ascending branches of medial & lateral femoral circumflex arteries
 - Occasionally a branch of the inferior gluteal artery
- (5) *Cruciate anastomosis* at the level of the lesser trochanter;
 - Descending branch of inferior gluteal artery
 - Transverse branches of medial & lateral femoral circumflex artery
 - Ascending branch of 1st Perforator of the Profunda Femoris



Causes;

- i) Slipped upper femoral epiphysis
- ii) **Perthe's Disease** - *painful disease of childhood characterized by avascular necrosis of the femoral head; 4-8yrs old; M>F*
- iii) Gaucher's disease
- iv) Infection
- v) Posterior dislocation of the hip - **Most common**
- vi) Fracture of the femoral neck
- vii) Sickle cell disease
- viii) Alcoholism
- ix) Radiation injuries

b) Non-Union:

- Avascular necrosis
- Incomplete immobilization
- Flushing of the fracture haematoma by *synovial fluid* which also contains *angiogenic inhibiting factors*
- Lack of a periosteum
- All healing must be endosteal

c) Late Osteoarthritis;

- *Mechanical damage* to the articular cartilage at the time of injury or operation
- *Impairment of the blood supply* to the basal layers of the cartilage, which are probably nourished largely from the vessels in the underlying bone
- From *union in faulty alignment*

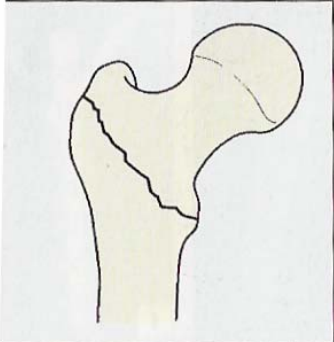
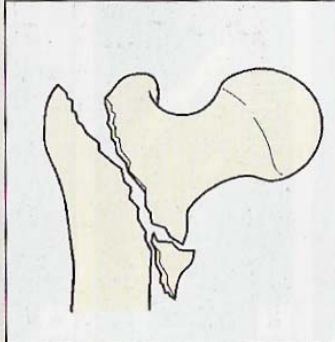
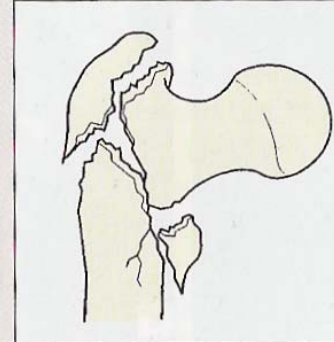
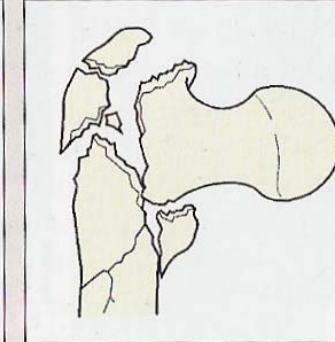
Prognosis

Garden I & II fractures, which are only slightly displaced, have a much better prognosis for union & for viability of the femoral head than the more severely displaced Garden III & IV fractures

Extracapsular Fractures

b) Intertrochanteric Fractures

Classification

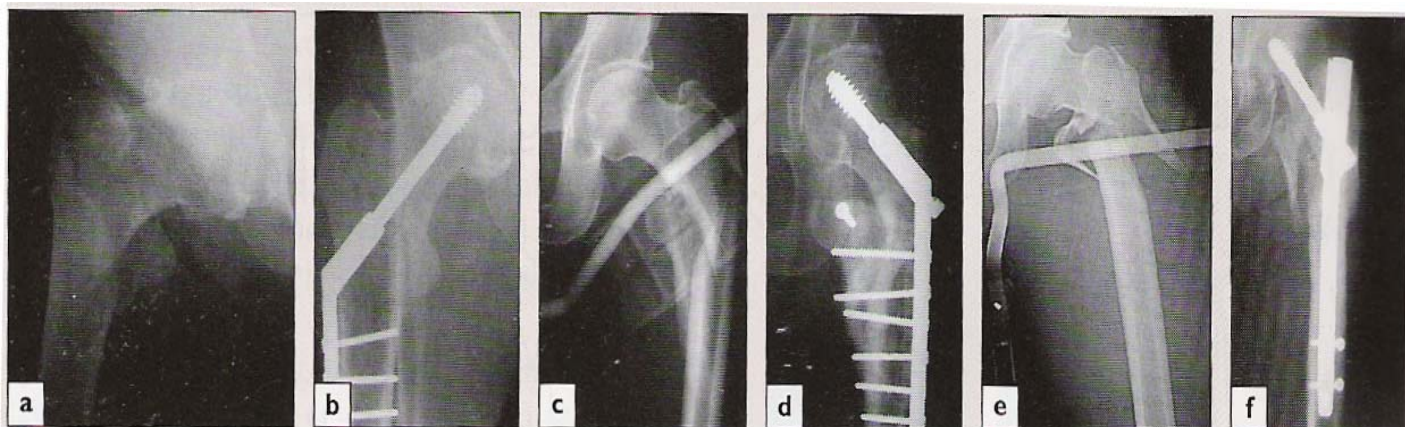
			
<p>TYPE 1 Undisplaced Uncomminuted</p>	<p>TYPE 2 Displaced Minimal comminution Lesser trochanter fracture Varus</p>	<p>TYPE 3 Displaced Greater trochanter fracture Comminuted Varus</p>	<p>TYPE 4 Severely comminuted Subtrochanter extension (Also reverse oblique)</p>

29.13 Intertrochanteric fractures – classification Types 1 to 4 are arranged in increasing degrees of instability and complexity. Types 1 and 2 account for the majority (nearly 60%). The reverse oblique type of intertrochanteric fracture represents a subgroup of Type 4; it causes similar difficulties with fixation.

S/S

- Patient old & unfit
- Following a fall she is unable to stand
- The leg is **shorter & more externally rotated** than fracture neck of femur (*because fracture is extracapsular*)
- Patient cannot lift her leg

Mx



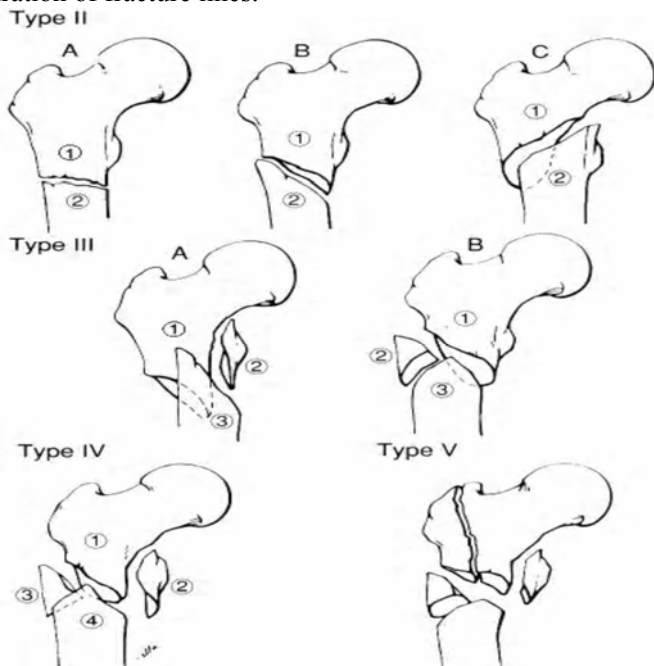
29.15 Intertrochanteric fractures – treatment Anatomic reduction is the ideal; but stable fixation is equally important. Types 1 and 2 fractures (a, b) can usually be held in good position with a compression screw and plate. If this is not possible, an osteotomy of the lateral cortex (c, d) will allow a screw to be inserted up the femoral neck and into the head of the femur; this can be used as a lever to reduce the fracture so that the medial spike of the proximal fragment engages securely into the femoral canal; fixation is completed with a side plate. Reverse oblique fractures (e, f) are inherently unstable even after perfect reduction; here one can use an intramedullary device with a locking screw that engages the femoral head. (Courtesy of Mr M Manning and Mr JS Albert.)

* (f) - Reconstruction nail

c) Subtrochanteric Fractures

Occur *up to 5cm below the lesser trochanter* or *between the lesser trochanter & the isthmus* - the narrowest part of the medullary canal.

Seinsheimer classification of subtrochanteric fractures - Based on number of fragments & location & configuration of fracture lines.



Three important features are looked for on x-ray;

- An unusually long fracture line extending proximally towards the greater trochanter & piriform fossa
- A large, displaced fragment which includes the lesser trochanter
- Lytic lesions in the femur

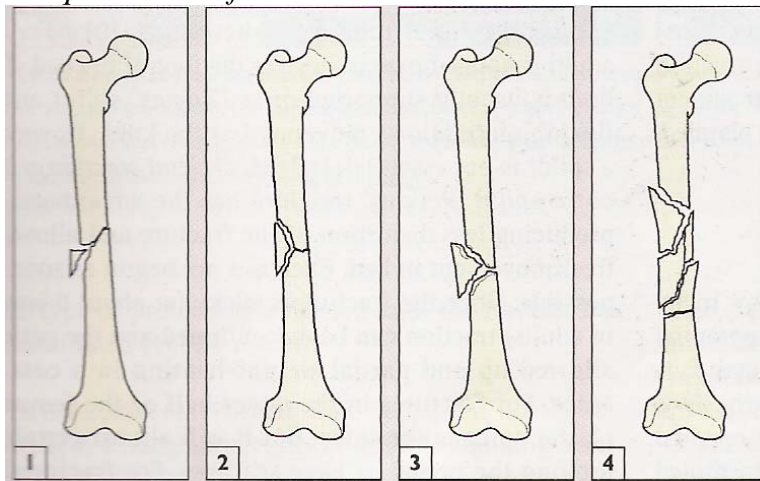
Mx

ORIF - *The posteromedial fragment (lesser trochanter) must be reduced & fixed*

- Fractures **extending to piriform fossa** - *95° angle plate*
- **Lesser Trochanter** - A *compression (dynamic) hip screw & plate*; A larger medial fragment including part of the lesser trochanter may need separate reduction & fixation to ensure stability
- **Below lesser trochanter** - *Interlocking nail*; if the fracture extends proximally, the locking screws will need to grip the femoral head. If the medial cortex is comminuted or deficient, bone grafts should be added.
- **Pathological fracture** - *Full length nail* as there may be tumour deposits in the distal part of the femur

d) Femoral shaft fractures

Winqvist's Classification



29.18 Femoral shaft fractures – classification

Winqvist's classification reflects the observation that the degrees of soft-tissue damage and fracture instability increase with increasing grades of comminution. In *Type 1* there is only a tiny cortical fragment. In *Type 2* the 'butterfly fragment' is larger but there is still at least 50% cortical contact between the main fragments. In *Type 3* the butterfly fragment involves more than 50% of the bone width. *Type 4* is essentially a segmental fracture.

Epidemiology

Essentially a fracture of the young adults; *Diaphyseal fractures in elderly patients should be considered 'pathological'* until proved otherwise. In children <4yrs of age, the possibility of physical abuse must be kept in mind.

C/P

- * **Proximal shaft fractures** - The proximal fragment *flexes, abducts & externally rotates* because of *gluteus medius & iliopsoas*; the distal fragment is frequently *adducted*.
- * **Mid-shaft fractures** - The proximal fragment *abducts less* but *flexion & external rotation* by *iliopsoas* persists.
- * **Lower 1/3 fractures** - The proximal fragment *adducts* & the distal fragment is *flexed* by *gastrocnemius*.

Bleeding from the **perforators of the profunda femoris** may be severe; >1ltr may be lost while within the femur, up to 3L

Ix

X-ray;

- Hip, Femur & Knee
- CXR - Baseline is useful as there is a risk of *PE & ARDS* in those with multiple injuries

Mx

- First-Aid;
 - i) Treat shock
 - ii) Splint fracture - **Thomas splint** - Helps to *control pain, reduce bleeding & make transfer easier*.
- Definitive treatment;
 - a) Indications for **traction**;
 - Fractures in children - *Skin traction*
 - Contraindications to anaesthesia
 - Lack of suitable skill or facilities for internal fixation
 - **Mid-shaft & Lower 1/3 - Traction & Bracing for 10-14wks.**
 - **Children - Skin traction without a splint for 4-6wks**
 - **Older children - Russell's traction**
 - **Adults(& older adolescents) - Skeletal traction** through a pin below the *tibial tubercle* with an **8-10Kg** traction applied over pulleys at the foot of the bed & the limb supported on a *Thomas' splint & a flexion piece* allows movement at the knee. Also, **Perkin's traction**.
 - Once the fracture is 'sticky' (6-8wks), traction can be discontinued & the patient allowed up & partial weight bearing in a *cast or functional bracing* is acceptable for the *lower 1/3* or *plaster spica* for the *Upper 1/2*
- b) **ORIF**;
 - i) **Plating**
 - The combination of *shaft & femoral neck fractures*
 - A shaft fracture with an associated *vascular injury*
 - ii) **K-Nail**
 - Fractures around the *isthmus of the femur*
 - iii) **Interlocking nail**;
 - Fractures near the *middle of the shaft*
 - Fractures prone to *rotational forces*
 - Fractures of bones with a *wide medullary cavity*
- c) Indications for **external fixation**

- Fractures in adolescents
 - Severe open fractures
 - Management of patients with multiple injuries where there is need to reduce operating time
 - Dealing with severe bone loss by the technique of bone transport
- **DVT prophylaxis**

Complications

- Shock - *1-2L of blood can be lost even with a closed fracture*
- Fat embolism & ARDS
- Thromboembolism
- Joint stiffness
- Refracture & implant failure

Prognosis

- In **children**, fracture union occurs within **2-4wks**(depending on the age of the child). Consolidation is usually complete by **6-12wks**.
- In **adults**, the fracture is usually 'sticky' in **6-8wks** & consolidates in **16-24wks**.

e) Supracondylar fractures of the femur

The fracture line is just above the condyles but may extend between them & up to the **distal 9cm** of the femur.

When the lower fragment is intact, it may be markedly *displaced by the pull of the gastrocnemius*, thus risking injury to the **popliteal artery** - Always palpate for the tibial pulses.

Mx

- **Traction** through the proximal tibia; the limb cradled on a;
 - **Thomas' splint with a knee flexion piece** & movements are encouraged
 - **Braun's splint** - To relax the gastrocnemius to prevent displacement of the distal fragment

Indications;

- Undisplaced or incomplete fractures
- Impacted stable fractures in elderly osteoporotic patients
- Spinal cord injury with fracture
- Contaminated open fractures
- **ORIF**;
 - a) **95° Angle plate**
 - b) **Locked intramedullary nail** which is introduced **retrograde** through the intercondylar notch

Complications

- **Vessel injury** - **Popliteal artery** - Posteriorly & **Femoral Artery** anteromedially

Patella

Examination of the Knee

Patient Upright - Varus & valgus deformity is best seen with the patient **standing & bearing weight**. He/she should be observed walking;

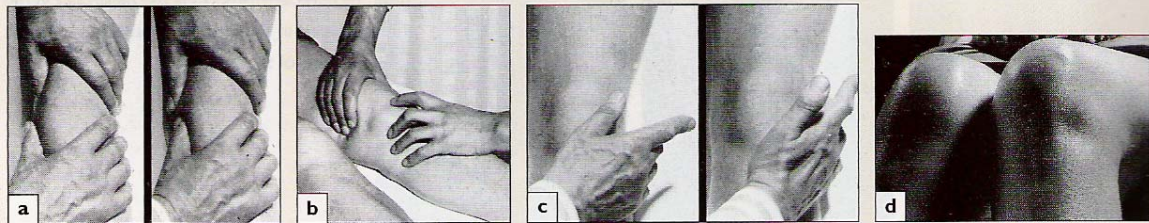
- Stance phase - Note whether the knee extends fully & if there is any lateral instability
- Swing phase - Note whether the knee moves freely or is held rigid (usually because of patellofemoral pain)

Patient Lying Supine

i) Inspection

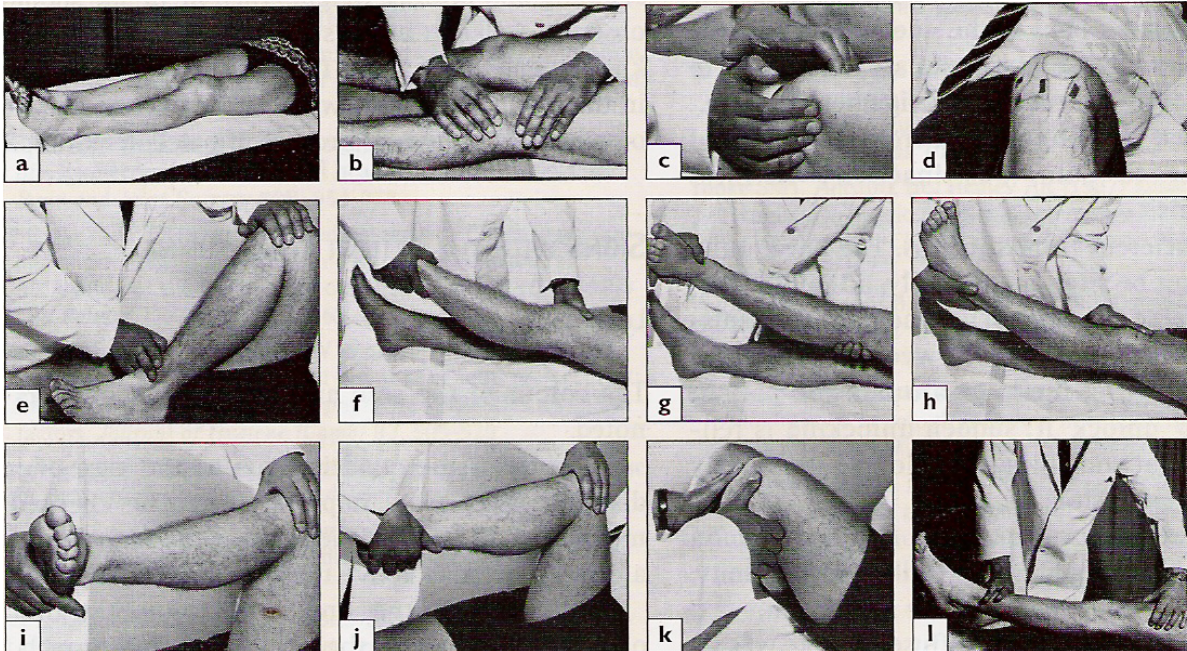
ii) Palpation

- Check for **intra-articular fluid**



- Cross-fluctuation:** The left hand compresses & empties the suprapatellar pouch while the right hand straddles the front of the joint below the patella; by squeezing with each hand alternately, a fluid impulse is transmitted across the joint.
- The patellar tap:** again the supra patellar pouch is compressed with the left hand, while the index finger of the right pushes the patella sharply backwards; with a positive test the patella can be felt striking the femur & bouncing off again.
- The bulge test:** This is useful when very little fluid is present. The medial compartment is emptied by pressing on that side of the joint; the hand is then lifted away & the lateral side is sharply compressed; a distinct ripple is seen on the flattened medial surface
- The patellar hollow test:** when the normal knee is flexed, a hollow appears lateral to the patellar ligament & disappears with further flexion; with excess fluid, the hollow fills & disappears at a lesser angle of flexion

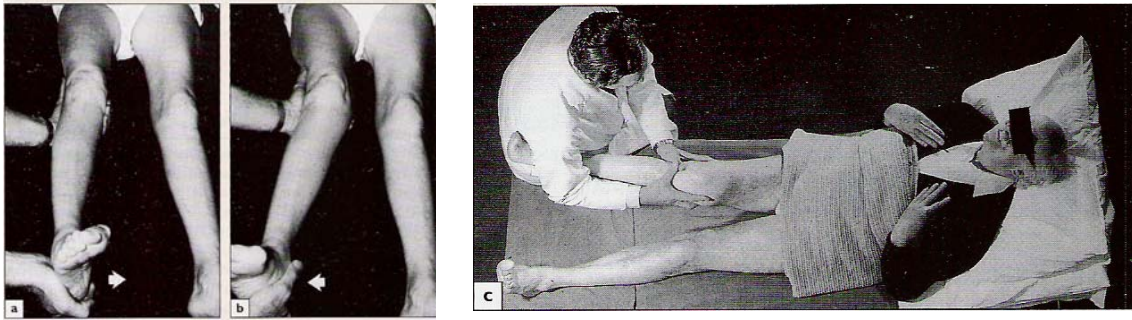
iii) Movement



20.2 Examination – supine (a) Looking at both knees – the left is swollen and the thigh wasted; (b) testing for fluid by cross-fluctuation; (c) feeling for synovial thickening; (d) the points which should be palpated for tenderness. Testing movements: (e) flexion, (f) extension, (g) abduction, (h) adduction. Lateral rotation (i), medial rotation (j) and anteroposterior glide (k) are tested with the knee bent; (l) testing quadriceps power.

iv) Tests for stability

a) The collateral ligaments



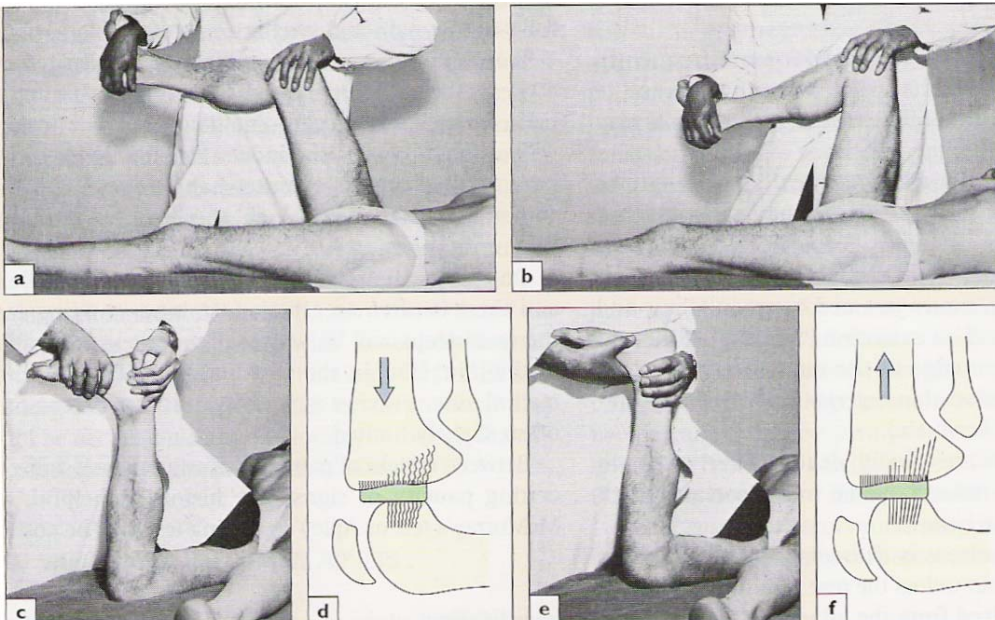
Tests for sideways instability Two ways of testing for collateral ligament laxity. **(a, b)** By stressing, first the laterals, then the medial side of the knee. **(c)** if the surgeon holds the leg between his arm & his chest he can impart valgus & varus stresses &, with his hands, detect any knee laxity with precision. Abnormality may be due to either;

- Torn or stretched ligaments & capsule or
- Loss of articular cartilage or bone, which allows the affected compartment to collapse

b) The Cruciate Ligaments (K)

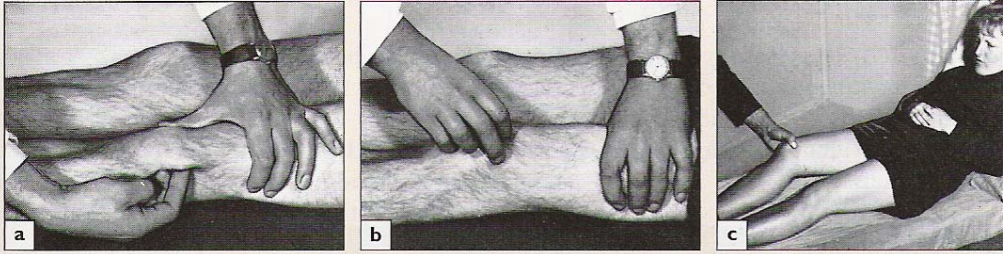
- With the knee in position (see (K)), the upper tibia is inspected from side to side; if its upper end has **dropped back**, or can be **gently pushed back**, this indicates a **tear of the posterior cruciate ligament** (the 'sag sign')
- With the knee in the same position, the foot is anchored by the examiner sitting on it (provided this is not painful); then using both hands, the upper end of the tibia is grasped firmly & **anteroposterior glide** (the 'drawer test'). Excessive **anterior** movement (a positive anterior drawer sign) denotes **anterior cruciate laxity**; excessive **posterior** movements (a positive posterior drawer sign) signifies **posterior cruciate laxity**.
- **Lachman test** - The patient's knee is **flexed 20°**; with one hand grasping the lower thigh & the other the upper part of the leg, the joint surfaces are shifted backwards & forwards upon each other. If the knee is stable, there should be no gliding.

v) **McMurray's test** - This is the classic test for a **torn meniscus**. The knee is flexed as far as possible; one hand steadies the joint & the other *rotates the leg medially & laterally* while the *knee is slowly extended*. The test is repeated several times, with the knee stressed in valgus or varus, feeling & listening for the click.



20.17 Torn medial meniscus – tests **(a, b)** McMurray's test is performed at varying angles of flexion. **(c, d)** The grinding test relaxes the ligaments but compresses the meniscus – it causes pain with meniscus lesions. **(e, f)** The distraction test releases the meniscus but stretches the ligaments and causes pain if these are injured.

vi) Examination of the Patella



20.7 Examination of patella (a) Feeling for tenderness behind the patella; (b) the patellar friction test; (c) the apprehension test.

- a) **Patellar friction test** - Moving the patella up & down while pressing it lightly against the femur causes painful grating if the central portion of the articular cartilage is damaged
- b) **Apprehension test** - Pressing the patellar laterally with the thumb while flexing the knee slightly may induce anxiety & resistance to further movement which is diagnostic of **recurrent patellar subluxation or dissociation**

Bow Legs & Knock Knees in Children

Bilateral **bow legs** can be recorded by measuring the distance **between the knees** with the child standing & the heels touching; it should be **<6cm**.

Similarly, **knock knees** can be estimated by measuring the distance **between the medial malleoli** when the knees are touching with the patellae facing forwards; it is usually **<8cm**

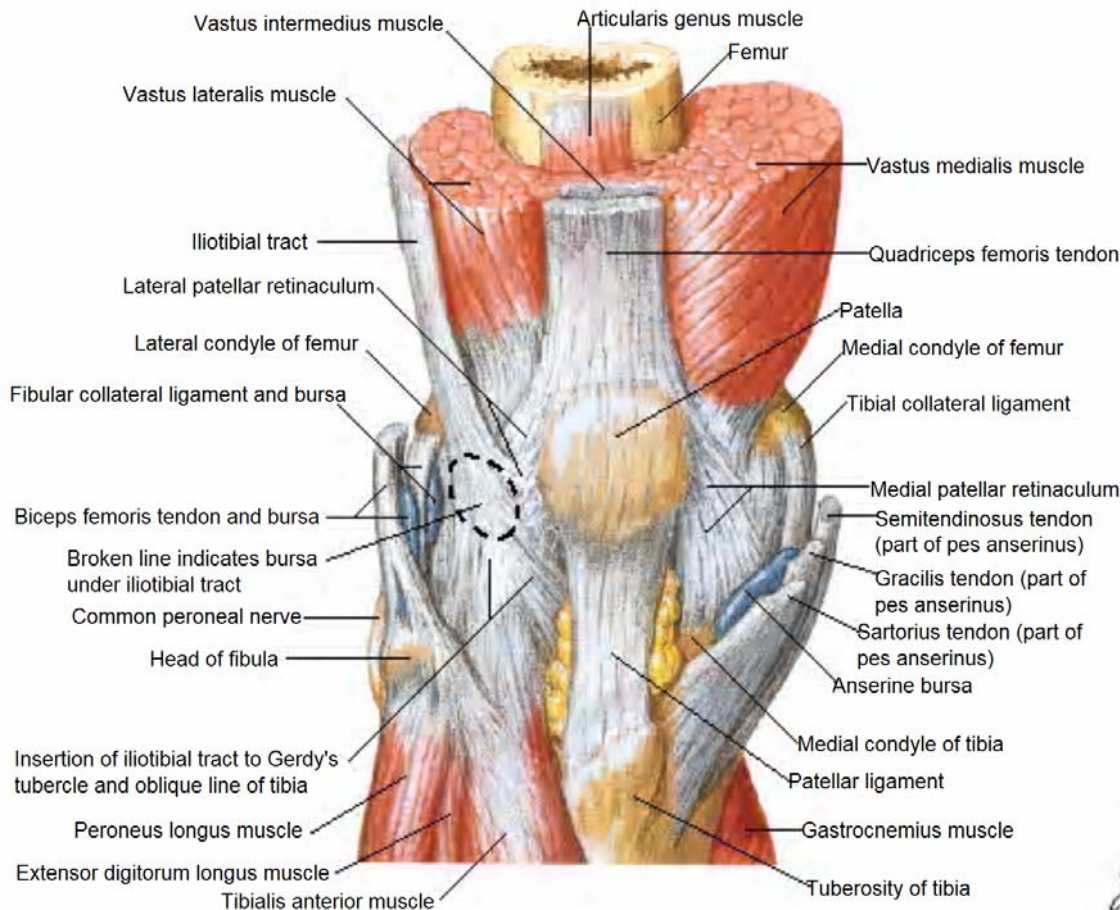
Bow legs & Knock knees in **4yr olds** are common but the occasional case where, by **10yrs**, the deformity is still marked (*i.e. The **intercondylar distance** is **>6cm** or the **intermalleolar distance** **>8cm**) operative correction should be advised.*

- Ix**
- X-ray including Hip when standing taking weight to confirm the **angulation of the neck of femur**

- Mx**
- Surgery (**Osteotomy**) is indicated if;
- The **intercondylar distance** is **>6cm** or the **intermalleolar distance** **>8cm** at **10yrs old**
 - Deformity severely interferes with lifestyle
 - Unilateral angulation

Anatomy

The patella is a **sesamoid bone**.



Mechanism of Injury

- **Direct injury** - Usually a fall onto the knee or a blow against the dashboard of a car - causes either an **undisplaced crack** or else a **comminuted ('stellate') fracture** without severe damage to the extensor expansions.
- **Indirect injury** - Occurs when someone catches his/her foot against a solid obstacle & to avoid falling, contracts the quadriceps muscle forcefully. This is a **transverse fracture with a gap** between the fragments.

C/P

- Knee becomes **painful & swollen**
- The patella is **tender & sometimes a gap can be felt**
- Active knee extension should be tested - If the patient **can lift the straight leg**, the quadriceps mechanism is still **intact**. If this movement is too painful, active extension can be tested with the patient lying on his side.

Classification

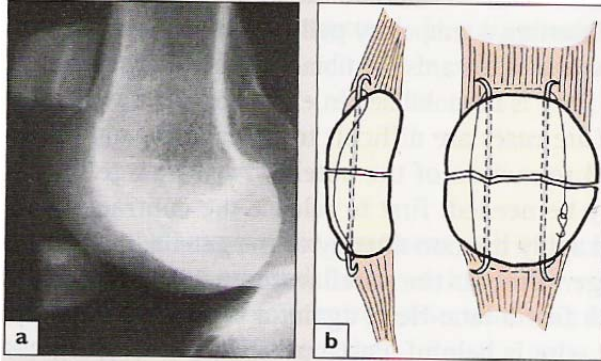
Displaced or Undisplaced

- **Transverse**
- **Longitudinal**
- **Polar**
- **Comminuted (stellate)**

Separation of the fragments is significant if it is sufficient to **create a step on the articular surface of the patella** or, in the case of a **transverse fracture**, if the gap is **>3cm**

Mx

- If there is *haemarthrosis it is aspirated*.
- **Undisplaced or minimally displaced fractures** - The extensor mechanism is intact & Mx is **Conservative** - A **Plaster cylinder** holding the knee straight is worn for **3-4wks**, & during this time quadriceps exercises are practised everyday.
- **Comminuted (stellate) fracture** - Extensor mechanisms are intact however, the undersurface of the patella is irregular & there is a serious risk of damage to the patellofemoral joint - **Patellectomy or Back-slab** is applied *but removed several times daily for exercises to mould the fragments into position & to maintain mobility*.
- **Displaced transverse fractures** - *Lateral expansions are torn & the entire extensor mechanism is disrupted*.



30.14 Fractured patella – transverse The separated fragments (a) are transfixed by Kirschner wires; malleable wire is then looped around the protruding ends of the Kirschner wires and tightened over the front of the patella (b).

A **plaster back-slab** is worn *until active extension of the knee is regained*; the back-slab may be removed everyday to permit active knee-flexion exercises.

Tibia & Fibula

Mx

Gustilo I & II

- a) **Undisplaced or minimally displaced** - A **full-length cast** from upper thigh to metatarsal necks is applied with the *knee slightly flexed (0-5°)* & the *ankle at a right angle*.
- b) **Displaced** - Closed reduction & casting as above
 - The limb is elevated & the patient is kept under observation for **48-72Hrs**. If there is excessive swelling, the cast is split. Patients are usually allowed up (& home) on the *2nd or 3rd day*, bearing minimal weight with the aid of crutches.
 - After **2wks** the position is checked by X-ray.
 - The cast is retained until the fracture unites, which is around **8wks** in **children** but **seldom under 16wks** in **adults**. Worry at **9months**
 - With **stable fractures** e.g. transverse fractures, *the full-length cast may be changed after 4-6wks to a functional below-knee cast/Patella tendon bearing cast or brace* which is carefully moulded to bear upon the upper tibia & patella tendon. This liberates the knee & allows full weight-bearing.

Skeletal fixation;

- **Locked Intramedullary nailing** - Used for *unstable diaphyseal fractures* e.g. *comminuted & segmental fractures* - use a **non-reamed** nail.
- **Plate fixation** - Best for;
 - * *Metaphyseal fractures* that are unsuitable for nailing
 - * Tibial shaft fractures *associated with displaced intra-articular fractures of the knee & ankle*
 - * Unstable low energy fractures in **children**.
- **External fixation** - This is the method of choice for *open fractures* & is an excellent alternative to closed nailing; it avoids exposure of the fracture site & it allows further adjustments to be made if this should be needed.

In cases of bone loss, small defects can be treated by *delayed bone grafting* & larger defects will need either **bone transport** or **compression-distraction with an external fixator**.

Post-op;

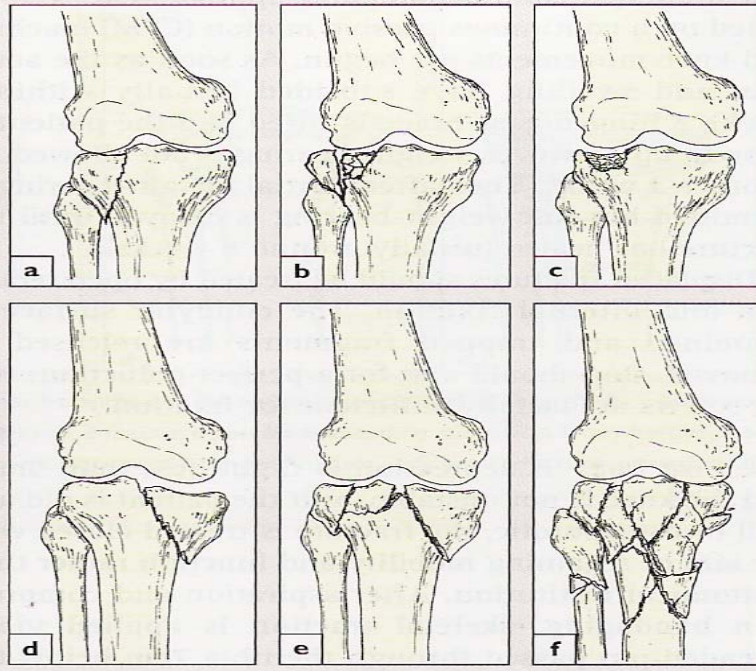
- After nailing of a **transverse or short oblique fracture**, weight bearing can be started within a few days, progressing to full weight when this is comfortable
- If the fracture is **comminuted or segmental**, almost all the load is taken by the nail & therefore only partial weight bearing is permitted until some callus is seen on X-ray.
- With **plate fixation**, additional support with a cast is needed if partial weight-bearing is to start soon after surgery; otherwise weight bearing is delayed for **6wks**

Tibial Plateau Fractures

Mechanism of injury

Fractures of the tibial plateau are caused by **varus or valgus force combined with axial loading** (a pure valgus force is more likely to rupture the ligaments) usually following a car striking a pedestrian (hence the term '*bumper fracture*'); more often it is due to a fall from a height in which the knee is forced into valgus or varus.

Schatzker Classification



- I - Vertical split of the lateral condyle** - It may be virtually undisplaced, or the wedge-shaped condylar fragment may be pushed inferiorly & tilted; the damaged lateral meniscus may be trapped in the crevice. The medial ligament is often **intact**; **Anterior cruciate** may also be injured- *Usually in young adults with dense cancellous bone*
- II - Vertical split of the lateral condyle combined with depression of the adjacent central load-bearing part of the condyle** - The wedge fragment is displaced laterally; the joint is widened &, if the fracture is not reduced, may later develop a valgus deformity - Usually in persons **>40yrs old** with **sparse cancellous bone**
- III - Depression of the lateral articular surface with an intact condylar rim** - **Commonest** type of plateau fracture, occurs in **osteoporotic bone** 2° to low-energy trauma - The joint is usually **stable** - Usually in **old people**
- IV - Fracture of the medial tibial condyle;**
- A -** A **depressed**, crush fracture of osteoporotic bone in an elderly person (a low-energy lesion)
 - B -** A high energy fracture resulting in a **condylar split** which runs obliquely from the inter-condylar eminence to the medial cortex. The momentary varus angulation may be severe enough to cause a **rupture of the lateral collateral or cruciate ligaments** & a **traction injury of the common peroneal nerve or peroneal vessels**
- V - Fracture of both condyles**
- VI - Combined condylar & subcondylar fractures** - High-energy injury. The tibial shaft is effectively disconnected from the tibial condyles. Associated with **compartment syndrome**

C/P

- The **knee is swollen & may be deformed**.
- **Bruising** is usually extensive & the **tissues feel 'doughy' because of haemarthrosis**

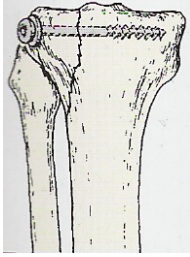
Ix

- X-rays - **AP, Lateral & Oblique**
- CT scan or Tomography - **To show the amount of comminution or plateau depression**

Mx

I - * **Undisplaced - Conservative** - The **haemarthrosis is aspirated & a compression bandage** is applied. As soon as **acute pain & swelling have subsided** (usually in a wk), a **hinged cast-brace** is fitted & the patient is allowed up; however weight bearing is not allowed for another **3wks** & healing is in **8wks**.

* **Displaced - ORIF with 1 or 2 lag screws**



II - a) **Conservative** - The **haemarthrosis is aspirated & a compression bandage is applied**. **Skeletal traction** is applied via a **threaded pin (Deinmann pin)** passed through the tibia **7cm below the fracture**. An attempt is made to squeeze the condyle into shape; the knee is then flexed & extended several times to 'mould' the upper tibia on the opposing femoral condyle. The leg is **cradled on pillows & with 5Kg traction in place**, active exercises are carried out every day. As soon as the fracture is 'sticky' (usually at **3-4wks**), the traction pin is removed, a **hinged cast-brace** is applied & the patient allowed up on crutches. Full weight bearing is deferred for another **6wks**.

Indications;

- * Patient is old & frail or osteoporotic
- * Slight depression (<5mm) + Stable knee

b) **Open reduction with elevation of the plateau & internal fixation with a Butress plate & screws**

Indications;

- Central depression >5mm
- Younger patients

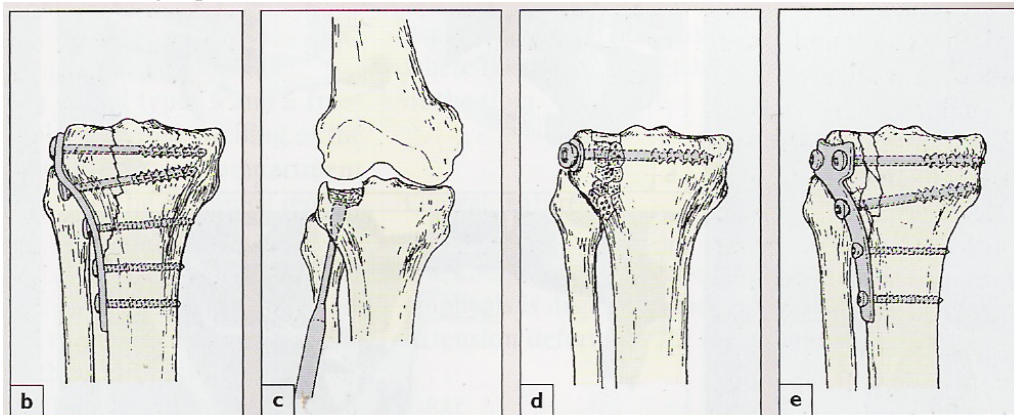


plate and screws is more secure. (c) Depression of more than 5mm in a type 2 fracture can be treated by elevation from below and (d) supported by bone grafts and fixation. (e) Type 3 fractures require a combination of both techniques – direct reduction, elevation of depressed areas, bone grafting and buttress plate fixation.

III - See IIb

IV - a) See IIb - The patient is likely to be left with some degree of varus deformity

b) * **Undisplaced** - See undisplaced Type I fractures

* **Displaced** - ORIF + Fix lateral ligament

V - Carry an added risk of a compartment syndrome. See IIa

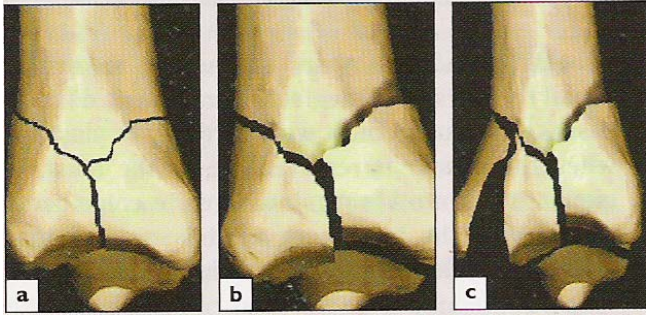
VI - Carry an added risk of a compartment syndrome - **ORIF with screw fixation with a ring external fixator**.

Pilon Fractures

Mechanism of Injury

This injury to the ankle joint occurs when a large force drives the talus upwards against the tibial plafond. There is considerable damage to the articular cartilage & the subchondral bone may be broken into several pieces.

Classification - Ruedi & Allgöner



31.11 Pilon fractures – imaging These are either (a) undisplaced (type 1), (b) minimally displaced (type 2) or (c) markedly displaced (type 3).

Mx

Conservative Mx;

- **Control soft-tissue swelling is a priority**; this is best achieved either by;
 - a) Elevation & calcaneal traction or
 - b) Applying an external fixator across the ankle joint

This may take **2-3wks** by which time surgery may be considered

Surgical Mx;

- **Type 1** fractures may be managed with **ORIF with plates & screws**
- High energy pilon fractures - **Type 2 & 3** carry a risk of wound breakdown & infection if treated by wide open reduction & plating. **Indirect reduction** techniques (**ligamentotaxis & percutaneous manipulation of fragments**) with minimal **internal fixation with small screws** to hold the fragments together are better tolerated. Bone grafts are often added to the defects in the metaphysis & a **circular external fixation & tensioned wires** is then applied to stabilize the tibial plafond on the shaft. Reduction is maintained until union occurs usually **6wks** & partial weight-bearing is permitted.

Pilon fractures usually take **12-16wks** to heal.

Ankle

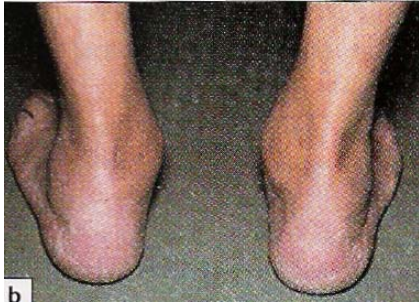
Examination of the Ankle

Patient Upright

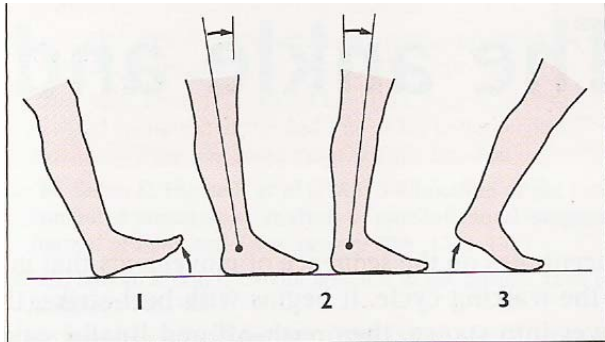
i) Inspection

The patient, whose lower limbs should be exposed from the knees down, stands first facing the examiner, then with his or her back to the surgeon.

- Ask the patient to rise up on tiptoes & then settle back on the heels; note the posture of the feet throughout this movement.
- Normally the heels are in **slightly valgus** while **standing & inverted on tiptoes**; the degree of inversion should be equal on the two sides, showing that the **subtalar joint** is mobile & the **tibialis posterior** functioning.
- Viewed from behind, if there is **excessive eversion** of one foot, the lateral toes are more easily visible on that side (**the 'too-many-toes' sign**) due to rupture of the **tibialis posterior tendon**.



ii) Gait



21.2 Gait – the three rockers of ankle-stance phase The first rocker begins with heel strike – if the anterior compartment muscles are weak, a 'foot slap' is noticeable; or if the ankle is in fixed equinus, this rocker may be absent altogether. In mid-stance, the centre of gravity of the body (and ground reaction force) moves from a position posterior to the ankle joint to anterior (second rocker). The third rocker produces an acceleration force which shifts the fulcrum of the pivot forwards to the metatarsal heads, just prior to toe-off (Gage, 1991).

Patient Sitting or Lying

- Inspection** - Thickening & keratosis may be seen over the proximal toe joints (**corns**); or on the soles (**callosities**)
- Palpation** - Feel for the *dorsalis pedis* (absent in **1:6** normal people), *popliteal* & *femoral* pulses
- Movement**
 - Ankle joint** - With the heel grasped in the hand & the midfoot in the right, the ranges of **plantarflexion & dorsiflexion** are estimated
 - Subtalar joint** - It is important to **'lock' the ankle joint** when assessing the **subtalar inversion & eversion**. This is done by ensuring the ankle is **10° plantigrade**, when the heel is moved
- Stability**;
 - Medial & Lateral stability - Checked by stressing the ankle in valgus then varus
 - Anteroposterior stability - Assessed by performing an **anterior 'drawer test'**
- Muscle Bulk, Tone & Power**

vi) Shoes

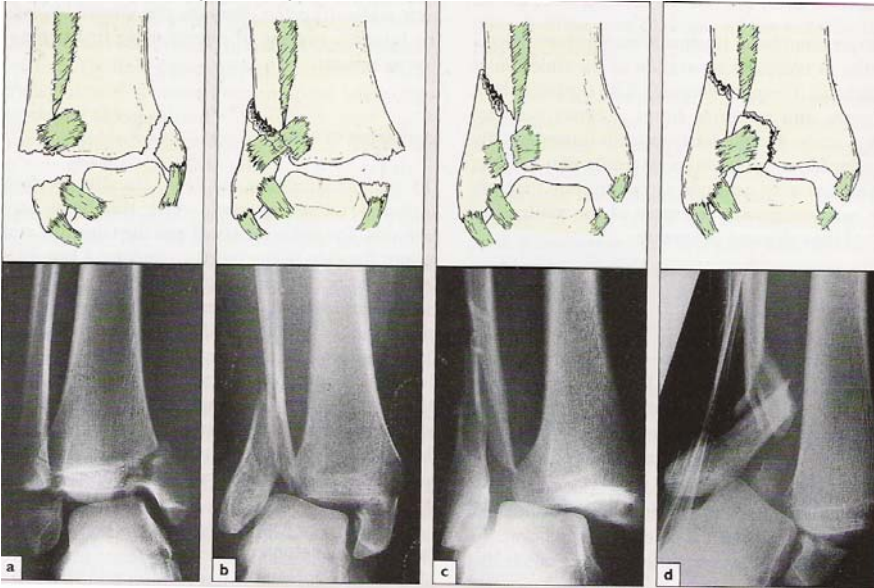
Mechanism of injury

Usually the foot is anchored to the ground while the body lunges forwards. The ankle is twisted & the talus tilts &/or rotates forcibly in the mortise, causing a low-energy fracture of one or both malleoli, with or without associated injuries of the ligaments.

If a malleolus is **pushed off**, it usually fractures **obliquely**; if it's **pulled off**, it fractures **transversely**

Danis & Weber Classification of Ankle Fractures

Based on the level of the **fibular fractures**.

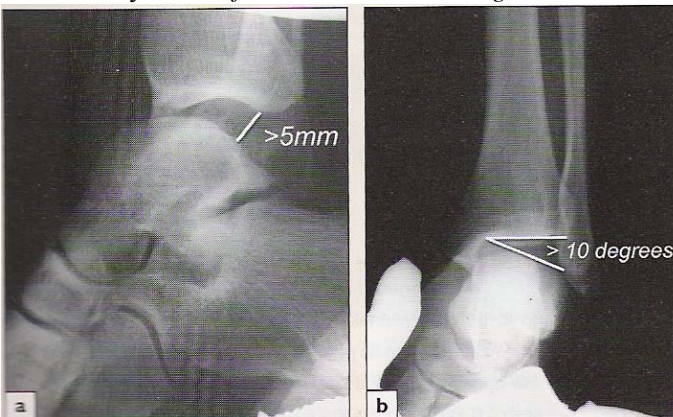


- A -** is a **transverse fracture of the fibula below the tibiofibular syndesmosis**, perhaps associated with an oblique or vertical fracture of the medial malleolus; this is almost certainly an **adduction (or adduction & internal rotation)** injury.
- B -** is **spiral/oblique fracture of the fibula in the sagittal plane** (& therefore better seen in the **lateral X-ray**) **at the level of the syndesmosis**, often associated with disruption of the anterior fibres of the tibiofibular ligament & fracture of the **posterior malleolus** (Posterior lip of the tibia) &/or an **avulsion injury on the medial side** (a torn deltoid ligament or an **oblique fracture of the medial malleolus** - caused by **forced abduction & external rotation**)
- C -** is **above the level of the syndesmosis** - which means that the tibiofibular ligament & part of the interosseus membrane must have been torn. This is due to severe **abduction or a combination of abduction & external rotation**. Associated injuries are an **avulsion fracture of the medial malleolus** (or rupture of the medial collateral ligament), a **posterior malleolar fracture & diastasis of the tibiofibular joint**.
- D -** Type C + the ligament **avulses a small piece of the tibia on the lateral side**

Ix

X-ray - All are done;

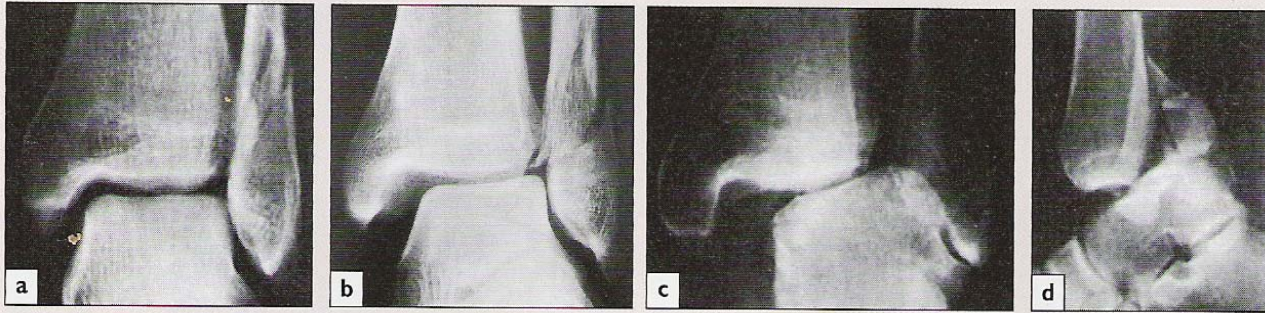
- AP
- Lateral - *Best for level of Fibular fracture*
- Stress X-rays - *Best for diastasis* - **>10° angle diastasis laterally means the lateral complex is torn.**



21.4 X-rays – stress views The ankle is held in approximately 10° of plantarflexion when carrying out the anterior drawer or talar tilt test. Comparisons are made with the normal side. (a) The anterior drawer tests the integrity of the anterior talofibular ligament; a difference of more than 5mm between the two sides signifies rupture of the ligament. (b) Inversion stress tests the integrity of both the anterior talofibular and calcaneofibular ligaments; a difference of greater than 10° of talar tilt between the two sides suggests ligament rupture (Mardner, 1994; Colville, 1994).

Mx

Best managed in the acute stage i.e. within **2wks** or possibility of difficult surgery & deformity



31.7 Ankle fractures – stable or unstable? (a) *Stable fracture*: in this Danis–Weber Type B fracture the tibiofibular syndesmosis has held; the surfaces of the tibia and talus are precisely parallel and the width of the joint space is regular both superiorly and medially. (b) *Slight subluxation*: the syndesmosis is intact but the talus has moved laterally with the distal fibular fragment; the medial joint space is too wide, signifying a deltoid ligament rupture. It is vital, after reduction of the fibular fracture, to check that the medial joint space is normal; if it isn't, the ligament has probably been trapped in the joint and it must be freed so as to allow perfect re-positioning of the talus. (c) *Fracture-dislocation*: in this high fibular fracture the syndesmosis has given way, the medial collateral ligament has been torn and the talus is displaced and tilted. The fibula must be fixed to full length and the tibiofibular joint secured before the ankle can be stabilized. (d) *Posterior fracture-dislocation*: if the posterior margin of the tibia is fractured, the talus may be displaced upwards. The fragment must be replaced and fixed securely.

Principles of reduction;

- The **fibular** must be restored to its full length
- The talus must sit squarely in the mortise, with the talar & tibial articular surfaces **parallel**
- The **medial joint** space must be restored to its normal width, & i.e. The same width as the tibiotalar space (*about 4mm*)
- Oblique x-rays must show there is **no** tibiofibular diastasis

Undisplaced fractures;

- **Type A** - Stable fracture - A ***firm bandage or plaster slab*** is applied mainly for comfort until the fracture heals.
- **Type B** fractures are potentially unstable only if the tibiofibular ligament is torn or avulsed; or if there is significant medial-sided injury.
 - * If syndesmosis or mortise is intact - A ***below-knee cast*** is applied with the ankle in the ***neutral (anatomical) position***
- **Type C,D** - ***ORIF***

Displaced Fractures;

- **Type A** - ***ORIF*** of the **medial malleolar** fragment with **one or two screws** directed almost parallel to the ankle joint. The **lateral malleolar** fracture, unless it is already perfectly reduced & stable, should be fixed with a **plate & screws or tension-band wiring**. Post-op a 'walking cast' is applied for **6wks**.
- **Type B** - **Closed reduction with traction** (to disimpact the fracture) & then internal rotation of the foot. If closed reduction succeeds, a **cast** is applied, following the same routine as for undisplaced fractures. Failure of closed reduction (sometimes a torn medial ligament is caught between the talus & medial malleolus) **or** late displacement calls for **internal fixation**.
- **Type C** - Unstable - ***ORIF*** - Reduce the **fibula** restoring its length & alignment; the fracture is then stabilised using a **plate & screws**. If there is a **medial fracture**, this is also **fixed**. If the **syndesmosis is torn**, it is stabilised by inserting a **transverse syndesmotic screw** across from the fibula into the tibia (the ankle should be held in **10° dorsiflexion** when the screw is inserted)

Delayed treatment - Fracture-subluxations **>1wk** old may prove difficult to reduce because of clot organization in the syndesmosis. Granulation tissue should be removed from the syndesmosis & transverse tibiofibular fixation secured.

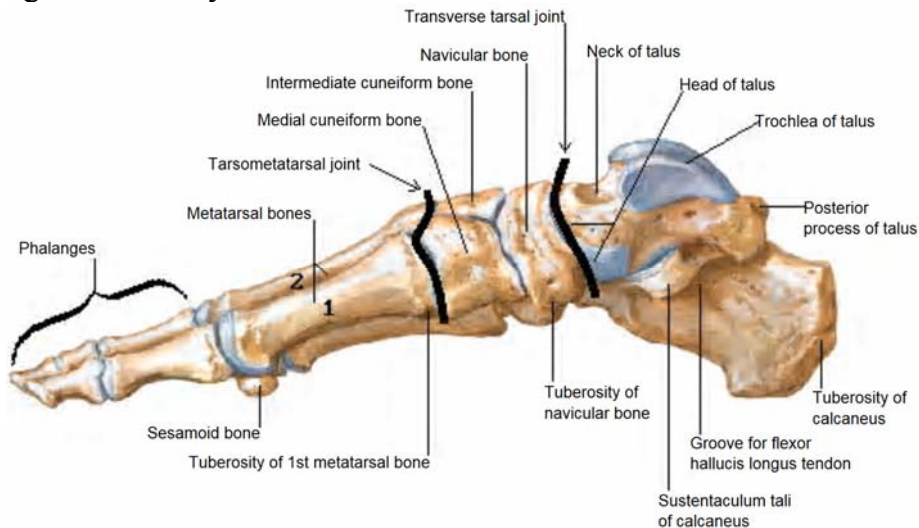
Post-op;

- In the first **2wks** after the operation, the ankle is left free to allow mobilising exercises; at the same time elevation is encouraged to reduce swelling. Thereafter it may be advisable to protect the ankle in a **below-knee plaster** for **6-12wks**
- The patient is then allowed partial weight-bearing with crutches; the cast is retained until the fractures have consolidated
- The **transverse tibiofibular screw** is removed after **3months**.

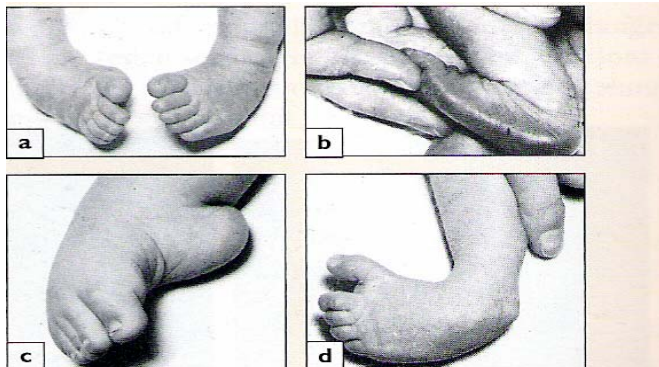
Congenital Talipes Equinovarus

Incidence - When one child is affected, there is a **2-6%** chance that the subsequent offspring will be affected. If the parent also has clubfoot, there is a **25%** chance that the other children will also have clubfoot.

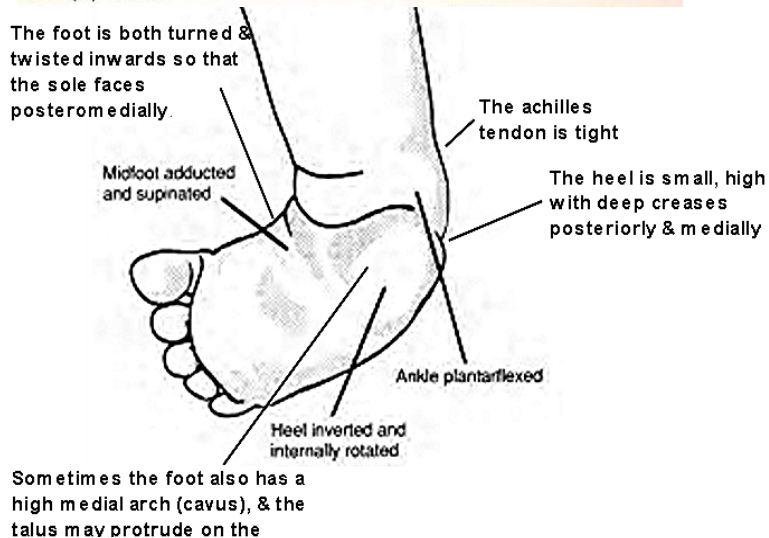
Pathological Anatomy - Medial View



- The **head & neck** of the **talus** points **downwards & deviates medially**. The body is rotated slightly outwards in relation to both the calcaneum & the ankle mortise
- The **posterior** part of the **calcaneum** is held close to the fibula by a **tight calcaneo-fibular ligament**, & is tilted into **equinus & varus**
- The **navicular** & the **entire forefoot** are **shifted medially & rotated** into **supination** (*the composite varus deformity*)



21.5 Talipes equinovarus (club foot) (a) True club foot is a fixed deformity, unlike (b) 'postural' talipes, which is easily correctable by gentle passive movement. (c) With true club foot the poorly developed heel is higher than the forefoot, which is also (d) varus.



/ internally rotated

Sometimes the foot also has a high medial arch (cavus), & the talus may protrude on the dorsolateral surface of the foot.

Ix

X-Rays are **not** necessary in the diagnosis of clubfoot.

	Normal	CTEV
Talo Calcaneal angle		
AP view A	30°-50°	<30°
Lateral View	25°-50°	<25°
Talo 1 st Metatarsal angle		
AP view B	5°-15°	Negative

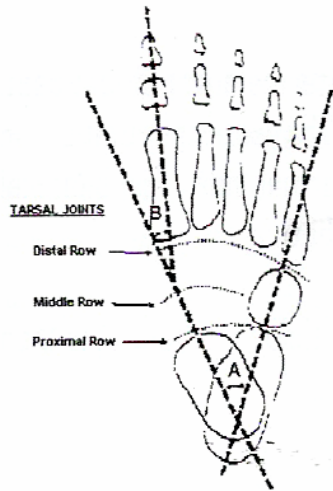


Fig 1a

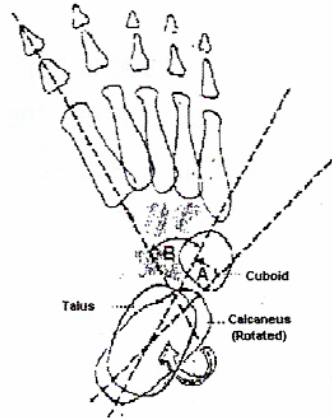


Fig1b

Fig 1 Talocalcaneal angle and Talo 1st Metatarsal angle AP View

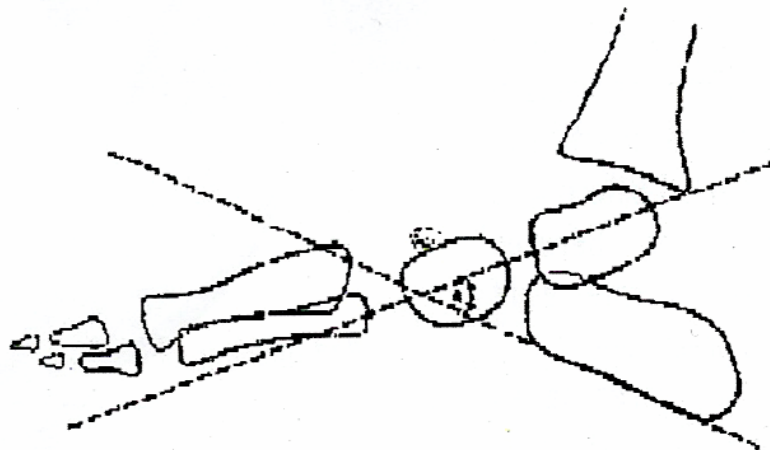


Fig2 Talocalcaneal angle Lateral View

Mx

a) **Ponseti Serial Casting Method;**

The correction should begin as soon as possible about **7-10days after birth** (*most effective when started before 9months of age but can still be used up to 28months*)

Position is held by applying a *light plaster cast* (over a protective layer of strapping) *which is soaked off & changed every week.*

- i) *The forefoot must be brought into rotational alignment with the hind foot by **increasing** the rotational deformity of the forefoot so that it corresponds with the relatively more supinated hind foot. The first metatarsal is reduced to correct the cavus deformity*
- ii) *Next, both hind foot & forefoot are together gradually brought out of the varus & supination; correction is assisted by keeping the fulcrum on the lateral side of the head of the talus*
- iii) *Finally equinus is corrected by bringing the heel down & dorsiflexing the ankle; It does not fully correct & one may need to perform an Achilles tenotomy - A cast is applied with the foot abducted at **60-70°** for **3wks.***

Bracing - The brace is applied after removal of the last cast **day & night** for the first **3months & night only** for **2-3yrs**;

- Unilateral clubfoot - 75° external rotation on the clubfoot side & 45° rotation on the normal side.
- Bilateral clubfoot - 75° external rotation on both sides

b) **Sx** - Indicated in patients ≥ 2 yrs

Infections

Acute Haematogenous Osteomyelitis

Invariably a **disease of children**.

Predisposing factors in adults;

- Diabetes
- Immunosuppression - *acquired or induced*
- Trauma - *may cause a small haematoma or fluid collection in bone*
- Sickle cell disease

Causal Organisms

- **Staph. Aureus - most common**
- Strep. Pyogenes & Strep. Pneumoniae
- **Children <4yrs - H. influenza**
- **In Sickle Cell Disease - Salmonella**

Pathogenesis

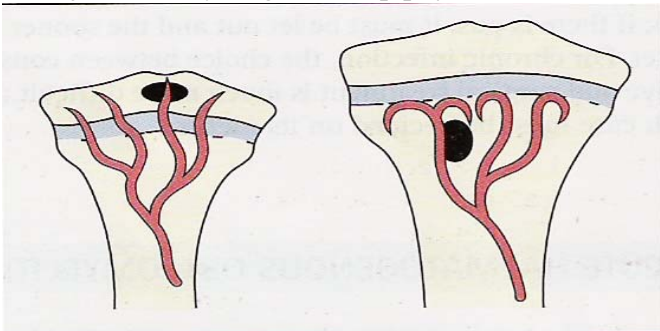
The blood stream is invaded, perhaps from *a minor skin abrasion, & boil, a septic tooth or - in the newborn - from an infected umbilical cord*. In adults, the source of infection may be a *urethral catheter, an indwelling arterial line or a dirty needle & syringe*.

Organisms **in children** usually settle in the **metaphysis**, most often;

- * In the **proximal tibia**
- * The **distal & proximal ends of the femur**

The predilection for the metaphysis has been attributed to the peculiar arrangement of the blood vessels in that area: the **non-anastomosing terminal branches of the nutrient artery twist back in hair-pin loops** before entering the large network of sinusoidal veins; the relative **vascular stasis** favours bacterial colonization.

In **young infants**, in whom there is still a **free anastomosis between metaphyseal & epiphyseal blood vessels**, infection can just as easily lodge in the **epiphysis**.



2.1 Acute osteomyelitis (I) In babies infection may settle near the very end of the bone; joint infection and growth disturbance easily follow. In children, metaphyseal infection is usual; the growth disc acts as a barrier to spread.

In **adults**, haematogenous infection is **more common** in the **thoracolumbar vertebral bodies** than in the long bones

Pathological Characteristics

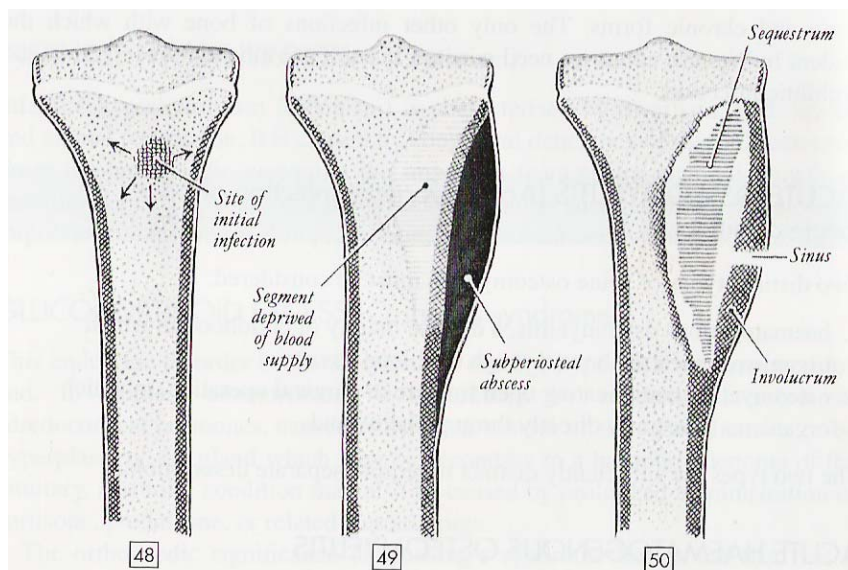
- a) **Inflammation** - The earliest change is an acute inflammatory reaction with **vascular congestion, exudation of fluid & infiltration by polymorphonuclear leucocytes**. The **interosseous pressure rises** rapidly, causing **intense pain, obstruction to blood flow & intravascular thrombosis**. Even at an early stage the tissues are threatened by impending ischemia.
- b) **Suppuration** - By **2nd-3rd day**, pus forms within the bone & forces its way along the **Volkman canals** to the surface where it produces a **subperiosteal abscess**. From there the pus spreads along the shaft, to **re-enter the bone** at another level or **burst into the surrounding tissues**.
- * In **infants**, infection often extends through the growth plate to the epiphysis & thence into the joint.
 - * In **older children** the growth plate acts as a barrier to direct spread but where the metaphysis is partly intracapsular (e.g. at the **hip, shoulder or elbow**), pus may discharge through the periosteum into the joint or even when the joint is not infected, it may swell from an effusion of clear fluid (**Sympathetic effusion**)
 - * In **adults**, the abscess is more likely to spread within the medullary cavity. Vertebral infection may spread through the end-plate & the intervertebral disc into the adjacent vertebral body.
- c) **Necrosis** - By the **end of the week**, there is microscopic evidence of bone death - **Sequestrum** due to **bacterial enzymes, leukocytic enzymes & increasing compromise of the blood supply** due to;
- Rising intraosseous pressure
 - Vascular stasis
 - Septic thrombosis
 - Periosteal stripping

In infants, the growth disc is often irreparably damaged & the *epiphysis may undergo avascular necrosis*.

There is gradual ingrowth of **granulation tissue** separating **sequestra**, from living bone & **macrophages & lymphocytes** slowly remove the debris by a combination of **phagocytosis & osteoclastic resorption**.

- d) **New bone formation** - New bone - **Involucrum**, forms in the deep layers of the stripped periosteum & is usually obvious by the **end of the 2nd week** & it grows to enclose the infected tissue & sequestra.

If the infection persists, pus & tiny sequestrated spicules of bone may continue to discharge through perforations in the involucrum (**cloacae**) & track by sinuses to the skin surfaces - the condition is now established as **chronic osteomyelitis**



Figs 48-50 The natural evolution of a focus of osteomyelitis. Figure 48: Initial lesion in the metaphysis. Figure 49: Pus has escaped to the surface of the bone and formed a subperiosteal abscess. Part of the bone has lost its blood supply from septic thrombosis of vessels. Figure 50: The devitalised area eventually separates as a sequestrum. Meanwhile new bone (involucrum) is formed beneath the stripped-up periosteum; it is perforated by sinuses through which pus escapes. This is the stage of chronic osteomyelitis. With prompt treatment the disease can often be arrested at the stage shown in Figure 48.

- e) **Resolution** - If infection is controlled & intraosseous pressure released at an early stage, the bone around the zone of infection is first osteoporotic (probably due to hyperaemia). With healing, there is **fibrosis & appositional new bone formation**; this together with **periosteal reaction**, results in **sclerosis & thickening of the bone**.

C/P (* may be attenuated if antibiotics have been administered)

- Recent history of infection - a septic toe, a boil, a sore throat or a discharge from the ear
- Pain
- Fever
- Raised pulse
- Acute tenderness near one of the larger joints (e.g. above or below the knee, in the popliteal fossa or in the groin)
- Joint movement is restricted
- Lymphadenopathy
- Local redness, swelling, warmth & oedema are *later signs* & signify that pus has escaped from the interior of the bone.

DDx

- Acute suppurative arthritis
- Acute rheumatism
- **Cellulitis** - diffuse & especially **subcutaneous** inflammation of **connective tissue** characterised by widespread **superficial redness & lymphangitis**
- Streptococcal necrotizing myositis
- Sickle-cell crisis
- Gaucher's disease

Ix

- Definitive diagnosis is made by **Needle aspiration or bone biopsy for bacterial culture** (which is the "gold standard")
- FHG - ↑WBC, ESR, CRP
- Blood m/c/s - **+ve in only 50%**
- In SCD **salmonella** may be cultured from the **faeces**
- **X-rays;**
 - * **Normal** during the first **10days**
 - * By the **end of the 2nd week** there may be a **faint extra-cortical outline** due to periosteal new bone formation - *this is the classical x-ray sign of pyogenic osteomyelitis*
 - * Later, the periosteal thickening becomes more obvious & there is **patchy rarefaction** (increase in porosity) of the metaphysis
 - * An important **late sign** is the combination of **regional osteoporosis** - a feature of metabolically active, & thus living bone; with a localized segment of apparently **increased density** - metabolically inactive & possibly dead.
- **Ultrasound** - May detect subperiosteal collection of fluid in the early stages (? Haematoma or pus)
- **Radioscintigraphy** - Reveals increased activity in both the perfusion & bone phases.
- **MRI** - can help differentiate *soft tissue infection & osteomyelitis*

Mx

- Supportive treatment for **pain & dehydration**
- **Splintage** of the affected part - for *pain relief & to prevent joint contractures*. Simple **skin traction** may suffice &, if the **hip** is involved, this also helps to *prevent dislocation*. Also, *plaster slab or half-cylinder*
- **Antibiotic therapy;**
 - * **Older children & previously fit adults** (Staph. Aureus) - **IV flucloxacillin & Fusidic acid** continuously until the condition begins to improve & CRP return to normal levels - usually after **1-2wks**. Thereafter, antibiotics are given **orally** for another **3-6wks**
 - * **Children <4yrs** (H. Influenza) - **Cefuroxime or Cefotaxime or Augmentin**
 - * **SCD - Chloramphenicol or Septrin or Augmentin**
- **Surgical drainage;** Indications;
 - * If the clinical features do not improve within **36hrs** of starting treatment
 - * Signs of deep pus (*Local redness, swelling, warmth, oedema & fluctuation*)
 - * If pus is aspirated

If pus is found - & released - there is little to be gained by drilling into the medullary cavity

If there is no obvious abscess, it is reasonable to *drill a few holes into the bone in various directions* or if there is an extensive intramedullary abscess, drainage can be better achieved by *cutting a small window in the cortex*.

The wound is closed **without a drain** & the *splint (or traction)* reapplied.

Post-op - Once the signs of infection subside, **physiotherapy** is instituted & full weight bearing is possible after **3-4wks**

Complications

- Chronic abscess with discharging sinus.

- Suppurative arthritis
 - * In **very young children**, in whom the growth disc is **not** an impenetrable barrier
 - * Where the metaphysis is intracapsular e.g. **upper femur, shoulder & elbow**
 - * From **metastatic infection**
- Pathological Fractures
- Chronic ulcers - *Non-healing with exposed bone*
- Tumours - *Osteosarcoma*, skin tumours from chronically discharging sinuses (*SCC*)
- Overgrowth of the limb due to hyperaemic stimulation
- Deformity or shortening due to growth plate damage
- Venous metastasis of infection to other areas - *Brain abscess, Empyema, Infections*
- Liver problems due to persistent infections (*Cirrhosis*)
- Postoperative infection

Prognosis

The prognosis is usually good even without surgery. **Cure takes about 6-8 weeks.**

Chronic Osteomyelitis

Risk factors - *conditions which predispose to bone infarcts*

- Open fractures
- Local trauma
- Presence of prosthetic orthopaedic implant
- Vascular insufficiency
- Neuropathy
- Sickle cell disease
- Diabetes mellitus
- IV drug use
- Haemodialysis

The Cierny & Mader Classification of Chronic Osteomyelitis

a) Anatomic Classification

Stage 1 – medullary

- Cancellous bone only involved
- Remove involved bone
- Pack with antibiotic-loaded implant
- Graft at 6–8 weeks
- No stabilisation required

Stage 2 – superficial

- Cortical bone only involved
- Excise involved cortex
- Provide soft-tissue cover
- Stabilise if more than one-third of cortex involved

Stage 3 – localised

- Cortical and cancellous bone involved
- Radical excision
- Staged reconstruction using graft
- Stabilisation often needed

Stage 4 – diffuse

- Most of bone and soft tissues involved in a segment
- Radical excision required, leaves segmental defect
- Stabilisation with external fixator required

b) Physiological Classification of the Host

- A - Normal
- B - Systemic compromised *e.g. Diabetes*
- C - Treatment worse than the disease

* Usually described as a combination of the **anatomic & physiological** status of the patient

C/P

- Chronic abscess with discharging sinus; Changes in **Scar - Hyperpigmentation, Adherent to the underlying tissues**
- Chronic ulcers - *Non-healing with exposed bone*
- **Brodie's abscess** - This is a special form of chronic osteomyelitis which arises **insidiously**, without a preceding acute attack. There is a *localised abscess within bone, often near the site of the metaphysis*.
 - S/S** - A deep 'boring' pain is the predominant symptom.
 - Ix** - X-Ray shows a *circular or oval cavity surrounded by a zone of sclerosis*.
 - Rx** - Surgery - The cavity is de-roofed & the pus evacuated & if possible the cavity filled with a muscle flap to obliterate the dead space.

Ix

X-ray - Bone resorption - *Patchy loss of density or frank excavation around an implant - with thickening & sclerosis of the surrounding bone (DDx - SCD)*

- * Codman's triangle (**DDx - Osteosarcoma**)

Mx

- **Antibiotic therapy** - *Fusidic acid, Clindamycin & cephalosporins*;
 - * To stop the spread of infection to healthy bone
 - * To control acute flares
- **Local treatment** - A sinus may be painless & need dressing simply to protect the clothing. Colostomy paste can be used to stop excoriation of the skin. An acute abscess may need urgent incision & drainage as a temporary measure.
- **Surgical operation**;
 - * The periosteum is incised to release any subperiosteal abscess. If none is found, the bone should be drilled to decompress the marrow & drain any intraosseous abscess
 - * Removal of dead bone - **Sequestrectomy** & *non-viable necrotic tissues* (Not bleeding or moving on touch) - are of utmost importance to effect cure. Pack the medullary cavity with local antibiotics e.g. *Gentamicin beads*.
 - * In patients with *vascular insufficiency or severe gangrenous infection*, **amputation** may be the only effective treatment
 - * If a large part is involved, *wait for the involucrum to become strong & bigger than the sequestrum (3-6months)* then remove sequestrum otherwise you end up with septic non-union.

Other Sx Methods

- Sequestrectomy & fix external clamp & from **5th day** apply traction to bring both callus together - moves at **½mm/d**
- Put a vascularized graft from the fibular
- Fake bone
- **Rehabilitation**

Septic Arthritis

Mechanisms of infection

- Direct invasion through a *penetrating wound, intra-articular injection or arthroscopy*
- Direct spread from an *adjacent bone abscess*
- Blood spread from a *distant site*

Causal organisms

- Staph. Aureus - **Most common**
- **Infants** - Haemophilus influenza
- **Neisseria gonorrhoea** - **commonest cause of septic arthritis in adults**
- Others - Streptococcus, E.Coli, Proteus

Predisposing Conditions

- Rheumatoid arthritis
- IV drug abuse
- Immunosuppression - *Chronic debilitating disorders; Immunosuppressive drug therapy; AIDS*

Pathology

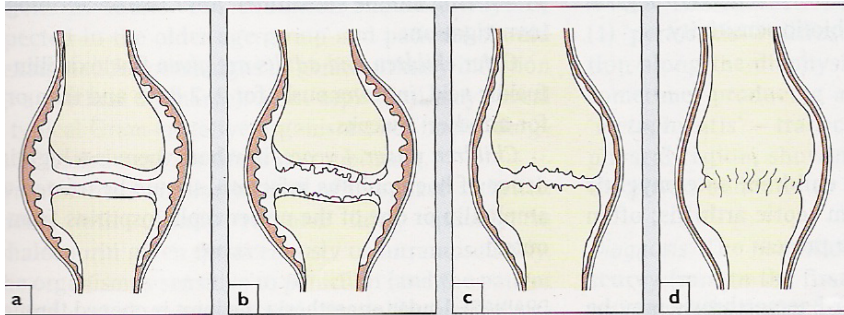
The usual trigger is a **haematogenous infection** which settles in the **synovial membrane**; there is an acute inflammatory reaction - **acute synovitis**, with a **serous or seropurulent exudate** & an **increase in synovial fluid**. As pus appears in the joint, **articular cartilage is eroded** & destroyed partly by **enzymes released from synovium, inflammatory cells & pus**.

In **infants**, the entire epiphysis, which is still largely cartilaginous, may be severely damaged; in **older children**, **vascular occlusion** may lead to **necrosis of the epiphyseal bone**. In **adults**, the effects are **usually confined to the articular cartilage**, but in the late cases, there may be extensive erosion due to **synovial proliferation & growth**.

If the infection goes **untreated**, it will **spread to the underlying bone** or **burst out of the joint to form abscesses & sinuses**.

With healing there may be;

- Complete resolution & a return to normal
- Partial loss of articular cartilage & fibrosis of the joint
- Loss of articular cartilage & bony ankylosis
- Bone destruction & permanent deformity of the joint



2.9 Acute suppurative arthritis

In the early stage (a) there is an acute synovitis with a purulent joint effusion. (b) Soon the articular cartilage is attacked by bacterial and cellular enzymes. If the infection is not arrested, the cartilage may be completely destroyed (c); healing then leads to bony ankylosis (d).

C/P

- * **Children** - Usually a large joint, commonly the **Hip**
- * **Adults** - Superficial joints - **Knee, Wrist or Ankle**
- * Acute pain
- * Swinging fever
- * Rapid pulse
- * The overlying skin looks red
- * Local warmth & marked tenderness
- * Reluctance to move the limb ('*pseudoparesis*') - *All movements are restricted, & often completely abolished, by pain & spasm*

DDx

- Acute osteomyelitis
- Gout & pseudogout
- Trauma - *Traumatic synovitis or haemarthrosis*
- Irritable joint
- Haemophilic bleed
- Rheumatic fever - *typically pain flits from joint to joint*
- Gaucher's disease - *Presents as acute joint pain & fever without any organism being found ('pseudooosteitis')*
- Bursitis
- SCD in crises

Ix

- X-ray - *Normal*
- FHG - ↑WBC & ESR
- Blood culture - *May be positive*
- Ultrasound;
 - Joint effusion
 - In **children** the joint 'space' may *seem to be widened* (because of the fluid in the joint) & there may be slight subluxation of the joint.
 - With **E. coli** infections there is sometimes **gas** in the joint.
 - **Narrowing or irregularity** of the joint space are **late features**.
- **Joint aspiration m/c/s** - Leukocyte counts **>50,000/ml**
 - * Normal synovial fluid leukocyte count - <300/ml
 - * Non-infective inflammatory disorders - >10,000/ml

Mx

- **Aspirate** joint
- Give **analgesics** for pain & **IV fluids** for dehydration
- **Rest** the joint on a *splint or in a widely split plaster*; with **hip infection**, the joint should be **abducted & 30° flexed, on traction**;
 - * To manage pain
 - * To prevent dislocation
 - * To keep the synovial cavity open to allow circulation
 - * In children;
 - To prevent slipping of the upper femoral epiphysis
 - To strengthen the perichondral ring
- **Antibiotics**;
 - * **<4years** - *Ampicillin or 3rd generation cephalosporins*
 - * **Older children & Adults** - *Flucloxacillin & Fusidic acid IV for 2-7days & then orally for another 3wks*
- In children, give **cod-liver oil** which reduces inflammation by supplying Omega 3 reducing the formation of arachidonic acid necessary for the formation of prostaglandins that mediate inflammation.
- **Surgical eradication**;
 - a) Under anaesthesia the joint is opened through a small incision, drained & washed out with physiological saline. *A small catheter is left in place & the wound is closed*; **suction-irrigation** is continued for another **2-3days**. This is advisable;
 - In very young infants
 - When the hip is involved (*Joint is opened from behind*)
 - If the aspirated pus is very thick
 - b) For **knee**, **arthroscopic debridement** from the *lateral aspect* & copious irrigation may be equally effective
 - c) Older children with **early septic arthritis** (symptoms for **<3days**) involving any joint **except the hip** - **Repeated closed aspiration** of the joint; however, *if there is no improvement within 48hrs, open drainage will be necessary*.

Post-op;

- * **Intact** articular cartilage - **Physiotherapy**
- * **Destroyed** articular cartilage - The joint is **splinted** in the optimum position awaiting *ankylosis (stiffness or fixation of a joint by disease or surgery)*

Complications

- Bone destruction
- In adults, *partial destruction of the joint* will result in **2° Osteoarthritis**
- Cartilage destruction -may lead to either **fibrous or bony ankylosis**
- **Growth disturbance** - presents either as a localized deformity or as shortening of the bone
- Dislocation of the **hip**
- **Osteomyelitis**

Osteoarthritis

OHCM 412-417

Osteoarthritis is a chronic joint disorder of **post middle age** in which there is **progressive softening & disintegration of articular cartilage** accompanied by **new growth of cartilage & bone at joint margins** (*osteophytes*) & **capsular fibrosis**.

Epidemiology

Most patients are **past middle-age (50yrs); M:F - 3:1**

When it occurs in younger patients, it is usually **2°** & develops if *articular cartilage* is **damaged** or *subjected to abnormal stress*.

>**80%** of persons 55 years old show radiological evidence of osteoarthritis but only **25%** have clinically significant symptoms.

Causes

1. Primary

Develops without any obvious underlying cause & is best characterized by **1° generalized nodal osteoarthritis**, a disorder affecting many joint groups, including;

- Hips
- Knees
- Zygapophyseal joints of the spine

Also;

- Elbow/Ankle
- IP joints of the fingers & toes

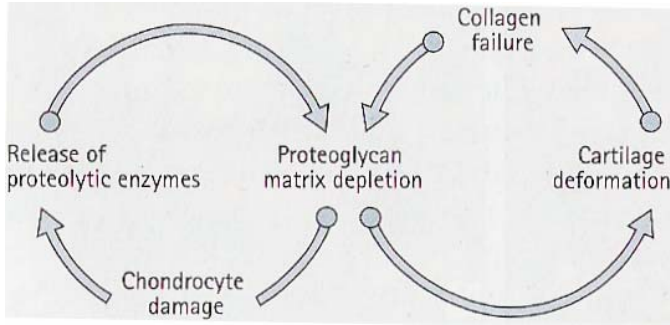
Studies have shown that there is a significant **increase in bone density** in people with osteoarthritis which is determined by a variety of **genetic, hormonal & metabolic** factors which may also **influence cartilage metabolism** independently of any effect due to bone density. Women with osteoporosis **seldom** have osteoarthritis.

2. Secondary - This is as a result of **increased stress, weakened cartilage or abnormal support of cartilage** e.g. avascular necrosis

- Genetic or developmental
 - Congenital hip dislocation
 - Slipped upper femoral epiphysis
 - Chondrodysplasia
 - Perthe's disease
 - Genu valgum or varum
 - Haemophilia
- Metabolic
 - Hyperuricaemia
 - CPPD arthropathy
 - Alkaptonuria
 - Gaucher's disease
- Endocrine
 - Diabetes mellitus
 - Hypo/Hyperthyroidism
 - Acromegaly
- 2° to Inflammatory Disorders
 - Septic arthritis
 - Rheumatoid Arthritis
 - Ankylosing spondylitis
 - Psoriatic arthritis
- Trauma
 - Fractures (*particularly osteochondral fractures*)
 - Joint instability (e.g. *cruciate ligament injury, joint hypermobility syndromes*)
 - Post meniscectomy
 - Osteochondritis dissecans
 - Neuropathic joints (*Charcot joints*)
 - Mechanical causes including *leg length discrepancy, instability, repetitive (occupational) injuries*

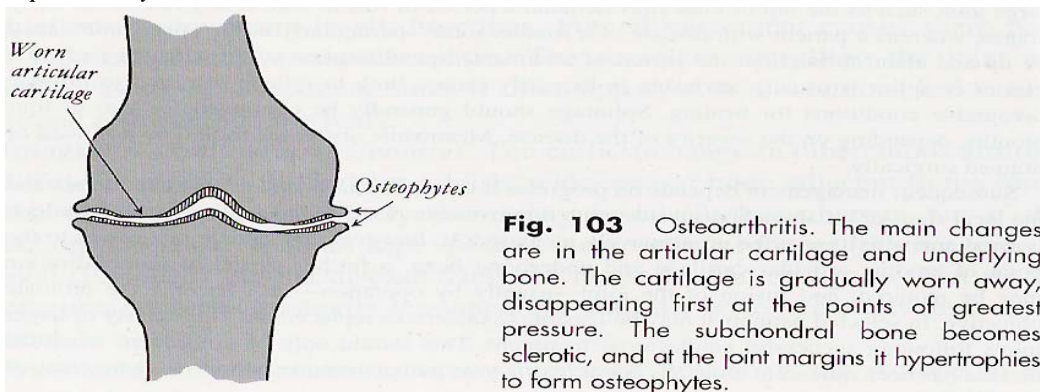
Pathogenesis

This is thought to be as a result of *intrinsic disturbances in the metabolism of cartilage* which leads to **increase in water content of the cartilage & easier extractability of the matrix proteoglycans** which leads to **chondrocyte damage & cartilage deformation**.



Cardinal features;

- i) **Inflammation** leads to **progressive cartilage destruction** forming an area of **fibrillation**, which is a hair-like patch where the cartilage matrix components are lost, leaving only a skeleton of disrupted collagen fibres attached to the bone below.
- ii) **Subarticular cyst formation** in the marrow below the subchondral bone from extrusion of joint fluid through the hyaline cartilage clefts into the marrow, with a *fibroblastic and osteoblastic cellular* reaction leading to **granulation tissue** formation in the cyst.
- iii) **Sclerosis of the surrounding bone** due to *increased synthesis of bone by subchondral osteoblasts*, presumably prompted by intercellular communication by cytokines between chondrocytes and osteoblasts. With increased bone formation in the subchondral area, physical properties change; the *bone becomes stiffer with decreased compliance, and microfractures occur*, followed by callus formation, more stiffness, and more microfractures. The term **eburnation** applies to the glistening appearance of the polished sclerotic bone surface.
- iv) **Metaplasia of the peripheral synovial cells** results in *peri-articular* formation of **osteophytes** (or, more correctly, *osteochondrophytes*, consisting of bone and a mixture of connective tissues with a coating of fibrocartilage and sometimes islands of hyaline cartilage within the osteophyte) and in **subchondral bone**, especially in areas denuded of cartilage.
- v) **Capsular fibrosis** - There is **NO primary change** in the capsule or synovial membrane, but the recurrent strains to which an osteoarthritic joint is subjected to often leads to slight **thickening & fibrosis of the capsule or synovial membrane**



S/S

Symptoms characteristically wax & wane, & pain may subside spontaneously for long periods.

Commonly affected joints

- DIP
- Thumb MCP
- Cervical & lumbar spine
- Knee

Early Osteoarthritis

- **Pain/Tenderness** (*worse at the end of the day; background pain at rest*) due to;
 - Exposure of nerve endings 2° to bone erosion
 - Capsular fibrosis → shrinking, with pain on stretching
 - Bone pressure due to vascular congestion
 - Muscular fatigue

Moderate Osteoarthritis

- **Stiffness** - In larger joints, movement is accompanied by *palpable or audible coarse crepitations*.
- **Swelling** due to;
 - Intermittent - *Effusion*
 - Continuous;
 - * *Capsular thickening*
 - * *Large osteophytes*
 - Gives the appearance of nodes in the *PIP* - **Bouchard's nodes**
 - " " " " *DIP* - **Heberden's nodes** - *common in women*

Severe osteoarthritis

- **Deformity** due to;

- Capsular contracture
- Joint instability

Fixed deformity (inability of the joint to assume the neutral anatomical position) is often found in the *Hip*, & sometimes at the *Knee* & in other joints.

- **Loss of function**

Ix

- Cardinal features on **X-Ray**;
 - Asymmetric narrowing of joint space**
 - Sclerosis of subchondral bone** under the area of cartilage loss
 - Subchondral cysts**
 - Osteophytes** at margins of joints

Also features of previous disorders.

- ↑ **CRP**
- **Radionuclide scanning** (^{99m}Tc) - shows increased activity during the *bone phase in the subchondral regions* of the affected joints. This is due to *increased vascularity & new bone formation*.

Mx

a) Early treatment principles;

- Relieve pain - **Analgesics & Anti-inflammatory therapy**
- Reduce rate of degeneration - **Proteoglycan matrix supplements** e.g. Glucosamine sulphate, Chondroitin sulphate
- Protect the joint from 'overload'
 - Reduce weight
 - Supportive footwear
 - Walking aids
- Modify daily activities
- Exercises

b) Intermediate treatment

- Maintain movement & muscle strength - **Physiotherapy**
- Injection of **depot intra-articular long acting steroids 6monthly** (S/E - *Osteoporosis*)

c) **Late treatment;**

Indications;

- Must be demanded by the patient
- Keeps patient awake at night
- Reduced walking distance to <100m
- Confinement of activity

i) Minimally invasive procedures - **Arthrotomy, Arthroscopy**

ii) **Intertrochanteric Realignment Osteotomy** - It must be done while the joint is still stable & mobile (usually in patients <50yrs old) & x-rays show that a major part of the articular surface (the radiographic 'joint space') is preserved. Objectives;

- To change the orientation of the femoral head in the socket so as to *reduce mechanical stress in a damaged segment*
- By realigning the proximal femur, to *improve joint congruity*
- By transecting the bone, to *reduce intraosseous hypertension & relieve pain*
- An unintentional & poorly understood consequence is *fibrocartilaginous repair of the articular surface*.

iii) **Arthrodesis** (surgical immobilisation of a joint so that the bones grow solidly together) - is indicated if the *stiffness is acceptable & neighbouring joints are not likely to be prejudiced* e.g. Lumbosacral tilting & rotation. This is a practical solution for young adults with marked destruction of a single joint.

iv) **Total joint replacement for hip & knee** - because of the *tendency for implants to loosen with time*, joint replacement is usually reserved for patients aged ≥ 65 yrs

Mechanical considerations;

- The prosthetic implants must be durable
- They must permit slippery movement at articulation
- They must be firmly fixed to the skeleton
- They must be inert & not provoke unwanted reaction in the tissues

The usual combination is a **metal femoral component** (*stainless steel, titanium, cobalt-chrome alloy*) articulating with a **polyethylene socket**

Complications;

Intra-op;

- Perforation/fracture of the femur or acetabulum
- Sciatic nerve palsy (usually due to traction but occasionally caused by direct injury)

Early;

- Infection
- DVT
- Dislocation
- Myositis ossificans

Late;

- **Aseptic loosening** due to granuloma formation of either the acetabular socket or the femoral stem is the **commonest cause of long-term failure**
- **Stress shielding** - Aggressive osteolysis with or without implant loosening
- Infection
- Dislocation

Charcot Joints

Neuropathic arthropathy 2° to **loss of sensation** associated with certain chronic disorders. The joint disease is usually progressive, with insidious swelling and instability of a single joint. Although said to be painless, Charcot's joints *may be painful, but not in proportion to the joint destruction*.

Causes (affected joint);

- Peripheral neuropathy
- DM (*tarsal and metatarsal, ankle*)
- 3° syphilis
- Leprosy
- Tabes dorsalis (*the vertebrae, hips, knees, & ankles*)
- Syringomyelia (*Shoulder or elbow*)
- Myelomeningocele

Tumours

Table 9.1 A classification of the less rare primary bone tumours

Cell type	Benign	Malignant
Bone	Osteoid osteoma	Osteosarcoma
Cartilage	Chondroma	Chondrosarcoma
	Osteochondroma	
Fibrous tissue	Fibroma	Fibrosarcoma
Marrow	Haemangioma	Angiosarcoma
Uncertain	Giant cell tumour	Malignant giant cell tumour

Mechanisms of spread

- Local
- Haematogenous
- Lymphatic
- Intramedullary
- *Others e.g. injections, transfer (iatrogenic)*

Clinical Diagnosis of tumours

a) Age of patient;

- < 5yrs old - **Malignant**
- 5-30yrs old - **Benign**; Also **Ewing's sarcoma & Osteosarcoma**
- 30-60yrs - **Mixed** - **Chondrosarcoma, Fibrosarcoma**
- > 60yrs - **Secondaries** (malignant); **Multiple myeloma**

b) Symptoms;

- **Benign** - No pain
- **Malignant** - Vascular pain - *Worse at night & throbbing due to ischemia due to increased blood demand*; Also 2° to *pressure effect on bone & soft tissue*

c) Duration of symptoms;

- **3 months** - Malignant
- **6 months** - Borderline
- **1 year** - Benign

d) Imaging;

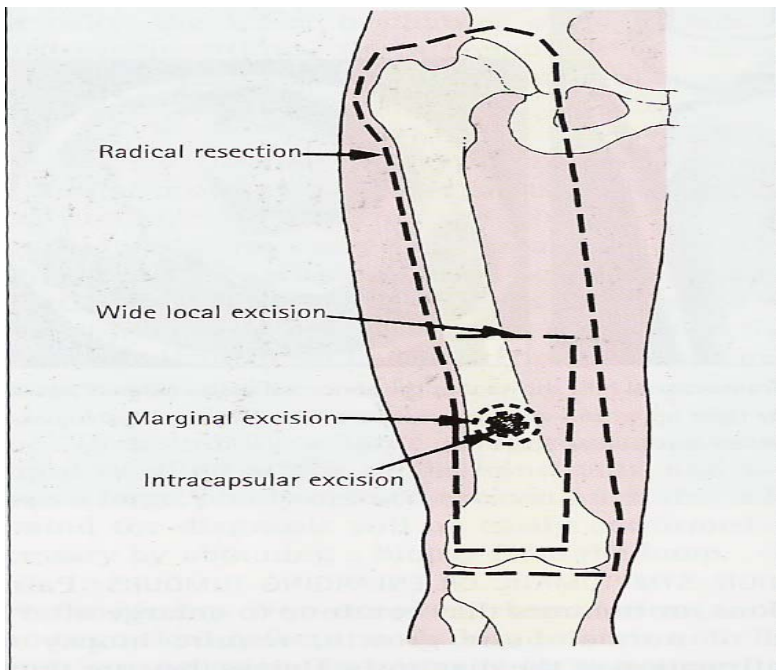
- **Benign** - *well defined transitional zone* with regular/Scalloped margins e.g. Osteochondroma which are mostly metaphyseal especially around the knee & may be pediculated or sessile
- **Malignant** - *Diffuse transitional zone*

DDx

- Soft-tissue haematoma
- Myositis ossificans
- Stress fracture
- Tendon avulsion injuries
- Bone infection
- Gout
- Other bone lesions e.g. *fibrous cortical defects, medullary infarcts & 'bone islands'*

Enneking System of Classifying Musculoskeletal Tumours

- I** - All **low-grade** sarcomas with <25% chance of metastasis e.g. 2° *chondrosarcoma, Parosteal osteosarcoma*
- II** - Histologically **high-grade** lesions with >25% chance of metastasis e.g. *osteosarcoma & fibrosarcoma*
- III** - Sarcomas which have **metastasized**
 - +
 - A** - **Intracompartmental** e.g. A lesion contained in a single muscle belly or a bone lesion that has not broken out into the surrounding soft tissue
 - B** - **Extracompartmental** e.g. A lesion in the *popliteal space, axilla, pelvis, or midportion of the hand or foot*



9.4 Tumour excision The more aggressive a tumour is, and the wider it has spread, the more widely it needs to be excised. Local excision is suitable only for low-grade tumours that are confined to a single compartment. Radical resection may be needed for high-grade tumours and this often means amputation at a level above the compartment involved.

Osteosarcoma

In its classic (**intramedullary**) form, osteosarcoma is a **high grade malignant tumour** arising within the bone & spreading rapidly outwards to the periosteum & surrounding soft tissues.

Epidemiology

- Children > Adults - **5-19yrs; 22-26yrs** - This has been attributed to **increased bone growth**
- Adults - **≥60yrs** - History of **exposure to radiation** when young &/or **bone infection**
- **M:F - 2:1**

Pathogenesis

The tumour is usually situated in the **metaphysis of a long bone**, especially **around the knee & at the proximal end of the humerus**, where it **destroys & replaces normal bone**. Areas of **bone loss & cavitation** alternate with **dense patches of abnormal new bone**. The tumour extends within the medulla & **across physal plate**. There may be obvious spread into the soft tissues with ossification at the periosteal margins & streaks of new bone extending into the extra-osseous mass. The tumour spreads mostly **haematogenously** > **intramedullary** > **local spread**. Rarely lymphatic.

Classification

a) Primary;

- Central (classical)
 - * High grade - *Distal femur, proximal tibia & proximal humerus*
- Juxtacortical;
 - * Low grade (Parosteal) - *Distal femur*
 - * Intermediate grade (Periosteal) - *Shaft of long bones*
 - * High grade (surface sarcoma) - *Shaft of long bones*
- Haemorrhagic or Telangiectatic;
 - * High grade - *Epiphysis*

b) Secondary;

- Paget's disease
- Radiation
- Fibrous dysplasia

C/P

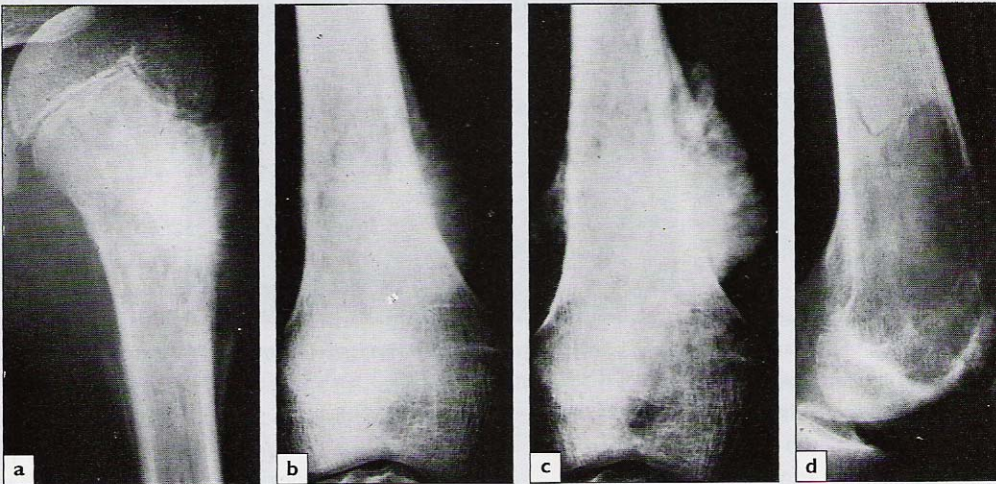
- Pain - constant, worse at night & gradually increases in severity
- Swelling
- Local tenderness

** Pathological fracture is rare

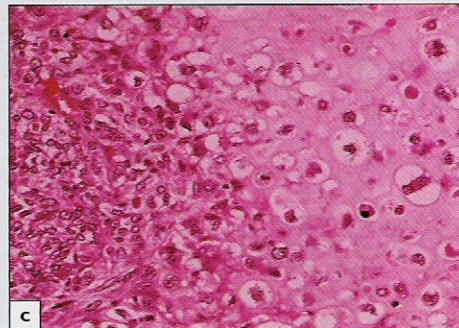
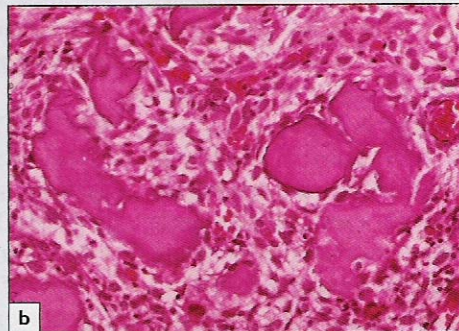
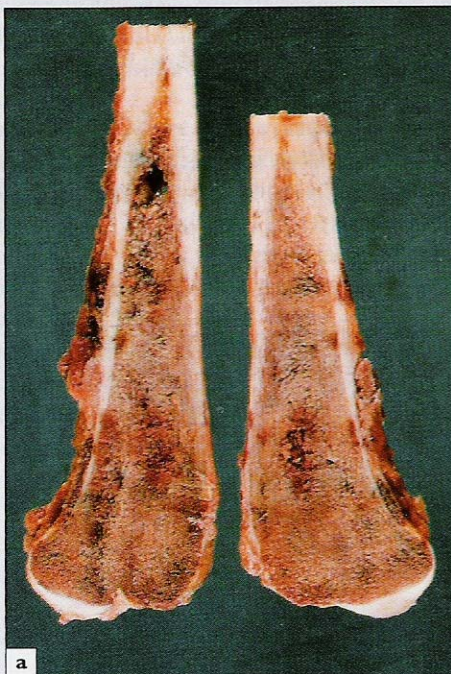
Ix

X-Ray;

- Hazy osteolytic** lesions alternating with unusually **dense osteoblastic** areas
- The **endosteal margin is poorly defined**
- The **cortex is breached** & the tumour extends into the adjacent tissues; when this happens, **streaks of new bone appear radiating outwards from the cortex - Sunburst effect**
- Where the tumour emerges from the cortex, **reactive new bone forms at the angles of periosteal elevation - Codman's triangle**



9.27 Osteosarcoma (a) The metaphyseal site, increased density, cortical erosion and periosteal reaction are characteristic. (b) Sunray spicules and Codman's triangle; (c) the same patient after radiotherapy. (d) A predominantly osteolytic tumour.



9.28 Osteosarcoma – pathology (a) After resection this lesion was cut in half; pale tumour tissue is seen occupying the distal third of the femur and extending through the cortex. (b) The dominant features in the histological sections were malignant stromal tissue showing osteoid formation (pink masses). (x480) (c) The same tumour showed areas of chondroblastic differentiation. (x480)

- Blood;
 - FHG + ESR
 - ↑ ALP + LDH
- CT for staging - **Pulmonary CT** is a much more sensitive detector of **lung metastases** which are present in about **10%** of patients at presentation.
- Liver ultrasound
- Scintigraphy using Methylidiphosphonate PC⁹⁹ (MDP)- *For skip lesions*
- Biopsy;
 - * FNAC
 - * Incisional biopsy - *All layers from skin to bone*
 - * Excisional biopsy - *Wide margin (at least 2mm)*
- **MRI is NOT very useful**

DDx

- Stress fracture
- Infection - *Acute osteomyelitis*
- Post-traumatic swelling
- 'Cystic' lesions
- Other tumours

Mx

- Supportive**
- Specific**

- **Multi-agent neo-adjuvant chemotherapy** is given for **8-12wks**;
 - * Eliminates micrometastasis
 - * Reduces size of tumour reactive zone
 - * Causes tumour necrosis

Then provided the tumour is resectable & there are no skip lesions, a **wide resection** is carried out. The tumour responds well to **Methotrexate, Adriamycin, Cisplatin, Ifafosphamide (MAC-i)**

- The segment of bone is replaced with either a large **bone graft** or a **custom made implant**; in some cases, amputation may be more appropriate.
- The tumour specimen is examined to assess response to pre-op chemotherapy & **if tumour necrosis is marked**, chemotherapy is continued for another **6-12months**; if response is poor, a different chemotherapeutic agent is substituted.
- Pulmonary metastases, especially if they are small & peripherally situated, may be completely resected with a wedge of lung tissue.

Prognosis

Long-term survival after wide resection & chemotherapy - **50-60%** if treated early & **<10%** if late presentation.

General

- Rheumatology - OHCM Pg 408-410
- Calcium Physiology - OHCM 694-696
- Metabolic bone diseases - OHCM 698-700
- Tourniquet Use in Surgery
 - Hand surgery - 250mmHg or $+50\text{mmHg SBP}$ Upper limbs
 - Leg surgery - 350mmHg or $*2\text{ SBP}$ Lower limbs
 - **Put up to 2 hrs** then **release for 15mins** while holding & elevating the area to prevent blood loss then put it again for **1hr**

Types;

- *Esmach*
- *Pneumatic*