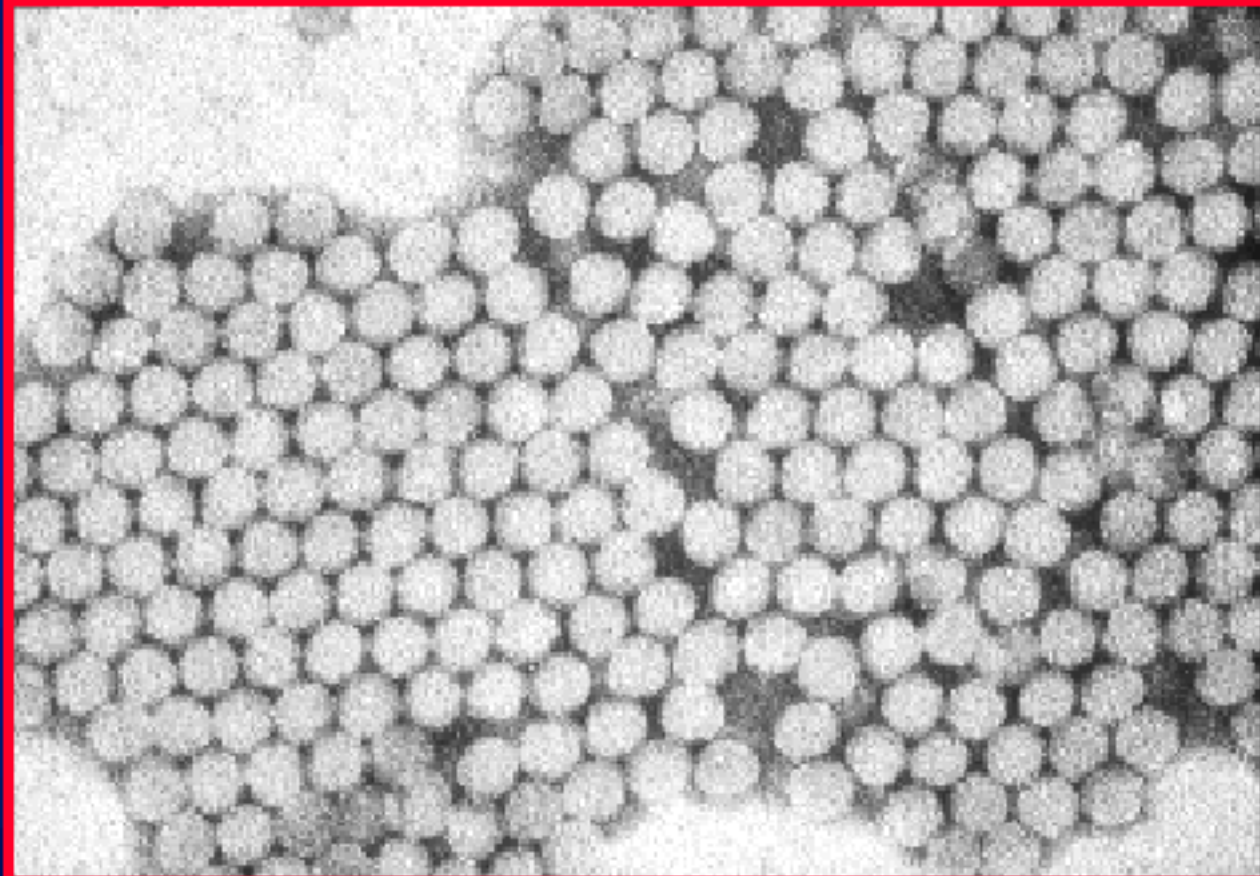
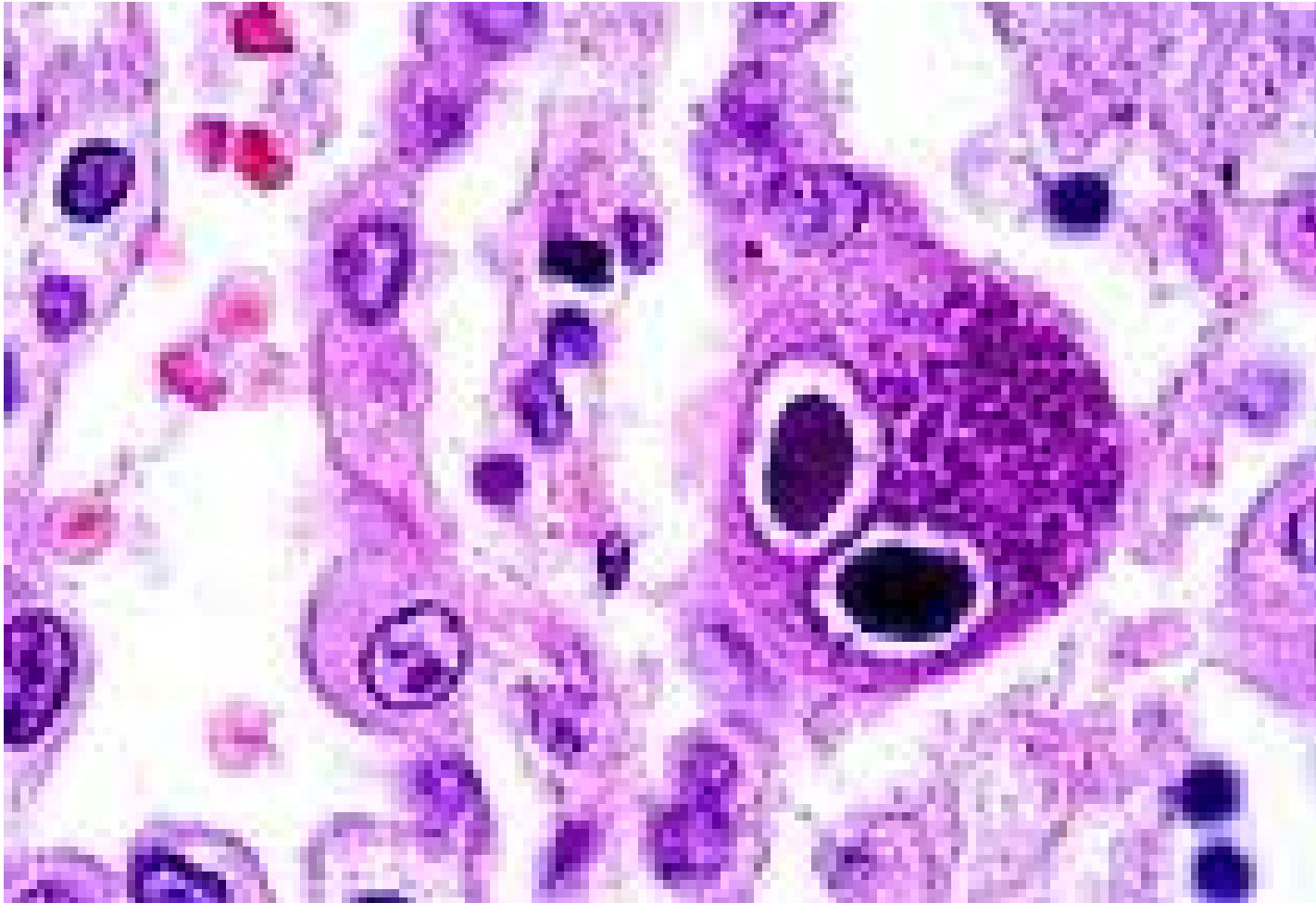


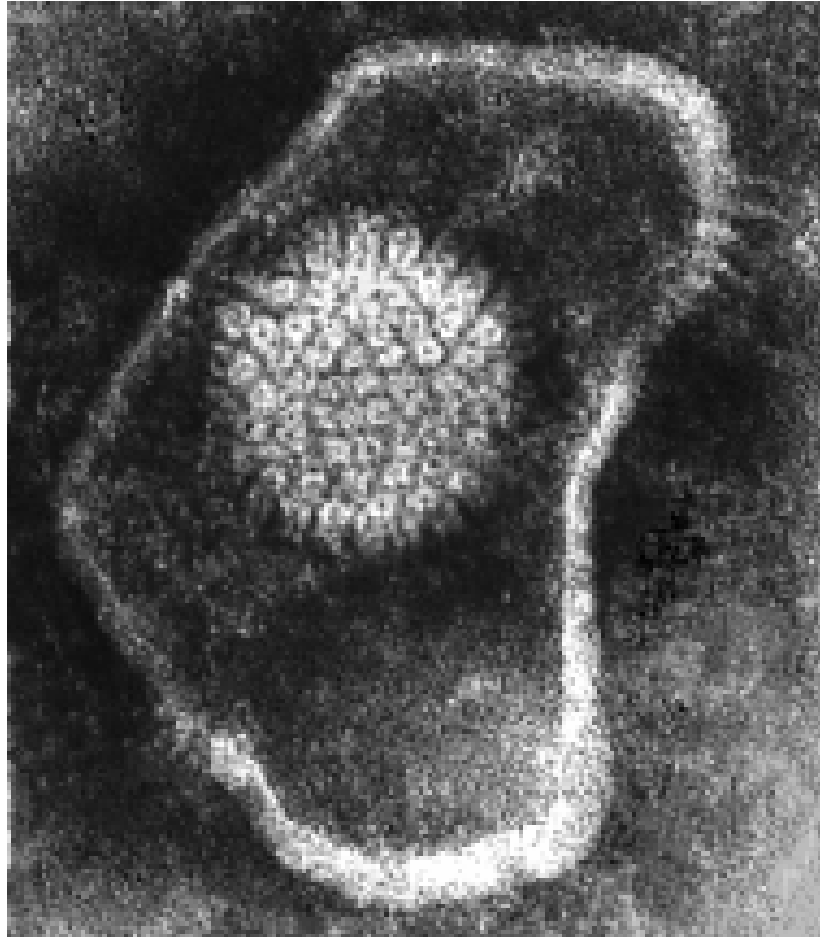
# Hepatitis A Virus



# CMV

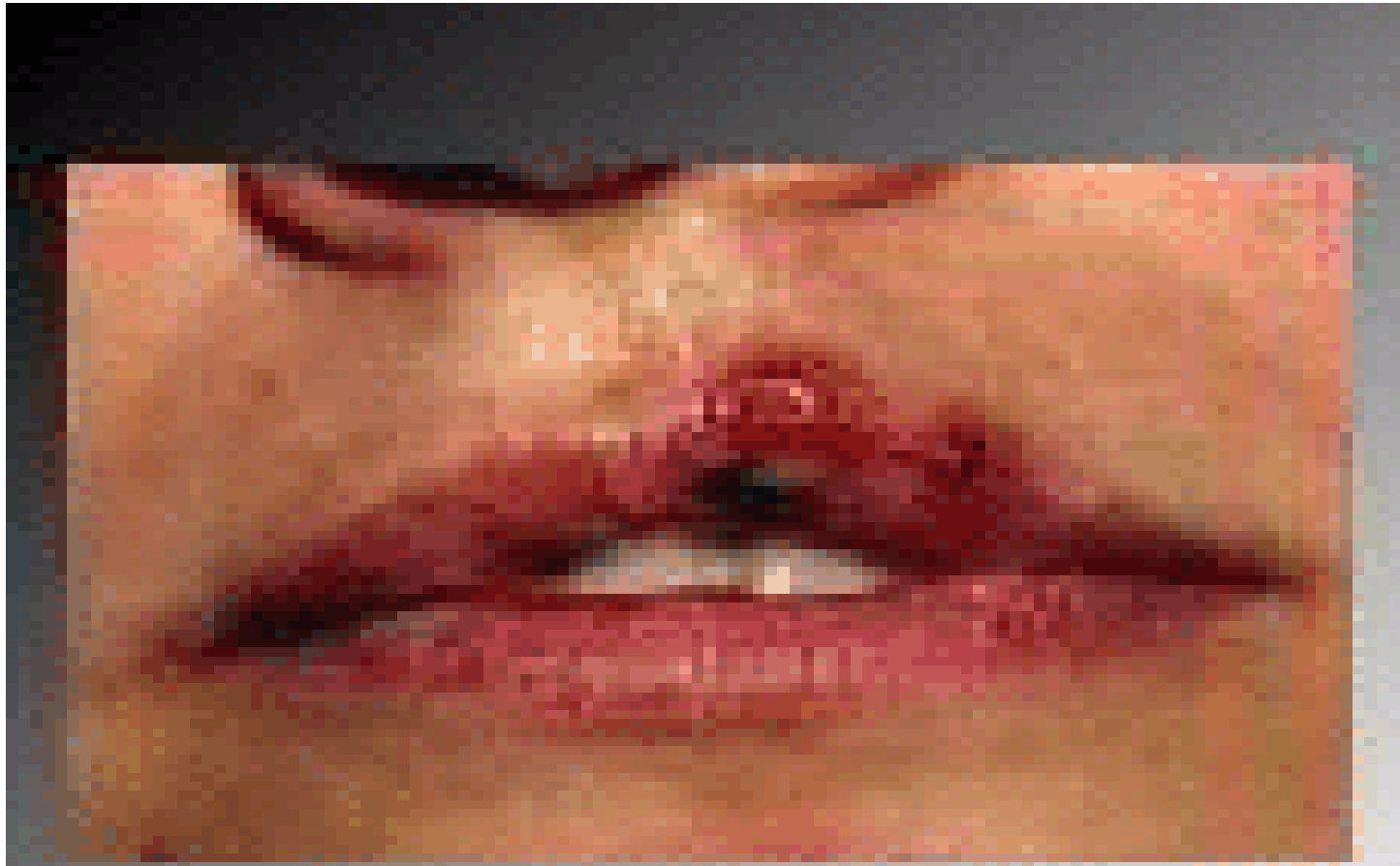

# Herpesviridae




# Herpes labialis

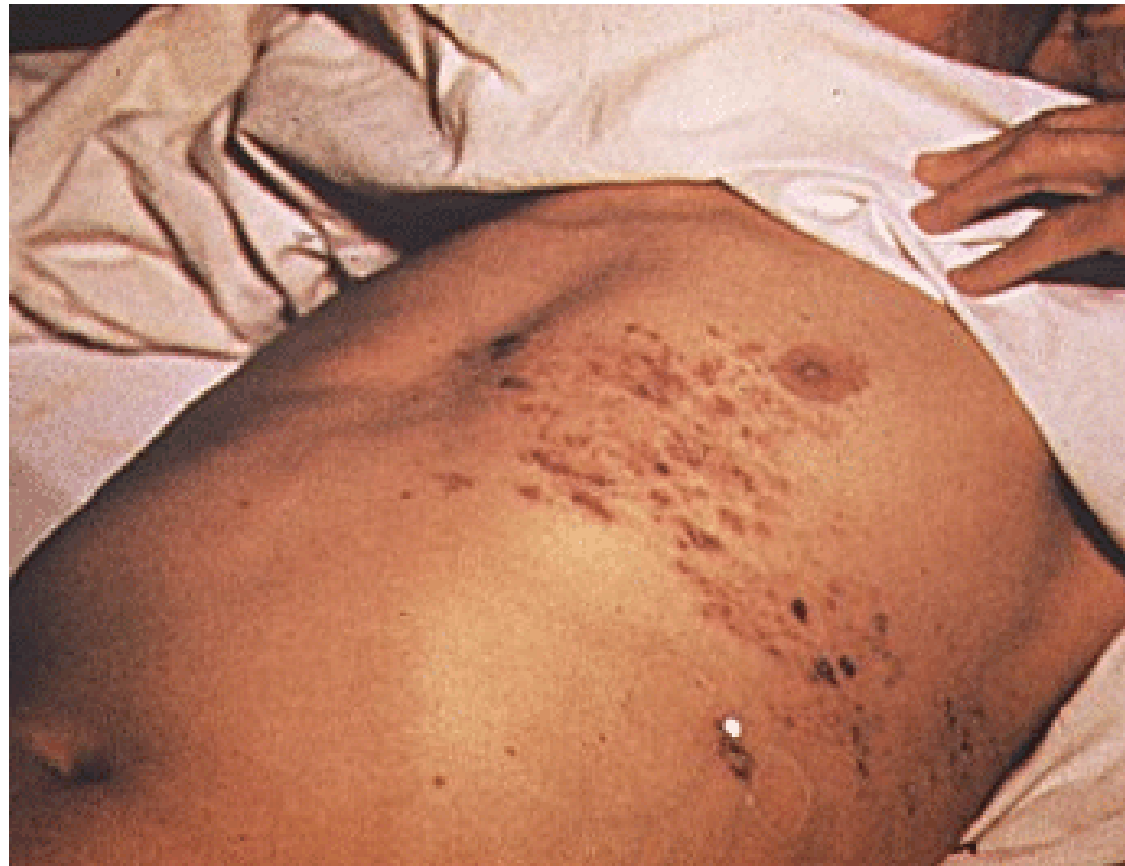- Name the infection below? It is a common feature of which virus?



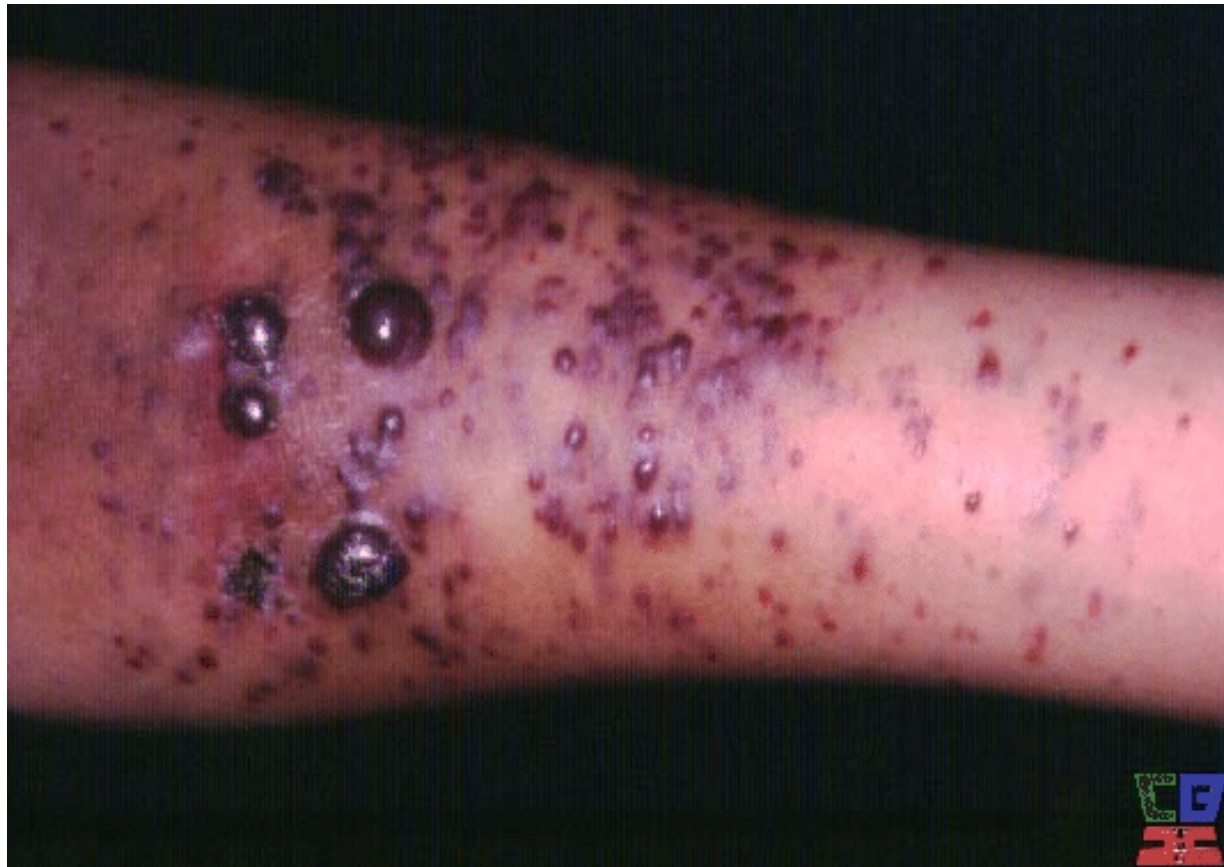# Chicken pox




# Shingles



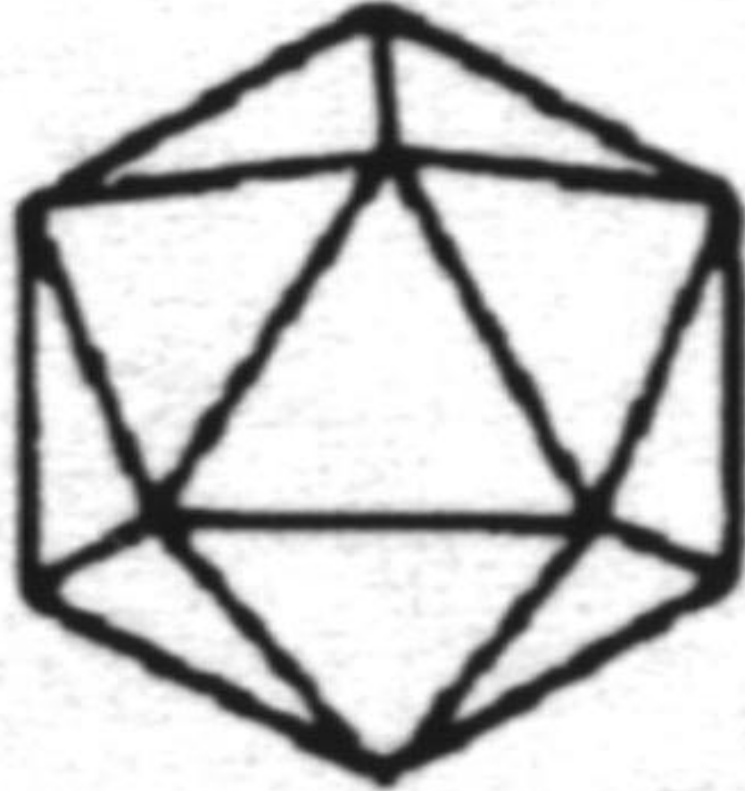
# Kaposi sarcoma



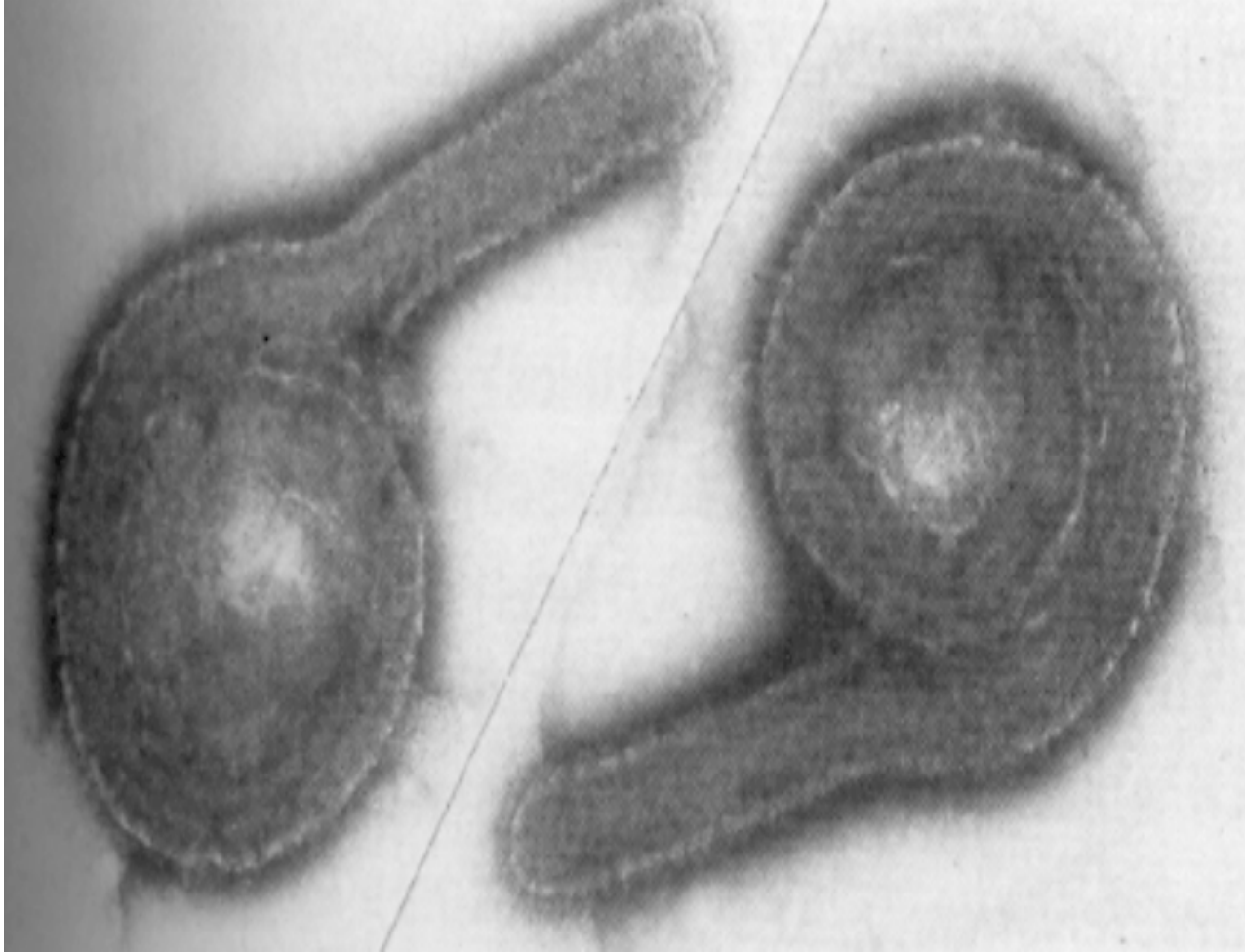



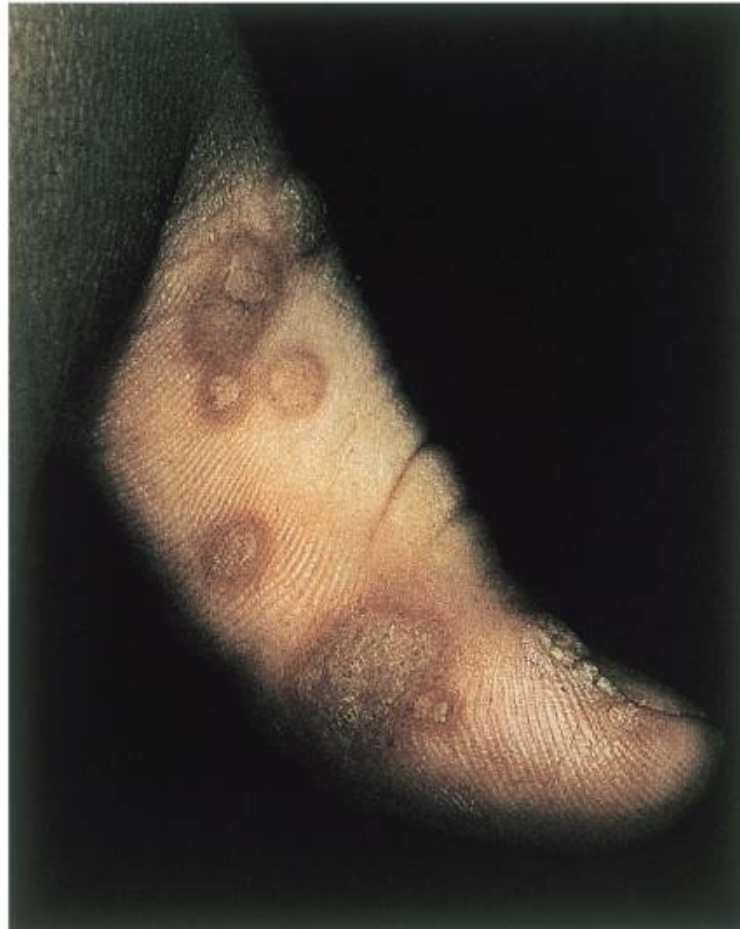# Adenovirus



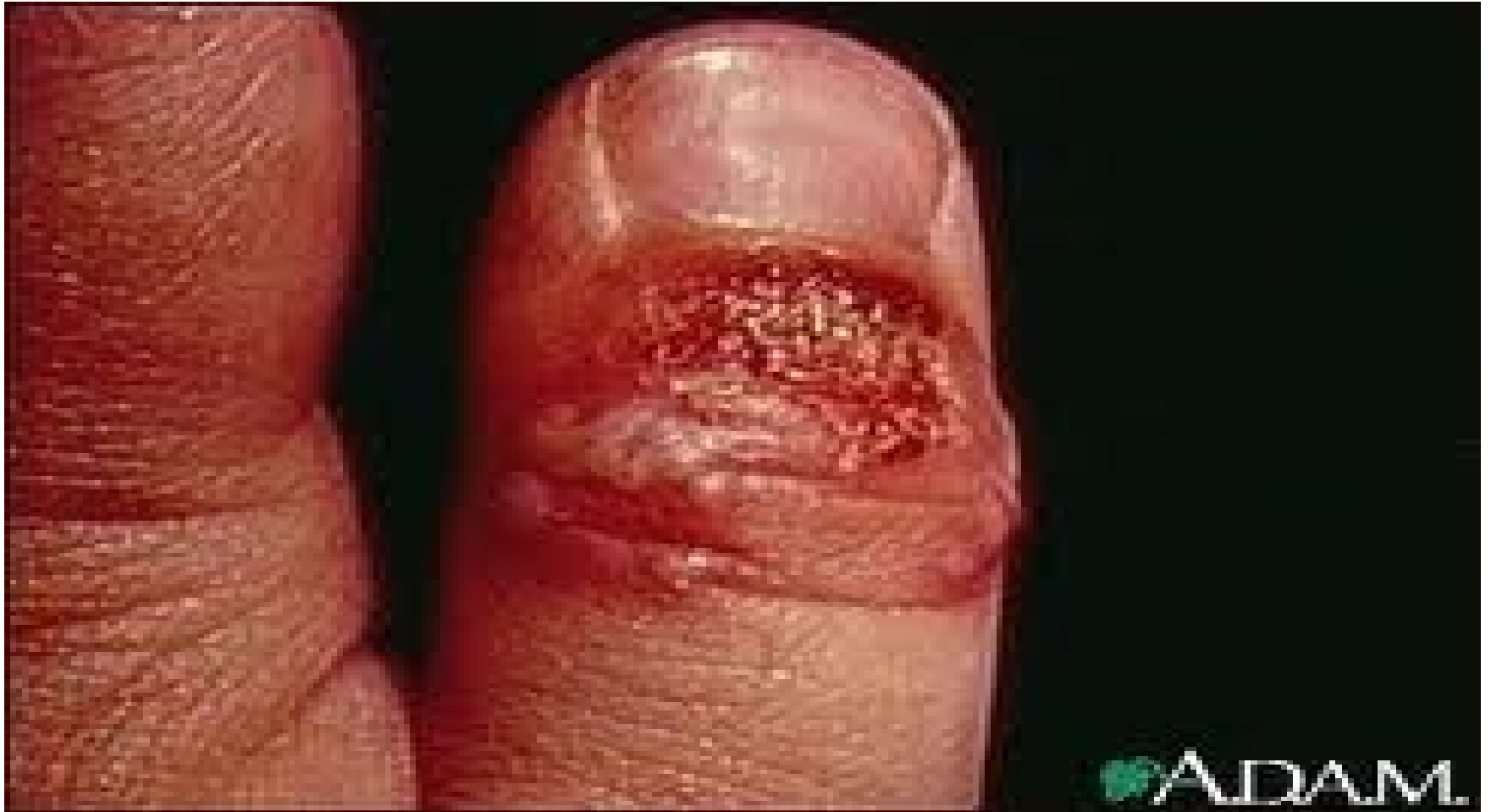# Filoviridae



# Warts

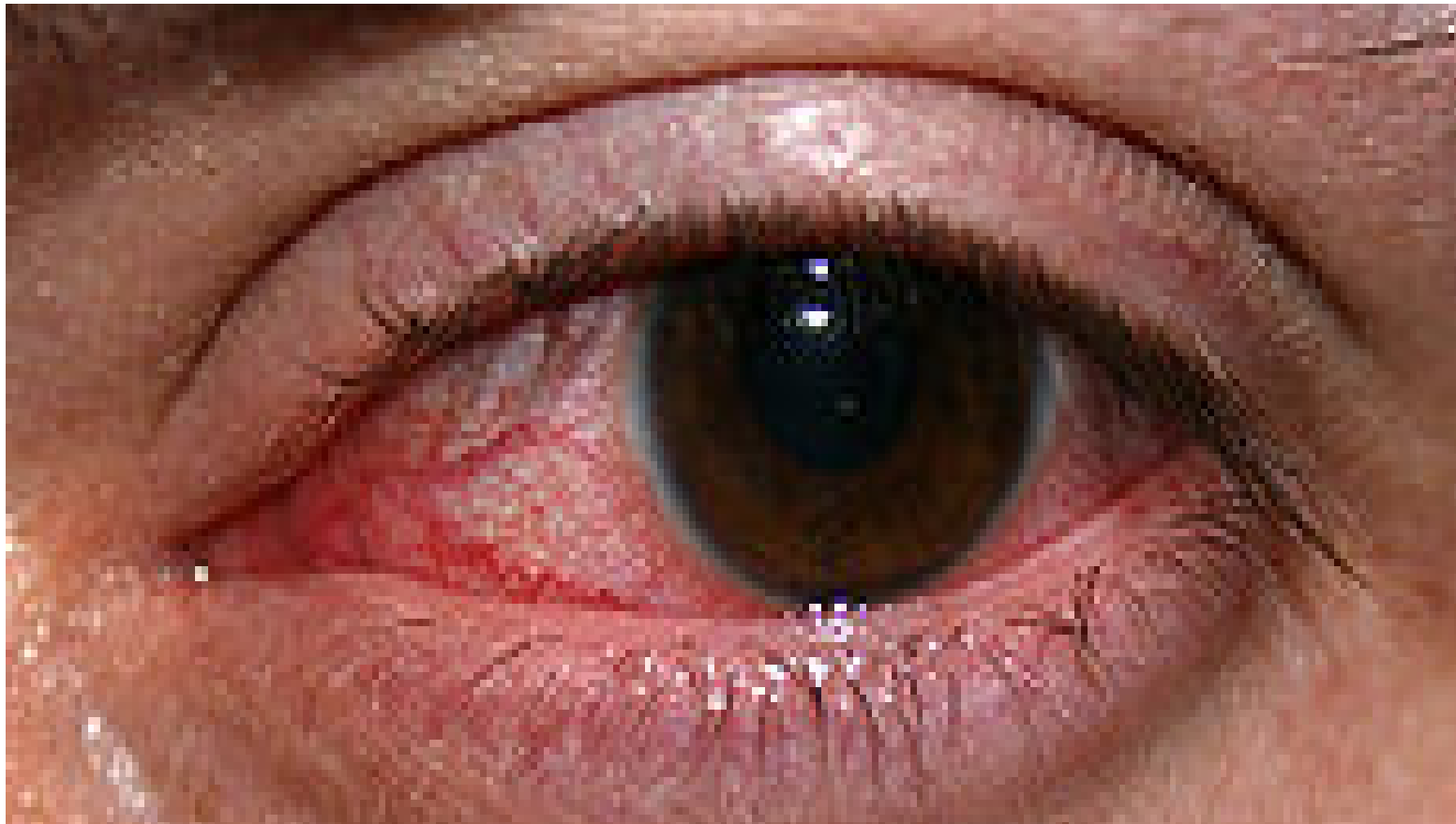

# Herpetic whitlow

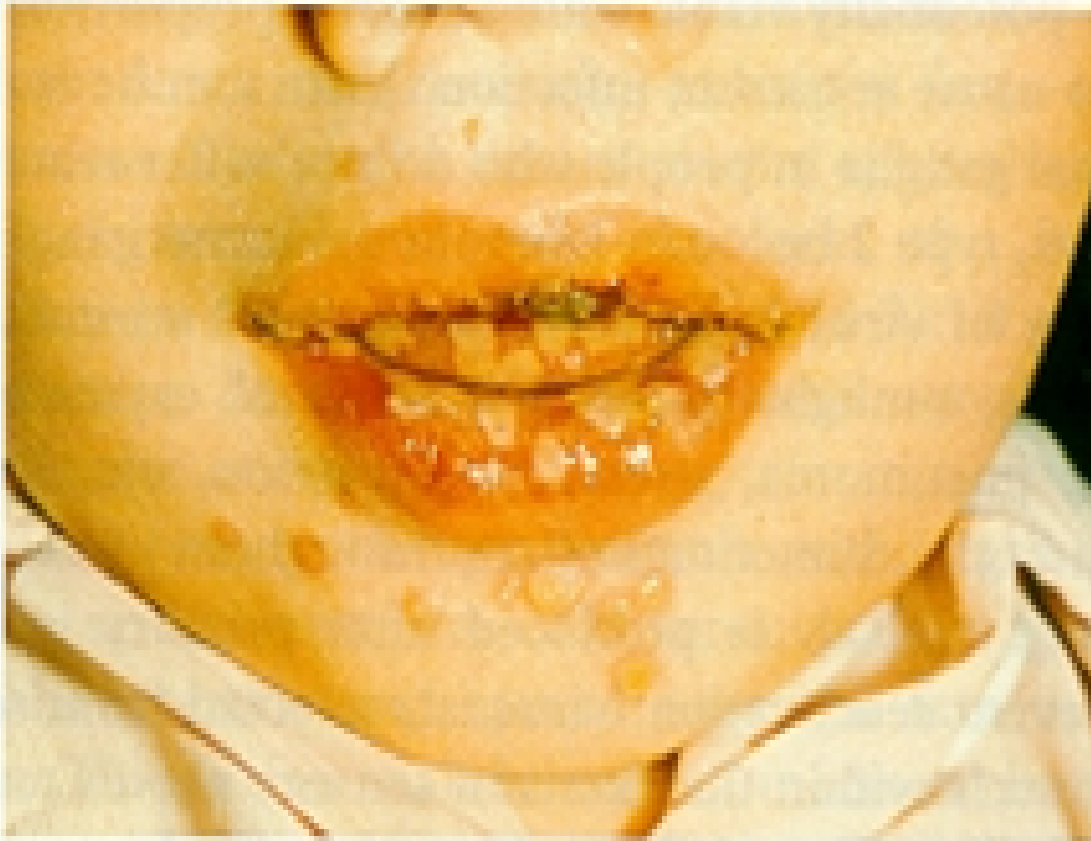

# keratoconjunctivitis

- State the treatment for this infection?

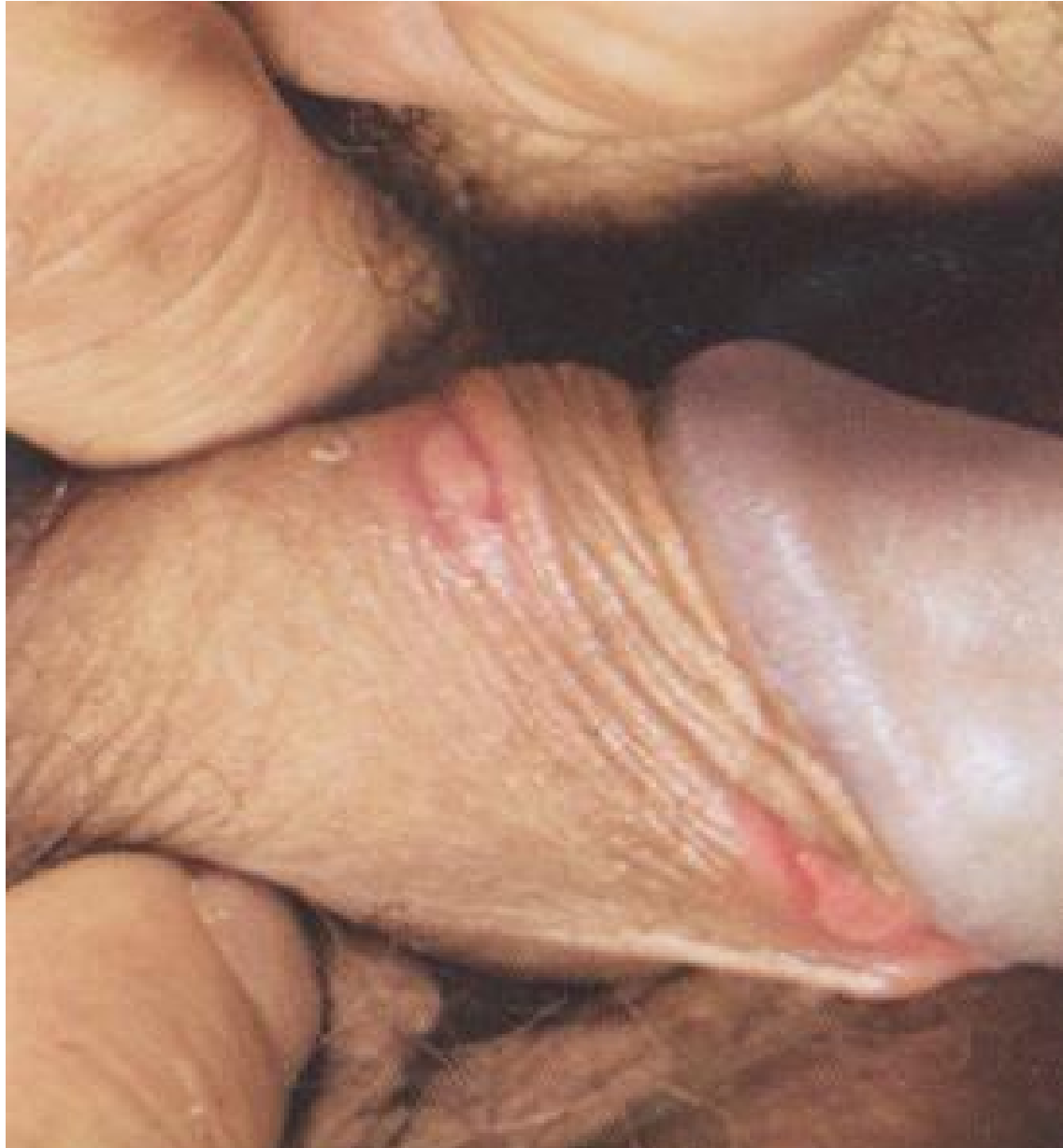

## Gingivostomatitis

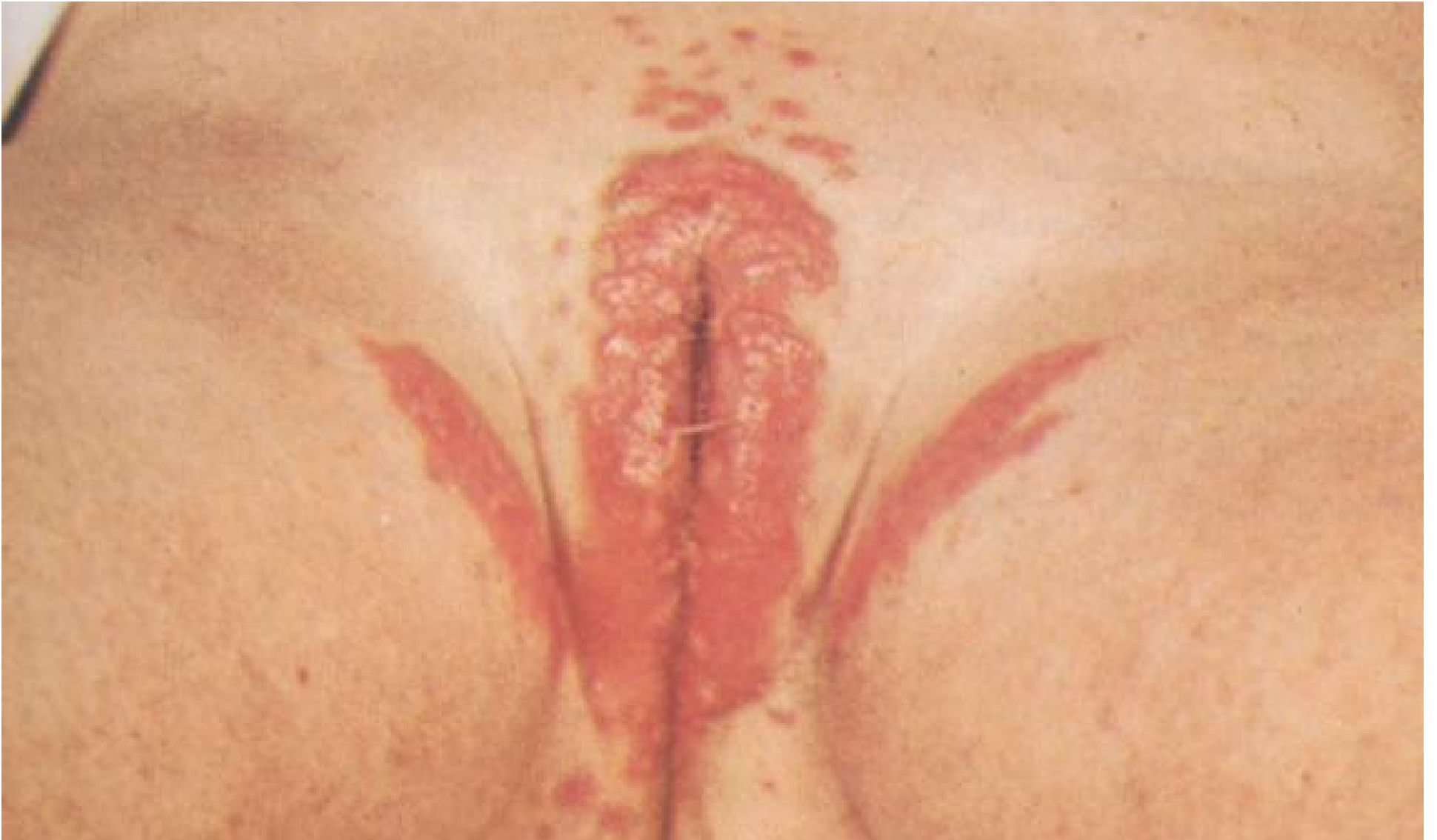

**Fig. 11.1** Primary herpes simplex infection. Stomatitis with satellite vesicles over the chin. (Reproduced, with permission, from *Diseases of Infection* by N.R. Grist, D.O. Ho-Yen, E. Walker and G.R. Williams, 1988. Oxford University Press.)

# Genital herpes-male

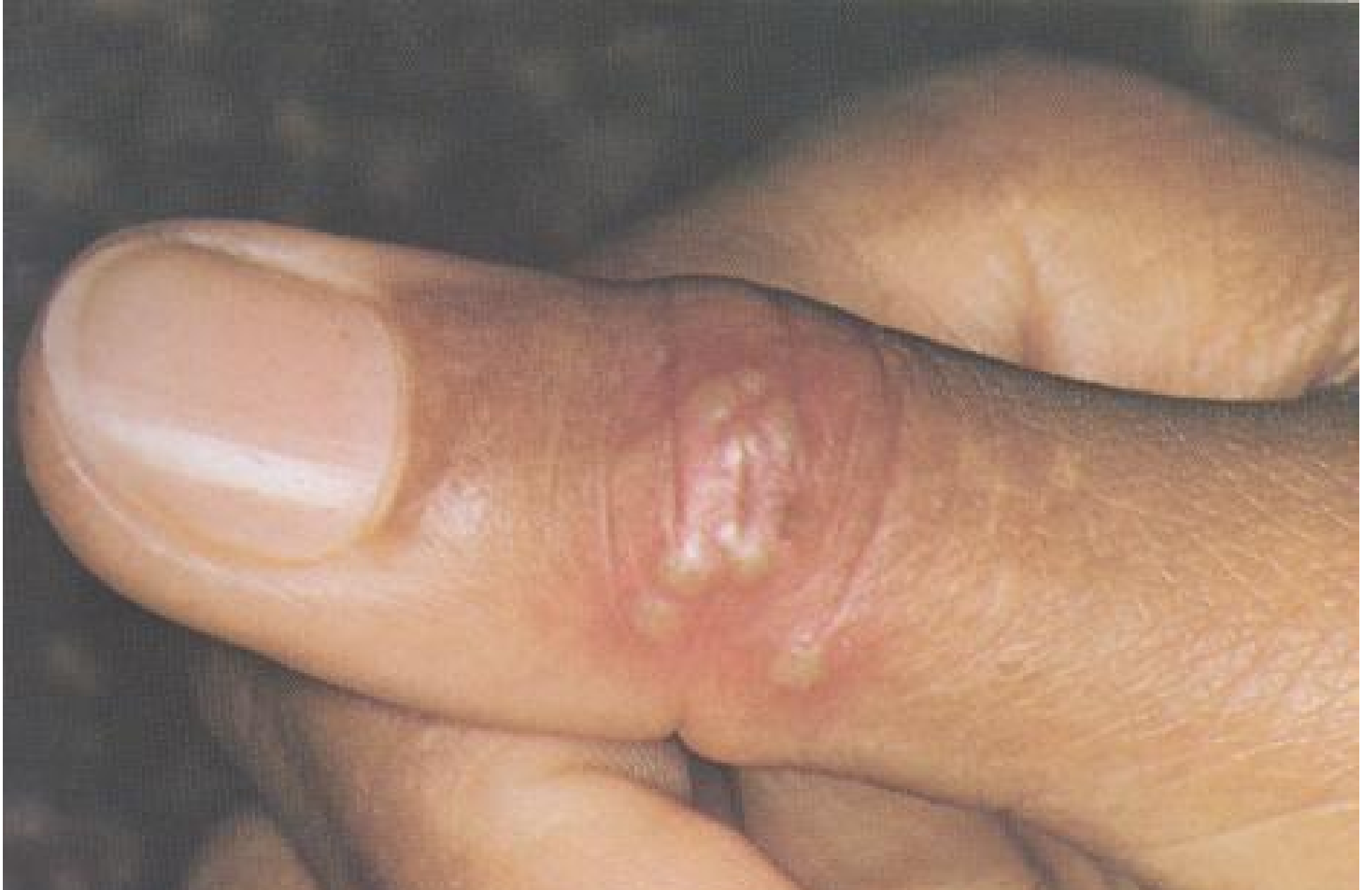

# Genital herpes

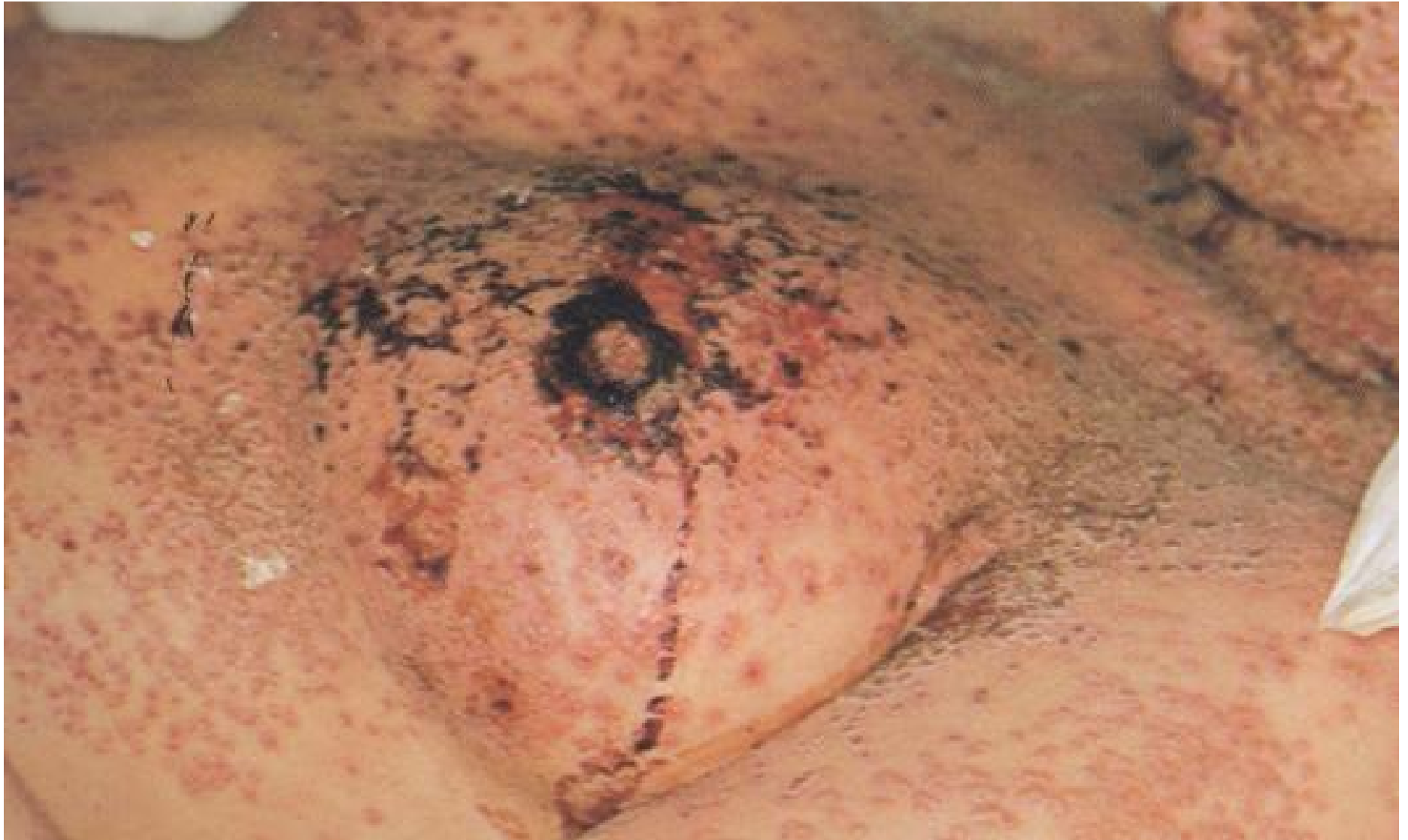


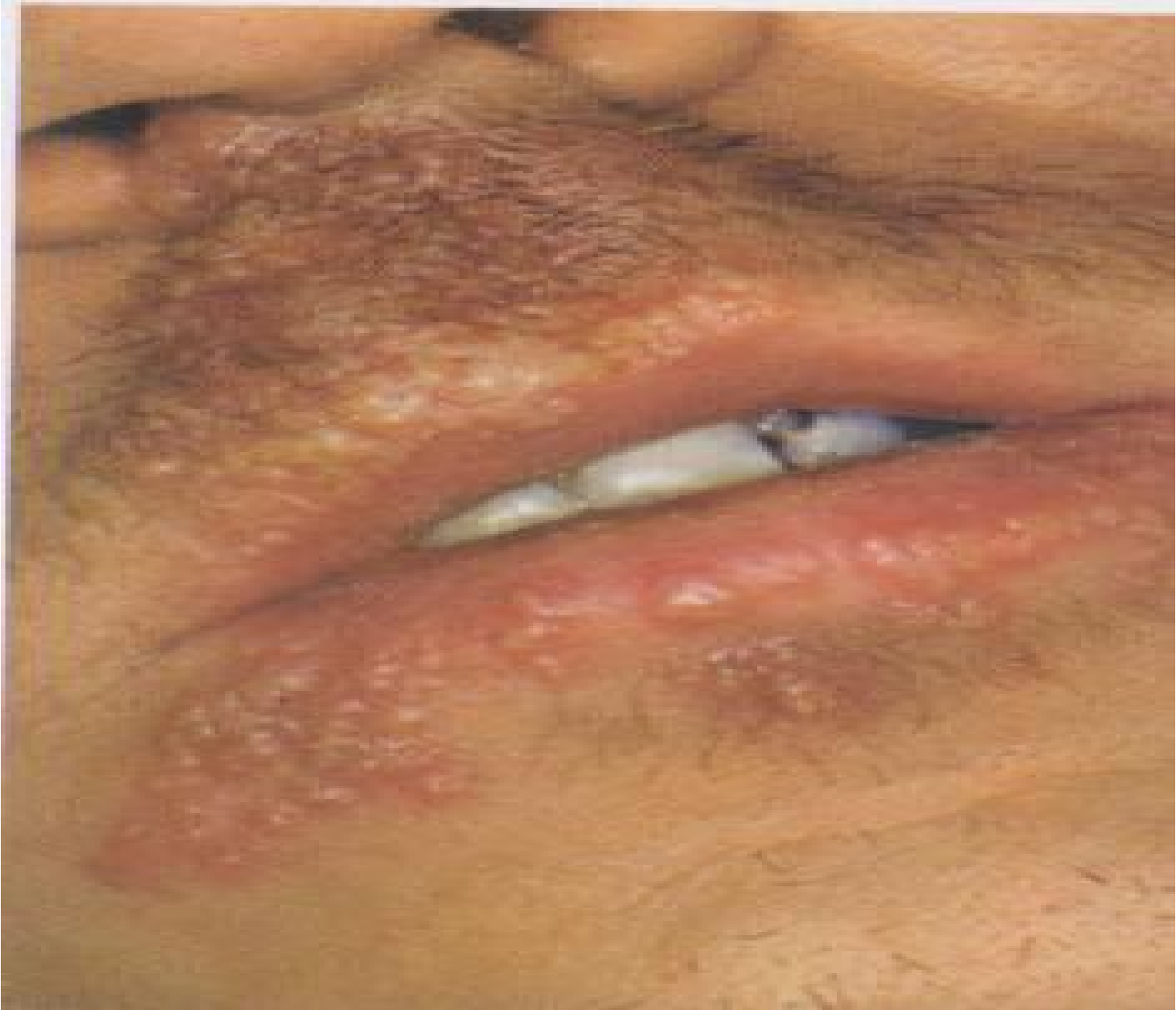
# Herpetic whitlow

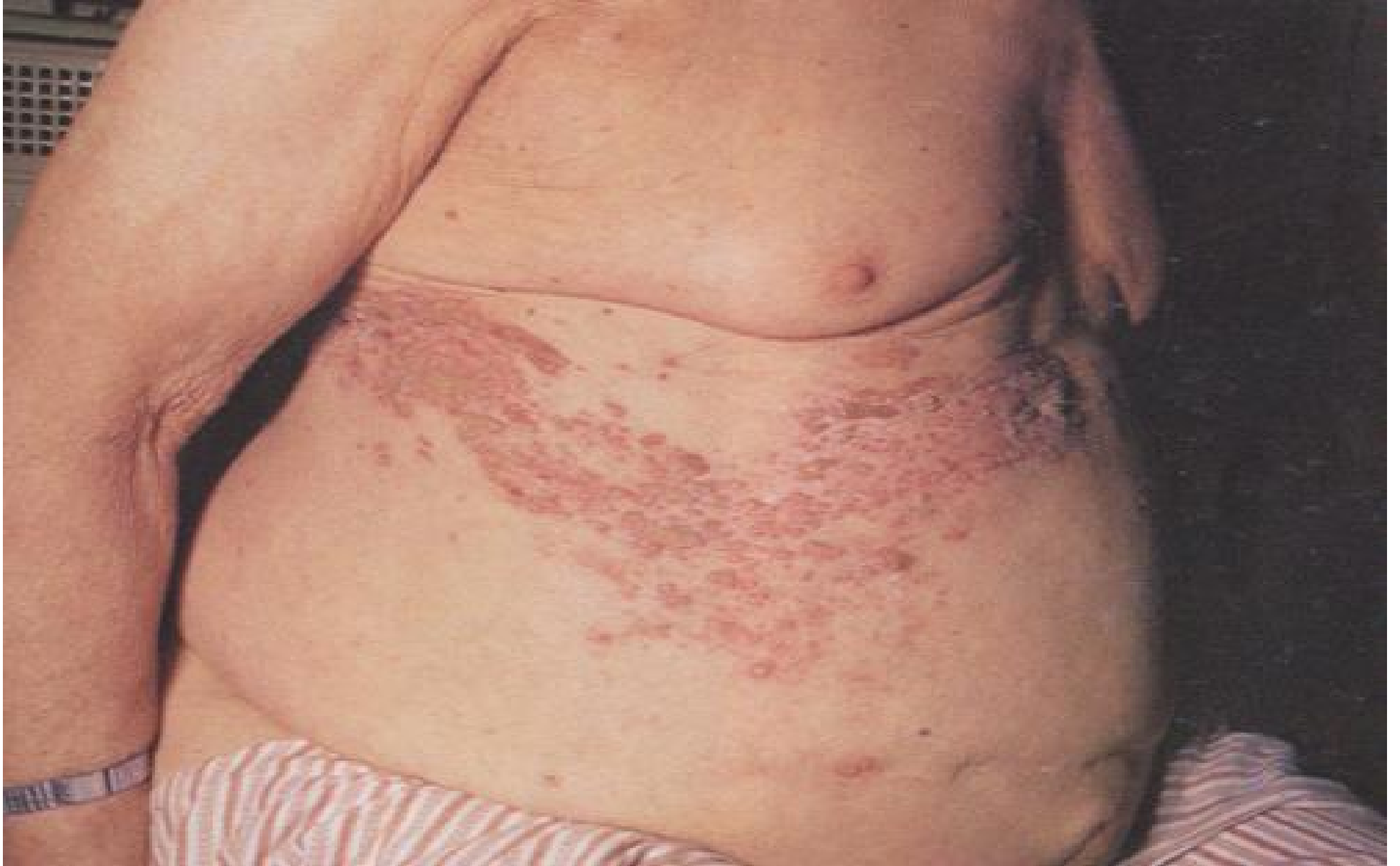

# Erythema multiforme/ Eczema herpeticum

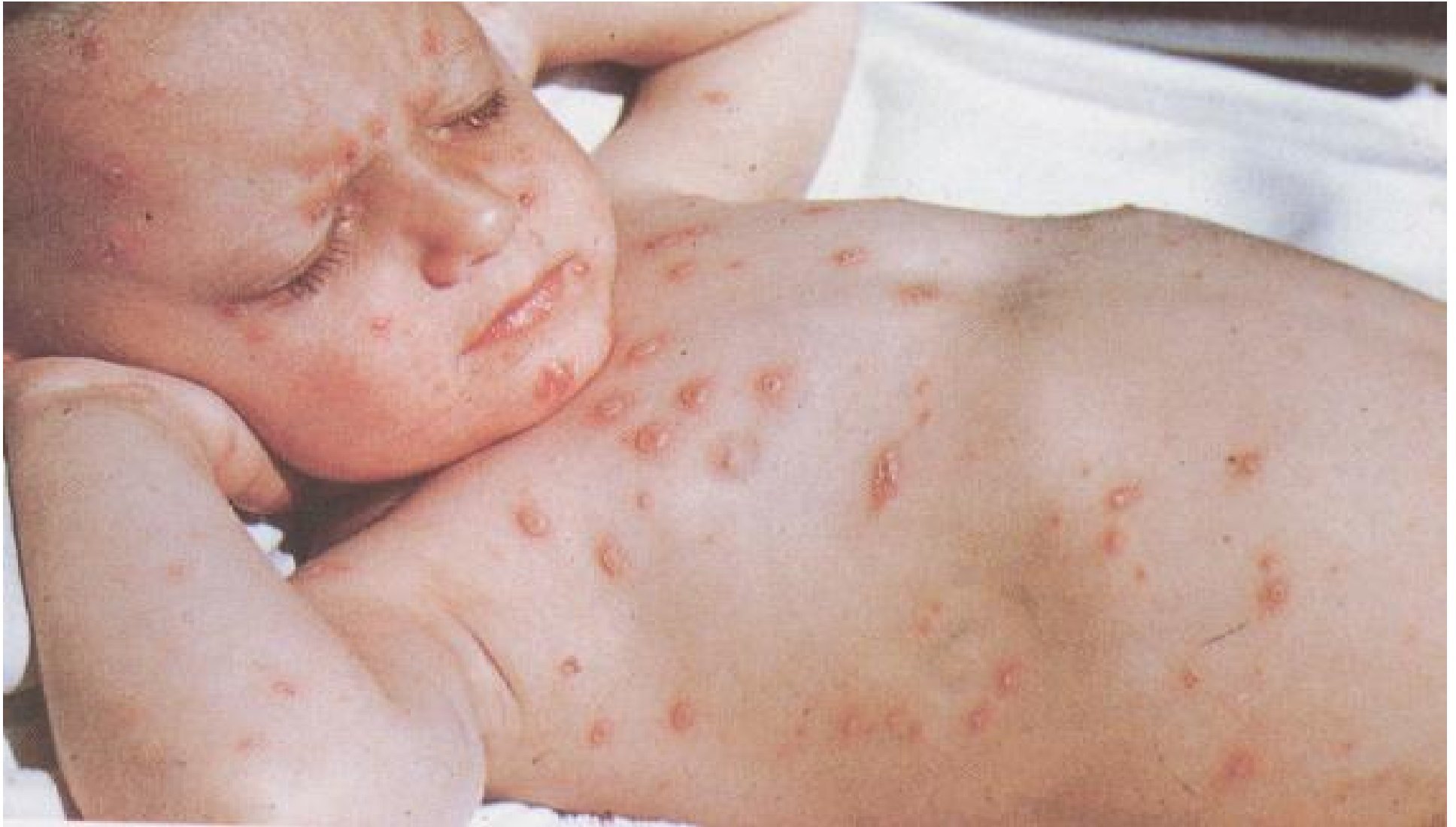


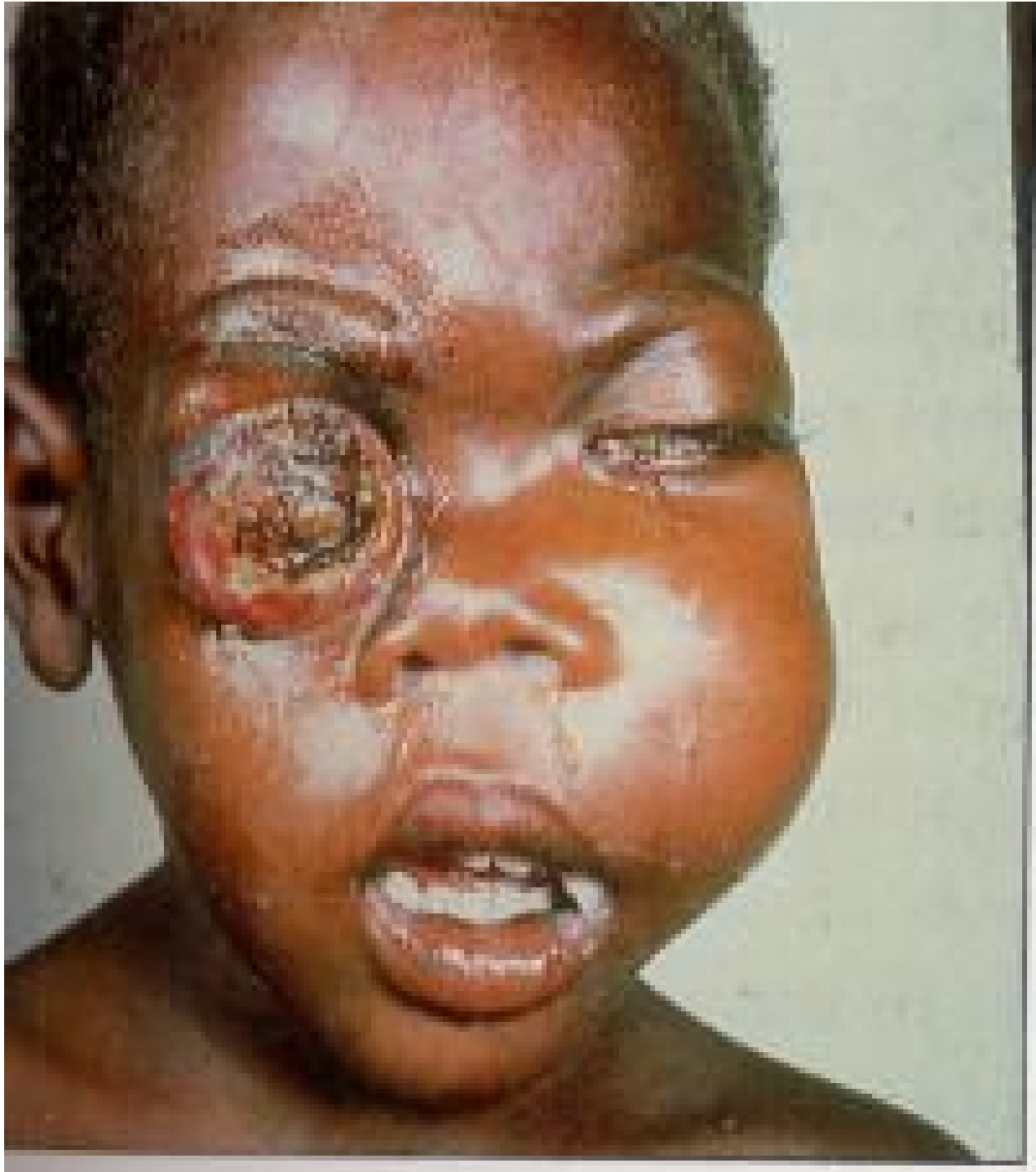
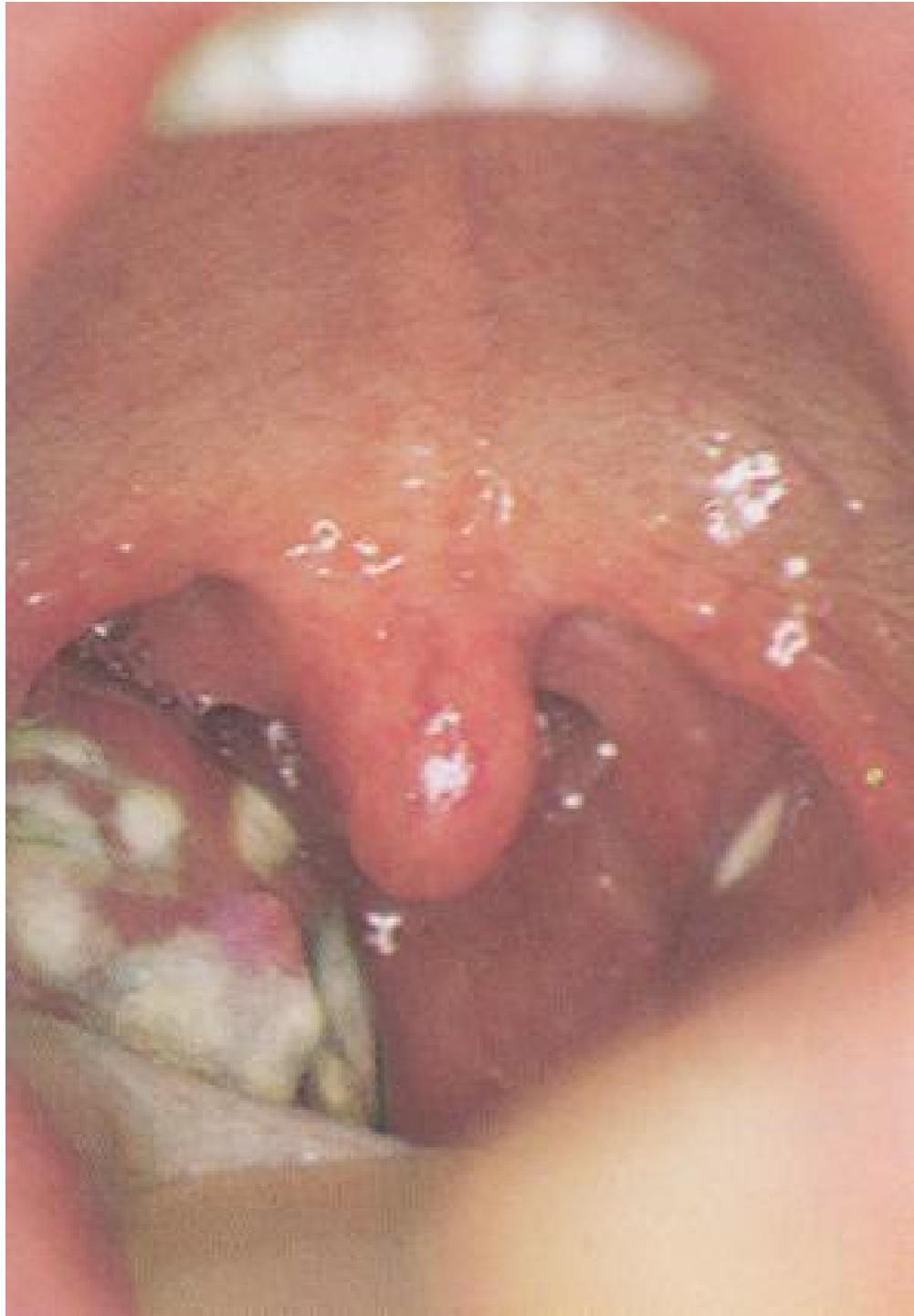# Zoster

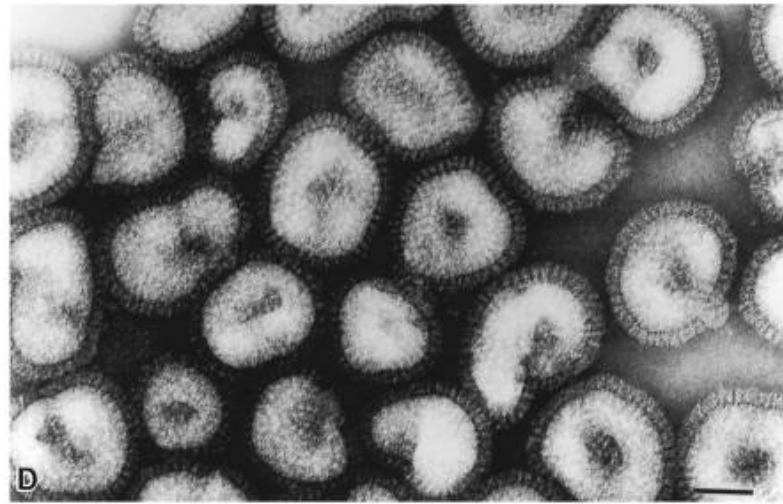
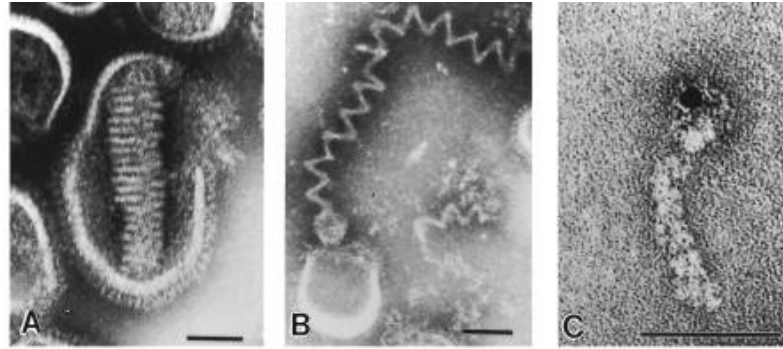


# Varicella

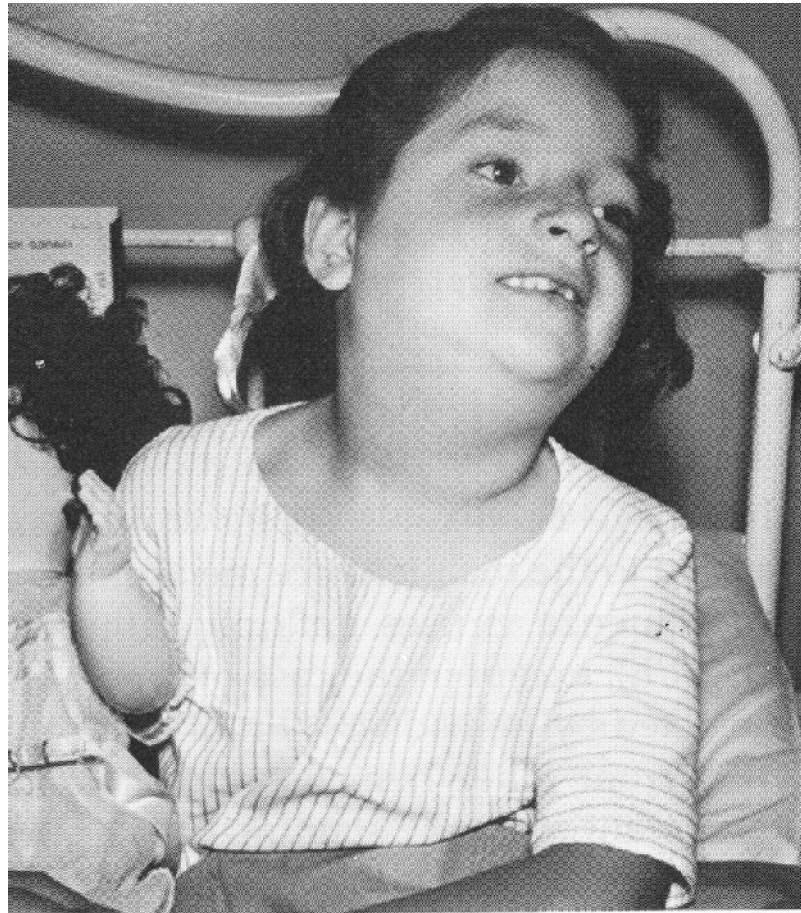



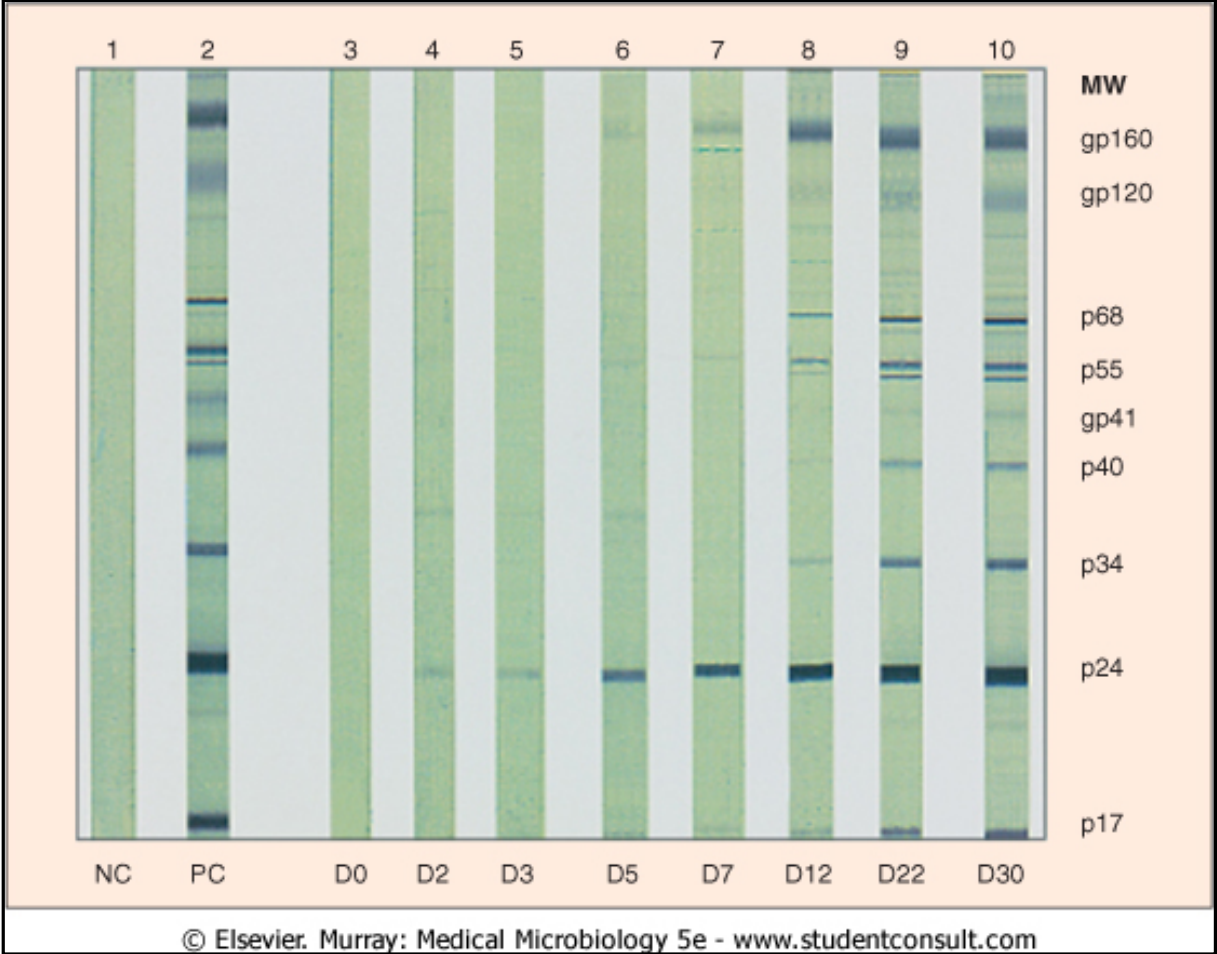





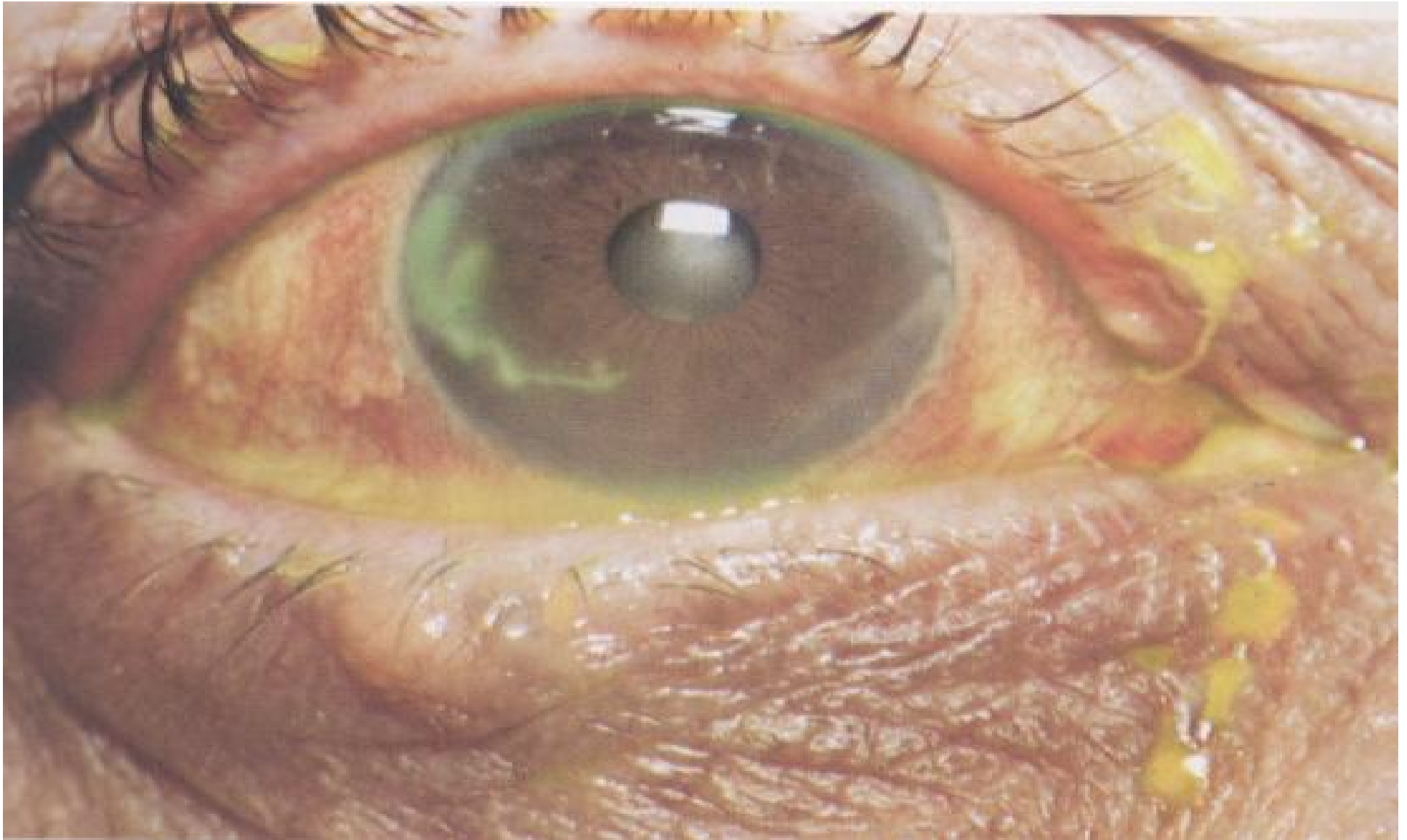


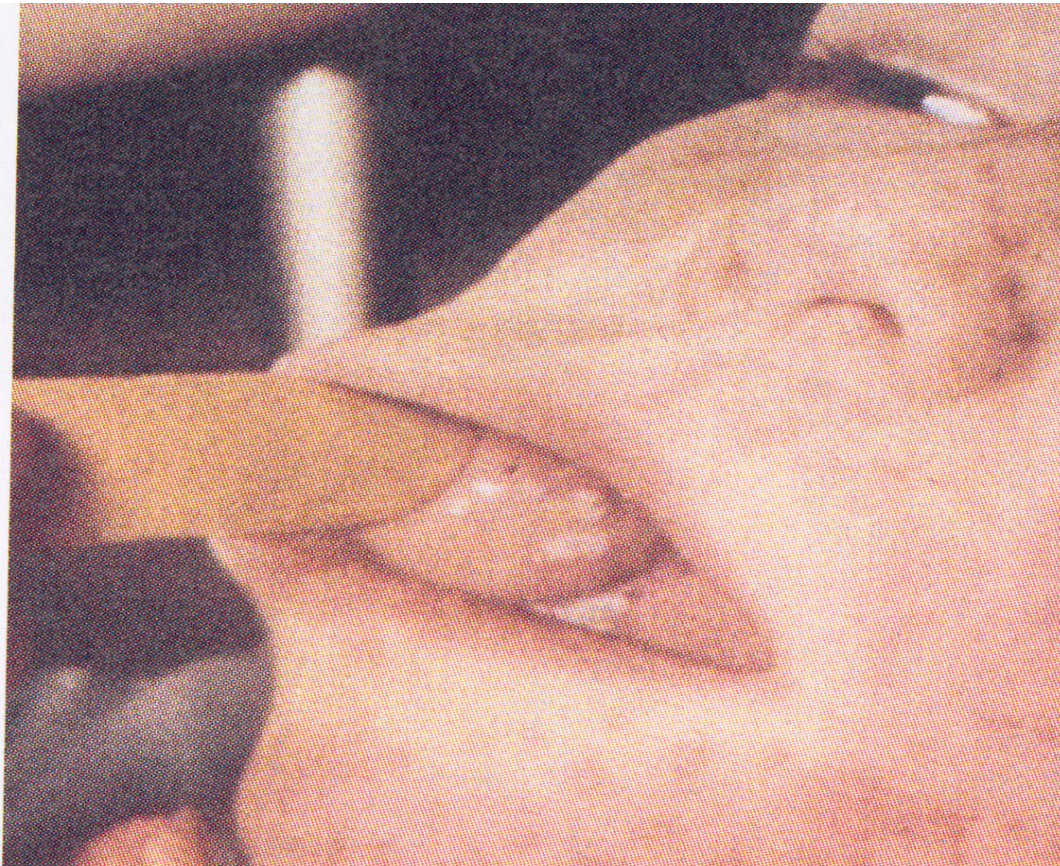
Note swelling of parotid and other salivary glands.

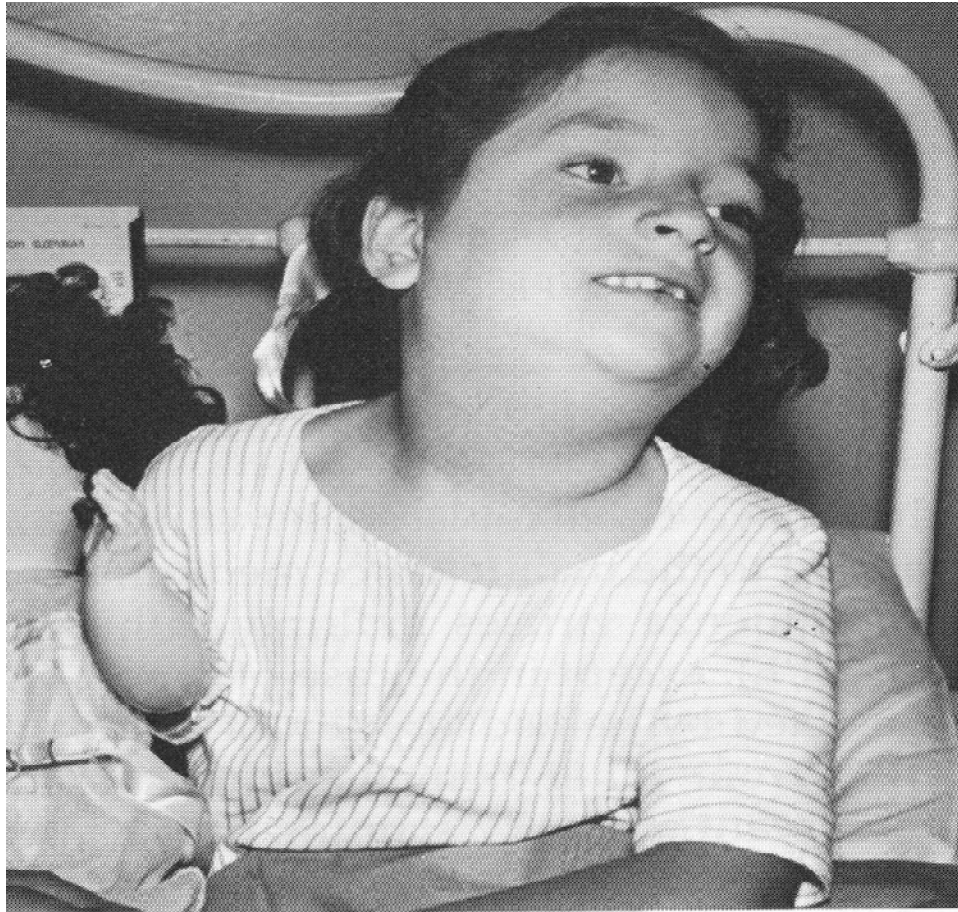

# Keratoconjunctivitis



# Koplik spots





Note swelling of parotid and other salivary glands.

