



ANTONIE VAN LEEUWENHOEK

Born: 24.10.1632 - Died: 26.8.1723
Delft, Holland

This man, born poor, with little education, a draper in his hometown of Delft had surprising visitors! They included great men of science as well as the Royalty like the Tsar Peter the Great, Frederick the Great of Prussia and King James II of England. This was due to his hobby of grinding fine lenses through which he looked at various objects and brought forth the wonder world of small things that none had seen before. He kept clear descriptions and accurate drawings of what he saw and communicated them to the Royal Society in London. A strict check convinced the Society of their authenticity. The unlettered Antonie was elected a Fellow of the Royal Society! The papers sent by him over decades can still be seen in the Philosophical Transactions of the Royal Society.

The discoveries he made are legion. He described the first protozoan pathogen Giardia. He also discovered many types of bacteria, human and animal spermatozoa, and eggs of various animals realizing their importance in reproduction. He could not recognize the significance of the different types of bacteria, and to him, they were just 'little animalcules'. His fault was in being much before the time, for it took two centuries more for people to accept the microbial origin of infectious diseases. But that should not deter us from acknowledging the great contributions made by Leeuwenhoek to Biology and many other branches of Science. He was truly the **Founder of Microbiology**.

Paniker's Textbook of
MEDICAL PARASITOLOGY

Paniker's Textbook of **MEDICAL PARASITOLOGY**

SEVENTH EDITION

CK Jayaram Paniker MD

Formerly

Director and Professor of Microbiology and Principal, Medical College Calicut
Dean, Faculty of Medicine, Calicut University, Kerala, India
Emeritus Medical Scientist
Indian Council of Medical Research, New Delhi, India

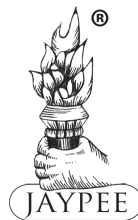Revised and Edited by

Sougata Ghosh MD, DCH

Professor, Department of Microbiology
Medical College, Kolkata, West Bengal, India

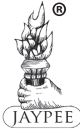Former Faculty

IPGME&R and School of Tropical Medicine, Kolkata, West Bengal, India



JAYPEE BROTHERS MEDICAL PUBLISHERS (P) LTD

New Delhi • London • Philadelphia • Panama



Jaypee Brothers Medical Publishers (P) Ltd

Headquarters

Jaypee Brothers Medical Publishers (P) Ltd
4838/24, Ansari Road, Daryaganj
New Delhi 110 002, India
Phone: +91-11-43574357
Fax: +91-11-43574314
Email: jaypee@jaypeebrothers.com

Overseas Offices

J.P. Medical Ltd
83, Victoria Street, London
SW1H 0HW (UK)
Phone: +44-2031708910
Fax: +02-03-0086180
Email: info@jpmedpub.com

Jaypee Medical Inc
The Bourse
111 South Independence Mall East
Suite 835, Philadelphia, PA 19106, USA
Phone: + 267-519-9789
Email: joe.rusko@jaypeebrothers.com

Jaypee-Highlights Medical Publishers Inc
City of Knowledge, Bld. 237, Clayton
Panama City, Panama
Phone: +507-301-0496
Fax: +507-301-0499
Email: cservice@jphmedical.com

Jaypee Brothers Medical Publishers (P) Ltd
17/1-B Babar Road, Block-B, Shaymali
Mohammadpur, Dhaka-1207
Bangladesh
Mobile: +08801912003485
Email: jaypeedhaka@gmail.com

Jaypee Brothers Medical Publishers (P) Ltd
Shorakhute, Kathmandu
Nepal
Phone: +00977-9841528578
Email: jaypee.nepal@gmail.com

Website: www.jaypeebrothers.com
Website: www.jaypeedigital.com

© 2013, Jaypee Brothers Medical Publishers (P) Ltd

All rights reserved. No part of this book may be reproduced in any form or by any means without the prior permission of the publisher.

Inquiries for bulk sales may be solicited at: jaypee@jaypeebrothers.com

This book has been published in good faith that the contents provided by the author contained herein are original, and is intended for educational purposes only. While every effort is made to ensure accuracy of information, the publisher and the author specifically disclaim any damage, liability, or loss incurred, directly or indirectly, from the use or application of any of the contents of this work. If not specifically stated, all figures and tables are courtesy of the author. Where appropriate, the readers should consult with a specialist or contact the manufacturer of the drug or device.

Paniker's Textbook of Medical Parasitology

First Edition : 1988
Second Edition : 1989, *Reprint* : 1991
Third Edition : 1993,
Fourth Edition : 1997, *Reprint* : 1999
Fifth Edition : 2002, *Reprint* : 2003, 2004
Sixth Edition : 2007, *Reprint* : 2011
***Seventh Edition* : 2013**

ISBN 978-93-5090-534-0

Printed at

Preface to the Seventh Edition

The current edition of this book is written in a new user-friendly format in contrast to the classic narrative style of Dr. Paniker's Textbook of Medical Parasitology that has served medical students and teachers for more than 25 years since 1988.

Considering the advancement in the field of Parasitology, I have updated the text thoroughly, incorporating the recent epidemiological data and new diagnostic methods especially the molecular techniques and current treatment modalities. Almost all chapters have been revised and few new chapters like *Pneumocystis jirovecii*, Microsporidia, and *Balantidium coli* are added.

The main emphasis of the current edition is to make the text more comprehensive, colorful, and student-friendly. Diagrams of life cycle have been redrawn in a manner to facilitate the students reproduce them during examinations. Several new tables, flowcharts, and easy-to-remember boxes are given to equip the students for better answering of theory and oral questions during examinations. More microscopic view pictures, photographs of specimens, and diagnostic images have been added in a manner to favor better visible impressions of parasitic diseases. I have included "Key points" of important parasites in box formats to highlight "must know facts" that are pertinent to the topic.

Important MCQs and review questions carefully selected from various university examination papers have been added to test and reinforce understanding of the topic by the student.

The aim of the book remains to be compact, yet informative, and useful for both undergraduate and postgraduate students.

My endeavor will be successful, if the book is found to be useful for faculty and students.

Expressions and emotions fail to find words to express thanks to my parents. I thank them for being a constant source of inspiration and motivation.

I am grateful to all the colleagues in my department for their valuable suggestions during preparing the texts.

I am especially indebted to the Director and Staff of School of Tropical Medicine, Kolkata for providing mounted specimens.

I gratefully acknowledge the help of Mr Jitendar P. Vij (Group Chairman), Mr Ankit Vij (Managing Director), Mr Tarun Duneja (Director Publishing) and Mr Sabyasachi Hazra for their professional help and guidance during the project.

The insight and skills of Dr Sakshi Arora (Chief Development Editor) along with her team helped in polishing this book to best meet the needs of students and faculty alike.

Lastly I acknowledge the support extended by my family members during revising the book.

All suggestions are welcome and may be emailed to: s_ghosh2006@rediffmail.com

SOUGATA GHOSH

Preface to the First Edition

Parasitic infections continue to account for a large part of human illness. Antimicrobial drugs and vaccines that have made possible the effective control of most bacterial and viral diseases have not been as successful against parasitic infections. The numbers of persons afflicted by parasites run into many millions. Malaria still affects over 500 millions, pinworm and whipworm 500 millions each, hookworm 800 millions and roundworm a billion persons. Filariasis, leishmaniasis and schistosomiasis remain serious public health problems. Infections due to opportunist parasites are becoming increasingly evident in the affluent countries.

In recent years there has been a resurgence in the study of parasitic infections. Much new knowledge has been gained making possible precise diagnosis and more effective control of parasites and the diseases they cause.

This textbook attempts to present the essential information on parasites and parasitic diseases, with emphasis on pathogenesis, epidemiology, diagnosis and control. Every effort has been made to incorporate recent advances in the subject.

It is hoped that medical students, teachers and physicians will find this book useful. Their comments and suggestions for improvement of the book will be most welcome.

SHANTHI, East Hill Road
Calicut, Kerala 673 006

CK JAYARAM PANIKER

Contents

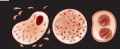	Chapter 1: General Introduction: Parasitology	1–8
	Introduction 1 ; Parasites 1 ; Host 2 ; Zoonosis 2 ; Host-parasite Relationships 3 ; Life Cycle of Parasites 3 ; Sources of Infection 3 ; Modes of Infection 4 ; Pathogenesis 5 ; Immunity in Parasitic Infection 5 ; Laboratory Diagnosis 6	
	Chapter 2: Protozoa	9–13
	General Features 9 ; Structure 9 ; Reproduction 10 ; Life Cycle 11 ; Classification of Protozoa 11 ; Phylum Sarcomastigophora 11 ; Phylum Apicomplexa 12 ; Phylum Ciliophora 12 ; Phylum Microspora 12	
	Chapter 3: Amoebae	14–29
	Entamoeba Histolytica 14 ; History and Distribution 14 ; Morphology 15 ; Life Cycle 16 ; Pathogenesis and Clinical Features 16 ; Extraintestinal Amoebiasis 18 ; Laboratory Diagnosis 20 ; Immunity 22 ; Treatment 22 ; Prophylaxis 23 ; Nonpathogenic Intestinal Amoeba 23 ; Entamoeba Coli 23 ; Entamoeba Hartmanni 24 ; Entamoeba Gingivalis 24 ; Endolimax Nana 24 ; Iodamoeba Buetschlii 25 ; Pathogenic Free-Living Amoebae 25 ; Naegleria Fowleri 25 ; History and Distribution 26 ; Morphology 26 ; Life Cycle 26 ; Pathogenicity and Clinical Features 27 ; Laboratory Diagnosis 27 ; Treatment 27 ; Acanthamoeba Species 27 ; Distribution 27 ; Morphology 27 ; Life Cycle 28 ; Pathogenesis and Clinical Features 28 ; Laboratory Diagnosis 28 ; Treatment 28 ; Balamuthia Mandrillaris 29 ; Morphology 29 ; Clinical Disease 29 ; Laboratory Diagnosis 29	
	Chapter 4: Intestinal, Oral, and Genital Flagellates	30–37
	Giardia Lamblia 30 ; History and Distribution 30 ; Habitat 31 ; Morphology 31 ; Life Cycle 32 ; Pathogenicity and Clinical Features 32 ; Laboratory Diagnosis 33 ; Treatment 33 ; Prophylaxis 33 ; Trichomonas Vaginalis 34 ; Trichomonas Tenax 36 ; Trichomonas Hominis 36 ; Chilomastix Mesnili 36 ; Enteromonas Hominis 36 ; Retortamonas Intestinalis 37 ; Dientamoeba Fragilis 37	
	Chapter 5: Hemoflagellates	38–62
	General Characteristics 38 ; Trypanosomes 39 ; Trypanosoma Brucei Gambiense (West African Trypanosomiasis) 40 ; History and Distribution 40 ; Habitat 40 ; Morphology 40 ; Antigenic Variation 41 ; Life Cycle 41 ; Pathogenicity and Clinical Features 41 ; Trypanosoma Brucei Rhodesiense (East African Trypanosomiasis) 42 ; Pathogenesis and Clinical Feature 43 ; Laboratory Diagnosis 43 ; Treatment 44 ; Prophylaxis 45 ; Trypanosoma Cruzi 45 ; History and Distribution 45 ; Habitat 45 ; Morphology 45 ; Life Cycle 46 ; Pathogenicity and Clinical Features 47 ; Laboratory Diagnosis 47 ; Treatment 49 ; Prophylaxis 49 ; Trypanosoma Rangeli 49 ; Leishmania 49 ; General Characteristics 49 ; Classification 50 ; Old World Leishmaniasis 51 ; Leishmania Donovanii 51 ; History and Distribution 51 ; Habitat 51 ; Morphology 52 ; Life Cycle 52 ; Pathogenicity 54 ; Clinical Features of Kala-Azar 55 ; Post Kala-azar Dermal Leishmaniasis 55 ; Immunity 55 ; Laboratory Diagnosis 55 ; Treatment 58 ; Prophylaxis 59 ; Leishmania Tropica Complex 59 ; History and Distribution 59 ; Habitat 59 ; Morphology 59 ; Life Cycle 59 ; Pathology 60 ; Clinical Features 60 ; Laboratory Diagnosis 60 ; Treatment 61 ; Prophylaxis 61 ; New World Leishmaniasis 61 ; L. braziliensis complex and L. mexicana complex 61 ; History and Distribution 61 ; Habitat 61 ; Morphology 61 ; Life Cycle 61 ; Clinical Features 61 ; Laboratory Diagnosis 61 ; Treatment 62 ; Prophylaxis 62	



Chapter 6: Malaria and Babesia

63–86

Classification **63**; **Malaria Parasite 64**; History and Distribution **64**; Vectors **64**; Life Cycle **65**; Types of Malaria **69**; **Plasmodium Vivax 69**; **Plasmodium Falciparum 69**; **Plasmodium Malariae 71**; **Plasmodium Ovale 73**; **Mixed Infections 73**; Pathogenesis **74**; Clinical Features **76**; Immunity **78**; Recrudescence and Relapse **78**; Laboratory Diagnosis **79**; Treatment of Uncomplicated Malaria **82**; Treatment of Complicated (Falciparum) Malaria **82**; Prophylaxis **83**; **Babesia Species 83**; Classification **83**; History and Distribution **84**; Habitat **84**; Morphology **84**; Life Cycle **84**; Pathogenicity and Clinical Features **84**; Laboratory Diagnosis **85**; Treatment **85**; Prophylaxis **85**



Chapter 7: Coccidia

87–99


Toxoplasma Gondii 87; History and Distribution **87**; Morphology **87**; Life Cycle **89**; Pathogenicity and Clinical Features **90**; Host Immunity **91**; Laboratory Diagnosis **91**; Treatment **92**; Prophylaxis **93**; **Isospora Belli 93**; History and Distribution **93**; Morphology **93**; Life Cycle **93**; Clinical Features **94**; Laboratory Diagnosis **94**; Treatment **94**; **Cryptosporidium Parvum 94**; History and Distribution **94**; Habitat **95**; Morphology **95**; Life Cycle **95**; Pathogenicity and Clinical Features **95**; Laboratory Diagnosis **96**; Treatment **97**; **Cyclospora Cayetanensis 97**; Morphology **97**; Life Cycle **97**; Pathogenicity and Clinical features **98**; Diagnosis **98**; Treatment **98**; **Blastocystis Hominis 98**; Habitat **98**; Morphology **98**; Pathogenicity and Clinical Features **98**; Diagnosis **98**; Treatment **98**; **Sarcocystis 98**; Clinical Features **99**; Laboratory Diagnosis **99**; Treatment **99**; Prophylaxis **99**



Chapter 8: Microspora

100–102

History and Distribution **100**; Morphology **101**; Life Cycle **101**; Clinical Features **101**; Laboratory Diagnosis **102**; Treatment **102**; Prophylaxis **102**



Chapter 9: Pneumocystis Jirovecii

103–106

History and Distribution **103**; Habitat **103**; Morphology **103**; Life cycle **104**; Pathogenesis **104**; Clinical Features **104**; Laboratory Diagnosis **105**; Treatment **105**; Prophylaxis **106**



Chapter 10: Balantidium Coli

107–109

History and Distribution **107**; Habitat **107**; Morphology **107**; Life Cycle **108**; Pathogenesis **108**; Clinical Features **109**; Laboratory Diagnosis **109**; Treatment **109**; Prophylaxis **109**



Chapter 11: Helminths: General Features

110–112

Introduction **110**; Phylum Platyhelminthes **110**; Class Cestoda **110**; Class Trematoda **110**; Phylum Nematelminthes (Nematoda) **110**; Important Features of Helminths **111**; Larval Forms **111**; Multiplication **111**; Zoological Classification of Helminths **112**; Phylum Platyhelminthes **112**; Phylum Nematelminthes **112**



Chapter 12: Cestodes: Tapeworms

113–137

Classification of Cestodes **113**; Tapeworms: General Characteristics **113**; Life Cycle **114**; **Pseudophyllidean Tapeworms 115**; **Diphyllobothrium Latum 115**; History and Distribution **115**; Habitat **115**; Morphology **116**; Life Cycle **116**; Pathogenicity and Clinical Features **118**; Laboratory Diagnosis **118**; Treatment **118**; Prophylaxis **118**; **Spirometra 118**; Distribution **119**; Habitat **119**; Life Cycle **119**; **Sparganosis 120**; Laboratory Diagnosis **120**; Treatment **120**; Prophylaxis **120**; **Cyclophyllidean Tapeworms 120**; **Taenia Saginata and Taenia Solium 120**; History and Distribution **120**; Habitat **120**; Morphology **120**; Life Cycle of Taenia Saginata **122**; Life Cycle of Taenia Solium **123**; Pathogenicity and Clinical Features **124**; Laboratory Diagnosis **125**; Laboratory Diagnosis of Cysticercosis **125**; Treatment **126**; Prophylaxis **126**; **Taenia Saginata**

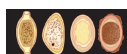Asiatica 127; Multiceps Multiceps (Taenia Multiceps) 127; Echinococcus Granulosus 127; History and Distribution **127;** Habitat **127;** Morphology **127;** Life Cycle **128;** Pathogenesis **128;** Clinical Features **130;** Laboratory Diagnosis **131;** Treatment **133;** Prophylaxis **133;** **Echinococcus Multilocularis 134; Hymenolepis Nana 134;** History and Distribution **134;** Habitat **134;** Morphology **134;** Life Cycle **135;** Clinical Features **135;** Laboratory Diagnosis **135;** Treatment **136;** Prophylaxis **136;** **Hymenolepis Diminuta 137; Dipylidium Caninum 137;** Morphology **137;** Life Cycle **137;** Clinical Features **137;** Diagnosis **137;** Treatment **137**



Chapter 13: Trematodes: Flukes

138–160

Classification of Trematodes **138;** Flukes: General Characteristics **139;** Life Cycle **139;** **Blood Flukes 140;** Schistosomes **140;** **Schistosoma Haematobium 141;** History and Distribution **141;** Habitat **141;** Morphology **141;** Life Cycle **142;** Pathogenicity and Clinical Features **142;** Laboratory Diagnosis **144;** Treatment **145;** Prophylaxis **145;** **Schistosoma Mansoni 145;** History and Distribution **145;** Habitat **145;** Morphology **145;** Life Cycle **145;** Pathogenicity and Clinical Features **146;** Laboratory Diagnosis **146;** Treatment **146;** Prophylaxis **146;** **Schistosoma Japonicum 146;** Distribution **146;** Habitat **146;** Morphology **146;** Life Cycle **147;** Pathogenicity and Clinical Features **147;** Laboratory Diagnosis **148;** Treatment **148;** Prophylaxis **148;** **Schistosoma Intercalatum 148;** **Schistosoma Mekongi 148;** Hermaphroditic Flukes: **Liver Flukes 148;** **Clonorchis Sinensis 148;** History and Distribution **148;** Habitat **148;** Morphology **148;** Life Cycle **149;** Pathogenicity **149;** Diagnosis **149;** Treatment **149;** Prophylaxis **150;** **Opisthorchis Species 150;** **Fasciola Hepatica 151;** History and Distribution **151;** Habitat **151;** Morphology **151;** Life Cycle **151;** Pathogenicity **152;** Diagnosis **153;** Treatment **153;** Prophylaxis **153;** **Dicrocoelium Dendriticum 153;** **Intestinal flukes 154;** **Fasciolopsis Buski 154;** History and Distribution **154;** Habitat **154;** Morphology **154;** Life Cycle **154;** Pathogenesis **155;** Laboratory Diagnosis **156;** Treatment **156;** Prophylaxis **156;** **Heterophyes 156;** **Metagonimus Yokogawai 156;** **Watsonius Watsoni 156;** **Echinostoma 156;** **Gastrodiscoides Hominis 156;** **Lung Flukes 157;** **Paragonimus Westermani 157;** History and Distribution **157;** Morphology **157;** Habitat **157;** Life Cycle **158;** Pathogenicity and Clinical Features **159;** Laboratory Diagnosis **159;** Treatment **159;** Prophylaxis **159**



Chapter 14: Nematodes: General Features

161–166

General Characteristics **161;** Life Cycle **162;** Modes of Infection **162;** Classification **162;** Larva Migrans **162;** Cutaneous Larva Migrans **164;** Visceral Larva Migrans **165**



Chapter 15: Trichinella Spiralis

167–171

History and Distribution **167;** Habitat **167;** Morphology **167;** Life Cycle **168;** Pathogenicity and Clinical Features **169;** Diagnosis **169;** Treatment **171;** Prophylaxis **171**



Chapter 16: Trichuris Trichiura

172–175

History and Distribution **172;** Habitat **172;** Morphology **172;** Life Cycle **173;** Pathogenicity and Clinical Features **174;** Laboratory Diagnosis **175;** Treatment **175;** Prophylaxis **175**



Chapter 17: Strongyloides Stercoralis

176–181

History and Distribution **176;** Habitat **176;** Morphology **176;** Life Cycle **178;** Pathogenicity and Clinical Features **180;** Laboratory Diagnosis **180;** Treatment **181;** Prophylaxis **181**



Chapter 18: Hookworm

182–189

History and Distribution **182;** **Ancylostoma Duodenale 182;** Habitat **182;** Morphology **183;** Life Cycle **184;** **Necator Americanus 186;** Morphology **186;** Pathogenicity and Clinical Features **186;** Laboratory Diagnosis **186;** Treatment **187;** Prophylaxis **187;** Other Hookworms **188;** **Trichostrongyliasis 188**



Chapter 19: Enterobius Vermicularis

190–194

History and Distribution **190**; Habitat **190**; Morphology **190**; Life Cycle **191**; Pathogenicity and Clinical Features **192**; Laboratory Diagnosis **193**; Treatment **194**; Prophylaxis **194**



Chapter 20: Ascaris Lumbricoides

195–202

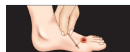History and Distribution **195**; Habitat **195**; Morphology **195**; Life Cycle **197**; Pathogenicity and Clinical Features **197**; Laboratory Diagnosis **199**; Treatment **200**; Prophylaxis **200**; Other Roundworms **201**; **Toxocara 201**; **Baylisascaris 201**



Chapter 21: Filarial Worms

203–219

Lymphatic Filariasis 205; **Wuchereria Bancrofti 205**; History and Distribution **205**; Habitat **206**; Morphology **206**; Life Cycle **207**; Pathogenesis **209**; Laboratory Diagnosis **210**; Treatment **213**; Prophylaxis **213**; **Brugia Malayi 214**; History and Distribution **214**; Morphology **214**; Life Cycle **215**; **Brugia Timori 215**; **Subcutaneous Filariasis 216**; **Loa Loa 216**; History and distribution **216**; Morphology **216**; Life cycle **216**; Pathogenicity and Clinical Features **216**; Laboratory Diagnosis **216**; Treatment **216**; **Onchocerca Volvulus 217**; History and Distribution **217**; Habitat **217**; Morphology **217**; Life Cycle **217**; Pathogenicity and Clinical Features **217**; Laboratory Diagnosis **218**; Prophylaxis **218**; Treatment **218**; **Mansonella Streptocerca 218**; **Serous Cavity Filariasis 219**; **Mansonella Ozzardi 219**; **Mansonella Perstans 219**; **Zoonotic Filariasis 219**; **Brugia Pahangi 219**; **Dirofilaria Immitis 219**; **Dirofilaria Repens 219**



Chapter 22: Dracunculus Medinensis

220–224

History and Distribution **220**; Habitat **220**; Morphology **220**; Life Cycle **221**; Pathogenicity and Clinical Features **223**; Laboratory Diagnosis **223**; Treatment **223**; Prophylaxis **224**



Chapter 23: Miscellaneous Nematodes

225–228

Angiostrongylus Cantonensis 225; History and Distribution **225**; Habitat **225**; Morphology **225**; Life Cycle **225**; Clinical Features **226**; Diagnosis **226**; Treatment **226**; **Capillaria Philippinensis 226**; History and Distribution **226**; Habitat **226**; Life Cycle **226**; Clinical Features **226**; Diagnosis **226**; Treatment **226**; **Gnathostoma Spinigerum 226**; History and Distribution **226**; Morphology **226**; Life Cycle **226**; Clinical Features **227**; Diagnosis **227**; Treatment **227**; **Anisakiasis 227**; Life Cycle **227**; Clinical Features **227**; Treatment **228**; Prophylaxis **228**



Chapter 24: Diagnostic Methods in Parasitology

229–243

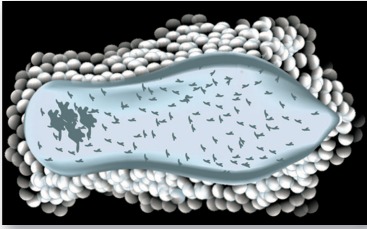
Introduction **229**; Examination of Stool **229**; Examination of Blood **235**; Examination for Malarial Parasites **235**; Examination for Microfilaria **237**; Sputum Examination **238**; Urine or Body Fluids Examination **238**; Tissue Biopsy **238**; Muscle Biopsy **239**; Culture Methods **239**; Animal Inoculation **241**; Xenodiagnosis **241**; Immunological Diagnosis **241**; Serology **241**; Skin Tests **242**; Molecular Methods **243**

Multiple Choice Questions

245–259

Index

261–266



General Introduction: Parasitology

1

Introduction

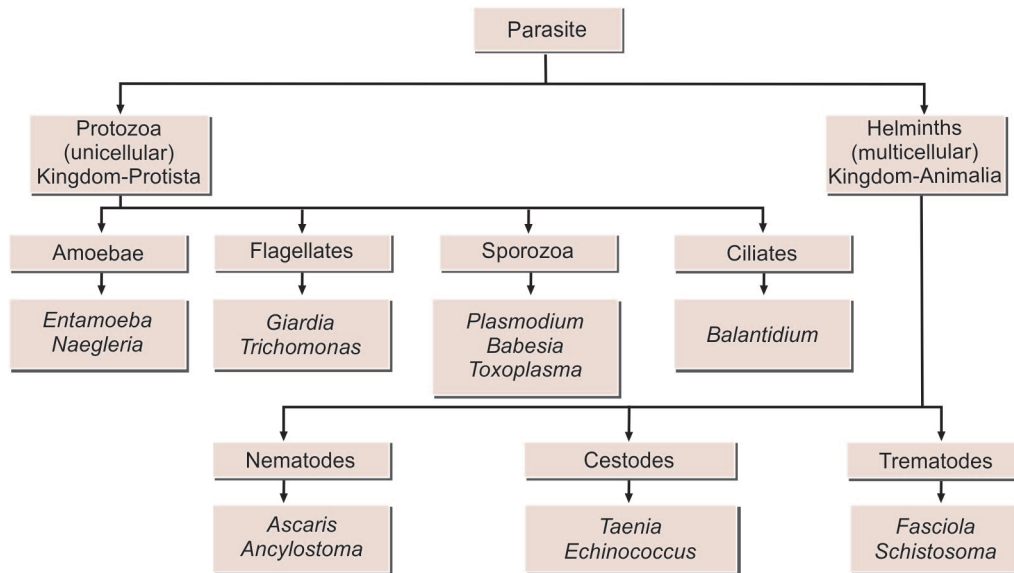
Medical parasitology deals with the parasites, which cause human infections and the diseases they produce.

- It is broadly divided into 2 parts—
 - Protozoology
 - Helminthology.
- The pioneer Dutch microscopist, **Antonie von Leeuwenhoek of Holland** in 1681, first introduced single lens microscope and observed *Giardia* in his own stools.
- **Louis Pastuer** in 1870, first published scientific study on a protozoal disease leading to its control and prevention during investigation of an epidemic silk worm disease in South Europe.
- A seminal discovery was made in 1878 by **Patrick Manson** about the role of mosquitoes in filariasis. This was the first evidence of vector transmission.
- Afterwards, **Laveran** in Algeria discovered the malarial parasite (1880), and **Ronald Ross** in Secunderabad and Calcutta in India, showed its transmission by mosquitoes (1897). A large number of vector-borne diseases have since then been identified.
- By mid-twentieth century, with dramatic advances in antibiotics and chemotherapy, insecticides and antiparasitic drugs, and improved lifestyles, all infectious diseases seemed amenable to control.

Parasites

Parasites are living organisms, which depend on a living host for their nourishment and survival. They multiply or undergo development in the host.

- The term '**parasite**' is usually applied to **Protozoa** (unicellular organisms) and **Helminths** (multicellular organisms) (Flowchart 1.1).
- Parasites can also be classified as:
 - **Ectoparasite:** Ectoparasites inhabit only the body surface of the host without penetrating the tissue. Lice, ticks, and mites are examples of ectoparasites. The term **infestation** is often employed for parasitization with ectoparasites.
 - **Endoparasite:** A parasite, which lives within the body of the host and is said to cause an infection is called an endoparasite. Most of the protozoan and helminthic parasites causing human disease are endoparasites.
 - **Free-living parasite:** It refers to nonparasitic stages of active existence, which live independent of the host, e.g. cystic stage of *Naegleria floweri*.
- Endoparasites can further be classified as:
 - **Obligate parasite:** The parasite, which cannot exist without a host, e.g. *Toxoplasma gondii* and *Plasmodium*.



Flowchart 1.1: Type of parasites

- **Facultative parasite:** Organism which may either live as parasitic form or as free living form.
- **Accidental parasites:** Parasites, which infect an unusual host are known as accidental parasites. *Echinococcus granulosus* infects man accidentally, giving rise to hydatid cysts.
- **Aberrant parasites:** Parasites, which infect a host where they cannot develop further are known as aberrant or wandering parasites, e.g. *Toxocara canis* (dog roundworm) infecting humans.

Host

Host is defined as an organism, which harbors the parasite and provides nourishment and shelter to latter and is relatively larger than the parasite.

- The host may be of the following types:
 - **Definitive host:** The host, in which the adult parasite lives and undergoes sexual reproduction is called the definitive host, e.g. mosquito acts as definitive host in malaria. The definitive host may be a human or any other living being. However, in majority of human parasitic infections, man is the definitive host (e.g. filaria, roundworm, hookworm).
 - **Intermediate host:** The host, in which the larval stage of the parasite lives or asexual multiplication takes place is called the intermediate host. In some parasites, 2 different intermediate hosts may be required to complete different larval stages. These

are known as **first and second intermediate hosts**, respectively.

- **Paratenic host:** A host, in which larval stage of the parasite remains viable without further development is referred as a paratenic host. Such host transmits the infection to another host.
- **Reservoir host:** In an endemic area, a parasitic infection is continuously kept up by the presence of a host, which harbors the parasite and acts as an important source of infection to other susceptible hosts, e.g. dog is the reservoir host of hydatid disease.
- **Accidental host:** The host, in which the parasite is not usually found, e.g. man is an accidental host for cystic echinococcosis.



Parasites with man as intermediate or secondary host

- *Plasmodium* spp.
- *Babesia* spp.
- *Toxoplasma gondii*
- *Echinococcus granulosus*
- *Echinococcus multilocularis*
- *Taenia solium*
- *Spirometra* spp.

Zoonosis

The word **zoonosis** was introduced by Rudolf Virchow in 1880 to include the diseases shared in nature by man and animals.

- Later, in 1959, the World Health Organization (WHO) defined zoonosis as “those diseases and infections, which are naturally transmitted between vertebrate animals and man”.
- It is of following types:
 - **Protozoal zoonoses**, e.g. toxoplasmosis, leishmaniasis, balantidiasis, and cryptosporidiasis
 - **Helminthic zoonoses**, e.g. hydatid disease, taeniasis
 - **Anthropozoonoses**: Infections transmitted to man from lower vertebrate animals, e.g. cystic echinococcosis
 - **Zoanthropozoonoses**: Infections transmitted from man to lower vertebrate animals, e.g. human tuberculosis to cattle.

Host-parasite Relationships

Host-parasite relationships are of following types (Flowchart 1.2):

- Symbiosis
- Commensalism
- Parasitism.

Life Cycle of Parasites

- **Direct life cycle**: When a parasite requires only single host to complete its development, it is called as direct life cycle, e.g. *Entamoeba histolytica* requires only a human host to complete its life cycle.
- **Indirect life cycle**: When a parasite requires 2 or more species of host to complete its development, the life cycle is called as indirect life cycle, e.g. malarial parasite requires both human host and mosquito to complete its life cycle.

Sources of Infection

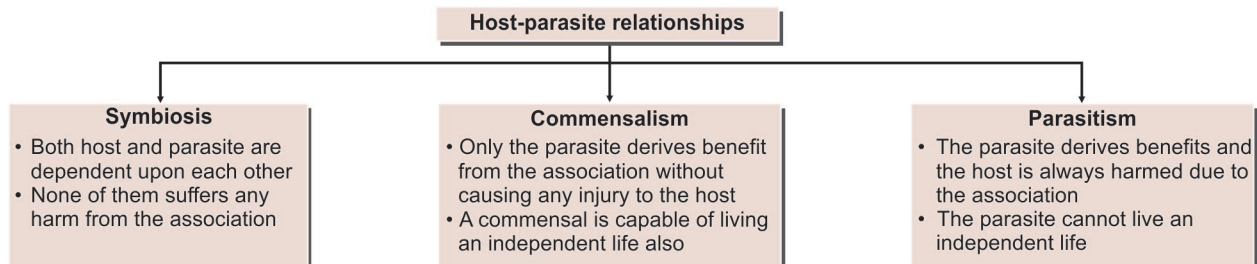
- **Contaminated soil and water**:
 - Soil polluted with embryonated eggs (roundworm, whipworm) may be ingested or infected larvae in soil, may penetrate exposed skin (hookworm)

Parasites having direct life cycle

Protozoa	Helminths
• <i>Entamoeba histolytica</i>	• <i>Ascaris lumbricoides</i>
• <i>Giardia lamblia</i>	• <i>Enterobius vermicularis</i>
• <i>Trichomonas vaginalis</i>	• <i>Trichuris trichiura</i>
• <i>Balantidium coli</i>	• <i>Ancylostoma duodenale</i>
• <i>Cryptosporidium parvum</i>	• <i>Necator americanus</i>
• <i>Cyclospora cayetanensis</i>	• <i>Hymenolepis nana</i>
• <i>Isospora belli</i>	
• <i>Microsporidia</i>	

Parasites having indirect life cycle

Parasite	Definitive host	Intermediate host
Protozoa		
<i>Plasmodium</i> spp.	Female Anopheles mosquito	Man
<i>Babesia</i>	Tick	Man
<i>Leishmania</i>	Man, dog	Sandfly
<i>Trypanosoma brucei</i>	Man	Tsetse fly
<i>Trypanosoma cruzi</i>	Man	Triatomine bug
<i>Toxoplasma gondii</i>	Cat	Man
Cestodes		
<i>Taenia solium</i>	Man	Pig
<i>Taenia saginata</i>	Man	Cattle
<i>Echinococcus granulosus</i>	Dog	Man
Trematodes		
<i>Fasciola hepatica</i>	Man	Snail
<i>Fasciolopsis buski</i>	Man, pig	Snail
<i>Schistosoma</i> spp.	Man	Snail
Nematodes		
<i>Trichinella spiralis</i>	Man	Pig
<i>Wuchereria bancrofti</i>	Man	Mosquito
<i>Brugia malayi</i>	Man	Mosquito
<i>Dracunculus medinensis</i>	Man	Cyclops



Flowchart 1.2: Host-parasite relationships

- Infective forms of parasites present in water may be ingested (cyst of amoeba and *Giardia*)
- Water containing the intermediate host may be swallowed (cyclops containing guineaworm larva)
- Infected larvae in water may enter by penetrating exposed skin, (cercariae of schistosomes)
- Free-living parasites in water may directly enter through vulnerable sites (*Naegleria* may enter through nasopharynx).
- **Food:**
 - Ingestion of contaminated food or vegetables containing infective stage of parasite (amoebic cysts, *Toxoplasma* oocysts, *Echinococcus* eggs)
 - Ingestion of raw or under-cooked meat harboring infective larvae (measly pork containing cysticercus cellulosae, the larval stage of *Taenia solium*).
- **Insect vectors:** A vector is an agent, usually an arthropod that transmits an infection from man to man or from other animals to man, e.g. female *Anopheles* is the vector of malarial parasite.

Vectors can be:

 - **Biological vectors:** The term biological vector refers to a vector, which not only assists in the transfer of parasites but the parasites undergo development or multiplication in their body as well. They are also called as **true vectors**. Example of true vectors are:
 - Mosquito—Malaria, filariasis
 - Sandflies—Kala-azar
 - Tsetse flies—Sleeping sickness
 - Reduviid bugs—Chagas' disease
 - Ticks—Babesiosis.
 - **Mechanical vectors:** The term mechanical vector refers to a vector, which assists in the transfer of parasitic form between hosts but is not essential in the life cycle of the parasite. Example of Mechanical vectors is:
 - Housefly—amoebiasis

In biological vectors, a certain period has to elapse after the parasite enters the vector, before it becomes infective. This is necessary because the vector can transmit the infection only after the parasite multiplies to a certain level or undergoes a developmental process in its body. This interval between the entry of the parasite into the vector and the time it takes to become capable of transmitting the infection is called the *extrinsic incubation period*.

- **Animals:**
 - Domestic:
 - Cow, e.g. *T. saginata*, *Sarcocystis*
 - Pig, e.g. *T. solium*, *Trichinella spiralis*
 - Dog, e.g. *Echinococcus granulosus*

- Cat, e.g. *Toxoplasma*, *Opisthorochis*.
- Wild:
 - Wild game animals, e.g. trypanosomiasis
 - Wild felines, e.g. *Paragonimus westermani*
 - Fish, e.g. fish tapeworm
 - Molluscs, e.g. liver flukes
 - Copepods, e.g. guineaworm.
- **Other persons**, which may be carriers of the parasite or patients, e.g. all anthroponotic infections, vertical transmission of congenital infections.
- **Self (autoinfection)**
 - Finger-to-mouth transmission, e.g. pinworm
 - Internal reinfection, e.g. *Strongyloides*.



Parasites causing autoinfection

- *Hymenolepis nana*
- *Enterobius vermicularis*
- *Taenia solium*
- *Strongyloides stercoralis*
- *Capillaria philippinensis*
- *Cryptosporidium parvum*

Modes of Infection

- **Oral transmission:** The most common method of transmission is through oral route by contaminated food, water, soiled fingers, or fomites. Many intestinal parasites enter the body in this manner, the infective stages being cysts, embryonated eggs, or larval forms. Infection with *E. histolytica* and other intestinal protozoa occurs when the infective cysts are swallowed.
- **Skin transmission:** Entry through skin is another important mode of transmission. Hookworm infection is acquired, when the larvae enter the skin of persons walking barefooted on contaminated soil. Schistosomiasis is acquired when the cercarial larvae in water penetrate the skin
- **Vector transmission:** Many parasitic diseases are transmitted by insect bite, e.g., malaria is transmitted by bite of female *Anopheles* mosquito, filariasis is transmitted by bite of *Culex* mosquito. A vector could be a biological vector or a mechanical vector.
- **Direct transmission:** Parasitic infection may be transmitted by person-to-person contact in some cases, e.g. by kissing in the case of gingival amoebae and by sexual intercourse in trichomoniasis.
- **Vertical transmission:** Mother to fetus transmission may take place in malaria and toxoplasmosis.
- **Iatrogenic transmission:** It is seen in case of transfusion malaria and toxoplasmosis after organ transplantation.

Pathogenesis

Parasitic infections may remain inapparent or give rise to clinical disease. A few organisms, such as *E. histolytica* may live as surface commensals, without invading the tissue.

- Clinical infection produced by parasite may take many forms—acute, subacute, chronic, latent, or recurrent.
- Pathogenic mechanisms, which can occur in parasitic infections are:
 - **Lytic necrosis:** Enzymes produced by some parasite can cause lytic necrosis. *E. histolytica* lyses intestinal cells and produces amoebic ulcers.
 - **Trauma:** Attachment of hookworms on jejunal mucosa leads to traumatic damage of villi and bleeding at the site of attachment.
 - **Allergic manifestations:** Clinical illness may be caused by host immune response to parasitic infection, e.g. eosinophilic pneumonia in *Ascaris* infection and anaphylactic shock in rupture of hydatid cyst.
 - **Physical obstruction:** Masses of roundworm cause intestinal obstruction. *Plasmodium falciparum* malaria may produce blockage of brain capillaries in cerebral malaria.
 - **Inflammatory reaction:** Clinical illness may be caused by inflammatory changes and consequent fibrosis e.g. lymphadenitis in filariasis and urinary bladder granuloma in *Schistosoma haematobium* infection.
 - **Neoplasia:** A few parasitic infection have been shown to lead to malignancy. The liver fluke, *Clonorchis* may induce bile duct carcinoma, and *S. haematobium* may cause urinary bladder cancer.

Immunity in Parasitic Infection

Like other infectious agents, parasites also elicit immunoresponses in the host, both humoral as well as cellular (Fig. 1.1). But immunological protection against parasitic infections is much less efficient, than it is against bacterial or viral infections. Several factors may contribute to this.

- Compared to bacteria and viruses, parasites are enormously larger or more complex structurally and antigenically, so that immune system may not be able to focus attack on the protective antigens.
- Many protozoan parasites are intracellular in location, and this protects them from immunological attack. Several protozoa and helminths live inside body cavities. This location limits the efficiency of immunological attack.

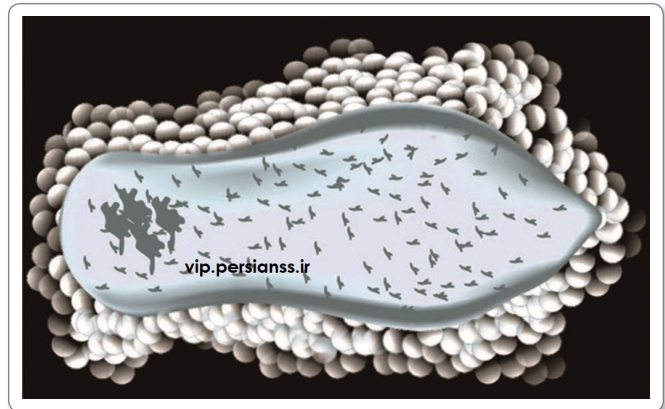


Fig. 1.1: Eosinophils surrounding schistosomulum (An example of immune attack in bloodstream)

- Once the parasitic infection is completely eliminated, the host becomes again susceptible to reinfection. This type of immunity to reinfection is dependent on the continued presence of residual parasite population and is known as '**Premunition**'.
- Antibodies belonging to different immunoglobulin classes are produced in response to parasitic infections. Selective tests for IgM are helpful in differentiating current infections from old infections.
- Excessive IgE response occurs in helminthiasis. A characteristic cellular response in helminth parasite is eosinophilia both local and systemic (Fig. 1.1).
- Parasites have evolved to be closely adapted to the host and most parasitic infections are chronic and show a degree of host specificity. For example, malarial parasites of human, bird, and rodents are confined to their own particular species.
- Parasites like trypanosomes exhibit antigenic variation within the host. This genetic switch protects them from antibodies. Similar mechanism may be operative in the recrudescences in human malaria.



Parasites exhibiting antigenic variations

- *Trypanosoma brucei gambiense*
- *Trypanosoma brucei rhodesiense*
- *Plasmodium* spp.
- *Giardia lamblia*

- Some parasites adopt antigenic disguise. Their surface antigens are so closely similar to host components that they are not recognized as foreign by the immune system.
- Some infections may produce immunodeficiency due to extensive damage to the reticuloendothelial system, as in case of visceral leishmaniasis.

Table 1.1: Parasite Escape Mechanisms

Parasite escape mechanisms	Example
Intracellular habitat	Malarial parasite, <i>Leishmania</i>
Encystment	<i>Toxoplasma</i> <i>Trypanosoma cruzi</i>
Resistance to microbial phagocytosis	<i>Leishmania</i>
Masking of antigens	Schistosomes
Variation of antigen	Trypanosomes <i>Plasmodium</i> spp.
Suppression of immune response	<i>Trichinella spiralis</i>
Malarial parasite	<i>Schistosoma mansoni</i>
Interference by polyclonal activation	Trypanosomes
Sharing of antigens between parasite and host-molecular mimicry	Schistosomes
Continuous turnover and release of surface antigens of parasite	Schistosomes

The fact that immunity normally plays an important role in the containment of parasitic infections is illustrated by the florid manifestations caused by opportunistic parasites such as *Pneumocystis jirovecii* and *T. gondii*, when the immune response is inadequate as in acquired immunodeficiency syndrome (AIDS) and other immunodeficiencies.

Immune Evasion

All animal pathogens, including parasitic protozoa and worms have evolved effective mechanism to avoid elimination by the host defence system as described in Table 1.1.

Vaccination

No effective vaccine for humans has so far been developed against parasites due to their complex life cycles, adaptive responses, and antigenic variation, great progress has been

made in identifying protective antigens in malaria and some other infections, with a view to eventual development of prophylactic vaccines.

Laboratory Diagnosis

Most of the parasitic infection cannot be conclusively diagnosed. On the basis of clinical features and physical examination laboratory diagnosis depends upon:

- Microscopy
- Culture
- Serological test
- Skin test
- Molecular method
- Animal inoculation
- Xenodiagnosis
- Imaging
- Hematology.

Microscopy

An appropriate clinical specimen should be collected for definitive diagnosis of parasitic infections.

- Following specimens are usually examined to establish a diagnosis:
 - Stool
 - Blood
 - Urine
 - Sputum
 - Cerebrospinal fluid (CSF)
 - Tissue and aspirates
 - Genital specimens.

Stool Examination

Examination of stool is very important for the detection of intestinal infections like *Giardia*, *Entamoeba*, *Ascaris*, *Ancylostoma*, etc.

Table 1.2: Parasites and Their Developmental Stages Found in Stool

Cysts/Trophozoites	Eggs	Larvae	Adult worms
<i>Entamoeba histolytica</i> <i>Giardia lamblia</i> <i>Balantidium coli</i> <i>Sarcocystis</i> spp. <i>Isospora belli</i> <i>Cyclospora cayatanensis</i> <i>Cryptosporidium parvum</i>	CESTODES <i>Taenia</i> spp. <i>Hymenolepis nana</i> <i>Hymenolepis diminuta</i> <i>Dipylidium caninum</i> <i>Diphyllobothrium latum</i> TREMATODES <i>Schistosoma</i> spp. <i>Fasciolopsis buski</i> <i>Fasciola hepatica</i> <i>Fasciola gigantica</i> <i>Clonorchis sinensis</i>	<i>Gastrodiscoides hominis</i> <i>Heterophyes heterophyes</i> <i>Metagonimus yokogawai</i> <i>Opisthorchis</i> spp. NEMATODES <i>Trichuris trichiura</i> <i>Enterobius vermicularis</i> <i>Ascaris lumbricoides</i> <i>Ancylostoma duodenale</i> <i>Necator americanus</i> <i>Trichostrongylus orientalis</i>	<i>Strongyloides stercoralis</i> <i>Taenia solium</i> <i>Taenia saginata</i> <i>Diphyllobothrium latum</i> <i>Ascaris lumbricoides</i> <i>Enterobius vermicularis</i> <i>Trichinella spiralis</i>

Cysts and trophozoites of *E. histolytica*, *G. lamblia* can be demonstrated in feces. Eggs of roundworm and tapeworm are also found in stool. The larvae are found in the feces in *S. stercoralis* infection (Table 1.2).

For further details refer to Chapter 24.

Blood Examination

Examination of blood is of vital importance for demonstrating parasites which circulate in blood vessels (Table 1.3). Malarial parasite is confirmed by demonstration of its morphological stages in the blood.

Table 1.3: Parasites Found in Peripheral Blood Film

Protozoa	Nematodes
<ul style="list-style-type: none"> • <i>Plasmodium</i> spp. • <i>Babesia</i> spp. • <i>Trypanosoma</i> spp. • <i>Leishmania</i> spp. 	<ul style="list-style-type: none"> • <i>Wuchereria bancrofti</i> • <i>Brugia malayi</i> • <i>Loa loa</i> • <i>Mansonella</i> spp.

Urine Examination

The characteristic lateral-spined eggs of *S. haematobium* and trophozoites of *T. vaginalis* can be detected in urine. Microfilaria of *W. bancrofti* are often demonstrated in the chylous urine.



Parasites found in urine

- *Schistosoma haematobium*
- *Wuchereria bancrofti*
- *Trichomonas vaginalis*

Sputum Examination

The eggs of *P. westermani* are commonly demonstrated in the sputum specimen. Occasionally, larval stages of *S. stercoralis* and *A. lumbricoides* may also be found in sputum.

Cerebrospinal Fluid Examination

Some protozoa like *T. brucei*, *Naegleria*, *Acanthamoeba*, *Balamuthia*, and *Angiostrongylus* can be demonstrated in the CSF.

Tissue and Aspirates Examination

The larvae of *Trichinella* and eggs of *Schistosoma* can be demonstrated in the muscle biopsy specimens. By histopathological examination of brain, *Naegleria* and *Acanthamoeba* can be detected. In Kala-azar, Leishman-Donovan (LD) bodies can be demonstrated in spleen and bone marrow aspirate. Trophozoites of *Giardia* can be demonstrated

in intestinal aspirates. Trophozoites of *E. histolytica* can be detected in liver pus in cases of amoebic liver abscess.

Genital Specimen Examination

Trophozoites of *T. vaginalis* are found in the vaginal and urethral discharge. Eggs of *E. vermicularis* are found in anal swabs.

Culture

Some parasites like *Leishmania*, *Entamoeba*, and *Trypanosoma* can be cultured in the laboratory in various axenic and polyxenic media.

Serological Tests

Serological tests are helpful for the detection and surveillance of many protozoal and helminthic infections. These tests are basically of 2 types:

- Tests for antigen detection,
- Tests for antibody detection.

Antigen Detection

Malaria antigen like *P. falciparum* lactate dehydrogenase (pLDH) and histidine-rich protein 2 (HRP-2) are detected by rapid immunochromatographic test. Filariar antigens are detected in current infection by enzyme-linked immunosorbent assay (ELISA) (Table 1.4).

Table 1.4: Antigen Detection in Parasitic Diseases

• Galactose lectin antigen	<i>Entamoeba histolytica</i>
• Giardia specific antigen 65	<i>Giardia lamblia</i>
• WKK and rk39 antigen	<i>Leishmania donovani</i>
• HRP-2 antigen	<i>Plasmodium falciparum</i>
• Vivax specific pLDH	<i>Plasmodium vivax</i>
• 200 KD Ag and OG4C3 antigen	<i>Wuchereria bancrofti</i>

Antibody Detection

The following antibody detection procedures are useful in detecting various parasitic infection like amoebiasis, echinococcosis, and leishmaniasis in man:

- Complement fixation test (CFT)
- Indirect hemagglutination (IHA)
- Indirect immunofluorescent antibody test (IFA)
- Rapid immunochromatography test
- ELISA test.

Skin Test

Skin tests are performed by injecting parasitic antigen intradermally and observing the reaction. In immediate

hypersensitivity reaction, wheal and flare response is seen within 30 minutes of infection, whereas erythema and induration seen after 48 hours of injection is called as delayed hypersensitivity reaction.



Important Skin tests done in parasitology

- Casoni's test done in Hydatid disease
- Montenegro test or Leishmanin test done in Kala-azar
- Frenkel's test done in Toxoplasmosis
- Fairley's test done in Schistosomiasis
- Bachman intradermal test done in Trichinellosis

Molecular Diagnosis

Molecular method most frequently used to diagnose human parasitic infection are DNA probes, polymerase chain reaction (PCR), and microarray technique. These tests are very sensitive and specific.

Animal Inoculation

It is useful for the detection of *Toxoplasma*, *Trypanosoma*, and *Babesia* from the blood and other specimens.

Xenodiagnosis

Some parasitic infection like Chagas' disease caused by *T. cruzi* can be diagnosed by feeding the larvae of reduviid bugs with patients blood and then detection of amastigotes of *T. cruzi* in their feces.

Imaging

Imaging procedures like X-ray, ultrasonography (USG) computed tomography (CT) scan and magnetic resonance Imaging (MRI) are now being extensively used for diagnosing various parasitic infection like neurocysticercosis and hydatid cyst disease.

Hematology

Anemia is frequently seen in hookworm infection and malaria. Eosinophilia is frequently present in helminthic infections. Hypergammaglobulinemia occurs in visceral leishmaniasis. Leukocytosis is seen in amoebic liver abscess.

Key points

- Leeuwenhoek in 1681, first observed the parasite *Giardia* in stools. Laveran in 1880, discovered malarial parasite and Ronald Ross in 1897 showed the transmission of malaria by mosquitoes.
- Protozoa belong to Kingdom Protista and helminths belong to Kingdom Animalia.
- **Definitive host:** The host in which the adult stage lives or the sexual mode of reproduction takes place.
- **Intermediate host:** The host in which the larval stage of the parasite lives or the asexual multiplication takes place.
- **Zoonoses:** Diseases which can be transmitted to humans from animals, e.g., malaria, leishmaniasis, trypanosomiasis, and echinococcosis.
- Parasites like trypanosomes exhibit antigenic variation within the host.
- Parasites like *Ascaris* and *Echinococcus* cause allergic manifestations in the host.
- Innate immunity against parasite may be genetic or by nonspecific direct cell-mediated or by complement activation.
- Acquired immunity in parasitic infections is by generating specific antibodies and effector T cells against parasitic antigens.
- Diagnosis of parasitic infections are made by direct identification of parasite in specimens like stool, blood, urine, bonemarrow, CSF, sputum, etc.
- Serological tests are also useful in diagnosis by detection of parasite-specific antibody and antigen.
- Other diagnostic modalities include imaging, molecular methods like PCR, skin test, and xenodiagnosis.

Review Questions

1. Write short notes on:

- (a) Parasites
- (c) Host-parasite relationship
- (e) Immune evasion mechanism of the parasites.

- (b) Host
- (d) Zoonoses

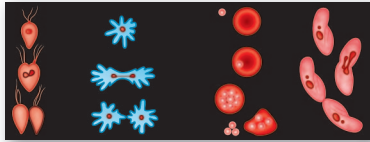
2. Discuss briefly the laboratory diagnosis of parasites.

3. Describe immunity in parasitic infections.

4. Differentiate between:

- (a) Direct and indirect life cycle

- (b) Definitive host and intermediate hosts



Protozoa 2

General Features

- Single-celled eukaryotic microorganisms belonging to kingdom protista are classified as **Protozoa** (Greek *Protos: first; zoon: animal*).
- The single protozoal cell performs all functions.
- Most of the protozoa are completely nonpathogenic but few may cause major diseases such as malaria, leishmaniasis, and sleeping sickness.
- Protozoa like *Cryptosporidium parvum* and *Toxoplasma gondii* are being recognized as opportunistic pathogens in patients affected with human immunodeficiency virus (HIV) and in those undergoing immunosuppressive therapy.
- Protozoa exhibit wide range of size (1–150 μm), shape, and structure; yet all possess essential common features.
- The differences between protozoa and metazoa are given in Table 2.1.

Structure

The typical protozoan cell is bounded by a trilaminar unit membrane, supported by a sheet of contractile fibrils enabling the cell to move and change in shape.

Cytoplasm

It has 2 portions:

- **Ectoplasm:** Outer homogeneous part that serves as the organ for locomotion and for engulfment of food

by producing **pseudopodia** is called as the ectoplasm. It also helps in respiration, discharging waste material, and in providing a protective covering of cell.

- **Endoplasm:** The inner granular portion of cytoplasm that contains nucleus is called endoplasm. The endoplasm shows number of structures—the golgi bodies, endoplasmic reticulum, food vacuoles, and contractile vacuoles. Contractile vacuoles serve to regulate the osmotic pressure.

Nucleus

The nucleus is usually single but may be double or multiple; some species having as many as hundred nuclei in a single cell.

- The nucleus contains one or more nucleoli or a central karyosome.

Table 2.1: Differences Between Protozoa and Metazoa

	Protozoa	Metazoa
Morphology	Unicellular; a single 'cell-like unit'	Multicellular; a number of cells, making up a complex individual
Physiology	A single cell performs all the functions: reproduction, digestion, respiration, excretion, etc.	Each special cell performs a particular function
Example	Amoeba	Tapeworm

Terminologies used In Protozoology

- **Chromatoid Body**
Extranuclear chromatin material is called chromatoid body (e.g., as found in *Entamoeba histolytica* cyst).
- **Karyosome**
It is a DNA containing body, situated peripherally or centrally within the nucleus and found in intestinal amoeba, e.g. *E. histolytica*, *E. coli*.
- **Kinetoplast**
Non-nuclear DNA present in addition to nucleus is called kinetoplast. It is seen in trypanosomes. Flagellum originates near the kinetoplast. Point of origin of flagellum is called as **basal body**.
- **Cilia**
These are fine, needle-like filaments, covering the entire surface of the body and are found in ciliates, e.g. *Balantidium coli*.
- **Trophozoite (Trophos: nourishment)**
Active feeding and growing stage of the protozoa is called the trophozoites. It derives nutrition from the environment by diffusion, pinocytosis, and phagocytosis.

➤ The chromatin may be distributed along periphery (peripheral chromatin) or as condensed mass around the karyosome.

Reproduction

Reproduction can be:

- Asexual reproduction
- Sexual reproduction.

Reproduction usually occurs asexually in protozoans; however, sexual reproduction occurs in ciliates and sporozoas.

Asexual Reproduction

- **Binary fission:** It is a method of asexual reproduction, by which a single parasite divides either longitudinally or transversally into two or more equal number of parasites. Mitotic division of nucleus is followed by division of the cytoplasm. In amoebae, division occurs along any plane, but in flagellates, division is along longitudinal axis and in ciliates, in the transverse plane (Fig. 2.1).
- **Multiple fission or schizogony:** *Plasmodium* exhibits schizogony, in which nucleus undergoes several successive divisions within the **schizont** to produce large number of **merozoites** (Fig. 2.1).
- **Endodyogeny:** Some protozoa like *Toxoplasma*, multiply by internal budding, resulting in the formation of two daughter cells.

Sexual Reproduction

➤ **Conjugation:** In ciliates, the sexual process is conjugation, in which two organisms join together and reciprocally exchange nuclear material (e.g. *Balantidium coli*).

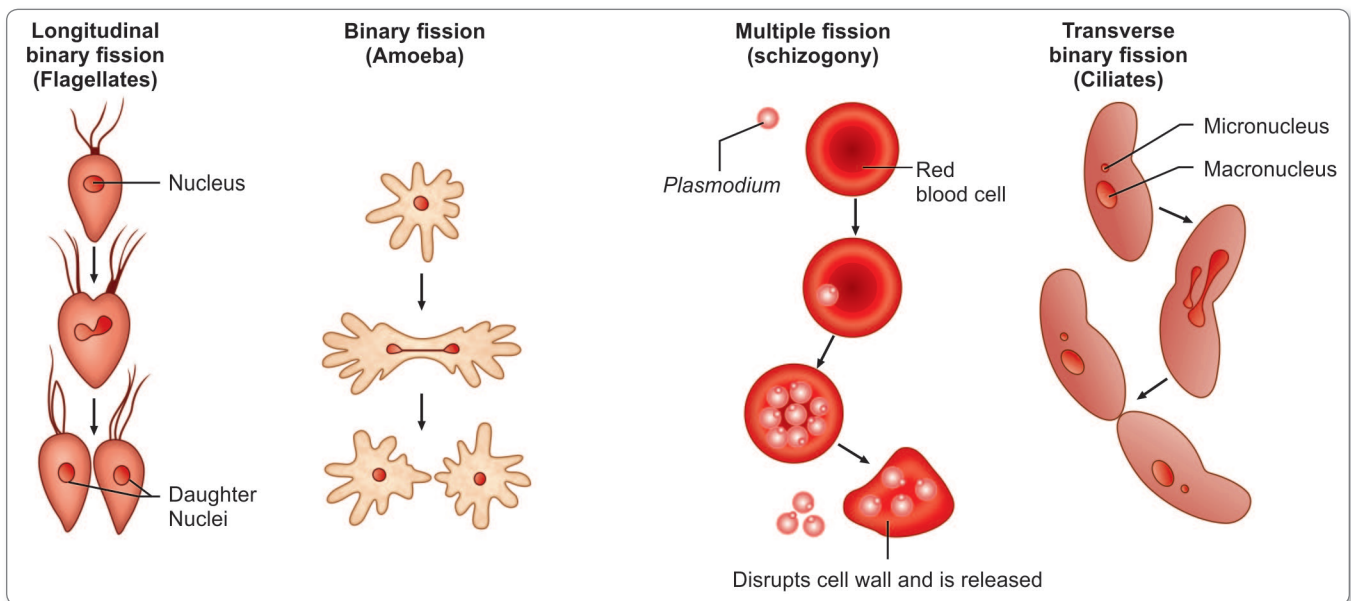


Fig. 2.1: Asexual reproduction in protozoans

- **Gametogony or syngamy:** In sporozoa, male and female gametocytes are produced, which after fertilization form the zygote, which gives rise to numerous sporozoites by sporogony (e.g. *Plasmodium*).

Life Cycle

- **Single Host:** Protozoa like intestinal flagellates and ciliates require only 1 host, within which they multiply asexually in trophic stage and transfer from one host to another by the **cystic form**.
- **Second host:** In some protozoa like *Plasmodium*, asexual method of reproduction occurs in one host (man) and sexual method of reproduction in another host (mosquito).

Classification of Protozoa

Protozoan parasites of medical importance have been classified into **kingdom** Protista, **subkingdom** Protozoa which is further divided into the following four phyla (Table 2.2):

- Sarcomastigophora

- Apicomplexa
- Microspora
- Ciliophora

The important protozoan pathogens of human are summarized in Table 2.3.

Phylum Sarcomastigophora

Phylum Sarcomastigophora has been subdivided into 2 subphyla based on their modes of locomotion.

- **Sarcodina** (*Sarcos meaning flesh or body*): It includes those parasites, which have no permanent locomotory organs, but move about with the aid of temporary prolongations of the body called **pseudopodia** (e.g. Amoebae).
- **Mastigophora** (*Mastix, meaning whip or flagellum*): It includes those protozoa which possess whip-like flagella (e.g. *Trypanosoma* and *Trichomonas*).

Amoebae

These protean animalcules can assume any shape and crawl along surfaces by means of foot-like projections called **pseudopodia** (literally meaning **false** feet). They are structurally very simple and are believed to have evolved from the flagellates by the loss of the flagella. Two groups of amoebae are of medical importance.

Table 2.2: Classification of Protozoa

Phylum	Subphylum	Superclass	Class	Subclass	Order	Suborder	Genus
Sarcomastigophora	Mastigophora (having one or more flagella)		Zoomastigophorea		Kinetoplastida	Trypanosomatina	<i>Trypanosoma</i> <i>Leishmania</i>
					Retortamonadida		<i>Retortamonas</i> <i>Chilomastix</i>
					Diplomonadida	Enteromonadina	Enteromonas
						Diplomonadina	<i>Giardia</i>
						Trichomonadida	<i>Trichomonas</i> <i>Dientamoeba</i>
Apicomplexa	Sarcodina (pseudopodia present)	Rhizopoda	Lobosea	Gymnamoebia	Amoebida	Tubulina	<i>Entamoeba</i> <i>Endolimax</i> <i>Iodamoeba</i>
						Acanthopodina	<i>Acanthamoeba</i>
						Schizopyrenida	<i>Naegleria</i>
Ciliophora			Sporozoea	Coccidia	Eucoccidia	Eimeriina	<i>Cryptosporidium</i> <i>Isoospora</i> <i>Sarcocystis</i> <i>Toxoplasma</i>
						Haemosporina	<i>Plasmodium</i>
				Piroplasmia	Piroplasmida		<i>Babesia</i>
			Kinetofragminophorea	Vestibuliferia	Trichostomastida	Trichostomatina	<i>Balantidium</i>
Microspora			Microsporea		Microsporida	Apansporoblastina	<i>Enterocytozoon</i> <i>Encephalitozoon</i> <i>Microsporium</i>

Table 2.3: Principal Protozoan Pathogen of Man

Species	Habitat	Disease
<i>Entamoeba histolytica</i>	Large intestine	Amoebic dysentery, amoebic liver abscess
<i>Naegleria fowleri</i>	CNS	Amoebic meningoencephalitis
<i>Acanthamoeba</i>	CNS, eye	Encephalitis, keratitis
<i>Giardia lamblia</i>	Small intestine	Malabsorption, diarrhea
<i>Trichomonas vaginalis</i>	Vagina, urethra	Vaginitis, urethritis
<i>Trypanosoma brucei</i>	Blood, lymphnode, CNS	Sleeping sickness
<i>Trypanosoma cruzi</i>	Macrophage of bone marrow, nerves, heart, colon etc.	Chagas' disease
<i>Leishmania donovani</i>	Reticuloendothelial system	Kala-azar, Post kala azar dermal leishmaniasis
<i>Leishmania tropica</i>	Skin	Cutaneous leishmaniasis (oriental sore)
<i>Leishmania braziliensis</i>	Naso-oral mucosa	Mucocutaneous leishmaniasis (Espundia, Chiclero's ulcer)
<i>Plasmodium</i> spp.	RBC	Malaria
<i>Babesia microti</i>	RBC	Babesiosis
<i>Isospora belli</i>	Intestine	Diarrhea in AIDS
<i>Cryptosporidium parvum</i>	Intestine	Diarrhea in AIDS
<i>Balantidium coli</i>	Large intestine	Dysentery

- **Amoebae of the alimentary canal:** The most important of these is *E. histolytica*, which causes intestinal and extraintestinal amoebiasis. Amoebae are also present in the mouth.
- **Potentially pathogenic free-living amoebae:** Several species of saprophytic amoebae are found in soil and water. Two of these, *Naegleria* and *Acanthamoeba* are of clinical interest because they can cause eye infections and fatal meningoencephalitis.

Flagellates

These protozoa have whip-like appendages called **flagella** as the organs of locomotion. The fibrillar structure of flagella is identical with that of **spirochetes** and it has been suggested that they may have been derived from symbiotic spirochetes, which have become endoparasites. In some species, the flagellum runs parallel to the body surface, to which it is connected by a membrane called the **undulating membrane**. Flagellates parasitic for man are divided into 2 groups:

- **Kinetoplastida:** These possess a kinetoplast from which a single flagellum arises. They are the **hemoflagellates** comprising the trypanosomes and *Leishmania*, which are transmitted by blood-sucking insects and cause systemic or local infections.
- **Flagellates without kinetoplast:** These bear multiple flagella. *Giardia*, *Trichomonas*, and other luminal flagellates belong to this group. Because most of them

live in the intestine, they are generally called **intestinal flagellates**.

Phylum Apicomplexa

Phylum Apicomplexa was formerly known as **sporozoa**. Members of this group possess, at some stage in their life cycle, a structure called the **apical complex** serving as the organ of attachment to host cells.

- They are tissue parasites.
- They have a complex life cycle with alternating sexual and asexual generations.
- To this group, belongs the malarial parasites (suborder: Haemosporina, Family: Plasmodiidae), *Toxoplasma*, *Sarcocystis*, *Isospora*, and *Cryptosporidium* (under the Suborder: Eimeriina), *Babesia* (under the subclass: Piroplasma), and the unclassified *Pneumocystis jirovecii*.

Phylum Ciliophora

These protozoa are motile by means of cilia, which cover their entire body surface. The only human parasite in this group is *Balantidium coli*, which rarely causes dysentery.

Phylum Microspora

Phylum Microspora contains many minute intracellular protozoan parasites, which frequently cause disease in immunodeficient subjects. They may also cause illness in the immunocompetent, rarely.

**Important points to remember**

- Only protozoan parasite found in lumen of human small intestine: *Giardia lamblia*.
- Largest protozoa: *Balantidium coli*.
- Most common protozoan parasite: *Toxoplasma gondii*.

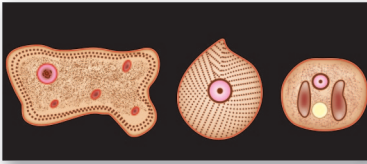
The zoological classification of protozoa is complex and is subject to frequent revisions. The classification described in the chapter is an abridged version of the classification proposed in 1980 by the Committee on Systematics and Evolution of the Society of Protozoologists, as applied to protozoa of medical importance.

Key points of Protozoa

- Protozoa are single-celled, eukaryotic microorganisms consisting of cell membrane, cytoplasm, and nucleus.
- Some protozoa have kinetoplast and flagella or cilia.
- Amoebae move about with temporary prolongations of the body called pseudopodia.
- Hemoflagellates comprising of *Trypanosoma* and *Leishmania* possess a single flagellum and kinetoplast.
- Luminal flagellates like *Giardia* and *Trichomonas* bear multiple flagella without kinetoplast.
- *Balantidium coli* belongs to the Phylum Ciliophora, which is motile by cilia that cover its entire body surface.
- Trophozoites are active feeding and growing stage of protozoa.
- Cysts are resting or resistant stage of protozoa bounded by tough cell wall.
- Protozoa multiply by both asexual and sexual modes of reproduction.
- Malaria parasite, *Toxoplasma*, and *Cyptosporidium* belong to Phylum Apicomplexa or Sporozoa, which possess apical complex at some stage of their life cycle and have a complex life cycle with alternating sexual and asexual generations.
- Microspora are intracellular protozoan parasites, which cause disease in immunodeficient patients.

Review Questions

1. Define Protozoa and describe their general characteristics.
2. Write short notes on:
 - (a) Classification of Protozoa
 - (b) Reproduction in Protozoa
3. Differentiate between Protozoa and Metazoa.



Amoebae 3

Amoebae are structurally simple protozoans which have no fixed shape. They are classified under **Phylum:** Sarcomastigophora, **Subphylum:** Sarcodina, **Super-class:** Rhizopoda and **Order:** Amoebida.

- The cytoplasm of amoeba is bounded by a membrane and can be differentiated into an **outer ectoplasm** and **inner endoplasm**.
- **Pseudopodia** are formed by the amoeba by thrusting out ectoplasm, followed by endoplasm. These are employed for locomotion and engulfment of food by phagocytosis.
- Reproduction occurs by fission and budding. Cyst is formed in unfavorable conditions and is usually the infective form for vertebrate host (e.g. *Entamoeba histolytica*).

Table 3.1: Classification of Amoebae

Intestinal amoebae	Free-living amoebae
<i>Entamoeba histolytica</i> <i>Entamoeba dispar</i> <i>Entamoeba coli</i> <i>Entamoeba polecki</i> <i>Entamoeba hartmanni</i> <i>Entamoeba gingivalis</i> <i>Endolimax nana</i> <i>Iodamoeba butschlii</i>	<i>Naegleria fowleri</i> <i>Acanthamoeba</i> spp. <i>Balamuthia mandrillaris</i>
Note: All intestinal amoebae are nonpathogenic, except <i>Entamoeba histolytica</i>	Note: All free-living amoebae are opportunistic pathogens

- Amoebae are classified as either free-living or intestinal amoebae (Table 3.1).
- A few of the free-living amoebae occasionally act as human pathogens producing meningoencephalitis and other infections, e.g. *Naegleria* and *Acanthamoeba*.
- The parasitic amoebae inhabit the alimentary canal.

Entamoeba Histolytica

History and Distribution

E. histolytica was discovered by Lösch in 1875, who demonstrated the parasite in the dysenteric feces of a patient in St. Petersburg in Russia.

- In 1890, William Osler reported the case of a young man with dysentery, who later died of liver abscess.
- Councilman and Lafleur in 1891 established the pathogenesis of intestinal and hepatic amoebiasis and introduced the terms '**amoebic dysentery**' and '**amoebic liver abscess**'.
- *E. histolytica* is worldwide in prevalence, being much more common in the tropics than elsewhere. It has been found wherever sanitation is poor, in all climatic zones from Alaska (61°N) to straits of Magellan (52°S).
- It has been reported that about 10% of world population and 50% of the inhabitants of developing countries may be infected with the parasite.
- The infection is not uncommon even in affluent countries, about 1% of Americans being reported to be infected.

- While the majority of infected humans (80–99%) are asymptomatic, invasive amoebiasis causes disabling illness in an estimated 50 million of people and causes 50,000 deaths annually, mostly in the tropical belt of Asia, Africa, and Latin America.
- It is the third leading parasitic cause of mortality, after malaria and schistosomiasis.

- Epidemiologically, India can be divided into 3 regions, depending on the prevalence of intestinal amoebiasis.
 - High prevalence states (>30%): Chandigarh, Tamil Nadu, and Maharashtra.
 - Moderate prevalence states (10–30%): Punjab, Rajasthan, Uttar Pradesh, Delhi, Bihar, Assam, West Bengal, Andhra Pradesh, Karnataka, and Kerala.
 - Low prevalence states (<10%): Haryana, Gujarat, Himachal Pradesh, Madhya Pradesh, Odisha, Sikkim, and Puducherry.

Morphology

E. histolytica occurs in 3 forms (Fig. 3.1).

- Trophozoite
- Precyst
- Cyst.

Trophozoite

Trophozoite is the vegetative or growing stage of the parasite (Fig. 3.1A). It is the only form present in tissues.

- It is irregular in shape and varies in size from 12–60 μm ; average being 20 μm .
- It is large and actively motile in freshly-passed dysenteric stool, while smaller in convalescents and carriers.
- The parasite, as it occurs free in the lumen as a commensal is generally smaller in size, about 15–20 μm and has been called the **minuta form**.
- **Cytoplasm:** Outer ectoplasm is clear, transparent, and refractile. Inner endoplasm is finely granular, having a **ground glass appearance**. The endoplasm contains nucleus, food vacuoles, erythrocytes, occasionally leucocytes, and tissue debris.

- **Pseudopodia** are finger-like projections formed by sudden jerky movements of ectoplasm in one direction, followed by the streaming in of the whole endoplasm.
- Typical amoeboid motility is a **crawling** or **gliding** movement and not a free swimming one. The direction of movement may be changed suddenly, with another pseudopodium being formed at a different site, when the whole cytoplasm flows in the direction of the new pseudopodium. The cell has to be attached to some surface or particle for it to move. In culture tubes, the trophozoites may be seen crawling up the side of the glass tube.
- Pseudopodia formation and motility are inhibited at low temperatures.
- **Nucleus** is spherical 4–6 μm in size and contains **central karyosome**, surrounded by clear halo and anchored to the nuclear membrane by fine radiating fibrils called the **linin network**, giving a **cartwheel appearance**. The nucleus is not clearly seen in the living trophozoites, but can be clearly demonstrated in preparations stained with iron-hematoxylin.
- The nuclear membrane is lined by a rim of chromatin distributed evenly as small granules.
- The trophozoites from acute dysenteric stools often contain phagocytosed erythrocytes. This feature is diagnostic as phagocytosed red cells are not found in any other commensal intestinal amoebae.
- The trophozoites divide by **binary fission** in every 8 hours.
- Trophozoites survive upto 5 hours at 37°C and are killed by drying, heat, and chemical sterilization. Therefore, the infection is not transmitted by trophozoites. Even if live trophozoites from freshly-passed stools are ingested, they are rapidly destroyed in stomach and cannot initiate infection.

Precystic Stage

Trophozoites undergo encystment in the intestinal lumen. Encystment does not occur in the tissues nor in feces outside the body.

- Before encystment, the trophozoite extrudes its food vacuoles and becomes round or oval, about 10–20

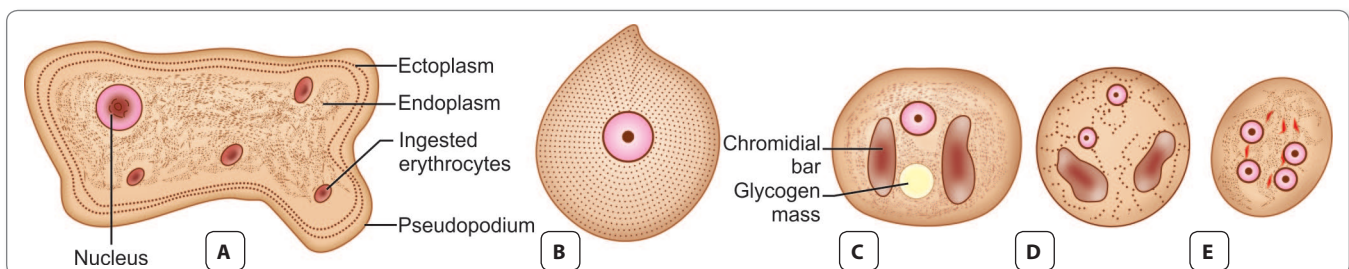


Fig. 3.1: *Entamoeba histolytica*. **A.** Trophozoite; **B.** Precystic stage; **C.** Uninucleate cyst; **D.** Binucleate cyst; **E.** Mature quadrinucleate cyst

µm in size. This is the precystic stage of the parasite (Fig. 3.1B).

- It contains a **large glycogen vacuole** and two **chromatid bars**.
- It then secretes a highly retractile cyst wall around it and becomes cyst.

Cystic Stage

The cyst is spherical in shape about 10–20 µm in size.

- The early cyst contains a single nucleus and two other structures—a mass of glycogen and 1–4 *chromatoid bodies or chromidial bars*, which are cigar-shaped refractile rods with rounded ends (Fig. 3.1C). The chromatoid bodies are so called because they stain with hematoxylin, like chromatin.
- As the cyst matures, the glycogen mass and chromidial bars disappear and the nucleus undergoes 2 successive mitotic divisions to form 2 (Fig. 3.1D) and then 4 nuclei. The mature cyst is, thus **quadrinucleate** (Fig. 3.1E).
- The cyst wall is a highly refractile membrane, which makes it highly resistant to gastric juice and unfavorable environmental conditions.
- The nuclei and chromidial bodies can be made out in unstained films, but they appear more prominently in stained preparations.
- With iron hemotoxylin stain, nuclear chromatin and chromatoid bodies appear deep blue or black, while the glycogen mass appears unstained.
- When stained with iodine, the glycogen mass appears golden brown, the nuclear chromatin and karyosome bright yellow, and the chromatoid bodies appear as clear space, being unstained.

Life Cycle

E. histolytica passes its life cycle only in 1 host-man (Flowchart 3.1 and Fig. 3.2).

Infective form: Mature quadrinucleate cyst passed in feces of convalescents and carriers. The cysts can remain viable under moist conditions for about 10 days.

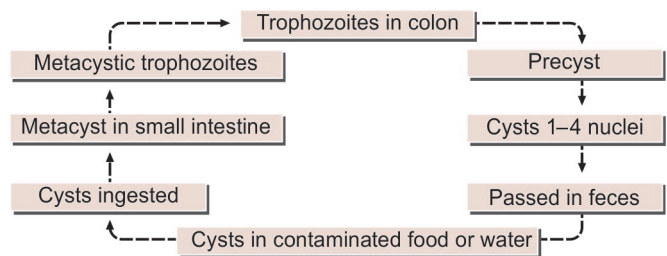
Mode of transmission: Man acquires infection by swallowing food and water contaminated with cysts.

- As the cyst wall is resistant to action of gastric juice, the cysts pass through the stomach undamaged and enter the small intestine.
- **Excystation:** When the cyst reaches caecum or lower part of the ileum, due to the alkaline medium, the cyst wall is damaged by trypsin, leading to excystation.
- The cytoplasm gets detached from the cyst wall and amoeboid movements appear causing a tear in the cyst wall, through which **quadrinucleate amoeba** is liberated. This stage is called the **metacyst** (Fig. 3.2).

➤ **Metacystic trophozoites:** The nuclei in the metacyst immediately undergo division to form **8 nuclei**, each of which gets surrounded by its own cytoplasm to become **8 small amoebulae or metacystic trophozoites**.

- If excystation takes place in the small intestine, the metacystic trophozoites do not colonize there, but are carried to the caecum.
- The optimal habitat for the metacystic trophozoite is the submucosal tissue of caecum and colon, where they lodge in the glandular crypts and grow by binary fission (Fig. 3.2).
- Some develop into precystic forms and cysts, which are passed in feces to repeat the cycle.
- The entire life cycle is, thus completed in one host.

In most of the cases, *E. histolytica* remains as a commensal in the large intestine without causing any ill effects. Such persons become carriers or asymptomatic cyst passers and are responsible for maintenance and spread of infection in the community. Sometimes, the infection may be activated and clinical disease ensues. Such latency and reactivation are the characteristics of amoebiasis.



Flowchart 3.1: Life cycle of *Entamoeba histolytica* (Schematic)

Pathogenesis and Clinical Features

- *E. histolytica* causes intestinal and extraintestinal amoebiasis.
- **Incubation period** is highly variable. On an average, it ranges from 4 days to 4 months.
- Amoebiasis can present in different forms and degree of severity, depending on the organ affected and the extent of damage caused.

Intestinal Amoebiasis

The lumen-dwelling amoebae do not cause any illness. They cause disease only when they invade the intestinal tissues. This happens only in about 10% of cases of infection, the remaining 90% being asymptomatic.

- Not all strains of *E. histolytica* are pathogenic or invasive. Differentiation between pathogenic and non-pathogenic strains can be made by susceptibility to complement-mediated lysis and phagocytic activity or

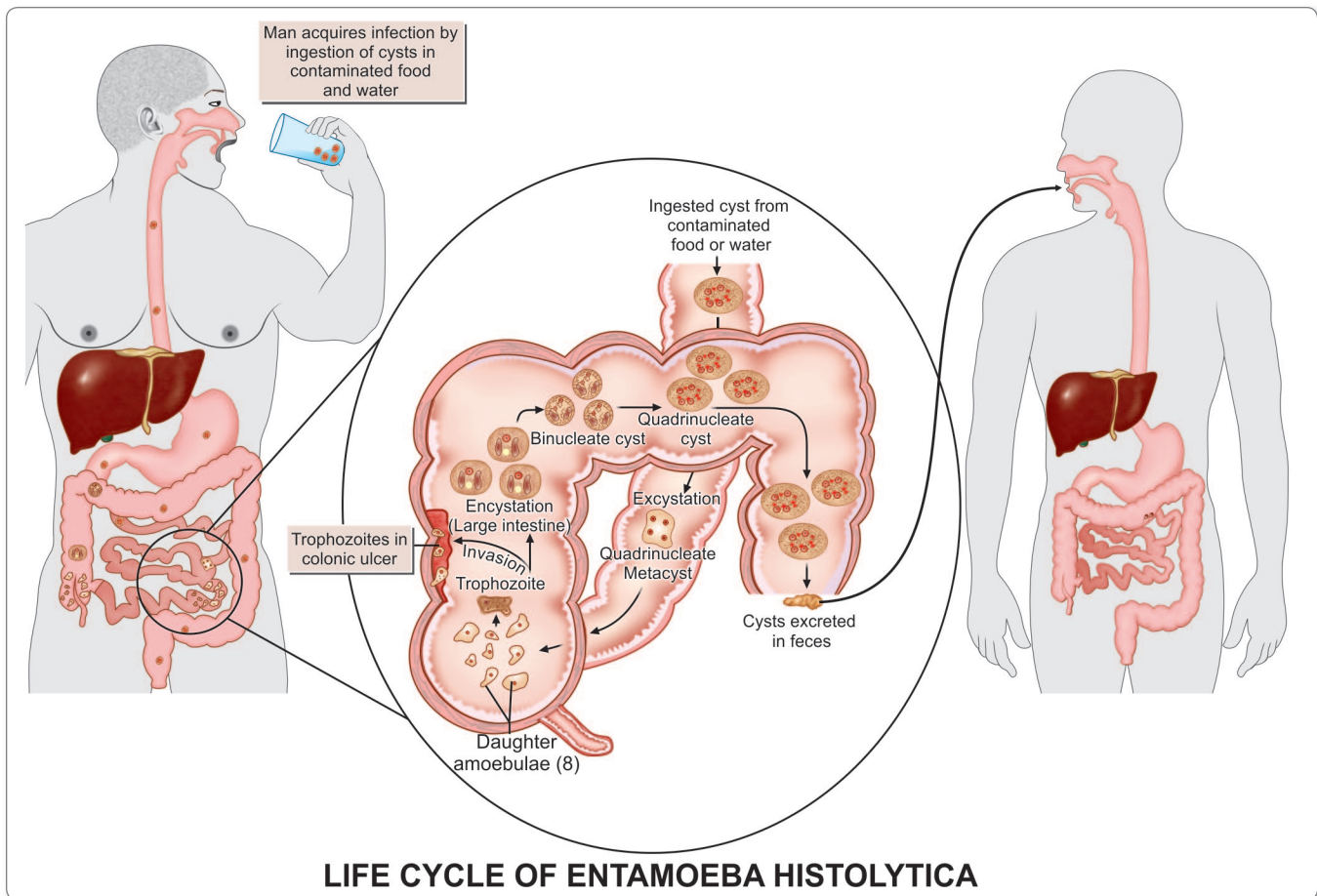


Fig. 3.2: Life cycle of *Entamoeba histolytica*

by the use of genetic markers or monoclonal antibodies and zymodeme analysis. (see box on page number 18)

- The metacystic trophozoites penetrate the columnar epithelial cells in the **crypts of Lieberkühn** in the colon.
- Penetration of the amoeba is facilitated by the motility of the trophozoites and the tissue lytic enzyme, **histolysin**, which damages the mucosal epithelium. Amoebic **lectin** another virulence factor mediates adherence.
- Mucosal penetration by the amoeba produces discrete ulcers with pinhead center and raised edges. Sometimes, the invasion remains superficial and heals spontaneously. More often, the amoeba penetrates to submucosal layer and multiplies rapidly, causing lytic necrosis and thus forming an abscess. The abscess breaks down to form an ulcer.
- **Amoebic ulcer** is the typical lesion seen in intestinal amoebiasis (Fig. 3.3). The ulcers are **multiple** and are confined to the colon, being most numerous in the **caecum** and next in the **sigmoido-rectal region**. The intervening mucous membrane between the ulcers remains healthy.



Fig. 3.3: Intestinal amoebiasis: Specimen showing amoebic ulcer in colon

Factors affecting virulence of *Entamoeba histolytica*

- Amoebic cystine proteinase, which inactivates complement factor C3 is an important virulence factor.
- Amoebic lectin and ionophore protein are other virulence factors.
- Host factors such as stress, malnutrition, alcoholism, corticosteroid therapy, and immunodeficiency influence the course of infection.
- Glycoproteins in colonic mucus blocks the attachment of trophozoites to epithelial cells, therefore alteration in the nature and quality of colonic mucus may influence virulence.
- Virulence may also be conditioned by the bacterial flora in the colon.

Based on electrophoretic mobility of 6 isoenzymes (acetylglucosaminidase, aldolase, hexokinase, NAD-diaphorase, peptidase and phosphoglucomutase), *E. histolytica* strains can be classified into at least 22 zymodemes. Of these only 9 are invasive and the rest are noninvasive commensals. The zymodemes show a geographical distribution. Even in endemic areas, nonpathogenic zymodemes are far more common than pathogenic ones, which account only about 10% of the total population.

It has been proposed that pathogenic and nonpathogenic strains though morphologically identical may represent 2 distinct species—the pathogenic strains being *E. histolytica*, and the nonpathogenic strains reclassified as *E. dispar*. Trophozoites of *E. dispar* contain bacteria, but no RBCs.

- Ulcers appear initially on the mucosa as raised nodules with pouting edges. They later break down discharging brownish necrotic material containing large numbers of trophozoites.
- The typical amoebic ulcer is **flask-shaped** in cross section, with mouth and neck being narrow and base large and rounded.
- Multiple ulcers may coalesce to form large necrotic lesions with ragged and undermined edges and are covered with brownish slough.
- **The ulcers generally do not extend deeper than submucosal layer**, but amoebae spread laterally in the submucosa causing extensive undermining and patchy mucosal loss. Amoebae are seen at the periphery of the lesions and extending into the surrounding healthy tissues. Occasionally, the ulcers may involve the muscular and serous coats of the colon, causing perforation and peritonitis. Blood vessel erosion may cause hemorrhage.
- The superficial lesions generally heal without scarring, but the deep ulcers form scars which may lead to strictures, partial obstruction, and thickening of the gut wall.

- Occasionally, a granulomatous pseudotumoral growth may develop on the intestinal wall from a chronic ulcer. This amoebic granuloma or **amoeboma** may be mistaken for a malignant tumor.

Lesions in chronic intestinal amoebiasis

- Small superficial ulcers involving only the mucosa.
- Round or oval-shaped with ragged and undermined margin and flask-shaped in cross-section.
- Marked scarring of intestinal wall with thinning, dilatation, and sacculation.
- Extensive adhesions with the neighboring viscera.
- Formation of tumor-like masses of granulation tissue (amoeboma).

Clinical Features of Intestinal Amoebiasis

The clinical picture covers a wide spectrum from noninvasive carrier state to fulminant colitis.

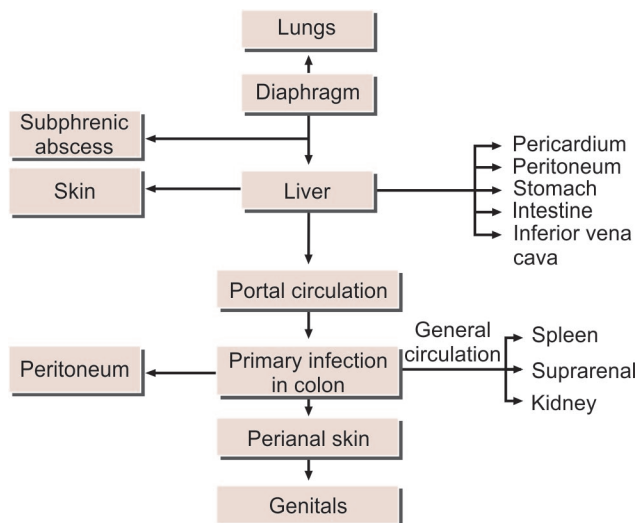
- The incubation period is highly variable from 1–4 months.
- The clinical course is characterized by prolonged latency, relapses and intermissions.
- The typical manifestation of intestinal amoebiasis is amoebic dysentery. This may resemble bacillary dysentery, but can be differentiated on clinical and laboratory grounds. Compared to bacillary dysentery, it is usually insidious in onset and the abdominal tenderness is less and localized (Table 3.2).
- The stools are large, foul-smelling, and brownish black, often with bloodstreaked mucus intermingled with feces. The RBCs in stools are clumped and reddish-brown in color. Cellular exudate is scanty. Charcot-Leyden crystals are often present. *E. histolytica* trophozoites can be seen containing ingested erythrocytes.
- The patient is usually afebrile and nontoxic.
- In fulminant colitis, there is confluent ulceration and necrosis of colon. The patient is febrile and toxic.
- Intestinal amoebiasis does not always result in dysentery. Quite often, there may be only diarrhea or vague abdominal symptoms popularly called '**uncomfortable belly**' or '**growling abdomen**'.
- Chronic involvement of the caecum causes a condition simulating appendicitis.

Extraintestinal Amoebiasis

The various extraintestinal lesions in amoebiasis have been summarized in Flowchart 3.2 and depicted in Fig. 3.5.

Hepatic Amoebiasis

Hepatic involvement is the most common extraintestinal complication of amoebiasis. Although trophozoites reach



Flowchart 3.2: Sites affected in amoebiasis

the liver in most cases of amoebic dysentery, only in a small proportion do they manage to lodge and multiply there. In the tropics, about 2–10% of the individuals infected with *E. histolytica* suffer from hepatic complications.

- The history of amoebic dysentery is absent in more than 50% of cases.
- Several patients with amoebic colitis develop an enlarged tender liver without detectable impairment of liver function or fever. This acute hepatic involvement (**amoebic hepatitis**) may be due to repeated invasion by amoebae from an active colonic infection or to toxic substances from the colon reaching the liver. It is probable that liver damage may not be caused directly by the amoebae, but by lysosomal enzymes and cytokines from the inflammatory cells surrounding the trophozoites.

Complications and sequelae of intestinal amoebiasis

Fulminant amoebic colitis

- Toxic megacolon
- Perianal ulceration
- Amoeboma

Extraintestinal amoebiasis

- Amoebic hepatitis
- Amoebic liver abscess
- Amoebic appendicitis and peritonitis
- Pulmonary amoebiasis
- Cerebral amoebiasis
- Splenic abscess
- Cutaneous amoebiasis
- Genitourinary amoebiasis

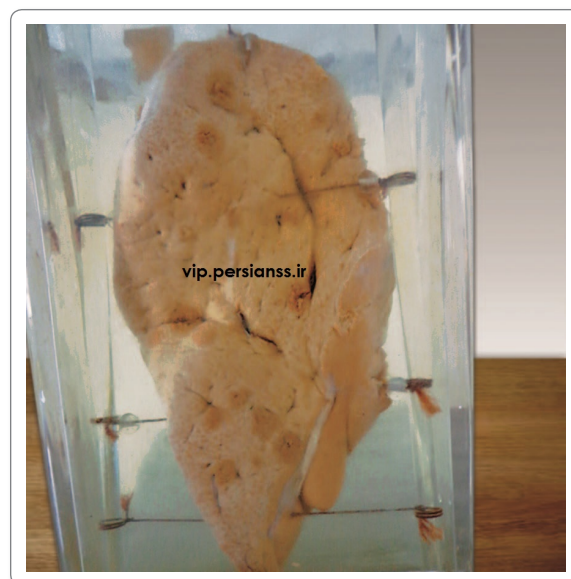

Fig. 3.4: Specimen showing amoebic liver abscess

- In about 5–10% of persons with intestinal amoebiasis, **liver abscesses** may ensue (Fig. 3.4). The center of the abscess contains **thick chocolate brown pus (anchovy sauce pus)**, which is liquefied necrotic liver tissue. It is bacteriologically sterile and free of amoeba. At the periphery, there is almost normal liver tissue, which contains invading amoeba.
- Liver abscess may be multiple or more often solitary, usually located in the upper right lobe of the liver. Jaundice develops only when lesions are multiple or when they press on the biliary tract.
- Untreated abscesses tend to rupture into the adjacent tissues through the diaphragm into the lung or pleural cavity, pericardium, peritoneal cavity, stomach, intestine, or inferior vena cava or externally through abdominal wall and skin.
- The incidence of liver abscess is less common in women and rare in children under 10 years of age.

Pulmonary Amoebiasis

Very rarely, primary amoebiasis of the lung may occur by direct hematogenous spread from the colon bypassing the liver, but it most often follows extension of hepatic abscess through the diaphragm and therefore, the lower part of the right lung is the usual area affected (Fig. 3.5).

- Hepatobronchial fistula usually results with expectoration of **chocolate brown sputum**. Amoebic empyema develops less often.
- The patient presents with severe pleuritic chest pain, dyspnea, and non-productive cough.

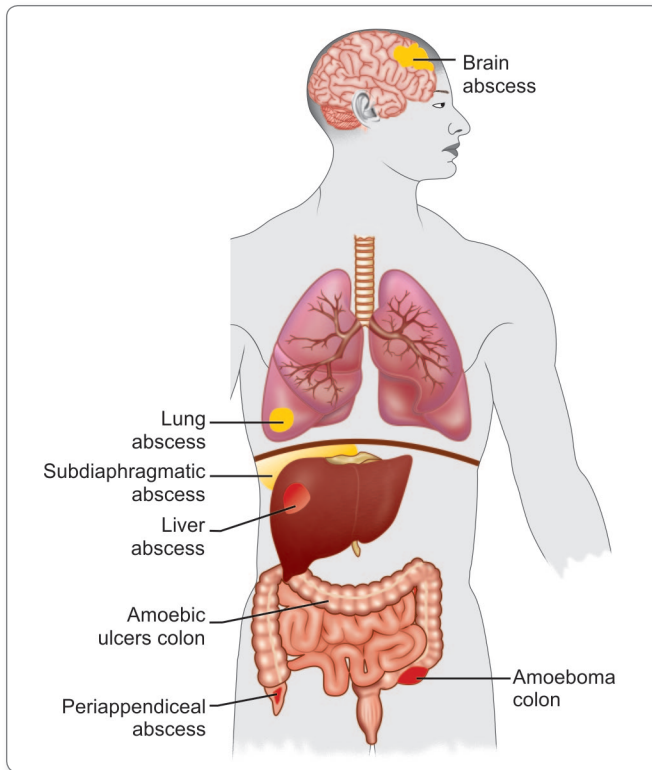


Fig. 3.5: Lesions of Amoebiasis

Metastatic Amoebiasis

Involvement of distant organs is by hematogenous spread and through lymphatics. Abscesses in kidney, brain, spleen, and adrenals have been noticed. Spread to brain leads to severe destruction of brain tissue and is fatal.

Cutaneous Amoebiasis

It occurs by direct extension around anus, colostomy site, or discharging sinuses from amoebic abscesses. Extensive gangrenous destruction of the skin occurs. The lesion may be mistaken for condyloma or epithelioma.

Genitourinary Amoebiasis

The prepuce and glans are affected in penile amoebiasis which is acquired through anal intercourse. Similar lesions in females may occur on vulva, vagina, or cervix by spread from perineum. The destructive ulcerative lesions resemble carcinoma.

Laboratory Diagnosis

Diagnosis of Intestinal Amoebiasis

Stool examination

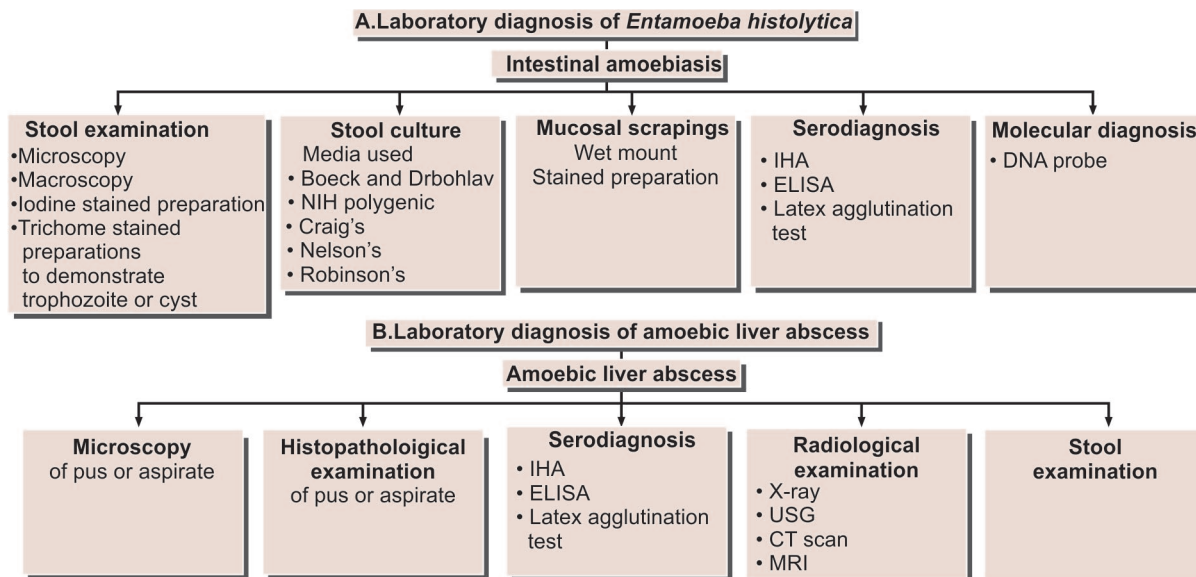
Intestinal amoebiasis has to be differentiated from bacillary dysentery (Table 3.2). The stool should be collected into a

Table 3.2: Differential Features of Amoebic and Bacillary Dysentery

Features	Amoebic dysentery	Bacillary dysentery
Clinical		
Onset	Slow	Acute
Fever	Absent	Present
Toxicity	Absent	Present
Abdominal tenderness	Localised	Generalised
Tenesmus	Absent	Present
Stool		
Frequency	6–8 per day	Over 10 per day
Odor	Offensive	Nil
Color	Dark red	Bright red
Nature	Feces mixed with blood and mucus	Blood and mucus with little or no feces
Consistency	Not adherent	Adherent to container
Reaction	Acid	Alkaline
Microscopy		
Cellular exudates	Scanty	Abundant
Red blood cells	Clumped yellowish brown	Discrete or in rouleaux, bright red
Macrophages	Few	Several, some with ingested red blood cells
Eosinophils	Present	Absent
Charcot-Leyden crystals	Present	Absent
Motile bacteria	Present	Absent
Amoeba	Motile trophozoites with ingested red blood cells	Absent

wide mouth container and examined without delay. It should be inspected macroscopically as well as microscopically, (Flowchart 3.3A).

- **Macroscopic Appearance:** The stool is foul-smelling, copious, semi-liquid, brownish black in color, and intermingled with blood and mucus. It does not adhere to the container.
- **Microscopic Appearance: Saline preparation**
 - The cellular exudate is scanty and consists of only the nuclear masses (pyknotic bodies) of a few pus cells, epithelial cells, and macrophages.
 - The RBCs are in clumps and yellow or brown red in color.
 - Charcot-Leyden crystals are often present. These are diamond-shaped, clear and refractile crystals.



Flowchart 3.3: A. Laboratory diagnosis of *Entamoeba histolytica*; B. Laboratory diagnosis of amoebic liver abscess

- Actively motile trophozoites throwing pseudopodia can be demonstrated in freshly-passed stool. Presence of ingested RBCs clinches the identity of *E. histolytica*. Nucleus is not visible but a faint outline may be detected.
- Cyst has a smooth and thin cell wall and contains round refractile chromatoid bars.
- For the demonstration of cysts or dead trophozoites, stained preparations may be required for the study of the nuclear character. Iodine-stained preparation is commonly employed for this purpose. The trophozoite of *E. histolytica* stains yellow to light brown. Nucleus is clearly visible with a central karyosome. The cytoplasm of the cystic stage shows smooth and hyaline appearance. Nuclear chromatin and karyosome appear bright yellow. Glycogen masses stain golden brown and chromatoid bars are not stained. Trichrome stain is useful to demonstrate intracellular features of both trophozoites and cysts.
- Since excretion of cysts in the stool is often intermittent, at least 3 consecutive specimens should be examined (Fig. 3.6).

- Media used for stool culture
 - Boeck and Drbohlav media
 - NIH polygenic media
 - Craig's medium
 - Nelson's medium
 - Robinson's medium

Serodiagnosis

Serological tests become positive only in invasive amoebiasis.

Mucosal Scrapings

Scraping obtained by sigmoidoscopy are often contributory. Examination method includes a direct wet mount and iron hemotoxylin and immunofluorescent staining.

Stool Culture

Stool culture is a sensitive method in diagnosing chronic and asymptomatic intestinal amoebiasis.

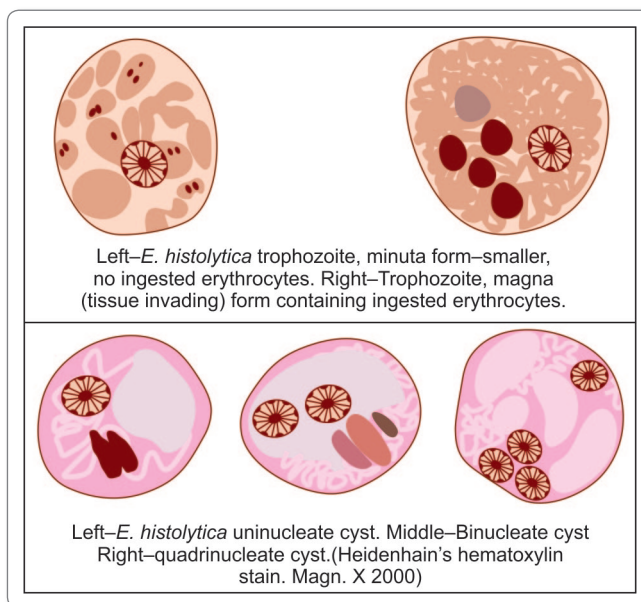


Fig. 3.6: *Entamoeba histolytica* as it appears in laboratory specimen

Various serological tests done include—

- **Indirect hemagglutination (IHA) test:** serum with antibody titer of 1:256 or more by IHA is diagnostic of amoebic hepatitis.
- **Latex agglutination test.**
- **Enzyme-linked immunosorbent assay (ELISA):** Commercially available tests that use ELISAs to detect *Entamoeba* antigens are less expensive and more easily performed and are being used with increasing frequency. Greater sensitivity than microscopy and the ability to detect *E. histolytica* specifically are claimed by some of the leading kits, representing significant advantages over microscopy.

Molecular Diagnosis

Recently, DNA probes and Radio immunoassay have been used to detect *E. histolytica* in stool. It is a rapid and specific method.

Diagnosis of Extraintestinal Amoebiasis

Microscopy

Microscopic examination of pus aspirated from liver abscess may demonstrate trophozoite of *E. histolytica* in less than 20 percent cases. In case of liver abscess, when diagnostic aspiration is done, the pus obtained from the center of the abscess may not contain amoeba as they are confined to the periphery. The fluid draining after a day or two is more likely to contain the trophozoite. Aspirates from the margins of the abscess would also show the trophozoites. Cysts are never seen in extraintestinal lesions.

Liver biopsy

Trophozoite of *E. histolytica* may be demonstrated in liver biopsy specimen, in case of hepatic amoebiasis or amoebic hepatitis.

Serological test

Serological test, are of immense value in the diagnosis of hepatitis amoebiasis.

Craig (1928) was the first to report a **complement fixation test** in amoebiasis. Subsequently a number of different serological tests have been developed including **indirect haemagglutination (IHA), latex agglutination (LA), gel diffusion precipitation (GDP), cellulose acetate membrane precipitation (CAP) test, counter current immunoelectrophoresis (CIE) and enzyme linked immunosorbent assay (ELISA)**. While IHA and LA are highly sensitive, they often give false-positive results. They remain positive for several years even after successful treatment.

Gel precipitation tests are less sensitive, but more specific. ELISAs are both sensitive and specific and like GDP and CIE become negative within six months of successful treatment.

Stool examination

It is not of much value as *E. histolytica* cyst can be detected in stool in less than 15% cases of amoebic hepatitis.

Radiological examination

- On X-Ray, the right lobe of the liver is generally found to be situated at a higher level.
- Radioisotope scan of the liver may locate the space-occupying lesions.
- Ultrasonography (USG), computed tomography (CT) scan, or (MRI) of liver may be found useful in detection of amoebic liver abscess (Flowchart 3.3B).

The diagnosis of amoebic liver abscess is based on the detection (generally by USG or CT) of one or more space-occupying lesions in the liver and a positive serologic test for antibodies against *E. histolytica* antigens. When a patient has a space-occupying lesion of the liver and a positive amoebic serology, it is highly sensitive (>94%) and highly specific (>95%) for the diagnosis of amoebic liver abscess (Flowchart 3.3B).

Immunity

Infection with invasive strains includes both humoral and cellular Immune responses. Local and systemic antibodies can be demonstrated within a week of invasive infection.

Infection confers some degree of protection as evidenced by the very low frequency of recurrence of invasive colitis and liver abscess in endemic areas. The course and severity of amoebiasis does not seem to be affected by human immunodeficiency virus (HIV) infection. Serological response is hardly ever seen in infection with non-invasive zymodemes.

Treatment

Three classes of drug are used in the treatment of amoebiasis.

- **Luminal amoebicides:** Diloxanide furoate, iodoquinol, paromomycin, and tetracycline act in the intestinal lumen but not in tissues.
- **Tissue amoebicides:** Emetine, chloroquine, etc. are effective in systemic infection, but less effective in the intestine. Dosage of chloroquine in amoebic liver abscess is 1 g for 2 days followed by 5 g daily for 3 weeks.
- **Both luminal and tissue amoebicides:** Metronidazole and related compounds like tinidazole and ornidazole act on both sites and are the drug of choice for treating amoebic colitis and amoebic liver abscess.

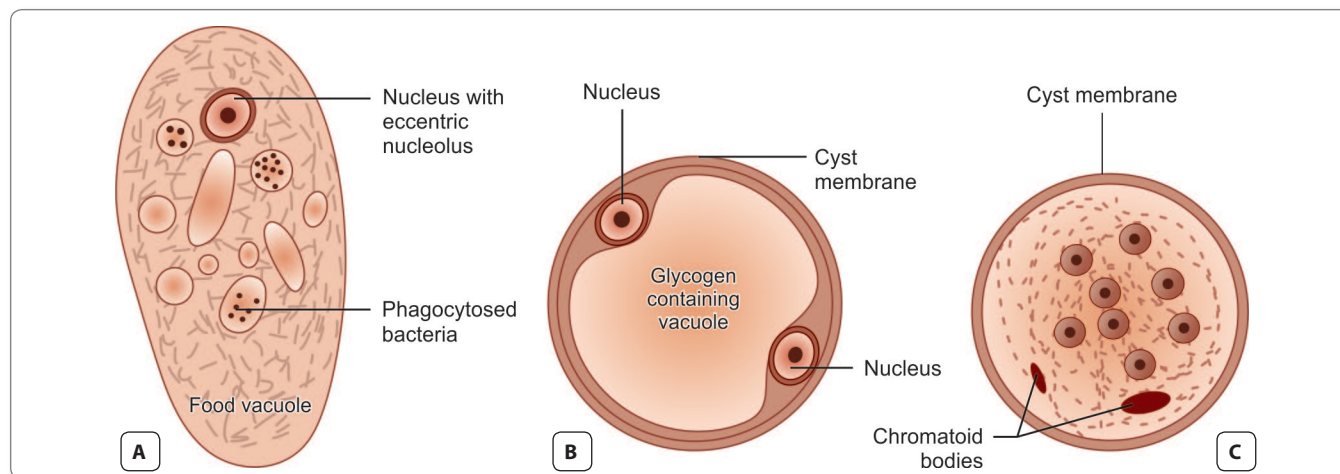


Fig. 3.7: Schematic diagram of the morphological forms of *Entamoeba coli* (Heidenhain's hematoxylin Magn. X 2000). **A.** Vegetative form; **B.** Binucleate cyst; **C.** Eight-nucleate cyst

Note: Although metronidazole and tinidazole act on both the sites but neither of them reach high levels in the gut lumen; therefore, patients with amoebic colitis or amoebic liver abscess should also receive treatment with a luminal agent (paromomycin or iodoquinol) to ensure eradication of infection (Table 3.3). Paromomycin is the preferred agent.

Table 3.3: Recommended Dosages of Antiamoebic Drugs

Drug	Dosage	Duration (in days)
Amoebic colitis or Amoebic liver abscess		
Tinidazole	2 g/day orally	3
Metronidazole	750 mg three times a day, orally or IV	5–10
Intestinal amoebiasis		
Paromomycin	30 mg/kg 4 times a day, orally in 3 divided doses	5–10
Iodoquinol	650 mg orally, three times day	20

- Asymptomatic individuals with documented *E. histolytica* infection should also be treated because of the risks of developing amoebic colitis or amoebic liver abscess in the future and risk of transmitting the infection to others. Paromomycin or iodoquinol in the doses listed in the Table 3.3 should be used in these cases.
- Oral rehydration and electrolyte replacement should be done wherever necessary.

Prophylaxis

General prophylaxis is as for all fecal-oral infections. Food and water have to be protected from contamination with human excreta.

- Detection and treatment of carriers and their exclusion from food handling occupations will help in limiting the spread of infection.
- Health education and inclusion of healthy personal habits helps in control.

NONPATHOGENIC INTESTINAL AMOEBIA

Entamoeba Coli

E. coli was first described by Lewis (1870) and Cunningham (1871) in Kolkata and its presence in healthy persons was reported by Grassi (1878).

- It is worldwide in distribution and a nonpathogenic commensal intestinal amoeba.
- It is larger than *E. histolytica* about 20–50 μm with sluggish motility and contains ingested bacteria but no red cells.
- The nucleus is clearly visible in unstained films and has a large eccentric karyosome and thick nuclear membrane lined with coarse granules of chromatin (Fig. 3.7A and B).
- Cysts are large, 10–30 μm in size, with a prominent glycogen mass in the early stage. The chromatoid bodies are **splinter-like and irregular**. The mature cyst has **8 nuclei** (Fig. 3.7C).
- The life cycle is the same as in *E. histolytica* except that it remains a luminal commensal without tissue invasion and is nonpathogenic.

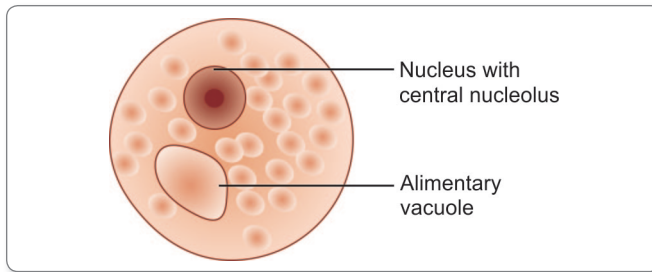


Fig. 3.8: Trophozoite of *Entamoeba hartmanni*

Entamoeba Hartmanni

E. hartmanni occurs wherever *E. histolytica* is found. It is now considered to be a separate species of nonpathogenic commensal intestinal amoeba.

- It is much smaller than *E. histolytica*, the trophozoite measuring 4–12 μm and cyst 5–10 μm in size (Fig. 3.8).
 - Trophozoites do not ingest red cells and their motility is less vigorous.
 - The cyst resembles that of *Endolimax nana*.
- Differential features of cyst and trophozoites of *E. coli*, *E. hartmanni*, and *E. histolytica* are shown in Table 3.4.

Entamoeba Gingivalis

E. gingivalis was the first amoeba of humans, discovered by Gros in 1849.

- It is global in distribution.
- Only the trophozoite is found; the cystic stage being apparently absent.
- The trophozoite is about 10–20 μm , actively motile with multiple pseudopodia.
- The cytoplasm contains food vacuoles with ingested bacteria, leucocytes, and epithelial cells.
- Nucleus is round with central karyosome lined by coarse chromatin granules.
- The amoeba lives in gingival tissues and is abundant in unhygienic mouths. It is a commensal and is not considered to cause any disease.
- It is transmitted by direct oral contact.
- *E. gingivalis* have been found in bronchial washings and vaginal and cervical smears, where it can be mistaken for *E. histolytica*.

Endolimax Nana

This common commensal amoeba is widely distributed.

- It lives in the human intestine.
- The trophozoite is small (*nana: small*), less than 10 μm in size with a sluggish motility (Fig. 3.9A).
- The nucleus has conspicuous karyosome connected to nuclear membrane by one or none coarse strands.
- The cyst is small, oval, and quadrinucleate with glycogen mass and chromidial bars, which are inconspicuous or absent (Fig. 3.9B).
- It is non-pathogenic.

Table 3.4: Differential Features of Intestinal Entamoebae

	<i>E. histolytica</i>	<i>E. coli</i>	<i>E. hartmanni</i>
Trophozoite			
Size (μm)	12–60	20–50	4–12
Motility	Active	Sluggish	Active
Pseudopodia	Finger-shaped, rapidly extruded	Short, blunt slowly extruded	Finger-shaped, rapidly extruded
Cytoplasm	Clearly defined into ectoplasm and endoplasm	Differentiation not distinct	Clearly defined into ectoplasm and endoplasm
Inclusions	RBCs present, no bacteria	Bacteria and other particles, no RBCs	Bacteria and other particles, no RBCs
Nucleus	Not clearly visible in unstained films	Visible in unstained films	Not visible in unstained films
Karyosome	Small, central	Large, eccentric	Small, eccentric
Nuclear Membrane	Delicate, with fine chromatin dots	Thick, with coarse chromatin granules	Coarse chromatin granules
Cyst			
Size (μm)	10–15	10–30	5–10
Nuclei in mature cyst	4	8	4
Glycogen mass	Seen in uninucleate, but not in quadinucleate stage	Seen up to quadrinucleate stage	Seen in uninucleate, but not in quadinucleate stage
chromidial	1–4 with rounded ends	Splinter like with angular ends	Many with irregular shape

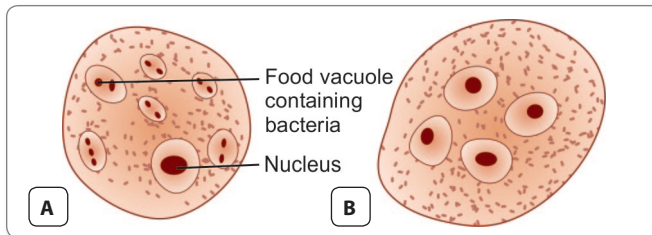


Fig. 3.9: *Endolimax nana*; A. Vegetative form; B. Quadrinucleate cyst

Iodamoeba Buetschlii

This is widely distributed, though less common than *E. coli* and *E. nana*.

- The trophozoite is small, 6–12 μm , with conspicuous nucleus (Fig. 3.10A).
- The prominent karyosome is half the size of the nucleus, having bull's eye appearance.
- The cyst is oval, uniucleate, and has a prominent iodine staining glycogen mass (**iodophilic body**). Hence, the name '*Iodamoeba*'. It is non-pathogenic (Fig. 3.10B).

The comparative morphology of amoebae infecting humans is illustrated in Fig. 3.11.

PATHOGENIC FREE-LIVING AMOEBAE

Among the numerous types of free-living amoebae found in water and soil, a few are potentially pathogenic and can cause human infections.

- **Primary amoebic meningoencephalitis (PAM)** – caused by amoeboflagellate *Naegleria* (**the brain eating amoeba**).

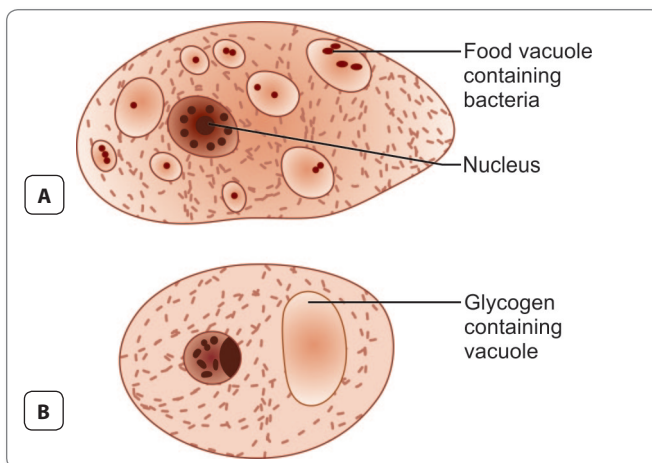


Fig. 3.10: *Iodamoeba buetschlii*; A. Vegetative form; B. Cyst

	Trophozoite	Cyst	Nucleus
<i>E. histolytica</i>			
<i>E. coli</i>			
<i>E. gingivalis</i>			
<i>E. nana</i>			
<i>I. buetschlii</i>			
<i>D. fragilis</i>			

Fig. 3.11: Comparative morphology of amoebae infecting humans, showing trophozoite and cyst stages, as well as enlarged representation of their nuclear structure

- **Granulomatous amoebic encephalitis (GAE)** and **chronic amoebic keratitis (CAK)** – caused by *Acanthamoeba*.

A few instances of GAE caused by lyptomyxid amoeba like *Balamuthia* have also been reported. While PAM and CAK occur in previously healthy individual, GAE has been associated with immunodeficient patients.

The term **amphizoic** has been used for organisms such as these, which can multiply both in the body of a host (**endozoic**) and in free-living (**exozoic**) conditions.

Naegleria Fowleri

It is the only species of genus *Naegleria*, which infects man.

N. fowleri causes the disease **primary amoebic meningoencephalitis (PAM)**, a brain infection that leads to destruction of brain tissue.

History and Distribution

N. fowleri is named after Fowler, who along with Carter described it first from Australia in 1965.

- *N. fowleri* is a heat-loving (**thermophilic**) amoeba that thrives in warm water at low oxygen tension and is commonly found in warm freshwater (e.g. lakes, rivers, and springs) and soil.
- It is world wide in distribution.
- In the last 10 years from 2002 to 2011, 32 infections were reported in the US, and in India, a total of 17 cases have been reported so far.

Morphology

N. fowleri occurs in 3 forms:

- Cyst
- Amoeboid trophozoite form
- Flagellate trophozoite form

Trophozoite Stage

The trophozoites occur in 2 forms, **amoeboid and flagellate**.

Amoeboid form

The amoeboid form is about 10–20 μm , showing rounded pseudopodia (**lobopodia**), a spherical nucleus with big endosome, and pulsating vacuoles.

- With electron microscopy, vacuole appear to be densely granular in contrast to highly vacuolated body of amoeba and are called as **amoebostomes**. They are used for engulfing RBCs and WBCs and vary in number, depending on the species.
- Amoeboid form is the feeding, growing, and replicating form of the parasite, seen on the surface of vegetation, mud, and water.
- It is the invasive stage of the parasite and the infective form of the parasite.

Flagellate form

The biflagellate form occurs when trophozoites are transferred to distilled water.

- This transformation of trophozoites to biflagellate pear-shaped form occurs within a minute.
- The flagellate can revert to the amoeboid form, hence *N. fowleri* is classified as **amoeboflagellate**.

Cyst Stage

Trophozoites encyst due to unfavorable conditions like food deprivation, dessication, cold temperature, etc.

- The cyst is 7–10 μm in diameter and has a smooth double wall.
- They are the resting or the dormant form and can resist unfavorable conditions, such as drying and chlorine up to 50 ppm.
- The trophozoites can withstand moderate heat (45°C), but die at chlorine levels of 2 ppm and salinity of 0.7%.
- Cysts and flagellate forms of *N. fowleri* have never been found in tissues of cerebrospinal fluid (CSF).

Life Cycle

Typically, infection occurs when people go swimming or diving in warm freshwater river or ponds and poorly-maintained swimming pools or nasal irrigation using contaminated tap water (Fig. 3.12).

- The life cycle of *N. fowleri* is completed in the external environment.
- The amoeboid form of trophozoite multiplies by binary fission.
- Under unfavorable conditions, it forms a cyst and which undergoes excystation in favorable conditions.
- Flagellate form of trophozoite helps in the spread of *N. fowleri* to new water bodies. Since the amoeboid form is the invasive stage, hence, the flagellate forms revert to amoeboid forms to become infective to man.

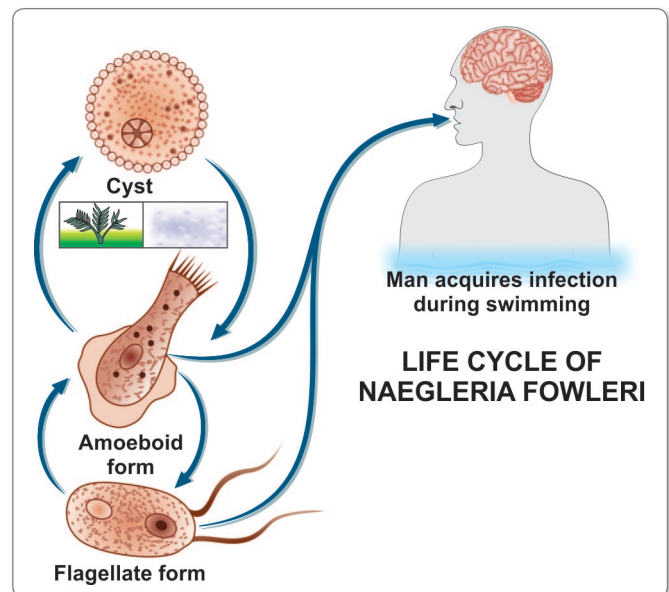


Fig. 3.12: Life cycle of *Naegleria fowleri*

Table 3.5: Differential features of *Naegleria* and *Acanthamoeba*

	<i>Naegleria</i>	<i>Acanthamoeba</i>
Disease	Primary amoebic meningoencephalitis (PAM)	Granulomatous amoebic encephalitis (GAE) and keratitis
Portal of entry	Nose	Upper Respiratory tract (?), cornea
Clinical course	Acute	Subacute or chronic
Pathogenicity	Acute suppurative inflammation	Granulomatous inflammation
Morphological forms	3 stages: trophozoite, cyst and flagellate form	2 stages: trophozoite and cyst flagellate form absent
Trophozoite	10–20 µm, with a single pseudopodia	20–50 µm, with spine-like pseudopodia
Cyst	7–10 µm, round with smooth wall	15–25 µm, polygonal double-walled with wrinkled surface
Nuclear division	By promitosis, nucleolus divides, nuclear membrane persists	Nuclear membrane dissolves
WBC in CSF	Predominantly neutrophils	Predominantly lymphocytes

Pathogenicity and Clinical Features

Patients are mostly previously healthy young adults or children.

- Human infection comes from water containing the amoebae and usually follows swimming or diving in ponds.
- The amoebae invade the nasal mucosa and pass through the olfactory nerve branches in the cribriform plate into the meninges, and brain to initiate an acute purulent meningitis and encephalitis, **called as primary amoebic meningo encephalitis (PAM)**.
- The incubation period varies from 2 days to 2 weeks.
- In the incubation period, the patient experiences anosmia.
- The disease advances rapidly, causing fever, headache, vomiting, stiff neck, ataxia, seizure, and coma.
- Cranial nerve palsies, especially of the third, fourth, and sixth nerves have also been documented.
- The disease almost always ends fatally within a week (average 5 days).

Laboratory Diagnosis

The diagnosis of PAM is based on the finding of motile *Naegleria* trophozoites in wet mounts of freshly-obtained CSF.

Cerebrospinal Fluid Examination

The CSF is cloudy to purulent, with prominent neutrophilic leucocytosis, elevated protein, and low glucose, resembling pyogenic meningitis.

- Wet film examination of CSF may show trophozoites.
- Cysts are not found in CSF or brain.
- At autopsy, trophozoites can be demonstrated in brain histologically by immunofluorescent staining.

Culture

N. fowleri can be grown in several kinds of liquid axenic media or non-nutrient agar plates coated with *Escherichia coli*. Both trophozoites and cysts occur in culture.

Molecular Diagnosis

Newer tests based on polymerase chain reaction (PCR) technology are being developed.

Treatment

The drug of choice is amphotericin-B intravenously. It can also be instilled directly into the brain.

- Treatment combining miconazole and sulfadiazine has shown limited success, only when administered early.
- More than 95% cases of PAM are fatal despite of treatment.

Acanthamoeba Species

A. culbertsoni (formerly, *Hartmanella culbertsoni*) is the species most often responsible for human infection but other species like *A. polyphagia*, *A. castalleni*, and *A. astromyx* have also been reported.

Distribution

This is an opportunistic protozoan pathogen found worldwide in the environment in water and soil.

- Approximately, 400 cases have been reported worldwide.

Morphology

Acanthamoeba exists as active trophozoite form and a resistant cystic form.

- The trophozoite is large, 20–50 µm in size and characterized by spine-like pseudopodia (**acanthopodia**).
- It differs from *Naegleria* in not having a flagellate stage and in forming cysts in tissues (Table 3.5).
- The polygonal double-walled cysts are highly resistant.
- The cysts are present in all types of environment, all over the world.

Life Cycle

- Both trophozoites and cysts are infective.
- Human beings acquire by inhalation of cyst or trophozoite, ingestion of cysts, or through traumatized skin or eyes (Fig. 3.13).
- After inhalation of aerosol or dust containing trophozoites and cysts, the trophozoites reach the lungs and from there, they invade the central nervous system through the blood stream, producing granulomatous amoebic encephalitis (**GAE**).

Pathogenesis and Clinical Features

- Infection usually occurs in patients with immunodeficiency, diabetes, malignancies, malnutrition, systemic lupus erythematosus (SLE), or alcoholism.
- The parasite spreads hematogenously into central nervous system. Subsequent invasion of the connective tissue and induction of proinflammatory responses lead to neuronal damage that can be fatal within days.
- A postmortem biopsy reveals severe edema and hemorrhagic necrosis.

Clinical Disease

It presents chiefly as 2 chronic conditions—keratitis and encephalitis.

- **Acanthamoeba keratitis:** An infection of the eye that typically occurs in healthy persons and develops from the entry of the amoebic cyst through abrasions on the cornea.
 - Majority of such cases have been associated with the use of contact lenses.
 - The picture resembles that of severe herpetic keratitis with a slow relapsing course, but the eye is severely painful in the amoebic infection.
 - Unilateral photophobia, excessive tearing, redness and foreign body sensation are the earliest signs and symptoms; disease is bilateral in some contact lens users.
 - Keratitis and uveitis can result in permanent visual impairment or blindness.
- **Granulomatous amoebic encephalitis(GAE):** It is a serious infection of the brain and spinal cord that

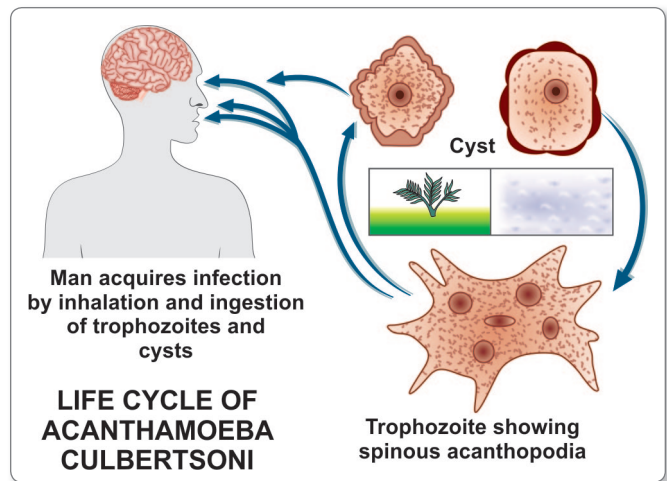


Fig. 3.13: Life cycle of *Acanthamoeba culbertsoni*

typically occurs in persons with a compromised immune system.

- GAE is believed to follow inhalation of the dried cysts.
- The incubation period is long and the evolution of the illness is slow.
- Clinical picture is that of intracranial space-occupying lesions with seizures, pareses, and mental deterioration.
- **Disseminated infection:** In immunocompromised states like acquired immunodeficiency syndrome (AIDS), a widespread infection can affect skin, lungs, sinuses, and other organs independently or in combination.

Laboratory Diagnosis

- **Diagnosis of amoebic keratitis** is made by demonstration of the cyst in corneal scrapings by wet mount, histology and culture. Growth can be obtained from corneal scrapings inoculated on nutrient agar, overlaid with live or dead *Escherichia coli* and incubated at 30°C.
- **Diagnosis of GAE** is made by demonstration of trophozoites and cysts in brain biopsy, culture, and immunofluorescence microscopy using monoclonal antibodies.
 - CSF shows lymphocytic pleocytosis, slightly elevated protein levels, and normal or slightly decreased glucose levels.
 - CT scan of brain provides inconclusive findings.

Treatment

In **acanthamoeba keratitis**, current therapy involves topical administration of biguanide or chlorhexidine with

or without diamidine agent. In severe cases, where vision is threatened, penetrating keratoplasty can be done.

No effective **treatment** is available **for GAE**. Multidrug combinations including pentamidine, sulfadiazine, rifampicin, and fluconazole are being used with limited success.

Balamuthia Mandrillaris

B. mandrillaris, a leptomixid free-living amoeba, is a newly identified species reported to cause GAE.

Morphology

It exists in amoeboid trophozoite stage. The flagellate stage is absent.

- It is relatively large (12–60 µm), irregular in shape, and actively motile by broad pseudopodia.
- Cyst of *B. mandrillaris* are usually spherical (6–20 µm), surrounded by a three-layered cyst wall—outer irregular

ectocyst, a middle mesocyst and an inner endocyst round wall. Under light microscopy, it appears to have two walls—an outer irregular wall and an inner smooth wall.

- Infection is transmitted through respiratory tract skin lesions; or eyes.
- Life cycle is similar to that of *Acanthamoeba* spp.

Clinical Disease

It causes granulomatous amoebic encephalitis in both healthy and immunocompromised hosts particularly in children and elderly.

Laboratory Diagnosis

Laboratory diagnosis is done by identifying trophozoites of *B. mandrillaris* in the CSF and trophozoites and cysts in brain tissue.

PCR also gives reliable diagnosis.

Key points of Amoebae

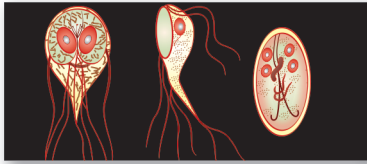
- *E. histolytica* is found in human colon and is mainly asymptomatic.
- Cyst contains glycogen mass and 1–4 chromatid bars.
- Pathogenic strains are identified by genetic markers and zymodeme analysis.
- **Stools:** In amoebic dysentery, stool are copious foul smelling, brownish black often with blood-streaked mucus.
- **Amoebic ulcers:** Typical ulcers are discrete, flask-shaped, with ragged undermined margin, found in caecum and sigmoido-rectal region.
- Amoebic granuloma or amoeboma may develop from chronic ulcers.
- **Extraintestinal complications:** Amoebic hepatitis and liver abscess are the most common.
- Abscesses in other organs such as lung, brain, spleen, and genitourinary tract may result from hematogenous spread or by direct spread from hepatic lesion.
- **Diagnosis:** By demonstration of trophozoites and cyst in stool and also by serological tests and imaging techniques in hepatic amoebiasis.
- **Treatment:** By Metronidazole or tinidazole along with paromomycin, diloxanide furoate, or chloroquine.
- *E. hartmanni*, *E. coli*, *E. gingivalis*, *E. nana*, and *Iodamoeba* are commensals and non-pathogenic amoebae.
- *Naegleria* and *Acanthamoeba* are pathogenic free-living amoeba.
- *N. fowleri* occurs in 3 forms – cyst, trophozoite, and flagellate. It causes PAM.
- *Acanthamoeba* species cause amoebic keratitis and also GAE in immunocompromised subjects.

Review Questions

1. Describe briefly the life cycle and laboratory diagnosis of *Entamoeba histolytica*.
2. Write short notes on:

(a) Extraintestinal amoebiasis	(b) Free-living amoebae
--------------------------------	-------------------------
3. Differentiate between:

(a) Amoebic dysentery and bacillary dysentery	(b) <i>Entamoeba histolytica</i> and <i>Entamoeba coli</i>
(b) <i>Naegleria</i> and <i>Acanthamoeba</i>	



Intestinal, Oral, and Genital Flagellates

4

Parasitic protozoa, which possess **whip-like flagella** as their organs of locomotion are called as **flagellates** and classified as—

Phylum: Sarcomastigophora

Subphylum: Mastigophora

Class: Zoomastigophora (*mastix: whip*)

- Depending on their habitat, they can be considered under:
 - **Lumen-dwelling flagellates:** Flagellates found in the alimentary tract and urogenital tract (Table 4.1).
 - **Hemoflagellates:** Flagellates found in blood and tissues (Table 4.1).
- Most luminal flagellates are nonpathogenic commensals. Two of them cause clinical diseases—*Giardia lamblia*, which can cause diarrhea and *Trichomonas vaginalis*, which can produce vaginitis and urethritis.

Giardia Lamblia

History and Distribution

It is one of the earliest protozoan parasite to have been recorded.

- The flagellate was first observed by Dutch scientist Antonie von Leeuwenhoek (1681) in his own stools.
- It is named '*Giardia*' after Professor Giard of Paris and '*lamblia*' after Professor Lambale of Prague, who gave a detailed description of the parasite.
- It is the most common protozoan pathogen and is worldwide in distribution.
- Endemicity is very high in areas with low sanitation, especially tropics and subtropics. Visitors to such places frequently develop traveller's diarrhea caused by giardiasis through contaminated water.

Table 4.1: Flagellates

Group	Parasites	Habitat
Lumen-dwelling flagellates	<i>Giardia lamblia</i> <i>Trichomonas vaginalis</i> <i>Trichomonas tenax</i> <i>Trichomonas hominis</i> <i>Chilomastix mesnili</i> <i>Enteromonas hominis</i> <i>Retortamonas intestinalis</i> <i>Dientamoeba fragilis</i>	Duodenum and jejunum Vagina and urethra Mouth Large intestine (caecum) Large intestine (caecum) Large intestine (colon) Large intestine (colon) Large intestine (caecum and colon)
Hemoflagellates	<i>Leishmania</i> spp. <i>Trypanosoma brucei</i> <i>Trypanosoma cruzi</i>	Reticuloendothelial cells Connective tissue and blood Reticuloendothelial cells and blood

Habitat

G. lamblia lives in the duodenum and upper jejunum and is the only protozoan parasite found in the lumen of the human small intestine.



Protozoans found in small intestine

- *Giardia lamblia*
- *Isoospora belli*
- *Cyclospora caytenensis*
- *Cryptosporidium parvum*
- *Sarcocystis hominis* and *suihominis*

Morphology

It exists in 2 forms:

- Trophozoite (or vegetative form)
- Cyst (or cystic form).

Trophozoite

The trophozoite is in the shape of a tennis racket (**heart-shaped** or **pyriform shaped**) and is rounded anteriorly and pointed posteriorly (Figs. 4.1 and 4.2A and B).

- It measures 15 μm x 9 μm wide and 4 μm thick.
- Dorsally, it is convex and ventrally, it has a concave sucking disc, which helps in its attachment to the intestinal mucosa.
- It is bilaterally symmetrical and possesses.
 - 1 pair of nuclei
 - 4 pairs of flagella
 - Blepharoplast, from which the flagella arise (4 pairs)
 - 1 pair of axostyles, running along the midline

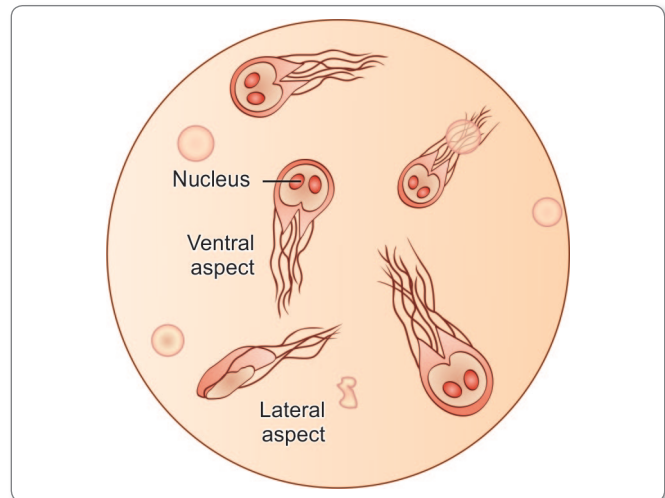


Fig. 4.1: *Giardia lamblia* in duodenal fluid wet preparation. Magnification X 1500

- Two sausage-shaped parabasal or median bodies, lying transversely posterior to the sucking disc.
- The trophozoite is motile, with a slow oscillation about its long axis, often resembling **falling leaf**.

Cyst

It is the infective form of the parasite (Fig. 4.2C).

- The cyst is small and oval, measuring 12 μm x 8 μm and is surrounded by a hyaline cyst wall.
- Its internal structure includes 2 pairs of nuclei grouped at one end. A young cyst contains 1 pair of nuclei.
- The axostyle lies diagonally, forming a dividing line within cyst wall.
- Remnants of the flagella and the sucking disc may be seen in the young cyst.

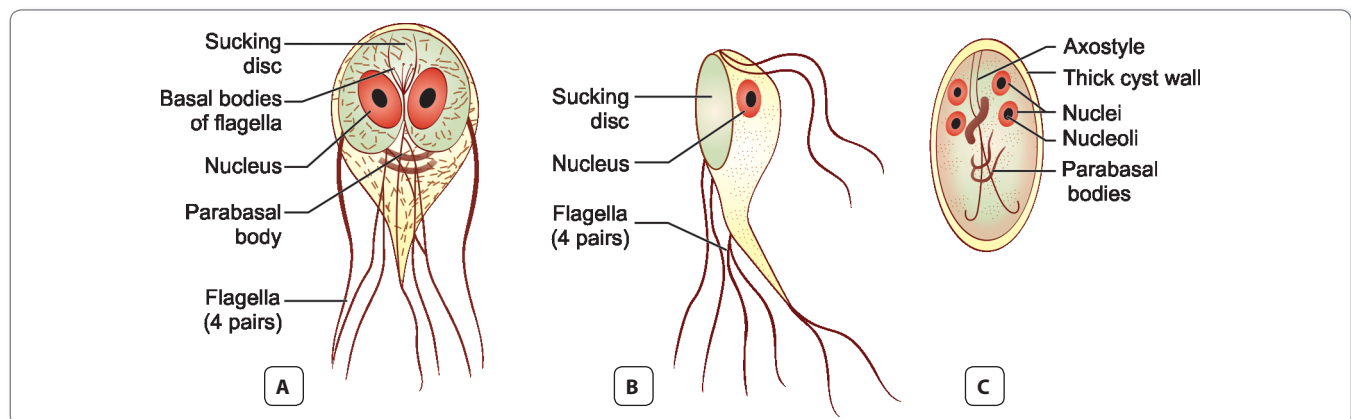


Fig. 4.2: Trophozoite. **A.** Ventral view; **B.** Lateral view; **C.** Quadrinucleate Cyst

Life Cycle

Giardia passes its life cycle in **1 host**.

Infective form: Mature cyst.

Mode of transmission:

- Man acquires infection by ingestion of cysts in contaminated water and food.
- Direct person-to-person transmission may also occur in children, male homosexuals, and mentally-ill persons.
- Enhanced susceptibility to giardiasis is associated with blood group A, achlorhydria, use of cannabis, chronic pancreatitis, malnutrition, and immune defects such as 19A deficiency and hypogammaglobulinemia.
- Within half an hour of ingestion, the cyst hatches out into two trophozoites, which multiply successively by binary fission and colonize in the duodenum (Fig. 4.3).
- The trophozoites live in the duodenum and upper part of jejunum, feeding by pinocytosis.
- During unfavorable conditions, encystation occurs usually in colon (Fig. 4.3).
- Cysts are passed in stool and remain viable in soil and water for several weeks.
- There may be 200,000 cysts passed per gram of feces.
- **Infective dose** is 10–100 cysts.

Pathogenicity and Clinical Features

G. lamblia is typically seen within the crypts of duodenal and jejunal mucosa. **It does not invade the tissue**, but remains tightly adhered to intestinal epithelium by means of the sucking disc.

- They may cause abnormalities of villous architecture by cell apoptosis and increased lymphatic infiltration of lamina propria.
- Variant specific surface proteins (VSSP) of giardia play an important role in virulence and infectivity of the parasite.
- Often they are asymptomatic, but in some cases, *Giardia* may lead to mucus diarrhea, **fat malabsorption** (steatorrhea), dull epigastric pain, and flatulence. The stool contains excess mucus and fat but no blood.
- Children may develop chronic diarrhea, malabsorption of fat, vitamin A, protein, sugars like xylose disaccharides, weight loss, and sprue-like syndrome.
- Occasionally, *Giardia* may colonize the gall bladder, causing biliary colic and jaundice.
- Incubation period is variable, but is usually about **2 weeks**.

Protozoan parasites causing diarrhea

- *Giardia lamblia*
- *Entamoeba histolytica*
- *Cyclospora cayetanensis*
- *Cryptosporidium parvum*
- *Isoospora belli*

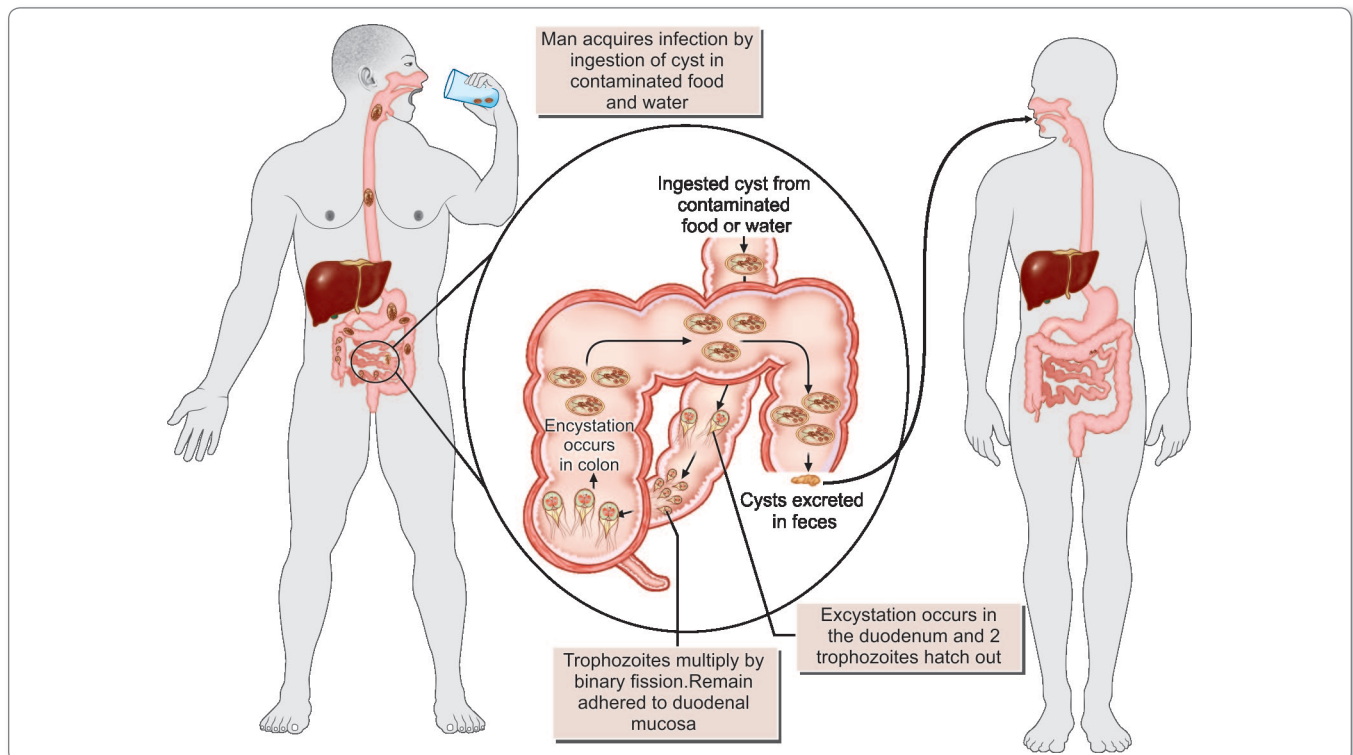
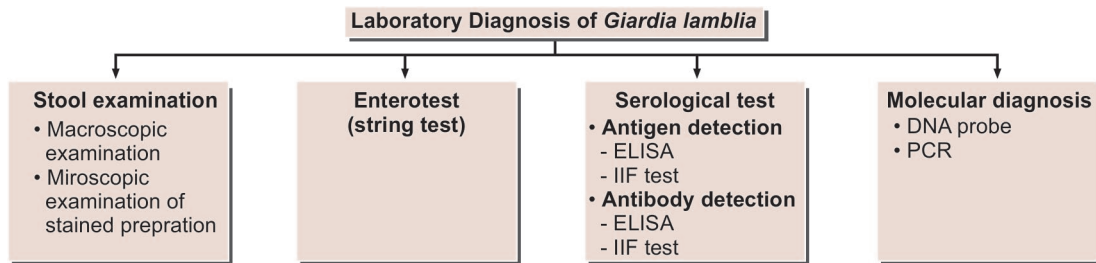


Fig. 4.3: Life cycle of *Giardia lamblia*



Flowchart 4.1: Laboratory diagnosis of *Giardia lamblia*

Laboratory Diagnosis

Stool Examination

Giardiasis can be diagnosed by identification of cysts of *Giardia lamblia* in the formed stools and the trophozoites and cysts of the parasite in diarrheal stools (Flowchart 4.1).

- On macroscopic examination fecal specimens containing *G. lamblia* may have an offensive odor, are pale colored and fatty, and float in water.
- On microscopic examination, cysts and trophozoites can be found in diarrheal stools by saline and iodine wet preparations.
- Often multiple specimens need to be examined and concentration techniques like formal ether or zinc acetate are used. In asymptomatic carriers, only the cysts are seen.

Enterotest (String test)

A useful method for obtaining duodenal specimen is **enterotest**. A coiled thread inside a small weighted gelatin capsule is swallowed by the patient, after attaching the free end of the thread in the cheek. The capsule passes through the stomach to the duodenum. After 2 hours, the thread is withdrawn, placed in saline, and is mechanically shaken. The centrifuged deposit of the saline is examined for *Giardia*. The use of enterotest is not recommended because of the very high cost of the test.

Serodiagnosis

Antigen detection

Enzyme-linked immunosorbent assay (ELISA), immunochromatographic strip tests and indirect immunofluorescent (IIF) tests using monoclonal antibodies have been developed for detection of *Giardia* antigens in feces (Flowchart 4.1).

- The presence of antigen indicates active infection.
- Commercially available ELISA kits (ProSpec T/*Giardia* kit) detects *Giardia*-specific antigen 65 (GAS 65).

- The sensitivity of the test is 95% and specificity is 100%, when compared to conventional microscopy.
- The test may be used for quantification of cysts and in epidemiological and control studies, but not for routine use.

Antibody detection

IIF test and ELISA are used to detect antibodies against *Giardia*.

- Demonstration of antibodies is useful in the epidemiological and pathophysiological studies.
- These tests cannot differentiate between recent and past infection and lack sensitivity and specificity.

Molecular Method

DNA probes and polymerase chain reaction (PCR) have been used to demonstrate parasitic genome in the stool specimen (Flowchart 4.1).

Treatment

Metronidazole (250 mg, thrice daily for 5–7 days) and tinidazole (2 g single dose) are the drugs of choice.

- Cure rates with metronidazole are more than 90%.
- Tinidazole is more effective than metronidazole.
- Furuzolidone and nitazoxamide are preferred in children, as they have fewer adverse effects.
- Parmomycin, an oral aminoglycoside can be given to symptomatic pregnant females.

Note: Only symptomatic cases need treatment.

Prophylaxis

Giardiasis can be prevented by following measures:

- Proper disposal of waste water and feces.
- Practice of personal hygiene like hand-washing before eating and proper disposal of diapers.
- Prevention of food and water contamination. Community chlorination of water is ineffective for inactivating cysts. Boiling of water and filtration by membrane filters are required.

Key points of *Giardia lamblia*

- *Giardia* is the only protozoan parasite found in the lumen of the human small intestine (duodenum and jejunum).
- Trophozoites are pear-shaped, bilaterally symmetrical with 2 nuclei, 4 pairs of flagella, and a ventral concave sucking disc. They exhibit motility resembling a 'falling leaf'.
- Ellipsoid cysts contain 4 nuclei with remnants of flagella.
- **Infective form:** Ellipsoid cysts.
- **Clinical features:** Mostly asymptomatic but in some cases may cause diarrhea, dull epigastric pain, and malabsorption. Stool contains excess mucus but no blood.
- **Diagnosis:** By microscopic demonstration of trophozoites or cysts in stool, enterotest, and serodiagnosis by ELISA (ProSpec *T/Giardia* antigen assay).
- **Treatment:** Metronidazole and tinidazole are the drugs of choice.

Trichomonas

Trichomonas differs from other flagellates, as they exist only in trophozoite stage. Cystic stage is not seen.

- Genus *Trichomonas* has 3 species, which occur in humans (Fig. 4.4).
 - *T. vaginalis* (Fig. 4.4 A)
 - *T. hominis* (Fig. 4.4 B)
 - *T. tenax* (Fig. 4.4 C)

Trichomonas Vaginalis

History and Distribution

T. vaginalis was first observed by Donne (1836) in vaginal secretion.

- Prevalence of trichomoniasis varies from 5% patients at hospitals to 75% in sexual workers.

Morphology

It is **pear-shaped** or **ovoid** and measures 10–30 μm in length and 5–10 μm in breadth with a short undulating membrane reaching upto the middle of the body (Fig. 4.4A).

- It has four anterior flagella and fifth running along the outer margin of the undulating membrane, which is supported at its base by a flexible rod, **costa**.
- A prominent **axostyle** runs throughout the length of the body and projects posteriorly like a tail.
- The cytoplasm shows prominent siderophilic granules, which are most numerous alongside the axostyle and costa.
- It is motile with a rapid **jerky or twitching** type movement.

Habitat

In females, it lives in vagina and cervix and may also be found in Bartholin's glands, urethra, and urinary bladder. In males, it occurs mainly in the anterior urethra, but may also be found in the prostate and preputial sac.

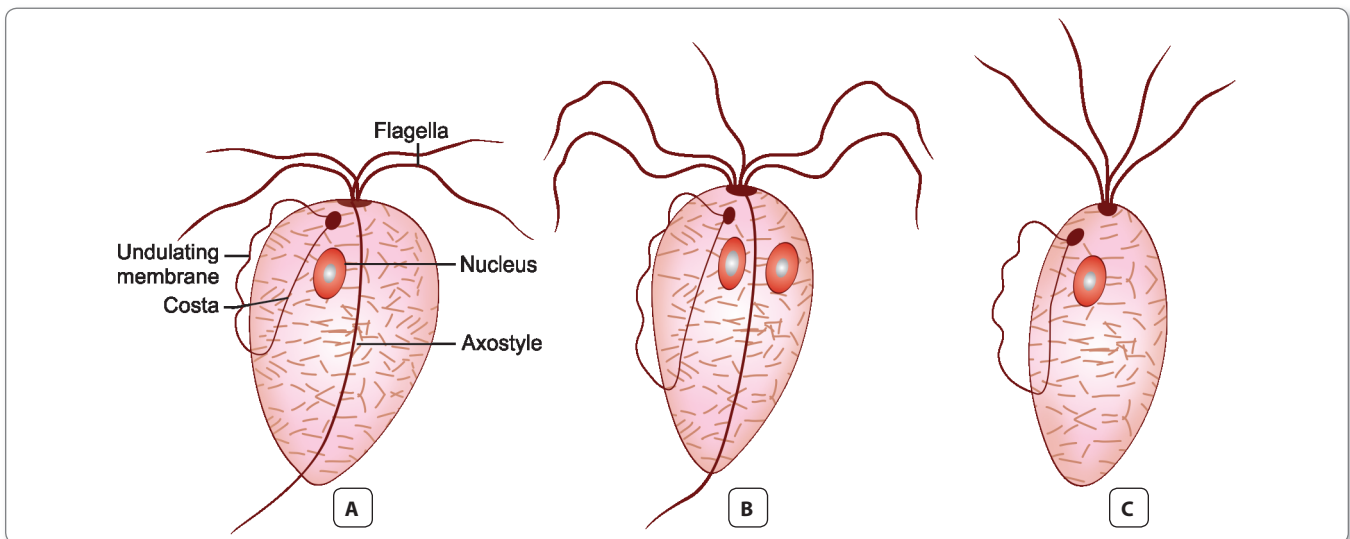


Fig. 4.4: *Trichomonas* species. A. *T. vaginalis*; B. *T. hominis*; C. *T. tenax*

Life Cycle

Life cycle of *T. vaginalis* is completed in a single host either male or female.

Mode of transmission:

- The trophozoite cannot survive outside and so infection has to be transmitted directly from person-to-person. Sexual transmission is the usual mode of infection.
- Trichomoniasis often coexists with other sexually transmitted diseases; like candidiasis, gonorrhea, syphilis, or human immunodeficiency virus (HIV).
- Babies may get infected during birth.
- Fomites such as towels have been implicated in transmission.
- Trophozoites divide by **binary fission**.
- As cysts are not formed, the **trophozoite** itself is the **infective form**.
- Incubation period is roughly 10 days.



Protozoa transmitted by sexual contact

- *Trichomonas vaginalis*
- *Giardia lamblia*
- *Entamoeba histolytica*

Pathogenesis

T. vaginalis particularly infects squamous epithelium and not columnar epithelium. It secretes cystine proteases, lactic acid, and acetic acid, which disrupt the glycogen levels and lower the pH of the vaginal fluid.

- It is an **obligate parasite** and cannot live without close association with the vaginal, urethral, or prostatic tissues.
- Parasite causes petechial hemorrhage (**strawberry mucosa**), metaplastic changes, and desquamation of the vaginal epithelium.
- Intracellular edema and so called **chicken-like epithelium**, is the most characteristic feature of trichomoniasis.

Clinical Features

Infection is often asymptomatic, particularly in males, although some may develop urethritis, epididymitis, and prostatitis.

- In females, it may produce severe pruritic vaginitis with an offensive, yellowish green, often frothy discharge, dysuria, and dyspareunia. Cervical erosion is common. Endometritis and pyosalpingitis are infrequent complications.
- Rarely, neonatal pneumonia and conjunctivitis have been reported in infants born to infected mothers.

- The incubation period of trichomoniasis is 4 days to 4 weeks.

Laboratory Diagnosis

Microscopic examination

- Vaginal or urethral discharge is examined microscopically in saline wet mount preparation for characteristic jerky and twitching motility and shape. In males, trophozoites may be found in urine or prostatic secretions.
- Fixed smears may be stained with acridine orange, papanicolaou, and Giemsa stains.
- Direct fluorescent antibody (DFA) is another method of detection of parasite and is more sensitive than the wet mount.

Culture

Culture is recommended when direct microscopy is negative and is considered as a '**gold standard**' as well as the most sensitive (95%) method for the diagnosis of *T. vaginalis* infection.

- It grows best at 35°–37°C under anaerobic conditions. The optimal pH for growth is 5.5–6.0.
- It can be grown in a variety of solid or liquid media, tissue culture, and eggs. Cysteine-peptone-liver-maltose (CPLM) medium and plastic envelope medium (PEM) are often used.

Serology

ELISA is used for demonstration of *T. vaginalis* antigen in vaginal smear using a monoclonal antibody for 65-KDA surface polypeptide of *T. vaginalis*.

Molecular method

DNA hybridization and PCR are also highly sensitive (97%) and specific (98%) tests for the diagnosis of trichomoniasis.

Treatment

- Simultaneous treatment of both partners is recommended.
- Metronidazole 2 g orally as a single dose or 500 mg orally twice a day for 7 days is the drug of choice.
 - In patients not responding to treatment with standard regime, the dose of metronidazole may be increased or it may be administered parenterally.
 - In pregnancy, metronidazole is safe in second and third trimesters.

Prophylaxis

Prevention is same as for other sexually transmitted diseases.

- Avoidance of sexual contact with infected partners and use of barrier method during intercourse prevent the disease.
- Patient's sexual partner should be tested for *T. vaginalis* when necessary.

Trichomonas Tenax

T. tenax, also known as *T. buccalis*, is a harmless commensal which lives in mouth-in the periodontal pockets, carious tooth cavities, and less often in tonsillar crypts.

- It is **smaller** (5–10 μm) than *T. vaginalis*.
- It is transmitted by kissing, through salivary droplets, and fomites. There are sporadic reports of its involvement in respiratory infections and thoracic abscesses.
- Better oral hygiene rapidly eliminates the infection and no therapy is indicated.

Trichomonas Hominis

T. hominis measures 8–12 μm, **pyriform-shaped**, and carries **5 anterior flagella** and an undulating membrane that extends the full length of the body.

- It is a **very harmless commensal** of the caecum.
- Microscopic examination of stool will reveal motile trophozoite of *T. hominis*.
- Transmission occurs in trophic form by fecal-oral route.

Key points of Trichomonas

- Trichomonas occurs only in trophozoite form, which is pear-shaped, with 5 flagella and an undulating membrane.
- The motility is rapid jerky or twitching type.
- **Habitat:** Vagina and cervix in female and urethra in males.
- **Clinical features:** Often asymptomatic in males. In females, it leads to pruritic vaginitis with greenish yellow discharge, strawberry mucosa and dysuria.
- **Diagnosis:** By wet mount microscopy of vaginal or urethral discharge, Culture (gold standard), PCR, and by demonstration of antigen in vaginal smear by ELISA.
- **Treatment:** Metronidazole is the drug of choice and simultaneous treatment of both partners is recommended.

Chilomastix Mesnili

This occurs as trophozoites and cysts (Fig. 4.5).

- The trophozoite is **pear-shaped** measuring 5–20 μm in length and 5–10 μm in breadth.
- At the anterior end, it has a **spherical nucleus**.

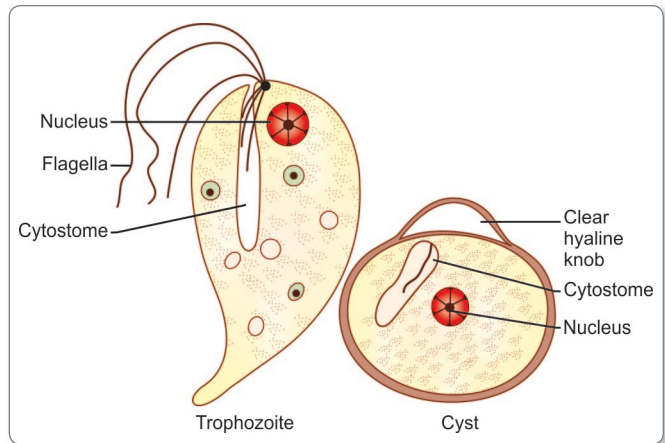


Fig. 4.5: Trophozoite and egg of *Chilomastix mesnili*

- A distinct spiral groove is seen on one side of the nucleus.
- The cysts are **lemon-shaped** having a spiral projection at the anterior end. It measures 5–10 μm in length and 4–6 μm in breadth and is surrounded by a thick cyst wall.
- Both trophozoites and cysts are demonstrated in the semi-formed stool.
- It is a **harmless commensal** of caecum where the organism feeds on bacteria and food debris. Since infection is acquired through ingestion of cysts, prevention depends on improved personal hygiene.

Enteromonas Hominis

E. hominis is a **non-pathogenic commensal** that lives in large intestine, mainly in the caecum.

- It exists in 2 forms: **trophozoite** and **cyst** (Fig. 4.6).
- The trophozoite is **pear-shaped**, with 3 anterior and 1 posterior flagella.

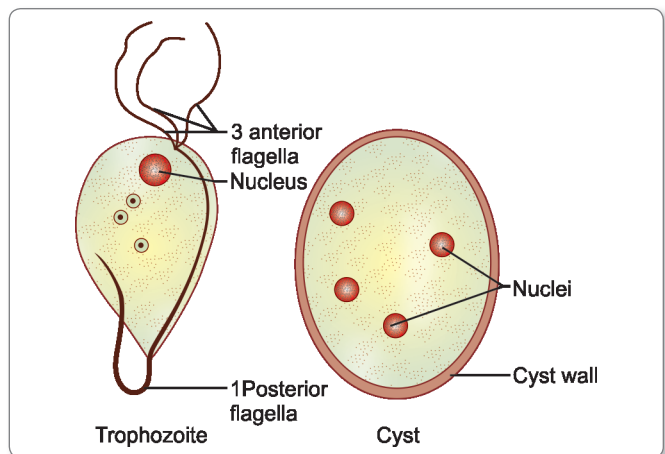


Fig. 4.6: Trophozoite and cyst of *Enteromonas hominis*

- It measures 5–10 μm in length and 3–6 μm in breadth.
- The cytoplasm contains numerous bacteria and an anteriorly placed nucleus but no cytostoma.
- It shows jerky forward movements.
- The **cyst** is oval in shape, measuring 5–8 μm in length and 4–6 μm in breadth.
 - It contains 2–4 nuclei.
 - The cyst of *E. hominis* may mimic a two-nucleated cyst of *E. nana*.
- Infection occurs through fecal-oral route by ingestion of cysts in contaminated food and water.
- Diagnosis is made by identification of trophozoites or cysts in the stool by iron-hematoxylin stain.

Retortamonas Intestinalis

Wenyon and O' Connor first observed the parasite in stool in Egypt.

- *R. intestinalis* is a small nonpathogenic flagellate found in the large intestine.
- It also exists in 2 forms—trophozoite and cyst.
- The trophozoite is elongated, **pyriform in shape**, measuring 5–10 μm in length and 3–4 μm in breadth.
 - The cytoplasm is granular and vacuolated.
 - It has a cleft-like cytosome, spherical nucleus, and central karyosome.
 - Two minute blepharoplasts are present near nucleus, from which two flagella originate.
 - The trophozoite multiplies by binary fission.
- The cyst is **ovoid or pyriform in shape**, measuring 6 μm in length and 3 μm in breadth.
- Water and food contaminated by cysts are the main source of infection.
- Diagnosis is made by identifying the cysts and trophozoites in the direct wet mount and iron hematoxylin-stained specimen of stool.

Dientamoeba Fragilis

D. fragilis was previously considered as an amoeba but has now been reclassified as an **amoeboflagellate**, based on electron microscopic study and antigenic similarity to *Trichomonas*.

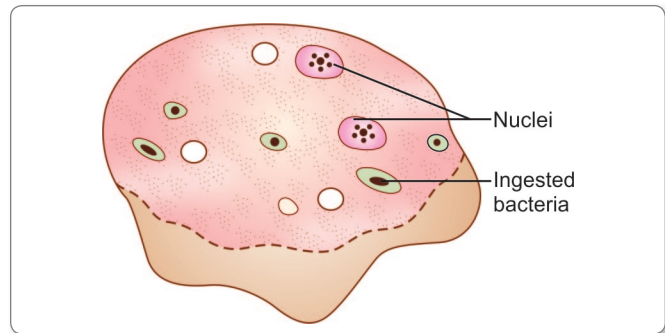


Fig. 4.7: Trophozoite of *Dientamoeba fragilis*

- It is unique as it has **only trophozoite stage but no cyst stage**.
- The name *Dientamoeba fragilis* is derived from the binucleate nature of trophozoite (**Dientamoeba**) and the fragmented appearance (**fragilis**) of its nuclear chromatin.
- It is seen worldwide and is reported to be the most common intestinal protozoan parasite in Canada.
- It lives in colonic mucosal crypts, feeding on bacteria. It does not invade tissues, but may rarely ingest RBCs.
- The trophozoite is 7–12 μm in diameter. It is motile with broad hyaline leaf-like pseudopodia. They have 1–4 nuclei; the binucleate form being the most common (Fig. 4.7). The nuclear chromatin is present as 3–5 granules in the center, with no peripheral chromatin on the nuclear membrane.
- In the absence of cyst stage, its mode of transmission is not clear. Possibly, it is transmitted from person-to-person by the fecal-oral route or by the eggs of *Enterobius vermicularis* and other nematodes, which may serve as a vector.
- Formerly believed to be nonpathogenic, it has now been associated with a variety of symptoms like intermittent diarrhea, abdominal pain, flatulence, anorexia, nausea, malaise, and fatigue.
- High incidence is seen among children between 2 and 10 years of age.
- Laboratory diagnosis is made by demonstration of trophozoites in stool. At least 3 stool specimens should be collected over a period of 7 days.
- Metronidazole, iodoquinol, paromomycin, and tetracycline have been used for treatment.

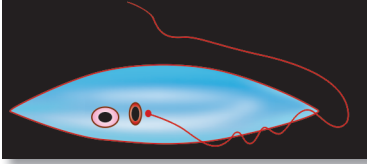
Review Questions

1. Describe briefly the life cycle and laboratory diagnosis of *Giardia lamblia*.

2. Write Short notes on:

(a) *Trichomonas vaginalis*

(b) *Dientamoeba fragilis*



Hemoflagellates

5

The blood and tissue flagellates belong to the family **Trypanosomatidae**.

The family consists of 6 genera, of which 2 genera *Trypanosoma* and *Leishmania* are pathogenic to humans.

Zoological Classification of Flagellates

Phylum	:	Sarcomastigophora
Subphylum	:	Mastigophora
Class	:	Kinetoplastida
Order	:	Trypanosomatida
Family	:	Trypanosomatidae

General Characteristics

- They live in the blood and tissues of man and other vertebrate hosts and in the gut of the insect vectors.
- Members of this family have a single nucleus, a kinetoplast, and a single flagellum (Fig 5.1).
- **Nucleus** is round or oval and is situated in the central part of the body.
- **Kinetoplast** consists of a deeply staining **parabasal body** and adjacent dot-like **blepharoplast**. The parabasal body and blepharoplast are connected by one or more thin fibrils (Fig 5.1).
- **Flagellum** is a thin, hair-like structure, which originates from the blepharoplast. The portion of the flagellum, which is inside the body of the parasite and extends from

the blepharoplast to surface of the body is known as **axoneme**. A free flagellum at the anterior end traverses on the surface of the parasite as a narrow **undulating membrane** (Fig. 5.1).

- Hemoflagellates exist in two or more of four morphological stages. These forms were formerly called the **leishmanial**, **leptomonad**, **crithidial**, and **trypanosomal** stages. But as these names are also given to different genera within the family, they were changed to **amastigote**, **promastigote**, **epimastigote** and **trypomastigote**. The names of the stages are formed by the suffix *mastigote*, combined with various prefixes, referring to the arrangement of the flagella in relation to

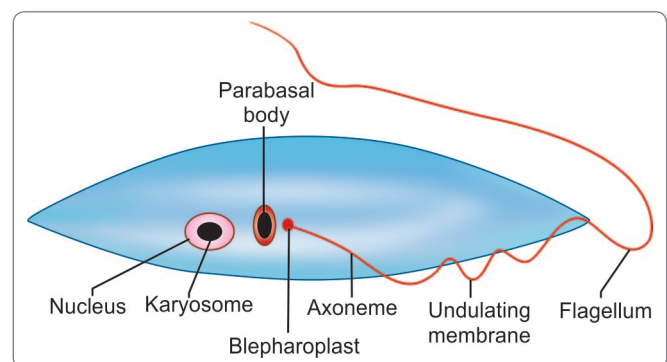
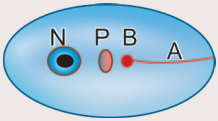
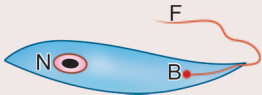
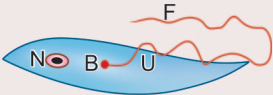
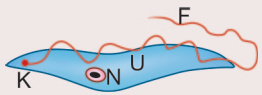


Fig. 5.1: Basic morphology of hemoflagellates

Note: Parabasal body and blepharoplast together constitute the kinetoplast

Table 5.1: Differences between Various Morphological Stages of Hemoflagellates

	Amastigote	Promastigote	Epimastigote	Trypomastigote
Morphological characteristics	Rounded or ovoid, without any external flagellum. The nucleus, kinetoplast, and axial filaments can be seen. The axoneme extends upto the anterior end of the cell	Lanceolate in shape. Kinetoplast is anterior to the nucleus (antenuclear kinetoplast) near the anterior end of the cell, from which flagellum emerges. There is no undulating membrane	Elongated, with the kinetoplast placed more posteriorly, though close to and in front of the nucleus (juxtenuclear kinetoplast). The flagellum runs alongside the body as a short undulating membrane, before emerging from the anterior end	This stage is elongated, spindle-shaped with a central nucleus. The kinetoplast is posterior to the nucleus (postnuclear kinetoplast) and situated at the posterior end of the body. The flagellum runs alongside the entire length of the cell to form a long undulating membrane before emerging as a free flagellum from the anterior end
Seen in	<i>Trypanosoma cruzi</i> and <i>Leishmania</i> as intracellular form in vertebrate host	It is the infective stage of <i>Leishmania</i> , found in the insect vector as well as in cultures <i>in-vitro</i>	It is the form in which <i>Trypanosoma brucei</i> occur in salivary gland of the vector tsetse fly and <i>Trypanosoma cruzi</i> in the midgut of the vector reduviid bug. Note: This stage is lacking in <i>Leishmania</i> .	This is the infective stage of trypanosomes found in arthropod vector and in the blood of infected vertebrate. Note: This stage is lacking in <i>Leishmania</i>
Schematic illustration				

N = Nucleus; P = Parbasal body; B = Blepharoplast; A = Axoneme; U = Undulating membrane; F = Flagellum.

Note: Besides the stages described in the table, some transitional stages have been recognized. These include the *sphaeromastigote*, a motile round form with free flagellum, which is a transitional stage from amastigote to promastigote, seen in the genus *Trypanosoma* and the *paramastigote*, a transitional form leading to the infective promastigote in *Leishmania*

the position of the nucleus and its point of emergence from the cells (Table 5.1).

- **Staining characteristics of trypanosomes:** For smears of body fluids, Romanowsky's Wrights stain, Giemsa stain, and Leishman's stain are suitable for identifying internal structures. The cytoplasm appears blue, the nucleus and flagellum appear pink, and the kinetoplast appears deep red. For tissue section, hematoxylin-eosin staining is done for demonstrating structures of the parasite.
- All members of the family have similar life cycles. They all require an insect vector as an intermediate host.
- Multiplication in both the vertebrate and invertebrate host is by **binary fission**. **No sexual cycle is known.**

Trypanosomes

General Characters

All members of the genus *Trypanosoma* (*trypanes*: to bore, *soma*: body), exist at sometime in their life cycle, as **trypomastigote** stage with an elongated spindle-shaped body, central nucleus, a posterior kinetoplast, and long

undulating membrane. Volutin granules are found in cytoplasm. Some trypanosomes such as *T. cruzi* assume **amastigote** forms in vertebrate hosts. In addition to the typical forms, cells with atypical features are frequently found, a condition known as **polymorphism**.

- *Trypanosoma* pass their life cycle in **2 hosts—vertebrate hosts (definitive hosts) and insect vectors (intermediate hosts)**. The vector becomes infective to the vertebrate host only after an extrinsic incubation period, during which the parasite undergoes development and multiplication.
- In the vector, the trypanosomes follow one or two modes of development and are accordingly classified into 2 groups—**Salivaria** and **Stercoraria**.
 - **Salivaria** (anterior station): In salivaria, the trypanosomes migrate to mouth parts of the vectors, so that infection is transmitted by their bite (**inoculative transmission**). Examples are *T. gambiense* and *T. rhodesiense* causing African trypanosomiasis, which are transmitted by the bite of tsetse flies.
 - **Stercoraria** (posterior station): In stercoraria, the trypanosomes migrate to the hindgut and are

Classification of Trypanosomes

Trypanosomes Infecting Man

- *Trypanosoma brucei* complex, causing African trypanosomiasis or sleeping sickness, sub-species are:
 - *Trypanosoma brucei gambiense*: causing West African sleeping sickness.
 - *Trypanosoma brucei rhodesiense*: causing East African sleeping sickness.
- *Trypanosoma cruzi*, causing South American trypanosomiasis or Chagas' disease.
- *Trypanosoma rangeli*, a nonpathogenic trypanosome causing human infection in South America.

Trypanosomes of Animals

- *Trypanosoma brucei brucei*, causing the economically important disease '**nagana**' in African cattle.
- *Trypanosoma evansi*, causing the disease '**surra**' in horses, camels, and elephants. It is transmitted mechanically by biting flies and also by vampire bats. This infection is found in India.
- *Trypanosoma equiperdum*, causing '**stallion's disease**' in horses and mules. It is transmitted by sexual contact, without the need for an insect vector.
- *Trypanosoma lewisi*, causing harmless infection of rats all over the world. The vector is rat flea. A trypanosome resembling *Trypanosoma lewisi* was reported from Madhya Pradesh in India in peripheral blood of 2 persons with short-term fever.

passed in feces (stercorian transmission), e.g. *T. cruzi* causing Chagas' disease, which is acquired by rubbing the feces of the vector bug into the wound caused by its bite and *T. lewisi*, the rat trypanosome, which is transmitted by ingestion of feces of infected rat fleas.

- **Distribution:** Human trypanosomiasis is strictly restricted to certain geographical regions; the African and South American trypanosomiasis being seen only in the respective continents. This is due to the vector being confined to these places alone.
 - **African trypanosomiasis** (sleeping sickness)
 - **South American trypanosomiasis** (Chagas' disease)

Trypanosoma Brucei Gambiense (West African Trypanosomiasis)

History and Distribution

Trypanosomiasis is believed to have been existing in tropical Africa from antiquity (Fig. 5.2).

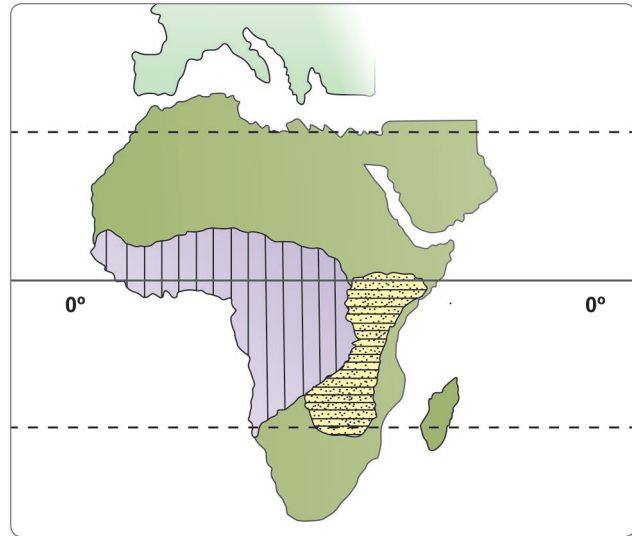


Fig. 5.2: Geographical distribution of trypanosomiasis in Africa. Lines indicate areas endemic for *Trypanosoma gambiense* and dots represent *Trypanosoma rhodesiense*

- Trypanosome was first isolated from the blood of a steamboat captain on the Gambia river in 1901 (hence, the name **gambiense**) by Forde.
- Dulton, in 1902, proposed the name *Trypanosoma gambiense*.
- It is endemic in scattered foci in West and Central Africa between 15°N and 18°S latitudes.

Habitat

Trypanosomes live in man and other vertebrate host. They are essentially a parasite of connective tissue, where they multiply rapidly and then invade regional lymph nodes, blood, and finally may involve central nervous system.

Morphology

Vertebrate Forms

In the blood of vertebrate host, *T. brucei gambiense* exists as **trypomastigote** form, which is highly pleomorphic.

- It occurs as a **long slender form**, a **stumpy short broad form** with attenuated or absent flagellum, and an **intermediate form**.
- The trypomastigotes are about 15–40 μm long and 1.5–3.5 μm broad.
- In fresh blood films, trypomastigotes are seen as colorless, spindle-shaped bodies that move rapidly, spinning around the red cells.
- In smears stained with Giemsa or other Romanowsky's stain, the cytoplasm appears pale blue and the nucleus appears red. The kinetoplast appears as a deep red dot

and volutin granules stain deep blue. The undulating membrane appears pale blue and the flagellum red.

Insect Forms

In insects, it occurs in 2 forms:

- Epimastigotes
- Metacyclic trypomastigote forms.

Antigenic Variation

Trypanosomes exhibit unique antigenic variation of their glycoproteins.

- There is a cyclical fluctuation in the trypanosomes in the blood of infected vertebrates after every 7–10 days.
- Each successive wave represents a **variant antigenic type (VAT)** of trypomastigote possessing **variant surface specific antigens (VSSA)** or **variant surface glycoprotein (VSG)** coat antigen.
- It is estimated that a single trypanosome may have as many as 1,000 or more VSG genes, that help to evade immune response. Besides this, trypanosomes have other mechanisms also that help them to evade host immune responses.

Life Cycle

T. brucei gambiense passes its life cycle in 2 hosts.

Vertebrate host: Man, game animals, and other domestic animals.

Invertebrate host: Tsetse fly.

Both male and female tsetse fly of *Glossina* species (*G. palpalis*) are capable of transmitting the disease to humans. These flies dwell on the banks of shaded streams, wooded savanna, and agricultural areas.

Infective form: Metacyclic trypomastigote forms are infective to humans.

Mode of transmission:

- By bite of tsetse fly
- Congenital transmission has also been recorded.

Reservoirs: Man is the only reservoir host, although pigs and others domestic animals can act as chronic asymptomatic carriers of the parasite.

Development in Man and Other Vertebrate Hosts

- **Metacyclic stage** (infective form) of trypomastigotes are inoculated into a man (definitive host) through skin when an infected tsetse fly takes a blood meal (Fig. 5.3).
- The parasite transforms into slender forms that multiply asexually for 1–2 days before entering the peripheral blood and lymphatic circulation.
- These become '**stumpy**' via intermediate forms and enter the blood stream.

- In chronic infection, the parasite invades the central nervous system.
- Trypomastigotes (short plumpy form) are ingested by tsetse fly (male or female) during blood meal.

Development in Tsetse Fly

- In the midgut of the fly, short stumpy trypomastigotes develop into long, slender forms and multiply.
- After 2–3 weeks, they migrate to the salivary glands, where they develop into **epimastigotes**, which multiply and fill the cavity of the gland and eventually transform into the infective **metacyclic trypomastigotes** (Fig. 5.3).
- Development of the infective stage within the tsetse fly requires 25–50 days (extrinsic incubation period).
- Thereafter, the fly remains infective throughout its life of about 6 months.

Pathogenicity and Clinical Features

T. brucei gambiense causes African trypanosomiasis (West African sleeping sickness).

The illness is **chronic** and can persist for many years.

- There is an initial period of parasitemia, following which parasite is localized predominately in the lymph nodes.
- A **painless chancre** (trypanosomal chancre) appears on skin at the site of bite by tsetse fly, followed by intermittent fever, chills, rash, anemia, weight loss, and headache.
- Systemic trypanosomiasis without central nervous system involvement is referred to as **stage I disease**. In this stage, there is hepatosplenomegaly and lymphadenopathy, particularly in the posterior cervical region (**Winterbottom's sign**).
- **Myocarditis** develops frequently in patients with stage I disease and is especially common in *T. brucei rhodesiense* infections.
- **Hematological manifestations** seen in stage I include anemia, moderate leucocytosis, and thrombocytopenia. High levels of immunoglobulins mainly immunoglobulin (Ig)M are a constant feature.
- **Stage II disease** involves invasion of central nervous system. With the invasion of central nervous system, which occurs after several months, the '**sleeping sickness**' starts. This is marked by increasing headache, mental dullness, apathy, and day time sleepiness. The patient falls into profound coma followed by death from asthenia.

Clinical staging of human African trypanosomiasis (HAT)

- Stage I: Characterized by hematogenous and lymphatic dissemination of the disease
- Stage II: Characterized by central nervous system involvement

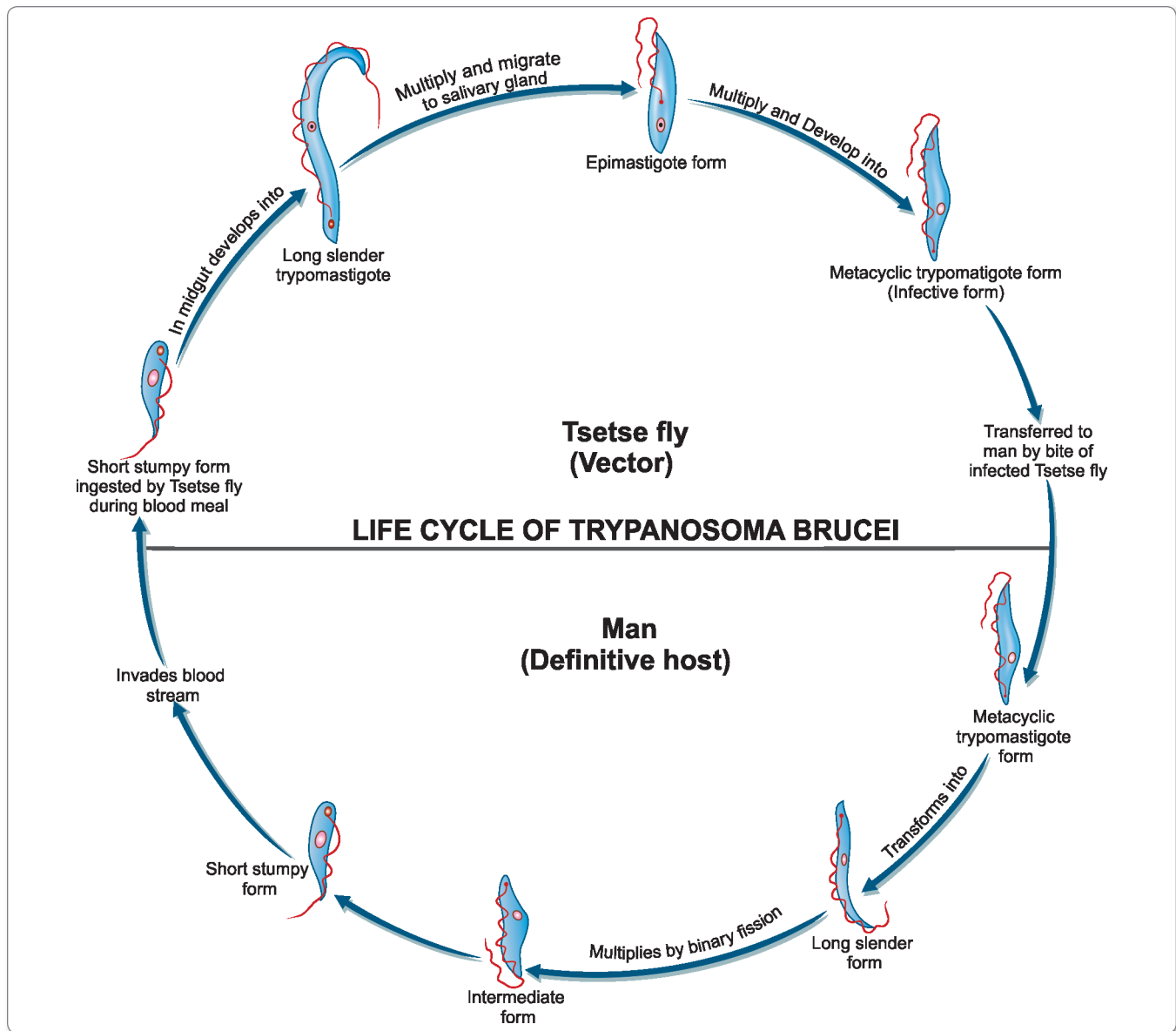


Fig. 5.3: Life cycle of *Trypanosoma brucei*

- **Histopathology** shows chronic meningoencephalitis. The meninges are heavily infiltrated with lymphocytes, plasma cells, and morula cells, which are atypical plasma cells containing **mulberry-shaped** masses of IgA. Brain vessels show perivascular cuffing. This is followed by infiltration of the brain and spinal cord, neuronal degeneration, and microglial proliferation.
- Abnormalities in cerebrospinal fluid include raised intracranial pressure, pleocytosis, and raised total protein concentrations.

Trypanosoma Brucei Rhodesiense (East African Trypanosomiasis)

- It is found in Eastern and Central Africa (Uganda, Tanzania, Zambia, and Mozambique) (Fig. 5.2).
- Stephans and Fantham discovered *T. brucei rhodsiense* in 1910 from the blood of a patient in Rhodesia suffering from sleeping sickness.
- The principal vector is *G. morsitans*, *G. palpalis*, and *G. Swynnertoni*, which live in the open savannah countries.

- Although the disease is usually transmitted by the vector from man-to-man, the disease is actually a zoonosis, with the reservoir being wild game animals like bush buck, antelope and domestic animals like cattle.
- Its morphology, habitat, and life cycle is similar to *T. brucei gambiense* (Fig. 5.3).
- The difference between *T. brucei gambiense* and *T. brucei rhodesiense* are detailed in Table 5.2.

Pathogenesis and Clinical Feature

T. brucei rhodesiense causes East African sleeping sickness (Table 5.2).

- East African trypanosomiasis is more **acute** than the Gambian form and appears after an incubation period of 4 weeks.
- It may end fatally within an year of onset, before the involvement of central nervous system develops.
- Pathological features are similar in both diseases with some variations—
 - Edema, myocarditis, and weakness are more prominent in East African sickness.
 - Lymphadenitis is less prominent.
 - Febrile paroxysms are more frequent and severe.
 - There is a larger quantity of parasite in the peripheral blood.
 - Central nervous system involvement occurs early. Mania and delusions may occur but the marked somnolence, which occurs in *T. brucei gambiense* infection is lacking.

Table 5.2: Differences Between West African and East African Trypanosomiasis

Characteristics	West African	East African
Organism	<i>T. brucei gambiense</i>	<i>T. brucei rhodesiense</i>
Distribution	West and Central Africa	East and Central Africa
Vector	Tsetse fly (<i>Glossina palpalis</i> group)	Tsetse fly (<i>Glossina morsilans</i> group)
Reservoir	Mainly humans	Wild and domestic animals
Virulence	Less	More
Course of disease	Chronic (late central nervous system invasions); months to years	Acute (early central nervous system invasion); less than 9 months
Parasitemia	Low	High and appears early
Lymphadenopathy	Early, prominent	Less common
Isolation in rodents	No	Yes
Mortality	Low	High



Parasites causing myocarditis

- *Trypanosoma brucei rhodesiense*
- *Trypanosoma cruzi*
- *Toxoplasma gondii*
- *Echinococcus granulosus*
- *Trichinella spiralis*

Laboratory Diagnosis

The diagnosis of both types of African trypanosomiasis is similar (Flowchart 5.1).

Non-specific Findings

- Anemia and monocytosis.
- Raised erythrocyte sedimentation rate due to rise in gamma globulin levels.
- Reversal of albumin:globulin ratio.
- Increased cerebrospinal fluid (CSF) pressure and raised cell count and proteins in CSF.

Specific Findings

Definitive diagnosis of sleeping sickness is established by the demonstration of trypanosomes in peripheral blood, bone marrow, lymphnode, CSF, and chancre fluid.

Microscopy

- Wet mount preparation of lymphnode aspirates and chancre fluid are used as a rapid method for demonstration of trypanosomes. These specimen are also examined for parasites after fixing and staining with Giemsa stain.
- Examination of Giemsa-stained thick peripheral blood smears reveals the presence of the trypomastigotes (Fig. 5.4).
- If parasitemia is low, then examination of concentrated blood smear is a highly sensitive method. Different concentration techniques employed are buffy coat examination, differential centrifugation, membrane filtration, and ion exchange column chromatography.
- Examination of wet mount and stained smear of the CSF may also show trypanosomes (Flowchart 5.1).

Culture

The organisms are difficult to grow, hence culture is not routinely used for primary isolation of the parasite. However, it can be cultivated in Weinman's or Tobie's medium.

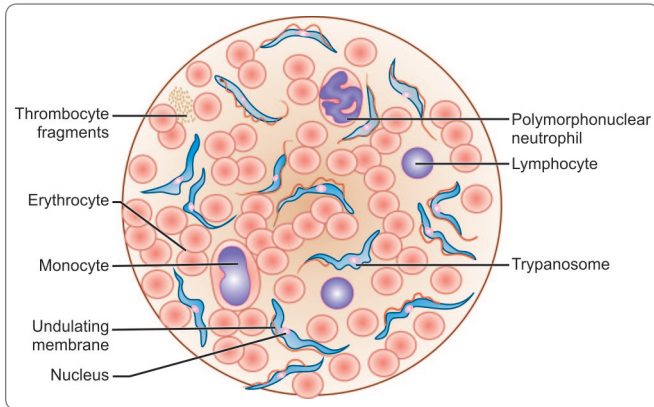


Fig. 5.4: *Trypanosoma rhodesiense*, blood smear Giemsa stain, magn X 1100

Animal Inoculation

Inoculation of specimens from suspected cases to white rat or white mice is a highly sensitive procedure for detection *T. brucei rhodesiense* infection.

Serodiagnosis

Antibody detection

Almost all patients with African trypanosomiasis have very high levels of total serum IgM antibodies and later, CSF IgM antibodies. Various serological methods have been developed to detect these antibodies and are as follows:

- Indirect hemagglutination (IHA)
- Indirect immunofluorescence (IIF)
- Enzyme-linked immunosorbent assay (ELISA)
- Card agglutination trypanosomiasis test (CATT)
- Complement fixation test (CFT)

Specific antibodies are detected by these tests in serum within 2–3 weeks of infection. Specific antibodies in CSF are demonstrated by IIF and ELISA. These serological tests are useful for field use and mass screening (Flowchart 5.1).

Antigen detection

Antigens from serum and CSF can be detected by ELISA.

Molecular Diagnosis

Polymerase chain reaction (PCR) assays for detecting African trypanosomes in humans have been developed, but none is commercially available.

Imaging

Computed tomography (CT) scan of the brain shows cerebral edema and magnetic resonance imaging (MRI) shows white matter enhancement in patients with late stage central nervous systems involvement (Flowchart 5.1).

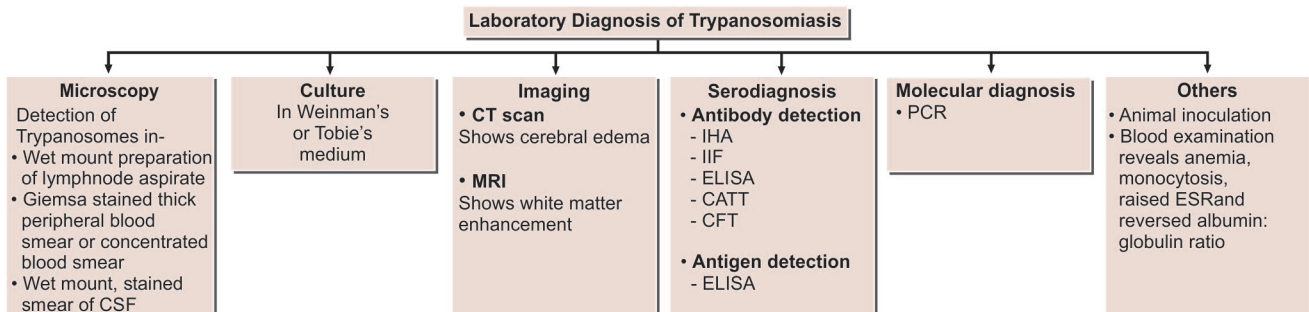
- For differentiation between the 'human strains' and 'animal strains' of *T. brucei*, the blood incubation infectivity test (BIIT) had been widely used.
- The strain is incubated with oxalated human blood and then inoculated into the multimammate rat or other susceptible rodents.
- The infectivity of 'animal strains' will be neutralized by human blood, while 'human strains' retain infectivity after incubation with human blood.
- In vitro culture systems are now employed instead of rodents for testing infectivity.
- More recently their differentiation is based on isoenzymes, DNA, and RNA characteristics (Flowchart 5.1).

Treatment

- In the initial stages, when central nervous system is not involved i.e. stage I, pentamidine is the drug of choice for gambiense HAT (human African trypanosomiasis) and suramin is the drug of choice for rhodesiense HAT.

Dose

- **Pentamidine:** Dose 3–4 mg/kg of body weight, intramuscularly daily for 7–10 days.
- **Suramin:** Dose 20 mg/kg of body weight in a course of 5 injections intravenously, at an interval of 5–7



Flowchart 5.1: Laboratory diagnosis of trypanosomiasis

days. Suramin does not cross blood brain barrier but it is nephrotoxic.

- In patients with central nervous system involvement, **melarsoprol** (Mel-B) is the drug of choice, as it can cross the blood brain barrier. Dose: 2–3 mg/kg/per day (max. 40 mg) for 3–4 days (Table 5.3).

Table 5.3: Treatment of Human African Trypanosomiasis

Causative organism	Clinical stage	
	I (Normal CSF)	II (Abnormal CSF)
<i>T. brucei gambiense</i> (West African)	Pentamidine	Eflornithine
<i>T. brucei rhodesiense</i> (East African)	Suramin	Melarsoprol

Prophylaxis

Control is based on early diagnosis and treatment of cases to reduce the reservoir of infection.

- Control of tsetse fly population (most important preventive measure) by wide spraying of insecticides, traps, and baits impregnated with insecticides.
- No vaccine is available.

Trypanosoma Cruzi

T. cruzi is the causative organism of **Chagas's disease** or South American trypanosomiasis.

History and Distribution

It is a zoonotic disease and is limited to South and Central America.

- Carlos Chagas, investigating malaria in Brazil in 1909, accidentally found this trypanosome in the intestine of a triatomine bug and then in the blood of a monkey bitten by the infected bugs.
- Chagas named the parasite *T. cruzi* after his mentor Oswaldo Cruz and the disease was named as Chagas' disease in his honor.

Habitat

- In humans, *T. cruzi* exists in both **amastigote** and **trypomastigote** forms.
 - Amastigotes are the intracellular parasites. They are found in muscular tissue, nervous tissue, and reticulo-endothelial system.
 - Trypomastigotes are found in the peripheral blood.

- In **reduviid bugs**, amastigote forms are found in the midgut and metacyclic trypomastigote forms are present in hindgut and feces.

🔗 Obligat intracellular parasites

- *Trypanosoma cruzi*
- *Leishmania* spp.
- *Plasmodium* spp.
- *Babesia* spp.
- *Toxoplasma gondii*
- *Microsporidia*

Morphology

Amastigote

Amastigotes are oval bodies measuring 2–4 μm in diameter having a nucleus and kinetoplast (Fig. 5.5A).

- Flagellum is absent.
- Morphologically, it resembles the amastigote of *Leishmania* spp., hence it is frequently called as **leishmanial form**.
- Multiplication of the parasite occurs in this stage.
- This form is found in muscles, nerve cells, and reticulo-endothelial systems.

Trypomastigote

Trypomastigotes are non-multiplying forms found in the peripheral blood of man and other mammalian hosts (Fig. 5.5B).

- In the blood, they appear either as long, thin flagellates about (20 μm long) or short stumpy form (15 μm long).
- Posterior end is wedge-shaped.

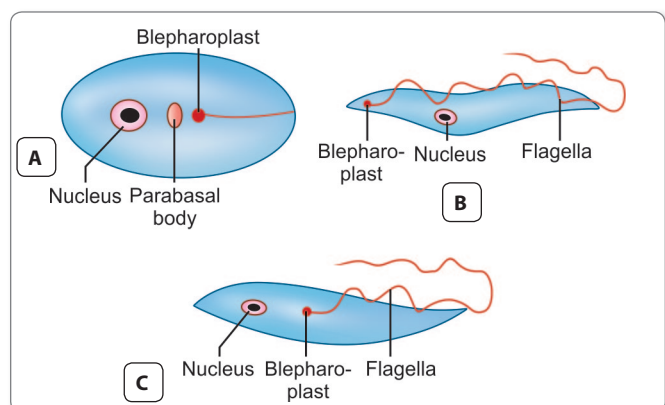


Fig. 5.5: *Trypanosoma cruzi*. **A.** Amastigote; **B.** Trypomastigote; **C.** Epimastigote

- In stained blood smears, they are shaped like alphabet 'C', 'U', or 'S', having a free flagellum of about one-third the length of the body.
- These forms do not multiply in humans and are taken up by the insect vectors.

Epimastigote Form

Epimastigote forms are found in the insect vector, the reduviid bug and in culture also (Fig. 5.5C).

- It has a kinetoplast adjacent to the nucleus.
- An undulating membrane runs along the anterior half of the parasite.
- Epimastigotes divide by binary fission in hindgut of the vector.

Life Cycle

T. cruzi passes its life cycle in 2 hosts (Fig. 5.6).

Definitive host: Man

Intermediate host (vector): Reduviid bug or triatomine bugs.

Reservoir host: Armadillo, cat, dog, and pigs.

Infective form: Metacyclic trypomastigotes forms are the infective forms found in feces of reduviid bugs.

- The parasite occurs in 3 different but overlapping infection cycles a **sylvatic zoonosis** in wild animals like armadillos and opossums, **peridomestic cycle** in dogs, cats, and other domestic animals, and **domestic cycle** in humans. Different vector species are active in these infection cycles.

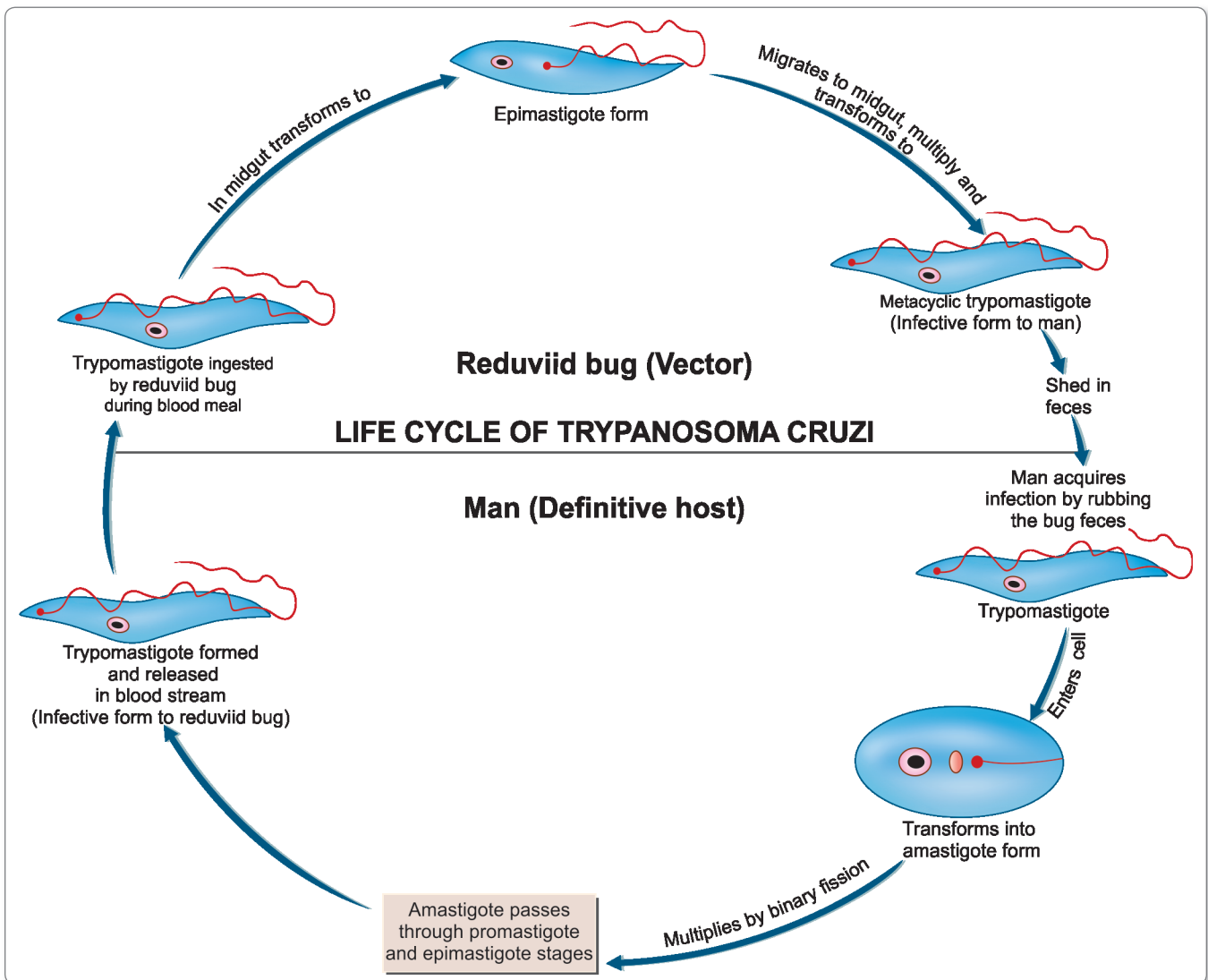


Fig. 5.6: Life cycle of *Trypanosoma cruzi*

- The vectors important in human infection are the reduviid bugs adapted to living in human habitations, mainly *Triatoma infestans*, *Rhodnius prolixus*, and *Panstrongylus megistus*. These are large (upto 3 cm long) night-biting bugs, which typically defecate while feeding. The feces of infected bugs contain the metacyclic trypomastigote.

Mode of transmission:

- Transmission of infection to man and other reservoir hosts takes place when mucus membranes, conjunctiva, or wound on the surface of the skin is contaminated by feces of the bug containing metacyclic trypomastigotes.
- *T. cruzi* can also be transmitted by the blood transfusion, organ transplantation, and vertical transmission i.e. from mother to fetus or very rarely by ingestion of contaminated food or drink.

Development in Man

- The **metacyclic trypomastigotes** introduced in human body by bite of Tsetse fly invade the reticulo endothelial system and spread to other tissues.
- After passing through promastigote and epimastigote forms, they again become trypomastigotes, which are released into the blood stream and are the infective stage for triatomine bug. No multiplication occurs in this stage. Multiplication takes place only intracellularly in the amastigote form and to some extent as promastigote or epimastigotes (Fig. 5.6).

Development in Reduviid Bugs

- Bugs acquire infection by feeding on an infected mammalian host.
- Most triatomine bugs are nocturnal.
- The trypomastigotes are transformed into epimastigotes in the midgut, from where they migrate to the hindgut and multiply.
- These, in turn, develop into **non-dividing metacyclic trypomastigotes** (infective form), which are excreted in feces (stercorarian transmission).
- The development of *T. cruzi* in the vector takes 8–10 days, which constitutes the extrinsic incubation period.

Pathogenicity and Clinical Features

The incubation period of *T. cruzi* in man is 1–2 weeks. The disease manifests in acute and chronic form.

Acute Chagas' Disease

Acute phase occurs soon after infection and may last for 1–4 months.

- It is seen often in children under 2 years of age.
- First sign appears within a week after invasion of parasite.

- '**Chagoma**' is the typical subcutaneous lesion occurring at the site of inoculation. Inoculation of the parasite in conjunctiva causes unilateral, painless edema of periocular tissues in the eye called as **Romana's sign**. This is a classical finding of the acute Chagas' disease.
- In few patients, there may be generalized infection with fever, lymphadenopathy, and hepatosplenomegaly.
- The patient may die of acute myocarditis and meningoencephalitis.
- Usually within 4–8 weeks, acute signs and symptoms resolve spontaneously and patients then enter the asymptomatic or indeterminate phase of chronic *T. cruzi* infection.

Chronic Chagas' Disease

The chronic form is found in adults and older children and becomes apparent years or even decades after the initial infection.

- In chronic phase, *T. cruzi* produces inflammatory response, cellular destruction, and fibrosis of muscles and nerves, that control tone of hollow organs like heart, esophagus, colon, etc. Thus, it can lead to cardiac **myopathy** and **megaesophagus** and **megacolon** (dilatation of esophagus and colon).

Congenital Infection

Congenital transmission is possible in both acute and chronic phase of the disease causing myocardial and neurological damage in the fetus.

Laboratory Diagnosis

Diagnosis is done by demonstration of *T. cruzi* in blood or tissues or by serology.

Microscopy

- The diagnosis of acute Chagas' disease requires detection of parasites.
- Microscopic examination of fresh anticoagulated blood or the buffy coat is the simplest way to see motile organisms.
- In wet mount, trypomastigotes are faintly visible but their snake-like motion against RBC's makes their presence apparent.
- Trypomastigotes can also be seen in thick and thin peripheral blood smear, stained with Giemsa stain (Fig. 5.7).
- Microhematocrit containing acridine orange as a stain can also be used.
- When used by experienced personnel, all these methods yield positive results in a high proportion of cases of acute Chagas's disease.

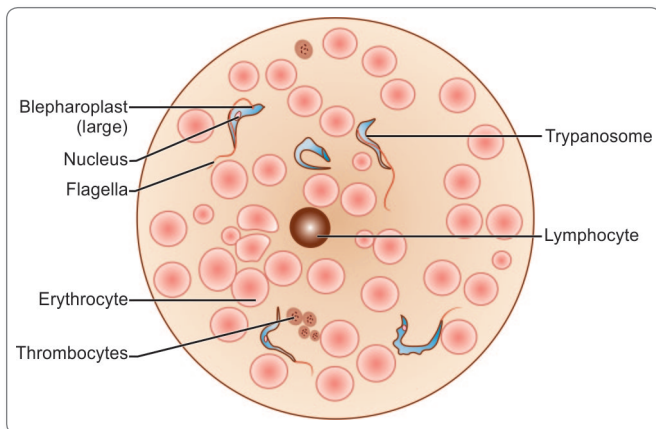


Fig. 5.7: *Trypanosoma cruzi*, blood smear Giemsa stain, magn x 1100

Note: Serologic testing plays no role in diagnosing acute Chagas' disease.



Protozoan parasites detected in peripheral blood film

- *Trypanosoma cruzi*
- *Trypanosoma brucei rhodesiense*
- *Trypanosoma brucei gambiense*
- *Leishmania* spp.
- *Plasmodium* spp.
- *Babesia* spp.

Culture

Novy, Neal, and Nicolle (NNN) medium or its modifications are used for growing *T. cruzi*.

- This medium is inoculated with blood and other specimens and incubated at 22°–24°C.
- The fluid from the culture is examined microscopically by 4th day and then every week for 6 weeks.
- Epimastigotes and trypomastigotes are found in the culture.
- Culture is more sensitive than smear microscopy.

Animal Inoculation

Guinea pig or mice inoculation may be done with blood, CSF, lymph node aspirate, or any other tissue material and the trypomastigote is looked for in its blood smears in a few days after successful inoculation.

Xenodiagnosis

This is the method of choice in suspected Chagas' disease, if other examinations are negative, especially during the early phase of the disease onset.

- The reduviid bugs are reared in a trypanosome-free laboratory and starved for 2 weeks. They are then fed on patients blood. If trypomastigotes are ingested, they will multiply and develop into epimastigotes and trypomastigotes, which can be found in the feces of the bug 2 weeks later.

Histopathology

Biopsy examination of lymphnodes and skeletal muscles and aspirate from Chagoma may reveal amastigotes of *T. cruzi*.

Serology

Antigen detection

T. cruzi antigen can be detected in urine and sera in patients with chronic Chagas' disease. ELISA has been developed for detection of antigens.

Antibody detection

Antibodies (IgG) against *T. cruzi* may be detected by the following tests –

- IHA
- CFT (Machado-Guerreiro test)
- ELISA
- IIF
- Direct agglutination test (DAT). It is a simple test being recommended for field use.
- Chagas' Radiolmmune Precipitation Assay (RIPA) is a highly sensitive and specific confirmatory method for detecting antibodies of *T. cruzi*.

The disadvantage of the antibody based tests is that they may be false positive with other disease like leishmaniasis and syphilis.

Intradermal Test

The antigen '**cruzin**' is prepared from *T. cruzi* culture and used for the intradermal test. A delayed hypersensitivity reaction is seen.

Molecular Diagnosis

PCR is available that detects specific primers, which have been developed against *T. cruzi* kinetoplastic or nuclear DNA. The disadvantage of the test is that it is not commercially available.

Other Tests

- **Electrocardiography (ECG)** and chest X-ray are useful for diagnosis and prognosis of cardiomyopathy seen

in chronic Chagas' disease. The combination of right bundle branch block (RBBB) and left anterior fascicular block is a typical feature of Chagas' heart disease.

- **Endoscopy** helps in visualization of megaesophagus in Chagas' disease.

Treatment

No effective specific treatment is available for treating Chagas' disease. Nifutrimox and benznidazole have been used with some success in both acute and chronic Chagas disease. These drugs kill only the extracellular trypanosomes but not the intracellular forms.

Dose: Nifutrimox: 8–10 mg/kg for adults and 15 mg/kg for children. The drug should be given orally in 4 divided doses each day for 90–120 days.

Benznidazole: 5–10 mg/day orally for 60 days.

Prophylaxis

- Application of insecticide to control the vector bug.
- Personal protection using insect repellent and mosquito net.
- Improvement in rural housing and environment to eliminate breeding places of bugs.

Trypanosoma Rangeli

T. rangeli was first described by Tejera in 1920 while examining the intestinal content of reduviid bug (*R. prolixus*).

- It is nonpathogenic.
- *T. rangeli* infections are encountered in most areas where *T. cruzi* infection also occurs (Mexico, Central America, and northern South America).
- Morphologically, it is similar to *T. cruzi*, except that it is slender and long (26–36 μm long) and has a smaller kinetoplast (Table 5.4).
- It is commonly found in dogs, cats, and humans.
- Infection is transmitted by both bite of triatomine bug and fecal contamination from reduviid bug.

Table 5.4: Differences Between *T. cruzi* and *T. rangeli*

<i>Trypanosoma cruzi</i>	<i>Trypanosoma rangeli</i>
Pathogenic	Nonpathogenic
15–20 μm long	30 μm long, more slender and longer
C or U-shaped	Not C or U-shaped
Kinetoplast: Large and terminal	Kinetoplast: Small and subterminal
Primary reservoirs: Opposums, dog, cats, and wild rodents	Primary reservoir: Wild rodents

- *T. rangeli* multiplies in human blood by binary fission. Intracellular stage is typically absent.
- *T. rangeli* can circulate in blood of infected animals for a long period, unlike *T. cruzi*.
- Although *T. rangeli* appears to be a normal commensal, they do reduce the life span of reduviid bug.
- Diagnostic methods are similar to that of *T. cruzi*.

Key points of Trypanosomes

- Trypanosomes follow one of the two developmental modes in vectors. **In Salivaria:** The trypanosomes migrate to mouth parts of vector tsetse fly, e.g. *T. gambiense*, *T. rhodesiense*. **In Stercoraria:** The trypanosomes migrate to hindgut of vector bug, e.g. *T. cruzi*.
- *T. brucei gambiense* causes West African sleeping sickness manifested by fever, hepatosplenomegaly, and posterior cervical lymphadenopathy with chronic central nervous system invasion.
- *T. brucei rhodesiense* causes East African sleeping sickness manifested by fever, early and acute central nervous system invasion, with loss of weight and myocarditis.
- **Diagnosis:** By detection of trypanosomes in wet mount preparations of lymph node aspirates or blood or by serology and PCR.
- **Drug of choice:** For stage I HAT by *T. brucei gambiense* is pentamidine and by *T. brucei rhodesiense* is suramin. In stage II, the drug of choice is melarsopro in both cases.
- South American trypanosomiasis (Chagas' disease) is caused by *T. cruzi*.
- It is transmitted by wound or conjunctival contamination of feces of the reduviid bugs.
- **Clinical features:** 'Chagoma' is the typical subcutaneous lesion commonly on face (Romana's sign) in Chagas' disease. Damage to nerve cells and muscles leads to megaesophagus, megacolon, and cardiac myopathy.
- **Diagnosis:** By demonstration of *T. cruzi* in blood or tissue or by serology and xenodiagnosis.
- **Treatment:** Nifutrimox and benznidazole.

Leishmania

General Characteristics

The genus *Leishmania* is named after Sir William Leishman, who discovered the flagellate protozoa causing Kala-azar, the Indian visceral leishmaniasis.

- All members of the genus *Leishmania* are **obligate intracellular parasites** that pass their life cycle in 2

hosts—the mammalian host and the insect vector, female sandfly.

- In humans and other mammalian hosts, they multiply within macrophages, in which they occur exclusively in the amastigote form, having an ovoid body containing a nucleus and kinetoplast.
- In the sandfly, they occur in the promastigote form, with a spindle-shaped body and a single flagellum arising from anterior end.
- Leishmaniasis has an immense geographical distribution in the tropics and subtropics of the world, extending through most of the Central and South America, part of North America, central and South-east Asia, India, China, the Mediterranean region, and Africa.
- The disease affects the low socio-economic group of people. Overcrowding, poor ventilation, and collection of organic material inside house facilitate its transmission.
- Across the tropics, 3 different diseases are caused by various species of genus *Leishmania*. These are:

- **Visceral leishmaniasis:** The species *L. donovani* complex infecting internal organs (liver, spleen, and bone marrow) of human is the causative parasite.
- **Cutaneous leishmaniasis:** The species *L. tropica* complex, *L. aethiopica*, *L. major* and *L. mexicana* complex are the causative parasite.
- **Mucocutaneous leishmaniasis :** It is caused by the *L. braziliensis* complex .

Classification

The genus *Leishmania* includes a number of different varieties and subspecies, which differ in several features such as antigenic structure, isoenzymes, and other biochemical characteristics, growth properties, host specificity, etc. (Table 5.5).

Leishmania species can also be classified on the basis of geographical distribution as given in Table 5.6.

The various manifestations of leishmaniasis and *Leishmania* species causing them have been summarized in Flowchart 5.2.

Table 5.5: *Leishmania* species Involved in Human Disease

Species	Disease	Geographical distribution	Vector	Reservoir	Transmission
<i>Leishmania donovani</i>	Visceral leishmaniasis (Kala-azar or dumdum fever)	Middle East, Africa, and Indian Subcontinent	<i>Phlebotomus argentipes</i> , <i>Phlebotomus orientalis</i>	Humans	Anthroponotic, occasionally zoonotic
<i>Leishmania infantum</i>	Visceral leishmaniasis, cutaneous leishmaniasis	Mediterranean Coast, Middle East, and China.	<i>Phlebotomus perniciosus</i> , <i>Phlebotomus ariasi</i> , <i>Phlebotomus papatasi</i>	Dog, fox, jackal, and wolf	Zoonotic
<i>Leishmania chagasi</i>	Visceral leishmaniasis	Tropical South America	<i>Lutzomyra longipalpis</i>	Fox and wild canines	Zoonotic
<i>Leishmania tropica</i>	Cutaneous Leishmaniasis (oriental sore, Baghdad boil)	Middle East and Central Asia	<i>Phlebotomus sergenti</i>	Humans	Anthroponotic
<i>Leishmania major</i>	Cutaneous leishmaniasis	Africa, Indian Subcontinent, and Central Asia	<i>Phlebotomus papatasi</i> , <i>Phlebotomus duboscqi</i>	Gerbil	Zoonotic
<i>Leishmania aethiopica</i>	Cutaneous and diffuse cutaneous leishmaniasis	Ethiopia and Kenya	<i>Phlebotomus longipes</i> <i>Phlebotomus pedifer</i>	Hydraxes	Zoonotic
<i>Leishmania braziliensis</i> complex	Mucocutaneous leishmaniasis (Espundia)	Tropical South America	<i>Lutzomyra umbratilis</i>	Forest rodents and peridomestic animals	Zoonotic
<i>Leishmania mexicana</i> complex	Mucocutaneous leishmaniasis (Chiclero's ulcer)	Central America and Amazon basin	<i>Lutzomyra olmeca</i> , <i>Lutzomyra flairscutellata</i>	Forest rodents and marsupials	Zoonotic

Table 5.6: Classification of *Leishmania* based on Geographical Distribution

Old world leishmaniasis	New world leishmaniasis
<i>Leishmania donovani</i>	<i>Leishmania braziliensis</i> complex
<i>Leishmania infantum</i>	<i>Leishmania mexicana</i> complex
<i>Leishmania tropica</i>	<i>Leishmania chagasi</i>
<i>Leishmania major</i>	<i>Leishmania peruviana</i>
<i>Leishmania aethiopica</i>	

Note: The vector for old world leishmaniasis is sandfly of the genus *Phlebotomus* and for new world leishmaniasis is sandfly of the genera *Lutzomyia* and *Psychodopygus*.

Old World Leishmaniasis

Leishmania *Donovani*

L. donovani causes **visceral leishmaniasis** or **Kala-azar**. It also causes the condition, **Post Kala-azar Dermal Leishmaniasis (PKDL)**.

History and Distribution

Sir William Leishman in 1900, observed the parasite in spleen smears of a soldier who died of '**Dumdum fever**' or Kala-azar contracted at Dum Dum, Calcutta. Leishman reported this finding from London in 1903. In the same year, Donovan also reported the same parasite in spleen smears of patients from Madras. The name *Leishmania donovani* was, therefore given to this parasite. The amastigote forms of the parasite as seen in smears from patients are called **Leishman Donovan (LD) bodies**.

- Visceral leishmaniasis or Kala-azar is a major public health problem in many parts of world. According to the World Health Organization (WHO), a total of 5,00,000 cases of visceral leishmaniasis occur every year. Of these new cases, 90% are found in the Indian subcontinent and Sudan and Brazil.

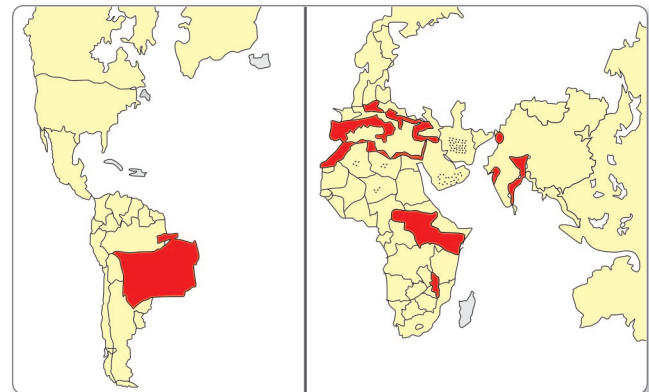
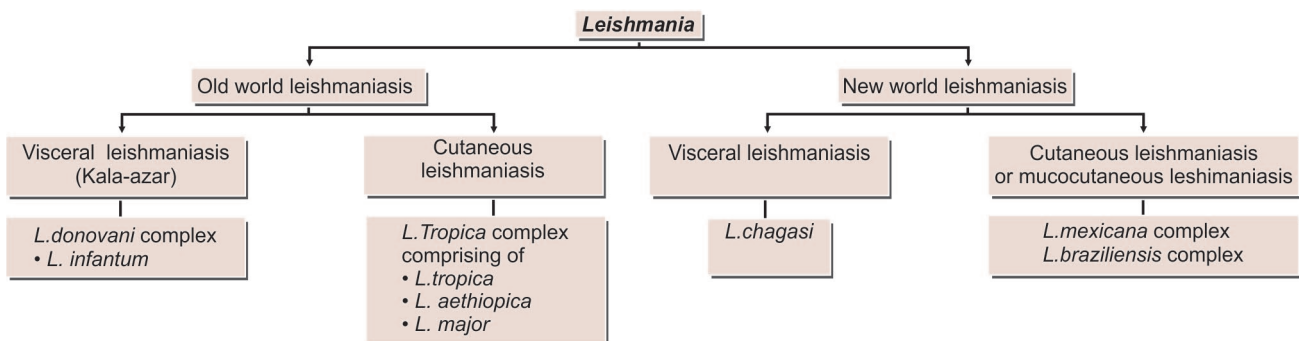


Fig. 5.8: Geographical distribution of visceral leishmaniasis. Endemic areas shaded; dots indicate sporadic cases

- The disease occurs in endemic, epidemic, or sporadic forms. Major epidemics of the disease are currently found in India, Brazil, and Sudan (Fig. 5.8).
- The resurgence of Kala-azar in India, beginning in the mid-1970s, assumed epidemic proportions in 1977 and involved over 1,10,000 cases in humans. Initially, the disease was confined to Bihar (Muzaffarpur, Samastipur, Vaishali, and Sitamarhi). Since then, the cases are increasing and involving newer areas. The epidemic extended to West Bengal and first outbreak occurred in 1980 in Malda district.
- At present, the disease has established its endemicity in 31 districts in Bihar, 11 districts in West Bengal, 5 districts in Jharkhand, and 3 districts in Uttar Pradesh. Sporadic cases have been reported from Tamil Nadu, Maharashtra, Karnataka, and Andhra Pradesh.

Habitat

The amastigote (LD body) of *L. donovani* is found in the reticuloendothelial system. They are found mostly within the macrophages in the spleen, liver, bone marrow and less often in other locations such as skin, intestinal mucosa, and mesenteric lymph nodes.



Flowchart 5.2: Distribution and disease caused by *Leishmania* spp.

Morphology

The parasite exists in 2 forms (Fig. 5.9).

- **Amastigote form:** in humans and other mammals.
- **Promastigote form:** in the sandfly and in artificial culture.

Amastigote

The amastigote form (LD body) is an ovoid or rounded cell, about 2–4 μm in size (Fig. 5.9A).

- It is typically intracellular, being found inside macrophages, monocytes, neutrophils, or endothelial cells.
- They are also known as **LD bodies**.
- Smears stained with Leishman, Giemsa, or Wright's stain show a pale blue cytoplasm enclosed by a limiting membrane.
- The large oval nucleus is stained red. Lying at the right angles to nucleus, is the red or purple-stained **kinetoplast**.
- In well-stained preparations, the kinetoplast can be seen consisting of a **parabasal body** and a dot-like **blepharoplast** with a delicate thread connecting the two. The axoneme arising from the blepharoplast extends to the anterior tip of the cell.
- Alongside the kinetoplast a clear unstained vacuole can be seen.
- Flagellum is absent.

Promastigote

It is a flagellar stage and is present in insect vector, sandfly and in cultures.

- The promastigotes, which are initially short, oval or pear-shaped forms, subsequently become long spindle-shaped cells, 15–25 μm in length and 1.5–3.5 μm in breadth (Fig. 5.9B).

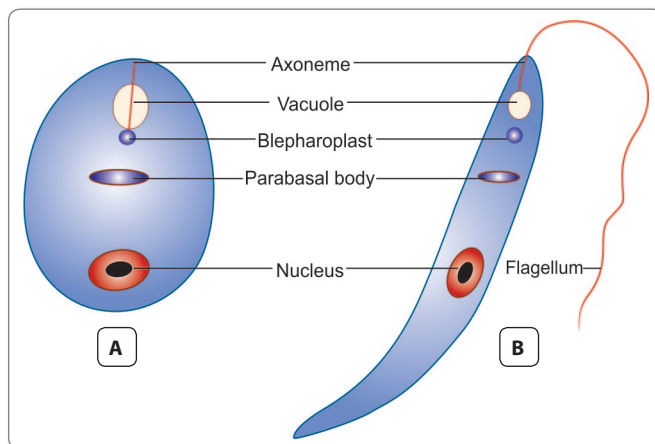


Fig. 5.9: Morphology of *Leishmania donovani*. **A.** Amastigote (LD body); **B.** Promastigote

- A single nucleus is situated at the center. The kinetoplast lies transversely near the anterior end.
- The flagellum is single, delicate, and measures 15–28 μm .
- Giemsa or Leishman-stained films show pale blue cytoplasm with a pink nucleus and bright red kinetoplast.
- A vacuole is present near the root of the flagellum.
- There is no undulating membrane.
- Promastigote forms, which develop in artificial cultures, have the same morphology as in the sandfly.

Life Cycle

L. donovani completes its life cycle in 2 hosts (Fig. 5.10).

Definitive host: Man, dog, and other mammals.

Vector: Female sandfly (*Phlebotomus* species).

Infective form: Promastigote form present in midgut of female sandfly.

Vector species responsible for transmission of *Leishmania donovani*

Country	Phlebotomus species
India	- <i>P. argentipes</i>
China, Bangladesh	- <i>P. chinenses</i> <i>P. sergenti</i>
Sudan and Africa	- <i>P. perniciosus</i> <i>P. orientalis</i> (Sudan) <i>P. longicupis</i> <i>P. sergenti</i>
Mediterranean countries	- <i>P. perniciosus</i> <i>P. papatasi</i> <i>P. major</i> <i>P. tobbi</i>
Middle East and Russia	- <i>P. perfulievi</i> <i>P. papatasi</i>
Central Asia	- <i>P. papatasi</i>
South America	- <i>P. longipalpis</i> <i>P. intermudias</i> <i>P. lutzi</i>

Mode of transmission:

- Humans acquire by bite of an infected female sandfly.
- It can also be transmitted vertically from mother to fetus, by blood transfusion, and accidental inoculation in the laboratory.

Incubation period: Usually 2–6 months, occasionally it may be as short as 10 days or as long as 2 years.

- The sandfly regurgitates the promastigotes in the wound caused by its proboscis.
- These are engulfed by the cells of reticuloendothelial system (macrophages, monocytes, and polymorpho-

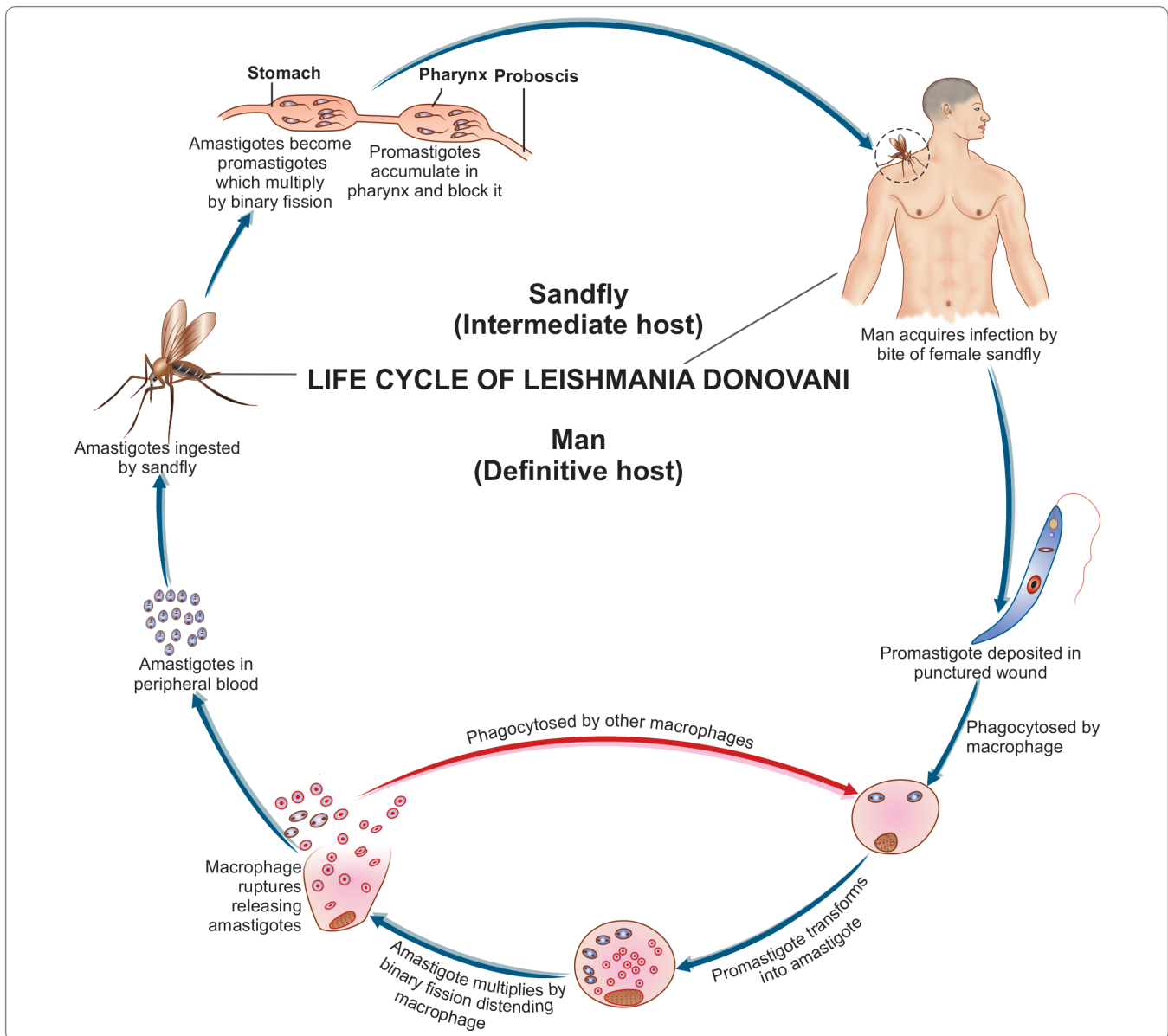


Fig. 5.10: Life cycle of *Leishmania donovani*

nuclear leucocytes) and change into amastigote (LD body) within the cells.

- The amastigote multiplies by binary fission, producing numerous daughter cells that distend the macrophage and rupture it. The liberated daughter cells are in turn, phagocytosed by other macrophages and histiocytes. Small number of LD bodies can be found in peripheral blood inside neutrophils or monocytes (Fig. 5.10).
- When a vector sandfly feeds on an infected person, the amastigotes present in peripheral blood and tissue fluids enter the insect along with its blood meal. In the midgut (stomach) of the sandfly, the amastigote elongates and develops into the promastigote form (Fig. 5.10).
- The promastigote multiplies by longitudinal binary fission and reaches enormous numbers. They may be seen as **large rosettes** with their flagella entangled.
- In the sandfly, they migrate from the midgut to the pharynx and hypostome, where they accumulate and block the passage.
- Such **blocked sandflies** have difficulty in sucking blood. When they bite a person and attempt to suck blood, plugs of adherent parasites may get dislodged from

the pharynx and they are deposited in the punctured wound. It takes about 10 days for the promastigotes to reach adequate numbers after ingestion of the amastigotes, so as to block the buccal cavity and pharynx of the sandfly. This is, therefore, the duration of **extrinsic incubation period**.

This period is also synchronous with the gonadotropic cycle of the vector, so that amastigotes ingested during a single blood meal, are ready to be transmitted when the sandfly takes the next blood meal after its eggs have been laid.

Pathogenicity

L. donovani causes visceral leishmaniasis or kala-azar.

- Kala-azar is a reticuloendotheliosis resulting from the invasion of reticuloendothelial system by *L. donovani*.
- The parasitized macrophages disseminate the infection to all parts of the body.
- In the spleen, liver, and bone marrow particularly, the amastigotes multiply enormously in the fixed macrophages to produce a 'blockade' of the reticuloendothelial system. This leads to a marked proliferation and destruction of reticuloendothelial tissue in these organs.
- **Spleen:**
 - The spleen is the most affected organ. It is grossly enlarged and the capsule is thickened due to perisplenitis.
 - Spleen is soft and friable and cuts easily due to absence of fibrosis.
 - The cut section is **red or chocolate** in color due to the dilated and engorged vascular spaces.
 - The trabeculae are thin and atrophic.
 - Microscopically, the reticulum cells are greatly increased in numbers and are loaded with LD bodies.
 - Lymphocytic infiltration is scanty, but plasma cells are numerous.
- **Liver:**
 - The liver is enlarged.
 - The K upffer cells and vascular endothelial cells are heavily parasitized, but hepatocytes are not affected.
 - Liver function is, therefore, not seriously affected, although prothrombin production is commonly decreased.
 - The sinusoidal capillaries are dilated and engorged.
 - Some degree of fatty degeneration is seen. The cut surface may show a '**nutmeg**' appearance.
- **Bone marrow:**
 - The bone marrow is heavily infiltrated with parasitized macrophages, which may crowd the hematopoietic tissues.

- **Peripheral lymphnodes** and lymphoid tissues of the nasopharynx and intestine are hypertrophic, although this is not seen in Indian cases.
- Severe **anemia** with hemoglobin levels of 5–10 g/dL may occur in Kala-azar, as a result of infiltration of the bone marrow as well as by the increased destruction of erythrocytes due to hypersplenism. Autoantibodies to red cells may contribute to hemolysis.

Ecological types

The epidemiology and clinical features of visceral leishmaniasis and the ecology of the parasite are very different in different geographical areas. The different clinical syndromes have, therefore been considered to be distinct entities and the parasite causing them have been given separate species or sub-species status, as listed below.

- **Indian visceral leishmaniasis:** Caused by *L. donovani* producing the anthroponotic disease Kala-azar and its sequel post Kala-azar dermal leishmaniasis (PKDL). The disease is not zoonotic; **human beings being the only host and reservoir**. Vector is the sandfly, *P. argentipes*.
- **Mediterranean leishmaniasis:** Middle eastern leishmaniasis caused by *L. donovani infantum* affecting mostly young children. It is a **zoonotic disease**; the reservoir being dog and wild canines such as foxes, jackals, and wolves. Vectors are *P. perniciosus* and *P. papatasi*.
- **East African leishmaniasis:** Caused by *L. archibaldi*. The disease is zoonotic, found mainly in rural areas.
- **South American leishmaniasis:** Caused by *L. donovani chagasi* (*L. chagasi*). The disease is zoonotic. Foxes and wild canines are reservoirs. Dogs act as link between the reservoir hosts and humans. The main vector is the sandfly, *Lutzomyia longipalpis*.
- **China:** The disease resembles the mediterranean type (*L. infantum*) in the north-west and Indian type *L. donovani* in the East.
- **American (New World) visceral leishmaniasis:** Caused by *L. chagasi*. It is present in most parts of Latin America and resembles the disease caused by *L. infantum*. The main vector is *L. longipalpis*.

- Leucopenia with marked neutropenia and thrombocytopenia are frequently seen. Antibodies against WBCs and platelets suggest an autoimmune basis for the pancytopenia observed in Kala-azar.

Causes of anemia in Kala-azar

- Splenic sequestration of RBCs
- Decreased erythropoiesis due to replacement of bone marrow with parasitized macrophages
- Autoimmune hemolysis
- Hemorrhage



Fig. 5.11: Kala-azar Spleen showing a greatly enlarged organ

Clinical Features of Kala-Azar

- The onset is typically insidious. The clinical illness begins with fever, which may be continuous, remittent, or irregular.
- **Splenomegaly** starts early and is progressive and massive (Fig. 5.11).
- **Hepatomegaly** and **lymphadenopathy** also occur but are not so prominent.
- Skin becomes **dry, rough,** and **darkly pigmented** (hence, the name **Kala-azar**).
- The hair become thin and brittle.
- **Cachexia** with marked anemia, emaciation, and loss of weight is seen.
- **Epistaxis** and bleeding from gums are common.
- Most untreated patients die in about 2 years, due to some intercurrent disease such as dysentery, diarrhea, and tuberculosis.

Post Kala-azar Dermal Leishmaniasis

About 3–10% cases of patients of visceral leishmaniasis in endemic areas develop PKDL, about an year or 2 after recovery from the systemic illness.

- PKDL is seen mainly in India and East Africa and not seen elsewhere. The Indian and African diseases differ in several aspects; important features of PKDL in these two regions are listed in Table 5.7.
- PKDL is a non-ulcerative lesion of skin. The lesions are of 3 types.
 - **Depigmented macules:** These commonly appear on the trunk and extremities and resemble tuberculoid leprosy.

Table 5.7: Differences Between PKDL of India and East Africa

Characteristics	India	East Africa
Incidence	5%	50%
Time interval between visceral leishmaniasis and PKDL	Occurs after visceral leishmaniasis. May take 3–5 years	Occurs during visceral leishmaniasis
Age group affected	Any age	Mostly children
Appearance of rash	Rashes appear after visceral leishmaniasis	Rashes may appear during visceral leishmaniasis
Spontaneous cure	Not seen	Seen
Duration of treatment with sodium stibogluconate	60–120 days	60 days

- **Erythematous patches:** These are distributed on the face in a '**butterfly distribution**'.
- **Nodular lesion:** Both of the above mentioned lesions may develop into painless yellowish pink non-ulcerating granulomatous nodules.
- The parasite can be demonstrated in the lesions.

Immunity

- The most important immunological feature in Kala-azar is the marked suppression of cell-mediated immunity to leishmanial antigens. This makes unrestricted intracellular multiplication of the parasite possible. Cellular responses to tuberculin and other antigens are also suppressed and may be regained some 6 weeks after recovery from the disease.
- In contrast, there is an overproduction of immunoglobulins, both specific anti-leishmanial antibodies as well as non-specific polyclonal IgG and IgM. Circulating immune complexes are demonstrable in serum.

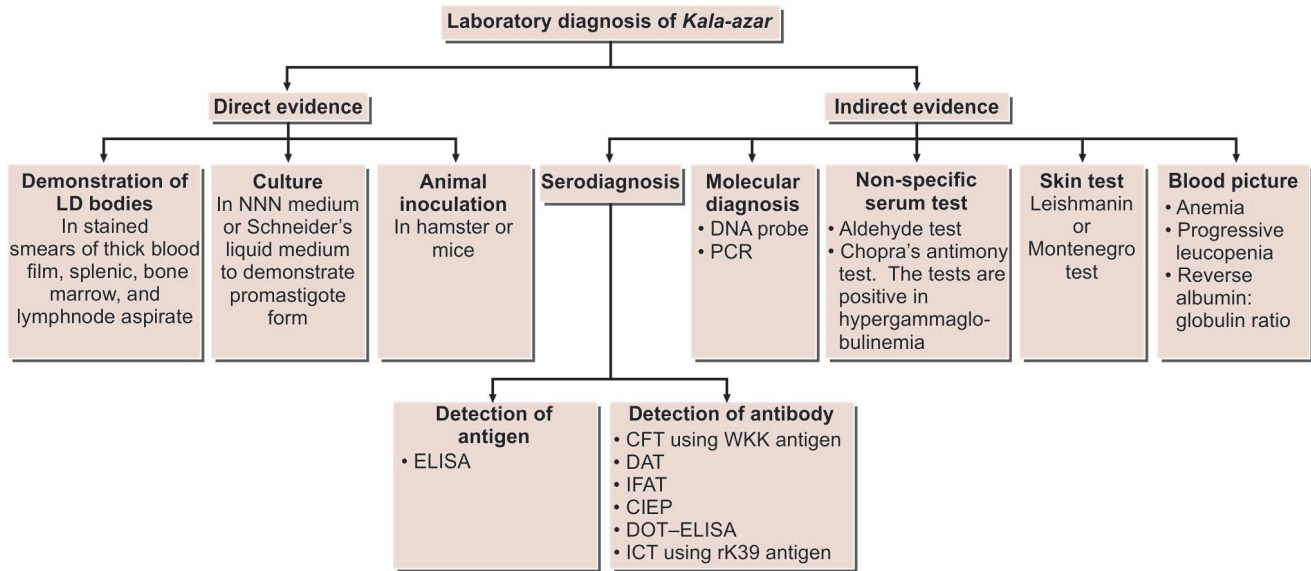
Laboratory Diagnosis

Laboratory diagnosis of Kala-azar depends upon direct and indirect evidences (Flowchart 5.3).

Direct Evidence

Microscopy

- Demonstration of amastigotes in smears of tissue aspirates is the **gold standard** for diagnosis of visceral leishmaniasis.



Flowchart 5.3: Laboratory diagnosis of Kala-azar

- For microscopic demonstration of the parasite, the materials collected are:
 - Peripheral blood
 - Bone marrow
 - Splenic aspirate
 - Enlarged lymph node.
- The smears are stained by Leishman, Giemsa, or Wright's stains and examined under oil immersion objective.
- Amastigote parasite can be seen within the macrophages, often in large numbers. A few extracellular forms can also be seen.
- **Peripheral blood smear:**
 - Peripheral blood contains the amastigotes present inside circulating monocytes and less often in neutrophils, but the numbers are so scanty that a direct blood smear may not show them.
 - Chances of detecting them are somewhat improved by examination of a thick blood film.
 - It is best to examine **buffy coat smear**, although even these are not often found positive.
 - Buffy coat smears show a diurnal periodicity, more smears being positive when collected during the day than at night.
- **Bone marrow aspirate:**
 - Bone marrow aspirate is the most common diagnostic specimen collected.
 - Generally, the sternal marrow is aspirated by puncturing the sternum at the level of the 2nd or 3rd intercostal space, using a sternal puncture needle.
 - This consists of a short stout needle with a stylet. It has a movable guard, which is fixed at 1–2 cm from the tip, depending on the thickness of the chest wall over the sternum.
 - After disinfecting and anesthetizing the skin, the needle is introduced into the sternal marrow and about 0.5 mL of marrow fluid is aspirated using a syringe. The puncture wound is sealed with celloidin or tincture benzoin. Bone marrow samples can also be obtained by puncturing the iliac crest.
- **Splenic aspirates:**
 - Splenic aspirates are richer in parasites and therefore, are more valuable for diagnosis.
 - But, the procedure can sometimes cause dangerous bleeding and therefore, should be done carefully and only when a marrow examination is inconclusive.
- **Lymphnode aspirates:**
 - Lymphnode aspirates are not useful in the diagnosis of Indian Kala-azar, although it is employed in visceral leishmaniasis in some other countries.
- **Comparison of aspiration biopsies:** Although splenic aspiration is the most sensitive method (98% positive), bone marrow puncture (50–85%, positive) is a safer procedure when compared to spleen puncture, as there is risk of hemorrhage in splenic puncture particularly in patients with advanced stage of disease with soft enlarged spleen. Splenic aspiration is contraindicated in patients with prolonged prothrombin time or if platelet count is less than 40,000/mm³. Liver biopsy is also not a safe procedure and carries a risk of hemorrhage. Lymph node aspiration is positive in 65% of cases of African Kala-azar, but not useful in cases of Indian Kala-azar.

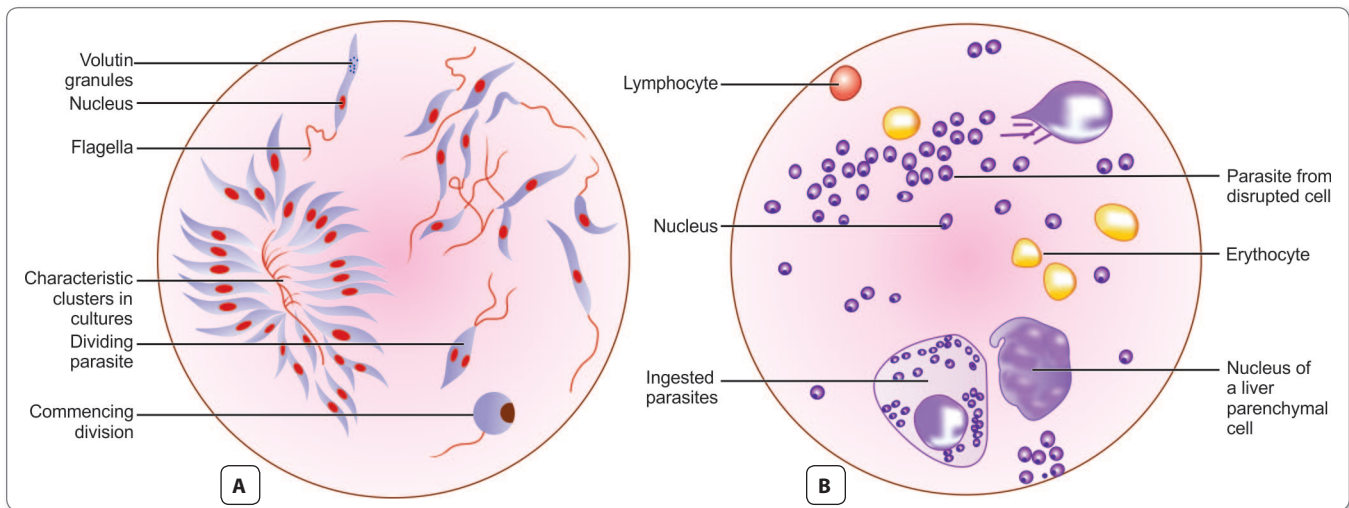


Fig. 5.12: *Leishmania donovani*. A. Culture form (Giemsa stain, magn. X 1100); B. Liver smear (Giemsa stain, magn. X 1100)

Culture

Different tissue materials or blood are cultured on **NNN medium**. This is a rabbit blood agar slope consisting of 2 parts of salt agar and 1 part of defibrinated rabbit blood. The material is inoculated into the water of condensation and culture is incubated at 22°–24°C for 1–4 weeks. At the end of each week, a drop of culture fluid is examined for promastigotes under high power objective or phase contrast illumination (Fig. 5.12). Other biphasic medium, like **Schneider's drosophila tissue culture medium** with added fetal calf serum can also be used.

Animal inoculation

Animal inoculation is not used for routine diagnosis.

- When necessary, Chinese golden hamster is the animal employed.
- The material is inoculated intraperitoneally or intradermally into the skin of nose and feet
- The inoculated animals are kept at 23°–26°C.
- In positive cases, the amastigote can be demonstrated in smears taken from ulcers or nodules developing at the sites of inoculation or from the spleen (Fig. 5.13).
- Animal inoculation is a very sensitive method, but takes several weeks to become positive.

Indirect Evidences

Serodiagnosis

- **Detection of antigen:** The concentration of antigen in the serum or other body fluids is very low. ELISA and PCR have been developed for detection of leishmanial antigen.

- **Detection of antibodies:** CFT was the first serological test used to detect serum antibodies in visceral leishmaniasis. The antigen originally used, was prepared from human tubercle bacillus by Witebsky, Kliengenstein, and Kühn (hence, called **WKK antigen**). CFT using WKK antigen becomes positive early in the disease, within weeks of infection. Positive reaction also occurs in other conditions, including tuberculosis, leprosy, and tropical eosinophilia.
 - Specific leishmanial antigens prepared from cultures have been used in a number of tests to demonstrate specific antibodies. These tests include:
 - Indirect immunofluorescent antibody test (IFAT)
 - Counter immunoelectrophoresis (CIEP)
 - ELISA and DOT-ELISA
 - DAT

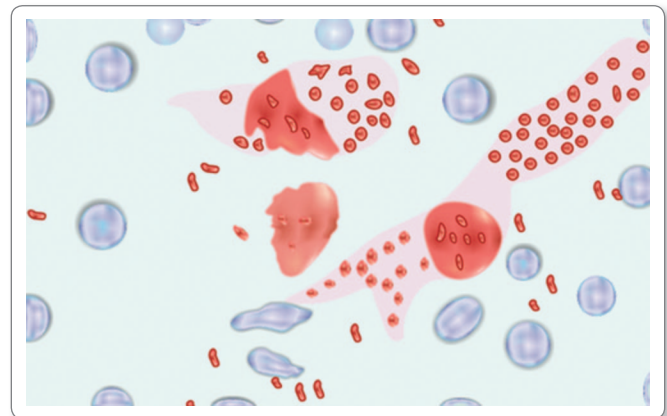


Fig. 5.13: LD body in spleen smear of experimentally infected animal (Giemsa stain)

- A specific rapid immunochromatographic dipstick (ICT) method for antibody has been developed using a recombinant leishmanial antigen **rk 39** consisting of 39 amino acids conserved in kinesin region of *L. infantum*. The sensitivity of the test is 98% and specificity is 90%.

Note: The direct agglutination test for antileishmanial antibody has been found to be highly specific and sensitive for diagnosis of Kala-azar. However, rk 39 antibody test is more useful and sensitive and recommended by National Vector-borne Disease Control Programme (NVDCP) in India.

Molecular diagnosis

A number of molecular diagnosis methods have been developed, which help in species identification of *Leishmania*. The methods include Western blot and PCR. The use of PCR is confined to specialized laboratories and is yet to be used for routine diagnosis of visceral leishmaniasis in endemic areas.

Non-specific serum tests

These tests are based on the greatly increased globulin content of serum in the disease.

- The 2 tests widely used are
 - **Napier's aldehyde or formogel test**
 - **Chopra's antimony test.**
- **Napier's aldehyde test:** 1 mL of clear serum from the patient is taken in a small test tube, a drop of formalin (40% formaldehyde) is added, shaken, and kept in a rack at room temperature.
 - A control tube with normal serum is also set up.
 - A positive reaction is jellification and opacification of the test serum, resembling the coagulated white of egg appearing within 3–30 minutes.
 - About 85% of patients with disease of 4 months or more give positive reaction.
 - Aldehyde test is always negative in cutaneous leishmaniasis.
 - The test merely indicates greatly increased serum gamma globulin and thus, is non-specific.
- **Chopra's antimony test:** It is done by taking 0.2 mL of serum diluted 1:10 with distilled water in a Dreyer's tube and overlaying with few drops of 4% solution of urea stibamine. Formation of flocculant precipitate indicates positive test.
 - The reaction is said to be more sensitive than the aldehyde test.
- Both the tests give false positive reactions in several other disease such as multiple myeloma, cirrhosis of liver, tuberculosis, leprosy, schistosomiasis, African trypanosomiasis, etc., where hypergammaglobulinemia exists.

Skin test

- **Leishmanin skin test (Montenegro test):**
 - It is delayed hypersensitivity test.
 - This was first discovered by Montenegro in South America and hence, named after him.
 - 0.1 mL of killed promastigote suspension (10^6 washed promastigotes/mL) is injected intradermally on the dorsoventral aspect of forearm.
 - Positive result is indicated by an induration and erythema of 5 mm or more after 48–72 hours.
 - Positive result indicates prior exposure to leishmanial parasite.
 - In active Kala-azar, this test is negative and becomes positive usually 6–8 weeks after cure from the disease.

Blood picture

- Complete blood count shows **normocytic normochromic anemia** and **thrombocytopenia**.
- Leucocyte count reveals **leucopenia** accompanied by a relative increase of lymphocytes and monocytes. Eosinophil granulocytes are absent. During the course of disease, there is a progressive diminution of leucocyte count falling to $1,000/\text{mm}^3$ of blood or even below that.
- The ratio of leucocyte to erythrocyte is greatly altered and may be about 1:200 to 1:100 (normal 1:750).
- Serum shows **hypergammaglobulinemia** and a reversal of the albumin: globulin ratio.
- Liver function tests show mild elevations.

Diagnosis of PKDL

- The nodular lesions are biopsied and amastigote forms are demonstrated in stained sections.
- The biopsy material can be cultured or animal inoculation can be done.
- Immunodiagnosis has no role in the diagnosis of PKDL.

Treatment

Kala-azar responds to treatment better than other forms of visceral leishmaniasis. The standard treatment consists pentavalent antimonial compound, which is the drug of choice in most of the endemic regions of the world, but there is resistance to antimony in Bihar in India, where amphotericin-B-deoxycholate or miltefosine is preferred.

Pentavalent Antimonial Compound

Two pentavalent antimonial (Sb^V) preparations are available:

- Sodium stibogluconate (100 mg of Sb^V/mL)
- Meglumine antimonate (85 mg of Sb^V/mL).

Dosage: The daily dose is 20 mg/kg by rapid intravenous (IV) infusion or intramuscular (IM) injection for 20–30 days.

Cure rates exceed 90% in most of the old world, except in Bihar (India) due to resistance.

Amphotericin B

- Amphotericin B is currently used as a first-line drug in Bihar. In other parts of the world, it is used when initial antimonial treatment fails.
- **Dosage:** 0.75–1.0 mg/kg on alternate days for a total of 15 infusions.

Note: Fever with chills is almost seen in all patients, using amphotericin-B infusions.

- **Liposomal amphotericin B:** It has been developed and used extensively to treat visceral leishmaniasis in all parts of the world. It is the only drug approved by the US Food and Drug Administration (FDA) for the treatment of visceral leishmaniasis; dose being 3 mg/kg daily. By using liposomal amphotericin-B, higher doses can be given, improving the cure, without toxicity.

Paromomycin

Paromomycin is an intramuscular aminoglycoside antibiotic with antileishmanial activity.

Dosage: It is given in a dose of 11 mg/kg daily for 21 days.

Miltefosine

Miltefosine is the first oral drug, approved for the treatment of leishmaniasis.

Dosage: 50 mg daily for 28 days for patients weighing less than 25 kg, and twice daily for patients weighing more than 25 kg.

Treatment of PKDL is same as that for visceral leishmaniasis.

Prophylaxis

- Early detection and treatment of all cases.
- Integrated insecticidal spraying to reduce sandfly population.
- Destruction of animal reservoir host in cases of zoonotic Kala-azar.
- Personal prophylaxis by using anti-sandfly measures like, using thick clothes, bed nets, window mesh, or insect repellants and keeping the environment clean.
- No vaccine is available against Kala-azar.

Leishmania Tropica Complex

It includes 3 species:

- *Leishmania tropica*
- *Leishmania major*

- *Leishmania aethiopica*
- All these species cause old world cutaneous leishmaniasis. The disease is also known as **oriental sore, Delhi boil, Bagdad boil, or Aleppo button.**

History and Distribution

Cunningham (1885) first observed the parasite in the tissues of a Delhi boil in Calcutta.

- Russian military surgeon, Borovsky (1891) gave an accurate description of its morphology and Luhe (1906) gave the name *L. tropica*.
- *L. tropica* and *L. major* are found in Middle-East, India, Afganistan, eastern Mediterranean countries, and North Africa.
- *L. aethiopica* occurs in Ethiopia and Kenya.
- In India, cutaneous leishmaniasis is restricted to the dry western half of the Indo-gangetic plains including dry areas bordering Pakistan, extending from Amritsar to Kutch and Gujrat plains. To the East, the cases have been reported from Delhi and Varanasi in Uttar Pradesh.

Habitat

L. tropica causing cutaneous leishmaniasis (old world cutaneous leishmaniasis) are essentially the parasite of skin. The amastigote forms occur in the reticuloendothelial cells of the skin, whereas promastigote forms are seen in sandfly vector.

Morphology

Morphology of *L. tropica* complex is indistinguishable from that of *L. donovani*.

Life Cycle

The life cycle of *L. tropica* is similar to that of *L. donovani* except

Vectors: The vectors of *L. tropica* complex are *Phlebotomus* sandflies. The following species of sandflies act as vector.

- *P. sergenti*
- *P. pappatasi*
- *P. caucasiasus*
- *P. intermedius*

Mode of transmission:

- The most common mode of infection is through bite of sandflies.
- Infection may also sometimes occur by direct contact.
- Infection may be transmitted from man-to-man or animal-to-man by direct inoculation of amastigotes
- Infection may also occur by autoinoculation.
- The amastigotes are present in the skin, within large mononuclear cells, neutrophils, inside capillary endothelial cells, and also free in the tissues.

- They are ingested by sandflies feeding near the skin lesions.
- In the midgut of the sandfly, the amastigotes develop into promastigotes, which replicate profusely.
- These are in turn transmitted to the skin of persons bitten by sandflies in the skin, the promastigotes are phagocytosed by mononuclear cells, in which they become amastigotes and multiply.
- However, they remain confined to the skin, without being transported to the internal organs, as is the case in visceral leishmaniasis.

Incubation period: Incubation period varies from 2–8 months.

Pathology

Amastigote forms are found in histiocytes and endothelial cells. There is an inflammatory granulomatous reaction with infiltration of lymphocyte and plasma cells. Early lesions are papular, followed by ulceration necrosis. **Papule** and **ulcer** are the main pathological lesions. They heal over months to years, leaving scars.

Clinical Features

L. tropica causes **Old World Cutaneous leishmaniasis**.

- Features of the disease vary with epidemiological pattern from region-to-region.
- Three distinct patterns of old world cutaneous leishmaniasis have been recognized.
- **The anthroponotic urban type** causing painless dry ulcerating lesions, leading to disfiguring scars, caused by the species *L. tropica*.
 - This is prevalent from the Middle East to north-western India. The most important vector is *P. sargenti*.
 - It is seen mainly in children in endemic areas and is called as **oriental sore** or **Delhi boil**.
 - It begins as a **raised papule**, which grows into a nodule that ulcerates over some weeks.
 - Lesions may be single or multiple and vary in size from 0.5 to more than 3 cm. Lymphatic spread and lymph gland involvement may be palpable and may precede the appearance of the skin lesion.
 - The margins of the ulcer are raised and indurated.
 - The ulcer is usually painless unless secondary bacterial infection occurs.
 - There may be satellite lesions, especially in *L. major* and *L. tropica* infections.
 - The dry ulcers usually heal spontaneously in about an year.
- **The zoonotic rural type** causing moist ulcers which are inflamed, often multiple, caused by *L. major*.
 - The incubation period is usually less than 4 months.

- Lesions due to *L. major* heal more rapidly than *L. tropica*
- This is seen in the lowland zones of Asia, Middle East, and Africa.
- Gerbils, rats, and other rodents are the reservoirs.
- *P. papatasi* is the most important vector.
- **The non-ulcerative and often diffuse lesions** caused by *L. aethiopica* and seen in the highlands of Ethiopia and Kenya are known as **diffuse cutaneous leishmaniasis**.
 - *P. longipes* is the usual vector.
 - It is a rare form of disease, where nodular lesions although restricted to skin are widely distributed.
 - It is characterized by low humoral as well as cell-mediated immunity.
 - The lesions last for years or even for entire age.
 - It is difficult to treat.

Leishmaniasis recidivans is a type of lesion seen in persons with a high degree of cell-mediated immunity to the parasite. The lesions are chronic with alternating periods of activity and healing, characterized by a central scar with peripheral activity. The lesions resemble those of lupus or tuberculoid leprosy. Parasites are very scanty in the lesions. The Leishmanin test is strongly positive. Chemotherapy is not very useful. Better results follow local application of heat.

Laboratory Diagnosis

Microscopy

- Smear is made from the material obtained from the indurated edge of nodule or sore and stained by Giemsa or Leishman stain.
- Amastigotes are found in large numbers inside the macrophages.
- Definitive diagnosis is made by demonstration of amastigote in the smear collected from the lesion.

Culture

Promastigote forms can be isolated by culture of the aspirate material in NNN medium.

Skin Test

Leishmanin skin test is helpful. Positive leishmanin test in children under 10 years of age from endemic areas is highly suggestive of the disease. The skin test is negative in diffuse cutaneous leishmaniasis.

Serology

These are of limited value as the patient shows no detectable levels of circulating antibodies.

Treatment

The specific treatment of cutaneous leishmaniasis is same as visceral leishmaniasis.

- Antimony-resistant diffuse cutaneous leishmaniasis can be treated with pentamidine.
- Topical treatment consists of a paste of 10% charcoal in sulphuric acid or liquid nitrogen.

Prophylaxis

- Control of sandfly population by insecticides and sanitation measures.
- Personal protection by use of protective clothing and use of insect repellants.
- Elimination of mammalian reservoir.

New World Leishmaniasis

L. braziliensis complex and *L. mexicana* complex

History and Distribution

Lindenberg and paranhos (1909) first described amastigotes in the ulcers of skin in a man in Brazil. Vianna (1911) named the species as *L. braziliensis*.

- *L. braziliensis* complex and *L. mexicana* complex cause new world leishmaniasis in Central and South America.

Habitat

These occur as intracellular parasite. The amastigote form is seen inside the macrophages of skin and mucous membrane of the nose and buccal cavity. The promastigote form occurs in vector species *Lutzomyia*.

Morphology

Morphology of amastigote and promastigote forms of both the parasites is same as that of the other 2 species of *Leishmania*.

Life Cycle

The life cycle of *Leishmania* species causing the new world cutaneous and mucocutaneous leishmaniasis is similar to that of *L. donovani* except:

- Amastigotes are found in the reticuloendothelial cells and lymphoid tissues of skin, but not in the internal organs.
- The infection is transmitted to man from animals by bite of sandfly vectors of genus **Lutzomyia**.
- Sylvatic rodents and domestic animals are the common sources and reservoir of infection.

- Direct transmission and autoinfection also occurs man-to-man.

Clinical Features

L. mexicana complex leads to cutaneous leishmaniasis which closely resembles the old world cutaneous leishmaniasis. However a specific lesion of caused by *L. mexicana* is **chiclero ulcer** which is characterized by ulcerations in pinna.

- Chiclero ulcer is also called as **self healing sore of Mexico**.

L. braziliensis complex causes both mucocutaneous leishmaniasis and cutaneous leishmaniasis.

- *L. braziliensis* causes the most severe and destructive form of cutaneous lesion.
- It involves the nose, mouth, and larynx.
- The patient experiences a nodule at the site of sandfly bite with symptoms consistent with oriental sore.
- Subsequent **mucocutaneous** involvement leads to nodules inside the nose, perforation of the nasal septum, and enlargement of the nose and lips (**espundia**).
- If the larynx is involved, the voice changes as well.
- Ulcerated lesions may lead to scarring and tissue destruction that can be disfiguring.
- The disease occurs predominantly in Bolivia, Brazil, and Peru.

Pian Bois

It is also known as '**forest yaws**'.

- It is caused by *L. braziliensis gyanensis* and is characterized by appearance of single or multiple painless dry persistent ulcers appear all.

Laboratory Diagnosis

Microscopy

Amastigotes are demonstrated in smears taken from lesions of skin and mucous membrane. *L. mexicana* amastigotes are larger than those of *L. braziliensis* and their kinetoplast is more centrally placed.

Biopsy

Amastigotes can also be demonstrated from slit-skin biopsy.

Culture

Culturing material obtained from ulcers in NNN medium demonstrates promastigotes. *L. mexicana* grows well in comparison to *L. braziliensis*, which is a grows slowly.

Serology

Antibodies can be detected in serum by IFA test, which is positive in 89–95% of cases. ELISA is also a sensitive method to detect antibody; being positive in 85% of cases.

Skin Test

Leishmanin test is positive in cutaneous and mucocutaneous leishmaniasis.

Treatment

Treatment with a pentavalent antimonial compound is moderately effective for mild mucocutaneous leishmaniasis.

- Amphotericin-B is the best alternative drug currently available.
- In case of respiratory complications, glucocorticoids can be used.

Prophylaxis

- Due to sylvatic and rural nature of the disease, control is often difficult.
- Use of insect repellants, spraying of insecticides, and screening are advisable.
- Forest workers should use protective clothing and other protective measures.
- A recently developed polyvalent vaccine using 5 *Leishmania* strains has been reported to be successful in reducing the incidence of cutaneous leishmaniasis in Brazil.

Key points of *Leishmania*

- Visceral leishmaniasis (Kala-azar) is caused by *L. donovani* and *L. infantum*.
- Vector of Kala-azar is sandfly (*argentipes*).
- Amastigote forms (LD body) is found in macrophages and monocytes in human.
- Promastigote forms with a single flagellum is found in vector sandfly and artificial culture.
- **Clinical features:** *Kala-azar*: Fever, hepatosplenomegaly, marked anemia, darkly pigmented skin, weight loss, cachexia, etc.
- **PKDL:** Seen after 1–2 years of treatment in 3–10% cases and is a non-ulcerative lesion of skin.
- **Diagnosis:** By demonstrations of LD bodies in peripheral blood, bone marrow aspirate, splenic aspirate, and lymph node aspirate; culture done in NNN medium; aldehyde test; detection of specific antigen and antibody by IIF, ELISA, DAT and rapid rk 39 antibody detection test.
- **Blood picture:** Anemia, thrombocytopenia, leucopenia with relative lymphocytosis, and hypergamma-globulinemia.
- **Treatment:** Sodium stibogluconate amphotericin-B, and oral miltefosine.
- Old world cutaneous leishmaniasis (oriental sore) is caused by *L. tropica* and the vectors are *P. surgenti* and *P. papatasi*.
- New world mucocutaneous and cutaneous leishmaniasis (espundia) are caused by *L. braziliensis* and *L. mexicana*. Vector is sandfly of genus *Lutzomyia*.

Review Questions

1. Describe briefly the life cycle and laboratory diagnosis of:

- (a) *Trypanosoma brucei gambiense*
(c) *Leishmania donovani*

- (b) *Trypanosoma cruzi*

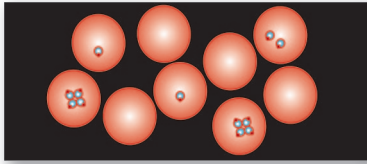
2. Write short notes on:

- (a) Sleeping sickness
(c) Antigenic variations of *Trypanosoma brucei gambiense*
(e) *Trypanosoma rangeli*
(g) Post kala-azar dermal leishmaniasis
(i) Diffuse cutaneous leishmaniasis

- (b) Chagas disease
(d) Morphological stages of hemoflagellates
(f) Kala-azar
(h) Cutaneous leishmaniasis

3. Differentiate between:

- (a) East African trypanosomiasis and West African trypanosomiasis
(b) *Trypanosoma cruzi* and *Trypanosoma rangeli*



Malaria and Babesia

6

Protozoan parasites characterized by the production of spore-like oocysts containing sporozoites were known as sporozoa.

- They live **intracellularly**, at least during part of their life cycle.
- At some stage in their life cycle, they possess a structure called the **apical complex**, by means of which they attach to and penetrate host cells.
- These protozoa are therefore grouped under the **Phylum Apicomplexa**.
- The medically important parasites in this group are the **malaria parasites, Coccidia, and Babesia**.
- The **Phylum Apicomplexa** includes 2 classes viz. haematozoa and coccidia and 3 orders—eimeriida, haemosporida, and piroplasmida (Table 6.1).

Note: Many minute intracellular protozoa formerly grouped as sporozoa have been reclassified because of some structural differences. These are now called **microspora**. They infect a

large spectrum of hosts including vertebrates and invertebrates. Infection is mostly asymptomatic, but clinical illness is often seen in the immunodeficient.

Classification

Malaria parasite belongs to

Phylum: Apicomplexa

Class: Sporozoa

Order: Haemosporida

Genus: *Plasmodium*.

- The genus *Plasmodium* is divided into 2 subgenera, *P. vivax*, *P. malariae* and *P. ovale* belong to the subgenus **Plasmodium** while *P. falciparum* is allocated to subgenus **Laverania** because it differs in a number of aspects from the other 3 species.
- *P. vivax*, *P. malariae*, and *P. ovale* are closely related to other primate malaria parasites. *P. falciparum* on the other hand, is more related to bird malaria parasites and appears to be a recent parasite of humans, in evolutionary terms. Perhaps for this reason, falciparum infection causes the severest form of malaria and is responsible for nearly all fatal cases.
- *P. knowlesi*, a parasite of long-tailed Macaque monkeys may also affect man.

Table 6.1: Phylum Apicomplexa (Sporozoa)

Class	Order	Genera
Haematozoa	Haemosporida Piroplasmida	<i>Plasmodium</i> <i>Babesia</i>
Coccidia	Eimeriida	<i>Toxoplasma</i> <i>Cyclospora</i> <i>Cryptosporidium</i> <i>Isospora</i> <i>Sarcocystis</i>

Causative Agents of Human Malaria

- *Plasmodium vivax*: Benign Tertian Malaria
- *Plasmodium falciparum*: Malignant Tertian Malaria

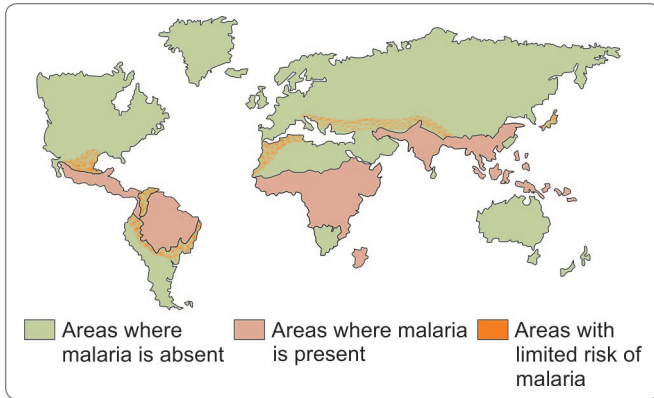


Fig. 6.1: Global distribution of malaria

- *Plasmodium malariae*: Benign Quartan Malaria
- *Plasmodium ovale*: Benign Tertian Malaria.

Malaria Parasite

History and Distribution

Malaria has been known from antiquity. Seasonal intermittent fevers with chills and shivering, recorded in the religious and medical texts of ancient Indian, Chinese, and Assyrian civilizations, are believed to have been malaria (Fig. 6.1).

- The name malaria (*mal*: bad, *aria*: air) was given in the 18th century in Italy, as it was believed to be caused by foul emanations from marshy soil.
- The specific agent of malaria was discovered in RBCs of a patient in 1880 by **Alphonse Laveran**, a French army surgeon in Algeria.
- In 1886, Golgi in Italy described the asexual development of the parasite in RBCs (*erythrocytic schizogony*), which therefore came to be called as **Golgi cycle**.
- Romanowsky in Russia in 1891, developed a method of staining malarial parasites in blood films.
- Three different species of malaria parasite infecting man, *P. vivax*, *P. malariae*, and *P. falciparum* were described in Italy between 1886 and 1890. The fourth species, *P. ovale* was identified only in 1922.
- The mode of transmission of the disease was established in 1897, when **Ronald Ross** in Secunderabad, India identified the developing stages of malaria parasites in mosquitoes. This led to various measures for the control and possible eradication of malaria by mosquito control. Both Ross (1902) and Laveran (1907) won the Nobel prize for their discoveries in malaria.
- Malaria affects mainly poor, underserved, and marginalized population in rural remote areas as well as in Urban areas. An epidemic can develop when there

are changes in environmental, economic, and social conditions such as migrations and heavy rains following draughts.

- The relative prevalence of the 4 species of malaria parasites varies in different geographical regions (Fig. 6.1).
 - *P. vivax* is the most widely distributed, being most common in Asia, North Africa, and Central and South America.
 - *P. falciparum*, the predominant species in Africa, Papua New Guinea, and Haiti, is rapidly spreading in South-east Asia and India.
 - *P. malariae* is present in most places but is rare, except in Africa.
 - *P. ovale* is virtually confined to West Africa where it ranks second after *P. falciparum* (Fig. 6.1).
- Malaria may occur in endemic as well as epidemic patterns. It is described as **endemic**, when it occurs constantly in an area over a period of several successive years and as **epidemic**, when periodic or occasional sharp rises occur in its incidence. The World Health Organization (WHO) has recommended the classification of endemicity depending on the spleen or parasite rate in a statistically significant sample in the populations of children (2–9 years) and adults. According to this:
 - **Hypoendemic** (transmission is low): Spleen or parasite rate <10%
 - **Mesoendemic** (transmission is moderate): Spleen or parasite rate 11–50%
 - **Hyperendemic** (transmission is intense but seasonal): Spleen or parasite rate 51–75%
 - **Holoendemic** (transmission of high intensity): Spleen or parasite rate >75%
- In India, malaria continues to be a major public health threat. In India, about **27% population** lives in high transmission (>1 case/1,000 population) and about 58% in low transmission (0–1 case)/1,000 population) area. Although total malaria cases has declined as compared to previous years, **the proportion of *P. falciparum* malaria** has increased.

Vectors

Human malaria is transmitted by over 60 species of female ***Anopheles* mosquito**.

- The male mosquito feeds exclusively on fruits and juices, but the female needs at least 2 blood meals, before the first batch of eggs can be laid.
- Out of 45 species of *Anopheles* mosquito in India, only few are regarded as the vectors of malaria. These are *An culicifacies*, *An fluvatilis*, *An stephansi*, *An minimus*, *An philippinensis*, *An sondaicus*, etc.

Life Cycle

Malaria parasite passes its life cycle in 2 hosts.

Definitive host: Female *Anopheles* mosquito.

Intermediate host: Man.

- The life cycle of malarial parasite comprises of 2 stages—**an asexual phase** occurring in humans, which act as the intermediate host and **a sexual phase** occurring in mosquito, which serves as a definitive host for the parasite (Fig. 6.2).

Asexual phase:

- In this stage, the malaria parasite multiplies by division or splitting a process designated to as *Schizogony* (from *schizo*: to split, and *gone*: generation).
- Because this asexual phase occurs in man, it is also called the *vertebrate, intrinsic, or endogenous phase*.
- In humans, schizogony occurs in 2 locations—in the red blood cell (**erythrocytic schizogony**) and in the liver cells (**exoerythrocytic schizogony** or the tissue phase).

- Because schizogony in the liver is an essential step before the parasites can invade erythrocytes, it is called **pre-erythrocytic schizogony**.
- The products of schizogony, whether erythrocytic or exoerythrocytic, are called **merozoites** (*meros*: a part, *zoon*: animal).

Sexual phase:

- The sexual phase takes place in the female *Anopheles* mosquito, even though the sexual forms of the parasite (**gametocytes**) originate in human red blood cells.
- Maturation and fertilization take place in the mosquito, giving rise to a large number of sporozoites (from *sporos*: seed). Hence this phase of sexual multiplication is called **sporogony**. It is also called the invertebrate, extrinsic, or exogenous phase.
- There is, thus an alternation of generations in the life cycle of malaria parasites—asexual and sexual generations, alternatively.

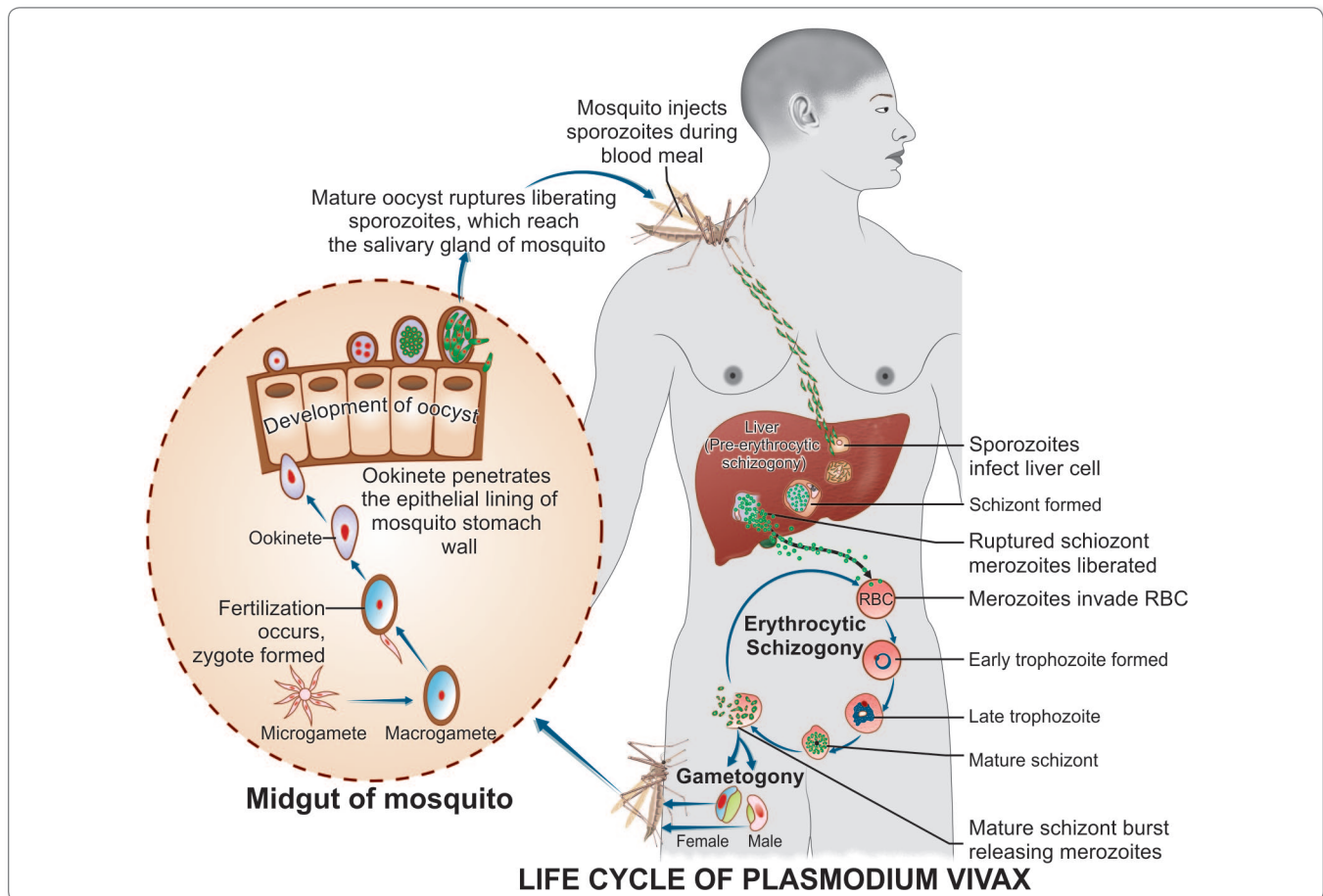


Fig. 6.2: Life cycle of the *Plasmodium vivax*

- There also occurs an alternation of hosts, as the asexual phase takes place in humans followed by the sexual phase in the mosquito. Therefore, the complete life cycle of the malaria parasite comprises an alternation of generations with an alternation of hosts.
- The interval between the entry of the sporozoites into the body and the first appearance of the parasites in blood is called the **prepatent period**.
- The duration of the pre-erythrocytic phase in the liver, the size of the mature schizont, and the number of merozoites produced vary with the species of the parasite (Table 6.2).

Human Cycle (Schizogony)

Human infection comes through the bite of the infective female *Anopheles* mosquito (Fig. 6.2).

- The sporozoites, which are infective forms of the parasite are present in the salivary gland of the mosquito.
- They are injected into blood capillaries when the mosquito feeds on blood after piercing the skin.
- Usually, 10–15 sporozoites are injected at a time, but occasionally, many hundreds may be introduced.
- The sporozoites pass into the blood stream, where many are destroyed by the phagocytes, but some reach the liver and enter the parenchymal cells (hepatocytes).

Pre-erythrocytic (Tissue) Stage or Exoerythrocytic Stage

Within an hour of being injected into the body by the mosquito, the sporozoites reach the liver and enter the hepatocytes to initiate the stage of **pre-erythrocytic schizogony or merogony**.

- The sporozoites, which are elongated spindle-shaped bodies, become rounded inside the liver cells.
- They enlarge in size and undergo repeated nuclear division to form several daughter nuclei; each of which is surrounded by cytoplasm.
- This stage of the parasite is called the **pre-erythrocytic or exoerythrocytic schizont or meront**.
- The hepatocyte is distended by the enlarging schizont and the liver cell nucleus is pushed to the periphery.
- Mature liver stage schizonts are spherical (45–60 μm), multinucleate, and contain 2000–50,000 **uninucleate merozoites**.
- Unlike erythrocytic schizogony, there is no pigment in liver schizonts. These normally rupture in 6–15 days and release thousands of merozoites into the blood stream.
- **The merozoites infect the erythrocytes by a process of invagination.**

- **Latent stage:** In *P. vivax* and *P. ovale*, two kinds of sporozoites are seen, some of which multiply inside hepatic cells to form schizonts and others persist and remain dormant (resting phase). The resting forms are called **hypnozoites** (*hypnos: sleep*). From time to time, some are activated to become schizonts and release merozoites, which go on infecting RBCs producing **clinical relapse**.
- In *P. falciparum* and *P. malariae*, initial tissue phase disappears completely, and no hypnozoites are found. However, small number of erythrocytic parasites persist in the blood stream and in due course of time, they multiply to reach significant numbers resulting in clinical disease (**short-term relapse or recrudescence**).

Erythrocytic Stage

The merozoites released by pre-erythrocytic schizonts invade the red blood cells.

- The receptor for merozoites is **glycophorin**, which is a major glycoprotein on the red cells. The differences in the glycophorins of red cells of different species may account for the species specificity of malaria parasites.
- Merozoites are **pear-shaped** bodies, about 1.5 μm in length, possessing an **apical complex (rhoptry)**. They attach to the erythrocytes by their apex and then the merozoites lie within an intraerythrocytic parasitophorous vacuole formed by red cell membrane by a process of invagination.
- In the erythrocyte, the merozoite loses its internal organelles and appears as a rounded body having a vacuole in the center with the cytoplasm pushed to the periphery and the nucleus at one pole. These young parasites are, therefore called the **ring forms** or **young trophozoites**.

Table 6.2: Features of Pre-erythrocytic Schizogony in Human Malaria Parasites

	<i>P. vivax</i>	<i>P. falciparum</i>	<i>P. malariae</i>	<i>P. ovale</i>
Pre-erythrocytic stage (days)	8	6	15	9
Diameter of pre-erythrocytic schizont (μm)	45	60	55	60
No. of merozoites in pre-erythrocytic schizont	10,000	30,000	15,000	15,000

- The parasite feeds on the hemoglobin of the erythrocyte. It does not metabolize hemoglobin completely and therefore, leaves behind a hematin-globin pigment called the **malaria pigment** or **haemozoin pigment**, as residue.

The appearance of malaria pigments varies in different species as follows:

- *P. vivax*: Numerous fine golden-brown dust-like particles
- *P. falciparum*: Few 1–3 solid blocks of black pigment
- *P. malariae*: Numerous coarse dark brown particles
- *P. ovale*: Numerous blackish brown particles.

- The malaria pigment released when the parasitized cells rupture is taken up by reticuloendothelial cells. Such pigment-laden cells in the internal organs provide histological evidence of previous malaria infection.
- As the ring form develops, it enlarges in size becoming irregular in shape and shows **amoeboid motility**. This is called the **amoeboid form** or late **trophozoite form**.
- When the amoeboid form reaches a certain stage of development, its nucleus starts dividing by mitosis followed by a division of cytoplasm to become mature **schizonts or meronts**.
- A mature schizont contains 8–32 merozoites and hemozoin. The mature schizont bursts releasing the merozoites into the circulation.
- The merozoites invade fresh erythrocytes within which they go through the same process of development. This cycle of **erythrocytic Schizogony** or **merogony** is repeated sequentially, leading to progressive increase in the parasitemia, till it is arrested by the development of host immune response.
- The rupture of the mature schizont releases large quantities of pyrogens. This is responsible for the febrile paroxysms characterizing malaria.
- The interval between the entry of sporozoites into the host and the earliest manifestation of clinical illness is the **incubation period**. This is different from **prepatent period**, which is the time taken from entry of the sporozoites to the first appearance of malaria parasite in peripheral blood.
- In *P. falciparum*, erythrocytic schizogony always takes place inside the capillaries and vascular beds of internal organs. Therefore, in *P. falciparum* infections, schizonts, and merozoites are usually not seen in the peripheral blood.
- The erythrocytic stages of all the 4 species of *Plasmodium* is shown in Figure 6.3.

Gametogony

After a few erythrocytic cycles, some of the merozoites that infect RBC's do not proceed to become trophozoites or schizonts but instead, develop into sexually differentiated forms, the **gametocytes**.

- They grow in size till they almost fill the RBC, but the nucleus remains undivided.
- Development of gametocytes generally takes place within the internal organs and only the mature forms appear in circulation.
- The mature gametocytes are round in shape, except in *P. falciparum*, in which they are **crenate-shaped**.
- In all species, the female gametocyte is larger (**macrogametocyte**) and has cytoplasm staining dark blue with a compact nucleus staining deep red. In the smaller male gametocyte (**microgametocyte**), the cytoplasm stains pale blue or pink and the nucleus is larger, pale stained and diffuse. Pigment granules are prominent.
- Female gametocytes are generally more numerous than the male.
- Gametocytes appear in circulation 4–5 days after the first appearance of asexual form in case of *P. vivax* and 10–12 days in *P. falciparum*.
- A person with gametocytes in blood is a carrier or reservoir.
- The gametocytes do not cause any clinical illness in the host, but are essential for transmission of the infection.
- A gametocyte concentration of 12 or more per cumm of blood in the human host is necessary for mosquitoes to become infected.

The Mosquito Cycle (Sporogony)

When a female *Anopheles* mosquito ingests parasitized erythrocytes along with its blood meal, the asexual forms of malaria parasite are digested, but the gametocytes are set free in the midgut (stomach) of mosquito and undergo further development.

- The nuclear material and cytoplasm of the male gametocytes divides to produce 8 microgametes with long, actively motile, whip-like filaments. (**exflagellating male gametocytes**) (Fig. 6.4).
- At 25°C, the exflagellation is complete in 15 minutes for *P. vivax* and *P. ovale* and 15–30 minutes for *P. falciparum*.
- The female gametocyte does not divide but undergoes a process of maturation to become the female gamete or macrogamete. It is fertilized by one of the microgametes to produce the **zygote** (Fig. 6.4).
- Fertilization occurs in half to two hours after the blood meal. The zygote, which is initially a motionless

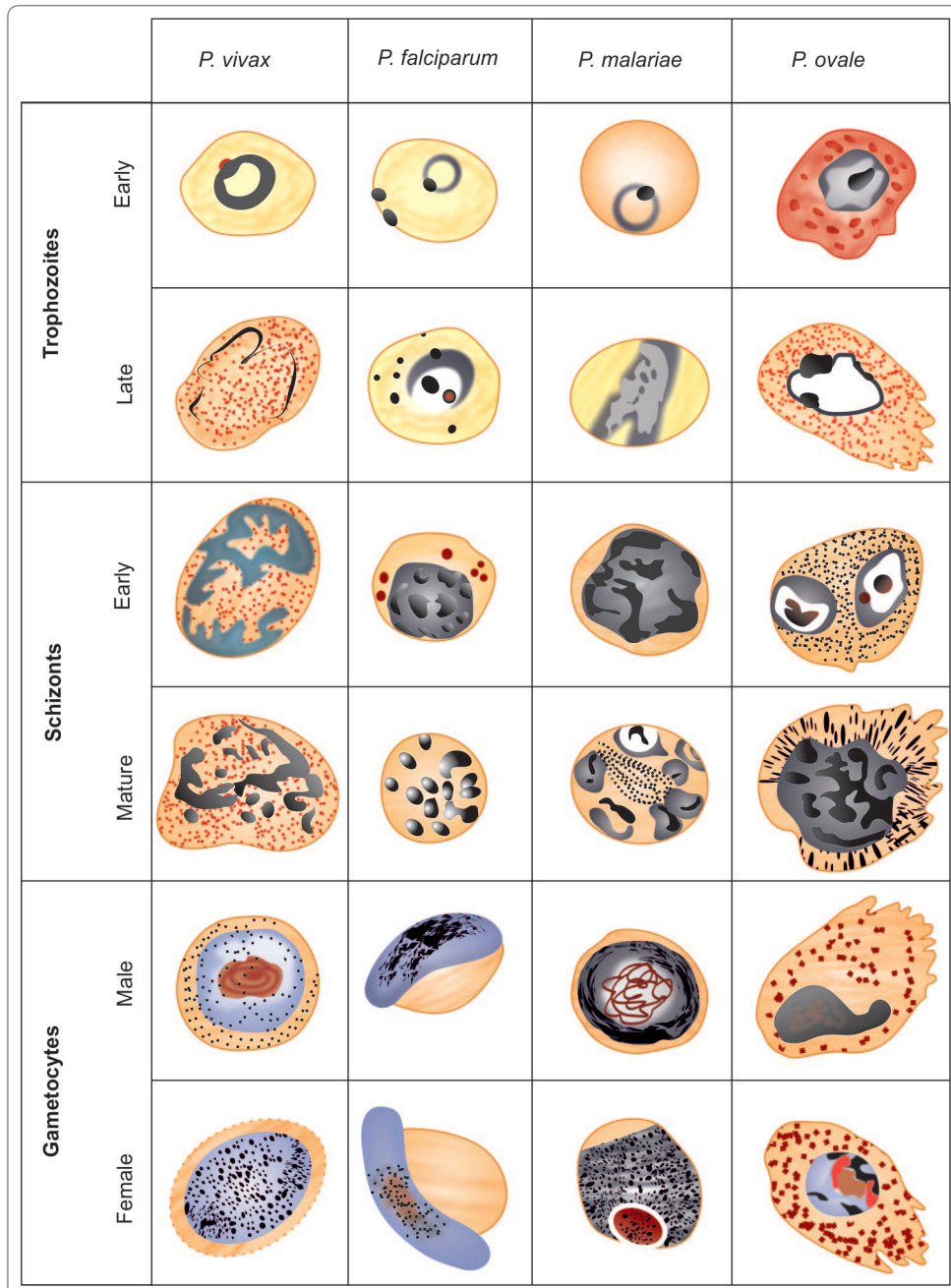


Fig. 6.3: Malaria parasites—Erythrocytic stages of the four species (Giemsa stain. Magn $\times 2000$)

round body, gradually elongates and within 18–24 hours, becomes a **vermicular motile** form with an apical complex anteriorly. This is called the **ookinete** ('travelling vermicle').

- It penetrates the epithelial lining of the mosquito stomach wall and comes to lie just beneath the basement membrane.
- It becomes rounded into a sphere with an elastic membrane. This stage is called the **ooocyst**, which is yet another multiplicative phase, within which numerous **sporozoites** are formed.
- The mature oocyst, which may be about 500 μm in size, bulges into body cavity of mosquito and when it ruptures, the sporozoites enter into the hemocele or

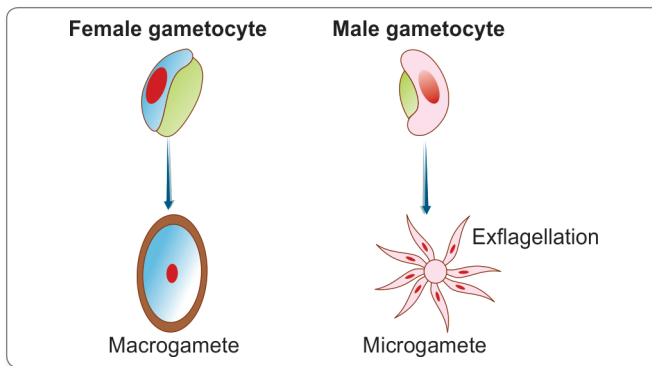


Fig. 6.4: Schematic diagram showing formation of microgamete and macrogamete

body cavity, from where some find their way to the salivary glands.

- The mosquito is now infective and when it feeds on humans, the sporozoites are injected into skin capillaries to initiate human infection.
- The time taken for completion of sporogony in the mosquito is about **1–4 weeks (extrinsic incubation period)**, depending on the environmental temperature and the species.

Types of Malarial Parasites

Plasmodium Vivax

P. vivax has the widest geographical distribution, extending through the tropics, subtropics and temperate regions. It is believed to account for 80% of all malaria infections. It is the most common species of malaria parasite in Asia and America, but is much less common in Africa. It causes **benign tertian malaria** with frequent relapses.

- The sporozoites of *P. vivax* are narrow and slightly curved. On entering the liver cells, the sporozoites initiate 2 types of infection. Some develop promptly into **exoerythrocytic schizonts**, while others persist in the dormant state for varying periods as **hypnozoites**. There may be 2 distinct types of sporozoites, the **tachysporozoites** (*tachy*: fast), which develops into the primary exoerythrocytic schizont and the **bradysporozoite** (*brady*: slow) which becomes the hypnozoite.
- The pre-erythrocytic schizogony lasts for 8 days and the average number of merozoites per tissue schizont is 10,000.
- Merozoites of *P. vivax* preferentially infect reticulocytes and young erythrocytes.
- All stages of erythrocytic schizogony can be seen in peripheral smears (Fig. 6.5).

- The degree of parasitization is not generally heavy, each infected red cell usually having only one trophozoite and not more than **2–5% of the red cells** being affected. Reticulocytes are preferentially infected.
- The trophozoite is actively motile, as indicated by its name *vivax*. The ring form is well-defined, with a prominent central vacuole. One side of the ring is thicker and the other side thin. Nucleus is situated on the thin side of the ring. The ring is about 2.5–3 μm in diameter, about a third of the size of an erythrocyte. The cytoplasm is blue and the nucleus red in stained films. The ring develops rapidly to the amoeboid form and accumulates malarial pigment (Figs 6.6 and 6.7).
- The infected erythrocytes are enlarged and show red granules known as **Schuffner's dots** on the surface. They become irregular in shape, lose their red color, and present a washed out appearance. A few of the parasitized erythrocytes retreat into the blood spaces of the internal organs.
- The schizont appears in about 36–40 hours. It occupies virtually the whole of the enlarged red cell. The schizont matures in the next 6–8 hours, with the development of merozoites, each with its central nucleus and surrounding cytoplasm. The pigment granules agglomerate into a few dark brown collections at the center, and with the merozoites around it, this stage presents a **rosette** appearance. There are about 12–24 (usually 16) merozoites per schizont.
- Erythrocytic schizogony takes approximately 48 hours. The red cell, which now measures about 10 μm in diameter is heavily stippled and often distorted. It bursts to liberate the merozoites and pigment. The pigment is phagocytosed by reticuloendothelial cells.
- The merozoites measure about 1.5 μm and have no pigment.
- Gametocytes appear early, usually within 4 days after the trophozoites first appear. Both male and female gametocytes are large, nearly filling the enlarged red cell. The macrogametocyte has dense cytoplasm staining deep blue and a small compact nucleus. The microgametocyte has pale-staining cytoplasm and a large diffuse nucleus. Pigment granules are prominent in the gametocytes.

Plasmodium Falciparum

The name **falciparum** comes from the characteristic sickle shape of the gametocytes of this species (*falx*: sickle, *parere*: to bring forth). This is the highly pathogenic of all the plasmodia and hence, the name malignant tertian or pernicious malaria for its infection.

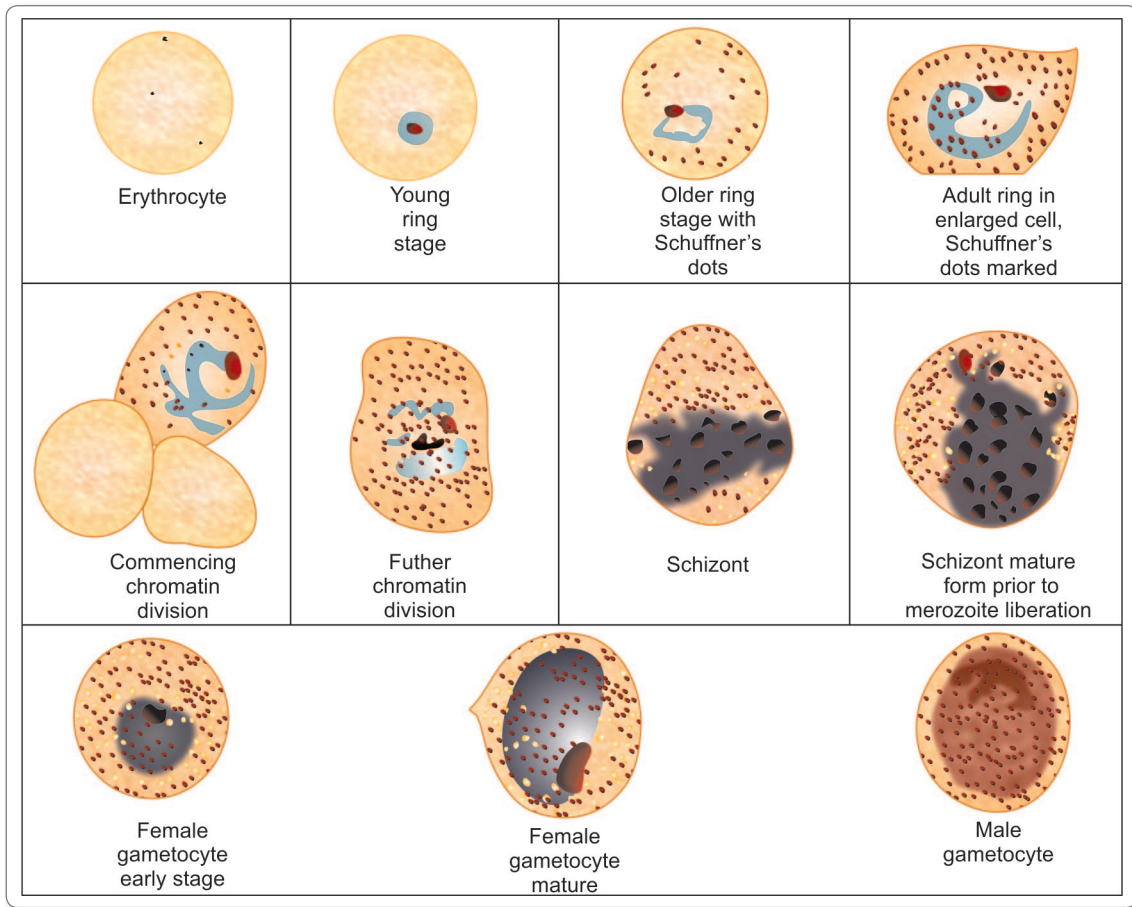


Fig. 6.5: *Plasmodium vivax* (Giemsa stain, magn x 2000)

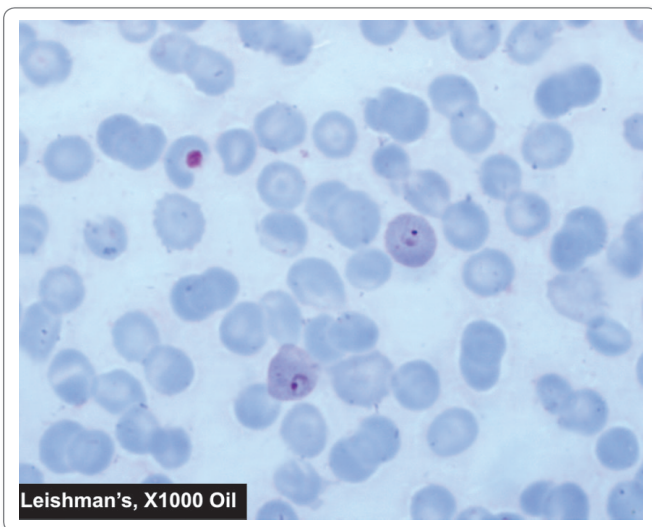


Fig. 6.6: Malarial parasite in blood film – Ring stage of *P. vivax*.
Courtesy: Harsh Mohan, Textbook of Pathology, 6th ed. New Delhi: Jaypee Brothers, 2013(R), p. 189

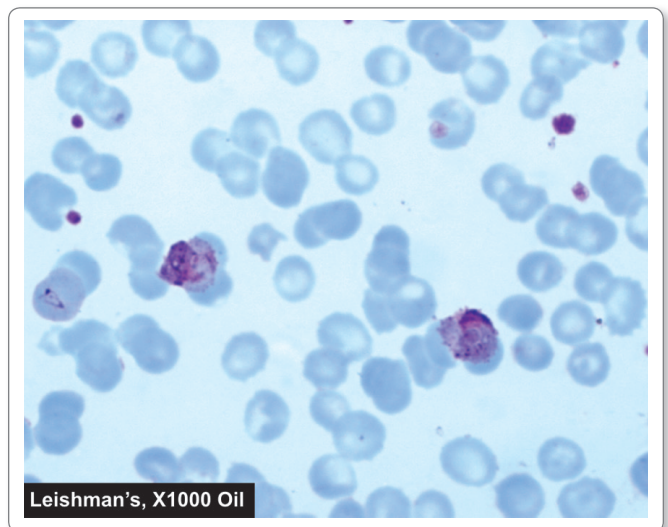


Fig. 6.7: Malarial parasite in blood film – Amoeboid form of *P. vivax*.
Courtesy: Harsh Mohan, Textbook of Pathology, 6th ed. New Delhi: Jaypee Brothers, 2013(R), p. 189

- The disease has a high rate of complications and unless treated, is often fatal. The species is responsible for almost all deaths caused by malaria.
- **Schizogony:** The sporozoites are sickle-shaped. The tissue phase consists of only a single cycle of pre-erythrocytic schizogony. **No hypnozoites occur.** The mature liver schizont releases about 30,000 merozoites.
- They attack both young and mature erythrocytes and so the population of cells affected is very large. Infected erythrocytes present a brassy coloration.
- **Ring form:** The early ring form in the erythrocyte is very **delicate** and tiny, measuring only a **sixth(1/6) of the red cell diameter**. Rings are often seen attached along the margin of the red cell, the so-called **form appliqué** or **accolé**. Binucleate rings (double chromatin) are common resembling **stereo headphones** in appearance. Several rings may be seen within a single erythrocyte. In course of time, the rings become larger, about a third of the size of the red cell and may have 1 or 2 grains of pigment in its cytoplasm (Figs 6.8 and 6.9).
- The subsequent stages of the asexual cycle—late trophozoite, early and mature schizonts—are not ordinarily seen in peripheral blood, except in very severe or pernicious malaria. The presence of *P. falciparum* schizonts in peripheral smears indicates a grave prognosis.
- The mature schizont is smaller than in any other species and has 8–24 (usually 16) merozoites. The erythrocytic schizogony takes about 48 hours or less, so that the periodicity of febrile paroxysms is 36–48 hours.
- Very high intensity of parasitization is seen in falciparum malaria. In very severe infections, the rate of parasitized cells may even be up to **50%**.
- The infected erythrocytes are of normal size. They show a few (6–12) coarse brick-red dots which are called **Maurer's clefts**. Some red cells show basophilic stippling.
- **Gametogony:** It begins after several generations of schizogony. Gametocytes are seen in circulation about 10 days after the ring stage first appears. The early gametocytes seldom appear in peripheral circulation. The mature gametocytes, which are seen in peripheral smears are curved oblong structures, described as **crenate, sickle, sausage, or banana-shaped**. They are usually referred to as **crenates** (Fig. 6.10).
- The male gametocytes are broad and sausage-shaped or kidney-shaped, with blunt rounded ends as compared to the female gametocytes, which are thinner and more typically **crenate**, with sharply rounded or pointed ends. The mature gametocyte is longer than the diameter of the red cell and so produces gross distortion and sometimes even apparent disappearance of the infected red cell. The red cell is often seen as a rim on the concave side of the gametocyte. The cytoplasm in the female gametocyte is deep blue, while in the male it is pale blue or pink. The nucleus is deep red and compact in the female, with the pigment granules closely aggregated around it, while in the male, it is pink, large and diffuse, with the pigment granules scattered in the cytoplasm.
- Falciparum crenates can survive in circulation for up to 60 days, much longer than in other species. Gametocytes are most numerous in the blood of young children, 9 months to 2 years old. They, therefore serve as the most effective source of infection to mosquitoes.

Pathogenesis of Malignant Malaria

The trophozoites usually disappear from peripheral circulation after about 24 hours. By then, membrane protuberances appear in erythrocyte's surface, 12–15 hours after cell invasion. These knobs extrude a high molecular weight, antigenically variant strain-specific erythrocyte membrane adhesive protein, Pf MP1, that mediates attachment to receptors on venular capillary endothelium, an event termed '**cytoadherence**'. Several vascular receptors have been identified of which intracellular adhesion molecule (ICAM-1) is probably most important in the brain, chondroitin sulfate B in the placenta, and CD36 in most other organs.

The infected erythrocytes stick inside and eventually block capillaries and venules. At the same stage, these *P. falciparum* infected RBCs adhere to uninfected RBCs to form rosettes. The process of cytoadherence, resetting, and agglutination are central to pathogenesis of falciparum malaria. They result in sequestration of RBCs containing mature form of the parasite in vital organs like brain, kidney, heart, lungs, spleen, intestine, bone marrow, and placenta, where they interfere with microcirculatory flow and metabolism and are responsible for many of the serious complications of falciparum malaria, such as cerebral malaria.

Plasmodium Malariae

This was the species of malaria parasite first discovered by Laveran in 1880 and the name **malariae** is the one given by him. It causes quartan malaria, in which febrile paroxysms occur **every fourth day**, with **72 hours'** interval between the bouts.

- The disease is generally mild, but is notorious for its long persistence in circulation in undetectable levels, for 50 years or more. **Recrudescence** may be provoked by splenectomy or immunosuppression.
- The development of the parasite, in man and mosquito is much slower than with other species. Chimpanzees

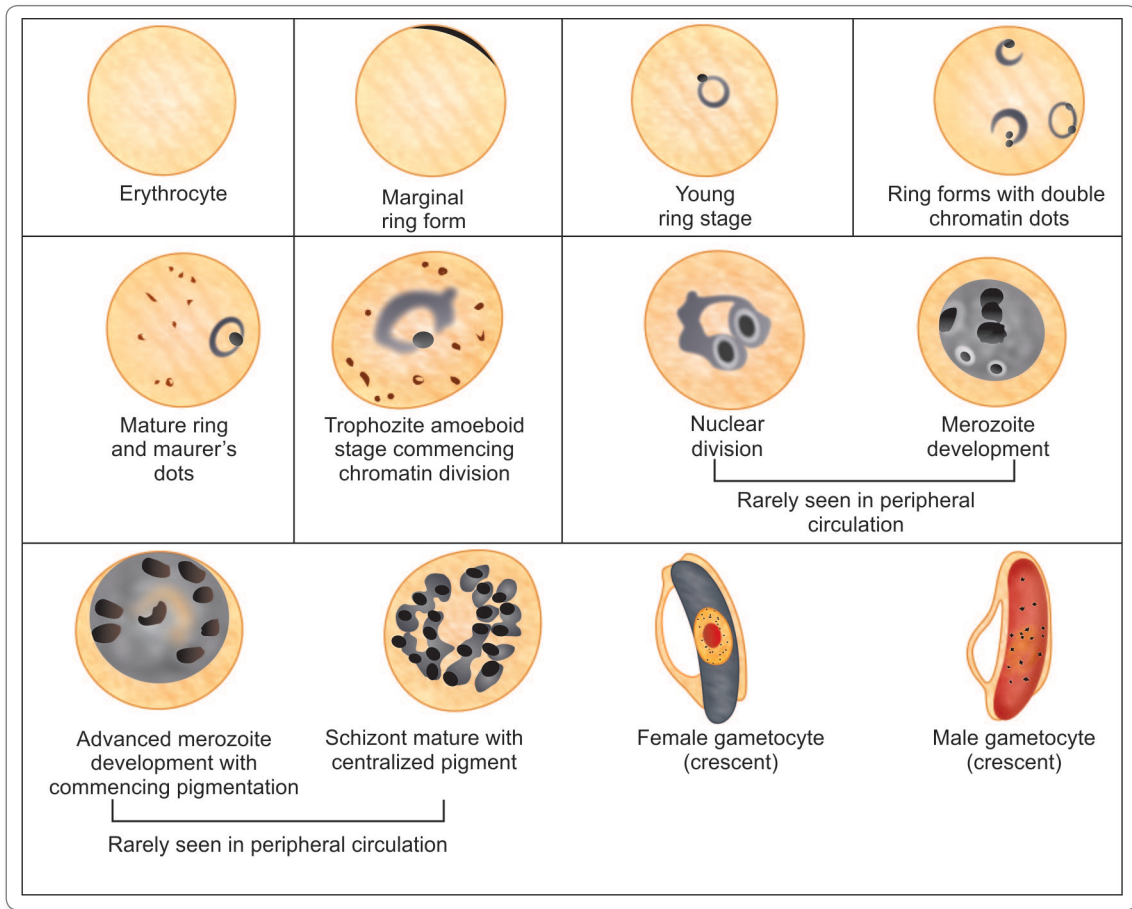


Fig. 6.8: *Plasmodium falciparum* (Giemsa stain, magn x 2000)

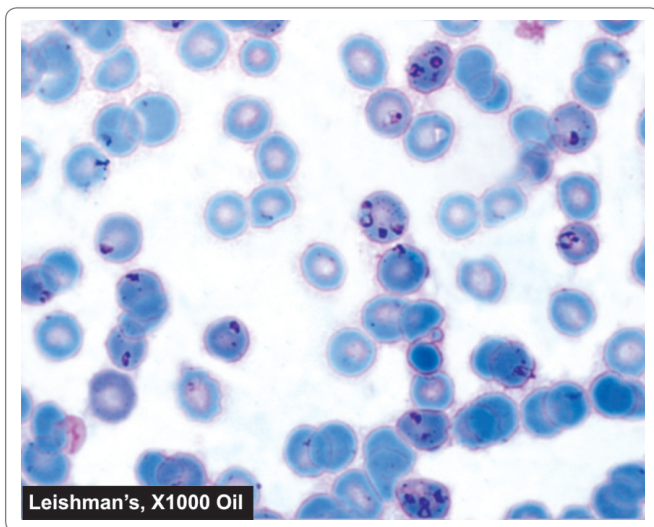


Fig. 6.9: Malarial parasite in blood film – Ring stage of *P. falciparum*.
 Courtesy: Harsh Mohan, Textbook of Pathology, 6th ed. New Delhi: Jaypee Brothers, 2013(R), p. 189

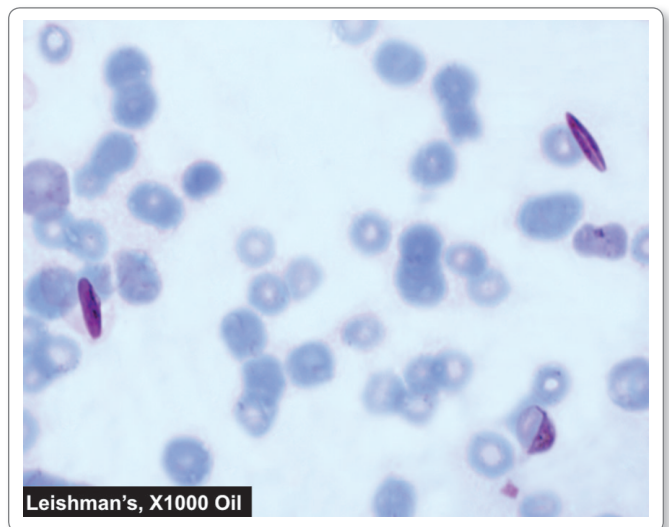


Fig. 6.10: Malarial parasite in blood film – Gametocytes of *P. falciparum*.
 Courtesy: Harsh Mohan, Textbook of Pathology, 6th ed. New Delhi: Jaypee Brothers, 2013(R), p. 189

may be naturally infected with *P. malariae* and may constitute a natural reservoir for quartan malaria.

- *P. malariae* occurs in tropical Africa, Sri Lanka, Burma, and parts of India, but its distribution is patchy.
- The sporozoites are relatively **thick**. Pre-erythrocytic schizogony takes about **15 days**, much longer than in other species. Each schizont releases about 15,000 merozoites. **Hypnozoites do not occur. The long latency** of the infection is believed to be due to persistence of small numbers of erythrocytic forms in some internal organs.
- *P. malariae* preferentially infects **older erythrocytes** and the degree of parasitization is **low**.
- The ring forms resembles those of *P. vivax*, although thicker and more intensely-stained. The old trophozoites are sometimes seen stretched across the erythrocyte as a **broad band**. These **band forms** are a unique feature of *P. malariae*. Numerous large pigment granules are seen (Fig. 6.11).
- The schizonts appear in about 50 hours and mature during the next 18 hours. The mature schizont has an average of 8 merozoites, which usually present a **rosette** appearance.
- The infected erythrocytes may be of the normal size or slightly smaller. Fine stippling, called **Ziemann's stippling**, may be seen with special stains. The degree of parasitization is lowest in *P. malariae*.
- Erythrocytic schizogony takes **72 hours**.
- The gametocytes develop in the internal organs and appear in the peripheral circulation when fully grown. Gametocytes occupy nearly the entire red cell. The male has pale blue cytoplasm with a large diffuse nucleus,

while the female has deep blue cytoplasm and a small compact nucleus.

Plasmodium Ovale

This parasite produces a tertian fever resembling vivax malaria, but with milder symptoms, prolonged latency and fewer relapses.

- It is the **rarest of all plasmodia** infecting humans and is seen mostly in tropical Africa, particularly along the West Coast.
- The pre-erythrocytic stage extends for 9 days. Hepatocytes containing schizonts usually have enlarged nuclei. The mature liver schizont releases about 15,000 merozoites. **Hypnozoites are present**.
- The trophozoites resemble those in vivax malaria, but are usually more compact, with less amoeboid appearance. **Schuffner's dots** appear earlier and are more abundant and prominent than in vivax infection (Fig. 6.12).
- The infected erythrocytes are slightly enlarged. In thin films, many of them present an oval shape with fimbriated margins. This oval appearance of the infected erythrocyte is the reason for the name **ovale** given to this species.
- The schizonts resemble those of *P. malariae*, except that the pigment is **darker** and the erythrocyte is usually **oval**, with prominent Schuffner's dots.

Mixed Infections

In endemic areas it is not uncommon to find mixed infections with **2 or more** species of malaria parasites in the same individual.

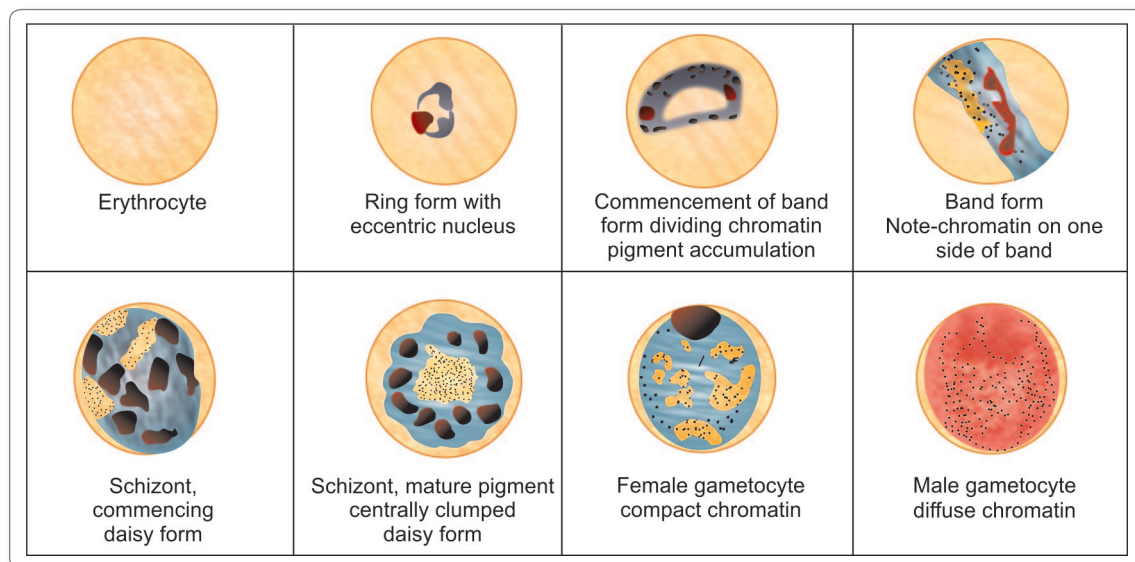


Fig. 6.11: *Plasmodium malariae* stages of erythrocytic schizogony (Giemsa stain, magn x 2000)

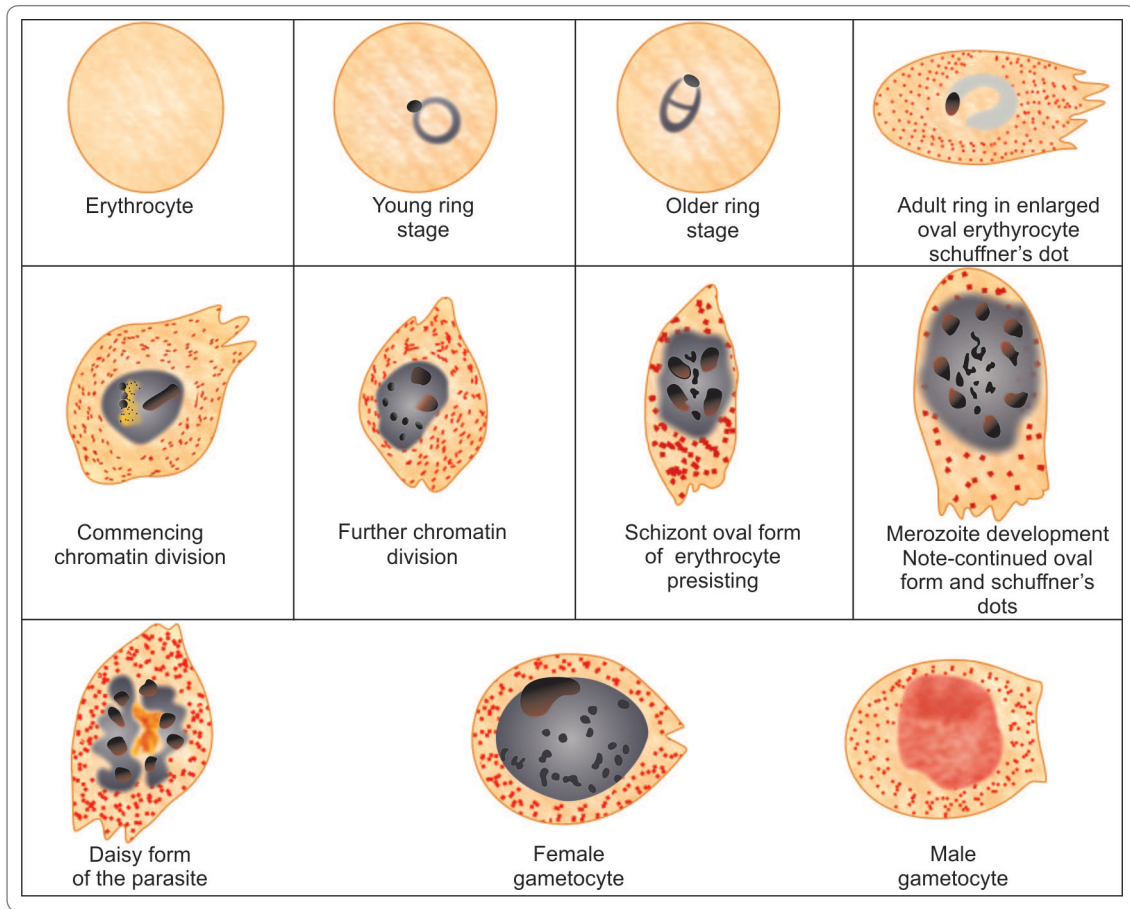


Fig. 6.12: *Plasmodium ovale* stages of erythrocytic schizogony (Giemsa stain, magn x 2000)

- Mixed infection with *P. vivax* and *P. falciparum* is the most common combination with a tendency for one or the other to predominate
 - The clinical picture may be **atypical** with bouts of fever occurring **daily**
 - Diagnosis may be made by demonstrating the characteristic parasitic forms in thin blood smears.
- The characteristics of the 4 species of plasmodia infecting man are listed in Table 6.3.

Pathogenesis

All clinical manifestation in malaria are due to products of erythrocytic schizogony and the host's reaction to them.

- The disease process in malaria occurs due to the local or systemic response of the host to parasite antigens and tissue hypoxia caused by reduced oxygen delivery because of obstruction of blood flow by the parasitized erythrocytes.
- **Liver** is enlarged and congested. Kupffer cells are increased and filled with parasites. Hemozoin pigments are also found in the parenchymal cells (Fig. 6.13).

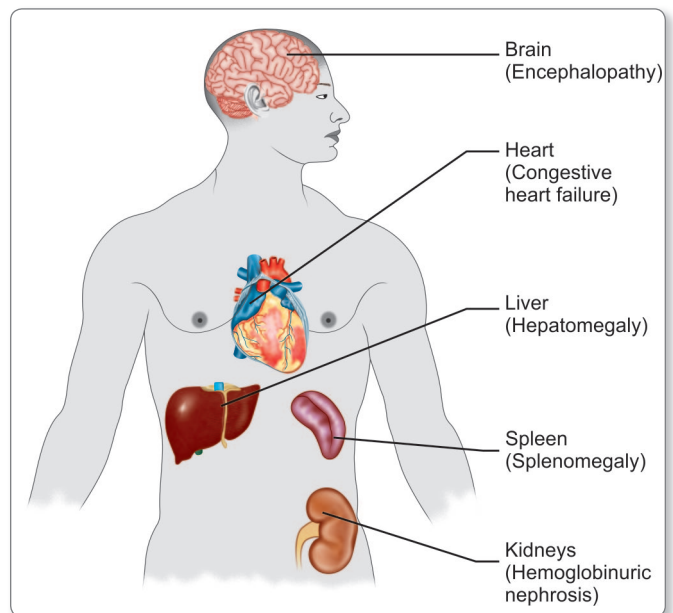


Fig. 6.13: Major pathological changes in organs in malaria

Table 6.3: Comparison of the Characteristics of Plasmodia Causing Human Malaria

	<i>P. vivax</i>	<i>P. falciparum</i>	<i>P. malariae</i>	<i>P. ovale</i>
Hypnozoites	Yes	No	No	Yes
Erythrocyte preference	Reticulocytes	Young erythrocytes, but can infect all stages	Old erythrocytes	Reticulocytes
Stages found in peripheral blood	Rings, trophozoites, schizonts, gametocytes	Only rings and gametocytes	As in vivax	As in vivax
Ring stage	Large, 2.5 μm , usually single, prominent chromatin	Delicate, small, 1.5 μm , double chromatin, and multiple rings common, Accole forms found.	Similar to vivax, but thicker	Similar to vivax, more compact
Late trophozoite	Large irregular, actively amoeboid, prominent vacuole	Compact, seldom seen in blood smear	Band form characteristic	Compact, coarse pigment
Schizont	Large filling red cell	Small, compact, seldom seen in blood smear	Medium size	Medium size
Number of merozoites	12–24 in irregular grape-like cluster	8–24 grape-like cluster	6–12 in daisy-head or rosette pattern	6–12 irregularly arranged
Microgametocyte	Spherical, compact, pale blue cytoplasm, diffuse nucleus	Sausage or banana-shaped pale blue or pink cytoplasm, large diffuse nucleus	As in vivax	As in vivax
Macrogametocyte	Large, spherical, deep blue cytoplasm, compact nucleus	Crescentic, deep blue cytoplasm, compact nucleus	As in vivax	As in vivax
Infected erythrocyte	Enlarged, pale, with Schuffner's dots	Normal size, Maurer's clefts, sometimes basophilic stippling	Normal, occasionally Ziemann's stippling	Enlarged, oval fimbriated, prominent Schuffner's dots
Duration of schizogony (days)	2	2	3	2
Prepatent period (days)	8	5	13	9
Average incubation period (days)	14	12	30	14
Appearance of gametocyte after parasite patency (days)	4–5	10–12	11–14	5–6
Duration of sporogony in mosquito (25°C) (days)	9–10	10–12	25–28	14–16
Average duration of untreated infection (years)	4	2	40	4

Parenchymal cells show fatty degeneration, atrophy, and centrilobular necrosis.

- **Spleen** is soft, moderately enlarged, and congested in acute infection. In chronic cases, spleen is hard with a thick capsule and **slate grey** or **dark brown** or even **black** in color due to dilated sinusoids, pigment accumulation, and fibrosis (Fig. 6.13).
- **Kidneys** are enlarged and congested. Glomeruli frequently contain malarial pigments and tubules may contain hemoglobin casts (Fig. 6.13).

- The **brain** in *P. falciparum* infection is congested. Capillaries of the brain are plugged with parasitized RBCs. The cut surface of the brain shows slate grey cortex with multiple punctiform hemorrhage in subcortical white matter.

- **Anemia** is caused by destruction of large number of red cells by complement-mediated and autoimmune hemolysis. Spleen also plays an active role by destroying a large number of unparasitized erythrocytes. There is also decreased erythropoiesis in bone marrow due to

tumor necrosis factor (TNF) toxicity and failure of the host to recycle the iron bound in hemozoin pigments.

- **Cytokines** such as TNF, interleukin (IL)-1, and interferon (IFN)-gamma play a pivotal role in the pathogenesis of end organ disease of malaria.

Causes of anemia in malaria

- Destruction of large number of RBCs by complement mediated and autoimmune hemolysis
- Suppression of erythropoiesis in the bone marrow
- Increased clearance of both parasitized and non parasitized RBCs by the spleen.
- Failure of the host to recycle the iron bound in hemozoin pigment
- Antimalarial therapy in G6PD deficient patients.

Clinical Features

Benign Malaria

The typical picture of malaria consists of periodic bouts of **fever** with rigor, followed by **anemia** and **splenomegaly**. Severe headache, nausea, and vomiting are common.

- The febrile paroxysm comprises of 3 successive stages—**cold stage, hot stage, and sweating stage**.
 - In the cold stage, that lasts for 15–60 minutes, the patient experiences intense cold and uncontrollable shivering.
 - This is followed by the hot stage, lasting for 2–6 hours, when the patient feels intensely hot. The temperature mounts to 41°C or higher.
 - Afterwards comes the sweating stage, when the patient is drenched in profuse sweat. The temperature drops rapidly and the patient usually falls into deep sleep, to wake up refreshed.

Incubation period

It is the interval between the infective mosquito bite and the first appearance of clinical symptoms. The duration of incubation period varies with the species of the parasite. The average incubation periods of different species of *Plasmodium* are as follows –

- *P. vivax*—14 (8–31) days
- *P. falciparum*—12 (8–14) days
- *P. ovale*—14 (8–31) days
- *P. malariae*—28 (18–40) days

The incubation period is to be distinguished from the *pre-patent period*, which is the interval between the entry of the parasites into the host and the time when they first become detectable in blood.

- The paroxysm usually begins in the **early afternoon** and lasts for 8–12 hours. The febrile paroxysm synchronises with the erythrocytic schizogony.
- The periodicity is approximately 48 hours in tertian malaria (in *P. vivax*, *P. falciparum*, and *P. ovale*) and 72 hours in quartan malaria (in *P. malariae*).
- Quotidian periodicity, with fever occurring at 24 hour intervals may be due to 2 broods of tertian parasites maturing on successive days or due to mixed infection.
- Regular periodicity is seldom seen in primary attack, but is established usually only after a few days of continuous, remittent, or intermittent fever. True rigor is typically present in vivax malaria and is less common in falciparum infection.
- There can be both hypoglycemia or hyperglycemia in malaria.
- Sometimes, there may be **hyperkalemia** due to red cell lysis and fall in blood pH.
- Infection with *P. vivax* usually follows a chronic course with periodic relapses, whereas *P. ovale* malaria is generally mild. Although *P. malariae* malaria is less severe, but it may lead to renal complications.
- Other features of benign malaria are anemia, splenomegaly, and hepatomegaly.

Malignant Tertian Malaria

The most serious and fatal type of malaria is malignant tertian malaria caused by *P. falciparum*. When not treated promptly and adequately, dangerous complications develop. The term **pernicious malaria** has been applied to a complex of life-threatening complications that sometimes supervene in acute falciparum malaria. These may present in various forms, the most important of which are the cerebral, algid, and septicemic varieties.

- **Cerebral Malaria:** It is the most common cause of death in malignant malaria.
 - Even with treatment, death occurs in 15% of children and 20% of adults who develop cerebral malaria.
 - It is manifested by headache, hyperpyrexia, coma or confusion, and paralysis.
 - This occurs particularly when non-immune persons have remained untreated or inadequately treated for 7–10 days after development of the primary fever.
 - Late stage schizonts of *P. falciparum* secrete a protein on the surface of RBCs to form knob-like deformities. This knob produces specific adhesive proteins, which promote aggregation of infected RBCs to other non-infected RBCs and capillary endothelial cells. These sequestered RBCs cause

capillary plugging of cerebral microvasculature, which results in anoxia, ischemia, and hemorrhage in brain.

- **Blackwater fever:** A syndrome called blackwater fever (malarial hemoglobinuria) is sometimes seen in falciparum malaria, particularly in patients, who have experienced repeated infections and inadequate treatment with quinine.
 - Patients with G6PD deficiency may develop this condition after taking oxidant drugs, even in the absence of malaria.
 - Clinical manifestation include bilious vomiting and prostration, with passage of dark red or blackish urine (**black water**).
 - The pathogenesis is believed to be massive intravascular hemolysis caused by anti-erythrocyte antibodies, leading to massive absorption of hemoglobin by the renal tubules (hemoglobinuric nephrosis) producing black water fever. Complications of black water fever include renal failure, acute liver failure, and circulatory collapse.
- **Algid Malaria:** This syndrome is characterized by peripheral circulatory failure, rapid thready pulse with low blood pressure, and cold clammy skin. There may be severe abdominal pain, vomiting, diarrhea, and profound shock.
- **Septicemic malaria:** It is characterized by high continuous fever with dissemination of the parasite to various organs, leading to multiorgan failure. Death occurs in 80% of the cases.

? Complications of falciparum malaria

- Cerebral Malaria
- Algid Malaria
- Septicemic Malaria
- Blackwater fever
- Pulmonary edema
- Acute renal failure
- Hypoglycemia (<40 mg/dL)
- Severe anemia (Hb <5 g/dL., PCV <15%)
- Hyperpyrexia
- Metabolic acidosis and shock

Merozoite-induced Malaria

Natural malaria is sporozoite-induced, the infection being transmitted by sporozoites introduced through the bite of vector mosquitoes. Injection of merozoites can lead to direct infection of red cells and erythrocytic schizogony with clinical illness. Such merozoite-induced malaria may occur in the following situations:

Table 6.4: Difference Between Mosquito-borne Malaria and Blood Transfusion Malaria

	Mosquito-borne malaria	Blood Transfusion malaria
Mode of transmission	Mosquito bite	Blood or Blood products transfusion
Infective stage	Sporozoite	Trophozoite
Incubation period	Long	Short
Pre-erythrocytic schizogony	Present	Absent
Hypnozoites	May be present	Absent
Severity	Comparitively less	More complications seen
Relapse	May occur	Does not occur
Radical treatment	Required	Not required

- **Transfusion Malaria:** Blood transfusion can accidentally transmit malaria, if the donor is infected with malaria. The parasites may remain viable in blood bank for 1–2 weeks. As this condition is induced by direct infection of red cells by the merozoites, pre-erythrocytic schizogony and hypnozoites are absent. **Relapse does not occur and incubation period is short.**
 - Table 6.4 enumerates the differences between mosquito-borne malaria and blood transfusion malaria.
- **Congenital malaria:** A natural form of merozoite induced malaria, where the parasite is transmitted transplacentally from mother to fetus.
- **Renal transplantation** may lead to malaria if the donor had parasitaemia.
- **Shared syringes** among drug addicts may be responsible.

Tropical Splenomegaly Syndrome

Tropical splenomegaly syndrome (TSS) also known as hyper-reactive malarial splenomegaly (HMS) is a chronic benign condition seen in some adults in endemic areas, mainly tropical Africa, New Guinea, and and Vietnam.

- This results from abnormal immunological response to malaria and is characterized by enormous splenomegaly, high titers of circulating anti-malaria antibodies and absence of malaria parasites in peripheral blood smears.
- Hypergammaglobulinemia (IgM), cryoglobulinemia reduced C3, and presence of rheumatoid factor without arthritis are its other features.
- A normocytic normochromic anemia is present which does not respond to hematinics or antihelmentics.

- Spleen and liver are enlarged, congested, with dilated sinusoids and marked lymphocytic infiltration. Numerous pigment-laden K upffer cells dot the liver. Changes are also seen in bone marrow, kidneys, and adrenals.
- TSS differs from various other types of splenomegalies seen in the tropics in its response to anti-malarial treatment.

Immunity

Immunity in malaria may be classified as **innate immunity** and **acquired immunity**.

Innate Immunity

- It refers to the inherent, non-immune mechanism of host resistance against malarial parasite.
- Innate immunity could be due to:
 - **Duffy negative RBCs:** The invasion of red cells by merozoites requires the presence of specific glycoprotein receptors on the erythrocyte surface. It has been found that persons, who lack the Duffy blood group (Fya and Fyb alleles) antigen, are refractory to infection by *P. vivax*. These genetically determined blood group antigen appears to be the specific receptor for *P. vivax*.
 - **Nature of hemoglobin:** Hemoglobin E provides natural protection against *P. vivax*. *P. falciparum* does not multiply properly in sickled red cells containing HbS. Sickle cell anemia trait is very common in Africa, where falciparum malaria is hyperendemic and offers a survival advantage. HbF present in neonates protects them against all *Plasmodium* species.
 - **G6PD deficiency:** Innate immunity to malaria has also been related to G6PD deficiency found in Mediterranean coast, Africa, Middle East, and India.
 - **HLA-B53:** HLA-B53 is associated with protection from malaria. There is some evidence that severe malnutrition and iron deficiency may confer some protection against malaria.
 - **Pregnancy:** Falciparum malaria is more severe in pregnancy, particularly in primigravida and may be enhanced by iron supplementation.
 - **Splenectomy:** The spleen appears to play an important role in immunity against malaria. Splenectomy enhances susceptibility to malaria.

Acquired Immunity

Infection with malaria parasite induces specific immunity involving both humoral and cellular immunity, which can

bring about clinical cure, but cannot eliminate parasites from the body.

- It can prevent superinfection, but is not powerful enough to defend against re-infection. This type of resistance in an infected host, which is associated with continued asymptomatic parasite infection is called **premunition**. This type of immunity disappears once the infection is eliminated.
- Humoral antibodies against asexual blood forms may protect against the malaria parasite by inhibiting red cell invasion and inhibiting growth inside the red cells, Antibodies against sexual stages are suggested to reduce malaria transmission.
- Acquired antibody-mediated immunity is transferred from mother to fetus across the placenta and is evident in endemic areas where infants below the age of 3 months are protected by passive maternal antibodies.
- Young children are highly susceptible to malaria. As they grow up, they acquire immunity by subclinical or clinical infections, so that incidence of malaria is low in older children and adults.

Recrudescence and Relapse

Recrudescence

In *P. falciparum* and *P. malariae* infections after the primary attack, sometimes there is a period of latency, during which there is no clinical illness. But some parasites persist in some erythrocytes, although the level of parasitemia is below the fever threshold or sometimes below the microscopic threshold. Erythrocytic schizogony continues in the body at low levels and gradually the number of parasites build up to cross the fever threshold. Fresh malarial attacks then develop. These new malarial attacks that appear after a period of latency usually within 8 weeks after the primary attack and resulting from persistence of the erythrocytic cycle of the parasites are called **recrudescences**. Recrudescence may be due to waning immunity of the host or possibly due to antigenic variation. In *P. falciparum* infections, recrudescences are seen for 1–2 years, while in *P. malariae* infection, they may last for long periods, even upto 50 years (Table 6.5).

Relapse

It is seen in *P. vivax* and *P. ovale* infections. In both these species, 2 kinds of sporozoites are seen, some of which multiply inside hepatocytes promptly to form schizonts and others which remain dormant. These latter forms are called **hypnozoites** (from *hypnos*: sleep). Hypnozoites remain inside the hepatocytes as uninucleated forms, 4–5 µm in

diameter, for long periods. Reactivation of hypnozoites leads to initiation of fresh erythrocytic cycles and new attacks of malarial fever. Such new attacks of malaria, caused by dormant exoerythrocytic forms, reactivated usually from 24 weeks to 5 years after the primary attack are called **relapses** (Table 6.5).

Table 6.5: Differences Between Recrudescence and Relapse

Recrudescence	Relapse
Seen in <i>P. falciparum</i> and <i>P. malariae</i>	Seen in <i>P. vivax</i> and <i>P. ovale</i>
Due to persistence of the parasite at a subclinical level in circulation	Due to reactivation of hypnozoites present in liver cells
Occurs within a few weeks or months of a previous attack	Occurs usually 24 weeks to 5 years after the primary attack
Can be prevented by adequate drug therapy or use of newer antimalarial drugs in case of drug resistance	Can be prevented by giving primaquine to eradicate hypnozoites

Laboratory Diagnosis

Demonstration of Parasite by Microscopy

Diagnosis of malaria can be made by demonstration of malarial parasite in the blood.

Two types of smears are prepared from the peripheral blood. One is called **thin smear** and the other is called **thick smear**.

- **Thin smears:** They are prepared from capillary blood of finger tip and spread over a good quality slide by a second slide held at an angle of 30°–45° from the horizontal such that a tail is formed.
 - A properly made thin film will consist of an unbroken smear of a single layer of red cells, ending in a tongue, which stops a little short of the edge of the slide.
 - Thin smears are air dried rapidly, fixed in alcohol and stained by one of the Romanowsky stains such as Leishman, Giemsa, Fields, or JSB stain (named after Jaswant Singh and Bhattacharjee).
 - Thin smears are used for detecting the parasites and **determining the species**.
- **Thick smears:** They can be made on the same slide of thin smear or separately.
 - In a thick film, usually 3 drops of blood are spread over a small area (about 10 mm).
 - The amount of blood in thin smear is about 1–1.5 μL , while in a thick smear it is 3–4 μL .

- The thick film is dried and kept in a koplín jar for 5–10 minutes for dehemoglobulination.
- It is not fixed in methanol.
- Thick film is stained similar to thin film.
- The stained film is examined under the oil immersion microscope.
- The thick film is more **sensitive**, when examined by an experienced person, because it concentrates 20–30 layers of blood cells in a small area.
- Thick film is more suitable for rapid detection of malarial parasite, particularly when they are few (as low as 20 parasites/ μL).
- The dehemoglobulinized and stained thick film does not show any red cells, but only leucocytes, and, when present, the parasites. But the parasites are often distorted in form, and as the diagnostic changes in blood cells such as **enlargement** and **stippling** cannot be made out, **species identification is difficult**.
- Thin film is examined first at the tail end and if parasites are found, there is no need for examining thick film. If parasites are not detected in thin film, then thick film should be examined.
- It is recommended that 200 oil immersion fields should be examined before a thick film is declared negative (Fig. 6.14).

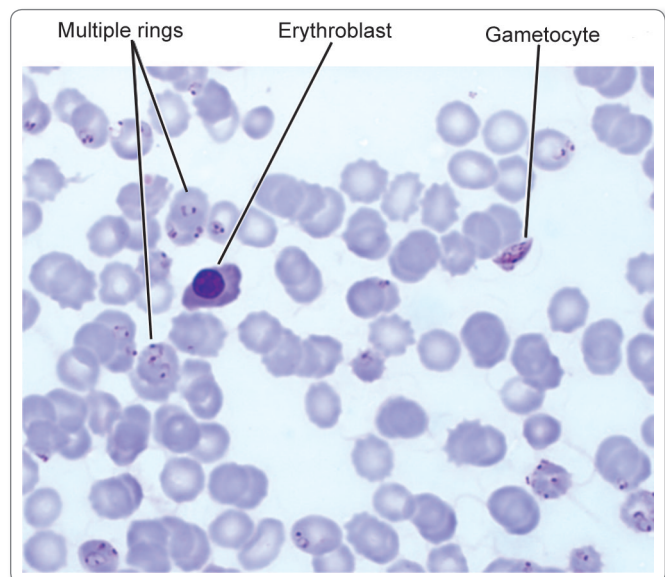


Fig. 6.14: Malarial parasite, *Plasmodium falciparum*, in the peripheral blood showing numerous ring stages and a crescent of gametocyte. The background shows a normoblast.

Courtesy: Textbook of Pathology, Harsh Mohan, 6th ed. New Delhi: Jaypee Brothers, 2013(R), p. 314

Morphological feature of malaria parasites in blood smear

- In *P. vivax*, *P. ovale*, and *P. malariae* all asexual forms and gametocytes can be seen in peripheral blood. In *P. falciparum* infection, only ring form alone or with gametocytes can be seen.
- Ring forms of all species appear as streaks of blue cytoplasm with detached nuclear dots. They are large and compact in *P. vivax*, *P. ovale*, and *P. malariae*, and fine delicate with double chromatin (**head-phone appearance**). In *P. falciparum*, multiple rings with 'accrole' forms are seen.
- Gametocytes are **banana-shaped** (crescents) in *P. falciparum* and **round** in *P. vivax*, *P. ovale*, and *P. malariae*.
- Enlarged RBCs with intracellular coarse brick-red stippling (**Schuffner's dots**) are characteristic in *P. vivax*. In *P. falciparum*, RBCs are normal in size with large red dots (**Maurer's dots**) and sometimes, with **basophilic stippling**. Careful search in blood should be made for *mixed infections*.



Quantification of parasites

Quantification of parasites can be done by thick smear. The counting of parasites are done to an approximate number in the following method.

+	=	1–10 parasite per 100 thick film fields
++	=	11–100 parasite per 100 thick film
+++	=	1–10 parasite per thick film field
++++	=	More than 10 parasite per thick film field.

Quantitative Buffy Coat, Smear

The Quantitative buffy coat (QBC) test developed by Becton-Dickinson, USA is a new simplified method for diagnosing malaria, wherein a small quantity of blood (50–110 μ L) of blood is spun in QBC centrifuge at 12,000 revolutions per minutes for 5 minutes.

- RBC containing malaria parasites are less dense than normal RBCs and concentrate just below the buffy coat of leucocytes at the top of the erythrocytic column.
- Pre-coating of the tube with acridine orange induces a fluorescence on the parasites, which can then be readily visualized under the oil immersion microscope because the parasite contains DNA, but the mature RBCs do not contain DNA and RNA. The nucleus of the parasite is detected by acridine orange stains and appears as fluorescing greenish-yellow against red background.

- The advantage of QBC is that it is faster and more sensitive than thick blood smear.
- The disadvantage of the test is that it is less sensitive than thick film and is expensive.
- A careful smear examination still remains as the '**gold standard**' in malaria diagnosis.

Microconcentration Technique

In microconcentration technique, blood sample is collected in microhematocrit tube and centrifuged at high speed. The sediment is mixed with normal serum and smear is prepared. Though it increases the positivity rate, it changes the morphology of the parasite.

Culture of Malaria Parasites

Attempts to culture malaria parasites *in vitro* were started in 1912 by Bass and Johns, who obtained limited multiplication of human plasmodia. The breakthrough came in 1976 with the discovery of a simple method by Trager and Jensen for the continuous culture of *P. falciparum*. The technique has been extended to culture other species also.

- The original method of petridish culture employed a candle jar to provide an atmosphere of 3% oxygen and 10% carbondioxide and a relatively simple culture medium supplemented with human, rabbit, or calf serum to maintain infected erythrocytes. Fresh red cells were added periodically for continuation of the growth and multiplication of plasmodia. The continuous flow method devised by Trager enables the prolonged maintenance of stock cultures.
- Computer-controlled culture systems, introduced subsequently, provide a steady abundant supply of parasites. Several culture lines have been established from blood of infected **Aotus monkey** or directly from human patients.
- Schizogony proceeds normally in culture. Gametocytes are formed infrequently. Pre-erythrocytic stages of some species have been obtained in tissue cultures. Plasmodia retain their infectivity in culture.
- Culture of plasmodia provides a source of the parasites for study of their antigenic structure, in seroepidemiologic surveys, drug sensitivity tests, and studies in immunoprophylaxis.

Serodiagnosis

Serodiagnosis is not helpful in clinical diagnosis because they will not differentiate between an active and past infection. It is used mainly for seroepidemiological survey and to identify the infected donors in transfusion malaria. The tests used are indirect hemagglutination (**IHA**),

indirect fluorescent antibody test (IFA), and enzyme-linked immunosorbent assay (ELISA).

Newer Methods of Diagnosis

Fluorescence Microscopy

Fluorescent dyes like acridine orange or benzothiocarboxy purine are used, which stain the parasites entering the RBCs but not WBCs. This is a method of differential staining.

- Acridine orange stains DNA as fluorescent green and cytoplasmic RNA as red.
- The stained slide is examined under fluorescent microscope.
- The method is mainly used for mass screening in field laboratory.

Rapid Antigen Detection Tests

Rapid diagnostic test are based on the detection of antigens using immunochromatographic methods. These rapid antigen detection tests have been developed in different test formats like the dipstick, card, and cassette-bearing monoclonal antibody, directed against the parasite antigens. Several kits are available commercially, which can detect *Plasmodium* in 15 minutes.

Parasite-F Test

This test is based on detection of histidine rich protein-2 (HRP-2) antigen produced by the asexual stages of *P. falciparum* expressed on the surface of red cells.

- Monoclonal antibody produced against HRP-2 antigen (Pf band) is employed in the test strip.
- **Advantage:** It is widely popular and has high sensitivity (98%) and specificity.
 - The test is said to detect low asexual parasitemia of more than 40 parasites/ μ L.
 - The test can be performed within 10 minutes.
- **Disadvantage:** Pf HRP-2 antigen detection test cannot detect the other 3 malaria species.
 - It remains positive upto 2 weeks after cure.
 - In *P. falciparum* infection, Pf HRP-2 is not secreted in gametogony stage. Hence in 'carriers', the Pf band may be absent.

Dual Antigen Test

The test detects pLDH – (parasite lactate dehydrogenase) produced by trophozoites and gametocytes of all plasmodium species and PF HRP-2 antigen.

- Thus, one band (Pv band) is genus specific (*Plasmodium* specific) and other is *Plasmodium falciparum* specific.

- This test is a rapid 2-site sandwich immunoassay used for specific detection and differentiation of *P. falciparum* and *P. vivax* malaria in areas with high rates of mixed infection.
- The 'Pv' band can be used for monitoring success of antimalarial therapy in case of stained alone *P. vivax*. Infection as the test will detect only live parasites and therefore will be negative, if the parasite has been killed by the treatment.
- The disadvantage of the test is that it is expensive and cannot differentiate between *P. vivax*, *P. ovale*, and *P. malariae*.

Molecular Diagnosis

DNA Probe

DNA probe is a highly sensitive method for the diagnosis of malaria. It can detect less than 10 parasites/ μ L of blood.

Polymerase Chain Reaction

Polymerase chain reaction (PCR) is increasingly used now for species specification and for detection of drug resistance in malaria.

- Chloroquine-resistance in *P. falciparum* has been attributed to mutation in the **PfCRT**, a **transporter gene** in the parasite.
- **Point mutation** in another **gene PfMDR1** have also been implicated in determining resistance *in vitro*.
- Pyrimethamine and sulfadoxime resistances are associated with point mutations in dihydrofolate reductase (**DHFR**) and (**DHPS**) **genes**, respectively.
- Mutation in **PfATPase gene** is associated with reduced susceptibility to artemisinin derivatives.

Other Tests

- Measurement of hemoglobin and packed cell volume (PCV), when there is malaria with heavy parasitemia, particularly in children and pregnant woman.
- Total WBC and platelet count in severe falciparum malaria.
- Measurement of blood glucose to detect hypoglycemia, particularly in young children and pregnant women with severe falciparum malaria and patients receiving quinine.
- Coagulation tests like measurement of anti-thrombin III level, plasma fibrinogen, fibrin degradation products (FDPs), prothrombin time (PTT), if abnormal bleeding is suspected in falciparum malaria.
- Urine for free hemoglobin, if blackwater fever is suspected.
- Blood urea and serum creatinine to monitor renal failure.

- G6PD screening before treatment with an antioxidant drug like primaquine.

Laboratory diagnosis of malaria

- Demonstration of malarial parasites in thick and thin blood smear examination by Leishman, Giemsa, or JSB stain
- Immunofluorescence staining and QBC smear
- Rapid immunochromatographic test (ICT) for detection of malaria antigen (PfHRP2 and PLDH)
- Molecular diagnosis: DNA probe and PCR
- Routine blood examination for Hb%, PCV, and blood sugar.

Treatment

Anti-malarial drugs are used with various objectives like clinical cure, prevention of relapse, prevention of transmission, and prophylaxis.

Therapeutic: Objective is to eradicate the erythrocytic cycle and clinical cure.

Radical cure: Objective is to eradicate the exoerythrocytic cycle in liver to prevent relapse.

Gametocidal: Objective is to destroy gametocytes to prevent mosquito transmission and thereby reducing human reservoir.

Chemoprophylaxis: Objective is to prevent infections in non-immune person visiting endemic areas.

The most commonly used antimalarials are chloroquine, amodiaquin, quinine, pyrimethamine, doxycycline, sulfadoxine, proguanil, and primaquine. Newer antimalarial like artemesinin, lumefantrine, mefloquine, halofantrin are now commonly used for multidrug resistant *P. falciparum* infections.

Treatment of Uncomplicated Malaria

Positive *P. vivax*, *P. ovale* and *P. malariae* cases are treated with chloroquine 25 mg/kg divided over 3 days.

- Vivax malaria relapses due to the presence of hypnozoites in the liver. The relapse rate of vivax malaria in India is about 30%.
- For prevention of relapse, primaquine is given in a dose of 0.25 mg/kg daily for 14 days under supervision.
- Primaquine is contraindicated in G6PD deficiency patients, infants and pregnant women.
- *In case of chloroquine resistance:* Quinine is given in a dose of 600 mg 8 hourly for 7 days along with doxycycline 100 mg/day.

Treatment of Complicated (Falciparum) Malaria

The treatment of *P. falciparum* malaria is based on areas identified as chloroquine resistant or chloroquine sensitive.

- **Chloroquine-sensitive falciparum malaria** is treated with chloroquine (dose as above) along with primaquine 45 mg (0.75 mg/kg) single dose (gametocidal).
- **In case of chloroquine resistance:** Artemesinin combined therapy (ACT) should be given.
 - ACT consists of an artemesinin derivative combined with a long-acting antimalarial drug (amodiaquine, lumefantrine, mefloquine, or sulfadoxine-pyrimethamine).
 - The ACT used in National Programme in India is artesunate + sulphadoxine-pyrimethamine.
 - Artemesinin derivative must never be given as monotherapy in uncomplicated malaria to prevent development of parasite resistance to these drugs.

Drug Resistance of Malarial Parasite

Effective, affordable, and safe treatment of malaria, particularly falciparum malaria is becoming increasingly difficult as resistance to commonly available quinoline and antifol antimalarial drugs continues to spread throughout the tropics.

- **A drug resistant parasite** is defined as a parasite that will survive and multiply in a dosage that normally cures the infection. Such resistance may be **relative** (yielding to increased doses of the drug tolerated by the host) or **complete** (withstanding a maximum dose tolerated by the host).
- Resistance arises from spontaneous point mutations in the genome or gene duplications. The emergence of resistance can be prevented by use of combination of drugs with different mechanisms of action and different drug target.
- Three levels of resistance (R) are defined by the World Health organisation (WHO).
 - **RI** – Following treatment, parasitemia clears but recrudescence occurs.
 - **RII** – Following treatment, there is a reduction but not a clearance of parasitemia.
 - **RIII** – Following treatment, there is no reduction of parasitemia.

The above method of classifying resistance is based on counting trophozoites in blood film daily for 7 days after treatment and monitoring the patient for any subsequent recrudescence. All patients with a falciparum parasitemia of more than one trophozoite per high power field (+++ or over) in areas of suspected drug resistance, should be

checked for a decrease and clearing of parasites following treatment.

Prophylaxis

Malaria Vaccine

Malaria vaccine is an area of intensive research. Over past decades, there has been a significant progress in malaria vaccine development. A completely effective vaccine is not yet available for malaria, although several vaccines are under development. **SPf66** was tested extensively in endemic areas in the 1990s, but clinical trials showed it to be insufficiently effective. Other vaccine candidates targeting the blood stage of parasite's life cycle have also been in insufficient on their own. Several potential vaccines targeting the pre-erythrocytic stage are being developed, with **RTS, S/AS01** showing the most promising results. The **RTS, S/AS01** (commercial name, **mosquirix**) was engineered using genes from the outer protein of *P. falciparum* and a portion of hepatitis B virus, plus a chemical adjuvant to boost immune response.

Vector Control Strategies

- **Residual spraying:** The spraying of the indoor surfaces of house with residual insecticides eg. dichloro-diphenyl-trichloroethane (DDT), malathion, and fenitrothin.
- **Space application:** Space Sprays are those where insecticidal formulation is sprayed into the atmosphere in the form of mist or fog to kill insects (pyrethrum extracts).
- **Individual protection:** Man-vector contact can be reduced by other preventive measures such as the use of repellants, protective clothing, bed net, preferably impregnated with long acting repellent, mosquito coils, and screening of house. For travelers visiting endemic areas, chemoprophylaxis provides effective protection. The drugs recommended for chemoprophylaxis are proguanil, chloroquin, or mefloquin weekly or doxycycline daily.

Anti-larval Measures

- Old antilarval measures such as oiling the collection of standing water or dusting them with **paris green** have now become promising with the increase of insecticide resistance.
- **Source reduction:** Techniques to reduce mosquito breeding sites, which include drainage or filling, deepening or flushing, management of water level,

intermittent irrigation are among the classical methods of malaria control.

Integrated Control

In order to reduce too much dependence on residual insecticides, increasing emphasis is being put on integrated vector control methodology, which includes bio-environmental and personal protection measures.

Malaria Control Programmes

In India the National Malaria Control Programme was introduced in 1958, with the objective of the ultimate eradication of the disease and operated successfully for 5 years, bringing down the annual incidence of malaria from 75 million in 1953 to 2 million.

- By 1961, the incidence dropped to an all time low of 50,000 cases and no deaths. However, there have been setbacks from 1970 and by 1976, the incidence rose to 6.4 million cases. With the implementation of modified plan of operation in 1977, the upsurge of malaria cases dropped down to 2.1 million cases in 1984. Since then, the epidemiological situation has not shown any improvement.
- Malaria control added impetus as '**Roll-back Malaria initiative**' launched jointly by WHO, United Nations Children's Fund (UNICEF), United Nations Development Programme (UNDP) and the World Bank in 1998. Accordingly National Vector Borne Disease Control Programme (**NVBDCP**) is implemented by Directorate of Health Services jointly with Mission directorate and National Rural Health Mission (**NRHM**). National goal established under the program is to reduce the number of cases and deaths recorded in 2000, by 50% or more in 2010 and by 75% or more by 2015.

Babesia Species

Babesia are intraerythrocytic sporozoan parasites that morphologically resemble *plasmodium* and cause tick-borne malaria like illness in domestic and wild animals.

It causes opportunistic infection in humans.

Classification

Order: Piroplasmida

Family: Babesiidae

Species: Medically important *Babesia* species are

- *B. microti* (rodent strain)
- *B. clivergens* (cattle strain)
- *B. bovis* (cattle strain)

History and Distribution

Babesia is so named after Babes, who in 1888 described the intraerythrocytic parasite in the blood of cattle and sheep in Romania.

- In 1893, the parasite was shown to cause the tick-borne disease, Texas fever, an acute hemolytic disease of cattle in southern USA.
- This was the first arthropod-borne disease to have been identified.
- In 2009, more than 700 cases were reported from endemic state of USA.
- Prevalence of *B. microti* is underestimated because young healthy individuals typically experience a mild self-limiting disease and may not seek medical attention.

Habitat

The parasite is present in erythrocytes and resembles the ring stage of *P. falciparum*.

Morphology

Trophozoites are pleomorphic 2–5 µm in diameter found inside the red cells. The shape may be pyriform, amoeboid, or spindle-like, usually in pairs and are often mistaken as ring form of *Plasmodium* (Fig. 6.15).

Merozoites may be spherical or oval or pyriform bodies, found in pairs.

Life Cycle

Definitive host: *Ixodid* ticks.

Intermediate host: Man or other mammals.

Infective form: Sporozoites are the infective form for humans.

Mode of Transmission: Infection in vertebrate occurs through bite of the nymphal stage of *Ixodid* ticks. Transmission occur during May to September. Incubation

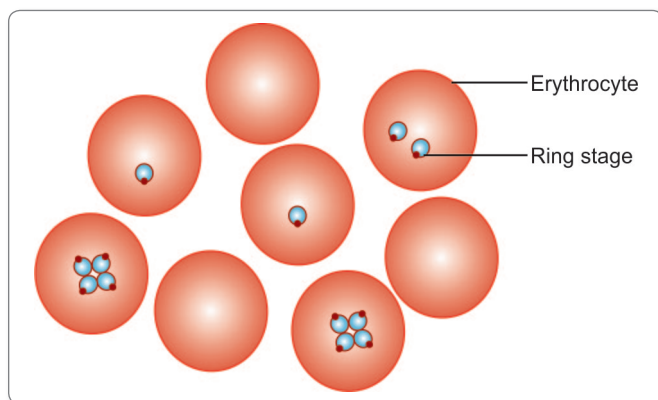


Fig. 6.15: Trophozoites of *Babesia microti* in human blood smear

period is 1–6 weeks Babesiosis can also be transmitted via blood transfusion. Transovarian transmission in ticks also occurs.

- In their life cycle, merogony takes place in vertebrate hosts and sporogony in the invertebrates.
- Man acquires infection by bite of the infected ticks (**definitive host**).
- Sporozoites present in the salivary glands of tick are introduced in man or other mammals (**intermediate host**).
- Sporozoites change to trophozoites in the circulation, which then invade the RBCs and multiply asexually by binary fission or schizogony to form 4 or more trophozoites. Newly formed trophozoites are released by rupturing erythrocytes and invade new erythrocytes.
- Some of the sporozoites grow slowly inside red cells and become folded like an accordion. These are thought to be gametocytes.
- Female ticks become infected by feeding the host blood.
- In the digestive tract of tick, the gametocytes multiply sexually and later migrate to the salivary glands where they divide by multiple fission into smaller forms known as '**vermecules**'.
- Vermecules undergo secondary schizogony to produce sporozoites, which are the infective forms for human.

Pathogenicity and Clinical Features

Hemolysis of the infected erythrocytes is primarily responsible for many clinical manifestations.

- There is accumulation of parasites in the capillaries of liver, spleen, and kidneys which leads to cellular degeneration and necrosis.
- The illness develops 1–6 weeks after the tick bite.
- This may be subclinical or mild self-limiting or acute illness, resembling malaria.
- In acute disease, there is malaise, fatigue, fever, myalgia, arthralgia, dry cough and anorexia. Fever exceeds 38°C and can reach 40.6°C accompanied by chill and sweat.
- Less common syndromes are neck stiffness, sore throat, abdominal pain, jaundice, and anemia.
- Severe babesiosis is associated with parasitemia levels of more than 4% infected RBCs and requires hospitalization. Fatality rate is 5% among hospitalized cases but is higher (20%) among immunocompromised patients.
- Complications of acute babesiosis are renal failure, disseminated intravascular coagulation (DIC), acute respiratory distress syndrome (ARDS), and congested cardiac failure (CCF).
- Risk factors for complication are severe anemia (<10 g%) and high levels of parasitemia.

Laboratory Diagnosis

Microscopy

Diagnosis of babesiosis is primarily done by examination of blood films stained with Leishman or Giemsa stain.

- *Babesia* appears as intraerythrocytic round or pyriform, or ring form simulating *P. falciparum* (Fig. 6.15).
- The ring forms is the most common and lacks the central hemozoin deposit, typical of *P. falciparum*.
- Other distinguishing features are the absence of schizonts and gametocytes and presence of tetrads (**maltose crosses**), which are pathognomic of *B. microti* or *B. duncani* (Table 6.6).

Polymerase Chain Reaction

If parasite cannot be identified by microscopy, amplification of babesial 18S RNA by PCR is recommended.

Serology

It is useful to confirm the diagnosis. An indirect immunofluorescent antibody (IFA) for *B. microti* is available.

IgM titer of more than 1:64 and IgG titer more than 1:1024, signify active or recent infection. Titer declines over 6–12 months.

Blood Picture

Parasitemia levels typically range from 1 to 20% in immunocompetent patients but can reach upto 85% in asplenic patients.

- Reticulocyte count is elevated.
- Thrombocytopenia is common.
- WBC count may be normal or slightly decreased.

Other Tests

Liver function tests serum glutamic pyruvate transaminase (SGPT) and alkaline phosphatase yield elevated value.

- Urine analysis may detect hemoglobinuria, excess urobilinogen, and proteinuria.
- In renal complications, increased blood urea nitrogen (BUN) and serum creatinine are found.

Table 6.6: Differential Features of Malaria and Babesiosis

Characteristics	Malaria	Babesiosis
Distribution	Worldwide	North America and Europe
Vector	<i>Anopheles</i> mosquito	Tick
Reservoir	Man	Rodent and cattle
No. of parasites per RBC	1 – 3	1 – 12
Schizont	Present	Absent
Gametocyte	Present	Absent
Pigment in trophozoite	Present	Absent
Antigenic variation	None	Profound
Level of parasitemia	Correlate with severity of disease	Does not correlate with severity of disease
Animal inoculation	Negative	Positive

Treatment

B. microti infection appears to be mild and self-limiting. Most of the patients recover without any specific chemotherapy, with only symptomatic treatment.

- In acute cases chemotherapy is required.
- Atovaquone 750 mg twice daily, along with azithromycin 500 mg–1 g/day for a period of 7–10 days is effective. Alternatively, clindamycin (300–600 mg, 6 hourly) along with quinine (650 mg 6–8 hourly) may be given intravenously.
- In fulminant cases, exchange transfusion is recommended.

Prophylaxis

No vaccine is available at present. There is no role of chemotherapy. Individuals who reside or travel in endemic areas, should wear protective clothing that covers lower part of the body and apply tick repellents.

Individuals with history of symptomatic babesiosis or with positive antibody titer should be indefinitely deferred from donating blood.

Key points of *Plasmodium* and *Babesia*

- **Malaria parasite** belongs to the genus *Plasmodium*.
- Four species of *Plasmodium* cause malaria in man—*P. vivax*, *P. falciparum*, *P. malariae*, and *P. ovale*.
- **Definitive host:** Anopheles mosquito (sexual phase of life cycle)
- **Intermediate host:** Man (asexual phase of life cycle)
- **Infective form:** Sporozoites present in salivary gland of mosquito.
- *P. vivax* and *P. ovale* cause benign tertian malaria, *P. falciparum* causes malignant tertian malaria and *P. malariae* causes benign quartan malaria.
- Acute falciparum malaria is the most dangerous and fatal form and is due to heavy parasitization of RBCs which cause blockage of capillary and venules by cytoadherence.
- **Clinical features:** Typical picture of malaria consist of periodic bouts of fever with rigor followed by anemia and splenomegaly. Febrile paroxysms comprise of cold stage, hot stage, and the sweating stage.
- TSS is a chronic benign condition resulting from abnormal immunological response to malaria.
- Relapse of malaria occurs in *P. vivax* and *P. ovale* infection due to persistence of dormant stage hypnozoites in liver. Recrudescence occurs commonly in *P. falciparum* and *P. malariae* due to persistence of parasite in circulation at a subclinical level.
- **Diagnosis:** By demonstration of parasite in thick and thin smear of peripheral blood and also by detection of malaria antigen by rapid ICT.
- **Treatment:** Chrooquine sulfadoxine, and pyrimethamine along with primaquine. In chloquine resistance, quinine or artemesinin are used.
- *Babesia species* comprising *B. microti*, *B. divergens*, and *B. bovis*, are intraerythrocytic sporozoan parasite resembling plasmodia. They cause opportunistic infections in humans.
- **Mode of transmission:** Through bite of Ixodid ticks.
- **Reservoirs:** Rodents and cattle.
- **Clinical features:** Mild and self-limiting. In immunocompromised patients, it causes anemia, jaundice, hemoglobinuria, respiratory failure, etc.
- **Diagnosis:** By examination of stained blood films for intraerythrocytic parasites, reticulocytosis, increased SGPT, alkaline phosphatase, hemoglobiniuria.
- **Treatment:** Atovaquone + azithromycin. Alternatively, clindamycin and quinine may be given.

Review Questions

1. Describe briefly the life cycle and laboratory diagnosis of:

(a) *Plasmodium vivax*

(b) *Plasmodium falciparum*

2. Write short notes on:

(a) Clinical features of malaria

(b) Cerebral malaria

(c) Black water fever

(d) Malignant tertian malaria

(e) Prophylaxis of malaria

(f) Treatment of malaria

(g) Rapid detection test

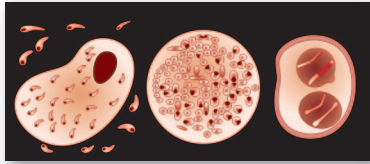
(h) Babesiosis

3. Differentiate between:

(a) Different malarial parasites

(b) Recrudescence and relapse

(c) Malaria and Babesiosis



Coccidia 7

The coccidia are unicellular protozoa and belong to the Phylum Apicomplexa.

- They live intracellularly, at least during a part of their life cycle and at some stage in their life cycle, they possess a structure called the **apical complex**, by means of which they attach to and penetrate host cells; hence included in Phylum Apicomplexa.
- All coccidian have a **sexual sporogonic phase** and an **asexual schizogonic phase**.
- Many of them also show an alteration of hosts; a definitive host and an intermediate host.
- Many parasites considered in this chapter have acquired great prominence due to their frequent association with HIV infection.

Toxoplasma Gondii

History and Distribution

Toxoplasma gondii is an obligate intracellular coccidian parasite, first described in 1908 by Nicolle and Manceaux in a small North American rodent called **gondii**, (*Ctenodactylus gondii*).

- Its importance as a human pathogen was recognized much later, when Janku in 1923 observed the cyst in the retina of a child with hydrocephalus and micro-ophthalmia.
- The name *Toxoplasma* is derived from the *Greek word 'Toxon'* meaning *arc or brow* referring to the curved shape of the trophozoite.

- *Toxoplasma* is now recognized as the most common protozoan parasite globally, with the widest range of hosts spread over 200 species of birds, reptiles, and mammals, including humans.

Morphology

T. gondii occurs in 3 forms (Fig. 7.1):

- Trophozoite
- Tissue cyst
- Oocyst.
- The trophozoite and tissue cyst represent stages in asexual multiplication (**schizogony**), while the oocyst is formed by sexual reproduction (**gametogony or sporogony**).
- All 3 forms occur in domestic cats and other felines, which are the definitive hosts and support both schizogony and gametogony.
- Only the asexual forms, trophozoites and tissue cysts are present in other animals, including humans and birds, which are the intermediate hosts.
- All the 3 forms are infectious to man.

Trophozoites (Tachyzoites)

The trophozoite is crescent-shaped, with one end pointed and the other end rounded.

- It measures 3–7 μm in length. The nucleus is ovoid and is situated at the blunt end of the parasite.
- Electron microscopy reveals an **apical complex** at the pointed end (Fig. 7.2).

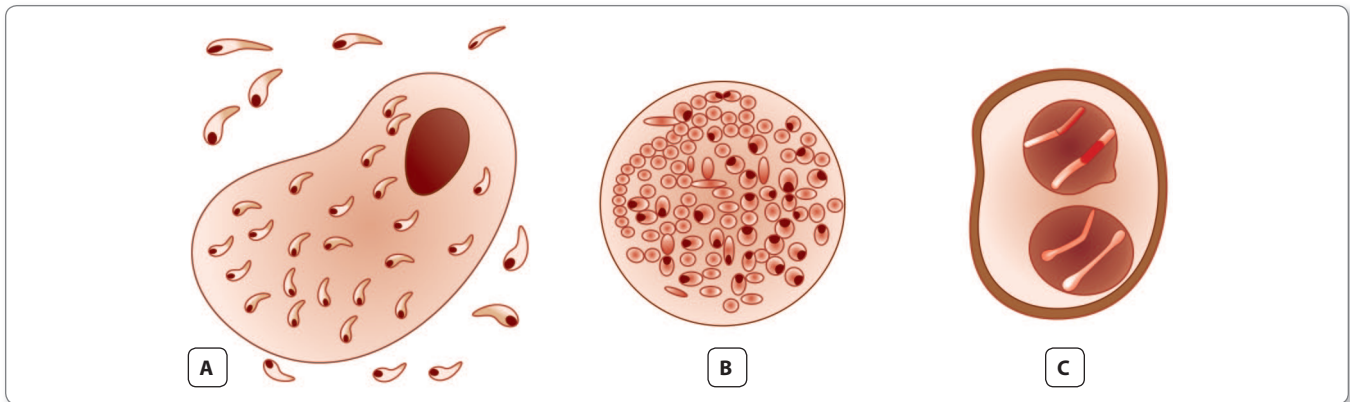


Fig. 7.1: *Toxoplasma gondii*. **A.** Smear from peritoneal fluid of infected mouse, showing crescentic tachyzoites—extracellular trophozoites and intracellular form within macrophage; **B.** Thick-walled tissue cyst containing rounded forms- bradyzoites; **C.** Oocyst containing 2 sporocysts with sporozoites inside

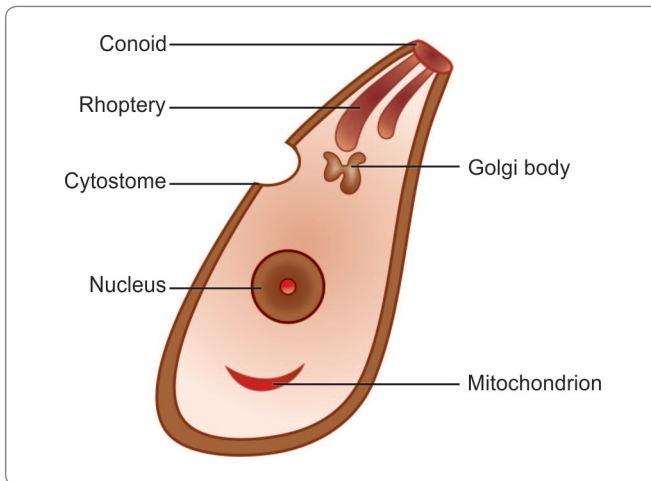


Fig. 7.2: *Toxoplasma gondii*. Trophozoite (tachyzoite), fine structure seen by electron microscopy

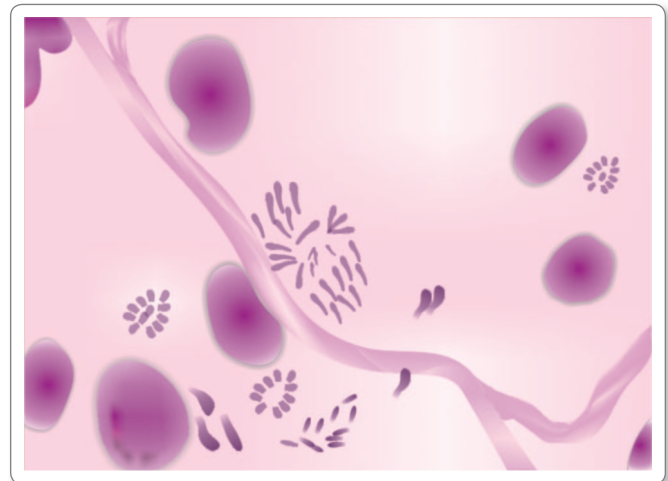


Fig. 7.3: *Toxoplasma gondii*. Trophozoite grows in tissue culture. Smear shows trophozoites arranged in different patterns—singly, in cluster, or as rosette (Giemsa stain)

- The trophozoite stains well with Giemsa stain, the cytoplasm appearing **azure blue** and the nucleus, **red** (Fig. 7.3).
- The actively multiplying trophozoite is seen intracellularly in various tissues during early acute phase of infection. Extracellular trophozoites can also be seen in impression smears.
- It can invade any nucleated cell and replicate within cytoplasmic vacuoles by a process called **endogony (internal budding)**, wherein 2 daughter trophozoites are formed, each surrounded by a membrane, while still within the parent cell. When the host cell becomes distended with the parasite, it disintegrates, releasing the trophozoites that infect other cells.
- During acute infection, the proliferating trophozoites within host cell may appear rounded and enclosed by

the host cell membrane. This is, called **pseudocyst** or **colony** and can be differentiated from tissue cysts by staining reactions.

- The rapidly proliferating trophozoites in acute infection are called **tachyzoites**
- The trophozoites are susceptible to drying, freeze-thawing, and gastric digestion.

Tissue Cyst

Tissue cysts are the resting form of the parasite.

- They are found during chronic stage of the infection and can be found in the brain (most common site), skeletal muscles, and various other organs.
- The cyst wall is eosinophilic and stains with silver, in contrast to the pseudocyst.

- With periodic acid Schiff (PAS) stain, the cyst wall stains weakly, and the parasites inside are stained deeply. The slowly multiplying parasites within the cyst are called **bradyzoites**.
- The cyst is round or oval, 10–20 µm in size and contains numerous bradyzoites. Cysts remain viable in tissue for several years.
- In immunologically normal hosts, the cysts remain silent, but in the immunodeficient subjects, they may get reactivated, leading to clinical disease.
- It is relatively resistant and when the raw or undercooked meat containing the cysts is eaten, infection occurs.
- The cyst wall is disrupted by peptic or tryptic digestion and the released parasites initiate infection by invading intestinal epithelial cells.
- They reach various tissues and organs through blood and lymphatic dissemination.
- Cysts are susceptible to dessication, freezing, and thawing, and heat above 60°C.
- It is oval in shape and measures 10–12 µm in diameter. Each cyst is surrounded by a thick resistant wall.
- The oocysts is formed by sexual reproduction (gametogony).
- Cats shed millions of oocysts per day in feces for about 2 weeks during the primary infection. The freshly passed oocyst is not infectious.
- They undergo sporulation in the soil with formation of 2 sporocysts, each containing 4 sporozoites. The sporulated oocyst is infective.
- Oocyst is very resistant to environmental conditions and can remain infective in soil for about an year.
- When the infective oocyst is ingested, it releases sporozoites in the intestine, which initiates infection.

Life Cycle

T. gondii completes its life cycle in 2 hosts (Fig. 7.4).

Definitive host: Cats and other felines, in which both sexual and asexual cycle takes place.

Intermediate hosts: Man and other mammals, in which only the asexual cycle takes place.

T. gondii has 2 types of life cycles:

- Enteric cycle
- Exoenteric cycle.

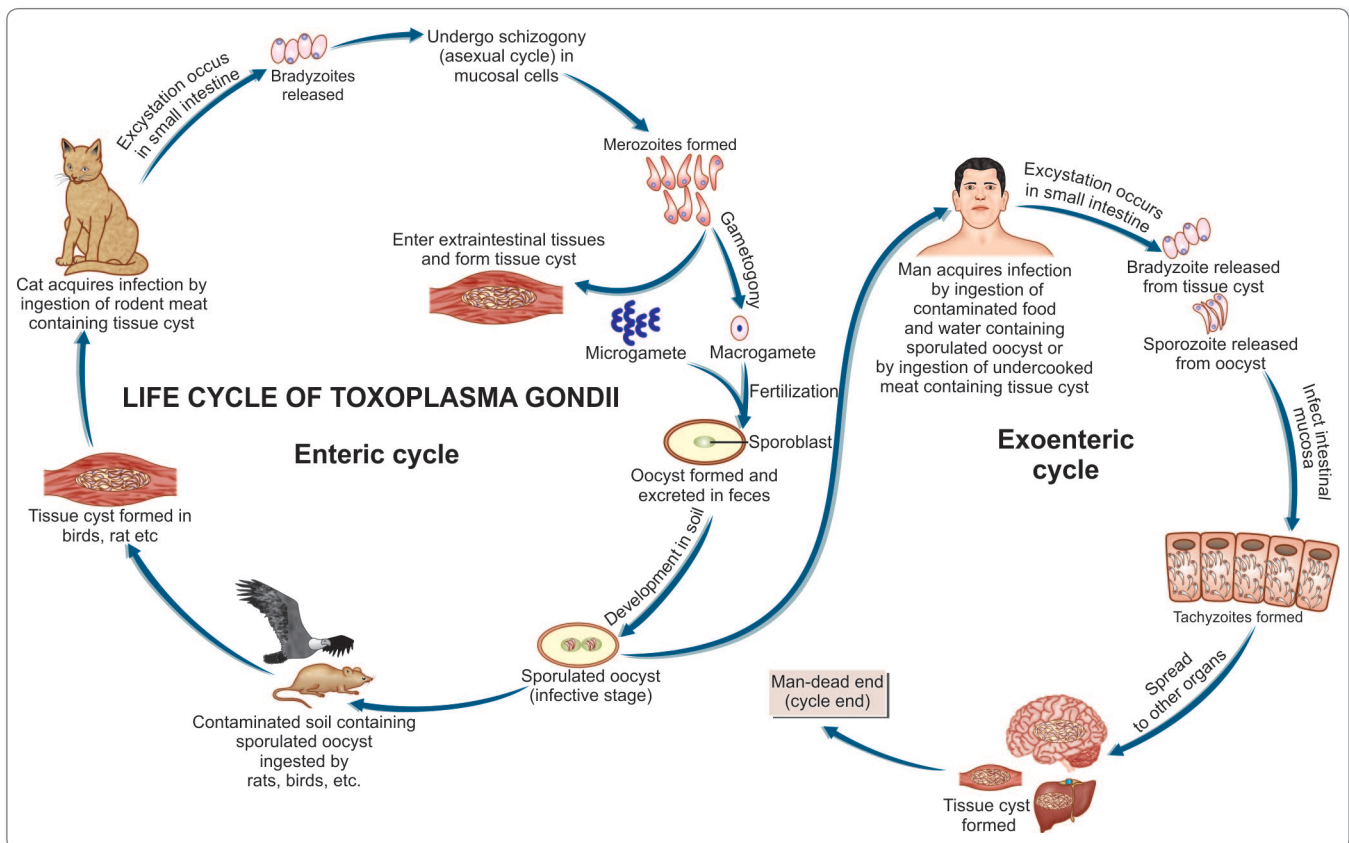


Fig. 7.4: Life cycle of *Toxoplasma gondii*.

Enteric Cycle

Enteric cycle occurs in cat and other definitive hosts (Fig. 7.4).

- Both sexual reproduction (gametogony) and asexual reproduction (schizogony) occur within the mucosal epithelial cells of the small intestine of the cat.
- Cat acquires infection by ingestion of tissue cysts in the meat of rats and other animals or by ingestion of oocysts passed in its feces.
- The bradyzoites are released in the small intestine and they undergo asexual multiplication (schizogony) leading to formation of merozoites.
- Some merozoites enter extraintestinal tissues resulting in the formation of tissue cysts in other organs of the body.
- Other merozoites transform into male and female gametocytes and sexual cycle (gametogony) begins, with the formation of **microgamete** and **macrogamete**.
- A macrogamete is fertilized by motile microgamete resulting in the formation of an oocyst, which passes through maturation stages (**sporulation**) in the soil after being excreted from host through feces.
- A mature oocyst containing 8 sporozoites is the infective form which may be ingested by rats or other mammals to repeat the cycle

Exoenteric Cycle

Exoenteric cycle occurs in humans, mice, rats, sheep, cattle, pigs and birds, which are the intermediate hosts.

Humans acquire infection after:

- Eating uncooked or undercooked infected meat, particularly lamb and pork containing tissue cysts
- Ingestion of mature oocysts through food, water, or fingers contaminated with cat feces directly or indirectly
- Intrauterine infection from mother to fetus (**congenital toxoplasmosis**)
- Blood transfusion or transplantation from infected donors.
- Sporozoites from the oocysts and bradyzoites from the tissue cysts enter into the intestinal **mucosa** and multiply **asexually** and **tachyzoites** are formed (**endodyogeny**).
- Tachyzoites continue to multiply and spread locally by lymphatic system and blood.
- Some tachyzoites also spread to distant extraintestinal organs like brain, eye, liver, spleen, lung, and skeletal muscles and form **tissue cysts**. The slowly multiplying forms inside the tissue cysts are known as **bradyzoites**, which remain viable for years.
- The dormant bradyzoites inside the cyst may be reactivated in immune suppression causing renewed infection in the host

- Human infection is a dead end for the parasite (Fig. 7.4).

- Human toxoplasmosis is a zoonosis.
- The full natural cycle is maintained predominantly by cats and mice.
- Mice eat materials contaminated with oocysts shed in cats feces. Tissue cysts develop in mice.
- When such mice are eaten by cats, they get infected and again shed oocysts in feces.

Pathogenicity and Clinical Features

The outcome of *Toxoplasma* infection depends on the immune status of the infected person.

- Active progression of infection is more likely in immunocompromised individuals. Toxoplasmosis has acquired great importance as one of the major fatal complications in acquired immunodeficiency syndrome (AIDS).
- Most human infections are asymptomatic.
- Clinical toxoplasmosis may be congenital or acquired.

Congenital Toxoplasmosis

Congenital toxoplasmosis results when *T. gondii* is transmitted transplacentally from mother to fetus.



Parasites which can be transmitted from mother to fetus

- *Toxoplasma gondii*
- *Plasmodium* spp.
- *Trypanosoma cruzi*

- This occurs when the mother gets primary toxoplasma infection, whether clinical or asymptomatic, during the pregnancy.
- The risk of fetal infection rises with progress of gestation; from 25%, when the mother acquires primary infection in first trimester to 65% in the third trimester. Conversely, the severity of fetal damage is highest, when infection is transmitted in early pregnancy.
- Mothers with chronic or latent *Toxoplasma* infection, acquired earlier, do not ordinarily infect their babies. But in some women with latent or chronic infection, the tissue cyst may be reactivated during pregnancy and liberate trophozoites, which may infect the fetus *in utero*
- Most infected newborns are asymptomatic at birth and may remain so throughout. Some develop clinical manifestations of toxoplasmosis weeks, months, and even years after birth.

- The manifestations of congenital toxoplasmosis include chorioretinitis, cerebral calcifications, convulsions, strabismus, deafness, blindness, mental retardation, microcephaly, and hydrocephalus.
- A few children are born with manifestations of acute toxoplasmosis, which may include fever, jaundice, petechial rashes, microphthalmia, cataract, glaucoma, chorioretinitis, lymphadenopathy, hepatosplenomegaly, myocarditis, cerebral calcifications, and chorioretinitis.
- In these patients, involvement of brain is most common.
- Clinical manifestation include encephalitis, altered mental state, seizures, cerebellar signs, meningismus, and neuropsychiatric manifestations.
- Besides central nervous system involvement, other organs involved are lungs, pancreas, gastrointestinal tract, eyes, heart, and liver.
- *Toxoplasma pneumoniae* can be confused with pneumocystis pneumonia.

Acquired Toxoplasmosis

- Infection acquired postnatally is mostly asymptomatic.
- The most common manifestation of acute acquired toxoplasmosis is lymphadenopathy; the cervical lymph nodes being most frequently affected.
- Fever, headache, myalgia, and splenomegaly are often present. The illness may resemble **mild flu** and is self-limited, although the lymphadenopathy may persist.
- In some cases, there may be a **typhus-like exanthema** with pneumonitis, myocarditis, and meningoencephalitis, which may be fatal.

Ocular Toxoplasmosis

Another type of toxoplasmosis is ocular.

- It may present as uveitis, choroiditis, or chorioretinitis.
- Some cases may be so severe that they require enucleation.

Toxoplasmosis in Immunocompromised Patients

Toxoplasmosis is most serious and often fatal in immunocompromised patients, particularly in AIDS, whether it may be due to reactivation of latent infection or new acquisition of infections.

Host Immunity

Host defence against *Toxoplasma* infection involves both humoral (antibody-mediated) and cellular responses. Specific IgG antibody can lyse extracellular trophozoites, but activated T cells and natural killer cells appear to be more important in containing the infection and preventing clinical disease.

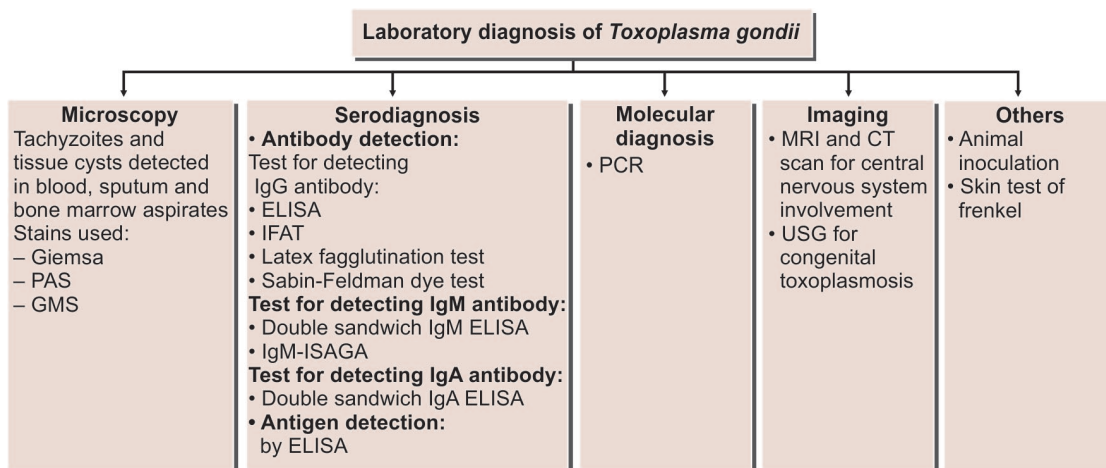
Laboratory Diagnosis

The diagnosis of acute toxoplasmosis is made mainly by demonstration of trophozoites and cysts in tissue and body fluids and by serology (Flowchart 7.1).

Microscopy

Tachyzoites and tissue cysts can be detected in various specimens like blood, sputum, bone marrow aspirate, cerebrospinal fluid (CSF), amniotic fluid, and biopsy material from lymphnode, spleen, and brain.

- Smear made from above specimens is stained by Giemsa, PAS, or Gomori methanamine silver (GMS) stain
- Tachyzoites appear as crescent-shaped structures with blue cytoplasm and dark nucleus.



Flowchart 7.1: Laboratory diagnosis of *Toxoplasma gondii*

- Tachyzoites or cyst can also be demonstrated effectively by fluorescent conjugated antibody technique in tissue biopsy or impression smear.
- Presence of only tissue cysts does not differentiate between active and chronic infection.
- The presence of cysts in placenta or tissues of newborn establishes congenital toxoplasma infection.

Animal Inoculation

Toxoplasma can be isolated by inoculating body fluids, blood, or tissue specimens by intraperitoneal inoculation in mice or in tissue culture. Mice should be examined for *Toxoplasma* in their peritoneal exudate after 7–10 days of inoculation.

Serodiagnosis

Serology is the main stay for diagnosis of toxoplasmosis.

Antibody detection

Diagnosis of acute infection with *T. gondii* can be made by detection of the simultaneous presence of IgM and IgG antibodies.

- Tests for detecting IgG antibody include:
 - Enzyme-linked immunosorbent assay (ELISA)
 - Indirect fluorescent antibody test (IFAT)
 - Latex agglutination test
 - Sabin-Feldman dye test.
- Positive IgG titer (>1:10) can be detected as early as 2–3 weeks after infection. Peak level of antibody is observed in blood 4–8 weeks after infection.
- A positive IgM antibody titer indicates an early primary infection. The serum IgM titer can be measured by double sandwich IgM ELISA or IgM immunosorbent assay (IgM-ISAGA). Both assays are equally specific and sensitive. Negative IgM titer and positive IgG titer indicate distant infection.
- The double sandwich IgA-ELISA test is used for detecting congenital infection in newborns.

Antigen detection

Detection of antigen by ELISA indicates recent *Toxoplasma* infection.

- In AIDS and other immunocompromised patients, antigen detection is very useful.
- Detection of antigen in amniotic fluid is helpful to diagnose congenital toxoplasmosis.

Skin test of Frenkel

Diluted toxoplasmin is injected intradermally and delayed positive reaction appears after 48 hours. This test is not very reliable for diagnosis of toxoplasma.

Sabin-Feldman dye test

This was the first serological test for *Toxoplasma* antibody to be described Sabin and Feldman (1948).

Principal: The test is based on specific inhibition by antibody, of the staining of trophozoites by alkaline methylene blue dye.

Technique: Equal volumes of diluted patient's serum are incubated with live trophozoites and normal human serum (accessory factor) for an hour at 37°C. Later, a drop of alkaline methylene blue dye is added to each tube and are examined under microscope. If less than 50% of the tachyzoites first take up stain and the cytoplasm remains colorless, the test is considered to be positive. The presence of 90–100% tachyzoites, deeply swollen and stained with blue color, shows the test to be negative. It denotes the absence of *Toxoplasma* antibodies. The highest dilution of the serum, which inhibits staining upto 50% is the *titer*.

Limitation: The test is reported to give false positive reaction in *Sarcocystis*, *Trichomonas vaginalis*, and *Trypanosoma Lewisii* infections.

Molecular Methods

DNA hybridization techniques and polymerase chain reaction (PCR) are increasingly used to detect *Toxoplasma* from different tissues and body fluids.

- B₁ gene of *T. gondii* can be detected by PCR of the amniotic fluid in case of congenital toxoplasmosis.

Imaging

Magnetic resonance imaging (MRI) and computed tomography (CT) scan are used to diagnose toxoplasmosis with central nervous system involvement.

- Ultrasonography (USG) of the fetus *in utero* at 20–24 weeks of pregnancy is useful for diagnosis of congenital toxoplasmosis.

Treatment

Congenital Toxoplasmosis

Neonates with congenital infection are treated with oral pyrimethamine (1 mg/kg) daily and sulfadiazine (100 mg/kg) with folic acid for 1 year. Systemic corticosteroid may be added to reduce chorioretinitis.

Immunocompetent Patients

Immunologically competent adults and older children, who have only lymphadenopathy, do not require specific therapy unless they have persistent, severe symptoms.

- Patients with ocular toxoplasmosis are treated for 1 month with pyrimethamine plus either sulfadiazine or clindamycin.

Immunocompromised Patients

AIDS patients who are seropositive for *T. gondii* and have a CD4+ T-lymphocyte count below $<100/\mu\text{L}$, should receive primary prophylaxis against toxoplasma encephalitis.

- Trimethoprim-sulfamethoxazole is the drug of choice. If trimethoprim-sulfamethoxazole cannot be tolerated by patients, dapsone-pyrimethamine is the recommended alternative drug of choice.
- Prophylaxis against toxoplasma encephalitis should be discontinued in patients who have responded to antiretroviral therapy (ART) and whose CD4+ T lymphocyte count has been above $200/\mu\text{L}$ for 3 months.

Prophylaxis

- Individuals at risk, particularly pregnant women, children, and immunocompromised persons should avoid contact with cat and its feces.
- Proper cooking of meal.
- Proper washing of hands and washing of vegetables and fruits before eating.
- Blood or blood products from seropositive persons should not be given and screening for *T. gondii* antibody should be done in all blood banks.

Control

It is difficult to control toxoplasmosis because of wide range of animal reservoirs. Currently, there is no effective vaccine available for humans. A genetically engineered vaccine is under development for use in cats.

Key points of *Toxoplasma gondii*

- Obligate intracellular parasite.
- Exists in 3 forms: trophozoite, tissue cyst, and oocyst.
- **Definitive host:** Cat family (enteric cycle).
- **Intermediate host:** Human (exoenteric cycle).
- Human infection occurs by ingestion of food containing oocyst and tissue cyst.
- Congenital infection can also occur.
- **Clinical features:** Acute encephalopathy, fever, chorioretinitis, lymphadenopathy, myocarditis, hepatosplenomegaly.
- Disseminated infection in AIDS.
- **Diagnosis:** By demonstration of parasite in tissue specimen, ELISA, IFAT, Sabin-Feldman dye test IgM-ISAGA.
- **Treatment:** Congenital infection is treated with pyrimethamine and sulfadiazine. For primary prophylaxis Trimethoprim-sulfamethoxazole is the drug of choice

ISOSPORA BELLI

History and Distribution

Isospora belli is a coccidian parasite which can cause diarrhea in humans.

- It was originally described by Virchow in 1860 but it was named in 1923.
- The name *belli* (from *bellium* meaning war) was given for its association with war, because several cases of infection with this parasite were seen among troops stationed in Middle East during first world war.
- It is more common in tropical and subtropical countries.

Morphology

Oocysts of *I. belli* are elongated-ovoid and measure $25 \mu\text{m} \times 15 \mu\text{m}$.

- Each oocyst is surrounded by a thin smooth 2 layered cyst wall (Fig. 7.5).
- Immature oocyst seen in the feces of patients contain two sporoblasts.
- The oocysts mature outside the body.
- On maturation, the sporoblast convert into **sporocysts**. Each sporocyst contain 4 crescent-shaped sporozoites (Fig. 7.6).
- The **sporulated oocyst containing 8 sporozoites** is the **infective stage** of the parasite.

Life Cycle

I. belli completes its life cycle in one host.

- Man gets infection by ingestion of food and water contaminated with sporulated oocyst.
- When a sporulated oocyst is swallowed, 8 sporozoites are released from the 2 sporocysts in the small intestine and invade the intestinal epithelial cells.

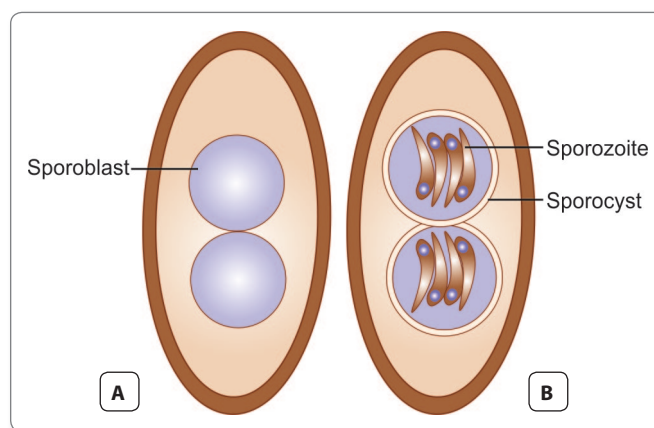


Fig. 7.5: Oocysts of *Isospora belli*. A. Immature cyst; B. Mature cyst

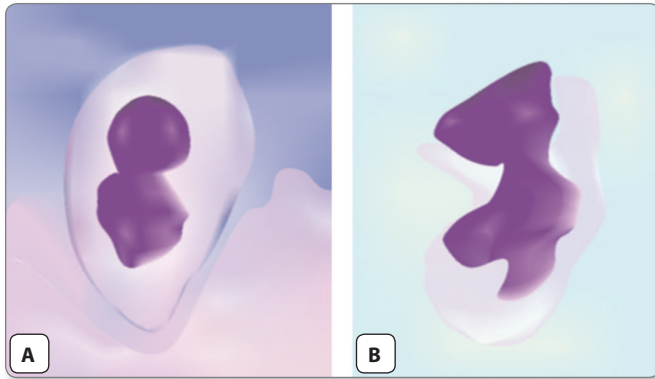


Fig. 7.6: Oocysts of *Isospora belli*. **A.** Oocyst showing 2 sporoblasts; **B.** Mature oocyst with 2 sporocysts containing sporozoites

- In the epithelium, the sporozoites transform into trophozoites, which multiply asexually (**schizogony**) to produce a number of (**merozoites**). The merozoites invade adjacent epithelial cells to repeat asexual cycle.
- Some of the trophozoites undergo sexual cycle (**gametogony**) in the cytoplasm of enterocytes and transform into **macrogametocytes** and **microgametocytes**.
- After fertilization, a **zygote** is formed, which secretes a cyst wall and develops into an **immature oocyst**.
- These immature oocysts are excreted with feces and mature in the soil.
- **Incubation period:** 1–4 days.

Clinical Features

Infection is usually asymptomatic.

- Clinical illness includes abdominal discomfort, mild fever, diarrhoea, and malabsorption.
- The diarrhoea is usually watery and does not contain blood or pus and is self-limiting. However, protracted diarrhoea, lasting for several years can be seen in immunocompromised persons, particularly in the human immunodeficiency virus (HIV) infected.

Laboratory Diagnosis

Stool Examination

Indirect evidence

- High fecal fat content.
- Presence of fatty acid crystals in stool.
- Presence of Charcot-Leyden crystals in stool.

Direct evidence

It may be difficult to demonstrate the transparent oocyst in saline preparation of stool.

- Stool concentration techniques may be required when direct wet mount of stools are negative.
- The staining technique used are Modified Ziehl-Neelsen stain or Kinyoun acid fast staining of stool smear. In these methods, pink colored acid fast large oocyst (>25 μm) can be demonstrated. The stool smear can also be stained by auramine rhodamine and Giemsa stains.

Duodenal Aspirates

After repeatedly negative stool examinations, duodenal aspirate examination or enterotest can be performed to demonstrate oocyst.

Intestinal Biopsy

Upper gastrointestinal endoscopy may provide biopsy specimens for demonstration of oocysts.

Others

Eosinophilia, which is generally not seen with other enteric protozoan infections, is detectable in case of isosporolosis.

Treatment

- No treatment is indicated in self-limiting infection in immunocompetent persons.
- Immunodeficient patients with diarrhea and excreting oocysts in the feces should be treated with cotrimoxazole (trimethoprim-sulfamethoxazole) in a dose of 2 tablet, 4 times a day for 10 days followed by 2 tablets 2 times a day for 3 weeks.
- For patients intolerant to sulfonamides, pyrimethamine 50–75 mg/day is given.
- Relapses can occur in persons with AIDS and necessitate maintenance therapy with cotrimoxazole 1 tablet thrice a week.

Cryptosporidium Parvum

History and Distribution

Cryptosporidia were first observed in the gastric mucosal crypts of laboratory mice by Tyzzer in 1907.

- Its importance as a pathogen causing diarrhoea in animals was recognized in 1971 and the first case of human infection was reported in 1976.
- *Cryptosporidium* has assumed great importance as a frequent cause of intractable diarrhoea, in AIDS patients, and immunocompromised subjects.
- It is worldwide in distribution.
- Two species of *Cryptosporidium*, *C. hominis* and *C. parvum* mostly cause human infections.

Habitat

C. parvum inhabits the small intestine. It may also be found in stomach, appendix, colon, rectum, and pulmonary tree.

Morphology

The infective form of the parasite is oocyst.

- The oocyst is spherical or oval and measures about 5 μm in diameter.
- Oocysts does not stain with iodine and is acid fast.
- The wall of the oocysts is thick, but in 20% cases, wall may be thin. These thin walled oocysts are responsible for autoinfection.
- Both thin walled and thick walled oocyst contain 4 crescent-shaped **sporozoites** (Fig. 7.7).
- Oocyst can remain viable in the environment for long periods, as it is very hard and resistant to most disinfectants and temperature upto 60°C.
- It can survive chlorinated water, but sequential application of ozone and chlorine has been found effective in eliminating the cysts.

Life Cycle

The parasite complete its life cycle, sexual and asexual phases in a single host (monoxenous) (Fig 7.8).

Suitable host: Man.

Reservoirs: Man, cattle, cat, and dog.

Mode of transmission:

Man acquires infection by:

- Ingestion of food and water contaminated with feces containing oocysts
- Autoinfection.

Infective form: Sporulated oocysts.

- The oocyst contains 4 sporozoites, which are released in the intestine.

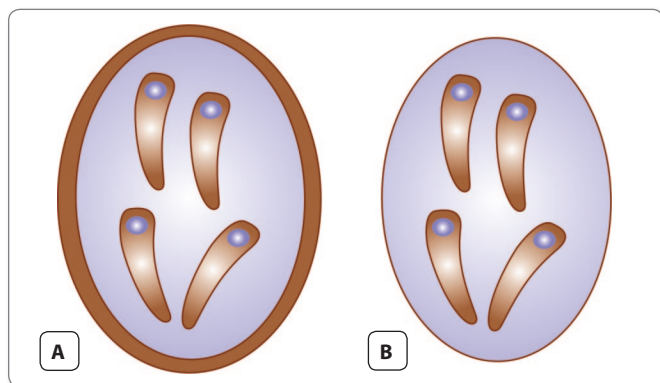


Fig. 7.7: Oocysts of *Cryptosporidium parvum*. **A.** Thick-walled oocyst; **B.** Thin-walled oocyst

- The sporozoites develop into trophozoites within parasitophorous vacuoles in the brush border of the intestine.
- The trophozoites undergo **asexual** multiplication (**schizogony**) to produce **type I meronts**.
- Eight merozoites are released from each type I meront. These merozoites enter adjacent epithelial cells to repeat schizogony or form type II meronts, which undergo gametogony.
- Four merozoites are released from each type II meront. The merozoites enter host cell to form sexual stages—**microgamete** and **macrogamete**.
- After fertilization, the zygote formed develops into the oocyst. The oocysts undergoes sporogony to form sporulated oocyst, which contain 4 sporozoites. Sporulated oocysts are released into the feces and transmit the infection from one person to another. Some of the oocysts have a thin wall surrounding 4 sporozoites and are called as **thin-walled oocysts**. These oocysts infect the same host and maintain the cycle of **autoinfection**.
- The oocysts are fully mature on release and are infective immediately without further development (Fig. 7.8).

Pathogenicity and Clinical Features

- Humans get infection either by ingestion of contaminated food and water with feces or by direct contact with infected animals. Human-to-human transmission can also occur. Incubation period is 2–14 days.
- Clinical manifestations of *C. parvum* infection vary depending upon the immune status of the host.
 - Infection in healthy immunocompetent persons may be asymptomatic or cause a self-limiting febrile illness, with watery diarrhea in conjunction with abdominal pain, nausea, and weight loss. It can also cause childhood and traveller's diarrhea, as well as water-borne outbreaks.
 - In immunocompromised hosts, especially those with AIDS and CD4+ T cell counts below 100/uL, diarrhea can be chronic, persistent, and remarkably profuse, causing significant fluid and electrolyte depletion, weight loss, emaciation, and abdominal pain. Stool volume may range from 1 to 25 L/day. Biliary tract involvement can manifest as right upper quadrant pain, sclerosing cholangitis, or cholecystitis.



Parasites causing travellers' diarrhea

- *Cryptosporidium parvum*
- *Entamoeba histolytica*
- *Giardia lamblia*
- *Cyclospora cayetanensis*

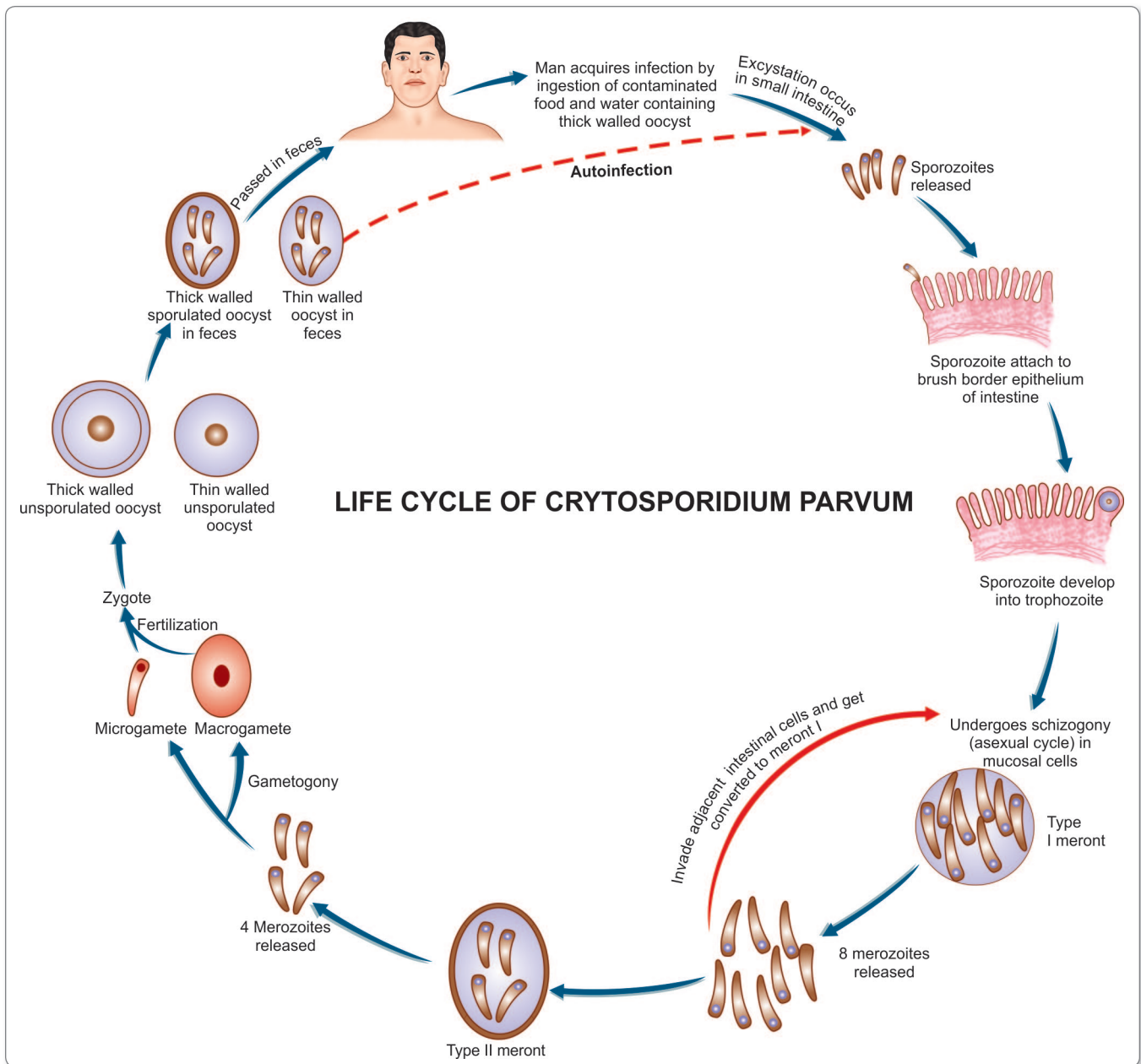


Fig. 7.8: Life cycle of *Cryptosporidium parvum*

Laboratory Diagnosis

Stool Examination

Diagnosis is made by demonstration of the oocysts in feces.

- A direct wet mount reveals colorless, spherical oocyst of 4–5 μm , containing large and small granules.
- The oocysts are difficult to visualize in unstained wet preparations.
- A number of staining techniques have been employed for demonstration of oocysts of *C. parvum* in the stool

specimen. Modified acid fast staining is the method of choice and by this method oocysts appear as red acid-fast spheres, against a blue background (Fig. 7.9). Yeast closely resembles oocysts of *C. parvum* in shape and size but can be differentiated by using acid-fast stain, as they are not acid-fast and appear blue in color. The staining can also be used for demonstration of oocysts in other specimens like sputum, bronchial washing, etc.

- If oocysts load is less and cannot be demonstrated even after examination of 3 wet mounts of stool

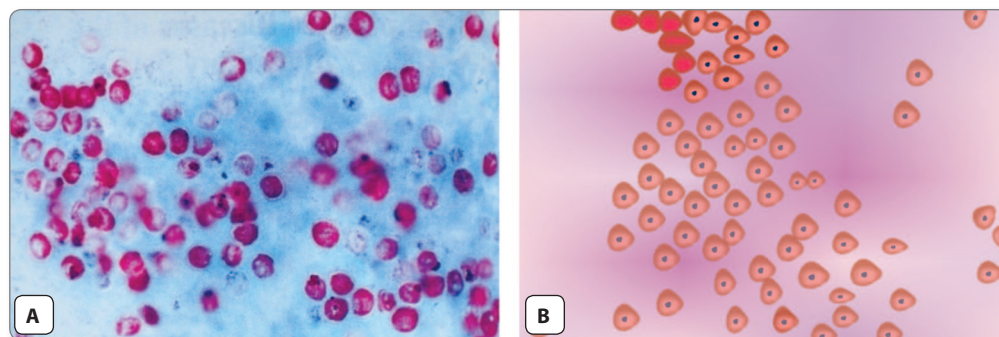


Fig. 7.9: Oocysts of *Cryptosporidium parvum*. **A.** Acid-fast stain; **B.** Ziehl-Neelsen stain

specimen, concentration techniques like Sheather's sugar floatation technique and zinc sulfate floatation technique can be applied.

- Fluorescent staining with auramine-phenol or acridine orange has also been reported to be a useful technique.
- Definitive identification can be made by indirect immunofluorescence microscopy using specific antibody.

Histopathological Examination

Cryptosporidia can also be identified by light and electron microscopy at the apical surface of intestinal epithelium from biopsy specimen of the small bowel (jejunum being the preferred site).

Serodiagnosis

Antibody specific to *C. parvum* can be demonstrated within 2 months of acute infection.

- Antibody persists for at least an year and can be demonstrated by ELISA or immunofluorescence.
- An ELISA for detection of *Cryptosporidium* antigens in stools using monoclonal antibody has also been developed and is highly sensitive and specific.

Molecular Diagnosis

For seroepidemiological study, western blot technique is employed by using a 17KDA and 27KDA sporozoite antigen.

- PCR technique has also been applied to detect viable cysts.

Treatment

No chemotherapeutic agent effective against *Cryptosporidium* has been identified, although nitazomamide or paromomycin may be partially effective in few patients with AIDS. Improvement in immune status with Antiretroviral therapy can lead to amelioration of cryptosporidiosis. Other

treatment methods include supportive therapy with fluid, electrolytes, and nutrient replacement.

Key points of *Cryptosporidium parvum*

- Sexual and asexual cycle in single host.
- **Infective form:** Sporulated oocyst in food and water.
- **Clinical features:** Self limited diarrhea with abdominal pain in healthy persons. Chronic persistent watery diarrhea in immunocompromised hosts.
- **Diagnosis:** Demonstration of round oocyst in stool by direct microscopy, fluorescent microscopy, and modified acid-fast stain.
- **Treatment:** Supportive therapy with electrolytes and fluids and early antiretroviral therapy in AIDS patients.

Cyclospora Cayetanensis

- It is a coccidian parasite.
- It was first reported from Nepal, where it caused seasonal outbreaks of prolonged diarrhea, with peak prevalence in the warm rainy months.

Morphology

The morphological form found in the feces is an oocyst.

- The oocyst is a non-refractile sphere, measuring 8–10 μm in diameter.
- It contains 2 sporocysts.
- Each sporocyst contains 2 sporozoites. Hence, each sporulated oocyst contains 4 sporozoites.

Life Cycle

Oocyst shed in feces sporulates outside the host.

- The sporulated oocysts are infectious to humans.
- Man acquires infection by ingestion of food and water contaminated with feces containing oocysts.
- Excystation of the sporocyst releases crescentic sporozoites measuring $9 \mu\text{m} \times 1.2 \mu\text{m}$.

- The sporozoites infect enterocytes in the small intestine.
- The sporozoites develop into unsporulated oocysts, which are excreted in feces.

Pathogenicity and Clinical features

Infection is through feco-oral route by ingestion of contaminated water and vegetables .

- Incubation period is of 1–7 days.
- Histopathological examination of the enterocytes show features of acute and chronic inflammation with blunting and atrophy of villi and hyperplasia of crypts.
- It causes prolonged diarrhea with abdominal pain, low grade fever, and fatigue.
- Like other coccidian parasites the infection is more severe in immunocompromised hosts, especially with AIDS.

Diagnosis

Stool Examination

Diagnosis is by direct wet mount demonstration of oocysts in feces.

- The oocysts can be stained by Zeihl-Neelson stain. Oocysts of *Cyclospora* are acid fast and stain red in color.
- Under ultraviolet illumination unstained oocysts of *C. cayetanensis* are autofluorescent.

Histopathology

Biopsy specimen from jejunum show villous atrophy and blunting of villi along with other inflammatory changes.

- The parasite can also be seen in small bowel biopsy material by electron microscopy.

Treatment

Cyclosporiasis is treated with cotrimoxazole (trimethoprim 160 mg/sulfamethoxazole 800 mg) twice daily for 7 days. HIV infected patients may require long-term suppressive maintenance therapy.

Blastocystis Hominis

Blastocystis hominis was previously considered a yeast, but recently it has been reclassified as a protozoan (Fig. 7.10).

Habitat

It is a strict anaerobic protozoa found in large intestine of humans.

Morphology

B. hominis has 3 morphological forms:

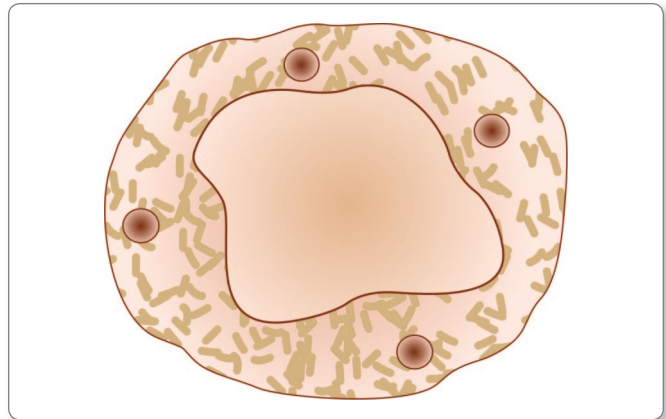


Fig. 7.10: *Blastocystis hominis*

- **Vacuolated form** is usually seen in stool specimen. It measures 8 μm in diameter and is characterized by its large central vacuole, which pushes the cytoplasm and the nucleus to the periphery. It multiplies by binary fission.
- **Amoeboid form** is a polymorphous cell slightly larger than the vacuolated form occasionally seen in the feces. It multiplies by sporulation.
- **Granular form** measures 10–60 μm in diameter and is seen exclusively in old cultures.

Pathogenicity and Clinical Features

The pathogenicity of *B. hominis* is doubtful. However, recent studies have shown the parasite to be associated with diarrhea.

- Clinical manifestations include diarrhea, abdominal pain, nausea, vomiting, fever, and chills.
- More than half of the patients suffering from infection with *B. hominis* have been found to be immunologically compromised.

Diagnosis

The condition is diagnosed by demonstration of the organism in stool smear stained by Giemsa or iron hematoxylin or Trichrome stains.

Treatment

If diarrheal symptoms are prominent, either metronidazole (750 mg thrice a day for 10 days) or iodoquinol (650 mg thrice a day for 20 days) can be used.

Sarcocystis

Three species of genus *Sarcocystis* can infect humans –

- *S. hominis* (transmitted through cattle)
- *S. suis* (transmitted through pig)
- *S. lindemanni*.
- Humans are the definitive host of *S. hominis* and *S. suis* and the intermediate host for *S. lindemanni*.
- *Sarcocystis* species produce cyst in the muscle of the intermediate hosts. These cysts, called *Sarcocysts* contain numerous merozoites (**bradyzoites**) (Fig. 7.11).
- When sarcocyst is eaten by the definitive host, the merozoites are released in the intestine, where they develop into male and female gametes.
- After fertilization, the zygote develops into an oocyst containing 2 sporocysts, each having 4 sporozoites (Fig. 7.12).
- These oocysts are shed in feces and are ingested by intermediate host.
- In the intermediate hosts, the sporozoite invade the bowel wall and reach the vascular endothelial walls, where they undergo schizogony producing **merozoites (tachyzoites)**.
- These spread to muscle fibers and develop into sarcocysts.
- Cow is the *intermediate host* for *S. hominis*. Human infection is acquired by eating raw or undercooked beef. Oocysts are shed in human feces, which contaminate grass and fodder eaten by cows.
- In the case of *S. suis*, the pig is the intermediate host and human infection is obtained through eating contaminated pork. Human infection with *S. hominis* and *S. suis* is related to food habits.
- Humans are the intermediate host in *S. lindemanni*; the definitive host of which is not yet known. It is believed that *S. lindemanni* may not be a single species but a group of, as yet unidentified species. Humans apparently get infected by ingestion of oocysts. Sarcocysts develop in the human skeletal muscles and myocardium.

Clinical Features

Intestinal sarcocystosis is usually asymptomatic. Patients may have nausea, abdominal pain, and diarrhea.

- **Muscular sarcocystosis** is also usually asymptomatic but may cause muscle pain, weakness, or myositis, depending on the size of the cyst.

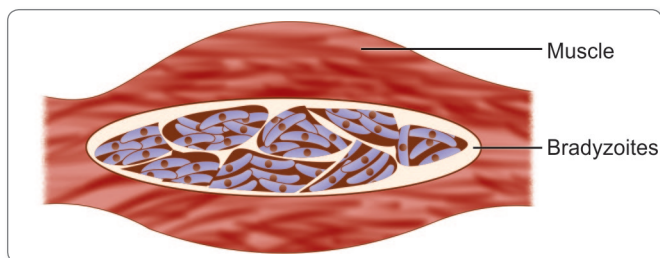


Fig. 7.11: Sarcocyst

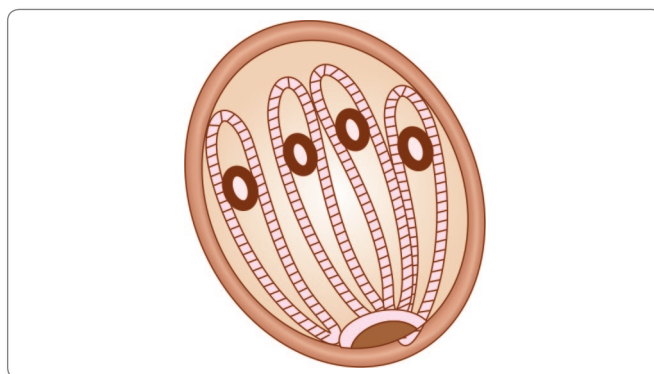


Fig. 7.12: Oocyst of *Sarcocystis hominis*

Laboratory Diagnosis

Stool Examination

Characteristically sporocysts or occasionally oocysts can be demonstrated in feces of human beings. Species identification is not possible with microscopy.

Muscular Sarcocystosis

Diagnosis can be made by demonstration of sarcocysts in the skeletal muscle and cardiac muscle by biopsy or during autopsy.

Treatment

No specific treatment is available for sarcocystosis.

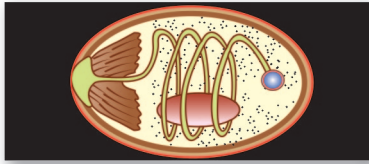
Prophylaxis

- By avoiding eating raw or under-cooked beef or pork
- By avoidance of contamination of food and drink with feces of cat, dog, or other carnivorous animals.

Review Questions

1. Describe the life cycle, clinical features and laboratory diagnosis of *Toxoplasma gondii*.
2. Discuss in brief life cycle of *Cryptosporidium Parvum*.
3. Write short notes on:

(a) Congenital Toxoplasmosis	(b) <i>Cryptosporidium parvum</i>
(c) Sabin-Feldman dye test	(d) Sarcocyst



Microspora

8

Microsporidia are classified under **Phylum** Microspora. They are minute, intracellular, Gram-positive, spore-forming protozoa.

- Microsporidia are also classified based on their habitat and the infections caused by them (Table 8.1).

History and Distribution

Microsporidia are of historical interest as they are the first protozoan parasite to have been successfully studied and controlled by Louis Pasteur in 1863, during an investigation

Table 8.1: Classification of Microsporidia

Genus	Species	Habitat and infection caused
<i>Enterocytozoon</i>	<i>E. bienewisi</i>	Small intestine epithelium (leading to diarrhea, and wasting). Also found in biliary tract of patients with cholecystitis. Rarely spreads to respiratory epithelium
<i>Encephalitozoon</i>	<i>E. intestinalis</i>	Small intestine epithelium (causing diarrhea and wasting). Also causes sinusitis, cholangitis, and bronchiolitis
	<i>E. hellem</i>	Conjunctival and corneal epithelium (causing keratoconjunctivitis). Also causes sinusitis, respiratory tract disease, and disseminated infection
	<i>E. cuniculi</i>	Small intestine epithelium (causing diarrhea). Corneal and conjunctival epithelium (causing keratoconjunctivitis). Rarely, may cause hepatitis and renal infection
<i>Pleistophora</i>	<i>P. ronniaefer</i>	Skeletal muscle (causing myositis)
<i>Brachiola</i>	<i>B. vesicularum</i>	Skeletal muscle (causing myositis)
	<i>B. conori</i>	Muscles (smooth and cardiac)
<i>Trachipleistophora</i>	<i>T. homini</i>	Cornea and conjunctival epithelium (leading to keratoconjunctivitis). Also causes myositis
	<i>T. anthropophtheria</i>	Brain
<i>Vittaforma</i>	<i>V. corneae</i>	Corneal stroma (causing stromal keratitis)
<i>Nosema</i>	<i>N. ocularum</i>	Corneal stroma (causing stromal keratitis)
<i>Microsporidium</i>	<i>M. ceylonensis</i>	Corneal stroma (causing stromal keratitis)
	<i>M. africanum</i>	

of silk worm disease epidemic in France. It was this experience, which led Pasteur to his epochal work on human and animal diseases that formed the foundation of **microbiology**. The causative agent of the silk worm disease (**Pebrine**) is *Nosema bombycis*, a microsporidian parasite.

- Microsporidia had been known as animal parasite for long, but their role as human pathogens was recognized only in the mid 1980s with the spreading of acquired immunodeficiency syndrome (AIDS).
- Some 9 genera and 13 species are associated with human disease, particularly in the human immunodeficiency virus (HIV) infected and other immunocompromised subjects.

Morphology

Microsporidia are **unicellular, obligate intracellular parasite**.

- They reproduce in host cells by producing **spores (sporogony)**
- Spores are 2–4 μm in size and oval to cylindrical in shape, with a polar filament or tubule (Fig. 8.1).
- The spores are the **infective stage of microsporidia** and the only stage of life cycle capable of existing outside the host cell.
- The **polar tubule** is an extrusion mechanism for injecting infective spore contents into the host cell.
- Spores are surround by thick double-layered cyst wall
 - Outer layer (**exospore**) is proteinaceous and electron-dense

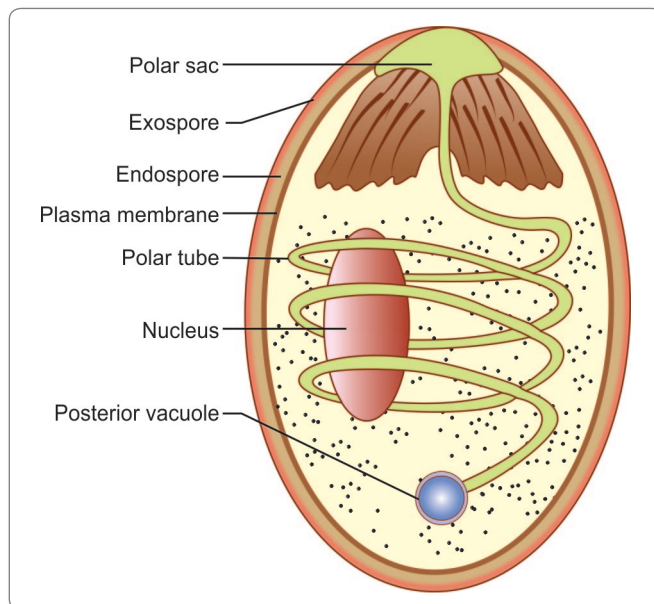


Fig. 8.1: Diagram showing microsporidian spore

- Inner layer (**endospore**) is chitinous and electron-lucent
- Spores are Gram-positive and acid fast.



Acid fast parasitic organisms

- Microsporidia (spore)
- *Cyclospora cayetanensis* (oocyst)
- *Isospora belli* (oocyst)
- *Cryptosporidium parvum* (oocyst)

Life Cycle

Infection in host is probably by ingestion or inhalation of spores.

- In the duodenum, the spore with its nuclear material is injected through the polar tubule into the host cell.
- Inside the cell, the microsporidia multiply by repeated binary fission (**merogony**) and produce large number of spores (**sporogony**).
- During sporogony, a thick **spore wall** is formed that provides environmental protection to the cyst.
- The spores are then liberated free from the host cell and infect other cells.

Clinical Features

They can cause wide range of illness in patients with HIV and other immunocompromised diseases.

- In patients with AIDS *Enterocytozoon bieneusi* and *Encephalitozoon intestinalis* lead to protracted and debilitating diarrhea in 10–40% of cases.
- *E. intestinalis* may also cause sinusitis, cholangitis, and bronchiolitis.
- Infection with *Pleistophora* can lead to myositis and *E. hellem* can cause superficial keratoconjunctivitis, sinusitis, respiratory disease, and disseminated infection.
- Stromal keratitis associated with trauma has been reported in infections with *Nosema*, *Vittaforma*, and *Microsporidium* in immunocompetent patients.

Parasites causing opportunistic infections in immunocompromised patients (HIV-positive cases)

- Microsporidia
- *Cyclospora cayetanensis*
- *Isospora belli*
- *Cryptosporidium parvum*
- *Toxoplasma gondii*
- *Strongyloides stercoralis*
- *Entamoeba histolytica*

Laboratory Diagnosis

Microscopy

Diagnosis of microsporidiasis is made by demonstration of the spores in stool, urine, cerebrospinal fluid (CSF), or small intestine biopsy specimen

- The spores can be stained with Gram's stain, periodic acid Schiff stain (PAS), or modified trichrome stain.

Note: Spores of microsporidia stain poorly with haematoxylin and eosin stain.

- Although intracellular spores can be visualized by light microscopy, electron microscopy is the gold standard.
- Identification of species and genera of microsporidia is based on electron microscopy of spore morphology.
- Direct fluorescent method using monoclonal antibody are also used for detection of microsporidia in clinical samples.

Cell Culture

Microsporidia spores can be cultured in monkey and rabbit kidney cells and human fetal lung fibroblast.

Molecular Diagnosis

Microsporidial DNA can be amplified and detected by polymerase chain reaction (PCR).

Treatment

There is no specific and effective drug for microsporidia.

- Intestinal microsporidia may be treated with metronidazole and albendazole.
- For superficial keratoconjunctivitis, topical therapy with fumagillin suspension can be used.

Prophylaxis


Improved personal hygiene and sanitation, especially in immunocompromised persons can prevent microsporidia.

Key points of Microsporidia

- Microsporidia are intracellular spore-forming protozoa, which belong to Phylum Microspora.
- Spores of Microsporidia are oval or cylindrical in shape with polar filaments or tubules.
- **Mode of infection:** By ingestion or inhalation of spores.
- **Reproduction:** Microsporidia multiply by both merogony and sporogony.
- **Clinical features:** Protracted and debilitating diarrhea and disseminated infection in eyes, muscles, and lungs.
- **Diagnosis:** By demonstration of spores in stool, urine, and CSF by Gram's, PAS, or modified trichrome stains. Serological diagnosis includes direct fluorescent antibody test. PCR is also very useful. Electron microscopy is useful in species identification of microsporidia.
- **Treatment:** There is no specific and effective treatment. Intestinal microsporidia can be treated with metronidazole and albendazole. Topical therapy with fumagillin suspension is used for superficial keratoconjunctivitis.

Review Questions

1. Describe briefly the laboratory diagnosis of Microsporidia.
2. Write short note on the morphology of Microsporidia species.



Pneumocystis Jirovecii 9

Pneumocystis jirovecii (*carinii*) is a yeast-like fungus of the genus *pneumocystis*.

- It is the causative organism of pneumocystic pneumonia
- It is an important human pathogen, particularly amongst immunocompromised patients.
- *P. jirovecii* was known as *P. carinii* prior to its discovery as a human pathogen and the term was applied to the organisms found in rats and human both.
- After DNA analysis showed significant difference in the human variant and it became clear that it was a fungus, the name was changed to *Pneumocystis jirovecii*, according to the International Code of Botanical Nomenclature (ICBN).

Note: The name *P. carinii* is incorrect for the human variant but still describes the species found in rats.

History and Distribution

- Pneumocystis was first described by Carlos Chagas (1909) and Carini (1910) in the lung of guinea pigs in Brazil.
- *Pneumocystis* was rediscovered as human pathogen in 1942 by 2 Dutch investigators, Van Der Meer and Brug.
- Frankel proposed the name as *P. jirovecii* in 1999 in honor of Otto Jirovec, who described pneumocystic pneumonia in humans in 1952.
- *Pneumocystis* has received much attention from 1980's as it is one of the characteristic opportunistic infections seen in acquired immunodeficiency syndrome (AIDS) patients.

- It is far more commonly seen in AIDS patients in America and Europe, than in Asia and Africa.

Habitat

P. jirovecii occurs as a saprophyte in the environment. It is also found as an extracellular parasite in the pulmonary alveoli of lungs of healthy humans and animals. Most healthy children are exposed to *Pneumocystis* by 3–4 years of age.

Morphology

It occurs in 2 forms: trophozoite and cyst.

Trophozoite

The trophozoite measures 1–5 μm in length, is **amoeboid** in shape, and has a **central nucleus**.

- Its cytoplasm contains mitochondria, ribosomes, endoplasmic reticulum, and various granules.
- It is covered with bilayer wall with tiny tubular projections, which aid in attachment to the epithelial cells and increase absorptive surface area.
- It divides by **binary fission**.

Cyst

It is **spherical**, usually measuring 5–10 μm in diameter.

- It is covered by a thick wall and contains 8 oval-shaped intracystic bodies or **sporozoites**.

Life cycle

- The cyst is the infective form of the parasite.
- The inhaled cysts in the alveoli excyst and release sporozoites.
- The sporozoites get converted into **trophozoites**.
- The trophozoites divide by binary fission.
- Some trophozoites become encysted and produce 8 daughter trophozoites within the cysts and are also known as **intracystic bodies or sporozoites**.
- The mature cyst is thick-walled.
- The cyst collapses and releases trophozoites, which initiate another cycle of multiplication, either in the same host or another host, if they have been spread by coughing.
- The collapsed cysts can be seen as irregular crescentic bodies (Fig. 9.1).

Pathogenesis

P. jirovecii (carinii) is normally a commensal in the lung and spreads by respiratory droplets.

- Pneumocystosis is an **opportunistic infection**; clinical disease being found only when the resistance is very low.

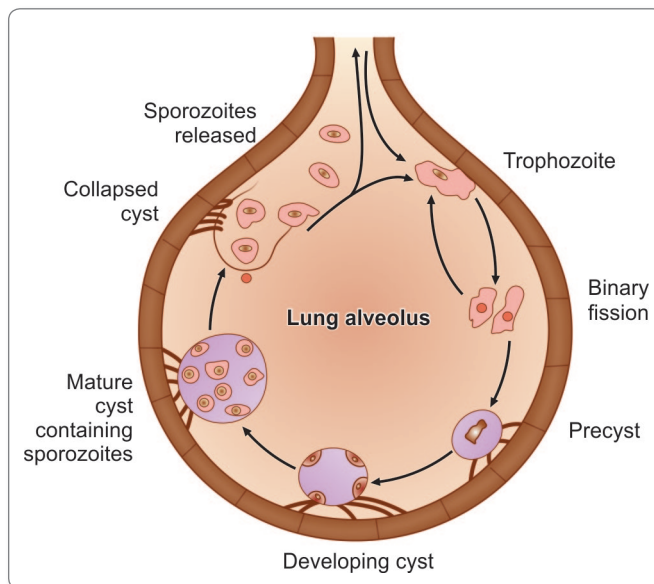


Fig. 9.1: Life cycle of *Pneumocystis carinii*. The parasite enters the lung in respiratory droplets and gets attached to alveolar epithelium. It divides by binary fission. Some form a thick-walled cyst, within which sporozoites develop. When mature cysts rupture, sporozoites are released, which initiate fresh cycles of infection

Predisposing factors for *pneumocystis*

- Human immunodeficiency virus (HIV) infected person when circulating CD4+ T-cell counts fall below 200/ μ L.
 - Patients receiving immunosuppressive drugs like glucocorticoids for organ transplantation, cancer, etc.
 - Those receiving biological agents like infliximab or etanercept for rheumatoid arthritis and inflammatory bowel disease.
 - Children with primary immunodeficiency diseases.
 - Premature malnourished infants.
 - Infants with hyper immunoglobulin (IgM) syndrome.
- In the lungs of healthy person, the alveolar macrophages ingest and kill the organism. But in the immunocompromised hosts, the organisms proliferate and can remain extracellular within alveolus, attaching lightly to **type I pneumocytes**.
 - Alveolar damage results in increased alveolar capillary permeability and surfactant abnormality.
 - Host inflammatory response to lung injury leads to increased interleukin (IL)-8 and neutrophil count in bronchoalveolar fluid.
 - Hematoxylin eosin stained lung biopsies show that alveoli are filled with a typical **foamy vacuolar exudate** containing numerous lymphocytes, macrophages, and plasma cells.
 - In severe disease, a characteristic **honey-comb pattern** with interstitial edema, fibrosis, and hyaline membrane formation are seen.

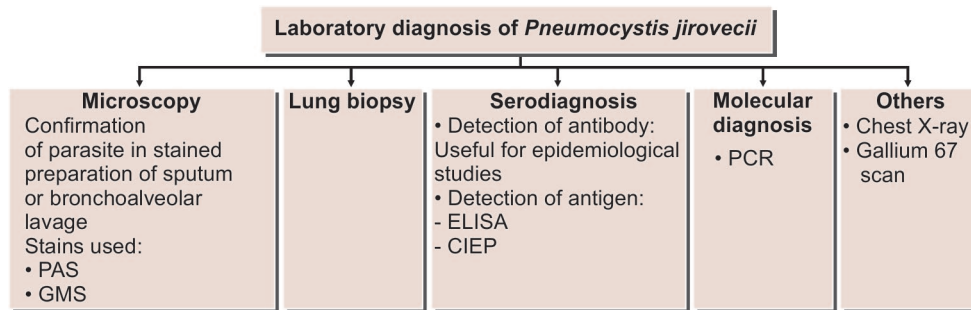
? Parasite causing opportunistic infections in AIDS

- *Pneumocystis jirovecii*
- *Entamoeba histolytica*
- *Giardia lamblia*
- *Leishmania* spp.
- *Toxoplasma gondii*
- Microsporidia
- *Isospora belli*
- *Cryptosporidium parvum*
- *Cyclospora caytanensis*
- *Strongyloides stercoralis*

Clinical Features

Pneumocystic pneumonia presents with non-productive cough, dyspnea, and high fever.

- There may be weight loss and night sweats.



Flowchart 9.1: Laboratory diagnosis of *Pneumocystis jirovecii*

- Large amount of sputum is usually not present unless the patient has a bacterial infection.
- *Pneumocystis* can invade other visceral organs such as liver, spleen, and kidney only in a minority of cases (<3%)
- In the immunocompromised patients, the disease progression is rapid, leading to significant hypoxia that can be fatal, if not treated aggressively
- Pneumothorax is a well-known complication of pneumocystic pneumonia.

Laboratory Diagnosis

Microscopy

Diagnosis of *P. jirovecii* pneumonia is confirmed by histological identification of the parasite in sputum or bronchoalveolar lavage (BAL), or tracheal aspirate.

- Specimens are stained by toluidine blue, periodic acid-Schiff (PAS), Gomori methanamine silver (GMS), or immunofluorescence stains, which show characteristic cysts (Flowchart 9.1).
- The cysts resemble **crushed ping-pong balls** and are present in aggregates of 2–8.
- Cyst wall thickening appears as **double comma** morphology.
- Disadvantage of the technique is that it does not stain internal contents of the cyst (Fig. 9.2).

Biopsy

A lung biopsy would show thickened alveolar septa with fluffy eosinophilic exudates in the alveoli.

Serodiagnosis

Antibody Detection

Serological assays to detect anti-*P. jirovecii* antibodies are useful for epidemiological studies, but not for diagnosis of pneumocystic pneumonia.




Fig. 9.2: *Pneumocystis jirovecii* cyst (methanamine silver stain)

Antigen Detection

P. jirovecii antigen can be demonstrated by enzyme-linked immunosorbent assay (ELISA) and counterimmunoelectrophoresis assay (CIEP) and are used to diagnose *Pneumocystis* infection (Flowchart 9.1).

Molecular Diagnosis

Detection of the presence of *P. jirovecii* can be accomplished by targeting the ribosomal sub-unit of mitochondrial r-RNA using direct or nested polymerase chain reaction (PCR).

Radiology

- Chest X-ray in pneumocystic pneumonia shows bilateral diffuse infiltrates starting from the perihilar regions of the lungs.
- **Gallium 67** scans are also used (Flowchart 9.1).

Treatment

Therapy is most effective when instilled before extensive lung damage. Trimethoprim-sulfamethoxazole or pentamidine isothianate is the drug of choice.

Dose

- Trimethoprim 5 mg/kg and sulfamethoxazole 25 mg/kg, 6–8 hourly oral or IV are given for 14 days in the non-HIV patients and for 21 days in HIV patients.
- Pentamidine 4 mg/kg/day, given parenterally once daily for 14 days, is effective in non-HIV patients.

Prophylaxis

Indications for giving prophylactic therapy:

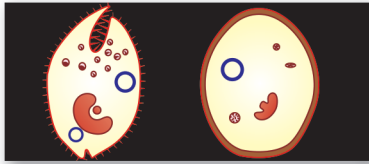
- HIV patients with CD4+ T-cell count less than 200/ μ L
- HIV patients with history of oropharyngeal candidiasis
- Both HIV and non-HIV infected patients, who have recovered from pneumocystic pneumonia.
- Prophylaxis may be discontinued when CD4+ T-cell count rises to more than 200/ μ L.
- Drug of choice for prophylaxis is trimethoprim and sulfamethoxazole.

Key points of *Pneumocystis jirovecii*

- *P. jirovecii*, a yeast-like fungus, occurs in 2 forms: trophozoite and cyst.
- **Infective stage:** Cyst.
- **Predisposing factors:** HIV patients with CD4+ cells <200/ μ L, patients receiving immunosuppressive agents, etc.
- **Clinical features:** Nonproductive cough, dyspnea, fever, weight loss, and reduced PO₂.
- **Diagnosis:** Demonstration of cyst in sputum, BAL, or tracheal aspirate by PAS, GMS, or immunofluorescent stains; lung biopsy; chest X-ray; CT scan; Galium 67 scan.
- **Treatment:** Drug of choice is Trimethoprim and sulfamethoxazole or pentamidine.
- **Prophylaxis:** Trimethoprim and sulfamethoxazole.

Review Question

1. Enumerate the opportunistic parasitic infections seen in HIV patients and discuss briefly the life cycle and laboratory diagnosis of *Pneumocystis jirovecii*.



Balantidium Coli 10

Balantidium coli belongs to the **Phylum** Ciliophora and **Family** Balantididae.

- It is the only **ciliate protozoan** parasite of humans
- It is the **largest protozoan** parasite of humans.



Largest protozoan parasite residing in the large intestine of man: *Balantidium coli*.

History and Distribution

It was first described by Malmsten in 1857, in the feces of dysenteric patients.

- It is present worldwide, but the prevalence of the infection is very low.
- The most endemic area is New Guinea, where there is a close association between man and pigs.

Habitat

B. coli resides in the large intestine of man, pigs, and monkeys.

Morphology

B. Coli occurs in 2 stages – trophozoite and cyst (Fig. 10.1).

Trophozoite

The trophozoite lives in the large intestine, feeding on cell debris, bacteria, starch grains, and other particles.

- The trophozoite is actively motile and is invasive stage of the parasite found in dysenteric stool.
- It is a large **ovoid** cell, about 60–70 μm in length and 40–50 μm in breadth. Very large cells, measuring upto 200 μm are sometimes seen.
- The cell is enclosed within a delicate pellicle showing longitudinal striations.
- The motility of trophozoite is due to the presence of short delicate cilia over the entire surface of the body.
- Its anterior end is narrow and posterior end is broad.
- At the anterior end, there is a groove (**peristome**) leading to the mouth (**cytostome**), and a short funnel-shaped gullet (**cytopharynx**).
- Posteriorly, there is a small anal pore (**cytopyge**).
- The cilia around the mouth are larger (**adoral cilia**).

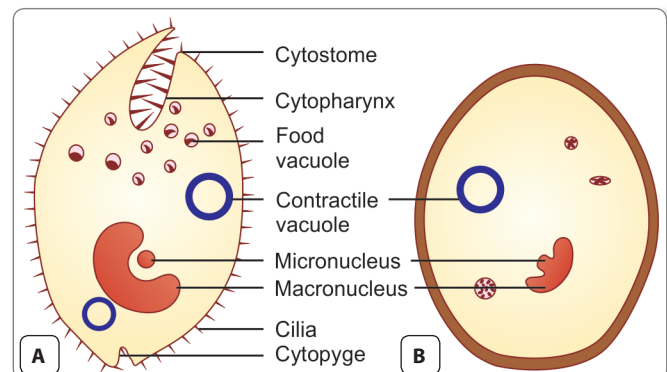


Fig. 10.1: Morphology of *Balantidium coli*. A. Trophozoites; B. Cyst

- The cell has 2 nuclei—a large kidney-shaped **macro-nucleus** and lying in its concavity a small **micronucleus**.
- The cytoplasm has 1 or 2 contractile vacuoles and several food vacuoles.

Cyst

The cyst is **spherical in** shape and measures 40–60 μm in diameter.

- It is surrounded by a thick and transparent double-layered wall.
- The cytoplasm is granular. Macronucleus, micronucleus, and vacuoles are also present in the cyst.
- The cyst is the **infective stage** of *B. coli*.
- It is found in chronic cases and carriers.

Life Cycle

B. coli passes its life cycle in one host only (monoxenous).

Natural host: Pig.

Accidental host: Man.

Reservoirs: Pig, monkey, and rat.

Infective form: Cyst.

Mode of transmission:

- Balantidiasis is a zoonosis. Human beings acquire infection by ingestion of food and water contaminated with feces containing the cysts of *B. coli*.
- Infection is acquired from pigs and other animal reservoirs or from human carriers.
- Once the cyst is ingested, **excystation** occurs in the small intestine (Fig. 10.2).
- From each cyst, a single trophozoite is produced which migrates to large intestine
- Liberated trophozoites multiply in the large intestine by **transverse binary fission**. Sexual union by **conjugation** also occurs infrequently, during which reciprocal exchange of nuclear material takes place between 2 trophozoites enclosed within a single cyst wall.
- **Encystation** occurs as the trophozoite passes down the colon or in the evacuated stool. In this process, the cell rounds up and secretes a tough cyst wall around it.
- The cysts remain viable in feces for a day or 2 and may contaminate food and water, thus it is transmitted to other human or animals.

Pathogenesis

In a healthy individual, *B. coli* lives as **lumen commensal** and is asymptomatic.

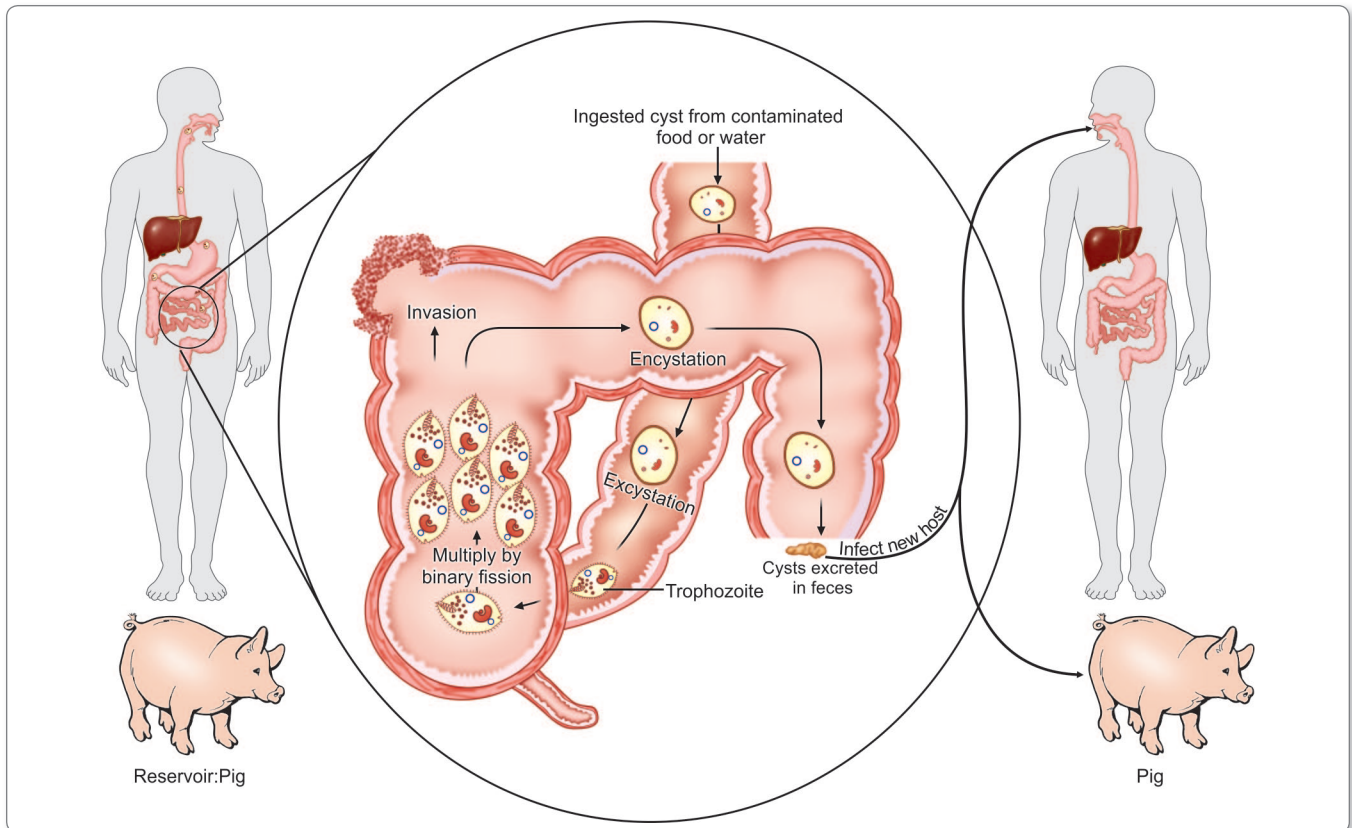


Fig. 10.2: Life cycle of *Balantidium coli*

- Clinical disease occurs only when the resistance of host is lowered by predisposing factors like malnourishment, alcoholism, achlorhydria, concurrent infection by *Trichuris trichiura*, or any bacterial infection.
- Clinical disease results when the trophozoites burrow into the intestinal mucosa, set up colonies, and initiate inflammatory reaction. This leads to mucosal ulcers and submucosal abscesses, resembling lesions in amoebiasis
- Unlike *E. histolytica*, *B. coli* does not invade liver or any other extraintestinal sites.

Clinical Features

Most infections are asymptomatic.

- Symptomatic disease or **balantidiasis** resembles amoebiasis causing diarrhea or frank dysentery with abdominal colic, tenesmus, nausea, and vomiting.
- *Balantidium* ulcers may be secondarily infected by bacteria.
- Occasionally, intestinal perforation peritonitis and even death may occur.
- Rarely, there may be involvement of genital and urinary tracts.
- In chronic balantidiasis, patients have diarrhea alternating with constipation.

Laboratory Diagnosis

Stool Examination

Diagnosis of *B. coli* infection is established by demonstration of trophozoites and cysts in feces.

- Motile trophozoites occur in diarrheic feces and cysts are found in formed stools.
- The trophozoites can be easily recognized by their large size, macronucleus, and rapid-revolving motility.
- The cysts can also be recognized in the formed stools by their round shape and presence of large macronucleus.

Biopsy

When stool examination is negative, biopsy specimens and scrapings from intestinal ulcers can be examined for presence of trophozoites and cysts.

Culture

B. coli can also be cultured *in vitro* in Locke's egg albumin medium or NIH polyxenic medium like *Entamoeba histolytica*, but it is rarely necessary.



Parasites which can be cultured in laboratory

- *Balantidium coli*
- *Acanthamoeba* spp.
- *Trichomonas vaginalis*
- *Leishmania* spp.
- *Entamoeba histolytica*
- *Giardia lamblia*
- *Trypanosoma* spp.

Treatment

Tetracycline is the drug of choice and is given 500 mg, 4 times daily for 10 days. Alternatively Doxycycline can be given. Metronidazole and nitroimidazole have also been reported to be useful in some cases.

Prophylaxis

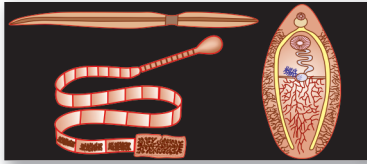
- Avoidance of contamination of food and water with human or animal feces.
- Prevention of human-pig contact.
- Treatment of infected pigs.
- Treatment of individuals shedding *B. coli* cysts.

Key points of *Balantidium coli*

- It is the only ciliate parasite of humans
- Largest protozoan parasite residing in large intestine.
- It occurs in 2 stages: trophozoite and cyst.
- Trophozoite is oval shaped with a slightly pointed anterior end with a groove, peristome leading to the mouth, cytostome. Rounded posterior end has a small anal pore, cytopygge and has a large kidney-shaped macronucleus and small micronucleus.
- **Cyst:** It is the infective stage of the parasite.
- **Mode of infection:** Infection is acquired from pigs and other animals by ingestion of cysts in contaminated food and drink.
- Infection leads to mucosal ulcers and submucosal abscess in intestine.
- **Clinical features:** Most infections are asymptomatic. In mild infections, it causes diarrhea, abdominal colic, tenesmus, nausea, and vomiting.
- **Diagnosis:** Based on demonstration of trophozoites and cysts in feces and examination of biopsy specimens and scrapings from intestinal ulcers.
- **Treatment:** Tetracycline is the drug of choice.
- **Prophylaxis:** Avoiding contamination of food and water and treatment of infected pigs and persons.

Review Questions

1. Write short notes on the morphology of *Balantidium coli* along with suitable illustration.
2. Discuss briefly the life cycle and laboratory diagnosis of *Balantidium coli*.



Helminths: 11 General Features

Introduction

The helminthic parasites are **multicellular** (metazoa) **bilaterally symmetrical** animals having **3** germ layers (**triploblastic metazoa**) and belong to the kingdom Metazoa.

- The term '*helminth*' (Greek *helmins*-'*worm*') originally referred to intestinal worms, but now comprises many other worms, including tissue parasites as well as many free-living species.
- Helminths, which occur as parasite in humans belong to 2 phyla:
 - Phylum Platyhelminthes (flatworms) – It includes 2 classes:
 - Class – Cestoda (tapeworms)
 - Class – Trematoda (flukes or digeneans)
 - Phylum Nematelminthes – It includes class nematoda and 2 subclasses:
 - Subclass – Adenophorea (Aphasmidia)
 - Subclass – Secernentea (Phasmidia).
- The differences between cestodes, trematodes, and nematodes have been summarized in Table 11.1.

Phylum Platyhelminthes

The platyhelminths are **tape-like**, dorsoventrally flattened worms.

- They either lack alimentary canal (as in cestodes) or their alimentary canal is incomplete, lacking an anus (as in trematodes).

- Body cavity is absent, viscera is suspended in gelatinous matrix.
- They are mostly **hermaphrodites (monoecious)**.
- Phylum Platyhelminthes includes 2 classes:
 - Class – Cestoda
 - Class – Trematoda.

Class Cestoda

Cestodes have tape-like, **dorsoventrally flattened**, segmented bodies.

- They do not possess an alimentary system.
- The head carries suckers and some also have hooks.
- They possess scolex, neck, and proglottids.
- They are monoecious and body cavity is absent.
- They are oviparous.

Class Trematoda

Trematodes have flat or fleshy, leaf-like unsegmented bodies.

- The alimentary canal is present but is incomplete i.e., without an anus.
- They possess suckers but no hooks.
- The sexes are separate in the schistosomes, while the other flukes are hermaphroditic.
- They are oviparous.

Phylum Nematelminthes (Nematoda)

Nematodes are elongated, **cylindrical** worms with an unsegmented body.

Table 11.1: Differences Between Cestodes, Trematodes, and Nematodes

	Cestodes	Trematodes	Nematodes
Shape	Tape-like, segmented	Leaf-like unsegmented	Elongated, cylindrical, unsegmented
Head end	Suckers present; some have attached hooks	Suckers are present but no hooks	Hooks and sucker absent. Well-developed buccal capsule with teeth or cutting plates seen in some species
Alimentary canal	Absent	Present but incomplete, no anus	Complete with anus
Body cavity	Absent, but inside is filled with spongy undifferentiated mesenchymatous cells, in the midst of which lie the viscera	Same as cestodes	Present and known as pseudocele . Viscera remains suspended in the pseudocele
Sex	Not separate: hermaphrodite (monecious)	Not separate: hermaphrodite except <i>Schistosoma</i>	Separate (diecious)
Life cycle	Requires 2 host except <i>Hymenolepis</i> (1 host) and <i>Diphyllobothrum</i> (3 host)	Requires 3 host except schistosomes (2 host)	Requires 1 host except filarial worms (2 host) and <i>Dracunculus</i> (2 host)

- They possess a relatively well-developed complete alimentary canal, with an anus.
- Body cavity is present.
- The head does not have suckers or hooks, but may have a buccal capsule with teeth or cutting plates.
- The sexes are separate (**diecious**).
- They are either oviparous or larviparous.

Important Features of Helminths

Adult Worms

Helminths have an outer protective covering, the **cuticle** or integument, which may be tough and armed with spines or hooks. The cuticle of live helminths is resistant to intestinal digestion.

- The mouth may be provided with teeth or cutting plates. Many helminths possess suckers or hooks for attachment to host tissues.
- They do not possess organs of locomotion, but in some species the suckers assist in movement.
- **Locomotion** is generally by muscular contraction and relaxation.
- Many helminths have a primitive nervous system.
- The excretory system is better developed.
- The greatest development is seen in the reproductive system. Helminths may be **monoecious** (with functioning male and female sex organs in the same individual) or **diecious** (the two sexes, male and female, separate). In the hermaphroditic helminths, both male and female reproductive systems are present in the same worm and self-fertilization as well as **cross-fertilization** take place. (e.g. *Taenia solium*) In the diecious species, males

and females are separate, the male being smaller than the female. (e.g. *Ascaris lumbricoides*) Rarely, the female is **parthenogenic**, being able to produce fertile eggs or larvae without mating with males (e.g. *Strongyloides*).

Eggs

The **eggs** or **larvae** are produced in enormous numbers—as many as 200,000 or more per female per day.

Various helminths have distinct morphology of eggs, which can be used to differentiate the helminths (discussed in the respective chapters).

Larval Forms

There are various larval forms of helminths found in man and other hosts. These forms are as follows:

- **Cestodes:** The various larval forms are cysticercus, coenurus, coracidium, cysticercoid, proceroid, hydatid cyst, and plerocercoid forms.
- **Trematodes:** The various larval forms are miracidium, cercaria, redia, metacercaria, and sporocyst.
- **Nematodes:** The various larval forms are microfilaria, filariform larva, and rhabditiform larva.

Multiplication

Helminths differ from protozoans in their inability to multiply in the body of the host. Protozoans multiply in the infected person, so that disease could result from a single infection. But helminths, apart from very rare exceptions, do not multiply in the human body, therefore, a single infection does not generally lead to disease. Heavy worm load follows multiple infections. Sometimes, multiplication occurs within larval forms in Platyhelminths.

Life Cycle

- **Cestodes:** They complete their life cycle in 2 different hosts, except *Hymenolepis nana*, which completes its life cycle in a single host and *Diphyllobothrium latum* which completes its life cycle in 3 hosts.
- **Trematodes:** They complete their life cycle in 1 definitive host (man) and 2 intermediate hosts. Fresh water snail or mollusc act as first intermediate host and fish or crab act as second intermediate host except schistosomes which require 2 hosts – 1 definitive host (man) and other intermediate host (snail).
- **Nematodes:** Nematodes require only 1 host to complete their life cycle except filarial nematodes and *Dracunculus medinensis*, which complete their life cycle in 2 hosts.

Zoological Classification of Helminths**Phylum Platyhelminthes***Class Trematoda*

- Blood flukes (sexes separate, infection by cercarial penetration)
 - **Family:** Schistosomatidae (schistosomes)
- Hermaphroditic flukes (bisexual, infection by ingestion of cercariae)
 - **Family:** Fasciolidae (large flukes; cercariae encyst on aquatic vegetation)
Genus: *Fasciola*, *Fasciolopsis*
 - **Family:** Paramphistomatidae (large ventral sucker posteriorly)
Genus: *Gastrodiscoides*
 - **Family:** Echinostomatidae (collar of spines behind oral sucker; cercariae encyst in mollusc or fish)
Genus: *Echinostoma*

- **Family:** Triglottrematidae (testes side-by-side behind ovary; cercariae encyst in Crustacea)
Genus: *Paragonimus*
- **Family:** Opisthorchidae (testes in tandem behind ovary; cercariae encyst in fish)
Genus: *Clonorchis*, *Opisthorchis*
- **Family:** Dicrocoelida (testes in front of ovary; cercariae encyst in insects)
Genus: *Dicrocoelium*
- **Family:** Heterophyidae (minute flukes; cercarial encyst in fish)
Genus: *Heterophyes*, *Metagonimus*.

Class Cestoda

- **Order:** Pseudophyllidea (Scolex has grooves)
Genus: *Diphyllobothrium*
- **Order:** Cyclophyllidea (Scolex has suckers)
 - **Family:** Taeniidae, (Proglottid longer than broad; numerous testes; one genital pore; larva in vertebrates)
Genus: *Taenia*, *Multiceps*, *Echinococcus*
 - **Family:** Hymenolepididae (transverse proglottids; one genital pore; larva in insects)
Genus: *Hymenolepis*
 - **Family:** Dilepididae (Two genital pores)
Genus: *Dipylidium*.

Phylum Nematelminthes

It includes class nematoda which is further divided into:

- **Subclass:** Adenophorea or Aphasmdia (no phasmids; no caudal papillae in male)
- **Subclass:** Secernentea or Phasmidia (phasmids present; numerous caudal papillae).

Detailed classification of class Nematodas is given in chapter 14.

Review Questions**1. Short notes on:**

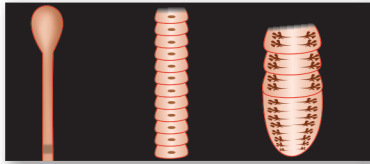
(a) General features of helminths

(b) Phylum Nematoda

2. Differentiate between:

(a) Trematodes and nematodes

(b) Cestodes and nematodes



Cestodes: Tapeworms 12

Cestodes (Greek *kestos*—*girdle or ribbon*) are multi-segmented, dorsoventrally flattened tape-like worms whose sizes vary from a few millimeters to several meters. The adult worms are found in the small intestine of humans.

Classification of Cestodes

Systemic Classification

Cestodes belong to Phylum Platyhelminthes and class Cestoidea. The class Cestoidea includes 2 orders:

- Pseudophyllidea
- Cyclophyllidea

For detailed classification see Table 12.1.

Classification of Cestodes Based on the Form of Parasite Important to Man

The detailed classification is given in Table 12.2.

Tapeworms: General Characteristics

Adult Worms

- The adult worm consists of 3 parts:
 - Head (scolex)
 - Neck
 - Trunk (strobila) (Fig. 12.1).

Head (Scolex)

It is the organ of attachment to the intestinal mucosa of the definitive host, human or animal (Fig. 12.1).

- In parasites of the order cyclophyllidea, the scolex possesses **4 suckers** (or **acetabula**). In some cyclophyllidea like *Taenia solium*, scolex has an apical protrusion called as the **rostellum**. The rostellum may or may not be armed with hooks.

Table 12.1: Classification of Medically Important Cestodes

Order	Family	Genus
Pseudophyllidea	Diphyllobothriidae	<i>Diphyllobothrium</i> <i>Spirometra</i>
Cyclophyllidea	Taeniidae	<i>Taenia</i> <i>Echinococcus</i>
	Hymenolepididae	<i>Hymenolepis</i>
	Dipylidiidae	<i>Dipylidium</i>

Table 12.2: Classification of Cestodes Based on the Form of Parasite Important to Man

Order	Adult worm seen in human intestine	Larval stage seen in humans
Pseudophyllidea	<i>Diphyllobothrium latum</i> , the fish tapeworm	<ul style="list-style-type: none"> • <i>Spirometra mansoni</i> • <i>Spirometra theileri</i> • <i>Spirometra erinace</i> (larval stage causing sparganosis)
Cyclophyllidea	<ul style="list-style-type: none"> • <i>Taenia saginata</i>, the beef tapeworm • <i>Taenia solium</i>, the pork tapeworm • <i>Hymenolepis nana</i>, the dwarf tapeworm • <i>Hymenolepis diminuta</i>, the rat tapeworm (rare) • <i>Dipylidium caninum</i>, the double-pored dog tapeworm (rare) 	<ul style="list-style-type: none"> • <i>Taenia solium</i>, the pork tapeworm (larval form can cause cysticercus cellulosae) • <i>Echinococcus granulosus</i>, the dog tapeworm (Larval form causes hydatid disease in man) • <i>Echinococcus multilocularis</i> (larval stage causes alveolar or multilocular hydatid disease) • <i>Multiceps multiceps</i> and other species (larval stage may cause coenurosis in man)

- In parasites of the order pseudophyllidea, the scolex does not possess suckers but possesses a pair of longitudinal grooves called as **bothria**, by which it attaches to the intestine of the host.

Neck

It is the part, immediately behind the head and is the region of growth from where the segments of the body (proglottids) are being generated continuously.

Trunk (strobila)

The trunk also called as **strobila** is composed of a chain of *proglottids* or *segments* (Fig. 12.1).

- The proglottids near the neck, are the young **immature** segments, behind them are the **mature** segments, and at the hind end, are the **gravid** segments.
- Tapeworms are **hermaphrodites (monoecious)** and every mature segment contains both male and female

sex organs. In the immature segments, the reproductive organs are not well-developed. They are well-developed in the mature segments. The gravid segments are completely occupied by the uterus filled with eggs.

- Tapeworms do not have a body cavity or alimentary canal
 - Rudimentary excretory and nervous systems are present.
- The differences between heads and proglottids of various Cestodes has been illustrated in Figure 12.2.

Eggs

The eggs of Cyclophyllidea and Pseudophyllidea are different from each other (Table 12.3).

Table 12.3: Differences Between Eggs of Orders Cyclophyllidea and Pseudophyllidea

Cyclophyllidean egg	Pseudophyllidean egg
<ul style="list-style-type: none"> • Covered by 2 layers: egg shell and embryophore • Spherical • Embryonated from the beginning • Eggs are not operculated and the embryo is not ciliated 	<ul style="list-style-type: none"> • Covered by 1 layer: egg shell • Ovoid in shape • Freshly passed eggs in feces are unembryonated. • Eggs are operculated and the embryo is ciliated

- The embryo inside the egg is called the **oncosphere** (meaning '**hooked ball**') because it is spherical and has hooklets.
- Oncospheres of human tapeworms typically have 3 pairs of hooklets and so, are called **hexacanth** (meaning **6-hooked**) embryos.

Life Cycle

Cestodes complete their life cycle in 2 hosts: definitive host and intermediate host.

- **Humans** are the **definitive host** for most tapeworms, which cause human infection. An important exception is the dog tapeworm, *Echinococcus granulosus*, for which

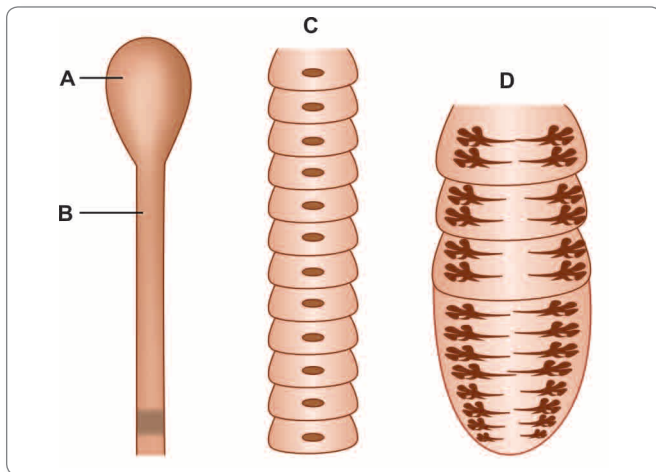


Fig. 12.1: Tapeworm. **A.** Scolex or head; **B.** Neck, leading to the region of growth below, showing immature segments; **C.** Mature segments; **D.** Gravid segments filled with eggs





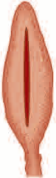







	<i>Taenia solium</i>	<i>Taenia saginata</i>	<i>Hymenolepis nana</i>	<i>Hymenolepis diminuta</i>	<i>Diphyllobothrium latum</i>	<i>Echinococcus granulosus</i>
Heads						
Proglottids	4 suckers 2 rows of hooks 	4 suckers No hooks 	4 suckers single row of 20-30 hooks 	4 suckers No hooks 	2 Suctorial grooves or bothria No suckers, No hooks 	4 suckers 2 rows of hooks 
	Longer than broad 7-12 uterine branches on each side	Longer than broad 15-30 uterine branches on each side	Broader than long	Broader than long	Broader than long Uterus coiled	Longer than broad

Fig. 12.2: Differences between heads and proglottids of various Cestodes

dog is the definitive host and man is the intermediate host. In *Taenia solium*, man is ordinarily the definitive host, but its larval stages also can also develop in the human body.



Cestodes complete their life cycle in 2 different hosts. Exceptions are:

Hymenolepis that requires only 1 host, man and *Diphyllobothrium* that requires 3 hosts, **definitive host:** man; **first intermediate host:** cyclops; and **second intermediate host:** fish.

- Clinical disease can be caused by the adult worm or the larval form. In general, adult worm causes only minimal disturbance, while the larvae can produce serious illness, particularly when they lodge in critical areas like the brain or the eyes.

- Pseudophyllidean tapeworms have a central **un-branched convoluted uterus**, which opens through a pore, possess ventrally situated genital pores, and produce operculated eggs that give rise to **ciliated larvae**
- In Cyclophyllidean tapeworms, the uterus is **branched** and does not have an opening. They have lateral genital pores and produce non-operculated eggs that yield larvae, which are not ciliated. Their larvae are called '**bladder worms**' and occur in 4 varieties, **cysticercus**, **cysticercoid**, **coenurus**, and **echinococcus**.

PSEUDOPHYLLIDEAN TAPEWORMS

Diphyllobothrium Latum

Common name: Fish tape worm/Broad tape worm

History and Distribution

The head of the worm was found by Bonnet in 1777, and its life cycle was worked out by Janicki and Rosen in 1917.

- Diphyllobothriasis (infection with *Diphyllobothrium*) occurs in central and northern Europe, particularly in the Scandinavian countries. It is also found in Siberia, Japan, North America, and Central Africa.
- In countries like India, where fish is eaten only after cooking, the infection does not occur.



Longest cestode infecting man: *Diphyllobothrium latum*

Smallest cestode infecting man: *Hymenolepis nana*

Habitat

The adult worm is found in the small intestine, usually in the ileum, where it lies folded in several loops with the scolex embedded in the mucosa.

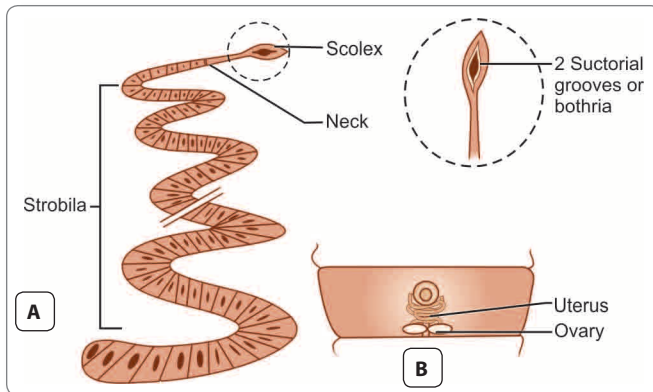


Fig. 12.3: *Diphyllobothrium latum* **A.** Adult worm showing spatulate scolex, neck, and strobila **B.** Mature proglottid

Morphology

Adult worm

It is **ivory-colored** and very long, measuring upto 10 meters or more. It is the **largest tape worm** inhabiting the small intestine of man.

- As in all cestodes, the adult worm has 3 parts: scolex, neck, and strobila.
- **Scolex** (head) is **spatulate** or **spoon-shaped**, about 2–3 mm long and 1 mm broad. It carries 2 slit-like longitudinal sucking grooves (**bothria**), one dorsal and the other ventral. The scolex lacks suckers and hooks (Fig. 12.3A).
- Neck is thin, unsegmented and is much more longer than the head.
- **Strobila** consists of 3,000–4,000 proglottids, consisting of immature, mature, and gravid segments in that order from front to backwards.
- The mature proglottid is broader than long, about 2–4 mm long and 10–20 mm broad and is practically filled with male and female reproductive organs (Fig. 12.3B).
- The testes are represented by numerous minute follicles situated laterally in the dorsal plane.
- The female reproductive organs are arranged along the midline, lying ventrally. The ovary is **bilobed**. The large rosette-like uterus lies convoluted in the center.
- Three genital openings are present ventrally along the midline—the openings of the vas deferens, vagina, and uterus in that order, from front backwards.
- The fertilized ova develop in the uterus and are discharged periodically through the uterine pore.
- The terminal segments become dried up after delivering many eggs and are discharged in strands of varying lengths in the feces.

Egg

D. latum is a prolific egg layer and a single worm may pass about a million eggs in a day.

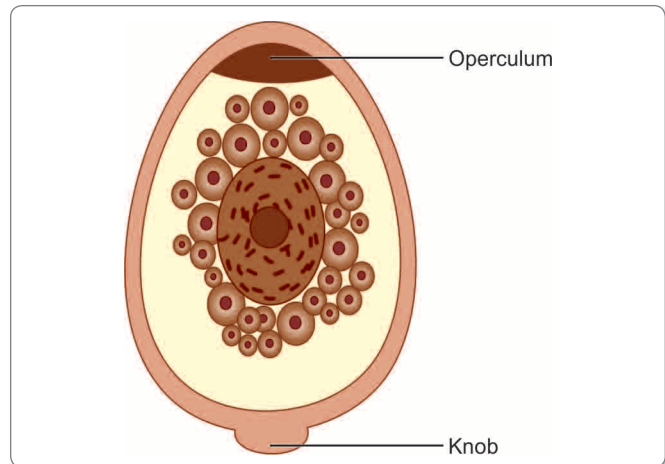


Fig. 12.4: Operculated egg of *Diphyllobothrium latum*

- Egg is broadly ovoid, about 65 μm by 45 μm , with a thick, light brown shell (Fig. 12.4).
- It has an **operculum** at one end and often a **small knob** at the other.
- The freshly passed egg contains an immature embryo surrounded by yolk granules. The eggs are resistant to chemicals but are killed by drying. The embryo with **6 hooklets** inside the egg is called the **oncosphere**.
- The egg **does not float** in saturated salt solution and is bile stained.
- They are not infective to humans.

Larval Stages

There are 3 stages of larval development:

- First stage larva (**coracidium**)
- Second stage larva (**proceroid**)
- Third stage larva (**plerocercoid**).

Life Cycle

Definitive hosts: Man, dog, and cat. Man is the optimal host.

First intermediate host: Fresh water copepod, mainly of genera *Cyclops* or *Diaptomus*.

Second intermediate host: Fresh water fish (salmon, trout etc.).

Infective form to human: Third stage plerocercoid larva.

- The adult worm lives in the small intestine. It lays operculated eggs which are passed along with the feces in water (Fig. 12.5).
- The freshly-passed egg contains an immature embryo surrounded by yolk granules. The embryo with 6 hooklets (**hexacanth embryo**) inside the egg is called the **oncosphere**.
- In water, it matures in about 10–15 days and **ciliated first stage larva**, called **coracidium** emerges through the operculum.

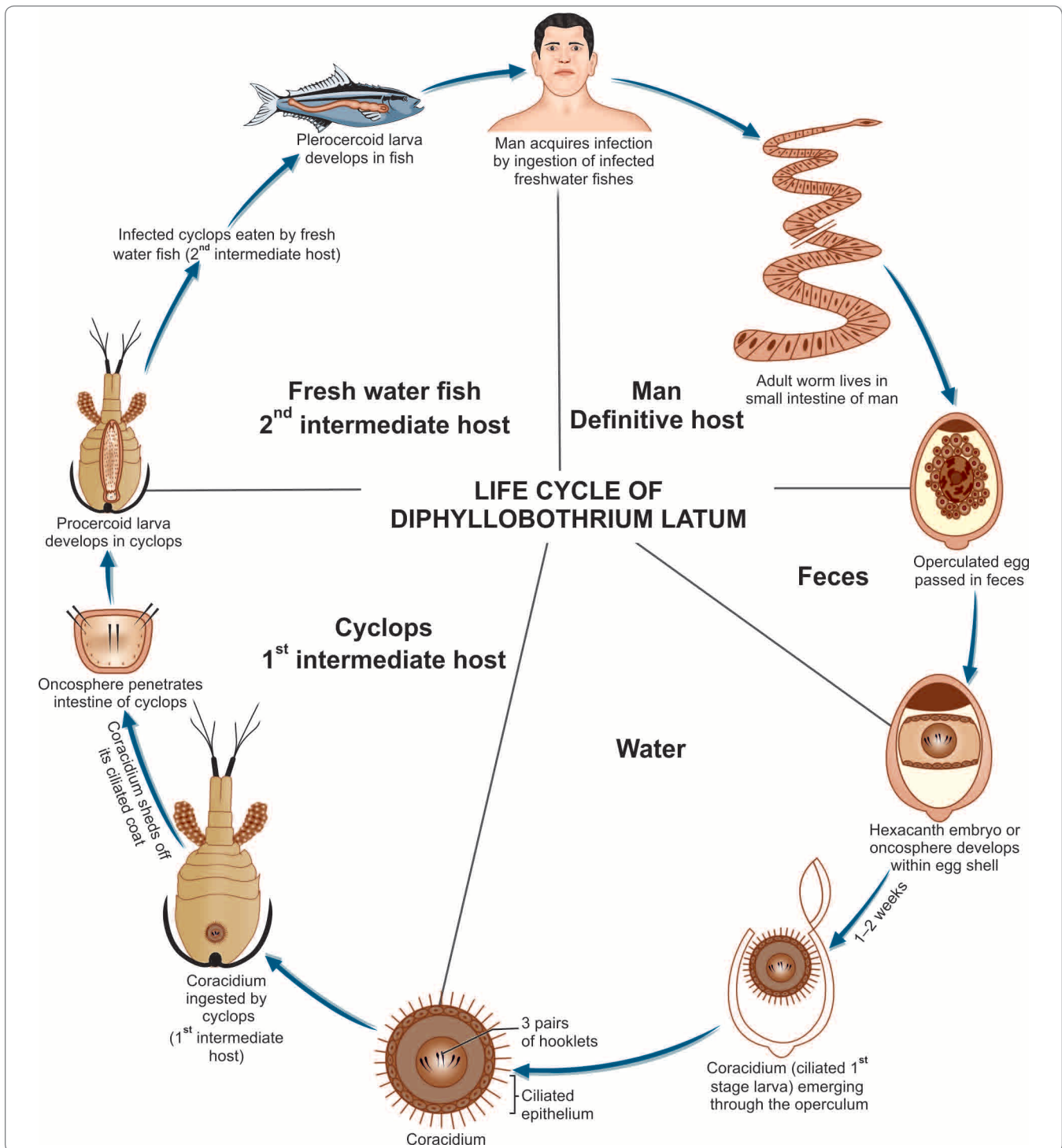


Fig. 12.5: Life cycle of *Diphyllobothrium latum*

- Coracidium (first stage larva) can survive in water for about 12 hours, by which time it should be ingested by the fresh water crustacean copepod *cyclops*, which is the first intermediate host (Fig. 12.5).
- In the midgut of the cyclops, the coracidium casts off its ciliated coat and by means of its 6 hooklets, penetrates into the hemocele (body cavity). In about 3 weeks, it becomes transformed into the **elongated second stage**

larva about 550 µm long, which is called the **proceroid larva**.

- Proceroid larva has a rounded caudal appendage (**cercomer**) which bears the now useless hooklets.
- If the infected cyclops is now eaten by a freshwater fish (second intermediate host), the proceroid larva penetrates the intestine of the fish and grows.
- In the fish, proceroid larva loses its caudal appendage and develops into the **third stage larva** called the **plerocercoid larva** or **sparganum** (Fig. 12.5).
- *Plerocercoid* larva has a glistening white flattened unsegmented vermicule, with a wrinkled surface, is about 1–2 cm long, and possesses rudimentary scolex. This is the stage **infective** for humans.
- Man gets infection by eating raw or under-cooked fish containing plerocercoid larva.
- The larva develops into adult worm in the small intestine
- The worm attains maturity in about 5–6 weeks and starts laying eggs, which are passed along with the feces. The cycle is thus repeated.
- The adult worm may live for about 10 years or more.

Pathogenicity and Clinical Features

The pathogenic effects of **diphyllobothriasis** depend on the mass of the worm, absorption of its byproducts by the host, and deprivation of the host's essential metabolic intermediates.

- In some persons, infection may be entirely asymptomatic, while in others there may be an evidence of mechanical obstruction.
- Transient abdominal discomfort, diarrhea, nausea, weakness, weightloss, and anemia are the usual manifestations. Patients may be frightened by noticing the strands of proglottids passed in their feces.
- A kind of pernicious anemia, sometimes caused by the infection, is called **bothriocephalus anemia**. This was formerly believed to be racially determined, being common in Finland and rare elsewhere. The anemia develops because the tape worm absorbs large quantity of vit B₁₂ and interferes with its ileal absorption, leading to **vit B₁₂ deficiency**.
- In severe cases, patients may exhibit neurologic sequelae of vit B₁₂ deficiency.

Laboratory Diagnosis

Stool Microscopy

Eggs are passed in very large number in feces, and therefore, their demonstration in feces offers an easy method of

diagnosis. The Proglottids passed in feces can also be identified by their morphology.

Serodiagnosis

A coproantigen detection test is available to diagnose diphyllobothriasis.

Treatment

- Praziquantel in a single dose of 10 mg/kg is effective.
- Parenteral vit B₁₂ should be given, if B₁₂ deficiency is present.

Prophylaxis

Infection can be prevented by

- Proper cooking of fish
- Deep freezing (–10°C for 24–48 hours) of fish, if it is to be consumed raw
- Prevention of fecal pollution of natural waters
- Periodical deworming of pet dogs and cats.

Key points of *Diphyllobothrium latum*

- Longest tapeworm found in man
- Adult worm upto 10 m in length having spoon-shaped head with 2 slit-like grooves (bothria)
- **Definitive host:** Man (optimal host), dogs and cats
- **First intermediate host:** Cyclops
- **Second intermediate host:** Fresh water fish
- Eggs are oval, operculated, bile stained and not infective to man
- **Infective stage:** Plerocercoid larva
- **Mode of transmission:** Man gets infection by consuming uncooked or undercooked fish containing third stage plerocercoid larva
- **Clinical features:** Abdominal discomfort, nausea, and megaloblastic anemia
- **Diagnosis:** Stool microscopy for egg and coproantigen test
- **Treatment:** Praziquantel and if required, vitamin B₁₂.

Spirometra

Genus *Spirometra* belongs to Diphylobothriidae family. Species of this genera which are medically important are—*S. mansoni*, *S. theileri*, and *S. erinacei*.

- *Spirometra* along with other *Diphyllobothrium* tapeworms that are not normal human parasite, can accidentally infect man and cause disease called as **sparganosis**.

- The disease is so named because it is caused by **sparganum (plerocercoid larva)** of the parasite.

Distribution

Sparganosis has been reported mostly from Japan and South-east Asia; less often from America and Australia. A few cases have been reported from India also.

Habitat

Adult worms live in the intestinal tract of cats and dogs.

Life Cycle

Definitive host: Dog and cat

First intermediate host: Cyclops

Second intermediate host: Snakes, frogs, and fishes

- Adult worms live in the intestinal tract of dogs and cats and produce large number of eggs which pass out along with feces in water (Fig. 12.6).

- Eggs hatch in fresh water to release ciliated **first stage larva** called as **coracidium**.
- The coracidium is ingested by cyclops (first intermediate host), where it develops into **second stage larva** called as **proceroid larva**.
- When the infected cyclop is ingested by fish, snakes, amphibians (second intermediate host), the proceroid larva migrates to various organs of the body and develops into **plerocercoid larva (sparganum larva)**. This is the **infective stage** of the larva for dogs and cats (definitive host) (Fig. 12.6).
- When a cat or dog eats the second intermediate host, the plerocercoid larva develops into adult worms in the intestine.
- Man acts as an **accidental host** and gets infection by
 - Ingestion of cyclops containing proceroid larva.
 - Ingestion of plerocercoid larva present in uncooked meat of animals or birds, frogs.
 - Local application of raw flesh of infected animals on skin or mucosa. The last method follows the practice

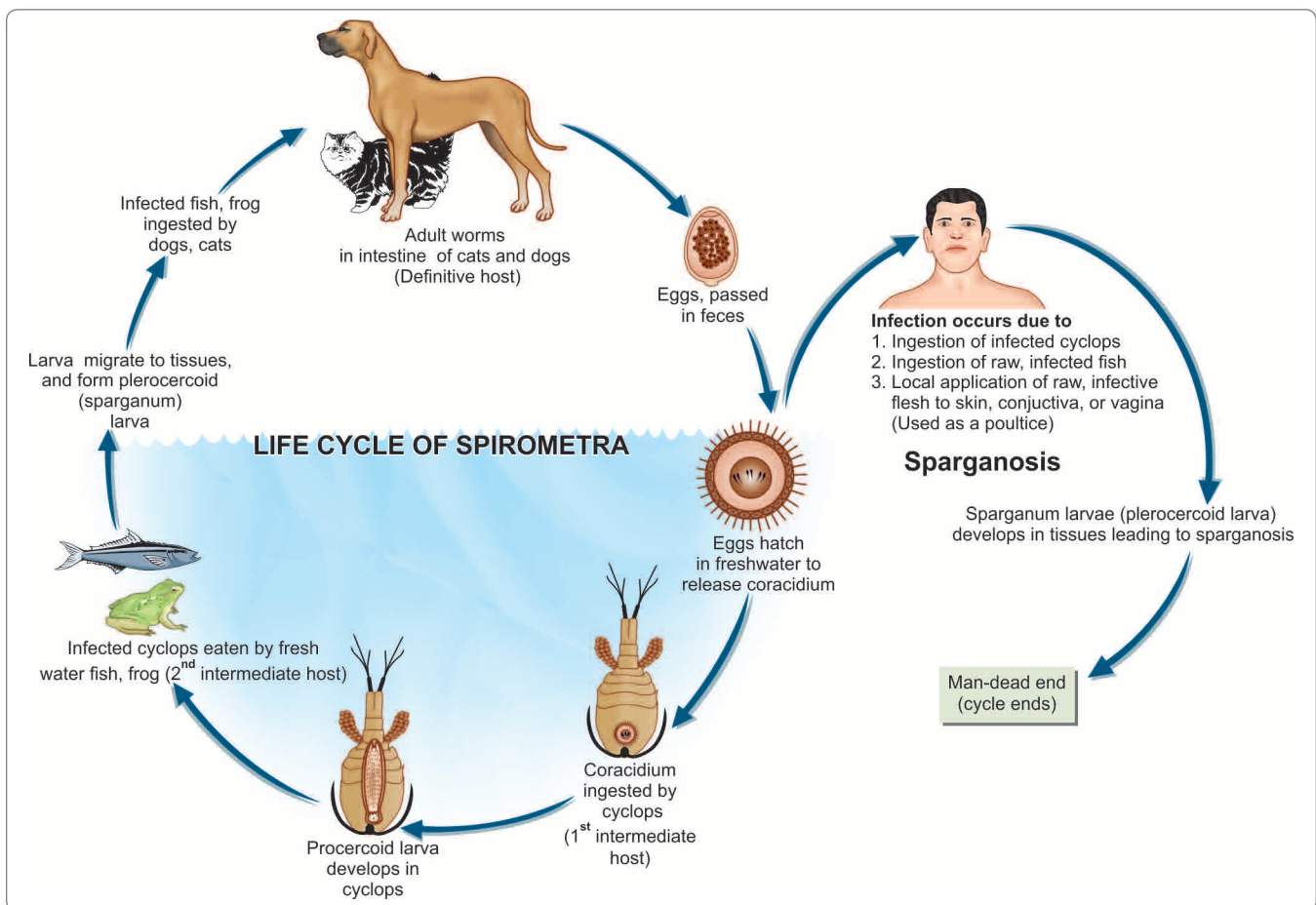


Fig. 12.6: Life cycle of *Spirometra*

prevalent among the Chinese, of applying split frogs on skin or eye sores as a poultice.

Sparganosis

The term sparganosis is used for ectopic infection by sparganum (plerocercoid larva) of *Spirometra* and some *Diphyllobothrium* species.

- The **sparganum** (L3 larva) are liberated from the cyclops in the human intestine. They penetrate the intestinal wall and migrate to subcutaneous tissue, where they become encysted and develop into **spargana**.
- The sparganum is usually found in the subcutaneous tissues in various parts of the body, but may also be present in the peritoneum, abdominal viscera, or brain.

Laboratory Diagnosis

Diagnosis is usually possible only after surgical removal of the nodules and demonstration of the worm.

Treatment

Definitive treatment is surgical removal of the nodule.

Prophylaxis

Humans sparganosis is prevented by

- Properly filtering and boiling drinking water
- Eating properly cooked flesh.

CYCLOPHYLLIDEAN TAPEWORMS

Taenia Saginata and Taenia Solium

Common name

Taenia saginata - Beef tapeworm

Taenia solium - Pork tapeworm

History and Distribution

T. saginata has been known as an intestinal parasite of man from very ancient times. But it was only in 1782 when Goeze differentiated it from the pork tapeworm, *T. solium*. Its life cycle was elucidated when Leuckart, in 1861, first experimentally demonstrated that cattle serve as the intermediate host for the worm.

- The name *Taenia* is derived from the Greek word meaning *tape or band*. It was originally used to refer to most tapeworms, but is now restricted to the members of the Genus *Taenia*.
- *T. saginata* is worldwide in distribution, but the infection is not found in vegetarians and those who do not eat beef.

- *T. solium* is also worldwide in distribution except in the countries and communities, which proscribe pork as taboo.

Habitat

The adult worms of both *T. saginata* and *T. solium* live in the human small intestine, commonly in the jejunum.



Cestodes living in small intestine

- *Diphyllobothrium latum*
- *Taenia solium*
- *Taenia saginata saginata*
- *Taenia saginata asiatica*
- *Hymenolepis nana*

Morphology

Adult Worm of T. saginata

The adult *T. saginata* worm is opalescent white in color, ribbon-like, dorsoventrally flattened, and segmented, measuring 5–10 m in length.

- The adult worm consists of head (scolex), neck, and strobila (body). The general features of adult worm are similar to any cyclophyllidean cestodes.
- **Scolex:** The scolex (head) of *T. saginata* is about 1–2 mm in diameter, quadrate in cross-section, bearing 4 hemispherical suckers situated at its four angles. They may be pigmented. The scolex has no rostellum or hooklets (which are present in *T. solium*). *T. saginata* is, therefore called the **unarmed tape worm**. The suckers serve as the sole organ for attachment (Fig. 12.7).
- The neck is long and narrow. The strobila (trunk) consists of 1000 to 2000 proglottides or segments—immature, mature and gravid.
- The gravid segments are nearly four times as they are broad, about 20 mm long and 5 mm broad. The segment contains male and female reproductive structures. The testes are numerous, 300 to 400 (twice as many as in *T.*

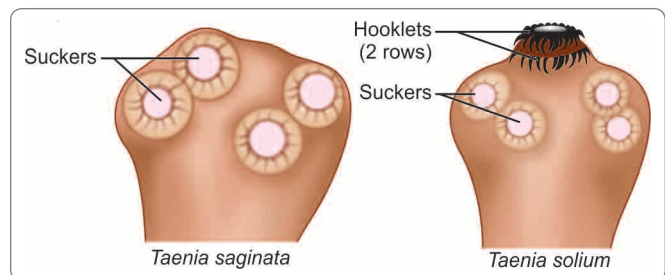


Fig. 12.7: Scolex of *Taenia saginata* and *Taenia solium*

solium. The gravid segment has 15 to 30 lateral branches (as against 7 to 13 in *T. solium*). It differs from *T. solium* also in having a prominent vaginal sphincter and in lacking the accessory ovarian lobe. The common genital pore opens on the lateral wall of the segments.

- The gravid segments break away and are expelled singly, actively forcing their way out through the anal sphincter. As there is no uterine opening, the eggs escape from the uterus through its ruptured wall.

Adult Worm of *T. solium*

- The adult worm is usually 2-3 meters long.
- The scolex of *T. solium* is small and globular about 1 mm in diameter, with 4 large cup-like suckers (0.5 mm in diameter), and a conspicuous rounded rostellum, armed with a double row of alternating round and small **dagger-shaped** hooks, 20–50 in number.
- The neck is short and half as thick as the head.
- The proglottides number less than a thousand. They resemble those of *T. saginata* in general. The gravid segments are twice as long as broad, 12 mm by 6 mm. The testes are composed of 150 to 200 follicles. There is an accessory lobe for the ovary. The vaginal sphincter is absent. The uterus has only 5 to 10 (under 13) thick lateral branches. A lateral thick-lipped genital pore is present, alternating between the right and left sides of adjacent segments.
- The gravid segments are not expelled singly, but pass passively out as short chains. The eggs escape from the ruptured wall of the uterus.

The other differentiating features of *T. saginata* and *T. solium* are given in Table 12.4.

Eggs

Eggs of both species are indistinguishable.

- The egg is **spherical**, measuring 30–40 μm in diameter.
- It has a thin hyaline embryonic membrane around it, which soon disappears after release.
- The **inner embryophore** is radially striated and is yellow-brown due to **bile staining** (Fig. 12.8).
- In the center is a fully-developed embryo (**oncosphere**) with 3 pairs of hooklets (**hexacanth embryo**).
- The eggs do not float in saturated salt solution.
- The eggs of *T. saginata* are infective only to cattle and not to humans, whereas the eggs of *T. solium* are infective to pigs and humans too.

Larva

The larval stage of *Taenia* is called as **cysticercus**.

- *Cysticercus bovis* is the larva of *T. saginata* (Fig. 12.9).
- *Cysticercus cellulosae* is the larva of *T. solium* (Fig. 12.11).

Table 12.4: Difference between *Taenia saginata* and *Taenia solium*

	<i>Taenia saginata</i>	<i>Taenia solium</i>
Length	5–10 m	2–3 m
Scolex	Large quadrate	Small and globular
	Rostellum and hooks are absent	Rostellum and hooks are present
	Suckers may be pigmented	Suckers not pigmented
Neck	Long	Short
Proglottids	1,000–2,000	Below 1,000
Measurement (gravid segment)	20 mm × 5 mm	12 mm × 6 mm
Expulsion	Expelled singly	Expelled passively in chains of 5 or 6
Uterus	Lateral branches 15–30 on each side; thin and dichotomous	Lateral branches 5–10 on each side; thick and dendritic
Vagina	Present	Absent
Accessory lobe of ovary	Absent	Present
Testes	300–400 follicles	150–200 follicles
Larva	<i>Cysticercus bovis</i> ; present in cow not in man	<i>Cysticercus cellulosae</i> ; present in pig and also in man
Egg	Not infective to man	Infective to man
Definitive host	Man	Man
Intermediate host	Cow	Pig, occasionally man
Disease	Causes intestinal taeniasis	Causes intestinal taeniasis and cysticercosis

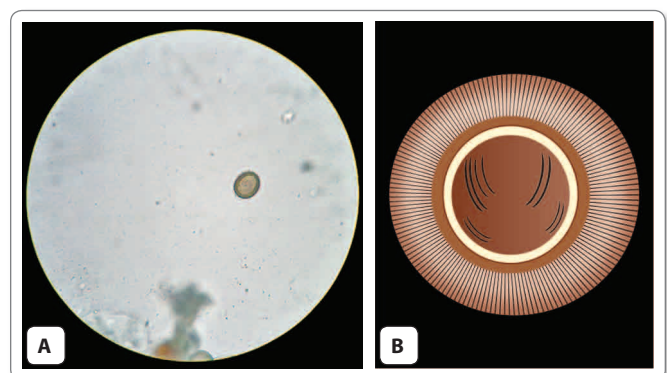


Fig. 12.8: Egg of *Taenia*. A. As seen under microscope; B. Schematic diagram

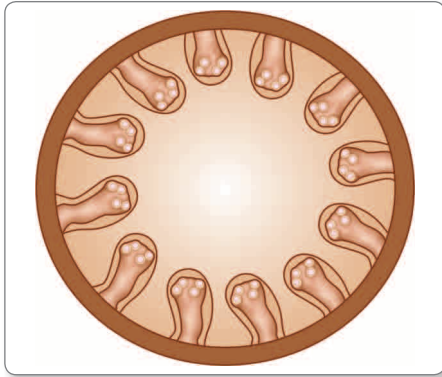


Fig. 12.9: Schematic diagram showing cysticercus bovis in muscle




Fig. 12.10: Cysticerci in muscles (measly pork)

Cysticercus bovis

- It is the larval form of *T. saginata*.
- The name cysticercus is derived from the Greek, *kystis—bladder and kerkos—tail*.
- The larva (*cysticercus bovis*) is **infective stage** for humans.
- The cysticercus is an ovoid, milky-white opalescent fluid-filled vesicle measuring about 5 mm × 10 mm in diameter, and contains a single invaginated scolex (**bladder worm**).
- The cysticerci are found in the muscles of mastication, cardiac muscles, diaphragm and tongue of infected cattle (Fig.12.9).
- They can be seen on visual inspection as shiny white dots in the **infected beef (measly beef)** (Fig. 12.10).
- *Cysticercus bovis* is unknown in humans.

Cysticercus cellulosae

- It is the larval form of *T. solium* and also the **infective form** of the parasite.
- It can develop in various organs of pig as well as in man.



Fig. 12.11: *Cysticercus cellulosae*

- The *cysticercus cellulosae* or '**bladder worm**' is ovoid opalescent milky-white, measuring 8–10 mm in breadth and 5 mm in length.
- The scolex of the larva, with its suckers, lies invaginated within the bladder and can be seen as a thick white spot. It remains viable for several months (Fig. 12.11).

Life Cycle of Taenia Saginata

T. saginata passes its life cycle in 2 hosts (Fig. 12.12).

Definitive host: Humans are the definitive hosts and harbor the adult worm.

Intermediate host: Cattle (cow or buffalo) are the intermediate host and harbor the larval stage of the worm.

Infective stage: *Cysticercus bovis* (larval stage) is the infective stage to man, while eggs are infective to cattle.

- The adult worm lives in the small intestine of man. The gravid segments from the adult worm breakaway and are expelled singly. They actively force their way out through the anal sphincter.
- The eggs or gravid segments are passed out with feces on the ground.
- The eggs deposited in soil remain viable for several weeks.
- They are infective to cattle, which ingest the eggs while grazing.

Development in Cattle

When ingested by cattle (cow or buffalo), the eggshell ruptures releasing onchosphere in the duodenum.

- The onchospheres, with their hooklets penetrate the intestinal wall, reach the mesenteric venules or lymphatics and enter the systemic circulation.
- They get filtered out in the striated muscles, particularly in muscles of the tongue, neck, shoulder, ham, and in the myocardium. In these sites, the onchospheres lose

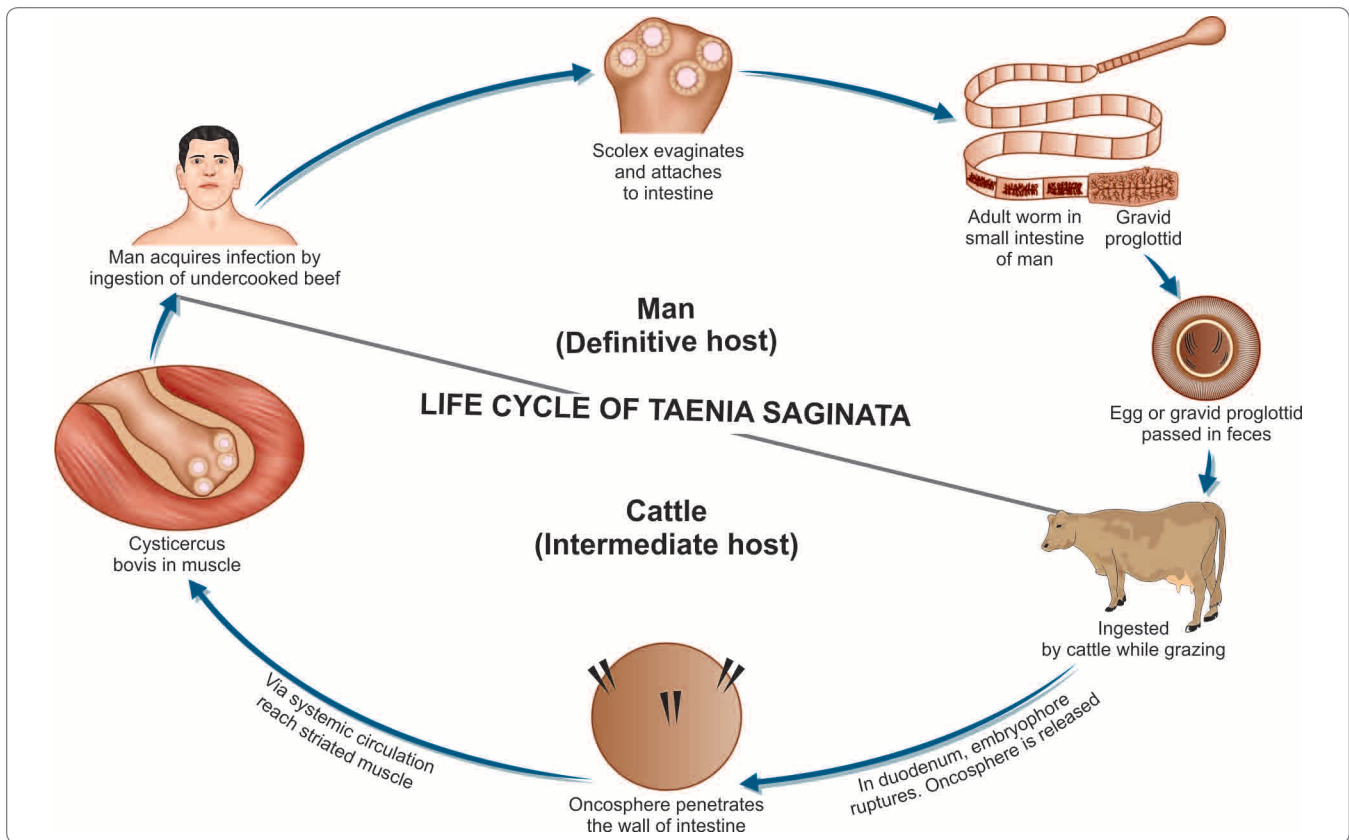


Fig. 12.12: Life cycle of *Taenia saginata*

their hooks and in about 60–70 days develop in the mature larva, **cysticercus bovis**.

- The cysticerci can live in flesh of cattle for about 8 months, but can develop further only when ingested by man, its definitive host.

Development in Man

Man acquires infection by ingesting raw or undercooked beef containing cysticerci (Fig. 12.12).

- The cysticerci are digested out of the meat in the stomach.
- In the upper part of the small intestine, the head (scolex) evaginates out of the cysticercus, becomes attached to the mucosa, and by gradual strobilization develops into the adult worm in about 2–3 months.

The adult worm has a life span of 10 years or more. Infection is usually with a single worm, but sometimes multiple infection is seen and 25 or more worms have been reported in patients.

Life Cycle of *Taenia Solium*

When *T. solium* causes intestinal taeniasis, its life cycle is similar to that of *T. saginata* except (Fig. 12.13).

Definitive host: Man

Intermediate host: Pig

Infective stage: *Cysticercus cellulosae* (larva)

- Humans are infected by consuming inadequately cooked pork containing *cysticercus cellulosae* (measly pork).
- Man harboring adult worms may autoinfect oneself either by unhygienic personal habits or by reverse peristaltic movements of the intestine.

When *Taenia* leads to cysticercosis, the life cycle is as follows:

Definitive host and Intermediate host: Both man

Infective stage: Eggs of *T. solium* (not larva)

- **Mode of infection:** Man acquires infection by ingesting eggs with contaminated food and water.
 - **Autoinfection:** A man harboring adult worm may autoinfect oneself, either by unhygienic personal habits or by reverse peristalsis of the intestine.
- The further development of the eggs is similar in man and pigs.
- The oncospheres are released in the duodenum or jejunum and penetrate the intestinal wall.
- They enter the **mesenteric venules** or **lymphatics** and are carried in systemic circulation to the different parts of the body.

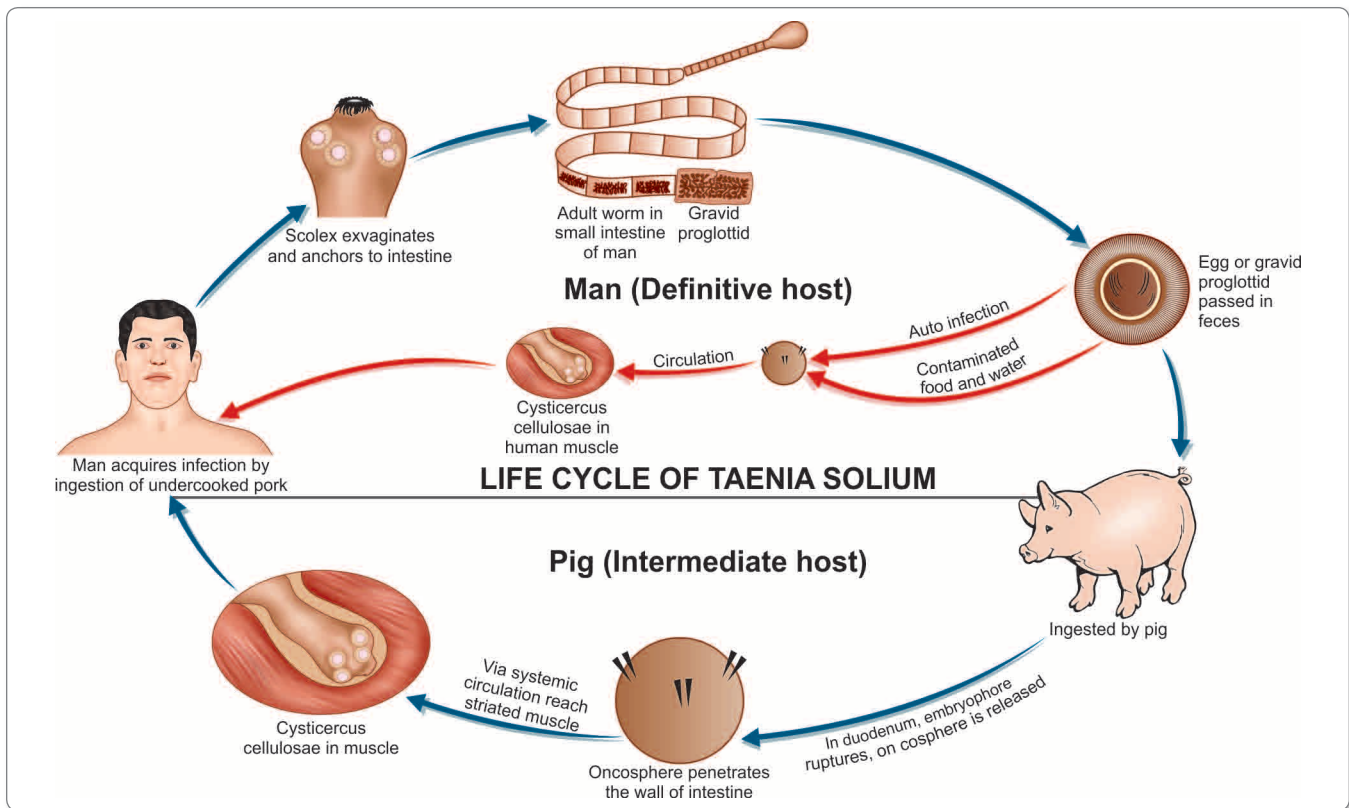


Fig. 12.13: Life cycle of *Taenia solium*

- They are filtered out principally in the muscles, where they develop into the larval stage, **cysticercus cellulosae** in about 60–70 days.
- In humans, it is a dead end and the larvae die without further development.

- Intestinal infection with *T. solium* occurs only in persons eating undercooked pork and usually in persons of low socio-economic condition with poor sanitation. It is uncommon in Jews and Mohammedans, who are not generally pork eaters. But cysticercosis may occur in any person residing in endemic areas, even in vegetarians because the mode of infection is contamination of food or drink with egg deposited in soil.
- Eggs of *T. solium* are infective to pigs as well as to man.

Pathogenicity and Clinical Features

Intestinal Taeniasis

It can be caused by both *T. saginata* and *T. solium*.

- The adult worm, in spite of its large size, causes surprisingly little inconvenience to the patient.
- When the infection is symptomatic, vague abdominal discomfort, indigestion, nausea, diarrhea, and weight

loss may be present. Occasional cases of acute intestinal obstruction, acute appendicitis, and pancreatitis have also been reported.

Cysticercosis

It is caused by larval stage (cysticercus cellulosae) of *T. solium*.

- Cysticercus cellulosae may be solitary or more often multiple.
- Any organ or tissue may be involved, the most common being subcutaneous tissues and muscles. It may also affect the eyes, brain, and less often the heart, liver, lungs, abdominal cavity, and spinal cord.
- The cysticercus is surrounded by a fibrous capsule except in the eye and ventricles of the brain.
- The larvae evoke a cellular reaction starting with infiltration of neutrophils, eosinophils, lymphocytes, plasma cells, and at times, giant cells. This is followed by fibrosis and death of the larva with eventual calcification.
- The clinical features depend on the site affected
 - **Subcutaneous nodules** are mostly asymptomatic
 - **Muscular cysticercosis** may cause acute myositis
 - **Neurocysticercosis** (cysticercosis of brain) is the most common and most serious form of cysticercosis. About 70% of adult-onset epilepsy is due to neurocysticercosis. Other clinical features of neuro-

cysticercosis are increased intracranial tension, hydrocephalus, psychiatric disturbances, meningo-encephalitis, transient paresis, behavioral disorders aphasia, and visual disturbances. It is considered as the second most common cause of intracranial space occupying lesion (ICSOL) after Tuberculosis in India.

- In **ocular cysticercosis**, cysts are found in vitreous humor, subretinal space and conjunctiva. The condition may present as blurred vision or loss of vision, iritis, uveitis, and palpebral conjunctivitis.

Laboratory Diagnosis

Stool Examination

(i) Eggs

- Microscopic examination of feces shows characteristic eggs of *Taenia* in 20–80% of patients.
- Formol ether sedimentation method of stool concentration is useful.
- Eggs can also be detected by **cellophane swab method** (NIH Swab) in 85–95% patients.
- Species identification cannot be made from the eggs, since the eggs of *T. saginata* and *T. Solium* are similar (Flowchart 12.1).

(ii) Proglottids

- Species identification can be done by examining with a hand lens, the gravid proglottid pressed between 2 slides, when branching can be made out. (15–20 lateral branches in *T. saginata*; under 13 in *T. Solium*).

(iii) Scolex

- Definitive diagnosis can also be established by demonstration of unarmed scolex in case of *T. saginata* after antihelminthic treatment.

- (iv) **Detection of *Taenia* Antigen in feces:** Antigen capture enzyme-linked immunosorbent assay (ELISA) using polyclonal antisera against *Taenia* is employed to detect **coproantigen** in feces since 1990 and is more sensitive than microscopy (specificity 100% and sensitivity 98%). The drawback of the test is that it cannot differentiate between *T. saginata* and *T. solium* (Flowchart 12.1).

Serodiagnosis

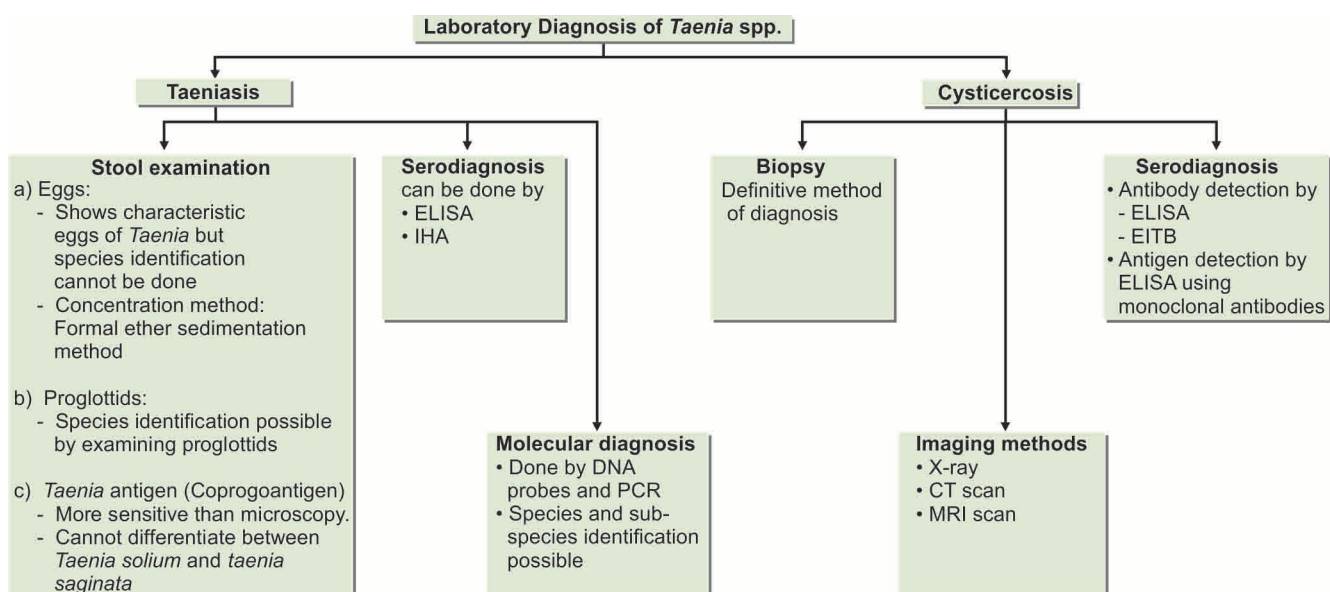
Specific antibodies in serum can be demonstrated by ELISA, indirect immunofluorescence test and indirect hemagglutination (IHA) test (Flowchart 12.1).

Molecular Diagnosis

Both DNA probes and polymerase chain reaction (PCR) technique are used to detect and differentiate between eggs and proglottids of *T. saginata* and *T. solium* (Flowchart 12.1). It can also differentiate between the 2 subspecies of *T. saginata*, viz *T. saginata saginata* and *T. saginata asiatica*.

Laboratory Diagnosis of Cysticercosis

Diagnosis of cysticercosis is based on the following (Flowchart 12.1):



Flowchart 12.1: Laboratory diagnosis of *Taenia* spp.

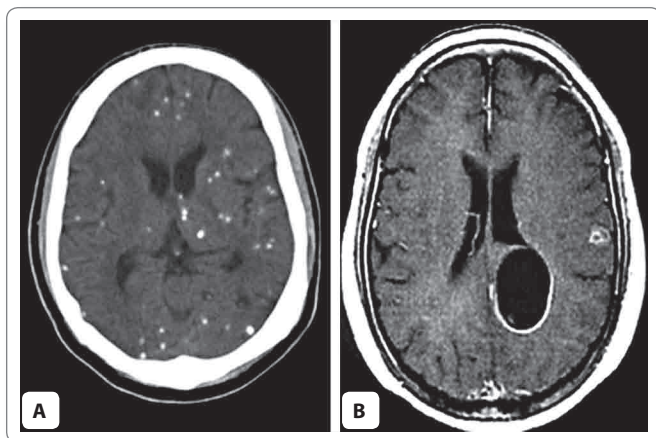


Fig. 12.14: **A.** CT Scan shows multiple calcified cysts of *Cysticercus cellulosae* in the brain parenchyma; **B.** CT Scan of brain shows clear cyst wall in a cysticercal lesion

Biopsy

Definitive diagnosis of cysticercosis is by biopsy of the lesion and its microscopic examination to show the invaginated scolex with suckers and hooks.

Imaging Methods

- **X-ray:** Calcified cysticerci can be detected by radiography of subcutaneous tissue and muscles particularly in the buttocks and thigh. X-ray of the skull many demonstrate cerebral calcified cyst.
- **Computed tomography (CT) scan** of brain is the best method for detecting dead calcified cysts. The cysticercal lesions appear as small hypodensities (ring or disc-like) with a bright central spot (Fig. 12.14).
- **Magnetic resonance imaging (MRI) scan** of the brain is more helpful in detection of non calcified cysts and ventricular cysts. It also demonstrates spinal cysticerci.

Serology

Antibody detection

Anticysticercus antibodies in serum or cerebrospinal fluid (CSF) can be detected by **ELISA** and enzyme-linked immunoelectrotransfer blot (**EITB**) tests.

Antigen detection

Antigen can be detected in serum and CSF by ELISA, using monoclonal antibodies and indicate recent infection.

Others

- **Ocular cysticercosis** can be made out by ophthalmoscopy
- **Eosinophilia:** Usually occurs in early stage of cysticercosis, but is not constant.

Treatment

Intestinal Taeniasis

Single dose of praziquantel (10–20 mg/kg) is the drug of choice.

- Niclosamide (2 g), single dose, is another effective drug.
- Purgation is not considered necessary.

Cysticercosis

- For cysticercosis, **excision** is the best method, wherever possible.
- Asymptomatic neurocysticercosis requires no treatment.
- For symptomatic cerebral cysticercosis, praziquantel in a dose of 50 mg/kg in 3 divided doses for 20–30 days and albendazole in a dose of 400 mg twice daily for 30 days may be administered.
- Corticosteroids may be given along with praziquantel or albendazole to reduce the inflammatory reactions caused by the dead cysticerci.
- In addition, antiepileptic drugs should be given until the reaction of the brain has subsided.
- Operative intervention is indicated for hydrocephalus.

Prophylaxis

- Beef and pork to be eaten by man should be subjected to effective inspection for cysticerci in slaughter house.
- Avoidance of eating raw or undercooked beef and pork. The critical thermal point of cysticercus is 56°C for 5 minutes.
- Maintenance of clean personal habits and general sanitary measures.

Key points of *Taenia saginata*

- Commonest, large ribbon-like tapeworm.
- Rostellum and hooks absent (unarmed tapeworm).
- 1,000–2,000 proglottids with 15–30 dichotomously branched uterus.
- **Definitive host:** Man
- **Intermediate host:** Cow
- **Mode of infection:** Undercooked (measly) beef containing cysticercus bovis
- Eggs are not infective to human.
- Asymptomatic, clinical features occur occasionally—abdominal discomfort, indigestion
- **Diagnosis:** Eggs or proglottids in stool, serodiagnosis, molecular diagnosis
- **Treatment:** Praziquantel is the drug of choice and excision in case of cysticercosis.
- **Prophylaxis:** By avoidance of eating undercooked beef.

Key points of *Taenia solium*

- Smaller than *T. saginata* with rostellum and hooks (armed tapeworm).
- Less than 1,000 Proglottids with 5–10 thick dendritic branched uterus.
- **Definitive host:** Man
- **Intermediate host:** Pig, occasionally man (in case of cysticercosis).
- **Mode of infection:** Undercooked (measly) pork containing cysticercus cellulosae; autoinfection and egg in contaminated vegetable, food, and water.
- Eggs are infective to human.
- **Clinical features:** Adult worm is asymptomatic. Larval forms cause cystic lesion in subcutaneous tissue, muscle, brain (neurocysticercosis), and eye.
- **Diagnosis:** Intestinal taeniasis—egg or proglottids in stool; Cysticercosis—biopsy, X-ray, CT Scan, MRI, and serology.
- **Treatment:** Praziquantel, albendazole, antiepileptics in neurocysticercosis
- **Prophylaxis:** By avoidance of eating undercooked pork and raw vegetables

- For control of cysticercosis, prevention of fecal contamination of soil, proper disposal of sewage and avoidance of eating raw vegetables grown in polluted soil are useful measures
- Detection and treatment of persons harboring adult worm, as they can develop cysticercosis due to autoinfection.

Taenia Saginata Asiatica

T. saginata asiatica is closely related to *T. saginata* and is found mainly in Asia.

- It is morphologically similar to *T. saginata* except.
 - It is smaller than *T. Saginata*.
 - Intermediate host is pig (not cow).
 - Its cysticerci are located primarily in liver of the pig (not muscle).
- Clinical features, diagnosis and treatment are similar to that of *T. saginata*.

Multiceps Multiceps (Taenia Multiceps)

Tapeworms of the Genus *Multiceps* (*M. multiceps*, *M. serialis*, *M. glomeratus*, etc.) are widespread natural parasites of dogs and other canines.

Definitive host: Dog, wolf, and fox

Intermediate host: Sheep, cattle, horses, and other ruminants

- Humans act as accidental intermediate host.
- Humans get infected by ingesting food or water contaminated with dogs feces containing eggs.
- Oncospheres hatch out from the eggs, penetrate the intestine and migrate to various organs, usually central nervous system (CNS) where it transforms into the larval stage called as **coenurus**.
- Coenurus is a roughly spherical or ovoid bladderworm, up to 3 cm in size, and bearing multiple invaginated protoscolices (hence, the name *multiceps*).
- In sheep, coenurus is typically seen in the brain and spinal cord. Affected sheep develop cerebellar ataxia, giving the disease its name 'stagers'.
- Human coenurosis has been reported from Africa, Europe, and the USA. The sites affected mainly are the orbit, brain, and subcutaneous tissue.
- Clinical disease is due to pressure effects, symptoms being headache, vomiting, paresis and seizures and also due to allergic reactions.
- Surgical removal, where feasible is the only mode of treatment.

Echinococcus Granulosus

Common name: Dog tape worm

History and Distribution

Hydatid cysts had been described by Hippocrates and other ancient physicians.

- Adult *E. granulosus* was described by Hartmann in the small intestine of dog in 1695 and the larval form (hydatid cysts) was recognized in 1782 by Goeze.
- The disease is prevalent in most parts of the world, though it is most extensive in the sheep and cattle-raising areas of Australia, Africa, and South America. It is also common in Europe, China, and the Middle East.
- It is a significant health problem in India. It is seen more often in temperate than in tropical regions.

Habitat

- The adult worm lives in the jejunum and duodenum of dogs and other canine carnivora (wolf and fox).
- The larval stage (hydatid cyst) is found in humans and herbivorous animals (sheep, goat, cattle and horse).

Morphology

Adult Worm

It is a small tapeworm, measuring only 3–6 mm in length.

- It consists of a scolex, a short neck, and strobila.
- The scolex is **pyriform**, with 4 suckers and a prominent rostellum bearing 2 circular rows of hooklets (25–30).

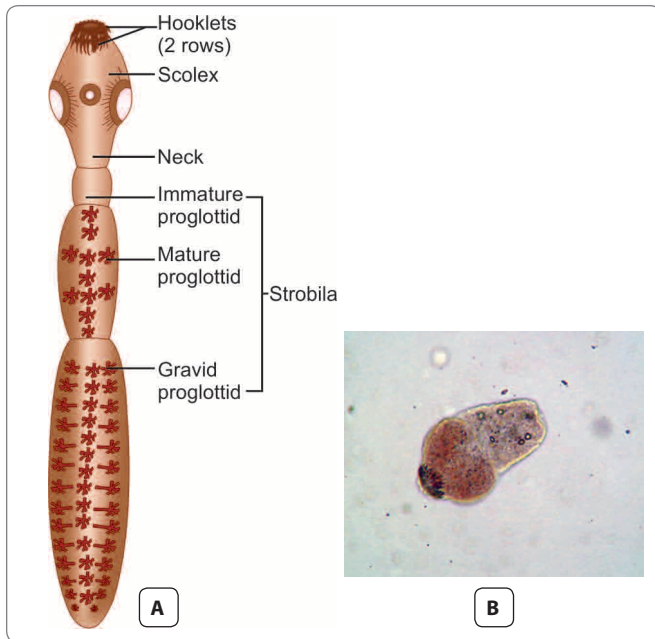


Fig. 12.15: *Echinococcus granulosus*. **A.** Schematic diagram of adult worm; **B.** Microscopic appearance of scolex of *Echinococcus*.

- The neck is short than the rest of the worm (3 mm × 6 mm).
- The strobila is composed of only 3 proglottids, the anterior immature, the middle mature, and the posterior gravid segment (Fig. 12.15).
- The terminal proglottid is longer and wider than the rest of the worm and contains a branched uterus filled with eggs.
- The adult worm lives for 6–30 months.

Egg

- The eggs of *Echinococcus* are indistinguishable from those of *Taenia* species.
- It is ovoid in shape and brown in color.
- It contains an embryo with 3 pairs of hooklets.

Larval Form

The larval form is found within the hydatid cyst developing inside various organs of the intermediate host.

- It represents the structure of the scolex of adult worm and remains **invaginated** within a vesicular body.
- After entering the definitive host, the scolex with suckers and rostellar hooklets, becomes **exvaginates** and develops into adult worm.

Life Cycle

The worm completes its life cycle in 2 hosts (Fig. 12.16).

Definitive hosts: Dog (optimal host), wolf, jackal, and fox

Intermediate host: Sheep and Cattle. Sheep is the ideal intermediate host.

- Man acts as an accidental intermediate host (dead end).
- The larval stage of the parasite is passed in intermediate hosts, including man, giving rise to hydatid cyst.
- The adult worm lives in the small intestine of dogs and other canine animals. These animals discharge numerous eggs in the feces.
- Intermediate hosts (sheep and cattle) ingest them while grazing.
- Human infection follows ingestion of the eggs due to intimate handling of infected dogs or by eating raw vegetables or other food items contaminated with dog feces.
- The ova ingested by man or by sheep and cattle are liberated from the chitinous wall by gastric juice liberating the **hexacanth embryos** which penetrate the intestinal wall and enter the **portal venules**, to be carried to the liver along the portal circulation.
- These are trapped in hepatic sinusoids, where they eventually develop into hydatid cyst. About 75% of hydatid cyst develop in liver, which acts as the first filter for embryo.
- However, some embryo which pass through the liver, enter the right side of heart and are caught in **pulmonary capillaries** (forming pulmonary hydatid cysts), so that the lung acts as the **second filter**.
- A few enter the systemic circulation and get lodged in various other organs and tissues such as the spleen, kidneys, eyes, brain, or bones.
- When sheep or cattle harboring hydatid cysts die or are slaughtered, dogs may feed on the carcass or offal. Inside the intestine of dogs, the scolices develop into the adult worms that mature in about 6–7 weeks and produce eggs to repeat the life cycle.
- When infection occurs in humans accidentally, the cycle comes to a dead end because the human hydatid cysts are unlikely to be eaten by dogs.

Pathogenesis

Evolution of Hydatid Cyst

At the site of deposition, the embryo slowly develops into a hollow bladder or cyst filled with fluid (Figs. 12.17-12.19). This becomes the hydatid cyst (Greek *hydatis*: a drop of water).

- It enlarges slowly and reaches a diameter of 0.5–1 cm in about 6 months. The growing cyst evokes host tissue reaction leading to the deposition of fibrous capsule around it.

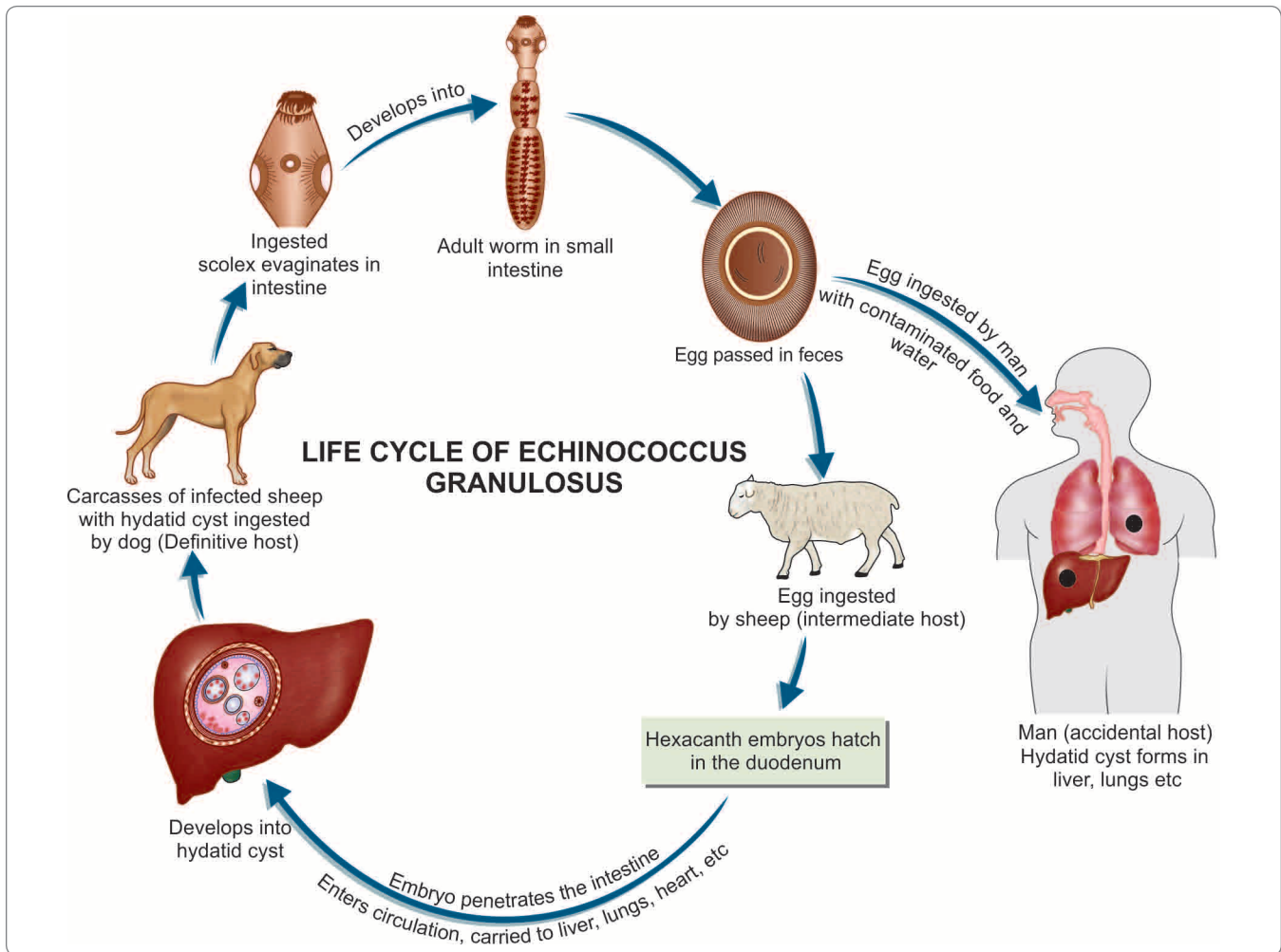


Fig. 12.16: Life cycle of *Echinococcus granulosus*

- The cyst wall secreted by the embryo consists of 3 indistinguishable layers (Figs 12.17 and 12.18).
 - **Pericyst** is the outer host inflammatory reaction consisting of fibroblastic proliferation, mononuclear cells, eosinophils, and giant cells, eventually developing into dense fibrous capsule which may even calcify.
 - **Ectocyst** is the intermediate layer composed of characteristic acellular, chitinous, laminated hyaline material. It has the appearance of the white of a hard boiled egg.
 - **Endocyst** is the inner germinal layer which is cellular and consists of number of nuclei embedded in a protoplasmic mass and is extremely thin (22–25 μm). The germinal layer is the vital layer of the cyst and is the site of asexual reproduction giving rise to brood capsules with scolices. It also secretes hydatid fluid, which fills the cyst.
- **Hydatid fluid:** The interior of the cyst is filled with a clear colorless or pale yellow fluid called as **hydatid fluid**.
 - pH of the fluid is 6.7 (acidic).

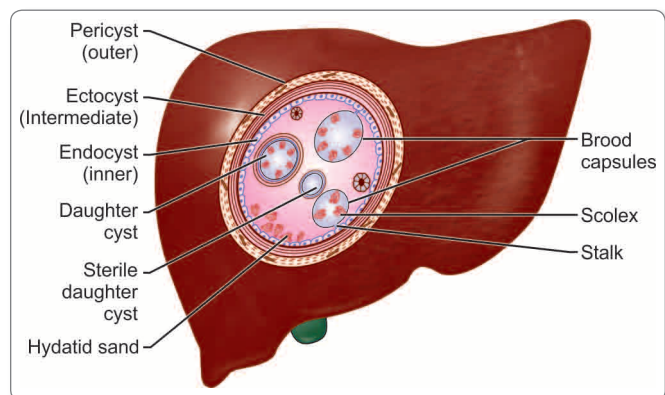


Fig. 12.17: Hydatid cyst in the liver

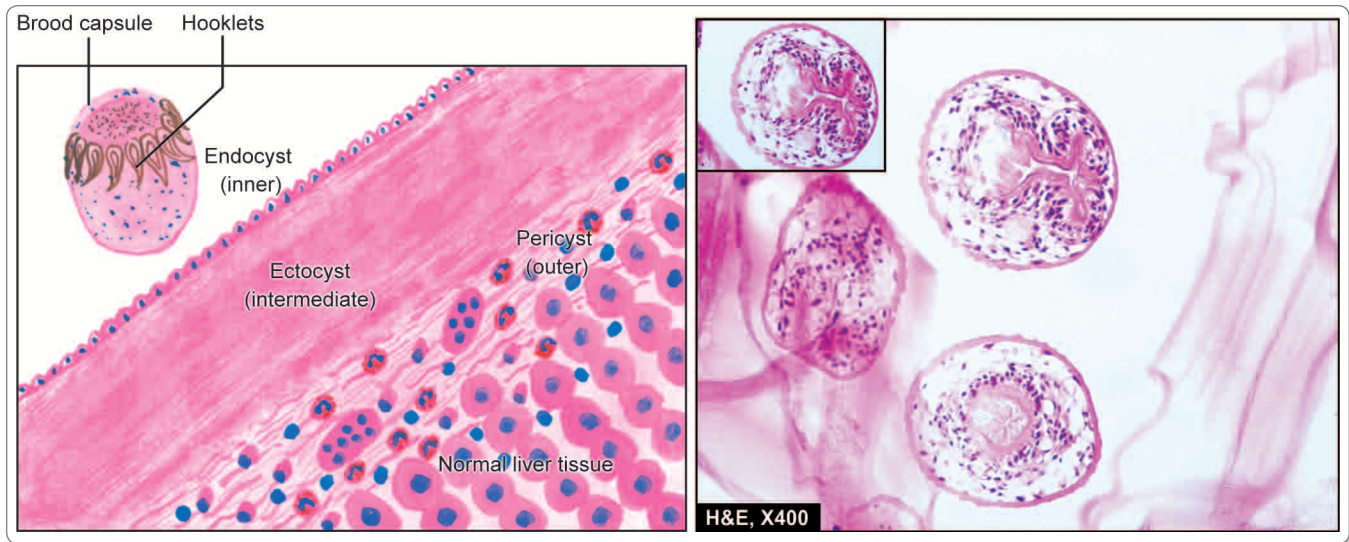


Fig. 12.18: Microscopy shows 3 layers in the wall of hydatid cyst. In box in the right photomicrograph shows a scolex with a row of hooklets. Courtesy: Harsh Mohan, Textbook of Pathology, 6th ed. New Delhi: Jaypee Brothers, 2013(R), p. 617

- **Composition:** It contains salts (sodium chloride 0.5%, sodium sulphate, sodium phosphate, and salts of succinic acid) and proteins.
- It is antigenic and highly toxic so that its liberation into circulation gives rise to pronounced eosinophilia or may even cause anaphylaxis.
- The fluid was used as the antigen for Casoni's intradermal test.
- A granular deposit or **hydatid sand** is found at the bottom of the cyst, consisting of **free brood capsules** and protoscolices and loose hooklets.

Brood capsules

From the germinal layer, small knob-like excrescences or gemmules protrude into the lumen of the cyst. These enlarge, become vacuolated, and are filled with fluid. These are called as **brood capsules**.

- They are initially attached to the germinal layer by a stalk, but later escape free into the fluid-filled cyst cavity.
- From the inner wall of the brood capsules, protoscolices (new larvae) develop, which represent the head of the potential worm, complete with invaginated scolex, bearing suckers and hooklets.
- Several thousands of protoscolices develop into a mature hydatid cyst, so that this represents an asexual reproduction of great magnitude.
- Inside mature hydatid cysts, further generation of cyst, **daughter** cysts and **grand-daughter** cysts may develop. The cyst grows slowly often taking 20 years or more to become big enough to cause clinical illness and is therefore, particularly seen in man.

Acephalocysts

Some cysts are sterile and may never produce brood capsules, while some brood capsule may not produce scolices. These are called *acephalocysts*.

Fate of hydatid cysts

The cyst may get calcified or spontaneously evacuated following inflammatory reaction. Hydatid cyst of liver may rupture into lung or other body cavity producing disseminated hydatid lesions.

Clinical Features

- Most of the times infection is asymptomatic and accidentally discovered.
- Clinical disease develops only when the hydatid cyst has grown big enough to cause obstructive symptoms. Disease results mainly from pressure effects caused by the enlarging cysts.
- In about half the cases, the primary hydatid cyst occurs in **liver** (63%) (Fig. 12.19), mostly in the right lobe. Hepatomegaly, pain, and obstructive jaundice are the usual manifestations.
- The next common site is the **lung** (25%) (most common being the lower lobe of the right lung). Cough, hemoptysis, chest pain, pneumothorax, and dyspnea constitute the clinical picture.
- In the kidney (2%), hydatid cyst causes pain and hematuria.
- **Other sites** affected include spleen (1%), brain (1%), pelvic organs, orbit, and bones (3%).

- Cerebral hydatid cysts may present as focal epilepsy.
- When hydatid cyst is formed inside the **bones**, the laminated layer is not well developed because of confinement by dense osseous tissues. The parasite migrates along the bony canals as naked excrescences that erode the bone tissue. This is called osseous hydatid cyst. Erosion of bone may lead to pathological fractures.
- Apart from pressure effects, another pathogenic mechanism in hydatid disease is **hypersensitivity** to the echinococcal antigen. The host is sensitized to the antigen by minute amounts of hydatid fluid seeping through the capsule. Hypersensitivity may cause **urticaria**. But if a hydatid cyst ruptures spontaneously or during surgical interference, massive release of hydatid fluid may cause severe, even **fatal anaphylaxis**.

Laboratory Diagnosis

Imaging

Radiological examinations and other imaging techniques such as ultrasonography (USG), CT scan, and MRI reveal the diagnosis in most cases of **cystic echinococcosis** (Flowchart 12.2).

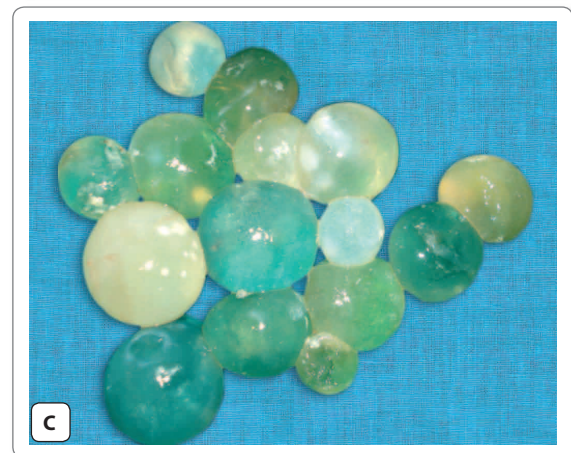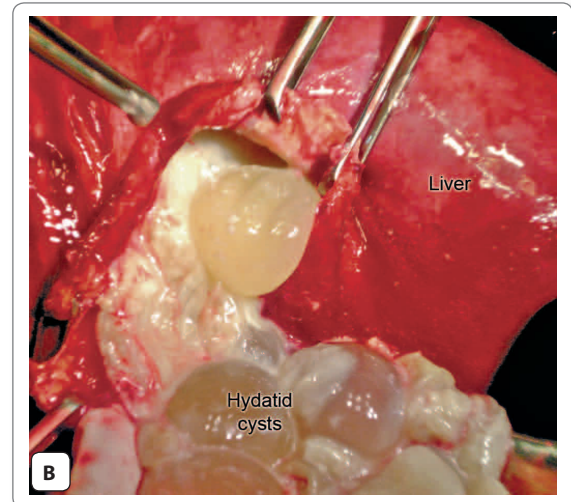
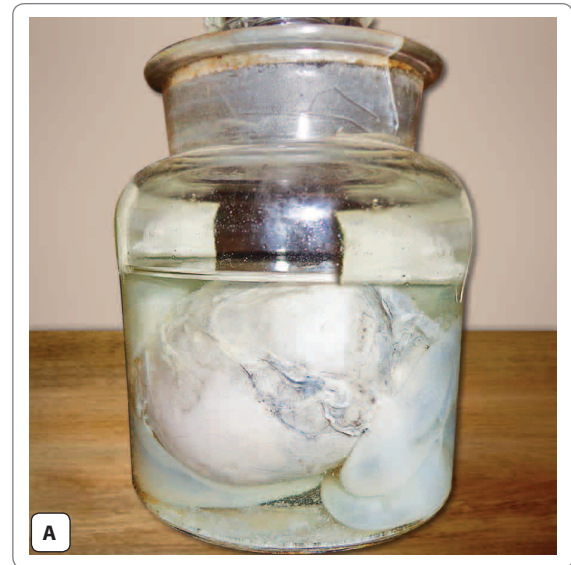- **USG** is the diagnostic procedure of choice. Cyst wall typically shows double echogenic lines separated by a hypoechoic layer (**double contour**). Pathogenic findings include daughter cysts and the '**water-lily**' sign due to detached endocyst floating within the cavity.
- **CT scan** is superior for the detection of extrahepatic disease (Figs 12.20 and 12.21).
- **MRI** appears to add diagnostic benefit for cysts, especially at difficult sites such as spinal vertebrae and cardiac cysts.
- **Plain X-rays** permit the detection of hydatid cyst in lung and bones. In cases where long bones are involved, a mottled appearance is seen in the skiagram (Fig. 12.22).
- **IV pyelogram** is often helpful for detection of renal hydatid cyst.

Examination of Cyst Fluid

Examination of aspirated cyst fluid under microscope after trichome staining reveals scolices, brood capsules, and hooklets. Exploratory puncture of the cyst to obtain cystic fluid should be avoided as it may cause escape of hydatid fluid and consequent anaphylaxis. Therefore, fluid aspirated from surgically removed cyst should only be examined (Flowchart 12.2).

Casoni's Intradermal Test

It is an immediate hypersensitivity (Type 1) skin test introduced by Casoni in 1911, using fresh sterile hydatid



Figs. 12.19A to C: Hydatid cyst of the liver—typical look.
 Courtesy (B & C): SRB's Manual of Surgery, 4th ed. New Delhi: Jaypee Brothers, 2013, p. 639

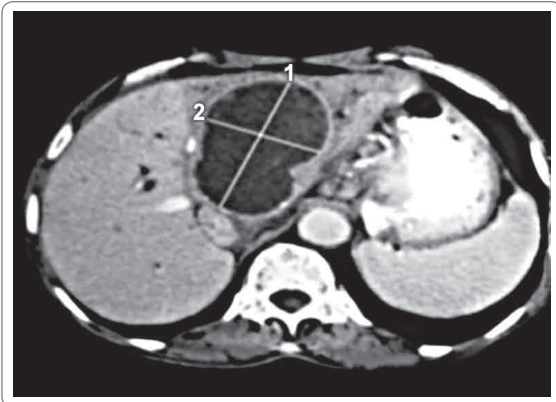


Fig. 12.20: CT scan shows a large noncalcified hydatid cyst in right hepatic lobe (Courtesy: Dr. Soma Sarkar)



Fig. 12.21: CT scan showing a hydatid cyst with noncalcified wall in right lower lobe of lung (Courtesy: Dr. Himangshu Roy)

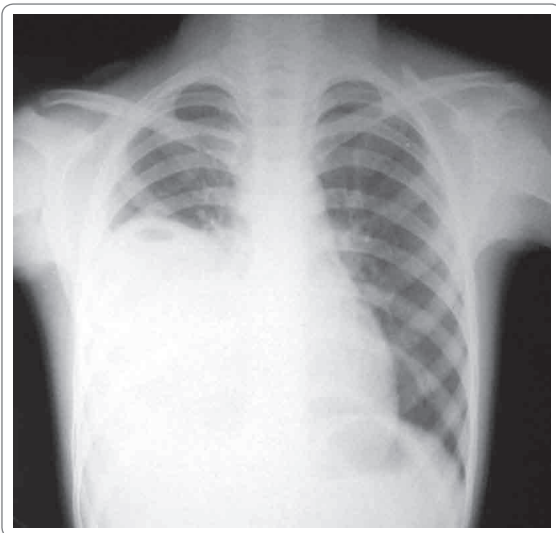


Fig. 12.22: Chest X-ray shows homogenous radio-opaque opacity involving right lower lung with costophrenic angle (Courtesy: Dr. Soma Sarkar)

fluid. The antigen in hydatid fluid is collected from animal or human cysts and is sterilized by Seitz or membrane filtration. The fluid is injected (0.2 mL) intradermally in one arm and an equal volume of saline as control is injected in the other arm. In a positive reaction, a large wheal of about 5 cm in diameter with multiple pseudopodia like projections appears within half an hour at the test side and fades in about an hour. A secondary reaction consisting of edema and induration appears after 8 hours. The test is almost abandoned now due to non specificity and has been supplemented by serological tests (Flowchart 12.2).

Serology

Antibody detection

- Detection of serum antibodies using specific antigens (8 and 16 KDA) from hydatid fluid are frequently used to support the clinical diagnosis of cystic echinococcosis. The tests include IHA, indirect immunofluorescence, and ELISA. In hepatic cysts, the sensitivity of test are relatively superior (85–98%) than pulmonary cyst (50–60%).
- The slide latex agglutination test and immune electrophoresis using hydatid fluid fraction 5 antigen are also widely used. Precipitin test and complement fixation test (CFT) with hydatid antigen have also been found to be positive. CFT is not very sensitive and false positive reaction is seen in those receiving neural antirabic vaccine. CFT is useful after surgical removal of cysts, when a negative test has a better prognostic value (Flowchart 12.2).

Antigen detection

Specific echinococcal antigen in sera and in CSF can be detected by double diffusion and counter immunoelectrophoresis technique (CIEP) (Flowchart 12.2).

Blood Examination

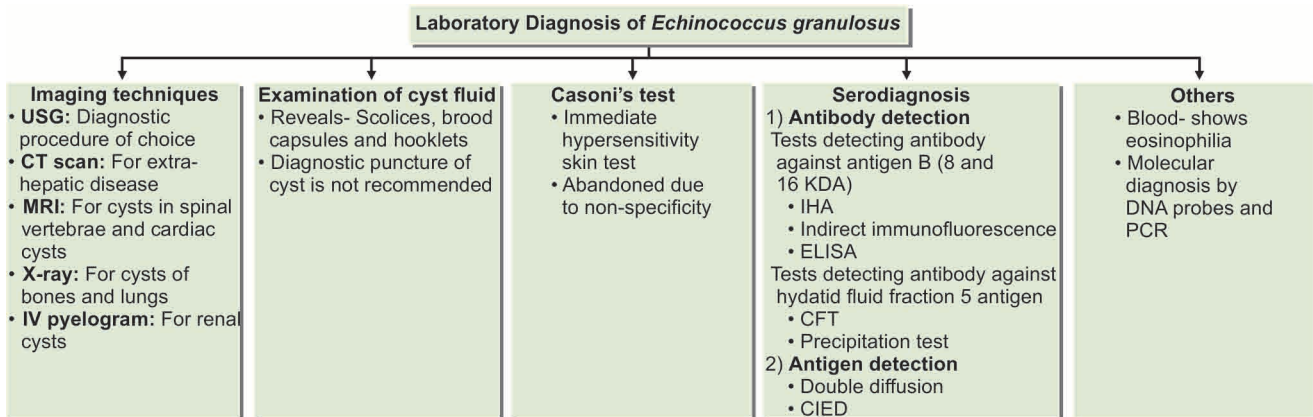
It may reveal a generalized **eosinophilia** of 20–25%.

Excretion of the Scolices

Excretion of scolices into the sputum or urine may be observed in pulmonary or renal cyst, respectively and can be demonstrated by acid fast staining or lactophenol cotton blue (LPCB) staining.

Specific Molecular Diagnostic

Specific molecular diagnostic methods have been developed involving DNA probes and PCR, but their application is limited by their technical complexity.



Flowchart 12.2: Laboratory diagnosis of *Echinococcus granulosus*

Treatment

Traditionally surgical removal was considered as the best mode of treatment of cysts. Currently, ultrasound staging is recommended and management depends on the stage.

In early stages, the treatment of choice is puncture, aspiration, injection, and reaspiration (PAIR).

Puncture, Aspiration, Injection, and Reaspiration (PAIR)

PAIR, considered as a controversial procedure earlier, is now widely used in early stages of the disease.

Indications of PAIR

- Cysts with internal echoes on ultrasound (**snowflake sign**) multiple cysts, cysts with detached laminar membrane.
- Contraindications of PAIR for superficially located cysts, cysts with multiple thick internal septal divisions (honey combing pattern), cysts communicating with biliary tree.

The basic steps involved in PAIR include-

- Ultrasound or CT- guided puncture of the cyst
- Aspiration of cyst fluid
- Infusion of scolicidal agent (usually 95% ethanol; alternatively, hypertonic saline)
- Reaspiration of the fluid after 5 minutes.
- Great care is taken to avoid spillage and cavities are sterilized with 0.5% silver nitrate or 2.7% sodium chloride for prophylaxis of secondary peritoneal echinococcosis due to inadvertent spillage of fluid during PAIR.
- Albendazole (15 mg/kg in 2 divided doses) is initiated 4 days before the procedure and continued for 4 weeks afterwards.

Scolicidal agents and their complications

- Cetrimide—can cause acidosis
- Alcohol 95%—can cause cholangitis
- Hypertonic saline—hypernatraemia
- Sodium hypochlorite—hypernataraemia
- Hydrogen peroxide

Note: In cases with biliary communication only hypertonic saline (15–20%) is used

Surgery

It is the treatment of choice for complicated *E. granulosus* cysts like those communicating with the biliary tract and in those cysts where PAIR is not possible.

- The preferred surgical approach is pericystectomy. For pulmonary cyst, treatment consists of wedge resection or lobectomy.
- Recurrence after surgery is common.
- Pre- and postoperative chemotherapy with albendazole for 2 years after curative surgery is recommended.
- Positron emission tomography (PET) scanning can be used to follow disease activity.
- Other new treatment modalities include laparoscopic hydatid liver surgery and percutaneous thermal ablation (PTA) of the germinal layer of the cyst using radiofrequency ablation device.

Chemotherapy

Chemotherapy with benzimidazole agents are restricted to residual, post-surgical, and inoperable cysts. Albendazole and praziquantel have proved beneficial.

Prophylaxis

E. granulosus infection can be prevented by—

- Ensuring pet dogs do not eat animal carcass or offal.

- Periodical deworming of pet dogs.
- Destruction of stray and infected dogs.
- Maintaining personal hygiene such as washing of hands after touching dogs and avoidance of kissing pet dogs.

Echinococcus species and the diseases caused by them

- *Echinococcus granulosus* : Hydatid disease
- *Echinococcus multilocularis* : Alveolar or multilocular hydatid disease
- *Echinococcus vogeli* and *Echinococcus oligarthrus* : Polycystic hydatid disease

Echinococcus Multilocularis

This causes the rare but serious condition of **alveolar** or **multilocular hydatid** disease in humans.

- It is found in the northern parts of the world, from Siberia in the East to Canada in the West.
- The adult worm is smaller than *E. granulosus* and lives in the intestines of foxes, dogs, and cats which are the definitive host.
- Rodents are the main intermediate hosts.
- Human infection develops from eating fruits or vegetables contaminated with their feces.
- *E. multilocularis* leads to multilocular hydatid cyst. The liver is the most commonly affected organ. The multilocular infiltrating lesion appears like a grossly invasive growth, without any fluid or free brood capsule or scolices which can be mistaken for a malignant tumor.
- Patients present with upper quadrant and epigastric pain. Liver enlargement and obstructive jaundice may also be present. It may also metastasize to the spleen, lungs, and brain in 2% cases.
- The prognosis is very grave and if untreated, 70% cases progress to death.
- Surgical resection, when possible, is the best method of treatment. Albendazole therapy is recommended for 2 years after curative surgery. In those cases, where surgery is not possible, indefinite treatment with albendazole is recommended.

Malignant hydatid disease

- It is a misnomer, as it is a benign condition.
- It is caused by *Echinococcus multilocularis* (*alveolaris*). It presents with multiple small cysts in both lobes of the liver.
- It is difficult to treat and mimics clinically and prognosis-wise to malignancy; hence the name.
- Patients die of liver failure.

Hymenolepis Nana

Common name: Dwarf tape worm

History and Distribution

The name *Hymenolepis* refers to the thin membrane covering the egg (Greek *hymen*—*membrane*, *lepis*—*ring* or *covering*) and *nana* to its small size (*nanus*—*dwarf*). It was first discovered by Bilharz in 1857.

- It is cosmopolitan in distribution but is more common in warm than in cold climates.
- Infection is most common in school children and institutional populations.



- *Hymenolepis nana* is the **smallest** and the **most common** tapeworm found in the human intestine.
- It is unique that it is the only cestode which completes its life cycle in **one** host—humans.

Habitat

The adult worm lives in the proximal ileum of man. *H. nana* var. *fraterna* is found in rodents like mice and rats, where they are found in the posterior part of the ileum.

Morphology

Adult Worm

H. nana is the smallest intestinal cestode that infects man.

- It is 5–45 mm in length and less than 1 mm thick. The scolex has 4 suckers and a retractile rostellum with a single row of hooklets (Fig. 12.23).

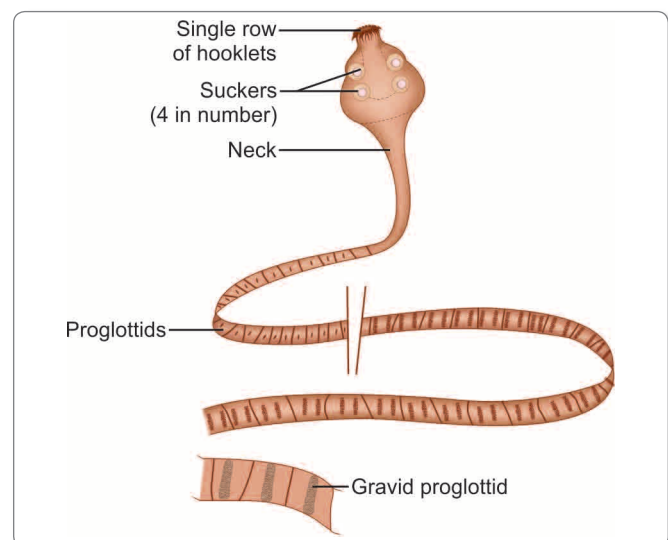


Fig. 12.23: Adult worm of *Hymenolepis nana*

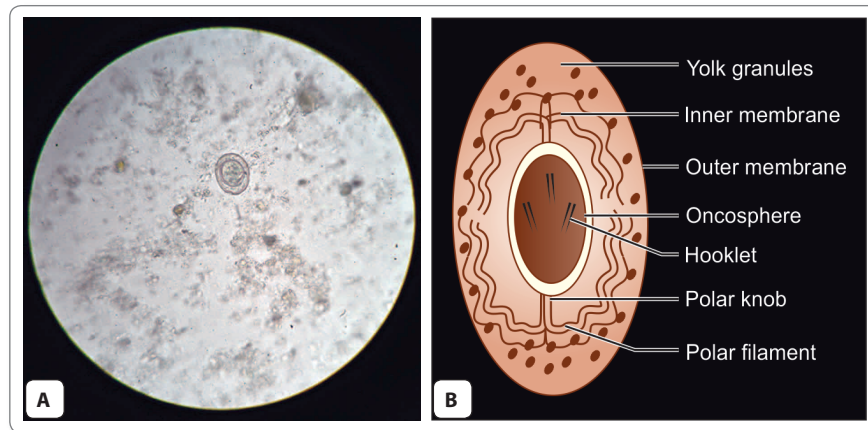


Fig. 12.24: Egg of *Hymenolepis nana*. A. As seen under microscope; B. Schematic diagram

- The long slender *neck* is followed by the *strobila* consisting of 200 or more proglotlids, which are much broader than long.
- Genital pores are situated on the same side along the margins.
- The uterus has lobulated walls and the testis are round and 3 in number.
- Eggs are released in the intestine by disintegration of the distal gravid segments.
- *H. nana* is unusual in that it undergoes multiplication in the body of the definitive host.
- When the eggs are swallowed, or in internal autoinfection, they hatch in the small intestine.
- The **hexacanth embryo** penetrates the intestinal villus and develops into the cysticercoid larva.
- This is a solid pyriform structure, with the vesicular anterior end containing the invaginated scolex and a short conical posterior end.
- After about 4 days, the mature larva emerging out of the villus evaginates its scolex and attaches to the mucosae.
- It starts strobilization, to become the mature worm, which begins producing eggs in about 25 days.

Egg

The echinococcal egg is roughly spherical or ovoid, 30–40 μm in size.

- It has a thin colorless outer membrane and inner **embryophore** enclosing the **hexacanth oncosphere** (Fig. 12.24).
- The space between 2 membranes contains **yolk granules** and **4–8 thread like polar filaments** arising from 2 knobs on the **embryophore**.
- The eggs float in saturated solution of salt and are **non-bile stained**.
- They are **immediately infective** and unable to survive for more than 10 days in external environment.

Life Cycle

Host: Man.

- There is no intermediate host.
- **Mode of transmission:** Infection occurs by ingestion of the food and water contaminated with eggs.
 - **Internal autoinfection** may also occur when the eggs released in the intestine hatch there itself (Fig. 12.25).
 - **External autoinfection** occurs when a person ingest own eggs by fecal oral route.

A different strain of *H. nana* infects rats and mice. The eggs passed in rodent feces are ingested by rat fleas (*Xenopsylla cheopis* and others), which acts as the intermediate host. The eggs develop into cysticercoid larvae in the hemocele of these insects. Rodents get infected when they eat these insects. The murine strain does not appear to infect man. However, the human strain may infect rodents, which may, therefore, constitute a subsidiary reservoir of infection for the human parasite.

Clinical Features

Hymenolopiasis occurs more commonly in children.

- There are usually no symptoms but in heavy infections, there is nausea, anorexia, abdominal pain, diarrhea, and irritability.
- Sometimes pruritus may occur due to an allergic response.

Laboratory Diagnosis

The diagnosis is made by demonstration of characteristic eggs in feces by direct microscopy. Concentration methods like salt flotation and formalin ether may be readily used. ELISA test has been developed with 80% sensitivity.

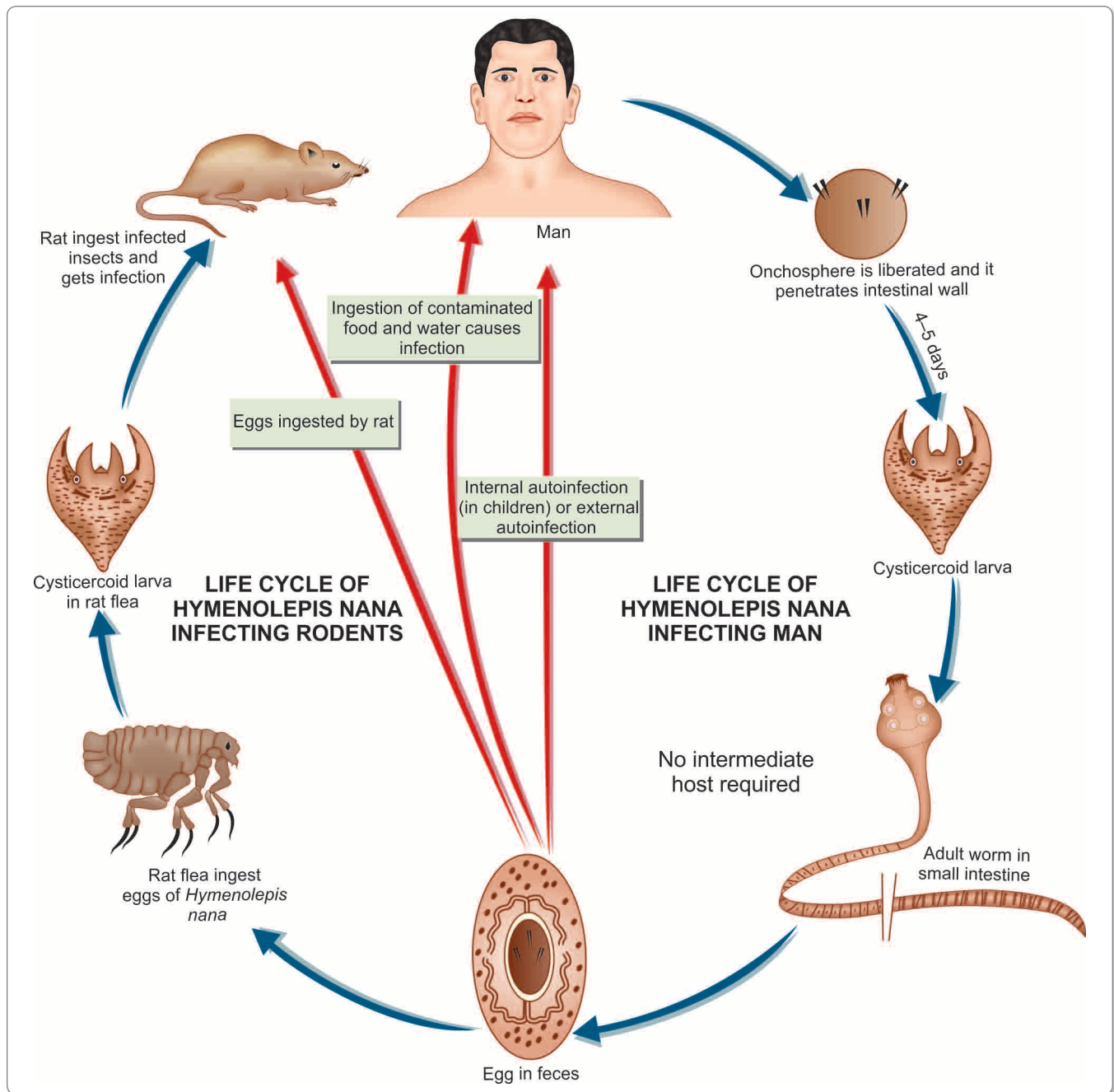


Fig. 12.25: Life cycle of *Hymenolepis nana*

Treatment

Praziquantel (single dose of 25 mg/kg) is the drug of choice, since it acts both against the adult worms and the cysticeroids in the intestinal villi.

- Nitazoxanide 500 mg BD for 3 days may be used as alternative.

Prophylaxis

- Maintenance of good personal hygiene and sanitary improvements.
- Avoiding of consumption of contaminated food and water.
- Rodent control.

Hymenolepis Diminuta

This is called the rat tapeworm and is a common parasite of rats and mice.

- The name '*diminuta*' is a misnomer, as it is larger than *H. nana* being 10–60 cm in length.
- Its life cycle is similar to that of the murine strain of *H. nana*.
- Rarely, human infection follows accidental ingestion of infected rat fleas. Human infection is asymptomatic.

Dipylidium Caninum

This common tapeworm of dogs and cats, it may accidentally cause human infection, mainly in children.

Morphology

- The adult worm in the intestine is about 10–70 cm long
- The scolex has 4 prominent suckers and a retractile rostellum with upto 7 rows of spines (Fig. 12.26).
- The mature proglottid has 2 *genital pores*, 1 on either side, hence the name *Dipylidium* (*dipylos*—2 entrances).
- Gravid proglottids are passed out of the anus of the host singly or in groups.

Life Cycle

Definitive host: Dogs, cats, and rarely man.

Intermediate host: Fleas.

- Man acquires infection by ingestion of flea harboring cysticercoid larva.
- The eggs or proglottids passed in feces of dogs and cats are eaten by larval stages of dog and cat fleas, *Ctenocephalus canis* and *C. felis*.
- The embryo develops into a tailed cysticercoid larva.

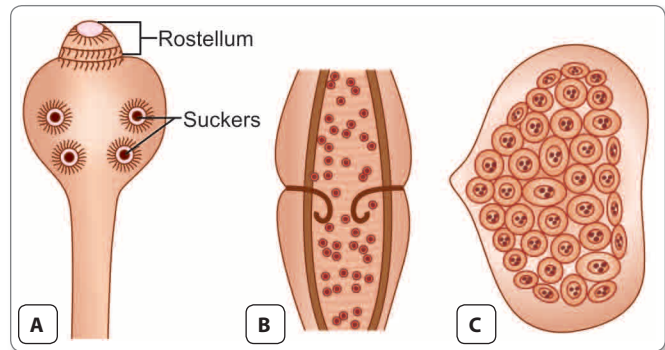


Fig. 12.26: *Dipylidium caninum*. **A.** Scolex showing 4 suckers and rostellum with multiple rows of hooklets; **B.** Mature proglottid showing 2 genital pores, one on either side; **C.** Eggs found in clusters enclosed in a membrane

- When the adult fleas containing the larvae are eaten by dogs, cats, or rarely humans, infection is transmitted.

Clinical Features

Human infection is generally asymptomatic, but the actively motile proglottids passed in stools may raise an alarm.

Diagnosis

The diagnosis is made by detection of proglottids or eggs in stool.

Treatment

The drug of choice is praziquantel.

Parasites requiring as Intermediate host:

- *Hymenolepis diminuta*
- *Dipylidium caninum*
- *Hymenolepis nana* (murine strain).

Review Questions

1. Describe briefly:

(a) General characters of cestodes

(b) Classification of cestodes

2. Short notes on:

(a) *Echinococcus granulosus*

(c) *Diphyllobothrium latum*

(e) Casoni's test

(g) Coenurosis

(i) *Cysticercus cellulosae*

(b) *Hymenolepis nana*

(d) Hydatid cyst

(f) Sparganosis

(h) *Dipylidium caninum*

(j) Neurocysticercosis

3. Describe morphology, life cycle, and laboratory diagnosis of:

(a) *Taenia solium*

(c) *Echinococcus granulosus*

(b) *Taenia saginata*

4. Differentiate between:

(a) *Taenia solium* and *Taenia saginata*

(b) *Taenia saginata saginata* and *Taenia saginata asiatica*



Trematodes: Flukes 13

Trematodes are unsegmented helminths, which are flat and broad, resembling the leaf of a tree or a flatfish (hence the name *Fluke*, from the *Anglo-saxon* word '*floc*' meaning '*flatfish*'). The name **Trematode** comes from their having large prominent suckers with a hole in the middle (Greek *trema*: *hole*, *eidos*: *appearance*).

Classification of Trematodes

Systemic Classification

Trematodes belong to—

Phylum: Platyhelminthes

Class: Trematoda

For detailed systemic classification see Table 13.1.

Classification Based on Habitat

Based on habitat, trematodes can be classified as (Table 13.2)

- i. Blood flukes
- ii. Liver flukes
- iii. Intestinal flukes
- iv. Lung flukes

Table 13.1: Zoological Classification of Trematodes

Superfamily	Family	Genus	Species
Schistosomatoidea	Schistosomatidae	<i>Schistosoma</i>	<i>S. haematobium</i> <i>S. mansoni</i> <i>S. japonicum</i> <i>S. mekongi</i> <i>S. intercalatum</i>
Paramphistomatoidea	Zygocotylidae	<i>Gastrodiscoides</i> <i>Watsonius</i>	<i>G. hominis</i> <i>W. watsoni</i>
Echinostomatoidea	Fasciolidae	<i>Fasciola</i> <i>Fasciolopsis</i>	<i>F. hepatica</i> <i>F. buski</i>
Opisthorchioidea	Opisthorchiidae	<i>Opisthorchis</i>	<i>O. felinus</i> <i>O. viverrini</i> <i>C. sinensis</i>
	Heterophyidae	<i>Clonorchis</i> <i>Heterophyes</i> <i>Metagonimus</i>	<i>H. heterophyes</i> <i>M. yokogawai</i>
Plagiorchioidea	Paragonimidae	<i>Paragonimus</i>	<i>P. westermani</i>

Table 13.2: Classification based on Habitat

Habitat	Trematodes
Blood (Blood fluke)	<i>Schistosoma haematobium</i> (In the vesical and pelvic venous plexuses) <i>Schistosoma mansoni</i> (In the inferior mesenteric vein) <i>Schistosoma japonicum</i> (In the superior mesenteric vein)
Biliary tract (Liver fluke)	<i>Clonorchis sinensis</i> <i>Fasciola hepatica</i> <i>Opisthorchis</i> spp.
Gastrointestinal tract (Intestinal fluke) Small intestine	<i>Fasciolopsis buski</i> <i>Heterophyes heterophyes</i> <i>Metagonimus yokogawai</i> <i>Watsonius watsoni</i>
Large intestine	<i>Gastrodiscoides hominis</i>
Respiratory tract (Lung fluke)	<i>Paragonimus westermani</i>

Flukes: General Characteristics

They vary in size from the species just visible to the naked eye, like *Heterophyes* to the large fleshy flukes, like *Fasciola* and *Fasciolopsis*.

- A conspicuous feature of flukes is the presence of 2 muscular cup-shaped suckers (hence called **distomata**)—**the oral sucker** surrounding the mouth at the anterior end and the **ventral sucker** or **acetabulum** in the middle, ventrally (Fig. 13.1).

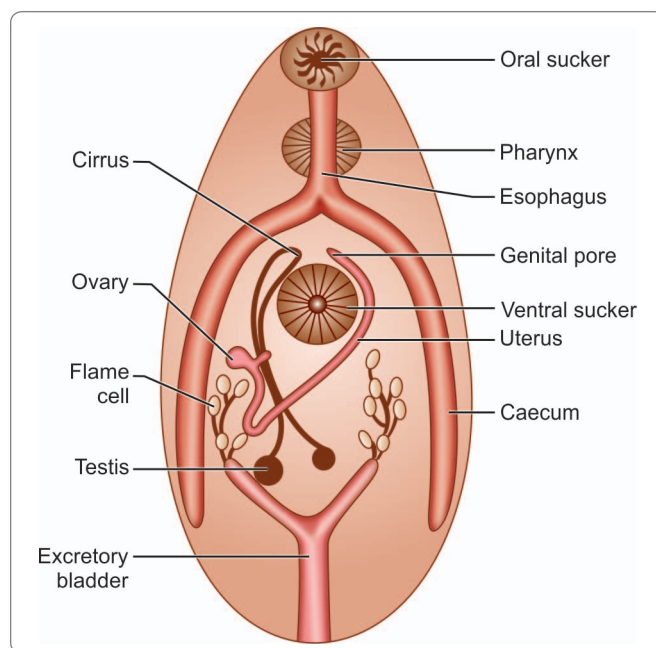


Fig. 13.1: Morphology of a hermaphroditic trematode

- The body is covered by an integument which often bears spines, papillae, or tubercles.
- They have no body cavity, circulatory and respiratory organs.
- The alimentary system consists of the mouth surrounded by the oral sucker, a muscular pharynx and the esophagus, which bifurcates anterior to the acetabulum to form 2 blind caeca, that reunite in some species. The alimentary canal, therefore appears like an **inverted Y**. The anus is absent (Fig. 13.1).
- The excretory system consists of flame cells and collecting tubules, which lead to a median bladder opening posteriorly (Fig. 13.1).
- There is a rudimentary nervous system consisting of paired ganglion cells.
- The reproductive system is well-developed. Flukes are **hermaphroditic (monoecious)** except for schistosomes, in which the sexes are separate (**dioecious**).
- The hermaphroditic flukes have both male and female structures, so that **self-fertilization** takes place, though in many species **cross-fertilization** also occurs. In the schistosomes, the sexes are separate, but the male and female live in close apposition (**in copula**), the female fitting snugly into the folded ventral surface of the male, which forms the **gynecophoric canal**.
- Trematodes are **oviparous** and lay eggs, which are **operculated**, except in the case of schistosomes.

Life Cycle

Medically important members of the class Trematoda belong to the subclass Digenea, as they are digenetic, i.e. require 2 hosts to complete their life cycle.

Definitive hosts: In which they pass the sexual or adult stage are **mammals, humans or animals.**

Intermediate hosts: In which they pass their asexual or larval stages are **freshwater molluscs or snails.**

Second intermediate host: Fish or crab is required for encystment in some trematodes.

- The eggs liberated by the definitive host hatch in water to form **the first stage larva**, the motile ciliated **miracidium** (Greek *miracidium*—a 'little boy').



Embryonated eggs of trematodes, which immediately hatch to form miracidium or L1 larva

- *Schistosoma haematobium*
- *Schistosoma mansoni*
- *Schistosoma japonicum*

Unembryonated eggs of trematodes which first embryonate in water and then hatch

- *Fasciola hepatica*
- *Fasciolopsis buski*
- *Paragonimus westermani*

Embryonated eggs of trematodes, which hatch in the body of the intermediate host

- *Clonorchis sinensis*
- *Opisthorchis felineus*
- *Opisthorchis viverrini*
- *Metagonimus yokogawai*

- The miracidium infects the intermediate host snail in which further development takes place.
- The miracidium sheds its cilia and becomes the sac-like **sporocyst** (meaning a 'bladder containing seeds'). Within the sporocyst, certain cells proliferate to form the **germ balls**, which are responsible for asexual replication.
- In schistosomes, the sporocyst develops into the second generation sporocyst, in which the infective larvae **cercariae** are formed by sexual multiplication. But in the hermaphroditic trematodes, the **sporocyst** matures into a more complex larval stage name **redia** (after the 17th century Italian naturalist, Francesco Redi), which produce cercariae. Cercariae thus develop within the second generation sporocyst (in schistosomes) or rediae (in all other trematodes).
- On maturity, the cercariae escape from the parent organism and then leave the snail host and become free-living in water.
- Cercariae are tailed larvae and hence their name (*Greek kerkos: tail*). In schistosomes, cercariae have a forked tail and infect the definitive host by direct skin penetration.

- In the hermaphroditic flukes, the cercariae have an unsplit tail and they encyst on vegetables or within a second intermediate host, fish or crab, to form the **metacercariae**, which are the infective forms to humans.
- Infection is acquired by ingesting metacercariae encysted on vegetables (*F. hepatica*, *F. buski*, *W. watsoni*), in fish (*C. sinensis*, *H. heterophyes*) or crabs (*P. westermani*).
- The asexual multiplication during larval development is of great magnitude and in some species, a single miracidium may give rise to over half a million cercariae.

Note: In Schistosomes, cercariae is the stage infective to man, whereas in rest of the trematodes, metacercariae are the infective form.

BLOOD FLUKES

Schistosomes

Schistosomes are **dioecious**, (sexes are separate) trematodes, which lead to **Schistosomiasis** (bilharziasis).

- Schistosomiasis is a water-borne disease constituting an important public health problem and affecting millions of persons in Africa, Asia, and Latin America.
- It is estimated that over 100 million people are infected with *S. haematobium*, *S. mansoni*, and *S. japonicum* each. Two other species of *Schistosoma* parasitizing humans are *S. mekongi* and *S. intercalatum*.
- The male worm is broader than the female and its lateral borders are rolled ventrally into a cylindrical shape, producing a long groove or trough called the **gynecophoric canal**, in which the female is held. It appears as though the body of the male is split longitudinally to produce this canal; hence the name schistosome (Greek *schisto: split* and *soma: body*) (Fig. 13.2).
- Schistosomes were formerly called *Bilharzia* after **Theodor Bilharz** who in 1851, first observed the worm in the mesenteric veins of an Egyptian in Cairo.

Features distinguishing schistosomes from other trematodes

Schistosomes differ from the hermaphroditic trematodes in many aspects.

- They are unisexual (diecious).
- They lack a muscular pharynx.
- Their intestinal caeca reunite after bifurcation to form a single canal.
- They produce non-operculated eggs.
- They have no redia stage in larval development.
- The cercariae have forked tails and infect by penetrating the unbroken skin of definitive hosts.

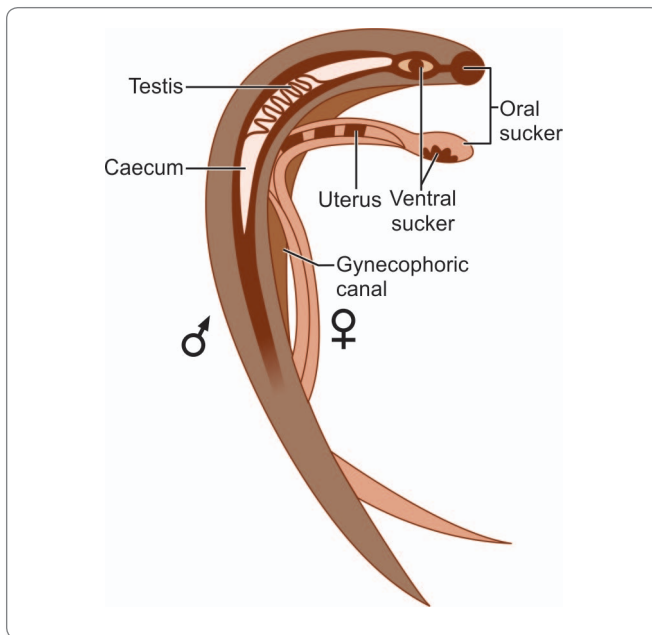


Fig. 13.2: Morphology of schistosomes: male and female in copula

- All schistosomes live in venous plexuses in the body of the definitive host, the location varying with the species.

Schistosoma Haematobium

History and Distribution

This vesical blood fluke, formerly known as *Bilharzia haematobium*, has been endemic in the Nile valley in Egypt for millenia. Its eggs have been found in the renal pelvis of an Egyptian mummy dating from 1,250–1,000 BC. Schistosome antigens have been identified by enzyme-linked immuno sorbant assay (ELISA) in Egyptian mummies of the Predynastic period, 3,100 BC.

- The adult worm was described in 1851 by Bilharz in Cairo. Its life cycle, including the larval stage in the snail, was worked out by Leiper in 1915 in Egypt.
- Although maximally entrenched in the Nile valley, *S. haematobium* is also endemic in most parts of Africa and in West Asia.
- An isolated focus of endemicity in India was identified in Ratnagiri, south of Mumbai by Gadgil and Shah in 1952.
- About 200 million persons are at a risk of infection and 90 million are infected by *S. haematobium* globally.

Habitat

The adult worms live in the vesical and pelvic plexuses of veins.

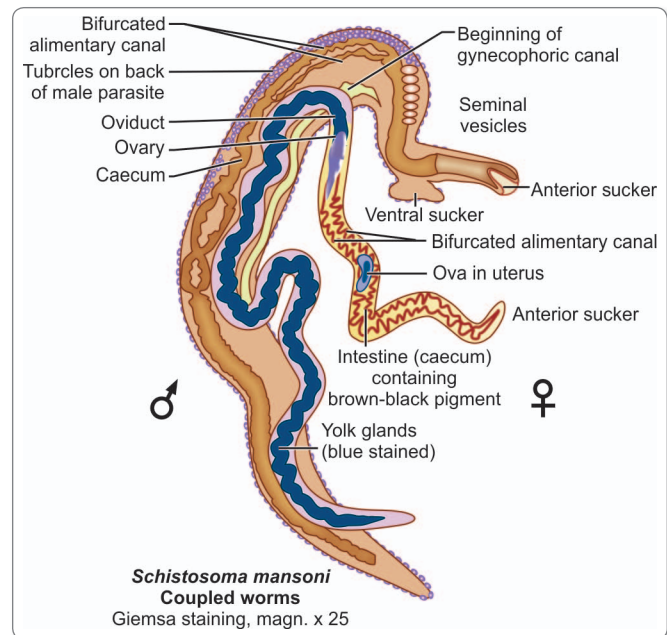


Fig. 13.3: Schematic diagram showing structural details of *Schistosoma* (coupled)

Morphology

Adult worm

- The male is 10–15 mm long by 1 mm thick and covered by a finely tuberculated cuticle.
- It has 2 muscular suckers, the oral sucker being small and the ventral sucker large and prominent. Beginning immediately behind the ventral sucker and extending to the caudal end is the gynecophoric canal, in which the female worm is held (Fig. 13.3).
- The adult female is long and slender, 20 mm by 0.25 mm with the cuticular tubercles confined to the two ends.
- The gravid worm contains 20–30 eggs in its uterus at one time and may pass up to 300 eggs a day.

Egg

The eggs are ovoid, about 150 μm by 50 μm , nonoperculated, with a brownish yellow transparent shell carrying a **terminal spine** at one pole; the terminal spine being characteristic of the species (Fig. 13.4).

Mechanism of Egg Expulsion

The eggs are laid usually in the small venules of the **vesical** and **pelvic plexuses**, though sometimes they are laid in the **mesenteric portal system**, **pulmonary arterioles**, and other **ectopic sites**.

- The eggs are laid one behind the other with the spine pointing posteriorly.

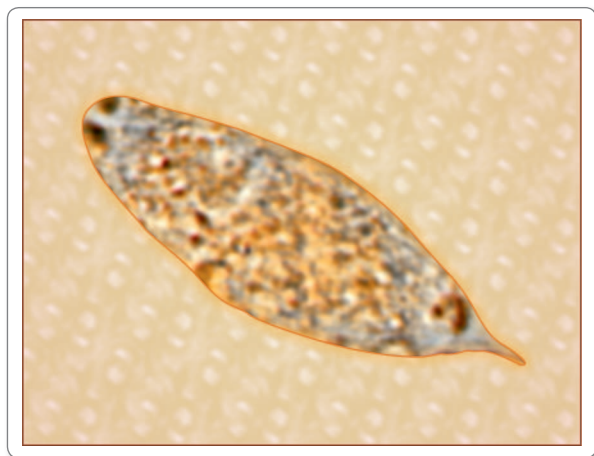


Fig. 13.4: Egg of *Schistosoma haematobium*

- From the venules, the eggs make their way through the vesical wall by the piercing action of the spine, assisted by the mounting pressure within the venules and a lytic substance released by the eggs.
- The eggs pass into the lumen of the **urinary bladder** together with some extravasated blood.
- They are discharged in the urine, particularly towards the end of micturition.
- For some unknown reasons, the eggs are passed in **urine** more during **midday** than at any other time of the day.
- The eggs laid in **ectopic sites** generally die and evoke local tissue reactions. They may be found, for instance in **rectal biopsies**, but are seldom passed live in feces.

Life Cycle

S. haematobium passes its life cycle in 2 hosts.

Definitive host: Humans are the only natural definitive hosts. No animal reservoir is known.

Intermediate host: Fresh water snails.

Infective form: Cercaria larva

- The eggs that are passed in urine are embryonated and hatch in water under suitable conditions to release the free living **ciliated miracidia**.
- Miracidia swim about in water and on encountering a suitable intermediate host, penetrate into its tissues and reach its liver (Fig. 13.6). The intermediate hosts are snails of *Bulinus* species in Africa. In India, the intermediate host is the limpet, *Ferrisia tenuis*.

Development in Snail

Inside the snail, the miracidia lose their cilia and in about 4–8 weeks, successively pass through the stages of the **first and second generation sporocysts** (Fig. 13.6).

- Large number of **cercariae** are produced by asexual reproduction within the second generation sporocyst.

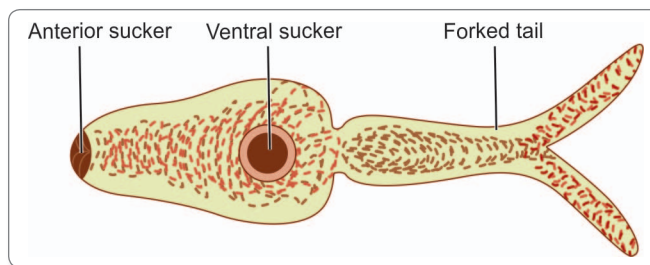


Fig. 13.5: Schematic diagram to show cercaria larva of *Schistosoma* spp.

The cercaria has an elongated ovoid body and **forked tail** (*furcocercous cercaria*) (Fig. 13.5).

- The cercariae escape from the snail.
- Swarms of cercariae swim about in water for 1–3 days. If during that period they come into contact with persons bathing or wading in the water, they penetrate through their unbroken skin. Skin penetration is facilitated by lytic substances secreted by penetration glands present in the cercaria.

Development in Man

On entering the skin, the cercariae shed their tails and become **schistosomulae** which enter the peripheral venules (Fig. 13.6).

- They then start a long migration, through the vena cava into the right side of the heart, the pulmonary circulation, the left side of the heart, and the systemic circulation, ultimately reaching the liver.
- In the intrahepatic portal veins, the schistosomulae grow and become sexually differentiated adolescents about 20 days after skin penetration.
- They then start migrating against the blood stream into the inferior mesenteric veins, ultimately reaching the **vesical and pelvic venous plexuses**, where they mature, mate, and begin laying eggs.
- Eggs start appearing in urine usually 10–12 weeks after cercarial penetration.
- The adult worms may live for 20–30 years.

Pathogenicity and Clinical Features

Clinical illness caused by schistosomes can be classified depending on the stages in the evolution of the infection, as follows:

- Skin penetration and incubation period
- Egg deposition and extrusion
- Tissue proliferation and repair.
- **The clinical features during the incubation period** may be **local cercarial dermatitis** or general **anaphylactic** or **toxic** symptoms.
 - Cercarial dermatitis consists of transient itching and petechial lesions at the site of entry of the cercariae (**swimmer's itch**).

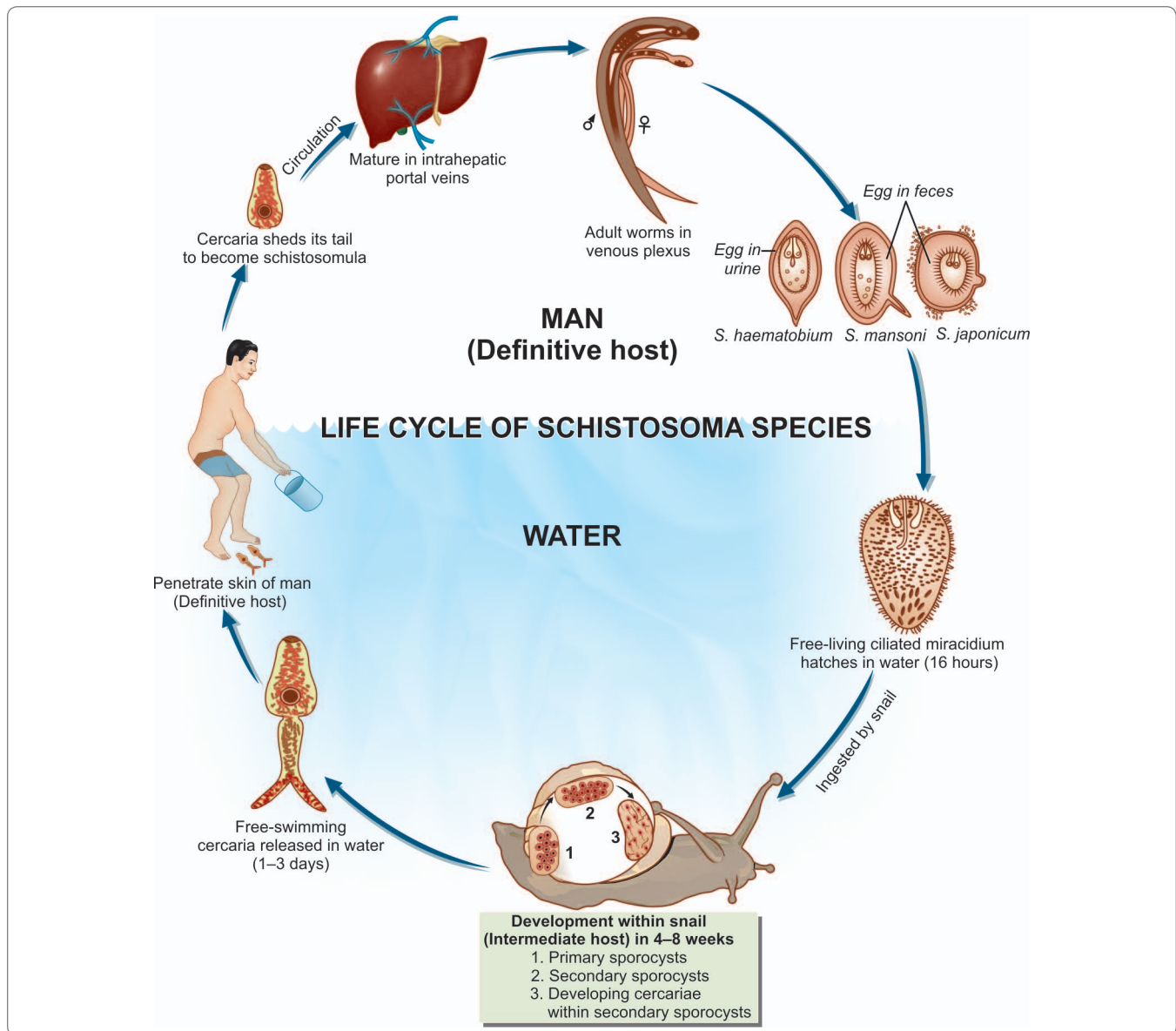


Fig. 13.6: Life cycle of *Schistosoma* spp.

- This is seen more often in visitors to endemic areas than in locals who may be immune due to repeated contacts.
- It is particularly severe when infection occurs with cercariae of nonhuman schistosomes.
- Anaphylactic or toxic symptoms include fever, headache, malaise, and urticaria.
- This is accompanied by leucocytosis, eosinophilia, enlarged tender liver, and a palpable spleen. This condition is more common in infection with *S. japonicum* (**Katayama fever**).
- **Clinical features during oviposition** include **painless terminal hematuria (endemic hematuria)**
 - Hematuria is initially microscopic, but becomes gross, if infection is heavy.
 - Most patients develop **frequency of micturition** and burning.
 - Cystoscopy shows **hyperplasia** and **inflammation of bladder mucosa**, with minute papular or vesicular lesions.
- **Clinical features during tissue proliferation and repair**

- In the **chronic stage**, there is generalized hyperplasia and fibrosis of the vesical mucosa with a granular appearance (**sandy patch**).
- At the sites of deposition of the eggs, dense infiltration with lymphocytes, plasma cells, and eosinophils leads to **pseudoabscesses**.
- Initially, the trigone is involved, but ultimately the entire mucosa becomes inflamed, thickened, and ulcerated.
- Secondary bacterial infection leads to **chronic cystitis**.
- **Calculi** form in the bladder due to deposition of oxalate and uric acid crystals around the eggs and blood clots.
- There may be **obstructive hyperplasia** of the ureters and urethra (**hydroureter**).
- **Chronic schistosomiasis** has been associated with squamous cell **carcinoma of the bladder**. Such malignancy is detected in a younger age group as compared to transitional cell carcinoma of the bladder. In fact, *S. haematobium* is now classified as a human carcinogen.



Parasites associated with malignancy

- | | |
|----------------------------------|---------------------|
| • <i>Schistosoma haematobium</i> | Bladder carcinoma |
| • <i>Clonorchis sinensis</i> | Bile duct carcinoma |
| • <i>Opisthorchis viverrini</i> | Bile duct carcinoma |

- Significant disease may occur in other organs during **schistosomiasis**.
 - Lungs and central nervous system (spinal cord), skin, and genital organs may be involved.
 - Ectopic lesions in the spinal cord produce a transverse myelitis-like syndrome.
 - Schistosomiasis favors urinary carriage of typhoid bacilli.

Laboratory Diagnosis

Urine Microscopy

The eggs with characteristic terminal spines can be demonstrated by microscopic examination of centrifuged deposits of urine or by filtration of a known volume of urine through nucleopore filters (Flowchart 13.1).

- Eggs are more abundant in the blood and pus passed by patients at the end of micturition.
- Nucleopore filtration method provides quantitative data on the intensity of infection, which is of value in assessing the degree of tissue damage and in monitoring the effect of chemotherapy.
- Eggs can also be seen in the seminal fluid in males.

Histopathology

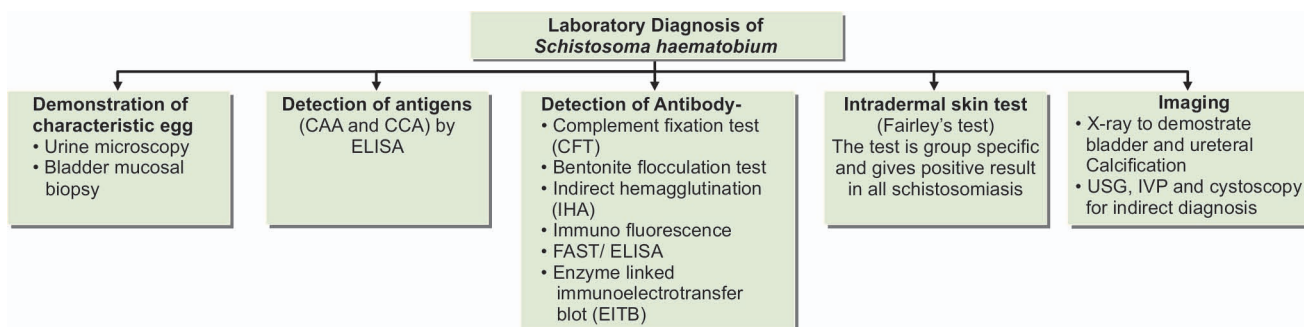
Schistosome infection may also be diagnosed by demonstrating its eggs in **bladder mucosal biopsy**.

Detection of Antigen

Another diagnostic method is by detection of specific schistosome antigens in serum or urine. Two glycoprotein antigens associated with the gut of adult schistosomes: circulating anodic antigen (CAA) and circulating cathodic antigens (CCA) can be demonstrated by ELISA using monoclonal antibodies. The test is very sensitive and specific, but is available only in specialized laboratories (Flowchart 13.1).

Detection of Antibody

Several serological tests have been described for detection of specific antibody, but are not very useful as they cannot differentiate between present and past infection. These include complement fixation test (CFT), bentonite flocculation test, indirect haemagglutination (IHA), immunofluorescence, and gel diffusion tests.



Flowchart 13.1: Laboratory diagnosis of *Schistosoma haematobium*

Two serological tests available at Centers For Disease Control and Prevention (CDC) are—the **falcon assay screening test (FAST)/ELISA** and the confirmatory enzyme-linked immunoelectrotransfer blot (EITB). Both these tests are highly sensitive and specific (95% sensitive and 99% specific).

In (FAST) ELISA test, *S. haematobium* adult worm microsomal antigen (**HAMA**) is used for detection of specific antibody (Flowchart 13.1).

Intradermal Skin Test (Fairley's test)

Skin tests are group-specific and give positive results in all schistosomiasis. The intradermal allergic test uses antigen from infected snails, cercariae, eggs, and adult schistosomes from experimentally-infected laboratory animals.

Imaging

- X-ray of the abdomen may show bladder and ureteral calcification.
- Ultrasonography (USG) is also useful in diagnosing *S. haematobium* infection. USG may show hydroureter and hydronephrosis.
- Intravenous pyelogram (IVP) and cystoscopy are also useful in indirect diagnosis of the disease.

Treatment

Praziquantel is the drug of choice (40mg/kg for 1 day). Metrifonate is the alternative drug of choice in schistosomiasis due to *S. haematobium*. (7.5 mg/kg. weekly for 3 weeks).

Prophylaxis

Prophylactic measures include:

- Eradication of the intermediate molluscan hosts.
- Prevention of environmental pollution with urine and feces.

- Effective treatment of infected persons.
- Avoid swimming, bathing, and washing in infected water.

Schistosoma Mansoni

History and Distribution

In 1902, Manson discovered eggs with lateral spines in the feces of a West Indian patient that led to the recognition of this second species of human schistosomes. It was, therefore named *S. mansoni*.

- It is widely distributed in Africa, South America, and the Caribbean islands.

Habitat

Adult worm lives in the **inferior mesenteric vein**.

Morphology

S. mansoni resembles *S. haematobium* in morphology and life cycle, except—

- The adult worms are smaller and their integuments studded with prominent coarse **tubercles**.
- In the gravid female, the uterus contains very few eggs, usually 1–3 only.
- The **prepatent period** (the interval between cercarial penetration and beginning of egg laying) is 4–5 weeks.
- The egg has a characteristic **lateral spine** (Fig. 13.7), more near to the rounded posterior end. The eggs are **non operculated** and **yellowish brown**.

Life cycle

Definitive host: Humans are the only natural definitive hosts, though in endemic areas monkeys and baboons have also been found infected.

Intermediate host: Planorbid fresh-water **snails** of the genus *Biomphalaria*.

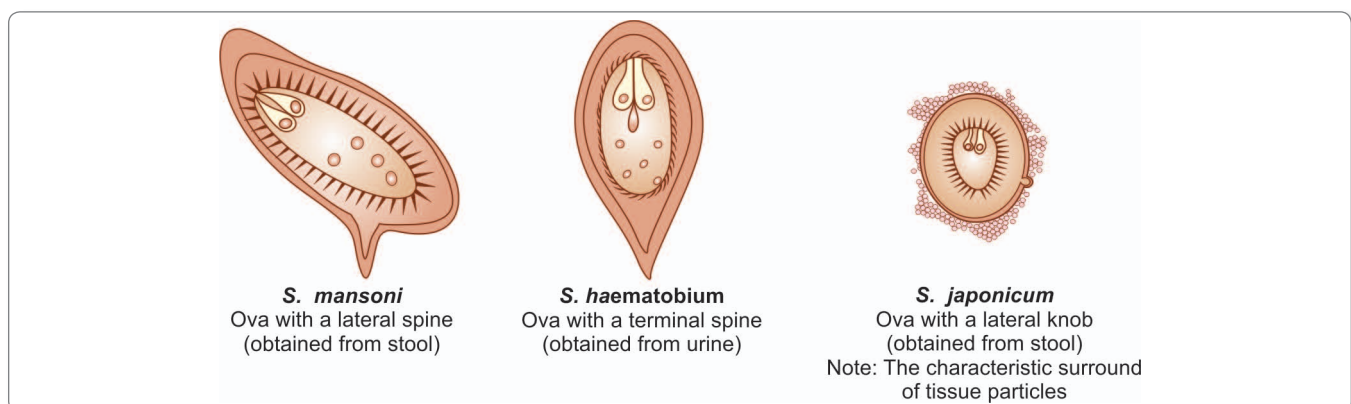


Fig. 13.7: Schematic diagram to show distinguishing features of eggs of *S. mansoni*, *S. haematobium*, and *S. japonicum*

Infective form: *Fork-tailed cercaria*.

In humans, the schistosomulae mature in the liver and the adult worms move against the blood stream into the venules of the **inferior mesenteric** group in the **sigmoidorectal** area. Eggs penetrate the gut wall, reach the colonic lumen, and are shed in feces.

Pathogenicity and Clinical Features

- **Following skin penetration by cercariae:** A pruritic rash called as **cercarial dermatitis** or swimmers itch may develop locally. Cercarial dermatitis is a self-limiting clinical entity.
- **During maturation and at the beginning of oviposition** (i.e. 4–8 weeks after skin invasion): Acute schistosomiasis or Katayama fever (a serum sickness-like syndrome) with fever, rash, myalgia, arthralgia, cough, generalized lymph adenopathy, and hepatosplenomegaly may develop.
 - Individual with acute schistosomiasis show high peripheral blood eosinophilia.
 - Parasite-specific antibodies may be detected at this stage before schistosoma eggs are identified in feces.
- **During the stage of egg deposition:** The symptomatology is mainly intestinal as the eggs are deposited in the small intestine. This condition is, therefore known as **intestinal bilharziasis** or schistosomal dysentery. Patients develop colicky abdominal pain and bloody diarrhea, which may go on intermittently for many years.
 - The eggs deposited in the gut wall cause inflammatory reactions leading to microabscesses, granulomas, hyperplasia, and eventual fibrosis. Egg granulomas are found in the distal part of the colon and rectum. Ectopic lesions include hepatosplenomegaly and periportal fibrosis, portal hypertension, as some of the eggs are carried through portal circulation into liver.
 - Portal hypertension may cause gastrointestinal hemorrhage.

Laboratory Diagnosis*Stool Microscopy*

Eggs with lateral spines may be demonstrated microscopically in stools. **Kato-katz thick smear** or other concentration methods may be required when infection is light. **Kato-katz thick smear** provides quantitative data on the intensity of infection, which is of value in assessing the degree of tissue damage and monitoring the effect of chemotherapy.

Rectal Biopsy

Proctoscopic biopsy of rectal mucosa may reveal eggs when examined as fresh squash preparation between 2 slides.

Serological Diagnosis

Serological diagnosis by detecting schistosomal antigen and antibody is similar to that of *S.haematobium*.

Imaging

Ultrasonography (USG) is useful to detect hepatosplenomegaly and periportal fibrosis.

Blood Examination

Blood examination may reveal eosinophilia, and increased levels of alkaline phosphatase.

Treatment

Praziquantel (single oral dose 40 mg/kg) is the drug of choice.

Oxamniquine (single oral dose 15 mg/kg.) is also effective. It damages the tegument of male worm and thereby, makes the worm more susceptible to lethal action of the immune system.

Prophylaxis

Same as *S. haematobium*

Schistosoma Japonicum

Common name: Oriental blood fluke

Distribution

S. japonicum is found in the far east, Japan, China, Taiwan, Philippines, and Sulawesi.

Habitat

The adult worms are seen typically in the venules of the superior mesenteric vein draining the ileocecal region. They are also seen in the intrahepatic portal venules and hemorrhoidal plexus of veins.

Morphology

Morphologically, they are similar to the schistosomes described above except—

- The adult male is comparatively slender (0.5 mm thick) and does not have cuticular tuberculations.
- In the gravid female, the uterus contains as many as 100 eggs at one time and up to 3,500 eggs may be passed daily by a single worm.
- The prepatent period is 4–5 weeks.
- The eggs are smaller and more spherical than those of *S. haematobium* and *S. mansoni*. The egg has **no spine**, but shows a lateral small rudimentary knob (Fig. 13.7).

Table 13.3: Differentiating Features of *S. haematobium*, *S. mansoni* and *S. japonicum*

	<i>Schistosoma haematobium</i>	<i>Schistosoma mansoni</i>	<i>Schistosoma japonicum</i>
Habitat	Veins of the vesical and pelvic plexuses, less commonly in portal vein and its mesenteric branches	Inferior mesenteric vein and its branches	Superior mesenteric vein and its branches
Morphology			
Size: <i>Male</i>	1.5 cm × 1 mm	1 cm × 1 mm	1.2–2 cm × 0.5 mm
<i>Female</i>	2 cm × 0.22 mm	1.4 cm × 0.25 mm	2.6 cm × 0.3 mm
Integument	Finely tuberculated	Grossly tuberculated	Non-tubercular
Number of testes	4–5 in groups	8–9 in a zigzag row	6–7 in a single file
Ovary	In the posterior one-third of the body	In the anterior half of the body	In the middle of the body
Uterus	Contains 20–30 eggs	1–3 eggs	50 or more eggs
Egg	Elongated with terminal spine	Elongated with lateral spine	Round with small lateral knob
Cephalic glands in Cercariae	2 pairs oxyphilic and 3 pairs basophilic	2 pairs oxyphilic and 4 pairs basophilic	5 pairs oxyphilic, no basophilic
Distribution	Africa, Near East, Middle East, India	Africa and south America	China, Japan, far east (oriental)
Definitive host	Man	Man	Man (mainly) domestic animals & rodents (which act as reservoir of infection)
Intermediate host	Snail of Genus <i>Bulinus</i>	Snail of Genus <i>Biomphalaria</i>	Amphibian snail of Genus <i>Oncomelania</i>

Differentiating features between the 3 species of *Schistosoma* are illustrated in Table 13.3.

Life Cycle

Life cycle of *S. japonicum* is similar to *S. haematobium* with the following exceptions.

Definitive host: Man is the definitive host but in endemic areas, natural infection occurs widely in several domestic animals and rodents, which act as reservoirs of infection.

Intermediate host: Amphibian snails of the genus *Oncomelania*.

Infective form for humans: Fork tailed cercaria.

- Eggs deposited in the **superior mesenteric venules** penetrate the gut wall and are passed in feces.
- They hatch in water and the **miracidia** infect the **intermediate hosts**, amphibian **snails** of the genus *Oncomelania*.
- The fork-tailed cercaria, which escapes from the snails is the **infective form** for men and other definitive hosts.

Pathogenicity and Clinical Features

Disease caused by *S. japonicum* is also known as **oriental schistosomiasis** or **Katayama disease**.

- Its pathogenesis is similar to that in other schistosomiasis, but probably because of the higher egg output, the clinical manifestations are more severe.

- During the acute phase of the disease, **Katayama fever** is similar to that seen in *S. mansoni*.
- In the chronic illness intestinal, hepatosplenic as well as several manifestations associated with portal hypertension are seen. Intestinal disease manifests as colicky abdominal pain, bloody diarrhoea and anemia. However, the liver is the site maximally affected. There is initial hepatomegaly followed by periportal fibrosis (**clay pipe stem fibrosis**). Portal hypertension leads to esophageal varices and gastrointestinal bleeding. The spleen is secondarily enlarged.
- Cerebral and pulmonary involvement (cor pulmonale) may occur in some cases.



Parasites leading to bloody diarrhea

- Intestinal schistosoma species:
 - *S. japonicum*
 - *S. mansoni*
 - *S. intercalatum*
 - *S. mekongi*
- *Trichuris trichiura*
- *Entamoeba histolytica*
- *Balantidium coli*

Laboratory Diagnosis

Similar to that of *S. mansoni*.

Treatment

S. japonicum infection is more resistant to treatment than other schistosomiasis. A prolonged course of intravenous tartar emetic gives good results. Praziquantel is the drug of choice.

Prophylaxis

Same as *S. hematobium*.

Schistosoma Intercalatum

This species, first recognized in 1934 is found in West-Central Africa.

- The eggs are fully embryonated without any operculum having terminal spines, but are passed exclusively in stools. The eggs are acid fast.
- It produces few symptoms involving the mesenteric portal system.
- Diagnosis is established by detection of the egg in feces and rectal biopsy.
- Praziquantel is the drug of choice.

Key points of Schistosomes

- Schistosomes are dieocious, sexes are separate.
- **Habitat:** In the mesenteric venous plexus (*S. mansoni* and *S. japonicum*) and vesical, and prostatic venous plexus (*S. haematobium*).
- Leaf-like unsegmented body with 2 cup-like suckers with delicate spines.
- Intestine is bifurcated (inverted 'y'-shaped).
- Male is broader than female.
- They produce elongated non-operculated eggs containing ciliated embryo, miracidium.
- **Definitive host:** Man.
- **Intermediate host:** Fresh water snails.
- **Infective form:** Fork-tailed cercariae.
- **Clinical features:** Swimmer's itch, Katayama fever, hematuria, and portal hypertension.
- **Diagnosis:** Detection of eggs in urine or stool, biopsy, imaging, and detection of antigen and antibody.
- **Treatment:** Praziquantel is the drug of choice.
- **Prophylaxis:** Avoidance of bathing in infected water and eradication of snail.

Schistosoma Mekongi

This species first recognized in 1978 is found in Thailand and Cambodia, along the Mekong river.

- It is closely related to *S. japonicum* but are slightly smaller and round.
- Man and dog are the definitive host.
- Man acquires infection in the same way as in *S. Japonicum*.
- Hepatosplenomegaly and ascites are the common clinical finding.

HERMAPHRODITIC FLUKES: LIVER FLUKES

The adult forms of all hermaphroditic flukes infecting humans live in the lumen of the biliary, intestinal, or respiratory tracts. This location affords the parasites considerable protection from host defense mechanisms and also facilitates dispersal of eggs to the environment.

- Flukes inhabiting the human biliary tract are *Clonorchis sinensis*, *Fasciola hepatica*, less often *Opisthorchis* species, and rarely, *Dicrocoelium dendriticum*.

Clonorchis Sinensis

Common name: The Chinese liver fluke, Oriental liver fluke

History and Distribution

C. sinensis was first described in 1875 by McConnell in the biliary tract of a Chinese carpenter in Calcutta Medical College Hospital.

- Complete life cycle of *Clonorchis* was worked out by Faust and Khaw in 1927.
- Human **clonorchiasis** occurs in Japan, Korea, Taiwan, China, and Vietnam, affecting about 10 million persons.

Habitat

Adult worm lives in the biliary tract and sometimes in the pancreatic duct.

Morphology

Adult worm

It has a flat, transparent, spatulate body; pointed anteriorly and rounded posteriorly (Fig. 13.8).

- It is 10–25 mm long and 3–5 mm broad.
- The adult worm can survive in the biliary tract for 15 years or more.
- The hermaphroditic worm discharges eggs into the bile duct.

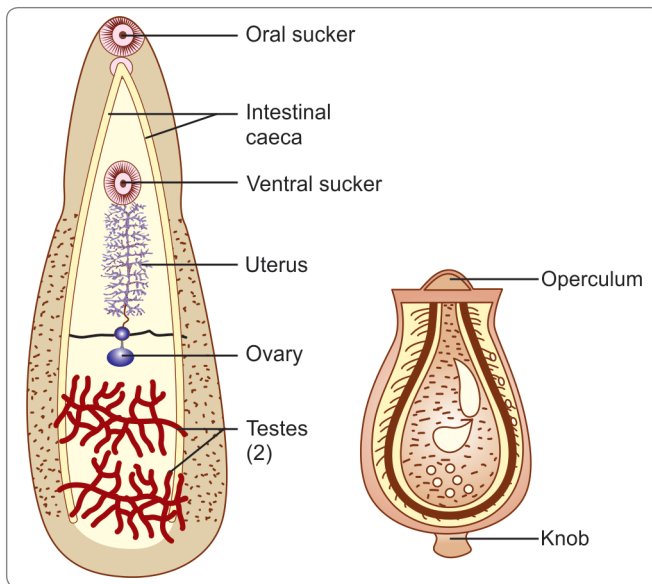


Fig. 13.8: Adult worm and egg of *Clonorchis sinensis*

Eggs

Eggs are broadly ovoid, 30 μm by 15 μm with a yellowish brown (bile-stained) shell.

- It has an operculum at one pole and a small hook-like spine at the other (Fig. 13.8).
- Eggs do not float in saturated solution of common salt.
- The eggs passed in feces contain the **ciliated miracidia**.

Life Cycle

Definitive host: Humans are the principal definitive host, but dogs and other fish-eating canines act as reservoir hosts.

Intermediate hosts: 2 intermediate hosts are required to complete its life cycle, the first being **snail** and the second being **fish**.

Infective form: Metacercaria larva

Mode of infection: Man acquires infection by eating undercooked fresh water fish carrying metacercariae larvae.

- *Clonorchis* eggs although embryonated do not hatch in water, but only when ingested by suitable species of **operculate snails** (First intermediate host), such as *Parafossarulus*, *Bulimus*, or *Alocinma* species.
- The miracidium develops through the **sporocyst** and **redia** stages to become the lophocercus cercaria with a large fluted tail in about 3 weeks (Fig. 13.9).
- The cercariae escape from the snail and swim about in water, waiting to get attached to the second intermediate host, suitable fresh-water fish of the Carp family.
- The cercariae shed their tails and encyst under the scales or in the flesh of the fish to become metacercariae, in about 3 weeks, which are the **infective stage** for humans.

- Infection occurs when such fish are eaten raw or inadequately processed by human or other definitive hosts. Frozen, dried, or pickled fish may act as source of infection (Fig. 13.9).
- Infection may also occur through fingers or cooking utensils contaminated with the metacercariae during preparation of the fish for cooking.
- The metacercariae excyst in the duodenum of the definitive host.
- The **adolescaria** that come out, enter the common bile duct through the **ampulla of Vater** and proceed to the distal bile capillaries, where they mature in about a month and assume the adult form (Fig. 13.8).
- Adult worms produce an average of 10,000 eggs per day, which exit the bile ducts and are excreted in the feces.
- The cycle is then repeated.

Pathogenicity

The migration of the larva up the bile duct induces desquamation, followed by hyperplasia, and sometimes, adenomatous changes. The smaller bile ducts undergo cystic dilatation.

- The adult worm may cause obstruction and blockage of the common bile duct leading to **cholangitis**.
- Patients in the early stage have fever, epigastric pain, diarrhea, and tender hepatomegaly. This is followed by biliary colic, jaundice, and progressive liver enlargement. Many infections are asymptomatic.
- Chronic infection may result in **calculus formation**.
- A few cases go on to **biliary cirrhosis** and **portal hypertension**.
- Some patients with chronic clonorchiasis tend to become biliary carriers of typhoid bacilli.
- Chronic infection has also been linked with **cholangiocarcinoma**.

Diagnosis

The eggs may be demonstrated in feces (**stool microscopy**) or aspirated bile. They do not float in concentrated saline.

- **Several serological tests** have been described including complement fixation and gel precipitation but extensive cross-reactions limit their utility. IHA with a saline extract of etherized worms has been reported to be sensitive and specific.
- **Intradermal allergic tests** have also been described.

Treatment

Drug of choice is Praziquantel 25 mg/kg, 3 doses in 1 day.

Surgical intervention may become necessary in cases with obstructive jaundice.

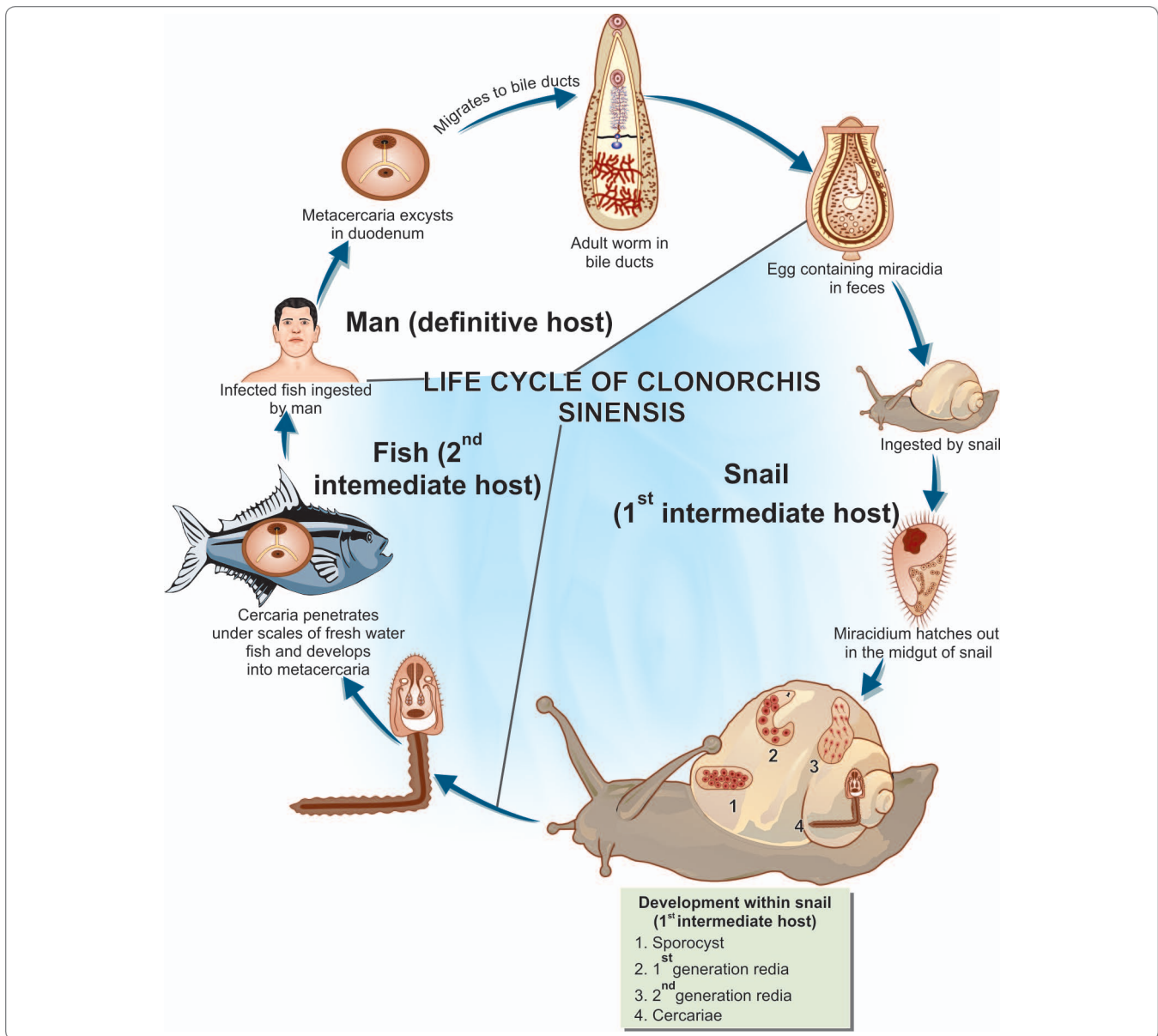


Fig. 13.9: Life cycle of *Clonorchis sinensis*

Prophylaxis

Clonorchiasis can be prevented by

- Proper cooking of fish
- Proper disposal of feces
- Control of snails.

Opisthorchis Species

Some species of *Opisthorchis*, which resemble *C. sinensis* can cause human infection.

- *O. felinus*, the cat liver fluke, which is common in Europe and the erstwhile Soviet Union, may infect humans.
- Infection is usually asymptomatic but may sometimes cause liver disease resembling **clonorchiasis**.
- *O. viverrini* is common in Thailand, where the civet cat is the reservoir host. Chandler found that 60% of cats in Calcutta, were infected with the parasite and human cases have also been reported from India.
- Except for the late sequelae, the exact clinical syndrome caused by clonorchiasis and opisthorchiasis are not well-defined. Since most infected individuals have a low worm burden, they are asymptomatic.

- *Cholangiocarcinoma* is epidemiologically related to *C. sinensis* infection in China and to *O. viverrini* infection in North-east Thailand.
- The life cycle and other features of *opisthorchis* are same as those of *Clonorchis*.

Fasciola Hepatica

Common name: Sheep liver fluke

History and Distribution

F. hepatica was the first trematode that was discovered more than 600 years ago in 1379 by Jehan de Brie.

- It was named by Linneus in 1758.
- It is the largest and most common liver fluke found in humans, but its primary host is the sheep and to a less extent, cattle.
- It is worldwide in distribution, being found mainly in sheep-rearing areas.
- It causes the economically-important disease, 'liver rot,' in sheep.

Habitat

The parasite resides in the liver and biliary passages of the definitive host.

Morphology

Adult Worm

- It is a large leaf-shaped fleshy fluke, 30 mm long and 15 mm broad, grey or brown in color.

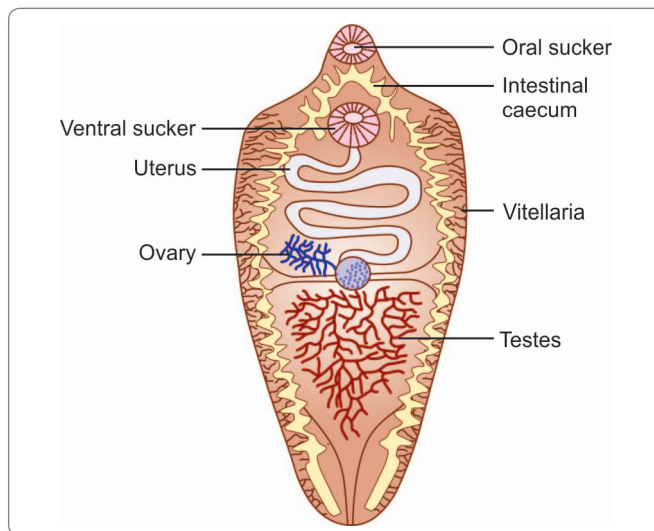


Fig. 13.10: Schematic diagram to show *Fasciola hepatica*

- It has a conical projection anteriorly containing an oral sucker and is rounded posteriorly (Fig. 13.10).
- The adult worm lives in the biliary tract of the definitive host for many years—about 5 years in sheep and 10 years in humans.
- Like all other trematodes, it is hermaphrodite.

Egg

The eggs are large, ovoid, operculated, bile-stained, and about 140 µm by 80 µm in size.

- Eggs contain an immature larva, the miracidium
- Eggs do not float in saturated solution of common salt
- Eggs of *F. hepatica* and *Fasciolopsis buski* cannot be differentiated
- Eggs are unembryonated when freshly passed.



Parasites with operculate eggs

- | | |
|----------------------------------|----------------------------------|
| • <i>Fasciola hepatica</i> | • <i>Fasciola gigantica</i> |
| • <i>Fasciolopsis buski</i> | • <i>Clonorchis sinensis</i> |
| • <i>Paragonimus westermani</i> | • <i>Gastrodiscoides hominis</i> |
| • <i>Opisthorchis felinus</i> | • <i>Opisthorchis viverrini</i> |
| • <i>Heterophyes heterophyes</i> | • <i>Diphyllbothrium latum</i> |

Life Cycle

F. hepatica passes its life cycle in 1 definitive host and 2 intermediate hosts.

Definitive host: Sheep, goat, cattle, and man.

Intermediate host: Snails of the genus *Lymnaea* and *Succinea*. Encystment occurs on aquatic plants, which act as **second intermediate host**.

Mode of infection: The definitive host, sheep and man, get infection by ingestion of **metacercariae** encysted on aquatic vegetation.

- Adult worm lives in the **biliary passage** of sheep or man. Eggs are laid in the biliary passages and are shed in feces.
- The embryo matures in water in about 10 days and the **miracidium** escapes. It penetrates the tissues of first intermediate host, snails of the genus *Lymnaea* (Fig. 13.11).
- In snail, the miracidium progresses through the **sporocyst** and the first and second generation **redia** stages to become the cercariae in about 1–2 months.
- The cercariae escape into the water and encyst on aquatic vegetation or blades of grass to become metacercariae, which can survive for long periods.
- Sheep, cattle, or humans eating watercress or other water vegetation containing the metacercaria become infected.
- The metacercariae excyst in the duodenum of the definitive host and pierce the gut wall to enter the peritoneal cavity.

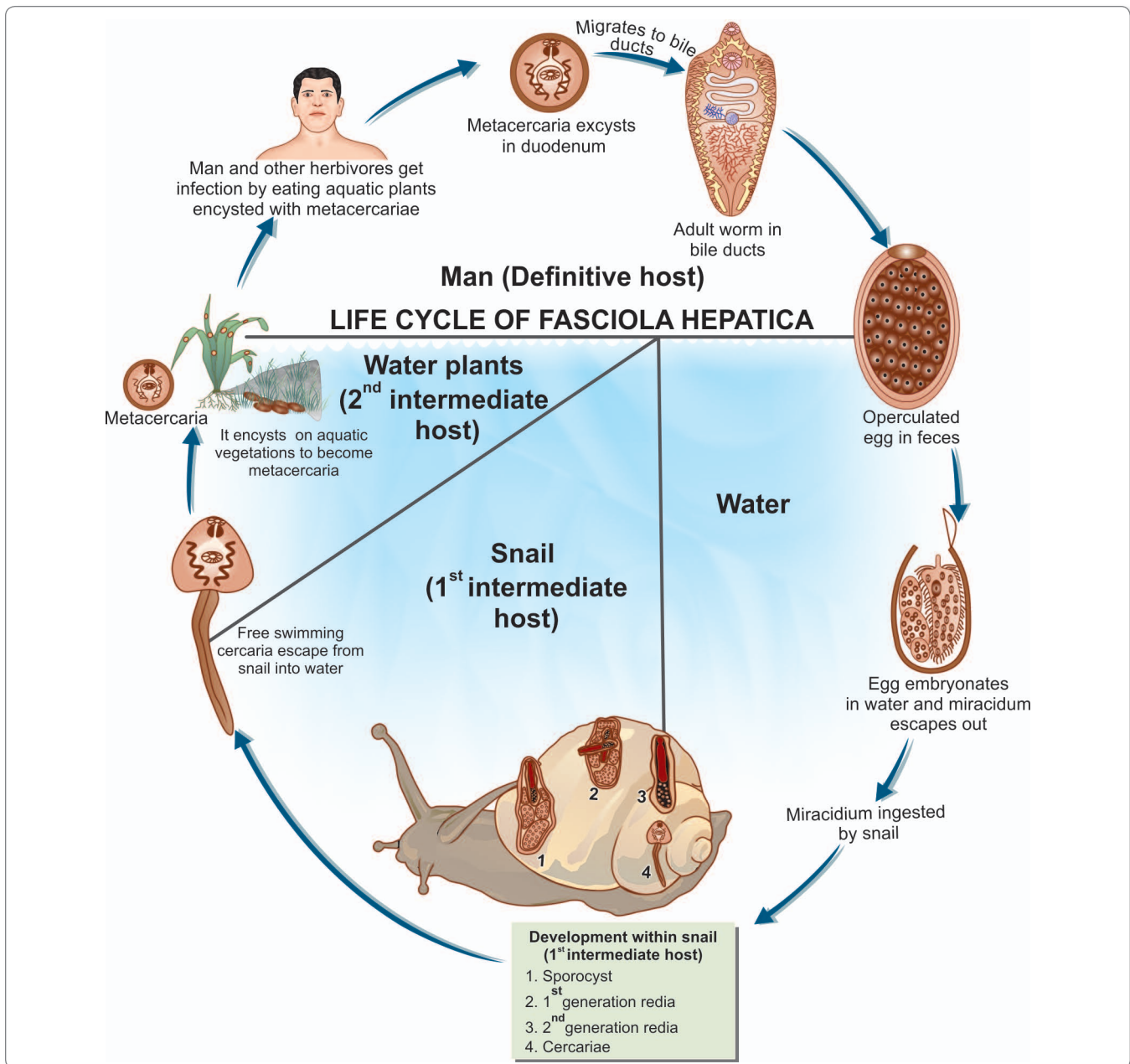


Fig. 13.11: Life cycle of *Fasciola hepatica*

- They penetrate the Glisson's capsule, traverse the liver parenchyma, and reach the biliary passages, where they mature into the adult worms in about 3–4 months (Fig. 13.11).



Parasites with aquatic vegetations as the source of infection

- *Fasciola hepatica*
- *Fasciolopsis buski*
- *Gastrodiscoides hominis*
- *Watsonius watsoni*

Pathogenicity

- **Fascioliasis** differs from clonorchiasis in that *F. hepatica* is larger and so causes more mechanical damage. In traversing the liver tissue, it causes parenchymal injury. As humans are not its primary host, it causes more severe inflammatory response. Some larvae penetrate right through the liver and diaphragm ending up in the lung.
- In acute phase during the migration of the larva, patients present with fever, right upper quadrant pain, eosinophilia, and tender hepatomegaly. The symptoms subside as parasites reach their final destination.

- In **chronic phase**, patients may develop biliary obstruction, biliary cirrhosis, obstructive jaundice, cholelithiasis, and anemia. No association to hepatic malignancy has been ascribed to **fascioliasis**.
- Occasionally, ingestion of raw liver of infected sheep results in a condition called **halzoun** (meaning *suffocation*). The adult worms in the liver attach to the pharyngeal mucosa, causing **edematous congestion** of the pharynx and surrounding areas, leading to dyspnea, acute dysphagia, deafness, and rarely, asphyxiation. However, this condition is more often due to pentastome larvae. Halzoun is particularly common in Lebanon and other parts of the Middle East and North Africa.
- Proper disinfection of watercourses and other water vegetations before consumption.

Key points of *Fasciola hepatica*

- Largest and commonest liver fluke.
- Large leaf-shaped with a dorsoventrally flattened body.
- Hermaphroditic parasite.
- Eggs are ovoid, operculated, and bile-stained.
- **Definitive host:** Primary definitive host is sheep, but it is also found in biliary tract of man.
- **First Intermediate host:** Fresh water snails (*Lymnaea*).
- **Second Intermediate host:** Aquatic vegetations.
- **Infective form:** Metacercariae encysted on raw aquatic vegetations.
- **Clinical features:** Acute phase—fever, right upper quadrant pain, hepatomegaly. Chronic phase—biliary obstruction, obstructive jaundice, cholelithiasis, and anemia.
- **Diagnosis:** Detection of eggs in stool and aspirated bile, USG, ERCP and ELISA
- **Treatment:** Oral triclabendazole or bithional.
- **Prophylaxis:** Preventing pollution of water with feces and proper disinfection.

Diagnosis

Stool Microscopy

Demonstration of eggs in feces or aspirated bile from duodenum is the best method of diagnosis. Eggs of *F. hepatica* and *F. buski* are indistinguishable.

Blood Picture

It reveals eosinophilia.

Serodiagnosis

Serological tests such as immunofluorescence, ELISA, immunoelectrophoresis, and complement fixation are helpful in lightly-infected individuals for detection of specific antibody. ELISA becomes positive within 2 weeks of infection and is negative after treatment. In chronic fascioliasis, *Fasciola* copro-antigen may be detected in stool.

Imaging

USG, CT scan, Endoscopic Retrograde Choangiopancreatography (ERCP) and percutaneous cholangiography may be helpful in diagnosis.

Treatment

Oral triclabendazole (10 mg/kg once) is the treatment of choice.

- Alternative drug is bithionol (30–50 mg for 10–15 days)
- Prednisolone at a dose of 10–20 mg/kg is used to control toxemia.

Prophylaxis

Fascioliasis can be prevented by

- Health education
- Preventing pollution of water courses with sheep, cattle, and human feces

Dicrocoelium Dendriticum

Also known as the '*lancet fluke*' because of its shape, *D. dendriticum* is a very common biliary parasite of sheep and other herbivores in Europe, North Africa, Northern Asia and parts of the far east.

Definitive host: Sheep and other herbivores

First intermediate host: Snails

Second intermediate host: Ants of genus *Formica*

- Eggs passed in feces of sheep are ingested by land snails.
- Cercariae appear in slime balls secreted by the snails and are eaten by ants of the genus *Formica*, in which metacercariae develop.
- Herbivores get infected when they accidentally eat the ants while grazing.
- Reports of human infection have come from Europe, Middle East and China.
- However, spurious infection is more common. In the latter, the eggs can be passed in feces for several days by persons eating infected sheep liver.
- ***Eurytrema pancreaticum***, a related fluke is commonly present in the pancreatic duct of cattle, sheep, and monkeys. Occasional human infection has been noticed in China and Japan.

INTESTINAL FLUKES

A number of flukes parasitize the human small intestine. These include *Fasciolopsis buski*, *Heterophyes*, *Metagonimus yokogawai*, *Watsonius watsoni*, and *Echinostoma*. Only one fluke *Gastrodiscoides hominis*, parasitizes the human large intestine.

Fasciolopsis Buski

Common name: Giant intestinal fluke

History and Distribution

It was first described by Busk in 1843 in the duodenum of an East Indian sailor, who died in London.

- It is a common parasite of man and pigs in China and in South-east Asian countries.
- In India it occurs in Assam and Bengal.

Habitat

The adult worm lives in the duodenum or jejunum of pigs and man.

Morphology

Adult worm

The adult is a large fleshy worm, 20–75 mm long and 8–20 mm broad (Fig. 13.12) and 0.5–3 mm in thickness.



- Largest trematode infecting humans: *Fasciolopsis buski*
- Smallest trematode infecting humans: *Heterophyes*

- It is elongated ovoid in shape, with a small oral sucker and a large acetabulum. It has no cephalic cone as in *F. hepatica* (Fig. 13.13).
- The adult worm has a lifespan of about 6 months.
- The two intestinal caeca do not bear any branches (Fig. 13.13).

Eggs

- The operculated eggs are similar to those of *F. hepatica*.
- Eggs are laid in the lumen of the intestine in large numbers, about 25,000 per day.

Life Cycle

F. buski passes its life cycle in 1 definitive host and 2 intermediate host.

Definitive host: Man and pigs. Pigs serve as a reservoir of infection for man.

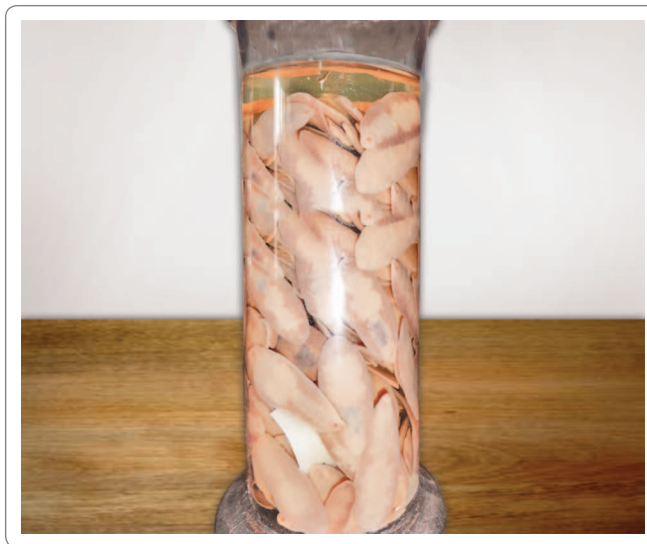

Fig. 13.12: Specimen showing *Fasciolopsis Buski*

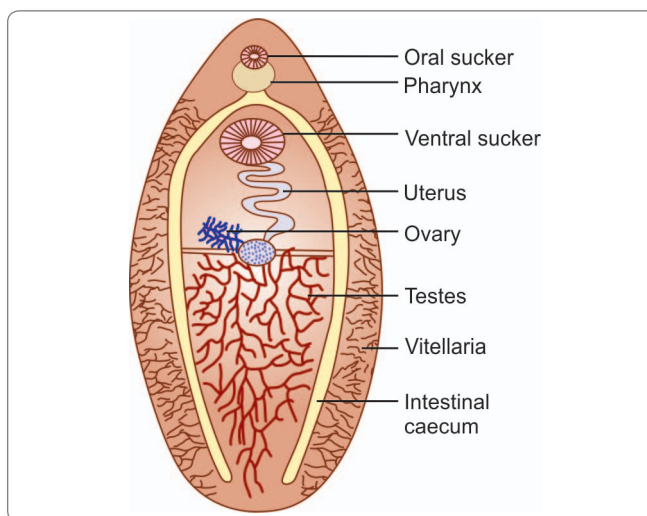


Fig. 13.13: Schematic diagram to show *Fasciolopsis buski*

First intermediate host: Snails of the genus *Segmentina*

Second intermediate host: Encystment occurs on **aquatic plants**, roots of the lotus, bulb of the water chestnut which act as **second intermediate host**.

Infective form: Encysted metacercariae on aquatic vegetation

- The eggs passed in feces of definitive host hatch in water in about 6 weeks, releasing the miracidia which swim about.
- On coming in contact with a suitable molluscan intermediate host, snails of the genus **Segmentina**, miracidia penetrates its tissues to undergo development in the next few weeks as sporocyst, first and second generation rediae, and cercariae (Fig. 13.14).

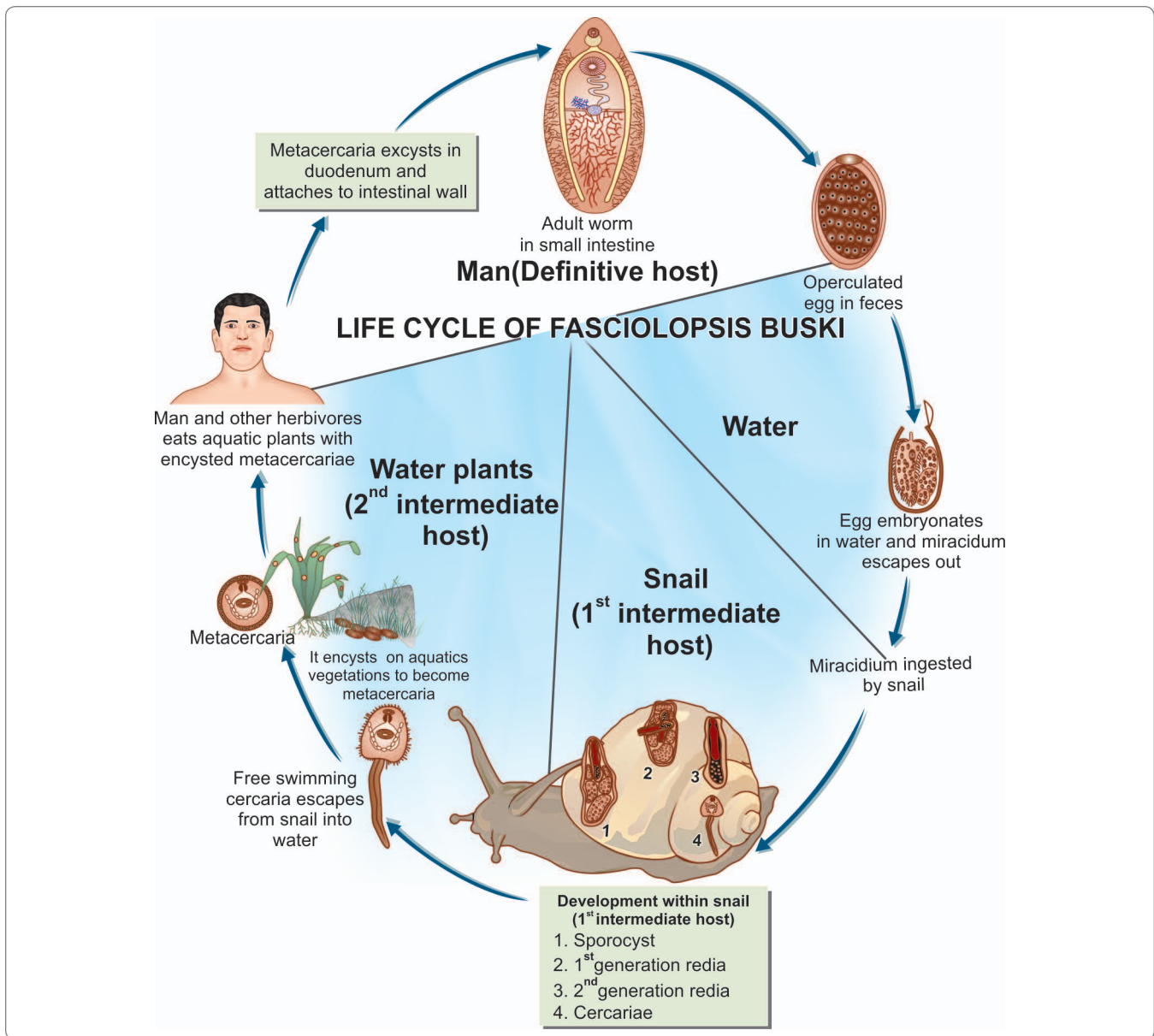


Fig. 13.14: Life cycle of *Fasciolopsis buski*

- The cercariae, which escape from the snail, encyst on the roots of the lotus, bulb of the water chestnut, and on other aquatic vegetations.
- When they are eaten by man, the metacercariae excyst in the duodenum, become attached to the mucosa and develop into adults in about 3 months (Fig. 13.14).
- Larvae that attach to the duodenal and jejunal mucosa cause inflammation and local ulceration. Intoxication and sensitization also account for clinical illness.
- In heavy infections, the adult worms cause partial obstruction of the bowel, malabsorption, protein-losing enteropathy, and impaired vit. B₁₂ absorption.
- The initial symptoms are diarrhea and abdominal pain.
- Toxic and allergic symptoms appear usually as edema, ascites, anemia, prostration, and persistent diarrhea.
- Paralytic ileus is a rare complication.

Pathogenesis

The pathogenesis of fasciolopsiasis is due to traumatic, mechanical, and toxic effects.

Laboratory Diagnosis

History of residence in endemic areas suggests the diagnosis, which is confirmed by demonstration of the egg in feces or of the worms after administration of a purgative or antihelminthic drug.

Treatment

Drug of choice is praziquantel.

- Hexylresorcinol and tetrachlorethylene have also been found useful.

Prophylaxis

- Treatment of infected persons.
- Adequate washing of water vegetables, preferably in hot water.
- Preventing contamination of ponds and other waters with pig or human excreta.
- Sterilization of night soil before use as fertilizer.
- Control of snails.

Heterophyes

This is the **smallest** trematode parasite of man.

- The infection is prevalent in the Nile delta, Turkey, and in the far east.
- The worm has been reported in a dog in India.
- The adult worm lives in the small intestine and has a lifespan of about 2 months.

Definitive hosts: Humans, cats, dogs, foxes and other fish eating mammals.

First intermediate host: Snails of the genera *Pironella* and *Cerithidea*.

Second intermediate host: Fishes, such as the mullet and tilapia; encystment occurs in fishes.

- Man acquires infection by eating raw or undercooked fishes containing metacercaria.
- In the small intestine, it can induce mucous diarrhea and colicky pains. Occasionally, the worms burrow into the gut mucosa, and their eggs are carried in the lymphatic and portal circulation to ectopic sites such as the brain, spinal cord and myocardium, where they induce granulomas. Rarely the worms themselves may be carried to these sites as emboli.
- Diagnosis is based on the finding of a minute operculated egg in the stool.

Drug of choice: Praziquantel.

Metagonimus Yokogawai

It is found in the far east, northern Siberia, Balkan states, and Spain.

Definitive hosts: Humans, pigs, dogs, cats and pelicans.

First intermediate host: Fresh water snail

Second intermediate host: Fish.

- Definitive hosts are infected by eating raw fish containing the metacercariae.
- Pathogenic effects consist of mucous diarrhoea and ectopic lesions in myocardium and central nervous system as in heterophyiasis.

Drug of choice: Praziquantel.

Watsonius Watsoni

This trematode infects various primates in Asia and Africa. Normal host is the monkey. Diagnosis, treatment, and prophylaxis is same as that of *Heterophyes*.

Echinostoma

Echinostomes are medium-sized flukes causing small intestinal infection of rats and dogs.

- Seen in Japan, Philippines, and all along the far east.
- The characteristic feature is a crown of spines on a disc surrounding the oral sucker, justifying its name '*Echinostoma*' which means '*spiny mouth*'.
- Its eggs resemble those of **fasciolopsis**. Mild infections are asymptomatic, but diarrhea and abdominal pain follow heavy infection.
- *E. ilocanum* is the species usually seen in human infections.

Gastrodiscoides Hominis

G. hominis is the only fluke inhabiting the human large intestine (Fig. 13.15).



Fig. 13.15: Specimen showing *Gastrodiscoides hominis*

- It was discovered by Lewis and McConnell in 1876 in the caecum of an Indian patient.
- It is a common human parasite in Assam. Cases have also been reported from Bengal, Bihar, and Orissa.
- It also occurs in Vietnam, Philippines, and some parts of erstwhile USSR.
- The adult worm is **pyriform**, with a conical anterior end and a discoidal posterior part. It is about 5-14 mm long and 4-6 mm broad.
- The eggs are operculated and measure 150 μm by 70 μm .

Definitive host: Man, pigs, monkey. Pigs are the reservoir hosts.

First intermediate host: Snails.

Second Intermediate host: Aquatic plants.

- The miracidia invade the tissues of the **intermediate molluscan host**.
- The cercariae encyst on water plants. Infected persons develop mucoid diarrhea.
- Man and animals become infected by feeding upon vegetations harboring the metacercaria.

Drug of choice: Praziquantel. Tetrachlorethylene is also useful in treatment.

LUNG FLUKES

Paragonimus Westermani

Common name: Oriental lung fluke

History and Distribution

P. westermani was discovered in 1878 by Kerbert in the lungs of Bengal tigers that died in the zoological gardens at Hamberg and Amsterdam.

- The parasite is endemic in the Far East—Japan, Korea, Taiwan, China, and south east asia—Sri Lanka and India. Cases have been reported from Assam, Bengal, Tamil Nadu, and Kerala.
- *P. mexicanus* is an important human pathogen in Central and South America.

Morphology

Adult Worm

The adult worm is **egg-shaped** about 10 mm long, 5 mm broad and 4 mm thick and reddish brown in color (Fig. 13.16).

- The integument is covered with scale like spines.
- It has an oral sucker placed anteriorly and a ventral sucker located towards the middle of the body (Fig. 13.17).
- It has 2 unbranched intestinal caeca which end blindly in the caudal area.
- They have a lifespan of up to 20 years in humans.

Egg

The eggs are operculated, golden brown in color and about 100 μm by 50 μm in size.

- They are unembryonated when freshly laid.

Habitat

Adults worms live in the lungs, usually in pairs in cystic spaces that communicate with bronchi.

Helminths present in lung

Trematode

- *Paragonimus westermani*

Cestode

- *Echinococcus granulosus*

Nematode

- *Capillaria aerophila*
- *Dicrofilaria imnitis*

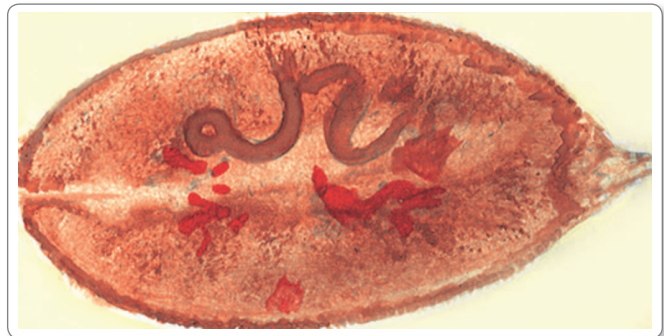

Fig. 13.16: *Paragonimus westermani* morphology

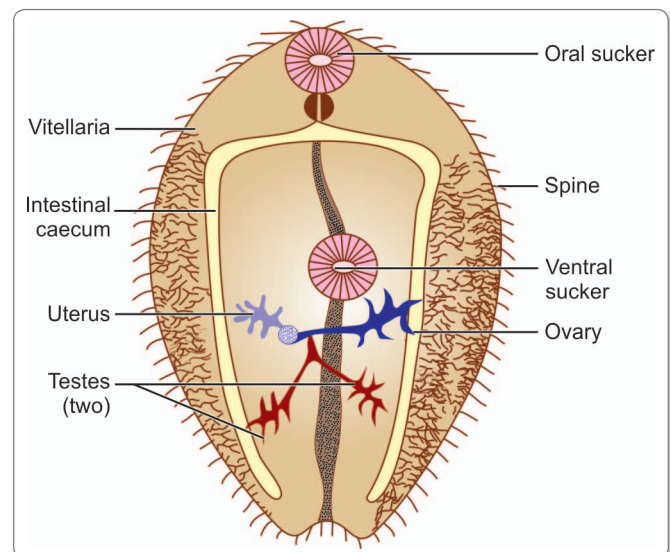


Fig. 13.17: Schematic diagram showing *Paragonimus westermani*

Life Cycle

Definitive host: Man. Besides humans, other definitive hosts include cats, tigers, leopards, foxes, dogs, pigs, beavers, mongoose, and many other crab-eating mammals and domestic animals.

First intermediate host: Fresh water snail, belonging to the genera *Semisulcospira* and *Brotia*.

Second intermediate host: Fresh water crab or cray fish.

Infective form: Metacercariae encysted in crab or cray fish.

Mode of infection: Man acquires infection by eating undercooked crab or cray fish containing metacercariae.

- The adult worms live in the respiratory tract of the definitive host.
- Unembryonated eggs escape into the bronchi and are coughed up and voided in sputum or swallowed and passed in feces (Fig. 13.18).
- The eggs mature in about 2 weeks and hatch to release free-swimming miracidia.

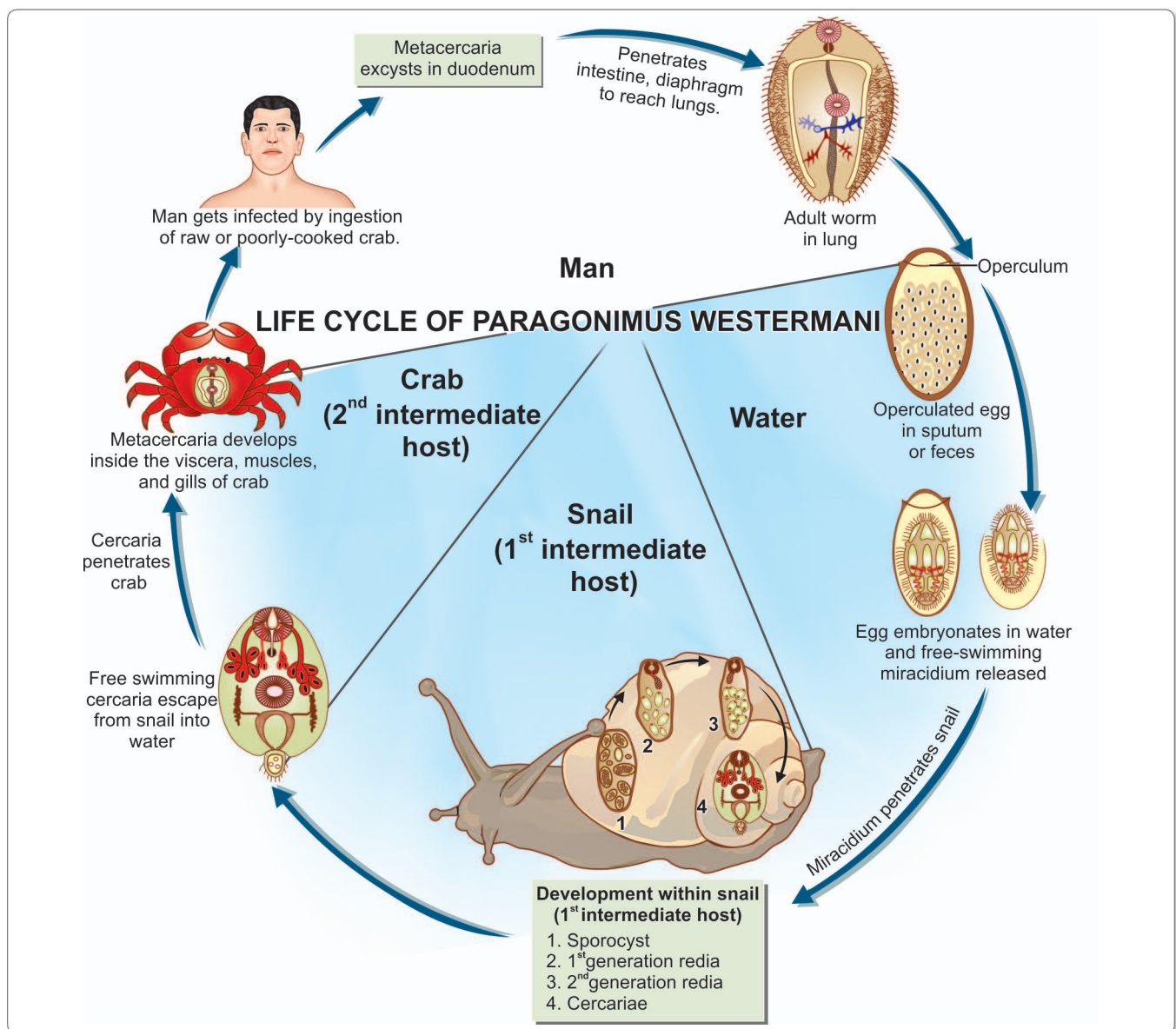


Fig. 13.18: Life cycle of *Paragonimus westermani*

- These infect the **first intermediate** molluscan host, snails belonging to the genera *Semisulcospira* and *Brotia*.
- Cercariae that are released from the snails after several weeks are microcercus, having a short stumpy tail.
- The cercariae that swim about in streams are drawn into the gill chambers of the **second intermediate crustacean host**, crabs or crayfish (Fig. 13.18).
- They encyst in the gills or muscles as **metacercariae**.
- Definitive hosts are infected when they eat such crabs or crayfish raw or inadequately cooked.
- The metacercariae excyst in the duodenum and the adolescaria penetrate the gut wall, reaching the abdominal cavity in a few hours.
- They then migrate up through the diaphragm into the pleural cavity and lungs finally reaching near the bronchi, where they settle and develop into adult worms in 2–3 months (Fig.13.18).
- The worm is hermaphroditic but usually it takes 2 for fertilization.
- Sometimes, the migrating larvae lose their way and reach ectopic sites such as the mesentery, groin, and brain.

Pathogenicity and Clinical Features

Pulmonary Features

In the lungs, the worms lie in cystic spaces surrounded by a fibrous capsule formed by the host tissues.

- The cysts, about a centimeter in diameter are usually in communication with a bronchus.
- Inflammatory reaction to the worms and their eggs lead to peribronchial granulomatous lesions, cystic dilatation of the bronchi, abscesses, and pneumonitis.
- Patients present with cough, chest pain, and hemoptysis.
- The viscous sputum is speckled with the golden brown eggs. Occasionally, the hemoptysis may be profuse.
- Chronic cases may resemble pulmonary tuberculosis.

Extrapulmonary Features

Paragonimiasis may also be extrapulmonary, the clinical features varying with the site affected—

- In the abdominal type, there may be abdominal pain and diarrhea.
- The cerebral type resembles cysticercosis and may cause Jacksonian epilepsy.
- Glandular involvement causes fever and multiple abscesses.

Laboratory Diagnosis

Microscopy

Demonstration of the eggs in sputum or feces provides definitive evidence.

Serology

Complement fixation test (CFT) is positive only during and shortly after active infection, while the intradermal test remains positive for much longer periods.

- IHA and ELISA tests are highly sensitive they become negative within 3–4 months after successful treatment.
- Serology is of considerable importance in egg-negative cases and in cerebral paragonimiasis.

Imaging

Chest X-ray reveals abnormal shadows (nodular, cystic, ring, infiltrative) in the middle and lower lung field.

- CT scan of chest also helps in diagnosis of pulmonary lesions and cerebral lesions. 'Soap-bubble' like appearance may be seen in cerebral cysts.

Treatment

- Praziquantel (25 mg/kg TDS for 1–2 days) is the drug of choice.
- Bithinol and Niclofolan are also effective in treatment.

Prophylaxis

- Adequate cooking of crabs and crayfish and washing the hands after preparing them for food.
- Treatment of infected persons.
- Disinfection of sputum and feces.
- Eradication of molluscan hosts.

Key points of *Paragonimus westermani*

- Adult worm is egg-shaped, reddish, brown and covered with scale like spine.
- **Habitat:** Cystic spaces in the lung.
- Eggs are oval, operculated, and golden brown.
- **Definitive hosts:** Man and domestic animals.
- **First intermediate host:** Snails of genera *Semisulcospira* (*melania species*).
- **Second intermediate host:** Crab or cray fish.
- **Infective form:** Encysted metacercaria in crab or cray fish.
- **Clinical features:** Peribronchial granuloma and cystic dilation of bronchi. Dyspnea, hemoptysis, pneumonitis, bronchiectasis, abscess, pneumothorax. Extrapulmonary lesions in brain and intestine.
- **Diagnosis:** Ova in sputum, X-ray and CT scan of chest, CFT, IHA, and ELISA.
- **Treatment:** Praziquantel is the drug of choice.
- **Prophylaxis:** Adequate cooking of crabs and crayfish, eradication of molluscan hosts and treatment of infected persons.

Review Questions

1. Describe briefly:

- (a) General characters of trematodes
- (c) General characters of schistosomes

- (b) Classification of trematodes

2. Short notes on:

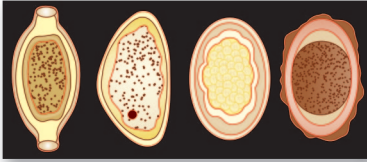
- (a) *Clonorchis sinensis*
- (c) *Paragonimus*

- (b) *Fasciolopsis buski*
- (d) *Opisthorchis* species

3. Describe morphology, life cycle and laboratory diagnosis of

- (a) *Fasciola hepatica*
- (b) *Schistosoma haematobium*

4. Differentiate between *Schistosoma haematobium*, *S. mansoni* and *S. japonicum*.



Nematodes: 14 General Features

Nematodes are said to be the most worm-like of all helminths. This is because they generally resemble the common earth worm in appearance, which is considered to be the prototype of 'worms'. However, taxonomically earthworms are not nematodes as they are segmented worms of the Phylum **Annelida**.

- Nematodes are elongated, cylindrical, unsegmented worms with tapering ends. The name '*nematode*' means '*thread-like*', from '*nema*' meaning '*thread*'.
- Unlike trematodes and cestodes, all of which are parasitic, most nematodes are **free-living** forms found in soil and water.
- Several species are parasites of plants and are of great economic importance. Many nematodes parasitize invertebrate and vertebrate animals.
- The largest number of helminthic parasites of humans belong to the class of nematodes. There are an estimated 500,000 species of nematodes.

General Characteristics

They are cylindrical, or filariform in shape, bilaterally symmetrical with a secondary **triradial symmetry at the anterior end**.

- The adults vary greatly in size, from about a millimeter (*Strongyloides stercoralis*) to a meter (*Dracunculus medinensis*) in length. Male is generally smaller than female and its posterior end is curved or coiled ventrally.

- Their body is covered with a **tough outer cuticle**, which may be smooth, striated, bossed, or spiny. The **middle** layer is hypodermis and the **inner layer** is the somatic muscular layer. They move by **sinuous flexion** of the body.
- The body cavity is a **pseudocoel**, in which all the viscera are suspended.
- The digestive system is complete, consisting of an anteriorly placed mouth leading to the esophagus, which characteristically varies in shape and structure in different groups. The intestine is lined with a single layer of columnar cells and leads to the rectum, opening through the anus. In the male, the rectum and the ejaculatory duct open into the **cloaca**.
- Nematodes have simple excretory and nervous systems.

? Types of female nematodes

The female nematodes may be divided as follows:

- **Oviparous** (laying eggs):
 - Unsegmented eggs: *Ascaris*, *Trichuris*
 - Segmented eggs: *Ancylostoma*, *Necator*
 - Eggs containing larvae: *Enterobius*
- **Viviparous** (producing larvae): *Trichinella*, *Wuchereria*, *Brugia*, *Dracunculus*.
- **Ovoviviparous** (laying eggs containing fully formed larvae, which hatch out immediately): *Strongyloides*.

- The nematodes are **dieocious** i.e. the sexes are separate.
- The male reproductive system consists of a single delicate tubule differentiated into testis, vas deferens, seminal vesicle, and ejaculatory duct, which opens into the cloaca. It also includes copulatory structures such as spicules or bursa or both.
- The female reproductive system consists of the ovary, oviduct, seminal receptacle, uterus, and vagina.
- Female nematodes may produce eggs (**oviparous**) or larvae (**viviparous**). Some lay eggs containing larvae, which immediately hatch out (**ovoviviparous**).

Life Cycle

The life cycle of nematodes consists typically of **4 larval stages** and the adult form. The cuticle is shed while passing from one stage to the other.

- Man is the **optimum host** for all the nematodes. They pass their life cycle in one host, except the **superfamilies Filarioidea** and **Dracunculoidea**, where two hosts are required. Insect vectors and *Cyclops* constitute the second hosts in these superfamilies, respectively.
- Nematodes localize in the intestinal tract and their eggs pass out with the feces of the host. They undergo few developmental changes before they enter new host.

Modes of Infection

- *By ingestion of:*
 - Eggs: *Ascaris*, *Enterobius*, *Trichuris*
 - Larvae within intermediate host: *Dracunculus*
 - Encysted larvae in muscle: *Trichinella*
- *By penetration of skin:* *Ancylostoma*, *Necator*, *Strongyloides*
- *By blood-sucking insects:* *Filariae*
- *By inhalation of dust containing eggs:* *Ascaris*, *Enterobius*.

Classification

Nematodes can be classified on the basis of the habitat of the adult worm (Table 14.1) and zoologically (Table 14.2).

Zoological Classification

Phylum – Nematelminthes (Nematoda)

Class – Nematoda which is divided into 2 subclasses based on the absence or presence of '**phasmids**', which are caudal chemoreceptors. The 2 subclasses were earlier called **Aphasmidia** and **Phasmidia**, but now have been renamed as **Adenophorea** and **Secernentea**, respectively (Table 14.3).

Detailed zoological classification of nematodes is given in Table 14.2.

Larva Migrans

The life cycles of most nematodes parasitizing humans include larval migration through various tissues and organs of the body. Sometimes the larvae appear to lose their way and wander around aimlessly. This condition is known as **larva migrans**.

- This is generally seen when human infection occurs with non-human species of nematodes. In such infections, the worm is unable to undergo normal development and complete its life cycle.
- Abnormal or arrested larval migration may also sometimes occur when human parasitic nematodes infect immune persons. The immunity is sufficient to prevent the normal progression of infection.
- Larva migrans can be classified into cutaneous or visceral types, depending on whether the larval migration takes place in the skin or in deeper tissues (Table 14.4).

Table 14.1: Classification of Nematodes on the Basis of the Habitat of Adult Worms

Intestinal Human Nematodes	Somatic Human Nematodes
Small Intestine <ul style="list-style-type: none"> • <i>Ascaris lumbricoides</i> (Common round worm) • <i>Ancylostoma duodenale</i> (Old world Hook worm) • <i>Necator americanus</i> (American or New World Hook worm) • <i>Strongyloides stercoralis</i> • <i>Trichinella spiralis</i> • <i>Capillaria philippinensis</i> Large intestine <ul style="list-style-type: none"> • <i>Trichuris trichiura</i> (Whip worm) • <i>Enterobius vermicularis</i> (Thread or pin worm) 	Lymphatics <ul style="list-style-type: none"> • <i>Wuchereria bancrofti</i> • <i>Brugia malayi</i> • <i>Brugia timori</i> Skin/subcutaneous tissue <ul style="list-style-type: none"> • <i>Loa loa</i> • <i>Onchocerca volvulus</i> • <i>Dracunculus medinensis</i> (Guinea worm) Mysentery <ul style="list-style-type: none"> • <i>Mansonella ozzardi</i> • <i>Mansonella perstans</i> Conjunctiva <ul style="list-style-type: none"> • <i>Loa loa</i>

Table 14.2: Zoological Classification of Nematodes

Subclass	Order	Superfamily	Family	Genus	Species
Adenophorea/ Aphasamida (no phasmids; no caudal papillae in male; eggs usually unsegmented with polar plugs or hatching in uterus)	Enoplida	Trichinelloidea (anterior part of body narrower than posterior)	Trichinellidae Trichuridae	<i>Trichinella</i> <i>Trichuris</i> <i>Capillaria</i>	<i>T. spiralis</i> <i>T. trichiura</i> <i>C. philippinensis</i> <i>C. aerophila</i> <i>C. hepatica</i>
Secernentea/ Phasmodia (phasmids present; numerous caudal papillae)	Rhabditida	Rhabditoidea (alternation of free-living and parasitic generations; parasitic females parthenogenetic)	Strongyloididae	<i>Strongyloides</i>	<i>S. stercoralis</i>
	Strongylida	Ancylostomatoidea (prominent buccal capsule with teeth or cutting plates) Metastrongyloidea (tissue parasites; inconspicuous buccal capsule; have intermediate hosts)	Ancylostomatidae Angiostrongylidae	<i>Ancylostoma</i> <i>Necator</i> <i>Angiostrongylus</i>	<i>A. duodenale</i> <i>N. americanus</i> <i>A. cantonensis</i>
	Ascaridida	Ascaridoidea (large worms of gut lumen; mouth has 3 lips)	Ascarididae Anisakidae	<i>Ascaris</i> <i>Anisakis</i>	<i>A. lumbricoides</i> <i>A. simplex</i>
	Oxyurida	Oxyuroidea (male has no caudal bursa; short stout body; esophagus has prominent bulb; eggs planoconvex, embryonate in uterus)	Oxyuridae	<i>Enterobius</i>	<i>E. vermicularis</i>
	Spirurida	Filarioidea (tissue parasites; viviparous; insect vector) Dracunculoidea (very long female and small male; viviparous; larvae escape from ruptured uterus) Gnathostomatoidea (spiny body with bulbous head)	Onchocercidae Dracunculidae Gnathostomatidae	<i>Wuchereria</i> <i>Brugia</i> <i>Dirofilaria</i> <i>Loa</i> <i>Mansonella</i> <i>Onchocerca</i> <i>Dracunculus</i> <i>Gnathostoma</i>	<i>W. bancrofti</i> <i>B. malayi</i> <i>D. conjunctivae</i> <i>D. immitis</i> <i>L. loa</i> <i>M. perstans</i> <i>M. ozzardi</i> <i>M. streptocerca</i> <i>O. volvulus</i> <i>D. medinensis</i> <i>G. spinigerum</i>

Table 14.3: Differences in Subclass Adenophorea and Secernentea

	Adenophorea	Secernentea
Phasmid (sensory structure)	Absent	Present
Excretory system	Without lateral canals	With lateral canals
Caudal papillae	Absent or few	Numerous
Infective stage of larva	1 st larval stage	3 rd larval stage

Table 14.4: Animal Nematodes Infecting Man

Visceral Larva Migrans	Cutaneous Larva Migrans
<ul style="list-style-type: none"> It is a syndrome caused by nematodes that are normally parasitic for nonhuman host species In human, these nematode larvae do not develop into adult worms, but, instead, migrate through host tissues and elicit eosinophilic inflammation 	<ul style="list-style-type: none"> It is a serpiginous skin eruption caused by burrowing larvae of animal hookworms, (usually the cat and the cat hook worm) The larvae hatch from eggs passed in dog and cat feces and mature in the soil. Humans become infected after skin contact with contaminated soil. After larvae penetrate the skin, erythematous lesions form along the tortuous tracks of their migration. It is also known as creeping eruption
<p>Common causes:</p> <ul style="list-style-type: none"> <i>Toxocara canis</i> (dog round worm) - most common <i>Toxocara cati</i> (cat round worm) <i>Ascaris suum</i> (pig ascaris) <i>Angiostrongylus cantonensis</i> <i>Gnathostoma spinigerum</i> <i>Anisakis simplex</i> <i>Baylisascaris procyonis</i> 	<p>Common causes:</p> <ul style="list-style-type: none"> <i>Ancylostoma braziliense</i> (hookworm of wild and domestic dogs and cats) <i>Ancylostoma caninum</i> (dog hookworm found in Australia) <i>Uncinaria stenocephala</i> (dog hookworm found in Europe) <i>Bunostomum phlebotomum</i> (cattle hookworm)

Cutaneous Larva Migrans

This condition also known as **creeping eruption** (also called **ground itch**) is caused by nematode larvae that infect by skin penetration.

Etiology

The most common cause is **non-human** species of **hookworm** (*Ancylostoma braziliense* and *A. caninum*).

Etiological agents

Zoophilic Nematode	Human Nematode
<ul style="list-style-type: none"> <i>Ancylostoma braziliense</i> <i>Ancylostoma caninum</i> <i>Gnathostoma spinigerum</i> <i>Dirofilaria</i> <i>Spirometra</i> <i>Uncinaria stenocephala</i> <i>Bunostomum phlebotomum</i> 	<ul style="list-style-type: none"> <i>Strongyloides stercoralis</i> <i>Necator americanus</i> <i>Loa Loa</i>
	Human Trematode
	<ul style="list-style-type: none"> Ectopic infection with <i>Fasciola</i> and <i>Paragonimus</i>
	Non-helmenthic agents
	<ul style="list-style-type: none"> Flies of genus <i>Hypoderma</i> and <i>Gastrophilus</i>

Pathogenesis

Parasite eggs are passed in the feces of infected animals into the soil, where the larvae hatch out.

- Infection with these hookworms of **dogs** and **cats** is acquired from soil contaminated with excreta of these animals.
- On coming in contact with human skin, the larvae penetrate the skin to cause infection.

- Between a few days and a few months after the initial infection, the larvae migrate beneath the skin.
- In normal animal host, the larvae are able to penetrate the deeper layers of the skin by reaching there via circulation.
- Once they enter intestine, they mature sexually and lay more eggs that are then excreted to repeat the cycle.
- However, in a human host, which is an accidental host for the parasite, the larvae are unable to penetrate the basement membrane to invade the dermis, so that the disease remains confined to the outer layers of the skin.

Clinical Features

- The larvae produce **itching papules**, which develop into **serpiginous tunnels** in the epidermis. With the movements of the larva in the skin, the lesion also shifts, hence the name 'creeping eruption'. Scratching may lead to secondary bacterial infection.
- Transient **creeping eruptions** may be produced sometimes by the **human hookworm**, *Necator americanus*. **Gnathostomiasis** and **sparganosis** may produce larva migrans, where the lesions are deeper, subcutaneous or in the muscles. **Loeffler's syndrome** may occur in one-fourth to one-half of the cases.
- A rapidly moving lesion is produced by *Strongyloides stercoralis* particularly in immune persons. This is known as **larva currens**.
- **Creeping myiasis** is caused by flies of the genus *Hypoderma* and *Eastrophilus*.
- Ectopic infections with *Fasciola* and *Paragonimus* may produce creeping lesions on abdominal wall.

Diagnosis

Eosinophilia is rare and occurs only when Loeffler's syndrome develop.

- Serological tests are not developed.
- On biopsy, larvae are rarely found in the skin lesion.
- Diganosis is based mainly on clinical features.

Treatment

Thiabendazole is useful in treatment. When the lesions are few, freezing the advancing part of the eruption with ethyl chloride is effective.

Visceral Larva Migrans

This condition is caused by the migration of larvae of **non-human species** of nematodes that infect by the oral route.

Etiology

The most common cause is the **dog ascarid**, *Toxocara canis* and less often the cat ascarid, *T. cati*. Visceral larva migrans may also be caused by *Anisakis*, which are large ascarid parasites of marine animals and also by *Gnathostoma spinigerum*, *Angiostrongylus cantonensis*. **Human nematodes** like *A. lumbricoides* and *S. stercoralis* may produce visceral larva migrans, when they get lost in ectopic sites.

Etiological agents

Zoophilic Nematode

- *Toxocara canis*
- *Toxocara cati*
- *Angiostrongylus cantonensis*
- *Angiostrongylus costaricensis*
- *Anisakis*
- *Gnathostoma spinigerum*

Nonhuman Nematode

- *Filaria* spp.
- *Dirofilaria immitis*
- *Brugia pahangi*
- *Brugia patei*

Human Nematode

- *Ascaris lumbricoides*
- *Strongyloides stercoralis*

Pathogenesis

When the infective eggs present in the soil contaminated by dog and cat feces are ingested, the larvae hatch in the small intestine, penetrate the gut wall, and migrate to the liver.

- They may remain there or migrate to other organs such as lungs, brain, or eyes.
- In humans they do not develop into adults, but induce **granulomatous** lesions, which cause local damage.

Clinical Features

Clinical manifestations depend on the sites affected and the degree and duration of infection.

- As **children** are more likely to swallow dirt, this condition is much more frequent in them.
- Fever, hepatomegaly, pneumonitis, hyperglobulinaemia, and pica are the common findings.
- Patients may develop neurological disturbances (**neural larva migrans**) and endophthalmitis (**ophthalmic larva migrans**).
- Marked leukocytosis occurs with persistently high eosinophilia.

Diagnosis

Serological tests, such as passive hemagglutination, bentonite flocculation, microprecipitation, and more specifically, ELISA have been developed for the diagnosis of toxocariasis (visceral larva migrans).

Treatment

Diethylcarbamazine (DEC), 100 mg TDS for 3 weeks in an adult, kills the larva and arrest the disease. Thiabendazole may be useful in treatment. Prednisolone should be administered concurrently either topically or systemically.

Prophylaxis

Deworming of household pets helps in prevention by limiting the contamination of soil.

Differences between cutaneous and visceral larva migrans are given in Table 14.5.

Table 14.5: Difference Between Cutaneous and Visceral Larva Migrans

	Cutaneous larva migrans	Visceral larva migrans
Tissue involved	Skin	Various organs of body like liver, lungs, and eyes
Infecting organism	Mostly by non-human nematodes	Mainly by dog and cat (<i>Toxocara</i> spp.)
Portal of entry	Penetration of skin	Ingestion of infected eggs
Eosinophila	Mild	Persistent high
Serodiagnosis	Not developed	Well developed
Treatment	Thiabendazole	Diethylcarbamazine and prednisolone

Common key points of Cutaneous and Visceral Larva Migrans

- Sometimes larvae lose their way and wander around aimlessly in human body, this condition is known as larva migrans (cutaneous or visceral).
- Mainly caused by non-human species of nematodes (zoophilic helminths), but occasionally by non-helminthic agents like mite and larvae of fly (myiasis).
- Man acquires the infection as an accidental host.
- Abnormal migrations also occur sometimes in human nematodes.
- The helminths are unable to complete their development and life cycle in man and are arrested at some level in skin or other organs like lung, liver, etc.
- **Pathogenesis:** Due to mechanical damage and host's inflammatory response against parasitic antigen.
- **Clinical manifestations:** Depend on route of entrance, sites affected, and degree, and duration of infection.
- **Diagnosis:** Based mainly on clinical features, skin biopsy, and serology.
- **Treatment:** Symptomatic and specific therapy with antihelminthics.

Review Questions

1. Describe briefly:

(a) General characters of Phylum Nematoda

(b) Systematic classification of nematodes

2. Short notes on:

(a) Classification of nematodes based on habitat

(b) Cutaneous larva migrans

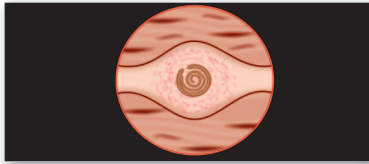
(c) Visceral larva migrans

(d) Viviparous nematodes

(e) Larva currens

3. Differentiate between class adenophorea and secernentea.

4. Enumerate the etiological agents of cutaneous and visceral larva migrans.



Trichinella Spiralis 15

Common name: Trichina worm

History and Distribution

Trichinella spiralis, tissue nematode, is the causative agent of **trichinosis**.

- The name *Trichinella* is derived from the minute size of the adult. (Greek *trichos*—hair; *ella* suffix for diminutive; *spiralis* refers to the spirally coiled appearance of larvae in muscles).
- It was first observed in **1821** in the muscles of a patient at autopsy by James Paget, who was then a first year medical student at St. Bartholomew's Hospital, London.
- Owen, in **1835**, described the encysted larval form in muscles and named it *Trichina spiralis*.
- Virchow discovered its life cycle in **1859**.
- The major source of human infection was shown to be the **consumption of inadequately cooked pork**.
- Trichinosis is recognized as an important public health problem in Europe and America, but is much less common in the tropics and oriental countries.
- Human trichinosis had not been recorded in India till 1996, when the first case was reported from Punjab.

Habitat

Adult worms live deeply buried in the **mucosa of small intestine (duodenum or jejunum)** of pig, bear, rat, or man. The encysted larvae are present in the **striated muscles** of these hosts. There are no free-living stages.

Morphology

Adult Worm

The adult *T. spiralis*, a small white worm just visible to the naked eye, is one of **the smallest nematodes** infecting humans.

- The **male** measures about 1.5 mm by 0.04 mm and the female about 3 mm by 0.06 mm (twice the length of male).
- The **anterior half** of the body is **thin and pointed**, well-adapted for **burrowing** into the mucosal epithelium (Fig. 15.1).

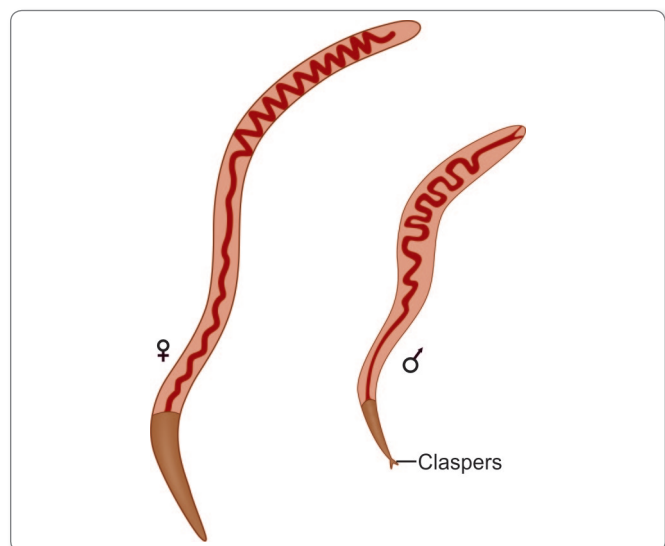


Fig. 15.1: Adult worms of *Trichinella spiralis* (male and female)

- The **posterior end** of the male has a pair of pear-shaped **clasp ing papillae** (termed as claspers), one on each side of the **cloacal orifice** that it uses to hold the female worm during mating (Fig. 15.1).
- The female worm is **viviparous** and discharge larva instead of eggs.
- The life span of the adult worm is very short. The male worm dies soon after fertilizing the female and the female dies after 4 weeks to 4 months (16 weeks), the time required for discharging the larvae.

Larvae

The larva becomes encysted in the striated muscle fiber (Fig. 15.2) and at the time of encystment measures 1 mm in length by 36 μm in diameter.

- The larva in the cyst is **coiled** and hence, the name *spiralis*.

Trichinella Cyst

- Cysts are ovoid 400 μm by 250 μm in size.
- The cyst is formed by the tissue reaction around the encapsulated larvae.
- Cysts develop preferentially in muscles relatively poor in glycogen and in hypoxic environment. Therefore, the diaphragm, biceps, muscles of jaw, extraocular muscles, neck, and lower back, which are constantly active, are the ones mostly affected.
- Cysts are more abundant near the sites of attachment of muscles to tendons and bones than in other parts. They lie longitudinally along the muscle fibers.
- The deltoid being easily accessible, is chosen for taking diagnostic muscle biopsies.
- The larva remains infective inside the cyst for years and eventually, most become calcified and die.

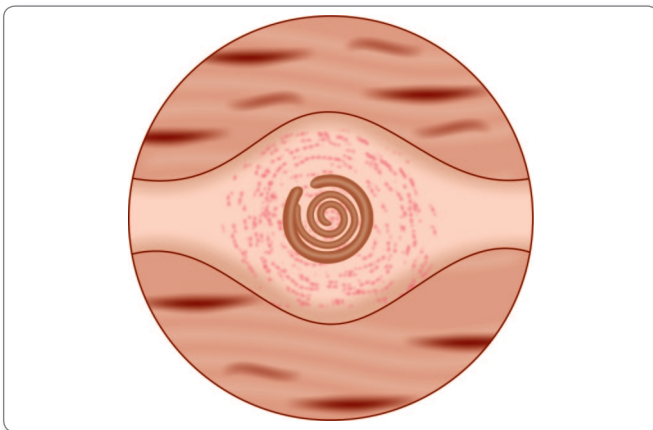


Fig. 15.2: Encysted larva in muscles; infective stage

Life Cycle

Trichinella is a parasite that has a direct life cycle, which means it completes all stages of development in one host.

But only a **single cycle** occurs in one host and for continuation of the cycle and maintenance of the species, it is necessary for the infection to be transmitted to another host of the same species or of different species (Fig. 15.3).

- **Optimum host:** Pig.
- **Alternate host:** Man.
- Infection can pass from—Pig-to-pig (facilitated by the custom of feeding pigs with untreated household garbage, which may contain bits of pork with infective cysts), rat-to-rat, and pig-to-rat.
- Man is the **dead-end** of the parasite, as the cysts in human muscles are unlikely to be eaten by another host.
- **Infective form:** Encysted larva found in the muscles of pigs and other animals (Fig. 15.2).
- **Mode of infection:** Man acquires infection mainly by eating raw or undercooked pork or inadequately processed sausages or other meat products containing the viable larvae.
- When such meat is eaten without adequate cooking, the cysts are digested by the gastric juice and viable larvae are released (excystation) in the stomach, duodenum, and jejunum.
- The larvae immediately penetrate the mucosal epithelium.
- They moult **4 times** and rapidly develop into adults, either male or female, by the second day of infection. Within 5 days, they become sexually mature.
- The male dies after fertilizing the female. The fertilized females start **releasing motile larvae** by the **sixth day** of infection.
- Larvae continue to be discharged during the remaining part of the lifespan of the female worm, which ranges from **4 weeks to 4 months**.
- Each female gives birth to approximately **1,000 larvae**.
- These larvae **enter the intestinal lymphatics** or **mesenteric venules** and are transported in circulation to different parts of the body.

? Parasites with source of infection

Pork

- *Taenia solium*
- *Trichinella spiralis*
- *Sarcocysts suihominis*

Beef

- *Taenia saginata*
- *Sarcocystis hominis*
- *Toxoplasma gondii*

Fish

- *Diphyllobothrium latum*
- *Clonorchis sinensis*
- *Metagonimus yokogawai*
- *Heterophyes* spp.
- *Gnathostoma* spp.

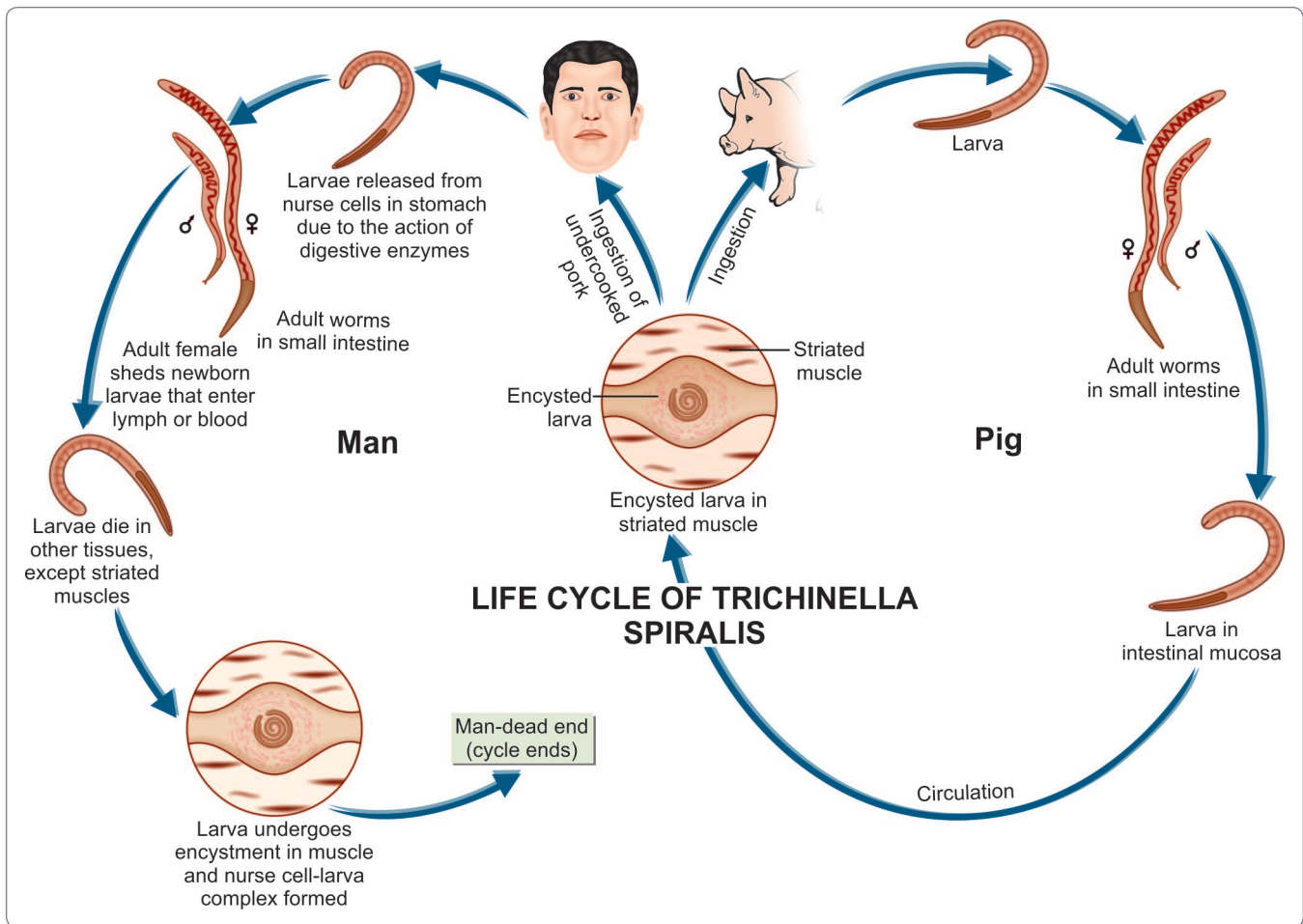


Fig. 15.3: Life cycle of *Trichinella spiralis*

- They get **deposited in the muscles, central nervous system, and other sites**. The larva die in most other situations, except the **skeletal muscles**, where it grows.
- **Deposition in the muscles** occurs mostly during the **second week** of infection. Larval development in muscles takes place during the next **3 or 4 weeks**.
- Within 20 days after entering the muscle cells, the larvae become encysted. A muscle cell carrying larva of *T. spiralis* is called as a **nurse cell**.
- Encysted larvae lie parallel to the muscles of host.
- Encysted larva can survive for months to years. In man, the life cycle ends here (Fig. 15.3).



Smoking, salting or drying the meat does not destroy the infective larvae. Prolonged freezing (20 days in a normal freezer or at -20°C for 3 days) decontaminates the meat.

Pathogenicity and Clinical Features

The disease caused by *T. spiralis* is called **trichinosis**.

- The manifestations vary from asymptomatic infection, which is very common, to an acute fatal illness, which is extremely rare.
- The pathology and clinical features vary according to the stage in the life cycle of the worm (Table 15.1).

Diagnosis

Diagnosis of trichinosis can be made by direct and indirect methods.

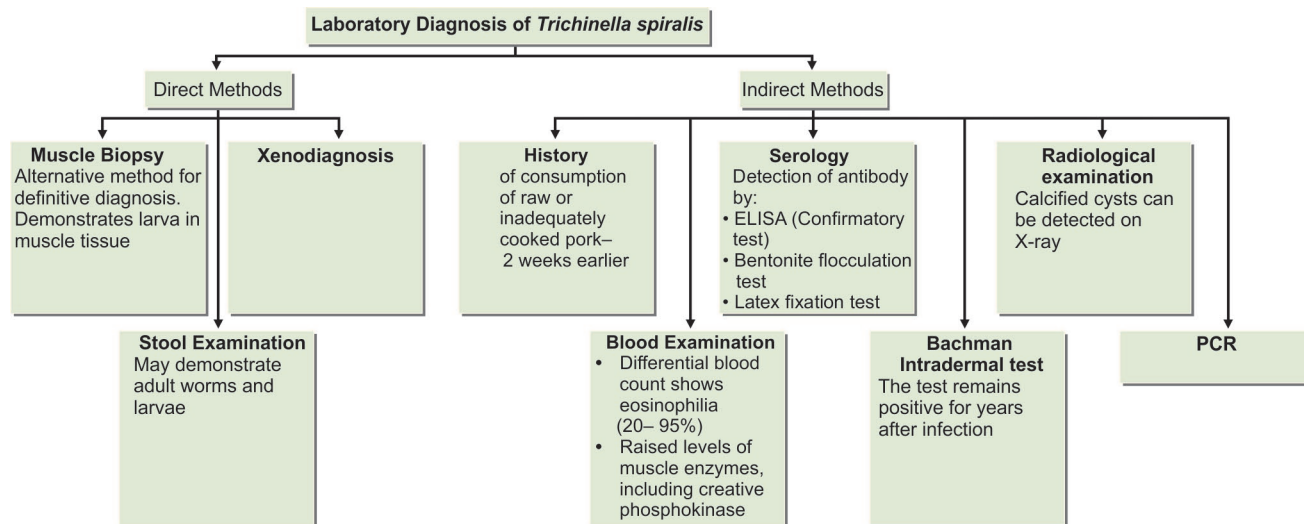
Direct Methods

- i. Detection of spiral larvae in muscle tissue by performing muscle biopsy. Deltoid, biceps, gastrocnemius, or pectoralis muscles are usually selected for biopsy

Table 15.1: Stages in the Life Cycle of *Trichinella spiralis* (in Man)

	Stage of intestinal invasion	Stage of muscle invasion	Stage of encystation
	First stage	Second stage	Final stage
Pathology	The stage begins with the ingestion of raw pork containing infective larvae and ends with the larvae invading the intestinal epithelium and developing into adult	The stage begins when new infective larvae are released from the adult female and ends with the deposition of the larvae in the muscles. Myositis and basophilic granular degeneration of muscles occur in this stage	This stage occurs only in striated muscle. The infective larvae become encysted in this stage
Clinical features	Malaise, nausea, vomiting, diarrhea, abdominal cramps Onset within 2 to 30 hours of ingestion of infective food	Fever, myalgia, periorbital edema, weakness of affected muscle, hemorrhage in subconjunctiva and new beds (splinter hemorrhages), myocarditis (if heart muscles are involved), and encephalitis (if central nervous tissue is involved). Eosinophilia is a constant feature of this stage The stage is seen 1–4 weeks after infection	All symptoms subside

- ii. Detection of adult worms and larvae in the stool during the diarrheic stage
 - iii. **Xenodiagnosis:** For xenodiagnosis, biopsy bits are fed to laboratory rats, which are killed a month or so, later. The larvae can be demonstrated more easily in the muscles of such infected rats (Flowchart 15.1).
 - o *T. spiralis* antibody can be detected by enzyme-linked immunosorbent assay (ELISA) test using TSL-1 secreting antigens obtained from the infective stage larvae. Bentonite flocculation test and latex fixation test for demonstration of antibodies have also been widely used. A positive test indicates recent infection.
- Indirect Methods**
- i. History of consumption of raw or inadequately cooked or processed pork, about two weeks earlier along with a recent episode of **gastroenteritis**.
 - ii. **Blood examination:** It shows eosinophilia (20–95%).
 - iii. **Serology:**
 - o There is massive hypergammaglobulinemia with elevated serum IgE.
 - iv. **Bachman intradermal test:** It uses a 1:5,000 or 1:10,000 dilution of the larval antigen. An erythematous wheal appears in positive cases within 15–20 minutes. The test remains positive for years after infection.
 - v. **Radiological examination:** Calcified cysts may be demonstrated on X-ray examination.
 - vi. **Molecular methods** like multiplex polymerase chain reaction (PCR) are now being used for species identification of *Trichinella* (Flowchart 15.1).

**Flowchart 15.1:** Laboratory diagnosis of *Trichinella spiralis*

Muscle biopsy

- Muscle biopsy specimen is collected for demonstration of spiral larvae.
- **Specimen:** Deltoid, biceps, gastronemius, or pectoralis.
- At least 1 g of muscle should be taken for biopsy, preferably near tendon insertion.
- **Examination technique:** Muscle fibers are digested with trypsin and mounted on a glass slide and examined under microscope. Young larvae may be digested and missed during such examination.
 - A teased preparation of muscle tissue is prepared in a drop of saline solution and it is squeezed between two glass slides.
 - Muscle tissue is stained with safranin.

Treatment

- **Mild cases:** Supportive treatment consisting of bed rest, analgesics, and antipyretics.
- **Moderate cases:** Albendazole 400 mg BID for 8 days or Mebendazole 200–400 mg TID for 3 days, then 400 mg TID for 8 days.
- **Severe cases:** Add glucocorticoids like prednisolone to albendazole or mebendazole.

Note: Mebendazole and albendazole are active against enteric stage of the parasite, but their efficacy against encysted larva has not yet been completely demonstrated.

Prophylaxis

- Proper cooking of pork and other meat likely to be infected.
- The most effective method is to stop the practice of feeding pigs with raw garbage.
- Extermination of rats from pig farms the spread of infection.

Key points of *Trichinella spiralis*

- One of the smallest nematodes infecting humans (1.5–3 mm).
- Entire life cycle is passed in one host.
- The female worm is viviparous.
- **Optimum host:** Pig.
- **Alternate host:** Man. Man is the dead end for parasite.
- **Infective form:** Encysted larvae in the striated muscles of pigs and other animals.
- Larvae remain encysted tightly coiled in striated muscles in human body.
- **Muscles commonly involved:** diaphragm, pectoralis, deltoid, biceps, and gastronemius.
- **Pathogenesis:** Myositis and basophilic degeneration of the muscles.
- **Clinical features:** Malaise, diarrhea, periorbital edema, muscle weakness, myocarditis, encephalitis.
- **Diagnosis:** Muscle biopsy for larvae, stool examination for adult worm or larvae, xenodiagnosis, Bachman intradermal test, ELISA, X-ray for calcified cyst, PCR.
- **Treatment:** Albendazole and mebendazole along with corticosteroids (in case of severe infection).

Review Questions

1. Name the various intestinal nematodes and describe briefly the life cycle of *Trichinella*.

2. Write Short notes on:

(a) *Trichinella* cysts

(b) Laboratory diagnosis of *Trichinella spiralis*



Trichuris Trichiura 16

Common name: Whipworm

History and Distribution

Trichuris trichiura, the human whipworm, was first described by **Linnaeus** in **1771**.

- The name *Trichuris* means a 'hair-like tail' (Greek *trichos*—hair, *oura*—tail). This name is not quite correct because it is the anterior end of the worm that is hair-like and not the tail. The name whipworm is more apt as the thick posterior part resembles the stock and the thin anterior end resembles the lash of a whip.
- The antiquity of the whipworm as a human parasite is indicated by the demonstration of its eggs in colonic contents of a young man, who died on the Alps some 5,300 years ago and whose well-preserved body was discovered in **1990**.
- It is worldwide in distribution, but is much more common in the tropics. The infection is widespread in tropical Africa, South America, and South-east Asia. *Trichuris* infection is found throughout India.
- Some 800 million people are estimated to be infected with this worm.
- While whipworm infection is extremely frequent, whipworm disease is relatively rare.

Habitat

T. trichiura lives in the large intestine. The adult worms are found attached to the wall of the **caecum** and less commonly to the vermiform appendix, colon, and anal canal.



Nematodes present in large intestine

- *Enterobius vermicularis*
- *Trichuris trichiura*
- *Oesophagostomum* spp.

Morphology

Adult Worm

The male worm is 30–45 mm long, while the female is slightly larger, about 40–50 mm.

- The worm is flesh-colored. In shape, it resembles a whip, with the anterior three-fifth thin and thread-like and the posterior two-fifth thick and fleshy, appearing like the handle of a **whip** (Fig. 16.1).
- The attenuated anterior portion, which contains the capillary esophagus, is embedded in the mucosa. The

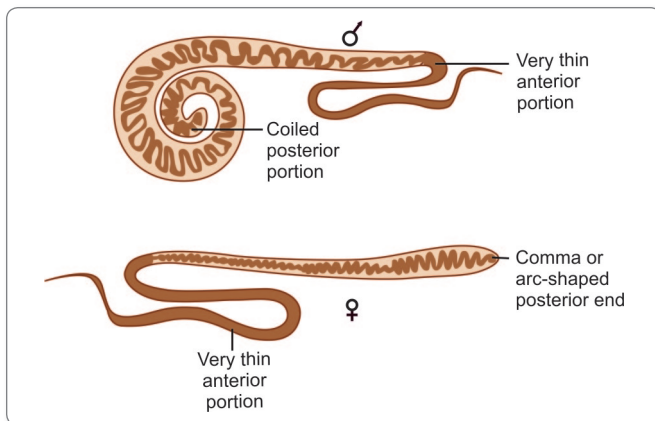


Fig. 16.1: Adult *Trichuris trichiura* worms (male and female)

posterior part contains the intestines and reproductive organs.

- The posterior end of the male is coiled ventrally, while the hind end of the female is straight, blunt, and rounded (Fig. 16.1).
- The worm has a lifespan of 5–10 years.

Egg

The egg has a characteristic appearance.

- It is brown in color being **bile-stained**.
- It has a **triple shell**, the outermost layer of which is stained brown.
- It is **barrel-shaped** and about 50 μm long and 25 μm wide in the middle, with a projecting **mucus plug** at each pole containing an unsegmented ovum (Fig. 16.2). The plugs are colorless.
- The egg floats in saturated salt solution.
- When freshly passed, the egg contains an unsegmented ovum. At this stage, it is not infective for humans.
- The fertilized female lays about 5,000 eggs per day.

Helminths whose eggs float in saturated salt solution

- *Enterobius vermicularis*
- *Ancylostoma duodenale*
- *Necator americanus*
- *Ascaris lumbricoides*
- *Trichuris trichiura*

Helminths whose eggs do not float in the saturated solution

- Eggs of *Taenia solium* and *Taenia saginata*
- Eggs of all intestinal flukes
- Unfertilized eggs of *Ascaris lumbricoides*

Life Cycle

Natural host: Man. No intermediate host is required.

Infective form: Embryonated eggs containing Rhabditiform larva.

- Adult female worm lives in large intestine worm lays eggs which are discharged in feces.
- The egg undergoes development in soil, optimally under warm, moist, shady conditions, when the **infective rhabditiform larva** develops within the egg in **3–4 weeks**. At lower temperatures, this may be delayed for 3 months or more (Fig. 16.3). These embryonated eggs are infective to man.
- **Mode of Transmission:** Infection occurs in humans when the mature embryonated eggs containing the infective larvae are swallowed in **contaminated food or water**.
- The eggs hatch in the **small intestine** and the larva, which emerges through the pole of the egg, passes down into the caecum.

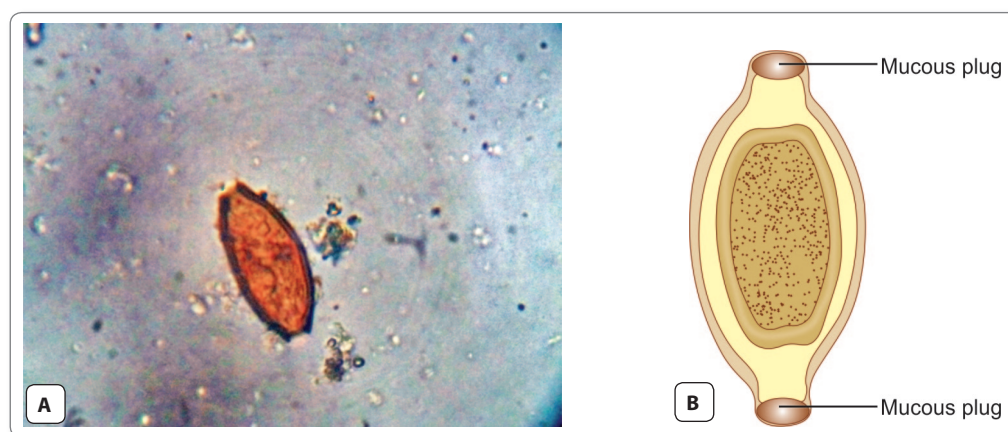


Fig. 16.2: Egg of *Trichuris trichiura*. A. As seen under microscope; B. Schematic diagram

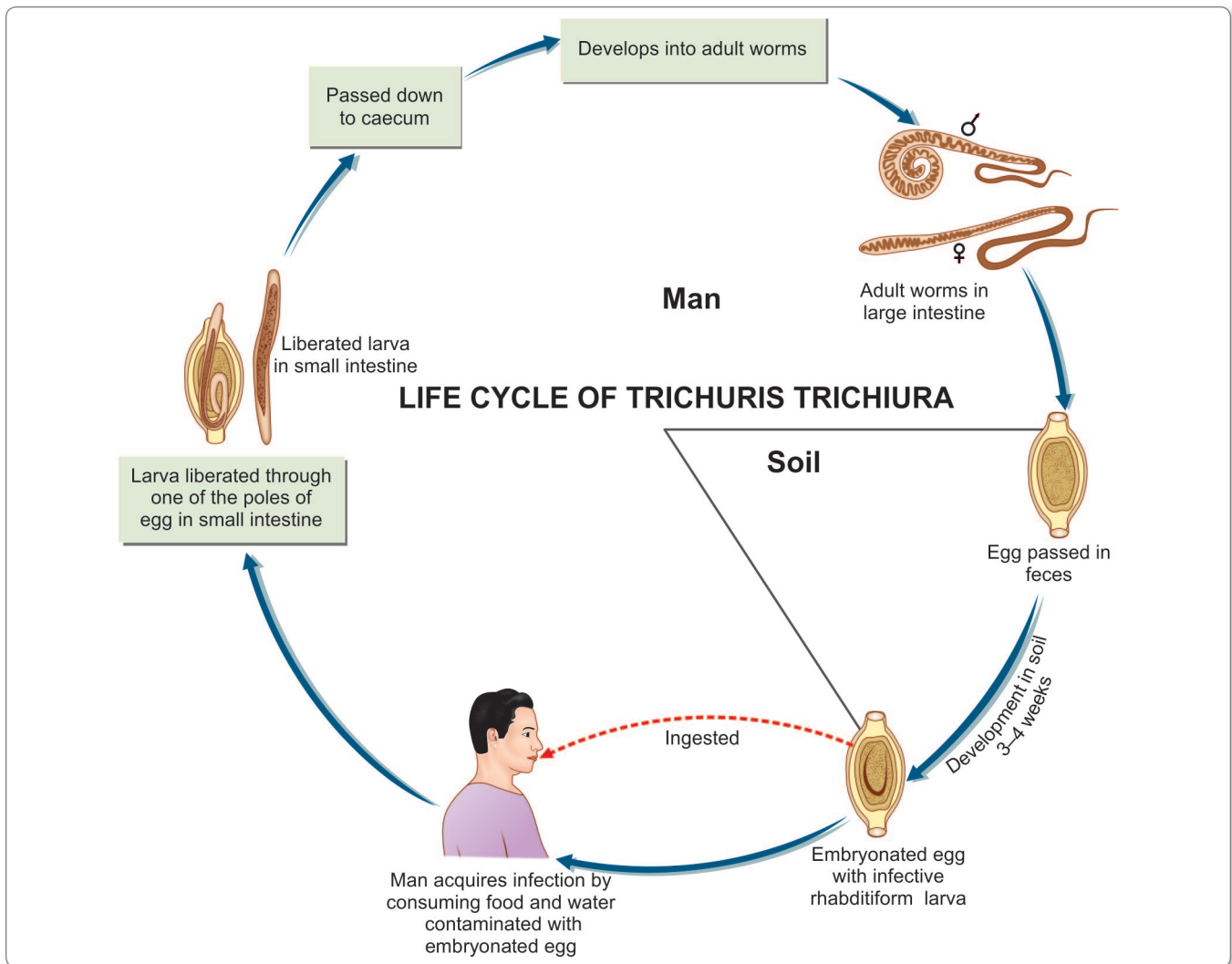


Fig. 16.3: Life cycle of *Trichuris trichiura*

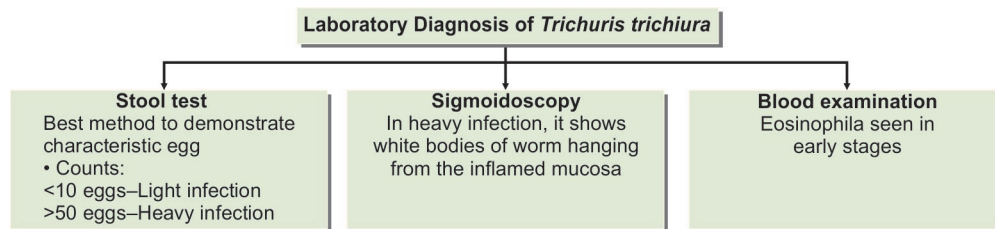
- In about **2–3 months**, they become mature adults and lie embedded in the cecal wall, with the thread-like anterior portion piercing the mucosa and the thick posterior end projecting out.
- The gravid adult female lays eggs, which are discharged in feces and the cycle is repeated (Fig. 16.3).
- Eggs start appearing in feces usually about **3 months** after infection.

Pathogenicity and Clinical Features

Infection with *T. trichiura* (**trichuriasis**, **whipworm infection**, or **trichocephaliasis**) is asymptomatic, except when the worm load is heavy. Disease may result either due to mechanical effects or allergic reaction.

- The entire life cycle can be passed in **one host**, from the ingested infective egg to the development of the adults and the release of their eggs in feces. But for transmission of infection to other hosts and perpetuation of the species, the egg has to undergo development in the soil and then infect another person.
- Humans are the **only natural host** for *T. trichiura*, but morphologically similar worms are found to infect pigs and some monkeys.

- The worms lie threaded into the cecal mucosa and even though it is not a blood feeder, oozing of blood may occur at the sites of attachment. The blood loss is **about 0.005 mL per worm per day**. Over a period of time, this may lead to anemia and malnutrition.
- It has been suggested that mechanical blockage of the appendiceal lumen by masses of whipworms may cause acute appendicitis.



Flowchart 16.1: Laboratory diagnosis of *Trichuris trichiura*

- In heavy infection, the worm may be abundant on the colonic mucosa, even upto the rectum. Mucus diarrhea, chronic dysentery and abdominal pain, and weight loss are frequently seen in such cases. Some patients, particularly young children, may develop rectal prolapse.

Laboratory Diagnosis

Stool Examination

The characteristic barrel-shaped eggs are found in stools.

- The degree of infection can be assessed by egg counts. **Less than 10 eggs** per smear in direct stool preparation is considered **light infection** and **more than 50** per smear as **heavy infection** (Flowchart 16.1).
- Light infection is not considered to cause clinical disease.

Sigmoidoscopy

Sigmoidoscopy is useful as worms are found in the rectal mucosa in whipworm diarrhea and dysentery. **Charcot-Leyden crystals** are usually abundant in stools of patients

with whipworm dysentery. In heavy infection, sigmoidoscopy may show white bodies of worm hanging from the inflamed mucosa, the so called **coconut cake rectum**.

Blood Examination

Differential leukocyte count (DLC) may show upto 25% eosinophilia in the early stage of the disease (Flowchart 16.1).

Treatment

Mebendazole (100 mg 12 hourly for 3–5 days) or Albendazole (single dose of 400 mg) are effective with cure rates of 70–90%.

Prophylaxis

Trichuriasis can be prevented by

- Proper disposal of feces.
- Avoiding consumption of unwashed fruits and vegetables.
- Treatment of infected persons.


Key points of *Trichuris trichiura*

- Adult *Trichuris* worm lives in large intestine.
- It resembles a whip. Anterior 3/5th is thin and posterior 2/5th is thick and stout, appearing as handle of a whip.
- Egg is triple-shelled, barrel-shaped with a mucus plug at each pole. It is bile-stained and contains an unsegmented ovum. The egg floats in saturated salt solution.
- **Natural host:** Man is the only host. No intermediate host.
- **Infective form:** Embryonated egg containing rhabditiform larva that develops in soil.
- **Clinical features:** Light infection is asymptomatic. In heavy infection, worm may give rise to acute appendicitis, abdominal pain, mucous diarrhea, anemia, prolapse of rectum, and weight loss.
- **Diagnosis:** Finding of characteristic eggs in stool and sigmoidoscopy may show worms hanging from the rectal mucosa.
- **Treatment:** Mebendazole or albendazole.

Review Questions

1. Describe briefly life cycle of *Trichuris trichiura*.
2. Short notes on:
 - (a) Trichuriasis

(b) Egg of *Trichuris trichiura*



Strongyloides Stercoralis 17

History and Distribution

Normand (1876) observed minute cylindrical worms in the diarrheic feces and intestinal walls of some French soldiers in Cochinchina. These were named *Strongyloides stercoralis* (*strongylus*—round; *eidosis*—resembling; *stercoralis*—fecal).

- It is found mainly in the warm moist tropics, but may also occur in the temperate regions. It is common in Brazil, Columbia, and in the Far East—Myanmar, Thailand, Vietnam, Malaysia, and Philippines.
- Another species *S. fullerborni* is widely prevalent in African monkeys. It infects pygmies in the forests of Zaire and Zambia. It also causes human infection in Papua New Guinea. *Trichostrongylus*, a parasite of sheep and goats, seen in Africa and Asia (including India), may cause human infection, which is usually asymptomatic.



Nematodes present in small intestine

- *Strongyloides stercoralis*
- *Ascaris lumbricoides*
- *Ancylostoma duodenale*
- *Necator americanus*
- *Trichinella spiralis*
- *Trichostrongylus* spp.
- *Capillaria philippinensis*

Habitat

The adult worm is found in the small intestine (duodenum and jejunum) of man.



- Largest Nematode known to cause human infection: *Ascaris lumbricoides*.
- Smallest Nematode known to cause human infection: *Strongyloides stercoralis*.

Morphology

Adult Worms

Female Worm

The female worm is **thin**, transparent, about 2.5 mm long and 0.05 mm wide (Fig. 17.1).

- It has a **cylindrical esophagus** occupying the anterior one-third of the body and the intestines in the posterior two-thirds, opening through the anus situated ventrally, a little in front of the pointed tail tip.
- The reproductive system contains paired uteri, vagina, and vulva. The paired uteri lead to the vulva situated at the junction of the middle and posterior thirds of the body. In the gravid female, the uteri contain thin-walled transparent ovoid eggs, 50 μ m by 30 μ m in size.

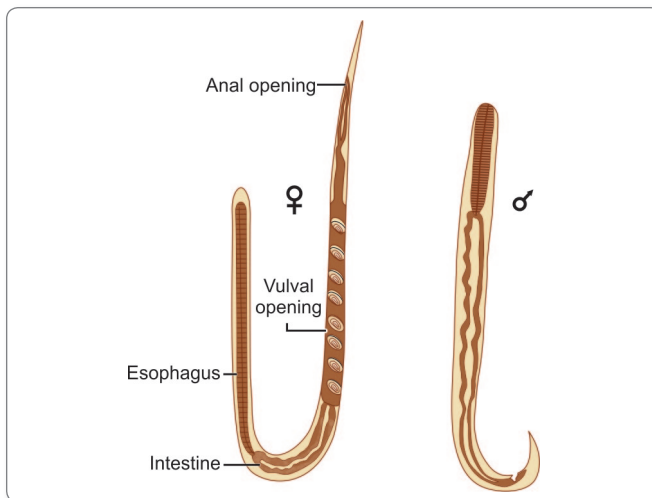


Fig. 17.1: Adult worm (male and female)

- The worm is **ovoviviparous**.
- The individual worm has a lifespan of 3 or 4 months, but because it can cause **autoinfection**, the infection may persist for years.

Male Worm

The male worms are shorter and broader than female, measuring 0.6–1 mm in length and 40–50 μm in width.

- The copulatory spicules, which penetrate the female during copulation, are located on each side of the gubernaculum (Fig. 17.1).
- They are not seen in human infection because they do not have penetrating power, therefore do not invade the intestinal wall.

Eggs

Eggs are conspicuous within the uterus of gravid female.

- Each uterus contains 8–10 eggs arranged antero-posteriorly in a single row (Fig. 17.1).
- They are oval and measure 50–60 μm in length and 30–35 μm in breadth (Fig. 17.2).

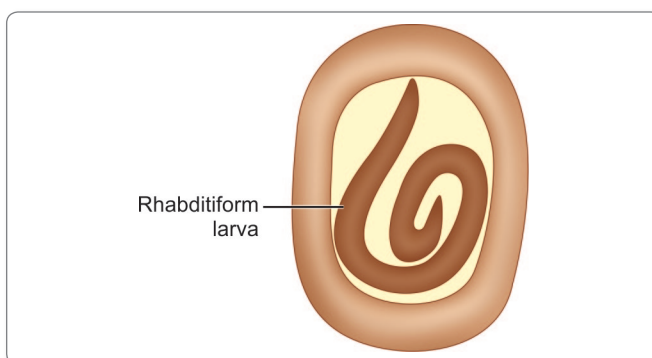


Fig. 17.2: Egg of *Strongyloides stercoralis*

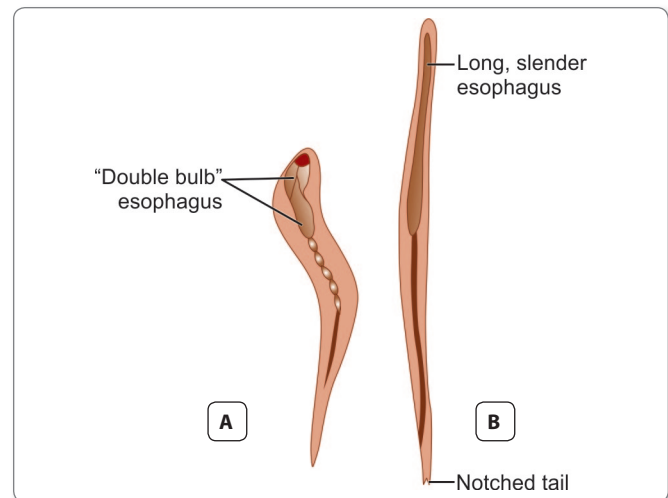


Fig. 17.3: Larvae of *Strongyloides stercoralis*. A. Rhabditiform larva; B. Filariform larva

- As soon as the eggs are laid, they hatch out to rhabditiform larva (1st stage larva). Thus, it is the larva and not the egg, which is excreted in feces and detected on stool examination and not egg.

Larva

Rhabditiform Larva (L1 stage)

This is the first stage of larva. Eggs hatch out to form L1 larva in the small intestine.

- It is the **most common form** of the parasite found in the feces.
- It measures 0.25 mm in length, with a relatively short muscular double bulb esophagus (Fig. 17.3A).
- The L1 larva migrates into the lumen of the intestine and passes down the gut to be released in feces.

Filariform Larva (L3 stage)

This is the third stage of larva.

- L1 larva moults twice to become the L3 larva.
- It is long and slender and measures 0.55 mm in length with a long esophagus of uniform width and notched tail (Fig. 17.3B).
- It is the **infective stage** of the parasite to man.

Table 17.1: Difference between filariform Larva of hook worm and *Strongyloides*

Hookworm	<i>Strongyloides</i>
• Esophagus extended upto 25% of the total body length	• Esophagus extended upto 40% of the total body
• Sheathed	• Non sheathed
• Tail: pointed	• Tail: forked

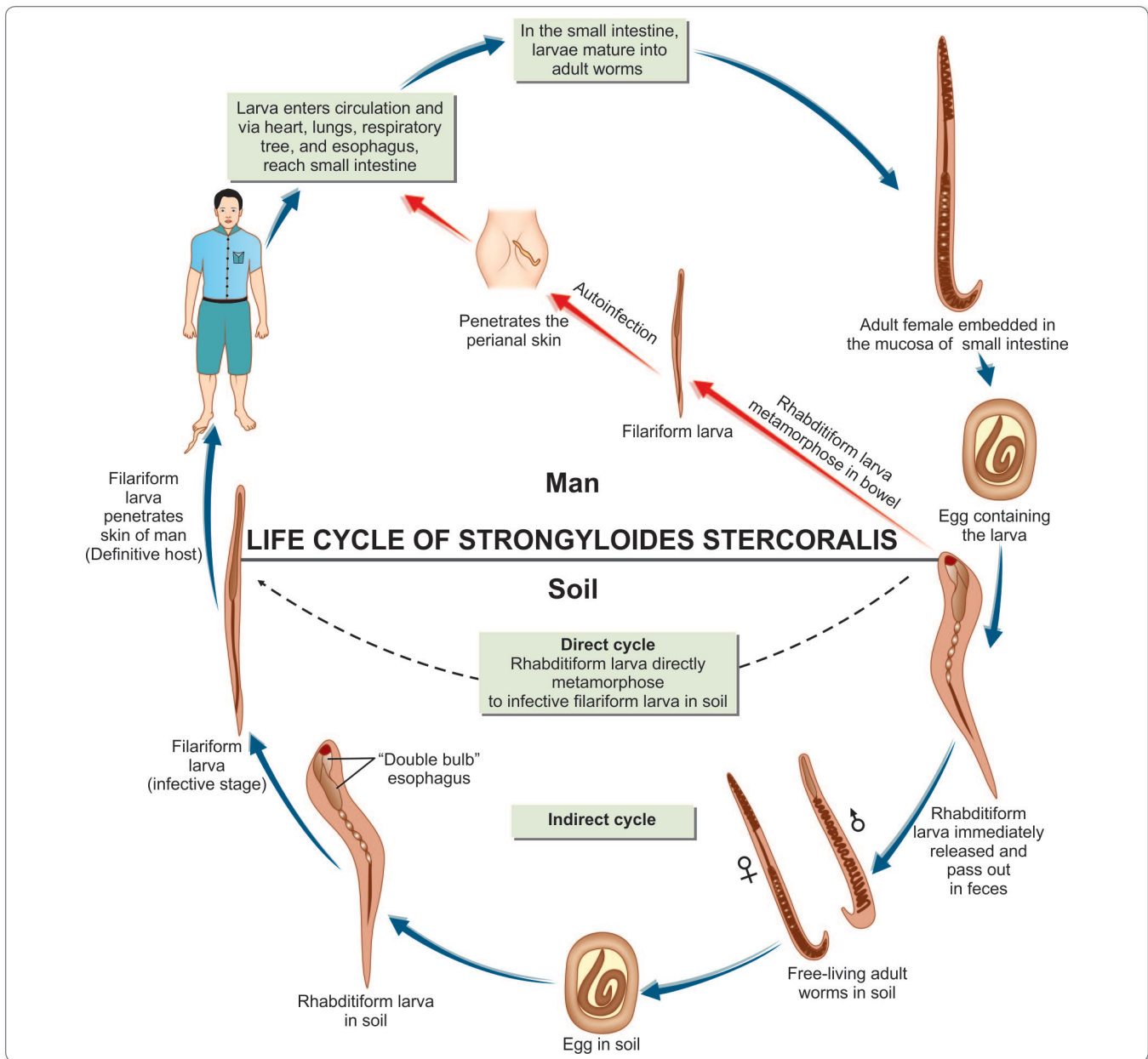


Fig. 17.4: Life cycle of *Strongyloides stercoralis*

Life Cycle

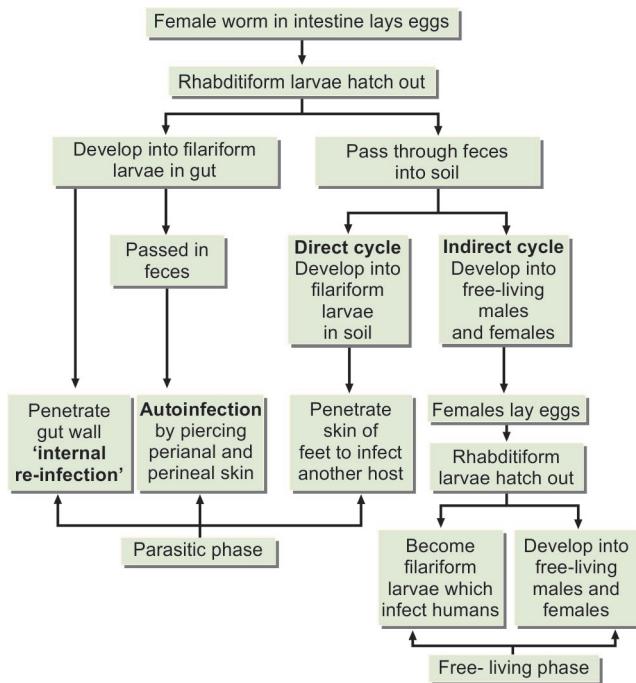
The life cycle of *S. stercoralis* is complex because of the multiplicity of pathways through which it can develop. It is unique among human nematodes as it has a parasitic cycle and a free-living soil cycle, in which it can persist for long periods in soil by feeding on soil bacteria, passing through several generations (Fig. 17.4 and Flowchart 17.1).

Natural host: Man, although dogs and cats are found infected with morphologically indistinguishable strains.

Infective form: Filariform larva.

➤ **Mode of infection:**

- Penetration of skin by the third stage filariform larva, when a person walks barefoot
- Autoinfection.
- The adult female worm is found in the human intestine embedded in the mucosa of the duodenum and upper jejunum.
- Since only the female worms are seen in the intestine, it was earlier believed that they are **parthenogenetic** and



Flowchart 17.1: Life cycle of *Strongyloides stercoralis*

can produce offsprings without being fertilized by the male. But it has now been established that parasitic males do exist. They can be demonstrated in experimentally infected dogs. They are not seen in human infections because they do not invade the intestinal wall and so are eliminated from the bowel soon after the females begin to oviposit. However, the majority of females are probably parthenogenetic.

- The eggs laid in the mucosa hatch immediately, releasing **rhabditiform** larva.
- The rhabditiform larva migrates into the lumen of the intestine and passes down the gut to be released in feces.
- The rhabditiform larva may even metamorphose into **filariform** larva during passage through the bowel.
- These filariform larvae may penetrate colonic mucosa or perianal skin without leaving the host and going to the soil, thus providing a source of autoinfection. This ability to cause autoinfection explains the persistence of the infection in patients for long periods, even 30–40 years, after leaving the endemic areas.
- The **rhabditiform** larva voided with the feces may undergo two types of development in the soil (Flowchart 17.1)
 - **Direct development**
 - **Indirect development.**
- **Direct development:** The rhabditiform larva on reaching the soil moults twice to become the infective filariform larva.

- Each rhabditiform larva gives rise to one filariform larva. When a person walks barefoot on soil containing the infective filariform larvae, they penetrate the skin and enter the circulation.
- The larvae are carried along the venous circulation to the right side of the heart and to the lungs.
- Here, they escape from the pulmonary capillaries into the alveoli, migrate up the respiratory tract to the pharynx, and are swallowed, reaching their final destination, small intestine.
- In the intestine, they mature into adult parasitic females and males in 15–20 days. Female worms then burrow into the mucosa of the intestine and lays eggs.
- The rhabditiform larvae hatch out immediately and enter into lumen of the bowel. They are excreted in the feces and thus, the life cycle is repeated.

➤ **Free-living phase/indirect development:** The rhabditiform larva passed in stools develop in moist soil into free-living males and females.

- They mate in soil.
- The fertilized female lays eggs, which hatch to release the next generation of rhabditiform larvae.
- These may repeat the free-living cycle or may develop into the filariform larvae, which infect humans and initiate the parasitic phase.

Autoinfection

- **External autoinfection:** *S. stercoralis* has a cycle of **autoinfection**. Here the rhabditiform larvae mature into the infective third stage larvae during their passage down the gut. These filariform larvae cause reinfection by piercing the perianal and perineal skin during defecation. The larvae wander in the dermis of the perianal region for sometime, causing a radiating perianal creeping eruption, a form of **cutaneous larva migrans**. They ultimately enter the lymphatics or venules and are carried to the right heart and the lungs to complete the life cycle as above.
- **Internal autoinfection:** In this type of autoinfection, seen typically in immunodeficient hosts, the rhabditiform larvae mature into the infective filariform larvae in the bowel itself. The filariform larvae penetrate the deeper layers of the intestine, to reach the mesenteric venules and are carried in circulation to complete the life cycle. This mode of autoinfection is called **internal reinfection**. It may lead to very heavy infection causing serious and sometimes even fatal illness.

Pathogenicity and Clinical Features

Strongyloidosis (infection caused by *S. stercoralis*) is generally benign and asymptomatic. Blood eosinophilia and larvae in stool being the only indications of infection.

- Sometimes it may cause clinical manifestations, which may be severe and even fatal, particularly in those with defective immune response.
- The clinical disease may have cutaneous, pulmonary, and intestinal manifestations.

Cutaneous Manifestations

There may be dermatitis, with erythema and itching at the site of penetration of the filariform larva, particularly when large numbers of larvae enter the skin.

- In those sensitized by prior infection, there may be an allergic response.
- Pruritis and urticaria, particularly around the perianal skin and buttocks, are symptoms of chronic strongyloidiasis.
- **The term larva currens** (meaning 'racing larvae') has been applied to the rapidly progressing linear or serpigenous urticarial tracks caused by migrating **filariform larvae**. These often follow autoinfection and start perianally.

Pulmonary Manifestations

When the larva escape from the pulmonary capillaries into the alveoli, small hemorrhages may occur in the alveoli and bronchioles.

- Bronchopneumonia may be present, which may progress to chronic bronchitis and asthmatic symptoms in some patients.
- Larva of *Strongyloides* may be found in the sputum of these patients.

Intestinal Manifestations

The symptoms may resemble those of peptic ulcer or of malabsorption syndrome.

- Mucus diarrhea is often present. In heavy infection, the mucosa may be honey-combed with the worm and

there may be extensive sloughing, causing dysenteric stools.

- Other manifestations are protein-losing enteropathy and paralytic ileus.

Hyperinfection

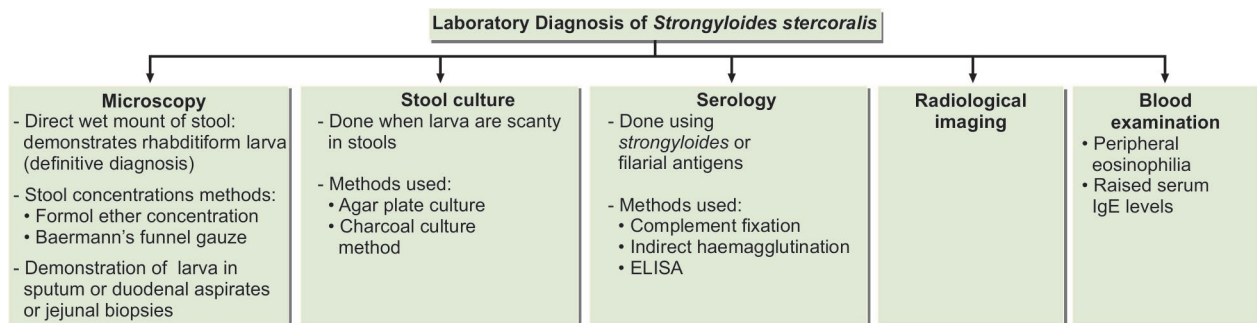
In debilitated individuals and particularly in those with cellular immune defects, extensive internal reinfection takes place, leading to an enormous number of adult worms in the intestines and lungs and larvae in various tissues and organs. This is known as **hyperinfection**.

- Severe malnutrition, **lepromatous leprosy**, lymphoreticular malignancies, acquired immunodeficiency syndrome (AIDS), immunosuppressive drugs, and other situations, in which cell-mediated immunity is defective, predispose to this condition.
- Hyperinfection is an important hazard of steroid therapy and other instances of prolonged immunosuppression as in transplant patients.
- During hyperinfection, the filariform larvae may enter into arterial circulation and lodge in various organs e.g. heart, lungs, brain, kidney, pancreas, liver, and lymphnodes. Manifestations depend on the sites affected.
- Brain abscess, meningitis, and peritonitis are major fatal complications.
- It has been reported that circulating *Strongyloides* larvae may carry intestinal bacteria, causing septicemia.

Laboratory Diagnosis

Microscopy

- **Direct wet mount of stool:** Demonstration of the rhabditiform larvae in freshly passed stools is the most important method of specific diagnosis. Larvae found in stale stools have to be differentiated from larvae hatched from hookworm eggs (Flowchart 17.2).
- **Concentration methods of stool examination:** Stool may be concentrated by formol ether concentration



Flowchart 17.2: Laboratory diagnosis of *Strongyloides stercoralis*

method or Baermann's funnel gauze method and examined for larvae more efficiently. Baermann's test requires a special apparatus and relies on the principal that larva will actively migrate out of the feces on a wire mesh covered with several layers of gauze.

- Larvae may sometimes be present in sputum or duodenal aspirates and jejunal biopsies.

Stool Culture

When larvae are scanty in stools, diagnosis may be facilitated by stool culture.

Culture techniques used—

- Agar plate culture
- Charcoal culture method
- The larvae develop into free-living forms and multiply in charcoal cultures set up with stools. Large number of free-living larvae and adult worms can be seen after 7–10 days.
- Serial examinations and the use of agar plate detection method improves the sensitivity of stool diagnosis.

Serology

Serological tests have been described, using *Strongyloides* or filarial antigens.

- Complement fixation, indirect hemagglutination, and enzyme-linked immunosorbent assay (ELISA) have been reported.
- ELISA has a sensitivity of 95 % and should be used when microscopic examinations are negative.
- **Limitations of serological tests:**
 - Larval antigens are not freely available.
 - There is extensive cross-reactions with other helminthic infections.

Imaging

Radiological appearances in intestinal and pulmonary infection are said to be characteristic and helpful in diagnosis.

Others

- Peripheral eosinophilia (>500/cumL of blood) is a constant finding. However, in severe hyperinfection, eosinophilia may sometimes be absent.

- Total serum immunoglobulin (Ig)E antibody level is elevated in more than half of the patients (Flowchart 17.2).

Treatment

All cases of **strongyloidosis**, whether symptomatic or not, should be treated to prevent severe invasive disease.

- Ivermectin (200 mg/kg daily for 2 days) is more effective than albendazole (400 mg daily for 3 days).
- For disseminated strongyloidosis, treatment with ivermectin should be extended for at least 5–7 days.

Prophylaxis

Strongyloidiasis can be prevented by

- Prevention of contamination of soil with feces.
- Avoiding contact with infective soil and contaminated surface waters.
- Treatment of all cases.

Key points of *Strongyloides stercoralis*

- It is the smallest nematode infecting man.
- Adult worm lives in duodenum and jejunum of man.
- Females are ovoviviparous.
- Egg is ovoid, thin walled and transparent.
- **Natural host:** Man (optimal host).
- **Infective form:** Third stage filariform larva.
- **Mode of transmission:** Penetration through the skin by the filariform larva in soil. Autoinfection can occur.
- **Clinical features:** Generally benign and asymptomatic, but may cause cutaneous, pulmonary, and intestinal manifestations.
- **Diagnosis:** By demonstrating larva or adult females in stool or by demonstrating larval antigen by serological methods like ELISA.
- **Technique for stool concentration:** Baermann's technique and formol-ether concentration.
- **Techniques for stool culture:** Agar plate culture, charcoal culture.
- **Treatment:** Drug of choice is ivermectin or albendazole.

Review Questions

1. Classify intestinal nematodes and describe briefly life cycle of *Strongyloides*.
2. Short notes on:
 - (a) *Strongyloides*
 - (b) Hyperinfection
 - (c) Larva currens
3. Differentiate between filariform larvae of hookworm and strongyloides.



Hookworm 18



History and Distribution

Hookworms have been known from very ancient times. They have been referred to in the Ebers papyrus (Circa 1600 BC).

- Two species of hookworms are human parasites, ***Ancylostoma duodenale*** and ***Necator americanus***.
- *Ancylostoma duodenale* (Greek *ankylos*—hooked; *stoma*—mouth) was originally described by Dubini in 1843 in Italy. The life cycle of the worm was worked out by Looss in 1898 in Egypt.
- The second species *Necator americanus* was identified by Stiles in 1902 in specimens obtained from Texas, USA. The name literally means the ‘**American murderer**’ (Latin *necator*—murderer). It is called the American or the ‘New World’ hookworm and *A. duodenale* the ‘Old World’ hookworm. But it is believed that *N. americanus* actually originated in Africa and was transported to America with the slave trade.
- Hookworm disease is prevalent throughout the tropics and subtropics. Even though it has been controlled in the advanced countries, it is estimated that it still affects some 900 million people, causing the loss of about 9 million litres of blood overall each day.
- *A. duodenale* was prevalent along the Mediterranean coast of Europe and Africa, in northern India, China and Japan, while *N. americanus* was prevalent in Central and

South America, Central and Southern Africa, Southern India, the far East and the Southern Pacific region.

- However, in more recent times, movement of infected persons has blurred the geographic differences in distribution of the two species. For example, *A. duodenale* is now commonly seen along with *N. americanus* in South India and S.E. Asia.

Conditions favoring Hookworm infection

- Presence of infected persons
- Dispersal of eggs in soil due to indiscriminate defecation and inadequate processing of excreta
- Appropriate environmental factors facilitating development of eggs in soil, and opportunity for the larva to infect people through their exposed skin surfaces.

Note: These conditions prevail throughout the year in most parts of the tropics, but in subtropical areas, these conditions exist only seasonally, being limited to the warmer months.

Ancylostoma Duodenale

Habitat

The adult worms live in the small intestines of infected persons, mostly in the **jejunum**, less often in the duodenum, and infrequently in the ileum.

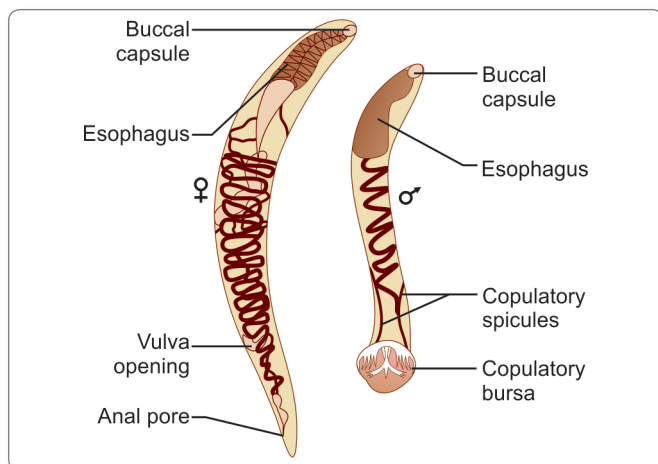


Fig. 18.1: Adult worm of *Ancylostoma duodenale* (male and female)

Morphology

Adult Worm

They are relatively **stout cylindroidal** worms.

- They are pale pink or greyish white, but may appear reddish brown due to ingested blood.
- The body is curved with the dorsal aspect concave and the ventral aspect convex. The anterior end is somewhat constricted and bent dorsally in the same direction of general body curvature. This cervical curvature gave it the name **hookworm** (Fig. 18.1).
- The mouth is not at the tip but directed dorsally. The prominent **buccal capsule**, reinforced with a hard chitin-like substance carries **6 teeth**; 4 hook-like teeth ventrally, and 2 knob-like with a median cleft dorsally.

Male Worm

The **male worm** is smaller than female worm 8-11 mm in length and 0.4 mm thick.

- The posterior end of the male is expanded into a copulatory bursa which consists of **3 lobes**; 1 dorsal and 2 lateral. Each lobe is supported by **13 fleshy chitinous rays**, 5 each in lateral lobes and 3 in dorsal lobe: one dorsal and two extradorsal rays. The dorsal ray is partially divided at the tip and each division is tripartite. The pattern of the rays helps in distinguishing between different species.
- The cloaca into which the rectum and genital canal open is situated within the copulatory bursa.
- There are 2 long retractile bristle-like **copulatory spicules**, the tips of which project from the bursa.

Female Worm

The female worm is larger, 10 to 13 mm long and 0.6 mm thick.

Table 18.1: Distinguishing Features of Male and Female worms of *Ancylostoma duodenale*

	Male	Female
Size	Smaller, about 8–11 mm in length	Larger, 10–13 mm in length
Copulatory bursa	Present	Absent
Genital opening	Opens in cloaca along with anus	Opens at the junction of the middle and posterior third of body

- Its hind end is conoid, with a subterminal anus situated ventrally.
- The vulva opens ventrally at the junction of the middle and posterior thirds of the body.
- The vagina leads to two intricately coiled ovarian tubes which occupy the hind and middle parts of the worm.
- During copulation the male attaches its copulatory bursa to the vulva. The copulating pair therefore presents a **Y-shaped** appearance.
- Sexes are easily differentiated by their size, the shape of the posterior end and the position of the genital opening (Table 18.1).

Egg

The egg of hookworm is:

- Oval or elliptical, measuring 60 μm by 40 μm .
- Colorless, **not bile stained**.
- Surrounded by a thin transparent hyaline shell membrane.
- Floats in saturated salt solution.
- When released by the worm in the intestine, the egg contains an unsegmented ovum.
- During its passage down the intestine, the ovum develops. When passed in feces, the egg contains a segmented ovum, usually with **4 or 8 blastomeres**.
- There is a **clear space** between the segmented ovum and the egg shell (Fig. 18.2).

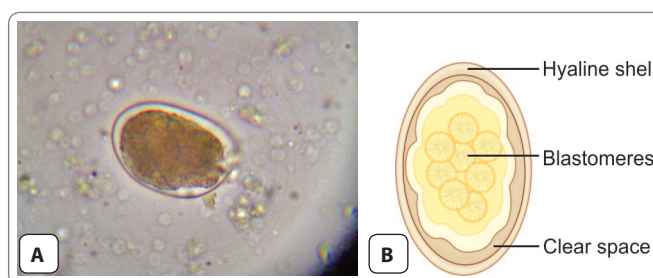


Fig. 18.2: Egg of *Ancylostoma duodenale*. A. As seen under microscope; B. Schematic diagram

- A single female worm lays about 25,000–30,000 eggs in a day and some 18–54 million during its life time.

Life Cycle

Life cycle of ancylostoma is completed in a **single host** (Fig. 18.3).

Definitive host: Humans are the only natural host. No intermediate host is required like other helminths.

Infective form: Third stage filariform larva.

- Adult worm inhabiting the small intestine of man attach themselves to the mucous membrane by means of their mouth parts. The female worm lays eggs.

Helminths requiring no intermediate host

- *Ancylostoma duodenale*
- *Necator americanus*
- *Ascaris lumbricoides*
- *Trichuris trichiura*
- *Enterobius vermicularis*
- *Hymenolepis nana*

- The eggs containing segmented ova with 4 blastomeres, are passed out in the feces of infected person (Fig. 18.3). Eggs freshly passed in feces are not infective for humans.

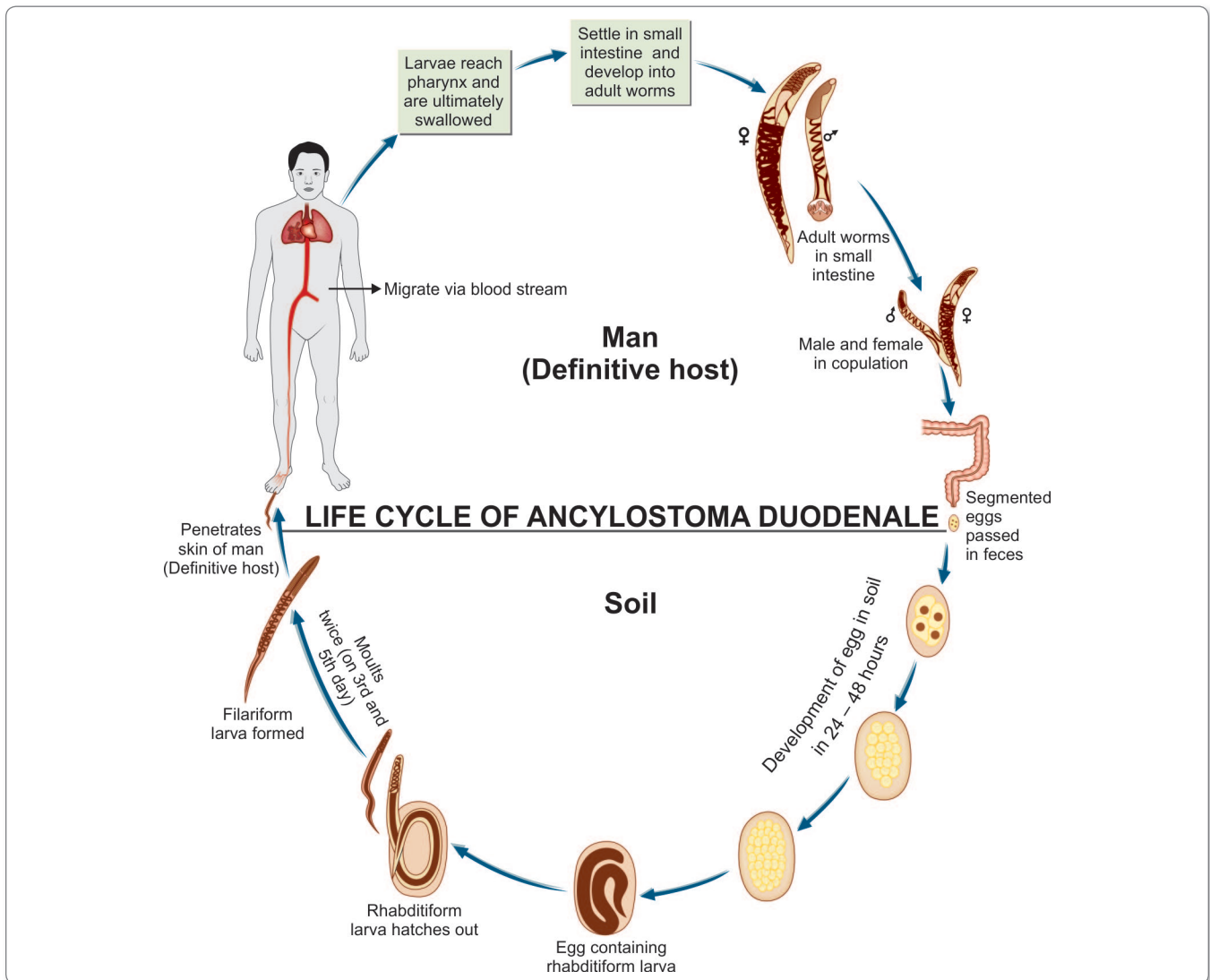


Fig. 18.3: Life cycle of *Ancylostoma duodenale*

- When deposited in the soil, the embryo develops inside the eggs. Its development takes place optimally in sandy loamy soil with decaying vegetation under a moist, warm, shady environment.
- In about **2 days**, a *rhabditiform larva*, measuring 250 µm in length, hatches out of the egg. It feeds on bacteria and other organic matter in the soil and grows in size (Fig. 18.3).
- It **moults twice**, on the **3rd and 5th days** after hatching to become the *third-stage infective filariform larva* (Fig. 18.3).
- *Filariform larva* is about 500–600 µm long, with a sharp pointed tail. The filariform larva are non-feeding. They can live in the soil for 5–6 weeks, with their heads waving in the air, waiting for their hosts. They can also ascend on blades of grass or other vegetation, being carried in capillary water films on their surface. Direct sunlight, drying, or salt water can kill the larva.
- **Mode of Infection:**
 - When a person walks **barefooted** on soil containing the filariform larva, they penetrate the **skin** and enter the subcutaneous tissue. The common sites of entry are the skin between the toes, the dorsum of the foot, and the medial aspect of the sole. In farm workers and miners, the larvae may penetrate the skin of the hands.
 - Rarely, infection may take place by the oral route, the filariform larva being carried on contaminated vegetables or fruits. The larvae may penetrate the buccal mucosa to reach the venous circulation and complete their migration via the lungs.
- Transmammary and transplacental transmission has been also reported for *Ancylostoma*, but not for *Necator*.
- Inside the human body, the larvae are carried along the venous circulation to the right side of the heart and to the lungs. Here, they escape from the pulmonary capillaries into the alveoli, migrate up the respiratory tract to the pharynx, and are swallowed, reaching their final destination small intestine.
- During migration or on reaching the esophagus, they undergo third **moulting**.
- They feed, grow in size, and undergo a **fourth and final moulting** in the small intestine and develop the buccal capsule, by which they attach themselves to the small intestine and grow into adults.
- There is no multiplication in the host and a single infective larva develops into a single adult, male or female.
- It takes usually about **6 weeks** from the time of infection for the adult worms to become sexually mature and start laying eggs. But sometimes, there may be an arrest in development and the process may take much longer, 6 months or more.
- Alternatively, the larvae may be swallowed and may develop directly into adults in the small intestine without a tissue phase.

Table 18.2: Differentiating Features of Two Species of Hookworm

	<i>Ancylostoma duodenale</i>	<i>Necator americanus</i>
Adult Worms		
Size	Large and thicker	Small and slender
Shape	Head bent in same direction as body	Head bent in opposite direction
Buccal capsule	4 ventral teeth and 2 dorsal knob like teeth	2 ventral and 2 dorsal chitinous cutting plates
Copulatory bursa	13 rays, two separate spicules, dorsal ray single	14 rays, two spicules fused at the tip, dorsal ray split
Caudal spine in female	Present	Absent
Vulval opening	Situated behind the middle of the body	Situated in anterior to middle part of body
Pathogenicity	More	Comparatively less
Eggs		
1st and 2nd stage Larve		
Egg/day	15,000–20,000	6,000–11,000
Rate of development	Faster	Slower
Pulmonary reaction	More common	Less common
Blood loss/worm	0.2 mL/day	0.03 mL/day
Iron loss (mg/day)	0.76 mg	0.45 mg
Male:female ratio	1:1	1.5:1
Life span	2–7 years	4–20 years

Necator Americanus

Morphology

The adult worms are slightly smaller than *A. duodenale*, the male being 7–9 mm by 0.3 mm and the female 9–11 mm by 0.4 mm.

- The anterior end is bent in a direction opposite to the general curvature of the body, while in *A. duodenale* the bend is in the same direction.
- They have a smaller buccal capsule with **2 pairs of semilunar cutting plates** instead of teeth as in *A. duodenale*.
- The copulatory bursa of the male is long and wide. The copulatory spicules are fused at the ends to form a barbed tip.
- In female, the vulva is placed in the middle of the body or anterior to it (Fig. 18.4).

The eggs of *N. americanus* are identical with those of *A. duodenale*. Their life cycle is similar to that of *A. duodenale*. The lifespan of *Necator* is much longer being about 4–20 years than in *Ancylostoma*, where it is of 2–7 years.

The differentiating features of *A. duodenale* and *N. americanus* have been discussed Table 18.2 and differentiating features between filariform larva of both species has been discussed in Table 18.3.

Pathogenicity and Clinical Features

For pathogenesis and clinical features, see flowchart 18.1.

Laboratory Diagnosis

Direct Methods

- Demonstration of characteristic oval segmented hookworm eggs in feces by direct wet microscopy or by concentration methods is the best method of diagnosis. In stool samples examined 24 hours or more after collection, the eggs may have hatched and rhabditiform

Causes of anemia in Hookworm infection

- Blood sucking by the parasite for their food
- Chronic hemorrhages from the punctured sites from jejunal mucosa
- Deficient absorption of vit B₁₂ and folic acid
- Depression of hemopoietic system by deficient intake of proteins
- Average blood loss by the host per worm per day is 0.03 mL with *N. americanus* and 0.2 mL with *A. duodenale*
- With iron deficiency, hypochromic microcytic anemia is caused and with deficiency of both iron and vit B₁₂ or folic acid, dimorphic anemia is caused.

larvae may be present. These have to be differentiated from *Strongyloides larvae*.

A count of less than 5 eggs per mg of feces seldom causes clinical disease, while counts of 20 eggs or more are associated with significant anaemia. Egg counts of 50 or more represent massive infection. **Egg counts** give a measure of the intensity of infection. Modified Kato-Katz smear technique is a useful method for quantitative estimation of eggs in stool.

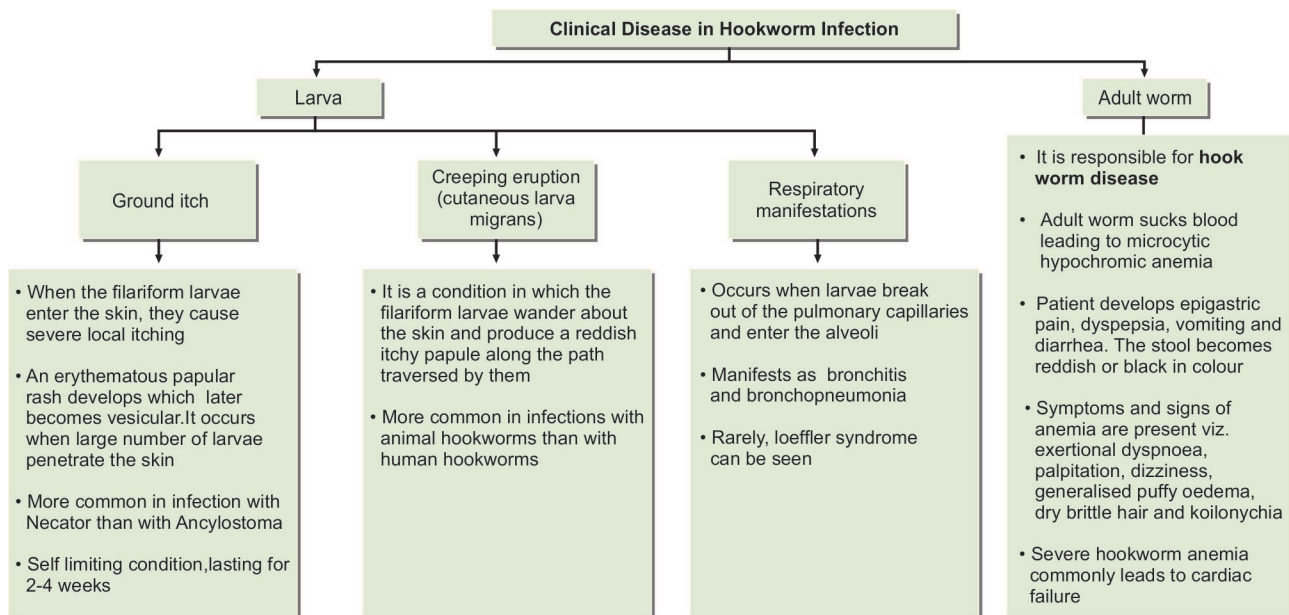
- Adult hookworms may sometimes be seen in feces. Eggs of *A. duodenale* and *N. americanus* cannot be differentiated by morphology. Thus specific diagnosis can only be made by studying morphology of adult worms.
- Duodenal contents may reveal eggs or adult worms.
- **Stool culture:** Harada Mori method of stool culture is carried out to demonstrate third stage filariform larvae which helps in distinguishing *A. duodenale* and *N. americanus* (Flowchart 18.2).

Indirect Methods

- Blood examination reveals microcytic, hypochromic anemia and eosinophilia.

Table 18.3: Differential Features of Filariform Larva (3rd stage larva)

	<i>Ancylostoma duodenale</i>	<i>Necator Americans</i>
Size	720 µm	660 µm
Head	Slightly conical	Rounded
Buccal cavity	Short, lumen larger	Larger, lumen shorter
Sheath	Faint cuticular striations	Prominent striation
Intestine	No gap between esophagus and intestine	A gap is present between esophagus and intestine
Posterior end of intestine	A small retractile body is present	No retractile body
Esophageal spears	Not prominent	Prominent
Tail	Long and blunt	Short and pointed



Flowchart 18.1: Clinical disease in Hookworm

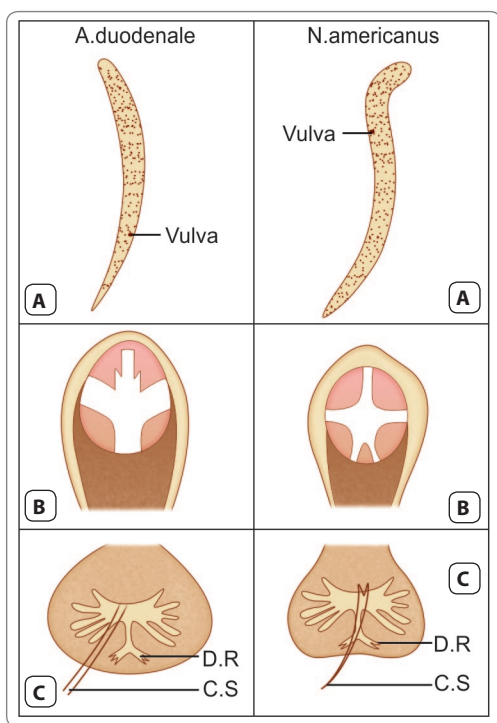


Fig. 18.4: Major distinguishing features between *Ancylostoma duodenale*, and *N. americanus*: **A.** Adult female in *Ancylostoma*—anterior curvature uniform with body curve; in *Necator*—anterior curvature in opposite direction to body curve. Vulva opens at junction of middle and posterior thirds in *Ancylostoma*; in *Necator* it opens a little in front of the middle; **B.** Buccal capsule, (*Ancylostoma*) has 2 pairs of hook-like teeth ventrally and a dental plate with median cleft dorsally; (*Necator*) has two pairs of semilunar cutting plates instead of teeth; **C.** Copulatory bursa. In (*Ancylostoma*), the dorsal ray (D.R.) is single with a split end, making a total of 13 rays; (*Necator*) has a paired dorsal ray, making a total of 14 rays. Copulatory spicules (C.S.) separate in (*Ancylostoma*); they are fused at the tip in (*Necator*)

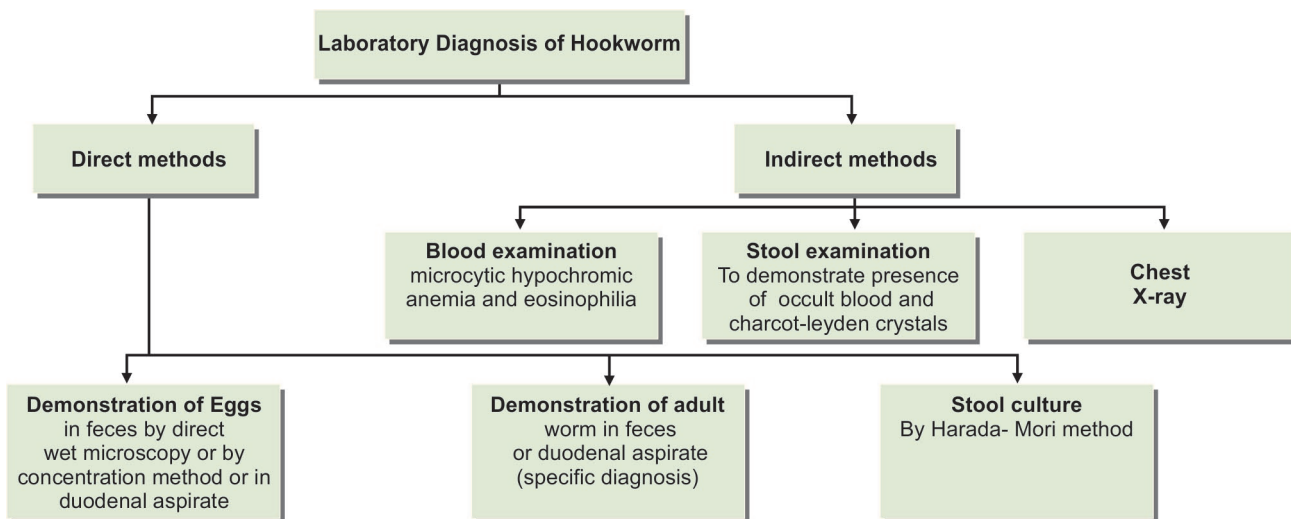
- Stool examination may show occult blood and Charcot-Leyden crystals (Flowchart 18.2).
- Chest X-ray may show pulmonary infiltrates in the migratory phase.

Treatment

- For specific antihelminthic treatment, the most practical and effective drug is albendazole (400 mg single dose) or mebendazole (500 mg once). Pyrantel pamoate (11 mg/kg × 3 days) is also effective and can be used in pregnancy. Thiabendazole is less effective. The old drug tetrachlorethylene is active, but toxic. Bephenium hydroxynaphthoate is active against *Ancylostoma* but not against *Necator*.
- Treatment of hookworm disease also includes relief of anemia. In hookworm disease, the intestinal absorption of iron is apparently normal so that oral administration of iron can correct the anemia, but in severe cases, a preliminary packed cell transfusion may be needed. When the hemoglobin level is very low, antihelminthic drugs should not be used before correcting the anemia.

Prephylaxis

- Prevention of soil pollution with feces and proper disposal of night soil and use of sanitary latrines.
- Use of footwear to prevent entry of larva through the skin of the foot. Gloves give similar protection to the hands of farm workers.
- Treatment of patients and carriers, preferably all at the same time, limit to the source of infection.



Flowchart 18.2: Laboratory diagnosis of hookworm

Other Hookworms

A. ceylanicum naturally parasitises cats and wild felines in South-East Asia, but can occasionally infect man. *A. braziliense*, a parasite of cats and dogs and some other species of animal ancylostomes have been reported to infect man, but they tend to cause creeping eruption (larva migrans) rather than intestinal infection.

Trichostrongylidosis

➤ *Trichostrongylus* species, normally parasitic in sheep and goats, can also cause human infections.

- This is particularly likely, where the use of night soil as manure is prevalent.
- The infection is present in some parts of India.
- The life cycle is similar to that of hookworms.
- Human infection is usually acquired by ingestion of leafy vegetables carrying the third-stage larva.
- Adults attach themselves to small intestinal mucosa, suck blood, and live for long periods. Infection is mostly asymptomatic but epigastric discomfort and anemia with marked eosinophilia occur in massive infections.
- The eggs passed in feces resemble hookworm eggs, but are larger, with more pointed ends and show greater segmentation with 16–32 blastomeres.
- Metronidazole is effective in treatment.

Key points of Hookworm

- *A. duodenale* is the old world hookworm and *N. americanus* is the new world hookworm.
- Adult worms live in small intestine (jejunum and duodenum).
- In *A. duodenale*, the anterior end is bent dorsally in the same direction of body curvature, hence the name hookworm. The mouth contains 6 teeth; 4 hook-like teeth ventrally and 2 knob-like dorsally. Posterior end of male has a copulatory bursa.
- Female is longer than male with tapering end.
- Eggs are oval, colorless, not bile-stained, and float in saturated salt solution and contain segmented ovum with 4 blastomeres.
- **Natural host:** Humans. Life cycle is completed in a single host.
- **Infective form:** Third-stage filariform larva.
- **Portal of entry:** Penetration of skin.
- **Clinical features:** Ground itch, creeping eruption (cutaneous larva migrans), bronchitis and bronchopneumonia in lung, hypochromic microcytic or dimorphic anemia and intestinal symptoms like epigastric pain, dyspepsia, nausea, and pica.
- **Diagnosis:** Done by demonstration of characteristic egg in the feces by direct microscopy or by concentration methods or by demonstration of adult worms in stool or duodenal aspirate.
- **Treatment:** Albendazole, mebendazole, pyrantel pamoate. Oral iron in anemia.

Review Questions

1. Name the helminths that do not require any intermediate host and describe briefly life cycle of *Ancylostoma duodenale*.

2. Short notes on:

(a) Causes of anemia in hookworm infection

(b) Clinical disease in hookworm infection

(c) Trichostrongylosis


(d) Prevention of hookworm infection

3. Differentiate between:

(a) Male and female of *Ancylostoma duodenale*

(b) *Ancylostoma duodenale* and *Necator americanus*

(c) Filariform larvae of *Ancylostoma* and *Necator*



Enterobius Vermicularis 19

Common name: Pinworm, Seatworm, Threadworm

History and Distribution

Enterobius vermicularis, formerly called *Oxyuris vermicularis* has been known from ancient times.

- The name *Enterobius vermicularis* means a tiny worm living in the intestine (Greek *enteron*—intestine, *bios*—life, and *vermiculus*—small worm). The term *Oxyuris* means 'sharp tail', a feature of the female worm, from which the name 'pinworm' is also derived.
- Leuckart (1865) first described the complete life cycle of the parasite.
- It is worldwide in distribution. Unlike the usual situation, where helminthic infections are more prevalent in the poor people of the tropics, *E. vermicularis* is one worm infestation which is far more common in the affluent nations in the cold and temperate regions (cosmopolitan).
- *E. vermicularis* is considered to be **world's most common** parasite, which specially affects the children.

Habitat

Adult worms are found in the caecum, appendix, and adjacent portion of ascending colon.

Morphology

Adult Worm

The adults are short, white, fusiform worms with pointed ends, looking like bits of white thread.

- The mouth is surrounded by 3 wing-like cuticular expansions (cervical alae), which are transversely striated.
- The esophagus has a double-bulb structure, a feature unique to this worm (Fig. 19.1).

Female Worm

The female is 8–13 mm long and 0.3–0.5 mm thick.

- Its posterior third is drawn into a thin pointed pin-like tail (Fig. 19.1).
- The vulva is located just in front of the middle third of the body and opens into the single vagina, which leads to the paired uteri, oviducts, and ovaries. In the gravid female, virtually the whole body is filled by the distended uteri carrying thousands of eggs.
- The worm is **oviparous**.
- Females survive for 5–12 weeks.

Male Worm

The male worm is 2–5 mm long and 0.1–0.2 mm thick.

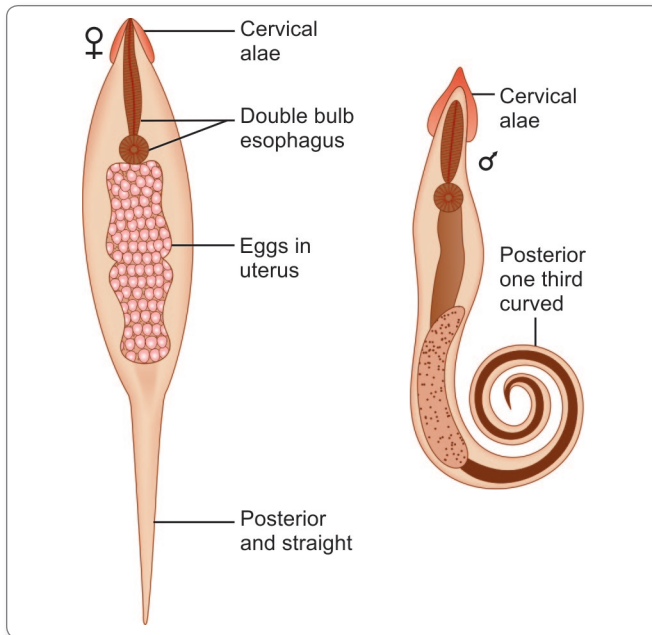


Fig. 19.1: Adult worm of *Enterobius vermicularis* (male and female)

- Its posterior end is tightly curved ventrally, sharply truncated and carries a prominent copulatory spicule (Fig. 19.1).
- Males live for about 7–8 weeks.

Egg

The egg is colorless and not bile-stained.

- It floats in saturated salt solution.
- It has a characteristic shape, being elongated ovoid, flattened on one side, and convex on the other

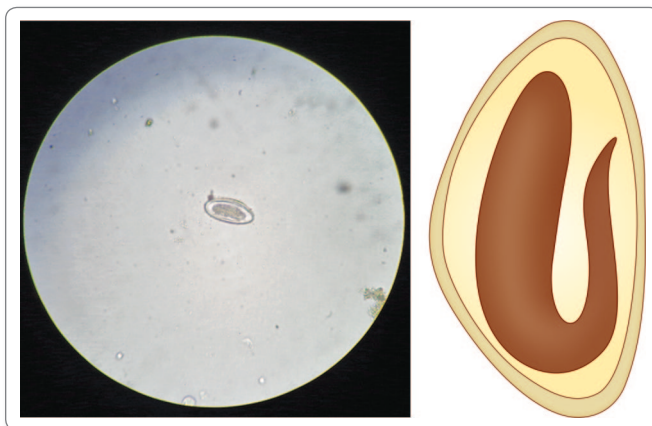


Fig. 19.2: Plano-convex egg of *Enterobius vermicularis* containing tadpole shaped embryo

(**planoconvex**), measuring 50–60 μm by 20–30 μm (Fig. 19.2).

- The egg shell is double layered and relatively thick, though transparent. The outer albuminous layer makes the eggs stick to each other and to clothing and other objects.
- The egg contains a **tadpole-shaped** coiled embryo, which is fully formed, but becomes infectious only 6 hours after being deposited on the skin. Under cool moist conditions, the egg remains viable for about 2 weeks (Fig. 19.2).
- A single female worm lays 5,000–17,000 eggs.

Life Cycle

E. vermicularis is monoxenous, passing its entire life cycle in the human host. It has no intermediate host and does not undergo any systemic migration.



Nematodes not showing systemic migration in man

- *Enterobius vermicularis*
- *Trichuris trichiura*

Natural host: Man

Infective form: Embryonated eggs

- **Mode of infection:** Man acquires infection by ingesting embryonated eggs containing larva by means of
 - Contaminated fingers
 - Autoinfection
- Eggs laid on perianal skin containing infective larvae are swallowed and hatch out in the intestine.
- They moult in the ileum and enter the caecum, where they mature into adults.
- It takes from 2 weeks to 2 months from the time the eggs are ingested, to the development of the gravid female, ready to lay eggs.
- The gravid female migrates down the colon to the rectum. At night, when the host is in bed, the worm comes out through the anus and crawls about on the perianal and perineal skin to lay its sticky eggs. The worm may retreat into the anal canal and come out again to lay more eggs.
- The female worm may wander into the vulva, vagina and even into the uterus and fallopian tubes, sometimes reaching the peritoneum.
- The male is seldom seen as it does not migrate. It usually dies after mating and is passed in the feces.

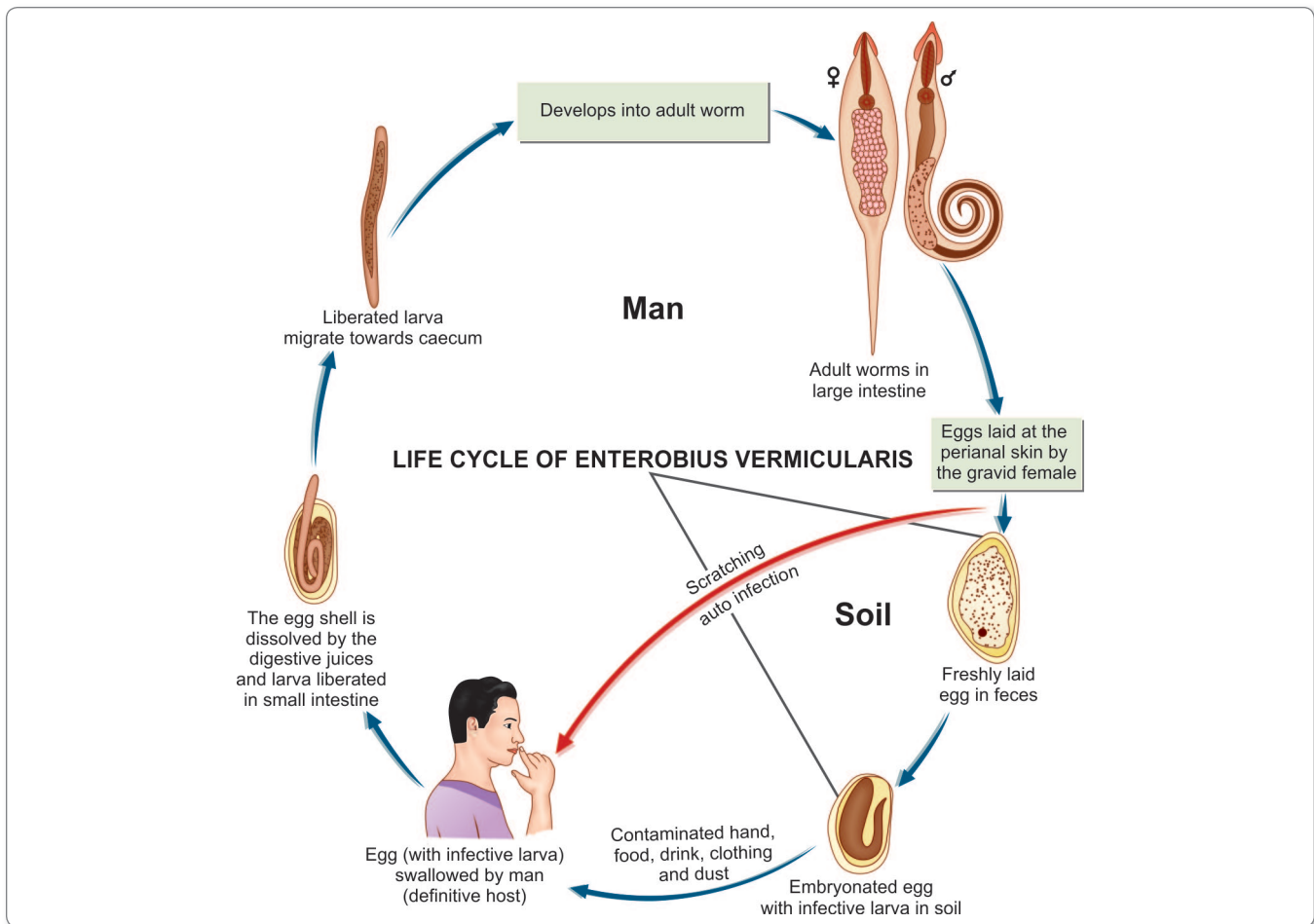


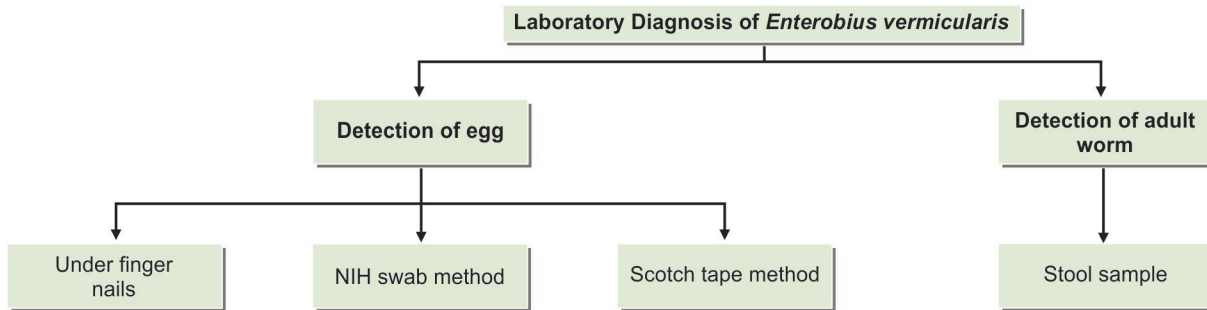
Fig. 19.3: Life cycle of *Enterobius vermicularis*

- When all the eggs are laid, the female worm dies or gets crushed by the host during scratching. The worm may often be seen on the feces, having been passively carried from the rectum. The eggs, however, are only infrequently found in feces, as the female worm lays eggs in the perianal area and not the rectum.
- Crawling of the gravid female worm leads to pruritis and the patient scratches the affected perianal area. These patients have eggs of *E. vermicularis* on fingers and under nails leading to autoinfection (Fig. 19.3).
- **Autoinfection:** Ingestion of eggs due to scratching of perianal area with fingers leading to deposition of eggs under the nails. This type of infection is mostly common in children. This mode of infection occurs from anus to mouth.
- **Retroinfection:** In this process, the eggs laid on the perianal skin immediately hatch into the infective stage larva and migrate through the anus to develop into worms in the colon. This mode of infection occurs from anus to colon.

Pathogenicity and Clinical Features

Enterobiasis occurs mostly in children. It is more common in females than in males. About one-third of infections are asymptomatic.

- The worm produces intense irritation and pruritus of the perianal and perineal area (**pruritis ani**), when it crawls out of the anus to lay eggs. This leads to scratching and excoriation of the skin around the anus.
- As the worm migrates out at night, it disturbs sleep. **Nocturnal enuresis** is sometimes seen.
- The worm crawling into the vulva and vagina causes irritation and a mucoid discharge. It may migrate upto the uterus, fallopian tubes and into the peritoneum. This may cause symptoms of **chronic salpingitis**, cervicitis, peritonitis, and recurrent urinary tract infections.
- The worm is sometimes found in surgically removed appendix and has been claimed to be responsible for **appendicitis**.



Flowchart 19.1: Laboratory diagnosis of *Enterobius vermicularis*

Laboratory Diagnosis

Pinworm infestation can be suspected from the history of perianal pruritus. Diagnosis depends on the demonstration of the eggs or adult worms (Flowchart 19.1).

Demonstration of Eggs

- Eggs are present in the feces only in a small proportion of patients and so feces examination is not useful in diagnosis.
- They are deposited in large numbers on the perianal and perineal skin at night and can be demonstrated in swabs collected from the sites early morning, before going to the toilet or bathing. Swabs from perianal folds are most often positive.
- The eggs may sometimes be demonstrated in the dirt collected from beneath the finger nails in infected children.

NIH Swab Method

The **NIH swab** (named after National Institutes of Health, USA) has been widely used for collection of specimens. This consists of a glass rod at one end of which a piece of transparent cellophane is attached with a rubber band. The glass rod is fixed on a rubber stopper and kept in a wide test tube. The cellophane part is used for swabbing by rolling over the perianal area (Fig. 19.4). It is returned to the test tube and sent to the laboratory, where the cellophane piece is detached, spread over a glass slide and examined microscopically.

Scotch Tape Method

Another method for collection of specimens is with scotch tape (adhesive transparent cellophane tape) held sticky side out, on a wooden tongue depressor. The mounted tape is firmly pressed against the anal margin, covering all sides. The tape is transferred to a glass slide, sticky side down, with a drop of toluene for clearing and examined under the microscope.

Demonstration of Adult Worm

The adult worms may sometimes be noticed on the surface of stools.

- They may occasionally be found crawling out of the anus while the children are asleep.
- They may be detected in stools collected after an enema and may be in the appendix during appendicectomy.

Note: Unlike the other intestinal nematodes, *Enterobius* infection is not associated with eosinophilia or with elevated IgE.



Infectious parasites which may be present in a fecal sample

- *Enterobius vermicularis*
- *Taenia solium*
- *Entamoeba histolytica*
- *Cryptosporidium parvum*
- *Strongyloides stercoralis*
- *Hymenolepis nana*
- *Giardia lamblia*

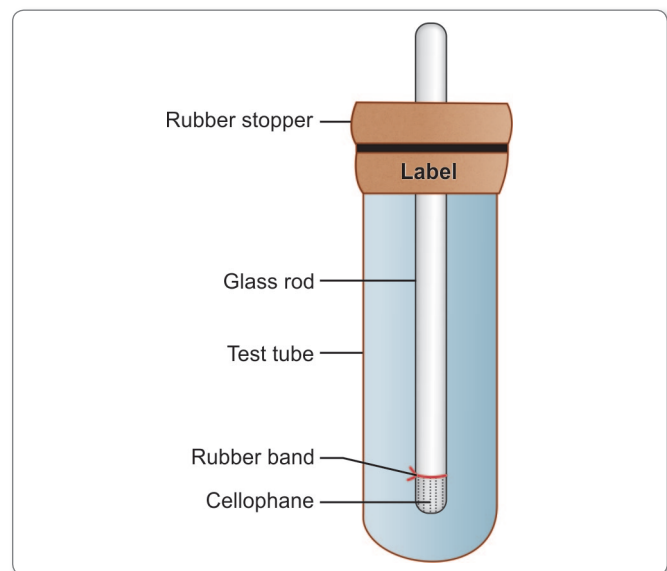


Fig. 19.4: NIH swab. A piece of transparent cellophane is attached with rubber band to one end of a glass rod, which is fixed on a rubber stopper and kept in a wide test tube

Treatment

Pyrantel pamoate (11 mg/kg once, maximum 1 g), Albendazole (400 mg once) or mebendazole (100 mg once) can be used for single dose therapy, while piperazine has to be given daily for one week.

- It is necessary to repeat the treatment after 2 weeks to take care of autochthonous infections and ensure elimination of all worms.

- As pinworm infection usually affects a group, it is advisable to treat the whole family or group of children, as the case may be.

Prophylaxis

- Maintenance of personal and community hygiene such as frequent hand washing, finger nail cleaning, and regular bathing.
- Frequent washing of night clothes and bed linen.

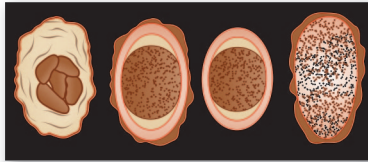
Key points of *Enterobius vermicularis*

- Adult worm lives in caecum and appendix.
- Mouth is surrounded by 3 wing-like cervical alae. Esophagus has a double bulb structure.
- Worm is oviparous.
- Eggs are colorless, not bile-stained; planoconvex in shape.
- **Natural host:** Humans. *E. vermicularis* passes its entire life cycle in human host. No intermediate host is required.
- **Infective form:** Embryonated egg containing infective larva.
- **Mode of infection:** By ingestion of eggs or autoinfection. Seen mostly in children and among family members.
- **Clinical features:** Pruritis ani, nocturnal enuresis. Sometimes, salpingitis, peritonitis, appendicitis, etc. may be seen.
- **Diagnosis:** Detection of eggs by NIH swab and cellophane scotch tape method. Detection of adult worm in finger nails or from stool after enema.
- **Treatment:** Mebendazole, albendazole, or pyrantel pamoate.

Review Questions

1. List the parasites causing autoinfection and describe briefly life cycle of *Enterobius vermicularis*.
2. Short notes on:

(a) Egg of <i>Enterobius vermicularis</i> (c) NIH swab	(b) Laboratory diagnosis of <i>Enterobius vermicularis</i>
---	--



Ascaris Lumbricoides 20

Common name: Roundworm

History and Distribution

Ascaris lumbricoides has been observed and described from very ancient times, when it was sometimes confused with the earthworm.

- Its specific name *lumbricoides* is derived from its resemblance with earthworm (*Lumbricus*, meaning *earthworm* in Latin).
- It is the most common of human helminths and is distributed worldwide. A billion people are estimated to be infected with roundworms. The individual worm burden could be very high, even up to over a thousand. An editorial in the *Lancet* in 1989 observed that if all the roundworms in all the people worldwide were placed end-to-end they would encircle the world 50 times.
- The incidence may be as high as 80–100% in rural areas with poor sanitation.

Habitat

Adult worms live in the small intestines (85% in jejunum and 15% in ileum).



The roundworm, *Ascaris lumbricoides* is the largest nematode parasite in the human intestine.

Morphology

Adult Worm

They are large **cylindrical** worms, with **tapering** ends, the anterior end being more pointed than the posterior (Fig. 20.1).

- They are pale pink or flesh colored when freshly passed in stools, but become white outside the body.



Fig. 20.1: Specimen of *Ascaris lumbricoides*

- The mouth at the anterior end has **3** finely toothed lips, **1 dorsal** and **2 ventrolateral** (Fig. 20.2).

Male Worm

- The adult male worm is little **smaller** than female. It measures 15–30 cm in length and 2–4 mm in thickness (Fig. 20.2).
- Its posterior end is curved ventrally to form a **hook** and carries **2 copulatory spicules** (Fig. 20.2).

Female Worm

The female is **larger** than male, measuring 20–40 cm in length and 3–6 mm in thickness.

- Its posterior extremity is **straight** and **conical**.
- The vulva is situated mid-ventrally, near the junction of the anterior and middle thirds of the body. A **distinct groove** is often seen surrounding the worm at the level of the vulvar opening. This is called the **vulvar waist** or **genital girdle** and is believed to facilitate mating (Fig. 20.2). The vulva leads to a single vagina, which branches into a pair of genital tubules that lie convoluted through much of the posterior two-thirds of the body. The genital tubules of the gravid worm contain an enormous number of eggs as many as 27 million at a time.

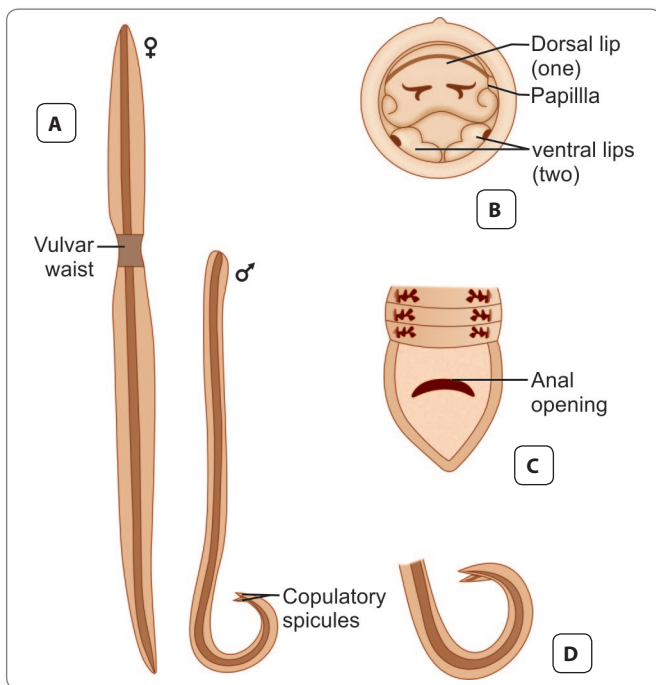


Fig. 20.2: *Ascaris lumbricoides*. **A.** Adult female and male worms; **B.** Anterior end of worm, head-on view, showing 1 dorsal and 2 ventral lips with papillae; **C.** Posterior end of female, showing anal opening, a little above the conical tip; **D.** Posterior end of male, showing 2 protruding copulatory spicules(s)

- A single worm lays up to 200,000 eggs per day. The eggs are passed in feces.

Egg

Two types of eggs are passed by the worms; fertilized and unfertilized.

- The fertilized eggs, laid by females, inseminated by mating with a male, are embryonated and develop into the infective eggs (Fig. 20.3A, B).
- The unfertilized eggs, are laid by unseminated female. These are non-embryonated and cannot become infective (Fig. 20.3D).

Table 20.1: Features of Round Worm Egg

Type of egg	Main feature
Unfertilized egg (Fig. 20.4A)	<ul style="list-style-type: none"> • Elliptical in shape • Narrower and longer • 80 μm × 55 μm in size • Has a thinner shell with an irregular coating of albumin • Contains a small atrophied ovum with a mass of disorganized highly refractile granules of various size • Does not float in salt solution
Fertilized eggs (Fig. 20.4B)	<ul style="list-style-type: none"> • Round or oval in shape • Size 60–75 μm × 40–45 μm • Always bile-stained • Golden brown in color • Surrounded by thick smooth translucent shell with an outer coarsely mammillated albuminous coat, a thick transparent middle layer and the inner lipoidal vitelline membrane • Some eggs are found in feces without the outer mammillated coat. They are called the decorticated eggs (Fig. 20.3C) • In the middle of the egg is a large unsegmented ovum, containing a mass of coarse lecithin granules. It nearly fills the egg, except for a clear crescentic area at either poles • Floats in saturated solution of common salt

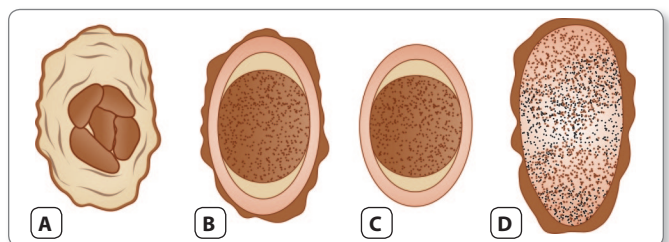


Fig. 20.3: Types of *Ascaris* eggs found in stools. **A.** Fertilized egg surface focus, showing outer mamillary coat; **B.** Fertilized egg, median focus, showing unsegmented ovum surrounded by 3 layers of coats; **C.** Decorticated fertilized egg, the mamillary coat is absent; **D.** Unfertilized egg, elongated, with atrophic ovum

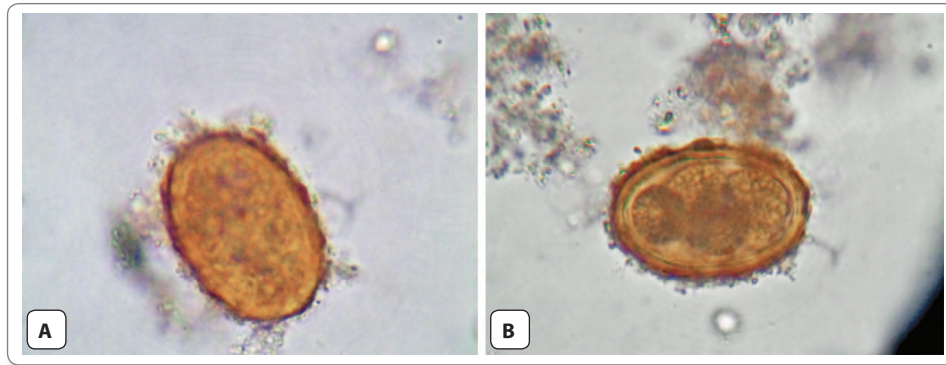


Fig. 20.4: A. Unfertilized egg of *Ascaris*; B. Fertilized egg of *Ascaris*

Note: Stool samples may show both fertilized and unfertilized eggs, or either type alone.



Parasites with bile stained eggs

- *Ascaris lumbricoides*
- *Trichuris trichiura*
- *Taenia solium*
- *Taenia saginata*
- *Clonorchis sinensis*
- *Fasciola hepatica*
- *Fasciolopsis buski*

Life Cycle

Life cycle of *Ascaris* involves only 1 host.

Natural host: Man. There is no intermediate host.

Infective form: Embryonated eggs

- **Mode of transmission:**
 - Infection occurs when the egg containing the **infective rhabditiform** larva is swallowed. A frequent mode of transmission is through fresh vegetables grown in fields manured with human feces ('night soil'). Infection may also be transmitted through contaminated drinking water.
 - Children playing about in mud can transmit eggs to their mouth through dirty fingers (**geophagy**).
 - Where soil contamination is heavy due to indiscriminate defecation, the eggs sometimes get airborne along with windswept dust and are inhaled. The inhaled eggs get swallowed.

Development in Soil

The fertilized egg passed in feces is not immediately infective. It has to undergo a period of incubation in soil before acquiring infectivity.

- The eggs are resistant to adverse conditions and can survive for several years.

- The development of the egg in soil depends on the nature of the soil and various environmental factors. A heavy clayey soil and moist shady location, with temperature between 20° and 30°C are optimal for rapid development of the embryo.
- The development usually takes from **10–40 days**, during which time the embryo **moults twice** and becomes the infective rhabditiform larva, coiled up within the egg.

Development in Man

When the swallowed eggs reach the duodenum, the larvae hatch out.

- The rhabditiform larva, about 250 µm in length and 14 µm in diameter, are actively motile.
- They penetrate the intestinal mucosa, enter the **portal vessels** and are carried to the **liver**.
- They then pass via the hepatic vein, inferior vena cava, and the right side of the heart and in about **4 days** reach the **lungs**, where they grow and **moult twice**.
- After development in the lungs, in about **10–15 days**, the larvae pierce the lung capillaries and reach the alveoli. They crawl up or are carried up the respiratory passage to the throat and are swallowed.
- The larvae **moult finally** and develop into adults in the upper part of the **small intestine**. They become sexually mature in about **6–12 weeks** and the gravid females start laying eggs to repeat the cycle (Fig. 20.5).
- The adult worm has a lifespan of 12–20 months.

Pathogenicity and Clinical Features

Disease caused by *A. lumbricoides* is called as *ascariasis*.

- Clinical manifestations in ascariasis can be caused either by the migrating larvae or by the adult worms.

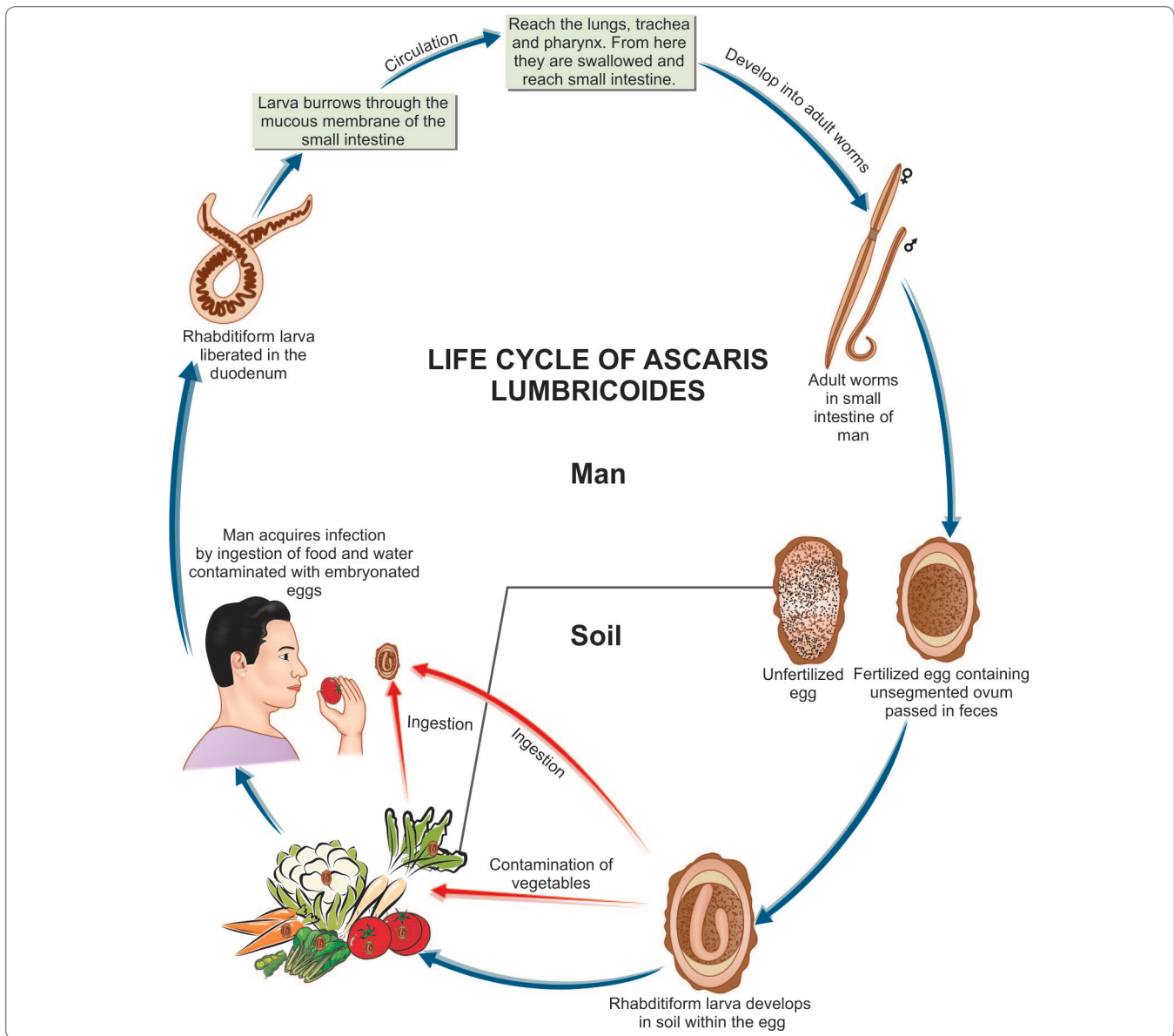


Fig. 20.5: Life cycle of *Ascaris lumbricoides*

Symptoms due to the Migrating Larvae

The pathogenic effects of larval migration are due to allergic reaction and not the presence of larvae as such. Therefore, the initial exposure to larvae is usually asymptomatic, except when the larval load is very heavy.

- When reinfection occurs subsequently, there may be intense cellular reaction to the migrating larvae in the lungs, with infiltration of eosinophils, macrophages, and epithelioid cells.
- This **ascaris pneumonia** is characterized by low grade fever, dry cough, asthmatic wheezing, urticaria,

eosinophilia, and mottled lung infiltration in the chest radiograph.

- The sputum is often **blood-tinged** and may contain **Charcot-Leyden** crystals. The larvae may occasionally be found in the sputum, but are seen more often in gastric washings. This condition is called **Loeffler's syndrome**.
- The clinical features generally clear in 1 or 2 weeks, though it may sometimes be severe and rarely, even fatal. Loeffler's syndrome can also be caused by hypersensitivity to other agents, both living and non-living.

? Parasites causing Pneumonitis or Loeffler's syndrome

- Migrating larvae of:
 - *Ascaris lumbricoides*
 - *Strongyloides stercoralis*
 - *Ancylostoma duodenale*
 - *Necator americanus*
- *Echinococcus granulosus*
- Eggs of *Paragonimus westermani*
- *Cryptosporidium parvum*
- *Trichomonas tenax*
- *Entamoeba histolytica*

Symptoms due to the Adult Worm

Clinical manifestations due to adult worm vary from asymptomatic infection to severe and even fatal consequences.

- **Asymptomatic infection:** Generally seen in mildly infected cases; however, it is not unusual to find children apparently unaffected in spite of heavy infestation with the worms.
- The pathological effects, when present, are caused by **spoliative action, toxic action, mechanical effects, and wandering effects.**
 - **The spoliative or nutritional effects** are usually seen when the worm burden is heavy. The worms may be present in enormous numbers, sometimes exceeding 500, in small children, occupying a large part of the intestinal tract. This interferes with proper digestion and absorption of food. Ascariasis may contribute to **protein-energy malnutrition** and **vitamin A deficiency**. Patients have loss of appetite and are often listless. Abnormalities of the jejunal mucosa are often present, including broadening and shortening of villi, elongation of crypts, and round cell infiltration of lamina propria. These changes are reversed when the worms are eliminated.
 - **The toxic effects** are due to hypersensitivity to the worm antigens and may be manifested as fever, urticaria, angioneurotic edema, wheezing, and conjunctivitis. These are more often seen in persons who come into contact with the worm occupationally, as in laboratory technicians and abattoir workers (who become sensitive to the pig ascarid, *A. suum*), than in children having intestinal infestation.
 - **The mechanical effects** are the most important manifestations of ascariasis. Mechanical effects can be due to masses of worms causing luminal occlusion or even a single worm infiltrating into a vital area. The adult worms live in the upper part of the small

intestine, where they maintain their position due to their body muscle tone, spanning the lumen.

They may stimulate reflex peristalsis, causing recurrent and often severe colicky pain in the abdomen. The worms may be clumped together into a mass, filling the lumen, leading to volvulus, intussusception, or intestinal obstruction and intestinal perforation.

- **Ectopic ascariasis (Wanderlust):** The worms are restless wanderers, apparently showing great inquisitiveness, in that they tend to probe and insinuate themselves into any aperture they find on the way. The wandering is enhanced when the host is ill, particularly when febrile, with temperature above 39°C. The male worm is more responsive to illness of the host, than the female. The worm may wander up or down along the gut. Going up, it may enter the opening of the biliary or pancreatic duct causing **acute biliary obstruction** or **pancreatitis**. It may enter the liver parenchyma, where it may lead to liver abscesses. The worm may go up the esophagus and come out through the mouth or nose. It may crawl into the trachea and the lung causing respiratory obstruction or lung abscesses. Migrating downwards, the worm may cause **obstructive appendicitis**. It may lead to peritonitis when it perforates the intestine, generally at weak spots such as typhoid or tuberculous ulcers or through suture lines. This tendency makes preoperative deworming necessary before gastrointestinal surgery in endemic areas. The wandering worm may also reach kidneys.

Laboratory Diagnosis

Detection of Parasite

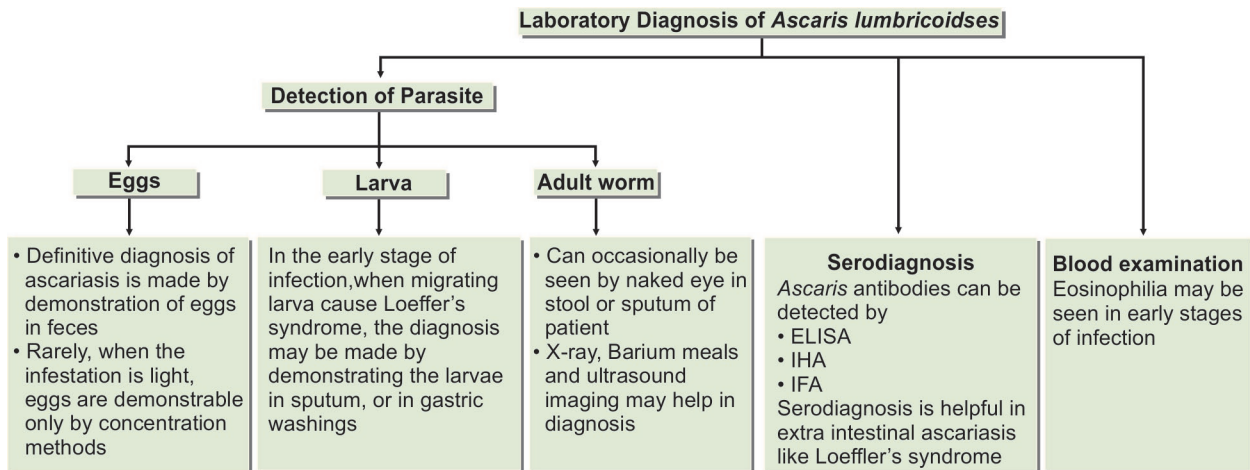
Adult Worm

The adult worm can occasionally be detected in stool or sputum of patient by naked eye.

- Barium meal may reveal the presence of adult worm in the small intestine.
- A plain abdominal film may reveal masses of worms in gas-filled loops of bowel in patients with intestinal obstruction.
- Pancreaticobiliary worms can be detected by ultrasound (more than 50% sensitive) and endoscopic retrograde cholangiopancreatography (ERCP; 90% sensitive).

Larvae

In the early stages of infection, when migrating larvae cause Loeffler's syndrome, the diagnosis may be made



Flowchart 20.1: Laboratory diagnosis of *Ascaris lumbricoides*

by demonstrating the larvae in **sputum**, or more often in **gastric washings**.

- Presence of Charcot-Leyden crystals in sputum and an attendant eosinophilia supports the diagnosis. At this stage, no eggs are seen in feces.
- Chest X-ray may show patchy pulmonary infiltrates.

Eggs

Definitive diagnosis of ascariasis is made by demonstration of eggs in **feces**.

- Ascarids are prolific egg layers. A single female may account for about 3 eggs per mg of feces. At this concentration, the eggs can be readily seen by microscopic examination of a saline emulsion of feces. Both fertilized and unfertilized eggs are usually present. Occasionally, only one type is seen. The fertilized eggs may sometimes appear decorticated. The unfertilized eggs are not detectable by salt floatation.
- Rarely when the infestation is light, eggs are demonstrable only by concentration methods.
- Eggs may not be seen if only male worms are present, as may occasionally be the case. Fecal films often contain many artefacts resembling *Ascaris* eggs and care must be taken to differentiate them.
- Eggs may be demonstrative in **the bile** obtained by **duodenal aspirates** (Flowchart 20.1).

Serological Tests

Ascaris antibody can be detected by:

- Indirect hemagglutination (IHA)
- Immunofluorescence antibody (IFA)
- Enzyme-linked immuno-sorbent assay (ELISA)
- Serodiagnosis is helpful in extra intestinal ascariasis like Loeffler's syndrome (Flowchart 20.1).

Blood Examination

Complete blood count may show eosinophilia in early stage of invasion (Flowchart 20.1).

Treatment

Several safe and effective drugs are now available for treatment of ascariasis. These include pyrantel pamoate (11 mg/kg once; maximum 1 g), albendazole (400 mg once), mebendazole (100 g twice daily for 3 days or 500 mg once), or ivermectin (150–200 mg/kg once). These medications are contraindicated in pregnancy; however, pyrantel pamoate is safe in pregnancy.

- Partial intestinal obstruction should be managed with nasogastric suction, intravenous fluid administration, and instillation of piperazine through the nasogastric tube.
- Complete obstruction requires immediate surgical intervention.

Prophylaxis

- Ascariasis can be eliminated by preventing fecal contamination of soil. The *Ascaris* egg is highly resistant. Therefore, the use of night soil as manure will lead to spread of the infection, unless destruction of the eggs is ensured by proper composting. Treatment of vegetables and other garden crops with water containing iodine 200 ppm for 15 minutes kills the eggs and larvae of *Ascaris* and other helminths.
- Avoid eating raw vegetables.
- Improvement of personal hygiene.
- Treatment of infected persons especially the children.

Key points of *Ascaris lumbricoides*

- *A. lumbricoides* is the largest nematode infecting human.
- Adult worm is cylindrical resembling an earth worm.
- Male is little smaller than female. Posterior end of male is curved ventrally to form a hook with 2 copulatory spicules. Posterior end of female is conical and straight.
- Fertilized eggs are bile-stained, round or oval, surrounded by a thin translucent wall with outer mammillated coat containing a large unsegmented ovum. Unfertilized eggs are elliptical, longer with a outer thinner irregular mammillated coat, containing a small atrophied ovum and refractile granules.
- **Natural host:** Man
- **Infective form:** Embryonated egg containing rhabditiform larva.
- **Clinical features:** Spoliative action—protein and vitamin A deficiency. Toxic action—urticaria and angioneurotic edema. Mechanical action—intestinal obstruction, intussusception, volvulus, intestinal perforation. In Lungs—*Ascaris* can cause pneumonia (Loeffler's syndrome).
- **Diagnosis:** Demonstration of eggs in stool, finding of larvae in sputum, finding of adult worm in stool or sputum.
- **Treatment:** Albendazole, mebendazole, ivermectin, or pyrantel pamoate.



Fig. 20.6: Adult worms of *Toxocara canis*

Other Roundworms

Toxocara

Toxocara canis and *T. cati*, natural parasites of dogs and cats (Fig. 20.6), respectively can cause aberrant infection in humans leading to **visceral larva migrans**.

- Infection is acquired in puppies by transmission of larvae transplacentally or lactogenically (through breast milk), but in kittens, only lactogenic transmission is recorded.
- Older animals are infected by ingestion of mature eggs in soil or of larvae by eating infected rodents, birds, or other paratenic hosts.
- Eggs are shed in feces and become infective in 2–3 weeks.
- Human infection is by ingestion of eggs.
- Larvae hatch out in the small intestine, penetrate the mucosa, and reach the liver, lungs, or other viscera. They do not develop any further.
- Most infections are asymptomatic, but in some, particularly in young children, **visceral larva migrans** develops, characterized by fever, hepatomegaly, cough, pulmonary infiltrates, high eosinophilia, and hyperglobulinemia. In some, the eye is affected (**ophthalmic larva migrans**).

Baylisascaris

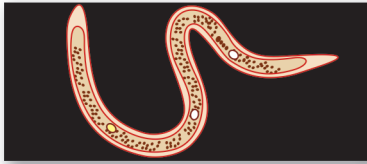Baylisascaris procyonis, an ascarid parasite of raccoons in North America, is known to cause serious zoonotic infections leading to visceral larva migrans, ophthalmic larva migrans, and **neural larva migrans**. Complications include blindness and central nervous system lesions ranging from minor neuropsychiatric conditions to seizures, coma, and death.

Geohelminths

- **Soil-transmitted** intestinal nematodes are called **Geohelminths**. In all of them, eggs passed in feces undergo maturation in soil. They are classified into 3 categories based on their life cycle.
 - **Direct:** Ingested infective eggs directly develop into adults in the intestine, e.g. whipworms.
 - **Modified direct:** Larvae from ingested eggs penetrate intestinal mucosa enter blood stream and through the liver, heart, lungs, bronchus, and esophagus, reach the gut to develop into adults, e.g. roundworms.
 - **Skin penetrating:** Infective larvae in soil penetrate host skin, reach the lung, and proceed to the gut as in the modified direct method, e.g. hookworms.
- Geohelminths pose a serious health problem in poor countries, particularly among children. Their control requires general measures such as personal hygiene, sanitation, and health education, besides provision of diagnostic and treatment facilities.

Review Questions

1. Name the parasites causing pneumonitis and describe briefly the life cycle and laboratory diagnosis of *Ascaris lumbricoides*.
2. Short notes on:
 - (a) Clinical manifestations of ascariasis
 - (b) Loeffler's syndrome
 - (c) Surgical complications of ascariasis
 - (d) Toxocariasis
 - (e) Geohelminths
3. Differentiate between fertilized and unfertilized egg of *Ascaris lumbricoides*.



Filarial Worms 21

Nematodes belonging to the **superfamily Filarioidea** are **slender thread-like worms** (Latin, *filum* and *thread*), which are transmitted by the bite of blood-sucking insects

- The filarial worms reside in the subcutaneous tissues, lymphatic system, or body cavities of humans (Table 21.1).
- The adult worm generally measures 80–100 mm in length and 0.25–0.30 mm in breadth; the female worm being longer than the males.
- The tail of the male worm has perianal papillae and unequal spicules but no caudal bursa.
- The female worms are **viviparous** and give birth to larvae known as **microfilariae**.
- The microfilariae released by the female worm, can be detected in the peripheral blood or cutaneous tissues, depending on the species.
- In some species, the microfilariae retain their egg membranes which envelop them as **sheath**. They are known as **sheathed** microfilariae.

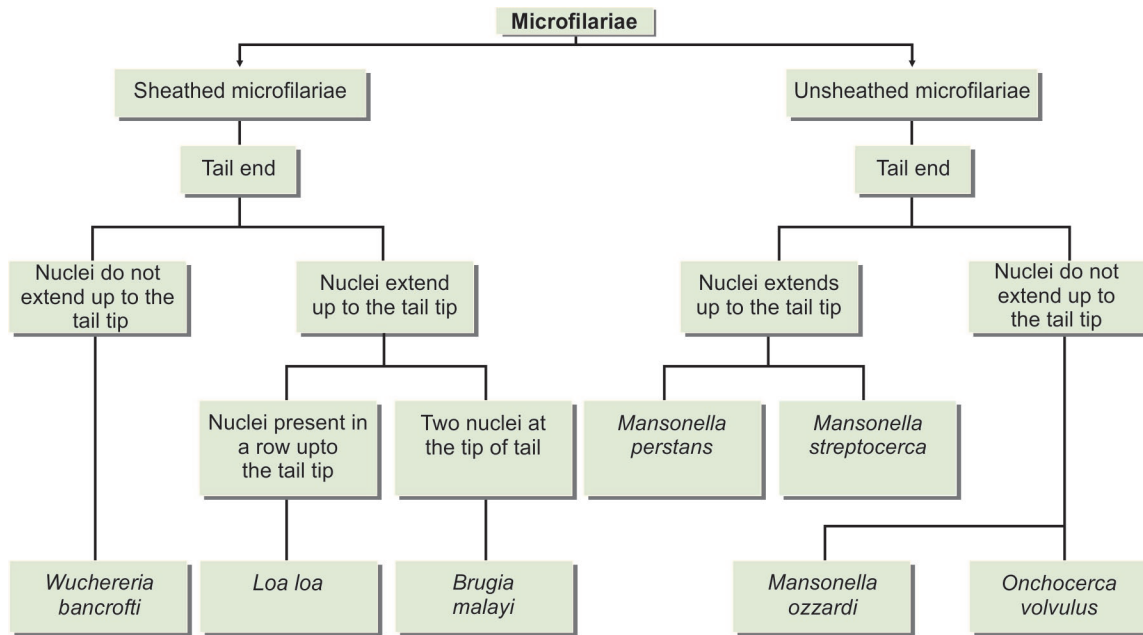
- In some other species of filarial nematodes, the egg membrane is ruptured and are known as **unsheathed** microfilariae.
- Once the microfilariae are classified on the basis of sheath as 'sheathed' or 'unsheathed', their further differentiation can be done on the characteristic arrangement of nuclei (Flowchart 21.1 and Fig. 21.1).
- **Periodicity:** Depending on when the largest number of microfilariae occur in blood, filarial worms can exhibit nocturnal, diurnal periodicity or no periodicity at all. The basis of periodicity is unknown but it may be an adaptation to the biting habits of the vector.

Table 21.1: Classification of Filarial Worm Based on Location in Body

Lymphatic filariasis	Subcutaneous filariasis	Serous cavity filariasis
<ul style="list-style-type: none"> • <i>Wuchereria bancrofti</i> • <i>Brugia malayi</i> • <i>Brugia timori</i> 	<ul style="list-style-type: none"> • <i>Loa loa</i> • <i>Onchocerca volvulus</i> • <i>Mansonella streptocerca</i> 	<ul style="list-style-type: none"> • <i>Mansonella perstans</i> • <i>Mansonella ozzardi</i> (They are virtually nonpathogenic)

- **Nocturnal periodicity:** When the largest number of microfilariae occur in blood at night, e.g. *Wuchereria bancrofti*
- **Diurnal periodicity:** When the largest number of microfilariae occur in blood during day, e.g. *Loa loa*
- **Nonperiodic:** When the microfilariae circulate at constant levels during the day and night, e.g. *Onchocerca volvulus*
- **Subperiodic or nocturnally subperiodic:** When the microfilariae can be detected in the blood throughout the day but are detected in higher numbers during the late afternoon or at night.

Note: The microfilariae are found in capillaries and blood vessels of lungs during the period when they are not present in the peripheral blood.



Flowchart 21.1: Differentiating features of various microfilariae on the basis of presence of nuclei in tail end

Species	<i>Wuchereria bancrofti</i>	<i>Brugia malayi</i>	<i>Loa loa</i>	<i>Mansonella perstans</i>	<i>Mansonella ozzardi</i>	<i>Onchocerca volvulus</i>
Shape						
Posterior end						
Tail nuclei	Nuclei do not extend to the tip of tail	2 nuclei at the tip of the tail	Nuclei form continuous row in the tip of the tail	Nuclei extend to the tip of the tail	Nuclei do not extend to the tip of the tail	Nuclei do not extend to the tip of the tail
Anterior end						
Size	300 x 8 μm	220 x 6 μm	270 x 8 μm	180 x 4 μm	220 x 4 μm	200 x 360 μm
Sheathed/unsheathed	Sheathed	Sheathed	Sheathed	Unsheathed	Unsheathed	Unsheathed
Habitat	Blood	Blood	Blood	Blood	Blood	Skin, eye

Fig. 21.1: Head and tail ends of microfilariae found in humans

Table 21.2: Filarial Nematodes Infecting Humans

Parasite	Location in body adult	Microfilaria	Characteristics of microfilaria	Periodicity of microfilaria	Principal vector
I. Lymphatic filariasis					
<i>Wuchereria bancrofti</i>	Lymphatics	Blood	Sheathed, pointed tail tip free of nuclei	Nocturnal	<i>Culex quinquefasciatus</i>
<i>Brugia malayi</i>	Lymphatics	Blood	Sheathed, blunt tail tip with 2 terminal nuclei	Nocturnal	<i>Mansonia</i> spp.
<i>Brugia timori</i>	Lymphatics	Blood	Sheathed, longer than <i>Mf.</i> <i>malayi</i>	Nocturnal	<i>Anopheles barbirostris</i>
II. Subcutaneous filariasis					
<i>Loa loa</i>	Connective tissue, conjunctiva	Blood	Sheathed, nuclei extending up to pointed tail tip	Diurnal	<i>Chrysops</i> spp.
<i>Onchocerca volvulus</i>	Subcutaneous nodules	Skin, eyes	Unsheathed, blunt tail tip free of nuclei	Non periodic	<i>Simulium</i> spp.
<i>Mansonella streptocerca</i>	Subcutaneous	Skin	Unsheathed blunt tail tip with nuclei	Non periodic	<i>Culicoides</i>
III. Serous cavity filariasis					
<i>Mansonella ozzardi</i>	Peritoneum and pleura	Blood	Unsheathed, pointed tail tip without nuclei	Non periodic	<i>Culicoides</i>
<i>Mansonella perstans</i>	Peritoneum and pleura	Blood	Unsheathed, pointed tail tip with nuclei	Non periodic	<i>Culicoides</i>

- The life cycle of filarial nematodes is passed in 2 hosts: **definitive host** is man and **intermediate host** are the **blood-sucking arthropods**.
- The microfilariae complete their development in the arthropod host to produce the infective larval stages. These are transmitted to humans by arthropod, which are their vectors also during the next feed. Adult worms live for many years whereas microfilariae survive for 3–36 months.
- **Eight species** of filarial worms infect humans, of them six are pathogenic—*Wuchereria bancrofti*, *Brugia malayi*, and *B. timori* cause lymphatic filariasis; *Loa loa* causes malabar swellings and allergic lesions; *Onchocerca volvulus* causes eye lesions and dermatitis; *Mansonella streptocerca* leads to skin diseases; and two of them, *M. ozzardi* and *M. perstans* are virtually nonpathogenic (Table 21.2).
- Infection with any of the filarial worms may be called **filariasis**, but traditionally, the term filariasis refers to lymphatic filariasis caused by *Wuchereria* or *Brugia* species.
- Adult filarial worm contains an endosymbiotic *Rickettsia*-like α -proteobacterium of the genus *Wolbachia* spp. This has got definite role in the pathogenesis of filariasis and has become a target for antifilarial chemotherapy.
- *Wolbachia* spp. along with filarial antigen activate the release of proinflammatory and chemotactic cytokines.

These include cellular infiltration and amplification of inflammatory processes. Toll-like receptors (TLRs) play an important role in the process.

LYMPHATIC FILARIASIS

Wuchereria Bancrofti

History and Distribution

Filariasis has been known from antiquity. Elephantiasis had been described in India by Sushruta and in Persia by Rhazes and Avicenna.

- **Elephantiasis** – painful, disfiguring swelling of the legs and genital organs – is a classic sign of late-stage disease
- The term **Malabar leg** was applied to the condition by Clarke in 1709 in Cochin.
- Microfilaria was first observed by Demarquay (1863) in the hydrocele fluid of a patient from Havana, Cuba. The genus is named after Wucherer, a Brazilian physician who reported microfilariae in chylous urine in 1868. Microfilaria was first demonstrated in human blood in Calcutta by Lewis (1872).
- In 1876, Bancroft first reported and described adult female worm and in 1888, adult male worm was described by Bourne.

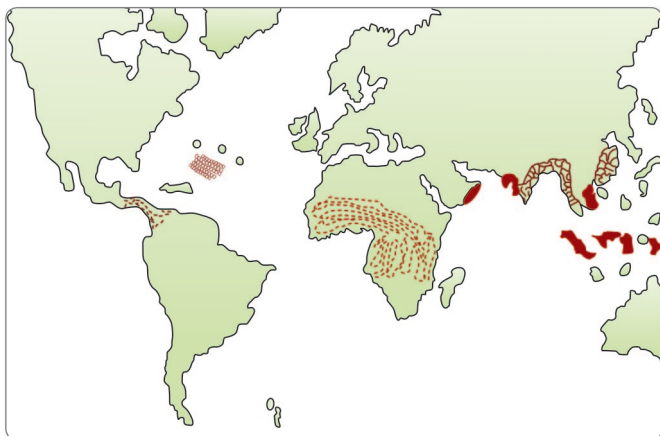


Fig. 21.2: Geographical distribution of *Wuchereria bancrofti*

- Manson (1878) in China identified the *Culex* mosquito as the vector. This was the first discovery of insect transmission of a human disease. Manson (1879) also demonstrated the nocturnal periodicity of microfilariae in peripheral blood.
- *W. bancrofti* is distributed widely in the tropics and subtropics of sub-Saharan Africa, South-East Asia, India, and the Pacific islands. The largest number of cases of filariasis occur in India (Fig. 21.2).
- In India, the endemic areas are mainly along the sea coast and along the banks of the large rivers, though infection occurs virtually in all states, except in the north-west.

Habitat

The adult worms reside in the lymphatic system of man. The microfilariae are found in blood.

Morphology

Adult Worm

The adults are whitish, translucent, thread-like worms with smooth cuticle and tapering ends.

- The female is larger (70–100 × 0.25 mm) than the male (25–40 × 0.1 mm).
- The posterior end of the female worm is straight, while that of the male is curved vertically and contains 2 spicules of unequal length.
- Males and females remain coiled together usually in the abdominal and inguinal lymphatics and in the testicular tissues (Fig. 21.3).
- The female worm is **viviparous** and directly liberates sheathed microfilariae into lymph.
- The adult worms live for many years, probably 10–15 years or more.

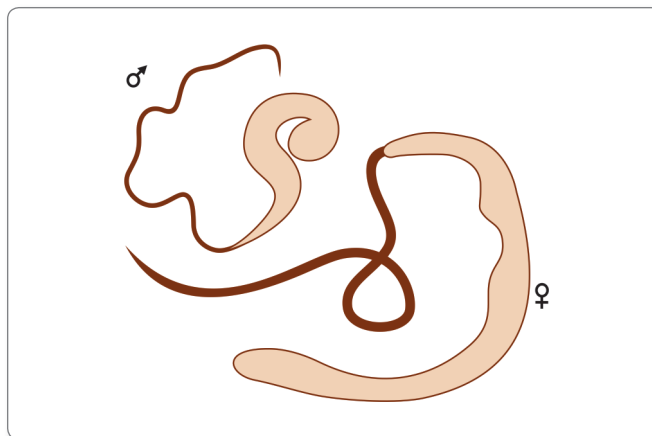


Fig. 21.3: Adult worm of *Wuchereria bancrofti*

Microfilariae

The microfilaria has a colorless, translucent body with a **blunt head**, and **pointed tail** (Fig. 21.4).

- It measures 250–300 μm in length and 6–10 μm in thickness. It can move forwards and backwards within the sheath which is much longer than the embryo.
- It is covered by a hyaline sheath, within which it can actively move forwards and backwards as sheath is much longer than the embryo.
- When stained with Leishman or other Romanowsky stains, structural details can be made out. Along the central axis of the microfilaria, a column of granules

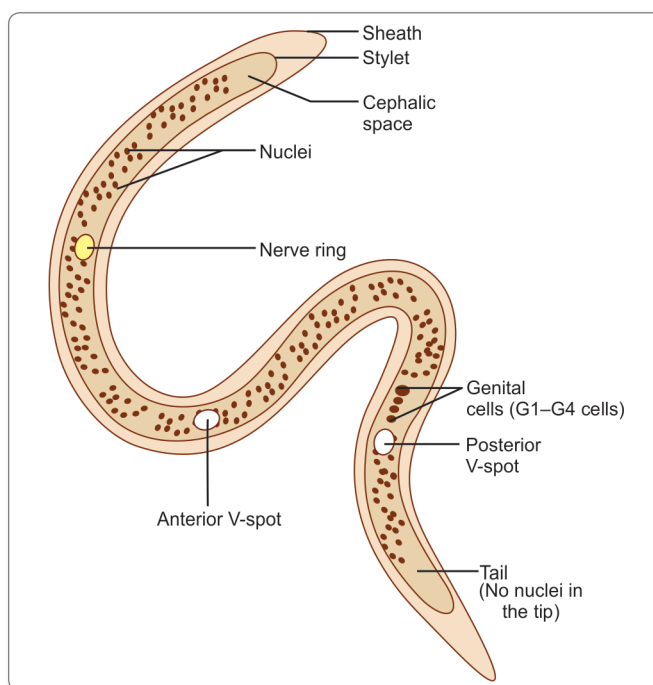


Fig. 21.4: Morphology of *Microfilaria bancrofti*

can be seen, which are called **somatic cells or nuclei**. The granules are absent at certain specific locations—a feature which helps in the identification of the species. The specific locations are as following (Fig. 21.4).

- At the head end is a clear space devoid of granules, called the **cephalic space**. In *Microfilaria bancrofti*, the cephalic space is as long as it is broad, while in *Microfilaria malayi*, it is longer than its breadth. With vital stains, a stylet can be demonstrated projecting from the cephalic space (Fig. 21.10).
 - In the anterior half of the microfilaria, is an oblique area devoid of granules called the **nerve ring**.
 - Approximately midway along the length of the microfilaria is the **anterior V-spot**, which represents the **rudimentary excretory system**.
 - The **posterior V-spot** (tail spot) represents the cloaca or anal pore.
 - The genital cells (**G-cells**) are situated anterior to the **anal pore**.
 - The **internal (central) body of Manson** extending from the anterior V-spot to G-cell 1, representing the **rudimentary alimentary system**.
 - The tail tip, devoid of nuclei in *Mf. bancrofti* (distinguishing feature), bears 2 distinct nuclei in *Mf. malayi* (Fig. 21.10).
- Microfilariae do not multiply or undergo any further development in the human body. If they are not taken up by a female vector mosquito, they die.
 - Their lifespan is believed to be about 2–3 months.
 - It is estimated that a microfilarial density of at least 15 per drop of blood is necessary for infecting mosquitoes.

Periodicity

- The microfilariae circulate in the blood stream.
- In India, China and many other Asian countries, they show a nocturnal periodicity in peripheral circulation; being seen in large numbers in peripheral blood only at night (between **10 pm** and **4 am**).
- This correlates with the night biting habit of the vector mosquito.
- Periodicity may also be related to the sleeping habits of the hosts. It has been reported that if the sleeping habits of the hosts are reversed over a period, the microfilariae change their periodicity from nocturnal to diurnal.
- Nocturnal periodic microfilariae are believed to spend the day time mainly in the capillaries of the lung and kidneys or in the heart and great vessels.
- In the Pacific islands and some parts of the Malaysian archipelago, the microfilariae are nonperiodic or diurnal subperiodic, such that they occur in peripheral circulation at all times, with a slight peak during the late

afternoon or evening. This is related to the day biting habits of the local vector mosquitoes. (Some authors separate the subperiodic Pacific type of *W. bancrofti* as a distinct species designated *W. pacifica*, but this is not widely accepted).

Life Cycle

W. bancrofti passes its life cycle in 2 hosts (Fig. 21.5).

Definitive host: Man. No animal host or reservoir is known for *W. bancrofti*.

Intermediate host: Female mosquito, of different species acts as vectors in different geographic areas. The major vector in India and most other parts of Asia is *Culex quinquefasciatus* (*C. fatigans*).

Infective form: Actively motile third-stage filariform larva is infective to man.

Mode of transmission: Humans get infection by bite of mosquito carrying filariform larva.

Development in Mosquito

When a vector mosquito feeds on a carrier, the microfilariae are taken in with the blood meal and reach the stomach of the mosquito.

- Within 2–6 hours, they cast off their sheaths (**exsheathing**), penetrate the stomach wall and within 4–17 hours migrate to the thoracic muscles where they undergo further development.
- During the next 2 days, they metamorphose into the **first-stage larva**, which is a **sausage-shaped** with a **spiky tail**, measuring 125–250 × 10–15 μm (Fig. 21.5).
- Within a week, it moults once or twice, increases in size and becomes the **second-stage larva**, measuring 225–325 × 15–30 μm (Fig. 21.5).
- In another week, it develops its internal structures and becomes the elongated **third-stage filariform larva**, measuring 1,500–2,000 × 15–25 μm. It is actively motile and is the **infective form** (Fig. 21.5).
- It enters the **proboscis sheath** of the mosquito, awaiting opportunity for infecting humans on whom the mosquito feeds.
- There is no multiplication of the microfilaria in the mosquito and 1 microfilaria develops into 1 infective larva only.
- The time taken from the entry of the microfilaria into the mosquito till the development of the infective third-stage larva located in its proboscis sheath, constitutes the **extrinsic incubation period**. Its duration varies with environmental factors such as temperature and humidity, as well as with the vector species. Under optimal conditions, its duration is 10–20 days.

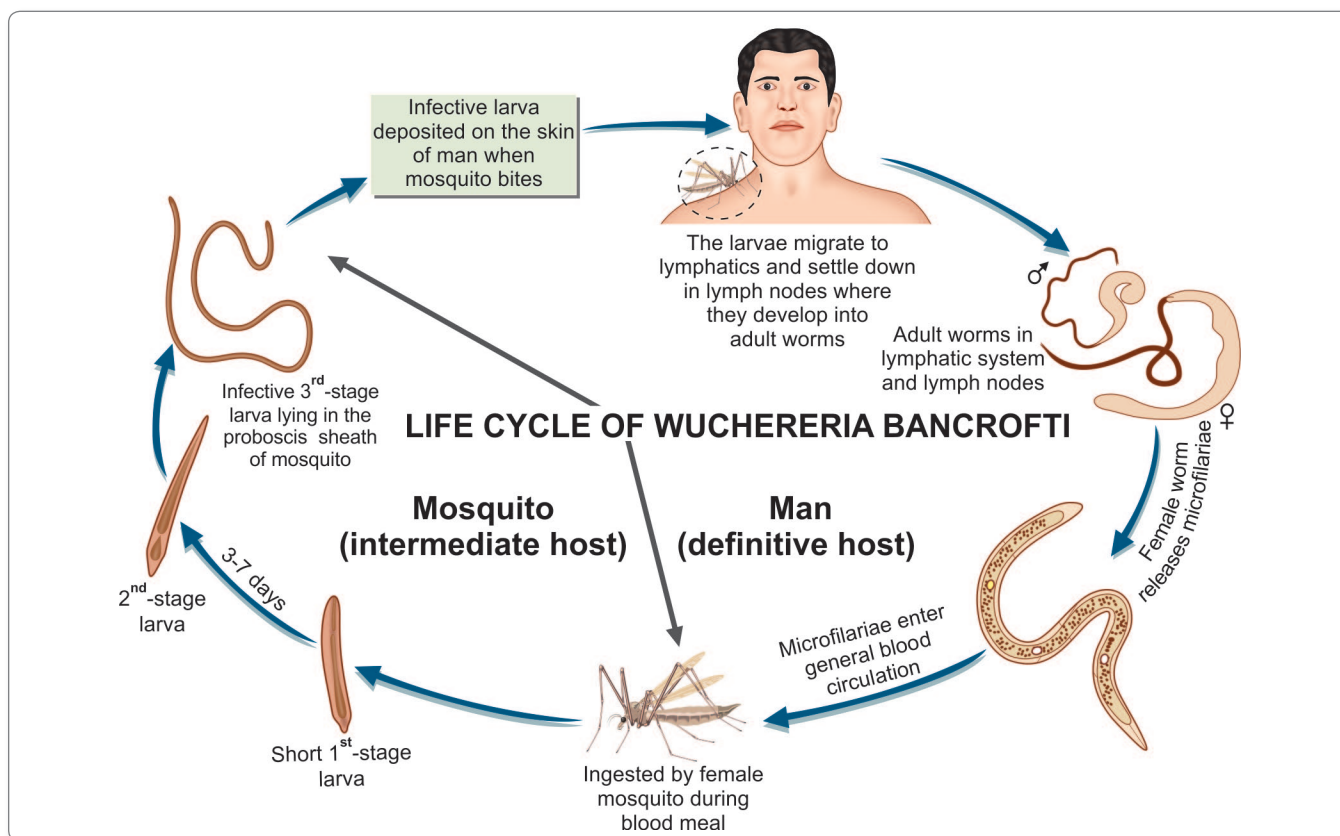


Fig. 21.5: Life cycle of *Wuchereria bancrofti*

- When a mosquito with infective larvae in its proboscis feeds on a person, the larvae get deposited, usually in pairs, on the skin near the puncture site.

Development in Man

The larvae enter through the puncture wound or penetrate the skin by themselves.

- The infective dose for man is not known, but many larvae fail to penetrate the skin by themselves and many more are destroyed in the tissues by immunological and other defence mechanisms. A very large number of infected mosquito bites are required to ensure transmission to man, perhaps as many as 15,000 infective bites per person.
- After penetrating the skin, the third-stage larvae enter the lymphatic vessels and are carried usually to abdominal or inguinal lymph nodes, where they develop into adult forms (Fig. 21.5).
- There is no multiplication at this stage and only 1 adult develops from 1 larva, male or female.
- They become sexually mature in about 6 months and mate.
- The gravid female worm releases large numbers of microfilariae, as many as 50,000 per day. They pass

through the thoracic duct and pulmonary capillaries to enter the peripheral circulation.

- The microfilariae are ingested with the blood meal by mosquito and the cycle is repeated.



Parasites with mosquito as Intermediate host

- *Wuchereria bancrofti*
- *Brugia spp.*
- *Mansonella spp.*
- *Dirofilaria spp.*

Prepatent period

The period from the entry of the infective third-stage larvae into the human host till the first appearance of microfilariae in circulation is called the **biological incubation period** or the **prepatent period**. This is usually about 8–12 months.

Clinical incubation period

The period from the entry of the infective larvae, till the development of the earliest clinical manifestation is called the **clinical incubation period**. This is very variable, but is usually 8–16 months, though it may often be much longer.

Table 21.3: Difference Between Classical and Occult Filariasis

	Classical filariasis	Occult filariasis
Cause	Due to adult and developing worms	Hypersensitivity to microfilarial antigen
Basic lesion	Lymphangitis, lymphadenitis	Eosinophilic granuloma formation
Organs involved	Lymphatic vessels and lymph node	Lymphatic system, lung, liver, spleen, joints
Microfilaria	Present in blood	Present in tissues but not in blood
Serological test	Complement fixation test not so sensitive	Complement fixation test highly sensitive
Therapeutic response	No response	Prompt response to DEC

Pathogenesis

Infection caused by *W. bancrofti* is termed as **wuchereriasis** or **bancroftian filariasis**.

The disease can present as (Table 21.3):

- Classical filariasis
- Occult filariasis.

Classical Filariasis

Pathogenesis

- It occurs due to blockage of lymph vessels and lymph nodes by the adult worms. The blockage could be due to **mechanical factors** or **allergic inflammatory reaction** to worm antigens and secretions. The affected lymph nodes and vessels are infiltrated with macrophages, eosinophils, lymphocytes, and plasma cells. The vessel walls get thickened and the lumen narrowed or occluded, leading to lymph stasis and dilatation of lymph vessels. The worms inside lymph nodes and vessels may cause granuloma formation, with subsequent scarring and even calcification. Inflammatory changes damage the valves in lymph vessels, further aggravating lymph stasis. Increased permeability of lymph vessel walls lead to leakage of protein-rich lymph into the tissues. This produces the typical hard pitting or brawny oedema of filariasis. Fibroblasts invade the oedematous tissues, laying down fibrous tissue, producing the non-pitting gross oedema of elephantiasis. Recurrent secondary bacterial infections cause further damage.
- Animal models have been developed, such as experimental filarial infection in cats with *brugia pahangi* or *Br. malayi*. These have helped in understanding the pathogenesis of the disease, but in cats and other

animals, filarial infection does not cause elephantiasis. Elephantiasis is a feature unique to human filariasis, apparently caused by human erect posture and consequent hydrodynamic factors affecting lymph flow.

Clinical manifestations: The most common presentations of lymphatic filariasis are asymptomatic (subclinical) microfilaremia, acute adenolymphangitis and chronic lymphatic disease.

- Most of the patients appear clinically asymptomatic but virtually all of them have subclinical disease including microscopic hematuria or proteinuria, dilated lymphatics (visualized by imaging) and in men with *W. bancrofti* infection, scrotal lymphangiectasia (detected by ultrasound).
- **ADL (acute adenolymphangitis)** is characterised by high fever, lymphatic inflammation (lymphangitis and lymphadenitis), and transient local edema.
 - Fever is of high grade, sudden in onset, associated with rigors and last for 2 or 3 days.
 - **Lymphangitis** is inflamed lymph vessels seen as red streaks underneath the skin. Lymphatics of the testes and spermatic cord are frequently involved, with epididymo-orchitis and funiculitis. Acute lymphangitis is usually caused by allergic or inflammatory reaction to filarial infection, but may often be associated with streptococcal infection also.
 - **Lymphadenitis:** Inflammation of lymph nodes. Most common affected lymph nodes being inguinal nodes followed by axillary nodes. The lymph nodes become enlarged, painful, and tender.
 - **Lymphedema:** This follows successive attacks of lymphangitis and usually starts as swelling around the ankle, spreading to the back of the foot and leg. It may also affect the arms, breast, scrotum, vulva, or any other part of body. Initially, the edema is pitting in nature, but in course of time, becomes hard and non-pitting.
 - **Lymphoangiovarix:** Dilatation of lymph vessels commonly occurs in the inguinal, scrotal, testicular, and abdominal sites.
 - The lymphangitis and lymphadenitis can involve both the upper and lower extremities in both bancroftian and brugian filariasis but involvement of genital lymphatics occurs exclusively with *W. bancrofti* infection. The genital involvement can be in the form of funiculitis, epididymitis, and hydrocele formation.
- **Hydrocoele:** This is a very common manifestation of filariasis. Accumulation of fluid occurs due to obstruction of lymph vessels of the spermatic cord and also by exudation from the inflamed testes and epididymis. The fluid is usually clear and straw colored but may sometimes

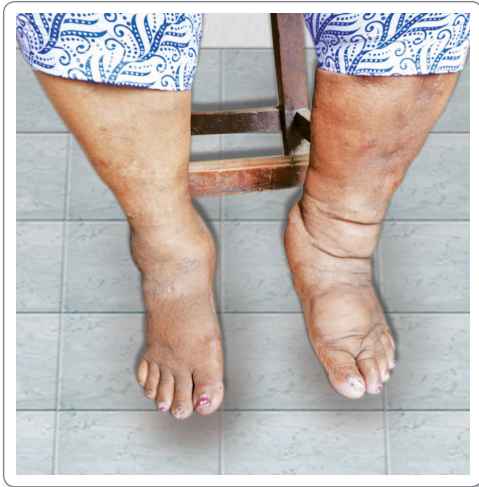

Fig. 21.6: Elephantiasis of the legs

be cloudy, milky, or hemorrhagic. The hydrocoele may be unilateral or bilateral and is generally small in size in the early stage, but may occasionally assume enormous proportions in association with elephantiasis of the scrotum. The largest reported hydrocoele weighed over 100 kilograms.

- **Lymphorrhagia:** Rupture of lymph varices leading to release of lymph or chyle and resulting in **chyluria** (Fig. 21.7), chylous diarrhea, chylous ascites, and chylothorax, depending on the involved site.
- **Elephantiasis:** This is a delayed sequel to repeated lymphangitis, obstruction and lymphedema. Repeated leakage of lymph into tissues first results in lymphedema, then to elephantiasis, in which there is non-pitting brawny edema with growth of new adventitious tissue and thickened skin, cracks, and fissures with secondary bacterial and fungal infections, commonly seen in leg but may also involve other parts of body (Fig. 21.6).

Occult Filariasis

- It occurs as a result of hypersensitivity reaction to microfilarial antigens, not directly due to lymphatic involvement.
- Microfilariae are not found in blood, as they are destroyed by the tissues.
- **Clinical manifestations:**
 - Massive eosinophilia (30–80%)
 - Hepatosplenomegaly
 - Pulmonary symptoms like dry nocturnal cough, dyspnea, and asthmatic wheezing.
 - Occult filariasis has also been reported to cause arthritis, glomerulonephritis, thrombophlebitis, tenosynovitis, etc.
 - Classical features of lymphatic filariasis are absent.

- **Meyers Kouwenaar syndrome** is a synonym for occult filariasis.
- **Tropical pulmonary eosinophilia:**
 - This is a manifestation of occult filariasis which presents with low-grade fever, loss of weight, and pulmonary symptoms such as dry nocturnal cough, dyspnea, and asthmatic wheezing.
 - Children and young adults are more commonly affected in areas of endemic filariasis including the Indian subcontinent.
 - There is a marked increase in **eosinophil count** (>3000 μm which may go up to 50,000 or more).
 - Chest X-ray shows mottled shadows similar to miliary tuberculosis.
 - It is associated with a high level of **serum IgE** and filarial antibodies.
 - Serological tests with filarial antigen are usually strongly positive.
 - The condition responds to treatment with diethyl-carbamazine (DEC), which acts on microfilariae.

Laboratory Diagnosis

The diagnosis of filariasis depends on the clinical features, history of exposure in endemic areas and on laboratory findings.

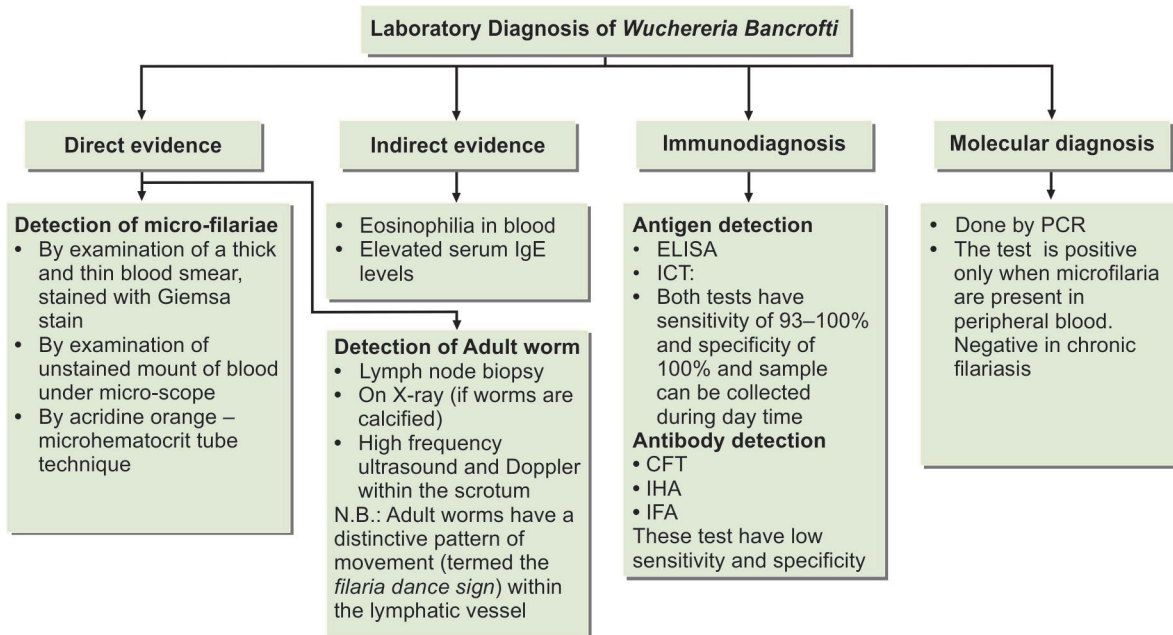
The laboratory tests (Flowchart 21.2) that can be used for diagnosis include the following.

Demonstration of Microfilaria

- Microfilaria can be demonstrated in blood, chylous urine (Fig. 21.7) exudate of lymph varix, and hydrocoele fluid. Peripheral blood is the specimen of choice.
- The method has the advantage that the species of the infecting filaria can be identified from the morphology of the microfilaria seen. It is also the method used for carrier surveys.



Fig. 21.7: Chylous urine



Flowchart 21.2: Laboratory diagnosis of *Wuchereria bancrofti*

- In India and other areas, where the prevalent filarial species is nocturnally periodic, it is best to collect 'night blood' samples between 10 pm and 4 am.
- Microfilaria can be demonstrated in unstained as well as stained preparations and in thick as well as thin smears (Fig. 21.8).
- By using a micropipette for taking a known quantity of blood (20–60 cu mm) for preparing the smear and counting the number of microfilariae in the entire stained smear, microfilaria counts can be obtained.

Unstained Film

- Examination under the low power microscope shows the actively motile microfilariae lashing the blood cells around.
- The timing of blood collection is critical and should be based on the periodicity of the microfilariae.
- The examination may be conveniently made the next morning as microfilariae retain their viability and motility for a day or two at room temperature.

Stained Film

A 'thick and thin' blood smear is prepared on a clean glass slide and dried.

- The thick part of the smear is dehemoglobinized by applying distilled water. The smear is fixed in methanol and stained with Giemsa, Leishman, or polychrome methylene blue stains. Microfilariae may be seen under the low power microscope in the thick film.
- The morphology of microfilariae can be studied in thin film. The microfilaria of *W. bancrofti* are sheathed and appear as smooth curves in stained smear and are 298 µm long and 7.5–10 µm in diameter (Fig. 21.8).

Concentration Techniques

When the microfilaria density is low, concentration techniques are used:

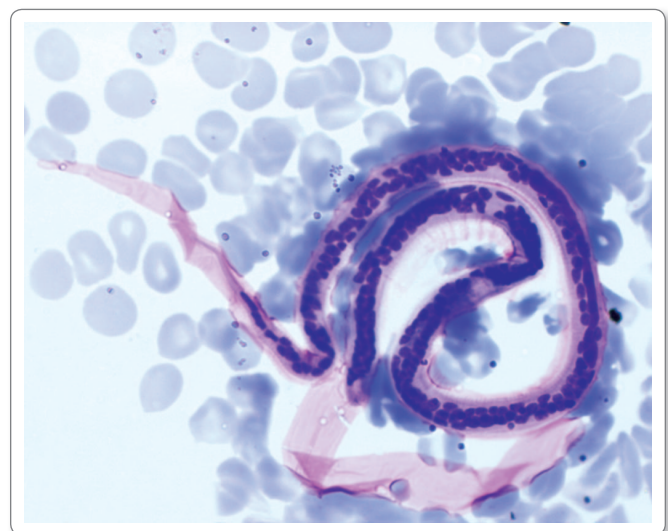


Fig. 21.8: Microfilaria in blood film.

Courtesy: Harsh Mohan, Textbook of Pathology, 6th ed. New Delhi: Jaypee Brothers, 2013(R), p. 190

- **Knott's concentration technique:** anticoagulated blood (1 mL) is placed in 9 mL of 2% formalin and centrifuged 500 × g for 1 minute. The sediment is spread on a slide to dry thoroughly. The slide is stained with Wright or Giemsa stain and examined microscopically for microfilariae.
- **Nucleopore filtration:** In the filtration methods used at present, larger volumes of blood, up to 5 mL, can be filtered through millipore or nucleopore membranes (3 μm diameter). The membranes may be examined as such or after staining, for microfilariae. The filter membrane technique is much more sensitive, so that blood can be collected even during day time for screening. The disadvantages of the technique are the cost and the need for venepuncture.
- **DEC provocation test:** A small dose of diethyl carbamazine (2 mg per kg body weight) induces microfilariae to appear in peripheral blood even during day time. For surveys, blood samples can be collected 20–50 minutes after the administration of one 100 mg tablet of DEC to adults.
- **Other specimens:** Microfilaria may be demonstrated in centrifuged deposits of lymph, hydrocele fluid, chylous urine or other appropriate specimens. Usually 10–20 mL of the first early morning urine is collected for examination and demonstration.



Parasites found in urine

- *Wuchereria bancrofti*
- *Schistosoma hematobium*
- *Trichomonas vaginalis*

Biopsy

Adult filarial worms can be seen in sections of biopsied lymph nodes, but this is not employed in routine diagnosis.

Skin Test

Intradermal injection of filarial antigens (extracts of microfilariae, adult worms, and third-stage larvae of *B. malayi* or of the dog filaria *Dirofilaria immitis*) induce an immediate hypersensitivity reaction. But the diagnostic value of the skin test is very limited due to the high rate of false-positive and negative reactions.

Imaging Techniques

Ultrasonography

High frequency ultrasonography (USG) of scrotum and female breast coupled with Doppler imaging may result

in identification of motile adult worm (**filaria dance sign**) within the dilated lymphatics.

- Adult worm may be visualized in the lymphatics of the spermatic cord in upto 80% of the infected men with microfilaria associated with *W. bancrofti*.

Radiology

- Dead and calcified worms can be detected occasionally by X-ray.
- In tropical pulmonary eosinophilia (TPE), chest X-ray shows mottled appearance resembling miliary tuberculosis.
- Intravenous urography, retrograde pyelography, lymphangiography, and lymphoscintigraphy may be used to demonstrate abnormal lymphatic urinary fistula.

Serodiagnosis

Demonstration of Antibody

Several serological tests, including complement fixation, indirect hemagglutination (IHA), indirect fluorescent antibody (IFA), immunodiffusion, and immunoenzyme tests have been described.

- But the tests available now are not sufficiently sensitive or specific to be used either for individual diagnosis or surveys.

Demonstration of Circulating Antigen

Highly sensitive and specific test for detection of specific circulating filarial antigen (CFA) have been developed for detection of recent bancroftian filariasis.

- The Trop bio test is a semiquantitative sandwich ELISA for detection of CFA in serum or plasma specimen.
- Immunochromatographic filariasis card test (ICT) is a new and rapid filarial antigen test that detects soluble *W. bancrofti* antigens using monoclonal antibody (ADIZ) in the serum of infected humans.
- Both assay have sensitivities of 93–100% and specificities approaching 100%.
- Specific IgG4 antibody against *W. bancrofti* antigen WbSXP-1 have been used to develop enzyme-linked immunosorbent assay (ELISA) for detecting circulating filarial antigen in sera of patients with filariasis.
- There is however, extensive cross reactivity between filarial antigens and antigens of other helminths, including intestinal round worm, thus interpretation of serological findings can be difficult.

Molecular Diagnostic Technique

Polymerase chain reaction (PCR) can detect filarial DNA from patient's blood, only when circulating microfilaria are present in peripheral blood but not in chronic carrier state.

- Usually the test provides sensitivities that are upto 10 fold greater than parasitic detection by direct examination and is 100% specific.

Indirect Evidences

Eosinophilia (5–15%) is a common finding in filariasis. Elevated serum IgE levels can also be seen.

Treatment

DEC is the drug of choice. It is given orally in a dose of 6 mg/kg body weight daily for a period of 12 days amounting to a total of 72 mg of DEC per kg of body weight. It has both macro- and micro-filaricidal properties. Following treatment with DEC severe allergic reaction (Mazzotti reaction) may occur due to death of microfilariae.

The administration of DEC can be carried out in 3 ways.

1. **Mass therapy:** In this approach, DEC is given to almost everyone in community irrespective of whether they have microfilaria disease manifestation or no signs of infection except those under 2 years of age, pregnant women, and seriously-ill patients. The dose recommended is 6 mg/kg body weight. In some countries it is used alone and in some, with albendazole or ivermectin. Mass therapy is indicated in highly endemic areas.
2. **Selective treatment:** DEC is given only to those who are microfilaria-positive. In India, the current strategy is based on detection and treatment of human carriers and filarial cases. The recommended dose in the Indian programme is DEC 6 mg/kg of body weight daily for 12 doses, to be completed in 2 weeks. In endemic areas, treatment must be repeated every 2 years.
3. **DEC medicated salts:** Common salt medicated with 1–4 g of DEC per kg has been used for filariasis control in Lakshadweep island, after an initial reduction in prevalence had been achieved by mass or selective treatment of microfilaria carriers.

Ivermectin: In doses of 200 µg/kg can kill the microfilariae but has no effect on adults. It is not used in India. It is used in regions of Africa.

Tetracyclines: Also have an effect in the treatment of filariasis by inhibiting endosymbiotic bacteria (*Wohlbachia* species) that are essential for the fertility of the worm.

Supportive Treatment

- Chronic condition may not be curable by antifilarial drugs and require other measures like elevation of the affected limb, use of elastic bandage, and local foot care reduce some of the symptoms of elephantiasis.
- Surgery is required for hydrocele.

- Medical management of chyluria includes bed rest, high protein diet with exclusion of fat, drug therapy with DEC, and use of abdominal binders.
- Surgical management of refractory case includes endoscopic sclerotherapy using silver nitrate.

Prophylaxis

The 2 major measures in prevention and control of filariasis are

- i. Eradication of the vector mosquito
- ii. Detection and treatment of carriers.

Eradication of Vector Mosquito

- **Antilarval measures:** The ideal method of vector control would be elimination of breeding places by providing adequate sanitation and underground waste water disposal system. However, this involves a lot of expenditure, hence current approach in India is to restrict the antilarval measures to urban areas by:
 - **Chemical control:** Using antilarval chemicals like,

Key points of *Wuchereria bancrofti*

- Adult worm is white, thread-like with smooth cuticle and tapering end.
- The female worm is viviparous. The embryo (microfilaria) is colorless, sheathed, with tail-tip free of nuclei, and actively motile.
- Microfilaria in blood shows nocturnal periodicity (10 pm to 4 am).
- **Definitive host:** Man.
- **Intermediate host:** *Culex quinquefasciatus* (*C. fatigans*).
- Microfilaria do not multiply in man. When taken up by vector mosquito, it undergoes stages of development and become 3rd stage filariform larva which is the **infective form**.
- **Pathogenesis:** Adult worm causes mechanical blockage of lymphatic system and allergic manifestations.
- **Clinical features:** Early stage—fever, malaise, urticaria, fugitive swelling, lymphangitis. Chronic stage—lymphadenitis, lymphangioma, chyluria, hydrocele, and elephantiasis. Tropical pulmonary eosinophilia occurs due to hypersensitivity reaction to filarial antigen.
- **Diagnosis:** Demonstration of microfilaria in peripheral blood or chylous urine. Demonstration of adult worm in biopsy, Doppler USG, and X-ray. Demonstration of filarial antigen and antibody.
- **Treatment:** Drug of choice is DEC and ivermectin. Supportive and surgical management in some cases.

- Mosquito larvicidal oil
- Pyrosene oil-E
- Organophosphorous larvicides like temephos, fenthion etc.
- Removal of Pistia plant: Mainly restricted to control of *Mansonia* mosquitoes leading to brugian filariasis.
- Antiadult measures: Adult mosquitoes can be restricted by use of DDT, dieldrin, and pyrethrum. However, vector mosquitoes of filariasis have become resistant to DDT, and dieldrin. Pyrethrum, as a space spray, is still being used.
- Personal prophylaxis: Using mosquito nets and mosquito repellants is the best method.

Detection and Treatment of Carriers

The recommended treatment is DEC 6 mg per kg body weight daily for 12 days, the drug being given for 2 weeks, 6 days in a week.

Brugia Malayi

History and Distribution

- The genus *Brugia* was named after **Brug**, who in 1927 described a new type of microfilaria in the blood of natives in Sumatra.
- The adult worm of *B. malayi* was described by Rao and Mapleson in India (1940).
- Besides *B. malayi*, the genus includes *B. timori*, which parasitizes humans in Timor, Indonesia and a number of animal species, such as *B. pahangi* and *B. patei* infecting dogs and cats.
- The geographical distribution of *B. malayi* is much more restricted than that of *W. bancrofti*. It occurs in India and far east, Indonesia, Philippines, Malaysia, Thailand, Vietnam, China, South Korea, and Japan.
- In **India**, Kerala is the largest endemic area, particularly the districts of Quilon, Alleppey, Kottayam, Ernakulam, and Trichur. Endemic pockets occur in Assam, Orissa, Madhya Pradesh, and West Bengal. *B. malayi* and *W. bancrofti* may be present together in the same endemic area, as in Kerala. In such places, *B. malayi* tends to be predominantly rural and *W. bancrofti* urban in distribution (Fig. 21.9).

Morphology

Adult Worms

- The adult worms of *B. malayi* are generally similar to those of *W. bancrofti*, though smaller in size.

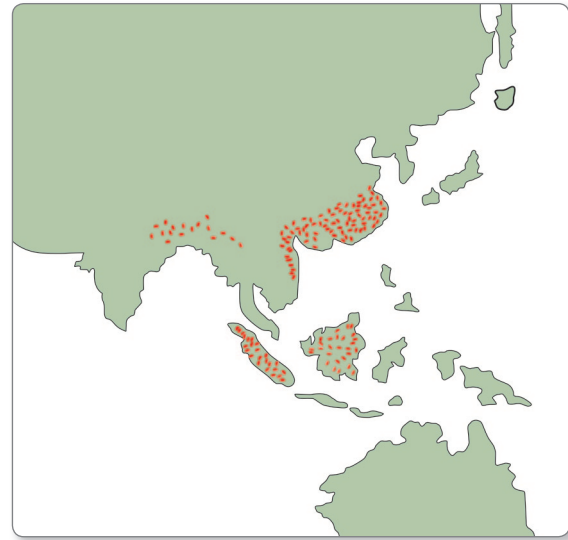


Fig. 21.9: Geographical distribution of *Brugia malayi*

Microfilariae

The microfilariae of *B. malayi*, although sheathed are different in a number of respects from *microfilaria bancrofti*.

- *Mf. malayi* is **smaller** in size; shows kinks and **secondary curves**; its cephalic space is **longer**; carries double stylets at the anterior end; the nuclear column appears blurred in Giemsa-stained films; and the tail tip carries **2 distinct nuclei**, one terminal and the other subterminal (Fig. 21.10 and table 21.4).

Table 21.4: Distinguishing Features of *Mf. bancrofti* and *Mf. malayi*

Features	<i>Mf. bancrofti</i>	<i>Mf. malayi</i>
Length	250–300 µm	175–230 µm
Appearance	Graceful, sweeping curves	Kinky, with secondary curves
Cephalic space	Length and breadth equal	Almost twice as long as broad
Stylet at anterior end	Single	Double
Excretory pore	Not prominent	Prominent
Nuclear column	Discrete nuclei	Blurred
Tail tip	Pointed; free of nuclei	2 distinct nuclei, are at tip, the other subterminal
Sheath	Faintly-stained	Well-stained

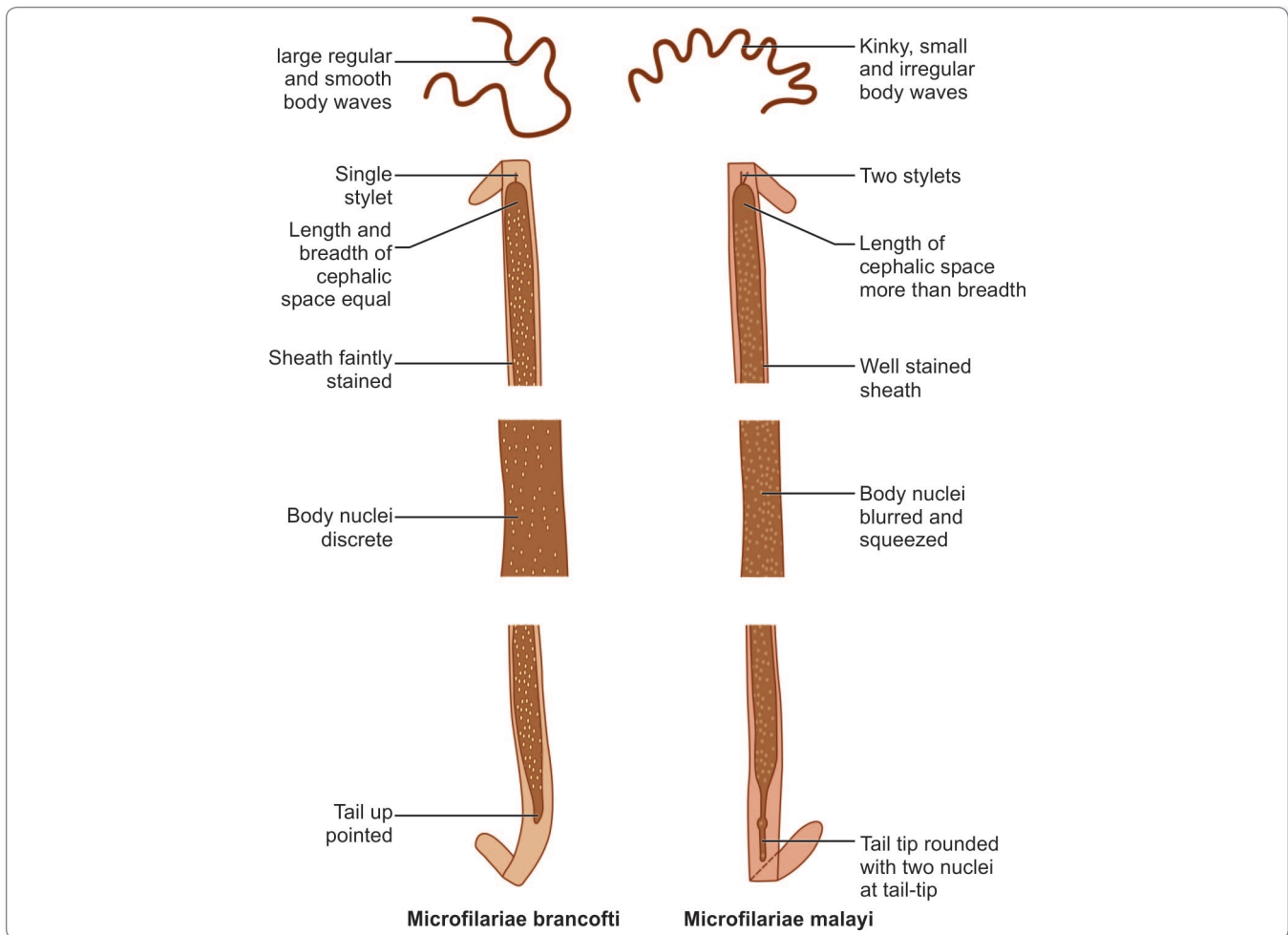


Fig. 21.10: Schematic diagram showing distinguishing features of *Microfilaria bancrofti* and *Microfilaria malayi*.

Life Cycle

The life cycle of *B. malayi* is similar to that of *W. bancrofti*; however, the intermediate host of *Brugia* are vectors of genera **Mansonia**, **Anopheles** and **Aedes**. In India, main vectors are *Mansonia annulifers* and *M. uniformis*.

- Pathogenicity, clinical features, laboratory diagnosis, and treatment are similar to *W. bancrofti*.
- **Prevention:** The breeding of *Mansonia* mosquito is associated with certain plants such as Pistia. In absence of these plants, mosquito cannot breed. Thus in countries like Sri Lanka and India where *M. annulifers* is the chief vector of *B. malayi*, the transmission of the parasite can be effectively reduced by removal of these plants in addition to the antilarval, antiadult, and self prophylaxis methods described in *W. bancrofti*.

Brugia Timori

B. timori is limited to Timor and some other islands of Eastern Indonesia.

- The vector of *B. timori* is *Anopheles barbirostris*, which breeds in rice fields and is a night feeder.
- **Definitive host:** Man. No animal reservoir is known.
- The microfilaria is larger than *Mf. malayi*. The sheath of *Mf. timori* fails to take Giemsa stain with 5–8 nuclei present in the tail.
- The lesions produced by *B. timori* are milder than those of bancroftian or malayan filariasis. A characteristic lesion is the development of draining abscesses caused by worms in lymph nodes and vessels along the saphenous vein, leading to scarring.

SUBCUTANEOUS FILARIASIS

Loa Loa

Common name: African eye worm

History and distribution

L. loa, causing loiasis, 'fugitive swellings' or 'calabar swellings', was first detected in the eye of a patient in West Indies in 1770. But at present, it is limited to its primary endemic areas in the forests of West and Central Africa, where about 10 million people are affected.

Morphology

Adult Worm

The adult worm is thin and transparent, measuring about 30–70 mm in length and 0.3–0.5 mm in thickness.

- In infected persons, they live in the subcutaneous tissues, through which they wander. They may also occur in the subconjunctival tissue.
- Adults live for 4–17 years.

Microfilaria

The microfilariae are **sheathed** with column of nuclei extending completely to the tip of the tail.

- They appear in peripheral circulation only during the day from 12 noon to 2 pm (**diurnal periodicity**).

Life cycle

Life cycle is completed in 2 hosts.

Definitive host: Man

Intermediate host or vectors: Day biting flies (mango flies) of the genus *Chrysops*, (*C. dimidiata*, *C. silacea*, and other species) in which the microfilariae develop into the **infective third-stage larvae**.

- Infection is transmitted to man through the bite of infected *Chrysops* during their blood meal.
- The infective third stage larvae enter the subcutaneous tissue, moult, and develop into mature adult worm over 6–12 months and migrate in subcutaneous tissues.
- Female worms produce sheathed microfilaria which have diurnal periodicity.
- The microfilaria are ingested by *Chrysops* during its blood meal.
- They cast off their sheaths, penetrate the stomach wall and reach thoracic muscles where they develop into infective larvae.

- Development in chrysops is completed in about 10 days.

Pathogenicity and Clinical Features

The pathogenesis of **loiasis** depends on the migratory habit of the adult worm.

- Their wanderings through subcutaneous tissues set up temporary foci of inflammation, which appear as swellings, of up to 3 cm in size, usually seen on the extremities. These are the **calabar swellings** or **fugitive swellings**, because they disappear in a few days, only to reappear elsewhere.
- Ocular manifestations occur when the worm reaches the subconjunctival tissues during its wanderings. The **ocular lesions** include **granulomata** in the bulbar conjunctiva, **painless edema** of the eyelids, and **proptosis**.
- Complications like nephropathy, encephalopathy, and cardiomyopathy can occur but are rare.

Laboratory Diagnosis

Diagnosis rests on the appearance of fugitive swelling in persons exposed to infection in endemic area.

- Definitive diagnosis requires the detection of microfilaria in peripheral blood or the isolation of the adult worm from the eye.
- Microfilariae may be shown in peripheral blood collected during the day.
- The adult worm can be demonstrated by removal from the skin or conjunctiva or from a subcutaneous biopsy specimen from a site of swelling.
- High eosinophil count is common.

Treatment

DEC (8–10 mg/kg per day for 21 days) is effective against both the adult and the microfilarial forms of *L. loa*, but requires multiple courses. It has to be used with caution as severe adverse reactions may develop following the sudden death of large numbers of microfilariae.

- Simultaneous administration of corticosteroids minimizes such reaction.
- Ivermectin or albendazole although not approved by food and drug administration (FDA) for this purpose, is effective in reducing microfilarial loads. Ivermectin is contraindicated in patients with heavy microfilariaemia (>5,000 microfilaria/mL).
- Treatment by surgical removal of the adult worms is rarely done.

Key points of *Loa loa*

- *Loa loa* is also known as African eye worm and causes loiasis.
- **Vectors:** Day-biting flies (*Chrysops*).
- Microfilaria are sheathed and nuclei extend upto tail tip.
- Microfilaria appears during the day (diurnal periodic).
- **Clinical features:** Subcutaneous swellings (calabar swellings), ocular granuloma, edema of eyelid, and proptosis.
- **Diagnosis:** Demonstration of adult worm from skin and conjunctiva. Demonstration of microfilaria in peripheral blood during day. High eosinophil count.
- **Treatment:** DEC with simultaneous administration of corticosteroid or other drugs which may be used. Ivermectin or albendazole.




Fig. 21.11: *Onchocerca volvulus*

Onchocerca Volvulus

History and Distribution

Onchocerca volvulus, the '**convoluted filaria**', or the '**blinding filaria**' producing onchocerciasis or '**river blindness**' was first described by Leuckart in 1893.

- It affects about 40 million people, mainly in tropical Africa, but also in Central and South America. A small focus of infection exists in Yemen and south Arabia.
- Onchocerciasis is the **second** major cause of blindness in the world.

Habitat

The adult worms are seen in nodules in subcutaneous connective tissue of infected persons.

Morphology

Adult worm

The adult worms are whitish, opalescent, with transverse striations on the cuticle (Fig. 21.11).

- The **posterior end** is curved, hence the name *Onchocerca*, which means '**curved tail**'.
- The male worm measures about 30 mm in length and 0.15 mm in thickness and the female measures 50 cm by 0.4 mm.

Microfilaria

The microfilariae are **unsheathed** and **non-periodic**.

- They measure about 300 by 0.8 μm .

- The microfilaria are found typically in the skin and subcutaneous lymphatics in the vicinity of parent worms.
- They may also be found in the conjunctiva and rarely in peripheral blood.

Life Cycle

Life cycle is completed in 2 hosts.

Definitive host: Humans are the only definitive host.

Intermediate hosts: Day-biting female black flies of the genus *Simulium* (black flies).

The vector *Simulium* species breed in '**fast-flowing rivers**'; and therefore, the disease is most common along the course of rivers. Hence, the name '**river blindness**'.

- The female black flies are 'pool feeders' and suck in blood and tissue fluids. Microfilariae from the skin and lymphatics are ingested and develop within the vector, becoming the infective third-stage larvae, which migrate to its mouth parts.
- The extrinsic incubation period is about 6 days. Infection is transmitted when an infected *Simulium* bites a person.
- The **prepatent period** in man is 3–15 months.
- The adult worm lives in the human host for about 15 years and the microfilariae for about 1 year.

Pathogenicity and Clinical Features

Pathogenesis depends on the host's allergic and inflammatory reactions to the adult worm and microfilariae.

- The infective larvae deposited in the skin by the bite of the vector develop at the site to adult worms. Adult worms are seen singly, in pairs, or in tangled masses in **subcutaneous tissues**. They may occur in the subcutaneous nodules or free in the tissues.

- The **subcutaneous** nodule or **onchocercoma** is a circumscribed, firm, non-tender tumor, formed as a result of fibroblastic reaction around the worms. Nodules vary in size from a few mm to about 10 cm. They tend to occur over anatomical sites where the bones are superficial, such as the scalp, scapulae, ribs, elbows, iliac crest, sacrum, and knees. The nodules are painless and cause no trouble except for their unsightly appearance
- Microfilariae cause lesions in the skin and eyes.
 - The skin lesion is a dermatitis with pruritus, pigmentation, atrophy, and fibrosis. In an immunologically hyperactive form of **onchodermatitis** called as **Sowdah**, the affected skin darkens as a result of intense inflammation, which occurs as result of clearing of microfilariae from blood
 - **Ocular** manifestations range from photophobia to gradual blurring of vision, progressing to total blindness. Lesions may develop in all parts of the eye. The most common early finding is conjunctivitis with photophobia. Other ocular lesions include punctate or sclerozing keratitis, iridocyclitis, secondary glaucoma, choroidoretinitis, and optic atrophy.

Laboratory Diagnosis

Microscopy

The microfilariae may be demonstrated by examination of **skin snip** from the area of maximal microfilarial density such as iliac crest or trapezius region, which is placed on a slide in water or saline. The specimen is best collected around midday. This method is specific and most accurate.

- Microfilariae may also be shown in **aspirated material** from subcutaneous nodules.
- In patients with ocular manifestations, microfilariae may be found in **conjunctival biopsies**.
- Adult worms can be detected in the biopsy material of the subcutaneous nodule.

Serology

Serological tests are useful for the diagnosis of cases in which microfilariae are not demonstrated in the skin.

- ELISA is more sensitive than skin snip tests. The test detects antibodies against specific onchocercal antigen.
- A rapid card test using antigen OV16 to detect IgG4 in serum has been evaluated.

Molecular Diagnosis

PCR from skin snips is done in specialized laboratories and is highly sensitive and specific.

Prophylaxis

In 1974, World Health Organization (WHO) launched a control programme in West Africa using aerial larvicide for vector control and treatment of patients with ivermectin. This is believed to have prevented blindness in millions of children.

Treatment

- Chemotherapy with Ivermectin is the main stay of treatment. Ivermectin is given orally in a single dose of 150 µg/kg either yearly or semiannually. In areas of Africa coendemic for *O. volvulus* and *Loa loa*, however, ivermectin is contraindicated because of severe post treatment encephalopathy seen in patients.
- DEC and suramin have also been used. DEC destroys microfilariae, but usually causes an intense reaction (**Mazzotti reaction**) consisting of pruritus, rash, lymphadenopathy, fever, hypotension, and occasionally, eye damage.
- A 6 week course of doxycycline is macrofilaristatic, rendering the female worm sterile as it targets the wolbachia endosymbiont of filarial parasites.
- Surgical excision is recommended when nodules are located on the head due to the proximity of the worm to the eyes.

Key points of *Onchocerca volvulus*

- *O. volvulus*, produces onchocerciasis or 'river blindness'.
- The adult worm is white with transverse striation on the cuticle. The posterior end is curved.
- Microfilaria is unsheathed, tail-tip free of nuclei, and nonperiodic.
- **Definitive host:** Humans.
- **Intermediate host:** Female black flies (*Simulium*).
- **Clinical features:** Subcutaneous nodule formation (onchocercoma). Ocular manifestations – sclerosing keratitis, secondary glaucoma, optic atrophy, chorioretinitis. It is the second major cause of blindness in world.
- **Diagnosis:** Demonstration of microfilaria from skin snips and aspirated material from subcutaneous nodules. Demonstration of IgG4 antibody and PCR.
- **Treatment:** Ivermectin is the drug of choice except in areas coendemic for *O. volvulus* and *L. loa*.

Mansonella Streptocerca

Also known as *Acanthocheilonema*, *Dipetalonema*, or *Tetrapetalonema streptocerca*, this worm is seen only in West Africa.

- The adult worms live in the dermis, just under the skin surface.
 - The **unsheathed** microfilariae are found in the **skin**.
 - *Culicoides* species are the vectors.
 - Chimpanzees may act as reservoir hosts.
 - Infection may cause dermatitis with pruritus and hypopigmented macules.
 - Diagnosis is made by demonstration of the microfilariae in skin clippings.
 - Ivermectin (single dose of 150 µg/kg) is effective in treating **streptocerciasis**.
- Infection is generally asymptomatic, though it has been claimed that it causes transient abdominal pain, rashes, angioedema and malaise.
 - Diagnosis is by demonstration of the microfilariae in peripheral blood or serosal effusion.
 - Doxycycline (200 mg twice a day for 6 weeks) targeting the wolbachia endosymbiont in *M. perstans* is the first effective treatment.

SEROUS CAVITY FILARIASIS

Mansonella Ozzardi

M. ozzardi is a new world filaria seen only in Central and South America and the West Indies.

- The adult worms are found in the peritoneal and pleural cavities of humans.
- The nonperiodic **unsheathed** microfilariae are found in the blood.
- *Culicoides* species are the vectors.
- Infection does not cause any illness.
- Diagnosis is made by demonstrating microfilariae in blood
- Ivermectin (single dose 6 mg) is effective in treatment.

Mansonella Perstans

Also known as *Acanthocheilonema*, *Dipetalonema*, or *Tetra-petalonema perstans*, this worm is extensively distributed in tropical Africa and coastal South America.

- The adult worms live in the **body cavities** of humans, mainly in **peritoneum**, less often in **pleura**, and rarely in **pericardium**.
- The microfilariae are unsheathed and subperiodic.
- Vectors are *Culicoides* species.
- African primates have been reported to act as reservoir hosts.

Zoonotic Filariasis

Filariae naturally parasitic in domestic and wild animals may rarely cause accidental infection in man through the bite of their vectors.

- In such zoonotic filariasis, the infective larvae develop into adults, but do not mature to produce microfilariae.
- The worm dies and the inflammatory reaction around the dead worm usually causes clinical manifestations.

Brugia Pahangi

A parasite of dogs and cats in Malaysia may infect man and cause lymphangitis and lymphadenitis.

Dirofilaria Immitis

The dog '**heart-worm**' is a common parasite of dogs, widely distributed in the tropics and subtropics. When humans get infected, the worm lodges in the right heart or branches of the pulmonary artery. The dead worm becomes an embolus blocking a small branch of the pulmonary artery, producing a pulmonary infarct. The healed infarct may appear as a '**coin lesion**' on chest radiography and can be mistaken for malignancy.

Dirofilaria Repens

A natural parasite of dogs, it may sometimes infect humans, causing subcutaneous and subconjunctival nodules. Many *Dirofilaria* species may form nodules in human conjunctiva and are collectively called '*Dirofilaria conjunctivae*.'

Review Questions

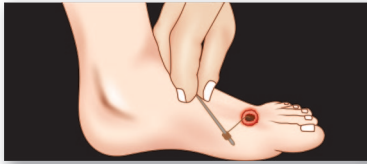
1. Name the species of filarial worms that infect humans and describe briefly the life cycle and laboratory diagnosis of *Wuchereria bancrofti*.
2. Short notes on:

(a) Microfilariae	(b) Periodicity of microfilariae
(c) Pathogenesis of lymphatic filariasis	(d) Tropical pulmonary eosinophilia
(e) Filariasis	(f) Preventive measures in filariasis
(g) <i>Brugia malayi</i>	(h) <i>Loa loa</i>
(i) <i>Onchocerca volvulus</i>	
3. Differentiate between:

(a) Occult and classical filariasis	(b) <i>Microfilaria bancrofti</i> and <i>microfilaria malayi</i>
-------------------------------------	--



Dracunculus Medinensis 22



Common name: Guinea Worm

History and Distribution

The guinea worm has been known from antiquity. It is believed to have been the '*fiery serpent*' in the Bible, which tormented the Israelites on the banks of the Red Sea.

- The technique of extracting the worm by twisting it on a stick, still practiced by patients in endemic areas is said to have been devised by Moses. The picture of the '*serpent worm*' on a stick may have given rise to the physician's symbol of caduceus.
- Galen named the disease **dracontiasis**, (Greek *draco-dragon or serpent*). Avicenna called it the *Medina worm* as it was prevalent there. Hence, the name *Dracunculus medinensis* (*Dracunculus* being the diminutive of *Draco*).

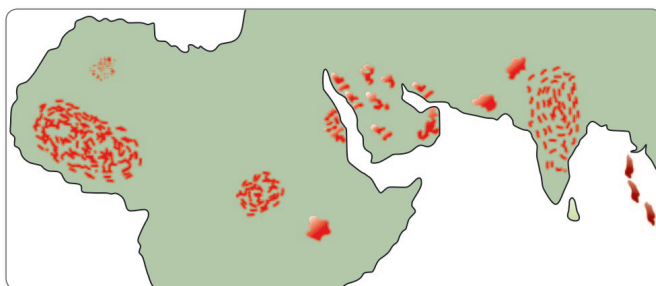


Fig. 22.1: Geographical distribution of *Dracunculus medinensis* infection (before its eradication)

- The worm was present in tropical Africa, the Middle-East in Arabia, Iraq, Iran, and in Pakistan and India. In **India**, it was seen in the dry areas in Rajasthan, Gujarat, Madhya Pradesh, Andhra Pradesh, Maharashtra, Tamil Nadu, and Karnataka (Fig. 22.1). About 50 million people were estimated to be infected with the worm.
- The infection has been **eradicated** from India and all of south-east Asia region by 2000.
- The disease still remains endemic in 13 African countries including Sudan (highest incidence), Niger, etc.

Habitat

The adult females of *D. medinensis* are usually found in the subcutaneous tissue of the legs, arms and back in man.

Morphology

Adult Worm

The adult female is a long, cylindrical worm with smooth milky-white cuticle resembling a long piece of white twine. It has a blunt anterior end and a tapering recurved tail (Fig. 22.2).

- It measures about a meter (60–120 cm) in length and 1–2 mm in thickness.
- The body of the gravid female is virtually filled with the branches of an enormous uterus, containing some 3 million embryos.



Fig. 22.2: Adult worm of *Dracunculus medinensis*

- The female worm is **viviparous**.
- The male worm, which is rarely seen, is much smaller than female being 10–40 mm long and 0.4 mm thick.
- Female worm survives for about an year, whereas life span of male worm is not more than 6 months.



Viviparous Nematodes

- *Dracunculus medinensis*
- *Trichinella spiralis*
- *Wuchereria bancrofti*
- *Brugia malayi*
- *Brugia timori*

Ovoviviparous Nematodes

- *Strongyloides stercoralis*

Larva

The larva measures 500–750 μm in length and 15–25 μm in breadth.

- It has a broad anterior end and a slender filiform tail which extends for a third of the entire body length (Fig. 22.3).
- The cuticle shows prominent striations.
- The larva swims about with a coiling and uncoiling motion.




Fig. 22.3: Larva of *Dracunculus medinensis*

Life Cycle

D. medinensis passes its life cycle in two hosts.

Definitive host: Man

Intermediate host: Cyclops, in which embryos undergo developmental changes. There is no animal reservoir.

Infective form: Third-stage larva present in the hemocele of infected cyclops.

- **Mode of transmission:** Humans get infected by drinking unfiltered water containing infected cyclops.
- **Incubation period:** About 1 year.
- The adult worm, which is viviparous discharges larvae, which are ingested by the **fresh water crustacean Cyclops**, the intermediate host.

Development of Adult Worm in Man

When water containing infected cyclops is swallowed by man, the cyclops is killed by the gastric acidity and the guinea worm larvae present in its hemocele are released.

- The larvae penetrate the wall of the duodenum and reach the retroperitoneal and subcutaneous connective tissues.
- Here, the larvae develop into male and female adults in about 3–4 months and mate.
- After mating, the male worms die in the tissues and sometimes become calcified.
- In another 6 months time, the fertilized female worm grows in size, matures, and migrates within the connective tissues throughout the body, to finally reach a site where it is likely to come into contact with water.
- The most common site involved is the leg, but other sites such as arms, shoulder, breast, buttocks, or genitalia may also be affected.

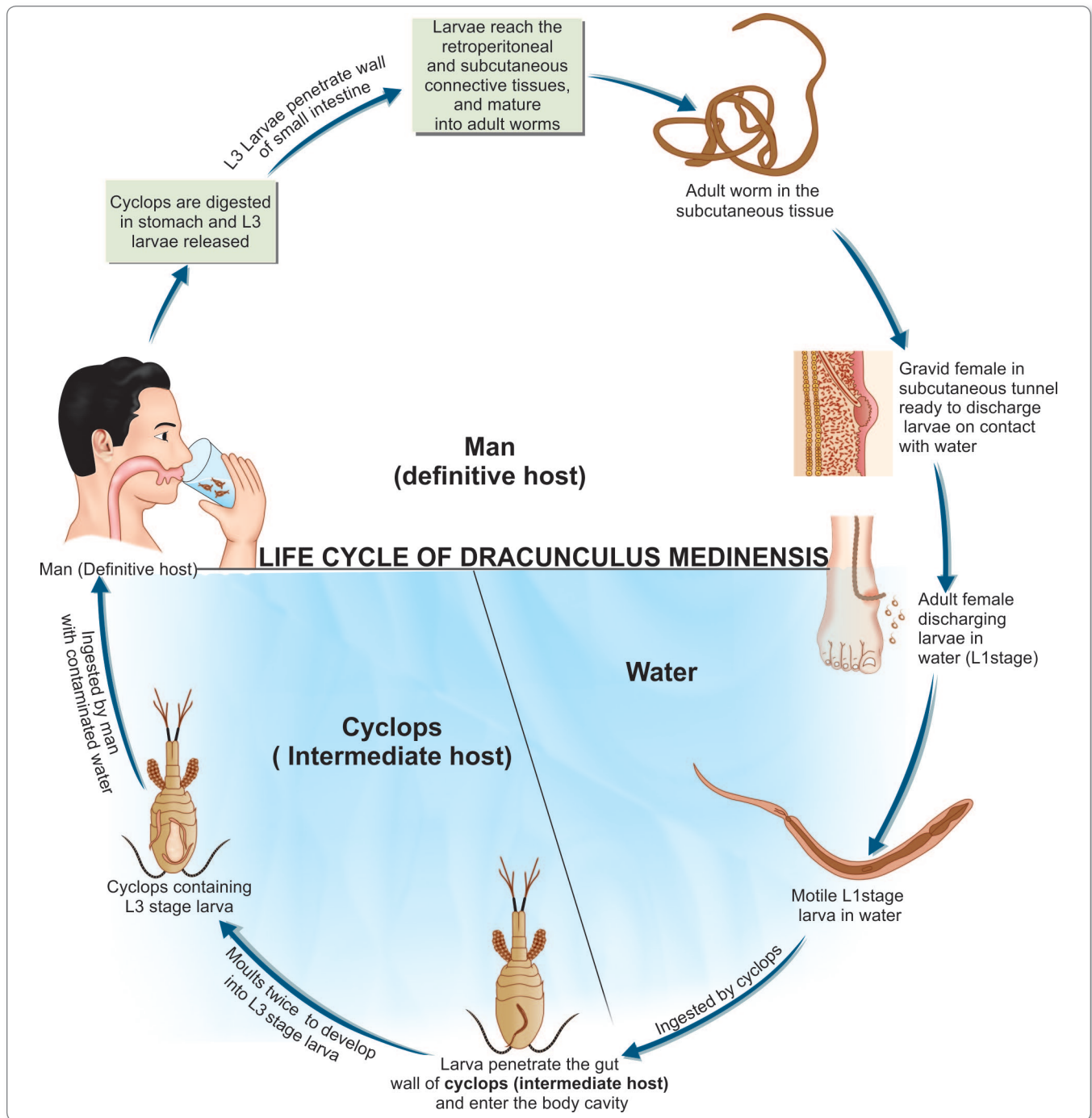


Fig. 22.4: Life cycle of *Dracunculus medinensis*

- At this site, it secretes a toxin that causes a **blister formation**, which eventually ruptures, discharging a milky-white fluid containing numerous L₁ stage larvae.
- This process continues for 2–3 weeks, till all the larvae are released.

Development of Larvae in Cyclops

The larvae swim about in water, where they survive for about a week.

- They are swallowed by the fresh water copepod **cyclops**, which is the **intermediate host** (Fig. 22.4).

- The larvae penetrate the gut wall of the cyclops and enter its body cavity, where they **moult twice**.
- In about **2–4 weeks**, they develop into the infective third-stage larvae (L₃).
- The entire life cycle takes about an year, so that all the infected persons develop the blisters and present with clinical manifestations at about the same time of the year (Fig. 22.4).

- **Skin test:** An intradermal test with guinea worm antigen elicits positive response.
- **Serological test:** Enzyme-linked immunosorbent assay (ELISA) and immunofluorescence assay (IFA) are frequently used to detected antibodies to *D. medinensis* (Flowchart 22.1).

Pathogenicity and Clinical Features

- D. medinensis* causes **dracunculiasis** or **dracunculosis**.
- Infection induces no illness till the gravid female worm comes to lie under the skin, ready to discharge its embryos.
 - The body fluid of the adult worm is **toxic** and leads to **blister formation**.
 - A few hours before the development of the blister, there may be constitutional symptoms such as nausea, vomiting, intense pruritus, and urticarial rash.
 - The blister develops initially as a reddish papule with a vesicular center and surrounding induration.
 - The most common sites for blister formation are the feet between the **metatarsal bones** or on the **ankles**.
 - The fluid in the blister is a **sterile yellowish liquid** with polymorphs, eosinophils, and mononuclear cells.
 - The local discomfort diminishes with the release of the embryos.
 - Secondary bacterial infection is frequent. Sometimes, it may lead to tetanus.
 - Sometimes, the worm travels to unusual sites such as the pericardium, the spinal canal, or the eyes, with serious effects.
 - **Dracunculiasis** lasts usually for 1–3 months.

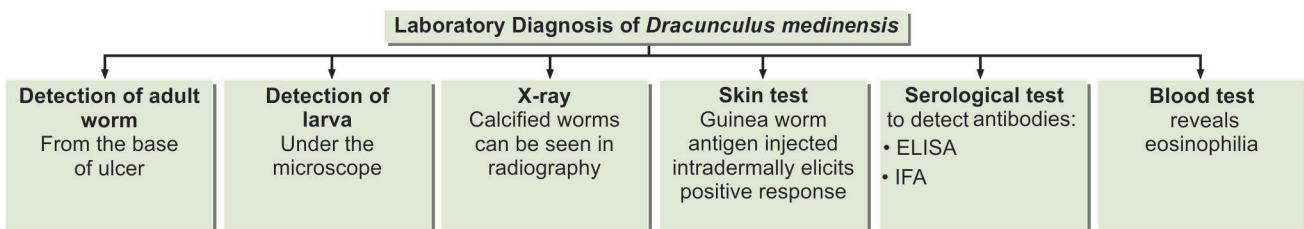
Treatment

- Antihistaminics and steroids are of help in the initial stage of allergic reaction.
- Metronidazole, niridazole, and thiabendazole are useful in treatment.

Parasites requiring one intermediate host to complete their life cycle	
Intermediate host	Parasite
• Man	<i>Plasmodium species</i> <i>Echinococcus granulosus</i> <i>Echinococcus multilocularis</i> <i>Taenia multiceps</i>
• Pig	<i>Taenia solium</i> <i>Taenia saginata asiatica</i> <i>Sarcocystis sui hominis</i> <i>Trichinella spiralis</i>
• Cow	<i>Taenia saginata</i> <i>Sarcocystis hominis</i>
• Snail	<i>Schistosoma species</i>
• Cyclops	<i>Dracunculus medinensis</i>
• Sandfly	<i>Leishmania species</i>
• Tsetse fly	<i>Trypanosoma species</i>
• Chrysops	<i>Loa loa</i>
• Mosquito	<i>Wuchereria bancrofti</i> <i>Brugia spp.</i> <i>Mansonella spp.</i> <i>Babesia species</i>
• Tick	<i>Trypanosoma cruzi</i>
• Triatomine bug	<i>Hymenolepis nana</i> <i>Hymenolepis diminuta</i>
• Flea	<i>Dipylidium caninum</i>

Laboratory Diagnosis

- **Detection of adult worm:** Diagnosis is evident when the tip of the worm projects from the base of the ulcer. Calcified worms can be seen by radiography.
- **Detection of larva:** By bathing the ulcer with water, the worm can be induced to release the embryos, which can be examined under the microscope.



Flowchart 22.1: Laboratory diagnosis of *Dracunculus medinensis*

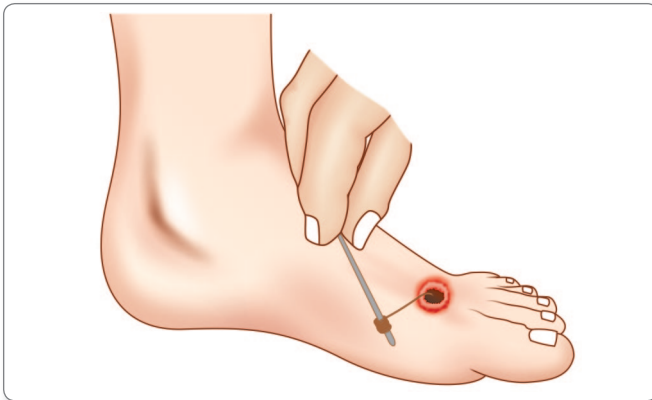


Fig. 22.5: Ancient technique of removing adult worm from blister

- For removal of the worm, the best method is the ancient technique of patiently twisting it around a stick. It may take 15-20 days to extract the whole worm but if care is taken not to snap the worm, this method is safe and effective (Fig. 22.5).
- Surgical removal of the worm under anaesthesia is another method of treatment.

Prophylaxis

- Provision of protected piped water supply is the best method of prevention or else Boiling or filtering water through a cloth and then consuming water.

- Destroying cyclops in water by chemical treatment with Abate (temephos).
- Not allowing infected persons to bathe or wade in sources of drinking water.

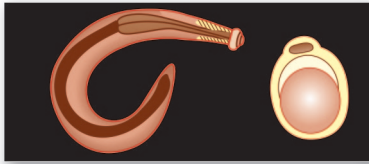
Note: Because of its simple life cycle, localized distribution, and the absence of animal reservoirs, guinea worm infection was eradicable. Measures to eliminate the infection have been successful. Global eradication of the infection is imminent.

Key points of *Dracunculus medinensis*

- Guinea worm infection has been eradicated from India.
- Adult females are found in subcutaneous tissue of man.
- Female worm is viviparous releasing thousands of motile first stage larvae into the water.
- **Definitive host:** Humans.
- **Intermediate host:** Cyclops, in which larvae undergo development changes to become third stage larvae.
- **Infective form to humans:** Cyclops containing L₃ larvae.
- **Clinical features:** Pruritus, urticarial rash, blister formation in skin, and cellulitis.
- **Diagnosis:** Detection of adult worm and larval form in ulcer. Demonstration of deadworm by X-ray. Serology—ELISA and IFA.
- **Treatment:** Antihistaminics and steroids in initial stage. Metronidazole and niridazole are useful. Surgical removal of the worm.

Review Questions

1. List viviparous nematodes and describe briefly the life cycle and laboratory diagnosis of *Dracunculus medinensis*.
2. Short notes on:
 - (a) Pathogenicity and clinical features of dracunculosis
 - (b) Tissue nematodes
 - (c) Prophylaxis of guineaworm infection



Miscellaneous Nematodes 23

Angiostrongylus Cantonensis

Common name: Rat lungworm

History and Distribution

A. cantonensis causes **eosinophilic meningoencephalitis (cerebral angiostrongyliasis)** in humans.

- This condition was first reported from Taiwan in 1945.
- Since then, hundreds of cases have occurred in Taiwan, Thailand, Indonesia, and the Pacific islands.
- Human infection has also been recorded in India, Egypt, Cuba, and the USA.

Habitat

The adult worm is present in the branches of pulmonary artery in rats.

Morphology

- It is about 20 mm long and 0.3 mm thick.
- Eggs of angiostrongylus resemble those of hookworms.

Life Cycle

Natural host: Rats.

Intermediate hosts: Molluscs, slugs, and snails.

Infective form: Third stage larvae.

- The eggs hatch in the lungs and the larvae which migrate up the trachea are swallowed and expelled in the feces.

- The larvae infect molluscs, slugs, and snails, which are the intermediate hosts. Crabs, fresh-water prawns, and frogs have also been found to be naturally infected.



Nematodes with Crabs and cray fishes as source of infection

- *Angiostrongylus cartonensis*
- *Paragonimus westermani*

- The larva undergoes two moults.
- In about 2 weeks, the infective third-stage larvae develop, which can survive in the body of the intermediate host for about an year.
- Rats become infected when they eat the molluscs.
- In the rat, the larvae penetrate the gut wall to enter the venules and are carried in circulation to the brain, where they develop into young adults in about a month.
- These penetrate the cerebral venules and reach the pulmonary artery, where they lodge, mature, and start laying eggs.
- **Human infection** is acquired by eating infected molluscs and other intermediate hosts containing the third-stage larvae. Infection may also occur through raw vegetables or water contaminated with the larvae.
- The larvae penetrate the gut and are carried to the brain, but they are unable to develop further.
- They die and induce an inflammatory reaction in the brain and meninges to produce **meningoencephalitis**.
- The incubation period is about 2–3 weeks.

Clinical Features

Patients present with intense headache, fever, neck stiffness, convulsions, and various degrees of pareses.

- The worm may also cause ocular complications.
- Infection does not seem to confer immunity, as second attacks have been recorded.
- Fatality is rare.

Diagnosis

Peripheral eosinophilia and high cerebrospinal fluid (CSF) eosinophilia (up to 90%) are constant features.

- Larvae and adult worms may be seen in CSF.



Parasites found in cerebrospinal fluid

Protozoa

- *Trypanosoma brucei* spp.
- *Naegleria fowleri*
- *Acanthamoeba* spp.

Helminths

- *Angiostrongylus cantonensis*

Treatment

Most cases recover spontaneously, only some develop residual pareses.

- **Anthelmintic** treatment is not recommended, as the disease is due to dead larvae.
- The drugs may even enhance the illness due to destruction of more larvae.

Note: *A. costaricensis*, inhabiting the mesenteric arteries of wild rodents in Costa Rica in Central America, may cause human infections. The disease presents as inflammation of the lower bowels and is known as *abdominal angiostrongyliasis*.

Capillaria Philippinensis

C. philippinensis is a small nematode, about 3–4 mm long. It belongs to the **superfamily** Trichuroidea.

History and Distribution

It has been responsible for several fatal cases of diarrheal illness in the Philippines from 1963.

- It has also been reported from Thailand, Japan, Iran, and Egypt.

Habitat

The adult worm inhabits the small intestine particularly the jejunum.

Life Cycle

Definitive host: Birds (Fish eating birds)

Intermediate host: Fish

- Its life cycle has not been worked out.
- Human infection is believed to occur by eating infected fish, which are the intermediate hosts harboring the infective larvae.
- **Autoinfection** is stated to be responsible for the high degree of infection in man.

Clinical Features

The clinical disease consists of malabsorption syndrome with severe diarrhea, borborygmi, and abdominal pain.

- Serious cases may be fatal in 2 weeks to 2 months.

Diagnosis

Diagnosis is made by detection of the eggs, larvae, and adults in stools. The eggs resemble those of *Trichuris trichiura*, but are smaller.

Treatment

Mebendazole is useful in treatment.

Note: *C. hepatica* is a common parasite of rats, which may occasionally infect man causing hepatitis that may be fatal.

Gnathostoma Spinigerum

History and Distribution

G. spinigerum, originally described from gastric tumors of a tiger, parasitizes dogs, cats, and their wild relatives.

- **Gnathostomiasis** is a zoonotic infection of man.
- Human infections have been reported from Thailand and other countries in the far east.
- Cases of human infection with *G. spinigerum* and a related species *G. hispidium* have also been reported from India.

Morphology

It is a small **spirurid nematode**. The female (25–55 mm) is longer than the male (10–25 mm).

- The eggs are oval, brown, unsegmented bearing a transparent knob like thickening at one end (Fig. 23.1).

Life Cycle

Definitive host: Dog, cat and other carnivorous animals

First intermediate host: Cyclops

Second intermediate host: Fresh water fish and frog

Paratenic host: Birds and humans

Helminths causing CNS infection

Cestodes

- *Taenia solium*
- *Taenia multiceps*
- *Spirometra* spp.
- *Echinococcus granulosus*
- *Echinococcus multilocularis*

Trematodes

- *Schistosoma japonicum*
- *Paragonimus westermani*

Nematodes

- *Trichinella spiralis*
- *Angiostrongylus cantonensis*
- *Toxocara canis*
- *Toxocara cati*
- *Gnathostoma spinigerum*
- *Strongyloides stercoralis*

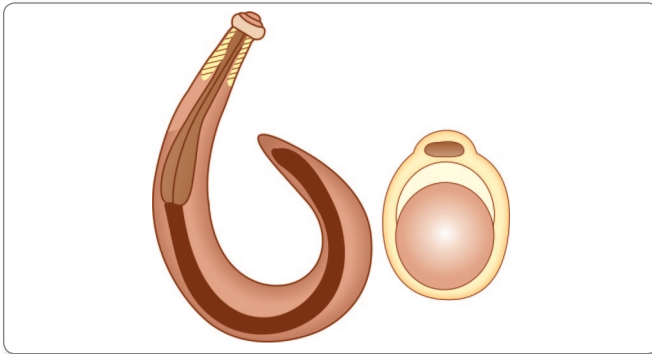


Fig. 23.1: Adult worm and egg of *Gnathostoma spinigerum*

- Adult worm resides in the tumors or granulomatous lesions of the stomach wall of cat and dog. Eggs are laid in the tumors.
- They pass into gastric lumen by means of an aperture and are discharged in feces into water, where they hatch into first stage larva.
- L₁ Larvae are ingested by Cyclops (**first intermediate host**) in which the **second-stage larvae** develop.
- Cyclops are eaten by fishes, frogs, and snakes, in which the **third-stage larvae develop** (L₃).
- When the third stage larvae are eaten by cats, dogs, or other suitable hosts, the larvae develop into adults inside their body.
- When other hosts that are not suited to be a definitive host (reptiles, birds or mammals) get infected, the larva does not undergo any further development and such a host is paratenic.
- Humans get infected by eating undercooked fish containing third stage larvae, but further development of the worm cannot proceed normally in **paratenic host**.
- The larvae migrate in the tissues of infected persons, causing **indurated nodules** or **abscesses** and **creeping eruption** (*larva migrans*).

Clinical Features

The migration of larvae in the tissues of the infected persons leads to indurated nodules or abscesses and creeping eruption.

- When the nodules are superficial, they can be incised and the larvae can be removed.
- The wandering larvae may reach the **brain** or eyes causing severe damage.

Diagnosis

An intradermal test using the larval or adult antigens has been described.

- The lesion can be biopsied and the presence of typical larva confirms the diagnosis.

Treatment

- Incision of the lesion and removal of larva.
- Albendazole, Mebendazole in high doses has also been recommended.

Anisakiasis

Anisakis species are nematode parasites of marine mammals like dolphins, seals, and whales.

Anisakiasis is common in Japan and other places where fresh or undertreated fish is a popular food.

Life Cycle

- The eggs are passed in sea water, hatch and infect marine **crustacea** (krill).
- Marine fish eats the infected krill and the infective larvae remain in the fish's viscera and flesh.
- When humans consume uncooked or improperly preserved fish containing the infective larvae, they penetrate the gut wall at the level of the throat, stomach, or intestine, leading to local inflammation and granuloma formation.

Clinical Features

- Local inflammation and granuloma formation is present at the level of throat, stomach, or intestine, depending on the level of penetration of gut wall.

? Parasites with fishes as the source of infection

Freshwater fish

- *Gnathostoma spinigerum*
- *Capillaria philippinensis*
- *Clonorchis sinensis*
- *Heterophyes heterophyes*
- *Metagonimus yokogawai*
- *Diphyllbothrium latum*

Marine fish

- *Anisakis simplex*

- The illness varies according to the site involved, such as throat irritation or acute gastric or bowel symptoms.

Treatment

Endoscopic surgical treatment of gastric and intestinal anisakiasis is the method of choice.


Prophylaxis

- Proper cooking of sea fish.

Review Questions

1. Short notes on:

- | | |
|--|-----------------------------------|
| (a) Anisakiasis | (b) <i>Gnathostoma spinigerum</i> |
| (c) <i>Angiostrongylus cantonensis</i> | (d) Paratenic host |



Diagnostic Methods in Parasitology 24

Introduction

Laboratory procedures play an important role in the diagnosis of parasitic infections, both for confirmation of clinical suspicion and for identifying unsuspected infections. The principles of laboratory diagnosis are the same as in bacterial and viral infections, but the relative importance of the different methods varies greatly.

- While isolation of the infecting agent and detection of specific antibodies are the major methods in bacteriology and virology, they are of much less importance in parasitology than morphological identification of the parasite by microscopy.
- Compared to bacteria and viruses, parasites are very large and possess distinctive shape and structure, which enables their specific diagnosis on morphological grounds.
- Due to their complex antigenic structure and extensive cross-reactions, serological diagnosis is of limited value in parasitic infections.
- Although many pathogenic parasites can be grown in laboratory cultures, this method is not suitable for routine diagnosis because of its relative insensitivity and the delay involved.
- Morphological diagnosis of parasites consists of **2 steps**—detection of the parasite or its parts in clinical samples and its identification
 - **Detection** depends on collection of the appropriate samples and their examination by suitable techniques

- **Identification** requires adequate skill and expertise in recognizing the parasite in its various stages and its differentiation from morphologically similar artefacts.

A description of the common diagnostic techniques in parasitology is given below.

Examination of Stool

Collection of Fresh Stool Specimen

- All stool specimens should be collected in a suitable, clean, wide mouthed container like a plastic container with a light fitting lid, waxed cardboard box, or match box.
- All fresh specimens should be handled carefully because each specimen represents a potential source of infectious material.
- The specimen should not be contaminated with water, urine, or disinfectants.

Liquid stools should be examined or preserved within 30 minutes of passage. Soft stools should be examined or preserved within 1 hour of passage and formed stool should be examined or preserved within 24 hours of passage.

- Normally passed stools are preferable, although samples obtained after purgative (sodium sulphate) or high saline enema may also be used.
- Examination of fresh specimens is necessary for observing motility of protozoan parasites
- Stool should be examined for its consistency, color, odor, and presence of blood or mucus.
- In some instances, parasites may be seen on gross inspection, as in the case of roundworm, pinworm, or tapeworm proglottids.

Microscopic Examination

- The microscope should be equipped with a **micrometer** eyepiece, as it is often essential to measure the size of parasites. For example, the differentiation between cysts of the pathogenic *Entamoeba histolytica* and the non-pathogenic *E.hartmanni* is based entirely on their sizes.
- Microscopy should also include contributory findings such as the presence of **Charcot-Leyden crystals** and **cellular exudates** such as pus cells, RBCs, and macrophages.
- For detection of parasites, it is best to employ a combination of methods, as different methods serve different purposes.
- The methods include examination of: (i) wet mounts, (ii) thick smears and, (iii) permanent stained preparations.
- Various concentration methods can be used to increase the sensitivity of microscopic examination.
- If there is a delay in examination, use of preservatives like formalin, sodium acetate, and polyvinyl alcohol is recommended.

Wet Mounts

- **Unstained wet film:** The unstained wet film is the standard preparation and is made by emulsifying a small quantity of stool in a drop of (0.85%) saline placed on a slide and applying a coverslip (22 mm × 22 mm) on top, avoiding air bubbles. A proper preparation should be just dense enough for newspaper print to be read through it. If the feces contains mucus, it is advisable to prepare films using the mucus part. The entire field under coverslip should be systematically examined with low power objective (10X) under low light intensity. Any suspicious object may then be examined with the high power objective.
- **Wet saline mounts:** Wet saline mounts are particularly useful for detecting live motile trophozoites of *E. histolytica*, *Balantidium coli*, and *Giardia lamblia*. Eggs of helminths are also readily seen. Rhabditiform larvae

of *Strongyloides stercoralis* are detected in freshly passed stool.

- **Eosin staining:** Eosin 1% aqueous solution, can be used for staining wet films. Eosin stains everything except living protoplasm. Trophozoites and cysts of protozoa, as well as helminth larvae and thin-walled eggs stand out as pearly-white objects against a pink background and can be easily detected. Chromatoid bodies and nuclei of amoebic cysts can be seen prominently. Eosin also indicates the viability of cysts; live cysts are unstained and dead ones are stained pink.
- **Iodine staining:** Iodine staining of wet mounts is another standard method of examination. Either Lugol's iodine diluted (5 g iodine, 10 g potassium iodide and 100 mL of distilled water) or Dobeil and O'Connor's iodine solution (1 g iodine, 2 g potassium iodide, and 50 mL of distilled water) are used. Iodine helps to confirm the identity of cysts, as it prominently stains the glycogen vacuoles and nuclei. Protozoan cyst stained with iodine show yellow-gold cytoplasm, brown glycogen material, and pale refractile nuclei.

Thick Smears

These are not useful for routine examination, but are valuable in surveys for intestinal helminth eggs.

The method described by Kato and Miura in 1954 is known as the **Kato thick smear technique**.

- About 50 mg stool is taken on a slide and covered with a special wettable cellophane coverslip soaked in glycerine containing aqueous malachite green.
- The preparation is left for about an hour at room temperature, during which the glycerine clears the stool, enabling the helminth eggs to be seen distinctly under low power magnification.
- **This method is however not useful for diagnosis of protozoa or helminth larvae.**

Permanent Stained Smears

Permanent stained smears are examined normally under oil immersion (100X) objective.

- Confirmation of the intestinal protozoan, both trophozoites and cysts, is the primary purpose of this technique.
- Helminthic eggs and larvae take up too much stain and usually cannot be identified.
- Permanent smear can be prepared with both fresh and polyvinyl alcohol preserved stool specimen.
- The 2 methods commonly used are the **iron-hematoxylin stain** and **Wheatley's trichrome stain**. The iron-hematoxylin is the older method, but is more difficult.

➤ Iron-hematoxylin stain

Procedure

- Fecal smear on a slide is fixed in **Schaudinn's solution** for 15 minutes and is immersed successively for 2–5 minutes in 70% alcohol, 70% alcohol containing a trace of iodine, and then 50% alcohol for 2–5 minutes.
- It is washed in water for 5–10 minutes and immersed in 2% aqueous ferric ammonium sulphate solution for 5–15 minutes
- It is again washed in water for 3–5 minutes and stained with 0.5% aqueous hematoxylin for 5–15 minutes
- It is washed for 2–5 minutes and differentiated in saturated aqueous solution of picric acid for 10–15 minutes
- It is then washed for 10–15 minutes and dehydrated by passing through increasing strengths of alcohol, cleared in toluene or xylol and mounted.

➤ Trichrome stain (Wheatley's method)

- The trichrome technique of Wheatley for stool specimens is a modification of Gomori's original staining procedure for tissue.
- It is a quicker and simpler method, which produces uniformly well-stained smears of the intestinal protozoa, human cells, yeast cells, and artefact material in about 45 minutes or less.

Procedure

- The smear is fixed in **Schaudinn's solution** and taken successively through alcohol, as above.
- Trichrome stain (chromotrope 2R, light green SF, phosphotungstic acid in glacial acetic acid, and distilled water) is then applied for 5–10 minutes, differentiated in acid-alcohol dehydrated, cleared, and mounted.

Reagents of Trichrome stain

Chromotrope 2R	0.6 g
Light green SF	9.3 g
Phosphotungstic acid	0.7 g
Acetic acid (glacial)	1.0 mL
Distilled water	100 mL

➤ Modified trichrome stain for Microsporidia

- This staining method is based on the fact that stain penetration of the microsporidial spore is very difficult, thus more dye is used in the chromotrope 2R than that routinely used to prepare Wheatley's modification of trichrome method and the staining time is much longer (90 minutes).

- Other staining techniques are used for special purpose. For example, modified acid-fast or Giemsa stain is employed for detection of oocysts of *Cryptosporidium* and *Isospora*.

➤ Modified Ziehl-Neelsen (acid-fast) stain (Hot method)

- Oocysts of *Cryptosporidium* and *Isospora* in fecal specimens may be difficult to detect, without special staining. Modified acid-fast stains are recommended to demonstrate these organisms.
- Application of heat to the carbol fuchsin assists in the staining and the use of a milder decolorizer (5% sulphuric acid) allows the organisms to retain more of their pink-red color.

➤ Kinyon's acid-fast stain (Cold method)

- *Cryptosporidium* and *Isospora* have been recognized as causes of severe diarrhea in immunocompromised hosts but can also cause diarrhea in immunocompetent hosts.
- Kinyon's acid-fast stains are recommended to demonstrate these organisms.
- Unlike the Ziehl-Neelsen modified acid-fast stain, Kinyon's stain does not require the heating of reagents for staining.

Reagents of Kinyon's acid-fast stain

- 50% ethanol (add 50 mL of absolute ethanol and 50 mL of distilled water)
- Kinyon's carbol fuchsin.
 - Solution A: Dissolve 4 g of basic fuchsin in 20 mL of 95% ethanol.
 - Solution B: Dissolve 8 g of phenol crystals in 100 mL of distilled water.
 - Mix solution A and B, and store at room temperature
- 1% sulphuric acid
- Alkaline methylene blue.
- Dissolve 0.3 g of methylene blue in 30 mL of 95% ethanol, and add 100 mL of dilute (0.01%) potassium hydroxide.

Procedure

- Smear 1–2 drops of specimen on the slide and allow it to air dry.
- Fix with absolute methanol for 1 minute.
- Flood the slide with Kinyon's carbol fuchsin and stain it for 5 minutes.
- Rinse the slide briefly (3–5 seconds) with 50% ethanol.
- Rinse the slide thoroughly with water.
- Decolorize by using 1% sulphuric acid for 2 minutes or until no more color runs from the slide.

- Rinse the slide with water (it may take less than 2 minutes; do not destain too much) and drain.
- Counterstain with methylene blue for 1 minute.
- Rinse the slide with water and air dry.
- Examine with the low or high dry objective. To see internal morphology, use the oil objective (100X).
- **Auramine O stain for Coccidia**
 - *Coccidia* are acid-fast organisms and also stain well with phenolized auramine O.
 - The size and typical appearance of *Cryptosporidium*, *Cyclospora*, and *Isoospora* oocysts enable auramine O-stained slides to be examined at low power under the 10X objective.
 - The entire sample area can usually be examined in less than 30 seconds.
 - The low cost of the reagents, the simple staining protocol, and the rapid microscopic examination also make this staining method suitable for screening unconcentrated stool specimens. Concentrated sediment from fresh or non-polyvinyl alcohol-preserved stool may also be used.

Concentration Methods

When the parasites are scanty in stools, routine microscopic examination may fail to detect them. It is then necessary to selectively concentrate the protozoan cysts and helminth eggs and larvae. Concentration may be done using fresh or preserved feces. Several concentration techniques have been described.

They can be classified as the floatation or sedimentation methods.

- In **floatation method**, the feces is suspended in a solution of high specific gravity, so that parasitic eggs and cysts float up and get concentrated at the surface.
- In **sedimentation method**, the feces is suspended in a solution with low specific gravity, so that the eggs and cysts get sedimented at the bottom, either spontaneously or by centrifugation.

Floatation Methods

➤ Saturated salt solution technique

Procedure

- A simple and popular method is salt-floatation using a saturated solution of sodium chloride, having a specific gravity of 1.2. About 2 mL of the salt solution is taken in a flat bottomed tube (or 'penicillin bottle') and 1 g of feces is emulsified in it.
- The container is then filled completely to the brim with the salt solution.
- A slide is placed on the container, so that it is in contact with the surface of the solution without

any intervening air bubbles. After standing for 20–30 minutes, the slide is removed, without jerking, reversed to bring the wet surface on top, and examined under the microscope.

- A coverslip need not to be applied if examination is done immediately. Any delay in examination may cause salt crystals to develop, interfering with clarity of vision.

This simple method is quite useful for detecting the eggs of the common nematodes such as roundworm, hookworms, and whipworm, but is not applicable for eggs of tapeworms, unfertilized egg of *Ascaris lumbricoides*, eggs of trematodes, and protozoan cysts.

➤ Zinc sulphate centrifugal floatation

Procedure

- Make a fine suspension of about 1 g of feces in 10 mL of water and strain through gauze to remove coarse particles.
- Collect the liquid in a small test tube and centrifuge for 1 minute at 2,500 revolutions per minute. Pour off the supernatant, add water, resuspend, and centrifuge in the same manner, repeating the process, till the supernatant is clear.
- Pour off the clear supernatant, add a small quantity of zinc sulphate solution (specific gravity 1.18–1.2), and resuspend the sediment well.
- Add zinc sulphate solution to a little below the brim and centrifuge at 2,500 revolution per minute for 1 minute (Fig. 24.1A).
- Take samples carefully from the surface, using a wire loop, transfer to slide, and examine under the microscope (Fig. 24.1B). A drop of dilute iodine helps to bring out the protozoan cysts in a better way.

This technique is useful for protozoan cysts and eggs of nematodes and small tapeworms, but it does not detect unfertilized roundworm eggs, nematode larvae, and eggs of most trematodes and large tapeworms.

➤ Sugar floatation technique

Sheather's sugar floatation technique is recommended for the detection of cryptosporidia infection.

Sedimentation Methods

➤ Formol-ether sedimentation technique

Formol-ether concentration method has been the most widely used sedimentation method (Fig. 24.1C).

Procedure

- Emulsify 1–2 g feces in 10 mL of water and let large particles sediment. Take the supernatant and spin at 2,500 revolutions per minute for 2–3 minutes.
- Discard the supernatant. Add 10% formol-saline, mix well, and let it stand for 10 minutes.

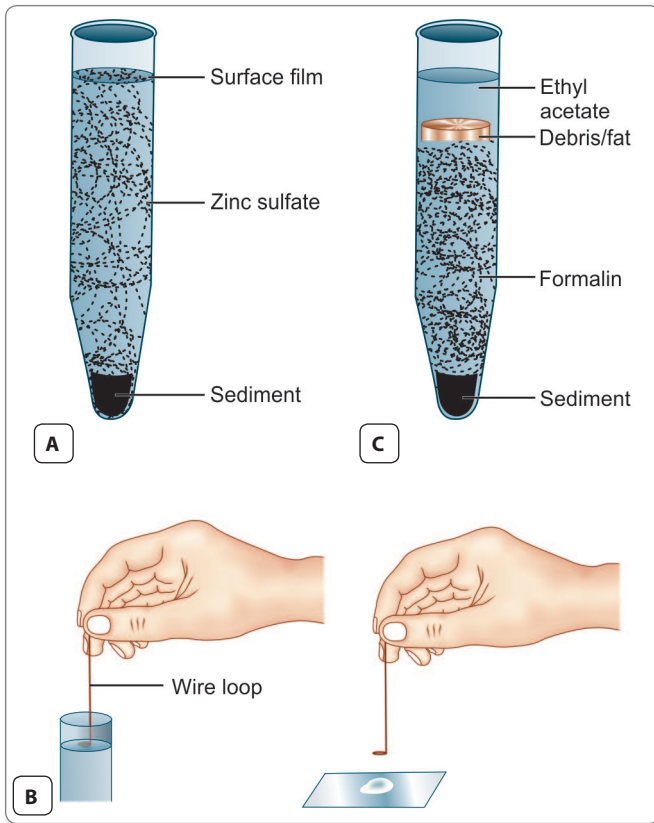


Fig. 24.1: A. Zinc sulfate floatation concentration technique; B. Method used to remove surface film in the zinc sulfate floatation concentration procedure; C. Formal ether sedimentation technique

- Add 3 mL ether and shake well. Spin at 2,500 revolutions per minute for 2–3 minutes. Four layers will form—a top layer of ether, a plug of debris at the interface, the formalin-saline layer, and the sediment at the bottom (Fig. 24.1C).
- Carefully detach the debris from the sides of the tube and discard the top 3 layers.
- Suspend the sediment in a few drops of fluid and examine wet mount and iodine preparation.
- As ether is inflammable and explosive, its use can be hazardous. Ethyl acetate can be conveniently used in its place, with equally good results.

The method is useful for all helminth eggs and protozoan cysts.

➤ **Baermann concentration method**
Procedure

- Another method of examination of stool specimen suspected of having small numbers of *Strongyloides* larvae is the use of a modified Baermann apparatus (Fig. 24.2).
- The Baermann technique, which involves using a funnel apparatus, relies on the principle that active

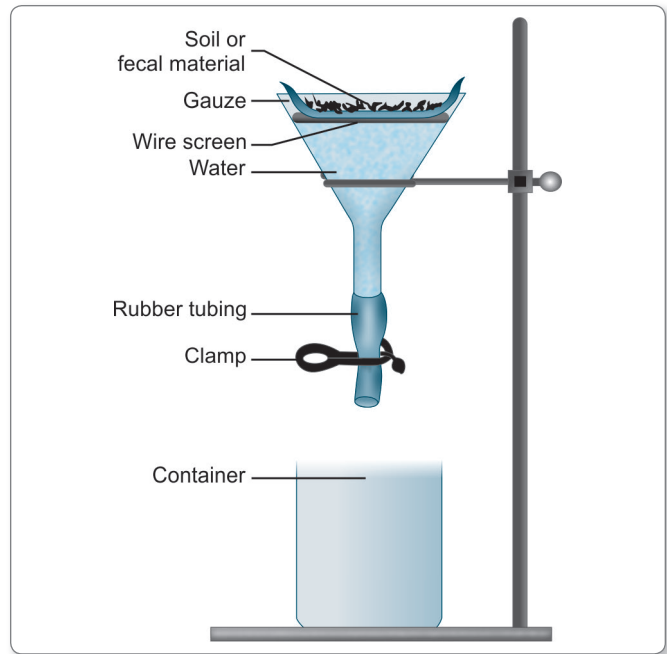


Fig. 24.2: Baermann concentration method

larvae migrate from a fresh fecal specimen that has been placed on a wire mesh with several layers of gauze, which are in contact with tap water.

- Larvae migrate through the gauze into the water and settle to the bottom of the funnel, where they can be collected and examined.
- Besides being used for patient’s stool specimens, this technique can be used to examine soil specimens for the presence of larvae.

Egg Counting Methods

A **semiquantitative assessment** of the worm burden can be made by estimating the number of eggs passed in stools. This is done by **egg counts** and by relating the counts to the number of worms present by assuming the number of eggs passed per worm per day.

However, these are at best approximations and only a rough indication of worm burden can be obtained. Egg counts help to classify helminth infections as heavy, moderate, or light. Egg counts can be done by different methods.

- The **standard wet mount** gives rough indication of the number of eggs. Ordinarily, 1–2 mg of feces is used for preparing a wet film and if all the eggs in the film are counted. The number of eggs per gram of feces can be assessed.
- The **modified Kato thick smear technique** using 50 mg of stool cleared by glycerine-soaked cellophane coverslip can be used for egg counting.

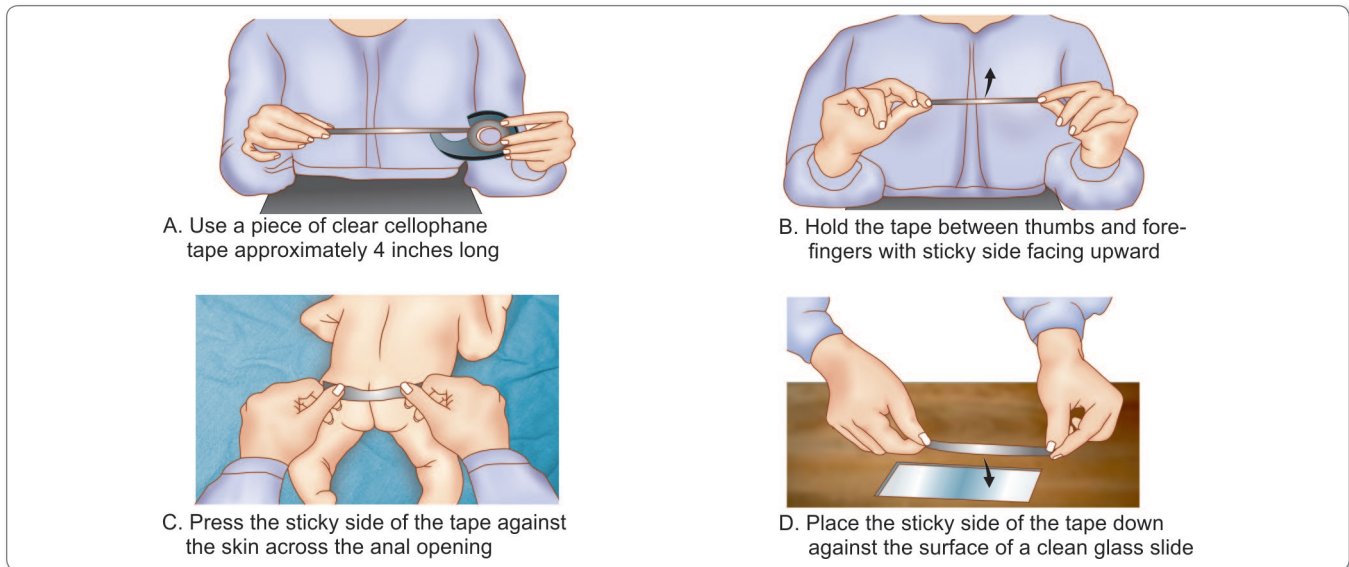


Fig. 24.3: Method for collection of a cellophane (Scotch) tape preparation for pinworm diagnosis. This method dispenses with the tongue depressor, requiring only tape and a glass microscope slide. The tape must be pressed deep into the anal crack

- **McMaster's egg counting** chamber can also be used. In this method, eggs in 20 mg of stool are concentrated by salt floatation on the squared grid on the roof of the chamber, which can be counted.
- In **Stoll's dilution technique**, 4 g of feces is mixed thoroughly with 56 mL of N/10 sodium hydroxide using beads in a rubber stoppered glass tube. Using a pipette, exactly 0.075 mL of the sample is transferred to a slide, coverglass is applied, and all the eggs present are counted. The number multiplied by 200 gives the number of eggs per gram of feces. This figure requires to be corrected for the consistency of feces, by multiplying by 1 for hard formed feces, by 2 for mushy formed feces, by 3 for loose stools, and by 4 for liquid stools. Watery stools are unfit for counting.
- Special techniques have been described for particular purposes as for example, **Bell's dilution-filtration count** for schistosome eggs.

Hatching test for *Schistosoma* eggs

This test is used to demonstrate the viability of the miracidia within the schistosome eggs recovered from the urine or stool. Fecal or urine specimens must be processed without any preservative. The specimens are placed in 10 volumes of dechlorinated or spring water. Living miracidia may be released by hatching within few hours. The specimens are examined microscopically for presence of miracidia, which indicates active infection.

➤ **Scotch tape method**

This is a simple and effective method for detection of eggs and female worms of *Enterobius vermicularis* and occasionally eggs of *Taenia solium*, *T. saginata*, and *Schistosoma mansoni*. In this method, a piece of transparent adhesive tape is pressed firmly against perianal skin, and the adhesive surface of the tape is spread on a glass slide (Fig. 24.3). The slide is then placed under microscope and observed for parasitic eggs. A drop of toluene or xylol may be placed between the tape and the slide to clear the preparation. The specimen should be collected for 3 consecutive days at night or early in the morning.

Fecal Culture

Fecal culture is not used for routine diagnosis, but for species identification, for example in differentiation between *Ancylostoma* and *Necator*.

Harada Mori Filter Paper Strip Culture

The test detects light infection with hookworm, *S. stercoralis*, *Trichostrongylus* spp., as well as to facilitate species identification of helminths.

The Harada-Mori culture method uses strips of filter paper on which feces is smeared in the middle third. The paper strips are kept in conical centrifuge tubes with water at the bottom, in which the strips dip (Fig. 24.4). The tubes are kept at room temperature in the dark for 7–10 days, during which time the larvae develop and fall into the water

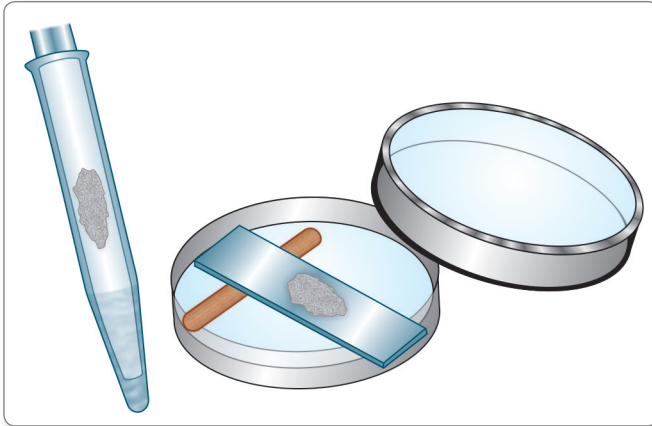


Fig. 24.4: Harada-Mori tube method and petri dish culture method

at the bottom, from which they can be collected. Also, caution must be exercised in handling the paper strip itself, since infective *Strongyloides* larvae may migrate upwards, as well as downwards on the paper strip.

Agar Plate Culture for *Strongyloides*

Agar plate cultures are used to recover larvae of *S. stercoralis* and appear to be more sensitive. Approximately, 2 g fecal specimens are inoculated onto agar plates. Then the plates are sealed with tape to prevent accidental infection and placed in room temperature for 2 days. In positive cases, larvae will crawl over the agar, making visible tracks over it. For further confirmation of larvae, the plates are examined microscopically.

Charcoal Culture

Charcoal cultures are simple and efficient. Softened feces is mixed with 5–10 parts of moistened charcoal granules and packed into a suitable container and kept covered. In 7–10 days, the larvae hatch out and come to the surface. They can be collected by applying a pad of soft cotton cloth on the surface for half an hour. The cloth is removed and kept upside down on a sedimentation flask, filled to the brim with warm water. The larvae fall to the bottom of the flask, while the charcoal particles remain on the cloth.

Examination of Blood

Next to feces, the largest number of parasites are found in blood. Blood examination is the routine diagnostic method in malaria, filariasis, African trypanosomiasis, and babesiosis. It is sometimes positive in Chagas' disease and rarely, in Kala-azar and toxoplasmosis. Blood examination is done in the following ways.

Examination for Malarial Parasites

The standard diagnostic method in malaria is the examination of stained blood films—both thin and thick smears.

Collection of Blood

For demonstration of malarial parasites, blood should be collected not during the peak of fever, but optimally several hours after it. Bouts of fever follow the synchronous rupture of large number of parasitised erythrocytes, releasing their membrane shreds and contents. The emerging merozoites parasitize other erythrocytes and initiate a fresh cycle of **erythrocytic schizogony**. The timing is particularly important in *P. falciparum* infections, as here the late stages of schizogony are not seen in peripheral circulation.

- In practice, the rule is to take a blood smear when a suspected malaria patient is first seen and then again subsequently after a bout of fever.
- Smears should invariably be collected before starting antimalarial treatment.

Thin smear

- A thin smear is prepared from finger prick or in infants from heel prick blood or ethylenediaminetetraacetic acid (EDTA) anticoagulated venous blood can also be used, provided blood films are made within 30 minutes.
- A small drop (**10–15 µL**) is spread on a clean **grease-free** slide with a spreader to give a uniform smear, ideally a single cell thick smear. The margins of the smear should be well short of the sides of the slide, and the tail should end a little beyond the center of its length.
- The thin smear displays blood cells and parasites clearly. Its only disadvantage is that only a small volume of blood can be surveyed, so that a light infection could be missed.
- If the smears are prepared from anticoagulated blood, which is more than an hour old, the morphology of both parasites and infected RBCs may not be typical.
- After drying, the smear is stained with Giemsa or Leishman stain.
- For **Giemsa stain**, the smear is fixed in methanol for 3–5 minutes. After drying, Giemsa stain, diluted 1 drop in 1 mL of buffered water, pH 7–7.2, is applied for 30–45 minutes. The slide is then flushed gently with tap water, dried, and examined under the oil immersion objective. The **cytoplasm** of malarial parasites is stained **blue** and the **chromatin dot** is stained **red**.
- For **Leishmans stain**, prior fixation is not necessary as the stain is an alcoholic solution, which fixes as it stains. Leishman stain is applied for 1–2 minutes and diluted with twice its volume of buffered water, pH 7–7.2 and is kept for 10–15 minutes. The smear is then dried and examined.

Reporting of thin blood films

- In malignant tertian malaria, only the ring stage and gametocytes are seen in peripheral smear, while in benign tertian malaria, all stages of schizogony and gametocytes can be seen.
- Thin smear examination enables the appreciation of changes in the erythrocytes, such as enlargement, alteration of shape, fimbriation, red cells stippling (**Schuffner's dots**) as seen with *P. vivax*, and irregular stippling (**Maurer's clefts**), as seen in mature *P. falciparum* trophozoites.
- Any marked increase in white cell numbers and if indicated perform a differential white cell count.
- Parasitized erythrocytes are seen most often in the upper and lower margins of the tail of the smear.
- Count the percentage of parasitized red cells, when there is high falciparum malaria parasitemia (+++ or more parasites seen in the thick film) to monitor a patient's response to treatment.
- A minimum of 100 fields should be examined before a negative report is given.

Thick smear

- Thick smears have the advantage that a larger quantity of blood can be tested. Increased volume of blood present on thick film may allow the malaria parasite to be detected even with low parasitemia. Compared with a thin film, a thick film is about **30 times** more sensitive and can detect about 20 parasites/ μL of blood.
- The disadvantages are that the red cells are lysed and the morphology of the parasites is distorted, so that species identification becomes difficult.
- A big drop of blood (20–30 μL) from finger or heel prick is collected on a clean grease-free slide and spread with the corner of another clean slide to form a uniformly thick smear of about 1 cm^2 . The thickness of the smear should be such that the hands of a wristwatch can be seen through it, but not the figures on the dial.
- The smear is dried in a horizontal position, kept covered from dust.
- Thick smears have to be dehemoglobinized before staining.
- They can be stained with **Giemsa or Leishmans stains** as described above. Wright's stain and JSB stain (so called because it was devised by Jaswant Singh and Bhattacharjee, in 1944) are very useful for staining large numbers of thick films as in malaria surveys.

Wright's stain consists of 2 solutions—

- Solution A contains methylene blue and azure B in phosphate buffer.

- Solution B contains eosin in phosphate buffer. The film is immersed in solution A for 5 seconds, washed in tap water, immersed in solution B for 5 seconds, washed, dried, and examined. Staining times may need adjustment. If the smear is too blue, stain longer in solution B; if too pink, in solution A.

JSB stain also consists of 2 solutions—

- i. The first contains methylene blue, potassium dichromate, sulphuric acid, potassium hydroxide, and water.
 - ii. The second solution is aqueous eosin.
- For staining, the smear is immersed in solution I for 10 seconds, washed for 2 seconds in acidulated water pH 6.2–6.6, stained in solution II for 1 second, washed in acidulated water, immersed again in solution I, and washed.

Reporting of thick blood films

- Select an area that is well stained and not too thick.
- Examine for malaria parasites and malaria pigment under oil immersion objective (100X).
- Examine at least 100 high power microscope fields for parasites.
- Report the approximate number of parasites (trophozoites, schizonts, and gametocytes) and also whether malaria pigment is present in white cells or not.
- The following plus sign scheme can be used to report parasite numbers.

Parasites

1–10 per 100 high power fields	+
11–10 per 100 high power fields	++
1–10 in every high power field	+++
More than 10 in every high power field	++++

Combined thick and thin blood films

- Combined thick and thin smears can be taken on the same slide.
- Draw a thick line with a glass-marking pencil on a slide, dividing it into 2 unequal parts. The thick smear is made on the smaller part and the thin smear drawn on the larger.
- Thick smear is first dehemoglobinized and the 2 are then stained together. An easy method is to add undiluted Leishman stain over the thin smear and then the diluted stain flooded over to the thick smear also.
- Do not allow the methanol to contact the thick film when fixing the thin film.
- The stained thin smear is examined first. If the thin smear is negative, the thick smear should be searched for parasites.

- When a slide is positive for malarial parasites, the report should indicate the species, the developmental stages found, and the density of parasites in the smear.

Examination for Microfilaria

Microfilariae may be detected in peripheral blood, both in unstained mounts and in stained smear.

Time of collection

In case of nocturnal periodic microfilariae, blood should be collected between 10 PM and 2 AM. In subperiodic nocturnal infection, the time of collection of blood should be between 8 PM and 10 PM and for subperiodic diurnal infection the time of collection should be ideally between 2 PM and 6 PM.

Wet Mount

- Two or three drops of blood are collected on a clean glass slide and mixed with 2 drops of water to lyse the red cells.
- The preparation is covered with a coverslip and sealed.
- The preparation is examined under the low power microscope for the motile microfilariae, which can be seen **wriggling** about, **swirling** the blood cells in their neighborhood.
- The examination may conveniently be deferred till next morning, as microfilariae retain their viability and motility for 1 or 2 days at room temperature.
- By using a simple counting chamber, microfilariae in the wet mount can be **counted**.

Stained Smears

- A thick smear is prepared as for malaria, dehemoglobinized, and stained with Leishman's, Giemsa, or Delafield's hematoxylin stains.
- Stained smears have the advantage that the morphology of microfilariae can be studied and species identification can be made. Thus, for differentiation between *Mf. bancrofti* and *Mf. malayi* stained smears are necessary.
- Sometimes, microfilariae may be seen in thin smears also.
- By using a measured quantity of blood for preparing smears, as for example with a 20 cubic mm pipette and counting the total number of microfilariae in the smear, microfilaria counts can be obtained. Multiplying the number of microfilariae in a 20 cubic mm smear by 50 gives the count per mL of blood.



Parasites found in peripheral blood film

Protozoa

- *Plasmodium* spp.
- *Babesia* spp.
- *Leishmania* spp.
- *Trypanosoma* spp.

Nematodes

- *Wuchereria bancrofti*
- *Brugia* spp.
- *Loa loa*
- *Mansonella ozzardi*

Concentration Methods

These methods have been developed to recover low numbers of microfilariae from blood and employ venous blood.

➤ Sedimentation method:

- In sedimentation method, the sample of blood is first lysed with acetic acid, saponin, or other lytic substance, or by freeze thawing, and then centrifuged.
- The sediment is stained and the microfilariae are counted.

➤ Membrane filtration concentration:

- In membrane filtration method, a measured quantity (1–5 mL) of blood is collected into an anticoagulant solution and passed through membrane filters fixed on syringes with Swinney filter holder. Blood cells and proteins sticking on to the filter are washed away by repeatedly passing saline through it.
- The filter is removed, placed on a slide, stained with dilute Giemsa stain, and examined under low power microscope for microfilariae.
- Millipore and nucleopore membrane filters (5 µm porosity) are available for this purpose; the latter being more sensitive, as it can screen larger volumes of blood.
- Membrane filtration recovers most species of microfilariae; however, because of their small size, *Mansonella perstans* and *M. ozzardi* may not be recovered. Membranes with smaller pores (3 µm) have been suggested to recover these 2 species.
- The membrane filter method is much more sensitive than the finger prick method as the blood samples are taken during day, it also give reliable results even with nocturnal periodic microfilariae.
- However, the method has the disadvantages that venepuncture is necessary, membranes are costly, and microfilariae may not be in a satisfactory condition for detailed morphological study.
- The number of microfilariae counted divided by 10 gives the number of microfilariae per mL of blood.
- This is the most sensitive method of detecting small numbers of microfilariae, but it is expensive for routine use.

- **Microhematocrit tube method:**
 - Capillary blood is collected in two heparanized capillary tubes or about 100 µL is first collected into EDTA anticoagulant and then transferred to plain capillary tubes.
 - The blood is centrifuged in a microhematocrit centrifuge.
 - The **buffy coat** is examined microscopically for motile microfilariae.
 - In areas where the species is known and *Mansonella* microfilariae are not found, this is a rapid technique for detecting microfilariae.
- **Buffy coat blood film:**
 - The buffy coat containing WBCs and platelets obtained after centrifugation of whole anticoagulated blood and the layer of RBCs just below the buffy coat layer, can be used to prepare thick and thin blood films in suspected infections with filaria, *Leishmania*, *Trypanosoma*, and malaria. The sensitivity of this method is much higher than that of routine thick film.

Diethylcarbamazine Provocation Test

Oral administration of diethylcarbamazine (DEC; 100 mg or 2 mg/kg of body weight) brings about mobilization of microfilariae into peripheral blood. Blood collected 20–50 minutes after the drug is given, will show microfilariae so that blood collection can be done during day time. This is a great advantage for surveys. But the drug may cause febrile reactions, particularly in brugianis. It cannot be used in areas endemic for onchocerciasis because of the danger of provoking severe reactions.

Sputum Examination

Sputum is examined commonly for the demonstration of eggs of *Paragonimus westermani*, and sometimes for detection of trophozoites of *E. histolytica* in amoebic pulmonary abscess. Rarerly, the larval stages of hookworm, *A. lumbricoides*, or *S. stercoralis* or the cestode hooklets may be seen in sputum samples.

- Concentrated stained preparations of induced sputum are commonly used to detect *P. jirovecii* and differentiate trophozoite and cyst forms from other possible causes of pneumonia, particularly in an acquired immunodeficiency syndrome (AIDS) patient.
- Normally, direct saline mount preparation is done for microscopy.
- If the sputum is thick, equal volume of 3% N-acetyl cysteine or 3% sodium hydroxide is added to the sputum to liquefy the specimen and after centrifugation, the sediment is examined for microscopic examination under low (10X) and high (40X) power magnifications.
- In a *Paragonimus* spp. infection, the sputum may be viscous and tinged with brownish flecks, which are clusters of eggs ('**iron filings**') and may be streaked with blood.



Parasites found in sputum

- *Paragonimus westermani*
- *Entamoeba histolytica* (trophozoites in case of pulmonary abscess)
- *Pneumocystis jirovecii*
- Rarely migrating larvae of *Ascaris lumbricoides*
- Rarely migrating larvae of *Strongyloides stercoralis*
- Rarely migrating larvae of *Ancylostoma duodenale*
- Rarely migrating larvae of *Nectar americanus*

Urine or Body Fluids Examination

- Large volume of urine samples should be allowed to settle for 1–2 hours.
- About 50 mL of the bottom sediment of the sample is taken for centrifugation.
- The highly concentrated sediment after centrifugation is examined for direct wet mount microscopy.
- May show eggs of *Schistosoma* and *Trichomonas vaginalis*. Microfilaria may be detected from chylous urine in lymphatic filariasis.

Tissue Biopsy

Tissue biopsies and fine needle aspirations are taken from cutaneous ulcers of trypanosomiasis or leishmaniasis and from skin nodules of onchocerciasis and post Kala-azar dermal leishmaniasis (PKDL).

- A **skin snip** can be obtained to diagnose subcutaneous filariasis or leishmaniasis by grasping with a forceps or elevating a portion of skin with the tip of needle. Tip of the small cone of the skin is then sliced with a sharp blade or razor.
- Wet mount preparation of lymphnode aspirate and chancre fluid are used as rapid methods for demonstration of trypanosomes.
- Biopsies from liver, spleen, bone marrow, and lymphnodes are taken in visceral leishmaniasis for demonstration of Leishman Donovan (LD) bodies.
- All biopsy tissues must be submitted to the laboratory without the addition of formalin fixative. If there is delay in transport or processing, the specimen should be

placed in polyvinyl alcohol fixative. In soft specimens, a small part should be scraped and examined as direct saline wet mount.

- **Impression smears** can be made from freshly cut tissue specimens on a glass slide and examined after fixation with Schaudinn's solution. Trichrome or other stains can be used.
- The residual part of the biopsy specimen may be processed for histopathological examination.
- Adult filarial worms can sometimes be found in section of biopsied lymphnode.
- Corneal scrapings are useful in diagnosis of *Acanthamoeba keratitis*.

Muscle Biopsy

Spiral larval form of *Trichinella spiralis*, larval form of *T. solium* (**cysticercus cellulosae**), and amastigote of *Trypanosoma cruzi* can be demonstrated in skeletal muscle biopsy. In trichinosis, muscle biopsy (gastrocnemius, deltoid, and biceps) specimen must be examined by compressing the tissue between 2 slides and checking the preparation under low power (10X) objective. This method does not become positive until 2–3 weeks after the illness.

Duodenal Capsule Technique (Enterotest)

Enterotest is a simple method of sampling duodenal contents.

- The device is composed of a length of nylon yarn coiled inside a gelatine capsule.
- The end of the yarn is affixed to the patient's face.
- The capsule is then swallowed and the gelatin dissolves in the stomach.
- The weighted string is carried into the duodenum by peristalsis.
- Bile-stained mucus is then retrieved after 3–4 hours and duodenal contents adherent to the yarn is scrapped off and examined under microscope as wet mount or as stained smear after preservation in formalin or polyvinyl alcohol.
- Usually 4–5 drops of material is obtained.
- Enterotest is used for detecting trophozoites of *Giardia*, larvae of *Strongyloides*, eggs of liver flukes, and oocysts of *Isospora*.

Sigmoidoscopy Material

Material obtained from sigmoidoscopy is useful in the diagnosis of *E. histolytica* that cannot be diagnosed by routine examination for at least 3 days.

- Material from the intestinal mucosa should be aspirated or scraped and not to be collected by cotton swabs.
- The material should be processed immediately.
- In heavy infection of *Trichuris*, sigmoidoscopy may show white bodies of the worms hanging from the inflamed mucosa of large intestine.

Urogenital Specimen

The detection of *T. vaginalis* is usually based on wet preparation of vaginal and urethral discharges and prostatic specimens. Specimens should be collected in small volume of 0.85% saline and should be sent immediately for detection of actively motile organisms, as the jerky movements of *Trichomonas* begin to diminish with time.

Culture Methods

Many parasites can now be grown in culture, but this has not become a routine diagnostic method in parasitic infections. It is sometimes employed for accurate identification of the parasite species. It is more often employed for obtaining large yields of the parasite as a source of antigen, animal inoculation, drug sensitivity testing, experimental or physiological studies, and teaching purposes. Some of the culture methods used for different parasites are indicated below.

? Parasites which can be cultured in the laboratory

- *Entamoeba histolytica*
- *Giardia lamblia*
- *Trichomonas vaginalis*
- *Leishmania* spp.
- *Trypanosoma* spp.
- *Acanthamoeba* spp.
- *Naegleria fowleri*
- *Balantidium coli*
- *Plasmodium* spp.

Amoeba

E. histolytica and other intestinal amoebae can be grown in diphasic or monophasic media, media containing other microorganisms, or axenic cultures.

- **Boeck and Drbohlav's diphasic medium**, the classical culture medium for amoeba has been modified by various workers.
 - The medium as used now, is basically an egg slant, with an overlay of sterile serum or liver extract in buffered saline.

- A loopful of sterile rice powder is added to the medium just before inoculation with fresh feces or its saline centrifugal sediment.
- Cultures can be obtained from feces containing cysts or trophozoites.
- The cultures are incubated at 37° C and subcultured at 48-hour intervals.
- Amoebae can be demonstrated in the liquid phase in unstained mounts or stained smears.

Composition of Boeck and Drbohlav's medium

Locke's solution

Sodium chloride: 9 g	Potassium chloride: 0.4 g
Calcium chloride: 0.2 g	Sodium bicarbonate: 0.2 g
Glucose: 2.5 g	Distilled water: 1,000 mL
Egg: 4 (clean and washed)	

- **Balamuth's monophasic liquid medium** is also used commonly for cultivation of amoebae and other intestinal protozoa. This is an egg yolk-liver extract infusion medium.

Composition of Balamuth's medium

Liver concentrate powder: 1 part
Egg yolk medium: 9 part
Phosphate buffer
Tribasic potassium phosphate: 212 g
Monobasic potassium: 136 g
Distilled water

- Both protozoa and bacteria present in stools grow in the above media.
- Bacterial growth can be reduced by addition of penicillin or other antibiotics that do not inhibit protozoa.
- Axenic cultures (pure cultures without bacteria or other microorganisms) were first developed by Diamond in 1961. Axenic cultivation has enabled precise antigenic and biochemical studies on amoebae.
- *B. coli* grows well in Balamuth's' medium. *G. lamblia* had been established in association with *Candida* and *Saccharomyces*, but axenic cultures were developed in 1970.
- *T. vaginalis* grows very well in several commercially available media such as trypticase serum media.
- *Naegleria* and *Acanthamoeba* from cerebrospinal fluid (CSF) can be grown on agar plates heavily seeded with *Escherichia coli*.

Leishmania and Trypanosomes

➤ NNN medium:

The classical **Nicolle, Novy, and Macneal (NNN) medium** first described in 1904 for cultivation of *Leishmania*, is equally satisfactory for trypanosomes also. This is a defibrinated rabbit blood agar medium. Several modifications of this medium have been introduced.

Composition of NNN medium

Bactoagar (Difco): 1.4 g
Sodium chloride: 0.6 g
Double distilled water: 90 mL
Defibrinated rabbit blood (10%): 10 mL

- Two bottles of culture are aseptically inoculated with 0.1 mL of specimen in each and incubated at 24°C for 4 weeks.
- The primary culture is examined every 4 days for promastigotes in leishmaniasis and for epimastigote stages in trypanosomiasis for upto 30 days.
- **Schneider's insect tissue culture medium:** It is recommended *in vitro* culture of *Leishmania*. This medium is said to be more sensitive than NNN medium.

Composition of Schneider's insect tissue culture medium

Schneider's <i>Drosophila</i> tissue culture medium: 80 mL
Fetal calf serum: 20 mL
Antibiotic-antimycotic solution: 1.2 mL

Malaria Parasites

- Cultivation of malaria parasites was first obtained by Bass and Jones in 1912. A simple method of cultivation is as follows.
 - About 10–12 mL of defibrinated or heparinized blood rich in ring forms of malaria parasite, mixed with 0.2 mL of 50% dextrose solution are incubated at 37°C in a sterile test tube in an upright position.
 - The blood separates into the erythrocytes below, plasma above, and the buffy coat in between.
 - Malaria parasites grow in the erythrocyte layer immediately below the buffy coat.
 - Smears are collected from this layer at intervals, without tilting the tube.
 - Segmented schizonts are usually observed after incubation for 24–36 hours.
- The breakthrough in cultivation of malarial parasites came in 1976 when Trager and Jensen successfully

maintained *P. falciparum* in continuous cultures in human erythrocytes using Roswell Park Memorial Institute (RPMI)1640 medium.

- The cultures are incubated at 38°C with 10% human serum at pH 6.8–7.2 under an atmosphere with 7% carbon dioxide and 1–5% oxygen.
- A continuous flow system is used in which the medium flows slowly and continuously over the layer of erythrocytes. The method has been applied to various species of plasmodia.
- It has been employed for preparation of antigens, drug sensitivity studies, vaccine tests, and many other purposes.

Animal Inoculation

Animal inoculation is not a routine diagnostic procedure in parasitic infections, but can be used in some instances because of its sensitivity .

- **Toxoplasmosis:** Animal inoculation can be used for isolating *Toxoplasma gondii* from infected persons. Lymphnode or other biopsy materials are inoculated intraperitoneally into immunosuppressed mice. Peritoneal fluid obtained 7–10 days later, may show the parasite in Giemsa-stained smears. However, serial passages may be necessary for its isolation. Brain smears may be examined for cysts after sacrificing the mice 3–4 weeks after inoculation. Seroconversion of the animal inoculation also indicates a positive result.
- **Visceral leishmaniasis:** Bone marrow, liver, spleen, or lymphnode aspirates from Kala-azar patients, injected intraperitoneally into hamsters is a very sensitive method for diagnosing visceral leishmaniasis. Even a single amastigote can establish the infection in the animal. Spleen smears taken 4–6 weeks later show LD bodies.
- **Trypanosomiasis:** Blood from patients with trypanosomiasis can be injected intraperitoneally or into the tail vein of mice, rats, and guinea pigs, etc. These animals are susceptible to infection by *T. brucei rhodesiense*. Parasitaemia can be demonstrated in 2 weeks.

Xenodiagnosis

This method involves the diagnostic infection of a vector, in which the parasite multiplies and can be demonstrated. In *T. cruzi*, diagnosis may be established by letting the vector reduviid bug feed on suspected patients. In 4–5 weeks, live flagellate forms can be seen in the feces of the bugs.

Immunological Diagnosis

Serology

Several serological tests have been developed for detection of antibodies to parasites using antigens from cultured parasites or from natural or experimental infections in animals or humans. In some cases, antigens are obtained from related parasites or even sometimes from bacteria. Advances in cultivation of parasites have made parasitic antigens more readily available. Cloning of parasitic antigens promises to be a new source.

In some instances, diagnosis is attempted by serological demonstration of parasitic antigens in blood, tissues, or secretions of suspected patients.

Virtually, all types of serological reactions have been used. However, serodiagnosis in parasitic infections has only limited value due to various factors.

- Parasites are complex antigenically and exhibit wide range of cross-reactions, so that serological tests are not sufficiently specific.
- Another difficulty is in distinguishing between past and current infections. This has been solved partly by looking for immunoglobulin (IgM) antibody, as in amoebiasis and toxoplasmosis.
- In general, indirect hemagglutination (IHA), enzyme-linked immunosorbent assay (ELISA), and counter immune electrophoresis (CIEP) are most sensitive; indirect immunofluorescence (IF), direct agglutination test (DAT) and complement fixation test (CFT) are moderately sensitive; and simple precipitation in gel and coated particle agglutination tests are least sensitive. Serology has not been very useful in the diagnosis of individual cases, but has been valuable as a screening method in epidemiological surveys. However, in some infections where parasites are seldom demonstrable in patients, for example in toxoplasmosis and hydatidosis, serology is of great help. Listed below are some of the applications of serology.

Amoebiasis

Serology is of no value in the diagnosis of acute amoebic dysentery or luminal amoebiasis. But in invasive amoebiasis, particularly in liver abscess, serology is very useful.

- **IHA is most widely employed.** Titers of 1:256 or more are significant in cases of amoebic liver abscess and have prognostic value.
- Tech Lab *E. histolytica* test was able to detect galactose lectin (**galnac**) antigen in almost all patients of amoebic liver abscess.

Giardiasis

ELISA and **indirect immunofluorescence test (IIF)** have been developed for detection of *Giardia*.

- Commercially available ELISA (ProSpec T/*Giardia*) Kit detects **Giardia-specific antigen 65 (GAS 65)**. The sensitivity of the test is 95% and specificity is 100%, when compared to conventional microscopy.

Trypanosomiasis

Serological tests used to detect trypanosomiasis are **IHA**, **indirect fluorescent antibody (IFA)**, and **ELISA**.

- Specific antibodies are detected by these tests in the serum within 2–3 weeks infection.
- Specific antibodies can be demonstrated by **IFA** and **ELISA** in **CSF**.

Leishmaniasis

IHA, **CIEP**, and **DOT-ELISA** are usually positive in Kala-azar.

- **Complement test using Witebsky Klingenstein, and Kuhn (WKK) antigen** from the acid-fast Kedrowsky bacillus are relatively less sensitive.
- IFA test is positive very early in the disease, even before the appearance of symptoms and becomes negative within 6 months of cure.
- **rK 39 micro ELISA test** is a qualitative immunochromatographic assay for detection of antibodies to *Leishmania*.

Malaria

IIF, **ELISA**, and **IHA** are sensitive and specific, but are not useful for diagnosis of acute malaria because antibodies persist for some years after cure.

- A negative test may, however help to exclude malaria.
- Serological tests are useful in epidemiological surveys for malaria.
- Molecular assays such as antigen capture for detection of **histidine-rich protein II (HRP-2)** and **lactate dehydrogenase (pLDH)** have been applied for developing rapid dip-stick tests (e.g. ParaSight-F in malignant tertian malaria).

Toxoplasmosis

Serological tests offer the most useful diagnostic method in toxoplasmosis.

- The original **Sabin-Feldman dye test**, though very specific and sensitive, is no longer in use. **IIF**, **IHA**, and **CFT** were other useful tests. The dye test remains positive for life, while CFT becomes negative soon after active infection.

- At present, **ELISA** is routinely used in *Toxoplasma* serology. It is very informative, as it provides titers of IgM and IgG antibodies separately for better interpretation of the results.

Cryptosporidiosis

IFA and **ELISA** using purified oocysts as antigens have been used to detect circulating antibodies specific to *Cryptosporidium parvum*.

Intestinal Helminths

Antibodies can be demonstrated in most intestinal helminthiasis, but extensive cross-reactions limit their use in diagnosis.

Trichinosis

Serology is very useful in diagnosis of trichinosis. **Bentonite flocculation slide tests** and **CFT** become positive 3–4 weeks after infection.

- **IIF** becomes positive even earlier.
- **ELISA** is also available. Demonstration of seroconversion is diagnostic.

Toxocariasis

High titers in serological tests are obtained in visceral larva migrans, but specificity is low due to cross-reactions with intestinal nematode antigens.

Filariasis

IHA and **bentonite flocculation tests** with antigen from *Dirofilaria immitis* gives positive reaction in patients, and high titers in tropical pulmonary eosinophilia. But cross-reactions are frequent.

- **Immunochromatographic filariasis card test (ICT)** is a new and rapid filarial antigen test that detects soluble *Wuchereria bancrofti* antigens in the serum of infected humans.

Echinococcosis

Several serological tests have been developed using hydatid fluid or scolex antigens from hydatid cysts in sheep. **IHA**, **IIF**, **CIEP**, and **ELISA** are very sensitive. Cross-reactions occur with cysticercosis.

Skin Tests

Intradermal tests have been used in many parasitic infections. They are sensitive and persist for many years, sometimes even for life. But specificity is relatively low.

- **Casoni's test:** This test had been used widely in the diagnosis of hydatid disease since its original description in 1911. The antigen is sterile hydatid fluid drawn from hydatid cysts from cattle, sheep, pig, or humans, filtered, and tested for sterility. Intradermal injection of 0.2 mL of the antigen induces a wheal and flare reaction within 20 minutes in positive cases. A saline control is used. False-positive tests are seen in schistosomiasis and some other conditions. Casoni's test is now largely replaced by serological tests.
- **Leishmanin (Montenegro) test:** This test is used to measure delayed hypersensitivity. *Leishmania* test is sensitive and relatively specific. The antigen is obtained from cultured *Leishmania* and consists of killed promastigotes in phenol saline. Intradermal injection of 0.1 mL induces a papule of 5 mm or more in diameter in 48–72 hours. This delayed hypersensitivity test is positive in cutaneous leishmaniasis and negative in diffuse cutaneous and visceral leishmaniasis.
- **Fairley's test:** This skin test is group-specific and gives positive results in all schistosomiasis. The intradermal allergic test uses antigen infected snails, cercariae, eggs, and adult schistosomes from experimentally infected laboratory animals.
- **Skin test in bancroftian filariasis:** Intradermal injection of filarial antigens (extracts of microfilariae, adult worms and third-stage larvae of *Brugia malayi*, or the dog filaria, *Dirofilaria immitis* induce an immediate hypersensitivity reaction, but the diagnostic value of the skin test is very limited due to the high rate of false-positive and negative reactions.

Molecular Methods

Nucleic acid-based diagnostic tests are mainly available in specialized or reference centers. Nucleic acid probes and amplification techniques like polymerase chain reaction (PCR) and multiplex PCR, western blot, and DNA hybridization techniques are increasingly used to detect parasites in specimens of blood, stool, or tissue from patients.

- These test are useful for detecting subspecies or stain level identification which is important for epidemiological studies and are also used to detect parasitic drug resistance. For example specific 17 KDA and 27 KDA sporozoite antigens are employed for seroepidemiological studies in cryptosporidiosis using western blot technique.
- DNA probe is a highly sensitive method for the diagnosis of malaria. It can detect even less than 10 parasite/ μ L of blood.
- B₁ gene of *T. gondii* can be detected by PCR of the amniotic fluid in case of congenital toxoplasmosis. PCR have been developed for detection of filarial DNA from patients blood. If parasite cannot be identified by microscopy, amplification of babesial 18S RNA by PCR is recommended.
- Drug resistances in malaria are detected now by PCR techniques. PCR is increasingly used now for species specification and for detection of drug resistance in malaria. Chloroquine resistance in *P. falciparum* has been attributed to mutation in the PfCRT, a transporter gene in the parasite. Point mutation in another gene PfMDR1 have also been implicated in determining resistance *in vitro*. Pyrimethamine and sulfadoxime resistances are associated with point mutations in DHFR and DHPS genes respectively. Mutation in PfATPase gene is associated with reduced susceptibility to artemisinin derivatives.

Review Questions

1. Enumerate the various methods employed for examination of stools and describe in detail the concentration methods of stool examination.
2. Describe various skin tests used for diagnosis in many parasitic infections.
3. Write short notes on:

<ul style="list-style-type: none"> (a) Scotch tape method (c) Blood examination for microfilaria (e) Casoni's test 	<ul style="list-style-type: none"> (b) Blood examination for malarial parasite (d) Enterotest (e) Floatation method of stool examination
---	---



Multiple Choice Questions

Chapter 1: General Introduction: Parasitology

1. Definitive host is one
 - a. In which sexual multiplication takes place and harbors adult form
 - b. In which asexual multiplication takes place and harbors adult form
 - c. In which sexual multiplication takes place and harbors larval form
 - d. In which asexual multiplication takes place and harbors adult form
2. Autoinfection is seen in all except
 - a. *Hymenolepis nana*
 - b. *Enterobius vermicularis*
 - c. *Taenia solium*
 - d. *Ascaris lumbricoides*
3. Antigenic variation is exhibited by
 - a. *Entamoeba*
 - b. *Schistosoma*
 - c. *Trypanosoma*
 - d. *Leishmania*
4. Which parasite enters, the body by piercing the skin
 - a. *Trichuris trichiura*
 - b. *Ascaris*
 - c. *Necator americanus*
 - d. *Plasmodium*
5. Which parasitic infection leads to malignancy
 - a. Babesiosis
 - b. *Clonorchis sinensis*
 - c. *Trypanosoma cruzi*
 - d. *Schistosoma hematobium*
6. Xenodiagnosis is useful in
 - a. *Wuchereria bancrofti*
 - b. *Trypanosoma cruzi*
 - c. *Trichinella spiralis*
 - d. All of the above
7. The following are zoonotic disease except
 - a. Leishmaniasis
 - b. Balantidiasis
 - c. Scabies
 - d. Taeniasis
8. Two hosts are required in
 - a. *Taenia solium*
 - b. *Entamoeba histolytica*
 - c. *Trichuris trichiura*
 - d. *Giardia*
9. Which of the following parasite passes its life cycle through three hosts
 - a. *Fasciola hepatica*
 - b. *Fasciola buski*
 - c. *Schistosoma hematobium*
 - d. *Clonorchis sinensis*
10. Man is the intermediate host for
 - a. *Stroglyoides stercoralis*
 - b. *Plasmodium vivax*
 - c. *Entamoeba histolytica*
 - d. *Enterobius vermicularis*

Answer

- | | | | |
|------|-------|------|------|
| 1. a | 2. d | 3. c | 4. c |
| 5. b | 6. d | 7. c | 8. a |
| 9. d | 10. b | | |

Chapter 2: Protozoa

1. Protozoa belong to kingdom
 - a. Monera
 - b. Protista
 - c. Plantae
 - d. Animalia
2. All are intercellular parasites except
 - a. Leishmania
 - b. Plasmodium
 - c. Toxoplasma
 - d. None of the above
3. Non-nuclear DNA present in addition to nucleus in protozoan parasite is
 - a. Chromatid body
 - b. Karyosome
 - c. Kinetoplast
 - d. Basal body
4. Entamoeba histolytica trophozoites multiply by
 - a. Binary fission
 - b. Schizogony
 - c. Gametogony
 - d. All of the above
5. In humans, malarial parasites multiply by
 - a. Binary fission
 - b. Budding
 - c. Gametogony
 - d. Schizogony
6. Which of the following is not a flagellate
 - a. Naegleria
 - b. Leishmania
 - c. Giardia
 - d. Dientamoebanj

Answer

- | | | | |
|------|------|------|------|
| 1. b | 2. d | 3. c | 4. a |
| 5. d | 6. a | | |

Chapter 3: Amoebae

1. The main reservoir of Entamoeba histolytica is
 - a. Man
 - b. Dirty water
 - c. Dog
 - d. Monkey
2. The infective form of Entamoeba histolytica is
 - a. Trophozoite
 - b. Binucleate cyst
 - c. Quadrinucleate
 - d. None of above
3. The pathogenicity of Entamoeba histolytica is indicated by
 - a. Zymodeme pattern
 - b. Size
 - c. Nuclear pattern
 - d. ELISA test
4. M/C site for extraintestinal amoebiasis is
 - a. Liver
 - b. Lung
 - c. Brain
 - d. Spleen
5. Amoebic liver abscess can be diagnosed by demonstrating
 - a. Cyst in the sterile pus
 - b. Trophozoites in the pus
 - c. Cyst in the intestine
 - d. Trophozoites in the feces
6. Stool of amoebic dysentery has all of the following characteristics except
 - a. Charcot-Leyden crystals
 - b. Pyknotic bodies
 - c. RBCs
 - d. Ghost cell
7. The term amoeboma is used to describe
 - a. Amoebic liver abscess
 - b. Skin lesion due to draining amoebic abscess
 - c. Granuloma at ileocaecal junction
 - d. None of the above

8. True statement regarding *Entamoeba histolytica* is
- The trophozoites are infective to man
 - Mature cyst has eccentric nucleolus
 - It can cause primary amoebic encephalitis
 - Cyst are resistant to chlorine concentration used in drinking water
9. All are nonpathogenic amoeba living in the lumen of large intestine except
- Entamoeba coli*
 - Entamoeba hartmanni*
 - Endolimax nana*
 - Entamoeba gingivalis*
10. Chronic amoebic keratitis is seen in
- Entamoeba histolytica*
 - Acanthamoeba*
 - Naegleria fowleri*
 - Hemoflagellates
11. Etiologic agent of granulomatous amoebic encephalitis is
- Entamoeba histolytica*
 - Acanthamoeba*
 - Naegleria*
 - Dientamoeba fragilis*

Answer

- | | | | |
|------|-------|-------|------|
| 1. a | 2. c | 3. a | 4. a |
| 5. b | 6. d | 7. c | 8. d |
| 9. d | 10. b | 11. b | |

Chapter 4: Intestinal, Oral and Genital Flagellates

1. Normal habitat of *Giardia* is
- Duodenum and jejunum
 - Stomach
 - Caecum
 - Ileum
2. All of the following protozoans are found in small intestine except
- Giardia lamblia*
 - Balantidium coli*
 - Cyclospora caytanensis*
 - Isospora belli*
3. The following is true of giardiasis except
- Fever and presence of blood and mucus in stool
 - Acute or chronic diarrhea
 - Duodenum and jejunum are the prime sites of involvement
 - Giardia* cysts are resistant to desiccation
4. *Giardia lamblia* was discovered by
- Giard
 - Robert hook
 - Leeuwenhoek
 - Losch
5. Drug of choice in giardiasis is
- Metronidazole
 - Albendazole
 - Thiabendazole
 - Diloxanide furoate
6. True about *Giardia* is
- May cause traveller's diarrhea
 - Giardia* inhabits ileum
 - Trophozoites are infective to man
 - Encystment of trophozoites occur in jejunum
7. Which one following test is used for diagnosis of *Giardia lamblia* infections
- Enterotest
 - Casoni's test
 - Parasight F test
 - Napier's test
8. Motility of *Trichomonas vaginalis* is described as
- Amoeboid
 - Jerky
 - Falling leaf
 - Lashing
9. Vaginal discharge in *Trichomonas vaginitis* is
- Colorless
 - Yellow
 - Curd-white
 - Blood stained
10. All of the following protozoan can be transmitted by sexual contact except:
- Trichomonas vaginalis*
 - Entamoeba histolytica*
 - Enteromonas hominis*
 - Giardia lamblia*

Answer

- | | | | |
|------|-------|------|------|
| 1. a | 2. b | 3. a | 4. c |
| 5. a | 6. a | 7. a | 8. b |
| 9. b | 10. c | | |

Chapter 5: Hemoflagellates

1. Vector for *Trypanosoma cruzi* is
 - a. Reduviid bug
 - b. Tsetse fly
 - c. Sandfly
 - d. Hard tick
2. All of the following are obligate intracellular parasite except
 - a. Plasmodium
 - b. *Trypanosoma cruzi*
 - c. *Toxoplasma gondii*
 - d. *Trypanosoma brucei gambiense*
3. Romana's sign occurs in
 - a. Babesiosis
 - b. Leishmaniasis
 - c. Trypanosomiasis
 - d. Schistosomiasis
4. Vector for *T. brucei gambiense* is
 - a. Sandfly
 - b. Reduviid bug
 - c. Tsetse fly
 - d. House fly
5. Winterbottom sign in sleeping sickness refers to
 - a. Unilateral conjunctivitis
 - b. Posterior cervical lymphadenitis
 - c. Narcolepsy
 - d. Transient erythema
6. The drug that can clear trypanosomes from blood and lymph nodes and is active in late nervous system stages of African sleeping sickness is
 - a. Emetine
 - b. Melarsoprol
 - c. Nifutrimox
 - d. Suramin
7. Which of the following is not true about West African trypanosomiasis
 - a. Primary reservoirs are human
 - b. Low parasitemia
 - c. Illness is usually chronic
 - d. Minimal lymphadenopathy
8. Chronic infections with which of the following hemoflagellates may be associated with megaesophagus or megacolon
 - a. *Trypanosoma gambiense*
 - b. *Trypanosoma cruzi*
 - c. *Leishmania donovani*
 - d. *Leishmania tropica*
9. True about visceral leishmaniasis is/are
 - a. Caused by *Leishmania tropica*
 - b. Post leishmaniasis dermatitis develops in 20% of patients
 - c. Antimonial compounds are useful
 - d. Vector is tsetse fly
10. Which of the following is most severely affected in Kala-azar
 - a. Spleen
 - b. Liver
 - c. Lymphnodes
 - d. Bone marrow
11. LD bodies are
 - a. Amastigotes of *Leishmania donovani* inside RBCs
 - b. Giant cells seen in leishmaniasis
 - c. Degenerative lesions seen in leishmaniasis
 - d. Amastigotes of *Leishmania donovani* inside macrophages
12. In a case of Kala-azar, aldehyde test becomes positive after
 - a. 2 weeks
 - b. 4 weeks
 - c. 8 weeks
 - d. 12 weeks
13. Mucocutaneous leishmaniasis is caused by
 - a. *Leishmania braziliensis*
 - b. *Leishmania donovani*
 - c. *Leishmania tropica*
 - d. None of the above
14. Chiclero's ulcer is caused by
 - a. *Leishmania mexicana* complex
 - b. *Leishmania braziliensis* complex
 - c. *Leishmania tropica*
 - d. *Leishmania infantum*

Answer

- | | | | |
|-------|-------|-------|-------|
| 1. a | 2. d | 3. c | 4. c |
| 5. b | 6. b | 7. d | 8. b |
| 9. c | 10. a | 11. d | 12. d |
| 13. a | 14. a | | |

Chapter 6: Malaria and Babesia

1. Old RBCs are preferentially infected by
 - a. Plasmodium falciparum
 - b. Plasmodium malariae
 - c. Plasmodium vivax
 - d. Plasmodium ovale
2. The infective form of the malaria parasite is
 - a. Oocyst
 - b. Sporozoite
 - c. Bradyzoite
 - d. Tachyzoite
3. Prolonged parasitism in malaria is due to
 - a. Antigenic variation
 - b. Intracellularity of parasite
 - c. Immunosuppression
 - d. Sequestration
4. Malaria pigment is formed by
 - a. Parasite
 - b. Bilirubin
 - c. Hemoglobin
 - d. All of the above
5. Schuffner's dot in RBCs are seen in infection with
 - a. Plasmodium vivax
 - b. Plasmodium falciparum
 - c. Plasmodium malariae
 - d. Plasmodium ovale
6. Quartan Malaria is caused by
 - a. Plasmodium vivax
 - b. Plasmodium falciparum
 - c. Plasmodium malariae
 - d. Plasmodium ovale
7. Schizonts of Plasmodium falciparum are not found in peripheral blood because
 - a. Schizonts are absent in the life cycle
 - b. Schizonts are killed by antibodies
 - c. Schizonts develop only in capillaries of internal organs
 - d. None of the above
8. Crescent-shaped or banana-shaped gametocytes are seen in infection with
 - a. Plasmodium vivax
 - b. Plasmodium falciparum
 - c. Plasmodium malariae
 - d. Plasmodium ovale
9. Malaria is not seen in patients with
 - a. G6PD deficiency
 - b. Sickle cell trait
 - c. Duffy negative blood group
 - d. All of the above
10. Which plasmodial infection is more often associated with nephritic syndrome
 - a. Plasmodium vivax
 - b. Plasmodium falciparum
 - c. Plasmodium malariae
 - d. Plasmodium ovale
11. Which is the treatment of choice for benign tertian malaria
 - a. Sulfamethoxazole – pyrimethamine
 - b. Quinine
 - c. Mefloquine
 - d. Chloroquine
12. Gametocidal perinicious malaria may occur in
 - a. Plasmodium vivax
 - b. Plasmodium falciparum
 - c. Plasmodium malariae
 - d. Plasmodium ovale
13. Babesiosis is transmitted by
 - a. Ticks
 - b. Mites
 - c. Flea
 - d. Mosquito
14. Maltose cross is a characteristic feature of
 - a. Cryptococcus neoformans
 - b. Babesia microti
 - c. Blastomycosis
 - d. Micrococcus

Answer

- | | | | |
|-------|-------|-------|-------|
| 1. b | 2. b | 3. b | 4. c |
| 5. a | 6. c | 7. c | 8. b |
| 9. d | 10. c | 11. d | 12. b |
| 13. a | 14. b | | |

Chapter 7: Coccidia

1. Route of transmission of *Toxoplasma*
 - a. Blood
 - b. Feces
 - c. Urine
 - d. None
2. *Toxoplasma gondii* lives inside the
 - a. Lumen of small intestine
 - b. Lumen of large intestine
 - c. Reticuloendothelial cell and many other nucleated cell
 - d. RBC
3. Oocyst of *Toxoplasma* is found in
 - a. Cat
 - b. Dog
 - c. Mosquito
 - d. Cow
4. Toxoplasmosis in the fetus can be best confirmed by
 - a. IgM antibodies in the mother
 - b. IgM antibodies in the fetus
 - c. IgG antibodies in the mother
 - d. IgG antibodies in the fetus
5. Intermediate hosts of toxoplasmosis are
 - a. Sheep
 - b. Cattle
 - c. Pigs
 - d. All of the above
6. The following statements regarding congenital toxoplasmosis are correct except
 - a. Most severe form of congenital infection occurs, if it is acquired in 1st trimester
 - b. Chorioretinitis and hydrocephalus are common manifestations in congenital infections
 - c. Presence of *Toxoplasma*-specific IgM antibodies in an infant are suggestive of congenital infection
 - d. Most severe form of congenital infection occur if it is acquired in 3rd trimester
7. Frenkels' skin test is positive in
 - a. Spinal cord compression
 - b. Toxoplasmosis
 - c. Pemphigus
 - d. Pemphigoid
8. In humans, cryptosporidiosis presents as
 - a. Meningitis
 - b. Diarrhea
 - c. Pneumonia
 - d. Asymptomatic infection
9. Which stain demonstrates the oocyst of *Cryptosporidium* best
 - a. Hematoxylin-eosin
 - b. Gram's stain
 - c. Kinyoun modified acid fast stain
 - d. Modified trichrome stain
10. All of the following cause diarrhea except
 - a. *Entamoeba histolytica*
 - b. *Giardia lamblia*
 - c. *Naegleria fowleri*
 - d. *Cyclospora caytanensis*
11. The oval oocyst of *Isospora belli* found in human feces measures
 - a. 1–3 μm \times 5–7 μm
 - b. 3–5 μm \times 8–10 μm
 - c. 5–8 μm \times 10–15 μm
 - d. 22–33 μm \times 10–15 μm
12. Stool in *Isospora belli* infection may contain all except
 - a. High fecal content
 - b. Blood
 - c. Fatty acid crystals
 - d. Charcot-Leyden crystals

Answer

- | | | | |
|------|-------|-------|-------|
| 1. a | 2. c | 3. a | 4. b |
| 5. d | 6. d | 7. b | 8. b |
| 9. c | 10. c | 11. d | 12. b |

Chapter 8: Microspora

1. All are true about Microsporidia except
 - a. First protozoan parasite studied by Louis Pasteur
 - b. Causative agent of silk worm disease
 - c. Extracellular spore-forming protozoa
 - d. Cause infection in immunocompromised subjects
2. Laboratory diagnosis of Microsporidia can be done by all except
 - a. Modified trichrome stain
 - b. Hematoxylin and eosin-stain
 - c. Direct fluorescent antibody
 - d. Electron microscopy

3. *Enterocytozoon bieneusi* preferentially infects
 - a. Brain
 - b. Conjunctiva
 - c. Kidneys
 - d. Small intestine
4. Microsporidial keratoconjunctivitis is commonly caused by
 - a. *Enterocytozoon bieneusi*
 - b. *Vittaforma*
 - c. *Encephalitozoon hellem*
 - d. *Encephalitozoon intestinalis*

Answer

- | | | | |
|------|------|------|------|
| 1. c | 2. b | 3. d | 4. c |
|------|------|------|------|

Chapter 9: *Pneumocystis jirovecii*

1. Which of the following has been recently classified as fungus
 - a. *Pneumocystis jirovecii*
 - b. *Cryptosporidium parvum*
 - c. *Isospora belli*
 - d. Microsporidia
2. Infective form of *Pneumocystis jirovecii* is
 - a. Tachyzoite
 - b. Cyst
 - c. Sporozoite
 - d. Trophozoite
3. In a case of pneumocystis pneumonia, chest can reveal all the following except
 - a. Cavitation
 - b. Nodular densities
 - c. Lobar infiltration
 - d. Honey-comb appearance
4. All of the following cause opportunistic infections in AIDS except
 - a. *Pneumocystis jirovecii*
 - b. *Toxoplasma gondii*
 - c. *Entamoeba coli*
 - d. Microsporidia

Answer

- | | | | |
|------|------|------|------|
| 1. a | 2. b | 3. a | 4. c |
|------|------|------|------|

Chapter 10: *Balantidium coli*

1. Largest protozoal parasite is
 - a. *Entamoeba histolytica*
 - b. *Trichomonas vaginalis*
 - c. *Leishmania donovani*
 - d. *Balantidium coli*
2. The infective form of *Balantidium coli* is
 - a. Tachyzoite
 - b. Cyst
 - c. Sporozoite
 - d. Trophozoite
3. Which of the following acts as the main reservoir of *Balantidium coli* infection
 - a. Man
 - b. Monkey
 - c. Pig
 - d. Cow
4. Drug of choice for treating balantidiasis
 - a. Doxycycline
 - b. Tetracycline
 - c. Metronidazole
 - d. Pentamidine

Answer

- | | | | |
|------|------|------|------|
| 1. d | 2. b | 3. c | 4. b |
|------|------|------|------|

Chapter 11: Helminths: General Features

1. Digestive tract is completely absent in
 - a. Trematodes
 - b. Cestodes
 - c. Nematodes
 - d. All of the above
2. Sexes are always separate in
 - a. Cestodes
 - b. Trematodes
 - c. Nematodes
 - d. None of the above
3. Nematodes are differentiated from other worms by the following except
 - a. Absent fragmentation
 - b. Flat or fleshy leaf-like worm
 - c. Separate sexes
 - d. Cylindrical body
4. Which of the following worm requires two intermediate host
 - a. *Taenia saginata*
 - b. *Diphyllobothrium latum*
 - c. *Hymenolepis nana*
 - d. *Echinococcus granulosus*
5. Which of the following statement is true in respect to trematodes
 - a. Dorsoventrally flattened
 - b. Intermediate host is snail
 - c. Hermaphrodite except schistosomes
 - d. All of the above

Answer

- | | | | |
|------|------|------|------|
| 1. b | 2. c | 3. b | 4. b |
| 5. d | | | |

Chapter 12: Cestodes: Tapeworms

1. Autoinfection is a mode of transmission in
 - a. *Trichinella*
 - b. Cysticercosis
 - c. *Ancylostoma*
 - d. *Ascaris*
2. Pigs are reservoir for
 - a. *Taenia solium*
 - b. *Diphyllobothrium latum*
 - c. *Trichinella spiralis*
 - d. *Ancylostoma*
3. On microscopic examination, eggs are seen, but on saturation with salt solution eggs are not seen. The eggs are likely to be of
 - a. *Trichuris trichiura*
 - b. *Taenia solium*
 - c. *Ascaris lumbricoides*
 - d. *Ancylostoma duodenale*
4. Which of the following is not a cestode
 - a. *Diphyllobothrium latum*
 - b. *Taenia saginata*
 - c. *Schistosoma mansoni*
 - d. *Echinococcus granulosus*
5. Consumption of uncooked pork is likely to cause which of the following helminthic disease
 - a. *Taenia saginata*
 - b. *Taenia solium*
 - c. Hydatid cyst
 - d. *Trichuris trichiura*
6. All of the following are true about neurocysticercosis, except
 - a. Not acquired by eating contaminated vegetables
 - b. Caused by regurgitation of larva
 - c. Acquired by orofecal route
 - d. Acquired by eating pork
7. The longest tapeworm found in man
 - a. *Diphyllobothrium latum*
 - b. *Taenia saginata*
 - c. *Taenia solium*
 - d. *Echinococcus granulosus*
8. Second intermediate host of *Diphyllobothrium latum* is
 - a. Cyclops
 - b. Man
 - c. Snail
 - d. Fresh water fish
9. Dwarf tapeworm refers to
 - a. *Echinococcus granulosus*
 - b. *Loa loa*
 - c. *Hymenolepis nana*
 - d. *Schistosoma mansoni*
10. The egg of which of the following parasites consists of polar filaments arising from either end of the embryophore
 - a. *Taenia saginata*
 - b. *Taenia solium*
 - c. *Echinococcus granulosus*
 - d. *Hymenolepis nana*

11. *Conenurus* is the larval form of
 a. *Taenia solium*
 b. *Taenia multiceps*
 c. *Echinococcus granulosus*
 d. *Echinococcus multilocularis*
12. Larval form of *Echinococcus granulosus* is seen in
 a. Dog
 b. Man
 c. Wolf
 d. Fox
13. The adult worm of *Echinococcus granulosus* contains
 a. 3–4 segments
 b. 50–100 segments
 c. 100–200 segments
 d. 1000–2000 segments
14. Which skin test is useful for diagnosis of hydatid disease
 a. Casoni's test
 b. Schick test
 c. Dick's test
 d. Tuberculin test

Answer

- | | | | |
|-------|-------|-------|-------|
| 1. b | 2. a | 3. b | 4. c |
| 5. b | 6. a | 7. a | 8. d |
| 9. c | 10. d | 11. b | 12. b |
| 13. a | 14. a | | |

Chapter 13: Trematodes: Flukes

1. Which of the following flukes is carcinogenic
 a. *Fasciola*
 b. *Clonorchis*
 c. *Paragonimus*
 d. *Gastrodiscoides*
2. Organism causing biliary tract obstruction
 a. *Ancylostoma duodenale*
 b. *Clonorchis sinensis*
 c. *Strongyloides stercoralis*
 d. *Enterobius vermicularis*
3. All float in a saturated salt solution except
 a. *Clonorchis sinensis*
 b. Fertilized eggs of *Ascaris*
 c. Larva of *Strongyloides*
 d. *Trichuris trichiura*
4. Terminal spined eggs are seen in
 a. *Schistosoma haematobium*
 b. *Schistosoma mansoni*
 c. *Schistosoma japonicum*
 d. *Clonorchis sinensis*
5. Largest trematode infecting humans
 a. *Fasciola hepatica*
 b. *Fasciolopsis buski*
 c. *Schistosoma haematobium*
 d. *Paragonimus westermani*
6. The second intermediate host of *Fasciola hepatica* is
 a. Snail
 b. Fresh water fish
 c. Crab
 d. Aquatic plants
7. *Schistosoma japonicum* resides in
 a. Superior mesenteric vein
 b. Inferior mesenteric vein
 c. Small intestine
 d. Gall bladder
8. All of the following lead to bloody diarrhea except
 a. *Schistosoma japonicum*
 b. *Entamoeba histolytica*
 c. *Schistosoma mansoni*
 d. *Schistosoma haematobium*

Answer

- | | | | |
|------|------|------|------|
| 1. b | 2. b | 3. a | 4. a |
| 5. b | 6. d | 7. a | 8. d |

Chapter 14: Nematodes: General Features

1. All of the following nematodes are oviparous except
 - a. Ascaris
 - b. Ancylostoma
 - c. Trichinella
 - d. Enterobius
2. Nematoda residing in large intestine
 - a. Necatar
 - b. Trichinella
 - c. Strongyloides
 - d. Trichuris
3. All of the following are somatic nematodes except
 - a. Loa loa
 - b. Capillaria philippinensis
 - c. Onchocerca volvulus
 - d. Brugia malayi
4. Most common cause of visceral larva migrans
 - a. Ancylostoma braziliensis
 - b. Anisakis simplex
 - c. Strongyloides stercoralis
 - d. Toxocara canis
5. Cutaneous larva migrans is due to
 - a. Ancylostoma braziliensis
 - b. Wuchereria bancrofti
 - c. Brugia malayi
 - d. Dracunculus medinensis
6. A teenager who plays with dogs developed skin rash, eosinophilia, and an enlarged liver and spleen for 1 year. The most likely cause of this infection is
 - a. Trichinosis
 - b. Schistosomiasis
 - c. Toxoplasmosis
 - d. Visceral larva migrans

Answer

- | | | | |
|------|------|------|------|
| 1. c | 2. d | 3. b | 4. d |
| 5. a | 6. d | | |

Chapter 15: Trichinella Spiralis

1. Larva found in muscle is
 - a. Trichinella spiralis
 - b. Ancylostoma duodenale
 - c. Trichuris trichiura
 - d. Enterobius vermicularis
2. Which of the following is not a neuroparasite
 - a. Taenia solium
 - b. Acanthamoeba
 - c. Naegleria
 - d. Trichinella spiralis
3. Which of the following is viviparous
 - a. Strongyloides stercoralis
 - b. Trichinella spiralis
 - c. Enterobius
 - d. Ascaris
4. Best site for taking biopsy for diagnosis of trichinellosis is
 - a. Deltoid muscle
 - b. Diaphragm
 - c. Pectoralis major
 - d. Liver
5. Bachman's test is done to diagnose infections with
 - a. Schistosoma japonicum
 - b. Trichinella spiralis
 - c. Trichuris trichiura
 - d. Ancylostoma duodenale
6. The larval form of Trichinella can be destroyed by
 - a. Smoking of meat
 - b. Deep freezing of meat
 - c. Drying of meat
 - d. Salting of meat

Answer

- | | | | |
|------|------|------|------|
| 1. a | 2. d | 3. b | 4. a |
| 5. b | 6. b | | |

Chapter 16: Trichuris Trichiura

- Which of the following resides in caecum
 - Trichuris trichiura*
 - Ascaris lumbricoides*
 - Strongyloides*
 - Ancylostoma*
- The common name for *Trichuris* is
 - Roundworm
 - Hookworm
 - Whipworm
 - Seatworm
- Heavy infection of *Trichuris* is characterized by
 - <10 eggs in stool
 - >10 eggs in stool
 - <50 eggs in stool
 - >50 eggs in stool
- All of the following statements about *Trichuris* are correct except
 - It resides in large intestine of man
 - Eggs of *Trichuris* float in saturated salt solution
 - Eggs of *Trichuris* do not float in saturated salt solution
 - Embryonated eggs containing rhabditiform larvae are infective to man

Answer

- | | | | |
|------|------|------|------|
| 1. a | 2. c | 3. d | 4. c |
|------|------|------|------|

Chapter 17: Strongyloides Stercoralis

- Parasites penetrating through skin for entry into the body are
 - Trichinella*
 - Strongyloides*
 - Roundworm
 - Trichuris trichiura*
- Larval form of the following parasites is found in stool except
 - Strongyloides stercoralis*
 - Ancylostoma duodenale*
 - Ascaris lumbricoides*
 - Necator americanus*
- Autoinfection is seen with
 - Cryptosporidium*
 - Strongyloides*
 - Giardia*
 - Gnathostoma*
- The term larva currens is used for migrating larva of
 - Strongyloides stercoralis*
 - Necator americanus*
 - Ancylostoma duodenale*
 - Hymenolepis nana*
- Smallest nematode known to cause infection in man is
 - Trichinella spiralis*
 - Strongyloides stercoralis*
 - Ancylostoma duodenale*
 - Trichuris trichiura*
- Infective form of *Strongyloides* is
 - Eggs
 - Rhabditiform larva
 - Filariform larva
 - Cercaria* larva
- Baermann's funnel gauze method is used for detection of larva of
 - Necator*
 - Strongyloides*
 - Ancylostoma*
 - Ascaris*
- Strongyloides* can be cultured in /by
 - NNN medium
 - Harada Mori method of stool culture
 - Agar plate culture
 - Hockmeyer's medium

Answer

- | | | | |
|------|------|------|------|
| 1. b | 2. c | 3. b | 4. a |
| 5. b | 6. c | 7. b | 8. c |

Chapter 18: Hookworm

1. Highest incidence of anemia in the tropics is due to
 - a. Hookworm
 - b. Thread worm
 - c. Ascaris
 - d. Guinea worm
2. The average blood loss per worm in ancylostomiasis is
 - a. 0.2 mL/day
 - b. 2 mL/day
 - c. 0.33 mL/day
 - d. 1 mL/day
3. Which of the following does not cause biliary tract obstruction
 - a. *Ascaris lumbricoides*
 - b. *Ancylostoma duodenale*
 - c. *Clonorchis sinensis*
 - d. *Fasciola hepatica*
4. Which of the following stages of *Ancylostoma duodenale* is infective to human beings
 - a. Rhabditiform larva
 - b. Filariform larva
 - c. Eggs
 - d. Adult worm
5. A 6-year-old girl is emaciated with a hemoglobin level of 6 g/dL. Her face appears puffy with swollen eyelids and edema over feet and ankles. There are no laboratory facilities available. The most likely cause of the child's condition is
 - a. Schistosomiasis
 - b. Cercarial dermatitis
 - c. Ascariasis
 - d. Hookworm disease
6. All of the following are characteristics of *Ancylostoma* except
 - a. Its copulatory bursa has 13 rays
 - b. Caudal spine is present in females
 - c. Head is bent in a direction opposite to body
 - d. Vulval opening is situated in the middle of the body.

Answer

- | | | | |
|------|------|------|------|
| 1. a | 2. a | 3. b | 4. b |
| 5. d | 6. c | | |

Chapter 19: Enterobius Vermicularis

1. Most common presenting symptom of thread worm infection amongst the following is
 - a. Abdominal pain
 - b. Rectal prolapse
 - c. Urticaria
 - d. Vaginitis
2. Which one of the following does not pass through the lungs
 - a. Hookworm
 - b. Ascaris
 - c. *Strongyloides*
 - d. *Enterobius vermicularis*
3. Infection with which of the following parasites may cause enuresis
 - a. *Ascaris lumbricoides*
 - b. *Enterobius vermicularis*
 - c. *Trichinella spiralis*
 - d. *Wuchereria bancrofti*
4. History of mild intestinal distress, sleeplessness, itching, and anxiety is seen in preschool child attending play school. Possible parasite agent causing these manifestations is
 - a. *Trichomonas vaginalis*
 - b. *Enterobius vermicularis*
 - c. *Ascaris lumbricoides*
 - d. *Necator americanus*
5. The common name for *Enterobius vermicularis* is
 - a. Threadworm
 - b. Pinworm
 - c. Seatworm
 - d. Whip worm
6. Which of the following nematodes lays eggs containing larvae
 - a. *Trichinella spiralis*
 - b. *Enterobius vermicularis*
 - c. *Brugia malayi*
 - d. *Ascaris lumbricoides*

Answer

- | | | | |
|------|------|------|------|
| 1. a | 2. d | 3. b | 4. b |
| 5. c | 6. b | | |

Chapter 20: Ascaris Lumbricoides

- Which of the following parasites does not penetrate human skin
 - Ascaris lumbricoides*
 - Ancylostoma duodenale*
 - Strongyloides stercoralis*
 - Schistosoma haematobium*
- The common name for *Ascaris lumbricoides* is
 - Roundworm
 - Hookworm
 - Threadworm
 - None of the above
- The largest intestinal nematode infecting humans is
 - Necator americanus*
 - Ascaris lumbricoides*
 - Enterobius vermicularis*
 - None of the above
- All of the following are correct regarding fertilized egg of *Ascaris* except
 - It is always bile-stained
 - Covered by an outer mammillated coat
 - Floats in saturated solution of salt
 - Does not float in saturated solution of salt
- All of the following parasites have bile-stained eggs except
 - Ascaris*
 - Clonorchis*
 - Taenia solium*
 - Enterobius*
- Loeffler's syndrome may be seen in infection with
 - Ancylostoma duodenale*
 - Ascaris lumbricoides*
 - Trichinella spiralis*
 - Trichuris trichiura*

Answer

- | | | | |
|------|------|------|------|
| 1. a | 2. a | 3. b | 4. d |
| 5. d | 6. b | | |

Chapter 21: Filarial Worms

- All are true regarding filariasis except
 - Man is an intermediate host
 - Caused by *Wuchereria bancrofti*
 - Involves lymphatic system
 - DEC is used in treatment
- All of the following are true about *Brugia malayi* except
 - The intermediate host in India is *Mansonia mosquito*
 - The tail tip is free from nuclei
 - Nuclei are blurred, so counting is difficult
 - Adult worm is found in the lymphatic system
- Hydrocele and edema in foot occurs in
 - Wuchereria bancrofti*
 - Brugia malayi*
 - Brugia timori*
 - Onchocerca volvulus*
- In which stage of filariasis are microfilaria seen in peripheral blood
 - Tropical eosinophilia
 - Early adenolymphangitis stage
 - Late adenolymphangitis stage
 - Elephantiasis
- Diurnal periodicity is seen in larvae of
 - Brugia malayi*
 - Wuchereria bancrofti*
 - Loa loa*
 - Mansonella perstans*
- Which of the following microfilariae is unsheathed
 - Mf. loa*
 - Mf. bancrofti*
 - Mf. malayi*
 - Mf. perstans*
- All of the following parasites can be detected in urine sample except
 - Wuchereria bancrofti*
 - Schistosoma haematobium*
 - Trichomonas vaginalis*
 - Giardia lamblia*
- Fugitive or calabar swelling is seen in infection with
 - Onchocerca volvulus*
 - Loa loa*
 - Wuchereria bancrofti*
 - Brugia timori*
- River blindness is the name given to disease caused by
 - Loa loa*
 - Onchocerca volvulus*
 - Toxoplasma gondii*
 - Acanthamoeba culbertsoni*
- The filarial worm which can be seen in conjunctiva is
 - Brugia malayi*
 - Loa loa*
 - Onchocerca volvulus*
 - None of the above

Answer

- | | | | |
|------|-------|------|------|
| 1. a | 2. b | 3. a | 4. b |
| 5. c | 6. d | 7. d | 8. b |
| 9. b | 10. b | | |

Chapter 22: Dracunculus Medinensis

- Which of the following parasite does not enter into the body by skin penetration
 - Dracunculus
 - Necator americanus
 - Ancylostoma duodenale
 - Strongyloides
- Definitive host for Guinea worm is
 - Man
 - Cyclops
 - Snail
 - Cyclops and man
- Guinea worm is
 - Enterobius
 - Trichuris
 - Dracunculus
 - Taenia solium
- Cyclops is the source of infection in
 - Dracunculus
 - Spirometra
 - Both
 - None

Answer

- | | | | |
|------|------|------|------|
| 1. a | 2. a | 3. c | 4. c |
|------|------|------|------|

Chapter 23: Miscellaneous Nematodes

- Rat lung worm is the common name of
 - Paragonimus westermani
 - Toxocara canis
 - Angiostrongylus cantonensis
 - Mansonella streptocerca
- Paratenic host for angiostrongylus cantonensis is
 - Rat
 - Man
 - Frog
 - Camel
- All of the following parasites are found in CSF except
 - Naegleria
 - Acanthamoeba
 - Angiostrongylus
 - Trypanosoma
- Definitive host for Capillaria philippinensis is
 - Man
 - Rat
 - Birds
 - Fish

Answer

- | | | | |
|------|------|------|------|
| 1. c | 2. b | 3. d | 4. c |
|------|------|------|------|

Chapter 24: Diagnostic Methods in Parasitology

1. Time of collection of blood is important in
 - a. *Microfilaria*
 - b. *Trypanosoma* spp.
 - c. *Leishmania* spp.
 - d. *Babesia* spp.
2. Modified acid-fast stain is used for the diagnosis of
 - a. *Entamoeba histolytica*
 - b. *Toxoplasma gondii*
 - c. *Cryptosporidium parvum*
 - d. *Leishmania donovani*
3. Sputum examination is commonly done for detecting the eggs of
 - a. *Strongyloides stercoralis*
 - b. *Entamoeba histolytica*
 - c. *Paragonimus westermani*
 - d. *Ascaris lumbricoides*
4. Larval forms of which parasite can be found in muscle biopsy
 - a. *Ascaris lumbricoides*
 - b. *Taenia solium*
 - c. *Trichuris trichiura*
 - d. *Ancylostoma duodenale*

Answer

1. a

2. c

3. c

4. b



Index

Page numbers followed by *f* refer to figure and *t* refer to table, respectively

A

- Acanthamoeba 27*t*
 - culbertsoni, life cycle of 28*f*
 - keratitis 28
 - species 27
- Acanthopodia 28
- Acephalocysts 130
- Acid fast
 - parasitic organisms 101
 - stain 97*f*
- Acid-fast stain See Ziehl-Neelsen stain, modified
- Acquired toxoplasmosis 91
- Acute adenolymphangitis 209
- Adenophorea 162
- Adenophorea and secernentea, differences in 163*t*
- ADL See Acute adenolymphangitis
- Adoral cilia 107
- Amastigote 38, 39, 45, 45*f*, 52*f*
- American
 - murderer 182
 - visceral leishmaniasis 54
- Amoeba 11, 239
- Amoebae, classification of 14*t*
- Amoebiasis 241
 - lesions of 20*f*
 - sites affected in 19
- Amoebic
 - and bacillary dysentery 20*t*
 - hepatitis 19
 - liver abscess 19*f*
 - ulcer 17
- Amoeboid form of *P. vivax* 67, 98
- Ancylostoma duodenale 182
 - adult worm of 183*f*
 - egg of 183*f*
 - female worm of 183
 - life cycle of 184*f*
 - male worm of 183
- Anemia 75
 - in kala-azar, causes of 54
 - in malaria, causes of 76
- Angiostrongylus cantonensis 225
- Animal inoculation 8, 241
- Animal nematodes infecting man 164*t*
- Anisakiasis 227
- Annelida 161
- Antiamoebic drugs, dosages of 23*t*
- Antigen detection in parasitic diseases 7*t*
- Aphasmodia 162
- Apical complex 87
- Apicomplexa 12, 63, 63*t*
- Ascariasis 197
 - ectopic 199
- Ascaris
 - eggs found in stools, types of 196*f*
 - fertilized egg of 197*f*
 - lumbricoides 176, 195, 196*f*, 200, 201
 - life cycle of 198*f*
 - specimen of 195*f*
 - pneumonia 198
 - unfertilized egg of 197*f*
- Auramine O stain for coccidia 232
- Autoinfection 95, 123, 177, 179, 192
 - external autoinfection 179
 - internal autoinfection 179

B

- Axoneme 38, 39
- Axostyle 34
- Babesia 63
 - species 83
 - bovis 83
 - clivergens 83
 - microti 83
- Baermann concentration method 233, 233*f*
- Balamuth's medium, composition of 240
- Balamuthia mandrillaris 29
- Balantidiasis 108, 109
- Balantididae 107
- Balantidium coli 107
 - life cycle of 108*f*
 - morphology of 107*f*
- Bancroftian
 - classical 209
 - occult 209
- Baylisascaris 201
- Bell's dilution-filtration 234
- Bilharziasis See Schistosomiasis
- Binary fission 10, 15
- Blackwater fever 77
- Bladder worm 122
- Blastocystis hominis
 - Granular form 98, 98*f*
- Blepharoplast 38, 39, 52
- Blocked sandflies 53

Blood
 flukes 140
 smear 44f
 Boeck and Drbohlav's medium, composition of 240
 Bothriocephalus anemia 118
 Bradyzoites 89, 90
 Brugia
 malayi 214
 pahangi 219
 timori 215

C

CAK See Chronic amoebic keratitis
 Calabar swellings 216
 Calculi 144
 Capillaria philippinensis 226
 Casoni's test 243
 Cattle strain See Clivergens
 Cellophane 193
 Cercariae 142
 Cestoda 110
 Cestodes
 heads and proglottids of, differences between 115f
 living in small intestine 120
 trematodes, and nematodes, differences between 111t
 Chagas'
 acute disease 47
 chronic disease 47
 disease 45
 Chagoma 47
 Charcoal culture 235
 Charcot-Leyden crystals 175, 230
 Chilomastix mesnili, egg of 36f
 Chopra's antimony test 58
 Chromatoid body 10
 Chronic amoebic keratitis 25
 Chronic meningoencephalitis 42
 Chronic salpingitis 192
 Chronic schistosomiasis 144
 Chylous urine 210f
 Cilia 10
 Ciliated miracidia 142
 Ciliophora 12, 107
 Clinical incubation period 208
 Clonorchis sinensis 148
 adult worm and egg of 149f
 life cycle of 150f
 Coccidia 63
 Coenurus 127
 Cold method See Kinyon's acid-fast stain
 Concentration techniques 211
 Conditions favoring hookworm infection 182
 Congenital toxoplasmosis 90
 Conjugation 10

Coracidium 116, 119
 Cray fishes of infection 225
 Creeping
 eruption 164, 227
 myiasis 164
 Cross-fertilization 111
 Cryptosporidiosis 242
 Cryptosporidium parvum 94, 97
 life cycle of 96f
 oocysts of 95f
 Culture methods 239
 Cutaneous larva migrans 166
 Cutaneous and visceral larva migrans between 165t
 Cyclophyllidea 113
 Cyclophyllidean 120
 Cyclospora cayetanensis 97
 Cyst 25f, 88, 103, 107f, 108
 of enteromonas hominis 36f
 binucleate 15f, 23f
 eight-nucleate 23f
 mature quadrinucleate 15f
 quadrinucleate 31f
 uninucleate 15f
 stage 16, 26
 Cysticerci in muscles 122f
 Cysticercosis 124, 126
 Cysticercus 121
 bovis 122
 in muscle 122f
 cellulosa 122, 122f
 Cytopharynx 107
 Cytopyge 107
 Cytostome 107

D

Dec provocation test 212
 Dicrocoelium dendriticum 153
 Deicious 111
 Dientamoeba fragilis 37
 Diethylcarbamazine provocation test 238
 Diphyllbothriasis 118
 Diphyllbothrium latum 115, 116f, 118
 lifecycle of 117f
 operculated egg of 116f
 Dipylidium caninum 137, 137f
 Dirofilaria
 immitis 219
 repens 219
 Diurnal periodicity 203
 DNA probe 81
 Dracontiasis 220
 Dracunculoidea 162
 Dracunculosis 223
 Dracunculus medinensis 224
 adult worm of 221f
 diagnosis of 223
 larva of 221f

life cycle of 222f
 Dual antigen test 81
 Duffy negative RBCs 78
 Dumdum fever 51
 Duodenal
 aspirates 94
 capsule technique 239

E

East African leishmaniasis 54
 East African trypanosomiasis See Trypanosoma brucei rhodesiense
 Echinococcosis 242
 Echinococcus
 granulosus 127, 128f
 life cycle of 129f
 multilocularis 134
 species and diseases 134
 Echinostoma 156
 Ectoparasite 1
 Ectoplasm 9
 Eggs of orders cyclophyllidea and pseudophyllidea, differences between 114t
 Elephantiasis 205, 210
 of legs 210f
 ELISA See Enzyme-linked immunosorbent assay
 Encysted larva in muscles 168f
 Endogony 88
 Endolimax nana 24, 25f
 quadrinucleate cyst 25f
 Endoparasite 1
 Endoplasm 9
 Endospore 101
 Entamoeba
 histolytica 239
 precystic stage 15, 15f
 coli 23
 Vegetative form 23f, 25f
 gingivalis 24
 hartmanni 24
 histolytica 14, 15f, 21f
 life cycles of 17f
 Enteric cycle 90
 Enterobius vermicularis 190, 194
 adult worm of 191f
 life cycle of 192f
 Enteromonas hominis 36
 Enterotest also known as Duodenal capsule technique 33
 Enzyme-linked immunosorbent assay 22, 81
 Eosin staining 230
 Eosinophilic meningoencephalitis 225
 Epimastigote 38, 45f, 46
 Erythrocytic stage 66
 Espundia 61
 Eurytrema pancreaticum 153

Excystation 16
 Exoenteric cycle 90
 Exoerythrocytic stage 66
 Exospore 101
 Extraintestinal amoebiasis 18, 19, 20
 cutaneous amoebiasis 20
 genitourinary amoebiasis 20
 hepatic amoebiasis 18, 19, 20
 metastatic amoebiasis 20
 pulmonary amoebiasis 19

F

Fairley's test 243
 Fasciola hepatica 151, 151f, 153
 life cycle of 152f
 Fascioliasis 152
 buski 154, 154f
 life cycle of 155f
 Female nematodes, types of 161
 Filarial worm in body, classification of 203t
 Filariasis 205, 242
 bancroftian 209
 classical and occult, difference between 209t
 lymphatic 205
 occult 210
 serous cavity 219
 subcutaneous 216
 zoonotic
 Filariform larva 177, 177f
 differential features of 186t
 Filarioidea 162, 203
 Flagella 12, 38, 39
 Flagellates 12, 30, 30t
 hemo 12
 hemoflagellates 30
 intestinal 12
 lumen-dwelling 30
 Floatation methods 232
 Flukes 139
 Fluorescence microscopy 81
 Formol-ether sedimentation technique 232
 Furcocercous cercaria 142

G

G6PD deficiency 78
 GAE See Granulomatous amoebic encephalitis
 Gametocytes of *P. falciparum* See Malarial parasite in blood film
 Gametogony 11, 67
 Gastrodiscoides hominis 156, 156f
 Geohelminths 201
 Geophages 197
 Giardia lamblia 30
 laboratory diagnosis of 33
 life cycle of 32f

Giardiasis 242
 Giemsa stain 57f, 235
 Gnathostoma spinigerum 226
 adult worm and egg of 227f
 Gnathostomiasis 226
 Granulomatous amoebic encephalitis 25, 28

H

Haemozoin pigment 67
 Halzoun 153
 Harada mori filter paper strip culture 234
 Helminths
 causing CNS infection 227
 eggs 173
 in lung 157
 no intermediate host 184
 Hematology 8
 Hemoflagellates
 basic morphology of 38f
 morphological stages of, differences between 39t
 Hermaphrodites 114
 Hermaphroditic trematode, morphology of 139f
 Heterophyes 156
 HIV-positive cases 101
 HLA-B53 78
 Hookworm
 disease in 187
 two species of, differentiating features of 185f
 Host 2
 accidental 2, 119
 definitive host 2
 intermediate 2
 paratenic 2
 reservoir 2
 Host parasite relationship 3
 commensalism 3
 parasitism 3
 symbiosis 3
 Human
 African trypanosomiasis, treatment of 45t
 cycle 66
 Hydatid cyst 128
 brood capsules 130
 endocyst 129
 fate of 130
 fluid 129
 in liver 129f, 131
 pericyst 129
 Hydrocoele 209
 Hymenolepis
 diminuta 137
 nana 134
 nana, adult worm of 134f
 nana, egg of 135f

 nana, life cycle of 136f
 Hymenolopiasis 135
 Hyperinfection 180
 Hypnozoites 66

I

Immune evasion 6
 Immunity 78
 acquired 78
 innate 78
 Incubation period 67
 Indian visceral leishmaniasis 54
 Infection modes of 4
 direct transmission 4
 iatrogenic transmission 4
 oral transmission 4
 skin transmission 4
 vector transmission 4
 vertical transmission 4
 Infection, sources of 3
 Infectious parasites in fecal sample 193
 Insect vectors 4
 biological 4
 true vectors 4
 mechanical 4
 Internal reinfection 179
 Intestinal amoebiasis 17f, 18
 complications and sequelae of 19
 Intestinal
 bilharziasis 146
 biopsy 94
 flukes 154
 helminths 242
 sarcocystosis 99
 taeniasis 124
 Iodamoeba buetschlii 25, 25f
 Iodine staining 230
 Iodophilic body 25
 Iron-hematoxylin stain 231
 Isospora belli 93
 oocysts of 93f, 94f
 immature cyst 93f
 mature cyst 93f

J

JSB stain 236

K

Kala azar
 laboratory diagnosis of 56
 spleen enlarged organ 55f
 Karyosome 10
 Katayama fever 143
 Kato thick smear technique 230
 Katayama fever 147
 Kinetoplast 10, 38, 52
 Kinetoplastida 12

Kinyon's acid-fast stain 231
 reagents of 231
 Knott's concentration 212

L

Larva
 currens 180
 migrans 162
 Latent stage 66
 LD bodies 52, 51
 LD body See Amastigote
 LD body in spleen smear of experimentally infected animal 57f
 Leishmania 49, 240
 aethiopica 59
 braziliensis complex 61
 donovani 51, 57
 life cycle of 53f
 morphology of 52f
 mexicana complex 61
 geographical distribution, classification of 51t
 major 59
 species in human disease 50t
 spp, disease caused by, distribution 51f
 tropica 59
 complex 59
 Leishmaniasis 50, 242
 China 54
 cutaneous 50
 visceral 50, 241
 Leishmanin
 skin test 58
 test 243
 Leishmans stain 235
 Liposomal amphotericin B 59
 Liver
 abscesses 19
 flukes 148
 rot 151
 Loa loa 216
 Loeffler's syndrome, Parasites causing pneumonitis 198
 Loiasis 216
 Lung flukes 157
 Lymphadenitis 209
 Lymphangitis 209
 Lymphedema 209
 Lymphoangiomas 209
 Lymphorrhagia 210

M

Malabar leg 205
 Malaria 242
 Endemic 64
 Epidemic 64
 Falciparum, complications of 77

algid 77
 and babesiosis, differential features of 85f
 benign 76
 cerebral 76
 congenital 77
 merozoite-induced 77
 ookinete 68
 organs effected 74f
 parasites 63, 64, 240
 in blood smear 80
 pigment 67
 transfusion 77
 types of 69, 71, 73
 vaccine 83
 Malarial parasite
 in blood film 70f
 types of 69
 Malignant
 hydatid disease 134
 malaria, Pathogenesis of 71
 Mansonella
 ozzardi 219
 perstans 219
 streptocerca 218
 Mastigophora 11
 Maurer's
 clefts 236
 dots 80
 Mazzotti reaction 218
 McMaster's egg counting 234
 Measly pork 122f
 Medically cestodes, classification of 113t
 Mediterranean leishmaniasis 54
 Membrane filtration concentration 237
 Merogony See Pre-erythrocytic schizogony
 Merozoites 65
 Metagonimus yokogawai 156
 Meyers kouwenaa syndrome 210
 MF bancrofti and MF malayi,
 distinguishing features of 214t
 Microfilaria 203
 bancrofti, morphology of 206f
 in blood film 211f
 Microhematocrit tube method 238
 Microspora 12, 100
 Microsporidia 100, 102
 classification of 100t
 Molecular diagnosis 8
 Monoecious 111
 Monoecious See Hermaphrodites
 Montenegro test See Leishmanin skin test
 Montenegro test See Leishmanin test
 Mosquito cycle 67
 Mosquito-borne malaria and blood transfusion malaria, difference between 77f
 Mucocutaneous leishmaniasis 50
 Multiceps multiceps 127

Multiple fission 10
 Muscle biopsy 171, 239
 Muscular sarcocystosis 99

N

Nagana disease 40
 Naegleria 27t
 fowleri 25
 fowleri, life cycle of 26f
 Necator americanus 186
 Nematelminthes 110
 Nematoda See Nematelminthes
 Nematodes
 classification of 163t
 filarial, infecting humans 205t
 in large intestine 172
 in small intestine 176
 on habitat of adult worms, classification of 162t
 with crabs and cray fishes as source of infection 225
 Neural larva migrans 201
 New world leishmaniasis 61
 NIH swab method 193
 NNN medium 240
 composition of 240
 Nocturnal enuresis 192
 Nocturnal periodicity 203
 Nocturnally subperiodic 203
 Nonperiodic 203
 Nucleopore filtration 212
 Nucleus 39

O

Ocular toxoplasmosis 91
 Old world leishmaniasis 51
 Onchocerca volvulus 217, 217f
 Oncosphere 114
 Oocyst 68, 89
 of cryptosporidium parvum 97f
 of sarcocystis hominis 99f
 thick-walled 95f
 thin-walled 95f
 Opisthorchis
 felineus 150
 species 150
 viverrini 150
 Opportunistic infection 104
 Oriental schistosomiasis 147
 Oviparous 162
 Ovoviviparous 162
 nematodes 221

P

PAIR See Puncture, aspiration, injection, and reaspiration

Parabasal body 38, 39, 52
 Paragonimus westermani 157, 157f, 159
 life cycle of 158f
 morphology 157f
 Parasite 1
 aberrant parasites 2
 accidental parasites 2
 and developmental stages in stool 6t
 causing
 autoinfection 4
 opportunistic infections in AIDS 104
 pneumonitis 199
 travellers diarrhea 95
 endoparasite 1
 escape mechanisms 6t
 exhibiting antigenic variations 5
 facultative parasite 2
 free-living 1
 parasite 1
 in cerebrospinal fluid 226
 in peripheral blood film 237
 in sputum 238
 in urine 7, 212
 leading to bloody diarrhea 147
 life cycle
 direct 3
 indirect 3
 obligate 1, 35
 intracellular 45
 parasite 1
 quantification of 80
 type of 2
 with aquatic vegetations as the source of infection 152
 with bile stained eggs 197
 with fishes as the source of infection 228
 associated with malignancy 144
 with mosquito as intermediate host 208
 with operculate eggs 151
 with source of infection 168
 Parasitic infection
 immunity in 5
 pathogenesis 5
 Paratenic host 227
 Pebrine 101
 Peridiocity 203, 207
 Peristome 107
 Phasmodia 162
 PKDL of India and East Africa, differences between 55t
 Plasmodia causing human malaria, comparison of 75t
 Plasmodium
 falciparum 72f
 malarial parasites types of 69
 malariae
 stages of erythrocytic schizogony 73f
 malarial parasites types of 71
 mixed infections 73

 ovale
 malarial parasites types of 73
 stages of erythrocytic schizogony 74f
 vivax 70f
 life cycle of 65f
 malarial parasites types of 69
 Platyhelminthes 110
 Plerocercoid larva 118, 119
 Plerocercoid larva See Sparganum
 Pneumocystis
 carinii, life cycle of 104f
 jirovecii 103, 106
 cyst 105f
 laboratory diagnosis of 105f
 predisposing factors for 104
 Polar tubule 101
 Polymerase chain reaction 81
 Polymorphism 39
 Post kala-azar dermal leishmaniasis 55
 Predisposing factors 106
 Pre-erythrocytic schizogony 66
 in human malaria parasites 66t
 Prepatent period 66, 67, 208
 Primary amoebic meningoencephalitis 25, 27
 Procercoid larva 118, 119
 Proglottid 116
 mature 116f
 Promastigote 38, 52, 52f
 Protozoa
 and metazoan, differences between 9t
 asexual reproduction in 10f
 classification of 11t
 parasites
 causing diarrhea 32
 in peripheral blood film 48
 pathogen of man, principal 12t
 transmitted by sexual contact 35
 Pruritis ani 192
 Pseudoabscesses 144
 Pseudocyst 88
 Pseudophyllidea 113
 Pseudophyllidean 115
 Pseudopodia 9, 11, 14, 15
 Puncture, aspiration, injection, and respiration 133

R

Recrudescence 78
 and relapse, differences between 79t
 Rectal biopsy 146
 Reduviid bugs, 45
 Relapse 78
 Reservoirs 41
 Retortomonas intestinalis 37
 Retroinfection 192
 Rhabditiform larva 177, 177f
 Ring stage of P falciparum See Malarial parasite in blood film

Ring stage of P vivax See Malarial parasite in blood film
 Rodent strain See Microti
 Romana's sign 47
 Rostellum 113
 Round worm 195, 201
 egg 196t

S

Sabin-Feldman dye test 92, 242
 Sarcocyst 99f
 Sarcocystis 98
 hominis 99
 lindenmani 99
 suihominis 99
 Sarcodina 11
 Sarcomastigophora 11
 Schistosoma eggs, hatching test for 234
 Schistosoma
 haematobium, egg of 145f
 japonicum 145f
 mansoni, egg of 145f
 haematobium 141, 144f
 egg of 142f
 intercalatum 148
 japonicum 146
 mansoni 145
 mekongi 148
 spp, cercaria larva of 142f
 spp, life cycle of 143f
 Schistosomes 140, 148
 morphology of 141f
 Schistosomiasis 140
 Schistosomulae 142
 Schizogony 10
 Schneider's
 dots 69, 80, 236
 drosophila tissue culture medium 57
 insect tissue culture medium 240
 Scolex 113, 114f, 116
 of taenia saginata and taenia solium 120f
 spatulate 116f
 Scotch tape method 234
 Secernentea 162
 Sedimentation methods 232, 237
 Septicemic malaria 77
 Serological tests 7
 Serology 241
 Sheathed microfilariae 203
 Simulium species 217
 Skin test 7
 done in parasitology 8
 in bancroftian filariasis 243
 of frenkel 92
 Sleeping sickness 41
 South American leishmaniasis 54
 Sowdah 218
 Spargana 120
 Sparganosis 120, 118

Sparganum 119
 Spirometra 118
 life cycle of 119f
 Sporoblasts 94f
 Sporogony 101
 Sporogony See Mosquito cycle
 Sputum examination 238
 Stallion's disease 40
 Stercoraria 39
 Stoll's dilution technique 234
 Strobila 114, 116
 Strongyloides stercoralis 176, 180f
 egg of 177f
 larvae of 177f
 life cycle of 178f, 179f
 Strongyloides, agar plate culture for 235
 Surra disease 40
 Swimmer's itch 142
 Syngamy See Gametogony

T

T cruzi and T rangeli, differences between 49t
 Taenia multiceps See Multiceps multiceps
 Taenia saginata 120, 126
 and taenia solium, difference between 121t
 asiatica 127
 life cycle of 122f, 123f
 Taenia solium 120, 127
 life cycle of 123, 124f
 Taenia spp, laboratory diagnosis of 125
 Taenia, egg of 121f
 Tapeworm 114f
 Tissue
 biopsy 238
 Toxocara 201
 canis 201
 adult worms of 201f
 cati 201
 Toxocariasis 242
 Toxoplasmosis 90
 Toxoplasma gondii 87, 88, 88f, 93
 laboratory diagnosis of 91f
 life cycle of 89f
 Tachyzoite 87
 oocyst containing sporocyst 88f
 Toxoplasmosis 241, 242

Travelling vermicle See Ookinete
 Trematoda 110
 Trematodes 138
 embryonated eggs of 140
 zoological classification of 138t
 Trichinella spiralis 167, 170f, 171
 adult worms of 167f
 life cycle of 169f
 stages in life cycle of (in man) 170t
 Trichinosis 242
 Trichomonas 34
 hominis 34f, hominis 36
 species 34f
 tenax 34f, 36
 vaginalis 34, 34f
 Trichostrongylasis 188
 Trichrome stain 231
 reagents of 231
 Trichuriasis 174, 175
 Trichuris trichiura 172, 175, 175f
 egg of 173f
 life cycle of 174f
 worms 173f
 Triploblastic metazoa 110
 Trophozoite 15, 15f, 31f, 36f, 88f, 103, 107, 107f
 of babesia microti in human blood smear 84f
 of dientamoeba fragilis 37f
 Tropical pulmonary eosinophilia 210
 Tropical splenomegaly syndrome 77
 Trypanosoma
 brucei
 gambiense 40
 rhodesiense 42
 cruzi 45, 45f
 blood smear 48f
 life cycle of 46f
 rangeli 49
 rhodesiense 44f
 Trypanosomal chancre 41
 Trypanosomes 240
 classification of 40
 Trypanosomiasis 241, 242
 diagnosis of 44
 West African and East African, differences between 43t
 Trypomastigote 38, 39, 45, 45f

U

Undulating membrane 12, 38, 39
 Unembryonated eggs of trematodes 140
 Unsheathed microfilariae 203
 Urogenital specimen 239

V

Vacuolated form 98
 Vector 64
 control strategies 83
 Vermecules 84
 Visceral larva migrans 201
 Vitamin B₁₂ deficiency 118
 Viviparous 162
 nematodes 221
 Vulvar waist 196

W

Wanderlust See Ectopic ascariasis
 Watsonius watsoni 156
 West African trypanosomiasis See Trypanosoma brucei gambiense
 Wheatley's method See Trichrome stain
 Winterbottom's sign 41
 Wuchereria bancrofti 205, 206
 adult worm of 206f
 diagnosis of 211
 life cycle of 208f
 Mass therapy 213

X

Xenodiagnosis 241

Z

Ziehl-Neelsen stain 97f
 modified 231
 Zinc sulphate
 centrifugal floatation 232
 floatation concentration technique 233f
 Zoonosis 2
 anthropo zoonosis 3
 helminthic zoonosis 3
 protozoal zoonosis 3
 zooanthroponoses zoonosis 3
 Zoonotic filariasis 219