

Third Edition

PATHOLOGY

QUICK REVIEW and MCQs

HARSH MOHAN



Based on
Harsh Mohan's
Textbook of
PATHOLOGY
Sixth Edition

JAYPEE

Prepared by
Dr. Prodigions

PATHOLOGY

Quick Review and MCQs

Based on
Textbook of Pathology
6th Edition

For free online Web Images and Web Tables cited in the text,
access on www.jaypeeonline.in

Scratch pin number available in the main textbook.

PATHOLOGY

Quick Review and MCQs

THIRD EDITION

Based on
Textbook of Pathology
6th Edition

Harsh Mohan MD, MNAMS, FICPath, FUICC
Professor & Head
Department of Pathology
Government Medical College
Sector-32 A, Chandigarh-160 031
INDIA
E-mail: drharshmohan@gmail.com



JAYPEE BROTHERS MEDICAL PUBLISHERS (P) LTD

St Louis (USA) • Panama City (Panama) • New Delhi • Ahmedabad • Bengaluru
Chennai • Hyderabad • Kochi • Kolkata • Lucknow • Mumbai • Nagpur

Published by

Jitendar P Viji

Jaypee Brothers Medical Publishers (P) Ltd

Corporate Office

4838/24 Ansari Road, Daryaganj, **New Delhi** 110 002, India, Phone: +91-11-43574357,
Fax: +91-11-43574314

Registered Office

B-3 EMCA House, 23/23B Ansari Road, Daryaganj, **New Delhi** 110 002, India
Phones: +91-11-23272143, +91-11-23272703, +91-11-23282021,+91-11-23245672
Rel: +91-11-32558559 Fax: +91-11-23276490, +91-11-23245683
e-mail: jaypee@jaypeebrothers.com, Website: www.jaypeebrothers.com

Branches

- ❑ 2/B, Akruiti Society, Jodhpur Gam Road Satellite
Ahmedabad 380 015 Phones: +91-79-26926233, Rel: +91-79-32988717
Fax: +91-79-26927094 e-mail: ahmedabad@jaypeebrothers.com
- ❑ 202 Batavia Chambers, 8 Kumara Krupa Road, Kumara Park East
Bengaluru 560 001 Phones: +91-80-22285971, +91-80-22382956, +91-80 22372664
Rel: +91-80-32714073 Fax: +91-80-22281761 e-mail: bangalore@jaypeebrothers.com
- ❑ 282 Illrd Floor, Khaleel Shirazi Estate, Fountain Plaza, Pantheon Road
Chennai 600 008 Phones: +91-44-28193265, +91-44-28194897, Rel: +91-44-32972089
Fax: +91-44-28193231 e-mail: chennai@jaypeebrothers.com
- ❑ 4-2-1067/1-3, 1st Floor, Balaji Building, Ramkote Cross Road
Hyderabad 500 095 Phones: +91-40-66610020, +91-40-24758498, Rel: +91-40-32940929
Fax: +91-40-24758499, e-mail: hyderabad@jaypeebrothers.com
- ❑ No. 41/3098, B & B1, Kuruvi Building, St. Vincent Road
Kochi 682 018, Kerala Phones: +91-484-4036109, +91-484-2395739, +91-484-2395740
e-mail: kochi@jaypeebrothers.com
- ❑ 1-A Indian Mirror Street, Wellington Square
Kolkata 700 013 Phones: +91-33-22651926, +91-33-22276404, +91-33-22276415
Fax: +91-33-22656075, e-mail: kolkata@jaypeebrothers.com
- ❑ Lekhraj Market III, B-2, Sector-4, Faizabad Road, Indira Nagar
Lucknow 226 016 Phones: +91-522-3040553, +91-522-3040554
e-mail: lucknow@jaypeebrothers.com
- ❑ 106 Amit Industrial Estate, 61 Dr SS Rao Road, Near MGM Hospital, Parel
Mumbai 400 012 Phones: +91-22-24124863, +91-22-24104532,
Rel: +91-22-32926896 Fax: +91-22-24160828, e-mail: mumbai@jaypeebrothers.com
- ❑ "KAMALPUSHPA" 38, Reshimbag, Opp. Mohota Science College, Umred Road
Nagpur 440 009 (MS) Phone: Rel: +91-712-3245220
Fax: +91-712-2704275 e-mail: nagpur@jaypeebrothers.com

North America Office

1745, Pheasant Run Drive, Maryland Heights (Missouri), **MO 63043, USA, Ph: 001-636-6279734**
e-mail: jaypee@jaypeebrothers.com, anjulav@jaypeebrothers.com

Central America Office

**Jaypee-Highlights Medical Publishers Inc., City of Knowledge, Bld. 237, Clayton,
Panama City, Panama, Ph: 507-317-0160**

Pathology Quick Review and MCQs

© 2010, Harsh Mohan

All rights reserved. No part of this publication should be reproduced, stored in a retrieval system, or transmitted in any form or by any means: electronic, mechanical, photocopying, recording, or otherwise, without the prior written permission of the author and the publisher.

This book has been published in good faith that the material provided by author is original. Every effort is made to ensure accuracy of material, but the publisher, printer and author will not be held responsible for any inadvertent error(s). In case of any dispute, all legal matters are to be settled under Delhi jurisdiction only.

First Edition : 2000

Second Edition : 2005

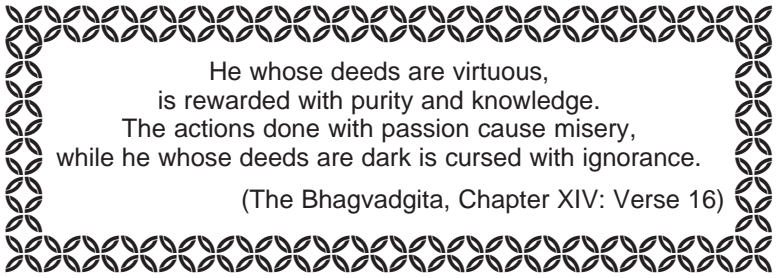
Third Edition : **2010**

Assistant Editors: Praveen Mohan, Tanya Mohan, Sugandha Mohan

ISBN: 978-81-8448-778-7

Typeset at JPBMP typesetting unit

Printed at Ajanta Press



He whose deeds are virtuous,
is rewarded with purity and knowledge.
The actions done with passion cause misery,
while he whose deeds are dark is cursed with ignorance.

(The Bhagvadgita, Chapter XIV: Verse 16)

To all those who matter so much to me:

*My family—wife Praveen and
daughters Tanya, Sugandha
and*

*All students and colleagues—former and present,
with whom I had occasion to share and interact.*

Preface

The release of the Third Revised Edition of *Pathology Quick Review and MCQs* simultaneous to the release of the *Sixth Edition* of its parent book, *Textbook of Pathology*, marks the completion of 10 years since its first launch. The satisfied users of this ancillary handy learning material during the decade have surely encouraged me and the publisher to continue the convention of providing the baby-book as a package with the mother-book. Besides, with this edition, a third learning resource has been added for the benefit of users—the buyer of the package now gets free access to the highly useful website containing all the images and tables included in the main textbook which can be used as an additional learning tool by the students for self-assessment and quick review of the subject while teachers may use the downloadable figures and tables for inclusion in their lectures.

The companion book is the abridged version of sixth revised edition of my textbook and has been aimed to serve the following twin purposes as before:

- ◆ For beginner students of Pathology who have undertaken an in-depth study of the main book earlier may like to revise the subject in a relatively short time from this book and may also undertake self-test on the MCQs given at the end of each chapter.
- ◆ For senior students and interns preparing for their postgraduate and other entrance examinations who are confronted with revision of all medical subjects besides pathology in a limited time, this book is expected to act as the main source material for quick revision and also expose them to MCQs based on essential pathology.

Pathology Quick Review book has the same 30 chapters divided into sections as in the main textbook—*Section I*: Chapters 1-11 (General Pathology and Basic Techniques), *Section II*: Chapters 12-14 (Haematology and Lymphoreticular Tissues), *Section III*: Chapters 15-30 (Systemic Pathology) and an *Appendix* containing essential Normal Values. Each major heading in the small book has cross-references of page numbers of the 6th edition of my textbook so that an avid and inquisitive reader interested in simultaneous consultation of the topic or for clarification of a doubt, may refer to it conveniently. Self-Assessment by MCQs given at the end of every chapter which keeps this book apart from other similar books, has over 100 new

questions raising their number to over 700 MCQs in the revised edition, besides modifying many old ones. While much more knowledge has been condensed in the baby-book from the added material in the main textbook, effort has been made not to significantly increase the volume of this book. It is hoped that the book with enhanced and updated contents continues to be user-friendly in learning the essential aspects of pathology, while at the same time, retaining the ease with which it can be conveniently carried by the users in the pocket of their white coats.

Preparation of this little book necessitated selection from enhanced information contained in the revised edition of my textbook and therefore, required application of my discretion, combined with generous suggestions from colleagues and users of earlier edition. In particular, valuable suggestions and help came from Drs Shailja and Tanvi, Senior Residents in the department, which is gratefully acknowledged.

I thank profusely the entire staff of M/s Jaypee Brothers Medical Publishers (P) Ltd. for their ever smiling support and cooperation in completion of this book in a relatively short time, just after we had finished the mammoth task of revision work of sixth edition of the main textbook.

Finally, although sincere effort has been made to be as accurate as possible, element of human error is still likely; I shall humbly request users to continue giving their valuable suggestions directed at further improvements of its contents.

Government Medical College
Sector-32 A
Chandigarh-160 031
INDIA
E-mail: drharshmohan@gmail.com

Harsh Mohan
MD, MNAMS, FICPath, FUICC
Professor and Head
Department of Pathology

Contents

SECTION I: GENERAL PATHOLOGY AND BASIC TECHNIQUES

1. Introduction to Pathology	01
2. Techniques for the Study of Pathology	06
3. Cell Injury and Cellular Adaptations	14
4. Immunopathology Including Amyloidosis	41
5. Derangements of Homeostasis and Haemodynamics	63
6. Inflammation and Healing	92
7. Infectious and Parasitic Diseases	131
8. Neoplasia	145
9. Environmental and Nutritional Diseases	185
10. Genetic and Paediatric Diseases	203
11. Basic Diagnostic Cytology	212

SECTION II: HAEMATOLOGY AND LYMPHORETICULAR TISSUES

12. Introduction to Haematopoietic System and Disorders of Erythroid Series	226
13. Disorders of Platelets, Bleeding Disorders and Basic Transfusion Medicine	266
14. Disorders of Leucocytes and Lymphoreticular Tissues	281

SECTION III: SYSTEMIC PATHOLOGY

15. The Blood Vessels and Lymphatics	322
16. The Heart	346
17. The Respiratory System	385
18. The Eye, ENT and Neck	425
19. The Oral Cavity and Salivary Glands	440
20. The Gastrointestinal Tract	455
21. The Liver, Biliary Tract and Exocrine Pancreas	500
22. The Kidney and Lower Urinary Tract	545
23. The Male Reproductive System and Prostate	587
24. The Female Genital Tract	603
25. The Breast	628
26. The Skin	641
27. The Endocrine System	659
28. The Musculoskeletal System	692
29. Soft Tissue Tumours	717
30. The Nervous System	727
APPENDIX: Normal Values	750
Index	757

Abbreviations Used

Throughout the book following abbreviations have been used:

G/A for Gross Appearance.

M/E for Microscopic Examination.

EM for Electron Microscopy.

IF for Immunofluorescence Microscopy.

Chapter 1

Introduction to Pathology

STUDY OF DISEASES (p. 1)

The word '*Pathology*' is derived from two Greek words—*pathos* meaning suffering, and *logos* meaning study. Pathology is, thus, scientific study of structure and function of the body in disease; or in other words, pathology consists of the abnormalities that occur in normal anatomy (including histology) and physiology owing to disease. Knowledge and understanding of pathology is essential for all would-be doctors, general medical practitioners and specialists. Remember the prophetic words of one of the eminent founders of modern medicine in late 19th and early 20th century, *Sir William Osler*, "Your practice of medicine will be as good as your understanding of pathology."

Since pathology is the study of disease, then what is *disease*? In simple language, disease is opposite of health i.e. what is not healthy is disease. *Health* may be defined as a condition when the individual is in complete accord with the surroundings, while *disease* is loss of ease (or comfort) to the body (i.e. dis-ease).

It is important for a beginner in pathology to be familiar with the language used in pathology:

- ◆ *Patient* is the person affected by disease.
- ◆ *Lesions* are the characteristic changes in tissues and cells produced by disease in an individual or experimental animal.
- ◆ *Pathologic changes* or *morphology* consist of examination of diseased tissues.
- ◆ Pathologic changes can be recognised with the naked eye (*gross or macroscopic changes*) or studied by *microscopic examination* of tissues.
- ◆ Causal factors responsible for the lesions are included in *etiology* of disease (i.e. 'why' of disease).
- ◆ Mechanism by which the lesions are produced is termed *pathogenesis* of disease (i.e. 'how' of disease).
- ◆ Functional implications of the lesion felt by the patient are *symptoms* and those discovered by the clinician are the *physical signs*.

EVOLUTION OF PATHOLOGY (p. 1)

Pathology as the scientific study of disease processes has its deep roots in medical history. Since the beginning of mankind, there has been desire as well as need to know more about the causes, mechanisms and nature of diseases. The answers to these questions have evolved over the centuries—from supernatural beliefs to the present state of our knowledge of modern pathology.

□ FROM RELIGIOUS BELIEFS AND MAGIC TO RATIONAL APPROACH (PREHISTORIC TIME TO AD 1500) (p. 2)

Present-day knowledge of primitive culture prevalent in the world in prehistoric times reveals that religion, magic and medical treatment were quite linked to each other in those times. The earliest concept of disease understood by the patient and the healer was the religious belief that disease was the outcome of 'curse from God' or the belief in magic that the affliction had supernatural origin from 'evil eye of spirits.' To ward them off, priests through prayers and sacrifices, and magicians by magic power used to act as faith-healers and invoke supernatural powers and please the gods. Remnants of ancient superstitions still exist in some parts of the world.

But the real practice of medicine began with *Hippocrates* (460–370 BC), the great Greek clinical genius of all times and regarded as ‘the father of medicine’ (**Web Image 1.1**). Hippocrates followed rational and ethical attitudes in practice and teaching of medicine as expressed in the collection of writings of that era. He firmly believed in study of patient’s symptoms and described methods of diagnosis.

Hippocrates introduced ethical concepts in the practice of medicine and is revered by the medical profession by taking ‘*Hippocratic oath*’ at the time of entry into practice of medicine.

Hippocratic teaching was propagated in Rome by Roman physicians, notably by *Cornelius Celsus* (53 BC–7 AD) and *Cladius Galen* (130–200 AD). Celsus first described four cardinal signs of inflammation—*rubor* (redness), *tumor* (swelling), *calor* (heat), and *dolor* (pain). Galen postulated humoral theory, later called Galenic theory.

The hypothesis of disequilibrium of four elements constituting the body (*Dhatus*) similar to Hippocratic doctrine finds mention in ancient Indian medicine books compiled about 200 AD—*Charaka Samhita* and *Sushruta Samhita*.

□ FROM HUMAN ANATOMY TO ERA OF GROSS PATHOLOGY (AD 1500 TO 1800) (p. 3)

The backwardness of Medieval period was followed by the Renaissance period i.e. revival of learning. Dissection of human body was started by *Vesalius* (1514–1564) on executed criminals. His pupils, *Gabriel Fallopius* (1523–1562) who described human oviducts (Fallopian tubes) and *Fabricius* who discovered lymphoid tissue around the intestine of birds (bursa of Fabricius) further popularised the practice of human anatomic dissection for which special postmortem amphitheatres came in to existence in various parts of ancient Europe (**Web Image 1.2**).

Antony van Leeuwenhoek (1632–1723), a cloth merchant by profession in Holland, during his spare time invented the first ever microscope.

The credit for beginning of the study of morbid anatomy (pathologic anatomy), however, goes to Italian anatomist-pathologist, *Giovanni B. Morgagni* (1682–1771). He laid the foundations of clinicopathologic methodology in the study of disease and introduced the concept of clinicopathologic correlation (CPC), establishing a coherent sequence of cause, lesions, symptoms, and outcome of disease (**Web Image 1.3**).

Sir Percival Pott (1714–1788), famous surgeon in England, identified the first ever occupational cancer in the chimney sweeps in 1775 and discovered chimney soot as the first carcinogenic agent. However, the study of anatomy in England during the latter part of 18th Century was dominated by the two Hunter brothers: *John Hunter* (1728–1793), a student of Sir Percival Pott, rose to become greatest surgeon-anatomist of all times and he, together with his elder brother *William Hunter* (1718–1788) who was a reputed anatomist-obstetrician (or man-midwife), started the first ever museum of pathologic anatomy (**Web Image 1.4**).

R.T.H. Laennec (1781–1826), a French physician, dominated the early part of 19th century by his numerous discoveries. He described several lung diseases (tubercles, caseous lesions, miliary lesions, pleural effusion, bronchiectasis), chronic sclerotic liver disease (later called Laennec’s cirrhosis) and invented stethoscope.

Morbid anatomy attained its zenith with appearance of *Carl F. von Rokitansky* (1804–1878), self-taught German pathologist who performed nearly 30,000 autopsies himself.

□ ERA OF TECHNOLOGY DEVELOPMENT AND CELLULAR PATHOLOGY (AD 1800 TO 1950s) (p. 4)

Pathology started developing as a diagnostic discipline in later half of the 19th century with the evolution of cellular pathology which was closely linked to

technology advancements in machinery manufacture for cutting thin sections of tissue, improvement in microscope, and development of chemical industry and dyes for staining.

The discovery of existence of disease-causing micro-organisms was made by French chemist *Louis Pasteur* (1822–1895). Subsequently, *G.H.A. Hansen* (1841–1912) in Germany identified Hansen's bacillus as causative agent for leprosy (Hansen's disease) in 1873.

Developments in chemical industry helped in switch over from earlier dyes of plant and animal origin to synthetic dyes. The impetus for the flourishing and successful dye industry came from the works of numerous pioneers as under:

- ◆ *Paul Ehrlich* (1854–1915), described Ehrlich's test for urobilinogen using Ehrlich's aldehyde reagent, staining techniques of cells and bacteria, and laid the foundations of clinical pathology (**Web Image 1.5**).
- ◆ *Christian Gram*, who developed bacteriologic staining by crystal violet.
- ◆ *D.L. Romanowsky*, Russian physician, who developed stain for peripheral blood film using eosin and methylene blue derivatives.
- ◆ *Robert Koch*, German bacteriologist who, besides Koch's postulate and Koch's phenomena, developed techniques of fixation and staining for identification of bacteria, discovered tubercle bacilli in 1882 and cholera vibrio organism in 1883.
- ◆ *May-Grunwald* and *Giemsa* developed blood stains.
- ◆ *Sir William Leishman* described Leishman's stain for blood films.
- ◆ *Robert Feulgen* described Feulgen reaction for DNA staining.

Until the end of the 19th century, the study of morbid anatomy had remained largely autopsy-based and thus had remained a retrospective science. *Rudolf Virchow* (1821–1905) in Germany is credited with the beginning of microscopic examination of diseased tissue at cellular level and thus began histopathology as a method of investigation. Virchow gave two major hypotheses:

- ◆ All cells come from other cells.
- ◆ Disease is an alteration of normal structure and function of these cells.

Virchow came to be referred as Pope in pathology in Europe and is aptly known as the 'father of cellular pathology' (**Web Image 1.6**).

The concept of frozen section examination when the patient was still on the operation table was introduced by Virchow's student, *Julius Cohnheim* (1839–1884).

The concept of surgeon and physician doubling up in the role of pathologist which started in the 19th century continued as late as the middle of the 20th century in most clinical departments. Assigning biopsy pathology work to some faculty member in the clinical department was common practice; that is why some of the notable pathologists of the first half of 20th century had background of clinical training.

A few other landmarks in further evolution of modern pathology in this era are as follows:

- ◆ *Karl Landsteiner* (1863–1943) described the existence of major human blood groups in 1900 and was awarded Nobel prize in 1930 and is considered father of blood transfusion (**Web Image 1.7**).
- ◆ *Ruska* and *Lorries* in 1933 developed electron microscope which aided the pathologist to view ultrastructure of cell and its organelles.
- ◆ The development of exfoliative cytology for early detection of cervical cancer began with *George N. Papanicolaou* (1883–1962), in 1930s who is known as 'father of exfoliative cytology' (**Web Image 1.8**).

Another pioneering contribution in pathology in the 20th century was by an eminent teacher-author, *William Boyd* (1885–1979), dominated and inspired the students of pathology all over the world due to his flowery language and lucid style for about 50 years till 1970s (**Web Image 1.9**).

4 MODERN PATHOLOGY (1950s TO PRESENT TIMES) (p. 6)

Section I

General Pathology and Basic Techniques

The strides made in the latter half of 20th century until the beginning of 21st century have made it possible to study diseases at molecular level, and provide an evidence-based and objective diagnosis and enable the physician to institute appropriate therapy. Some of the revolutionary discoveries during this time are as under (**Web Image 1.10**):

- ◆ Description of the structure of DNA of the cell by *Watson and Crick* in 1953.
- ◆ Identification of chromosomes and their correct number in humans (46) by *Tijo and Levan* in 1956.
- ◆ Identification of Philadelphia chromosome t(9;22) in chronic myeloid leukaemia by *Nowell and Hagerford* in 1960 as the first chromosomal abnormality in any cancer.
- ◆ Flexibility and dynamism of DNA invented by *Barbara McClintock* for which she was awarded Nobel prize in 1983.
- ◆ In 1998, researchers in US found a way of harvesting stem cells, a type of primitive cells, from embryos and maintaining their growth in the laboratory, and thus started the era of *stem cell research*. Stem cells are seen by many researchers as having virtually unlimited application in the treatment of many human diseases such as Alzheimer's disease, diabetes, cancer, strokes, etc.
- ◆ In April 2003, Human Genome Project (HGP) consisting of a consortium of countries, was completed which coincided with 50 years of description of DNA double helix by *Watson and Crick* in April 1953. The *sequencing of human genome* reveals that human genome contains approximately 3 billion of the base pairs, which reside in the 23 pairs of chromosomes within the nucleus of all human cells. Each chromosome contains an estimated 30,000 genes in the human genome.

These inventions have set in an era of human molecular biology which is no longer confined to research laboratories but is ready for application as a modern diagnostic and therapeutic tool.

Human pathology is the largest branch of pathology. It is conventionally divided into *General Pathology* dealing with general principles of disease, and *Systemic Pathology* that includes study of diseases pertaining to the specific organs and body systems.

A. HISTOPATHOLOGY. Histopathology, used synonymously with anatomic pathology, pathologic anatomy, or morbid anatomy, is the classic method of study and still the most useful one which has stood the test of time. It includes the following 3 main subdivisions:

1. **Surgical pathology** deals with the study of tissues removed from the living body.
2. **Forensic pathology and autopsy work** includes the study of organs and tissues removed at postmortem for medicolegal work and for determining the underlying sequence and cause of death.
3. **Cytopathology** includes study of cells shed off from the lesions (exfoliative cytology) and fine-needle aspiration cytology (FNAC) of superficial and deep-seated lesions for diagnosis.

B. HAEMATOLOGY deals with the diseases of blood.

C. CHEMICAL PATHOLOGY includes analysis of biochemical constituents of blood, urine, semen, CSF and other body fluids.

1. **The concept of clinicopathologic correlation (CPC) by study of morbid anatomy was introduced by:**
 - A. Hippocrates
 - B. Virchow
 - C. John Hunter
 - D. Morgagni
2. **The first ever museum of pathologic anatomy was developed by:**
 - A. John Hunter
 - B. Rokitansky
 - C. Rudolf Virchow
 - D. Morgagni
3. **ABO human blood group system was first described by:**
 - A. Edward Jenner
 - B. Karl Landsteiner
 - C. Hippocrates
 - D. Laennec
4. **Frozen section was first introduced by:**
 - A. Cohnheim
 - B. Ackerman
 - C. Virchow
 - D. Feulgen
5. **Electron microscope was first developed by:**
 - A. Barbara McClintock
 - B. Watson and Crick
 - C. Tijo and Levan
 - D. Ruska and Lorries
6. **Structure of DNA of the cell was described by:**
 - A. Watson and Crick
 - B. Tijo and Levan
 - C. Ruska and Lorries
 - D. Barbara McClintock
7. **Flexibility and dynamism of DNA was invented by:**
 - A. Watson and Crick
 - B. Tijo and Levan
 - C. Ruska and Lorries
 - D. Barbara McClintock
8. **Father of cellular pathology is:**
 - A. Carl Rokitansky
 - B. Rudolf Virchow
 - C. G. Morgagni
 - D. FT Schwann
9. **Humans genome consists of following number of genes:**
 - A. 20,000
 - B. 30,000
 - C. 50,000
 - D. 100,000
10. **Stem cell research consists of:**
 - A. Human cells grown *in vitro*
 - B. Plant cells grown *in vitro*
 - C. Cadaver cells grown *in vitro*
 - D. Synonymous with PCR
11. **PCR technique was introduced by:**
 - A. Ian Wilmut
 - B. Watson
 - C. Nowell Hagerford
 - D. Kary Mullis
12. **Human genome project was completed in:**
 - A. 2001
 - B. 2002
 - C. 2003
 - D. 2004

KEY

- | | | | |
|-------|--------|--------|--------|
| 1 = D | 2 = A | 3 = B | 4 = A |
| 5 = D | 6 = A | 7 = D | 8 = B |
| 9 = B | 10 = A | 11 = D | 12 = C |



Techniques for the Study of Pathology

AUTOPSY PATHOLOGY (p. 9)

Professor William Boyd in his unimitable style wrote 'Pathology had its beginning on the autopsy table'. The significance of study of autopsy in pathology is summed up in Latin inscription in an autopsy room translated in English as "The place where death delights to serve the living".

Traditionally, there are two methods for carrying out autopsy:

1. Block extraction of abdominal and thoracic organs.
 2. *In situ* organ-by-organ dissection.
- The study of autopsy throws new light on the knowledge and skills of both physician as well as pathologist. The main *purposes* of autopsy are as under:

1. *Quality assurance of patientcare* by:
 - i) confirming the cause of death;
 - ii) establishing the final diagnosis; and
 - iii) study of therapeutic response to treatment.
2. *Education of the entire team* involved in patientcare by:
 - i) making autopsy diagnosis of conditions which are often missed clinically
 - ii) discovery of newer diseases made at autopsy
 - iii) study of demography and epidemiology of diseases; and
 - iv) education to students and staff of pathology.

Declining autopsy rate throughout world in the recent times is owing to the following reasons:

1. Higher diagnostic confidence made possible by advances in imaging techniques e.g. CT, MRI, angiography etc.
2. Physician's fear of legal liability on being wrong.

SURGICAL PATHOLOGY (p. 9)

Surgical pathology is the classic and time-tested method of tissue diagnosis made on gross and microscopic study of tissues.

With technology development and advances made in the dye industry in the initial years of 20th Century, the speciality of diagnostic surgical pathology by biopsy developed.

□ SURGICAL PATHOLOGY PROTOCOL (p. 10)

REQUEST FORMS. It must contain the entire relevant information about the case and the disease (history, physical and operative findings, results of other relevant biochemical/haematological/radiological investigations, and clinical and differential diagnosis) and reference to any preceding cytology or biopsy examination done in the pathology services.

TISSUE ACCESSION. The laboratory staff receiving the biopsy specimen must always match the ID of the patient on the request form with that on the specimen container. For routine tissue processing by paraffin-embedding technique, the tissue must be put in either appropriate fixative solution (most commonly 10% formol-saline or 10% buffered formalin) or received fresh-unfixed. For frozen section, the tissue is always transported fresh-unfixed.

GROSS ROOM. Proper gross tissue cutting, gross description and selection of representative tissue sample in larger specimens is a crucial part of the pathologic examination of tissue submitted.

Calcified tissues and bone are subjected to decalcification to remove the mineral and soften the tissue by treatment with decalcifying agents such as acids and chelating agents (most often aqueous nitric acid).

HISTOPATHOLOGY LABORATORY. Majority of histopathology departments use automated tissue processors (**Web Image 2.1**) having 12 separate stages completing the cycle in about 18 hours by overnight schedule:

- ◆ 10% formalin for fixation;
- ◆ ascending grades of alcohol (70%, 95% through 100%) for dehydration for about 5 hours in 6-7 jars,
- ◆ xylene/toluene/chloroform for clearing for 3 hours in two jars; and
- ◆ paraffin impregnation for 6 hours in two thermostat-fitted waxbaths.

Embedding of tissue is done in molten wax, blocks of which are prepared using metallic L (Leuckhart's) moulds. Nowadays, plastic moulds in different colours for blocking different biopsies are also available. The entire process of embedding of tissues and blocking can be temperature-controlled for which tissue embedding centres are available (**Web Image 2.2**). The blocks are then trimmed followed by sectioning by microtomy, most often by rotary microtome, employing either fixed knife or disposable blades (**Web Image 2.3**).

Cryostat or frozen section eliminates all the steps of tissue processing and paraffin-embedding. Instead, the tissue is quickly frozen to ice at about -25°C which acts as embedding medium and then sectioned (**Web Image 2.4**). Sections are then ready for staining. Frozen section is a rapid intraoperative diagnostic procedure for tissues before proceeding to a major radical surgery. Besides, it is also used for demonstration of certain constituents which are normally lost in processing in alcohol or xylene e.g. fat, enzymes etc.

Paraffin-embedded sections are routinely stained with haematoxylin and eosin (H & E). Frozen section is stained with rapid H & E or toluidine blue routinely. Special stains can be employed for either of the two methods according to need. The sections are mounted and submitted for microscopic study.

SURGICAL PATHOLOGY REPORT. The ideal report must contain following aspects:

- i) History
- ii) Precise gross description.
- iii) Brief microscopic findings.
- iv) Morphologic diagnosis which must include the organ for indexing purposes using SNOMED (Scientific Nomenclature in *Medicine*) codes.

QUALITY CONTROL. An internal quality control by mutual discussion in controversial cases and self-check on the quality of sections can be carried out informally in the set up. Presently, external quality control programme for the entire histopathology laboratory is also available.

HISTOPATHOLOGIST AND THE LAW. In equivocal biopsies and controversial cases, it is desirable to have internal and external consultations to avoid allegations of negligence and malpractice.

In certain 'special' circumstances when the pathologist wants to demonstrate certain specific substances or constituents of the cells to confirm etiologic, histogenic or pathogenetic components, special stains (also termed histochemical stains), are employed.

Some of the substances for which special stains are commonly used in a surgical pathology laboratory are amyloid, carbohydrates, lipids, proteins, nucleic acids, connective tissue, microorganisms, neural tissues, pigments, minerals; these stains are listed in **Web Table 2.1**.

Enzyme histochemical techniques require fresh tissues for cryostat section and cannot be applied to paraffin-embedded sections or formalin-fixed tissues since enzymes are damaged rapidly.

Presently, some of common applications of enzyme histochemistry in diagnostic pathology are in demonstration of muscle related enzymes (ATPase) in myopathies, acetylcholinesterase in diagnosis of Hirschsprung's disease, choloroacetate esterase for identification of myeloid cells and mast cells, DOPA reaction for tyrosinase activity in melanocytes, endogenous dehydrogenase (requiring nitroblue tetrazolium or NBT) for viability of cardiac muscle, and acid and alkaline phosphatases.

LIGHT MICROSCOPY. The usual type of microscope used in clinical laboratories is called *light microscope*. In general, there are two types of light microscopes:

Simple microscope. This is a simple hand magnifying lens. The magnification power of hand lens is from 2x to 200x.

Compound microscope. This has a battery of lenses which are fitted in a complex instrument. One type of lens remains near the object (objective lens) and another type of lens near the observer's eye (eye piece lens). The eyepiece and objective lenses have different magnification. The compound microscope can be *monocular* having single eyepiece or *binocular* which has two eyepieces (**Web Image 2.5**).

Dark ground illumination (DGI). This method is used for examination of unstained living microorganisms e.g. *Treponema pallidum*.

Polarising microscope. This method is used for demonstration of birefringence e.g. amyloid, foreign body, hair etc.

Immunofluorescence technique is employed to localise antigenic molecules on the cells by microscopic examination. This is done by using specific antibody against the antigenic molecule forming antigen-antibody complex at the specific antigenic site which is made visible by employing a fluorochrome which has the property to absorb radiation in the form of ultraviolet light.

FLUORESCENCE MICROSCOPE. Fluorescence microscopy is based on the principle that the exciting radiation from ultraviolet light of shorter wavelength (360 nm) or blue light (wavelength 400 nm) causes fluorescence of certain substances and thereafter re-emits light of a longer wavelength.

Source of light. Mercury vapour and xenon gas lamps are used as source of light for fluorescence microscopy.

Filters. A variety of filters are used between the source of light and objective.

Condenser. Dark-ground condenser is used in fluorescence microscope so that no direct light falls into the object and instead gives dark contrast background to the fluorescence.

TECHNIQUES. There are two types of fluorescence techniques both of which are performed on cryostat sections of fresh unfixed tissue: direct and indirect.

◆ In the *direct technique*, first introduced by Coons (1941) who did the original work on immunofluorescence, antibody against antigen is directly conjugated with the fluorochrome and then examined under fluorescence microscope.

◆ In the *indirect technique*, also called sandwich technique, there is interaction between tissue antigen and specific antibody, followed by a step of washing and then addition of fluorochrome for completion of reaction.

APPLICATIONS. These are as under:

1. *Detection of autoantibodies in the serum.*
2. *In renal diseases* for detection of deposits of immunoglobulins, complement and fibrin in various types of glomerular diseases.
3. *In skin diseases* to detect deposits of immunoglobulin in various bullous dermatosis.
4. For study of *mononuclear cell surface markers.*
5. For specific diagnosis of *infective disorders.*

ELECTRON MICROSCOPY (p. 14)

EM is currently applied to the following areas of diagnostic pathology:

1. In renal pathology in conjunction with light microscopy and immunofluorescence.
2. Ultrastructure of tumours of uncertain histogenesis.
3. Subcellular study of macrophages in storage diseases.
4. For research purposes.

There are two main types of EM:

1. **Transmission electron microscope (TEM).** TEM is the tool of choice for pathologist for study of ultrastructure of cell at organelle level. The magnification obtained by TEM is 2,000 to 10,000 times.
2. **Scanning electron microscope (SEM).** SEM scans the cell surface architecture and provides three-dimensional image. For example, for viewing the podocytes in renal glomerulus.

Technical Aspects (p. 15)

1. **Fixation.** Whenever it is planned to undertake EM examination of tissue, small thin piece of tissue not more than 1 mm thick should be fixed in 2-4% buffered glutaraldehyde or in mixture of formalin and glutaraldehyde.
2. **Embedding.** Tissue is plastic-embedded with resin on grid.
3. **Semithin sections.** First, semithin sections are cut at a thickness of 1 μm and stained with methylene blue or toluidine blue.
4. **Ultrathin sections.** For ultrastructural examination, ultrathin sections are cut by use of diamond knife.

Immunohistochemistry (IHC) is the application of immunologic techniques to the cellular pathology. The technique is used to detect the status and localisation of particular antigen in the cells (membrane, cytoplasm or nucleus) by use of specific antibodies which are then visualised by chromogen as brown colour. This then helps in determining cell lineage specifically, or is used to confirm a specific infection. IHC has revolutionised diagnostic pathology ("*brown revolution*") and in many sophisticated laboratories.

Now, it is possible to use routinely processed paraffin-embedded tissue blocks for IHC, thus making profound impact on diagnostic surgical pathology which has added *objectivity*, *specificity* and *reproducibility* to the surgical pathologist's diagnosis.

Major Applications of IHC (p. 16)

1. **Tumours of uncertain histogenesis.** Towards this, IHC stains for *intermediate filaments* (keratin, vimentin, desmin, neurofilaments, and glial fibrillary acidic proteins) expressed by the tumour cells are of immense value besides others listed in **Web Table 2.2**.
2. **Prognostic markers in cancer.** The second important application of IHC is to predict the prognosis of tumours by detection of micrometastasis, occult metastasis, and by identification of certain features acquired, or products

elaborated, or genes overexpressed, by the malignant cells to predict the biologic behaviour of the tumour.

3. Prediction of response to therapy. IHC is widely used to predict therapeutic response in two important tumours—carcinoma of the breast and prostate. The specific receptors for growth regulating hormones are located on respective tumour cells.

4. Infections. e.g. detection of viruses (HBV, CMV, HPV, herpesviruses), bacteria (e.g. *Helicobacter pylori*), and parasites (*Pneumocystis carinii*) etc.

CYTOGENETICS (p. 16)

Human somatic cells are diploid and contain 46 chromosomes: 22 pairs of autosomes and one pair of sex chromosomes (XX in the case of female and XY in the males). Gametes (sperm and ova) contain 23 chromosomes and are called *haploid cells*. All ova contain 23X while sperms contain either 23X or 23Y chromosomes. Thus, the sex of the offspring is determined by paternal chromosomal contribution i.e. if the ovum is fertilised by X-bearing sperm, female zygote results, while an ovum fertilised by Y-bearing sperm forms male zygote.

Karyotype is defined as the sequence of chromosomal alignment on the basis of size, centromeric location and banding pattern.

Determination of karyotype of an individual is an important tool in cytogenetic analysis. Broad outlines of karyotyping are as under:

1. Cell selection. Cells capable of growth and division are selected for cytogenetic analysis. These include: cells from amniotic fluid, chorionic villus (CVS) sampling, peripheral blood lymphocytes, bone marrow, lymph node, solid tumours etc.

2. Cell culture. The sample so obtained is cultured in mitogen media. A *mitogen* is a substance which induces mitosis in the cells e.g. PPD, phytohaemagglutinin (PHA), pokeweed mitogen (PWM), phorbol ester etc. The dividing cells are then arrested in metaphase.

3. Staining/banding. When stained, chromosomes have the property of forming alternating dark and light bands. For this purpose, fixed metaphase preparation is stained by one of the following banding techniques:

- Giemsa banding* or *G-banding*, the most commonly used.
- Quinacrine banding* or *Q-banding*.
- Constitutive banding* or *C-banding*.
- Reverse staining Giemsa banding* (or *R-banding*).

4. Microscopic analysis. Chromosomes are then photographed by examining the preparation under the microscope. The centromere divides the chromosome into a short upper arm called *p arm* (p for *petit* in French meaning 'short') and a long lower arm called *q arm* (letter q next to p).

Applications (p. 17)

- Chromosomal numerical abnormalities* e.g. Down's syndrome, Klinefelter's syndrome, Turner's syndrome, spontaneous abortions.
- Chromosome structural abnormalities* include translocations {e.g. Philadelphia chromosome, deletions, insertions, isochromosome, and ring chromosome formation.
- Cancer* is characterised by multiple and complex chromosomal abnormalities which include deletions, amplifications, inversions and translocations.

These techniques detect abnormalities at the level of DNA or RNA of the cell.

Broadly speaking, all the DNA/RNA-based molecular techniques employ hybridization (meaning joining together) technique based on recombinant technology.

1. IN SITU HYBRIDISATION. *In situ* hybridisation (ISH) is a molecular hybridisation technique which allows localisation of nucleic acid sequence directly in *the intact cell* (i.e. *in situ*) without DNA extraction.

ISH is used for the following:

- i) In *viral infections* e.g. HPV, EBV, HIV, CMV, HCV etc.
- ii) In *human tumours* for detection of gene expression and oncogenes.
- iii) In *chromosomal disorders*, particularly by use of fluorescent *in situ* hybridisation (FISH).

2. FILTER HYBRIDISATION. In this method, target DNA or RNA is extracted from the tissue. Hybridisation of the target DNA is then done with labelled probe and analysed by various methods:

- i) *Slot and dot blots*
- ii) *Southern blot*
- iii) *Northern blot*
- iv) *Western blot*.

Applications. These techniques have widespread applications in diagnostic pathology:

- i) In *neoplasia*, haematologic as well as non-haematologic.
- ii) In *infectious diseases*.
- iii) In *inherited genetic diseases*.
- iv) In *identity determination*.

3. POLYMERASE CHAIN REACTION. The technique is based on the *principle* that a single strand of DNA has limitless capacity to duplicate itself to form millions of copies. This is done using a *primer* which acts as an initiating template.

A cycle of PCR consists of three steps:

- i) *Heat denaturation* of DNA.
- ii) *Annealing* of the primers.
- iii) *Extension* of the annealed primers with DNA polymerase.

Applications. PCR analysis has the same applications as for filter hybridisation techniques and has many advantages over them in being more rapid, can be automated. However, PCR suffers from the risk of contamination.

□ FLOW CYTOMETRY (p. 18)

Flow cytometry is a modern tool used for the study of properties of cells suspended in a single moving stream. Flow cytometry, thus, overcomes the problem of subjectivity involved in microscopic examination of cells and tissues in histopathology and cytopathology.

Flow cytometric analysis finds uses in clinical practice in the following ways:

1. *Immunophenotyping*.
2. Measurement of *proliferation-associated antigens* e.g. Ki67, PCNA.
3. *Measurement of nucleic acid content*.
4. *Diagnosis and prognostication of immunodeficiency*.
5. To *diagnose the cause of allograft rejection* in renal transplantation.
6. *Diagnosis of autoantibodies*.

□ METHODS FOR CELL PROLIFERATION ANALYSIS (p. 18)

Besides flow cytometry, the degree of proliferation of cells in tumours can be determined by various other methods: **Mitotic count, Radioautography, Microspectrophotometric analysis, Immunohistochemistry, Nucleolar organiser region (NOR).**

12 **COMPUTERS IN PATHOLOGY LABORATORY** (p. 19)

There are two main purposes of having computers in the laboratory:

- ◆ for the *billing* of patients' investigations; and
- ◆ for *reporting* of results of tests in numeric, narrative and graphic format.

Applications

1. *Improved patient care.*
2. *Shortened turn-around time.*
3. *Improved productivity* of laboratory staff.
4. *Coding and indexing* of results and data of different tests.
5. For *research purposes* and getting *accreditation* so as to get grants for research.
6. *Storage and retrieval of laboratory data* to save time and space.

IMAGE ANALYSER AND MORPHOMETRY (p. 19)

Image analyser is a system that is used to perform measurement of architectural, cellular and nuclear features of cells.

Applications

1. *Morphometric study* of tumour cells.
2. *Quantitative nuclear DNA ploidy* measurement.
3. Quantitative valuation of *immunohistochemical staining*.

DNA MICROARRAYS (p. 19)

DNA microarray eliminates use of DNA probes. Fluorescent labelling of an array of DNA fragment (complimentary or cDNA) is used to hybridise with target from test sample. High resolution laser scanners are used for detecting fluorescent signals emitted.

DNA microarrays is used for molecular profiling of tumours which aids in arriving at specific histogenetic diagnosis and predicting prognosis.

LASER MICRODISSECTION (p. 19)

Laser microdissection is used for carrying out molecular profiling on tissue material. It involves dissection of a single cell or part of the cell (e.g. chromosomes) by sophisticated laser technology and employs software for the procedure.

TELEPATHOLOGY AND VIRTUAL MICROSCOPY (p. 19)

Telepathology is defined as the practice of diagnostic pathology by a remote pathologist utilising images of tissue specimens transmitted over a telecommunications network.

Depending upon need and budget, telepathology system is of two types:

- ◆ *Static (store-and-forward, passive telepathology).*
- ◆ *Dynamic (Robotic interactive telepathology).*

The era of "*digital pathology*" in 21st Century has reached its zenith with availability of technology for preparation of *virtual pathology slides (VPS)* by high speed scanners and then storing the scanned data in large memory output computers.

◆ **SELF ASSESSMENT**

1. **Frozen section is employed for the following purposes except:**
 - A. Fat demonstration
 - B. Amyloid
 - C. Rapid diagnosis
 - D. Enzymes
2. **For frozen section, the tissue should be sent to the laboratory as under:**
 - A. In 10% formalin
 - B. In Carnoy's fixative
 - C. In saline
 - D. Fresh unfixed

3. Decalcification of calcified tissue and bone is done by the following methods **except**:
 - A. Aqueous nitric acid
 - B. Chelating agents
 - C. Glacial acetic acid
 - D. Microwave
4. Fluorescent microscopy is employed for the following purposes **except**:
 - A. Glomerular diseases
 - B. Tumour of uncertain origin
 - C. Bullous dermatosis
 - D. Serum autoantibodies
5. Usual chromogens used in immunohistochemical staining techniques impart the following colour to indicate positivity:
 - A. Pink
 - B. Blue
 - C. Brown
 - D. Red
6. Immunohistochemistry is employed for the following purpose:
 - A. To distinguish neoplastic from non-neoplastic lesion
 - B. To distinguish benign and malignant lesion
 - C. To localise the cell of origin of tumour
 - D. To detect autoantibodies in the serum
7. Tissues for electron microscopy are fixed in:
 - A. Carnoy's fixative
 - B. 10% buffered formalin
 - C. Saline
 - D. 4% glutaraldehyde
8. For karyotyping, the dividing cells are arrested by addition of colchicine in the following mitotic phase:
 - A. Prophase
 - B. Metaphase
 - C. Anaphase
 - D. Telophase
9. For counting of CD4 + T cells in AIDS, the following technique is often employed:
 - A. In situ hybridisation
 - B. Polymerase chain reaction
 - C. Flow cytometry
 - D. Electron microscopy
10. DNA extraction is a pre-requisite for the following molecular techniques **except**:
 - A. PCR technique
 - B. In situ hybridisation
 - C. Western blot technique
 - D. Southern blot technique
11. Which of the following is a synthetic probe:
 - A. Genomic probe
 - B. cDNA probe
 - C. Oligonucleotide probe
 - D. Riboprobe
12. All are methods of cell proliferation analysis **except**:
 - A. Microspectrophotometry
 - B. Flow cytometry
 - C. PCR
 - D. Immunohistochemistry

KEY

- | | | | |
|-------|--------|--------|--------|
| 1 = B | 2 = D | 3 = C | 4 = B |
| 5 = C | 6 = C | 7 = D | 8 = B |
| 9 = C | 10 = B | 11 = C | 12 = C |



Cell Injury and Cellular Adaptations

Cell injury is defined as a variety of stresses a cell encounters as a result of changes in its internal and external environment. The cellular response to stress may vary and depends upon the following variables:

- i) The type of cell and tissue involved.
- ii) Extent and type of cell injury.

Various forms of cellular responses to cell injury may be as follows (**Web Image 3.1**):

1. When there is increased functional demand, the cell may adapt to the changes which are expressed morphologically and then revert back to normal after the stress is removed (*cellular adaptations*).
2. When the stress is mild to moderate, the injured cell may recover (*reversible cell injury*), while when the injury is persistent cell death may occur (*irreversible cell injury*).
3. The residual effects of reversible cell injury may persist in the cell as evidence of cell injury at subcellular level (*subcellular changes*), or metabolites may accumulate within the cell (*intracellular accumulations*).

A cell is enclosed by cell membrane that extends internally to enclose nucleus and various subcellular organelles suspended in cytosol (**Web Image 3.2**).

□ CELL MEMBRANE (p. 21)

Electron microscopy has shown that cell membrane or plasma membrane has a trilaminar structure having a total thickness of about 7.5 nm and is known as *unit membrane*. The three layers consist of two electron-dense layers separated by an electronlucent layer. Biochemically, the cell membrane is composed of complex mixture of phospholipids, glycolipids, cholesterol, proteins and carbohydrates.

In brief, the cell membrane performs the following important functions:

- i) Selective permeability that includes diffusion, membrane pump (sodium pump) and pinocytosis (cell drinking).
- ii) Bears membrane antigens (e.g. blood group antigens, transplantation antigen).
- iii) Possesses cell receptors for cell-cell recognition and communication.

□ NUCLEUS (p. 22)

The nucleus consists of an outer nuclear membrane enclosing nuclear chromatin and nucleoli.

The main substance of the nucleus is comprised by the nuclear chromatin which is in the form of shorter pieces of thread-like structures called *chromosomes* of which there are 23 pairs (46 chromosomes) together measuring about a metre in length in a human diploid cell. Depending upon the length of chromosomes and centromeric location, 46 chromosomes are categorised into 7 groups from A to G according to *Denver classification* (adopted at a meeting in Denver, USA).

Chromosomes are composed of 3 components, each with distinctive function. These are: deoxyribonucleic acid (DNA) comprising about 20%,

ribonucleic acid (RNA) about 10%, and the remaining 70% consists of nuclear proteins that include a number of basic proteins (histones), neutral proteins, and acid proteins. DNA of the cell is largely contained in the nucleus.

The **DNA molecule** as proposed by Watson and Crick in 1953 consists of two complementary polypeptide chains forming a double helical strand which is wound spirally around an axis composed of pentose sugar-phosphoric acid chains. The molecule is spirally twisted in a ladder-like pattern, the steps of which are composed of *4 nucleotide bases*: *two purines* (adenine and guanine, i.e. A and G) and *two pyrimidines* (cytosine and thymine, i.e. C and T); however, A pairs specifically with T while G pairs with C (**Web Image 3.3**).

In the interphase nucleus (i.e. between mitosis), part of the chromatin that remains relatively inert metabolically and appears deeply basophilic due to condensation of chromosomes is called *heterochromatin*, while the part of chromatin that is lightly stained (i.e. vesicular) due to dispersed chromatin is called *euchromatin*.

The nucleus may contain one or more rounded bodies called nucleoli. Nucleolus is the site of synthesis of ribosomal RNA.

□ **CYTOSOL AND ORGANELLES** (p. 23)

The cytosol or the cytoplasm is the gel-like ground substance in which the organelles (meaning *little organs*) of the cells are suspended. These organelles are the site of major enzymatic activities of the cell which are possibly mediated by enzymes in the cytosol.

1. CYTOSKELETON. Microfilaments, intermediate filaments, and microtubules are responsible for maintaining cellular form and movement and are collectively referred to as cytoskeleton.

i) Microfilaments are long filamentous structures having a diameter of 6-8 nm. They are composed of contractile proteins, actin and myosin, and diverse materials like parts of microtubules and ribonucleoprotein fibres.

ii) Intermediate filaments are filamentous structures, 10 nm in diameter, and are cytoplasmic constituent of a number of cell types. They are composed of proteins. There are 5 principal types of intermediate filaments:

- Cytokeratin* (found in epithelial cells).
- Desmin* (found in skeletal, smooth and cardiac muscle).
- Vimentin* (found in cells of mesenchymal origin).
- Glial fibrillary acidic protein* (present in astrocytes and ependymal cells).
- Neurofilaments* (seen in neurons of central and peripheral nervous system).

iii) Microtubules are long hollow tubular structures about 25 nm in diameter. They are composed of protein, tubulin. *Cilia* and *flagella* which project from the surface of cell are composed of microtubules enclosed by plasma membrane.

2. MITOCHONDRIA. Mitochondria are oval structures and are more numerous in metabolically active cells. They are enveloped by two layers of membrane—the outer smooth and the inner folded into incomplete septa or sheaf-like ridges called *cristae*.

Mitochondria perform the important metabolic function of oxidative phosphorylation, and in the process generate free radicals injurious to membranes.

3. RIBOSOMES. Ribosomes are spherical particles which contain 80-85% of the cell's RNA. They may be present in the cytosol as 'free' unattached form, or in 'bound' form when they are attached to membrane of endoplasmic reticulum. They may lie as 'monomeric units' or as 'polyribosomes'.

Ribosomes synthesise proteins by translation of messenger RNA into peptide sequences followed by packaging of proteins for the endoplasmic reticulum.

4. ENDOPLASMIC RETICULUM. Endoplasmic reticulum is composed of vesicles and intercommunicating canals. It is composed of unit membrane which is continuous with both nuclear membrane and the Golgi apparatus, and possibly with the cell membrane. The main function of endoplasmic reticulum is the manufacture of protein. Morphologically, there are 2 forms of endoplasmic reticulum: rough (or granular) and smooth (or agranular).

5. GOLGI APPARATUS. Morphologically, it appears as vesicles, sacs or lamellae composed of unit membrane and is continuous with the endoplasmic reticulum.

Its main functions are synthesis of carbohydrates and complex proteins and packaging of proteins synthesised in the RER into vesicles.

6. LYSOSOMES. Lysosomes are rounded to oval membrane-bound organelles containing powerful lysosomal digestive (hydrolytic) enzymes. There are 3 forms of lysosomes:

- i) *Primary lysosomes or storage vacuoles* are formed from the various hydrolytic enzymes synthesised by the RER and packaged in the Golgi apparatus.
- ii) *Secondary lysosomes or autophagic vacuoles* are formed by fusion of primary lysosomes with the parts of damaged or worn-out cell components.
- iii) *Residual bodies* are indigestible materials in the lysosomes, e.g. lipofuscin.

□ INTERCELLULAR COMMUNICATION (P. 24)

All cells in the body constantly exchange information with each other to perform their functions properly. This process is accomplished in the cells by direct cell-to-cell contact, and by chemical agents, also called as molecular agents or factors as under.

Intercellular Junctions (p. 24)

Plasma membranes of epithelial and endothelial cells, communicate across a space through intercellular junctions or junctional complexes visible under electron microscope and are of 4 types (**Web Image 3.4**):

1. Occluding junctions (Zonula occludens).
2. Adhering junctions (Zonula adherens).
3. Desmosomes (Macula densa).
4. Gap junctions (Nexus).

Molecular Interactions between Cells (p. 25)

Besides having intercellular junctions, most cells communicate at molecular level as follows:

1. CELL ADHESION MOLECULES (CAMs). These are chemicals which mediate the interaction between cells (cell-cell interaction) as well as between cells and extracellular matrix (cell-ECM interaction). The ECM is the ground substance or matrix of connective tissue which provides environment to the cells and consists of 3 components:

- i) fibrillar structural proteins (collagen, elastin);
- ii) adhesion proteins (fibronectin, laminin, fibrillin, osteonectin, tenacin); and
- iii) molecules of proteoglycans and glycosaminoglycans (heparan sulphate, chondroitin sulphate, dermatan sulphate, keratan sulphate, hyaluronic acid).

There are 5 groups of CAMs:

i) Integrins. They have alpha (or CD11) and beta (CD18) subunits and have a role in cell-ECM interactions and in leucocyte-endothelial cell interaction.

ii) Cadherins. Various types of cadherins include: E-cadherin (epithelial cell), N-cadherin (nerve cell), M-cadherin (muscle cell), and P-cadherin (placenta).

iii) Selectins. Selectins are of 3 types: *P-selectin* (from platelets, also called CD62), *E-selectin* (from endothelial cells, also named ECAM), and *L-selectin* (from leucocytes, also called LCAM).

iv) Immunoglobulin superfamily. This group consists of a variety of immunoglobulin molecules present on most cells of the body. This group includes ICAM-1,2 (intercellular adhesion molecule, also called CD54), VCAM (vascular cell adhesion molecule, also named CD106), NCAM (neural cell adhesion molecule).

v) CD44. CD44 molecule binds to hyaluronic acid and is expressed on leucocytes.

2. CYTOKINES. Cytokines are soluble proteins secreted by haemopoietic and non-haemopoietic cells in response to various stimuli. Their main role is in activation of immune system. Presently, about 200 cytokines have been identified which are grouped in 6 categories:

- i) Interferons (IFN)
- ii) Interleukins (IL)
- iii) Tumour necrosis factor group (TNF, cachectin)
- iv) Transforming growth factor (TGF)
- v) Colony stimulating factor (CSF)
- vi) Growth factors (e.g. platelet-derived growth factor PDGF, epidermal growth factor EGF, fibroblast growth factor FGF, endothelial-derived growth factor EDGF, transforming growth factor TGF).

3. CELL MEMBRANE RECEPTORS. Cell receptors are molecules consisting of proteins, glycoproteins or lipoproteins and may be located on the outer cell membrane, inside the cell, or may be trans-membranous. These receptor molecules are synthesised by the cell itself depending upon their requirement, and thus there may be upregulation or downregulation of number of receptors. There are 3 main types of receptors:

- i) Enzyme-linked receptors.** These receptors are involved in control of cell growth e.g. tyrosine kinase associated receptors.
- ii) Ion channels.** The activated receptor for ion exchange such as for sodium, potassium and calcium and certain peptide hormones.
- iii) G-protein receptors.** These are trans-membranous receptors and activate phosphorylating enzymes for metabolic and synthetic functions of cells.

□ HEAT SHOCK PROTEINS AND UBIQUITIN (p. 26)

Two proteins which move molecules within the cell cytoplasm are *heat shock proteins (HSP)* (also called *stress proteins*) and *ubiquitin* (so named due to its universal presence in the cells of the body).

HSPs. These are a variety of intracellular carrier proteins present in most cells of the body, especially in renal tubular epithelial cells. They normally perform the role of *chaperones* (house-keeping) i.e. they direct and guide metabolic molecules to the sites of metabolic activity e.g. protein folding, disaggregation of protein-protein complexes.

Ubiquitin. Like HSPs, ubiquitin too directs intracellular molecules for either degradation or for synthesis. Ubiquitin has been found to be involved in a variety of human degenerative diseases.

□ CELL CYCLE (p. 26)

Multiplication of the somatic (mitosis) and germ (meiosis) cells is the most complex of all cell functions. Mitosis-promoting protein molecules are *cyclins A, B and E*. These cyclins activate *cyclin-dependent kinases (CDKs)* which act in conjunction with cyclins.

Period between the mitosis is called *interphase*. The *cell cycle* is the phase between two consecutive divisions (**Web Image 3.5**). There are

4 sequential phases in the cell cycle: G_1 (gap 1) phase, S (synthesis) phase, G_2 (gap 2) phase, and M (mitotic) phase.

G_1 (Pre-mitotic gap) phase is the stage when messenger RNAs for the proteins and the proteins themselves required for DNA synthesis (e.g. DNA polymerase) are synthesised. The process is under control of cyclin E and CDKs.

S phase involves replication of nuclear DNA. Cyclin A and CDKs control it.

G_2 (Pre-mitotic gap) phase is the short gap phase in which correctness of DNA synthesised is assessed. This stage is promoted by cyclin B and CDKs.

M phase is the stage in which process of mitosis to form two daughter cells is completed. This occurs in 4 sequential stages: *prophase*, *metaphase*, *anaphase*, and *telophase* (acronym= PMAT).

G_0 phase. The daughter cells may continue to remain in the cell cycle and divide further, or may go out of the cell cycle into resting phase, called G_0 phase.

The cells may be injured by two major ways:

- A. By genetic causes
- B. By acquired causes

Based on underlying agent, the acquired causes of cell injury can be further categorised as under:

1. HYPOXIA AND ISCHAEMIA. Deficiency of oxygen or hypoxia results in failure to carry out these activities by the cells. Hypoxia is the most common cause of cell injury. Hypoxia may result from the following:

- Reduced supply of blood to cells due to interruption i.e. ischaemia.
- From other causes, e.g. disorders of oxygen-carrying RBCs (e.g. anaemia, carbon monoxide poisoning), heart diseases, lung diseases and increased demand of tissues.

2. PHYSICAL AGENTS. Physical agents in causation of disease are: mechanical trauma (e.g. road accidents); thermal trauma (e.g. by heat and cold); electricity; radiation (e.g. ultraviolet and ionising); and rapid changes in atmospheric pressure.

3. CHEMICALS AND DRUGS. Important examples include: chemical poisons such as cyanide, arsenic, mercury; strong acids and alkalis; environmental pollutants; insecticides and pesticides; oxygen at high concentrations; hypertonic glucose and salt; social agents such as alcohol and narcotic drugs; and therapeutic administration of drugs.

4. MICROBIAL AGENTS. Injuries by microbes include infections caused by bacteria, rickettsiae, viruses, fungi, protozoa, metazoa, and other parasites.

5. IMMUNOLOGIC AGENTS. Immunity is a 'double-edged sword'—it protects the host against various injurious agents but it may also turn lethal and cause cell injury, e.g. hypersensitivity reactions; anaphylactic reactions; and autoimmune diseases.

6. NUTRITIONAL DERANGEMENTS. Nutritional deficiency diseases may be due to overall deficiency of nutrients (e.g. starvation), of protein calorie (e.g. marasmus, kwashiorkor), of minerals (e.g. anaemia), or of trace elements.

Nutritional excess is a problem of affluent societies resulting in obesity, atherosclerosis, heart disease and hypertension.

7. AGING. Cellular aging or senescence leads to impaired ability of the cells to undergo replication and repair, and ultimately lead to cell death culminating in death of the individual.

8. PSYCHOGENIC DISEASES. There are no specific biochemical or morphologic changes in common acquired mental diseases. However, problems of drug addiction, alcoholism, and smoking result in various organic diseases such as liver damage, chronic bronchitis, lung cancer, peptic ulcer, hypertension, ischaemic heart disease etc.

9. IATROGENIC CAUSES. There are some diseases as well as deaths attributed to iatrogenic causes (owing to physician). Examples include occurrence of disease or death due to error in judgment by the physician and untoward effects of administered therapy (drugs, radiation).

10. IDIOPATHIC DISEASES. Finally, there remain many diseases for which exact cause is undetermined. For example, most common form of hypertension (90%) is idiopathic (or essential) hypertension. Similarly, exact etiology of many cancers is still incompletely known.

Injury to the normal cell by one or more of the above listed etiologic agents may result in a state of reversible or irreversible cell injury. In general, the following *principles* apply in pathogenesis of most forms of cell injury by various agents:

1. Type, duration and severity of injurious agent: e.g. small dose of chemical toxin or short duration of ischaemia cause reversible cell injury while large dose of the same chemical agent or persistent ischaemia cause cell death.

2. Type, status and adaptability of target cell: e.g. skeletal muscle can withstand hypoxic injury for long-time while cardiac muscle suffers irreversible cell injury after 20-30 minutes of persistent ischaemia.

3. Underlying intracellular phenomena: Following essential biochemical phenomena underlie all forms of cell injury:

- i) Mitochondrial damage causing ATP depletion.
- ii) Cell membrane damage disturbing the metabolic and trans-membrane exchanges.
- iii). Release of toxic free radicals.

4. Morphologic consequences: The ultrastructural changes become apparent earlier than the light microscopic alterations.

□ PATHOGENESIS OF ISCHAEMIC AND HYPOXIC INJURY (p. 29)

Ischaemia and hypoxia are the most common forms of cell injury (**Web Images 3.6 and 3.7**):

REVERSIBLE CELL INJURY. If the ischaemia or hypoxia is of short duration, the effects may be reversible on rapid restoration of circulation.

1. Decreased generation of cellular ATP: Damage by ischaemia versus hypoxia from other causes. ATP in human cell is derived from 2 sources:

firstly, by aerobic respiration or oxidative phosphorylation (which requires oxygen) in the mitochondria, and

secondly, cells may switch over to anaerobic glycolytic oxidation to maintain constant supply of ATP (in which ATP is generated from glucose/glycogen in the absence of oxygen).

◆ In *ischaemia*, aerobic respiration as well as glucose availability are both compromised resulting in more severe and faster effects of cell injury.

◆ In *hypoxia from other causes* (RBC disorders, heart disease, lung disease), anaerobic glycolytic ATP generation continues, and thus cell injury is less severe.

However, highly specialised cells such as myocardium, proximal tubular cells of the kidney, and neurons of the CNS are dependent solely on aerobic

respiration for ATP generation and thus these tissues suffer from ill-effects of ischaemia more severely and rapidly.

2. Intracellular lactic acidosis: Nuclear clumping. Due to low oxygen supply to the cell, aerobic respiration by mitochondria fails first. This is followed by switch to anaerobic glycolytic pathway for the requirement of energy (i.e. ATP). This results in rapid depletion of glycogen and accumulation of lactic acid lowering the intracellular pH. Early fall in intracellular pH (i.e. intracellular lactic acidosis) results in clumping of nuclear chromatin.

3. Damage to plasma membrane pumps: Hydropic swelling and other membrane changes. Lack of ATP interferes in generation of phospholipids from the cellular fatty acids which are required for continuous repair of membranes. This results in damage to membrane pumps operating for regulation of sodium and calcium.

Ultrastructural evidence of reversible cell membrane damage is seen in the form of loss of microvilli, intramembranous particles and focal projections of the cytoplasm (blebs). *Myelin figures* may be seen lying in the cytoplasm or present outside the cell, these are derived from membranes (plasma or organellar) enclosing water and dissociated lipoproteins between the lamellae of injured membranes.

4. Reduced protein synthesis: Dispersed ribosomes. As a result of continued hypoxia, ribosomes are detached from granular endoplasmic reticulum and polysomes are degraded to monosomes, thus dispersing ribosomes in the cytoplasm and inactivating their function.

Up to this point, withdrawal of acute stress that resulted in reversible cell injury can restore the cell to normal state.

IRREVERSIBLE CELL INJURY. Persistence of ischaemia or hypoxia results in irreversible damage to the structure and function of the cell (cell death). The stage at which this *point of no return or irreversibility* is reached from reversible cell injury is unclear but the sequence of events is a continuation of reversibly injured cell. Two essential phenomena always distinguish irreversible from reversible cell injury:

- ◆ Inability of the cell to reverse *mitochondrial dysfunction* on reperfusion or reoxygenation.

- ◆ *Disturbance in cell membrane function* in general, and in plasma membrane in particular.

1. Calcium influx: Mitochondrial damage. As a result of continued hypoxia, a large cytosolic influx of calcium ions occurs, especially after reperfusion of irreversibly injured cell. Excess intracellular calcium collects in the mitochondria disabling its function.

2. Activated phospholipases: Membrane damage. Damage to membrane function in general, and plasma membrane in particular, is the most important event in irreversible cell injury in ischaemia. Increased calcium activates endogenous *phospholipases*. These in turn degrade membrane phospholipids progressively. Other lytic enzyme which is activated is *ATPase* which causes further depletion of ATP.

3. Intracellular proteases: Cytoskeletal damage. The normal cytoskeleton of the cell (microfilaments, microtubules and intermediate filaments) which anchors the cell membrane is damaged due to degradation by activated intracellular proteases.

4. Activated endonucleases: Nuclear damage. The nucleoproteins are damaged by the activated lysosomal enzymes such as proteases and endonucleases. Irreversible damage to the nucleus can be in three forms: (i) *Pyknosis*, (ii) *Karyorrhexis*, and (iii) *Karyolysis*.

5. Lysosomal hydrolytic enzymes: Lysosomal damage, cell death and phagocytosis. The lysosomal membranes are damaged and result in

escape of lysosomal hydrolytic enzymes, e.g. hydrolase, RNAase, DNAase, protease, glycosidase, phosphatase, lipase, amylase, cathepsin etc). The dead cell is eventually replaced by masses of phospholipids called *myelin figures* which are either phagocytosed by macrophages or there may be formation of calcium soaps.

Liberated enzymes just mentioned leak across the abnormally permeable cell membrane into the serum, the estimation of which may be used as clinical parameters of cell death. For example, in myocardial infarction, estimation of elevated serum glutamic oxaloacetic transaminase (SGOT), lactic dehydrogenase (LDH), isoenzyme of creatine kinase (CK-MB), and cardiac troponins (cTn) are useful guides for death of heart muscle. Some of the common enzyme markers of cell death in different forms of cell death are given in **Web Table 3.1**.

Ischaemia-Reperfusion Injury and Free Radical-Mediated Cell Injury (p. 31)

Depending upon the duration of ischaemia/hypoxia, restoration of blood flow may result in the following 3 different consequences:

- 1. From ischaemia to reversible injury.** *When the period of ischaemia is of short duration*, reperfusion with resupply of oxygen restores the structural and functional state of the injured cell i.e. reversible cell injury.
- 2. From ischaemia to reperfusion injury.** *When ischaemia is for longer duration*, then rather than restoration of structure and function of the cell, reperfusion paradoxically deteriorates the already injured cell. This is termed ischaemia-reperfusion injury.
- 3. From ischaemia to irreversible injury.** *Much longer period of ischaemia* may produce irreversible cell injury *during ischaemia itself* when so much time has elapsed that neither blood flow restoration is helpful nor reperfusion injury can develop.

The underlying mechanism of reperfusion injury and free radical mediated injury involves three main components:

1. CALCIUM OVERLOAD. Upon restoration of blood supply, the ischaemic cell is further bathed by the blood fluid that has more calcium ions at a time when the ATP stores of the cell are low. This results in further calcium overload on the already injured cells, triggering lipid peroxidation of the membrane causing further membrane damage.

2. GENERATION OF REACTIVE OXYGEN RADICALS. Although oxygen is the lifeline of all cells and tissues, its molecular forms as reactive oxygen radicals or reactive oxygen species can be most devastating for the cells.

Mechanism of oxygen free radical generation. The reaction of O_2 to H_2O involves 'four electron donation' in four steps involving transfer of one electron at each step. Oxygen free radicals are the intermediate chemical species having an unpaired oxygen in their outer orbit. Three intermediate molecules of partially reduced species of oxygen are generated depending upon the number of electrons transferred (**Web Image 3.8**):

- ◆ Superoxide oxygen (O_2^-): one electron
- ◆ Hydrogen peroxide (H_2O_2): two electrons
- ◆ Hydroxyl radical (OH^-): three electrons

Other oxygen free radicals. *Nitric oxide (NO), hypochlorous acid (HOCl).*

Cytotoxicity of oxygen free radicals. The net effect of free radical injury in physiologic and disease states, depends upon the rate of free radical formation and rate of their elimination.

However, if not degraded, then free radicals are highly destructive to the cell since they have electron-free residue and thus bind to all molecules of the cell; this is termed *oxidative stress*. Out of various free radicals, hydroxyl

radical is the most reactive species. Free radicals may produce membrane damage by the following mechanisms (**Web Image 3.9**):

- i) *Lipid peroxidation.*
- ii) *Oxidation of proteins.*
- iii) *DNA damage.*
- iv) *Cytoskeletal damage.*

Conditions with free radical injury. Ischaemic reperfusion injury, ionising radiation by causing radiolysis of water, chemical toxicity, chemical carcinogenesis, hyperoxia (toxicity due to oxygen therapy), cellular aging, killing of microbial agents, inflammatory damage, destruction of tumour cells, and atherosclerosis.

Antioxidants. Antioxidants are endogenous or exogenous substances which inactivate the free radicals. These substances include: vitamins E, A and C (ascorbic acid), sulfhydryl-containing compounds e.g. cysteine and glutathione, serum proteins e.g. ceruloplasmin and transferrin.

3. SUBSEQUENT INFLAMMATORY REACTION. Ischaemia-reperfusion event is followed by inflammatory reaction. Incoming activated neutrophils utilise oxygen quickly (*oxygen burst*) and release a lot of oxygen free radicals.

PATHOGENESIS OF CHEMICAL INJURY (p. 33)

Chemicals induce cell injury by one of the two mechanisms:

DIRECT CYTOTOXIC EFFECTS e.g. in mercuric chloride poisoning, chemotherapeutic agents used in treatment of cancer, toxic heavy metals such as mercury, lead and iron.

CONVERSION TO REACTIVE TOXIC METABOLITES e.g. toxic liver necrosis caused by carbon tetrachloride (CCl_4), acetaminophen (commonly used analgesic and antipyretic) and bromobenzene.

PATHOGENESIS OF PHYSICAL INJURY (p. 34)

Killing of cells by *ionising radiation* is the result of direct formation of hydroxyl radicals from radiolysis of water (**Web Image 3.10**). These hydroxyl radicals damage the cell membrane as well as may interact with DNA of the target cell.

Depending upon the severity of cell injury, degree of damage and residual effects on cells and tissues are variable (**Web Table 3.2**).

MORPHOLOGY OF REVERSIBLE CELL INJURY (p. 34)

Hydropic Change (p. 34)

Other synonyms used are *cloudy swelling* (for gross appearance of the affected organ) and *vacuolar degeneration* (due to cytoplasmic vacuolation).

The common causes include acute and subacute cell injury from various etiologic agents such as bacterial toxins, chemicals, poisons, burns, high fever, intravenous administration of hypertonic glucose or saline etc.

Cloudy swelling results from impaired regulation of sodium and potassium at the level of cell membrane. This results in intracellular accumulation of sodium and escape of potassium. This, in turn, leads to rapid flow of water into the cell to maintain iso-osmotic conditions and hence cellular swelling occurs. Hydropic swelling is an entirely reversible change upon removal of the injurious agent.

G/A The affected organ such as kidney, liver, pancreas, or heart muscle is enlarged due to swelling. The cut surface bulges outwards and is slightly opaque.

M/E (Web Image 3.11): The features are as under:

- i) The cells are swollen and the microvasculature compressed.
- ii) Small clear vacuoles are seen in the cells and hence the term vacuolar degeneration.
- iii) Small cytoplasmic blebs may be seen.
- iv) The nucleus may appear pale.

Hyaline Change (p. 35)

The word 'hyaline' means glassy (*hyalos* = glass). Hyaline is a descriptive histologic term for glassy, homogeneous, eosinophilic appearance of material in haematoxylin and eosin-stained sections. It may be intracellular or extracellular.

INTRACELLULAR HYALINE e.g.

1. *Hyaline droplets* in the proximal tubular epithelial cells in cases of excessive reabsorption of plasma proteins.
2. *Hyaline degeneration* of rectus abdominalis muscle, Zenker's degeneration, occurring in typhoid fever.
3. *Mallory's hyaline* represents aggregates of intermediate filaments in the hepatocytes in alcoholic liver cell injury.
4. Nuclear or cytoplasmic *hyaline inclusions* seen in some viral infections.
5. *Russell's bodies* representing excessive immunoglobulins in the rough endoplasmic reticulum of the plasma cells (**Web Image 3.12**).

EXTRACELLULAR HYALINE e.g.

1. Hyaline degeneration in *leiomyomas* of the uterus (**Web Image 3.13**).
2. Hyalinised *old scar* of fibrocollagenous tissues.
3. *Hyaline arteriosclerosis* in renal vessels in hypertension and diabetes mellitus.
4. Hyalinised glomeruli in *chronic glomerulonephritis*.
5. *Corpora amylacea* are rounded masses of concentric hyaline laminae seen in the prostate in the elderly, in the brain and in the spinal cord in old age.

Mucoid Change (p. 35)

Mucus secreted by mucous glands is a combination of proteins complexed with mucopolysaccharides. *Mucin*, a glycoprotein, is its chief constituent. Both types of mucin are stained by alcian blue. However, epithelial mucin stains positively with periodic acid-Schiff (PAS), while connective tissue mucin is PAS negative but is stained positively with colloidal iron.

EPITHELIAL MUCIN e.g.

1. Catarrhal inflammation of mucous membrane (e.g. of respiratory tract, alimentary tract, uterus).
2. Obstruction of duct leading to mucocele in the oral cavity and gallbladder.
3. Cystic fibrosis of the pancreas.
4. Mucin-secreting tumours (e.g. of ovary, stomach, large bowel etc) (**Web Image 3.14**).

CONNECTIVE TISSUE MUCIN e.g.

1. Mucoid or myxoid degeneration in some tumours e.g. myxomas, neurofibromas, fibroadenoma, soft tissue sarcomas etc (**Web Image 3.15**).
2. Dissecting aneurysm of the aorta due to Erdheim's medial degeneration and Marfan's syndrome.

3. Myxomatous change in the dermis in myxoedema.
4. Myxoid change in the synovium in ganglion on the wrist.

INTRACELLULAR ACCUMULATIONS (p. 37)

Intracellular accumulation of substances in abnormal amounts can occur within the cytoplasm (especially lysosomes) or nucleus of the cell.

Such abnormal intracellular accumulations can be divided into 3 groups:

- i) *Accumulation of constituents of normal cell metabolism produced in excess* e.g. accumulations of lipids (fatty change, cholesterol deposits), proteins and carbohydrates. In addition, deposits of amyloid and urate are discussed separately later.
- ii) *Accumulation of abnormal substances* produced as a result of abnormal metabolism due to lack of some enzymes e.g. storage diseases or inborn errors of metabolism. These are discussed in Chapter 10.
- iii) *Accumulation of pigments* e.g. endogenous pigments under special circumstances, and exogenous pigments due to lack of enzymatic mechanisms to degrade the substances or transport them to other sites.

□ **FATTY CHANGE (STEATOSIS) (p. 37)**

Fatty change, steatosis or fatty metamorphosis is the intracellular accumulation of neutral fat within parenchymal cells. It is especially common in the liver but may occur in other non-fatty tissues like the heart, skeletal muscle, kidneys (lipoid nephrosis or minimum change disease) and other organs.

Fatty Liver (p. 37)

Liver is the commonest site for accumulation of fat because it plays central role in fat metabolism. Depending upon the cause and amount of accumulation, fatty change may be mild and reversible, or severe producing irreversible cell injury and cell death.

ETIOLOGY. Fatty change in the liver may result from one of the two types of causes:

1. Conditions with excess fat:

- i) Obesity
- ii) Diabetes mellitus
- iii) Congenital hyperlipidaemia

2. Liver cell damage:

- i) Alcoholic liver disease (most common)
- ii) Starvation
- iii) Protein calorie malnutrition
- iv) Chronic illnesses (e.g. tuberculosis)
- v) Acute fatty liver in late pregnancy
- vi) Hypoxia (e.g. anaemia, cardiac failure)
- vii) Hepatotoxins (e.g. carbon tetrachloride, chloroform, ether, aflatoxins and other poisons)
- viii) Drug-induced liver cell injury (e.g. administration of methotrexate, steroids, CCl₄, halothane anaesthetic, tetracycline etc)
- ix) Reye's syndrome

PATHOGENESIS (Web Image 3.16). Lipids as free acids enter the liver cell from either of the following 2 sources (**Web Image 3.18**):

- ◆ From diet as chylomicrons (containing triglycerides and phospholipids) and as free fatty acids; and
- ◆ From adipose tissue as free fatty acids.

Normally, besides above two sources, a small part of fatty acids is also synthesised from acetate in the liver cells. Most of free fatty acid is esterified to triglycerides by the action of α -glycerophosphate and only a small part is changed into cholesterol, phospholipids and ketone bodies. While cholesterol, phospholipids and ketones are used in the body, intracellular triglycerides are converted into lipoproteins, which requires 'lipid acceptor protein'. Lipoproteins are released from the liver cells into circulation as plasma lipoproteins (LDL, VLDL).

In fatty liver, intracellular accumulation of triglycerides can occur due to defect at one or more of the following 6 steps in the normal fat metabolism shown in **Web Image 3.16**:

1. Increased entry of free fatty acids into the liver.
2. Increased synthesis of fatty acids by the liver.
3. Decreased conversion of fatty acids into ketone bodies resulting in increased esterification of fatty acids to triglycerides.
4. Increased α -glycerophosphate causing increased esterification of fatty acids to triglycerides.
5. Decreased synthesis of 'lipid acceptor protein' resulting in decreased formation of lipoprotein from triglycerides.
6. Block in the excretion of lipoprotein from the liver into plasma.

In most cases of fatty liver, one of the above mechanisms is operating. But in the case of liver cell injury by chronic alcoholism, many factors are implicated which include:

- increased lipolysis;
- increased free fatty acid synthesis;
- decreased triglyceride utilisation;
- decreased fatty acid oxidation to ketone bodies; and
- block in lipoprotein excretion.

An alcoholic who has not developed progressive fibrosis in the form of cirrhosis, the enlarged fatty liver may return to normal if the person becomes teetotaler.

G/A The liver in fatty change is enlarged with a tense, glistening capsule and rounded margins. The cut surface bulges slightly and is pale-yellow to yellow and is greasy to touch (**Web Image 3.17**).

M/E Characteristic feature is the presence of numerous lipid vacuoles in the cytoplasm of hepatocytes. Fat in H & E stained section prepared by paraffin-embedding technique appear non-staining vacuoles because it is dissolved in alcohol (**Web Image 3.18**):

- i) The vacuoles are initially small and are present around the nucleus (*microvesicular*).
- ii) But with progression of the process, the vacuoles become larger pushing the nucleus to the periphery of the cells (*macrovesicular*).
- iii) At times, the hepatocytes laden with large lipid vacuoles may coalesce to form fatty cysts.
- iv) Infrequently, *lipogranulomas* may appear consisting of collections of lymphocytes, macrophages, and some multinucleated giant cells.
- v) Fat can be demonstrated in fresh unfixed tissue by frozen section followed by *fat stains* such as Sudan dyes (Sudan III, IV, Sudan black) and oil red O.

Stromal Fatty Infiltration (p. 39)

Stromal fatty infiltration is the deposition of mature adipose cells in the stromal connective tissue in contrast to intracellular deposition of fat in the parenchymal cells in fatty change. The condition occurs most often in patients with obesity. The two commonly affected organs are the heart and the pancreas.

□ INTRACELLULAR ACCUMULATION OF PROTEINS (p. 39)

Pathologic accumulation of proteins in the cytoplasm of cells may occur in the following conditions:

1. In *proteinuria*, there is excessive renal tubular reabsorption of proteins by the proximal tubular epithelial cells which show pink hyaline droplets in their cytoplasm.
2. The cytoplasm of actively functioning plasma cells shows pink hyaline inclusions called *Russell's bodies* representing synthesised immunoglobulins.
3. In α_1 -*antitrypsin deficiency*, the cytoplasm of hepatocytes shows eosinophilic globular deposits of a mutant protein.
4. *Mallory's body* or alcoholic hyalin in the hepatocytes is intracellular accumulation of intermediate filaments of cytokeratin.

□ INTRACELLULAR ACCUMULATION OF GLYCOGEN (p. 40)

1. In *diabetes mellitus*, there is intracellular accumulation of glycogen in different tissues. Best's carmine and periodic acid-Schiff (PAS) staining may be employed to confirm the presence of glycogen in the cells.
2. In *glycogen storage diseases or glycogenosis*, there is defective metabolism of glycogen due to genetic disorders.

There are 2 broad categories of pigments: endogenous and exogenous (**Web Table 3.3**).

□ A. ENDOGENOUS PIGMENTS (p. 40)

Melanin (p. 40)

Melanin is the brown-black, non-haemoglobin-derived pigment normally present in the hair, skin, choroid of the eye, meninges and adrenal medulla. It is synthesised in the melanocytes and dendritic cells, both of which are present in the basal cells of the epidermis and is stored in the form of cytoplasmic granules in the phagocytic cells called the melanophores, present in the underlying dermis. Melanocytes possess the enzyme tyrosinase necessary for synthesis of melanin from tyrosine.

Various disorders of melanin pigmentation cause generalised and localised hyperpigmentation and hypopigmentation:

- i) Generalised hyperpigmentation** e.g. in *Addison's disease*, *chloasma* observed during pregnancy and in *chronic arsenical poisoning*.
- ii) Focal hyperpigmentation** e.g. *Café-au-lait spots*, *Peutz-Jeghers syndrome*, *melanosis coli*, *melanotic tumours*, *lentigo* and *dermatopathic lymphadenitis*.
- iii) Generalised hypopigmentation:** *Albinism* is an extreme degree of generalised hypopigmentation in which tyrosinase activity of the melanocytes is genetically defective and no melanin is formed.
- iv) Localised hypopigmentation** e.g. *leucoderma*, *vitiligo* and *acquired focal hypopigmentation*.

Alkaptonuria (p. 40)

This is a rare autosomal recessive disorder in which there is deficiency of an oxidase enzyme required for break-down of homogentisic acid which then accumulates in the tissues and is excreted in the urine (homogentisic aciduria). The pigment is melanin-like and is deposited both intracellularly and intercellularly in the cartilages, capsules of joints, ligaments and tendons.

Haemoprotein-derived Pigments (p. 41)

Haemoproteins are the most important endogenous pigments derived from haemoglobin, cytochromes and their break-down products. In disordered iron metabolism and transport, haemoprotein-derived pigments accumulate in the body. These pigments are haemosiderin, acid haematin (haemozoin), bilirubin, and porphyrins.

1. HAEMOSIDERIN. Iron is stored in the tissues in 2 forms:

- ◆ *Ferritin*, which is iron complexed to apoferritin and can be identified by electron microscopy.
- ◆ *Haemosiderin*, which is formed by aggregates of ferritin and is identifiable by light microscopy as golden-yellow to brown, granular pigment, especially within the mononuclear phagocytes of the bone marrow, spleen and liver. Haemosiderin is ferric iron that can be demonstrated by Perl's stain that produces Prussian blue reaction (**Web Image 3.20**).

Excessive storage of haemosiderin occurs in situations when there is increased break-down of red cells, or systemic overload of iron due to primary (idiopathic, hereditary) haemochromatosis, and secondary (acquired) causes such as in thalassaemia, sideroblastic anaemia, alcoholic cirrhosis, multiple blood transfusions etc.

Accordingly, the effects of haemosiderin excess are as under (**Web Image 3.21**):

a) Localised haemosiderosis. This develops whenever there is haemorrhage into the tissues. With lysis of red cells, haemoglobin is liberated which is taken up by macrophages where it is degraded and stored as haemosiderin, e.g. changing colours of a bruise or a *black eye*, *brown induration* in the lungs.

b) Generalised (Systemic or Diffuse) haemosiderosis. Systemic overload with iron may result in generalised haemosiderosis. There can be two types of patterns:

- ◆ *Parenchymatous deposition of haemosiderin* in liver, pancreas, kidney, and heart.
- ◆ *Reticuloendothelial deposition* in the liver, spleen, and bone marrow.

Generalised or systemic overload of iron may occur due to following causes:

i) Increased erythropoietic activity e.g. in various forms of chronic haemolytic anaemia, there is excessive break-down of haemoglobin and hence iron overload.

ii) Excessive intestinal absorption of iron: A form of haemosiderosis in which there is excessive intestinal absorption of iron even when the intake is normal, is known as *idiopathic or hereditary haemochromatosis*. It is an autosomal dominant disease associated with much more deposits of iron than cases of acquired haemosiderosis. It is characterised by *triad* of pigmentary liver cirrhosis, pancreatic damage resulting in diabetes mellitus, and skin pigmentation (*bronze diabetes*).

iii) Excessive dietary intake of iron: A common example of excessive intake of iron is *Bantu's disease* in black tribals of South Africa.

2. ACID HAEMATIN (HAEMOZOIN). Acid haematin or haemozoin is a haemoprotein-derived brown-black pigment containing haem iron in ferric form in acidic medium. But it differs from haemosiderin because it cannot be stained by Prussian blue (Perl's) reaction. Haematin pigment is seen most commonly in chronic malaria and in mismatched blood transfusions.

3. BILIRUBIN. Bilirubin is the normal non-iron containing pigment present in the bile. It is derived from porphyrin ring of the haem moiety of haemoglobin. Normal level of bilirubin in blood is less than 1 mg/dl. Excess of bilirubin or hyperbilirubinaemia causes an important clinical condition called jaundice. Hyperbilirubinaemia may be unconjugated or conjugated, and jaundice may appear in one of the following 3 ways:

- a) *Prehepatic or haemolytic*, when there is excessive destruction of red cells.
- b) *Posthepatic or obstructive*, which results from obstruction to the outflow of conjugated bilirubin.
- c) *Hepatocellular* that results from failure of hepatocytes to conjugate bilirubin and inability of bilirubin to pass from the liver to intestine.

Excessive accumulation of bilirubin pigment can be seen in different tissues and fluids of the body, especially in the hepatocytes, Kupffer cells and bile sinusoids. Skin and sclerae become distinctly yellow.

4. PORPHYRINS. Porphyrins are normal pigment present in haemoglobin, myoglobin and cytochrome. Porphyria refers to an uncommon disorder of inborn abnormality of porphyrin metabolism. It results from genetic deficiency of one of the enzymes required for the synthesis of haem, resulting in excessive production of porphyrins. Porphyrins are broadly of 2 types—

a) Erythropoietic porphyrias. These have defective synthesis of haem in the red cell precursors in the bone marrow. These may be further of 2 subtypes: *congenital erythropoietic porphyria* and *erythropoietic protoporphyria*.

b) Hepatic porphyrias. These are more common and have a normal erythroid precursors but have a defect in synthesis of haem in the liver. Its further subtypes include: *acute intermittent porphyria*, *porphyria cutanea tarda* and *mixed (Variegata) porphyrias*.

Lipofuscin (Wear and Tear Pigment) (p. 43)

Lipofuscin or lipochrome is yellowish-brown intracellular lipid pigment (*lipo* = fat, *fuscus* = brown). The pigment is often found in atrophied cells of old age and hence the name 'wear and tear pigment'. It is seen in the myocardial fibres, hepatocytes, Leydig cells of the testes and in neurons in senile dementia.

M/E The pigment is coarse, golden-brown granular and often accumulates in the central part of the cells around the nuclei. In the heart muscle, the change is associated with wasting of the muscle and is commonly referred to as 'brown atrophy' (**Web Image 3.22**). The pigment can be stained by fat stains but differs from other lipids in being fluorescent and having acid-fastness.

By electron microscopy, lipofuscin appears as intralysosomal electron-dense granules in perinuclear location.

□ B. EXOGENOUS PIGMENTS (p. 43)

Exogenous pigments are the pigments introduced into the body from outside such as by inhalation, ingestion or inoculation.

Inhaled Pigments (p. 43)

Anthraxis (i.e. deposition of carbon particles) is seen in almost every adult lung and generally provokes no reaction of tissue injury (**Web Image 3.23**).

Ingested Pigments (p. 43)

Chronic ingestion of certain metals may produce pigmentation, e.g. *argyria*, *chronic lead poisoning*, *melanosis coli* and *carotenaemia*.

Injected Pigments (Tattooing) (p. 43)

Pigments like India ink, cinnabar and carbon are introduced into the dermis in the process of tattooing.

□ **AUTOLYSIS** (p. 44)

Autolysis (i.e. *self-digestion*) is disintegration of the cell by its own hydrolytic enzymes liberated from lysosomes. Autolysis can occur in the living body when it is surrounded by inflammatory reaction (*vital reaction*), but the term is generally used for postmortem change in which there is complete absence of surrounding inflammatory response. Autolysis is *rapid* in some tissues rich in hydrolytic enzymes such as in the pancreas, and gastric mucosa; *intermediate* in tissues like the heart, liver and kidney; and *slow* in fibrous tissue. Morphologically, autolysis is identified by homogeneous and eosinophilic cytoplasm with loss of cellular details and remains of cell as debris.

□ **NECROSIS** (p. 44)

Necrosis is defined as a localised area of death of tissue followed by degradation of tissue by hydrolytic enzymes liberated from dead cells; it is invariably accompanied by inflammatory reaction.

Two essential changes characterise irreversible cell injury in necrosis of all types (**Web Image 3.24,A**):

i) **Cell digestion by lytic enzymes.**

ii) **Denaturation of proteins.**

Types of Necrosis (p. 45)

Morphologically, there are five types of necrosis:

1. COAGULATIVE NECROSIS. This is the most common type of necrosis caused by irreversible focal injury, mostly from sudden cessation of blood flow (ischaemia), and less often from bacterial and chemical agents.

G/A Foci of coagulative necrosis in the early stage are pale, firm, and slightly swollen. With progression, they become more yellowish, softer, and shrunken.

M/E The hallmark of coagulative necrosis is the conversion of normal cells into their 'tombstones' i.e. outlines of the cells are retained so that the cell type can still be recognised but their cytoplasmic and nuclear details are lost (**Web Image 3.25**).

2. LIQUEFACTION (COLLIQUATIVE) NECROSIS. Liquefaction or colliquative necrosis occurs commonly due to ischaemic injury and bacterial or fungal infections. The common examples are infarct brain and abscess cavity.

G/A The affected area is soft with liquefied centre containing necrotic debris. Later, a cyst wall is formed.

M/E The cystic space contains necrotic cell debris and macrophages filled with phagocytosed material. The cyst wall is formed by proliferating capillaries, inflammatory cells, and gliosis (proliferating glial cells) in the case of brain and proliferating fibroblasts in the case of abscess cavity (**Web Image 3.26**).

3. CASEOUS NECROSIS. Caseous necrosis is found in the centre of foci of tuberculous infections. It combines features of both coagulative and liquefactive necrosis.

G/A Foci of caseous necrosis, resemble dry cheese and are soft, granular and yellowish.

M/E The necrosed foci are structureless, eosinophilic, and contain granular debris (**Web Image 3.27**). The surrounding tissue shows characteristic granulomatous inflammatory reaction consisting of epithelioid cells with

interspersed giant cells of Langhans' or foreign body type and peripheral mantle of lymphocytes.

4. FAT NECROSIS. Fat necrosis is a special form of cell death occurring at two anatomically different locations but morphologically similar lesions. These are: following *acute pancreatic necrosis*, and *traumatic fat necrosis* commonly in breasts.

G/A Fat necrosis appears as yellowish-white and firm deposits. Formation of calcium soaps imparts the necrosed foci firmer and chalky white appearance.

M/E The necrosed fat cells have cloudy appearance and are surrounded by an inflammatory reaction. Formation of calcium soaps is identified in the tissue sections as amorphous, granular and basophilic material (**Web Image 3.28**).

5. FIBRINOID NECROSIS. Fibrinoid necrosis is characterised by deposition of fibrin-like material which has the staining properties of fibrin. It is encountered in various examples of immunologic tissue injury (e.g. in immune complex vasculitis, autoimmune diseases, Arthus reaction etc), arterioles in hypertension, peptic ulcer etc.

M/E Fibrinoid necrosis is identified by brightly eosinophilic, hyaline-like deposition in the vessel wall. Necrotic focus is surrounded by nuclear debris of neutrophils (leucocytoclasia) (**Web Image 3.29**).

□ APOPTOSIS (p. 46)

Apoptosis is a form of 'coordinated and internally programmed cell death' having significance in a variety of physiologic and pathologic conditions.

APOPTOSIS IN BIOLOGIC PROCESSES

Physiologic Processes:

1. Organised cell destruction in sculpting of tissues during *development of embryo*.
2. Physiologic involution of cells in *hormone-dependent tissues* e.g. endometrial shedding, regression of lactating breast after withdrawal of breast-feeding.
3. Normal cell destruction followed by *replacement proliferation* such as in intestinal epithelium.
4. *Involution of the thymus* in early age.

Pathologic Processes:

1. Cell death in tumours exposed to *chemotherapeutic agents*.
2. *Cell death by cytotoxic T cells* in immune mechanisms such as in graft-versus-host disease and rejection reactions.
3. Progressive *depletion of CD4+T cells* in the pathogenesis of AIDS.
4. *Cell death in viral infections* e.g. formation of Councilman bodies in viral hepatitis.
5. *Pathologic atrophy* of organs and tissues on withdrawal of stimuli e.g. prostatic atrophy after orchiectomy, atrophy of kidney or salivary gland on obstruction of ureter or ducts, respectively.
6. Cell death in response to *injurious agents* involved in causation of necrosis e.g. radiation, hypoxia and mild thermal injury.
7. In *degenerative diseases of CNS* e.g. in Alzheimer's disease, Parkinson's disease, and chronic infective dementias.
8. *Heart diseases* e.g. heart failure, acute myocardial infarction (20% necrosis and 80% apoptosis).

M/E

1. Involvement of *single cells or small clusters of cells* in the background of viable cells.

2. The apoptotic cells are round to oval *shrunken masses* of intensely eosinophilic cytoplasm (mummified cell) containing shrunken or almost-normal organelles (**Web Image 3.30**).
3. The nuclear chromatin is condensed or fragmented (*pyknosis* or *karyorrhexis*).
4. The cell membrane may show *convolutions* or *projections* on the surface.
5. There may be formation of membrane-bound near-spherical bodies on or around the cell called *apoptotic bodies* containing compacted organelles.
6. Characteristically, unlike necrosis, there is *no acute inflammatory reaction* around apoptosis.
7. *Phagocytosis* of apoptotic bodies by macrophages takes place at varying speed.

Techniques to identify and count apoptotic cells. In addition to routine H & E stain, apoptotic cells can be identified and counted by:

1. Staining of chromatin condensation (haematoxylin, Feulgen, acridine orange).
2. Flow cytometry to visualise rapid cell shrinkage.
3. DNA changes detected by *in situ* techniques or by gel electrophoresis.
4. Annexin V as marker for apoptotic cell membrane having phosphatidylserine on the cell exterior.

BIOCHEMICAL CHANGES

1. Proteolysis of cytoskeletal proteins.
2. Protein-protein cross linking.
3. Fragmentation of nuclear chromatin by activation of nuclease.
4. Appearance of phosphatidylserine on the outer surface of cell membrane.
5. In some forms of apoptosis, appearance of an adhesive glycoprotein thrombospondin on the outer surface of apoptotic bodies.

The contrasting features of apoptosis and necrosis are illustrated in **Web Image 3.24** and summarised in **Web Table 3.4**.

MOLECULAR MECHANISMS OF APOPTOSIS

1. Initiators of apoptosis. Triggers for signalling programmed cell death act at the cell membrane, either intracellularly or extracellularly.

- i) Withdrawal of signals required for normal cell survival (e.g. absence of certain hormones, growth factors, cytokines).
- ii) Extracellular signals triggering of programmed cell death (e.g. activation of FAS receptor belonging to TNF-R family).
- iii) Intracellular stimuli e.g. heat, radiation, hypoxia etc.

2. Process of programmed cell death. After the cell has been initiated into self-destruct mode, the programme inbuilt in the cell gets activated as under:

- i) *Activation of caspases.* Caspases are a series of proteolytic or protein-splitting enzymes which act on nuclear proteins and organelles containing protein components.
- ii) *Activation of death receptors.* Activated caspases set in activation of FAS receptor (CD 95), a cell surface receptor present on cytotoxic (CD 8+) T cells, belonging to the family of tumour necrosis factor receptors (TNF-R).
- iii) *Activation of growth controlling genes (BCL-2 and p53).* BCL-2 gene is a human counterpart of CED-9 (cell death) gene found in programmed cell death of nematode worm *Caenorabditis elegans*. The net effect on the mitochondrial membrane is based on the pro-apoptotic and anti-apoptotic actions of BCL-2 gene family.
- iv) *Cell death.* The above mechanisms lead to proteolytic actions on nucleus, chromatin clumping, cytoskeletal damage, disruption of endoplasmic reticulum, mitochondrial damage, and disturbed cell membrane.

3. Phagocytosis. The dead apoptotic cells develop membrane changes which promote their phagocytosis. The phagocytosis is unaccompanied by any other inflammatory cells.

The mechanism of apoptosis is schematically represented in **Web Image 3.31**.

□ **GANGRENE** (*p. 49*)

Gangrene is a form of necrosis of tissue with superadded putrefaction.

There are 2 main forms of gangrene—dry and wet, and a variant form of wet gangrene called gas gangrene.

Dry Gangrene (*p. 49*)

This form of gangrene begins in the distal part of a limb due to ischaemia. The typical example is the dry gangrene in the toes and feet of an old patient due to arteriosclerosis. Other causes of dry gangrene foot include thromboangiitis obliterans (Buerger's disease), Raynaud's disease, trauma, ergot poisoning.

G/A The affected part is dry, shrunken and dark black, resembling the foot of a mummy. The line of separation usually brings about complete separation with eventual falling off of the gangrenous tissue if it is not removed surgically (**Web Image 3.32**).

M/E There is necrosis with smudging of the tissue. The line of separation consists of inflammatory granulation tissue (**Web Image 3.33**).

Wet Gangrene (*p. 50*)

Wet gangrene occurs in naturally moist tissues and organs such as the mouth, bowel, lung, cervix, vulva etc. Diabetic foot is another example of wet gangrene due to high sugar content in the necrosed tissue which favours growth of bacteria. *Bed sores* occurring in a bed-ridden patient due to pressure on sites like the sacrum, buttocks and heels are the other important clinical conditions included in wet gangrene.

G/A The affected part is soft, swollen, putrid, rotten and dark. The classic example is gangrene of bowel, commonly due to strangulated hernia, volvulus or intussusception (**Web Image 3.34**).

M/E There is coagulative necrosis with stuffing of affected part with blood. There is ulceration of the mucosa and intense inflammatory infiltration. Lumen of the bowel contains mucus and blood. The line of demarcation between gangrenous segment and viable bowel is generally not clear-cut (**Web Image 3.35**).

Contrasting features of two main forms of gangrene are summarised in **Web Table 3.5**.

GAS GANGRENE. It is a special form of wet gangrene caused by gas-forming clostridia (gram-positive anaerobic bacteria) which gain entry into the tissues through open contaminated wounds, especially in the muscles, or as a complication of operation on colon which normally contains clostridia.

G/A The affected area is swollen, oedematous, painful and crepitant due to accumulation of gas bubbles within the tissues. Subsequently, the affected tissue becomes dark black and foul smelling.

M/E The muscle fibres undergo coagulative necrosis with liquefaction.

□ **PATHOLOGIC CALCIFICATION** (*p. 51*)

Deposition of calcium salts in tissues other than osteoid or enamel is called pathologic or heterotopic calcification. Two distinct types of pathologic calcification are recognised:

◆ *Dystrophic calcification*, which is characterised by deposition of calcium salts in dead or degenerated tissues with normal calcium metabolism and normal serum calcium levels.

◆ *Metastatic calcification*, on the other hand, occurs in apparently normal tissues and is associated with deranged calcium metabolism and hypercalcaemia.

Etiology and pathogenesis of the two are different but morphologically the deposits in both resemble normal minerals of the bone.

M/E In routine H and E stained sections, calcium salts appear as deeply basophilic, irregular and granular clumps. Calcium deposits can be confirmed by special stains like silver impregnation method of *von-Kossa* producing black colour, and *alizarin red S* that produces red staining.

Etiopathogenesis (p. 52)

DYSTROPHIC CALCIFICATION. It may occur due to 2 types of causes:

- ◆ Calcification in dead tissue
- ◆ Calcification of degenerated tissue.

Calcification in dead tissue, e.g.

- i) *Caseous necrosis* in tuberculosis is the most common site for dystrophic calcification (**Web Image 3.36**).
- ii) *Liquefaction necrosis* in chronic abscesses.
- iii) *Fat necrosis* following acute pancreatitis or traumatic fat necrosis in the breast.
- iv) *Gamna-Gandy bodies* in chronic venous congestion (CVC) of the spleen.
- v) *Infarcts, Thrombi*, especially in the veins.
- vi) *Haematomas* in the vicinity of bones.
- vii) *Dead parasites* like in hydatid cyst, *Schistosoma* eggs, and cysticercosis.
- viii) Calcification in *breast cancer*. *Congenital toxoplasmosis* involving the central nervous system.

Calcification in degenerated tissues, e.g.

- i) *Dense old scars, Atheromas* in the aorta and coronaries.
- ii) *Mönckeberg's sclerosis* shows calcification in the tunica media of muscular arteries in elderly people (**Web Image 3.37**).
- iii) *Stroma of tumours* such as uterine fibroids, breast cancer, thyroid adenoma.
- iv) Some tumours show characteristic spherules of calcification called *psammoma bodies* or *calcospherites* such as in meningioma, papillary serous cystadenocarcinoma of the ovary and papillary carcinoma of the thyroid.
- v) Cysts which have been present for a long time, e.g. epidermal and pilar cysts.
- vi) *Calcinosis cutis*. *Senile degenerative changes* such as in costal cartilages, tracheal or bronchial cartilages, and pineal gland in the brain etc.

Pathogenesis of dystrophic calcification. The process of dystrophic calcification has been likened to the formation of normal hydroxyapatite in the bone involving 2 phases: initiation and propagation.

METASTATIC CALCIFICATION. Since metastatic calcification occurs in normal tissues due to hypercalcaemia, its causes would include one of the following two conditions:

Excessive mobilisation of calcium from the bone, e.g. *Hyperparathyroidism*, *bony destructive lesions* such as multiple myeloma, metastatic carcinoma. *Prolonged immobilisation* of a patient.

Excessive absorption of calcium from the gut, e.g. *hypervitaminosis D*, *milk-alkali syndrome* and *hypercalcaemia of infancy*.

Sites of metastatic calcification. Metastatic calcification may occur in any normal tissue of the body but affects the following organs more commonly:

1. *Kidneys*, especially at the basement membrane of tubular epithelium and in the tubular lumina causing nephrocalcinosis (**Web Image 3.38**).
2. *Lungs*, especially in the alveolar walls.
3. *Stomach*, on the acid-secreting fundal glands.
4. *Blood vessels*, especially on the internal elastic lamina.
5. *Cornea* is another site affected by metastatic calcification.
6. *Synovium* of the joint causing pain and dysfunction.

Pathogenesis of metastatic calcification. Metastatic calcification at the above-mentioned sites occurs due to excessive binding of inorganic phosphate ions with calcium ions, which are elevated due to underlying metabolic derangement. Metastatic calcification is reversible upon correction of underlying metabolic disorder.

The distinguishing features between the two types of pathologic calcification are summarised in **Web Table 3.6**.

For the sake of survival on exposure to stress, the cells make adjustments with the changes in their environment (i.e. adapt) to the physiologic needs (*physiologic adaptation*) and to non-lethal pathologic injury (*pathologic adaptation*). Broadly speaking, such physiologic and pathologic adaptations occur by following processes (**Web Image 3.39**):

- ◆ Decreasing or increasing their size i.e. *atrophy* and *hypertrophy* respectively, or by increasing their number i.e. *hyperplasia*.
- ◆ Changing the pathway of phenotypic differentiation of cells i.e. *metaplasia* and *dysplasia*.

In general, the adaptive responses are reversible on withdrawal of stimulus. The concept of evolution 'survival of the fittest' holds true for adaptation as '*survival of the adaptable*'.

□ **ATROPHY** (p. 55)

Reduction of the number and size of parenchymal cells of an organ or its parts which was once normal is called atrophy.

Causes

A. Physiologic atrophy, e.g. atrophy of lymphoid tissue in lymph nodes, appendix and thymus, atrophy of gonads after menopause and atrophy of brain with aging.

B. Pathologic atrophy e.g.

1. *Starvation atrophy*
2. *Ischaemic atrophy* e.g.
 - i) Small atrophic kidney in atherosclerosis of renal artery.
 - ii) Atrophy of brain in cerebral atherosclerosis.
3. *Disuse atrophy* e.g.
 - i) Wasting of muscles of limb immobilised in cast.
 - ii) Atrophy of the pancreas in obstruction of pancreatic duct.
4. *Neuropathic atrophy* e.g.
 - i) Poliomyelitis
 - ii) Motor neuron disease
 - iii) Nerve section.
5. *Endocrine atrophy* e.g.
 - i) Hypopituitarism may lead to atrophy of thyroid, adrenal and gonads.
 - ii) Hypothyroidism may cause atrophy of the skin and its adnexal structures.
6. *Pressure atrophy* e.g.
 - i) Erosion of spine by tumour in nerve root.

- ii) Erosion of skull by meningioma arising from pia-arachnoid.
- iii) Erosion of sternum by aneurysm of arch of aorta.

7. *Idiopathic atrophy*, e.g.

- i) Myopathies.
- ii) Testicular atrophy.

G/A The organ is small, often shrunken. The cells become smaller in size but are not dead cells.

M/E Shrinkage in cell size is due to reduction in cell organelles, chiefly mitochondria, myofilaments and endoplasmic reticulum. There is often increase in the number of autophagic vacuoles containing cell debris (**Web Image 3.40**).

□ **HYPERTROPHY** (p. 55)

Hypertrophy is an increase in the size of parenchymal cells resulting in enlargement of the organ or tissue, without any change in the number of cells.

Causes

A. Physiologic hypertrophy. Enlarged size of the uterus in pregnancy is an excellent example of physiologic hypertrophy as well as hyperplasia.

B. Pathologic hypertrophy

1. *Hypertrophy of cardiac muscle e.g.*

- i) Systemic hypertension
- ii) Aortic valve disease (stenosis and insufficiency)
- iii) Mitral insufficiency

2. *Hypertrophy of smooth muscle e.g.*

- i) Cardiac achalasia (in oesophagus)
- ii) Pyloric stenosis (in stomach)
- iii) Intestinal strictures
- iv) Muscular arteries in hypertension.

3. *Hypertrophy of skeletal muscle* e.g. hypertrophied muscles in athletes and manual labourers.

4. *Compensatory hypertrophy* e.g.

- i) Following nephrectomy on one side in a young patient, there is compensatory hypertrophy as well as hyperplasia of the nephrons of the other kidney.
- ii) Adrenal hyperplasia following removal of one adrenal gland.

G/A The affected organ is enlarged and heavy. For example, a hypertrophied heart of a patient with systemic hypertension may weigh 700-800 g as compared to average normal adult weight of 350 g.

M/E There is enlargement of muscle fibres as well as of nuclei (**Web Image 3.41**).

□ **HYPERPLASIA** (p. 56)

Hyperplasia is an increase in the number of parenchymal cells resulting in enlargement of the organ or tissue. Quite often, both hyperplasia and hypertrophy occur together. Hyperplasia occurs due to increased recruitment of cells from G_0 (resting) phase of the cell cycle to undergo mitosis, when stimulated. Neoplasia differs from hyperplasia in having hyperplastic growth with loss of growth-regulatory mechanism due to change in genetic composition of the cell. Hyperplasia, on the other hand, persists so long as stimulus is present.

A. Physiologic hyperplasia

1. *Hormonal hyperplasia* e.g.
 - i) Hyperplasia of female breast at puberty, during pregnancy and lactation.
 - ii) Hyperplasia of pregnant uterus.
 - iii) Proliferative activity of normal endometrium after a normal menstrual cycle.
 - iv) Prostatic hyperplasia in old age.
2. *Compensatory hyperplasia* e.g.
 - i) Regeneration of the liver following partial hepatectomy
 - ii) Regeneration of epidermis after skin abrasion
 - iii) Following nephrectomy on one side, there is hyperplasia of nephrons of the other kidney.

B. Pathologic hyperplasia e.g.

- i) Endometrial hyperplasia following oestrogen excess.
- ii) In wound healing, there is formation of granulation tissue due to proliferation of fibroblasts and endothelial cells.
- iii) Formation of skin warts from hyperplasia of epidermis due to human papilloma virus.
- iv) Pseudocarcinomatous hyperplasia of the skin.
- v) Intraductal epithelial hyperplasia in the breast in fibrocystic breast disease.

G/A & M/E There is enlargement of the affected organ or tissue and increase in the number of cells (**Web Image 3.42**).

□ **METAPLASIA** (p. 57)

Metaplasia is defined as a reversible change of one type of epithelial or mesenchymal adult cells to another type of adult epithelial or mesenchymal cells, usually in response to abnormal stimuli, and often *reverts back to normal on removal of stimulus*. However, if the stimulus persists for a long time, epithelial metaplasia may transform into cancer (**Web Image 3.43**).

Metaplasia is broadly divided into 2 types:

A. EPITHELIAL METAPLASIA. Depending upon the type epithelium transformed, two types of epithelial metaplasia are seen:

1. Squamous metaplasia. This is more common. Various types of specialised epithelium are capable of undergoing squamous metaplastic change due to chronic irritation that may be mechanical, chemical or infective in origin e.g.

- i) In *bronchus* (normally lined by pseudostratified columnar ciliated epithelium) in chronic smokers.
- ii) In *uterine endocervix* (normally lined by simple columnar epithelium) in prolapse of the uterus and in old age (**Web Image 3.44**).
- iii) In *gallbladder* (normally lined by simple columnar epithelium) in chronic cholecystitis with cholelithiasis.
- iv) In *prostate* (ducts normally lined by simple columnar epithelium) in chronic prostatitis and oestrogen therapy.
- v) In *renal pelvis* and *urinary bladder* (normally lined by transitional epithelium) in chronic infection and stones.
- vi) In *vitamin A deficiency*, apart from xerophthalmia, there is squamous metaplasia in the nose, bronchi, urinary tract, lacrimal and salivary glands.

2. Columnar metaplasia e.g.

- i) Intestinal metaplasia in healed chronic gastric ulcer.
- ii) Columnar metaplasia in Barrett's oesophagus (**Web Image 3.45**).
- iii) Conversion of pseudostratified ciliated columnar epithelium in chronic bronchitis and bronchiectasis to columnar type.

iv) In cervical erosion (congenital and adult type), there is variable area of endocervical glandular mucosa everted into the vagina.

B. MESENCHYMAL METAPLASIA. Less often, there is transformation of one adult type of mesenchymal tissue to another.

1. Osseous metaplasia e.g.

- i) In arterial wall in old age (Mönckeberg's medial calcific sclerosis)
- ii) In soft tissues in myositis ossificans
- iii) In cartilage of larynx and bronchi in elderly people
- iv) In scar of chronic inflammation of prolonged duration
- v) In the fibrous stroma of tumour (**Web Image 3.46**).

2. Cartilaginous metaplasia. In healing of fractures, cartilaginous metaplasia may occur where there is undue mobility.

□ **DYSPLASIA** (p. 58)

Dysplasia means 'disordered cellular development', often accompanied with metaplasia and hyperplasia; it is therefore also referred to as *atypical hyperplasia*. Dysplasia occurs most often in epithelial cells. Epithelial dysplasia is characterised by cellular proliferation and cytologic changes.

1. Increased number of layers of epithelial cells
2. Disorderly arrangement of cells from basal layer to the surface layer
3. Loss of basal polarity i.e. nuclei lying away from basement membrane
4. Cellular and nuclear pleomorphism
5. Increased nucleocytoplasmic ratio
6. Nuclear hyperchromatism
7. Increased mitotic activity.

The two most common examples of dysplastic changes are the *uterine cervix* (**Web Image 3.47**) and *respiratory tract*.

The differences between dysplasia and metaplasia are contrasted in **Web Table 3.7**.

Old age is a concept of longevity in human beings. The consequences of aging appear after reproductive age.

The average age of death of primitive man was barely 20-25 years compared to life-expectancy now which is approaching 80 years, survival being longer in women than men (3:2).

In general, the life expectancy of an individual depends upon the following factors:

1. *Intrinsic genetic process.*
2. *Environmental factors.*
3. *Lifestyle of the individual.*
4. *Age-related diseases* e.g. atherosclerosis and ischaemic heart disease, diabetes mellitus, hypertension, osteoporosis, Alzheimer's disease, Parkinson's disease etc.

□ **CELLULAR BASIS** (p. 59)

With age, structural and functional changes occur in different organs and systems of the human body. The following hypotheses based on investigations explain the cellular basis of aging:

1. Experimental cellular senescence. By *in vitro* studies of tissue culture, it has been observed that cultured human fibroblasts replicate for up to 50 population doublings and then the culture dies out. Studies have shown that there is either loss of chromosome 1 or deletion of its long arm (1q). Alternatively it has been observed that with every cell division there is progressive shortening of *telomere* present at the tips of chromosomes, which in normal cell is repaired by the presence of RNA enzyme, *telomerase* (**Web Image 3.48**).

2. Genetic control in invertebrates. Clock (*clk*) genes responsible for controlling the rate and time of aging have been identified in lower invertebrates e.g. *clk-1* gene mutation in the metazoa, *Caenorhabditis elegans*.

3. Diseases of accelerated aging. Aging under genetic control in human beings is supported by the observation of high concordance in lifespan of identical twins. A heritable condition associated with signs of accelerated aging process is termed *progeria* and is characterised by baldness, cataracts, and coronary artery disease.

4. Oxidative stress hypothesis (free radical-mediated injury). Currently, it is believed that aging is partly caused by progressive and reversible molecular oxidative damage due to persistent oxidative stress on the human cells. With aging, there is low metabolic rate with generation of toxic oxygen radicals, which fail to get eliminated causing their accumulation and hence cell damage. The underlying mechanism appears to be oxidative damage to mitochondria. The role of antioxidant in retarding the oxidant damage has been reported in some studies.

□ ORGAN CHANGES IN AGING (p. 60)

Although all organs start showing deterioration with aging, following organs show evident morphologic and functional changes:

1. **Cardiovascular system:** Atherosclerosis, arteriosclerosis with calcification, Mönckeberg's medial calcification, brown atrophy of heart, loss of elastic tissue from aorta and major arterial trunks causing their dilatation.

2. **Nervous system:** Atrophy of gyri and sulci, Alzheimer's disease, Parkinson's disease.

3. **Musculoskeletal system:** Degenerative bone diseases, frequent fractures due to loss of bone density, age related muscular degeneration.

4. **Eyes:** Deterioration of vision due to cataract and vascular changes in retina.

5. **Hearing:** Disability in hearing due to senility is related to otosclerosis.

6. **Immune system:** Reduced IgG response to antigens, frequent and severe infections.

7. **Skin:** Laxity of skin due to loss of elastic tissue.

8. **Cancers:** 80% of cancers occur in the age range of 50 and 80 years.

◆ SELF ASSESSMENT

- Besides nucleus, the only other place in the cell having DNA is:**
 - Ribosome
 - Golgi apparatus
 - Mitochondria
 - Endoplasmic reticulum
- The DNA molecule is a double helical strand having the following nucleotide bases:**
 - Cytosine, thymine, alanine, guanine
 - Adenine, guanine, valine, thymine
 - Cytosine, lysine, adenine, guanine
 - Adenine, guanine, cytosine, thymine
- Actin and myosin proteins are found in:**
 - Microtubules
 - Microfilaments
 - Intermediate filaments
 - Ribosomes
- In ischaemia-reperfusion cell injury, there are:**
 - Increased Ca^{++} ions in the extracellular fluid
 - Increased Ca^{++} ions in the cytosol
 - Ca^{++} ions are equal in the cytosol and in extracellular fluid
 - Ca^{++} ion equilibrium is unaffected

5. The major mechanism of damage to plasma membrane in ischaemia is:
 - A. Reduced intracellular pH
 - B. Increased intracellular accumulation of sodium
 - C. Increased Ca^{++} ions in the cytosol
 - D. Reduced aerobic respiration
6. Out of various free radical species, the following radical is most reactive:
 - A. Superoxide (O_2^-)
 - B. Hydrogen peroxide (H_2O_2)
 - C. Hydroxyl (OH^-)
 - D. Nitric oxide (NO)
7. In fatty liver due to chronic alcoholism, the following mechanisms are involved **except**:
 - A. Increased free fatty acid synthesis
 - B. Decreased triglyceride utilization
 - C. Increased α -glycerophosphate
 - D. Block in lipoprotein excretion
8. The following pigments are stainable by Prussian blue reaction **except**:

A. Haemosiderin	B. Ferritin
C. Haematin	D. Haemochromatosis
9. Enzymatic digestion is the predominant event in the following type of necrosis:

A. Coagulative necrosis	B. Liquefactive necrosis
C. Caseous necrosis	D. Fat necrosis
10. Mechanism of mammalian apoptosis involves the most important role of the following protein:

A. Receptor for TNF	B. <i>BCL-2</i>
C. <i>TP53</i>	D. <i>CED-9</i>
11. Apoptosis has the following features **except**:
 - A. There is cell shrinkage in apoptosis
 - B. There are no acute inflammatory cells surrounding apoptosis
 - C. There may be single cell loss or affect clusters of cells
 - D. Apoptosis is seen in pathologic processes only
12. Diabetic foot is an example of:

A. Dry gangrene	B. Wet gangrene
C. Gas gangrene	D. Necrotising inflammation
13. Idiopathic calcinosis cutis is an example of:

A. Necrotising inflammation	B. Dystrophic calcification
C. Metastatic calcification	D. Calcified thrombi in veins
14. In atrophy, the cells are:

A. Dead cells	B. Shrunken cells
C. Irreversibly injured cells	D. Reversibly injured cells
15. For metaplasia the following holds true:
 - A. It is a disordered growth
 - B. It affects only epithelial tissues
 - C. It is a reversible change
 - D. It is an irreversible and progressive change
16. In cell cycle, signal transduction system is activated by:

A. G protein receptors	B. Selectins
C. Cadherins	D. Integrins
17. Immune system in the body is activated by:

A. Cell adhesion molecules	B. Cytokines
C. G-protein receptors	D. Ion channels
18. Which of the following is proapoptotic:

A. <i>p53</i>	B. <i>Bcl-2</i>
C. <i>c-myc</i>	D. <i>Bax</i>

19. Annexin V is used as a marker for:

- A. Necrosis
 B. Fatty change
 C. Apoptosis
 D. Gangrene

20. Enzyme which prevents aging is:

- A. Catalase
 B. Superoxide dismutase
 C. Metalloproteinase
 D. Telomerase

KEY

1 = C	2 = D	3 = B	4 = B
5 = C	6 = C	7 = C	8 = C
9 = B	10 = B	11 = D	12 = B
13 = B	14 = B	15 = C	16 = A
17 = B	18 = D	19 = C	20 = D



Immunopathology Including Amyloidosis

Immunity and immunopathology are proverbial two edges of 'double-edged sword'.

- ◆ An **antigen (Ag)** is defined as a substance, usually protein in nature, which when introduced into the tissues stimulates antibody production.
- ◆ **Hapten** is a non-protein substance which has no antigenic properties, but on combining with a protein can form a new antigen capable of forming antibodies.
- ◆ An **antibody (Ab)** is a protein substance produced as a result of antigenic stimulation. Circulating antibodies are immunoglobulins (Igs) of which there are 5 classes: IgG, IgA, IgM, IgE and IgD.
- ◆ An antigen may induce **specifically sensitised cells** having the capacity to recognise, react and neutralise the injurious agent or organisms.
- ◆ The antigen may combine with antibody to form **antigen-antibody complex**. The reaction of Ag with Ab *in vitro* may be *primary* or *secondary phenomena* (**Web Image 4.1**).

TYPES OF IMMUNITY. Broadly speaking, immunity or body defense mechanism is divided into 2 types, each with humoral and cellular components:

- ◆ **Natural or innate immunity** is *non-specific* and is considered as the first line of defense without antigenic specificity. It has 2 major components:
 - a) *Humoral*: comprised by complement.
 - b) *Cellular*: consists of neutrophils, macrophages, and natural killer (NK) cells.
- ◆ **Specific or adaptive immunity** is *specific* and is characterised by antigenic specificity. It too has 2 main components:
 - a) *Humoral*: consisting of antibodies formed by B cells.
 - b) *Cellular*: mediated by T cells.The various components of both types of immunity are interdependent and interlinked for their functions.

□ **ORGANS OF IMMUNE SYSTEM** (p. 61)

a) **Primary lymphoid organs:**

- i) Thymus
- ii) Bone marrow

b) **Secondary lymphoid organs:**

- i) Lymph nodes
- ii) Spleen
- iii) MALT (Mucosa-Associated Lymphoid Tissue located in the respiratory tract and GIT).

□ **CELLS OF IMMUNE SYSTEM** (p. 61)

While morphologic aspects of these cells are covered elsewhere in the book, their immune functions are briefly considered below and summarised in **Web Table 4.1**.

Lymphocyte is the master of human immune system. Morphologically, lymphocytes appear as a homogeneous group but functionally two major lymphocyte populations, *T* and *B lymphocytes* are identified; while a third type, *NK (natural killer) cells*, comprises a small percentage of circulating lymphocytes having the distinct appearance of *large granular lymphocytes*.

Just as other haematopoietic cells, all three subtypes of lymphocytes are formed from lymphoid precursor cells in the bone marrow. However, unlike other haematopoietic cells, lymphocytes undergo maturation and differentiation in the bone marrow (B cells) and thymus (T cells) and acquire certain genetic and immune surface characters which determine their type and function; this is based on *cluster of differentiation* (CD) molecule on their surface. CD surface protein molecules belong to immunoglobulin superfamily of cell adhesion molecules (CAMs).

Features and functions of subtypes of lymphocytes are summed up below and illustrated diagrammatically in **Web Image 4.2**:

B CELLS. These cells are involved in humoral immunity by inciting antibody response. B cells in circulation comprise about 10-15% of lymphocytes. On coming in contact with antigen (e.g. invading microorganisms), B cells are activated to proliferate and transform into plasmacytoid lymphocytes and then into plasma cells. Common B cell markers include: CD 19, 20, 21, 23. These cells also possess B cell receptors (BCR) for surface immunoglobulins (IgM and IgG) and Fc receptor for attaching to antibody molecule.

T CELLS. These cells are implicated in inciting cell-mediated immunity and delayed type of hypersensitivity. T cells in circulation comprise 75-80% of lymphocytes. Pan T cell markers are CD3, CD7 and CD2. Besides, T cells also carry receptor (TCR) for recognition of MHC molecules. Depending upon functional activity, T cells have two major subtypes.

T helper cells. Abbreviated as T_H cells, these cells promote and enhance the immune reaction and are also termed as *T-regulatory cells*. They carry CD4 molecule on their surface and hence are also called *CD4+ cells*. CD4+ cells in circulation are about twice the number of CD8+ cells (CD4+/CD8 ratio 2:1). These cells act by elaboration of variety of cytokines. Depending upon the type of cytokines elaborated, these T_H cells are further of two subclasses: T_H 1 and T_H 2.

- ◆ T_H 1 cells elaborate IL-2 and interferon (IFN)- γ .

- ◆ T_H 2 cells elaborate IL-4, IL-5, IL-6, and IL-10.

CD4+ cells are predominantly involved in cell-mediated reactions to viral infections (e.g. in HIV), tissue transplant reactions and tumour lysis.

T suppressor cells. Abbreviated as T_S cells, they suppress immune reactions but are cytotoxic and actually destroy the invading antigen; hence are also termed as *cytotoxic T lymphocytes (CTL)*. These cells carry CD8 molecule on their surface and hence are also called *CD8+ cells*. CD8+ cells in circulation are about half the number of CD4+ cells. Compared to CD4+ cells which act by elaboration of cytokines, CD8+ cells are directly cytotoxic to the antigen.

CD8+ cells are particularly involved in destroying cells infected with viruses, foreign cells and tumour cells.

Contrasting features of B and T cells are given in **Web Table 4.2**.

NATURAL KILLER (NK) CELLS. NK cells comprise about 10-15% of circulating lymphocytes. These lymphocytes do not have B or T cell markers, nor are these cells dependent upon thymus for development unlike CD4+ and CD8+ T cells. NK cells carry surface molecules of CD2, CD16 and CD56, but negative for T cell marker CD3. NK cells are morphologically distinct from B and T cells in being *large granular lymphocytes*.

NK cells are part of the natural or innate immunity. These cells recognise antibody-coated target cells and bring about killing of the target directly; this process is termed as *antibody-dependent cell-mediated cytotoxicity (ADCC)*. This mechanism is particularly operative against viruses and tumour cells.

Monocytes and Macrophages (p. 64)

Circulating monocytes are immature macrophages and constitute about 5% of peripheral leucocytes. They remain in circulation for about 3 days before they enter tissues to become macrophages. The macrophage subpopulations like the dendritic cells found in the lymphoid tissue and Langerhans' cells seen in the epidermis, are characterised by the presence of dendritic cytoplasmic processes and are active in the immune system.

Salient features and important immune functions of macrophages are as follows:

- 1. Antigen recognition.** They possess cell surface receptors to several extracellular molecules—receptor for cytokines, component of complement (C3b), selectins, integrins and Fc (constant fragment) of antibody. Macrophages have capacity to distinguish self from non-self by presence of human leucocyte antigens (HLA) or major histocompatibility complex (MHC).
- 2. Phagocytosis.** Antigen that has been recognised by the macrophages due to availability of above-mentioned surface receptors, or the opsonised antigen, is ready to be engulfed by the process of cell-eating by macrophages.
- 3. Secretory function.** Macrophages secrete important substances e.g. (i) *cytokines* (IL-1, IL-2, IL-6, 8, IL-10, IL-12, tumour necrosis factor- α) and *prostaglandins* (PGE, thromboxane-A, leukotrienes) which are chemical mediators of inflammation and activate other leucocytes. (ii) *Secretion of proteins involved in wound healing* e.g. collagenase, elastase, fibroblast growth factor, angiogenesis factor. (iii) *Acute phase reactants* e.g. fibronectin, microglobulin, complement components.
- 4. Antigen presentation.** When macrophages are unable to lyse an antigen or an organism, the next best course adopted by them is to act as antigen-presenting cells for presenting to immunocompetent T cells (subtype CD4+ or CD8+ cells), or to B cells.

Basophils and Mast Cells (p. 64)

Basophils are a type of circulating granulocytes (0-1%) while mast cells are their counterparts seen in tissues, especially in connective tissue around blood vessels and in submucosal location. Basophils and mast cells have IgE surface receptor; thus on coming in contact with antigen binding to IgE (e.g. allergic reaction to parasites), these cells get activated and release granules i.e. degranulate. These granules contain substances such as: histamine, platelet activating factor, heparin and certain chemical mediators (e.g. prostaglandins, leukotrienes).

Mast cells and basophils are thus involved in mediating inflammation in allergic reactions and have a role in wound healing.

Neutrophils (p. 64)

Polymorphonuclear neutrophils (PMNs) are normally the most numerous of the circulating leucocytes (40-75%). The cytoplasm of PMNs contains lysosomal granules of three types: primary (azurophilic), secondary, and tertiary.

PMNs have similar function to those of macrophages and are therefore appropriately referred to as '*microphages*' owing to their role as first line of defense against an invading foreign organism in the body. However, these cells have limitation of size and type of organisms to be engulfed.

Eosinophils are also circulating granulocytes (1-6%). These cells play a role in allergic reactions and in intestinal helminthiasis. The granules of eosinophils contain lysosomal enzymes, peroxidases, and chemical mediators of inflammation (e.g. prostaglandins, leukotrienes). On coming in contact with IgE opsonised antigen (e.g. helminths), eosinophils degranulate and release the chemicals stored in granules and incite inflammation.

HLA stands for *Human Leucocyte Antigens* because these antigens or genetic proteins in the body which determine one's own tissue from non-self (histocompatibility) were first discovered on the surface of leucocytes. Subsequently, it was found that HLA are actually gene complexes of proteins on the surface of all nucleated cells of the body and platelets. Since these complexes are of immense importance in matching donor and recipient for organ transplant, they are called *major histocompatibility complex (MHC)* or *HLA complex*.

Out of various genes for histocompatibility, most of the transplantation antigens or MHC are located on a portion of *chromosome 6* of all nucleated cells of the body and platelets. These genes occupy four regions or loci—A, B, C and D, on the short (p) arm of chromosome 6 and exhibit marked variation in allelic genes at each locus. Therefore, the product of HLA antigens is highly polymorphic. HLA system is part of immunoglobulin superfamily of CAMs.

Depending upon the characteristics of MHC, they have been divided into 3 classes (**Web Image 4.3**):

- ◆ **Class I MHC antigens** have loci as HLA-A, HLA-B and HLA-C. CD8+ (i.e. T suppressor) lymphocytes carry receptors for class I MHC and these cells are used to identify class I antigen on them.

- ◆ **Class II MHC antigens** have single locus as HLA-D. These antigens have further 3 loci: DR, DQ and DP. Class II MHC is identified by B cells and CD4+ (i.e. T helper) cells.

- ◆ **Class III MHC antigens** are some components of the complement system (C2 and C4) coded on HLA complex but are not associated with HLA expression and are not used in antigen identification.

ROLE OF HLA COMPLEX. The HLA complex is significant in a number of ways:

1. **Organ transplantation.** Historically, the major importance of HLA system is in matching donor and recipient for tissue transplantation. The recipient's immune system can recognise the histocompatibility antigens on the donor organ and accordingly accept it or reject it. Both humoral as well as cell-mediated immune responses are involved in case of genetically non-identical transplants.

2. **Regulation of the immune system.** Class I and II histocompatibility antigens play a role in regulating both cellular and humoral immunity:

- ◆ *Class I MHC antigens* regulate the function of cytotoxic T cells (CD8+ subpopulation) e.g. in virus infections.

- ◆ *Class II MHC antigens* regulate the function of helper T cells (CD4+ subpopulation).

3. **Association of diseases with HLA.** (i) *Inflammatory disorders.* (ii) *Autoimmune disorders.* (iii) *Inherited disorders of metabolism.*

According to the genetic relationship between donor and recipient, transplantation of tissues is classified into 4 groups:

1. *Autografts* are grafts in which the donor and recipient is the same individual.
2. *Isografts* are grafts between the donor and recipient of the same genotype.
3. *Allografts* are those in which the donor is of the same species but of a different genotype.
4. *Xenografts* are those in which the donor is of a different species from that of the recipient.

Presently, surgical skills exist for skin grafts and for organ transplants such as kidney, heart, lungs, liver, pancreas, cornea and bone marrow. But most commonly practised are skin grafting, and kidney and bone marrow transplantation. For any successful tissue transplant without immunological rejection, matched major histocompatibility locus antigens (HLA) between the donor and recipient are of paramount importance as discussed already.

Besides the rejection reaction, a peculiar problem occurring especially in bone marrow transplantation is *graft-versus-host (GVH) reaction*. In humans, GVH reaction results when immunocompetent cells are transplanted to an immunodeficient recipient e.g. when severe combined immunodeficiency is treated by bone marrow transplantation. The clinical features of GVH reaction include: fever, weight loss, anaemia, dermatitis, diarrhoea, intestinal malabsorption, pneumonia and hepatosplenomegaly.

Mechanisms of Graft Rejection (p. 66)

Except for autografts and isografts, an immune response against allografts is inevitable.

1. CELL-MEDIATED IMMUNE REACTIONS. These are mainly responsible for graft rejection and are mediated by T cells.

2. HUMORAL IMMUNE REACTIONS. Currently, in addition to the cell-mediated immune reactions, a role for humoral antibodies in certain rejection reactions has been suggested. These include: *performed circulating antibodies* due to *pre-sensitisation* of the recipient before transplantation.

Types of Rejection Reactions (p. 66)

Based on the underlying mechanism and time period, rejection reactions are classified into 3 types.

1. HYPERACUTE REJECTION. Hyperacute rejection appears within minutes to hours of placing the transplant and destroys it. It is mediated by performed humoral antibody against donor-antigen.

2. ACUTE REJECTION. This usually becomes evident within a few days to a few months of transplantation. Acute graft rejection may be mediated by cellular or humoral mechanisms. Acute cellular rejection is more common than acute humoral rejection.

3. CHRONIC REJECTION. Chronic rejection may follow repeated attacks of acute rejection or may develop slowly over a period of months to a year or so. The underlying mechanisms of chronic rejection may be immunologic or ischaemic.

DISEASES OF IMMUNITY (p. 66)

The word *immunity* is synonymous with *resistance* meaning protection from particular diseases or injuries, whereas the term *hypersensitivity* is interchangeable with *allergy* meaning a state of exaggerated or altered

immune response to a given agent. The diseases of the immune system are broadly classified into the following 4 groups:

I. Immunodeficiency disorders characterised by deficient cellular and/or humoral immune functions. This group is comprised by a list of *primary and secondary immunodeficiency diseases* including the dreaded *acquired immunodeficiency syndrome (AIDS)*.

II. Hypersensitivity reactions characterised by hyperfunction of the immune system and cover the various mechanisms of *immunologic tissue injury*.

III. Autoimmune diseases occur when the immune system fails to recognise 'self' from 'non-self'. A growing number of *autoimmune and collagen diseases* are included in this group.

IV. Possible immune disorders in which the immunologic mechanisms are suspected in their etiopathogenesis. Classical example of this group is *amyloidosis*.

□ IMMUNODEFICIENCY DISEASES (p. 67)

Traditionally, immunodeficiency diseases are classified into 2 types:

A. *Primary immunodeficiencies* are usually the result of genetic or developmental abnormality of the immune system.

B. *Secondary immunodeficiencies* arise from acquired suppression of the immune system.

A list of most immunodeficiency diseases with the possible defect in the immune system is given in **Web Table 4.3**.

ACQUIRED IMMUNODEFICIENCY SYNDROME (AIDS) (p. 67)

EPIDEMIOLOGY. Although AIDS was first described in the US, the disease has now attained pandemic proportions involving all continents. Presently, developing countries comprise majority of cases and Africa alone constitutes 50% of all positive cases globally. According to a rough estimate, 1 in every 100 sexually active adults worldwide is infected with HIV. Half of all serologically positive cases are in women while children comprise 5% of all cases. About 2.5 million new cases are getting added every year. In India, epicentre of the epidemic lies in the states of Maharashtra and Tamil Nadu which together comprise about 50% of all HIV positive cases (mostly contracted sexually), while North-East state of Manipur accounts for 8% of all cases (mostly among intravenous drug abusers).

ETIOLOGIC AGENT. AIDS is caused by an RNA retrovirus called human immunodeficiency virus (HIV) which is a type of human T cell leukaemia-lymphoma virus (HTLV).

HIV resembles other HTLVs in shape and size and both have *tropism for CD4 molecules* present on subpopulation of T cells which are the particular targets of attack by HIV. However, *HIV differs from HTLV in being cytolytic for T cells causing immunodeficiency (cytopathic virus) while HTLV may transform the target cells into T cell leukaemia (transforming virus)*. Two forms of HIV have been described, HIV1 being the etiologic agent for AIDS in the US and Central Africa, while HIV2 causes a similar disease in West Africa and parts of India.

HIV-1 virion or virus particle is spherical in shape and 100-140 nm in size (**Web Image 4.4**):

- ◆ It contains a *core* having *core proteins*, chiefly p24 and p18, two strands of genomic RNA and the enzyme, reverse transcriptase.

- ◆ The core is covered by a *double layer of lipid membrane* derived from the outer membrane of the infected host cell during budding process of virus. The membrane is studded with 2 *envelope glycoproteins, gp120 and gp41*.

Besides various other genes, **three important genes** code for the respective components of virion:

- i) *gag* (*group antigen*) for core proteins,
- ii) *pol* (*polymerase*) for reverse transcriptase, and
- iii) *env* (*envelope*) for the envelope proteins.

ROUTES OF TRANSMISSION

1. Sexual transmission. Sexual contact is the main mode of spread and constitutes 75% of all cases of HIV transmission. Most cases of AIDS in the industrialised world like in the US occur in *homosexual or bisexual males* while *heterosexual promiscuity* seems to be the dominant mode of HIV infection in Africa and Asia.

2. Transmission via blood and blood products. This mode of transmission is the next largest group (25%) and occurs in 3 groups of high-risk populations: (i) *Intravenous drug abusers* (ii) *Haemophiliacs* (iii) *Recipients of HIV-infected blood and blood products*.

3. Perinatal transmission. HIV infection occurs from infected mother to the newborn during pregnancy *transplacentally*, or in immediate post-partum period *through contamination* with maternal blood, infected amniotic fluid or breast milk.

4. Occupational transmission. There have been a small number of health care workers (HCW), laboratory workers and those engaged in disposal of waste of sharps who have developed HIV infection by occupational exposure to HIV-infected material.

5. Transmission by other body fluids. Although besides blood, HIV has been isolated and identified from a number of body fluids such as saliva, tears, sweat and urine, semen, vaginal secretions, cervical secretions, breast milk, CSF, synovial, pleural, peritoneal and pericardial fluid, there is no definite evidence that HIV transmission can occur by any of these fluids.

It should also be appreciated that HIV contaminated waste products can be *sterilised and disinfected* by most of the chemical germicides used in laboratories at a much lower concentration. These are: sodium hypochlorite (liquid chlorine bleach), formaldehyde (5%), ethanol (70%), glutaraldehyde (2%), β -propiolactone. HIV is also heat-sensitive and can be inactivated at 56°C for 30 min.

PATHOGENESIS. The pathogenesis of HIV infection is largely related to the *depletion of CD4+ T cells (helper T cells) resulting in profound immunosuppression*.

The sequence of events shown schematically in **Web Image 4.5** is outlined below:

1. Selective tropism for CD4 molecule receptor. gp120 envelope glycoprotein of HIV has selective tropism for cells containing CD4 molecule receptor on their surface; these cells most importantly are CD4+ T cells (T helper cells); other such cells include monocyte-macrophages, microglial cells, epithelial cells of the cervix, Langerhans cells of the skin and follicular dendritic cells.

2. Internalisation. gp120 of the virion combines with CD4 receptor, but for fusion of virion with the host cell membrane, a chemokine coreceptor (CCR) is necessary.

3. Uncoating and viral DNA formation. Once the virion has entered the T cell cytoplasm, reverse transcriptase of the viral RNA forms a single-stranded DNA. Using the single-stranded DNA as a template, DNA polymerase copies it to make it double-stranded DNA.

4. Viral integration. The viral DNA so formed may initially remain *unintegrated* in the affected cell but later viral integrase protein inserts the viral DNA into nucleus of the host T cell and *integrates* in the host cell DNA.

5. Viral replication. HIV provirus having become part of host cell DNA, host cell DNA transcripts for viral RNA with presence of *tat* gene. Multiplication of viral particles is further facilitated by release of cytokines from T helper cells (CD4+ T cells). Released cytokines are also responsible for spread of infection to other body sites, in particular to CNS by TNF- α .

6. Latent period and immune attack. In an inactive infected T cell, the infection may remain in latent phase for a long time, accounting for the long incubation period. However, this period is short and the virus soon overpowers the host immune system.

7. CD4+ T cell destruction. Viral particles replicated in the CD4+ T cells start forming *buds* from the cell wall of the host cell. As these particles detach from the infected host cell, they damage part of the cell membrane of the host cell and cause death of host CD4+ T cells by apoptosis.

8. Viral dissemination. Release of viral particles from infected host cell spreads the infection to more CD4+ host cells and produces viraemia.

9. Impact of HIV infection on other immune cells. HIV infects other cells of the host immune system and also affects non-infected lymphoid cells.

The net result of immunological changes in the host due to HIV infection lead to profound immunosuppression rendering the host susceptible to opportunistic infections and tumours, to which he ultimately succumbs.

10. HIV infection of nervous system. Out of non-lymphoid organ involvement, HIV infection of nervous system is the most serious and 75-90% of AIDS patients may demonstrate some form of neurological involvement at autopsy. It infects microglial cells, astrocytes and oligodendrocytes.

A summary of major abnormalities in the immune system in AIDS is given in **Web Table 4.4**.

NATURAL HISTORY. HIV infection progresses from an early acute syndrome to a prolonged asymptomatic state to advanced disease. Generally, in an immunocompetent host, the biologic course passes through following 3 phases (**Web Table 4.5**):

1. Acute HIV syndrome (3-12 weeks). Entry of HIV into the body is heralded by the following sequence of events:

- i) High levels of plasma *viraemia* due to replication of the virus.
- ii) Virus-specific immune response by formation of anti-HIV antibodies (*seroconversion*) after 3-6 weeks of initial exposure to HIV.
- iii) Initially, sudden marked reduction in *CD4+ T cells* (helper T cells) followed by return to normal levels.
- iv) Rise in *CD8+ T cells* (Cytotoxic T cells).
- v) Appearance of self-limited non-specific *acute viral illness* (flu-like or infectious mononucleosis-like) in 50-70% of adults within 3-6 weeks of initial infection.

2. Middle chronic phase (10-12 years). The initial acute seroconversion illness is followed by a phase of competition between HIV and the host immune response as under:

- i) *Viraemia* due to viral replication in the lymphoid tissue continues which is initially not as high but with passage of time viral load increases due to crumbling host defenses.
- ii) Chronic stage, depending upon host immune system, may continue as long as *10 years*.
- iii) *CD 4+ T cells* continue to proliferate but net result is moderate fall in CD4+ T cell counts.
- iv) Cytotoxic CD8+ T cell count remains high.
- v) Clinically, it may be a stage of *latency* and the patient may be asymptomatic, or may develop mild constitutional symptoms and persistent generalised lymphadenopathy.

3. Final crisis phase. This phase is characterised by profound immunosuppression and onset of full-blown AIDS and has the following features:

- i) Marked increase in *viraemia*.
- ii) The time period from HIV infection through chronic phase into full-blown AIDS may last 7-10 years and culminate in death.
- iv) CD4+ T cells are markedly reduced (below 200 per μ l).

The average survival after the onset of full-blown AIDS is about 2 years.

Children often have a rapidly progressive disease and full blown AIDS occurring at 4 to 8 years of age.

REVISED CDC HIV CLASSIFICATION SYSTEM. The Centers for Disease Control and Prevention (CDC), US in 1993 revised the classification system for HIV infection in adults and children based on 2 parameters: clinical manifestations and CD4+ T cell counts. According to this classification, HIV-AIDS has 3 categories: A, B and C (**Web Table 4.5**).

Similarly, there are revised parameters for *paediatric HIV classification* in which age-adjusted CD4+ T cell counts are given which are relatively higher in each corresponding category.

PATHOLOGICAL LESIONS AND CLINICAL MANIFESTATIONS OF HIV/AIDS. HIV/AIDS affects all body organs and systems. In general, clinical manifestations and pathological lesions in different organs and systems are owing to progressive deterioration of body's immune system. Pathological lesions and clinical manifestations in HIV disease can be explained by 4 mechanisms: (i) *Due to viral infection directly* (ii) *Due to opportunistic infections* (iii) *Due to secondary tumours* (iv) *Due to drug treatment*.

Based on above mechanisms, salient clinical features and pathological lesions in different organs and systems are briefly outlined below and illustrated in **Web Image 4.6**.

1. Wasting syndrome.
2. Persistent generalised lymphadenopathy.
3. GI lesions and manifestations.
4. Pulmonary lesions and manifestations.
5. Mucocutaneous lesions and manifestations.
6. Haematologic lesions and manifestations.
7. CNS lesions and manifestations.
8. Gynaecologic lesions and manifestations.
9. Renal lesions and manifestations.
10. Hepatobiliary lesions and manifestations.
11. Cardiovascular lesions and manifestations.
12. Ophthalmic lesions.
13. Musculoskeletal lesions.
14. Endocrine lesions.

DIAGNOSIS OF HIV/AIDS. The investigations of a suspected case of HIV/AIDS are categorised into 3 groups. These tests are as under (**Web Table 4.6**):

1. Tests for establishing HIV infection:

i) *Antibody tests:* (a) *ELISA* (b) *Western blot*.

ii) *Direct detection of HIV:* (a) *p24 antigen capture assay*. (b) *HIV RNA assay methods*. (c) *DNA-PCR* by amplification of proviral DNA. (d) *Culture* of HIV from blood monocytes and CD4+ T cells.

2. Tests for defects in immunity:

- i) *CD4+ T cell counts*.
- ii) *Rise in CD8+ T cells*.
- iii) *Reversal of CD4+ to CD8+ T cell ratio*.
- iv) *Lymphopenia*.
- v) *Polyclonal hypergammaglobulinaemia*.

- vi) Increased β -2 microglobulin levels.
- vii) Platelet count revealing thrombocytopenia.

3. Tests for detection of opportunistic infections and secondary tumours: Diagnosis of organs involved in opportunistic infection and specific tumours secondary to HIV/AIDS is made by aspiration or biopsy methods.

□ **HYPERSENSITIVITY REACTIONS
(IMMUNOLOGIC TISSUE INJURY) (p. 73)**

Hypersensitivity is defined as an exaggerated or inappropriate state of normal immune response with onset of adverse effects on the body. These lesions are termed as hypersensitivity reactions or immunologic tissue injury, of which 4 types are described: type I, II, III and IV. Depending upon the *rapidity, duration and type* of the immune response, these 4 types of hypersensitivity reactions are grouped into immediate and delayed type:

- 1. Immediate type** in which on administration of antigen, the reaction occurs immediately (within seconds to minutes). Immune response in this type is mediated largely by *humoral antibodies* (B cell mediated). Immediate type of hypersensitivity reactions includes *type I, II and III*.
- 2. Delayed type** in which the reaction is slower in onset and develops within 24-48 hours and the effect is prolonged. It is mediated by *cellular response* (T cell mediated) and it includes *Type IV reaction*.

The mechanisms and examples of immunologic tissue injury by the 4 types of hypersensitivity reactions are summarised in **Web Table 4.7**.

Type I: Anaphylactic (Atopic) Reaction (p. 73)

Type I hypersensitivity is defined as a state of rapidly developing or anaphylactic type of immune response to an antigen (i.e. allergen) to which the individual is previously sensitised (anaphylaxis is the opposite of prophylaxis). The reaction appears within 15-30 minutes of exposure to antigen.

Type I reaction is mediated by *humoral antibodies of IgE type or reagin antibodies* in response to antigen. Although definite cause for this form of immediate reaction to allergen is not known, the possible hypotheses are: genetic basis, environmental pollutants and concomitant factors.

Type I reaction includes participation by B lymphocytes and plasma cells, mast cells and basophils, neutrophils and eosinophils.

Examples of Type I Reaction

Systemic anaphylaxis:

- i) Administration of antisera e.g. anti-tetanus serum (ATS).
- ii) Administration of drugs e.g. penicillin.
- iii) Sting by wasp or bee.

Local anaphylaxis:

- i) Hay fever (seasonal allergic rhinitis) due to pollen sensitisation of conjunctiva and nasal passages.
- ii) Bronchial asthma due to allergy to inhaled allergens like house dust.
- iii) Food allergy to ingested allergens like fish, cow's milk, eggs etc.
- iv) Cutaneous anaphylaxis due to contact of antigen with skin characterised by urticaria, wheal and flare.
- v) Angioedema, an autosomal dominant inherited disorder characterised by laryngeal oedema, oedema of eyelids, lips, tongue and trunk.

Type II: Cytotoxic (Cytolytic) Reaction (p. 76)

Type II or cytotoxic reaction is defined as reactions by humoral antibodies that attack cell surface antigens on the specific cells and tissues and cause lysis of target cells. Type II reaction too appears generally within 15-30

minutes after exposure to antigen but in myasthenia gravis and thyroiditis it may appear after longer duration.

In general, type II reactions have participation by complement system, tissue macrophages, platelets, natural killer cells, neutrophils and eosinophils while main antibodies are IgG and IgM. Type II hypersensitivity is tissue-specific and reaction occurs after antibodies bind to tissue specific antigens, most often on blood cells.

Examples of Type II Reaction

Cytotoxic antibodies to blood cells. Most common examples of type II reaction are on blood cells.

- i) *Autoimmune haemolytic anaemia*
- ii) *Transfusion reactions*
- iii) Haemolytic disease of the newborn (*erythroblastosis foetalis*)
- iv) *Idiopathic thrombocytopenic purpura* (ITP)
- v) *Leucopenia with agranulocytosis*
- vi) *Drug-induced cytotoxic antibodies* .

2. Cytotoxic antibodies to tissue components. Cellular injury may be brought about by autoantibodies reacting with some components of tissue cells in certain diseases, e.g. in *Graves' disease* (primary hyperthyroidism), *myasthenia gravis*, *male sterility*, *type 1 diabetes mellitus*, *hyperacute rejection reaction*.

Type III: Immune Complex Mediated (Arthus) Reaction (p. 76)

Type III reactions result from deposition of antigen-antibody complexes on tissues, which is followed by activation of the complement system and inflammatory reaction, resulting in cell injury. The onset of type III reaction takes place about 6 hours after exposure to the antigen.

Type III reaction is not tissue specific and occurs when antigen-antibody complexes fail to get removed by the body's immune system. There can be 3 types of possible etiologic factors precipitating type III reaction:

1. Persistence of low-grade microbial infection.
2. Extrinsic environmental antigen.
3. Autoimmune process.

It may be mentioned here that both type II and type III reactions have antigen-antibody complex formation but the two can be distinguished—antigen in type II is tissue specific while in type III is not so; moreover the mechanism of cell injury in type II is direct but in type III it is by deposition of antigen-antibody complex on tissues and subsequent sequence of cell injury takes place.

Type III reaction has participation by IgG and IgM antibodies, neutrophils, mast cells and complement.

Examples of Type III Reaction

- i) Immune complex glomerulonephritis in which the antigen may be GBM or exogenous agents (e.g. Streptococcal antigen).
- ii) Goodpasture syndrome having GBM as antigen.
- iii) SLE in which there is nuclear antigen (DNA, RNA) and there is formation of anti-nuclear and anti-DNA autoantibodies.
- iv) Rheumatoid arthritis in which there is nuclear antigen.
- v) Farmer's lung in which actinomycetes-contaminated hay acts as antigen.
- vi) Polyarteritis nodosa and Wegener's granulomatosis with antineutrophil cytoplasmic antigen.
- vii) Henoch-Schönlein purpura in which respiratory viruses act as antigen.
- viii) Drug-induced vasculitis in which the drug acts as antigen.

52 Type IV: Delayed Hypersensitivity (Cell-Mediated) Reaction (p. 77)

Type IV or delayed hypersensitivity reaction is tissue injury by cell mediated immune response without formation of antibodies (contrary to type I, II and III) but is instead a slow and prolonged response of specifically-sensitised T lymphocytes. The reaction occurs about 24 hours after exposure to antigen and the effect is prolonged which may last up to 14 days.

Type IV reaction involves role of mast cells and basophils, macrophages and CD8+ T cells.

Examples of Type IV Reaction

1. Reaction against mycobacterial infection e.g. tuberculin reaction, granulomatous reaction in tuberculosis, leprosy.
2. Reaction against virally infected cells.
3. Reaction against malignant cells in the body.
4. Reaction against organ transplantation e.g. transplant rejection, graft versus host reaction.

□ AUTOIMMUNE DISEASES (p. 77)

Autoimmunity is a state in which the body's immune system fails to distinguish between 'self' and 'non-self' and reacts by formation of autoantibodies against one's own tissue antigens. In other words, there is loss of tolerance to one's own tissues; *autoimmunity is the opposite of immune tolerance*.

PATHOGENESIS (THEORIES) OF AUTOIMMUNITY (p. 77)

The mechanisms by which the immune tolerance of the body is broken causes autoimmunity. These mechanisms or theories of autoimmunity may be immunological, genetic, and microbial, all of which may be interacting.

1. Immunological factors. Failure of immunological mechanisms of tolerance initiates autoimmunity. These mechanisms are as follows:

- i) *Polyclonal activation of B cells.*
- ii) *Generation of self-reacting B cell clones*
- iii) *Decreased T suppressor and increased T helper cell activity.*
- iv) *Fluctuation of anti-idiotypic network control*
- v) *Sequestered antigen released from tissues.*

2. Genetic factors. There is evidence in support of genetic factors in the pathogenesis of autoimmunity as under:

- i) There is increased expression of *Class II HLA antigens* on tissues involved in autoimmunity.
- ii) There is increased *familial incidence* of some of the autoimmune disorders.

3. Microbial factors. Infection with microorganisms, particularly viruses (e.g. EBV infection), and less often bacteria (e.g. streptococci, *Klebsiella*) and mycoplasma, has been implicated in the pathogenesis of autoimmune diseases.

TYPES AND EXAMPLES OF AUTOIMMUNE DISEASES (p. 78)

1. Organ specific diseases. In these, the autoantibodies formed react specifically against an organ or target tissue component and cause its chronic inflammatory destruction.

2. Organ non-specific (Systemic) diseases. These are diseases in which a number of autoantibodies are formed which react with antigens in many tissues and thus cause systemic lesions. The examples of this group are various systemic collagen diseases.

Based on these 2 main groups, a comprehensive list of autoimmune (or collagen) diseases is presented in **Web Table 4.8**.

Systemic Lupus Erythematosus (SLE) (p. 78)

SLE is the classical example of systemic autoimmune or collagen diseases. Two forms of lupus erythematosus are described:

1. **Systemic or disseminated form** is characterised by acute and chronic inflammatory lesions widely scattered in the body and there is presence of various nuclear and cytoplasmic autoantibodies in the plasma.
2. **Discoid form** is characterised by chronic and localised skin lesions involving the bridge of nose and adjacent cheeks without any systemic manifestations.

ETIOLOGY. The exact etiology of SLE is not known. However, autoantibodies against nuclear and cytoplasmic components of the cells are demonstrable in plasma by immunofluorescence tests in almost all cases of SLE.

i) **Antinuclear antibodies (ANA)** are the antibodies against common nuclear antigen that includes DNA as well as RNA. These are demonstrable in about 98% cases and is the best as screening test.

ii) **Antibodies to double-stranded (anti-dsDNA)** is the most specific for SLE, especially in high titres, and is present in 70% cases.

iii) **Anti-Smith antibodies (anti-Sm)**

iv) **Other non-specific antibodies**

- a) *Anti-ribonucleoproteins (anti-RNP)*.
- b) *Anti-histone antibody.*
- c) *Antiphospholipid antibodies or lupus anticoagulant.*
- d) *Antiribosomal P antibody.*

The source of these autoantibodies as well as hypergammaglobulinaemia seen in SLE is the **polyclonal activation of B cells** brought about by following derangements:

1. *Immunologic factors.*
2. *Genetic factors.*
3. *Other factors.*

LE CELL PHENOMENON. This was the first diagnostic laboratory test described for SLE. The test is based on the principle that ANAs cannot penetrate the intact cells and thus cell nuclei should be exposed to bind them with the ANAs. The binding of exposed nucleus with ANAs results in homogeneous mass of nuclear chromatin material which is called *LE body* or *haematoxylin body*.

LE cell is a phagocytic leucocyte, commonly polymorphonuclear neutrophil, and sometimes a monocyte, which engulfs the homogeneous nuclear material of the injured cell. For demonstration of LE cell phenomenon *in vitro*, the blood sample is traumatised to expose the nuclei of blood leucocytes to ANAs. This results in binding of denatured and damaged nucleus with ANAs. The ANA-coated denatured nucleus is chemotactic for phagocytic cells.

◆ If this mass is engulfed by a neutrophil, displacing the nucleus of neutrophil to the rim of the cell, it is called *LE cell (Web Image 4.8,A)*.

◆ If the mass, more often an intact lymphocyte, is phagocytosed by a monocyte, it is called *Tart cell (Web Image 4.8,B)*.

LE cell test is positive in 70% cases of SLE. A few other conditions may also show positive LE test e.g. rheumatoid arthritis, lupoid hepatitis, penicillin sensitivity etc.

The manifestations of SLE are widespread in different visceral organs as well as show erythematous cutaneous eruptions. The principal lesions are renal, vascular, cutaneous and cardiac; other organs and tissues involved are serosal linings (pleuritis, pericarditis); joints (synovitis); spleen (vasculitis); liver (portal triaditis); lungs (interstitial pneumonitis, fibrosing alveolitis), CNS (vasculitis) and in blood (autoimmune haemolytic anaemia, thrombocytopenia).

M/E The characteristic lesion in SLE is *fibrinoid necrosis* which may be seen in the connective tissue, beneath the endothelium in small blood vessels,

under the mesothelial lining of pleura and pericardium, under the endothelium in endocardium, or under the synovial lining cells of joints.

Web Table 4.9 summarises the morphology of lesions in different organs and tissues in SLE.

Scleroderma (Progressive Systemic Sclerosis) (p. 80)

Just like SLE, scleroderma was initially described as a skin disease characterised by progressive fibrosis. But now, 2 main types are recognised:

1. *Diffuse scleroderma* in which the skin shows widespread involvement and may progress to involve visceral structures.
2. *CREST syndrome* of progressive systemic sclerosis characterised by Calcinosis (C), Raynaud's phenomenon (R), Esophageal hypomotility (E), Sclerodactyly (S) and Telangiectasia (T).

The etiology of this disease is not known.

The *immune mechanisms* leading to stimulation of fibroblasts may act in the following ways:

1. *Elaboration of cytokines*
2. *Endothelial cell injury* due to cytotoxic damage.

1. **Skin changes.** Skin is involved diffusely, beginning distally from fingers and extending proximally to arms, shoulders, neck and face. In advanced stage, the fingers become claw-like and face mask-like.

M/E The features are as under:

● *Early stage* shows oedema and degeneration of collagen.
 ● *Late stage* reveals thin and flat epidermis. Dermis is largely replaced by compact collagen.

2. **Kidney changes.** Involvement of kidneys is seen in majority of cases of systemic sclerosis. The lesions are prominent in the walls of interlobular arteries.

3. **Smooth muscle of GIT.** Muscularis of the alimentary tract, particularly oesophagus, is progressively atrophied and replaced by fibrous tissue.

4. **Skeletal muscle.** The interstitium of skeletal muscle shows progressive fibrosis and degeneration of muscle fibres with associated inflammatory changes.

5. **Cardiac muscle.** Involvement of interstitium of the heart may result in heart failure.

6. **Lungs.** Diffuse fibrosis may lead to contraction of the lung substance. There may be epithelium-lined honey-combed cysts of bronchioles.

Polymyositis-Dermatomyositis (p. 81)

As the name suggests, this disease is a combination of symmetric muscle weakness and skin rash.

The skeletal muscles usually affected are of pelvis, shoulders, neck, chest and diaphragm.

M/E Vacuolisation and fragmentation of muscle fibres and numerous inflammatory cells are present. In late stage, muscle fibres are replaced by fat and fibrous tissue.

Sjögren's Syndrome (p. 81)

Sjögren's syndrome is characterised by the *triad* of dry eyes (*keratoconjunctivitis sicca*), dry mouth (*xerostomia*), and *rheumatoid arthritis*. The combination of the former two symptoms is called *sicca syndrome*.

M/E In *early stage*, the lacrimal and salivary glands show periductal infiltration by lymphocytes and plasma cells, which at times may form lymphoid follicles (pseudolymphoma). In *late stage*, glandular parenchyma is replaced by fat and fibrous tissue. The ducts are also fibrosed and hyalinised.

Reiter's Syndrome (p. 81)

This syndrome is characterised by *triad of arthritis, conjunctivitis and urethritis*.

Amyloidosis is the term used for a group of diseases characterised by extracellular deposition of fibrillar proteinaceous substance called amyloid having common morphological appearance, staining properties and physical structure but with variable protein (or biochemical) composition.

By H&E staining under *light microscopy*, amyloid appears as extracellular, homogeneous, structureless and eosinophilic hyaline material; it stains *positive with Congo red* staining and shows apple-green birefringence on *polarising microscopy*.

□ **PHYSICAL AND CHEMICAL NATURE OF AMYLOID (p. 82)**

It emerges that on the basis of morphology and physical characteristics, all forms of amyloid are similar in appearance, but they are chemically heterogeneous. Based on these analysis, amyloid is composed of 2 main types of complex proteins (**Web Image 4.9**):

I. Fibril Proteins (p. 82)

By electron microscopy, it became apparent that major component of all forms of amyloid (about 95%) consists of meshwork of fibril proteins. The *fibrils* are delicate, randomly dispersed, non-branching, each measuring 7.5-10 nm in diameter and having indefinite length. The fibrils are shown to have *cross- β -pleated* sheet configuration that gives the characteristic staining properties of amyloid with Congo red and birefringence under polarising microscopy.

Chemically two major forms of amyloid fibril proteins were first identified in 1970s while currently 20 biochemically different proteins are known to form amyloid fibrils in humans in different clinicopathologic settings. Thus these proteins can be categorised as under:

AL PROTEIN. AL amyloid fibril protein is derived from immunoglobulin light chain, which in most cases includes amino-terminal segment of the immunoglobulin light chain and part of C region. AL fibril protein is more frequently derived from the lambda (λ) light chain than kappa (κ), the former being twice more common. However, in any given case, there is amino acid sequence homology.

AL type of fibril protein is produced by immunoglobulin-secreting cells and is therefore seen in association with plasma cell dyscrasias and is included in primary systemic amyloidosis.

AA PROTEIN. AA fibril protein is composed of protein with molecular weight of 8.5-kD which is derived from larger precursor protein in the serum called SAA (serum amyloid-associated protein) with a molecular weight of 12.5-kD. SAA is an acute phase reactant protein synthesised in the liver, its level being high in chronic inflammatory and traumatic conditions.

SAA fibril protein is found in secondary amyloidosis which includes the largest group of diseases associated with amyloidosis.

OTHER PROTEINS. Apart from the two major forms of amyloid fibril proteins, a few other forms of proteins are found in different clinical states:

1. Transthyretin (TTR). It is a serum protein synthesised in the liver and transports *thyroxine* and *retinol* normally (trans-thy-retin).

ATTR is the most common form of hereditary amyloidosis e.g. in familial amyloid polyneuropathies. However, the deposits of ATTR in the elderly primarily involving the heart (senile cardiac amyloidosis) consists of normal TTR without any mutation.

2. **A β ₂-microglobulin (A β ₂M).** This form of amyloid is seen in cases of long-term haemodialysis (for 8-10 years). As the name suggests, β ₂M is a small protein which is a normal component of major histocompatibility complex (MHC) and has β -pleated sheet structure.
3. **β -amyloid protein (A β).** A β is distinct from A β ₂M and is seen in cerebral plaques as well as cerebral blood vessels in Alzheimer's disease.
4. **Immunoglobulin heavy chain amyloid (AH).** AH is derived from truncated heavy chain of immunoglobulin and is an uncommon form of systemic amyloidosis.

II. Non-fibrillar Components (p. 83)

Non-fibrillar components comprise about 5% of the amyloid material. These include the following:

1. **Amyloid P (AP)-component.** It is synthesised in the liver and is present in all types of amyloid. It is derived from circulating serum amyloid P-component, a glycoprotein resembling the normal serum α ₁-glycoprotein and is PAS-positive. It is structurally related to C-reactive protein, an acute phase reactant, but is not similar to it. By electron microscopy, it has a pentagonal profile (P-component) or doughnut-shape with an external diameter of 9 nm and internal diameter of 4 nm.
2. **Apolipoprotein-E (apoE).** It is a regulator of lipoprotein metabolism and is found in all types of amyloid.
3. **Sulfated glycosaminoglycans(GAGs).** These are constituents of matrix proteins; particularly associated is heparan sulfate in all types of tissue amyloid.

□ PATHOGENESIS OF AMYLOIDOSIS (p. 83)

It is now appreciated that amyloidosis or fibrillogenesis is multifactorial and that different mechanisms are involved in different types of amyloid.

Irrespective of the type of amyloid, amyloidogenesis in general *in vivo*, occurs in the following sequence (**Web Image 4.10**):

1. *Pool of amyloidogenic precursor protein* is present in circulation in different clinical settings and in response to stimuli e.g. increased hepatic synthesis of AA or ATTR, increased synthesis of AL etc.
2. *A nidus for fibrillogenesis*, meaning thereby an alteration in microenvironment, to stimulate deposition of amyloid protein is formed.
3. *Partial degradation or proteolysis* occurs prior to deposition of fibrillar protein which may occur in macrophages or reticuloendothelial cells e.g. partial degradation of AL, AA.
4. *Exceptions to this generalisation*, however, are seen in ATTR (heredofamilial type in which there are amino acid mutations in most cases), A β ₂M (in which there are elevated levels of normal β ₂M protein which remain unfiltered during haemodialysis) and prionosis (in which β -pleated sheet is formed *de novo*).
5. The role of *non-fibrillar components* such as AP, apoE and GAGs in amyloidosis is unclear; probably they facilitate in aggregation of proteins and protein folding leading to fibril formation, substrate adhesion and protection from degradation.

Deposition of AL Amyloid (p. 84)

1. The stimulus for production of AL amyloid is some disorder of *immunoglobulin synthesis* e.g. multiple myeloma, B cell lymphoma, other plasma cell dyscrasias.
2. Excessive immunoglobulin production is in the form of *monoclonal gammopathy* i.e. there is production of either intact immunoglobulin, or λ light chain, or κ light chain, or rarely heavy chains. This takes place by monoclonal proliferation of plasma cells, B lymphocytes, or their precursors.

3. *Partial degradation* in the form of limited proteolysis of larger protein molecules occurs in macrophages that are anatomically closely associated with AL amyloid.
4. *Non-fibrillar components* like AP and GAGs play some role in folding and aggregation of fibril proteins.

Deposition of AA Amyloid (p. 85)

1. AA amyloid is directly related to *SAA levels*, a high-density lipoprotein. SAA is synthesised by the liver in response to *cytokines*, notably interleukin 1 and 6, released from activated macrophages.
2. The levels of SAA are elevated in *long-standing tissue destruction* e.g. in chronic inflammation, cancers. However, SAA levels in isolation do not always lead to AA amyloid.
3. As in AL amyloid, *partial degradation* in the form of limited proteolysis takes place in reticuloendothelial cells.
4. In AA amyloid, a significant role is played by another glycoprotein, *amyloid enhancing factor (AEF)*.
5. As in AL amyloid, there is a role of *AP component* and *glycosaminoglycans* in the fibril protein aggregation and to protect it from disaggregation again.

□ CLASSIFICATION OF AMYLOIDOSIS (p. 85)

With availability of biochemical composition of various forms of amyloid and diverse clinical settings in which these specific biochemical forms of amyloid are deposited, a *clinicopathologic classification* has been proposed which is widely acceptable (**Web Table 4.10**). According to this classification, amyloidosis can be divided into 2 major categories and their subtypes depending upon clinical settings:

A. SYSTEMIC AMYLOIDOSIS (p. 86)

1. Primary Systemic (AL) Amyloidosis (p. 86)

Primary amyloidosis consisting of AL fibril proteins is systemic or generalised in distribution. About 30% cases of AL amyloid have some form of plasma cell dyscrasias, most commonly multiple myeloma (in about 10% cases), and less often other monoclonal gammopathies. Almost all cases of multiple myeloma have either λ or κ light chains (Bence Jones proteins) in the serum and are excreted in the urine.

The remaining 70% cases of AL amyloid do not have evident B-cell proliferative disorder or any other associated diseases and are thus cases of true 'primary' (idiopathic) amyloidosis.

AL amyloid is most prevalent type of systemic amyloidosis in North America and Europe and is seen in individuals past the age of 40 years. Primary amyloidosis is often severe in the heart, kidney, bowel, skin, peripheral nerves, respiratory tract, skeletal muscle, and other organs.

2. Secondary/Reactive (AA) Systemic Amyloidosis (p. 86)

The second form of systemic or generalised amyloidosis is reactive or inflammatory or secondary in which the fibril proteins contain AA amyloid. Secondary or reactive amyloidosis occurs typically as a complication of chronic infectious (e.g. tuberculosis, bronchiectasis, chronic osteomyelitis, chronic pyelonephritis, leprosy, chronic skin infections), non-infectious chronic inflammatory conditions associated with tissue destruction (e.g. autoimmune disorders such as rheumatoid arthritis, inflammatory bowel disease), some tumours (e.g. renal cell carcinoma, Hodgkin's disease) and in familial Mediterranean fever, an inherited disorder (discussed below).

Secondary amyloidosis is typically distributed in solid abdominal viscera like the kidney, liver, spleen and adrenals. Secondary reactive amyloidosis

is seen less frequently in developed countries due to containment of infections before they become chronic but this is the more common type of amyloidosis in underdeveloped and developing countries of the world. Secondary systemic amyloidosis can occur at any age including children.

The contrasting features of the two main forms of systemic amyloidosis are given in **Web Table 4.11**.

3. Haemodialysis-Associated (A β_2 M) Amyloidosis (p. 86)

Patients on long-term dialysis for more than 10 years for chronic renal failure may develop systemic amyloidosis derived from β_2 -microglobulin which is normal component of MHC. The amyloid deposits are preferentially found in the vessel walls at the synovium, joints, tendon sheaths and subchondral bones.

4. Heredofamilial Amyloidosis (p. 87)

i) Hereditary polyneuropathic (ATTR) amyloidosis. This is an autosomal dominant disorder in which amyloid is deposited in the peripheral and autonomic nerves resulting in muscular weakness, pain and paraesthesia, or may have cardiomyopathy. This type of amyloid is derived from transthyretin (ATTR) with single amino acid substitution in the structure of TTR.

ii) Amyloid in familial Mediterranean fever (AA). This is an autosomal recessive disease and is seen in the Mediterranean region (i.e. people residing in the countries surrounding the Mediterranean sea e.g. Sephardic Jews, Armenians, Arabs and Turks).

B. LOCALISED AMYLOIDOSIS (p. 87)

1. Senile cardiac amyloidosis (ATTR). Senile cardiac amyloidosis is seen in 50% of people above the age of 70 years. The deposits are seen in the heart and aorta. The type of amyloid in these cases is ATTR but without any change in the protein structure of TTR.

2. Senile cerebral amyloidosis (A β , APrP). Senile cerebral amyloidosis is heterogeneous group of amyloid deposition of varying etiologies that includes sporadic, familial, hereditary and infectious. Some of the important diseases associated with cerebral amyloidosis and the corresponding amyloid proteins are: Alzheimer's disease (A β), Down's syndrome (A β) and transmissible spongiform encephalopathies (APrP) such as in Creutzfeldt-Jakob disease, fatal familial insomnia, mad cow disease, kuru.

In Alzheimer's disease, deposit of amyloid is seen as Congoophilic angiopathy (amyloid material in the walls of cerebral blood vessels), neurofibrillary tangles and in senile plaques.

3. Endocrine amyloidosis (Hormone precursors). Some endocrine lesions are associated with microscopic deposits of amyloid. The examples are as follows:

- i) Medullary carcinoma of the thyroid (from procalcitonin i.e. ACaI).
- ii) Islet cell tumour of the pancreas (from islet amyloid polypeptide i.e. AIAPP or Amylin).
- iii) Type 2 diabetes mellitus (from pro-insulin, i.e. AIns).

4. Localised tumour forming amyloid (AL). Sometimes, isolated tumour like formation of amyloid deposits are seen e.g. in lungs, larynx, skin, urinary bladder, tongue, eye, isolated atrial amyloid. In most of these cases, the amyloid type is AL.

□ STAINING CHARACTERISTICS OF AMYLOID (p. 87)

Various stains and techniques employed to distinguish and confirm amyloid deposits in sections are as given in **Web Table 4.12**.

1. **H & E.** Amyloid by light microscopy with haematoxylin and eosin staining appears as extracellular, homogeneous, structureless and eosinophilic hyaline material, especially in relation to blood vessels.

2. **METACHROMATIC STAINS (ROSANILINE DYES).** Amyloid has the property of metachromasia i.e. the dye reacts with amyloid and undergoes a colour change. Metachromatic stains employed are rosaniline dyes such as methyl violet and crystal violet which impart *rose-pink* colouration to amyloid deposits.

3. **CONGO RED AND POLARISED LIGHT.** All types of amyloid have affinity for Congo red stain; therefore this method is used for confirmation of amyloid of all types. The stain may be used on both gross specimens and microscopic sections; amyloid of all types stains *pink red colour*. If the stained section is viewed in polarised light, the amyloid characteristically shows *apple-green birefringence* due to cross- β -pleated sheet configuration of amyloid fibrils.

4. **FLUORESCENT STAINS.** Fluorescent stain thioflavin-T binds to amyloid and fluoresce *yellow* under ultraviolet light i.e. amyloid emits secondary fluorescence. Thioflavin-S is less specific.

5. **IMMUNOHISTOCHEMISTRY.** More recently, type of amyloid can be classified by immunohistochemical stains. Most useful in confirmation for presence of amyloid of any type is *anti-AP stain*.

□ **DIAGNOSIS OF AMYLOIDOSIS (p. 88)**

1. **BIOPSY EXAMINATION.** Histologic examination of biopsy material is the commonest and confirmatory method for diagnosis in a suspected case of amyloidosis, e.g. *kidney biopsy* in a case of dialysis, sural nerve biopsy in familial polyneuropathy. Currently, fine needle aspiration of abdominal *subcutaneous fat* followed by Congo red staining and polarising microscopic examination for confirmation has become an acceptable simple and useful technique with excellent result.

2. **IN VIVO CONGO RED TEST.** A known quantity of Congo red dye may be injected intravenously in living patient. If amyloidosis is present, the dye gets bound to amyloid deposits and its levels in blood rapidly decline. The test is, however, not popular due to the risk of anaphylaxis to the injected dye.

□ **MORPHOLOGIC FEATURES OF AMYLOIDOSIS OF ORGANS (p. 88)**

G/A The affected organ is usually enlarged, pale and rubbery. Cut surface shows firm, waxy and translucent parenchyma which takes positive staining with the iodine test.

M/E The deposits of amyloid are found in the extracellular locations, initially in the walls of small blood vessels producing microscopic changes and effects, while later the deposits are in large amounts causing macroscopic changes and effects of pressure atrophy.

Amyloidosis of Kidneys (p. 89)

Amyloidosis of the kidneys is most common and most serious because of ill-effects on renal function. The deposits in the kidneys are found in most cases of secondary amyloidosis and in about one-third cases of primary amyloidosis. Amyloidosis of the kidney accounts for about 20% of deaths from amyloidosis.

G/A The kidneys may be normal-sized, enlarged or terminally contracted due to ischaemic effect of narrowing of vascular lumina. Cut surface is pale, waxy and translucent (**Web Image 4.11**).

M/E Amyloid deposition occurs primarily in the glomeruli, though it may involve peritubular interstitial tissue and the walls of arterioles as well (**Web Image 4.12**):

Congo red staining showing red pink colour and polarising microscopy showing apple-green birefringence confirms the presence of amyloid (**Web Image 4.13**).

Amyloidosis of Spleen (p. 90)

Amyloid deposition in the spleen, for some unknown reasons, may have one of the following two patterns (**Web Image 4.14**):

1. SAGO SPLEEN. G/A The splenomegaly is not marked and cut surface shows characteristic translucent pale and waxy nodules resembling sago grains and hence the name.

M/E The amyloid deposits begin in the walls of the arterioles of the white pulp and may subsequently replace the follicles.

2. LARDACEOUS SPLEEN. G/A There is generally moderate to marked splenomegaly (weight up to 1 kg). Cut surface of the spleen shows map-like areas of amyloid (lardaceous-lard-like; *lard* means fat of pigs) (**Web Image 4.15**).

M/E The deposits involve the walls of splenic sinuses and the small arteries and in the connective tissue of the red pulp (**Web Image 4.16**). Confirmation is by seeing Congophilia in Congo Red staining and demonstration of apple-green birefringence under polarising microscopy in the corresponding positive areas.

Amyloidosis of Liver (p. 90)

G/A The liver is often enlarged, pale, waxy and firm.

M/E The features are as under (**Web Image 4.17**):

- ◆ The amyloid initially appears in the space of Disse.
- ◆ Later, as the deposits increase, they compress the cords of hepatocytes so that eventually the liver cells are shrunken and atrophic and replaced by amyloid.

Amyloidosis of Heart (p. 92)

Heart is involved in systemic amyloidosis quite commonly, more so in the primary than in secondary systemic amyloidosis. In advanced cases, there may be a pressure atrophy of the myocardial fibres and impaired ventricular function which may produce restrictive cardiomyopathy.

Amyloidosis of Alimentary Tract (p. 92)

Involvement of the gastrointestinal tract by amyloidosis may occur at any level from the oral cavity to the anus. Rectal and gingival biopsies are the common sites for diagnosis of systemic amyloidosis.

◆ SELF ASSESSMENT

- 1. Transplantation antigens are located on portion of:**

A. Chromosome 1	B. Chromosome 6
C. Chromosome 9	D. Chromosome 22
- 2. Class I HLA antigens are located on:**

A. All nucleated cells of the body	B. B and T lymphocytes
C. Macrophages	D. Complement system

3. HIV contaminated waste products can be decontaminated by the following agents **except**:
 - A. Sodium hypochlorite
 - B. Methanol
 - C. Formaldehyde
 - D. Glutaraldehyde
4. CD4 bearing subpopulation of macrophages are attacked by HIV and cause the following **except**:
 - A. Cytopathic effects
 - B. Act as reservoir of HIV infection
 - C. Act as source of infection in nervous system
 - D. Defects in CD4+ T lymphocytes
5. In autoimmune haemolytic anaemia, the following type of immunologic tissue injury is involved:
 - A. Type I (anaphylactic)
 - B. Type II (cytotoxic)
 - C. Type III (immune complex)
 - D. Type IV (cell mediated)
6. Out of various antinuclear antibodies, pathognomonic of SLE is:
 - A. Antibody to single-stranded DNA
 - B. Antibody to double-stranded DNA
 - C. Antibody to histones
 - D. Antibody to nucleolar antigen
7. In cases of renal failure on long-term haemodialysis, there is development of following type of amyloid:
 - A. Amyloid light chain (AL)
 - B. Amyloid-associated protein (AA)
 - C. Amyloid β_2 microglobulin ($A\beta_2m$)
 - D. β amyloid protein ($A\beta$)
8. The most common form of amyloid in third world countries is:
 - A. Primary
 - B. Secondary
 - C. Hereditary
 - D. Localised
9. Cardiac amyloidosis often produces:
 - A. Dilated cardiomyopathy
 - B. Constrictive cardiomyopathy
 - C. Restrictive cardiomyopathy
 - D. Ischaemic cardiomyopathy
10. In senile cardiac amyloidosis, the biochemical form of amyloid is:
 - A. AL
 - B. AA
 - C. ATTR
 - D. $A\beta_2M$
11. In Alzheimer's disease, cerebral plaques consist of:
 - A. ATTR protein
 - B. $A\beta_2M$ protein
 - C. $A\beta$ protein
 - D. Prion protein
12. Amyloid enhancing factor (AEF) plays a significant role in:
 - A. Primary amyloid
 - B. Secondary amyloid
 - C. Senile cerebral amyloid
 - D. Haemodialysis-associated amyloid
13. Grave's disease is a type of:
 - A. Type I reaction
 - B. Type II reaction
 - C. Type III reaction
 - D. Type IV reaction
14. Non-fibrillar amyloid components include all **except**:
 - A. Amyloid P component
 - B. Apolipoprotein E
 - C. Protein X
 - D. Cystatin
15. Which of the following is heredo-familial form of amyloidosis?
 - A. Polyneuropathic amyloidosis
 - B. Cardiac amyloidosis
 - C. Cerebral amyloidosis
 - D. Endocrine amyloidosis
16. CD4 T cell count in crisis phase of HIV according to revised HIV/AIDS classification is:
 - A. < 100/ microlitre
 - B. < 200/ microlitre
 - C. <250/ microlitre
 - D. < 500/ microlitre

17. Test useful for detection of HIV during window period:

- A. ELISA
- B. Western blot
- C. CD4+ cell count
- D. p24 antigen capture assay

18. Haematoxylin body represents:

- A. Nuclear chromatin material
- B. RNA
- C. Cytosolic components
- D. Cell membrane components

KEY

1 = B	2 = A	3 = B	4 = A
5 = B	6 = B	7 = C	8 = B
9 = C	10 = C	11 = C	12 = B
13 = B	14 = D	15 = A	16 = B
17 = D	18 = A		



Derangements of Homeostasis and Haemodynamics

The mechanism by which the constancy of the internal environment is maintained and ensured is called the *homeostasis*.

The normal composition of internal environment consists of the following components (**Web Image 5.1**):

1. WATER. Water is the principal and essential constituent of the body. The total body water in a normal adult male comprises 50-70% (average 60%) of the body weight and about 10% less in a normal adult female (average 50%). The total body water (assuming average of 60%) is distributed into 2 main compartments of body fluids separated from each other by membranes freely permeable to water. These are as under (**Web Image 5.2**):

i) Intracellular fluid compartment. This comprises about 33% of the body weight, the bulk of which is contained in the muscles.

ii) Extracellular fluid compartment. This constitutes the remaining 27% of body weight containing water. Included in this are the following 4 subdivisions of extracellular fluid (ECF):

- Interstitial fluid including lymph fluid.*
- Intravascular fluid or blood plasma.*
- Mesenchymal tissues.*
- Transcellular fluid.*

2. ELECTROLYTES. The concentration of cations (positively charged) and anions (negatively charged) is different in intracellular and extracellular fluids:

◆ *In the intracellular fluid*, the main cations are potassium and magnesium and the main anions are phosphates and proteins. It has low concentration of sodium and chloride.

◆ *In the extracellular fluid*, the predominant cation is sodium and the principal anions are chloride and bicarbonate. Besides these, a small proportion of non-diffusible proteins and some diffusible nutrients and metabolites such as glucose and urea are present in the ECF.

□ ACID-BASE BALANCE (p. 94)

The pH of blood and acid-base balance are regulated in the body as follows.

1. BUFFER SYSTEM. Buffers are substances which have weak acids and strong bases and limit the change in H^+ ion concentration to the normal range.

2. PULMONARY MECHANISM. During respiration, CO_2 is removed by the lungs depending upon the partial pressure of CO_2 in the arterial blood.

3. RENAL MECHANISM. The other route by which H^+ ions can be excreted from the body is in the urine. Here, H^+ ions secreted by the renal tubular cells are buffered in the glomerular filtrate by:

- ◆ *combining with phosphates* to form phosphoric acid;
- ◆ *combining with ammonia* to form ammonium ions; and
- ◆ *combining with filtered bicarbonate ions* to form carbonic acid.

Normal Fluid Pressures (p. 95)

1. OSMOTIC PRESSURE. This is the pressure exerted by the chemical constituents of the body fluids. Accordingly, osmotic pressure may be of the following types (*Web Image 5.3,A*):

- ◆ **Crystalloid osmotic pressure** exerted by electrolytes present in the ECF and comprises the major portion of the total osmotic pressure.

- ◆ **Colloid osmotic pressure (Oncotic pressure)** exerted by proteins present in the ECF and constitutes a small part of the total osmotic pressure but is more significant physiologically. Since the protein content of the plasma is higher than that of interstitial fluid, oncotic pressure of plasma is higher (average 25 mmHg) than that of interstitial fluid (average 8 mmHg).

- ◆ **Effective oncotic pressure** is the difference between the higher oncotic pressure of plasma and the lower oncotic pressure of interstitial fluid and is *the force that tends to draw fluid into the vessels*.

2. HYDROSTATIC PRESSURE. This is the capillary blood pressure.

There is considerable *pressure gradient* at the two ends of capillary loop—being higher at the arteriolar end (average 32 mmHg) than at the venular end (average 12 mmHg).

- ◆ **Tissue tension** is the hydrostatic pressure of interstitial fluid and is lower than the hydrostatic pressure in the capillary at either end (average 4 mmHg).

- ◆ **Effective hydrostatic pressure** is the difference between the higher hydrostatic pressure in the capillary and the lower tissue tension; it is *the force that drives fluid through the capillary wall into the interstitial space*.

Normal Fluid Exchanges (p. 95)

Normally, the fluid exchanges between the body compartments take place as under:

- ◆ *At the arteriolar end of the capillary*, the balance between the hydrostatic pressure (32 mmHg) and plasma oncotic pressure (25 mmHg) is the hydrostatic pressure of 7 mmHg which is the outward-driving force so that a small quantity of fluid and solutes leave the vessel to enter the interstitial space.

- ◆ *At the venular end of the capillary*, the balance between the hydrostatic pressure (12 mmHg) and plasma oncotic pressure (25 mmHg) is the oncotic pressure of 13 mmHg which is the inward-driving force so that the fluid and solutes re-enter the plasma.

- ◆ *The tissue fluid* left after exchanges across the capillary wall escapes into the lymphatics from where it is finally drained into venous circulation.

- ◆ *Tissue factors* i.e. oncotic pressure of interstitial fluid and tissue tension, are normally small and insignificant forces opposing the plasma hydrostatic pressure and capillary hydrostatic pressure, respectively.

□ **OEDEMA** (p. 96)**DEFINITION AND TYPES** (p. 96)

Oedema may be defined as abnormal and excessive accumulation of “free fluid” in the interstitial tissue spaces and serous cavities.

- ◆ *Free fluid in body cavities:* Depending upon the body cavity in which the fluid accumulates, it is correspondingly known as ascites (if in the peritoneal cavity), hydrothorax or pleural effusion (if in the pleural cavity), and hydropericardium or pericardial effusion (if in the pericardial cavity).

◆ **Free fluid in interstitial space:** The oedema fluid lies free in the interstitial space between the cells and can be displaced from one place to another. In the case of oedema in the subcutaneous tissues, momentary pressure of finger produces a depression known as *pitting oedema*. The other variety is *non-pitting* or *solid oedema* in which no pitting is produced on pressure e.g. in myxoedema, elephantiasis.

The oedema may be of 2 main types:

1. **Localised** when limited to an organ or limb e.g. lymphatic oedema, inflammatory oedema, allergic oedema.
2. **Generalised (anasarca or dropsy)** when it is systemic in distribution, particularly noticeable in the subcutaneous tissues e.g. renal oedema, cardiac oedema, nutritional oedema.

Besides, there are a few *special forms* of oedema (e.g. pulmonary oedema, cerebral oedema) discussed later.

Depending upon fluid composition, oedema fluid may be:

◆ **transudate** which is more often the case, such as in oedema of cardiac and renal disease; or

◆ **exudate** such as in inflammatory oedema.

The differences between transudate and exudate are tabulated in **Web Table 5.1**.

PATHOGENESIS OF OEDEMA (p. 96)

Oedema is caused by mechanisms that interfere with normal fluid balance of plasma, interstitial fluid and lymph flow.

These mechanisms are discussed below and illustrated in **Web Image 5.3**:

1. DECREASED PLASMA ONCOTIC PRESSURE. The plasma oncotic pressure exerted by the total amount of plasma proteins tends to draw fluid into the vessels normally. A fall in the total plasma protein level (hypoproteinaemia of less than 5 g/dl), results in lowering of plasma oncotic pressure in a way that it can no longer counteract the effect of hydrostatic pressure of blood. This results in increased outward movement of fluid from the capillary wall and decreased inward movement of fluid from the interstitial space causing oedema. Hypoproteinaemia usually produces generalised oedema (anasarca).

The **examples** of oedema by this mechanism are seen in:

- i) *Oedema of renal disease* e.g. in nephrotic syndrome, acute glomerulonephritis.
- ii) *Ascites* of liver disease e.g. in cirrhosis of the liver.
- iii) *Oedema due to other causes* of hypoproteinaemia.

2. INCREASED CAPILLARY HYDROSTATIC PRESSURE. The hydrostatic pressure of the capillary is the force that normally tends to drive fluid through the capillary wall into the interstitial space by counteracting the force of plasma oncotic pressure. A rise in the hydrostatic pressure at the venular end of the capillary which is normally low (average 12 mmHg) to a level more than the plasma oncotic pressure results in minimal or no reabsorption of fluid at the venular end, consequently leading to oedema.

The **examples** of oedema by this mechanism are seen in the following disorders:

- i) *Oedema of cardiac disease* e.g. in congestive cardiac failure, constrictive pericarditis.
- ii) *Ascites of liver disease* e.g. in cirrhosis of the liver.
- iii) *Passive congestion* e.g. in mechanical obstruction due to thrombosis of veins of the lower legs, varicosities, pressure by pregnant uterus, tumours etc.

iv) *Postural oedema* e.g. transient oedema of feet and ankles due to increased venous pressure seen in individuals who remain standing erect for longtime such as traffic constables.

3. LYMPHATIC OBSTRUCTION. Normally, the interstitial fluid in the tissue spaces escapes by way of lymphatics. Obstruction to outflow of these channels causes localised oedema, known as lymphoedema.

The **examples** of lymphoedema include the following:

- i) *Removal of axillary lymph nodes* in radical mastectomy for carcinoma of the breast produces lymphoedema of the affected arm.
- ii) *Pressure from outside* on the main abdominal or thoracic duct such as due to tumours, effusions in serous cavities etc may produce lymphoedema.
- iii) *Inflammation of the lymphatics* as seen in filariasis (infection with *Wuchereria bancrofti*) results in chronic lymphoedema of scrotum and legs known as elephantiasis.
- iv) *Occlusion of lymphatic channels* by malignant cells may result in lymphoedema.
- v) *Milroy's disease or hereditary lymphoedema* is due to abnormal development of lymphatic channels. It is seen in families and the oedema is mainly confined to one or both the lower limbs.

4. TISSUE FACTORS. In some situations, the tissue factors in combination with other mechanisms play a role in causation of oedema. These are as under:

- i) *Elevation of oncotic pressure of interstitial fluid* as occurs due to increased vascular permeability and inadequate removal of proteins by lymphatics.
- ii) Lowered tissue tension as seen in *loose subcutaneous tissues* of eyelids and external genitalia.

5. INCREASED CAPILLARY PERMEABILITY. An intact capillary endothelium is a semipermeable membrane which permits the free flow of water and crystalloids but allows minimal passage of plasma proteins normally. However, when the capillary endothelium is injured by various 'capillary poisons' such as toxins and their products, capillary permeability to plasma proteins is enhanced due to development of gaps between the endothelial cells, leading to leakage of plasma proteins into interstitial fluid which consequently produces oedema.

The **examples** of oedema due to increased vascular permeability are seen in the following conditions:

- i) *Generalised oedema* occurring in systemic infections, poisonings, certain drugs and chemicals, anaphylactic reactions and anoxia.
- ii) *Localised oedema* e.g. *inflammatory oedema* and *angioneurotic oedema*.

6. SODIUM AND WATER RETENTION. Normally, about 80% of sodium is reabsorbed by the proximal convoluted tubule under the influence of either intrinsic renal mechanism or extra-renal mechanism while retention of water is affected by release of antidiuretic hormone (**Web Image 5.4**):

◆ **Intrinsic renal mechanism** is activated in response to sudden reduction in the effective arterial blood volume (hypovolaemia) e.g. in severe haemorrhage. Hypovolaemia stimulates the arterial baroreceptors present in the carotid sinus and aortic arch which, in turn, send the sympathetic outflow via the vasomotor centre in the brain. As a result of this, renal ischaemia occurs which causes reduction in the glomerular filtration rate, decreased excretion of sodium in the urine and consequent retention of sodium.

◆ **Extra-renal mechanism** involves the secretion of aldosterone, a sodium retaining hormone, by the *renin-angiotensin-aldosterone system*. Renin is an enzyme secreted by the granular cells in the juxta-glomerular apparatus. Its release is stimulated in response to low concentration of sodium in the tubules. Its main action is stimulation of the angiotensinogen. On stimulation, angiotensin I, a decapeptide, is formed in the plasma which is

subsequently converted into angiotensin II, an octapeptide, in the lungs and kidneys by angiotensin converting enzyme (ACE). Angiotensin II stimulates the adrenal cortex to secrete aldosterone hormone. Aldosterone increases sodium reabsorption in the renal tubules and sometimes causes a rise in the blood pressure.

◆ **ADH mechanism.** Retention of sodium leads to retention of water secondarily under the influence of anti-diuretic hormone (ADH) or vasopressin.

The possible factors responsible for causation of oedema by excessive retention of sodium and water in the extravascular compartment via stimulation of intrinsic renal and extra-renal mechanisms as well as via release of ADH are as under:

- i) Reduced glomerular filtration rate in response to hypovolaemia.
- ii) Enhanced tubular reabsorption of sodium and consequently its decreased renal excretion.
- iii) Increased filtration factor i.e. increased filtration of plasma from the glomerulus.
- iv) Decreased capillary hydrostatic pressure associated with increased renal vascular resistance.

The **examples** of oedema by these mechanisms are *oedema of cardiac disease*, *ascites* of liver disease, and *oedema of renal disease*.

PATHOGENESIS AND MORPHOLOGY OF IMPORTANT TYPES OF OEDEMA (p. 99)

Renal Oedema (p. 99)

1. Oedema in nephrotic syndrome. Since there is persistent and heavy proteinuria (albuminuria) in nephrotic syndrome, there is hypoalbuminaemia causing decreased plasma oncotic pressure resulting in severe generalised oedema (*nephrotic oedema*). The hypoalbuminaemia causes fall in the plasma volume activating renin-angiotensin-aldosterone mechanism which results in retention of sodium and water.

The *nephrotic oedema* is classically more severe and marked and is present in the subcutaneous tissues as well as in the visceral organs. The affected organ is enlarged and heavy with tense capsule.

2. Oedema in nephritic syndrome. Oedema occurs in conditions with diffuse glomerular disease such as in acute diffuse glomerulonephritis and rapidly progressive glomerulonephritis (*nephritic oedema*). In contrast to nephrotic oedema, nephritic oedema is not due to hypoproteinaemia but is largely due to excessive reabsorption of sodium and water in the renal tubules via renin-angiotensin-aldosterone mechanism. The protein content of oedema fluid in glomerulonephritis is quite low (less than 0.5 g/dl).

The *nephritic oedema* is usually mild as compared to nephrotic oedema and begins in the loose tissues such as on the face around eyes, ankles and genitalia. Oedema in these conditions is usually not affected by gravity (unlike cardiac oedema).

The salient differences between the nephrotic and nephritic oedema are outlined in **Web Table 5.2**.

3. Oedema in acute tubular injury. Acute tubular injury following shock or toxic chemicals results in gross oedema of the body.

Cardiac Oedema (p. 99)

Generalised oedema develops in right-sided and congestive cardiac failure. Pathogenesis of cardiac oedema is explained on the basis of the following hypotheses (**Web Image 5.5**):

1. Reduced cardiac output causes hypovolaemia which stimulates intrinsic-renal and extra-renal hormonal (renin-angiotensin-aldosterone) mechanisms

as well as ADH secretion resulting in sodium and water retention and consequent oedema.

2. Due to heart failure, there is elevated central venous pressure which is transmitted backward to the venous end of the capillaries, raising the capillary hydrostatic pressure and consequent transudation; this is known as *back pressure hypothesis*.

3. Chronic hypoxia may injure the capillary wall causing increased capillary permeability and result in oedema; this is called *forward pressure hypothesis*.

In left heart failure, the changes are, however, different. There is venous congestion, particularly in the lungs, so that pulmonary oedema develops rather than generalised oedema (described below).

Cardiac oedema is influenced by gravity and is thus characteristically *dependent oedema* i.e. in an ambulatory patient it is on the lower extremities, while in a bed-ridden patient oedema appears on the sacral and genital areas. The accumulation of fluid may also occur in serous cavities.

Pulmonary Oedema (p. 100)

Acute pulmonary oedema is the most important form of local oedema as it causes serious functional impairment but has special features. It differs from oedema elsewhere in that the fluid accumulation is not only in the tissue space but also in the pulmonary alveoli.

ETIOPATHOGENESIS. The hydrostatic pressure in the pulmonary capillaries is much lower (average 10 mmHg). Normally the plasma oncotic pressure is adequate to prevent the escape of fluid into the interstitial space and hence lungs are normally free of oedema. Pulmonary oedema can result from either the elevation of pulmonary hydrostatic pressure or the increased capillary permeability (**Web Image 5.6**).

1. Elevation in pulmonary hydrostatic pressure (Haemodynamic oedema). In heart failure, there is increase in the pressure in pulmonary veins which is transmitted to pulmonary capillaries. This results in imbalance between pulmonary hydrostatic pressure and the plasma oncotic pressure so that excessive fluid moves out of pulmonary capillaries into the interstitium of the lungs. The interstitial fluid so collected is cleared by the lymphatics present around the bronchioles, small muscular arteries and veins. As the capacity of the lymphatics to drain the fluid is exceeded (about ten-fold increase in fluid), the excess fluid starts accumulating in the interstitium (*interstitial oedema*).

Examples of pulmonary oedema by this mechanism are seen in left heart failure, mitral stenosis, pulmonary vein obstruction, thyrotoxicosis, cardiac surgery, nephrotic syndrome and obstruction to the lymphatic outflow by tumour or inflammation.

2. Increased vascular permeability (Irritant oedema). The vascular endothelium as well as the alveolar epithelial cells (alveolo-capillary membrane) may be damaged causing increased vascular permeability so that excessive fluid and plasma proteins leak out, initially into the interstitium and subsequently into the alveoli.

This mechanism explains pulmonary oedema in *examples* such as in fulminant pulmonary and extrapulmonary infections, inhalation of toxic substances, aspiration, shock, radiation injury, hypersensitivity to drugs or antisera, uraemia and adult respiratory distress syndrome (ARDS).

3. Acute high altitude oedema. Individuals climbing to high altitude suddenly without halts and without waiting for acclimatisation to set in, suffer from serious circulatory and respiratory ill-effects. Commonly, the deleterious effects begin to appear after an altitude of 2500 metres is reached. These changes include appearance of oedema fluid in the lungs, congestion and widespread minute haemorrhages. These changes can cause death within a few days. The underlying mechanism appears to be anoxic damage to the pulmonary vessels.

G/A Irrespective of the underlying mechanism in the pathogenesis of pulmonary oedema, the fluid accumulates more in the basal regions of lungs. The thickened interlobular septa along with their dilated lymphatics may be seen in chest X-ray as linear lines perpendicular to the pleura and are known as *Kerley's lines*. The lungs in pulmonary oedema are heavy, moist and subcrepitant. Cut surface exudes frothy fluid (mixture of air and fluid).

M/E The alveolar capillaries are congested. Initially, the excess fluid collects in the interstitial lung spaces (interstitial oedema). Later, the fluid fills the alveolar spaces (alveolar oedema). Oedema fluid in the interstitium as well as the alveolar spaces appears as eosinophilic, granular and pink proteinaceous material, often admixed with some RBCs and macrophages (**Web Image 5.7**).

Cerebral Oedema (p. 101)

Cerebral oedema or swelling of brain is the most threatening example of oedema. The mechanism of fluid exchange in the brain differs from elsewhere in the body since there are no draining lymphatics in the brain but instead, the function of fluid-electrolyte exchange is performed by the blood-brain barrier located at the endothelial cells of the capillaries.

Cerebral oedema can be of 3 types:

1. VASOGENIC OEDEMA. This is the most common type and corresponds to oedema elsewhere resulting from increased filtration pressure or increased capillary permeability.

G/A There is separation of tissue elements by the oedema fluid and swelling of astrocytes. The perivascular (Virchow-Robin) space is widened and clear halos are seen around the small blood vessels.

2. CYTOTOXIC OEDEMA. In this type, the blood-brain barrier is intact and the fluid accumulation is intracellular.

M/E The cells are swollen and vacuolated. In some situations, both vasogenic as well as cytotoxic cerebral oedema results e.g. in purulent meningitis.

3. INTERSTITIAL OEDEMA. This type of cerebral oedema occurs when the excessive fluid crosses the ependymal lining of the ventricles and accumulates in the periventricular white matter.

Hepatic Oedema (p. 102)

Briefly the mechanisms involved in causation of oedema of the legs and ascites in cirrhosis of the liver is as under:

- i) There is hypoproteinaemia due to impaired synthesis of proteins by the diseased liver.
- ii) Due to portal hypertension, there is increased venous pressure in the abdomen, and hence raised hydrostatic pressure.
- iii) Failure of inactivation of aldosterone in the diseased liver and hence hyperaldosteronism.
- iv) Secondary stimulation of renin-angiotensin mechanism promoting sodium and water retention.

Nutritional Oedema (p. 102)

Oedema due to nutritional deficiency of proteins (kwashiorkor, prolonged starvation, famine, fasting), vitamins (beri-beri due to vitamin B₁ deficiency) and chronic alcoholism occurs on legs but sometimes may be more generalised. The main contributing factors are hypoproteinaemia and sodium-water retention related to metabolic abnormalities.

Myxoedema (p. 102)

Myxoedema from hypothyroidism is a form of non-pitting oedema occurring on skin of face and other parts of the body as also in the internal organs due to excessive deposition of glycosaminoglycans in the interstitium.

Dehydration is a state of pure deprivation of water leading to sodium retention and hence a state of hypernatraemia.

ETIOLOGY. Pure water deficiency is less common than salt depletion but can occur in the following conditions:

1. **GI excretion:** Severe vomitings, diarrhoea and cholera.
2. **Renal excretion:** Acute renal failure in diuretic phase, extensive use of diuretics, and endocrine diseases e.g. diabetes insipidus, Addison's disease.
3. **Loss of blood and plasma:** Severe injuries, severe burns and during childbirth.
4. **Loss through skin:** Excessive perspiration and hyperthermia.
5. **Accumulation in third space:** Sudden development of ascites and acute intestinal obstruction with accumulation of fluid in the bowel.

□ **OVERHYDRATION** (p. 102)

Overhydration is increased extracellular fluid volume due to pure water excess or water intoxication.

ETIOLOGY. Overhydration is generally an induced condition and is encountered in the following situations:

1. **Excessive unmonitored intravascular infusion:** Normal saline (0.9% sodium chloride) and ringer lactate.
2. **Renal retention of sodium and water:** Congestive heart failure, acute glomerulonephritis, cirrhosis, Cushing's syndrome and chronic renal failure.

DISTURBANCES OF ELECTROLYTES (p. 103)

Among the important components in electrolyte imbalance, abnormalities in serum levels of sodium (hypo- and hypernatraemia), potassium (hypo- and hyperkalaemia), calcium (hypo- and hypercalcaemia) and magnesium (hypo- and hypermagnesaemia) are clinically more important. It is beyond the scope of this book to delve into this subject in detail. However, a few general principles on electrolyte imbalances are as under:

1. Electrolyte imbalance in a given case may result from one or more conditions.
2. Resultant abnormal serum level of more than one electrolyte may be linked to each other. For example, abnormality in serum levels of sodium and potassium; calcium and phosphate.
3. Generally, the reflection of biochemical serum electrolyte levels is in the form of metabolic syndrome and clinical features rather than morphological findings in organs.
4. Clinical manifestations of a particular electrolyte imbalance are related to its pathophysiologic role in that organ or tissue.

A list of important clinical conditions producing abnormalities in sodium and potassium are given in **Web Table 5.3** while calcium and phosphate imbalances are discussed in Chapter 28.

ACID-BASE IMBALANCE
(**ABNORMALITIES IN pH OF BLOOD**) (p. 103)

The pH of blood depends on 2 principal factors;

- ◆ serum concentration of bicarbonate; and
- ◆ partial pressure of CO_2 that determines the concentration of carbonic acid.

Accordingly, the disorders of the pH of the blood, termed as acidosis (blood pH below 7.4) and alkalosis (blood pH above 7.4), can be of 2 types:

1. **Alterations in the blood bicarbonate levels:** These are metabolic acidosis and alkalosis.
2. **Alteration in P_{CO_2}** (which depends upon the ventilatory function of the lungs): These are respiratory acidosis and alkalosis.

The principles of blood flow are called haemodynamics. Normal circulatory function requires uninterrupted flow of blood from the left ventricle to the farthest capillaries in the body; return of blood from systemic capillary network into the right ventricle; and from the right ventricle to the farthest pulmonary capillaries and back to the left atrium (**Web Image 5.8**).

Derangements of blood flow or haemodynamic disturbances are considered under 2 broad headings:

- I. *Disturbances in the volume of the circulating blood.* These include: hyperaemia and congestion, haemorrhage and shock.
- II. *Circulatory disturbances of obstructive nature.* These are: thrombosis, embolism, ischaemia and infarction.

□ DISTURBANCES IN THE VOLUME OF CIRCULATING BLOOD (p. 105)

HYPERAEMIA AND CONGESTION (p. 105)

Hyperaemia and congestion are the terms used for localised increase in the volume of blood within dilated vessels of an organ or tissue; the increased volume from arterial and arteriolar dilatation being referred to as *hyperaemia* or *active hyperaemia*, whereas the impaired venous drainage is called *venous congestion* or *passive hyperaemia*. If the condition develops rapidly it is called *acute*, while more prolonged and gradual response is known as *chronic*.

Active Hyperaemia (p. 105)

The dilatation of arteries, arterioles and capillaries is effected either through sympathetic neurogenic mechanism or via the release of vasoactive substances. The affected tissue or organ is pink or red in appearance (erythema).

The *examples* of active hyperaemia are seen in the following conditions:

Inflammation, blushing, menopausal flush, muscular exercise, high grade fever, goitre and arteriovenous malformations.

Passive Hyperaemia (Venous Congestion) (p. 105)

The dilatation of veins and capillaries due to impaired venous drainage results in passive hyperaemia or venous congestion, commonly referred to as *congestion*. Congestion may be acute or chronic, the latter being more common and called *chronic venous congestion* (CVC). Obstruction to the venous outflow may be local or systemic. Accordingly, venous congestion is of 2 types:

- ◆ *Local venous congestion* results from obstruction to the venous outflow from an organ or part of the body e.g. portal venous obstruction in cirrhosis of the liver, outside pressure on the vessel wall as occurs in tight bandage, plasters, tumours, pregnancy, hernia etc, or intraluminal occlusion by thrombosis.

- ◆ *Systemic (General) venous congestion* is engorgement of systemic veins e.g. in left-sided and right-sided heart failure and diseases of the lungs which interfere with pulmonary blood flow like pulmonary fibrosis, emphysema etc. Usually the fluid accumulates upstream to the specific chamber of the heart which is initially affected. For example, in *left-sided heart failure* (such as due to mechanical overload in aortic stenosis, or due to weakened left ventricular wall as in myocardial infarction) pulmonary congestion results, whereas in *right-sided heart failure* (such as due to pulmonary stenosis or pulmonary hypertension) systemic venous congestion results. **Web Image 5.9** illustrates the mechanisms involved in passive or venous congestion of different organs.

CVC Lung (p. 106)

Chronic venous congestion of the lung occurs in left heart failure, especially in rheumatic mitral stenosis so that there is consequent rise in pulmonary venous pressure.

G/A The lungs are heavy and firm in consistency. The sectioned surface is dark. The sectioned surface is rusty brown in colour referred to as *brown induration* of the lungs.

M/E The alveolar septa are widened due to the presence of interstitial oedema as well as due to dilated and congested capillaries. The septa are mildly thickened due to slight increase in fibrous connective tissue. Rupture of dilated and congested capillaries may result in minute intra-alveolar haemorrhages. The breakdown of erythrocytes liberates haemosiderin pigment which is taken up by alveolar macrophages, so called *heart failure cells*, seen in the alveolar lumina. The brown induration observed on the cut surface of the lungs is due to the pigmentation and fibrosis (**Web Image 5.10**).

CVC Liver (p. 106)

Chronic venous congestion of the liver occurs in right heart failure and sometimes due to occlusion of inferior vena cava and hepatic vein.

G/A The liver is enlarged and tender and the capsule is tense. Cut surface shows characteristic *nutmeg** appearance due to red and yellow mottled appearance, corresponding to congested centre of lobules and fatty peripheral zone respectively (**Web Image 5.11**).

M/E The changes of congestion are more marked in the centrilobular zone due to severe hypoxia than in the peripheral zone. The central veins as well as the adjacent sinusoids are distended and filled with blood. The centrilobular hepatocytes undergo degenerative changes, and eventually *centrilobular haemorrhagic necrosis* may be seen. Long-standing cases may show fine centrilobular fibrosis and regeneration of hepatocytes, resulting in cardiac cirrhosis. The peripheral zone of the lobule is less severely affected by chronic hypoxia and shows some *fatty change* in the hepatocytes (**Web Image 5.12**).

CVC Spleen (p. 106)

Chronic venous congestion of the spleen occurs in right heart failure and in portal hypertension from cirrhosis of liver.

G/A The spleen in early stage is slightly to moderately enlarged (up to 250 g as compared to normal 150 g), while in long-standing cases there is progressive enlargement and may weigh up to 500 to 1000 g. The organ is deeply congested, tense and cyanotic. Sectioned surface is grey tan (**Web Image 5.13**).

M/E The features are as under (**Web Image 5.14**):

- i) *Red pulp* is enlarged due to congestion and marked sinusoidal dilatation and here are areas of recent and old haemorrhages. Sinusoids may get converted into capillaries (capillarisation of sinusoids).
- ii) There is *hyperplasia* of reticuloendothelial cells in the red pulp of the spleen (splenic macrophages).
- iii) There is *fibrous thickening* of the capsule and of the trabeculae.
- iv) Some of haemorrhages overlying fibrous tissue get deposits of haemosiderin pigment and calcium salts; these organised structures are termed as *Gamna-Gandy bodies* or siderofibrotic nodules.

*Nutmeg (vernacular name *jaiphal*) is the seed of a spice tree that grows in India, used in cooking as spice for giving flavours.

□ HAEMORRHAGE (p. 107)

Haemorrhage is the escape of blood from a blood vessel. The bleeding may occur *externally*, or *internally* into the serous cavities (e.g. haemothorax, haemoperitoneum, haemopericardium), or into a hollow viscus. Extravasation of blood into the tissues with resultant swelling is known as *haematoma*. Large extravasations of blood into the skin and mucous membranes are called *ecchymoses*. *Purpuras* are small areas of haemorrhages (upto 1 cm) into the skin and mucous membrane, whereas *petechiae* are minute pinhead-sized haemorrhages. Microscopic escape of erythrocytes into loose tissues may occur following marked congestion and is known as *diapedesis*.

1. *Trauma* to the vessel wall e.g. penetrating wound in the heart or great vessels, during labour etc.
2. *Spontaneous haemorrhage* e.g. rupture of an aneurysm, septicaemia, bleeding diathesis (such as purpura), acute leukaemias, pernicious anaemia, scurvy.
3. *Inflammatory lesions of the vessel wall* e.g. bleeding from chronic peptic ulcer, typhoid ulcers, blood vessels traversing a tuberculous cavity in the lung, syphilitic involvement of the aorta, polyarteritis nodosa.
4. *Neoplastic invasion* e.g. haemorrhage following vascular invasion in carcinoma of the tongue.
5. *Vascular diseases* e.g. atherosclerosis.
6. *Elevated pressure within the vessels* e.g. cerebral and retinal haemorrhage in systemic hypertension, severe haemorrhage from varicose veins due to high pressure in the veins of legs or oesophagus.

EFFECTS. The effects of blood loss depend upon 3 main factors:

- ◆ the amount of blood loss;
- ◆ the speed of blood loss; and
- ◆ the site of haemorrhage.

The loss up to 20% of blood volume suddenly or slowly generally has little clinical effects because of compensatory mechanisms. A sudden loss of 33% of blood volume may cause death, while loss of up to 50% of blood volume over a period of 24 hours may not be necessarily fatal. However, chronic blood loss generally produces iron deficiency anaemia, whereas acute haemorrhage may lead to serious immediate consequences such as hypovolaemic shock.

□ SHOCK (p. 108)

Shock is a life-threatening clinical syndrome of cardiovascular collapse characterised by:

- ◆ an acute reduction of effective circulating blood volume (hypotension); and
- ◆ an inadequate perfusion of cells and tissues (hypoperfusion).

If uncompensated, these mechanisms may lead to impaired cellular metabolism and death.

Thus, by definition "*true (or secondary) shock*" is a circulatory imbalance between oxygen supply and oxygen requirements at the cellular level, and is also called as circulatory shock.

The term "*initial (or primary) shock*" is used for transient and usually a benign vasovagal attack resulting from sudden reduction of venous return to the heart caused by neurogenic vasodilatation and consequent peripheral pooling of blood e.g. immediately following trauma, severe pain or emotional overreaction such as due to fear, sorrow or surprise. Clinically, patients of primary shock suffer from the attack lasting for a few seconds or minutes and develop brief unconsciousness, weakness, sinking sensation, pale and clammy limbs, weak and rapid pulse, and low blood pressure.

Although in a given clinical case, two or more factors may be involved in causation of true shock, a simple etiologic classification of shock syndrome divides it into following 3 major types and a few other variants (**Web Table 5.4**):

1. **Hypovolaemic shock.** This form of shock results from inadequate circulatory blood volume by various etiologic factors that may be *either* from the loss of red cell mass and plasma from haemorrhage, *or* from the loss of plasma volume alone.
2. **Cardiogenic shock.** Acute circulatory failure with sudden fall in cardiac output from acute diseases of the heart without actual reduction of blood volume (normovolaemia) results in cardiogenic shock.
3. **Septic (Toxaemic) shock.** Severe bacterial infections or septicaemia induce septic shock. It may be the result of Gram-negative septicaemia (endotoxic shock) which is more common, or Gram-positive septicaemia (exotoxic shock).
4. **Other types.** These include following types:
 - i) *Traumatic shock.* Shock resulting from trauma is initially due to hypovolaemia, but even after haemorrhage has been controlled, these patients continue to suffer loss of plasma volume into the interstitium of injured tissue and hence is considered separately in some descriptions.
 - ii) *Neurogenic shock.* Neurogenic shock results from causes of interruption of sympathetic vasomotor supply.
 - iii) *Hypoadrenal shock.* Hypoadrenal shock occurs from unknown adrenal insufficiency in which the patient fails to respond normally to the stress of trauma, surgery or illness.

Pathogenesis (p. 109)

In general, all forms of shock involve following 3 derangements:

- ◆ Reduced effective circulating blood volume.
- ◆ Reduced supply of oxygen to the cells and tissues with resultant anoxia.
- ◆ Inflammatory mediators and toxins released from shock-induced cellular injury.

These derangements initially set in compensatory mechanisms (discussed below) but eventually a vicious cycle of cell injury and severe cellular dysfunction lead to breakdown of organ function (**Web Image 5.15**).

1. **Reduced effective circulating blood volume.** It may result by either of the following mechanisms:
 - i) by actual loss of blood volume as occurs in hypovolaemic shock; or
 - ii) by decreased cardiac output without actual loss of blood (normovolaemia) as occurs in cardiogenic shock and septic shock.
2. **Impaired tissue oxygenation.** Following reduction in the effective circulating blood volume from either of the above two mechanisms and from any of the etiologic agents, there is decreased venous return to the heart resulting in decreased cardiac output. This consequently causes reduced supply of oxygen to the organs and tissues and hence tissue anoxia, which sets in cellular injury.
3. **Release of inflammatory mediators.** In response to cellular injury, innate immunity of the body gets activated as a body defense mechanism and release inflammatory mediators but eventually these agents themselves become the cause of cell injury. Endotoxins in bacterial wall in septic shock stimulate massive release of pro-inflammatory mediators (cytokines) but a similar process of release of these agents takes place in late stages of shock from other causes. Several pro-inflammatory inflammatory mediators are released from monocytes-macrophages, other leucocytes and

other body cells, the most important being the tumour necrosis factor-(TNF)- α and interleukin-1 (IL-1) cytokines (**Web Image 5.16**).

After these general comments on mechanisms in shock, features specific to pathogenesis of three main forms of shock are given below:

COMPENSATED (NON-PROGRESSIVE, INITIAL, REVERSIBLE) SHOCK. In the early stage of shock, an attempt is made to maintain adequate cerebral and coronary blood supply by redistribution of blood so that the vital organs (brain and heart) are adequately perfused and oxygenated. This is achieved by activation of various neurohormonal mechanisms causing *widespread vasoconstriction* and by *fluid conservation by the kidney*. If the condition that caused the shock is adequately treated, the compensatory mechanism may be able to bring about recovery and re-establish the normal circulation; this is called compensated or reversible shock. These compensatory mechanisms are as under:

i) Widespread vasoconstriction. In response to reduced blood flow (hypotension) and tissue anoxia, the neural and humoral factors (e.g. baroreceptors, chemoreceptors, catecholamines, renin, and angiotensin-II) are activated. All these bring about vasoconstriction, particularly in the vessels of the skin and abdominal viscera. Widespread vasoconstriction is a protective mechanism as it causes increased peripheral resistance, increased heart rate (tachycardia) and increased blood pressure.

ii) Fluid conservation by the kidney. In order to compensate the actual loss of blood volume in hypovolaemic shock, the following factors may assist in restoring the blood volume and improve venous return to the heart:

- ◆ Release of aldosterone from hypoxic kidney by activation of renin-angiotensin-aldosterone mechanism.
- ◆ Release of ADH due to decreased effective circulating blood volume.
- ◆ Reduced glomerular filtration rate (GFR) due to arteriolar constriction.
- ◆ Shifting of tissue fluids into the plasma due to lowered capillary hydrostatic pressure (hypotension).

iii) Stimulation of adrenal medulla. In response to low cardiac output, adrenal medulla is stimulated to release excess of catecholamines (epinephrine and non-epinephrine) which increase heart rate and try to increase cardiac output.

PROGRESSIVE DECOMPENSATED SHOCK. This is a stage when the patient suffers from some other stress or risk factors (e.g. pre-existing cardiovascular and lung disease) besides persistence of the shock so that there is progressive deterioration. The effects of progressive decompensated shock due to tissue hypoperfusion are as under:

i) Pulmonary hypoperfusion. Decompensated shock worsens pulmonary perfusion and increases vascular permeability resulting in tachypnoea and adult respiratory distress syndrome (ARDS).

ii) Tissue ischaemia. Impaired tissue perfusion causes switch from aerobic to anaerobic glycolysis resulting in *metabolic lactic acidosis*. Lactic acidosis lowers the tissue pH which in turn makes the vasomotor response ineffective. This results in vasodilatation and peripheral pooling of blood.

IRREVERSIBLE DECOMPENSATED SHOCK. When the shock is so severe that in spite of compensatory mechanisms and despite therapy and control of etiologic agent which caused the shock, no recovery takes place, it is called decompensated or irreversible shock. Its effects due to widespread cell injury include the following:

i) Progressive vasodilatation. During later stages of shock, anoxia damages the capillary and venular wall and arteioles become unresponsive to vasoconstrictors listed above and begin to dilate. Vasodilatation results in peripheral pooling of blood which further deteriorate the effective circulating blood volume.

ii) Increased vascular permeability. Anoxic damage to tissues releases inflammatory mediators which cause increased vascular permeability. This results in escape of fluid from circulation into the interstitial tissues thus deteriorating effective circulating blood volume.

iii) Myocardial depressant factor (MDF). Progressive fall in the blood pressure and persistently reduced blood flow to myocardium causes coronary insufficiency and myocardial ischaemia due to release of myocardial depressant factor (MDF). This results in further depression of cardiac function, reduced cardiac output and decreased blood flow.

iv) Worsening pulmonary hypoperfusion. Further pulmonary hypoperfusion causes respiratory distress due to pulmonary oedema, tachypnoea and adult respiratory distress syndrome (ARDS).

v) Anoxic damage to heart, kidney, brain. Progressive tissue anoxia causes severe metabolic acidosis due to anaerobic glycolysis. There is release of inflammatory cytokines and other inflammatory mediators and generation of free radicals. Since highly specialised cells of myocardium, proximal tubular cells of the kidney, and neurons of the CNS are dependent solely on aerobic respiration for ATP generation, there is ischaemic cell death in these tissues.

vi) Hypercoagulability of blood. Tissue damage in shock activates coagulation cascade with release of clot promoting factor, thromboplastin and release of platelet aggregator, ADP, which contributes to slowing of blood-stream and vascular thrombosis. In this way, hypercoagulability of blood with consequent microthrombi impair the blood flow and cause further tissue necrosis.

MORPHOLOGIC FEATURES

Eventually, shock is characterised by multisystem failure. The morphologic changes in shock are due to hypoxia resulting in degeneration and necrosis in various organs. The major organs affected are the brain, heart, lungs and kidneys. Morphologic changes are also noted in the adrenals, gastrointestinal tract, liver and other organs. The predominant morphologic changes and their mechanisms are shown in **Web Image 5.17** and described below.

1. BRAIN IN SHOCK.

G/A The area supplied by the most distal branches of the cerebral arteries suffers from severe ischaemic necrosis which is usually the border zone between the anterior and middle cerebral arteries.

M/E The changes are noticeable if ischaemia is prolonged for 12 to 24 hours. Neurons, particularly Purkinje cells, are more prone to develop the effects of ischaemia. The cytoplasm of the affected neurons is intensely eosinophilic and the nucleus is small pyknotic. Dead and dying nerve cells are replaced by gliosis.

2. HEART IN SHOCK. Heart is affected in cardiogenic as well as in other forms of shock. There are 2 types of morphologic changes in heart in all types of shock:

i) *Haemorrhages and necrosis.* There may be small or large ischaemic areas or infarcts, particularly located in the subepicardial and subendocardial region.

ii) *Zonal lesions.* These are opaque transverse contraction bands in the myocytes near the intercalated disc.

3. SHOCK LUNG. Lungs due to dual blood supply are generally not affected by hypovolaemic shock but in septic shock the morphologic changes in lungs are quite prominent termed 'shock lung'.

G/A The lungs are heavy and wet.

M/E Changes of adult respiratory distress syndrome (ARDS) are seen. Briefly, the changes include congestion, interstitial and alveolar oedema, interstitial lymphocytic infiltrate, alveolar hyaline membranes, thickening

and fibrosis of alveolar septa, and fibrin and platelet thrombi in the pulmonary microvasculature.

4. SHOCK KIDNEY. The renal ischaemia following systemic hypotension is considered responsible for renal changes in shock. The end-result is generally anuria and death.

G/A The kidneys are soft and swollen. Sectioned surface shows blurred architectural markings.

M/E The tubular lesions are seen at all levels of nephron and are referred to as acute tubular necrosis (ATN) which can occur following other causes besides shock.

5. ADRENALS IN SHOCK. The adrenals show stress response in shock. This includes release of aldosterone in response to hypoxic kidney, release of glucocorticoids from adrenal cortex and catecholamines like adrenaline from adrenal medulla. In severe shock, acute adrenal haemorrhagic necrosis may occur.

6. HAEMORRHAGIC GASTROENTEROPATHY. The hypoperfusion of the alimentary tract in conditions such as shock and cardiac failure may result in mucosal and mural infarction called haemorrhagic gastroenteropathy.

G/A The lesions are multifocal and widely distributed throughout the bowel. The lesions are superficial ulcers, reddish purple in colour. The adjoining bowel mucosa is oedematous and haemorrhagic.

M/E The involved surface of the bowel shows dilated and congested vessels and haemorrhagic necrosis of the mucosa and sometimes submucosa.

7. LIVER IN SHOCK. G/A Faint nutmeg appearance is seen.

M/E Depending upon the time lapse between injury and cell death, ischaemic shrinkage, hydropic change, focal necrosis, or fatty change may be seen. Liver function may be impaired.

Clinical Features and Complications (p. 113)

The classical features of decompensated shock are characterised by *depression of 4 vital processes*:

- ◆ Very low blood pressure
- ◆ Subnormal temperature
- ◆ Feeble and irregular pulse
- ◆ Shallow and sighing respiration

In addition, the patients in shock have pale face, sunken eyes, weakness, cold and clammy skin.

Life-threatening complications in shock are due to hypoxic cell injury resulting in immuno-inflammatory responses and activation of various cascades (clotting, complement, kinin). These include the following*:

1. Acute respiratory distress syndrome (ARDS)
2. Disseminated intravascular coagulation (DIC)
3. Acute renal failure (ARF)
4. Multiple organ dysfunction syndrome (MODS)

With progression of the condition, the patient may develop stupor, coma and death.

□ CIRCULATORY DISTURBANCES OF OBSTRUCTIVE NATURE (p. 113)

THROMBOSIS (p. 113)

Thrombosis is the process of formation of solid mass in circulation from the constituents of flowing blood; the mass itself is called a *thrombus*. In

*Major complications of shock can be remembered from acronym ADAM: A = ARDS; D = DIC, A = ARF; M = MODS.

contrast, a *blood clot* is the mass of coagulated blood formed *in vitro* e.g. in a test tube. *Haematoma* is the extravascular accumulation of blood clot e.g. into the tissues. *Haemostatic plugs* are the blood clots formed in healthy individuals at the site of bleeding e.g. in injury to the blood vessel. Haemostatic plugs are useful as they stop the escape of blood and plasma, whereas thrombi developing in the unruptured cardiovascular system may be life-threatening by causing one of the following harmful effects:

1. *Ischaemic injury*. Thrombi may decrease or stop the blood supply to part of an organ or tissue and cause ischaemia which may subsequently result in infarction.
2. *Thromboembolism*. The thrombus or its part may get dislodged and be carried along in the bloodstream as embolus to lodge in a distant vessel.

Pathophysiology (p. 114)

Since the protective haemostatic plug formed as a result of normal haemostasis is an example of thrombosis, it is essential to describe *thrombogenesis* in relation to the normal haemostatic mechanism.

Virchow described three primary events which predispose to thrombus formation (*Virchow's triad*): endothelial injury, altered blood flow, and hypercoagulability of blood. To this are added the processes that follow these primary events: activation of platelets and of clotting system (**Web Image 5.18**). These events are discussed below:

1. ENDOTHELIAL INJURY. The integrity of blood vessel wall is important for maintaining normal blood flow.

Vascular injury exposes the subendothelial connective tissue (e.g. collagen, elastin, fibronectin, laminin and glycosaminoglycans) which are thrombogenic and thus plays important role in initiating haemostasis as well as thrombosis. Injury to vessel wall also causes vasoconstriction of small blood vessels briefly so as to reduce the blood loss. A number of factors and conditions may cause vascular injury and predispose to the formation of thrombi. These are as under:

- i) Endocardial injury in myocardial infarction, myocarditis, cardiac surgery, prosthetic valves.
- ii) Ulcerated plaques in advanced atherosclerosis.
- iii) Haemodynamic stress in hypertension.
- iv) Arterial diseases.
- v) Diabetes mellitus.
- vi) Endogenous chemical agents such as hypercholesterolaemia, endotoxins.
- vii) Exogenous chemical agents such as cigarette smoke.

2. ROLE OF PLATELETS. Following endothelial cell injury, platelets come to play a central role in normal haemostasis as well as in thrombosis. The sequence of events is as under (**Web Image 5.19**):

i) Platelet adhesion. The platelets in circulation recognise the site of endothelial injury and adhere to exposed subendothelial collagen (*primary aggregation*); von Willebrand's factor is required for such adhesion between platelets and collagen.

ii) Platelet release reaction. The activated platelets then undergo release reaction by which the platelet granules are released to the exterior. Two main types of platelet granules are released:

- a) *Alpha granules* containing fibrinogen, fibronectin, platelet-derived growth factor, platelet factor 4 (an antiheparin) and cationic proteins.
- b) *Dense bodies* containing ADP (adenosine diphosphate), ionic calcium, 5-HT (serotonin), histamine and epinephrine.

As a sequel to platelet activation and release reaction, the phospholipid complex-platelet factor 3 gets activated which plays important role in the intrinsic pathway of coagulation.

iii) **Platelet aggregation.** Following release of ADP, a potent platelet aggregating agent, aggregation of additional platelets takes place (*secondary aggregation*). This results in formation of temporary haemostatic plug. However, stable haemostatic plug is formed by the action of fibrin, thrombin and thromboxane A_2 .

3. ROLE OF COAGULATION SYSTEM. Coagulation mechanism is the conversion of the plasma fibrinogen into solid mass of fibrin. The coagulation system is involved in both haemostatic process and thrombus formation. **Web Image 5.20** shows the schematic representation of the cascade of intrinsic (blood) pathway, the extrinsic (tissue) pathway, and the common pathway leading to formation of fibrin polymers.

Regulation of coagulation system. The blood is kept in fluid state normally and coagulation system kept in check by controlling mechanisms. These are as under:

- a) *Protease inhibitors.* These act on coagulation factors so as to oppose the formation of thrombin e.g. antithrombin III, protein C, C_1 inactivator, α_1 -antitrypsin, α_2 -macroglobulin.
- b) *Fibrinolytic system.* Plasmin, a potent fibrinolytic enzyme, is formed by the action of plasminogen activator on plasminogen present in the normal plasma. Two types of plasminogen activators (PA) are identified:
 - ◆ *Tissue-type PA* derived from endothelial cells and leucocytes.
 - ◆ *Urokinase-like PA* present in the plasma.
 Plasmin so formed acts on fibrin to destroy the clot and produces fibrin split products (FSP).

4. ALTERATION OF BLOOD FLOW. *Turbulence* means unequal flow while *stasis* means slowing.

- i) *Normally*, there is axial flow of blood in which the most rapidly-moving central stream consists of leucocytes and red cells. The platelets are present in the slow-moving laminar stream adjacent to the central stream while the peripheral stream consists of most slow-moving cell-free plasma close to endothelial layer (**Web Image 5.21,A**).
- ii) *Turbulence and stasis* occur in thrombosis in which the normal axial flow of blood is disturbed. When blood slows down, the blood cells including platelets marginate to the periphery and form a kind of pavement close to endothelium (margination and pavementing) (**Web Image 5.21,B**). While stasis allows a higher release of oxygen from the blood, turbulence may actually injure the endothelium resulting in deposition of platelets and fibrin. Formation of arterial and cardiac thrombi is facilitated by *turbulence* in the blood flow, while *stasis* initiates the venous thrombi even without evidence of endothelial injury.

5. HYPERCOAGULABILITY OF BLOOD. The occurrence of thrombosis in some conditions such as in nephrotic syndrome, advanced cancers, extensive trauma, burns and during puerperium is explained on the basis of hypercoagulability of blood. The effect of hypercoagulability on thrombosis is favoured by advancing age, smoking, use of oral contraceptives and obesity. Hypercoagulability may occur by the following changes in the composition of blood:

- i) *Increase in coagulation factors* e.g. fibrinogen, prothrombin, factor VIIa, VIIIa and Xa.
- ii) *Increase in platelet count* and their adhesiveness.
- iii) *Decreased levels of coagulation inhibitors* e.g. antithrombin III, fibrin split products.

Predisposing Factors (p. 117)

A number of primary (genetic) and secondary (acquired) factors favour thrombosis.

Primary (Genetic) factors:

- i) Deficiency of antithrombin
- ii) Deficiency of protein C or S
- iii) Defects in fibrinolysis
- iv) Mutation in factor V

Secondary (acquired) factors:*a) Risk factors:*

- i) Advanced age
- ii) Prolonged bed-rest
- iii) Immobilisation
- iv) Cigarette smoking

b) Clinical conditions predisposing to thrombosis:

- i) Heart diseases (e.g. myocardial infarction, CHF, rheumatic mitral stenosis, cardiomyopathy)
- ii) Vascular diseases (e.g. atherosclerosis, aneurysms of the aorta and other vessels, varicosities of leg veins)
- iii) Hypercoagulable conditions (e.g. polycythaemia, dehydration, nephrotic syndrome, disseminated cancers)
- iv) Shock
- v) Tissue damage e.g. trauma, fractures, burns, surgery
- vi) Late pregnancy and puerperium
- vii) Certain drugs (e.g. anaesthetic agents, oral contraceptives).

Morphologic Features (p. 117)

G/A Thrombi may be of various shapes, sizes and composition depending upon the site of origin. Arterial thrombi tend to be white and mural while the venous thrombi are red and occlusive. Mixed or laminated thrombi are also common and consist of alternate white and red layers called lines of Zahn. Red thrombi are soft, red and gelatinous whereas white thrombi are firm and pale.

M/E The composition of thrombus is determined by the rate of flow of blood i.e. whether it is formed in the rapid arterial and cardiac circulation, or in the slow moving flow in veins. The lines of Zahn are formed by alternate layers of light-staining aggregated platelets admixed with fibrin meshwork and dark-staining layer of red cells (**Web Image 5.22**).

Red thrombi (antemortem) have to be distinguished from postmortem clots (**Web Table 5.5**).

Origin of Thrombi (p. 118)

Thrombi may arise from the heart, arteries, veins or in microcirculation.

CARDIAC THROMBI. Thrombi may form in any of the chambers of the heart and on the valve cusps. They are more common in the atrial appendages, especially of the right atrium, and on mitral and aortic valves called vegetations which may be seen in infective endocarditis and non-bacterial thrombotic endocarditis.

Rarely, large round thrombus may form and obstruct the mitral valve and is called *ball-valve thrombus*.

ARTERIAL AND VENOUS THROMBI. The examples of major forms of vascular thrombi are as under:

Arterial thrombi:

- i) *Aorta:* aneurysms, arteritis.
- ii) *Coronary arteries:* atherosclerosis.
- iii) *Mesenteric artery:* atherosclerosis, arteritis.
- iv) *Arteries of limbs:* atherosclerosis, diabetes mellitus, Buerger's disease, Raynaud's disease.
- v) *Renal artery:* atherosclerosis, arteritis.
- vi) *Cerebral artery:* atherosclerosis, vasculitis.

Venous thrombi:

- i) *Veins of lower limbs*: deep veins of legs, varicose veins.
- ii) *Popliteal, femoral and iliac veins*: postoperative stage, postpartum.
- iii) *Pulmonary veins*: CHF, pulmonary hypertension.
- iv) *Hepatic and portal vein*: portal hypertension.
- v) *Superior vena cava*: infections in head and neck.
- vi) *Inferior vena cava*: extension of thrombus from hepatic vein.
- vii) *Mesenteric veins*: volvulus, intestinal obstruction.
- viii) *Renal vein*: renal amyloidosis.

Distinguishing features between thrombi formed in rapidly-flowing arterial circulation and slow-moving venous blood are given in **Web Table 5.6**.

CAPILLARY THROMBI. Minute thrombi composed mainly of packed red cells are formed in the capillaries in acute inflammatory lesions, vasculitis and in disseminated intravascular coagulation (DIC).

Fate of Thrombus (p. 118)

The possible fate of thrombi can be as under (**Web Image 5.23**):

- 1. RESOLUTION.** Thrombus activates the fibrinolytic system with consequent release of plasmin which may dissolve the thrombus completely resulting in resolution.
- 2. ORGANISATION.** If the thrombus is not removed, it starts getting organised. Phagocytic cells (neutrophils and macrophages) appear and begin to phagocytose fibrin and cell debris. The proteolytic enzymes liberated by leucocytes and endothelial cells start digesting coagulum. Capillaries grow into the thrombus from the site of its attachment and fibroblasts start invading the thrombus. Thus, fibrovascular granulation tissue is formed which subsequently becomes dense and less vascular and is covered over by endothelial cells.
- 3. PROPAGATION.** The thrombus may enlarge in size due to more and more deposition from the constituents of flowing blood. In this way, it may ultimately cause obstruction of some important vessel.
- 4. THROMBOEMBOLISM.** The thrombi in early stage and infected thrombi are quite friable and may get detached from the vessel wall. These are released in part or completely in bloodstream as emboli which produce ill-effects at the site of their lodgement.

EMBOLISM (p. 119)

Embolism is the process of partial or complete obstruction of some part of the cardiovascular system by any mass carried in the circulation; the transported intravascular mass detached from its site of origin is called an *embolus*. Most usual forms of emboli (90%) are thromboemboli i.e. originating from thrombi or their parts detached from the vessel wall.

Emboli may be of various types:

A. Depending upon the matter in the emboli:

- i) *Solid* e.g. detached thrombi (thromboemboli), atheromatous material, tumour cell clumps, tissue fragments, parasites, bacterial clumps, foreign bodies.
- ii) *Liquid* e.g. fat globules, amniotic fluid, bone marrow.
- iii) *Gaseous* e.g. air, other gases.

B. Depending upon whether infected or not:

- i) *Bland*, when sterile.
- ii) *Septic*, when infected.

C. Depending upon the source of the emboli:

- i) *Cardiac emboli* from left side of the heart e.g. emboli originating from atrium and atrial appendages, infarct in the left ventricle, vegetations of endocarditis.

- ii) *Arterial emboli* e.g. in systemic arteries in the brain, spleen, kidney, intestine.
- iii) *Venous emboli* e.g. in pulmonary arteries.
- iv) *Lymphatic emboli* can also occur.

D. Depending upon the flow of blood, two special types of emboli are mentioned:

- i) *Paradoxical embolus*. An embolus which is carried from the venous side of circulation to the arterial side or vice versa is called paradoxical or crossed embolus e.g. through arteriovenous communication such as in patent foramen ovale, septal defect of the heart, and arteriovenous shunts in the lungs.
- ii) *Retrograde embolus*. An embolus which travels against the flow of blood is called retrograde embolus e.g. metastatic deposits in the spine from carcinoma prostate. The spread occurs by retrograde embolism through intraspinal veins which carry tumour emboli from large thoracic and abdominal veins due to increased pressure in body cavities e.g. during coughing or straining.

Some of the important types of embolism are tabulated in **Web Table 5.7** and described below:

Thromboembolism (p. 120)

A detached thrombus or part of thrombus constitutes the most common type of embolism. These may arise in the arterial or venous circulation (**Web Image 5.24**):

Arterial (systemic) thromboembolism. Arterial emboli may be derived from the following sources:

- A. *Causes within the heart* (80-85%): These are mural thrombi in the left atrium or left ventricle, vegetations on the mitral or aortic valves, prosthetic heart valves and cardiomyopathy.
- B. *Causes within the arteries*: These include emboli developing in relation to atherosclerotic plaques, aortic aneurysms, pulmonary veins and paradoxical arterial emboli from the systemic venous circulation.

The *effects* of arterial emboli depend upon their size, site of lodgement, and adequacy of collateral circulation.

Venous thromboembolism. Venous emboli may arise from the following sources:

- i) Thrombi in the veins of the lower legs are the most common cause of venous emboli.
- ii) Thrombi in the pelvic veins.
- iii) Thrombi in the veins of the upper limbs.
- iv) Thrombosis in cavernous sinus of the brain.
- v) Thrombi in the right side of heart.

Pulmonary Thromboembolism (p. 120)

DEFINITION. Pulmonary embolism is the most common and fatal form of venous thromboembolism in which there is occlusion of pulmonary arterial tree by thromboemboli. Pulmonary thrombosis as such is uncommon and may occur in pulmonary atherosclerosis and pulmonary hypertension. Differentiation of pulmonary thrombosis from pulmonary thromboembolism is tabulated in **Web Table 5.8**.

ETIOLOGY. Pulmonary emboli are more common in hospitalised or bed-ridden patients, though they can occur in ambulatory patients as well. The causes are as follows:

- i) Thrombi originating from large veins of lower legs (such as popliteal, femoral and iliac) are the cause in 95% of pulmonary emboli.

ii) Less common sources include thrombi in varicosities of superficial veins of the legs, and pelvic veins such as peri-prostatic, periovarian, uterine and broad ligament veins.

PATHOGENESIS. Detachment of thrombi from any of the above-mentioned sites produces a thrombo-embolus that flows through venous drainage into the larger veins draining into right side of the heart.

◆ If the thrombus is large, it is impacted at the bifurcation of the main pulmonary artery (*saddle embolus*), or may be found in the right ventricle or its outflow tract.

◆ More commonly, there are *multiple emboli*, or a large embolus may be fragmented into many smaller emboli which are then impacted in a number of vessels, particularly affecting the lower lobes of lungs.

◆ Rarely, *paradoxical embolism* may occur by passage of an embolus from right heart into the left heart through atrial or ventricular septal defect. In this way, pulmonary emboli may reach systemic circulation.

CONSEQUENCES OF PULMONARY EMBOLISM. The following consequences can result (*Web Image 5.25*):

i) Sudden death. Massive pulmonary embolism results in instantaneous death, without occurrence of chest pain or dyspnoea.

ii) Acute cor pulmonale. Numerous small emboli may obstruct most of the pulmonary circulation resulting in acute right heart failure.

iii) Pulmonary infarction. Obstruction of relatively small-sized pulmonary arterial branches may result in pulmonary infarction.

iv) Pulmonary haemorrhage. Obstruction of terminal branches (endarteries) leads to central pulmonary haemorrhage.

v) Resolution. Vast majority of small pulmonary emboli (60-80%) are resolved by fibrinolytic activity.

vi) Pulmonary hypertension, chronic cor pulmonale and pulmonary arteriosclerosis. These are the sequelae of multiple small thromboemboli undergoing healing rather than resolution.

Systemic Embolism (p. 121)

This is the type of arterial embolism that originates commonly from thrombi in the diseased heart, especially in the left ventricle. These diseases of heart include myocardial infarction, cardiomyopathy, RHD, congenital heart disease, infective endocarditis, and prosthetic cardiac valves. These arterial emboli invariably cause infarction at the sites of lodgement which include, in descending order of frequency, lower extremity, brain, and internal visceral organs (spleen, kidneys, intestines). *Thus, the effects and sites of arterial emboli are in striking contrast to venous emboli* which are often lodged in the lungs.

Fat Embolism (p. 121)

Obstruction of arterioles and capillaries by fat globules constitutes fat embolism. If the obstruction in the circulation is by fragments of adipose tissue, it is called fat-tissue embolism.

ETIOLOGY

i) Traumatic causes:

◆ *Trauma to bones* is the most common cause of fat embolism e.g. in fractures of long bones leading to passage of fatty marrow in circulation, concussions of bones, after orthopaedic surgical procedures etc.

◆ *Trauma to soft tissue* e.g. laceration of adipose tissue and in puerperium due to injury to pelvic fatty tissue.

ii) Non-traumatic causes:

Extensive burns, diabetes mellitus, fatty liver, pancreatitis, sickle cell anaemia, decompression sickness, inflammation of bones and soft tissues, extrinsic fat or oils introduced into the body.

CONSEQUENCES OF FAT EMBOLISM. The effects of fat embolism depend upon the size and quantity of fat globules, and whether or not the emboli pass through the lungs into the systemic circulation.

i) Pulmonary fat embolism. In patients dying after fractures of bones, presence of numerous fat emboli in the capillaries of the lung is a frequent autopsy finding because the small fat globules are not likely to appreciably obstruct the vast pulmonary vascular bed.

ii) Systemic fat embolism. Some of the fat globules may pass through the pulmonary circulation such as via patent foramen ovale, arteriovenous shunts in the lungs and vertebral venous plexuses, and get lodged in the capillaries of organs like the brain, kidney, skin etc.

◆ **Brain.** The pathologic findings in the brain are petechial haemorrhages on the leptomeninges and minute haemorrhages in the parenchyma.

◆ **Kidney.** Renal fat embolism present in the glomerular capillaries, may cause decreased glomerular filtration.

◆ **Other organs.** Besides the brain and kidneys, other findings in systemic fat embolism are petechiae in the skin, conjunctivae, serosal surfaces, fat globules in the urine and sputum.

Gas Embolism (p. 122)

Air, nitrogen and other gases can produce bubbles within the circulation and obstruct the blood vessels causing damage to tissue. Two main forms of gas embolism—air embolism and decompression sickness are described below.

Air Embolism (p. 122)

VENOUS AIR EMBOLISM. Air may be sucked into systemic veins under the following circumstances:

i) Operations on head and neck, and trauma. The accidental opening of a major vein of the neck like jugular, or neck wounds involving the major neck veins, may allow air to be drawn into venous circulation.

ii) Obstetrical operations and trauma. During childbirth by normal vaginal delivery, caesarean section, abortions and other procedures, fatal air embolism may result from the entrance of air into the opened-up uterine venous sinuses and endometrial veins.

iii) Intravenous infusion of blood and fluid. Air embolism may occur during intravenous blood or fluid infusions if only positive pressure is employed.

iv) Angiography. During angiographic procedures, air may be entrapped into a large vein causing air embolism.

The effects of venous air embolism depend upon the following factors:

- i) Amount of air introduced into the circulation.
- ii) Rapidity of entry of a smaller volume of air.
- iii) Position of the patient during or soon after entry of air.
- iv) General condition of the patient.

The mechanism of death is by entrapment of air emboli in the pulmonary arterial trunk in the right heart.

ARTERIAL AIR EMBOLISM. Entry of air into pulmonary vein or its tributaries may occur in the following conditions:

i) Cardiothoracic surgery and trauma. Arterial air embolism may occur following thoracic operations, thoracocentesis, rupture of the lung, penetrating wounds of the lung, artificial pneumothorax etc.

ii) Paradoxical air embolism. This may occur due to passage of venous air emboli to the arterial side of circulation through a patent foramen ovale or via pulmonary arteriovenous shunts.

iii) Arteriography. During arteriographic procedures, air embolism may occur.

The effects of arterial air embolism are in the form of certain characteristic features:

- i) Marble skin due to blockage of cutaneous vessels.
- ii) Air bubbles in the retinal vessels seen ophthalmoscopically.
- iii) Pallor of the tongue due to occlusion of a branch of lingual artery.
- iv) Coronary or cerebral arterial air embolism may cause sudden death by much smaller amounts of air than in the venous air embolism.

Decompression Sickness (p. 123)

This is a specialised form of gas embolism known by various names such as caisson's disease, divers' palsy or aeroembolism.

PATHOGENESIS. Decompression sickness is produced when the individual decompresses suddenly, either from high atmospheric pressure to normal level, or from normal pressure to low atmospheric pressure.

◆ In divers, workers in caissons (diving-bells), offshore drilling and tunnels, who *descend* to high atmospheric pressure, increased amount of atmospheric gases (mainly nitrogen; others are O₂, CO₂) are dissolved in blood and tissue fluids. When such an individual ascends too rapidly i.e. comes to normal level suddenly from high atmospheric pressure, the gases come out of the solution as minute bubbles, particularly in fatty tissues which have affinity for nitrogen. These bubbles may coalesce together to form large emboli.

◆ In aeroembolism, seen in those who *ascend* to high altitudes or air flight in unpressurised cabins, the individuals are exposed to sudden decompression from low atmospheric pressure to normal levels. This results in similar effects as in divers and workers in caissons.

EFFECTS. The effects of decompression sickness depend upon the following:

- ◆ Depth or altitude reached
- ◆ Duration of exposure to altered pressure
- ◆ Rate of ascent or descent
- ◆ General condition of the individual

Pathologic changes are more pronounced in sudden decompression from high pressure to normal levels than in those who decompress from low pressure to normal levels. The changes are more serious in obese persons as nitrogen gas is more soluble in fat than in body fluids.

Clinical effects of decompression sickness are of 2 types—acute and chronic.

◆ **Acute form** occurs due to acute obstruction of small blood vessels in the vicinity of joints and skeletal muscles. The condition is clinically characterised by the following:

- i) 'The bends', as the patient doubles up in bed due to acute pain in joints, ligaments and tendons.
- ii) 'The chokes' occur due to accumulation of bubbles in the lungs, resulting in acute respiratory distress.
- iii) *Cerebral effects* may manifest in the form of vertigo, coma, and sometimes death.

◆ **Chronic form** is due to foci of ischaemic necrosis throughout body, especially the skeletal system. Ischaemic necrosis may be due to embolism *per se*, but other factors such as platelet activation, intravascular coagulation and hypoxia might contribute. The features of chronic form are as under:

- i) *Avascular necrosis of bones* e.g. head of femur, tibia, humerus.

- ii) *Neurological symptoms* may occur due to ischaemic necrosis in the central nervous system. These include paraesthesias and paraplegia.
- iii) *Lung involvement* in the form of haemorrhage, oedema, emphysema and atelectasis may be seen. These result in dyspnoea, nonproductive cough and chest pain.
- iv) *Skin manifestations* include itching, patchy erythema, cyanosis and oedema.
- v) *Other organs* like parenchymal cells of the liver and pancreas may show lipid vacuoles.

Amniotic Fluid Embolism (p. 123)

This is the most serious, unpredictable and unpreventable cause of maternal mortality. During labour and in the immediate postpartum period, the contents of amniotic fluid may enter the uterine veins and reach right side of the heart resulting in fatal complications. The amniotic fluid components which may be found in uterine veins, pulmonary artery and vessels of other organs are: epithelial squames, vernix caseosa, lanugo hair, bile from meconium, and mucus.

M/E Notable changes are seen in the lungs such as haemorrhages, congestion, oedema and changes of ARDS, and dilatation of right side of the heart. These changes are associated with identifiable amniotic fluid contents within the pulmonary microcirculation.

The *clinical syndrome* of amniotic fluid embolism is characterised by the following features:

- ◆ Sudden respiratory distress and dyspnoea
- ◆ Deep cyanosis
- ◆ Cardiovascular shock
- ◆ Convulsions
- ◆ Coma
- ◆ unexpected death

The *cause of death* may not be obvious but can occur as a result of the following mechanisms:

- i) Mechanical blockage of the pulmonary circulation in extensive embolism.
- ii) Anaphylactoid reaction to amniotic fluid components.
- iii) Disseminated intravascular coagulation (DIC) due to liberation of thromboplastin by amniotic fluid.
- iv) Haemorrhagic manifestations due to thrombocytopenia and afibrinogenaemia.

Atheroembolism (p. 124)

Atheromatous plaques, especially from aorta, may get eroded to form atherosclerotic emboli which are then lodged in medium-sized and small arteries.

Tumour Embolism (p. 124)

Malignant tumour cells invade the local blood vessels and may form tumour emboli to be lodged elsewhere, producing metastatic tumour deposits.

ISCHAEMIA (p. 124)

DEFINITION. Ischaemia is defined as deficient blood supply to part of a tissue. The cessation of blood supply may be *complete* (complete ischaemia) or *partial* (partial ischaemia). The adverse effects of ischaemia may result from 3 ways:

1. **Hypoxia** due to deprivation of oxygen to tissues; this is the most important and common cause. It may be of 4 types:
 - i) *Hypoxic hypoxia* : due to low oxygen in arterial blood.
 - ii) *Anaemic hypoxia*: due to low level of haemoglobin in blood.

- iii) *Stagnant hypoxia*: due to inadequate blood supply.
- iv) *Histotoxic hypoxia*: low oxygen uptake due to cellular toxicity.

2. Malnourishment of cells due to inadequate supply of nutrients to the tissue (i.e. glucose, amino acids); this is less important.

3. Inadequate clearance of metabolites which results in accumulation of metabolic waste-products in the affected tissue; this is relevant in some conditions such as muscle ache after ischaemia from heavy exercise.

ETIOLOGY. The causes are as under:

1. Causes in the heart. Inadequate cardiac output resulting from heart block, ventricular arrest and fibrillation from various causes may cause hypoxic injury to the brain.

- i) If the arrest continues for 15 seconds, consciousness is lost.
- ii) If the condition lasts for more than 4 minutes, irreversible ischaemic damage to the brain occurs.
- iii) If it is prolonged for more than 8 minutes, death is inevitable.

2. Causes in the arteries. The commonest and most important causes of ischaemia are due to obstruction in arterial blood supply.

i) *Luminal occlusion of artery:*

- a) Thrombosis
- b) Embolism

ii) *Causes in the arterial walls:*

- a) Vasospasm (e.g. in Raynaud's disease)
- b) Hypothermia, ergotism
- c) Arteriosclerosis
- d) Polyarteritis nodosa
- e) Thromboangiitis obliterans (Buerger's disease)
- f) Severed vessel wall

iii) *Outside pressure on an artery:*

- a) Ligature
- b) Tourniquet
- c) Tight plaster, bandages
- d) Torsion.

3. Causes in the veins. Blockage of venous drainage may lead to engorgement and obstruction to arterial blood supply resulting in ischaemia.

i) *Luminal occlusion of vein:*

- a) Thrombosis of mesenteric veins
- b) Cavertous sinus thrombosis

ii) *Causes in the vessel wall of vein:*

- a) Varicose veins of the legs

iii) *Outside pressure on vein:*

- a) Strangulated hernia
- b) Intussusception
- c) Volvulus

4. Causes in the microcirculation. Ischaemia may result from occlusion of arterioles, capillaries and venules.

i) *Luminal occlusion in microvasculature:*

- a) By red cells e.g. in sickle cell anaemia, red cells parasitised by malaria, acquired haemolytic anaemia, sludging of the blood.
- b) By white cells e.g. in chronic myeloid leukaemia
- c) By fibrin e.g. defibrination syndrome
- d) By precipitated cryoglobulins
- e) By fat embolism
- f) In decompression sickness.

ii) *Causes in the microvasculature wall:*

- a) Vasculitis e.g. in polyarteritis nodosa, Henoch-Schönlein purpura, Arthus reaction, septicaemia.
- b) Frost-bite injuring the wall of small blood vessels.

iii) *Outside pressure on microvasculature:*

a) *Bedsores.*

FACTORS DETERMINING SEVERITY OF ISCHAEMIC INJURY. The extent of damage produced by ischaemia due to occlusion of arterial or venous blood vessels depends upon a number of factors.

1. Anatomic pattern. The extent of injury by ischaemia depends upon the anatomic pattern of arterial blood supply of the organ or tissue affected. There are 4 different patterns of arterial blood supply:

- i) *Single arterial supply without anastomosis.*
- ii) *Single arterial supply with rich anastomosis.*
- iii) *Parallel arterial supply.*
- iv) *Double blood supply.*

2. General and cardiovascular status. The general status of an individual as regards cardiovascular function is an important determinant to assess the effect of ischaemia.

- i) *Anaemias (sickle cell anaemia, in particular)*
- ii) *Lowered oxygenation of blood (hypoxaemia)*
- iii) *Senility with marked coronary atherosclerosis*
- iv) *Cardiac failure*
- v) *Blood loss*
- vi) *Shock.*

3. Type of tissue affected. The vulnerability of tissue of the body to the effect of ischaemia is variable. The mesenchymal tissues are quite resistant to the effect of ischaemia as compared to parenchymal cells of the organs. The following tissues are more vulnerable to ischaemia:

- i) *Brain (cerebral cortical neurons, in particular).*
- ii) *Heart (myocardial cells).*
- iii) *Kidney (especially epithelial cells of proximal convoluted tubules).*

4. Rapidity of development. Sudden vascular obstruction results in more severe effects of ischaemia than if it is gradual since there is less time for collaterals to develop.

5. Degree of vascular occlusion. Complete vascular obstruction results in more severe ischaemic injury than the partial occlusion.

EFFECTS. The effects of ischaemia are variable and range from 'no change' to 'sudden death'.

1. *No effects on the tissues.*
2. *Functional disturbances.*
3. *Cellular changes.*
4. *Sudden death.*

□ **INFARCTION** (p. 126)

Infarction is the process of tissue necrosis resulting from some form of circulatory insufficiency; the localised area of necrosis so developed is called an *infarct*.

ETIOLOGY. All the causes of ischaemia discussed above can cause infarction. There are a few other noteworthy features in infarction:

- ◆ *Most commonly, infarcts are caused by interruption in arterial blood supply, called ischaemic necrosis.*
- ◆ *Less commonly, venous obstruction can produce infarcts termed stagnant hypoxia.*
- ◆ *Generally, sudden, complete, and continuous occlusion (e.g. thrombosis or embolism) produces infarcts.*
- ◆ *Infarcts may be produced by nonocclusive circulatory insufficiency as well e.g. incomplete atherosclerotic narrowing of coronary arteries may produce myocardial infarction due to acute coronary insufficiency.*

TYPES OF INFARCTS. Infarcts are classified depending upon different features:

1. According to their colour:

● *Pale or anaemic*, due to arterial occlusion and are seen in compact organs e.g. in the kidneys, heart, spleen.

● *Red or haemorrhagic*, seen in soft loose tissues and are caused either by pulmonary arterial obstruction (e.g. in the lungs) or by arterial or venous occlusion (e.g. in the intestines).

2. According to their age:

● *Recent or fresh*

● *Old or healed*

3. According to presence or absence of infection:

● *Bland*, when free of bacterial contamination

● *Septic*, when infected.

G/A Infarcts of solid organs are usually wedge-shaped, the apex pointing towards the occluded artery and the wide base on the surface of the organ. Infarcts due to arterial occlusion are generally pale while those due to venous obstruction are haemorrhagic. Most infarcts become pale later as the red cells are lysed but pulmonary infarcts never become pale due to extensive amount of blood. Cerebral infarcts are poorly defined with central softening (encephalomalacia). Recent infarcts are generally slightly elevated over the surface while the old infarcts are shrunken and depressed under the surface of the organ.

M/E The pathognomonic cytologic change in all infarcts is coagulative (ischaemic) necrosis of the affected area of tissue or organ. In cerebral infarcts, however, there is characteristic liquefactive necrosis. Some amount of haemorrhage is generally present in any infarct. At the periphery of an infarct, inflammatory reaction is noted.

Infarcts of Different Organs (p. 126)

Web Image 5.26 shows the organs most commonly affected by infarction.

INFARCT LUNG

G/A Pulmonary infarcts are classically wedge-shaped with base on the pleura, haemorrhagic, variable in size, and most often in the lower lobes (**Web Image 5.27**). Fibrinous pleuritis usually covers the area of infarct. Cut surface is dark purple and may show the blocked vessel near the apex of the infarcted area. Old organised and healed pulmonary infarcts appear as retracted fibrous scars.

M/E The characteristic histologic feature is coagulative necrosis of the alveolar walls. Initially, there is infiltration by neutrophils and intense alveolar capillary congestion, but later their place is taken by haemosiderin, phagocytes and granulation tissue (**Web Image 5.28**).

INFARCT KIDNEY

G/A Renal infarcts are often multiple and may be bilateral. Characteristically, they are pale or anaemic and wedge-shaped with base resting under the capsule and apex pointing towards the medulla. Generally, a narrow rim of preserved renal tissue under the capsule is spared because it draws its blood supply from the capsular vessels. Cut surface of renal infarct in the first 2 to 3 days is red and congested but by 4th day the centre becomes pale yellow (**Web Image 5.29**).

M/E The affected area shows characteristic coagulative necrosis of renal parenchyma i.e. there are ghosts of renal tubules and glomeruli without intact nuclei and cytoplasmic content. The margin of the infarct shows

90 inflammatory reaction—initially acute but later macrophages and fibrous tissue predominate (**Web Image 5.30**).

INFARCT SPLEEN

G/A Splenic infarcts are often multiple. They are characteristically pale or anaemic and wedge-shaped with their base at the periphery and apex pointing towards hilum (**Web Image 5.31**).

M/E The features are similar to those found in anaemic infarcts in kidney. Coagulative necrosis and inflammatory reaction are seen. Later, the necrotic tissue is replaced by shrunken fibrous scar (**Web Image 5.32**).

INFARCT LIVER

G/A Ischaemic infarcts of the liver are usually anaemic but sometimes may be haemorrhagic due to stuffing of the site by blood from the portal vein. Infarcts of Zahn (non-ischaemic infarcts) produce sharply defined red-blue area in liver parenchyma.

M/E Ischaemic infarcts show characteristics of pale or anaemic infarcts as in kidney or spleen. Infarcts of Zahn occurring due to reduced portal blood flow over a long duration result in chronic atrophy of hepatocytes and dilatation of sinusoids.

Web Table 5.9 summarises the gross appearance and the usual outcome of the common types of infarction.

SELF ASSESSMENT

- The essential difference between plasma and interstitial fluid compartment is:**
 - Glucose is higher in the former
 - Urea is higher in the former
 - Protein content is higher in the former
 - Potassium is higher in the former
- Osmotic pressure exerted by the chemical constituents of the body fluids has the following features except:**
 - Crystalloid osmotic pressure comprises minor portion of total osmotic pressure
 - Oncotic pressure constitutes minor portion of total osmotic pressure
 - Oncotic pressure of plasma is higher
 - Oncotic pressure of interstitial fluid is lower
- For causation of oedema by decreased osmotic pressure, the following factor is most important:**
 - Fall in albumin as well as globulin
 - Fall in globulin level
 - Fall in albumin level
 - Fall in fibrinogen level
- Transudate differs from exudate in having the following except:**
 - No inflammatory cells
 - Low glucose content
 - Low protein content
 - Low specific gravity
- Nephritic oedema differs from nephrotic oedema in having the following except:**
 - Mild oedema
 - Distributed on face, eyes
 - Heavy proteinuria
 - Occurs in acute glomerulonephritis
- The following type of oedema is characteristically dependent oedema:**
 - Nephrotic oedema
 - Nephritic oedema
 - Pulmonary oedema
 - Cardiac oedema

7. **Pulmonary oedema appears due to elevated pulmonary hydrostatic pressure when the fluid accumulation is:**
 - A. Two fold
 - B. Four fold
 - C. Eight fold
 - D. Ten fold
8. **Active hyperaemia is the result of:**
 - A. Dilatation of capillaries
 - B. Dilatation of arterioles
 - C. Venous engorgement
 - D. Lymphatic obstruction
9. **Sectioned surface of lung shows brown induration in:**
 - A. Pulmonary embolism
 - B. Pulmonary haemorrhage
 - C. Pulmonary infarction
 - D. CVC lung
10. **In septic shock, pathogenesis of endothelial cell injury involves the following mechanisms except:**
 - A. Lipopolysaccharide from lysed bacteria injures the endothelium
 - B. Interleukin-1 causes endothelial cell injury
 - C. TNF- α causes direct cytotoxicity
 - D. Adherence of PMNs to endothelium causes endothelial cell injury
11. **An intact endothelium elaborates the following anti-thrombotic factors except:**
 - A. Thrombomodulin
 - B. ADPase
 - C. Tissue plasminogen activator
 - D. Thromboplastin
12. **The most common cause of arterial thromboemboli is:**
 - A. Cardiac thrombi
 - B. Aortic aneurysm
 - C. Pulmonary veins
 - D. Aortic atherosclerotic plaques
13. **Venous emboli are most often lodged in:**
 - A. Intestines
 - B. Kidneys
 - C. Lungs
 - D. Heart
14. **Pathologic changes between sudden decompression from high pressure to normal levels and decompression from low pressure to normal levels are:**
 - A. More marked in the former
 - B. More marked in the latter
 - C. No difference between the two
 - D. Acute form is more marked in the latter
15. **The infarct of following organ is invariably haemorrhagic:**
 - A. Infarct kidney
 - B. Infarct spleen
 - C. Infarct lung
 - D. Infarct heart
16. **Milroy's disease is:**
 - A. Cerebral oedema
 - B. Pulmonary oedema
 - C. Hereditary lymphoedema
 - D. Postural oedema
17. **Pick the correct sequence:**
 - A. Renin-Angiotensin II-Angiotensin I-Angiotensinogen-Aldosterone
 - B. Angiotensinogen-Renin-Angiotensin II-Angiotensin I-Aldosterone
 - C. Renin-Angiotensinogen-Angiotensin I-Angiotensin II-Aldosterone
 - D. Aldosterone-Renin-Angiotensinogen-Angiotensin II-Angiotensin I
18. **Which of the following is true?**
 - A. Arterial thrombi are white and occlusive
 - B. Venous thrombi are white and occlusive
 - C. Arterial thrombi are white and mural
 - D. Venous thrombi are red and mural

KEY

1 = C	2 = A	3 = C	4 = B
5 = C	6 = D	7 = D	8 = B
9 = D	10 = A	11 = D	12 = A
13 = C	14 = A	15 = C	16 = C
17 = C	18 = C		



Inflammation and Healing

□ INTRODUCTION (p. 130)

DEFINITION AND CAUSES. Inflammation is defined as the local response of living mammalian tissues to injury due to any agent. It is a body defense reaction in order to eliminate or limit the spread of injurious agent, followed by removal of the necrosed cells and tissues.

The agents causing inflammation may be as under:

1. *Infective agents* like bacteria, viruses and their toxins, fungi, parasites.
2. *Immunological agents* like cell-mediated and antigen-antibody reactions.
3. *Physical agents* like heat, cold, radiation, mechanical trauma.
4. *Chemical agents* like organic and inorganic poisons.
5. *Inert materials* such as foreign bodies.

Thus, *inflammation is distinct from infection*—while inflammation is a protective response by the body to variety of etiologic agents (infectious or non-infectious), while infection is invasion into the body by harmful microbes and their resultant ill-effects by toxins. Inflammation involves 2 basic processes with some overlapping, viz. early *inflammatory response* and later followed by *healing*.

SIGNS OF INFLAMMATION. The Roman writer Celsus in 1st century A.D. named the famous 4 *cardinal signs of inflammation* as:

- *rubor* (redness);
- *tumor* (swelling);
- *calor* (heat); and
- *dolor* (pain).

To these, fifth sign *functio laesa* (loss of function) was later added by Virchow.

TYPES OF INFLAMMATION. Depending upon the defense capacity of the host and duration of response, inflammation can be classified as acute and chronic.

A. *Acute inflammation* is of short duration (lasting less than 2 weeks) and represents the early body reaction, resolves quickly and is usually followed by healing.

Sometimes, the acute inflammatory response may be quite severe and is termed as *fulminant acute inflammation*.

B. *Chronic inflammation* is of longer duration and occurs either after the causative agent of acute inflammation persists for a long time, or the stimulus is such that it induces chronic inflammation from the beginning. A variant, *chronic active inflammation*, is the type of chronic inflammation in which during the course of disease there are acute exacerbations of activity.

In some instances, the term *subacute inflammation* is used for the state of inflammation between acute and chronic.

ACUTE INFLAMMATION (p. 130)

Acute inflammatory response by the host to any agent is a continuous process but for the purpose of discussion, it can be divided into following two events:

- I. Vascular events.
- II. Cellular events.

Intimately linked to these two processes is the release of mediators of acute inflammation, discussed just thereafter.

□ I. VASCULAR EVENTS (p. 130)

Alteration in the microvasculature (arterioles, capillaries and venules) is the earliest response to tissue injury. These alterations include: haemodynamic changes and changes in vascular permeability.

Haemodynamic Changes (p. 130)

The earliest features of inflammatory response result from changes in the vascular flow and calibre of small blood vessels in the injured tissue. The sequence of these changes is as under:

1. Irrespective of the type of injury, immediate vascular response is of **transient vasoconstriction** of arterioles. With mild form of injury, the blood flow may be re-established in 3-5 seconds.
2. Next follows **persistent progressive vasodilatation** which involves mainly the arterioles, but to a lesser extent, affects other components of the microcirculation like venules and capillaries. This change is obvious within half an hour of injury.
3. Progressive vasodilatation, in turn, may elevate the **local hydrostatic pressure** resulting in transudation of fluid into the extracellular space. This is responsible for swelling at the local site of acute inflammation.
4. **Slowing or stasis** of microcirculation follows which causes increased concentration of red cells, and thus, raised blood viscosity.
5. Stasis or slowing is followed by **leucocytic margination** or peripheral orientation of leucocytes (mainly neutrophils) along the vascular endothelium. The leucocytes stick to the vascular endothelium briefly, and then move and migrate through the gaps between the endothelial cells into the extravascular space. This process is known as *emigration* (discussed later in detail).

The features of haemodynamic changes in inflammation are best demonstrated by the **Lewis experiment**. Lewis induced the changes in the skin of inner aspect of forearm by firm stroking with a blunt point. The reaction so elicited is known as *triple response* or *red line response* consisting of the following (**Web Image 6.1**):

- i) *Red line* appears within a few seconds following stroking and is due to local vasodilatation of capillaries and venules.
- ii) *Flare* is the bright reddish appearance or flush surrounding the red line and results from vasodilatation of the adjacent arterioles.
- iii) *Wheal* is the swelling or oedema of the surrounding skin occurring due to transudation of fluid into the extravascular space.

Altered Vascular Permeability (p. 131)

PATHOGENESIS. In and around the inflamed tissue, there is accumulation of oedema fluid in the interstitial compartment which comes from blood plasma by its escape through the endothelial wall of peripheral vascular bed. In the initial stage, the escape of fluid is due to vasodilatation and consequent elevation in hydrostatic pressure. This is transudate in nature. But subsequently, the characteristic inflammatory oedema, exudate, appears by increased vascular permeability of microcirculation.

The appearance of inflammatory oedema due to increased vascular permeability of microvascular bed is explained on the basis of **Starling's hypothesis**. In normal circumstances, the fluid balance is maintained by two opposing sets of forces:

- i) Forces that cause **outward movement** of fluid from microcirculation are *intravascular hydrostatic pressure* and *colloid osmotic pressure of interstitial fluid*.

- ii) Forces that cause **inward movement** of interstitial fluid into circulation are *intravascular colloid osmotic pressure* and *hydrostatic pressure of interstitial fluid*.

Whatever little fluid is left in the interstitial compartment is drained away by lymphatics and, thus, no oedema results normally (**Web Image 6.2,A**). However, in inflamed tissues, the endothelial lining of microvasculature becomes more leaky. Consequently, intravascular colloid osmotic pressure decreases and osmotic pressure of the interstitial fluid increases resulting in excessive outward flow of fluid into the interstitial compartment which is exudative inflammatory oedema (**Web Image 6.2,B**).

MECHANISMS OF INCREASED VASCULAR PERMEABILITY. In acute inflammation, normally non-permeable endothelial layer of microvasculature becomes leaky. This is explained by one or more of the following mechanisms which are diagrammatically illustrated in **Web Image 6.3**.

- i) **Contraction of endothelial cells.** This is the most common mechanism of increased leakiness that affects venules exclusively while capillaries and arterioles remain unaffected. The endothelial cells develop temporary gaps between them due to their contraction resulting in vascular leakiness. It is mediated by the release of histamine, bradykinin and other chemical mediators. The response begins immediately after injury, is usually reversible, and is for short duration (15-30 minutes).

Example of such *immediate transient leakage* is mild thermal injury of skin of forearm.

- ii) **Retraction of endothelial cells.** In this mechanism, there is structural re-organisation of the cytoskeleton of endothelial cells that causes reversible retraction at the intercellular junctions. This change too affects venules and is mediated by cytokines such as interleukin-1 (IL-1) and tumour necrosis factor (TNF)- α . The onset of response takes 4-6 hours after injury and lasts for 2-4 hours or more (*somewhat delayed and prolonged leakage*).

The example of this type of response exists *in vitro* experimental work only.

- iii) **Direct injury to endothelial cells.** Direct injury to the endothelium causes cell necrosis and appearance of physical gaps at the sites of detached endothelial cells. Process of thrombosis is initiated at the site of damaged endothelial cells. The change affects all levels of microvasculature (venules, capillaries and arterioles). The increased permeability may either appear immediately after injury and last for several hours or days (*immediate sustained leakage*), or may occur after a delay of 2-12 hours and last for hours or days (*delayed prolonged leakage*).

The examples of immediate sustained leakage are severe bacterial infections while delayed prolonged leakage may occur following moderate thermal injury and radiation injury.

- iv) **Endothelial injury mediated by leucocytes.** Adherence of leucocytes to the endothelium at the site of inflammation may result in activation of leucocytes. The activated leucocytes release proteolytic enzymes and toxic oxygen species which may cause endothelial injury and increased vascular leakiness. This form of increased vascular leakiness affects mostly venules and is a *late response*.

The examples are seen in sites where leucocytes adhere to the vascular endothelium e.g. in pulmonary venules and capillaries.

- v) **Leakiness in neovascularisation.** In addition, the newly formed capillaries under the influence of vascular endothelial growth factor (VEGF) during the process of repair and in tumours are excessively leaky.

These mechanisms are summarised in **Web Table 6.1**.

□ II. CELLULAR EVENTS (p. 133)

The cellular phase of inflammation consists of two processes:

1. exudation of leucocytes; and
2. phagocytosis.

Exudation of Leucocytes (p. 133)

The changes leading to migration of leucocytes are as follows (**Web Image 6.4**):

1. CHANGES IN THE FORMED ELEMENTS OF BLOOD. In the early stage of inflammation, the rate of flow of blood is increased due to vasodilatation. But subsequently, there is slowing or stasis of bloodstream. With stasis, changes in the normal axial flow of blood in the microcirculation take place. Due to slowing and stasis, the central stream of cells widens and peripheral plasma zone becomes narrower because of loss of plasma by exudation. This phenomenon is known as *margination*. As a result of this redistribution, the neutrophils of the central column come close to the vessel wall; this is known as *pavementing*.

2. ROLLING AND ADHESION. Peripherally marginated and paved neutrophils slowly roll over the endothelial cells lining the vessel wall (*rolling phase*). This is followed by the transient bond between the leucocytes and endothelial cells becoming firmer (*adhesion phase*). The following molecules bring about rolling and adhesion phases:

- i) **Selectins** are expressed on the surface of activated endothelial cells which recognise specific carbohydrate groups found on the surface of neutrophils, the most important of which is s-Lewis X molecule.
- ii) **Integrins** on the endothelial cell surface are activated during the process of loose and transient adhesions between endothelial cells and leucocytes.
- iii) **Immunoglobulin gene superfamily adhesion molecule** such as intercellular adhesion molecule-1 (ICAM-1) and vascular cell adhesion molecule-1 (VCAM-1) allow a tighter adhesion and stabilise the interaction between leucocytes and endothelial cells.

3. EMIGRATION. After sticking of neutrophils to endothelium, the former move along the endothelial surface till a suitable site between the endothelial cells is found where the neutrophils throw out cytoplasmic pseudopods. Subsequently, the neutrophils lodged between the endothelial cells and basement membrane cross the basement membrane by damaging it locally with secreted collagenases and escape out into the extravascular space; this is known as *emigration*.

Simultaneous to emigration of leucocytes, escape of red cells through gaps between the endothelial cells, *diapedesis*, takes place.

4. CHEMOTAXIS. The chemotactic factor-mediated transmigration of leucocytes after crossing several barriers (endothelium, basement membrane, perivascular myofibroblasts and matrix) to reach the interstitial tissues is called chemotaxis. The concept of chemotaxis is well illustrated by *Boyden's chamber experiment*. In this, a millipore filter (3 μm pore size) separates the suspension of leucocytes from the test solution in tissue culture chamber. If the test solution contains chemotactic agent, the leucocytes migrate through the pores of filter towards the chemotactic agent (**Web Image 6.5**).

The following agents act as potent chemotactic substances or *chemokines* for neutrophils:

- i) Leukotriene B₄ (LT-B₄), a product of lipoxygenase pathway of arachidonic acid metabolites
- ii) Components of complement system (C5a and C3a in particular)
- iii) Cytokines (Interleukins, in particular IL-8)
- iv) Soluble bacterial products (such as formylated peptides).

Phagocytosis is defined as the process of engulfment of solid particulate material by the cells (cell-eating). The cells performing this function are called *phagocytes*. There are 2 main types of phagocytic cells:

- i) Polymorphonuclear neutrophils (PMNs) which appear early in acute inflammatory response, sometimes called as *microphages*.
- ii) Circulating monocytes and fixed tissue mononuclear phagocytes, commonly called as *macrophages*.

Neutrophils and macrophages on reaching the tissue spaces produce several proteolytic enzymes—lysozyme, protease, collagenase, elastase, lipase, proteinase, gelatinase, and acid hydrolases. These enzymes degrade collagen and extracellular matrix. The microbe undergoes the process of phagocytosis by polymorphs and macrophages and involves the following 3 steps (**Web Image 6.6**):

1. RECOGNITION AND ATTACHMENT

Phagocytosis is initiated by the expression of surface receptors on macrophages which recognise microorganisms: *mannose receptor* and *scavenger receptor*. The process of phagocytosis is further enhanced when the microorganisms are coated with specific proteins, *opsonins*, from the serum or they get opsonised.

- i) *IgG opsonin* is the Fc fragment of immunoglobulin G; it is the naturally occurring antibody in the serum that coats the bacteria while the PMNs possess receptors for the same.
- ii) *C3b opsonin* is the fragment generated by activation of complement pathway. It is strongly chemotactic for attracting PMNs to bacteria.
- iii) *Lectins* are carbohydrate-binding proteins in the plasma which bind to bacterial cell wall.

2. ENGULFMENT

The opsonised particle bound to the surface of phagocyte is ready to be engulfed. This is accomplished by formation of cytoplasmic pseudopods around the particle due to activation of actin filaments beneath cell wall, enveloping it in a phagocytic vacuole. Eventually, the plasma membrane enclosing the particle breaks from the cell surface so that membrane lined phagocytic vacuole or phagosome lies internalised and free in the cell cytoplasm. The phagosome fuses with one or more lysosomes of the cell and form bigger vacuole called phagolysosome.

3. KILLING AND DEGRADATION

Next comes the stage of killing and degradation of microorganism to dispose it off justifying the function of phagocytes as scavenger cells. The microorganisms after being killed by antibacterial substances are degraded by hydrolytic enzymes. However, this mechanism fails to kill and degrade some bacteria like tubercle bacilli.

Disposal of microorganisms can proceed by following mechanisms:

A. INTRACELLULAR MECHANISMS. There are intracellular metabolic pathways which more commonly kill microbes by oxidative mechanism and less often non-oxidative pathways.

i) Oxidative bactericidal mechanism by oxygen free radicals. An important mechanism of microbicidal killing is by oxidative damage by the production of reactive oxygen metabolites (O_2 , H_2O_2 , OH' , $HOCl$, HOI , $HOBr$).

A phase of increased oxygen consumption ('respiratory burst') by activated phagocytic leucocytes requires the essential presence of NADPH oxidase.

NADPH-oxidase present in the cell membrane of phagosome reduces oxygen to superoxide ion (O_2^-).

This type of bactericidal activity is carried out either via enzyme myeloperoxidase (MPO) present in the azurophilic granules of neutrophils and monocytes, or independent of enzyme MPO.

ii) Oxidative bactericidal mechanism by lysosomal granules. In this mechanism, the preformed granule-stored products of neutrophils and macrophages are discharged or secreted into the phagosome and the extracellular environment. Progressive degranulation of neutrophils and macrophages along with oxygen free radicals degrades proteins i.e. induces proteolysis.

iii) Non-oxidative bactericidal mechanism. Some agents released from the granules of phagocytic cells do not require oxygen for bactericidal activity. These include the following:

a) Granules. Some of liberated lysosomal granules do not kill by oxidative damage but cause lysis of within phagosome. These are lysosomal hydrolases, permeability increasing factors, cationic proteins (defensins), lipases, ptoteases, DNAases.

b) Nitric oxide. Nitric oxide reactive free radicals similar to oxygen free radicals are formed by nitric oxide synthase and is a potent mechanism of microbial killing. Nitric oxide is produced by endothelial cells as well as by activated macrophages.

B. EXTRACELLULAR MECHANISMS. Following mechanisms explain the bactericidal activity at extracellular level:

i) Granules. Degranulation of macrophages and neutrophils explained above continues to exert its effects of proteolysis outside the cells as well.

ii) Immune mechanisms. As already discussed in Chapter 4, immune-mediated lysis of microbes takes place outside the cells by mechanisms of cytolysis, antibody-mediated lysis and by cell-mediated cytotoxicity.

□ CHEMICAL MEDIATORS OF INFLAMMATION (p. 136)

Also called as permeability factors or endogenous mediators of increased vascular permeability, these are a large and increasing number of endogenous compounds which can enhance vascular permeability.

The substances acting as chemical mediators of inflammation may be released from the cells, the plasma, or damaged tissue itself.

Web Table 6.2 presents a list of chemical mediators of acute inflammation.

Chemical mediators derived from various sources and their contribution in acute inflammation are shown in **Web Image 6.7**.

I. Cell-derived Mediators (p. 136)

1. VASOACTIVE AMINES. Two important pharmacologically active amines that have role in the early inflammatory response (first one hour) are histamine and 5-hydroxytryptamine (5-HT) or serotonin; another recently added group is of neuropeptides.

i) Histamine. It is stored in the granules of mast cells, basophils and platelets. Histamine is released from these cells by various agents as under:

- Stimuli or substances inducing acute inflammation e.g. heat, cold, irradiation, trauma, irritant chemicals, immunologic reactions etc.
- Anaphylatoxins like fragments of complement C3a, and C5a, which increase vascular permeability and cause oedema in tissues.
- Histamine-releasing factors from neutrophils, monocytes and platelets.
- Interleukins.

The main actions of histamine are: vasodilatation, increased vascular (venular) permeability, itching and pain. Stimulation of mast cells and basophils also releases products of arachidonic acid metabolism including

the release of *slow-reacting substances of anaphylaxis (SRS-As)*. The SRS-As consist of various leukotrienes (LTC_4 , LTD_4 and LTE_4).

ii) 5-Hydroxytryptamine (5-HT or serotonin). It is present in tissues like chromaffin cells of GIT, spleen, nervous tissue, mast cells and platelets. The actions of 5-HT are similar to histamine but it is a less potent mediator of increased vascular permeability and vasodilatation than histamine.

iii) Neuropeptides. Another class of vasoactive amines is tachykinin neuropeptides, such as substance P, neurokinin A, vasoactive intestinal polypeptide (VIP) and somatostatin. These small peptides are produced in the central and peripheral nervous systems.

The major proinflammatory *actions* of these neuropeptides is as follows:

- Increased vascular permeability.
- Transmission of pain stimuli.
- Mast cell degranulation.

2. ARACHIDONIC ACID METABOLITES (EICOSANOIDS). Arachidonic acid metabolites or eicosanoids are the most potent mediators of inflammation, much more than oxygen free radicals.

i) Metabolites via cyclo-oxygenase pathway: Prostaglandins, thromboxane A_2 , prostacyclin. The name 'prostaglandin' was first given to a substance found in human seminal fluid but now the same substance has been isolated from a number of other body cells.

Cyclo-oxygenase (COX), a fatty acid enzyme present as COX-1 and COX-2, acts on activated arachidonic acid to form prostaglandin endoperoxide (PGG_2). PGG_2 is enzymatically transformed into PGH_2 with generation of free radical of oxygen. PGH_2 is further acted upon by enzymes and results in formation of the following 4 metabolites (**Web Image 6.8**):

- Prostaglandins (PGD_2 , PGE_2 and $PGF_2-\alpha$).
- Thromboxane A_2 (TXA_2).
- Prostacyclin (PGI_2).
- Resolvins.

It may be mentioned here that some of the major anti-inflammatory drugs act by inhibiting activity of the enzyme COX; e.g. non-steroidal anti-inflammatory drugs (NSAIDs), COX-2 inhibitors.

ii) Metabolites via lipo-oxygenase pathway: 5-HETE, leukotrienes, lipoxins. The enzyme, lipo-oxygenase, a predominant enzyme in neutrophils, acts on activated arachidonic acid to form hydroperoxy eicosatetraenoic acid (5-HPETE) which on further peroxidation forms following 2 metabolites (**Web Image 6.9**):

- 5-HETE (hydroxy compound), an intermediate product, is a potent chemotactic agent for neutrophils.
- Leukotrienes (LT) are so named as they were first isolated from leucocytes.
- Lipoxins (LX) are a recently described product of lipoxygenase pathway.

3. LYSOSOMAL COMPONENTS. The inflammatory cells—neutrophils and monocytes, contain lysosomal granules which on release elaborate a variety of mediators of inflammation.

i) Granules of neutrophils. Neutrophils have 3 types of granules:

- Primary or azurophil granules* are large azurophil granules which contain functionally active enzymes. These are myeloperoxidase, acid hydrolases, acid phosphatase, lysozyme, defensin (cationic protein), phospholipase, cathepsin G, elastase, and protease.
- Secondary or specific granules* contain alkaline phosphatase, lactoferrin, gelatinase, collagenase, lysozyme, vitamin- B_{12} binding proteins, plasminogen activator.
- Tertiary granules or C particles* contain gelatinase and acid hydrolases.

Myeloperoxidase causes oxidative lysis by generation of oxygen free radicals, acid hydrolases act within the cell to cause destruction of bacteria

in phagolysosome while proteases attack on the extracellular constituents such as basement membrane, collagen, elastin, cartilage etc.

However, degradation of extracellular components like collagen, basement membrane, fibrin and cartilage by proteases results in harmful tissue destruction which is kept in check by presence of antiproteases like α_1 -antitrypsin and α_2 -macroglobulin.

ii) Granules of monocytes and tissue macrophages. These cells on degranulation also release mediators of inflammation like acid proteases, collagenase, elastase and plasminogen activator. However, they are more active in chronic inflammation than acting as mediators of acute inflammation.

4. PLATELET ACTIVATING FACTOR (PAF). It is released from IgE-sensitised basophils or mast cells, other leucocytes, endothelium and platelets. Apart from its action on platelet aggregation and release reaction, the actions of PAF as mediator of inflammation are:

- ◆ increased vascular permeability;
- ◆ vasodilatation in low concentration and vasoconstriction otherwise;
- ◆ bronchoconstriction;
- ◆ adhesion of leucocytes to endothelium; and
- ◆ chemotaxis.

5. CYTOKINES. Cytokines are polypeptide substances produced by activated lymphocytes (*lymphokines*) and activated monocytes (*monokines*). These agents may act on 'self' cells producing them or on other cells. Although over 200 cytokines have been described, major cytokines acting as mediators of inflammation are: interleukin-1 (IL-1), tumour necrosis factor (TNF)- α and β , interferon (IFN)- γ , and chemokines (IL-8, PF-4).

The actions of various cytokines as mediator of inflammation are as under:

i) IL-1 and TNF- α , TNF- β induce endothelial effects in the form of increased leucocyte adherence, thrombogenicity, elaboration of other cytokines, fibroblastic proliferation and acute phase reactions.

ii) IFN- γ causes activation of macrophages and neutrophils and is associated with synthesis of nitric acid synthase.

iii) Chemokines are a family of chemoattractants for inflammatory cells (as discussed above) and include:

- ◆ IL-8 chemotactic for neutrophils;
- ◆ platelet factor-4 chemotactic for neutrophils, monocytes and eosinophils;
- ◆ MCP-1 chemotactic for monocytes; and
- ◆ eotaxin chemotactic for eosinophils.

6. FREE RADICALS: OXYGEN METABOLITES AND NITRIC OXIDE. Free radicals act as potent mediator of inflammation:

i) Oxygen-derived metabolites are released from activated neutrophils and macrophages and include superoxide oxygen (O_2^-), H_2O_2 , OH^{\cdot} and toxic NO products. These oxygen-derived free radicals have the following action in inflammation:

- ◆ Endothelial cell damage and thereby increased vascular permeability.
- ◆ Activation of protease and inactivation of antiprotease causing tissue matrix damage.
- ◆ Damage to other cells.

ii) Nitric oxide (NO) was originally described as vascular relaxation factor produced by endothelial cells. Now it is known that NO is formed by activated macrophages during the oxidation of arginine by the action of enzyme, NO synthase. NO plays the following role in mediating inflammation:

- ◆ Vasodilatation
- ◆ Anti-platelet activating agent
- ◆ Possibly microbicidal action.

These include the various products derived from activation and interaction of 4 interlinked systems: kinin, clotting, fibrinolytic and complement. Each of these systems has its inhibitors and accelerators in plasma with negative and positive feedback mechanisms respectively.

The inter-relationship among 4 systems is summarised in **Web Image 6.10**.

1. THE KININ SYSTEM. This system on activation by factor XIIa generates bradykinin, so named because of the slow contraction of smooth muscle induced by it. First, kallikrein is formed from plasma prekallikrein by the action of prekallikrein activator which is a fragment of factor XIIa. Kallikrein then acts on high molecular weight kininogen to form bradykinin (**Web Image 6.11**).

Bradykinin acts in the early stage of inflammation and its effects include:

- ◆ smooth muscle contraction;
- ◆ vasodilatation;
- ◆ increased vascular permeability; and
- ◆ pain.

2. THE CLOTTING SYSTEM. Factor XIIa initiates the cascade of the clotting system resulting in formation of fibrinogen which is acted upon by thrombin to form fibrin and fibrinopeptides (**Web Image 6.12**).

The actions of fibrinopeptides in inflammation are:

- ◆ increased vascular permeability;
- ◆ chemotaxis for leucocyte; and
- ◆ anticoagulant activity.

3. THE FIBRINOLYTIC SYSTEM. This system is activated by plasminogen activator, the sources of which include kallikrein of the kinin system, endothelial cells and leucocytes. Plasminogen activator acts on plasminogen present as component of plasma proteins to form plasmin. Further breakdown of fibrin by plasmin forms fibrinopeptides or fibrin split products (**Web Image 6.13**).

The actions of plasmin in inflammation are as follows:

- ◆ activation of factor XII to form prekallikrein activator that stimulates the kinin system to generate bradykinin;
- ◆ splits off complement C₃ to form C_{3a} which is a permeability factor; and
- ◆ degrades fibrin to form fibrin split products which increase vascular permeability and are chemotactic to leucocytes.

4. THE COMPLEMENT SYSTEM. The activation of complement system can occur either:

- i) by *classic pathway* through antigen-antibody complexes; or
- ii) by *alternate pathway* via non-immunologic agents such as bacterial toxins, cobra venoms and IgA.

Complement system on activation by either of these two pathways yields activated products which include anaphylatoxins (C_{3a}, C_{4a} and C_{5a}), and membrane attack complex (MAC) i.e. C_{5b}, C₆, C₇, C₈, C₉.

The actions of activated complement system in inflammation are as under:

- ◆ C_{3a}, C_{5a}, C_{4a} (anaphylatoxins) activate mast cells and basophils to release of histamine, cause increased vascular permeability causing oedema in tissues, augments phagocytosis.
- ◆ C_{3b} is an opsonin.
- ◆ C_{5a} is chemotactic for leucocytes.
- ◆ Membrane attack complex (MAC) (C_{5b}-C₉) is a lipid dissolving agent and causes holes in the phospholipid membrane of the cell.

□ REGULATION OF INFLAMMATION (p. 140)

The onset of inflammatory responses outlined above may have potentially damaging influence on the host tissues as evident in hypersensitivity conditions. Such self-damaging effects are kept in check by the host mechanisms in order to resolve inflammation. These mechanisms are as follows:

i) Acute phase reactants. A variety of acute phase reactant (APR) proteins are released in plasma in response to tissue trauma and infection. Their major role is to protect the normal cells from harmful effects of toxic molecules generated in inflammation and to clear away the waste material. APRs include the following:

- i) *Certain cellular protection factors* (e.g. α_1 -antitrypsin, α_1 -chymotrypsin, α_2 -antiplasmin, plasminogen activator inhibitor).
- ii) *Some coagulation proteins* (e.g. fibrinogen, plasminogen, von Willebrand factor, factor VIII).
- iii) *Transport proteins* (e.g. ceruloplasmin, haptoglobin).
- iv) *Immune agents* (e.g. serum amyloid A and P component, C-reactive protein).
- v) *Stress proteins* (e.g. heat shock proteins—HSP, ubiquitin).
- vi) *Antioxidants* (e.g. ceruloplasmin).

The APR are synthesised mainly in the liver, and to some extent in macrophages. APR along with systemic features of fever and leucocytosis is termed '*acute phase response*'. Deficient synthesis of APR leads to severe form of disease in the form of chronic and repeated inflammatory responses.

ii) Glucosteroids. The endogenous glucocorticoids act as anti-inflammatory agents. Their levels are raised in infection and trauma by self-regulating mechanism.

iii) Free cytokine receptors. The presence of freely circulating soluble receptors for cytokines in the serum correlates directly with disease activity.

iv) Anti-inflammatory chemical mediators. As already described, PGE₂ or prostacyclin have both pro-inflammatory as well as anti-inflammatory actions.

□ THE INFLAMMATORY CELLS (p. 141)

The cells participating in acute and chronic inflammation are circulating leucocytes, plasma cells and tissue macrophages. Summary of their morphology, characteristics and functions is given in **Web Table 6.3**.

1. Polymorphonuclear Neutrophils (PMNs) (p. 141)

Commonly called as neutrophils or polymorphs, these cells along with basophils and eosinophils are known as granulocytes due to the presence of granules in the cytoplasm. These granules contain many substances like proteases, myeloperoxidase, lysozyme, esterase, aryl sulfatase, acid and alkaline phosphatase, and cationic proteins. These cells comprise 40-75% of circulating leucocytes and their number is increased in blood (neutrophilia) and tissues in acute bacterial infections.

The functions of neutrophils in inflammation are as follows:

i) Initial phagocytosis of microorganisms as they form the first line of body defense in bacterial infection. The steps involved are adhesion of neutrophils to vascular endothelium, emigration through the vessel wall, chemotaxis, engulfment, degranulation, killing and degradation of the foreign material.

ii) Engulfment of antigen-antibody complexes and non-microbial material.

iii) Harmful effect of neutrophils in causing basement membrane destruction of the glomeruli and small blood vessels.

102 2. Eosinophils (p. 141)

These are larger than neutrophils but are fewer in number, comprising 1 to 6% of total blood leucocytes. Eosinophils share many structural and functional similarities with neutrophils like presence of granules in the cytoplasm containing a variety of enzymes, of which major basic protein and eosinophil cationic protein are the most important which have bactericidal and toxic action against helminthic parasites. However, granules of eosinophils are richer in myeloperoxidase than neutrophils and lack lysozyme.

The absolute number of eosinophils is increased in the following conditions and, thus, they partake in inflammatory responses associated with these conditions:

- i) allergic conditions;
- ii) parasitic infestations;
- iii) skin diseases; and
- iv) certain malignant lymphomas.

3. Basophils (Mast Cells) (p. 141)

The basophils comprise about 1% of circulating leucocytes and are morphologically and pharmacologically similar to mast cells of tissue. These cells contain coarse basophilic granules in the cytoplasm and a polymorphonuclear nucleus. These granules are laden with heparin and histamine. Basophils and mast cells have receptors for IgE and degranulate when cross-linked with antigen.

The role of these cells in inflammation are:

- i) in immediate and delayed type of hypersensitivity reactions; and
- ii) release of histamine by IgE-sensitised basophils.

4. Lymphocytes (p. 142)

Next to neutrophils, these cells are the most numerous of the circulating leucocytes (20-45%). Apart from blood, lymphocytes are present in large numbers in spleen, thymus, lymph nodes and mucosa-associated lymphoid tissue (MALT). They have scanty cytoplasm and consist almost entirely of nucleus.

Their role in antibody formation (B lymphocytes) and in cell-mediated immunity (T lymphocytes) has been discussed in Chapter 4; in addition these cells participate in the following types of inflammatory responses:

- i) *In tissues*, they are dominant cells in chronic inflammation and late stage of acute inflammation.
- ii) *In blood*, their number is increased (lymphocytosis) in chronic infections like tuberculosis.

5. Plasma Cells (p. 142)

These cells are larger than lymphocytes with more abundant cytoplasm and an eccentric nucleus which has cart-wheel pattern of chromatin. Plasma cells are normally not seen in peripheral blood. They develop from B lymphocytes and are rich in RNA and γ -globulin in their cytoplasm. These cells are most active in antibody synthesis.

Their number is increased in the following conditions:

- i) prolonged infection with immunological responses e.g. in syphilis, rheumatoid arthritis, tuberculosis;
- ii) hypersensitivity states; and
- iii) multiple myeloma.

6. Mononuclear-Phagocyte System (Reticuloendothelial System) (p. 143)

This cell system includes cells derived from 2 sources with common morphology, function and origin. These are as under:

Blood monocytes. These comprise 4-8% of circulating leucocytes.

Tissue macrophages. These include the following cells in different tissues:

- i) Macrophages in inflammation.
- ii) Histiocytes which are macrophages present in connective tissues.
- iii) Kupffer cells are macrophages of liver cells.
- iv) Alveolar macrophages (type II pneumocytes) in lungs.
- v) Macrophages/histiocytes of the bone marrow.
- vi) Tingible body cells of germinal centres of lymph nodes.
- vii) Littoral cells of splenic sinusoids.
- viii) Osteoclasts in the bones.
- ix) Microglial cells of the brain.
- x) Langerhans' cells/dendritic histiocytes of the skin.
- xi) Hoffbauer cells of the placenta.
- xii) Mesangial cells of glomerulus.

The mononuclear phagocytes are the scavenger cells of the body as well as participate in immune system of the body (Chapter 4); their functions in inflammation are as under:

Role of macrophages in inflammation. The functions of mononuclear-phagocyte cells are as under:

- i) *Phagocytosis* (cell eating) and *pinocytosis* (cell drinking).
- ii) *Macrophages on activation* by lymphokines released by T lymphocytes or by non-immunologic stimuli elaborate a variety of biologically active substances as under:
 - a) Proteases like collagenase and elastase which degrade collagen and elastic tissue.
 - b) Plasminogen activator which activates the fibrinolytic system.
 - c) Products of complement.
 - d) Some coagulation factors (factor V and thromboplastin) which convert fibrinogen to fibrin.
 - e) Chemotactic agents for other leucocytes.
 - f) Metabolites of arachidonic acid.
 - g) Growth promoting factors for fibroblasts, blood vessels and granulocytes.
 - h) Cytokines like interleukin-1 and TNF- α .
 - i) Oxygen-derived free radicals.

7. Giant Cells (p. 143)

A few examples of multinucleate giant cells exist in normal tissues (e.g. osteoclasts in the bones, trophoblasts in placenta, megakaryocytes in the bone marrow). However, in chronic inflammation when the macrophages fail to deal with particles to be removed, they fuse together and form multinucleated giant cells. Besides, morphologically distinct giant cells appear in some tumours also. Some of the common types of giant cells are described below (**Web Image 6.14**):

A. Giant cells in inflammation:

- i) *Foreign body giant cells.* These contain numerous nuclei (up to 100) which are uniform in size and shape and resemble the nuclei of macrophages. These nuclei are scattered throughout the cytoplasm. These are seen in chronic infective granulomas, leprosy and tuberculosis.
- ii) *Langerhans' giant cells.* These are seen in tuberculosis and sarcoidosis. Their nuclei are like the nuclei of macrophages and epithelioid cells. These nuclei are arranged either around the periphery in the form of horseshoe or ring, or are clustered at the two poles of the giant cell.
- iii) *Touton giant cells.* These multinucleated cells have vacuolated cytoplasm due to lipid content e.g. in xanthoma.
- iv) *Aschoff giant cells.* These multinucleate giant cells are derived from cardiac histiocytes and are seen in rheumatic nodule.

B. Giant cells in tumours:

- i) *Anaplastic cancer giant cells.* These are larger, have numerous nuclei which are hyperchromatic and vary in size and shape. These giant cells are not derived from macrophages but are formed from dividing nuclei of the neoplastic cells e.g. carcinoma of the liver, various soft tissue sarcomas etc.
- ii) *Reed-Sternberg cells.* These are also malignant tumour giant cells which are generally binucleate and are seen in various histologic types of Hodgkin's lymphomas.
- iii) *Giant cell tumour of bone.* This tumour of the bones has uniform distribution of osteoclastic giant cells spread in the stroma.

□ **FACTORS DETERMINING VARIATION IN INFLAMMATORY RESPONSE** (p. 144)

Although acute inflammation is typically characterised by vascular and cellular events with emigration of neutrophilic leucocytes, not all examples of acute inflammation show infiltration by neutrophils. On the other hand, some chronic inflammatory conditions are characterised by neutrophilic infiltration. For example, *typhoid fever* is an example of acute inflammatory process but the cellular response in it is lymphocytic; *osteomyelitis* is an example of chronic inflammation but the cellular response in this condition is mainly neutrophilic.

The variation in inflammatory response depends upon a number of factors and processes. These are discussed below:

1. Factors Involving the Organisms (p. 144)

- i) Type of injury and infection.
- ii) Virulence.
- iii) Dose.
- iv) Portal of entry.
- v) Product of organisms.

2. Factors Involving the Host (p. 144)

- i) Systemic diseases.
- ii) Immune status of host.
- iii) Congenital neutrophil defects.
- iv) Leukopenia.
- v) Site or type of tissue involved.
- vi) Local host factors.

3. Type of Exudation (p. 144)

The appearance of escaped plasma determines the morphologic type of inflammation as under:

- i) **Serous**, when the fluid exudate resembles serum or is watery e.g. pleural effusion in tuberculosis, blister formation in burns.
- ii) **Fibrinous**, when the fibrin content of the fluid exudate is high e.g. in pneumococcal and rheumatic pericarditis.
- iii) **Purulent or suppurative exudate** is formation of creamy pus as seen in infection with pyogenic bacteria e.g. abscess, acute appendicitis.
- iv) **Haemorrhagic**, when there is vascular damage e.g. acute haemorrhagic pneumonia in influenza.
- v) **Catarrhal**, when the surface inflammation of epithelium produces increased secretion of mucous e.g. common cold.

□ **MORPHOLOGY OF ACUTE INFLAMMATION** (p. 144)

Inflammation of an organ is usually named by adding the suffix-*itis* to its Latin name e.g. appendicitis, hepatitis, cholecystitis, meningitis etc. A few morphologic varieties of acute inflammation are described below:

1. PSEUDOMEMBRANOUS INFLAMMATION. It is inflammatory response of mucous surface (oral, respiratory, bowel) to toxins of diphtheria or irritant gases. As a result of denudation of epithelium, plasma exudes on the surface where it coagulates, and together with necrosed epithelium, forms false membrane that gives this type of inflammation its name.

2. ULCER. Ulcers are local defects on the surface of an organ produced by inflammation. Common sites for ulcerations are the stomach, duodenum, intestinal ulcers in typhoid fever, intestinal tuberculosis, bacillary and amoebic dysentery, ulcers of legs due to varicose veins etc. In the acute stage, there is infiltration by polymorphs with vasodilatation while long-standing ulcers develop infiltration by lymphocytes, plasma cells and macrophages with associated fibroblastic proliferation and scarring.

3. SUPPURATION (ABSCESS FORMATION). When acute bacterial infection is accompanied by intense neutrophilic infiltrate in the inflamed tissue, it results in tissue necrosis. A cavity is formed which is called an abscess and contains purulent exudate or pus and the process of abscess formation is known as suppuration. The bacteria which cause suppuration are called pyogenic.

M/E Pus is creamy or opaque in appearance and is composed of numerous dead as well as living neutrophils, some red cells, fragments of tissue debris and fibrin. In old pus, macrophages and cholesterol crystals are also present (**Web Image 6.15**).

Some of the common examples of abscess formation are as under:

- i) *Boil or furuncle* which is an acute inflammation via hair follicles in the dermal tissues.
- ii) *Carbuncle* is seen in untreated diabetics and occurs as a loculated abscess in the dermis and soft tissues of the neck.

4. CELLULITIS. It is a diffuse inflammation of soft tissues resulting from spreading effects of substances like hyaluronidase released by some bacteria.

5. BACTERIAL INFECTION OF THE BLOOD. This includes the following 3 conditions:

i) **Bacteraemia** is defined as presence of small number of bacteria in the blood which do not multiply significantly. They are commonly not detected by direct microscopy. Blood culture is done for their detection e.g. infection with *Salmonella typhi*, *Escherichia coli*, *Streptococcus viridans*.

ii) **Septicaemia** means presence of rapidly multiplying, highly pathogenic bacteria in the blood e.g. pyogenic cocci, bacilli of plague etc. Septicaemia is generally accompanied by systemic effects like toxæmia, multiple small haemorrhages, neutrophilic leucocytosis and disseminated intravascular coagulation (DIC).

iii) **Pyæmia** is the dissemination of small septic thrombi in the blood which cause their effects at the site where they are lodged. This can result in pyæmic abscesses or septic infarcts.

- a) *Pyæmic abscesses* are multiple small abscesses in various organs such as in cerebral cortex, myocardium, lungs and renal cortex, resulting from very small emboli fragmented from septic thrombus. Microscopy of pyæmic abscess shows a central zone of necrosis containing numerous bacteria, surrounded by a zone of suppuration and an outer zone of acute inflammatory cells (**Web Image 6.16,A**).
- b) *Septic infarcts* result from lodgement of larger fragments of septic thrombi in the arteries with relatively larger foci of necrosis, suppuration and acute inflammation e.g. septic infarcts of the lungs, liver, brain, and kidneys from septic thrombi of leg veins or from acute bacterial endocarditis (**Web Image 6.16,B**).

Acute inflammation is associated with systemic effects as well.

1. Fever occurs due to bacteraemia. It is thought to be mediated through release of factors like prostaglandins, interleukin-1 and TNF- α in response to infection.

2. Leucocytosis commonly accompanies the acute inflammatory reactions, usually in the range of 15,000-20,000/ μ l. When the counts are higher than this with 'shift to left' of myeloid cells, the blood picture is described as leukaemoid reaction. Usually, in bacterial infections there is neutrophilia; in viral infections lymphocytosis; and in parasitic infestations, eosinophilia. Typhoid fever, an example of acute inflammation, however, induces leucopenia with relative lymphocytosis.

3. Lymphangitis-lymphadenitis is one of the important manifestations of localised inflammatory injury. The lymphatics and lymph nodes that drain the inflamed tissue show reactive inflammatory changes in the form of lymphangitis and lymphadenitis. The affected lymph nodes may show hyperplasia of lymphoid follicles (follicular hyperplasia) and proliferation of mononuclear phagocytic cells in the sinuses of lymph node (sinus histiocytosis).

4. Shock may occur in severe cases. Massive release of cytokine TNF- α , a mediator of inflammation, in response to severe tissue injury or infection results in profuse systemic vasodilatation, increased vascular permeability and intravascular volume loss. The net effect of these changes is hypotension and shock. Systemic activation of coagulation pathway may occur leading to microthrombi throughout the body and result in disseminated intravascular coagulation (DIC), bleeding and death.

□ **FATE OF ACUTE INFLAMMATION** (p. 146)

The acute inflammatory process can culminate in one of the following outcomes (**Web Image 6.17**):

1. Resolution. It means complete return to normal tissue following acute inflammation. This occurs when tissue changes are slight and the cellular changes are reversible e.g. resolution in lobar pneumonia.

2. Healing. Healing by fibrosis takes place when the tissue destruction in acute inflammation is extensive so that there is no tissue regeneration. But when tissue loss is superficial, it is restored by regeneration.

3. Suppuration. When the pyogenic bacteria causing acute inflammation result in severe tissue necrosis, the process progresses to suppuration. Initially, there is intense neutrophilic infiltration. Subsequently, mixture of neutrophils, bacteria, fragments of necrotic tissue, cell debris and fibrin comprise pus which is contained in a cavity to form an abscess. The abscess, if not drained, may get organised by dense fibrous tissue, and in time, get calcified.

4. Chronic inflammation. Persisting or recurrent acute inflammation may progress to chronic inflammation in which the processes of inflammation and healing proceed side by side.

CHRONIC INFLAMMATION (p. 147)

DEFINITION AND CAUSES. Chronic inflammation is defined as prolonged process in which tissue destruction and inflammation occur at the same time.

Chronic inflammation can be caused by one of the following 3 ways:

1. Chronic inflammation following acute inflammation. When the tissue destruction is extensive, or the bacteria survive and persist in small numbers

at the site of acute inflammation e.g. in osteomyelitis, pneumonia terminating in lung abscess.

2. Recurrent attacks of acute inflammation. When repeated bouts of acute inflammation culminate in chronicity of the process e.g. in recurrent urinary tract infection leading to chronic pyelonephritis, repeated acute infection of gallbladder leading to chronic cholecystitis.

3. Chronic inflammation starting *de novo*. When the infection with organisms of low pathogenicity is chronic from the beginning e.g. infection with *Mycobacterium tuberculosis*.

□ GENERAL FEATURES OF CHRONIC INFLAMMATION (p. 147)

Following general features characterise any chronic inflammation:

1. MONONUCLEAR CELL INFILTRATION. Chronic inflammatory lesions are infiltrated by mononuclear inflammatory cells like phagocytes and lymphoid cells. Phagocytes are represented by circulating monocytes, tissue macrophages, epithelioid cells and sometimes, multinucleated giant cells. The macrophages comprise the most important cells in chronic inflammation.

The blood monocytes on reaching the extravascular space transform into tissue macrophages. Besides the role of macrophages in phagocytosis, they may get activated in response to stimuli such as cytokines (lymphokines) and bacterial endotoxins. On activation, macrophages release several biologically active substances e.g. acid and neutral proteases, oxygen-derived reactive metabolites and cytokines. These products bring about tissue destruction, neovascularisation and fibrosis.

Other chronic inflammatory cells include lymphocytes, plasma cells, eosinophils and mast cells. In chronic inflammation, lymphocytes and macrophages influence each other and release mediators of inflammation.

2. TISSUE DESTRUCTION OR NECROSIS. Tissue destruction and necrosis are central features of most forms of chronic inflammatory lesions. This is brought about by activated macrophages which release a variety of biologically active substances e.g. protease, elastase, collagenase, lipase, reactive oxygen radicals, cytokines (IL-1, IL-8, TNF- α), nitric oxide, angiogenesis growth factor etc.

3. PROLIFERATIVE CHANGES. As a result of necrosis, proliferation of small blood vessels and fibroblasts is stimulated resulting in formation of inflammatory granulation tissue. Eventually, healing by fibrosis and collagen laying takes place.

□ SYSTEMIC EFFECTS OF CHRONIC INFLAMMATION (p. 147)

Chronic inflammation is associated with following systemic features:

1. Fever. Invariably there is mild fever, often with loss of weight and weakness.

2. Anaemia. Chronic inflammation is accompanied by anaemia of varying degree.

3. Leucocytosis. As in acute inflammation, chronic inflammation also has leucocytosis but generally there is relative lymphocytosis in these cases.

4. ESR. ESR is elevated in all cases of chronic inflammation.

5. Amyloidosis. Long-term cases of chronic suppurative inflammation may develop secondary systemic (AA) amyloidosis.

□ TYPES OF CHRONIC INFLAMMATION (p. 147)

Conventionally, chronic inflammation is subdivided into 2 types:

1. Chronic non-specific inflammation. It is characterised by non-specific inflammatory cell infiltration e.g. chronic osteomyelitis, lung abscess. A

variant of this type of chronic inflammatory response is chronic suppurative inflammation in which infiltration by polymorphs and abscess formation are additional features e.g. actinomycosis.

2. Chronic granulomatous inflammation. It is characterised by formation of granulomas e.g. tuberculosis, leprosy, syphilis, actinomycosis, sarcoidosis etc.

□ **GRANULOMATOUS INFLAMMATION** (p. 148)

Granuloma is defined as a circumscribed, tiny lesion, about 1 mm in diameter, composed predominantly of collection of modified macrophages called epithelioid cells, and rimmed at the periphery by lymphoid cells.

PATHOGENESIS OF GRANULOMA. Formation of granuloma is a type IV granulomatous hypersensitivity reaction. It is a protective defense reaction by the host but eventually causes tissue destruction because of persistence of the poorly digestible antigen e.g. *Mycobacterium tuberculosis*, *M. leprae*, suture material, particles of talc etc.

The sequence in evolution of granuloma is schematically shown in **Web Image 6.18** and is briefly outlined below:

1. Engulfment by macrophages. Macrophages and monocytes engulf the antigen and try to destroy it. But since the antigen is poorly degradable, these cells fail to digest and degrade the antigen, and instead undergo morphologic changes to epithelioid cells.

2. CD4+ T cells. Macrophages, being antigen-presenting cells, having failed to deal with the antigen, present it to CD4+ T lymphocytes. These lymphocytes get activated and elaborate lymphokines (IL-1, IL-2, interferon- γ , TNF- α).

3. Cytokines. Various cytokines formed by activated CD4+ T cells and also by activated macrophages perform the following roles:

i) *IL-1 and IL-2* stimulate proliferation of more T cells.

ii) *Interferon- γ* activates macrophages.

iii) *TNF- α* promotes fibroblast proliferation and activates endothelium to secrete prostaglandins which have role in vascular response in inflammation.

iv) *Growth factors* (transforming growth factor- β , platelet-derived growth factor) elaborated by activated macrophages stimulate fibroblast growth.

Thus, a granuloma is formed of macrophages modified as epithelioid cells in the centre, with some interspersed multinucleate giant cells, surrounded peripherally by lymphocytes (mainly T cells), and healing by fibroblasts or collagen depending upon the age of granuloma.

COMPOSITION OF GRANULOMA. In general, a granuloma has the following structural composition:

1. Epithelioid cells. These are so called because of their epithelial cell-like appearance, are modified macrophages/histiocytes which are somewhat elongated, having vesicular and lightly-staining slipper-shaped nucleus, and pale-staining abundant cytoplasm with hazy outlines so that the cell membrane of adjacent epithelioid cells is closely apposed. Epithelioid cells are weakly phagocytic.

2. Multinucleate giant cells. Multinucleate giant cells are formed by fusion of adjacent epithelioid cells and may have 20 or more nuclei. These nuclei may be arranged at the periphery like horseshoe or ring, or are clustered at the two poles (Langhans' giant cells), or they may be present centrally (foreign body giant cells). The former are commonly seen in tuberculosis while the latter are common in foreign body tissue reactions.

3. Lymphoid cells. As a cell mediated immune reaction to antigen, the host response by lymphocytes is integral to composition of a granuloma. Plasma cells indicative of accelerated humoral immune response are present in some types of granulomas.

4. Necrosis. Necrosis may be a feature of some granulomatous conditions e.g. central caseation necrosis of tuberculosis, so called because of cheese-like appearance and consistency of necrosis.

5. Fibrosis. Fibrosis is a feature of healing by proliferating fibroblasts at the periphery of granuloma.

The classical example of granulomatous inflammation is the tissue response to tubercle bacilli which is called *tubercle* seen in tuberculosis (described below). A fully-developed tubercle is about 1 mm in diameter with central area of caseation necrosis, surrounded by epithelioid cells and one to several multinucleated giant cells (commonly Langhans' type), surrounded at the periphery by lymphocytes and bounded by fibroblasts and fibrous tissue (**Web Image 6.19**).

EXAMPLES OF GRANULOMATOUS INFLAMMATION (p. 149)

A comprehensive list of important examples of granulomatous conditions, their etiologic agents and salient features is given in **Web Table 6.4**.

□ TUBERCULOSIS (p. 149)

Tissue response in tuberculosis represents classical example of chronic granulomatous inflammation in humans.

CAUSATIVE ORGANISM. Tubercle bacillus or Koch's bacillus (named after discovery of the organism by Robert Koch in 1882) called *Mycobacterium tuberculosis* causes tuberculosis in the lungs and other tissues of the human body. *The organism is a strict aerobe and thrives best in tissues with high oxygen tension such as in the apex of the lung.*

Out of various pathogenic strains for human disease included in *Mycobacterium tuberculosis* complex, currently most common is *M. tuberculosis hominis* (human strain), while *M. tuberculosis bovis* (bovine strain) used to be common pathogen to human beings during the era of consumption of unpasteurised milk but presently constitutes a small number of human cases. A non-pathogenic strain, *M. smegmatis*, is found in the smegma and as contaminant in the urine of both men and women.

M. tuberculosis hominis is a slender rod-like bacillus, 0.5 μm by 3 μm , is neutral on Gram staining, and can be demonstrated by the following methods:

1. *Acid fast (Ziehl-Neelsen) staining.* The acid fastness of the tubercle bacilli is due to mycolic acids, cross-linked fatty acids and other lipids in the cell wall of the organism making it impermeable to the usual stains. It takes up stain by heated carbol fuchsin and resists decolourisation by acids and alcohols (acid fast and alcohol fast) and can be decolourised by 20% sulphuric acid (compared to 5% sulphuric acid for decolourisation for *M. leprae* which are less acid fast) (**Web Image 6.20**).
2. *Fluorescent dye methods.*
3. *Culture* of the organism from sputum in Lowenstein-Jensen (L.J.) medium for 6 weeks.
4. *Guinea pig inoculation* method by subcutaneous injection of the organisms.
5. *Molecular methods* such as PCR are the most recent methods.

ATYPICAL MYCOBACTERIA (NON-TUBERCULOUS MYCOBACTERIA).

The term atypical mycobacteria or non-tuberculous mycobacteria is used for mycobacterial species other than *M. tuberculosis* complex and *M. leprae*. Non-tuberculous mycobacteria are widely distributed in the environment and are, therefore, also called as *environmental mycobacteria*. They too are acid fast. Occasionally, human tuberculosis may be caused by atypical mycobacteria which are non-pathogenic to guinea pigs and resistant to usual anti-tubercular drugs.

Conventionally, atypical mycobacteria are classified on the basis of colour of colony produced in culture and the speed of growth in media:

110 i) Rapid growers

ii) **Slow growers.** Based on the colour of colony formed, they are further divided into following:

Photochromogens, Scotochromogens, Non-chromogens.

The examples of slow growers are *M. avium-intracellulare*, *M. kansasii*, *M. ulcerans* and *M. fortuitum*.

Bacteraemias by *M. avium-intracellulare* as seen in immunosuppressed patients of AIDS.

INCIDENCE. In spite of great advances in chemotherapy and immunology, tuberculosis still continues to be worldwide in distribution, more common in developing countries of Africa, Latin America and Asia. Other factors contributing to higher incidence of tuberculosis are malnutrition, inadequate medical care, poverty, crowding, chronic debilitating conditions like uncontrolled diabetes, alcoholism and immunocompromised states like AIDS.

HIV-infected individuals have very high incidence of tuberculosis all over the world. Vice-versa, rate of HIV infection in patients of tuberculosis is very high. Moreover, HIV-infected individual on acquiring infection with tubercle bacilli develops active disease rapidly (within few weeks) rather than after months or years. Infection with *M. avium-intracellulare* (avian or bird strain) is common in patients with HIV/AIDS.

MODE OF TRANSMISSION. Human beings acquire infection with tubercle bacilli by one of the following routes:

1. *Inhalation.*
2. *Ingestion.*
3. *Inoculation.*
4. *Transplacental route.*

SPREAD OF TUBERCULOSIS. The disease spreads in the body by various routes:

1. **Local spread.** This takes place by macrophages carrying the bacilli into the surrounding tissues.
2. **Lymphatic spread.** Tuberculosis is primarily an infection of lymphoid tissues. The bacilli may pass into lymphoid follicles of pharynx, bronchi, intestines or regional lymph nodes resulting in regional tuberculous lymphadenitis which is typical of childhood infections.
3. **Haematogenous spread.** This occurs either as a result of tuberculous bacillaemia because of the drainage of lymphatics into the venous system or due to caseous material escaping through ulcerated wall of a vein. This produces millet seed-sized lesions in different organs of the body like lungs, liver, kidneys, bones and other tissues and is known as miliary tuberculosis.
4. **By the natural passages.** Infection may spread from:
 - i) lung lesions into pleura (tuberculous pleurisy);
 - ii) transbronchial spread into the adjacent lung segments;
 - iii) tuberculous salpingitis into peritoneal cavity (tuberculous peritonitis);
 - iv) infected sputum into larynx (tuberculous laryngitis);
 - v) swallowing of infected sputum (ileocaecal tuberculosis); and
 - vi) renal lesions into ureter and down to trigone of bladder.

HYPERSENSITIVITY AND IMMUNITY IN TUBERCULOSIS. Hypersensitivity or allergy, and immunity or resistance, play a major role in the development of lesions in tuberculosis. Tubercle bacilli as such do not produce any toxins. Tissue changes seen in tuberculosis are not the result of any exotoxin or endotoxin but are instead the result of host response to the organism which is in the form of development of cell-mediated hypersensitivity (or type IV hypersensitivity) and immunity. Both these host responses develop as a consequence of several lipids present in the microorganism which include the following:

1. **mycosides** such as 'cord factor'.
2. **glycolipids** present in the mycobacterial cell wall like 'Wax-D'.

It has been known since the time of Robert Koch that the tissue reaction to tubercle bacilli is different in healthy animal not previously infected (primary infection) from an animal who is previously infected (secondary infection).

1. In the primary infection, intradermal injection of tubercle bacilli into the skin of a healthy guinea pig evokes no visible reaction for 10-14 days. After this period, a nodule develops at the inoculation site which subsequently ulcerates and heals poorly as the guinea pig, unlike human beings, does not possess any natural resistance. The regional lymph nodes also develop tubercles. This process is a manifestation of delayed type of hypersensitivity (type IV reaction) and is comparable to primary tuberculosis in children although healing invariably occurs in children.

2. In the secondary infection, the sequence of changes is different. The tubercle bacilli are injected into the skin of the guinea pig who has been infected with tuberculosis 4-6 weeks earlier. In 1-2 days, the site of inoculation is indurated and dark, attaining a diameter of about 1 cm. The skin lesion ulcerates which heals quickly and the regional lymph nodes are not affected. This is called *Koch's phenomenon* and is indicative of hypersensitivity and immunity in the host.

Tuberculin (Mantoux) skin test. This test is done by intradermal injection of 0.1 ml of tuberculoprotein, purified protein derivative (PPD). Delayed type of hypersensitivity develops in individuals who are having or have been previously infected with tuberculous infection which is identified as an indurated area of more than 15 mm in 72 hours. However, patients having disseminated tuberculosis may show negative test due to release of large amount of tuberculoproteins from the endogenous lesions masking the hypersensitivity test. A positive test is indicative of cell-mediated hypersensitivity to tubercular antigens but does not distinguish between infection and disease. The test may be false positive in atypical mycobacterial infection and false negative in sarcoidosis, some viral infections, Hodgkin's disease and fulminant tuberculosis.

Immunisation against tuberculosis. Protective immunisation against tuberculosis is induced by injection of attenuated strains of bovine type of tubercle bacilli, *Bacille Calmette-Guérin* (BCG). Cell-mediated immunity with consequent delayed hypersensitivity reaction develops with healing of the lesion, but the cell-mediated immunity persists, rendering the host tuberculin-positive and hence immune.

EVOLUTION OF TUBERCLE. The sequence of events which take place when tubercle bacilli are introduced into the tissue are as under (**Web Image 6.21**):

1. When the tubercle bacilli are injected intravenously into the guinea pig, the bacilli are lodged in pulmonary capillaries where an *initial response of neutrophils* is evoked which are rapidly destroyed by the organisms.
2. After about 12 hours, there is *progressive infiltration by macrophages*. This is due to coating of tubercle bacilli with serum complement factors C2a and C3b which act as opsonins and attract the macrophages. Macrophages dominate the picture throughout the remaining life of the lesions. If the tubercle bacilli are, however, inhaled into the lung alveoli, macrophages predominate the picture from the beginning.
3. The macrophages start *phagocytosing* the tubercle bacilli and either kill the bacteria or die away themselves. In the latter case, they further proliferate locally as well as there is increased recruitment of macrophages from blood monocytes.
4. As a part of body's immune response, T and B cells are activated. Activated CD4+T cells develop the cell-mediated *delayed type hypersensitivity reaction*, while B cells result in formation of antibodies which play no role in body's defence against tubercle bacilli.

5. In 2-3 days, the macrophages undergo structural changes as a result of immune mechanisms—the cytoplasm becomes pale and eosinophilic and their nuclei become elongated and vesicular. These modified macrophages resemble epithelial cells and are called *epithelioid cells*.
6. The epithelioid cells in time aggregate into tight clusters or *granulomas*. Release of cytokines in response to sensitised CD4+T cells and some constituents of mycobacterial cell wall play a role in formation of granuloma.
7. Some of the macrophages form *multinucleated giant cells* by fusion of adjacent cells. The giant cells may be Langhans' type having peripherally arranged nuclei in the form of horseshoe or ring, or clustered at the two poles of the giant cell; or they may be foreign body type having centrally-placed nuclei.
8. Around the mass of epithelioid cells and giant cells is a zone of lymphocytes, plasma cells and fibroblasts. The lesion at this stage is called *hard tubercle* due to absence of central necrosis.
9. Within 10-14 days, the centre of the cellular mass begins to undergo caseation necrosis, characterised by cheesy appearance and high lipid content. This stage is called *soft tubercle* which is the hallmark of tuberculous lesions. The development of caseation necrosis is possibly due to interaction of mycobacteria with activated T cells (CD4+ helper T cells via IFN- γ and CD8+ suppressor T cells directly) as well as by direct toxicity of mycobacteria on macrophages.
10. The soft tubercle which is a fully-developed granuloma with caseous centre does not favour rapid proliferation of tubercle bacilli. *Acid-fast bacilli* are difficult to find in these lesions and may be demonstrated at the margins of recent necrotic foci and in the walls of the cavities.

The **fate of a granuloma** is variable:

- i) The caseous material may undergo liquefaction and extend into surrounding soft tissues, discharging the contents on the surface. This is called *cold abscess* although there are no pus cells in it.
- ii) In tuberculosis of tissues like bones, joints, lymph nodes and epididymis, sinuses are formed and the *sinus tracts* are lined by tuberculous granulation tissue.
- iii) The adjacent granulomas may *coalesce* together enlarging the lesion which is surrounded by progressive fibrosis.
- iv) In the granuloma enclosed by fibrous tissue, calcium salts may get deposited in the caseous material (*dystrophic calcification*) and sometimes the lesion may even get ossified over the years.

TYPES OF TUBERCULOSIS (p. 152)

Lung is the main organ affected in tuberculosis. Depending upon the type of tissue response and age, the infection with tubercle bacilli is of 2 main types:

- A. Primary tuberculosis; and
- B. Secondary tuberculosis.

A. Primary Tuberculosis (p. 153)

The infection of an individual who has not been previously infected or immunised is called *primary tuberculosis* or *Ghon's complex* or *childhood tuberculosis*.

Primary complex or Ghon's complex is the lesion produced in the tissue of portal of entry with foci in the draining lymphatic vessels and lymph nodes. The most commonly involved tissues for primary complex are lungs and hilar lymph nodes.

Primary complex or Ghon's complex in lungs consists of 3 components (**Web Image 6.22**):

1. **Pulmonary component.** Lesion in the lung is the primary focus or Ghon's focus. It is 1-2 cm solitary area of tuberculous pneumonia located

peripherally under a patch of pleurisy, in any part of the lung but more often in subpleural focus in the upper part of lower lobe.

M/E The lung lesion consists of tuberculous granulomas with caseation necrosis.

2. Lymphatic vessel component. The lymphatics draining the lung lesion contain phagocytes containing bacilli and may develop beaded, miliary tubercles along the path of hilar lymph nodes.

3. Lymph node component. This consists of enlarged hilar and tracheo-bronchial lymph nodes in the area drained. The affected lymph nodes are matted and show caseation necrosis (**Web Image 6.23, A**).

M/E The lesions are characterised by extensive caseation, tuberculous granulomas and fibrosis. Nodal lesions are potential source of re-infection later (**Web Image 6.23, B**).

In the case of primary tuberculosis of the alimentary tract due to ingestion of tubercle bacilli, a small primary focus is seen in the intestine with enlarged mesenteric lymph nodes producing *tabes mesenterica*. The enlarged and caseous mesenteric lymph nodes may rupture into peritoneal cavity and cause tuberculous peritonitis.

FATE OF PRIMARY TUBERCULOSIS. Primary complex may have one of the following sequelae (**Web Image 6.24**):

1. The lesions of primary tuberculosis of lung commonly do not progress but instead heal by *fibrosis*, and in time undergo *calcification* and even *ossification*.
2. In some cases, the primary focus in the lung continues to grow and the caseous material is disseminated through bronchi to the other parts of the same lung or the opposite lung. This is called *progressive primary tuberculosis*.
3. At times, bacilli may enter the circulation through erosion in a blood vessel and spread to various tissues and organs. This is called *primary miliary tuberculosis* and the lesions are seen in organs like the liver, spleen, kidney, brain and bone marrow.
4. In certain circumstances like in lowered resistance and increased hypersensitivity of the host, the healed lesions of primary tuberculosis may get reactivated. The bacilli lying dormant in acellular caseous material are activated and cause *progressive secondary tuberculosis*. It affects children more commonly but adults may also develop this kind of progression.

B. Secondary Tuberculosis (p. 155)

The infection of an individual who has been previously infected or sensitised is called *secondary*, or *post-primary* or *reinfection*, or *chronic tuberculosis*.

The infection may be acquired from (**Web Image 6.25**):

● *endogenous source* such as reactivation of dormant primary complex; or

exogenous source such as fresh dose of reinfection by the tubercle bacilli.

Secondary tuberculosis occurs most commonly in lungs in the region of apex. Other sites and tissues which can be involved are tonsils, pharynx, larynx, small intestine and skin.

Secondary Pulmonary Tuberculosis (p. 155)

The lesions in secondary pulmonary tuberculosis usually begin as 1-2 cm apical area of consolidation of the lung, which may in time develop a small area of central caseation necrosis and peripheral fibrosis. It occurs by haematogenous spread of infection from primary complex to the apex of the affected lung where the oxygen tension is high and favourable for growth of aerobic tubercle bacilli. *Microscopically*, the appearance is typical of tuberculous granulomas with caseation necrosis.

Patients with HIV infection previously exposed to tuberculous infection have particularly high incidence of reactivation of primary tuberculosis and the pattern of lesions in such cases is similar to that of primary tuberculosis i.e. with involvement of hilar lymph nodes rather than cavitory and apical lesions in the lung. In addition, infection with *M. avium-intracellulare* occurs more frequently in cases of AIDS.

FATE OF SECONDARY PULMONARY TUBERCULOSIS. The subapical lesions in lungs can have the following courses:

1. The lesions may *heal* with fibrous scarring and calcification.
2. The lesions may *coalesce* together to form larger area of tuberculous pneumonia and produce progressive secondary pulmonary tuberculosis with the following pulmonary and extrapulmonary involvements:

- i) Fibrocaceous tuberculosis
- ii) Tuberculous caseous pneumonia
- iii) Miliary tuberculosis.

I. FIBROCACEOUS TUBERCULOSIS. The original area of tuberculous pneumonia undergoes massive central caseation necrosis which may:

- ◆ either break into a bronchus from a cavity (*cavitory or open fibrocaceous tuberculosis*); or
- ◆ remain, as a soft caseous lesion without drainage into a bronchus or bronchiole to produce a non-cavitory lesion (*chronic fibrocaceous tuberculosis*).

The cavity provides favourable environment for proliferation of tubercle bacilli due to high oxygen tension. The cavity may communicate with bronchial tree and becomes the source of spread of infection (*'open tuberculosis'*). Ingestion of sputum containing tubercle bacilli from endogenous pulmonary lesions may produce *laryngeal and intestinal tuberculosis*.

G/A Tuberculous cavity is spherical with thick fibrous wall, lined by yellowish, caseous, necrotic material and the lumen is traversed by thrombosed blood vessels. Around the wall of cavity are seen foci of consolidation. The overlying pleura may also be thickened (**Web Image 6.26**).

M/E The wall of cavity shows eosinophilic, granular, caseous material which may show foci of dystrophic calcification. Widespread coalesced tuberculous granulomas composed of epithelioid cells, Langhans' giant cells and peripheral mantle of lymphocytes and having central caseation necrosis are seen. The outer wall of cavity shows fibrosis (**Web Image 6.27**).

Complications of cavitory secondary tuberculosis are as follows:

- a) Aneurysms of patent arteries crossing the cavity producing haemoptysis.
- b) Extension to pleura producing bronchopleural fistula.
- c) Tuberculous empyema from deposition of caseous material on the pleural surface.
- d) Thickened pleura from adhesions of parietal pleura.

II. TUBERCULOUS CASEOUS PNEUMONIA. The caseous material from a case of secondary tuberculosis in an individual with high degree of hypersensitivity may spread to rest of the lung producing caseous pneumonia (**Web Image 6.28, A**).

M/E The lesions show exudative reaction with oedema, fibrin, polymorphs and monocytes but numerous tubercle bacilli can be demonstrated in the exudates (**Web Image 6.28, B**).

III. MILIARY TUBERCULOSIS. This is lymphohaematogenous spread of tuberculous infection from primary focus or later stages of tuberculosis. The spread may occur to systemic organs or isolated organ. The spread is either by entry of infection into pulmonary vein producing disseminated or isolated organ lesion in different extra-pulmonary sites (e.g. liver, spleen, kidney,

brain and bone marrow) or into pulmonary artery restricting the development of miliary lesions within the lung (**Web Image 6.29**). The miliary lesions are millet seed-sized (1 mm diameter), yellowish, firm areas without grossly visible caseation necrosis.

M/E The lesions show the structure of tubercles with minute areas of caseation necrosis (**Web Image 6.30**).

Clinical Features and Diagnosis of Tuberculosis (p. 156)

The clinical manifestations in tuberculosis may be variable depending upon the location, extent and type of lesions.

1. Referable to lungs—such as productive cough, may be with haemoptysis, pleural effusion, dyspnoea, orthopnoea etc. Chest X-ray may show typical apical changes like pleural effusion, nodularity, and miliary or diffuse infiltrates in the lung parenchyma.

2. Systemic features—such as fever, night sweats, fatigue, loss of weight and appetite. Long-standing and untreated cases of tuberculosis may develop systemic secondary amyloidosis.

The *diagnosis* is made by the following tests:

- i) Positive Mantoux skin test.
- ii) Positive sputum for AFB (on smear or culture).
- iii) Complete haemogram (lymphocytosis and raised ERR).
- iv) Chest X-ray (characteristic hilar nodules and other parenchymal changes).
- v) Fine needle aspiration cytology of an enlarged peripheral lymph node is quite helpful for confirmation of diagnosis.

Causes of death in pulmonary tuberculosis are usually pulmonary insufficiency, pulmonary haemorrhage, sepsis due to disseminated miliary tuberculosis, cor pulmonale or secondary amyloidosis.

□ LEPROSY (p. 157)

Leprosy or Hansen's disease (after discovery of the causative organism by Hansen in 1874), was first described in ancient Indian text going back to 6th Century BC, is a chronic non-fatal infectious disease affecting mainly the cooler parts of the body such as the skin, mouth, respiratory tract, eyes, peripheral nerves, superficial lymph nodes and testis.

Causative Organism (p. 157)

The disease is caused by *Mycobacterium leprae* which closely resembles *Mycobacterium tuberculosis* but is less acid-fast. The organisms in tissues appear as compact rounded masses (*globi*) or are arranged in parallel fashion like *cigarettes-in-pack*.

M. leprae can be demonstrated in tissue sections, in split skin smears by splitting the skin, scrapings from cut edges of dermis, and in nasal smears by the following techniques:

1. *Acid-fast (Ziehl-Neelsen) staining*. The staining procedure is similar as for demonstration of *M. tuberculosis* but can be decolourised by lower concentration (5%) of sulphuric acid (less acid-fast) (**Web Image 6.31**).
2. *Fite-Faraco staining* procedure is a modification of Z.N. procedure and is considered better for more adequate staining of tissue sections.
3. *Gomori methenamine silver (GMS) staining* can also be employed.
4. *Molecular methods* by PCR.
5. *IgM antibodies to PGL-1 antigen* seen in 95% cases of lepromatous leprosy but only in 60% cases of tuberculoid leprosy.

Although lepra bacilli were the first bacteria identified for causing human disease, *M. leprae* remains one of the few bacterial species which is yet to be cultured on artificial medium. Nine-banded armadillo, a rodent, acts as an

116 experimental animal model as it develops leprosy which is histopathologically and immunologically similar to human leprosy.

Incidence (p. 158)

The disease is endemic in areas with hot and moist climates and in poor tropical countries. According to the WHO, 8 countries—India, China, Nepal, Brazil, Indonesia, Myanmar (Burma), Madagascar and Nigeria, together constitute about 80% of leprosy cases, of which India accounts for one-third of all registered leprosy cases globally. In India, the disease is seen more commonly in regions like Tamil Nadu, Bihar, Pondicherry, Andhra Pradesh, Orissa, West Bengal and Assam. Very few cases are now seen in Europe and the United States.

Mode of Transmission (p. 158)

Leprosy is a slow communicable disease and the incubation period between first exposure and appearance of signs of disease varies from 2 to 20 years (average about 3 years). The infectivity may be from the following sources:

1. *Direct contact* with untreated leprosy patients who shed numerous bacilli from damaged skin, nasal secretions, mucous membrane of mouth and hair follicles.
2. *Materno-foetal transmission* across the placenta.
3. Transmission from *milk* of leprosy patient to infant.

Immunology of Leprosy (p. 158)

Like in tuberculosis, the immune response in leprosy is also T cell-mediated delayed hypersensitivity (type IV reaction) but the two diseases are quite dissimilar as regards immune reactions and lesions. *M. leprae* do not produce any toxins but instead the damage to tissues is immune-mediated. This is due to following peculiar aspects in immunology of leprosy:

1. Antigens of leprosy bacilli. Lepra bacilli have several antigens. The bacterial cell wall contains large amount of *M. leprae*-specific phenolic glycolipid (PGL-1) and another surface antigen, lipo-arabinomannan (LAMN). These antigens of the bacilli determine the immune reaction of host lymphocytes and macrophages. Another unique feature of leprosy bacilli is invasion in peripheral nerves which is due to binding of trisaccharide of *M. leprae* to basal lamina of Schwann cells.

2. Genotype of the host. Genetic composition of the host as known by MHC class (or HLA type) determines which antigen of leprosy bacilli shall interact with host immune cells. Accordingly, the host response to the leprosy bacilli in different individuals is variable.

3. T cell response. There is variation in T cell response in different individuals infected with leprosy bacilli:

- i) Unlike tubercle bacilli, there is not only *activation* of CD4+ T cells but also of CD8+ T cells.
- ii) CD4+ T cells in lepra bacilli infected persons act not only as helper and promoter cells but also assume the role of *cytotoxicity*.
- iii) The two subpopulations of CD4+ T cells (or T helper cells)— T_H 1 cells and T_H 2 cells, elaborate different types of *cytokines* in response to stimuli from the lepra bacilli and macrophages.
- iv) In tuberculoid leprosy, the response is largely by CD4+ T cells, while in lepromatous leprosy although there is excess of CD8+ T cells (suppressor T) but the macrophages and suppressor T cells fail to destroy the bacilli due to *CD8+ T cell defect*.

4. Humoral response. Though the patients of lepromatous leprosy have humoral components like high levels of immunoglobulins (IgG, IgA, IgM) and antibodies to mycobacterial antigens but these antibodies do not have any protective role against lepra bacilli.

LEPROMIN TEST. It is not a diagnostic test but is used for classifying leprosy on the basis of immune response. Intradermal injection of lepromin, an antigenic extract of *M. leprae*, reveals delayed hypersensitivity reaction in patients of tuberculoid leprosy:

- ◆ An early positive reaction appearing as an indurated area in 24-48 hours is called *Fernandez reaction*.
- ◆ A delayed granulomatous lesion appearing after 3-4 weeks is called *Mitsuda reaction*.

Patients of lepromatous leprosy are negative by the lepromin test.

Classification (p. 159)

Conventionally, leprosy is classified into 2 main types:

- ◆ Lepromatous type representing *low resistance*; and
- ◆ Tuberculoid type representing *high resistance*.

Salient differences between the two main forms of leprosy are summarised in **Web Table 6.5**.

Since both these types of leprosy represent two opposite poles of host immune response, these are also called *polar forms* of leprosy. Cases not falling into either of the two poles are classified as *borderline* and *indeterminate types*.

Leprosy is classified into 5 clinico-pathologic groups (*modified Ridley and Jopling's classification*) as under:

- TT—Tuberculoid Polar (*High resistance*)
- BT—Borderline Tuberculoid
- BB—Mid Borderline (dimorphic)
- BL—Borderline Lepromatous
- LL—Lepromatous Polar (*Low resistance*)

Reactional Leprosy (p. 159)

There may be two types of lepra reactions:

TYPE I: REVERSAL REACTIONS. The polar forms of leprosy do not undergo any change in clinical and histopathological picture. The borderline groups are unstable and may move across the spectrum in either direction with upgrading or downgrading of patient's immune state. Accordingly, there may be two types of borderline reaction:

1. **Upgrading reaction** is characterised by increased cell-mediated immunity and occurs in patients of borderline lepromatous (BL) type on treatment who upgrade or shift towards tuberculoid type.
2. **Downgrading reaction** is characterised by lowering of cellular immunity and is seen in borderline tuberculoid (BT) type who downgrade or shift towards lepromatous type.

TYPE II: ERYTHEMA NODOSUM LEPROSUM (ENL). ENL occurs in lepromatous patients after treatment. It is characterised by tender cutaneous nodules, fever, iridocyclitis, synovitis and lymph node involvement.

M/E The lesions in ENL show infiltration by neutrophils and eosinophils and prominence of vasculitis. Inflammation often extends deep into the subcutaneous fat causing panniculitis. Bacillary load is increased.

Histopathology of Leprosy (p. 160)

In general, for histopathologic evaluation in all suspected cases of leprosy the following broad *guidelines* should be followed:

- ◆ cell type of granuloma;
- ◆ nerve involvement; and
- ◆ bacterial load.

118 The main features in various groups are given below.

1. Lepromatous leprosy:

The following features characterise lepromatous polar leprosy (**Web Image 6.32**):

i) In the dermis, there is proliferation of macrophages with foamy change, particularly around the blood vessels, nerves and dermal appendages. The foamy macrophages are called '*lepra cells*' or '*Virchow cells*'.

ii) The lepra cells are heavily laden with acid-fast bacilli demonstrated with AFB staining. The AFB may be seen as compact globular masses (*globi*) or arranged in parallel fashion like '*cigarettes-in-pack*'.

iii) The dermal infiltrate of lepra cells characteristically does not encroach upon the basal layer of epidermis and is separated from epidermis by a subepidermal uninvolved *clear zone*.

iv) The *epidermis* overlying the lesions is thinned out, flat and may even ulcerate.

2. Tuberculoid leprosy:

The polar tuberculoid form presents the following histological features (**Web Image 6.33**):

i) The dermal lesions show granulomas resembling *hard tubercles* composed of epithelioid cells, Langhans' giant cells and peripheral mantle of lymphocytes.

ii) Lesions of tuberculoid leprosy have predilection for *dermal nerves* which may be destroyed and infiltrated by epithelioid cells and lymphocytes.

iii) The granulomatous infiltrate erodes the basal layer of epidermis i.e. there is *no clear zone*.

iv) The *lepra bacilli* are few and seen in destroyed nerves.

3. Borderline leprosy:

The histopathologic features of the three forms of borderline leprosy are as under:

i) *Borderline tuberculoid (BT)* form shows epithelioid cells and plentiful lymphocytes. There is a narrow clear subepidermal zone. Lepra bacilli are scanty and found in nerves.

ii) *Borderline lepromatous (BL)* form shows predominance of histiocytes, a few epithelioid cells and some irregularly dispersed lymphocytes. Numerous lepra bacilli are seen.

iii) *Mid-borderline (BB)* or dimorphic form shows sheets of epithelioid cells with no giant cells. Some lymphocytes are seen in the peri-neurium. Lepra bacilli are present, mostly in nerves.

Clinical Features (p. 161)

1. Lepromatous leprosy:

i) The skin lesions in LL are generally symmetrical, multiple, slightly hypopigmented and erythematous macules, papules, nodules or diffuse infiltrates. The nodular lesions may coalesce to give *leonine facies* appearance.

ii) The lesions are hypoaesthetic or anaesthetic but the sensory disturbance is not as distinct as in TT.

2. Tuberculoid leprosy:

i) The skin lesions in TT occur as either single or as a few asymmetrical lesions which are hypopigmented and erythematous macules.

ii) There is a distinct sensory impairment.

□ SYPHILIS (p. 161)

Syphilis is a venereal (sexually-transmitted) disease caused by spirochaetes, *Treponema pallidum*.

Causative Organism (p. 161)

T. pallidum is a coiled spiral filament 10 µm long that moves actively in fresh preparations. The organism cannot be stained by the usual methods and can be demonstrated in the exudates and tissues by:

1. *dark ground illumination (DGI)* in fresh preparation;
2. *fluorescent antibody technique*;
3. *silver impregnation techniques*; and
4. *PCR* as a research method.

The organism has not been cultivated in any culture media but experimental infection can be produced in rabbits and chimpanzees. The organism is rapidly destroyed by cold, heat, and antiseptics.

Immunology (p. 161)

T. pallidum does not produce any endotoxin or exotoxin. The pathogenesis of the lesions appears to be due to host immune response.

There are two types of serological tests for syphilis: treponemal and non-treponemal.

A. Treponemal serological tests: These tests measure antibody to *T. pallidum* antigen and are as under:

- i) *Fluorescent treponemal antibody-absorbed (FTA-ABS) test*.
- ii) *Agglutinin assays* e.g. microhaemagglutination assay for *T. pallidum* (MHA-TP), and Serodia TP-PA which is more sensitive.
- iii) *T. pallidum passive haemagglutination (TPHA) test*.

B. Non-treponemal serological tests. These tests measure non-specific reaginic antibodies IgM and IgG immunoglobulins directed against cardiolipin-lecithin-cholesterol complex and are more commonly used. These tests are as under:

- i) *Reiter protein complement fixation (RPCF) test*: test of choice for rapid diagnosis.
- ii) *Venereal Disease Research Laboratory (VDRL) test*: Wassermann described a complement fixing antibody against antigen of human syphilitic tissue. This antigen is used in the Standard Test for Syphilis (STS) in Wassermann complement fixing test and Venereal Disease Research Laboratory (VDRL) test.

Mode of Transmission (p. 162)

1. *Sexual intercourse* resulting in lesions on glans penis, vulva, vagina and cervix.
2. *Intimate person-to-person contact* with lesions on lips, tongue or fingers.
3. *Transfusion* of infected blood.
4. *Materno-foetal transmission* in congenital syphilis if the mother is infected.

Stages of Acquired Syphilis (p. 162)

Acquired syphilis is divided into 3 stages: primary, secondary and tertiary syphilis.

1. PRIMARY SYPHILIS. Typical lesion of primary syphilis is *chancre* which appears on genitals or at extra-genital sites in 2-4 weeks after exposure to infection (**Web Image 6.34,A**). Initially, the lesion is a painless papule which ulcerates in the centre so that the fully-developed chancre is an indurated lesion with central ulceration accompanied by regional lymphadenitis. The chancre heals without scarring, even in the absence of treatment.

120 **M/E** The chancre has following features:

- i) Dense infiltrate of mainly plasma cells, some lymphocytes and a few macrophages.
- ii) Perivascular aggregation of mononuclear cells, particularly plasma cells (periarteritis and endarteritis).
- iii) Proliferation of vascular endothelium.

Antibody tests are positive in 1-3 weeks after the appearance of chancre. Spirochaetes can be demonstrated in the exudates by DGI.

2. SECONDARY SYPHILIS. Inadequately treated patients of primary syphilis develop *mucocutaneous lesions* and painless lymphadenopathy in 2-3 months after the exposure (**Web Image 6.34,B**). Mucocutaneous lesions may be in the form of the mucous patches on mouth, pharynx and vagina; and generalised skin eruptions and condyloma lata in anogenital region.

Antibody tests are always positive at this stage. Secondary syphilis is *highly infective stage* and spirochaetes can be easily demonstrated in the mucocutaneous lesions.

3. TERTIARY SYPHILIS. After a latent period of appearance of secondary lesions and about 2-3 years following first exposure, tertiary lesions of syphilis appear. Lesions of tertiary syphilis are much less infective than the other two stages and spirochaetes can be demonstrated with great difficulty. These lesions are of 2 main types (**Web Image 6.34,C**):

i) **Syphilitic gumma.** It is a solitary, localised, rubbery lesion with central necrosis, seen in organs like liver, testis, bone and brain. In liver, the gumma is associated with scarring of hepatic parenchyma (*hepar lobatum*).

M/E The structure of gumma shows the following features (**Web Image 6.35**):

- a) Central coagulative necrosis resembling caseation but is less destructive so that outlines of necrosed cells can still be faintly seen.
- b) Surrounding zone of palisaded macrophages with many plasma cells, some lymphocytes, giant cells and fibroblasts.

ii) **Diffuse lesions of tertiary syphilis.** The lesions appear following widespread dissemination of spirochaetes in the body. The diffuse lesions are predominantly seen in cardiovascular and nervous systems.

a) **Cardiovascular syphilis** mainly involves thoracic aorta. The wall of aorta is weakened and dilated due to syphilitic aortitis and results in aortic aneurysm, incompetence of aortic valve and narrowing of mouths of coronary ostia.

b) **Neurosyphilis** may manifest as:

- ◆ meningovascular syphilis affecting chiefly the meninges;
- ◆ tabes dorsalis affecting the spinal cord; and
- ◆ general paresis affecting the brain.

CONGENITAL SYPHILIS. Congenital syphilis may develop in a foetus of more than 16 weeks gestation who is exposed to maternal spirochaetaemia. The major morphologic features as under:

- i) Saddle-shaped nose deformity due to destruction of bridge of the nose.
- ii) The characteristic 'Hutchinson's teeth' which are small, widely spaced, peg-shaped permanent teeth.
- iii) Mucocutaneous lesions of acquired secondary syphilis.
- iv) Bony lesions like epiphysitis and periostitis.
- v) Interstitial keratitis with corneal opacity.
- vi) Diffuse fibrosis in the liver.
- vii) Interstitial fibrosis of lungs.
- viii) If the foetus with congenital syphilis is born dead, it is premature, with macerated skin, enlarged spleen and liver, and with syphilitic epiphysitis.

□ ACTINOMYCOSIS (p. 163)

Actinomycosis is a chronic suppurative disease caused by anaerobic bacteria, *Actinomycetes israelii*. The disease is conventionally included in mycology though the causative organism is filamentous bacteria and not true fungus. The disease is worldwide in distribution. The organisms are commensals in the oral cavity, alimentary tract and vagina. The infection is always endogenous in origin and not by person-to-person contact. The organisms invade, proliferate and disseminate in favourable conditions like break in mucocutaneous continuity, some underlying disease etc.

MORPHOLOGIC FEATURES. Depending upon the anatomic location of lesions, actinomycosis is of 4 types: (**Web Image 6.36**).

1. **Cervicofacial actinomycosis.** This is the commonest form (60%) and has the best prognosis. The infection enters from tonsils, carious teeth, periodontal disease or trauma following tooth extraction. Initially, a firm swelling develops in the lower jaw ('lumpy jaw'). In time, the mass breaks down and abscesses and sinuses are formed. The discharging pus contains typical tiny yellow sulphur granules. The infection may extend into adjoining soft tissues as well as may destroy the bone.
2. **Thoracic actinomycosis.** The infection in the lungs is due to aspiration of the organism from oral cavity or extension of infection from abdominal or hepatic lesions.
3. **Abdominal actinomycosis.** This type is common in appendix, caecum and liver. The abdominal infection results from swallowing of organisms from oral cavity or extension from thoracic cavity.
4. **Pelvic actinomycosis.** Infection in the pelvis occurs as a complication of intrauterine contraceptive devices (IUCD's).

M/E Irrespective of the location of actinomycosis, the following features are seen (**Web Image 6.37**):

- i) The inflammatory reaction is a granuloma with central suppuration. There is formation of abscesses in the centre of lesions and at the periphery chronic inflammatory cells, giant cells and fibroblasts are seen.
- ii) The centre of each abscess contains the bacterial colony, 'sulphur granule', characterised by radiating filaments (hence previously known as *ray fungus*) with hyaline, eosinophilic, club-like ends representative of secreted immunoglobulins.
- iii) Bacterial stains reveal the organisms as gram-positive filaments, nonacid-fast, which stain positively with Gomori's methenamine silver (GMS) staining.

□ SARCOIDOSIS (BOECK'S SARCOID) (p. 164)

Sarcoidosis is a systemic disease of unknown etiology. It is worldwide in distribution and affects adults from 20-40 years of age. The disease is characterised by the presence of non-caseating epithelioid cell granulomas ('sarcoid granuloma') in the affected tissues and organs, notably lymph nodes and lungs. Other sites are the skin, spleen, uvea of the eyes, salivary glands, liver and bones of hands and feet.

ETIOLOGY AND PATHOGENESIS. The cause of sarcoidosis remains unknown. Currently, possible etiology is an infectious or noninfectious environmental agent in a genetically susceptible individual. Since the disease is characterised by granulomatous tissue reaction, possibility of cell-mediated immune mechanisms has been suggested.

MORPHOLOGIC FEATURES. The lesions in sarcoidosis are generalised and may affect various organs and tissues at sometime in the course of disease, but brunt of the disease is borne by the lungs and lymph nodes (**Web Image 6.38**).

M/E (Web Image 6.39): The features are as under:

1. The diagnostic feature in sarcoidosis of any organ or tissue is the *non-caseating sarcoid granuloma*, composed of epithelioid cells, Langhans' and foreign body giant cells and surrounded peripherally by fibroblasts.
2. Typically, granulomas of sarcoidosis are '*naked*' i.e. either devoid of peripheral rim of lymphocytes or there is paucity of lymphocytes.
3. In late stage, the granuloma is either *enclosed by hyalinised fibrous tissue* or is replaced by hyalinised fibrous mass.
4. The giant cells in sarcoid granulomas contain certain *cytoplasmic inclusions* as follows:
 - i) *Asteroid bodies*
 - ii) *Schaumann's bodies or conchoid (conch like) bodies*
 - iii) *Birefringent cytoplasmic crystals*.

KVIEM'S TEST. It is a useful intradermal diagnostic test. The antigen prepared from involved lymph node or spleen is injected intradermally. In a positive test, nodular lesion appears in 3-6 weeks at the inoculation site which on microscopic examination shows presence of non-caseating granulomas.

Healing is the body response to injury in an attempt to restore normal structure and function. Healing involves 2 distinct processes:

- ◆ *Regeneration* when healing takes place by proliferation of parenchymal cells and usually results in complete restoration of the original tissues.
- ◆ *Repair* when healing takes place by proliferation of connective tissue elements resulting in fibrosis and scarring.

At times, both the processes take place simultaneously.

□ REGENERATION (p. 165)

Some parenchymal cells are short-lived while others have a longer lifespan. In order to maintain proper structure of tissues, these cells are under the constant regulatory control of their cell cycle. These include growth factors such as: epidermal growth factor, fibroblast growth factor, platelet-derived growth factor, endothelial growth factor, transforming growth factor- β .

Cell cycle is defined as the period between two successive cell divisions and is divided into 4 unequal phases (**Web Image 6.40**):

- ◆ *M (mitosis) phase:* Phase of mitosis.
- ◆ *G₁ (gap 1) phase:* The daughter cell enters G₁ phase after mitosis.
- ◆ *S (synthesis) phase:* During this phase, the synthesis of nuclear DNA takes place.
- ◆ *G₂ (gap 2) phase:* After completion of nuclear DNA duplication, the cell enters G₂ phase.
- ◆ *G₀ (gap 0) phase:* This is the quiescent or resting phase of the cell after an M phase.

Not all cells of the body divide at the same pace. Some mature cells do not divide at all while others complete a cell cycle every 16-24 hours. The main difference between slowly-dividing and rapidly-dividing cells is the duration of G₁ phase.

Depending upon their capacity to divide, the cells of the body can be divided into 3 groups: labile cells, stable cells, and permanent cells.

1. Labile cells. These cells continue to multiply throughout life under normal physiologic conditions. These include: surface epithelial cells of the epidermis, alimentary tract, respiratory tract, urinary tract, vagina, cervix, uterine endometrium, haematopoietic cells of bone marrow and cells of lymph nodes and spleen.

2. Stable cells. These cells decrease or lose their ability to proliferate after adolescence but retain the capacity to multiply in response to stimuli throughout adult life. These include: parenchymal cells of organs like liver, pancreas, kidneys, adrenal and thyroid; mesenchymal cells like smooth muscle cells, fibroblasts, vascular endothelium, bone and cartilage cells.

3. Permanent cells. These cells lose their ability to proliferate around the time of birth. These include: neurons of nervous system, skeletal muscle and cardiac muscle cells.

□ REPAIR (p. 166)

Repair is the replacement of injured tissue by fibrous tissue. Two processes are involved in repair:

Granulation Tissue Formation (p. 166)

The term granulation tissue derives its name from slightly granular and pink appearance of the tissue. Each granule corresponds histologically to proliferation of new small blood vessels which are slightly lifted on the surface by thin covering of fibroblasts and young collagen.

The following 3 phases are observed in the formation of granulation tissue (**Web Image 6.41**):

1. PHASE OF INFLAMMATION. Following trauma, blood clots at the site of injury. There is acute inflammatory response with exudation of plasma, neutrophils and some monocytes within 24 hours.

2. PHASE OF CLEARANCE. Combination of proteolytic enzymes liberated from neutrophils, autolytic enzymes from dead tissues cells, and phagocytic activity of macrophages clear off the necrotic tissue, debris and red blood cells.

3. PHASE OF INGROWTH OF GRANULATION TISSUE. This phase consists of 2 main processes:

i) Angiogenesis (neovascularisation). Formation of new blood vessels at the site of injury takes place by proliferation of endothelial cells from the margins of severed blood vessels. Initially, the proliferated endothelial cells are solid buds but within a few hours develop a lumen and start carrying blood. The newly formed blood vessels are more leaky, accounting for the oedematous appearance of new granulation tissue. Soon, these blood vessels differentiate into muscular arterioles, thin-walled venules and true capillaries.

The process of angiogenesis is stimulated with proteolytic destruction of basement membrane. Angiogenesis takes place under the influence of following factors:

- a) Vascular endothelial growth factor (VEGF) elaborated by mesenchymal cells while its receptors are present in endothelial cells only.
- b) Platelet-derived growth factor (PDGF), transforming growth factor- β (TGF- β), basic fibroblast growth factor (bFGF) and surface integrins are all associated with cellular proliferation.

ii) Fibrogenesis. The newly formed blood vessels are present in an amorphous ground substance or matrix. The new fibroblasts originate from fibrocytes as well as by mitotic division of fibroblasts. Some of these fibroblasts have combination of morphologic and functional characteristics of smooth muscle cells (*myofibroblasts*). Collagen fibrils begin to appear by about 6th day. As maturation proceeds, more and more of collagen is formed while the number of active fibroblasts and new blood vessels decreases. This results in formation of inactive looking scar known as *cicatrization*.

Contraction of Wounds (p. 167)

The wound starts contracting after 2-3 days and the process is completed by the 14th day. During this period, the wound is reduced by approximately 80%

of its original size. Contracted wound results in rapid healing since lesser surface area of the injured tissue has to be replaced.

In order to explain the mechanism of wound contraction, a number of factors have been proposed.

1. *Dehydration* as a result of removal of fluid by drying of wound was first suggested but without being substantiated.
2. *Contraction of collagen* was thought to be responsible for contraction but wound contraction proceeds at a stage when the collagen content of granulation tissue is very small.
3. Discovery of *myofibroblasts* appearing in active granulation tissue has resolved the controversy surrounding the mechanism of wound contraction. These cells have features intermediate between those of fibroblasts and smooth muscle cells.

□ WOUND HEALING (p. 167)

Healing of skin wounds provides a classical example of combination of regeneration and repair described above. Wound healing can be accomplished in one of the following two ways:

Healing by First Intention (Primary Union) (p. 168)

This is defined as healing of a wound which has the following characteristics:

- i) clean and uninfected;
- ii) surgically incised;
- iii) without much loss of cells and tissue; and
- iv) edges of wound are approximated by surgical sutures.

The sequence of events in primary union is illustrated in **Web Image 6.42** and described below:

1. Initial haemorrhage. Immediately after injury, the space between the approximated surfaces of incised wound is filled with blood which then clots and seals the wound against dehydration and infection.

2. Acute inflammatory response. This occurs within 24 hours with appearance of polymorphs from the margins of incision. By 3rd day, polymorphs are replaced by macrophages.

3. Epithelial changes. The basal cells of epidermis from both the cut margins start proliferating and migrating towards incisional space in the form of epithelial spurs. A well-approximated wound is covered by a layer of epithelium in 48 hours. The migrated epidermal cells separate the underlying viable dermis from the overlying necrotic material and clot, forming *scab* which is cast off.

4. Organisation. By 3rd day, fibroblasts also invade the wound area. By 5th day, new collagen fibrils start forming which dominate till healing is completed. In 4 weeks, the scar tissue with scanty cellular and vascular elements, a few inflammatory cells and epithelialised surface is formed.

5. Suture tracks. Each suture track is a separate wound and incites the same phenomena as in healing of the primary wound i.e. filling the space with haemorrhage, some inflammatory cell reaction, epithelial cell proliferation along the suture track from both margins, fibroblastic proliferation and formation of young collagen. When sutures are removed around 7th day, much of epithelialised suture track is avulsed and the remaining epithelial tissue in the track is absorbed. However, sometimes the suture track gets infected (*stitch abscess*), or the epithelial cells may persist in the track (*implantation or epidermal cysts*).

Healing by Second Intention (Secondary Union) (p. 168)

This is defined as healing of a wound having the following characteristics:

- i) open with a large tissue defect, at times infected;

ii) having extensive loss of cells and tissues; and

iii) the wound is not approximated by surgical sutures but is left open.

The basic events in secondary union are similar to primary union but differ in having a larger tissue defect which has to be bridged. Hence healing takes place from the base upwards as well as from the margins inwards. The healing by second intention is slow and results in a large, at times ugly, scar as compared to rapid healing and neat scar of primary union.

The sequence of events in secondary union is illustrated in **Web Image 6.43** and described below:

1. Initial haemorrhage. As a result of injury, the wound space is filled with blood and fibrin clot which dries.

2. Inflammatory phase. There is an initial acute inflammatory response followed by appearance of macrophages which clear off the debris as in primary union.

3. Epithelial changes. As in primary healing, the epidermal cells from both the margins of wound proliferate and migrate into the wound in the form of epithelial spurs till they meet in the middle and re-epithelialise the gap completely. However, the proliferating epithelial cells do not cover the surface fully until granulation tissue from base has started filling the wound space.

4. Granulation tissue. Main bulk of secondary healing is by granulations. Granulation tissue is formed by proliferation of fibroblasts and neovascularisation from the adjoining viable elements. The newly-formed granulation tissue is deep red, granular and very fragile. With time, the scar on maturation becomes pale and white due to increase in collagen and decrease in vascularity.

5. Wound contraction. Contraction of wound is an important feature of secondary healing, not seen in primary healing. Due to the action of myofibroblasts present in granulation tissue, the wound contracts to one-third to one-fourth of its original size.

6. Presence of infection. Bacterial contamination of an open wound delays the process of healing due to release of bacterial toxins that provoke necrosis, suppuration and thrombosis. Surgical removal of dead and necrosed tissue, *debridement*, helps in preventing the bacterial infection of open wounds.

Differences between primary and secondary union of wounds are given in **Web Table 6.6**.

Complications of Wound Healing (p. 169)

During the course of healing, following complications may occur:

1. *Infection*
2. *Implantation (epidermal) cyst*
3. *Pigmentation*
4. *Deficient scar formation*
5. *Incisional hernia*
6. *Hypertrophied scars and keloid formation*
7. *Excessive contraction*
8. *Neoplasia.*

Extracellular Matrix— Wound Strength (p. 170)

The wound is strengthened by proliferation of fibroblasts and myofibroblasts which get structural support from the extracellular matrix (ECM). In addition to providing structural support, ECM can direct cell migration, attachment, differentiation and organisation.

ECM has five main components: collagen, adhesive glycoproteins, basement membrane, elastic fibres, and proteoglycans.

1. COLLAGEN. The collagens are a family of proteins which provide structural support to the multicellular organism. It is the main component of tissues such as fibrous tissue, bone, cartilage, valves of heart, cornea, basement membrane etc.

Depending upon the biochemical composition, 18 types of collagen have been identified called collagen *type I to XVIII*, many of which are unique for specific tissues. Type I collagen is normally present in the skin, bone and tendons and accounts for 90% of collagen in the body:

2. ADHESIVE GLYCOPROTEINS. Various adhesive glycoproteins acting as glue for the ECM and the cells consist of fibronectin, tenascin (cytotactin) and thrombospondin.

3. BASEMENT MEMBRANE. Basement membranes are periodic acid-Schiff (PAS)-positive amorphous structures that lie underneath epithelia of different organs and endothelial cells. They consist of collagen type IV and laminin.

4. ELASTIC FIBRES. While the tensile strength in tissue comes from collagen, the ability to recoil is provided by elastic fibres. Elastic fibres consist of 2 components—elastin glycoprotein and elastic microfibril. Elastases degrade the elastic tissue e.g. in inflammation, emphysema etc.

5. PROTEOGLYCANS. Various proteoglycans are distributed in different tissues as under:

- i) *Chondroitin sulphate*—abundant in cartilage, dermis
- ii) *Heparan sulphate*—in basement membranes
- iii) *Dermatan sulphate*—in dermis
- iv) *Keratan sulphate*—in cartilage
- v) *Hyaluronic acid*—in cartilage, dermis.

In wound healing, the deposition of proteoglycans precedes collagen laying.

Factors Influencing Healing (p. 170)

Two types of factors influence the wound healing:

A. LOCAL FACTORS:

1. *Infection*
2. *Poor blood supply*
3. *Foreign bodies*
4. *Movement*
5. Exposure to *ionising radiation*
6. Exposure to *ultraviolet light*
7. *Type, size and location of injury* .

B. SYSTEMIC FACTORS:

1. *Age*
2. *Nutrition*
3. *Systemic infection*
4. *Administration of glucocorticoids*
5. *Uncontrolled diabetics*
6. *Haematologic abnormalities.*

□ HEALING IN SPECIALISED TISSUES (p. 171)

Fracture Healing (p. 171)

Healing of fracture by callus formation depends upon some clinical considerations whether the fracture is:

- ◆ *traumatic* (in previously normal bone), or *pathological* (in previously diseased bone);
- ◆ *complete or incomplete* like green-stick fracture; and
- ◆ *simple* (closed), *comminuted* (splintering of bone), or *compound* (communicating to skin surface).

However, basic events in healing of any type of fracture are similar and resemble healing of skin wound to some extent.

◆ **Primary union of fractures** occurs in a few special situations when the ends of fracture are approximated as is done by application of compression clamps. In these cases, bony union takes place with formation of medullary callus without periosteal callus formation. The patient can be made ambulatory early but there is more extensive bone necrosis and slow healing.

◆ **Secondary union** is the more common process of fracture healing. Though it is a continuous process, secondary bone union is described under the following 3 headings:

- i) Procallus formation
- ii) Osseous callus formation
- iii) Remodelling

These processes are illustrated in **Web Image 6.44**.

I. PROCALLUS FORMATION. Steps involved in the formation of procallus are as follows:

1. Haematoma
2. Local inflammatory response
3. Ingrowth of granulation tissue
4. Callus composed of woven bone and cartilage (**Web Image 6.45**).

II. OSSEOUS CALLUS FORMATION. The procallus acts as scaffolding on which osseous callus composed of lamellar bone is formed. The woven bone is cleared away by incoming osteoclasts and the calcified cartilage disintegrates. In their place, newly-formed blood vessels and osteoblasts invade, laying down osteoid which is calcified and lamellar bone is formed by developing Haversian system concentrically around the blood vessels.

III. REMODELLING. During the formation of lamellar bone, osteoblastic laying and osteoclastic removal are taking place remodelling the united bone ends, which after sometime, is indistinguishable from normal bone.

COMPLICATIONS OF FRACTURE HEALING. These are as under:

1. Fibrous union
2. Non-union
3. Delayed union.

Healing of Nervous Tissue (p. 172)

CENTRAL NERVOUS SYSTEM. The nerve cells of the brain, spinal cord and ganglia once destroyed are not replaced. Axons of CNS also do not show any significant regeneration. The damaged neuroglial cells, however, may show proliferation of astrocytes called gliosis.

PERIPHERAL NERVOUS SYSTEM. In contrast to the cells of CNS, the peripheral nerves show regeneration, mainly from proliferation of Schwann cells and fibrils from distal end.

Healing of Muscle (p. 172)

All three types of muscle fibres have limited capacity to regenerate.

SKELETAL MUSCLE. The regeneration of striated muscle is similar to peripheral nerves. On injury, the cut ends of muscle fibres retract but are held together by stromal connective tissue. The injured site is filled with fibrinous material, polymorphs and macrophages. After clearance of damaged fibres by macrophages, one of the following two types of regeneration of muscle fibres can occur:

◆ If the muscle sheath is intact, sarcolemmal tubes containing histiocytes appear along the endomysial tube which, in about 3 months time, restores properly oriented muscle fibres e.g. in Zenker's degeneration of muscle in typhoid fever.

◆ If the muscle sheath is damaged, it forms a disorganised multinucleate mass and scar composed of fibrovascular tissue e.g. in Volkmann's ischaemic contracture.

SMOOTH MUSCLE. Non-striated muscle has limited regenerative capacity e.g. appearance of smooth muscle in the arterioles in granulation tissue. However, in large destructive lesions, the smooth muscle is replaced by permanent scar tissue.

CARDIAC MUSCLE. Destruction of heart muscle is replaced by fibrous tissue. However, in situations where the endomysium of individual cardiac fibre is intact (e.g. in diphtheria and coxsackie virus infections), regeneration of cardiac fibres may occur in young patients.

Healing of Mucosal Surfaces (p. 173)

The cells of mucosal surfaces have very good regeneration and are normally being lost and replaced continuously e.g. mucosa of alimentary tract, respiratory tract, urinary tract, uterine endometrium etc. This occurs by proliferation from margins, migration, multilayering and differentiation of epithelial cells in the same way as in the epidermal cells in healing of skin wounds.

Healing of Solid Epithelial Organs (p. 173)

Following gross tissue damage to organs like the kidney, liver and thyroid, the replacement is by fibrous scar e.g. in chronic pyelonephritis and cirrhosis of liver. However, in parenchymal cell damage with intact basement membrane or intact supporting stromal tissue, regeneration may occur.

◆ SELF ASSESSMENT

- Which of the complement components act as chemokines?

A. C3b	B. C4b
C. C5a	D. C4a
- All are types of tissue macrophages *except*:

A. Littoral cells	B. Hoffbauer cells
C. Osteoclasts	D. Osteoblasts
- Formation of granuloma is:
 - Type I hypersensitivity reaction
 - Type II hypersensitivity reaction
 - Type III hypersensitivity reaction
 - Type IV hypersensitivity reaction
- Which of the following is atypical mycobacteria?
 - Mycobacterium microti
 - Mycobacterium canneti
 - Mycobacterium africanum
 - Mycobacterium ulcerans
- IgM antibody against PGL-1 antigen is used for the diagnosis of:
 - Leprosy
 - Tuberculosis
 - Syphilis
 - Brucellosis
- Which category of leprosy is not included in Ridley-Jopling classification?
 - Mid borderline leprosy
 - Borderline tuberculoid leprosy
 - Indeterminate leprosy
 - Tuberculoid polar leprosy
- Hepar lobatum is seen in:

A. Primary syphilis	B. Secondary syphilis
C. Tertiary syphilis	D. Congenital syphilis

8. Killing of *M. tuberculosis* that grows within the macrophage is brought about by the following mechanisms:
 - A. By reactive oxygen species
 - B. By oxygen-independent bactericidal mechanism
 - C. By nitric oxide mechanism
 - D. By hydrolytic enzymes
9. Main cytokines acting as mediators of inflammation are as under except:
 - A. Interleukin-1 (IL-1)
 - B. Tumour necrosis factor α (TNF- α)
 - C. Nitric oxide (NO)
 - D. Interferon- γ (IF- γ)
10. Receptor for IgE is present on:

A. Polymorphs	B. Eosinophil
C. Basophil	D. Plasma cell
11. Typhoid fever is an example of:
 - A. Acute inflammation
 - B. Chronic nonspecific inflammation
 - C. Chronic granulomatous inflammation
 - D. Chronic suppurative inflammation
12. Tubercle bacilli cause lesions by the following mechanisms:
 - A. Elaboration of endotoxin
 - B. Elaboration of exotoxin
 - C. Type IV hypersensitivity
 - D. Direct cytotoxicity
13. The following statements are correct for tubercle bacilli except:
 - A. Tubercle bacilli can be cultured
 - B. Tubercle bacilli are anaerobe
 - C. Tubercle bacilli thrive best in the apex of lung
 - D. *M. smegmatis* is not pathogenic to man
14. Tubercle bacilli in caseous lesions are best demonstrated in:
 - A. Caseous centre
 - B. Margin of necrosis with viable tissue
 - C. Epithelioid cells
 - D. Langhans' giant cells
15. Leprosy bacilli are:
 - A. Not acid fast
 - B. As acid fast as tubercle bacilli
 - C. Less acid fast compared to tubercle bacilli
 - D. More acid fast compared to tubercle bacilli
16. Lepromin test is always positive in:
 - A. Lepromatous leprosy
 - B. Borderline lepromatous leprosy
 - C. Tuberculoid leprosy
 - D. Indeterminate leprosy
17. Spirochaetes are most difficult to demonstrate in:

A. Primary syphilis	B. Secondary syphilis
C. Tertiary syphilis	D. Congenital syphilis
18. Actinomycosis is caused by:

A. Fungus	B. Gram-negative bacteria
C. Anaerobic bacteria	D. Acid fast bacteria
19. Typically, sarcoid granuloma has the following features except:
 - A. Non caseating granuloma
 - B. Giant cells have cytoplasmic inclusions
 - C. Peripheral mantle of lymphocytes
 - D. Fibroblastic proliferation at the periphery of a granuloma

20. The following holds true for stable cells in cell cycle:
- They remain in cell cycle from one mitosis to the next
 - They are in resting phase but can be stimulated to enter the cell cycle
 - They have left the cell cycle
 - They do not have capacity to multiply in response to stimuli throughout adult life
21. Connective tissue in scar is formed by the following types of fibrillar collagen:
- Type II, III, IV
 - Type I, III, V
 - Type I, II, V
 - Type III, V, VII
22. Basement membrane consists of:
- Type I collagen
 - Type II collagen
 - Type III collagen
 - Type IV collagen
23. The following adhesion molecules play a significant role in rolling of PMNs over endothelial cells *except*:
- Selectins
 - Integrins
24. Which of the following is non-fibrillar collagen?
- Type V
 - Type I
 - Type III
 - Type VI
25. Which is false about primary union?
- Exuberant granulation tissue to fill the gap
 - Clear margins
 - Uninfected
 - Lead to neat linear scar.

KEY

1 = C	2 = D	3 = D	4 = D
5 = A	6 = C	7 = C	8 = A
9 = C	10 = C	11 = A	12 = C
13 = B	14 = B	15 = C	16 = C
17 = C	18 = C	19 = C	20 = B
21 = B	22 = D	23 = C	24 = D
25 = A			



Microorganisms, namely bacteria, viruses, fungi and parasites, are present everywhere—in the soil, water, atmosphere and on the body surfaces, and are responsible for a large number of infectious diseases in human beings. There are several examples of certain *infectious diseases* which are not so common in the developed world now but they continue to be major health problems in the developing countries e.g. tuberculosis, leprosy, typhoid fever, cholera, measles, pertussis, malaria, amoebiasis, pneumonia etc. *Vaccines* have, however, been successful in controlling or eliminating some diseases all over the world e.g. smallpox, poliomyelitis, measles, pertussis etc. Similarly, insecticides have helped in controlling malaria to an extent. However, infections still rank very high as a *cause of death* in the world. Reasons for this trend are not difficult to seek:

- ◆ Development of newer and antibiotic-resistant strains of microorganisms; classic example is that of methicillin-resistant *Staph. aureus* (MRSA).
- ◆ Administration of immunosuppressive therapy to patients with malignant tumours and transplanted organs making them susceptible to opportunistic infections
- ◆ Increasing number of patients reporting to hospital for different illnesses but instead many developing hospital-acquired infections.
- ◆ Lastly, discovery in 1981 of previously unknown deadly disease i.e. acquired immunodeficiency syndrome (AIDS) caused by human immunodeficiency virus (HIV).

While talking of microbial infective diseases, let us not forget the fact that many microorganisms may actually benefit mankind. Following is the range of *host-organism inter-relationship*, which may vary quite widely:

1. *Symbiosis* i.e. cooperative association between two dissimilar organisms beneficial to both.
2. *Commensalism* i.e. two dissimilar organisms living together benefitting one without harming the other.
3. *True parasitism* i.e. two dissimilar organisms living together benefitting the parasite but harming the host.
4. *Saprophytism* i.e. organisms living on dead tissues.

Besides microorganisms, more recently a modified host protein present in the mammalian CNS has been identified called *prion protein*.

Transmission of infectious diseases requires a chain of events and is the consequence of inter-relationship between disease-producing properties of microorganisms and host-defense capability against the invading organisms.

□ CHAIN IN TRANSMISSION OF INFECTIOUS DISEASES (p. 174)

Transmission of infections occurs following a chain of events pertaining to various parameters as under:

- i) Reservoir of pathogen.
- ii) Route of infection.
- iii) Mode of transmission.
- iv) Susceptible host.

Key to management of infection lies in breaking or blocking this chain for transmission and spread of infection.

132 □ FACTORS RELATING TO INFECTIOUS AGENTS (p. 174)

i) **Mode of entry.** Microorganisms causing infectious diseases may gain entry into the body by various routes e.g.

- ◆ through ingestion (external route);
- ◆ inoculation (parenteral method);
- ◆ inhalation (respiration);
- ◆ perinatally (vertical transmission);
- ◆ by direct contact (contagious infection); and
- ◆ by contaminated water, food, soil, environment or from an animal host (zoonotic infections).

ii) **Spread of infection.** Microorganisms after entering the body may spread further through the phagocytic cells, blood vessels and lymphatics.

iii) **Production of toxins.** Bacteria liberate toxins which have effects on cell metabolism. *Endotoxins* are liberated on lysis of the bacterial cell while *exotoxins* are secreted by bacteria and have effects at distant sites too.

iv) **Virulence of organisms.** Many species and strains of organisms may have varying virulence e.g. the three strains of *C. diphtheriae* (*gravis*, *intermedius* and *mitis*) produce the same diphtherial exotoxin but in different amounts.

v) **Product of organisms.** Some organisms produce enzymes that help in spread of infections e.g. hyaluronidase by *Cl. welchii*, streptokinase by streptococci, staphylokinase and coagulase by staphylococci.

Factors Relating to Host (p. 175)

Microorganisms invade human body when defenses are not adequate. These factors include the following:

i) **Physical barrier.** A break in the continuity of the skin and mucous membranes allows the microorganisms to enter the body.

ii) **Chemical barrier.** Mucus secretions of the oral cavity and the alimentary tract and gastric acidity prevent bacterial colonisation.

iii) **Effective drainage.** Ducts of various glands are the conduits of drainage of secretions. Obstruction in any of these passages promotes infection.

iv) **Immune defense mechanisms.** These include the phagocytic leucocytes of blood (polymorphs and monocytes), phagocytes of tissues (mononuclear-phagocyte system) and the immune system.

□ METHODS OF IDENTIFICATION (p. 175)

The organisms causing infections and parasitic diseases may be identified by routine H & E stained sections in many instances. However, confirmation in most cases requires either application of special staining techniques or is confirmed by molecular biologic methods (**Web Table 7.1**). In addition, culture of lesional tissue should be carried out for species identification and drug sensitivity. Generally, the organism is looked for at the advancing edge of the lesion in the section rather than in the necrotic centre (**Web Image 7.1**).

Web Table 7.2 provides an abbreviated classification of bacterial diseases and their etiologic agents.

□ PLAGUE (p. 175)

Plague is caused by *Yersinia (Pasteurella) pestis* which is a small Gram-negative coccobacillus that grows rapidly on most culture media. Direct

identification of the organism in tissues is possible by fluorescence antisera methods.

Plague has been a great killer since 14th century and is known to have wiped out populations of cities. However, the modern Europe is plague free, possibly due to widespread use of arsenic as rat poison. Currently, the world over, Vietnam and Tanzania have most cases of plague. However, an outbreak in Surat in the state of Gujarat in Western part of India in 1994 alarmed the world once again that we are not totally free of this dreaded 'black death'.

Infection to humans occurs by rat-flea or by inhalation. After the organisms enter the bloodstream, they reach the draining lymph nodes where, rather than being phagocytosed by phagocytic cells, they proliferate rapidly giving rise to tender lymphadenopathy. This occurs within 24-48 hours of infection and is accompanied by chills, fever, myalgia, nausea, vomiting and marked prostration. If untreated, death occurs from disseminated intravascular coagulation (DIC) within 1 to 2 days with development of widespread petechiae and ecchymoses leading to gangrene, and hence the name *black death*. In other cases, death results from multi-organ failure due to profound toxæmia. The patient and his fluids are highly infectious and can be transmitted by arthropods as well as person-to-person contact, giving rise to secondary cases.

Virulence of the organism *Y. pestis* is attributed to the elaboration of plague toxins: pesticin and lipopolysaccharide endotoxin.

MORPHOLOGIC FEATURES. Following forms of plague are recognised (*Web Image 7.2*):

1. Bubonic plague, the most common
2. Pneumonic plague
3. Typhoidal plague
4. Septicaemic plague

□ **ANTHRAX** (*p. 178*)

Anthrax is a bacterial disease of antiquity caused by *Bacillus anthracis* that spreads from animals to man. The disease is widely prevalent in cattle and sheep but human infection is rare. However, much of knowledge on human anthrax has been gained owing to fear of use of these bacteria for military purpose by rogue countries or for "bio-terrorism" (other microbial diseases in this list include: botulism, pneumonic plague, smallpox). In India, anthrax in animals is endemic in South due to large unprotected and uncontrolled live-stock population.

ETIOPATHOGENESIS. The causative organism, *Bacillus anthracis*, is a gram-positive, aerobic bacillus, 4.5 µm long. It is a spore-forming bacillus and the spores so formed outside the body are quite resistant. The disease occurs as an exogenous infection by contact with soil or animal products contaminated with spores.

Depending upon the portal of entry, three types of human anthrax is known to occur:

- i) **Cutaneous form** by direct contact with skin and is most common.
- ii) **Pulmonary form** by inhalation, also called as "wool-sorters' disease" and is most fatal.
- iii) **Gastrointestinal form** by ingestion and is rare.

The mechanism of infection includes spread of bacilli from the portal of entry to the regional lymph nodes through lymphatics where the bacteria proliferate. There is delayed accumulation of polymorphs and macrophages. Macrophages also play a role in expression of bacterial toxicity; bacterial toxin is quite lethal to macrophages.

LABORATORY DIAGNOSIS. It includes following tests:

- i) *Smear examination:* Gram stained smear shows rod-shaped, spore-forming, gram-positive bacilli. Endospores are detectable by presence of unstained defects or holes within the cell.
- ii) *Culture:* Anthrax bacteria grow on sheep blood agar as flat colonies with an irregular margin (medusa head).

Anthrax contaminated work surfaces, materials and equipment must be decontaminated with 5% hypochlorite or 5% phenol.

□ **WHOOPIING COUGH (PERTUSSIS)** (p. 178)

Whooping cough is a highly communicable acute bacterial disease of childhood caused by *Bordetella pertussis*. The use of DPT vaccine has reduced the prevalence of whooping cough in different populations.

The causative organism, *B. pertussis*, has strong tropism for the brush border of the bronchial epithelium. The organisms proliferate here and stimulate the bronchial epithelium to produce abundant tenacious mucus. Within 7-10 days after exposure, catarrhal stage begins which is the most infectious stage. There is low grade fever, rhinorrhoea, conjunctivitis and excess tear production. Paroxysms of cough occur with characteristic 'whoop'. The condition is self-limiting but may cause death due to asphyxia in infants. *B. pertussis* produces a heat-labile toxin, a heat-stable endotoxin, and a lymphocytosis-producing factor called histamine-sensitising factor.

M/E The lesions in the respiratory tract consist of necrotic bronchial epithelium covered by thick mucopurulent exudate. In severe cases, there is mucosal erosion and hyperaemia. The peripheral blood shows marked lymphocytosis upto 90% (**Web Image 7.3**) and enlargement of lymphoid follicles in the bronchial mucosa and peribronchial lymph nodes.

□ **GRANULOMA INGUINALE** (p. 178)

Granuloma inguinale is a sexually-transmitted disease affecting the genitalia and inguinal and perianal regions caused by *Calymmatobacterium donovani*. The disease is common in tropical and subtropical countries such as New Guinea, Australia and India. The organism inhabits the intestinal tract. The infection is transmitted through vaginal or anal intercourse and by autoinoculation. The incubation period varies from 2 to 4 weeks. Initially, the lesion is in the form of a papule, a subcutaneous nodule or an ulcer. Within a few weeks, it develops into a raised, soft, painless, reddish ulcer with exuberant granulation tissue.

M/E The margin of the ulcer shows epithelial hyperplasia. The ulcer bed shows neutrophilic abscesses. The dermis and subcutaneous tissues are infiltrated by numerous histiocytes containing many bacteria called *Donovan bodies*, and lymphocytes, plasma cells and neutrophils. These organisms are best demonstrated by silver impregnation techniques.

□ **STAPHYLOCOCCAL INFECTIONS** (p. 179)

A wide variety of suppurative diseases are caused by *Staph. aureus* which includes the following (**Web Image 7.4**):

1. Infections of skin. Staphylococcal infections of the skin are quite common. The infection begins from lodgement of cocci in the hair root due to poor hygiene and results in obstruction of sweat or sebaceous gland duct. This is termed *folliculitis*. Involvement of adjacent follicles results in larger lesions called *furuncle*. Further spread of infection horizontally under the skin and subcutaneous tissue causes *carbuncle* or *cellulitis*. *Styes* are staphylococcal infection of the sebaceous glands of Zeis, the glands of Moll and eyelash follicles. *Impetigo* is yet another staphylococcal skin infection common in school children in which there are multiple pustular lesions on

face forming honey-yellow crusts. *Breast abscess* may occur following delivery when staphylococci are transmitted from infant having neonatal sepsis or due to stasis of milk.

2. Infections of burns and surgical wounds. These are quite common due to contamination from the patient's own nasal secretions or from hospital staff. Elderly, malnourished, obese patients and neonates have increased susceptibility.

3. Infections of the upper and lower respiratory tract. Small children under 2 years of age get staphylococcal infections of the respiratory tract commonly. These include pharyngitis, bronchopneumonia, staphylococcal pneumonia and its complications.

4. Bacterial arthritis. Septic arthritis in the elderly is caused by *Staph. aureus*.

5. Infection of bone (Osteomyelitis). Young boys having history of trauma or infection may develop acute staphylococcal osteomyelitis.

6. Bacterial endocarditis. Acute and subacute bacterial endocarditis are complications of infection with *Staph. aureus* and *Staph. epidermidis*.

7. Bacterial meningitis. Surgical procedures on central nervous system may lead to staphylococcal meningitis.

8. Septicaemia. Staphylococcal septicaemia may occur in patients with lowered resistance or in patients having underlying staphylococcal infections. Patients present with features of bacteraemia such as shaking chills and fever.

9. Toxic shock syndrome. Toxic shock syndrome is a serious complication of staphylococcal infection characterised by fever, hypotension and exfoliative skin rash. The condition affects young menstruating women who use tampons of some brands which when kept inside the vagina cause absorption of staphylococcal toxins from the vagina.

□ STREPTOCOCCAL INFECTIONS (p. 180)

Streptococci are also gram-positive cocci but unlike staphylococci, they are more known for their non-suppurative autoimmune complications than suppurative inflammatory responses. Streptococcal infections occur throughout the world but their problems are greater in underprivileged populations where antibiotics are not instituted readily.

The following groups and subtypes of streptococci have been identified and implicated in different streptococcal diseases (**Web Image 7.5**):

1. *Group A or Streptococcus pyogenes*, also called β -haemolytic streptococci, are involved in causing upper respiratory tract infection and cutaneous infections (erysipelas). In addition, beta haemolytic streptococci are involved in autoimmune reactions in the form of rheumatic heart disease (RHD).

2. *Group B or Streptococcus agalactiae* produces infections in the newborn and is involved in non-suppurative post-streptococcal complications such as RHD and acute glomerulonephritis.

3. *Group C and G streptococci* are responsible for respiratory infections.

4. *Group D or Streptococcus faecalis*, also called enterococci are important in causation of urinary tract infection, bacterial endocarditis, septicaemia etc.

□ CLOSTRIDIAL DISEASES (p. 180)

Clostridia are gram-positive spore-forming anaerobic microorganisms found in the gastrointestinal tract of herbivorous animals and man. These organisms may undergo vegetative division under anaerobic conditions, and sporulation

under aerobic conditions. These spores are passed in faeces and can survive in unfavourable conditions. On degeneration of these microorganisms, the plasmids are liberated which produce many toxins responsible for the following clostridial diseases depending upon the species (**Web Image 7.6**):

1. Gas gangrene by *C. perfringens*
2. Tetanus by *C. tetani*
3. Botulism by *C. botulinum*
4. Clostridial food poisoning by *C. perfringens*
5. Necrotising enterocolitis by *C. perfringens*.

DISEASES CAUSED BY FUNGI (p. 181)

Of the large number of known fungi, only a few are infective to human beings. Many of the human fungal infections are opportunistic i.e. they occur in conditions with impaired host immune mechanisms. Such conditions include defective neutrophil function, administration of corticosteroids, immunosuppressive therapy and immunodeficiency states (congenital and acquired). A list of common fungal infections of human beings is given in **Web Table 7.3**.

□ MYCETOMA (p. 182)

Mycetoma is a chronic suppurative infection involving a limb, shoulder or other tissues and is characterised by draining sinuses. The material discharged from the sinuses is in the form of grains consisting of colonies of fungi or bacteria. Mycetomas are of 2 main types:

- ◆ *Mycetomas* caused by actinomyces (higher bacteria) comprising about 60% of cases.
- ◆ *Eumycetomas* caused by true fungi comprising the remaining 40% of the cases.

Most common fungi causative for eumycetoma are *Madurella mycetomatis* or *Madurella grisea*, both causing black granules from discharging sinuses.

MORPHOLOGIC FEATURES. After several months of infection, the affected site, most commonly foot, is swollen and hence the name 'madura foot'. The lesions extend deeply into the subcutaneous tissues, along the fascia and eventually invade the bones. They drain through sinus tracts which discharge purulent material and grains. The surrounding tissue shows granulomatous reaction (**Web Image 7.7**).

□ CANDIDIASIS (p. 182)

Candidiasis is an opportunistic fungal infection caused most commonly by *Candida albicans* and occasionally by *Candida tropicalis*. In human beings, *Candida* species are present as normal flora of the skin and mucocutaneous areas, intestines and vagina. The organism becomes pathogenic when the balance between the host and the organism is disturbed. Various predisposing factors are: impaired immunity, prolonged use of oral contraceptives, long-term antibiotic therapy, corticosteroid therapy, diabetes mellitus, obesity, pregnancy etc.

MORPHOLOGIC FEATURES. *Candida* produces superficial infections of the skin and mucous membranes, or may invade deeper tissues as described under:

1. **Oral thrush.** This is the commonest form of mucocutaneous candidiasis seen especially in early life. Full-fledged lesions consist of creamy white pseudomembrane composed of fungi covering the tongue, soft palate, and buccal mucosa. In severe cases, ulceration may be seen.
2. **Candidal vaginitis.** Vaginal candidiasis or monilial vaginitis is characterised clinically by thick, yellow, curdy discharge. The lesions form

pseudomembrane of fungi on the vaginal mucosa. They are quite pruritic and may extend to involve the vulva (vulvovaginitis) and the perineum.

3. Cutaneous candidiasis. Candidal involvement of nail folds producing change in the shape of nail plate (paronychia) and colonisation in the intertriginous areas of the skin, axilla, groin, infra- and inter-mammary, intergluteal folds and interdigital spaces are some of the common forms of cutaneous lesions caused by *Candida albicans* (**Web Image 7.8**).

4. Systemic candidiasis. Invasive candidiasis is rare and is usually a terminal event of an underlying disorder associated with impaired immune system. The organisms gain entry into the body through an ulcerative lesion on the skin and mucosa or may be introduced by iatrogenic means such as via intravenous infusion, peritoneal dialysis or urinary catheterisation.

□ SUPERFICIAL MYCOSIS (p. 183)

Dermatophytes are the most important example of cutaneous mycosis caused by *Microsporum*, *Trichophyton* and *Epidermophyton*. These superficial fungi are spread by direct contact or by fomites and infect tissues such as the skin, hair and nails. Examples of diseases pertaining to these tissues are as under:

- ◆ *Tinea capitis* characterised by patchy alopecia affecting the scalp and eyebrows.
- ◆ *Tinea barbae* is acute folliculitis of the beard.
- ◆ *Tinea corporis* is dermatitis with formation of erythematous papules.

DISEASES CAUSED BY VIRUSES (p. 183)

Viruses are essentially intracellular parasites. Depending upon their nucleic acid genomic composition, they may be single-stranded or double-stranded, RNA or DNA viruses. A list of common viruses and diseases caused by them is given in **Web Table 7.4**.

□ VIRAL HAEMORRHAGIC FEVERS (p. 183)

Viral haemorrhagic fevers are a group of acute viral infections which have common features of causing haemorrhages, shock and sometimes death. Viruses causing haemorrhagic fevers were earlier called *arthropod-borne (or arbo)* viruses since their transmission was considered to be from arthropods to humans. However, now it is known that all such viruses are not transmitted by arthropod vectors alone and hence now such haemorrhagic fevers are classified according to the routes of transmission and other epidemiologic features into 4 groups:

- ◆ Mosquito-borne (e.g. yellow fever, dengue fever, Rift Valley fever)
- ◆ Tick-borne (e.g. Crimean haemorrhagic fever, Kyasanur Forest disease)
- ◆ Zoonotic (e.g. Korean haemorrhagic fever, Lassa fever)
- ◆ Marburg virus disease and Ebola virus disease by unknown route.

Of these, mosquito-borne viral haemorrhagic fevers in which *Aedes aegypti* mosquitoes are vectors, are the most common problem the world over, especially in developing countries. Two important examples of *Aedes* mosquito-borne viral haemorrhagic fevers are yellow fever and dengue fever, which are discussed below.

Yellow Fever (p. 183)

Yellow fever is the oldest known viral haemorrhagic fever restricted to some regions of Africa and South America. Monkeys carry the virus without suffering from illness and the virus is transmitted from them to humans by *Aedes aegypti* as vector.

Yellow fever is characterised by sudden onset of high fever, chills, myalgia, headache, jaundice, hepatic failure, renal failure, bleeding disorders and hypotension.

138 **MORPHOLOGIC FEATURES.** Major pathologic changes are seen in the liver and kidneys.

Liver. The characteristic changes include: midzonal necrosis, Councilman bodies, and microvesicular fat.

Kidneys. The kidneys show the following changes:

- i) coagulative necrosis of proximal tubules;
- ii) accumulation of fat in the tubular epithelium; and
- iii) haemorrhages.

Dengue Haemorrhagic Fever (DHF) (p. 184)

Dengue is caused by virus transmitted by bites of mosquito *Aedes aegypti*; the transmission being highest during and after rainy season when mosquitoes are numerous. An outbreak of DHF occurred in Delhi and neighbouring cities in 1996 claiming several lives. Since then, some cases of DHF have been reported in post-monsoon period every year in North India.

Dengue occurs in two forms:

1. *Dengue fever or break-bone fever* in an uncomplicated way is a self-limited febrile illness affecting muscles and joints with severe back pain due to myalgia (and hence the name 'break-bone' fever).
2. *Dengue haemorrhagic fever (DHF)*, on the other hand, is a severe and potentially fatal form of acute febrile illness characterised by cutaneous and intestinal haemorrhages due to thrombocytopenia, haemoconcentration, hypovolaemic shock and neurologic disturbances. DHF is most common in children under 15 years of age.

Dengue virus infects blood monocytes, lymphocytes and endothelial cells. This initiates complement activation and consumptive coagulopathy including thrombocytopenia. The entire process takes place rapidly and may evolve over a period of a few hours. If patient is treated appropriately at this stage, there is rapid and dramatic recovery. But in untreated cases, *dengue shock syndrome* develops and death occurs.

Diagnosis of DHF is confirmed by:

- ◆ serologic testing for detection of antibodies;
- ◆ detection of virus by immunofluorescence method and monoclonal antibodies; and
- ◆ rapid methods such as reverse transcriptase-PCR and fluorogenic-ELISA.

At autopsy, the predominant organ changes observed are as follows:

- i) *Brain:* intracranial haemorrhages, cerebral oedema, dengue encephalitis.
- ii) *Liver:* enlarged; necrosis of hepatocytes and Kupffer cells, Reye's syndrome in children.
- iii) *Kidneys:* petechial haemorrhages and features of renal failure.
- iv) *Muscles and joints:* perivascular mononuclear cell infiltrate.

Chikungunya Virus Infection (p. 184)

The word chikungunya means "that which bends up" and is derived from the language in Africa where this viral disease was first found in human beings. Chikungunya virus infection is primarily a disease in nonhuman primates but the infection is transmitted to humans by *A. aegypti* mosquito. The disease is endemic in parts of Africa and Asia and occurs sporadically elsewhere. A massive outbreak occurred in 2004 in Indian Ocean region affecting people in Sri Lanka, Maldives, Mauritius and parts of India.

◆ *Clinically*, the disease is characterised by abrupt onset of fever, severe arthralgia (producing bending posture of patient due to pain and hence the name), migratory polyarthritis affecting small joints, chills, headache, anorexia, nausea, abdominal pain, rash, petechiae and ocular symptoms such as photophobia.

◆ *Major laboratory findings* include leucopenia, mild thrombocytopenia, elevated transaminases and raised CRP.

□ INFLUENZA VIRUS INFECTIONS (p. 184)

Influenza virus infection is an important and common form of communicable disease, especially prevalent as a seasonal infection in the developed countries. Its general clinical features range from a mild afebrile illness similar to common cold by appearance of sudden fever, headache, myalgia, malaise, chills and respiratory tract manifestations such as cough, soar throat to a more severe form of acute respiratory illness and lymphadenopathy.

ETIOLOGIC AGENT. Influenza virus is a single-stranded RNA virus belonging to coronaviruses. Depending upon its antigenic characteristics of the nucleoprotein and matrix, 3 distinct types are known: A, B and C. Out of these, influenza type A is responsible for most serious and severe forms of outbreaks in human beings while types B and C cause a milder form of illness. Type A influenza virus is further subtyped based on its 2 viral surface features:

Haemagglutinin (H): H antigen elicits host immune response by antibodies and determines the future protection against influenza A viruses. There are 16 distinct H subtypes of type A influenza viruses.

Neuraminidase (N): Antibody response against N antigen limits the spread of viral infection and is responsible for reduction of infection. N antigen of influenza A exists in 9 subtypes.

Thus, the subtypes of influenza A viruses are designated by denoting serial subtype numbers of H and N antigens as H1N1, H2N2 etc.

Influenza A viruses infect human beings, birds, pigs and horses. In view of a high antigenic variation in H and N components, influenza A viruses are responsible for many known epidemics and pandemics in history and in present times. Major antigenic variation in H or N antigens is called *antigenic shift* while minor variation is termed *antigenic drift*. In general, population at high risk are immunosuppressed patients, elderly individuals and infants.

Two of the known subtypes of influenza A viruses which have affected the mankind in recent times and have attracted a lot of attention of the media and the WHO are as under:

Bird Flu ((Influenza A/H5N1) (p. 185)

H5N1 subtype of the influenza type A virus infection causes severe acute respiratory syndrome (SARS) which is the human form of bird flu or avian influenza with having similar symptomatology. Every year, there have been outbreaks in poultry birds in different parts of the world resulting in slaughtering of millions of infected chickens every year. Human outbreak of the disease called SARS reemerged in December 2003 in southern China, Hong Kong and Vietnam and then spread to other countries in Asia, Europe and America.

PATHOGENESIS. SARS is caused by influenza type A/H5N1 respiratory virus, also called SARS-associated coronaviruses (SARS-CoV). Though it is not fatal for wild birds, it can kill poultry birds and people. Humans acquire infection through contaminated nasal, respiratory and faecal material from infected birds. No person-to-person transmission has been reported so far. Humans do not have immune protection against avian viruses.

LABORATORY DIAGNOSIS. Following abnormalities in laboratory tests are noted:

1. Almost normal-to-low TLC with lymphopaenia in about half the cases, mostly due to fall in CD4+ T cells.
2. Thrombocytopenia.
3. Elevated liver enzymes: aminotransferases, creatine kinase and LDH.
4. Virus isolation by reverse transcriptase-PCR on respiratory sample, plasma, urine or stool.

5. Tissue culture.
6. Detection of serum antibodies by ELISA or immunofluorescence.

Swine Flu (Influenza A/H1N1) (p. 185)

H1N1 influenza type A flu which appeared last in 1977-78 as a mild form of pandemic has reappeared in April 2009 as an outbreak in Mexico but is rapidly spreading elsewhere. Presently, the disease has already spread to 39 countries including US.

PATHOGENESIS. H1N1 influenza type A virus is primarily an infection in pigs with low mortality in them. Human beings acquire infection by direct contact with infected pigs. However, further transmission of H1N1 flu occurs by person-to-person contact such as by coughing, sneezing etc but it is not known to occur from eating pork.

The disease has the usual flu-like clinical features, but additionally one-third of cases have been found to have diarrhoea and vomiting.

Since human beings do not have immune protection by antibody response against H1N1 influenza type A and the usual seasonal flu vaccine does not provide protection against H1N1, personal hygiene and prophylaxis remain the mainstay of further spread of disease.

□ VARICELLA ZOSTER VIRUS INFECTION (p. 186)

Varicella zoster virus is a member of herpes virus family and causes chickenpox (varicella) in non-immune individuals and herpes zoster (shingles) in those who had chickenpox in the past.

HERPES SIMPLEX VIRUS INFECTION (p. 186)

Two of the herpes simplex viruses (HSV)—type 1 and 2, cause 'fever blisters' and herpes genitalis respectively.

HSV-1 causes vesicular lesions on the skin, lips and mucous membranes. The infection spreads by close contact. The condition is particularly severe in immunodeficient patients and neonates while milder attacks of infection cause fever-blisters on lips, oral mucosa and skin. Severe cases may develop complications such as meningoencephalitis and keratoconjunctivitis. Various stimuli such as fever, stress and respiratory infection reactivate latent virus lying in the ganglia and result in recurrent attacks of blisters.

HSV-2 causes herpes genitalis characterised by vesicular and necrotising lesions on the cervix, vagina and vulva. Like HSV-1 infection, lesions caused by HSV-2 are also recurrent and develop in non-immune individuals. Latency of HSV-2 infection is similar to HSV-1 and the organisms are reactivated by stimuli such as menstruation and sexual intercourse.

□ LYMPHOGRANULOMA VENEREUM (p. 186)

Lymphogranuloma venereum (LGV) is a sexually-transmitted disease caused by *Chlamydia trachomatis* and is characterised by mucocutaneous lesions and regional lymphadenopathy. Though described here under viral infections, chlamydia are no more considered as filterable viruses as was previously thought but are instead intracellular gram-negative bacteria.

The condition begins as a painless, herpes-like lesion on the cervix, vagina, or penis. The organisms are carried via lymphatics to regional lymph nodes. The involved lymph nodes are tender, fluctuant and may ulcerate and drain pus.

M/E The lymph nodes have characteristic stellate-shaped abscesses surrounded by a zone of epithelioid cells (granuloma). Healing stage of the acute lesion takes place by fibrosis and permanent destruction of lymphoid structure.

□ **CAT-SCRATCH DISEASE** (p. 186)

Another condition related to LGV, cat-scratch disease, is caused by *Bartonella henselae*, an organism linked to rickettsiae but unlike rickettsiae this organism can be grown in culture. The condition occurs more commonly in children (under 18 years of age). There is regional nodal enlargement which appears about 2 weeks after cat-scratch, and sometimes after thorn injury. The lymphadenopathy is self-limited and regresses in 2-4 months.

M/E

- i) Initially, there is formation of non-caseating sarcoid-like granulomas.
- ii) Subsequently, there are neutrophilic abscesses surrounded by palisaded histiocytes and fibroblasts, an appearance simulating LGV discussed above.
- iii) The organism is extracellular and can be identified by silver stains.

□ **RABIES** (p. 186)

Rabies is a fatal form of encephalitis in humans caused by rabies virus. The virus is transmitted into the human body by a bite by infected carnivores e.g. dog, wolf, fox and bats. The virus spreads from the contaminated saliva of these animals. The organism enters a peripheral nerve and then travels to the spinal cord and brain. A latent period of 10 days to 3 months may elapse between the bite and onset of symptoms. Since the virus localises at the brainstem, it produces classical symptoms of difficulty in swallowing and painful spasm of the throat termed hydrophobia.

M/E Neurons of the brainstem show characteristic Negri bodies which are intracytoplasmic, deeply eosinophilic inclusions.

Parasites may cause disease due to their presence in the lumen of the intestine, due to infiltration into the blood stream, or due to their presence inside the cells. A short list of parasitic diseases is given in **Web Table 7.5**.

□ **AMOEBIASIS** (p. 187)

Amoebiasis is caused by *Entamoeba histolytica*, named for its lytic action on tissues. It is the most important intestinal infection of man. The condition is particularly more common in tropical and subtropical areas with poor sanitation.

The parasite occurs in 2 forms: a *trophozoite form* which is active adult form seen in the tissues and diarrhoeal stools, and a *cystic form* seen in formed stools but not in the tissues. The trophozoite form can be stained positively with PAS stain in tissue sections while amoebic cysts having four nuclei can be identified in stools.

MORPHOLOGIC FEATURES. The lesions of amoebiasis include amoebic colitis, amoeboma, amoebic liver abscess and spread to other sites (**Web Image 7.9**).

◆ **Amoebic colitis**, the most common type of amoebic infection begins as a small area of necrosis of mucosa which may ulcerate. These ulcerative lesions may enlarge, develop undermining of margins of the ulcer due to lytic action of the trophozoite and have necrotic bed. Such chronic amoebic ulcers are described as flask-shaped ulcers due to their shape. The margin of the ulcer shows inflammatory response consisting of admixture of polymorphonuclear as well as mononuclear cells besides the presence of trophozoites of *Entamoeba histolytica* (**Web Image 7.10**).

◆ **Amoeboma** is the inflammatory thickening of the wall of large bowel resembling carcinoma of the colon.

◆ **Amoebic liver abscess** may be formed by invasion of the radicle of the portal vein by trophozoites. Amoebic liver abscess may be single or multiple. The amoebic abscess contains yellowish-grey amorphous liquid material in

142 which trophozoites are identified at the junction of the viable and necrotic tissue.

□ **MALARIA** (p. 188)

Malaria is a protozoal disease caused by any one or combination of four species of plasmodia: *Plasmodium vivax*, *Plasmodium falciparum*, *Plasmodium ovale* and *Plasmodium malariae*. While *Plasmodium falciparum* causes malignant malaria, the other three species produce benign form of illness. These parasites are transmitted by bite of female *Anopheles* mosquito.

The life cycle of plasmodia is complex and is diagrammatically depicted in **Web Image 7.11**, *A. P. falciparum* differs from other forms of plasmodial species in 4 respects:

- i) It does not have exo-erythrocytic stage.
- ii) Erythrocytes of any age are parasitised while other plasmodia parasitise juvenile red cells.
- iii) One red cell may contain more than one parasite.
- iv) The parasitised red cells are sticky causing obstruction of small blood vessels by thrombi, a feature which is responsible for extraordinary virulence of *P. falciparum*.

The main clinical features of malaria are cyclic peaks of high fever accompanied by chills, anaemia and splenomegaly.

MORPHOLOGIC FEATURES. Parasitisation and destruction of erythrocytes are responsible for major pathologic changes as under (**Web Image 7.11,B**):

1. Malarial pigment liberated by destroyed red cells accumulates in the phagocytic cells of the reticuloendothelial system resulting in enlargement of the spleen and liver (*hepatosplenomegaly*).
2. In falciparum malaria, there is massive absorption of haemoglobin by the renal tubules producing *blackwater fever* (*haemoglobinuric nephrosis*).
3. At autopsy, *cerebral malaria* is characterised by congestion and petechiae on the white matter.
4. Parasitised erythrocytes in falciparum malaria are sticky and get attached to endothelial cells resulting in obstruction of capillaries of deep organs such as of the brain leading to hypoxia and death. If the patient lives, *microhaemorrhages* and *microinfarcts* may be seen in the brain.

The diagnosis of malaria is made by demonstration of malarial parasite in thin or thick blood films or sometimes in histologic sections (**Web Image 7.12**).

□ **FILARIASIS** (p. 190)

Wuchereria bancrofti and *Brugia malayi* are responsible for causing Bancroftian and Malayan filariasis in different geographic regions. The lymphatic vessels inhabit the adult worm, especially in the lymph nodes, testis and epididymis. Microfilariae seen in the circulation are produced by the female worm (**Web Image 7.13**). Majority of infected patients remain asymptomatic. Symptomatic cases may have two forms of disease—an acute form and a chronic form.

MORPHOLOGIC FEATURES. The most significant histologic changes are due to the presence of adult worms in the lymphatic vessels causing lymphatic obstruction and lymphoedema. The regional lymph nodes are enlarged and their sinuses are distended with lymph. The tissues surrounding the blocked lymphatics are infiltrated by chronic inflammatory cell infiltrate consisting of lymphocytes, histiocytes, plasma cells and eosinophils. Chronicity of the process causes enormous thickening and induration of the skin of legs and scrotum resembling the hide of an elephant and hence the name *elephantiasis*.

□ **CYSTICERCOSIS** (p. 190)

Cysticercosis is infection by the larval stage of *Taenia solium*, the pork tapeworm. The adult tapeworm resides in the human intestines. The eggs

are passed in human faeces which are ingested by pigs or they infect vegetables. These eggs then develop into larval stages in the host, spread by blood to any site in the body and form cystic larvae termed *cysticercus cellulosae*. Human beings may acquire infection by the larval stage by eating undercooked pork ('measly pork'), by ingesting uncooked contaminated vegetables, and sometimes, by autoinfection.

MORPHOLOGIC FEATURES. The cysticercus may be single or there may be multiple cysticerci in the different tissues of the body. The cysts may occur virtually anywhere in body and accordingly produce symptoms; most common sites are the brain, skeletal muscle and skin. Cysticercus consists of a round to oval white cyst, about 1 cm in diameter, contains milky fluid and invaginated scolex with birefringent hooklets. Later, the lesion may become scarred and calcified (**Web Image 7.14**).

TORCH COMPLEX (p. 190)

Acronym 'TORCH' complex refers to development of common complex of symptoms in infants due to infection with different microorganisms that include: *Toxoplasma*, Others, Rubella, Cytomegalovirus, and Herpes simplex virus; category of 'Others' refers to infections such as hepatitis B, coxsackievirus B, mumps and poliovirus. The infection may be acquired by the foetus during intrauterine life, or perinatally and damage the foetus or infant. Since the symptoms produced by TORCH group of organisms are indistinguishable from each other, it is a common practice in a suspected pregnant mother or infant to test for all the four main TORCH agents.

It has been estimated that TORCH complex infections have an overall incidence of 1-5% of all live born children. All the microorganisms in the TORCH complex are transmitted transplacentally and, therefore, infect the foetus from the mother. Herpes and cytomegalovirus infections are common intrapartum infections acquired venereally.

The classic features of syndrome produced by TORCH complex are seen in congenital rubella. The features include: ocular defects, cardiac defects, CNS manifestations, sensorineural deafness, thrombocytopenia and hepatosplenomegaly (**Web Image 7.15**).

SELF ASSESSMENT

- The causative organisms of plague are:**
 - Cocci
 - Bacilli
 - Coccobacilli
 - Nocardia
- Lymphocytosis in whooping cough occurs due to:**
 - Endotoxin by the microorganism
 - Exotoxin by the microorganism
 - Cytokine
 - Histamine-sensitising factor
- Granuloma inguinale is characterised by the following except:**
 - It is caused by Donovan bacilli
 - It is characterised by lymphadenopathy
 - It is a sexually transmitted disease
 - There are neutrophilic abscesses in the dermis
- Prion proteins are implicated in the etiology of:**
 - Spongiform encephalopathy
 - Viral encephalitis
 - Perivenous encephalomyelitis
 - Progressive multifocal leucoencephalopathy

5. Streptococci are commonly implicated in the etiology of the following **except**:
- A. Rheumatic heart disease
 B. Glomerulonephritis
 C. Breast abscess
 D. Subacute bacterial endocarditis
6. Clostridia are implicated in the following **except**:
- A. Botulism
 B. Necrotising enterocolitis
 C. Bacillary dysentery
 D. Pseudomembranous colitis
7. Fungi in general can be identified by the following stains **except**:
- A. Silver stain
 B. Periodic acid Schiff
 C. Giemsa
 D. Mucicarmine
8. Mosquito-borne viral haemorrhagic fever include the following examples **except**:
- A. Dengue fever
 B. Yellow fever
 C. Rift Valley fever
 D. Kyasanur Forest fever
9. Dengue haemorrhagic fever is characterised by following laboratory findings **except**:
- A. Leucopenia
 B. Lymphocytosis
 C. Decreased haematocrit
 D. Thrombocytopenia
10. Granuloma inguinale and lymphogranuloma venereum are similar in following aspects, **except**:
- A. Both are sexually transmitted diseases
 B. Both are caused by bacteria
 C. Both are characterised by lymphadenopathy
 D. Both begin as lesions on genitals
11. Necrotic lesions of *Entamoeba histolytica* are due to:
- A. Cyst stage
 B. Trophozoite stage
 C. Both cyst and trophozoites
 D. Neither cysts nor trophozoites
12. *P. falciparum* differs from other plasmodia in following aspects **except**:
- A. It does not have exoerythrocytic stage
 B. It parasitises only juvenile red cells
 C. It causes malignant malaria
 D. One red cell may contain more than one parasite
13. In the case of SARS in human beings, the mode of infection is:
- A. From mosquito
 B. Person to person
 C. Poultry birds
 D. Domestic dogs
14. Swine flu influenza virus is:
- A. H5N1
 B. H1N1
 C. H5N2
 D. H1N2
15. Chikungunya is transmitted to humans by:
- A. Aedes
 B. Anopheles
 C. Culex
 D. Tick

KEY

1 = C	2 = D	3 = B	4 = A
5 = C	6 = C	7 = C	8 = D
9 = C	10 = C	11 = B	12 = B
13 = C	14 = B	15 = A	



Neoplasia

NOMENCLATURE AND CLASSIFICATION (p. 192)

□ INTRODUCTION

The term 'neoplasia' means new growth; the new growth produced is called 'neoplasm' or 'tumour'.

Satisfactory definition of a neoplasm or tumour is 'a mass of tissue formed as a result of abnormal, excessive, uncoordinated, autonomous and purposeless proliferation of cells even after cessation of stimulus for growth which caused it'. The branch of science dealing with the study of neoplasms or tumours is called oncology (*oncos*=tumour, *logos*=study). Neoplasms may be 'benign' when they are slow-growing and localised without causing much difficulty to the host, or 'malignant' when they proliferate rapidly, spread throughout the body and may eventually cause death of the host. The common term used for all malignant tumours is cancer. Hippocrates (460-377 BC) coined the term *karkinos* for cancer of the breast. The word 'cancer' means crab, thus reflecting the true character of cancer since 'it sticks to the part stubbornly like a crab'.

All tumours, benign as well as malignant, have 2 basic components:

- ◆ 'Parenchyma' comprised by proliferating tumour cells; parenchyma determines the nature and evolution of the tumour.

- ◆ 'Supportive stroma' composed of fibrous connective tissue and blood vessels; it provides the framework on which the parenchymal tumour cells grow.

The tumours derive their nomenclature on the basis of the parenchymal component comprising them. The suffix '-oma' is added to denote benign tumours. Malignant tumours of epithelial origin are called *carcinomas*, while malignant mesenchymal tumours are named *sarcomas* (*sarcos* = fleshy) (**Web Image 8.1**).

Although, this broad generalisation regarding nomenclature of tumours usually holds true in majority of instances, some examples contrary to this concept are: *melanoma* for carcinoma of the melanocytes, *hepatoma* for carcinoma of the hepatocytes, *lymphoma* for malignant tumour of the lymphoid tissue, and *seminoma* for malignant tumour of the testis. *Leukaemia* is the term used for cancer of blood forming cells.

□ SPECIAL CATEGORIES OF TUMOURS

1. Mixed tumours. When two types of tumours are combined in the same tumour, it is called a mixed tumour. For example:

i) *Adenosquamous carcinoma* is the combination of adenocarcinoma and squamous cell carcinoma in the endometrium.

ii) *Adenoacanthoma* is the mixture of adenocarcinoma and benign squamous elements in the endometrium.

iii) *Carcinosarcoma* is the rare combination of malignant tumour of the epithelium (carcinoma) and of mesenchymal tissue (sarcoma) such as in thyroid.

iv) *Collision tumour* is the term used for morphologically two different cancers in the same organ which do not mix with each other.

v) *Mixed tumour of the salivary gland* (or pleomorphic adenoma) is the term used for benign tumour having combination of both epithelial and mesenchymal tissue elements.

2. Teratomas. These tumours are made up of a mixture of various tissue types arising from totipotent cells derived from the three germ cell layers—ectoderm, mesoderm and endoderm. Most common sites for teratomas are ovaries and testis (*gonadal teratomas*). But they occur at *extra-gonadal sites* as well, mainly in the midline of the body such as in the head and neck region, mediastinum, retroperitoneum, sacrococcygeal region etc. Teratomas may be *benign or mature* (most of the ovarian teratomas) or *malignant or immature* (most of the testicular teratomas).

3. Blastomas (Embryomas). Blastomas or embryomas are a group of malignant tumours which arise from embryonal or partially differentiated cells which would normally form blastema of the organs and tissue during embryogenesis. These tumours occur more frequently in infants and children (under 5 years of age) and include some examples of tumours in this age group: neuroblastoma, nephroblastoma (Wilms' tumour), hepatoblastoma, retinoblastoma, medulloblastoma, pulmonary blastoma.

4. Hamartoma. Hamartoma is benign tumour which is made of mature but disorganised cells of tissues indigenous to the particular organ e.g. hamartoma of the lung consists of mature cartilage, mature smooth muscle and epithelium. Thus, all mature differentiated tissue elements which comprise the bronchus are present in it but are jumbled up as a mass.

5. Choristoma. Choristoma is the name given to the ectopic islands of normal tissue. Thus, choristoma is heterotopia but is not a true tumour, though it sounds like one.

CLASSIFICATION. Currently, classification of tumours is based on the histogenesis (i.e. cell of origin) and on the anticipated behaviour (**Web Table 8.1**).

The characteristics of tumours are described under the following headings:

- I. Rate of growth
- II. Cancer phenotype and stem cells
- III. Clinical and gross features
- IV. Microscopic features
- V. Local invasion (Direct spread)
- VI. Metastasis (Distant spread).

Based on these characteristics, contrasting features of benign and malignant tumours are summarised in **Web Table 8.2** and illustrated in **Web Image 8.2**.

□ I. RATE OF GROWTH (*p. 194*)

The tumour cells generally proliferate more rapidly than the normal cells. In general, benign tumours grow slowly and malignant tumours rapidly. However, there are exceptions to this generalisation. The rate at which the tumour enlarges depends upon 2 main factors:

1. Rate of cell production, growth fraction and rate of cell loss. Rate of growth of a tumour depends upon 3 important parameters:

- i) doubling time of tumour cells,
- ii) number of cells remaining in proliferative pool (growth fraction), and
- iii) rate of loss of tumour cells by cell shedding.

In general, malignant tumour cells have increased mitotic rate (doubling time) and slower death rate i.e. the cancer cells do not follow normal controls in cell cycle and are immortal. If the rate of cell division is high, it is likely that tumour cells in the centre of the tumour do not receive adequate nourishment and undergo ischaemic necrosis.

2. Degree of differentiation. Secondly, the rate of growth of malignant tumour is directly proportionate to the degree of differentiation. Poorly differentiated tumours show aggressive growth pattern as compared to better differentiated tumours.

The regulation of tumour growth is under the control of growth factors secreted by the tumour cells e.g. epidermal growth factor (EGF), fibroblast growth factor (FGF), platelet-derived growth factor (PDGF), colony stimulating factor (CSF), transforming growth factors- β (TGF- β), interleukins (IL), vascular endothelial growth factor (VEGF).

□ II. CANCER PHENOTYPE AND STEM CELLS (p. 196)

Normally growing cells in an organ are related to the neighbouring cells—they grow under normal growth controls, perform their assigned function and there is a balance between the rate of cell proliferation and the rate of cell death including cell suicide (i.e. apoptosis). Thus normal cells are socially desirable. However, cancer cells exhibit anti-social behaviour as under:

- i) Cancer cells disobey the growth controlling signals in the body and thus *proliferate rapidly*.
- ii) Cancer cells escape death signals and achieve *immortality*.
- iii) Imbalance between cell proliferation and cell death in cancer causes *excessive growth*.
- iv) Cancer cells lose properties of differentiation and thus perform *little or no function*.
- v) Due to loss of growth controls, cancer cells are genetically unstable and develop *newer mutations*.
- vi) Cancer cells overrun their neighbouring tissue and *invade locally*.
- vii) Cancer cells have the ability to travel from the site of origin to other sites in the body where they colonise and establish *distant metastasis*.

Cancer cells originate by clonal proliferation of a single progeny of a cell (monoclonality). Cancer cells arise from stem cells normally present in the tissues in small number and are not readily identifiable.

□ III. CLINICAL AND GROSS FEATURES (p. 196)

Clinically, benign tumours are generally slow growing, and depending upon the location, may remain asymptomatic (e.g. subcutaneous lipoma), or may produce serious symptoms (e.g. meningioma in the nervous system). On the other hand, malignant tumours grow rapidly, may ulcerate on the surface, invade locally into deeper tissues, may spread to distant sites (metastasis), and also produce systemic features such as weight loss, anorexia and anemia. In fact, two of the cardinal clinical features of malignant tumours are: *invasiveness and metastasis*.

G/A Benign and malignant tumours may be quite variable and the features may not be diagnostic on the basis of gross appearance alone. However, certain distinctive features characterise almost all tumours compared to neighbouring normal tissue—they have a different colour, texture and consistency. Gross terms such as papillary, fungating, infiltrating, haemorrhagic, ulcerative and cystic are used to describe the macroscopic appearance of the tumours. General gross features of benign and malignant tumours are as under (**Figs. 8.2 and 8.3**):

◆ **Benign tumours** are generally spherical or ovoid in shape. They are encapsulated or well-circumscribed, freely movable, more often firm and uniform, unless secondary changes like haemorrhage or infarction supervene.

◆ **Malignant tumours**, on the other hand, are usually irregular in shape, poorly-circumscribed and extend into the adjacent tissues. Secondary changes like haemorrhage, infarction and ulceration are seen more often. Sarcomas typically have fish-flesh like consistency while carcinomas are generally firm.

□ IV. MICROSCOPIC FEATURES (p. 196)

For recognising and classifying the tumours, the microscopic characteristics of tumour cells are of greatest importance. These features which are appreciated in histologic sections are as under:

The tumour cells may be arranged in a variety of patterns in different tumours as under:

- ◆ The *epithelial tumours* generally consist of acini, sheets, columns or cords of epithelial tumour cells that may be arranged in solid or papillary pattern.
- ◆ The *mesenchymal tumours* have mesenchymal tumour cells arranged as interlacing bundles, fascicles or whorls, lying separated from each other usually by the intercellular matrix substance such as hyaline material in leiomyoma, cartilaginous matrix in chondroma, osteoid in osteosarcoma, reticulin network in soft tissue sarcomas etc.
- ◆ Certain tumours have *mixed patterns* e.g. teratoma arising from totipotent cells, pleomorphic adenoma of salivary gland (mixed salivary tumour), fibroadenoma of the breast, carcinosarcoma of the uterus and various other combinations of tumour types.
- ◆ *Haematopoietic tumours* such as leukaemias and lymphomas often have none or little stromal support.
- ◆ Generally, most benign tumours and low grade malignant tumours *reduplicate* the normal structure of origin more closely so that there is little difficulty in identifying and classifying such tumours. However, anaplastic tumours differ greatly from the arrangement in normal tissue of origin of the tumour and may occasionally pose problems in classifying the tumour.

2. Cytomorphology of Neoplastic Cells (Differentiation and Anaplasia) (p. 197)

The neoplastic cell is characterised by morphologic and functional alterations, the most significant of which are '*differentiation*' and '*anaplasia*'.

◆ **Differentiation** is defined as the extent of morphological and functional resemblance of parenchymal tumour cells to corresponding normal cells. If the deviation of neoplastic cell in structure and function is minimal as compared to normal cell, the tumour is described as '*well-differentiated*' such as most benign and low-grade malignant tumours. '*Poorly differentiated*', '*undifferentiated*' or '*dedifferentiated*' are synonymous terms for poor structural and functional resemblance to corresponding normal cell.

◆ **Anaplasia** is lack of differentiation and is a characteristic feature of most malignant tumours. Depending upon the degree of differentiation, the extent of anaplasia is also variable i.e. poorly differentiated malignant tumours have high degree of anaplasia.

As a result of anaplasia, noticeable morphological and functional alterations in the neoplastic cells are observed. These are considered below and are diagrammatically illustrated in **Web Image 8.4**:

i) *Loss of polarity*. Normally, the nuclei of epithelial cells are oriented along the basement membrane which is termed as basal polarity. This property is based on cell adhesion molecules, particularly selectins. Early in malignancy, tumour cells lose their basal polarity so that the nuclei tend to lie away from the basement membrane (**Web Image 8.5**).

ii) *Pleomorphism*. The term pleomorphism means variation in size and shape of the tumour cells. The extent of cellular pleomorphism generally correlates with the degree of anaplasia. Tumour cells are often bigger than normal but in some tumours they can be of normal size or smaller than normal (**Web Image 8.6**).

iii) *N:C ratio*. Generally, the nuclei of malignant tumour cells show more conspicuous changes. Nuclei are enlarged disproportionate to the cell size so that the nucleocytoplasmic ratio is increased from normal 1:5 to 1:1 (**Web Image 8.6**).

iv) *Anisonucleosis*. Just like cellular pleomorphism, the nuclei too, show variation in size and shape in malignant tumour cells (**Web Image 8.6**).

v) *Hyperchromatism*. Characteristically, the nuclear chromatin of malignant cell is increased and coarsely clumped. This is due to increase in the amount of nucleoprotein resulting in dark-staining nuclei, referred to as hyperchromatism (**Web Image 8.6**).

vi) *Nucleolar changes*. Malignant cells frequently have a prominent nucleolus or nucleoli in the nucleus reflecting increased nucleoprotein synthesis (**Web Image 8.6**). This may be demonstrated as Nucleolar Organiser Region (NOR) by silver (Ag) staining called AgNOR material.

vii) *Mitotic figures*. The parenchymal cells of poorly-differentiated tumours often show large number of mitoses as compared with benign tumours and well-differentiated malignant tumours. As stated above, these appear as either normal or abnormal mitotic figures (**Web Image 8.7**):

◆ *Normal mitotic figures* may be seen in some non-neoplastic proliferating cells (e.g. haematopoietic cells of the bone marrow, intestinal epithelium, hepatocytes etc), in certain benign tumours and some low grade malignant tumours; in sections they are seen as a dark band of dividing chromatin at two poles of the nuclear spindle.

◆ *Abnormal or atypical mitotic figures* are more important in malignant tumours and are identified as tripolar, quadripolar and multipolar spindles in malignant tumour cells.

viii) *Tumour giant cells*. Multinucleate tumour giant cells or giant cells containing a single large and bizarre nucleus, possessing nuclear characters of the adjacent tumour cells, are another important feature of anaplasia in malignant tumours (**Web Image 8.8**).

ix) *Functional (Cytoplasmic) changes*. Structural anaplasia in tumours is accompanied with functional anaplasia as appreciated from the cytoplasmic constituents of the tumour cells. The functional abnormality in neoplasms may be quantitative, qualitative, or both.

x) *Chromosomal abnormalities*. All tumour cells have abnormal genetic composition and on division they transmit the genetic abnormality to their progeny. The chromosomal abnormalities are more marked in more malignant tumours which include deviations in both morphology and number of chromosomes. Most malignant tumours show *DNA aneuploidy*, often in the form of an increase in the number of chromosomes, reflected morphologically by the increase in the size of nuclei.

One of the most important examples of a consistent chromosomal abnormality in human malignancy is the presence of Philadelphia chromosome (named after the city in which it was first described) in 95% cases of chronic myeloid leukaemia. In this, part of the long arm of chromosome 9 is translocated to part of the long arm of chromosome 22 (t 9; 22).

3. Tumour Angiogenesis and Stroma (p. 199)

The connective tissue along with its vascular network forms the supportive framework on which the parenchymal tumour cells grow and receive nourishment.

TUMOUR ANGIOGENESIS. In order to provide nourishment to growing tumour, new blood vessels are formed from pre-existing ones (angiogenesis). How this takes place under the influence of angiogenic factors elaborated by tumour cells such as vascular endothelium growth factor (VEGF) is discussed later under molecular pathogenesis of cancer. However, related morphologic features are as under:

i) *Microvascular density*. The new capillaries add to the vascular density of the tumour which has been used as a marker to assess the rate of growth of tumours and hence grade the tumours. This is done by counting microvascular density in the section of the tumour.

ii) *Central necrosis*. However, if the tumour outgrows its blood supply as occurs in rapidly growing tumours or tumour angiogenesis fails, its core undergoes ischaemic necrosis.

TUMOUR STROMA. The collagenous tissue in the stroma may be scanty or excessive. In the former case, the tumour is soft and fleshy (e.g. in sarcomas, lymphomas), while in the latter case the tumour is hard and gritty (e.g. infiltrating duct carcinoma breast). Growth of fibrous tissue in tumour is stimulated by basic fibroblast growth factor (bFGF) elaborated by tumour cells.

◆ If the epithelial tumour is almost entirely composed of parenchymal cells, it is called *medullary* e.g. medullary carcinoma of the breast (**Web Image 8.9, A**), medullary carcinoma of the thyroid.

◆ If there is excessive connective tissue stroma in the epithelial tumour, it is referred to as *desmoplasia* and the tumour is hard or *scirrhous* e.g. infiltrating duct carcinoma breast (**Web Image 8.9, B**), linitis plastica of the stomach.

4. Inflammatory Reaction (p. 199)

At times, prominent inflammatory reaction is present in and around the tumours. It could be the result of ulceration in the cancer when there is secondary infection. The inflammatory reaction in such instances may be acute or chronic. However, some tumours show chronic inflammatory reaction, chiefly of lymphocytes, plasma cells and macrophages, and in some instances granulomatous reaction, in the absence of ulceration. This is due to cell-mediated immunologic response by the host in an attempt to destroy the tumour. In some cases, such an immune response improves the prognosis.

The *examples* of such reaction are: seminoma testis (**Web Image 8.10**), malignant melanoma of the skin, lymphoepithelioma of the throat, medullary carcinoma of the breast, choriocarcinoma, Warthin's tumour of salivary glands etc.

□ V. LOCAL INVASION (DIRECT SPREAD) (p. 200)

BENIGN TUMOURS. Most benign tumours form encapsulated or circumscribed masses that *expand and push aside* the surrounding normal tissues without actually invading, infiltrating or metastasising.

MALIGNANT TUMOURS. Malignant tumours also enlarge by expansion and some well-differentiated tumours may be partially encapsulated as well e.g. follicular carcinoma thyroid. But characteristically, they are distinguished from benign tumours by *invasion, infiltration and destruction* of the surrounding tissue, besides distant metastasis (described below). In general, tumours invade via the route of least resistance, though eventually most cancers recognise no anatomic boundaries.

□ VI. METASTASIS (DISTANT SPREAD) (p. 200)

Metastasis (*meta* = transformation, *stasis* = residence) is defined as spread of tumour by invasion in such a way that discontinuous secondary tumour mass/masses are formed at the site of lodgement. *Metastasis and invasiveness are the two most important features to distinguish malignant from benign tumours*: benign tumours do not metastasise while all the malignant tumours with a few exceptions like gliomas of the central nervous system and basal cell carcinoma of the skin, can metastasise.

Routes of Metastasis (p. 200)

Cancers may spread to distant sites by following pathways:

1. Lymphatic spread
2. Haematogenous spread
3. Spread along body cavities and natural passages (Transcoelomic spread, along epithelium-lined surfaces, spread via cerebrospinal fluid, implantation).

1. LYMPHATIC SPREAD. *In general, carcinomas metastasise by lymphatic route while sarcomas favour haematogenous route.* However, sarcomas may also spread by lymphatic pathway. The involvement of lymph nodes by malignant cells may be of two forms:

i) *Lymphatic permeation.* The walls of lymphatics are readily invaded by cancer cells and may form a continuous growth in the lymphatic channels called lymphatic permeation.

ii) *Lymphatic emboli.* Alternatively, the malignant cells may detach to form tumour emboli so as to be carried along the lymph to the next draining lymph node. The tumour emboli enter the lymph node at its convex surface and are lodged in the subcapsular sinus where they start growing (**Web Image 8.11**). Later, of course, the whole lymph node may be replaced and enlarged by the metastatic tumour (**Web Image 8.12**).

◆ Generally, regional lymph nodes draining the tumour are invariably involved producing *regional nodal metastasis* e.g. from carcinoma breast to axillary lymph nodes, from carcinoma thyroid to lateral cervical lymph nodes, bronchogenic carcinoma to hilar and para-tracheal lymph nodes etc.

◆ However, all regional nodal enlargements are not due to nodal metastasis because necrotic products of tumour and antigens may also incite regional lymphadenitis of *sinus histiocytosis*.

◆ Sometimes lymphatic metastases do not develop first in the lymph node nearest to the tumour because of venous-lymphatic anastomoses or due to obliteration of lymphatics by inflammation or radiation, so called *skip metastasis*.

◆ Other times, due to obstruction of the lymphatics by tumour cells, the lymph flow is disturbed and tumour cells spread against the flow of lymph causing *retrograde metastases* at unusual sites e.g. metastasis of carcinoma prostate to the supraclavicular lymph nodes, metastatic deposits from bronchogenic carcinoma to the axillary lymph nodes.

◆ *Virchow's lymph node* is nodal metastasis preferentially to supraclavicular lymph node from cancers of abdominal organs e.g. cancer stomach, colon, and gall bladder.

2. HAEMATOGENOUS SPREAD. *Blood-borne metastasis is the common route for sarcomas but certain carcinomas also frequently metastasise by this mode,* especially those of the lung, breast, thyroid, kidney, liver, prostate and ovary. The sites where blood-borne metastasis commonly occurs are: the liver, lungs, brain, bones, kidney and adrenals, all of which provide 'good soil' for the growth of 'good seeds' (*seed-soil theory*). However, a few organs such as spleen, heart, and skeletal muscle generally do not allow tumour metastasis to grow. Spleen is unfavourable site due to open sinusoidal pattern which does not permit tumour cells to stay there long enough to produce metastasis. In general, only a proportion of cancer cells are capable of clonal proliferation in the proper environment; others die without establishing a metastasis.

◆ *Systemic veins* drain blood into vena cavae from limbs, head and neck and pelvis. Therefore, cancers of these sites more often metastasise to the lungs.

◆ *Portal veins* drain blood from the bowel, spleen and pancreas into the liver. Thus, tumours of these organs frequently have secondaries in the liver.

◆ *Arterial spread* of tumours is less likely because they are thick-walled and contain elastic tissue which is resistant to invasion. Nevertheless, arterial spread may occur when tumour cells pass through pulmonary capillary bed or through pulmonary arterial branches which have thin walls.

◆ *Retrograde spread* by blood route may occur at unusual sites due to retrograde spread after venous obstruction, just as with lymphatic metastases. Important examples are vertebral metastases in cancers of the thyroid and prostate.

G/A Blood-borne metastases in an organ appear as multiple, rounded nodules of varying size, scattered throughout the organ (**Web Image 8.13**). Sometimes, the metastasis may grow bigger than the primary tumour. At times, metastatic deposits may come to attention first without an evident primary tumour. In such cases search for primary tumour may be rewarding, but rarely the primary tumour may remain undetected or occult. Metastatic deposits just like primary tumour may cause further dissemination via lymphatics and blood vessels (**Web Image 8.14, A**).

M/E The secondary deposits generally reproduce the structure of primary tumour (**Web Image 8.14, B**). However, the same primary tumour on metastasis at different sites may show varying grades of differentiation, apparently due to the influence of local environment surrounding the tumour for its growth.

3. SPREAD ALONG BODY CAVITIES AND NATURAL PASSAGES.

Uncommonly, some cancers may spread by *seeding* across body cavities and natural passages.

i) Transcoelomic spread. Certain cancers invade through the serosal wall of the coelomic cavity so that tumour fragments or clusters of tumour cells break off to be carried in the coelomic fluid and are implanted elsewhere in the body cavity. Peritoneal cavity is involved most often, but occasionally pleural and pericardial cavities are also affected. A few examples of transcoelomic spread are as follows:

- a) *Carcinoma of the stomach* seeding to both ovaries (Krukenberg tumour).
- b) *Carcinoma of the ovary* spreading to the entire peritoneal cavity without infiltrating the underlying organs.
- c) *Pseudomyxoma peritonei* is the gelatinous coating of the peritoneum from mucin-secreting carcinoma of the ovary or appendix.

ii) Spread along epithelium-lined surfaces. It is unusual for a malignant tumour to spread along the epithelium-lined surfaces because intact epithelium and mucus coat are quite resistant to penetration by tumour cells. However, exceptionally a malignant tumour may spread through:

- a) the fallopian tube from the endometrium to the ovaries or *vice-versa*;
- b) through the bronchus into alveoli; and
- c) through the ureters from the kidneys into lower urinary tract.

iii) Spread via cerebrospinal fluid. Malignant tumour of the ependyma and leptomeninges may spread by release of tumour fragments and tumour cells into the CSF and produce metastases at other sites in the central nervous system.

iv) Implantation. Rarely, a tumour may spread by implantation by surgeon's scalpel, needles, sutures, or may be implanted by direct contact such as transfer of cancer of the lower lip to the apposing upper lip.

MECHANISM AND BIOLOGY OF INVASION AND METASTASIS (p. 203)

The process of local invasion and distant spread by lymphatic and haematogenous routes discussed above involves passage through barriers before gaining access to the vascular lumen. This includes making the passage by the cancer cells by dissolution of extracellular matrix (ECM) at three levels—at the basement membrane of tumour itself, at the level of interstitial connective tissue, and at the basement membrane of microvasculature. The following steps are involved at the molecular level which are schematically illustrated in **Web Image 8.15**.

1. Aggressive clonal proliferation and angiogenesis. The first step in the spread of cancer cells is the development of rapidly proliferating clone of cancer cells. This is explained on the basis of *tumour heterogeneity*, i.e. in the population of monoclonal tumour cells, a subpopulation or clone of tumour cells has the right biologic characteristics to complete the steps

involved in the development of metastasis. Tumour angiogenesis plays a very significant role in metastasis since the new vessels formed as part of growing tumour are more vulnerable to invasion as these evolving vessels are directly in contact with cancer cells.

2. Tumour cell loosening. Normal cells remain glued to each other due to presence of cell adhesion molecules (CAMs) i.e. E (epithelial)-cadherin. In epithelial cancers, there is either loss or inactivation of E-cadherin and also other CAMs of immunoglobulin superfamily, all of which results in loosening of cancer cells.

3. Tumour cell-ECM interaction. Loosened cancer cells are now attached to ECM proteins, mainly *laminin* and *fibronectin*. This attachment is facilitated due to profoundness of receptors on the cancer cells for both these proteins. There is also loss of *integrins*, the transmembrane receptors, further favouring invasion.

4. Degradation of ECM. Tumour cells overexpress *proteases* and matrix-degrading enzymes, *metalloproteinases*, that includes collagenases and gelatinase, while the inhibitors of metalloproteinases are decreased. Another protease, cathepsin D, is also increased in certain cancers. These enzymes bring about dissolution of ECM—firstly basement membrane of tumour itself, then make way for tumour cells through the interstitial matrix, and finally dissolve the basement membrane of the vessel wall.

5. Entry of tumour cells into capillary lumen. The tumour cells after degrading the basement membrane are ready to migrate into lumen of capillaries or venules for which the following mechanisms play a role:

- i) *Autocrine motility factor (AMF)* is a cytokine derived from tumour cells and stimulates receptor-mediated motility of tumour cells.
- ii) *Cleavage products of matrix components* which are formed following degradation of ECM have properties of tumour cell chemotaxis, growth promotion and angiogenesis in the cancer.

6. Thrombus formation. The tumour cells protruding in the lumen of the capillary are now covered with constituents of the circulating blood and form the thrombus. Thrombus provides nourishment to the tumour cells and also protects them from the immune attack by the circulating host cells. In fact, normally a large number of tumour cells are released into circulation but they are attacked by the host immune cells. Actually a very small proportion of malignant cells (less than 0.1%) in the blood stream survive to develop into metastasis.

7. Extravasation of tumour cells. Tumour cells in the circulation (capillaries, venules, lymphatics) may mechanically block these vascular channels and attach to vascular endothelium. In this way, the sequence similar to local invasion is repeated and the basement membrane is exposed.

8. Survival and growth of metastatic deposit. The extravasated malignant cells on lodgement in the right environment grow further under the influence of growth factors produced by host tissues, tumour cells and by cleavage products of matrix components. These growth factors in particular include: PDGF, FGF, TGF- β and VEGF. The metastatic deposits grow further if the host immune defense mechanism fails to eliminate it.

□ GRADING AND STAGING OF CANCER (p. 204)

'Grading' and 'staging' are the two systems to predict tumour behaviour and guide therapy after a malignant tumour is detected. *Grading is defined as the gross and microscopic degree of differentiation of the tumour, while staging means extent of spread of the tumour within the patient.* Thus, grading is histologic while staging is clinical.

Cancers may be graded grossly and microscopically. Gross features like exophytic or fungating appearance are indicative of less malignant growth than diffusely infiltrating tumours. However, grading is largely based on 2 important histologic features: *the degree of anaplasia, and the rate of growth*. Based on these features, cancers are categorised from grade I as the most differentiated, to grade III or IV as the most undifferentiated or anaplastic. Many systems of grading have been proposed but the one described by *Broders* for dividing squamous cell carcinoma into 4 grades depending upon the degree of differentiation is followed for other malignant tumours as well.

However, grading of tumours has several shortcomings. It is subjective and the degree of differentiation may vary from one area of tumour to the other. Therefore, it is common practice with pathologists to grade cancers in descriptive terms (e.g. well-differentiated, undifferentiated, keratinising, non-keratinising etc) rather than giving the tumours grade numbers.

More objective criteria for histologic grading include use of flow cytometry for mitotic cell counts, cell proliferation markers by immunohistochemistry, and by applying image morphometry for cancer cell and nuclear parameters.

Staging (p. 205)

The extent of spread of cancers can be assessed by 3 ways—by clinical examination, by investigations, and by pathologic examination of the tissue removed. Two important staging systems currently followed are: TNM staging and AJC staging.

TNM staging. (T for primary tumour, N for regional nodal involvement, and M for distant metastases) was developed by the UICC (Union Internationale Contre Cancer, Geneva). For each of the 3 components namely T, N and M, numbers are added to indicate the extent of involvement, as under:

T_0 to T_4 : In situ lesion to largest and most extensive primary tumour.

N_0 to N_3 : No nodal involvement to widespread lymph node involvement.

M_0 to M_2 : No metastasis to disseminated haematogenous metastases.

AJC staging. American Joint Committee staging divides all cancers into stage 0 to IV, and takes into account all the 3 components of the preceding system (primary tumour, nodal involvement and distant metastases) in each stage.

TNM and AJC staging systems can be applied for staging most malignant tumours.

EPIDEMIOLOGY AND PREDISPOSITION TO NEOPLASIA (p. 205)

□ CANCER INCIDENCE (p. 205)

Worldwide, it is estimated that about 20% of all deaths are cancer-related. There have been changing patterns in incidence of cancers in both the sexes and in different geographic locations as outlined below. **Web Table 8.3** shows worldwide incidence (in descending order) of different forms of cancer in men, women, and children.

In general, most common cancers in the developed and developing countries are as under:

◆ *Developed world:* lung, breast, prostate and colorectal.

◆ *Developing world:* liver, cervical and oesophageal.

Overall, there has been a declining trend in incidence of some of the cancers due to cancer screening programmes for cervical, breast, colorectal and prostate cancer.

□ EPIDEMIOLOGIC FACTORS (p. 205)

It is widely known that no single factor is responsible for development of tumours. The role of some factors in causation of neoplasia is established while that of others is epidemiological and many others are still unknown.

A. Predisposing Factors (p. 205)

1. FAMILIAL AND GENETIC FACTORS. It has long been suspected that familial predisposition and heredity play a role in the development of cancers. In general, the risk of developing cancer in relatives of a known cancer patient is almost three times higher as compared to control subjects. Some of the cancers with familial occurrence are colon, breast, ovary, brain and melanoma. Familial cancers occur at a relatively early age, appear at multiple sites and occur in 2 or more close relatives. The overall estimates suggest that genetic cancers comprise not greater than 5% of all cancers. Some of the common examples are as under:

i) Retinoblastoma. About 40% of retinoblastomas are familial and show an autosomal dominant inheritance. Carriers of such genetic composition have 10,000 times higher risk of developing retinoblastoma which is often bilateral. Such patients are predisposed to develop another primary malignant tumour, notably osteogenic sarcoma.

Familial form of retinoblastoma is due to missing of a portion of chromosome 13 where *RB* gene is normally located.

ii) Familial polyposis coli. This condition has autosomal dominant inheritance. The polypoid adenomas may be seen at birth or in early age. By the age of 50 years, almost 100% cases of familial polyposis coli develop cancer of the colon.

iii) Multiple endocrine neoplasia (MEN). A combination of adenomas of pituitary, parathyroid and pancreatic islets (MEN-I) or syndrome of medullary carcinoma thyroid, pheochromocytoma and parathyroid tumour (MEN-II) are encountered in families.

iv) Neurofibromatosis or von Recklinghausen's disease. This condition is characterised by multiple neurofibromas and pigmented skin spots (*cafe au lait spots*). These patients have family history consistent with autosomal dominant inheritance in 50% of patients.

v) Cancer of the breast. Female relatives of breast cancer patients have 2 to 6 times higher risk of developing breast cancer. Inherited breast cancer comprises about 5-10% of all breast cancers. As discussed later, there are two breast cancer susceptibility genes, *BRCA-1* and *BRCA-2*.

vi) DNA-chromosomal instability syndromes. These are a group of pre-neoplastic conditions having defect in DNA repair mechanism. A classical example is xeroderma pigmentosum, an autosomal recessive disorder, characterised by extreme sensitivity to ultraviolet radiation. The patients may develop various types of skin cancers such as basal cell carcinoma, squamous cell carcinoma and malignant melanoma.

2. RACIAL AND GEOGRAPHIC FACTORS. Differences in racial incidence of some cancers may be partly attributed to the role of genetic composition but are largely due to influence of the environment and geographic differences affecting the whole population such as climate, soil, water, diet, habits, customs etc. Some of the examples of racial and geographic variations in various cancers are as under:

i) White Europeans and Americans develop most commonly malignancies of the lung, breast, and colon. Liver cancer is uncommon in these races. Breast cancer is uncommon in Japanese women but is more common in American women.

ii) Black Africans, on the other hand, have more commonly cancers of the skin, penis, cervix and liver.

- iii) **Japanese** have five times higher incidence of carcinoma of the stomach than the Americans.
- iv) **South-East Asians**, especially of Chinese origin develop nasopharyngeal cancer more commonly.
- v) **Indians** of both sexes have higher incidence of carcinoma of the oral cavity and upper aerodigestive tract, while in females carcinoma of uterine cervix and of the breast run parallel in incidence. Cancer of the liver in India is more often due to viral hepatitis (HBV and HCV) and subsequent cirrhosis, while in western populations it is more often due to alcoholic cirrhosis.

3. ENVIRONMENTAL AND CULTURAL FACTORS. Some of the examples are given below:

i) **Cigarette smoking** is the single most important environmental factor implicated in the etiology of cancer of the oral cavity, pharynx, larynx, oesophagus, lungs, pancreas and urinary bladder.

ii) **Alcohol abuse** predisposes to the development of cancer of oropharynx, larynx, oesophagus and liver.

iii) **Alcohol and tobacco together** further accentuate the risk of developing cancer of the upper aerodigestive tract.

iv) **Cancer of the cervix** is linked to a number of factors such as age at first coitus, frequency of coitus, multiplicity of partners, parity etc. Sexual partners of circumcised males have lower incidence of cervical cancer than the partners of uncircumcised males.

v) **Penile cancer** is rare in the Jews and Muslims as they are customarily circumcised. Carcinogenic component of smegma appears to play a role in the etiology of penile cancer.

vi) **Betel nut cancer** of the cheek and tongue is quite common in some parts of India due to habitual practice of keeping the bolus of *paan* in a particular place in mouth for a long time.

vii) A large number of **industrial and environmental substances** are carcinogenic and are occupational hazard for some populations. These include exposure to substances like arsenic, asbestos, benzene, vinyl chloride, naphthylamine etc.

viii) **Certain constituents of diet** have also been implicated in the causation of cancer. Overweight individuals, deficiency of vitamin A and people consuming diet rich in animal fats and low in fibre content are more at risk of developing certain cancers such as colonic cancer. Diet rich in vitamin E, on the other hand, possibly has some protective influence by its antioxidant action.

4. AGE. The most significant risk factor for cancer is age. Generally, cancers occur in older individuals past 5th decade of life (two-third of all cancers occur above 65 years of age), though there are variations in age incidence in different forms of cancers. Some tumours have two peaks of incidence e.g. acute leukaemias occur in children and in older age group. Besides acute leukaemias, *other tumours in infancy and childhood* are: neuroblastoma, nephroblastoma (Wilms' tumour), retinoblastoma, hepatoblastoma, rhabdomyosarcoma, Ewing's sarcoma, teratoma and CNS tumours.

5. SEX. Apart from the malignant tumours of organs peculiar to each sex, most tumours are generally more common in men than in women except cancer of the breast, gall bladder, thyroid and hypopharynx. Although there are geographic and racial variations, *cancer of the breast* is the commonest cancer in *women* throughout the world while *lung cancer* is the commonest cancer in *men*.

B. Chronic Non-neoplastic (Pre-malignant) Conditions (p. 207)

Premalignant lesions are a group of conditions which predispose to the subsequent development of cancer. Many of these conditions are charac-

terised by morphologic changes in the cells such as increased nuclear-cytoplasmic ratio, pleomorphism of cells and nuclei, increased mitotic activity, poor differentiation, and sometimes accompanied by chronic inflammatory cells.

1. Carcinoma *in situ* (intraepithelial neoplasia). When the cytological features of malignancy are present but the malignant cells are confined to epithelium without invasion across the basement membrane, it is called as carcinoma *in situ* or intraepithelial neoplasia (CIN). The common sites are as under:

- i) Uterine cervix at the junction of ecto- and endocervix (**Web Image 8.16**)
- ii) Bowen's disease of the skin
- iii) Actinic or solar keratosis
- iv) Oral leukoplakia
- v) Intralobular and intraductal carcinoma of the breast.

The area involved in carcinoma *in situ* may be single and small, or multifocal. As regards the behaviour of CIN, it may regress and return to normal or may develop into invasive cancer. In some instances such as in cervical cancer, there is a sequential transformation from squamous metaplasia, to epithelial dysplasia, to carcinoma *in situ*, and eventually to invasive cancer.

2. Some benign tumours. Commonly, benign tumours do not become malignant. However, there are some exceptions e.g.

- i) Multiple villous adenomas of the large intestine have high incidence of developing adenocarcinoma.
- ii) Neurofibromatosis (von Recklinghausen's disease) may develop into sarcoma.

3. Miscellaneous conditions. Certain inflammatory and hyperplastic conditions are prone to development of cancer, e.g.

- i) Patients of long-standing ulcerative colitis are predisposed to develop colorectal cancer.
- ii) Cirrhosis of the liver has predisposition to develop hepatocellular carcinoma.
- iii) Chronic bronchitis in heavy cigarette smokers may develop cancer of the bronchus.
- iv) Chronic irritation from jagged tooth or ill-fitting denture may lead to cancer of the oral cavity.
- v) Squamous cell carcinoma developing in an old burn scar (Marjolin's ulcer).

C. Hormones and Cancer (p. 207)

Cancer is more likely to develop in organs and tissues which undergo proliferation under the influence of excessive hormonal stimulation. On cessation of hormonal stimulation, such tissues become atrophic. Hormone-sensitive tissues developing tumours are the breast, endometrium, myometrium, vagina, thyroid, liver, prostate and testis. Some examples of hormones influencing carcinogenesis in experimental animals and humans are given below:

1. OESTROGEN. Examples of oestrogen-induced cancers are as under:

- i) In experimental animals.** Induction of breast cancer in mice by administration of high-dose of oestrogen and reduction of the tumour development following oophorectomy is the most important example. It has been known that associated infection with mouse mammary tumour virus (MMTV, *Bittner milk factor*) has an added influence on the development of breast cancer in mice.

ii) **In humans.** Women receiving oestrogen therapy and women with oestrogen-secreting granulosa cell tumour of the ovary have increased risk of developing endometrial carcinoma. Adenocarcinoma of the vagina is seen with increased frequency in adolescent daughters of mothers who had received oestrogen therapy during pregnancy.

2. CONTRACEPTIVE HORMONES. The sequential types of oral contraceptives increase the risk of developing breast cancer.

3. ANABOLIC STEROIDS. Consumption of anabolic steroids by athletes to increase the muscle mass is not only unethical athletic practice but also increases the risk of developing benign and malignant tumours of the liver.

4. HORMONE-DEPENDENT TUMOURS. It has been shown in experimental animals that induction of hyperfunction of adenohypophysis is associated with increased risk of developing neoplasia of the target organs following preceding functional hyperplasia. There is tumour regression on removal of the stimulus for excessive hormonal secretion. A few examples of such phenomena are seen in humans:

- i) *Prostatic cancer* usually responds to the administration of oestrogens.
- ii) *Breast cancer* may regress with oophorectomy, hypophysectomy or on administration of male hormones.
- iii) *Thyroid cancer* may slow down in growth with administration of thyroxine that suppresses the secretion of TSH by the pituitary.

CARCINOGENESIS: ETIOLOGY AND PATHOGENESIS OF CANCER (p. 208)

Carcinogenesis or oncogenesis or tumorigenesis means mechanism of induction of tumours (*pathogenesis of cancer*); agents which can induce tumours are called *carcinogens (etiology of cancer)*.

The subject of etiology and pathogenesis of cancer is discussed under the following 4 broad headings:

- A. Molecular pathogenesis of cancer (genes and cancer)
- B. Chemical carcinogens and chemical carcinogenesis
- C. Physical carcinogens and radiation carcinogenesis
- D. Biologic carcinogens and viral oncogenesis.

□ **A. MOLECULAR PATHOGENESIS OF CANCER (GENETIC MECHANISMS OF CANCER) (p. 208)**

Basic Concept of Molecular Pathogenesis (p. 208)

The general concept of molecular mechanisms of cancer is briefly outlined below and diagrammatically shown in **Web Image 8.17**.

1. Monoclonality of tumours. There is strong evidence to support that most human cancers arise from a single clone of cells by genetic transformation or mutation. For example:

- i) In a case of multiple myeloma (a malignant disorder of plasma cells), there is production of a single type of immunoglobulin or its chain as seen by monoclonal spike in serum electrophoresis.
- ii) Due to inactivation of one of the two X-chromosomes in females (paternal or maternal derived), women are mosaics with two types of cell populations for glucose-6-phosphatase dehydrogenase (G6PD) isoenzyme A and B. It is observed that all the tumour cells in benign uterine tumours (leiomyoma) contain either A or B genotype of G6PD (i.e. the tumour cells are derived from a single progenitor clone of cell), while the normal myometrial cells are mosaic of both types of cells derived from A as well as B isoenzyme (**Web Image 8.18**).

2. Field theory of cancer. In an organ developing cancer, in the backdrop of normal cells, limited number of cells only grow in to cancer after undergoing

sequence of changes under the influence of etiologic agents. This is termed as 'field effect' and the concept called as field theory of cancer.

3. Multi-step process of cancer growth and progression. Carcinogenesis is a gradual multi-step process involving many generations of cells. The various causes may act on the cell one after another (*multi-hit process*). The same process is also involved in further progression of the tumour. Ultimately, the cells so formed are genetically and phenotypically transformed cells having phenotypic features of malignancy—excessive growth, invasiveness and distant metastasis.

4. Genetic theory of cancer. Cell growth of normal as well as abnormal types is under genetic control. In cancer, there are either genetic abnormalities in the cell, or there are normal genes with abnormal expression. The abnormalities in genetic composition may be from inherited or induced mutations (induced by etiologic carcinogenic agents namely: chemicals, viruses, radiation). The mutated cells transmit their characters to the next progeny of cells and result in cancer.

5. Genetic regulators of normal and abnormal mitosis. In normal cell growth, regulatory genes control mitosis as well as cell aging, terminating in cell death by apoptosis.

◆ **In normal cell growth**, there are 4 regulatory genes:

- i) *Proto-oncogenes* are growth-promoting genes i.e. they encode for cell proliferation pathway.
- ii) *Anti-oncogenes* are growth-inhibiting or growth suppressor genes.
- iii) *Apoptosis regulatory genes* control the programmed cell death.
- iv) *DNA repair genes* are those normal genes which regulate the repair of DNA damage that has occurred during mitosis and also control the damage to proto-oncogenes and anti-oncogenes.

◆ **In cancer**, the transformed cells are produced by abnormal cell growth due to genetic damage to these normal controlling genes. Thus, corresponding abnormalities in these 4 cell regulatory genes are as under:

- i) *Activation of growth-promoting oncogenes* causing transformation of cell (mutant form of normal proto-oncogene in cancer is termed *oncogene*). Many of these cancer associated genes, oncogenes, were first discovered in viruses, and hence named as *v-onc*. Gene products of oncogenes are called *oncoproteins*. Oncogenes are considered *dominant* since they appear in spite of presence of normal proto-oncogenes.
- ii) *Inactivation of cancer-suppressor genes* (i.e. inactivation of anti-oncogenes) permitting the cellular proliferation of transformed cells. Anti-oncogenes are active in *recessive* form i.e. they are active only if both alleles are damaged.
- iii) *Abnormal apoptosis regulatory genes* which may act as oncogenes or anti-oncogenes. Accordingly, these genes may be active in dominant or recessive form.
- iv) *Failure of DNA repair genes* and thus inability to repair the DNA damage resulting in mutations.

Cancer-related Genes and Cell Growth (Hallmarks of Cancer) (p. 209)

It is apparent from the above discussion that genes control the normal cellular growth, while in cancer these controlling genes are altered, typically by mutations. A large number of such cancer-associated genes have been described, each with a specific function in cell growth. Some of these genes are commonly associated in many tumours (e.g. *p53* or *TP53*), while others are specific to particular tumours. Therefore, it is considered appropriate to discuss the role of cancer-related genes with regard to their functions in cellular growth. Following are the *major genetic properties or hallmarks of cancer*:

These properties of cancer cells are described below in terms of molecular genetics and schematically illustrated in **Web Image 8.19**.

Mutated form of normal protooncogenes in cancer is called oncogenes. Protooncogenes become activated oncogenes by following mechanisms as under:

- ◆ By mutation in the protooncogene which alters its structure and function.
- ◆ By retroviral insertion in the host cell.
- ◆ By damage to the DNA sequence that normally regulates growth-promoting signals of protooncogenes resulting in its abnormal activation.
- ◆ By erroneous formation of extra copies of protooncogene causing gene amplification and hence its overexpression or overproduction that promotes autonomous and excessive cellular proliferation.

In general, overactivity of oncogenes enhances cell proliferation and promotes development of human cancer. About 100 different oncogenes have been described in various cancers. Transformation of proto-oncogene (i.e. normal cell proliferation gene) to oncogenes (i.e. cancer cell proliferation gene) may occur by three mechanisms:

- i) *Point mutations* i.e. an alteration of a single base in the DNA chain.
- ii) *Chromosomal translocations* i.e. transfer of a portion of one chromosome carrying protooncogene to another chromosome, e.g. Philadelphia chromosome seen in 95% cases of chronic myelogenous leukaemia in which *c-ABL* protooncogene on chromosome 9 is translocated to chromosome 22.
- iii) *Gene amplification* i.e. increasing the number of copies of DNA sequence in protooncogene.

Possible effects of oncogenes in signal transduction for cell proliferation in human tumours are discussed below in relation to the role of protooncogenes in mitosis in normal cell cycle and are listed in **Web Table 8.4** and schematically shown in **Web Image 8.20**:

i) Growth factors (GFs). GFs were the first protooncogenes to be discovered which encode for cell proliferation cascade.

A cancer cell may synthesise a GF and respond to it as well; this way cancer cells acquire growth self-sufficiency. The examples of such tumour secreted GFs are as under:

- a) *Platelet-derived growth factor- (PDGF- β)*
- b) *Transforming growth factor- α (TGF- α)*
- c) *Fibroblast growth factor (FGF)*
- d) *Hepatocyte growth factor (HGF).*

ii) Receptors for GFs. Growth factors cannot penetrate the cell directly and require to be transported intracellularly by GF-specific cell surface receptors. These receptors are transmembrane proteins and thus have two surfaces: the outer surface of the membrane has an area for binding growth factor, and the inner surface of the membrane has enzyme-activating area which eventually activates cell proliferation pathway.

Examples of tumours by mutated receptors for growth factors are as under:

- a) *EGF receptors*
- b) *c-KIT receptor*
- c) *RET receptor*

iii) Cytoplasmic signal transduction proteins. The normal signal transduction proteins in the cytoplasm transduce signal from the GF receptors present on the cell surface, to the nucleus of the cell, to activate intracellular growth signaling pathways.

There are examples of oncogenes having mutated forms of cytoplasmic signaling pathways located in the inner surface of cell membrane in some cancers. These are as under:

- a) *Mutated RAS gene.*
- b) *BCR-ABL hybrid gene.*

iv) Nuclear transcription factors. The signal transduction pathway that started with GFs ultimately reaches the nucleus where it regulates DNA transcription and induces the cell to enter into S phase. Out of various nuclear regulatory transcription proteins described, the most important is *MYC* gene located on long arm of chromosome 8.

The examples of tumours carrying *MYC* oncogene are as under:

- a) *C-MYC oncogene*
- b) *N-MYC oncogene*
- c) *L-MYC oncogene*.

v) Cell cycle regulatory proteins. Normally the cell cycle is under regulatory control of cyclins and cyclin-dependent kinases (CDKs) A, B, E and D. Cyclins are so named since they are cyclically synthesised during different phases of the cell cycle and their degradation is also cyclic.

The examples of tumours having such oncogenes are as under:

- a) *Mutated form of cyclin D* protooncogene.
- b) *Mutated form of cyclin E*.
- b) *Mutated form of CDK4*.

2. REFRACTORINESS TO GROWTH INHIBITION: GROWTH SUPPRESSING ANTI-ONCOGENES

The mutation of normal growth suppressor anti-oncogenes results in removal of the brakes for growth; thus the inhibitory effect to cell growth is removed and the abnormal growth continues unchecked. In other words, mutated anti-oncogenes behave like growth-promoting oncogenes.

As compared to the signals and signal transduction pathways for oncogenes described above, the steps in mechanisms of action by growth suppressors are not so well understood. In general, the point of action by anti-oncogenes is also G1 → S phase transition and probably act either by inducing the dividing cell from the cell cycle to enter into G0 (resting) phase, or by acting in a way that the cell lies in the post-mitotic pool losing its dividing capability.

Major anti-oncogenes implicated in human cancers are as under (**Web Table 8.5**):

i) *RB* gene. *RB* gene is located on long arm (q) of chromosome 13. *RB* gene is termed as master 'break' in the cell cycle and is virtually present in every human cell. It can exist in both an *active* and an *inactive* form:

◆ The *active form* of *RB* gene blocks cell division by binding to transcription factor.

◆ *Inactive form* of *RB* gene occurs when it is hyperphosphorylated by cyclin dependent kinases (CDKs) which occurs when growth factors bind to their receptors. This removes pRB function from the cell (i.e. the 'break' on cell division is removed) and thus cell proliferation pathway is stimulated by permitting the cell to cross G1 → S phase.

The mutant form of *RB* gene (i.e. inactivating mutation of *RB* gene) is involved in several human tumours, most commonly in retinoblastoma, the most common intraocular tumour in young children. The tumour occurs in two forms: sporadic and inherited/familial. Besides retinoblastoma, children inheriting mutant *RB* gene have 200 times greater risk of development of other cancers in early adult life, most notably osteosarcoma; others are cancers of breast, colon and lungs.

ii) *p53* gene (*TP53*). Located on the short arm (p) of chromosome 17, *p53* gene (also termed *TP53* because of molecular weight of 53 kd for the protein) like *pRB* is inhibitory to cell cycle.

The two major functions of *p53* in the normal cell cycle are as under:

- a) *In blocking mitotic activity*.
- b) *In promoting apoptosis*.

Because of these significant roles in cell cycle, *p53* is called as 'protector of the genome'. In its mutated form *p53* ceases to act as protector or as growth suppressor but instead acts like a growth promoter or oncogene.

iii) **Transforming growth factor- β ($TGF-\beta$) and its receptor.** Normally, $TGF-\beta$ is significant inhibitor of cell proliferation, especially in epithelial, endothelial and haematopoietic cells. It acts by binding to $TGF-\beta$ receptor and then the complex so formed acts in G1 phase of cell cycle at two levels:

- ◆ It activates CDK inhibitors (CDKIs) with growth inhibitory effect.
- ◆ It suppresses the growth promoter genes such as *MYC*, *CDKs* and cyclins.

Mutant form of $TGF-\beta$ gene or its receptor impairs the growth inhibiting effect and thus permits cell proliferation. Examples of mutated form of $TGF-\beta$ are seen in cancers of pancreas, colon, stomach and endometrium.

iv) **Adenomatous polyposis coli (APC) gene and β -catenin protein.** The *APC* gene is normally inhibitory to mitosis, which takes place by a cytoplasmic protein, β -catenin. β -catenin normally has dual functions: firstly, it binds to cytoplasmic E-cadherin that is involved in intercellular interactions, and secondly it can activate cell proliferation signaling pathway. In colon cancer cells, *APC* gene is lost and thus β -catenin fails to get degraded, allowing the cancer cells to undergo mitosis without the inhibitory influence of β -catenin.

Patients born with one mutant *APC* gene allele develop large number of polyps in the colon early in life, while after the age of 20 years these cases start developing loss of second *APC* gene allele. It is then that almost all these patients invariably develop malignant transformation of one or more polyps.

v) **Other antioncogenes.** A few other tumour-suppressor genes having mutated germline in various tumours are as under:

a) ***BRCA 1 and BRCA 2 genes:*** These are two breast (*BR*) cancer (*CA*) susceptibility genes: *BRCA1* located on chromosome 17q21 and *BRCA2* on chromosome 13q12-13. Women with inherited defect in *BRCA1* gene have very high risk (85%) of developing breast cancer and ovarian cancer (40%). Inherited breast cancer constitutes about 5-10% cases, it tends to occur at a relatively younger age and more often tends to be bilateral.

b) ***VHL gene.*** von-Hippel-Lindau (*VHL*) disease is a rare autosomal dominant disease characterised by benign and malignant tumours of multiple tissues. The disease is inherited as a mutation in *VHL* tumour suppressor gene located on chromosome 3p. This results in activation of genes that promote angiogenesis, survival and proliferation; *VHL* gene is found inactivated in 60% cases of renal cell carcinoma.

c) ***Wilms' tumour (WT) gene:*** Both *WT1* and *WT2* genes are located on chromosome 11 and normally prevent neoplastic proliferation of cells in embryonic kidney. Mutant form of *WT-1* and *2* are seen in hereditary Wilms' tumour.

d) ***Neurofibroma (NF) gene:*** *NF* genes normally prevent proliferation of Schwann cells. Two mutant forms are described: *NF1* and *NF2* seen in neurofibromatosis type 1 and type 2.

The contrasting features of growth-promoting oncogenes and growth-suppressing anti-oncogenes are summarised in **Web Table 8.6**.

3. ESCAPING CELL DEATH BY APOPTOSIS:

GENES REGULATING APOPTOSIS AND CANCER

Besides the role of mutant forms of growth-promoting oncogenes and growth-suppressing anti-oncogenes, another mechanism of tumour growth is by escaping cell death by apoptosis. Apoptosis in normal cell is guided by cell death receptor, CD95, resulting in DNA damage. Besides, there is role of some other pro-apoptotic factors (*BAD*, *BAX*, *BID* and *p53*) and apoptosis-inhibitors (*BCL2*, *BCL-X*).

In cancer cells, the function of apoptosis is interfered due to mutations in the above genes which regulate apoptosis in the normal cell. The examples of tumours by this mechanism are as under:

- a) **BCL2 gene** is seen in normal lymphocytes, but its mutant form with characteristic translocation (t14;18) (q32;q21) was first described in B-cell lymphoma and hence the name BCL. It is also seen in many other human cancers such as that of breast, thyroid and prostate. Mutation in **BCL2** gene removes the apoptosis-inhibitory control on cancer cells, thus more live cells undergoing mitosis contributing to tumour growth.
- b) **CD95** receptors are depleted in hepatocellular carcinoma and hence the tumour cells escape apoptosis.

4. AVOIDING CELLULAR AGING: TELOMERES AND TELOMERASE IN CANCER

After each mitosis (cell doubling) there is progressive shortening of telomeres which are the terminal tips of chromosomes. Telomerase is the RNA enzyme that helps in repair of such damage to DNA and maintains normal telomere length in successive cell divisions. However, it has been seen that after repetitive mitosis for a maximum of 60 to 70 times, telomeres are lost in normal cells and the cells cease to undergo mitosis.

Cancer cells in most malignancies have markedly upregulated telomerase enzyme, and hence telomere length is maintained. Thus, cancer cells avoid aging, mitosis does not slow down or cease, thereby immortalising the cancer cells.

5. CONTINUED PERFUSION OF CANCER: TUMOUR ANGIOGENESIS

Cancers can only survive and thrive if the cancer cells are adequately nourished and perfused, as otherwise they cannot grow further. Neovascularisation in the cancers not only supplies the tumour with oxygen and nutrients, but the newly formed endothelial cells also elaborate a few growth factors for progression of primary as well as metastatic cancer. The stimulus for angiogenesis is provided by the release of various factors:

i) Promoters of tumour angiogenesis include the most important *vascular endothelial growth factor (VEGF)* (released from genes in the parenchymal tumour cells) and *basic fibroblast growth factor (bFGF)*.

ii) Anti-angiogenesis factors inhibiting angiogenesis include *thrombospondin-1* (also produced by tumour cells themselves), *angiostatin*, *endostatin* and *vasculostatin*. Mutated form of *p53* gene in both alleles in various cancers results in removal of anti-angiogenic role of thrombospondin-1, thus favouring continued angiogenesis.

6. INVASION AND DISTANT METASTASIS: CANCER DISSEMINATION

One of the most important characteristic of cancers is invasiveness and metastasis. The mechanisms involved in the biology of invasion and metastasis are discussed already along with spread of tumours.

7. DNA DAMAGE AND REPAIR SYSTEM: MUTATOR GENES AND CANCER

Normal cells during complex mitosis suffer from minor damage to the DNA which is detected and repaired before mitosis is completed so that integrity of the genome is maintained. Similarly, small mutational damage to the dividing cell by exogenous factors (e.g. by radiation, chemical carcinogens etc) is also repaired. *p53* gene is held responsible for detection and repair of DNA damage. However, if this system of DNA repair is defective as happens in some inherited mutations (mutator genes), the defect in unrepaired DNA is passed to the next progeny of cells and cancer results.

The examples of mutator genes exist in the following inherited disorders associated with increased propensity to cancer:

- i) *Hereditary non-polyposis colon cancer* (Lynch syndrome).

- ii) *Ataxia telangiectasia (AT)*.
- iii) *Xeroderma pigmentosum*.
- iv) *Bloom syndrome*.
- v) *Hereditary breast cancer*.

8. CANCER PROGRESSION AND HETEROGENEITY: CLONAL AGGRESSIVENESS

Another feature of note in biology of cancers is that with passage of time cancers become more aggressive; this property is termed *tumour progression*. Clinical parameters of cancer progression are: increasing size of the tumour, higher histologic grade (as seen by poorer differentiation and greater anaplasia), areas of tumour necrosis (i.e. tumour outgrows its blood supply), invasiveness and distant metastasis.

In terms of molecular biology, this attribute of cancer is due to the fact that with passage of time cancer cells acquire more and more *heterogeneity*. This means that though cancer cells remain monoclonal in origin, they acquire more and more mutations which, in turn, produce multiple-mutated subpopulations of more aggressive clones of cancer cells (i.e. heterogeneous cells) in the growth which have tendency to invade, metastasise and be refractory to hormonal influences. Some of these mutations in fact may kill the tumour cells as well.

9. CANCER A SEQUENTIAL MULTISTEP MOLECULAR PHENOMENON: MULTISTEP THEORY

It needs to be appreciated that cancer occurs following several sequential steps of abnormalities in the target cell e.g. initiation, promotion and progression in proper sequence. Similarly, multiple steps are involved at genetic level by which cell proliferation of cancer cells is activated: by activation of growth promoters, loss of growth suppressors, inactivation of intrinsic apoptotic mechanisms and escaping cellular aging. A classic example of this sequential genetic abnormalities in cancer is seen in adenoma-carcinoma sequence in development of colorectal carcinoma. Recent studies on human genome in cancers of breast and colon have revealed that there is a multistep phenomenon of carcinogenesis at molecular level.

10. MICRO-RNAs IN CANCER: ONCOMIRS

MicroRNAs (miRNAs) are evolutionally conserved, endogenous, noncoding single stranded RNA molecules with a length of 22 nucleotides only. Normally, miRNAs function as the posttranslational gene regulators of cell proliferation, differentiation and survival. More than 500 miRNAs have been identified. Recent evidence indicates that miRNAs have an oncogenic role in initiation and progression of cancer and are termed as oncogenic microRNAs, abbreviated as *oncomiRs*. In combination with other tumour associated genes, oncomiRs can perform various functions: as tumour suppressor, as tumour promoter, and as pro-apoptotic.

The above properties of cancer cells are schematically illustrated in **Web Image 8.21**.

□ B. CHEMICAL CARCINOGENESIS (p. 216)

The first ever evidence of any cause for neoplasia came from the observation of Sir Percival Pott in 1775 that there was higher incidence of cancer of the scrotum in chimney-sweeps in London than in the general population. This invoked wide interest in soot and coal tar as possible carcinogenic agent and the possibility of other occupational cancers. Since then the list of chemical carcinogens which can experimentally induce cancer in animals and have epidemiological evidence in causing human neoplasia, is ever increasing.

Stages in Chemical Carcinogenesis (p. 216)

The induction of cancer by chemical carcinogens occurs after a delay—weeks to months in the case of experimental animals, and often several years in man. Other factors that influence the induction of cancer are the dose and mode of administration of carcinogenic chemical, individual susceptibility and various predisposing factors.

Basic mechanism of chemical carcinogenesis is by induction of mutation in the proto-oncogenes and anti-oncogenes. The phenomena of cellular transformation by chemical carcinogens (as also other carcinogens) is a progressive process involving 3 sequential stages: initiation, promotion and progression (**Web Image 8.22**).

1. INITIATION OF CARCINOGENESIS

Initiation is the first stage in carcinogenesis induced by initiator chemical carcinogens. The change can be produced by a single dose of the initiating agent for a short time, though larger dose for longer duration is more effective. The change so induced is sudden, irreversible and permanent. Chemical carcinogens acting as initiators of carcinogenesis can be grouped into 2 categories (**Web Table 8.7**):

I. Direct-acting carcinogens. These are a few chemical substances (e.g. alkylating agents, acylating agents) which can induce cellular transformation without undergoing any prior metabolic activation.

II. Indirect-acting carcinogens or procarcinogens. These require metabolic conversion within the body so as to become 'ultimate' carcinogens having carcinogenicity e.g. polycyclic aromatic hydrocarbons, aromatic amines, azo dyes, naturally-occurring products and others.

In either case, the following steps are involved in transforming 'the target cell' into 'the initiated cell':

a) Metabolic activation. Vast majority of chemical carcinogens are indirect-acting or procarcinogens requiring metabolic activation, while direct-acting carcinogens do not require this activation. The indirect-acting carcinogens are activated in the liver by the mono-oxygenases of the cytochrome P-450 system in the endoplasmic reticulum. In some circumstances, the procarcinogen may be detoxified and rendered inactive metabolically.

b) Reactive electrophiles. While direct-acting carcinogens are intrinsically electrophilic, indirect-acting substances become electron-deficient after metabolic activation i.e. they become reactive electrophiles. Following this step, both types of chemical carcinogens behave alike and their reactive electrophiles bind to electron-rich portions of other molecules of the cell such as DNA, RNA and other proteins.

c) Target molecules. The primary target of electrophiles is DNA, producing mutagenesis. The change in DNA may lead to 'the initiated cell' or some form of cellular enzymes may be able to repair the damage in DNA. The classic example of such a situation occurs in xeroderma pigmentosum, a precancerous condition, in which there is hereditary defect in DNA repair mechanism of the cell and thus such patients are prone to develop skin cancer.

d) The initiated cell. The unrepaired damage produced in the DNA of the cell becomes permanent and fixed only if the altered cell undergoes at least one cycle of proliferation. This results in transferring the change to the next progeny of cells so that the DNA damage becomes *permanent* and *irreversible*, which are the characteristics of the initiated cell, vulnerable to the action of promoters of carcinogenesis.

The stimulus for proliferation may come from regeneration of surviving cells, dietary factors, hormone-induced hyperplasia, viruses etc.

2. PROMOTION OF CARCINOGENESIS

Promotion is the next sequential stage in the chemical carcinogenesis. Promoters of carcinogenesis are substances such as phorbol esters, phenols,

hormones, artificial sweeteners and drugs like phenobarbital. They differ from initiators in the following respects:

- i) They do not produce sudden change.
- ii) They require application or administration, as the case may be, *following* initiator exposure, for sufficient time and in sufficient dose.
- iii) The change induced may be reversible.
- iv) They do not damage the DNA *per se* and are thus not mutagenic but instead enhance the effect of direct-acting carcinogens or procarcinogens.
- v) Tumour promoters act by further clonal proliferation and expansion of initiated (mutated) cells, and have reduced requirement of growth factor, especially after *RAS* gene mutation.

It may be mentioned here that persistent and sustained application/exposure of the cell to initiator alone unassociated with subsequent application of promoter may also result in cancer. But the *vice versa* does not hold true since neither application of promoter alone, nor its application prior to exposure to initiator carcinogen, would result in transformation of target cell.

3. PROGRESSION OF CARCINOGENESIS

Progression of cancer is the stage when mutated proliferated cell shows phenotypic features of malignancy. These features pertain to morphology, biochemical composition and molecular features of malignancy. Such phenotypic features appear only when the initiated cell starts to proliferate rapidly and in the process acquires more and more mutations. The new progeny of cells that develops after such repetitive proliferation inherits genetic and biochemical characteristics of malignancy.

Carcinogenic Chemicals in Humans (p. 218)

Depending upon the mode of action of carcinogenic chemicals, they are divided into 2 broad groups: initiators and promoters (**Web Table 8.7**).

1. INITIATOR CARCINOGENS

I. DIRECT-ACTING CARCINOGENS. These are as follows:

a) Alkylating agents. This group includes mainly various anti-cancer drugs (e.g. cyclophosphamide, chlorambucil, busulfan, melphalan, nitrosourea etc), β -propiolactone and epoxides. They are weakly carcinogenic and are implicated in the etiology of the lymphomas and leukaemias in human beings.

b) Acylating agents. The examples are acetyl imidazole and dimethyl carbamyl chloride.

II. INDIRECT-ACTING CARCINOGENS (PROCARCINOGENS). These are chemical substances which require prior metabolic activation before becoming potent 'ultimate' carcinogens. This group includes vast majority of carcinogenic chemicals. It includes the following 4 categories:

a) Polycyclic aromatic hydrocarbons. They comprise the largest group of common procarcinogens which, after metabolic activation, can induce neoplasia in many tissues in experimental animals and are also implicated in a number of human neoplasms.

Main sources of polycyclic aromatic hydrocarbons are: combustion and chewing of tobacco, smoke, fossil fuel (e.g. coal), soot, tar, mineral oil, smoked animal foods, industrial and atmospheric pollutants. Important chemical compounds included in this group are: anthracenes (benza-, dibenza-, dimethyl benza-), benzopyrene and methylcholanthrene. The following examples have evidence to support the etiologic role of these substances:

- ◆ *Smoking and lung cancer.*
- ◆ *Skin cancer.*
- ◆ *Tobacco and betel nut chewing and cancer oral cavity.*

b) Aromatic amines and azo-dyes. This category includes the following substances implicated in chemical carcinogenesis:

- ◆ *β-naphthylamine* in the causation of bladder cancer, especially in aniline dye and rubber industry workers.
- ◆ *Benzidine* in the induction of bladder cancer.
- ◆ *Azo-dyes* used for colouring foods (e.g. butter and margarine) to give them yellow colour, scarlet red for colouring cherries etc) in the causation of hepatocellular carcinoma.

c) Naturally-occurring products. Some of the important chemical carcinogens derived from plant and microbial sources are aflatoxin B₁, actinomycin D, mitomycin C, safrole and betel nuts. Out of these, aflatoxin B₁ implicated in causing human hepatocellular carcinoma is the most important, especially when concomitant viral hepatitis B is present. It is derived from the fungus, *Aspergillus flavus*, that grows in stored grains and plants.

d) Miscellaneous. A variety of other chemical carcinogens having a role in the etiology of human cancer are as under:

- ◆ *Nitrosamines and nitrosamides* are involved in gastric carcinoma.
- ◆ *Vinyl chloride monomer* derived from PVC (polyvinyl chloride) polymer in the causation of haemangiosarcoma of the liver.
- ◆ *Asbestos* in bronchogenic carcinoma and mesothelioma, especially in smokers.
- ◆ *Arsenical compounds* in causing epidermal hyperplasia and basal cell carcinoma.
- ◆ *Metals* like nickel, lead, cobalt, chromium etc in industrial workers causing lung cancer.
- ◆ *Insecticides and fungicides* (e.g. aldrin, dieldrin, chlordane) in carcinogenesis in experimental animals.
- ◆ *Saccharin and cyclomates* in cancer in experimental animals.

2. PROMOTER CARCINOGENS

Promoters are chemical substances which lack the intrinsic carcinogenic potential but their application subsequent to initiator exposure helps the initiated cell to proliferate further. These substances include phorbol esters, phenols, certain hormones and drugs.

i) Phorbol esters. The best known promoter in experimental animals is *TPA* (tetradecanoyl phorbol acetate) which acts by signal induction protein activation pathway.

ii) Hormones. Endogenous or exogenous oestrogen excess in promotion of cancers of endometrium and breast, prolonged administration of diethylstilbestrol in the etiology of postmenopausal endometrial carcinoma and in vaginal cancer in adolescent girls born to mothers exposed to this hormone during their pregnancy.

iii) Miscellaneous e.g. dietary fat in cancer of colon, cigarette smoke and viral infections etc.

The feature of initiators and promoters are contrasted in **Web Table 8.8**.

Tests for Chemical Carcinogenicity (p. 220)

There are 2 main methods of testing chemical compound for its carcinogenicity:

1. EXPERIMENTAL INDUCTION. The traditional method is to administer the chemical compound under test to a batch of experimental animals like mice or other rodents by an appropriate route e.g. painting on the skin, giving orally or parenterally, or by inhalation.

2. TESTS FOR MUTAGENICITY (AMES' TEST). A mutagen is a substance that can permanently alter the genetic composition of a cell. Ames' test evaluates the ability of a chemical to induce mutation in the mutant strain of

Salmonella typhimurium that cannot synthesise histidine. Such strains are incubated with the potential carcinogen to which liver homogenate is added to supply enzymes required to convert procarcinogen to ultimate carcinogen. If the chemical under test is mutagenic, it will induce mutation in the mutant strains of *S. typhimurium* in the form of functional histidine gene, which will be reflected by the number of bacterial colonies growing on histidine-free culture medium (**Web Image 8.23**).

□ **C. PHYSICAL CARCINOGENESIS** (p. 220)

Physical agents in carcinogenesis are divided into 2 groups:

1. Radiation Carcinogenesis (p. 220)

Ultraviolet (UV) light and ionising radiation are the two main forms of radiation carcinogens which can induce cancer in experimental animals and are implicated in causation of some forms of human cancers. A property common between the two forms of radiation carcinogens is the appearance of mutations followed by a long period of latency after initial exposure, often 10-20 years or even later. Also, radiation carcinogens may act to enhance the effect of another carcinogen (co-carcinogens) and, like chemical carcinogens, may have sequential stages of initiation, promotion and progression in their evolution. Ultraviolet light and ionising radiation differ in their mode of action as described below:

i) ULTRAVIOLET LIGHT. The main source of UV radiation is the sunlight; others are UV lamps and welder's arcs. UV light penetrates the skin for a few millimetres only so that its effect is limited to epidermis. The efficiency of UV light as carcinogen depends upon the extent of light-absorbing protective melanin pigmentation of the skin. In humans, excessive exposure to UV rays can cause various forms of skin cancers—squamous cell carcinoma, basal cell carcinoma and malignant melanoma.

Mechanism. UV radiation may have various effects on the cells. The most important is induction of mutation; others are inhibition of cell division, inactivation of enzymes and sometimes causing cell death. The most important biochemical effect of UV radiation is the formation of pyrimidine dimers in DNA. The proof in favour of mutagenic effect of UV radiation comes from following recessive hereditary diseases characterised by a defect in DNA repair mechanism and associated with high incidence of cancers:

- a) Xeroderma pigmentosum is predisposed to skin cancers at younger age (under 20 years of age).
- b) Ataxia telangiectasia is predisposed to leukaemia.
- c) Bloom's syndrome is predisposed to all types of cancers.
- d) Fanconi's anaemia with increased risk to develop cancer.

Besides, like with other carcinogens, UV radiation also induces mutation in oncogenes (in particular *RAS* gene) and anti-oncogenes (*p53* gene).

ii) IONISING RADIATION. Ionising radiation of all kinds like X-rays, α -, β - and γ -rays, radioactive isotopes, protons and neutrons can cause cancer in animals and in man. Most frequently, radiation-induced cancers are all forms of leukaemias (except chronic lymphocytic leukaemia); others are cancers of the thyroid (most commonly papillary carcinoma), skin, breast, ovary, uterus, lung, myeloma, and salivary glands (**Web Image 8.24**). The evidence in support of carcinogenic role of ionising radiation is cited in the following examples:

- a) Higher incidence of radiation dermatitis and subsequent malignant tumours of the skin was noted in X-ray workers and radiotherapists who did initial pioneering work in these fields before the advent of safety measures.
- b) High incidence of osteosarcoma was observed in young American watch-working girls engaged in painting the dials with luminous radium who unknowingly ingested radium while using lips to point their brushes.

- c) Miners in radioactive elements have higher incidence of cancers.
- d) Japanese atom bomb survivors of the twin cities of Hiroshima and Nagasaki after World War II have increased frequency of malignant tumours, notably acute and chronic myeloid leukaemias, and various solid tumours of breast, colon, thyroid and lung.
- e) Accidental leakage at nuclear power plant in 1985 in Chernobyl (in former USSR, now in Ukraine) has caused long-term hazardous effects of radioactive material to the population living in the vicinity.
- f) It has been observed that therapeutic X-ray irradiation results in increased frequency of cancers, e.g. in patients of ankylosing spondylitis, in children with enlarged thymus, and in children irradiated *in utero* during investigations on the mother.

Mechanism. Radiation damages the DNA of the cell by one of the 2 possible mechanisms:

- a) It may directly alter the cellular DNA.
- b) It may dislodge ions from water and other molecules of the cell and result in formation of highly reactive free radicals that may bring about the damage.

Damage to the DNA resulting in mutagenesis is the most important action of ionising radiation. It may cause chromosomal breakage, translocation, or point mutation.

2. Non-radiation Physical Carcinogenesis (p. 221)

Mechanical injury to the tissues such as from stones in the gallbladder, stones in the urinary tract, and healed scars following burns or trauma, has been suggested as the cause of increased risk of carcinoma in these tissues but the evidence is not convincing.

□ D. BIOLOGIC CARCINOGENESIS (p. 222)

The epidemiological studies on different types of cancers indicate the involvement of transmissible biologic agents in their development, chiefly *viruses*. Other biologic agents implicated in carcinogenesis are as follows:

◆ **Parasites.** *Schistosoma haematobium* infection of the urinary bladder is associated with high incidence of squamous cell carcinoma of the urinary bladder in some parts of the world such as in Egypt. *Clonorchis sinensis*, the liver fluke, lives in the hepatic duct and is implicated in causation of cholangiocarcinoma.

◆ **Fungus.** *Aspergillus flavus* grows in stored grains and liberates aflatoxin; its human consumption, especially by those with HBV infection, is associated with development of hepatocellular carcinoma.

◆ **Bacteria.** *Helicobacter pylori*, a gram-positive spiral-shaped microorganism, colonises the gastric mucosa and has been found in cases of chronic gastritis and peptic ulcer; its prolonged infection may lead to gastric lymphoma and gastric carcinoma.

However, the role of viruses in the causation of cancer is more significant. Therefore, biologic carcinogenesis is largely *viral carcinogenesis*, described below.

VIRAL CARCINOGENESIS (p. 222)

It has been estimated that about 20% of all cancers worldwide are due to persistent virus infection. The contagious nature of the common human wart was first established in 1907. Since then, a number of viruses capable of inducing tumours (oncogenic viruses) in experimental animals, and some implicated in humans, have been identified.

Oncogenic Viral Infections: General Aspects (p. 222)

Based on their nucleic acid content, oncogenic viruses fall into 2 broad groups:

1. Those containing deoxyribonucleic acid are called *DNA oncogenic viruses*.
2. Those containing ribonucleic acid are termed *RNA oncogenic virus* or *retroviruses*.

Both types of oncogenic viruses usually have 3 genes and are abbreviated according to the coding pattern by each gene:

- i) *gag* gene: codes for group antigen.
- ii) *pol* gene: codes for polymerase enzyme.
- iii) *env* gene: codes for envelope protein.

Viral Oncogenesis: General Aspects (p. 222)

In general, persistence of DNA or RNA viruses may induce mutation in the target host cell, although persistence of viral infection alone is not sufficient for oncogenesis but is one step in the multistep process of cancer development. Generally, RNA viruses have very high mutation rate (e.g. HIV, HCV) than DNA viruses. Mechanisms as to how specific DNA and RNA viruses cause mutation in the host cell are varied, but in general persistence of DNA or RNA viral infection causes activation of growth-promoting pathways or inhibition of tumour-suppressor products in the infected cells. Thus, such virus-infected host cells after having undergone genetic changes enter cell cycle and produce next progeny of transformed cells which have characteristics of autonomous growth and survival completing their role as oncogenic viruses.

1. Mode of DNA viral oncogenesis. Host cells infected by DNA oncogenic viruses may have one of the following 2 results (**Web Image 8.25**):

- i) *Replication*. The virus may replicate in the host cell with consequent lysis of the infected cell and release of virions.
- ii) *Integration*. The viral DNA may integrate into the host cell DNA.

The latter event (integration) results in inducing mutation and thus neoplastic transformation of the host cell, while the former (replication) brings about cell death but no neoplastic transformation.

2. Mode of RNA viral oncogenesis. RNA viruses or retroviruses contain two identical strands of RNA and the enzyme, reverse transcriptase (**Web Image 8.26**):

- i) Reverse transcriptase is RNA-dependent DNA synthetase that acts as a template to synthesise a *single strand of matching viral DNA* i.e. reverse of the normal in which DNA is transcribed into messenger RNA.
- ii) The single strand of viral DNA is then copied by DNA-dependent DNA synthetase to form another strand of complementary DNA resulting in *double-stranded viral DNA* or provirus.
- iii) The provirus is then integrated into the DNA of the host cell genome and may induce mutation and thus transform the cell into *neoplastic cell*.
- iv) Retroviruses are *replication-competent*. The host cells which allow replication of integrated retrovirus are called permissive cells. Non-permissible cells do not permit replication of the integrated retrovirus.
- v) Viral replication begins after integration of the provirus into host cell genome. Integration results in transcription of proviral genes or progenes into messenger RNA which then forms *components of the virus particle*—virion core protein from *gag* gene, reverse transcriptase from *pol* gene, and envelope glycoprotein from *env* gene. The three components of virus particle are then assembled at the plasma membrane of the host cell and the virus particles released by budding off from the plasma membrane, thus completing the process of replication.

Specific DNA Oncogenic Viruses (p. 224)

DNA oncogenic viruses have direct access to the host cell nucleus and are incorporated into the genome of the host cell. DNA viruses are classified into

5 subgroups, each of which is capable of producing neoplasms in different hosts (**Web Table 8.9**).

1. PAPOVAVIRUSES. This group consists of the papilloma virus including the human papilloma virus (HPV), polyoma virus and SV-40 (simian vacuolating) virus. These viruses have an etiologic role in following benign and malignant neoplasms in animals and in humans:

i) Papilloma viruses. These viruses were the first to be implicated in the etiology of any human neoplasia. These viruses appear to replicate in the layers of stratified squamous epithelium. More than 100 HPV types have been identified; the individual types are associated with different lesions. The following examples of benign and malignant tumours are cited to demonstrate their role in oncogenesis:

- ◆ HPV was first detected as etiologic agent in common *skin warts* or *verruca vulgaris* (squamous cell papillomas) by Shope in 1933; the condition is infectious. Current evidence supports implication of low-risk HPV types 1,2, 4 and 7 in common viral warts.

- ◆ Low-risk HPV types 6 and 11 are involved in the etiology of genital warts (*condyloma acuminata*).

- ◆ Viral DNA of high-risk HPV types 16, 18, 31, 33 and 45 has been seen in 75-100% cases of *invasive cervical cancer* and its precursor lesions (carcinoma *in situ* and dysplasia) and is strongly implicated.

- ◆ High-risk HPVs are also involved in causation of *other squamous cell carcinomas* and dysplasias such as of anus, perianal region, vagina, vulva, penis and oral cavity.

- ◆ HPV types 5 and 8 are responsible for causing an uncommon condition, *epidermodysplasia verruciformis*. The condition is characterised by multiple skin warts and a genetic defect in the cell-mediated immunity. About one-third of cases develop squamous cell carcinoma in the sun-exposed warts.

- ◆ Some strains of HPV are responsible for causing multiple *juvenile papillomas* of the larynx.

HPV ONCOGENESIS IN HUMAN CANCER—

Persistent infection with high-risk HPV types in target epithelial cells drives the molecular hallmarks of cancer discussed earlier and directly affect cell growth by following mechanisms:

i) HPV integrates in to the host cell DNA which results in overexpression of viral proteins E6 and E7 from high risk HPV types. E6 and E7 from high-risk HPVs has high affinity for target host cells than these viral oncoproteins from low-risk HPVs.

ii) E6 and E7 viral proteins cause loss of *p53* and *pRB*, the two cell proteins with tumour-suppressor properties. Thus the breaks in cell proliferation are removed, permitting the uncontrolled proliferation.

iii) These viral proteins activate cyclin A and E, and inactivate CDKIs, thus permitting further cell proliferation.

iv) These viral proteins mediate and degrade *BAX*, a proapoptotic gene, thus inhibiting apoptosis.

v) These viral proteins activate telomerase, immortalising the transformed host target cells.

ii) Polyoma virus. Polyoma virus occurs as a natural infection in mice.

- ◆ Polyoma virus infection is not known to produce any human tumour. But it is involved in causation of polyomavirus nephropathy in renal allograft recipients and is also implicated in the etiology of progressive demyelinating leucoencephalopathy, a fatal demyelinating disease.

iii) SV-40 virus. As the name suggests, simian vacuolating virus exists in monkeys without causing any harm but can induce sarcoma in hamsters. There is some evidence of involvement of SV-40 infection in mesothelioma of the pleura.

2. HERPESVIRUSES. Primary infection of all the herpesviruses in man persists probably for life in a latent stage which can get reactivated later. Important members of herpesvirus family are Epstein-Barr virus, herpes simplex virus type 2 (HSV-2) and human herpesvirus 8 (HHV8), cytomegalovirus (CMV), Lucke's frog virus and Marek's disease virus. Out of these, Lucke's frog virus and Marek's disease virus are implicated in animal tumours only (renal cell carcinoma and T-cell leukaemia-lymphoma respectively). There is no oncogenic role of HSV-2 and CMV in human tumours.

EPSTEIN-BARR VIRUS (EBV). EBV infects human B-lymphocytes and epithelial cells and long-term infection stimulates them to proliferate and development of malignancies. EBV is implicated in the following human tumours—Burkitt's lymphoma, anaplastic nasopharyngeal carcinoma, post-transplant lymphoproliferative disease, primary CNS lymphoma in AIDS patients, and Hodgkin's lymphoma. It is also shown to be causative for infectious mononucleosis, a self-limiting disease in humans. The role of EBV in the first two human tumours is given below while others have been discussed elsewhere in relevant chapters.

Burkitt's lymphoma. Burkitt's lymphoma was initially noticed in African children by Burkitt in 1958 but is now known to occur in 2 forms—*African endemic form*, and *sporadic form* seen elsewhere in the world.

There is strong evidence linking Burkitt's lymphoma, a B-lymphocyte neoplasm, with EBV as observed from the following features:

- a) Over 90% of Burkitt's lymphomas are EBV-positive in which the tumour cells carry the viral DNA.
- b) 100% cases of Burkitt's lymphoma show elevated levels of antibody titers to various EBV antigens.
- c) EBV has strong tropism for B lymphocytes. EBV-infected B cells grown in cultures are immortalised i.e. they continue to develop further along B cell-line to propagate their progeny in the altered form.
- d) Though EBV infection is almost worldwide in all adults and is also known to cause self-limiting infectious mononucleosis, but the fraction of EBV-infected circulating B cells in such individuals is extremely small.
- e) Linkage between Burkitt's lymphoma and EBV infection is very high in African endemic form of the disease and probably in cases of AIDS than in sporadic form of the disease.

However, a few observations, especially regarding sporadic cases of Burkitt's lymphoma, suggest that certain other supportive factors may be contributing. *Immunosuppression* appears to be one such most significant factor.

Anaplastic nasopharyngeal carcinoma. This is the other tumour having close association with EBV infection. The tumour is prevalent in South-East Asia, especially in the Chinese, and in Eskimos. The evidence linking EBV infection with this tumour is as follows:

- a) 100% cases of nasopharyngeal carcinoma carry DNA of EBV in nuclei of tumour cells.
- b) Individuals with this tumour have high titers of antibodies to various EBV antigens.

However, like in case of Burkitt's lymphoma, there may be some *co-factors* such as genetic susceptibility that account for the unusual geographic distribution.

EBV ONCOGENESIS IN HUMAN CANCER—

Persistent EBV infection is implicated in the causation of malignancies of B lymphocytes and epithelial cells. The mechanism of oncogenesis is as under:

- i) Latently infected epithelial cells or B lymphocytes express viral oncogene *LMP1* (latent membrane protein) which is most crucial step in evolution of EBV-associated malignancies. Immunosuppressed individuals are unable to mount attack against EBV infection and thus are more affected.
- ii) *LMP1* viral protein dysregulates normal cell proliferation and survival of infected cells and acts like CD40 receptor molecule on B cell surface. Thus, it stimulates B-cell proliferation by activating growth signaling pathways via nuclear factor κ B (NF- κ B) and JAK/STAT pathway.
- iii) *LMP1* viral oncoprotein also activates *BCL2* and thereby prevents apoptosis.
- iv) Persistent EBV infection elaborates another viral protein *EBNA-2* which activates cyclin D in the host cells and thus promotes cell proliferation.
- v) In immunocompetent individuals, *LMP1* is kept under control by the body's immune system and in these persons therefore lymphoma cells appear only after another characteristic mutation t(8;14) activates growth promoting *MYC* oncogene.

HUMAN HERPESVIRUS 8 (HHV-8). It has been shown that infection with HHV-8 or Kaposi's sarcoma-associated herpesvirus (KSHV) is associated with Kaposi's sarcoma, a vascular neoplasm common in patients of AIDS. Compared to sporadic Kaposi's sarcoma, the AIDS-associated tumour is multicentric and more aggressive. HHV-8 has lymphotropism and is also implicated in causation of pleural effusion lymphoma and multicentric variant of Castleman's disease.

HHV-8 (KSHV) ONCOGENESIS IN HUMAN CANCER—

- i) Viral DNA is seen in nuclei of all tumour cells in Kaposi's sarcoma.
- ii) There is overexpression of several KSHV oncoproteins by latently infected cells: v-cyclin, v-interferon regulatory factor (v-IRF) and LANA (latency-associated nuclear antigen).
- iii) These viral proteins cause increased proliferation and survival of host cells and thus induce malignancy.

3. ADENOVIRUSES. The human adenoviruses cause upper respiratory infections and pharyngitis.

- ◆ *In humans*, they are not known to be involved in any tumour.
- ◆ *In hamsters*, they may induce sarcomas.

4. POXVIRUSES. This group of oncogenic viruses is involved in the etiology of following lesions:

- ◆ *In rabbits*—poxviruses cause myxomatosis.
- ◆ *In humans*—poxviruses cause molluscum contagiosum and may induce squamous cell papilloma.

5. HEPADNAVIRUSES. *Hepatitis B virus (HBV)* is a member of hepadnavirus (*hepa-* from hepatitis, *-dna* from DNA) family. HBV infection in man causes an acute hepatitis and is responsible for a carrier state, which can result in some cases to chronic hepatitis progressing to hepatic cirrhosis, and onto hepatocellular carcinoma. Suffice this to say here that there is strong epidemiological evidence linking HBV infection to development of hepatocellular carcinoma as evidenced by the following:

- a) The geographic differences in the incidence of hepatocellular carcinoma closely match the variation in prevalence of HBV infection e.g. high incidence in Far-East and Africa.
- b) Epidemiological studies in high incidence regions indicate about 200 times higher risk of developing hepatocellular carcinoma in HBV-infected cases as compared to uninfected population in the same area.

Possible mechanism of hepatocellular carcinoma occurring in those harbouring long-standing infection with HBV is chronic destruction of HBV-infected hepatocytes followed by continued hepatocyte proliferation. This process renders the hepatocytes vulnerable to the action of other risk factors such as to aflatoxin causing mutation and neoplastic proliferation.

More recent evidence has linked an oncogenic role to another hepatotropic virus, hepatitis C virus (HCV) as well which is an RNA virus, while HBV is a DNA virus. HCV is implicated in about half the cases of hepatocellular carcinoma in much the same way as HBV.

HEPATITIS VIRUS ONCOGENESIS IN HUMAN CANCER—

Epidemiologic data firmly support that two hepatotropic viruses, HBV—a DNA virus, and HCV—an RNA virus, are currently involved in causation of 70-80% cases of hepatocellular carcinoma worldwide. Although HBV DNA has been found integrated in the genome of human hepatocytes in many cases of liver cancer which causes mutational changes but a definite pattern is lacking. Thus, exact molecular mechanism as to how HBV and HCV cause hepatocellular carcinoma is yet not quite clear. Probably, multiple factors are involved.

Specific RNA Oncogenic Viruses (p. 227)

RNA oncogenic viruses are retroviruses i.e. they contain the enzyme reverse transcriptase (RT), though all retroviruses are not oncogenic (**Web Table 8.10**). The enzyme, reverse transcriptase, is required for reverse transcription of viral RNA to synthesise viral DNA strands i.e. reverse of normal—rather than DNA encoding for RNA synthesis, viral RNA transcripts for the DNA by the enzyme RT present in the RNA viruses. RT is a DNA polymerase and helps to form complementary DNA (cDNA) that moves in to host cell nucleus and gets incorporated in to it.

Based on their activity to transform target cells into neoplastic cells, RNA viruses are divided into 3 subgroups—acute transforming viruses, slow transforming viruses, and human T-cell lymphotropic viruses (HTLV). The former two are implicated in inducing a variety of tumours in animals only while HTLV is causative for human T-cell leukaemia and lymphoma.

1. ACUTE TRANSFORMING VIRUSES. This group includes retroviruses which transform all the cells infected by them into malignant cells rapidly ('acute'). All the viruses in this group possess one or more viral oncogenes (*v-oncs*). All the members of acute transforming viruses discovered so far are defective viruses in which the particular *v-onc* has substituted other essential genetic material such as *gag*, *pol* and *env*. These defective viruses cannot replicate by themselves unless the host cell is infected by another 'helper virus'. Acute oncogenic viruses have been identified in tumours in different animals only.

2. SLOW TRANSFORMING VIRUSES. These oncogenic retroviruses cause development of leukaemias and lymphomas in different species of animals (e.g. in mice, cats and bovine) and include the mouse mammary tumour virus (MMTV) that causes breast cancer in the daughter-mice suckled by the MMTV-infected mother via the causal agent in the mother's milk (*Bittner milk factor*). These viruses have long incubation period between infection and development of neoplastic transformation ('slow'). Slow transforming viruses cause neoplastic transformation by *insertional mutagenesis*.

3. HUMAN T-CELL LYMPHOTROPIC VIRUSES (HTLV). HTLV is a form of slow transforming virus but is described separately because of 2 reasons:

- i) This is the only retrovirus implicated in human cancer.
- ii) The mechanism of neoplastic transformation is different from slow transforming as well as from acute transforming viruses.

Four types of HTLVs are recognised—HTLV-I, HTLV-II, HTLV-III and HTLV-IV.

A link between HTLV-I infection and cutaneous adult T-cell leukaemia-lymphoma (ATLL) has been identified while HTLV-II is implicated in causation of T-cell variant of hairy cell leukaemia. HTLV-I is transmitted through sexual contact, by blood, or to infants during breastfeeding. The highlights of this association and mode of neoplastic transformation are as under:

- i) Epidemiological studies by tests for antibodies have shown that HTLV-I infection is endemic in parts of Japan and West Indies where the incidence of ATLL is high. The latent period after HTLV-I infection is, however, very long (20-30 years).
- ii) The initiation of neoplastic process is similar to that for Burkitt's lymphoma except that HTLV-I has tropism for CD4+T lymphocytes as in HIV infection, while EBV of Burkitt's lymphoma has tropism for B lymphocytes.
- iii) As in Burkitt's lymphoma, immunosuppression plays a supportive role in the neoplastic transformation by HTLV-I infection.

HTLV ONCOGENESIS IN HUMAN CANCER—

The molecular mechanism of ATLL leukaemogenesis by HTLV infection of CD4+ T lymphocytes is not clear. Neoplastic transformation by HTLV-I infection differs from acute transforming viruses because it does not contain *v-onc*, and from other slow transforming viruses because it does not have fixed site of insertion for insertional mutagenesis. Probably, the process is multifactorial:

- i) HTLV-I genome has unique region called pX distinct from other retroviruses, which encodes for two essential viral oncoproteins— *TAX* and *REX*. *TAX* protein up-regulates the expression of cellular genes controlling T-cell replication, while *REX* gene product regulates viral protein production by affecting mRNA expression.
- ii) *TAX* viral protein interacts with transcription factor, NF- κ B, which stimulates genes for cytokines (interleukins) and their receptors in infected T cells which activates proliferation of T cells by autocrine pathway.
- iii) The inappropriate gene expression activates pathway of the cell proliferation by activation of cyclins and inactivation of tumour suppressor genes CDKN2A/p16 and p53, stimulating cell cycle.
- iv) Initially, proliferation of infected T cells is polyclonal but subsequently several mutations appear due to *TAX*-based genomic changes in the host cell and monoclonal proliferation of leukaemia occurs.

VIRUSES AND HUMAN CANCER: A SUMMARY (p. 228)

A summary of different viruses implicated in human tumours is presented (**Web Image 8.27**):

Benign tumours. There are 2 conditions which are actually doubtful as tumours in which definite viral etiology is established. These are:

- i) Human wart (papilloma) caused by human papilloma virus; and
- ii) Molluscum contagiosum caused by poxvirus.

Malignant tumours. The following 8 human cancers have enough epidemiological, serological, and in some cases genomic evidence, that viruses are implicated in their etiology:

- i) *Burkitt's lymphoma* by Epstein-Barr virus.
- ii) *Nasopharyngeal carcinoma* by Epstein-Barr virus.
- iii) *Primary hepatocellular carcinoma* by hepatitis B virus and hepatitis C virus.
- iv) *Cervical cancer* by high risk human papilloma virus types (HPV 16 and 18).
- v) *Kaposi's sarcoma* by human herpes virus type 8 (HHV-8).
- vi) *Pleural effusion B cell lymphoma* by HHV8.
- vii) *Adult T-cell leukaemia and lymphoma* by HTLV-I.
- viii) *T-cell variant of hairy cell leukaemia* by HTLV-II.

□ TUMOUR-HOST INTER-RELATIONSHIP (p. 228)

The natural history of a neoplasm depends upon 2 features:

- i) Host response against tumour (Immunology of cancer)
- ii) Effect of tumour on host

It has long been known that body's immune system can recognise tumour cells as 'non-self' and attempt to destroy them and limit the spread of cancer. The following observations provide basis for this concept:

1. Certain cancers evoke significant lymphocytic infiltrates composed of immunocompetent cells and such tumours have somewhat better prognosis e.g. medullary carcinoma breast (as compared with infiltrating ductal carcinoma), seminoma testis (as compared with other germ cell tumours of testis).
2. Rarely, a cancer may spontaneously regress partially or completely, probably under the influence of host defense mechanism. For example, rare spontaneous disappearance of malignant melanoma temporarily from the primary site which may then reappear as metastasis.
3. It is highly unusual to have primary and secondary tumours in the spleen due to its ability to destroy the growth and proliferation of tumour cells.
4. Immune surveillance exists is substantiated by increased frequency of cancers in immunodeficient host e.g. in AIDS patients, or development of post-transplant lymphoproliferative disease.

In an attempt to substantiate the above observations and to understand the underlying host defense mechanisms, experimental animal studies involving tumour transplants were carried out. The findings of animal experiments coupled with research on human cancers has led to the concept of immunology of cancer:

1. TUMOUR ANTIGENS. Tumour cells express surface antigens which have been seen in animals and in some human tumours. Older classification of tumour antigens was based on their surface sharing characteristics on normal versus tumour cells and on their recognition by cytotoxic T lymphocytes CTL (CD8+T cells) on the basis of class I MHC molecules. Accordingly, tumour antigens were categorised into following two types:

- i) *Tumour-specific antigens (TSAs)* located on tumour cells and are unique or specific antigens for particular tumour and not shared by normal cells.
- ii) *Tumour associated antigens (TAAs)* are present on tumour cells as well as on some normal cells from where the tumour originated.

Currently, various groups of tumour antigens are as follows:

1. *Oncoproteins from mutated oncogenes:* Protein products derived from mutated oncogenes result in expression of cell surface antigens on tumour cells. The examples include products of *RAS*, *BCL/ABL* and *CDK4*.
2. *Protein products of tumour suppressor genes.* In some tumours, protein products of mutated tumour suppressor genes cause expression of tumour antigens on the cell surface. The examples are mutated proteins *p53* and β -catenin.
3. *Overexpressed cellular proteins.* Some tumours are associated with a normal cellular protein but is excessively expressed in tumour cells and incite host immune response. For example, in melanoma the tumour antigen is structurally normal melanocyte specific protein, tyrosinase, which is overexpressed compared with normal cells. Similarly, *HER2/neu* protein is overexpressed in many cases of breast cancer.
4. *Abnormally expressed cellular proteins.* Sometimes, a cellular protein is present in some normal cells but is abnormally expressed on the surface of tumour cells of some cancers. The classic example is presence of *MAGE* gene silent in normal adult tissues except in male germ line but *MAGE* genes are expressed on surface of many tumours such as melanoma.
5. *Tumour antigens from viral oncoproteins.* As already discussed above, many oncogenic viruses express viral oncoproteins which result in expression of antigens on tumour cells e.g. viral oncoproteins of HPV (E6, E7) in cervical cancer and EBNA proteins of EBV in Burkitt's lymphoma.
6. *Tumour antigens from randomly mutated genes.* Various other carcinogens such as chemicals and radiation induce random mutations in the target

cells. These mutated cells elaborate protein products targeted by the CTL of the immune system causing expression of tumour antigens.

7. *Cell specific differentiation antigens.* Normally differentiated cells have cellular antigens which forms the basis of diagnostic immunohistochemistry. Cancers have varying degree of loss of differentiation but particular lineage of the tumour cells can be identified by tumour antigens. For example, various CD markers for various subtypes of lymphomas, prostate specific antigen (PSA) in carcinoma of prostate.

8. *Oncofetal antigens.* Oncofetal antigens such as α -foetoprotein (AFP) and carcinoembryonic antigen (CEA) are normally expressed in embryonic life. But these antigens appear in certain cancers—AFP in liver cancer and CEA in colon cancer which can be detected in serum as cancer markers.

9. *Abnormal cell surface molecules.* The normal cell expresses surface molecules of glycolipids, glycoproteins, mucins and blood group antigens. In some cancers, there is abnormally changed expression of these molecules. For example, there may be changed blood group antigen, or abnormal expression of mucin in ovarian cancer (CA-125) and in breast cancer (MUC-1).

2. ANTI-TUMOUR IMMUNE RESPONSES. Although the host immune response to tumour is by both cell-mediated and humoral immunity, the major anti-tumour effector mechanism is cell-mediated.

i) Cell-mediated mechanism. This is the main mechanism of destruction of tumour cells by the host. The following cellular responses can destroy the tumour cells and induce tumour immunity in humans:

a) *Specifically sensitised cytotoxic T lymphocytes (CTL)* i.e. CD8+ T cells are directly cytotoxic to the target cell and require contact between them and tumour cells. CTL have been found to be effective against virally-induced cancers e.g. in Burkitt's lymphoma (EBV-induced), invasive squamous cell carcinoma of cervix (HPV-induced).

b) *Natural killer (NK) cells* are lymphocytes which after activation by IL-2, destroy tumour cells without sensitisation, either directly or by antibody-dependent cellular cytotoxicity (ADCC). NK cells together with T lymphocytes are the first line of defense against tumour cells and can lyse tumour cells.

c) *Macrophages* are activated by interferon- γ secreted by T-cells and NK-cells, and therefore there is close collaboration of these two subpopulation of lymphocytes and macrophages. Activated macrophages mediate cytotoxicity by production of oxygen free radicals or by tumour necrosis factor.

ii) Humoral mechanism. As such there are no anti-tumour humoral antibodies which are effective against cancer cells *in vivo*. However, *in vitro* humoral antibodies may kill tumour cells by complement activation or by antibody-dependent cytotoxicity. Based on this, monoclonal antibody treatment is offered to cases of some non-Hodgkin's lymphoma.

iii) Immune regulatory mechanism. In spite of host immune responses, most cancers grow relentlessly. This is due to some of the following controlling mechanisms:

- During progression of the cancer, immunogenic cells may disappear.
- Cytotoxic T-cells and NK-cells may play a self regulatory role.
- Immunosuppression mediated by various acquired carcinogenic agents (viruses, chemicals, radiation).
- Immunosuppressive role of factors secreted by tumour cells e.g. transforming growth factor- β .

The mechanisms of these immune responses are schematically illustrated in **Web Image 8.28**.

3. IMMUNOTHERAPY. Despite the existence of anti-tumour immune responses, the cancers still progress and eventually cause death of the host. The immune responses to be effective enough must eliminate the

cancer cells more rapidly than their rate of proliferation and hence the role of boosting the immune response or immunotherapy.

i) **Non-specific stimulation** of the host immune response was initially attempted with BCG.

ii) **Specific stimulation** of the immune system was attempted.

iii) **Current status of immunotherapy** is focussed on following three main approaches:

a) *Cellular immunotherapy* consists of infusion of tumour-specific cytotoxic T cells which will increase the population of tumour-infiltrating lymphocytes (TIL).

b) *Cytokine therapy* is used to build up specific and non-specific host defenses. These include: interleukin-2, interferon- α and - γ , tumour necrosis factor- α , and granulocyte-monocyte colony stimulating factor (GM-CSF).

c) *Monoclonal antibody therapy* is currently being tried against CD20 molecule of B cells in certain B cell leukaemias and lymphomas.

EFFECT OF TUMOUR ON HOST (p. 230)

Malignant tumours produce more ill-effects than the benign tumours. The effects may be local, or generalised and more widespread.

1. LOCAL EFFECTS. Both benign and malignant tumours cause local effects on the host due to their size or location. Malignant tumours due to rapid and invasive growth potential have more serious effects. Some of the local effects of tumours are as under:

i) **Compression.** Many benign tumours pose only a cosmetic problem. Some benign tumours, however, due to their critical location, have more serious consequences e.g. pituitary adenoma may lead to serious endocrinopathy; a small benign tumour in ampulla of Vater may lead to biliary obstruction.

ii) **Mechanical obstruction.** Benign and malignant tumours in the gut may produce intestinal obstruction.

iii) **Tissue destruction.** Malignant tumours, both primary and metastatic, infiltrate and destroy the vital structures.

iv) **Infarction, ulceration, haemorrhage.** Cancers have a greater tendency to undergo infarction, surface ulceration and haemorrhage than the benign tumours. Secondary bacterial infection may supervene. Large tumours in mobile organs (e.g. an ovarian tumour) may undergo torsion and produce infarction and haemorrhage.

2. CANCER CACHEXIA. Patients with advanced and disseminated cancers terminally have asthenia (emaciation), and anorexia, together referred to as cancer cachexia (meaning wasting). Possibly, cachectin or tumour necrosis factor α (TNF- α) and interleukin-1 derived from macrophages play a contributory role in cachexia.

3. FEVER. Fever of unexplained origin may be presenting feature in some malignancies such as in Hodgkin's disease, adenocarcinoma kidney, osteogenic sarcoma and many other tumours.

4. TUMOUR LYSIS SYNDROME. This is a condition caused by extensive destruction of a large number of rapidly proliferating tumour cells. The condition is seen more often in cases of lymphomas and leukaemias than solid tumours and may be due to large tumour burden (e.g. in Burkitt's lymphoma), chemotherapy, administration of glucocorticoids or certain hormonal agents (e.g. tamoxifen).

5. PARANEOPLASTIC SYNDROMES. Paraneoplastic syndromes (PNS) are a group of conditions developing in patients with advanced cancer which are neither explained by direct and distant spread of the tumour, nor by the usual hormone elaboration by the tissue of origin of the tumour. About 10 to

15% of the patients with advanced cancer develop one or more of the syndromes included in the PNS. Rarely, PNS may be the earliest manifestation of a latent cancer.

The various clinical syndromes included in the PNS are as summarised in **Web Table 8.11** and are briefly outlined below:

i) Endocrine syndrome. Elaboration of hormones or hormone-like substances by cancer cells of non-endocrine origin is called as ectopic hormone production. Some examples are given below:

a) *Hypercalcaemia.* Symptomatic hypercalcaemia unrelated to hyperparathyroidism is the most common syndrome in PNS. It occurs from elaboration of parathormone-like substance by tumours such as squamous cell carcinoma of the lung, carcinoma kidney, breast and adult T cell leukaemia lymphoma.

b) *Cushing's syndrome.* About 10% patients of small cell carcinoma of the lung elaborate ACTH or ACTH-like substance producing Cushing's syndrome.

c) *Polycythaemia.* Secretion of erythropoietin by certain tumours such as renal cell carcinoma, hepatocellular carcinoma and cerebellar haemangioma may cause polycythaemia.

d) *Hypoglycaemia.* Elaboration of insulin-like substance by fibrosarcomas, islet cell tumours of pancreas and mesothelioma may cause hypoglycaemia.

ii) Neuromyopathic syndromes. About 5% of cancers are associated with progressive destruction of neurons throughout the nervous system without evidence of metastasis in the brain and spinal cord. This is probably mediated by immunologic mechanisms.

iii) Effects on osseous, joints and soft tissue. e.g. hypertrophic osteoarthropathy and clubbing of fingers in cases of bronchogenic carcinoma by unknown mechanism.

iv) Haematologic and vascular syndrome. e.g. venous thrombosis (Trousseau's phenomenon), non-bacterial thrombotic endocarditis, disseminated intravascular coagulation (DIC), leukemoid reaction and normocytic normochromic anaemia occurring in advanced cancers.

v) Gastrointestinal syndromes. Malabsorption of various dietary components as well as hypoalbuminaemia may be associated with a variety of cancers which do not directly involve small bowel.

vi) Renal syndromes. Renal vein thrombosis or systemic amyloidosis may produce nephrotic syndrome in patients with cancer.

vii) Cutaneous syndromes. Acanthosis nigricans characterised by the appearance of black warty lesions in the axillae and the groins may appear in the course of adenocarcinoma of gastrointestinal tract.

viii) Amyloidosis. Primary amyloid deposits may occur in multiple myeloma whereas renal cell carcinoma and other solid tumours may be associated with secondary systemic amyloidosis.

□ PATHOLOGIC DIAGNOSIS OF CANCER (p. 232)

1. Histological Methods (p. 232)

These methods are based on microscopic examination of properly fixed tissue (excised tumour mass or open/needle biopsy from the mass), supported with complete clinical and investigative data. These methods are most valuable in arriving at the accurate diagnosis. The tissue must be fixed in 10% formalin for light microscopic examination and in glutaraldehyde for electron microscopic studies, while quick-frozen section and hormonal analysis are carried out on fresh unfixed tissues.

The histological diagnosis by either of these methods is made on the basis that morphological features of *benign tumours* resemble those of normal tissue and that they are unable to invade and metastasise, while

180 *malignant tumours* are identified by lack of differentiation in cancer cells termed 'anaplasia' or 'cellular atypia' and may invade as well as metastasise.

2. Cytological Methods (p. 232)

i) **Exfoliative cytology.** Cytologic smear (Papanicolaou or Pap smear) method was initially employed for detecting dysplasia, carcinoma *in situ* and invasive carcinoma of the uterine cervix. However, its use has now been widely extended to include examination of sputum and bronchial washings; pleural, peritoneal and pericardial effusions; urine, gastric secretions, and CSF. The method is based on microscopic identification of the characteristics of malignant cells which are incohesive and loose and are thus shed off or 'exfoliated' into the lumen. However, a 'negative diagnosis' does not altogether rule out malignancy due to possibility of sampling error.

ii) **Fine needle aspiration cytology (FNAC).** Currently, cytopathology includes not only study of exfoliated cells but also materials obtained from superficial and deep-seated lesions in the body which do not shed off cells freely. The latter method consists of study of cells obtained by a fine needle introduced under vacuum into the lesion, so called *fine needle aspiration cytology (FNAC)*. The superficial masses can be aspirated under direct vision while deep-seated masses such as intra-abdominal, pelvic organs and retroperitoneum are frequently investigated by ultrasound (US) or computed tomography (CT)-guided fine needle aspirations. FNAC has a diagnostic reliability between 80-97% but it must not be substituted for clinical judgement or compete with an indicated histopathologic biopsy.

3. Histochemistry and Cytochemistry (p. 233)

Histochemistry and cytochemistry are additional diagnostic tools which help the pathologist in identifying the chemical composition of cells, their constituents and their products by special staining methods.

Though immunohistochemical techniques are more useful for tumour diagnosis (see below), histochemical and cytochemical methods are still employed for this purpose.

Some of the common examples are summarised in **Web Table 8.12**.

4. Immunohistochemistry (p. 233)

This is an immunological method of recognising a cell by one or more of its specific components in the cell membrane, cytoplasm or nucleus. These cell components (called antigens) combine with specific antibodies on the formalin-fixed paraffin sections or cytological smears. The complex of antigen-antibody on slide is made visible for light microscopic identification by either fluorescent dyes ('fluorochromes') or by enzyme system ('chromogens'). The specific antibody against a particular cellular antigen is obtained by hybridoma technique for monoclonal antibody production. These monoclonal antibodies, besides being *specific* against antigen, are highly sensitive in detection of antigenic component, and, therefore, impart objectivity to the subjective tumour diagnosis made by the surgical pathologist.

Though the list of immunohistochemical stains is ever increasing, an important group of antibody stains directed against various classes of intermediate filaments is useful in classification of poorly-differentiated tumours of epithelial or mesenchymal origin (**Web Table 8.13**). An abbreviated list of antibody stains in some common cancers of unknown origin is given in **Web Table 2.3**.

5. Electron Microscopy (p. 233)

Ultrastructural examination of tumour cells offers selective role in diagnostic pathology. EM examination may be helpful in confirming or substantiating a tumour diagnosis arrived at by light microscopy and immunohistochemistry.

A few general features of malignant tumour cells by EM examination can be appreciated:

- i) Cell junctions, their presence and type.
- ii) Cell surface, e.g. presence of microvilli.
- iii) Cell shape and cytoplasmic extensions.
- iv) Shape of the nucleus and features of nuclear membrane.
- v) Nucleoli, their size and density.
- vi) Cytoplasmic organelles—their number is generally reduced.
- vii) Dense bodies in the cytoplasm.
- viii) Any other secretory product in the cytoplasm e.g. melanosomes in melanoma and membrane-bound granules in endocrine tumours.

6. Tumour Markers (Biochemical Assays) (p. 233)

In order to distinguish from the preceding techniques of tumour diagnosis in which 'stains' are imparted on the tumour cells in section or smear, tumour markers are biochemical assays of products elaborated by the tumour cells in blood or other body fluids. It is, therefore, pertinent to keep in mind that many of these products are produced by normal body cells too, and thus the biochemical estimation of the product in blood or other fluid reflects the total substance and not by the tumour cells alone. These methods, therefore, lack sensitivity as well as specificity and can only be employed for the following:

• *Firstly*, as an adjunct to the pathologic diagnosis arrived at by other methods and not for primary diagnosis of cancer.

Secondly, it can be used for prognostic and therapeutic purposes.

Tumour markers include: cell surface antigens (or oncofoetal antigens), cytoplasmic proteins, enzymes, hormones and cancer antigens; these are listed in **Web Table 8.14**. However, two of the best known examples of oncofoetal antigens secreted by foetal tissues as well as by tumours are alpha-foetoproteins (AFP) and carcinoembryonic antigens (CEA):

a) Alpha-foetoprotein (AFP): This is a glycoprotein synthesised normally by foetal liver cells. Their serum levels are elevated in hepatocellular carcinoma and non-seminomatous germ cell tumours of the testis. Certain non-neoplastic conditions also have increased serum levels of AFP e.g. in hepatitis, cirrhosis, toxic liver injury and pregnancy.

b) Carcino-embryonic antigen (CEA): CEA is also a glycoprotein normally synthesised in embryonic tissue of the gut, pancreas and liver. Their serum levels are high in cancers of the gastrointestinal tract, pancreas and breast. As in AFP, CEA levels are also elevated in certain non-neoplastic conditions e.g. in ulcerative colitis, Crohn's disease, hepatitis and chronic bronchitis.

7. Other Modern Aids in Pathologic Diagnosis of Tumours (p. 234)

i) Flow cytometry. This is a computerised technique by which the detailed characteristics of individual tumour cells are recognised and quantified and the data can be stored for subsequent comparison too. Since for flow cytometry, single cell suspensions are required to 'flow' through the 'cytometer', it can be employed on blood cells and their precursors in bone marrow aspirates and body fluids, and sometimes on fresh-frozen unfixed tissue. The method employs either identification of cell surface antigen (e.g. in classification of leukaemias and lymphomas), or by the DNA content analysis (e.g. aneuploidy in various cancers).

ii) *In situ* hybridisation. This is a molecular technique by which nucleic acid sequences (cellular/viral DNA and RNA) can be localised by specifically-labelled nucleic acid probe directly in the intact cell (*in situ*) rather than by DNA extraction (see below). A modification of *in situ* hybridisation technique is fluorescence *in situ* hybridisation (FISH) in which fluorescence dyes

applied and is used to detect microdeletions, subtelomere deletions and to look for alterations in chromosomal numbers.

iii) Molecular diagnostic techniques. The group of molecular biologic methods in the tumour diagnostic laboratory are a variety of DNA/RNA-based molecular techniques in which the DNA/RNA are extracted (compared from *in situ* above) from the cell and then analysed. These techniques are highly sensitive, specific and rapid and have revolutionised diagnostic pathology in neoplastic as well as non-neoplastic conditions (e.g. in infectious and inherited disorders, and in identity diagnosis). Molecular diagnostic techniques include: DNA analysis by Southern blot, RNA analysis by northern blot, and polymerase chain reaction (PCR).

iv) DNA microarray analysis of tumours. Currently, it is possible to perform molecular profiling of a tumour by use of gene chip technology which allows measurement of levels of expression of several thousand genes (up-regulation or down-regulation) simultaneously.

◆ SELF ASSESSMENT

1. **Hamartoma refers to:**
 - A. Tumour differentiating towards more than one cell line
 - B. Tumour arising from totipotent cells
 - C. Mass of disorganised but mature cells indigenous to the part
 - D. Mass of ectopic rests of normal tissue
2. **Increased number of normal mitoses may be present in the following tissues except:**
 - A. Bone marrow cells
 - B. Nails
 - C. Hepatocytes
 - D. Intestinal epithelium
3. **A tumour is termed medullary when it is almost entirely composed of:**
 - A. Amyloid stroma
 - B. Large areas of necrosis
 - C. Abundant lymphoid tissue
 - D. Parenchymal cells
4. **All the following malignant tumours metastasise except:**
 - A. Synovial sarcoma
 - B. Malignant mesothelioma
 - C. Glioma
 - D. Neuroblastoma
5. **The following malignant tumours frequently spread through haematogenous route except:**
 - A. Bronchogenic carcinoma
 - B. Renal cell carcinoma
 - C. Follicular carcinoma thyroid
 - D. Seminoma testis
6. **Degradation of ECM is brought about by the following except:**
 - A. Proteases
 - B. Metalloproteinases
 - C. Free radicals
 - D. Cathepsin D
7. **Grading of tumours depends upon the following except:**
 - A. Degree of anaplasia
 - B. Metastatic spread
 - C. Rate of growth of cells
 - D. Degree of differentiation
8. **Patients of xeroderma pigmentosum are prone to develop the following cancers except:**
 - A. Basal cell carcinoma
 - B. Sweat gland carcinoma
 - C. Malignant melanoma
 - D. Squamous cell carcinoma
9. **The primary target of reactive electrophiles is as under:**
 - A. Cytochrome P-450
 - B. RNA
 - C. DNA
 - D. Mitochondria
10. **Carcinogenic influence of radiation appears after:**
 - A. < 2 years
 - B. 2-5 years
 - C. 5-10 years
 - D. > 10 years

11. The following hereditary diseases have higher incidence of cancers due to inherited defect in DNA repair mechanism **except**:
 - A. Ataxia telangiectasia
 - B. Xeroderma pigmentosum
 - C. Familial polyposis coli
 - D. Bloom's syndrome
12. The following form of ionising radiation exposure is associated with highest risk of cancer:
 - A. α -rays
 - B. β -rays
 - C. γ -rays
 - D. X-rays
13. Women receiving oestrogen therapy have an increased risk of developing the following cancers **except**:
 - A. Breast cancer
 - B. Endometrial carcinoma
 - C. Gallbladder cancer
 - D. Hepatocellular carcinoma
14. Important cyclins in cell cycle include the following **except**:
 - A. Cyclin A
 - B. Cyclin B
 - C. Cyclin C
 - D. Cyclin D
15. Bittner milk factor is a transmissible agent belonging to the following category:
 - A. Acute transforming virus
 - B. Slow transforming virus
 - C. HTLV-I
 - D. HTLV-II
16. Important examples of tumour suppressor genes implicated in human cancers include the following **except**:
 - A. RB gene
 - B. *TP53*
 - C. APC
 - D. ERB-B
17. An example of tumour-associated antigen (TAA) is:
 - A. Testis specific antigen (MAGE)
 - B. Alpha-fetoprotein (AFP)
 - C. Carcinoembryonic antigen (CEA)
 - D. Prostate specific antigen (PSA)
18. Hypercalcaemia as a paraneoplastic syndrome is observed in the following tumours **except**:
 - A. Squamous cell carcinoma lung
 - B. Small cell carcinoma lung
 - C. Renal cell carcinoma
 - D. Breast cancer
19. Lymphocytic infiltrate is frequently present in the following tumours indicative of host immune response **except**:
 - A. Seminoma testis
 - B. Medullary carcinoma breast
 - C. Papillary carcinoma thyroid
 - D. Malignant melanoma
20. The following antibody-stain is used in immunohistochemistry to identify epithelial cells:
 - A. Desmin
 - B. Vimentin
 - C. Cytokeratin
 - D. Neurofilaments
21. Which of the following viral infection is not known to produce any human tumour?
 - A. Polyoma virus
 - B. EBV
 - C. HSV
 - D. HTLV
22. All are autosomal dominant inherited cancer syndromes **except**:
 - A. Retinoblastoma
 - B. Xeroderma pigmentosum
 - C. HNPCC
 - D. Neurofibromatosis
23. Phosphorylation of retinoblastoma gene:
 - A. Inhibits cell replication
 - B. Promotes cellular quiescence
 - C. Stops cell cycle progression
 - D. Promotes cell division

24. p53:
 A. Activates cyclins
 B. Activates BAX
 C. Activates CDKs
 D. Activates bcl2
25. All are matrix metalloproteinases *except*:
 A. Collagenase
 B. Gelatinase
 C. Stromelysin
 D. Elastase
26. All are anti-angiogenesis factors *except*:
 A. Thrombospondin-1
 B. Basic fibroblast growth factor (bFGF)
 C. Endostatin
 D. Angiostatin
27. Which of the following is a test for mutagenicity?
 A. Kveim's test
 B. Ame's test
 C. Schilling's test
 D. Mantoux test
28. All are autosomal dominant inherited cancer syndromes *except*:
 A. Retinoblastoma
 B. Xeroderma pigmentosum
 C. HNPCC
 D. Neurofibromatosis

KEY

1 = C	2 = B	3 = D	4 = C
5 = D	6 = C	7 = B	8 = B
9 = C	10 = D	11 = C	12 = A
13 = C	14 = C	15 = B	16 = D
17 = D	18 = B	19 = C	20 = C
21 = A	22 = B	23 = D	24 = B
25 = D	26 = B	27 = B	28 = B



Environmental and Nutritional Diseases

INTRODUCTION (p. 236)

The subject of environmental hazards to health has assumed great significance in the modern world.

Some of the important factors which have led to the alarming environmental degradation are as under:

1. Population explosion
2. Urbanisation of rural and forest land to accommodate the increasing numbers
3. Accumulation of wastes
4. Unsatisfactory disposal of radioactive waste
5. Industrial effluents and automobile exhausts.

But the above atmospheric pollutants appear relatively minor compared with *voluntary intake of three pollutants*—use of tobacco, consumption of alcohol and intoxicant drugs.

ENVIRONMENTAL POLLUTION (p. 236)

□ AIR POLLUTION (p. 236)

A vast variety of pollutants are inhaled daily, some of which may cause trivial irritation to the upper respiratory pathways, while others may lead to acute or chronic injury to the lungs, and some are implicated in causation of lung cancer. Whereas some pollutants are prevalent in certain industries (such as coal dust, silica, asbestos), others are general pollutants present widespread in the ambient atmosphere (e.g. sulphur dioxide, nitrogen dioxide, carbon monoxide). In highly polluted cities where coal consumption and automobile exhaust accumulate in the atmosphere, the air pollutants become visible as 'smog'.

The adverse effects of air pollutants on lung depend upon a few variables that include:

- ◆ longer duration of exposure;
- ◆ total dose of exposure;
- ◆ impaired ability of the host to clear inhaled particles; and
- ◆ particle size of 1-5 μm capable of getting impacted in the distal airways to produce tissue injury.

□ TOBACCO SMOKING (p. 237)

Habits (p. 237)

Tobacco smoking is the most prevalent and preventable cause of disease and death. The harmful effects of smoking pipe and cigar are somewhat less. Long-term smokers of filter-tipped cigarettes appear to have 30-50% lower risk of development of cancer due to reduced inhalation of tobacco smoke constituents.

In India, a country of 1.2 billion people, a quarter (300 million) are tobacco users in one form or the other (**Web Image 9.1**). Smoking *bidis* and chewing *pan masala*, *zarda* and *gutka* are more widely practiced than cigarettes. Habit of smoking *chutta* (a kind of indigenous cigar) in which the lighted end is put in mouth is practiced in the Indian state of Andhra Pradesh

and is associated with higher incidence of squamous cell carcinoma of hard palate. Another habit prevalent in Indian states of Uttar Pradesh and Bihar and in parts of Sri Lanka is chewing of tobacco alone or mixed with slaked lime as a bolus of *paan* kept in mouth for long hours which is the major cause of cancer of upper aerodigestive tract and oral cavity. *Hookah* smoking, in which tobacco smoke passes through a water-filled chamber which cools the smoke before it is inhaled by the smoker, is believed by some reports to deliver less tar and nicotine than cigarettes and hence fewer tobacco-related health consequences.

Besides the harmful effects of smoking on active smokers themselves, involuntary exposure of smoke to bystanders (passive smoking) is also injurious to health, particularly to infants and children.

Dose and Duration (p. 237)

Tobacco contains several harmful constituents which include nicotine, many carcinogens, carbon monoxide and other toxins (**Web Table 9.1**).

The harmful effects of smoking are related to a variety of factors, the most important of which is dose of exposure expressed in terms of pack years. For example, one pack of cigarettes daily for 5 years means 5 pack years. It is estimated that a person who smokes 2 packs of cigarettes daily at the age of 30 years reduces his life by 8 years than a non-smoker. On cessation of smoking, the higher mortality slowly declines and the beneficial effect reaches the level of non-smokers after 20 or more of smoke-free years.

Tobacco-Related Diseases (p. 237)

The major diseases accounting for higher mortality in tobacco smokers include the following (in descending order of frequency):

- i) Coronary heart disease
- ii) Cancer of the lung
- iii) Chronic obstructive pulmonary disease (COPD).

Besides above, smokers suffer higher risk of development of a few other cancers and non-neoplastic conditions as illustrated in **Web Image 9.2**.

CORONARY HEART DISEASE. Cigarette smoking is one of the four major risk factors for myocardial infarction and acts synergistically with the other three—hypercholesterolaemia, hypertension and diabetes mellitus. There is more severe, extensive and accelerated atherosclerosis of coronary arteries and aorta in smokers, possibly due to increased platelet aggregation and impaired lung function that causes reduced myocardial oxygen supply.

LUNG CANCER. This is the most common cancer in men throughout world and most frequent cancer in women too in the United States exceeding in incidence beyond that of breast cancer in that country.

OTHER CANCERS. Besides lung cancer, smokers have higher risk of development of cancer of upper aerodigestive tract (lips, oral cavity, larynx, oesophagus), pancreas, urinary bladder and kidney.

NON-NEOPLASTIC DISEASES. A few examples are as under:

- i) Chronic obstructive pulmonary disease (COPD) that includes chronic bronchitis and emphysema as the most common.
- ii) Peptic ulcer disease with 70% higher risk in smokers.
- iii) Early menopause in smoker women.
- iv) In smoking pregnant women, higher risk of lower birth weight of foetus, higher perinatal mortality and intellectual deterioration of newborn.

CHEMICAL AND DRUG INJURY (p. 238)

During life, each one of us is exposed to a variety of chemicals and drugs. These are broadly divided into the following three categories:

- ◆ *Therapeutic (iatrogenic) agents* e.g. drugs, which when administered indiscriminately are associated with adverse effects.
- ◆ *Non-therapeutic agents* e.g. alcohol, lead, carbon monoxide, drug abuse.
- ◆ *Environmental chemicals* e.g. long-term or accidental exposure to certain man-made or naturally-occurring chemicals.

□ THERAPEUTIC (IATROGENIC) DRUG INJURY (p. 238)

Adverse effects of drugs may appear due to:

- ◆ overdose;
- ◆ genetic predisposition;
- ◆ exaggerated pharmacologic response;
- ◆ interaction with other drugs; and
- ◆ unknown factors.

It is beyond the scope of this book to delve into the list of drugs with their harmful effects. However, some of the common forms of iatrogenic drug injury and the offending drugs are listed in **Web Table 9.2**.

□ NON-THERAPEUTIC TOXIC AGENTS (p. 238)

ALCOHOLISM (p. 238)

Chronic alcoholism is defined as the regular imbibing of an amount of ethyl alcohol (ethanol) that is sufficient to harm an individual socially, psychologically or physically. However, adverse effects—acute as well as chronic, are related to the quantity of alcohol content imbibed and duration of consumption. Generally, 10 gm of ethanol is present in:

- ◆ a can of beer (or half a bottle of beer);
- ◆ 120 ml of neat wine; or
- ◆ 30 ml of 43% liquor (small peg).

A daily consumption of 40 gm of ethanol (4 small pegs or 2 large pegs) is likely to be harmful but intake of 100 gm or more daily is certainly dangerous. Daily and heavy consumption of alcohol is more harmful than moderate social drinking since the liver, where ethanol is metabolised, gets time to heal.

Metabolism (p. 238)

Absorption of alcohol begins in the stomach and small intestine and appears in blood shortly after ingestion. Alcohol is then distributed to different organs and body fluids proportionate to the blood levels of alcohol. About 2-10% of absorbed alcohol is excreted via urine, sweat and exhaled through breath, the last one being the basis of breath test employed by law-enforcement agencies for alcohol abuse. In brief alcohol is metabolised in the liver by the following 3 pathways (**Web Image 9.3**):

- ◆ By the major rate-limiting pathway of alcohol dehydrogenase (ADH) in the cytosol, which is then quickly destroyed by aldehyde dehydrogenase (ALDH), especially with low blood alcohol levels.
- ◆ Via microsomal P-450 system (microsomal ethanol oxidising system, MEOS) when the blood alcohol level is high.
- ◆ Minor pathway via catalase from peroxisomes.

III-Effects of Alcoholism (p. 239)

A. ACUTE ALCOHOLISM. The acute effects of inebriation are most prominent on the central nervous system but it also injures the stomach and liver.

1. Central nervous system. Alcohol acts as a CNS depressant; the intensity of effects of alcohol on the CNS are related to the quantity consumed and duration over which consumed, which are reflected by the blood levels of alcohol.

However, chronic alcoholics develop CNS tolerance and adaptation and, therefore, can withstand higher blood levels of alcohol without such serious effects.

2. Stomach. Acute alcohol intoxication may cause vomiting, acute gastritis and peptic ulceration.

3. Liver. Acute alcoholic injury to the liver.

B. CHRONIC ALCOHOLISM. Chronic alcoholism produces widespread injury to organs and systems. It is now known that most of the alcohol-related injury to different organs is due to toxic effects of alcohol and accumulation of its main toxic metabolite, acetaldehyde, in the blood. Other proposed mechanisms of tissue injury in chronic alcoholism is free-radical mediated injury and genetic susceptibility to alcohol-dependence and tissue damage.

Some of the more important organ effects in chronic alcoholism are as under (**Web Image 9.4**):

1. Liver. Alcoholic liver disease and cirrhosis are the most common and important effects of chronic alcoholism.

2. Pancreas. Chronic calcifying pancreatitis and acute pancreatitis are serious complications of chronic alcoholism.

3. Gastrointestinal tract. Gastritis, peptic ulcer and oesophageal varices associated with fatal massive bleeding may occur.

4. Central nervous system. Peripheral neuropathies and Wernicke-Korsakoff syndrome, cerebral atrophy, cerebellar degeneration and amblyopia (impaired vision) are seen in chronic alcoholics.

5. Cardiovascular system. Alcoholic cardiomyopathy and beer-drinkers' myocardiosis with consequent dilated cardiomyopathy may occur. Level of HDL (atherosclerosis-protective lipoprotein), however, has been shown to increase with moderate consumption of alcohol.

6. Endocrine system. In men, testicular atrophy, feminisation, loss of libido and potency, and gynaecomastia may develop. These effects appear to be due to lowering of testosterone levels.

7. Blood. Haematopoietic dysfunction with secondary megaloblastic anaemia and increased red blood cell volume may occur.

8. Immune system. Alcoholics are more susceptible to various infections.

9. Cancer. There is higher incidence of cancers of upper aerodigestive tract in chronic alcoholics but the mechanism is not clear.

□ **LEAD POISONING** (p. 240)

Lead poisoning may occur in children or adults due to accidental or occupational ingestion.

In children, following are the main sources of lead poisoning:

- ◆ Chewing of lead-containing furniture items, toys or pencils.
- ◆ Eating of lead paint flakes from walls.

In adults, the sources are as follows:

- ◆ Occupational exposure to lead during spray painting, recycling of automobile batteries (lead oxide fumes), mining, and extraction of lead.
- ◆ Accidental exposure by contaminated water supply, house freshly coated with lead paint, and sniffing of lead-containing petrol (hence unleaded petrol introduced as fuel).

Lead is absorbed through the gastrointestinal tract or lungs. The absorbed lead is distributed in two types of tissues (**Web Image 9.5**):

- a) *Bones, teeth, nails and hair* representing relatively harmless pool of lead.

b) *Brain, liver, kidneys and bone marrow* accumulate the remaining 10% lead which is directly toxic to these organs. It is excreted via kidneys.

Lead toxicity occurs in the following organs predominantly:

1. **Nervous system:** The changes are as under:

● *In children*, lead encephalopathy; oedema of brain, flattening of gyri and compression of ventricles.

● *In adults*, demyelinating peripheral motor neuropathy which typically affects radial and peroneal nerves resulting in wristdrop and footdrop respectively.

2. **Haematopoietic system:** The changes in blood are quite characteristic:

● *Microcytic hypochromic anaemia* due to inhibition of two enzymes: delta-aminolevulinic acid dehydrogenase required for haem synthesis, and through inhibition of ferrochelatase required for incorporation of ferrous iron into the porphyrin ring.

● Prominent basophilic stippling of erythrocytes.

3. **Kidneys:** Lead is toxic to proximal tubular cells of the kidney and produces *lead nephropathy* characterised by accumulation of intranuclear inclusion bodies consisting of lead-protein complex in the proximal tubular cells.

4. **Gastrointestinal tract:** Lead toxicity in the bowel manifests as acute abdomen presenting as lead colic.

□ CARBON MONOXIDE POISONING (p. 241)

Carbon monoxide (CO) is a colourless and odourless gas produced by incomplete combustion of carbon. Sources of CO gas are:

- automobile exhaust;
- burning of fossil fuel in industries or at home; and
- tobacco smoke.

CO poisoning may present in 2 ways:

● **Acute CO poisoning** in which there is sudden development of brain hypoxia characterised by oedema and petechial haemorrhages.

● **Chronic CO poisoning** presents with nonspecific changes of slowly developing hypoxia of the brain.

□ DRUG ABUSE (p. 241)

Drug abuse is defined as the use of certain drugs for the purpose of 'mood alteration' or 'euphoria' or 'kick' but subsequently leading to habit-forming, dependence and eventually addiction. Some of the commonly abused drugs and substances are as under:

1. *Marijuana* or '*pot*' is psychoactive substance.
2. *Derivatives of opium* that includes heroin and morphine.
3. *CNS depressants* include barbiturates, tranquilisers and alcohol.
4. *CNS stimulants* e.g. cocaine and amphetamines.
5. *Psychedelic drugs* (meaning enjoyable perception-giving) e.g. LSD.
6. *Inhalants* e.g. glue, paint thinner, nail polish remover, aerosols, amyl nitrite.

Following are a few common drug abuse-related infectious complications:

1. At the site of injection—cellulitis, abscesses, ulcers, thrombosed veins
2. Thrombophlebitis
3. Bacterial endocarditis
4. High risk for AIDS
5. Viral hepatitis and its complications
6. Focal glomerulonephritis
7. Talc (foreign body) granuloma formation in the lungs.

190 □ ENVIRONMENTAL CHEMICALS (p. 242)

A large number of chemicals are found as contaminants in the ecosystem, food and water supply and find their way into the food chain of man. These substances exert their toxic effects depending upon their mode of absorption, distribution, metabolism and excretion. Some of the substances are directly toxic while others cause ill-effects via their metabolites.

Some of the common examples of environmental chemicals are given below:

1. Agriculture chemicals. Modern agriculture thrives on pesticides, fungicides, herbicides and organic fertilisers which may pose a potential acute poisoning as well as long-term hazard.

◆ Acute poisoning by organophosphate insecticides is quite well known in India as accidental or suicidal poison by inhibiting acetyl cholinesterase and sudden death.

◆ Chronic human exposure to low level agricultural chemicals is implicated in cancer, chronic degenerative diseases, congenital malformations and impotence but the exact cause-and-effect relationship is lacking.

2. Volatile organic solvents. Such substances include methanol, chloroform, petrol, kerosene, benzene, ethylene glycol, toluene etc.

3. Metals. Pollution by occupational exposure to toxic metals such as mercury, arsenic, cadmium, iron, nickel and aluminium are important hazardous environmental chemicals.

4. Aromatic hydrocarbons. The halogenated aromatic hydrocarbons containing polychlorinated biphenyl which are contaminant in several preservatives, herbicides and antibacterial agents are a chronic health hazard.

5. Cyanide. Cyanide in the environment is released by combustion of plastic, silk and is also present in cassava and the seeds of apricots and wild cherries. Cyanide is a very toxic chemical and kills by blocking cellular respiration by binding to mitochondrial cytochrome oxidase.

6. Environmental dusts. These substances causing pneumoconioses are discussed in chapter 17 while those implicated in cancer are discussed in Chapter 8.

□ THERMAL AND ELECTRICAL INJURY (p. 242)

Thermal and electrical burns, fall in body temperature below 35°C (hypothermia) and elevation of body temperature above 41°C (hyperthermia), are all associated with tissue injury.

◆ **Hypothermia** may cause focal injury as in frostbite, or systemic injury and death as occurs on immersion in cold water for varying time.

◆ **Hyperthermia** likewise, may be localised as in cutaneous burns, and systemic as occurs in fevers.

◆ **Thermal burns** depending upon severity are categorised into full thickness (third degree) and partial thickness (first and second degree). The most serious complications of burns are haemoconcentration, infections and contractures on healing.

◆ **Electrical burns** may cause damage *firstly*, by electrical dysfunction of the conduction system of the heart and death by ventricular fibrillation, and *secondly* by heat produced by electrical energy.

□ INJURY BY RADIATION (p. 242)

The most important form of radiation injury is ionising radiation which has three types of effects on cells:

- i) Somatic effects which cause acute cell killing.
- ii) Genetic damage by mutations and therefore, passes genetic defects in the next progeny of cells.
- iii) Malignant transformation of cells.

Ionising radiation is widely employed for diagnostic purpose as well as for radiotherapy of malignant tumours. Radiation-induced cell death is mediated by radiolysis of water in the cell with generation of toxic hydroxyl radicals. During radiotherapy, some normal cells coming in the field of radiation are also damaged. In general, radiation-induced tissue injury predominantly affects endothelial cells of small arteries and arterioles, causing necrosis and ischaemia.

Ionising radiation causes damage to the following major organs:

1. *Skin*: radiation dermatitis, cancer.
2. *Lungs*: interstitial pulmonary fibrosis.
3. *Heart*: myocardial fibrosis, constrictive pericarditis.
4. *Kidney*: radiation nephritis.
5. *Gastrointestinal tract*: strictures of small bowel and oesophagus.
6. *Gonads*: testicular atrophy in males and destruction of ovaries.
7. *Haematopoietic tissue*: pancytopenia due to bone marrow depression.
8. *Eyes*: cataract.

Besides ionising radiation, other form of harmful radiation is *solar (u.v.) radiation* which may cause acute skin injury as sunburns, chronic conditions such as solar keratosis and early onset of cataracts in the eyes.

Before describing the nutritional diseases, it is essential to know the components of normal and adequate nutrition.

1. **Energy.** The requirement of energy by the body is calculated in Kcal per day. In order to retain stable weight and undertake day-to-day activities, the energy intake must match the energy output.
2. **Proteins.** Dietary proteins provide the body with amino acids for endogenous protein synthesis and are also a metabolic fuel for energy (1 g of protein provides 4 Kcal). *Nine essential amino acids* (histidine, isoleucine, leucine, lysine, methionine/cystine, phenylalanine/tyrosine, theonine, tryptophan and valine) must be supplied by dietary intake as these cannot be synthesised in the body.
3. **Fats.** Fats and fatty acids (in particular linolenic, linoleic and arachidonic acid) should comprise about 35% of diet (1 g of fat yields 9 Kcal).
4. **Carbohydrates.** Dietary carbohydrates, are the major source of dietary calories, especially for the brain, RBCs and muscles (1 g of carbohydrate provides 4 Kcal).
5. **Vitamins.** These are mainly derived from exogenous dietary sources and are essential for maintaining the normal structure and function of cells. A healthy individual requires 4 fat-soluble vitamins (A, D, E and K) and 11 water-soluble vitamins (C, B₁/thiamine, B₂/riboflavin, B₃/niacin/nicotinic acid, B₅/pantothenic acid, B₆/pyridoxine, folate/folic acid, B₁₂/cyanocobalamin, choline, biotin, and flavonoids). Vitamin deficiencies result in individual deficiency syndromes, or may be part of a multiple deficiency state.
6. **Minerals.** A number of minerals like iron, calcium, phosphorus and certain trace elements (e.g. zinc, copper, selenium, iodine, chlorine, sodium, potassium, magnesium, manganese, cobalt, molybdenum etc) are essential for health.
7. **Water.** Water intake is essential to cover the losses in faeces, urine, exhalation and insensible loss so as to avoid under- or over-hydration. Although body's water needs varies according to physical activities and weather conditions, average requirement of water is 1.0-1.5 ml water/ Kcal

of energy spent. Infants and pregnant women have relatively higher requirements of water.

8. Non-essential nutrients. Dietary fibre composed of cellulose, hemicellulose and pectin, though considered non-essential, are important due to their beneficial effects in lowering the risk of colonic cancer, diabetes and coronary artery disease.

Pathogenesis of Deficiency Diseases (p. 243)

The nutritional deficiency disease develops when the essential nutrients are not provided to the cells adequately. The nutritional deficiency may be of 2 types:

1. **Primary deficiency.** This is due to either the lack or decreased amount of essential nutrients in diet.
2. **Secondary or conditioned deficiency.** Secondary or conditioned deficiency is malnutrition occurring as a result of the various factors. These are as under:
 - i) *Interference with ingestion.*
 - ii) *Interference with absorption.*
 - iii) *Interference with utilisation.*
 - iv) *Increased excretion.*
 - v) *Increased nutritional demand.*

□ OBESITY (p. 243)

Obesity is defined as an excess of adipose tissue that imparts health risk; a body weight of 20% excess over ideal weight for age, sex and height is considered a health risk.

ETIOLOGY. *Obesity results when caloric intake exceeds utilisation.* The imbalance of these two components can occur in the following situations:

1. *Inadequate pushing of oneself away from the dining table* causing overeating.
2. *Insufficient pushing of oneself out of the chair* leading to inactivity and sedentary life style.
3. *Genetic predisposition* to develop obesity.
4. *Diets largely derived from carbohydrates* and fats than protein-rich diet.
5. *Secondary obesity* may result following a number of underlying diseases such as hypothyroidism, Cushing's disease, insulinoma and hypothalamic disorders.

PATHOGENESIS. The lipid storing cells, adipocytes comprise the adipose tissue, and are present in vascular and stromal compartment in the body. Besides the generally accepted role of adipocytes for fat storage, these cells also release endocrine-regulating molecules. These molecules include: energy regulatory hormone (leptin), cytokines (TNF- α and interleukin-6), insulin sensitivity regulating agents (adiponectin, resistin and RBP4), prothrombotic factors (plasminogen activator inhibitor), and blood pressure regulating agent (angiotensinogen).

Adipose mass is increased due to enlargement of adipose cells due to excess of intracellular lipid deposition as well as due to increase in the number of adipocytes. Recently, two obesity genes have been found: *ob* gene and its protein product leptin, and *db* gene and its protein product leptin receptor.

SEQUELAE OF OBESITY. Marked obesity is a serious health hazard and may predispose to a number of clinical disorders and pathological changes described below and illustrated in **Web Image 9.6**.

METABOLIC CHANGES. These are as under:

1. Hyperinsulinaemia.
2. Type 2 diabetes mellitus.

3. Hypertension.
4. Hyperlipoproteinaemia.
5. Atherosclerosis.
6. Nonalcoholic fatty liver disease (NAFLD).
7. Cholelithiasis.
8. Hypoventilation syndrome (Pickwickian syndrome).
9. Osteoarthritis.
10. Cancer.

□ STARVATION (p. 245)

Starvation is a state of overall deprivation of nutrients. Its causes may be the following:

- i) deliberate fasting—religious or political;
- ii) famine conditions in a country or community; or
- iii) secondary undernutrition such as due to chronic wasting diseases (infections, inflammatory conditions, liver disease), cancer etc. Cancer results in malignant cachexia as a result of which cytokines are elaborated e.g. tumour necrosis factor- α , elastases, proteases etc.

METABOLIC CHANGES. The following metabolic changes take place in starvation:

1. **Glucose.** During fasting state, insulin-independent tissues such as the brain, blood cells and renal medulla continue to utilise glucose while insulin-dependent tissues like muscle stop taking up glucose. This results in release of glycogen stores of the liver to maintain normal blood glucose level.
2. **Proteins.** *Proteins* breakdown to release amino acids which are used as fuel for hepatic gluconeogenesis so as to maintain glucose needs of the brain. This results in nitrogen imbalance due to excretion of nitrogen compounds as urea.
3. **Fats.** After about one week of starvation, protein breakdown is decreased while *triglycerides* of adipose tissue breakdown to form glycerol and fatty acids. The fatty acids are converted into ketone bodies in the liver which are used by most organs including brain in place of glucose.

□ PROTEIN-ENERGY MALNUTRITION (p. 245)

The inadequate consumption of protein and energy as a result of primary dietary deficiency or conditioned deficiency may cause loss of body mass and adipose tissue, resulting in protein energy or protein calorie malnutrition (PEM or PCM).

The spectrum of *clinical syndromes* produced as a result of PEM includes the following (**Web Image 9.7**):

1. *Kwashiorkor* which is related to protein deficiency though calorie intake may be sufficient.
2. *Marasmus* is starvation in infants occurring due to overall lack of calories.

The salient features of the two conditions are contrasted in **Web Table 9.3**.

DISORDERS OF VITAMINS (p. 246)

Vitamins are organic substances which cannot be synthesised within the body and are essential for maintenance of normal structure and function of cells. Thus, these substances must be provided in the human diet. Most of the vitamins are of plant or animal origin so that they normally enter the body as constituents of ingested plant food or animal food.

ETIOLOGY OF VITAMIN DEFICIENCIES. In the developing countries, *multiple deficiencies* of vitamins and other nutrients are common due to generalised malnutrition of dietary origin. In the developed countries, *individual*

vitamin deficiencies are noted more often, particularly in children, adolescent, pregnant and lactating women, and in some due to poverty.

CLASSIFICATION OF VITAMINS. Vitamins are conventionally divided into 2 groups: fat-soluble and water-soluble.

Web Table 9.4 sums up the various clinical disorders produced by vitamin deficiencies.

□ **FAT-SOLUBLE VITAMINS** (p. 247)

Vitamin A (Retinol) (p. 247)

PHYSIOLOGY. Vitamin A or retinol is a fat-soluble alcohol. It is available in diet in 2 forms:

- ◆ *As preformed retinol*, the dietary sources of which are animal-derived foods such as yolk of eggs, butter, whole milk, fish, liver, kidney.
- ◆ *As provitamin precursor carotenoid*, which is derived from β -carotene-containing foods such as yellow plants and vegetables e.g. carrots, potatoes, pumpkins, mangoes, spinach. β -carotene can be absorbed intact or converted in the intestinal mucosa to form retinaldehyde which is subsequently reduced to retinol.

The **physiologic functions** of retinol are as follows:

1. *Maintenance of normal vision in reduced light.*
2. *Maintenance of structure and function of specialised epithelium.*
3. *Maintenance of normal cartilaginous and bone growth.*
4. *Increased immunity* against infections in children.
5. *Anti-proliferative effect.* .

LESIONS IN VITAMIN A DEFICIENCY. Consequent to vitamin A deficiency, following pathologic changes are seen (**Web Image 9.8**):

1. Ocular lesions. Lesions in the eyes are most obvious. *Night blindness* is usually the first sign of vitamin A deficiency. As a result of replacement metaplasia of mucus-secreting cells by squamous cells, there is dry and scaly scleral conjunctiva (*xerophthalmia*). The lacrimal duct also shows hyperkeratosis. Corneal ulcers may occur which may get infected and cause *keratomalacia*. *Bitot's spots* may appear which are focal triangular areas of opacities due to accumulation of keratinised epithelium. If these occur on cornea, they impede transmission of light. Ultimately, infection, scarring and opacities lead to *blindness*.

2. Cutaneous lesions. The skin develops papular lesions giving toad-like appearance (*xeroderma*). This is due to follicular hyperkeratosis and keratin plugging in the sebaceous glands.

3. Other lesions. These are as under:

- i) *Squamous metaplasia of respiratory epithelium* of bronchus and trachea may predispose to respiratory infections.
- ii) *Squamous metaplasia of pancreatic ductal epithelium* may lead to obstruction and cystic dilatation.
- iii) *Squamous metaplasia of urothelium* of the pelvis of kidney may predispose to pyelonephritis and perhaps to renal calculi.
- iv) Long-standing metaplasia may cause progression to *anaplasia* under certain circumstances.
- v) *Bone growth* in vitamin A deficient animals is retarded.
- vi) *Immune dysfunction* may occur due to damaged barrier epithelium and compromised immune defenses.
- vii) *Pregnant women* may have increased risk of maternal infection, mortality and impaired embryonic development.

HYPERVITAMINOSIS A. Very large doses of vitamin A can produce toxic manifestations in children as well as in adults. These may be *acute* or *chronic*.

Acute toxicity. This results from a single large dose of vitamin A. The effects include neurological manifestations resembling brain tumour e.g. headache, vomiting, stupor, papilloedema.

Chronic toxicity. The clinical manifestations of chronic vitamin A excess are as under:

- i) *Neurological*
- ii) *Skeletal pains*
- iii) *Cutaneous involvement*
- iv) *Hepatomegaly*
- v) *Hypercarotenaemia*.

Vitamin D (Calcitriol) (p. 248)

PHYSIOLOGY. This fat-soluble vitamin exists in 2 activated *sterol forms*:

- ◆ Vitamin D₂ or *calciferol*; and
- ◆ Vitamin D₃ or *cholecalciferol*.

There are 2 *main sources* of vitamin D:

i) Endogenous synthesis. 80% of body's need of vitamin D is met by endogenous synthesis from the action of ultraviolet light on 7-dehydrocholesterol widely distributed in oily secretions of the skin.

ii) Exogenous sources. The other source of vitamin D is diet such as deep sea fish, fish oil, eggs, butter, milk, some plants and grains.

Irrespective of the source of vitamin D, it must be converted to its *active metabolites* (25-hydroxy vitamin D and 1,25-dihydroxy vitamin D or calcitriol) after its metabolism in the liver and kidney for being functionally active (**Web Image 9.9**).

1, 25-dihydroxy vitamin D (calcitriol) is 5-10 times more potent biologically than 25-hydroxy vitamin D. The production of calcitriol by the kidney is regulated by:

- ◆ plasma levels of calcitriol (hormonal feedback);
- ◆ plasma calcium levels (hypocalcaemia stimulates synthesis); and
- ◆ plasma phosphorus levels (hypophosphataemia stimulates synthesis).

The main **physiologic functions** of the most active metabolite of vitamin D, calcitriol, are mediated by its binding to nuclear receptor superfamily, vitamin D receptor, expressed on a wide variety of cells. These actions are as under:

1. Maintenance of normal plasma levels of calcium and phosphorus.

The major essential function of vitamin D is to promote mineralisation of bone. This is achieved by the following actions of vitamin D:

- i) *Intestinal absorption* of calcium and phosphorus.
- ii) *On bones*.
- iii) *On kidneys*.

2. Antiproliferative effects.

LESIONS IN VITAMIN D DEFICIENCY. Deficiency of vitamin D may result from:

- i) reduced endogenous synthesis due to inadequate exposure to sunlight;
- ii) dietary deficiency of vitamin D;
- iii) malabsorption of lipids due to lack of bile salts such as in intrahepatic biliary obstruction, pancreatic insufficiency and malabsorption syndrome;
- iv) derangements of vitamin D metabolism as occur in kidney disorders (chronic renal failure, nephrotic syndrome, uraemia), liver disorders (diffuse liver disease) and genetic disorders; and
- v) resistance of end-organ to respond to vitamin D.

Deficiency of vitamin D from any of the above mechanisms results in 3 types of lesions:

RICKETS. The primary defects in rickets are:

- ◆ interference with mineralisation of bone; and
- ◆ deranged endochondral and intramembranous bone growth.

The pathogenesis of lesions in rickets is better understood by contrasting them with sequence of changes in normal bone growth as outlined in **Web Table 9.5**.

MORPHOLOGIC FEATURES. Rickets occurs in growing children from 6 months to 2 years of age. The disease has the following lesions and clinical characteristics (**Web Image 9.10**):

Skeletal changes. These are as under:

- i) *Craniotabes*
- ii) *Harrison's sulcus*
- iii) *Rachitic rosary*
- iv) *Pigeon-chest deformity*
- v) *Bow legs*
- vi) *Knock knees*
- vii) *Lower epiphyses of radius may be enlarged.*
- viii) *Lumbar lordosis.*

OSTEOMALACIA. Osteomalacia is the adult counterpart of rickets in which there is failure of mineralisation of the osteoid matrix.

MORPHOLOGIC FEATURES. Due to deficiency of vitamin D, osteoid matrix laid down fails to get mineralised. In H and E stained microscopic sections, this is identified by widened and thickened osteoid seams (stained pink) and decreased mineralisation at the borders between osteoid and bone (stained basophilic). *von Kossa's stain* for calcium may be employed to mark out the wide seams of unstained osteoid while the calcified bone is stained black.

Clinical features. Osteomalacia is characterised by:

- i) muscular weakness;
- ii) vague bony pains;
- iii) fractures following trivial trauma;
- iv) incomplete or greenstick fractures; and
- v) looser's zones or pseudofractures at weak places in bones.

HYPERVITAMINOSIS D. Very large excess of vitamin D may cause increased intestinal absorption of calcium and phosphorus, leading to hypercalcaemia, hyperphosphataemia and increased bone resorption. These changes may result in the following effects:

- i) increased urinary excretion of calcium and phosphate;
- ii) predisposition to renal calculi;
- iii) osteoporosis; and
- iv) widespread metastatic calcification, more marked in the renal tubules, arteries, myocardium, lungs and stomach.

Vitamin E (α -Tocopherol) (p. 250)

PHYSIOLOGY. Out of many naturally-occurring tocoferols and tocotrienols, α -tocopherol is biologically the most active fat soluble compound for humans. Vitamin E is found in most of the ordinary foods such as vegetables, grains, nuts and oils. It is absorbed from the intestine and transported in blood in the form of chylomicrons. It is stored in fat depots, liver and muscle.

The main **physiologic functions** of vitamin E are as under:

1. *Anti-oxidant activity*
2. *Scavenger of free radicals*
3. *Inhibits prostaglandin synthesis.*
4. *Activates protein kinase C and phospholipase A₂.*

LESIONS IN VITAMIN E DEFICIENCY. Lesions of vitamin E deficiency are as follows:

1. *Neurons* with long axons develop degeneration in the posterior columns of spinal cord.
2. *Peripheral nerves* may also develop myelin degeneration in the axons.

3. *Skeletal muscles* may develop denervation.
4. *Retinal pigmentary degeneration* may occur.
5. *Red blood cells* deficient in vitamin E such as in premature infants have reduced lifespan.
6. In experimental animals, vitamin E deficiency can produce *sterility* in both male and female animals.

Vitamin K (p. 250)

PHYSIOLOGY. Vitamin K (*K for Koagulations in Danish*) exists in nature in 2 forms:

- ◆ Vitamin K₁ or *phyloquinone*, obtained from exogenous dietary sources such as most green leafy vegetables; and
- ◆ Vitamin K₂ or *menaquinone*, produced endogenously by normal intestinal flora. Phylloquinone can be converted into menaquinone in some organs.

The main **physiologic function** of vitamin K is in hepatic microsomal carboxylation reaction for vitamin K-dependent coagulation factors (most importantly factor II or prothrombin; others are factors VII, IX and X).

LESIONS IN VITAMIN K DEFICIENCY. Since vitamin K is necessary for the manufacture of prothrombin, its deficiency leads of *hypoprothrombinaemia*.

Because most of the green vegetables contain vitamin K and that it can be synthesised endogenously, vitamin K deficiency is frequently a conditioned deficiency. The conditions which may bring about vitamin K deficiency are as follows:

1. Haemorrhagic disease of newborn.
2. Biliary obstruction.
3. Due to malabsorption syndrome.
4. Due to anticoagulant therapy.
5. Due to antibiotic therapy.
6. Diffuse liver disease.

□ WATER-SOLUBLE VITAMINS (p. 251)

Vitamin C (Ascorbic Acid) (p. 251)

PHYSIOLOGY. Vitamin C exists in natural sources as L-ascorbic acid closely related to glucose. The major sources of vitamin C are citrus fruits such as orange, lemon, grape fruit and some fresh vegetables like tomatoes and potatoes. It is present in small amounts in meat and milk.

The **physiologic functions** of vitamin C are due to its ability to carry out *oxidation-reduction reactions*:

1. Vitamin C has been found to have *antioxidant* properties and can scavenge free radicals.
2. Ascorbic acid is required for hydroxylation of proline to form hydroxyproline which is an essential component of *collagen*.
3. Besides collagen, it is necessary for the *ground substance* of other mesenchymal structures such as osteoid, chondroitin sulfate, dentin and cement substance of vascular endothelium.
4. Vitamin C being a *reducing substance* has other functions such as:
 - ◆ hydroxylation of dopamine to norepinephrine;
 - ◆ maintenance of folic acid levels by preventing oxidation of tetrahydrofolate; and
 - ◆ role in iron metabolism in its absorption, storage and keeping it in reduced state.

LESIONS IN VITAMIN C DEFICIENCY. Vitamin C deficiency in the food or as a conditioned deficiency results in scurvy. The lesions and clinical manifestations of scurvy are seen more commonly at two peak ages: in early childhood and in the very aged. These are as under (**Web Image 9.11**):

2. Skeletal lesions. The most prominent change is the *deranged formation of osteoid matrix and not deranged mineralisation*. Consequently, mineralised cartilage under the widened and irregular epiphyseal plates project as *scorbutic rosary*.

3. Delayed wound healing. There is delayed healing of wounds in scurvy due to following:

- ◆ deranged collagen synthesis;
- ◆ poor preservation and maturation of fibroblasts; and
- ◆ localisation of infections in the wounds.

4. Anaemia. Anaemia is common in scurvy. It may be the result of haemorrhage, interference with formation of folic acid or deranged iron metabolism.

5. Lesions in teeth and gums. Scurvy may interfere with development of dentin. The gums are soft and swollen, may bleed readily and get infected commonly.

6. Skin rash. Hyperkeratotic and follicular rash may occur in scurvy.

VITAMIN B COMPLEX (p. 252)

The term vitamin B was originally coined for a substance capable of curing beriberi (B from beriberi). Now, vitamin B complex is commonly used for a *group of essential compounds which are biochemically unrelated but occur together in certain foods* such as green leafy vegetables, cereals, yeast, liver and milk. Most of the vitamins in this group are involved in metabolism of proteins, carbohydrates and fats.

Thiamine (Vitamin B₁) (p. 252)

PHYSIOLOGY. Thiamine was the first in the family of vitamin B complex group and hence named B₁. Thiamine hydrochloride is available in a variety of items of diet such as peas, beans, pulses, yeast, green vegetable roots, fruits, meat, pork, rice and wheat bran. A few substances in the diet (strong tea, coffee) act as *anti-thiamines*.

The main **physiologic function** of thiamine is in carbohydrate metabolism. Thiamine after absorption is phosphorylated to form thiamine pyrophosphate which is the functionally active compound.

LESIONS IN THIAMINE DEFICIENCY. Thiamine deficiency can occur from primary or conditioned causes, chronic alcoholism being an important cause. The deficiency state leads to failure of complete combustion of carbohydrate and accumulation of pyruvic acid. This results in beriberi which produces lesions at 3 target tissues (peripheral nerves, heart and brain).

The features of 3 forms of beriberi are as under:

1. *Dry beriberi (peripheral neuritis).*
2. *Wet beriberi (cardiac manifestations).* The heart in beriberi is flabby (due to thin and weak myocardium), enlarged and globular in appearance due to 4-chamber dilatation (**Web Image 9.12**).
3. *Cerebral beriberi (Wernicke-Korsakoff's syndrome).*
 - i) Wernicke's encephalopathy
 - ii) Korsakoff's psychosis

Riboflavin (Vitamin B₂) (p. 253)

PHYSIOLOGY. Riboflavin used to be called 'yellow respiratory enzyme' (*flavus* = yellow), now known as 'cytochrome oxidase enzyme' which is important in view of its role as cellular respiratory coenzyme. The vitamin is usually distributed in plant and animal foods such as the liver, beef, mutton,

pork, eggs, milk and green vegetables. Like other water-soluble vitamins, it is rapidly absorbed from the bowel and stored in tissues like liver.

LESIONS IN RIBOFLAVIN DEFICIENCY. Lesions due to primary or conditioned deficiency of riboflavin (*aribo flavinosis*) are as follows:

1. *Ocular lesions*
2. *Cheilosis and angular stomatitis*
3. *Glossitis*
4. *Skin changes*
5. *Anaemia.*

Niacin/Nicotinic Acid (Vitamin B₃) (p. 253)

PHYSIOLOGY. As with thiamine and riboflavin, niacin or nicotinic acid or vitamin B₃ is also widely distributed in plant and animal foods such as the liver, kidney, meat, green vegetables and whole grain cereals. Niacin includes biologically active derivative *nicotinamide* which is essential for the formation of 2 oxidative coenzymes (*dehydrogenases*):

- ◆ NAD (nicotinamide adenine dinucleotide) which is required for dehydrogenation in the metabolism of fat, carbohydrates and proteins.
- ◆ NADP (nicotinamide adenine dinucleotide phosphate) which is essential for dehydrogenation in the hexose monophosphate shunt of glucose metabolism.

LESIONS IN NIACIN DEFICIENCY. Deficiency of niacin causes pellagra, so named because of the rough skin of such patients (Italian *pelle agra* = rough skin). Pellagra may result from dietary deficiency in those who largely subsist on maize since niacin in maize is present in bound form and hence not absorbable.

Lesions in pellagra are characterised by 3Ds:

1. *Dermatitis*
2. *Diarrhoea*
3. *Dementia.*

Pyridoxine (Vitamin B₆) (p. 253)

PHYSIOLOGY. Pyridoxine or vitamin B₆ is widely distributed in all animal and plant foods such as meat, liver, eggs, green vegetables and whole grain cereals. Pyridoxine exists in 3 closely related naturally-occurring substances—*pyridoxine*, *pyridoxal* and *pyridoxamine*. All of these can be converted into biologically active coenzyme, pyridoxal 5-phosphate.

The major **physiologic functions** of pyridoxine are related to:

- ◆ fat metabolism;
- ◆ protein metabolism;
- ◆ amino acid metabolism such as decarboxylation of amino acids, transmethylation of methionine, conversion of tryptophan to niacin;
- ◆ steroid metabolism;
- ◆ neurotransmitter synthesis; and
- ◆ haem synthesis.

LESIONS IN PYRIDOXINE DEFICIENCY. Vitamin B₆ deficiency may result from inadequate dietary intake or may result from secondary deficiency such as increased demand in pregnancy and lactation, chronic alcoholism and intake of certain drugs (e.g. isoniazid in the treatment of tuberculosis, penicillamine, oestrogen in oral contraceptives etc).

The **lesions** of pyridoxine deficiency include the following:

1. Convulsions in infants born to mothers who had been administered large doses of vitamin B₆ for hyperemesis gravidarum (pyridoxine dependence)
2. Dermatitis and seborrhoea
3. Cheilosis and angular stomatitis
4. Glossitis (bald tongue)

5. Neuropathy
6. Depression, confusion
7. Sideroblastic anaemia.

Folate (Folic Acid) and Cyanocobalamin (Vitamin B₁₂) (p. 253)

Both these vitamins included in the B complex group are required for red cell formation. Their deficiency leads to megaloblastic anaemia which is discussed in Chapter 12.

Biotin (p. 253)

PHYSIOLOGY. Biotin is a water-soluble vitamin and a member of vitamin B complex group. It is available in food sources such as organ meat, soya beans, egg yolk; however egg-white has a protein avidin which binds to biotin and blocks its bioavailability.

The major **physiologic functions** of biotin are as under:

1. In gene expression
2. In gluconeogenesis
3. In fatty acid synthesis
4. In catabolism of certain amino acids such as leucine
4. As carrier of CO₂ in carboxylase enzymes.

LESIONS IN BIOTIN DEFICIENCY. The lesions of biotin deficiency are as under:

1. Mental and neurologic symptoms such as hallucination, depression, paraesthesia
2. Anorexia
3. Nausea
4. Scaly, seborrhoeic dermatitis
5. In infants, hypotonia, alopecia and rash near ears.

CHOLINE (p. 254)

PHYSIOLOGY. Choline is precursor form of acetylcholine and betaine. Choline is widely distributed as lecithin in foods such as egg yolk, milk, wheat and organ meat. Choline is also synthesised in the liver.

The major **physiologic functions** of choline are as under:

1. In maintenance structural integrity of cell membranes
2. In transmembrane signaling pathways
3. In cholinergic neurotransmission
4. In metabolism of lipids and cholesterol.

LESIONS IN CHOLINE DEFICIENCY. Choline deficiency develops in patients on choline-free parenteral nutrients:

1. Fatty liver with deranged liver enzymes
2. Skeletal muscle damage with elevated CPK levels.

FLAVONOIDS (p. 254)

PHYSIOLOGY. Flavonoids are a form of polyphenols present in several fruits and vegetables and are the constituents which imparts colour, flavour and taste to these edible products. Particular food and vegetables rich in flavonoids are berries, grapes, apples, broccoli, onions, legumes etc.

The major **physiologic functions** of flavonoids are as under:

1. As antioxidants
2. In cell signaling pathways

LESIONS IN BIOTIN DEFICIENCY. Flavonoids have been a recent addition to the family of vitamins. Present data on animal experiments and human clinical studies indicates that they play a role in prevention of neurodegenerative diseases, osteoporosis and diabetes.

METALS AND TRACE ELEMENTS (p. 254)

Several minerals in trace amounts are essential for health since they form components of enzymes and cofactors for metabolic functions. Besides *calcium* and *phosphorus* required for vitamin D manufacture, others include: *iron, copper, iodine, zinc, selenium, manganese, nickel, chromium, molybdenum, fluorine*. However, out of these, the dietary deficiency of first five trace elements is associated with deficiency states which are discussed in detail in respective chapters later. These are as under:

- i) *Iron*: Microcytic hypochromic anaemia.
- ii) *Calcium*: reduced bone mass, osteoporosis.
- iii) *Phosphorous*: Rickets, osteomalacia.
- iv) *Copper*: Muscle weakness, neurologic defect, anaemia, growth retardation.
- v) *Iodine*: Goitre and hyperthyroidism, cretinism.

DIET AND CANCER (p. 254)

There are three possible mechanisms on which the story of this relationship can be built up:

1. Dietary content of exogenous carcinogens:

- i) The most important example in this mechanism comes from naturally-occurring carcinogen *aflatoxin* which is strongly associated with high incidence of hepatocellular carcinoma in those consuming grain contaminated with mould, *Aspergillus flavus*.
- ii) *Artificial sweeteners* (e.g. saccharine cyclomates), food additives and pesticide contamination of food are implicated as carcinogens derived from diet.

2. Endogenous synthesis of carcinogens or promoters:

- i) In the context of etiology of *gastric carcinoma*, nitrites, nitrates and amines from the digested food are transformed in the body to carcinogens—nitrosamines and nitrosamides.
- ii) In the etiology of *colon cancer*, low fibre intake and high animal-derived fats are implicated. High fat diet results in rise in the level of bile acids and their intermediate metabolites produced by intestinal bacteria which act as carcinogens. The low fibre diet, on the other hand, does not provide adequate protection to the mucosa and reduces the stool bulk and thus increases the time the stools remain in the colon.
- iii) In the etiology of *breast cancer*, epidemiologic studies have implicated the role of animal proteins, fats and obesity with as yet unsubstantiated evidence.

3. Inadequate protective factors:

As already mentioned, some components of diet such as *vitamin C, A, E, selenium*, and *β-carotenes* have protective role against cancer.

SELF ASSESSMENT

1. **The harmful effects of smoking of following tobacco products are most severe:**

A. Cigarettes	B. Bidis
C. Cigar	D. Pipe
2. **The major pathway of ethanol metabolism in the liver is via:**
 - A. Alcohol dehydrogenase in the SER
 - B. Microsomal P-450
 - C. Catalase in the peroxisomes
 - D. None of the above

3. **Lead poisoning produces the following change in red cells:**
 - A. Pappenheimer bodies
 - B. Howell-Jolly bodies
 - C. Basophilic stippling
 - D. Heinz bodies
4. **Between CO and O₂, haemoglobin has:**
 - A. Greater affinity for former
 - B. Greater affinity for latter
 - C. Equal affinity for both
 - D. No affinity for the former
5. **1 g of carbohydrate provides:**
 - A. 2 Kcal
 - B. 4 Kcal
 - C. 7 Kcal
 - D. 9 Kcal
6. **Health risk in obesity is due to weight in excess of the following for age and sex:**
 - A. 10%
 - B. 20%
 - C. 30%
 - D. 40%
7. **Obesity is due to:**
 - A. Hyperplasia of adipocytes only
 - B. Hypertrophy of adipocytes only
 - C. Hyperplasia as well as hypertrophy of adipocytes
 - D. Fatty change in liver only
8. **In starvation, first nutrient to be depleted in the body is:**
 - A. Fat
 - B. Carbohydrate
 - C. Protein
 - D. Vitamins
9. **State of hypervitaminosis occurs in:**
 - A. Vitamin A and B
 - B. Vitamin B and C
 - C. Vitamin C and D
 - D. Vitamin A and D
10. **The main function of vitamin E is:**
 - A. Immune regulation
 - B. Hepatic microsomal carboxylation
 - C. Antioxidant activity
 - D. Maintenance of structure and function of epithelia
11. **Most active form of Vitamin D is:**
 - A. 7-dehydrocholesterol
 - B. Ergosterol
 - C. 25-hydroxy Vitamin D
 - D. 1, 25-dihydroxy Vitamin D
12. **Which of the following is the gene for obesity?**
 - A. Rb gene
 - B. db gene
 - C. p53 gene
 - D. p63 gene

KEY

- | | | | |
|-------|--------|--------|--------|
| 1 = B | 2 = A | 3 = C | 4 = A |
| 5 = C | 6 = B | 7 = C | 8 = B |
| 9 = D | 10 = C | 11 = D | 12 = B |



Genetic and Paediatric Diseases

In the western countries, developmental and genetic birth defects constitute about 50% of total mortality in infancy and childhood, while in the developing and underdeveloped countries 95% of infant mortality is attributed to environmental factors such as poor sanitation and undernutrition.

Genetic and paediatric diseases are covered under the following headings:

1. *Developmental defects*: Errors in morphogenesis
2. *Cytogenetic (Karyotypic) defects*: chromosomal abnormalities
3. *Single-gene defects*: Mendelian disorders
4. *Multifactorial inheritance disorders*
5. *Other paediatric diseases*

DEVELOPMENTAL DEFECTS (p. 256)

Developmental defects are a group of abnormalities during foetal life due to errors in morphogenesis. The branch of science dealing with the study of developmental anomalies is called *teratology*. Certain chemicals, drugs, physical and biologic agents are known to induce such birth defects and are called *teratogens*. The morphologic abnormality or defect in an organ or anatomic region of the body so produced is called *malformation*.

Pathogenesis (p. 256)

The teratogens may result in one of the following outcomes:

- i) Intrauterine death
- ii) Intrauterine growth retardation (IUGR)
- iii) Functional defects
- iv) Malformation

The **effects** of teratogens in inducing developmental defects are related to the following factors:

- ◆ *Variable individual susceptibility to teratogen.*
- ◆ *Intrauterine stage at which patient is exposed to teratogen.*
- ◆ *Dose of teratogen.*
- ◆ *Specificity of developmental defect for specific teratogen.*

Classification (p. 256)

Various developmental anomalies resulting from teratogenic effects are categorised as under:

Agensis means the complete absence of an organ e.g. unilateral or bilateral agensis of kidney.

Aplasia is the absence of development of an organ with presence of rudiment or anlage e.g. aplasia of lung with rudimentary bronchus.

Hypoplasia is incomplete development of an organ not reaching the normal adult size e.g. microglossia.

Atresia refers to incomplete formation of lumen in hollow viscus e.g. oesophageal atresia.

Developmental dysplasia is defective development of cells and tissues resulting in abnormal or primitive histogenetic structures e.g. renal dysplasia.

Dystraphic anomalies are the defects resulting from failure of fusion e.g. spina bifida.

204 **Ectopia or heterotopia** refers to abnormal location of tissue at ectopic site e.g. pancreatic heterotopia in the wall of stomach.

Examples of Developmental Defects (p. 256)

1. **Anencephaly-spina bifida complex.** This is the group of anomalies resulting from failure to fuse (dystraphy). While anencephaly results from failure of neural tube closure, spina bifida occurs from incomplete closure of the spinal cord and vertebral column, often in the lumbar region. The latter results in meningocele or meningomyelocele.
2. **Thalidomide malformations.** Thalidomide is the best known example of teratogenic drug which was used as a sedative by pregnant women in 1960s in England and Germany and resulted in high incidence of limb-reduction anomalies (phocomelia) in the newborns.
3. **Foetal hydantoin syndrome.** Babies born to mothers on anti-epileptic treatment with hydantoin have characteristic facial features and congenital heart defects.
4. **Foetal alcohol syndrome.** Ethanol is another potent teratogen. Consumption of alcohol by pregnant mother in first trimester increases the risk of miscarriages, stillbirths, growth retardation and mental retardation in the newborn.
5. **TORCH complex.** Infection with TORCH group of organisms (*Toxoplasma*, Others, *Rubella*, *Cytomegalovirus*, and *Herpes simplex*) during pregnancy is associated with multisystem anomalies and TORCH syndrome in the newborn.
6. **Congenital syphilis.** Vertical transmission of syphilis from mother to foetus is characterised by Hutchinson's triad: interstitial keratitis, sensorineural deafness and deformed Hutchinson's teeth, along with saddle-nose deformity.

CYTOGENETIC (KARYOTYPIC) ABNORMALITIES (p. 257)

In a female, one of the two X chromosomes (paternal or maternal derived) is inactivated during embryogenesis as stated in *Lyon hypothesis*. This inactivation is passed to all the somatic cells while the germ cells in the female remain unaffected i.e. ovary will always have active X chromosome. Such an inactive X chromosome in the somatic cells in females lies condensed in the nucleus and is called as *sex chromatin* seen specifically in the somatic cells in females. *Nuclear sexing* can be done for genetic female testing by preparing and staining the smears of squamous cells scraped from oral cavity, or by identifying the *Barr body* in the circulating neutrophils as drumstick appendage attached to one of the nuclear lobes (**Web Image 10.1**). A minimum of 30% cells positive for sex chromatin is indicative of genetically female composition.

Though chromosomes can be studied in any human nucleated cells, circulating lymphocytes are more often used for this purpose. The study is done by arresting the dividing cells in metaphase by colchicine and then spreading them on glass slide and staining them with Giemsa stain.

Karyotype is the photographic representation of the stained preparation of chromosomes.

Each chromosome is composed of a pair of identical double helix of chromosomal DNA called *chromatids*. The chromosomes are classified based on their length and location of the *centromere*; centromere is the point where the two chromatids cross each other (**Web Image 10.2**). The distal end of each chromosome is called telomere.

Chromosomal banding techniques are employed for study of classes of chromosomes. Chromosomal bands are unique alternate dark and light staining patterns. Banding techniques include:

- i) G-banding (Giemsa stain);
- ii) Q-banding (quinacrine fluorescence stain);

- iii) R-banding (reverse Giemsa staining); and
- iv) C-banding (constitutive heterochromatin demonstration).

Numerical Abnormalities (p. 257)

1. **Polyploidy** is the term used for the number of chromosomes which is a multiple of haploid number e.g. triploid or 3N (69 chromosomes), tetraploid or 4N (92 chromosomes). Polyploidy occurs normally in megakaryocytes and dividing liver cells. Polyploidy in somatic cells of conceptus results in spontaneous abortions.

2. **Aneuploidy** is the number of chromosomes which is not an exact multiple of haploid number e.g. hypodiploid or 2N-1 (45 chromosomes) monosomy, hyperdiploid or 2N+1 (47 chromosomes) trisomy.

The most common mechanism of aneuploidy is **nondisjunction**. Nondisjunction is the failure of chromosomes to separate normally during cell division during first or second stage of meiosis, or in mitosis.

Three clinically important syndromes resulting from numerical aberrations of chromosomes due to nondisjunction are as under and their main clinical features are illustrated in **Web Image 10.3**:

- ◆ **Down's syndrome.** There is trisomy 21 in about 95% cases of Down's syndrome due to nondisjunction during meiosis in one of the parents. Down's syndrome is the most common chromosomal disorder and is the commonest cause of mental retardation. The incidence of producing offspring with Down's syndrome rises in mothers over 35 years of age.

- ◆ **Klinefelter's syndrome.** Klinefelter's syndrome is the most important example of sex chromosome trisomy. About 80% cases have 47, XXY karyotype while others are mosaics. Typically, these patients have testicular dysgenesis. In general, sex chromosome trisomies are more common than trisomies of autosomes.

- ◆ **Turner's syndrome.** Turner's syndrome is an example of monosomy (45, X0) most often due to loss of X chromosome in paternal meiosis.

Structural Abnormalities (p. 258)

During cell division (meiosis as well as mitosis), certain structural abnormalities of chromosomes may appear. These may occur during gametogenesis and then transmitted to all somatic cells and cause hereditary transmissible disorders, or may produce somatic cell mutations and result in changes varying from no effect to some forms of cancers. Structural abnormalities may be balanced or unbalanced.

- ◆ **Balanced structural alteration** means no change in total number of genes or genetic material.

- ◆ **Unbalanced structural alteration** refers to gene rearrangement resulting in loss or gain of genetic material.

Some common forms of structural abnormalities are as under (**Web Image 10.4**):

TRANSLOCATIONS. Translocation means crossing over or exchange of fragment of chromosome which may occur between non-homologous or homologous chromosomes. There are two main types of translocations: reciprocal in about two-third and Robertsonian in one-third cases:

- ◆ **Reciprocal translocation** is the exchange of genetic material between two non-homologous (heterologous) chromosomes without involving centromere (acentric). Such translocations occur due to single breaks in both the chromosomes and the exchange is detected by banding techniques. Reciprocal translocation may be balanced (without any loss of genetic material during the exchange) or unbalanced (with some loss of genetic material).

- i) **Balanced reciprocal translocation** is more common and the individual is phenotypically normal e.g. translocation between long arm (q) of chromosomes 22 and long arm (q) of chromosome 9 written as 46, XX, t(9;22). This translocation is termed Philadelphia chromosome seen in most cases of chronic myeloid leukaemia.

ii) *Unbalanced reciprocal translocations* are less common and account for repeated abortions and malformed children.

◆ **Robertsonian translocation** is less common than reciprocal translocation. In this, there is fusion of two acrocentric chromosomes (having very short arms) at the centromere (centric fusion) with loss of short arms.

DELETIONS. Loss of genetic material from the chromosome is called deletion. Deletion may be from the terminal or middle portion of the chromosome. The examples of deletion are: *cri du chat* (named after cry of infant like that of a cat) syndrome (deletion of short arm of chromosome 5).

INVERSION. Inversion is a form of rearrangement involving breaks of a single chromosome at two points. Inversion may be pericentric or paracentric, depending upon whether the rotation occurs at the centromere or at the acentric portion of the arm of chromosome.

RING CHROMOSOME. A ring of chromosome is formed by a break at both the telomeric (terminal) ends of a chromosome followed by deletion of the broken fragment and then end-to-end fusion.

ISOCHROMOSOME. When centromere, rather than dividing parallel to the long axis, instead divides transverse to the long axis of chromosome, it results in either two short arms only or two long arms only called isochromosomes. The example involving isochromosome of X-chromosome is seen in some cases (15%) of Turner's syndrome.

SINGLE-GENE DEFECTS (MENDELIAN DISORDERS) (p. 259)

In order to unravel causes of disease at genetic level, spectacular advances have been made in human genetics. With mapping of human genome consisting of about 30,000 genes, it is possible to perform molecular profiling of diseases at genetic level.

Single-gene defects follow the classic mendelian patterns of inheritance and are also called mendelian disorders. These disorders are the result of mutation of a single gene of large effect.

MUTATIONS. The term mutation is applied to permanent change in the DNA of the cell. Mutations affecting germ cells are transmitted to the next progeny producing *inherited diseases*, while the mutations affecting somatic cells give rise to *various cancers* and *congenital malformations*. Presently, following types of mutations have been described:

i) **Point mutation** is the result of substitution of a single nucleotide base by a different base i.e. replacement of an amino acid by another e.g. in sickle cell anaemia there is point mutation by substitution of glutamic acid by valine in the polypeptide chain.

ii) **Stop codon or nonsense mutation** refers to a type of point mutation in which the protein chain is prematurely terminated or truncated.

iii) **Frameshift mutation** occurs when there is insertion or deletion of one or two base pairs in the DNA sequence e.g. in cystic fibrosis of pancreas.

iv) **Trinucleotide repeat mutation** is characterised by amplification of a sequence of three nucleotides.

INHERITANCE PATTERN. The inheritance pattern of genetic abnormalities may be *dominant or recessive, autosomal or sex-linked*:

◆ A *dominant gene** produces its effects, whether combined with similar dominant or recessive gene. *Recessive genes* are effective only if both genes are similar. However, when both alleles of a gene pair are expressed

*A particular characteristic of an individual is determined by a pair of single *genes*, located at the same specific site termed *locus*, on a pair of homologous chromosomes. These paired genes are called *alleles* which may be *homozygous* when alike, and *heterozygous* if dissimilar. *Genotype* is the genetic composition of an individual while *phenotype* is the effect of genes produced.

in heterozygous state, it is called *codominant inheritance*. A single gene may express in multiple allelic forms known as *polymorphism*.

◆ *Autosomal dominant inheritance* pattern is characterised by one faulty copy of gene (i.e. mutant allele) in any autosome and one copy of normal allele; disease phenotype is seen in all such individuals. Patients having autosomal dominant inheritance disease have 50% chance of passing on the disease to the next generation.

◆ *In autosomal recessive inheritance*, both copies of genes are mutated. Usually, it occurs when both parents are carriers of the defective gene, i.e. having one normal allele and one defective allele in each parent, and each parent passes on their defective gene to the next progeny causing disease. There is 25% chance of transmission of autosomal recessive disease when both parents are carriers.

◆ *X-linked disorders* are caused by mutations in genes on X-chromosome, derived from either one of the two X-chromosomes in females, or from the single X-chromosome of the male. There are much fewer genes on Y-chromosome and are determinant for testis; they are not known to cause any sex-linked disorder. Therefore, all sex-linked disorders are, in fact, X-linked disorders.

Web Table 10.1 lists important examples of groups of genetic disorders: *autosomal* recessive (the largest group), *codominant* (intermediate), and *dominant*, and *sex-(X-) linked* recessive and dominant disorders.

STORAGE DISEASES (INBORN ERRORS OF METABOLISM) (p. 260)

Storage diseases or inborn errors of metabolism are biochemically distinct groups of disorders occurring due to genetic defect in the metabolism of carbohydrates, lipids, and proteins resulting in intracellular accumulation of metabolites. Since lysosomes comprise the chief site of intracellular digestion (autophagy as well as heterophagy), the material is naturally stored in the lysosomes, and hence the generic name 'lysosomal storage diseases'. Cells of mononuclear-phagocyte system are particularly rich in lysosomes; therefore, reticuloendothelial organs containing numerous phagocytic cells like the liver and spleen are most commonly involved in storage disease.

Based on the biochemical composition of the accumulated material within the cells, storage diseases are classified into distinct groups, each group containing a number of diseases depending upon the specific enzyme deficiency. A summary of major groups of storage diseases along with their respective enzyme deficiencies, major accumulating metabolites and the organs involved is presented in **Web Table 10.2**. A few general comments can be made about all storage diseases:

- ◆ All the storage diseases occur either as a result of autosomal recessive, or sex-(X-) linked recessive genetic transmission.
- ◆ Most, but not all, of the storage diseases are lysosomal storage diseases. Out of the glycogen storage diseases, only type II (Pompe's disease) is due to lysosomal enzyme deficiency.

A few important forms of storage diseases are described below:

Glycogen Storage Diseases (Glycogenoses) (p. 261)

These are a group of inherited disorders in which there is defective glucose metabolism resulting in excessive intracellular accumulation of glycogen in various tissues. Based on specific enzyme deficiencies, glycogen storage diseases are divided into 8 main types designated by Roman numerals I to VIII. However, based on pathophysiology, glycogen storage diseases can be divided into 3 main subgroups:

1. Hepatic forms are characterised by inherited deficiency of hepatic enzymes required for synthesis of glycogen for storage (e.g. von Gierke's disease or type I glycogenosis) or due to lack of hepatic enzymes necessary for breakdown of glycogen into glucose (e.g. type VI glycogenosis).

2. Myopathic forms on the other hand, are those disorders in which there is genetic deficiency of glycolysis to form lactate in the striated muscle resulting in accumulation of glycogen in the muscles (e.g. McArdle's disease or type V glycogenosis, type VII disease).

3. Other forms are those in which glycogen storage does not occur by either hepatic or myopathic mechanisms. In Pompe's disease or type II glycogenosis, there is lysosomal storage of glycogen, while in type IV there is deposition of abnormal metabolites of glycogen in the brain, heart, liver and muscles.

Mucopolysaccharidoses (MPS) (p. 262)

Mucopolysaccharidoses are a group of six inherited syndromes numbered from MPS I to MPS VI. Each of these results from deficiency of specific lysosomal enzyme involved in the degradation of mucopolysaccharides or glycosaminoglycans, and are, therefore, a form of lysosomal storage diseases. Mucopolysaccharides which accumulate in the MPS are: chondroitin sulphate, dermatan sulphate, heparan sulphate and keratan sulphate. All these syndromes are autosomal recessive disorders except MPS II (Hunter's syndrome) which has X-linked recessive transmission.

Syndrome of MPS manifests in infancy or early childhood and involves multiple organs and tissues, chiefly connective tissues, liver, spleen, bone marrow, lymph nodes, kidneys, heart and brain.

Gaucher's Disease (p. 262)

This is an autosomal recessive disorder in which there is mutation in lysosomal enzyme, acid β -glucosidase (earlier called glucocerebrosidase), which normally cleaves glucose from ceramide. This results in lysosomal accumulation of glucocerebroside (ceramide-glucose) in phagocytic cells of the body and sometimes in the neurons.

Clinically, 3 subtypes of Gaucher's disease are identified based on neuronopathic involvement:

- ◆ **Type I or classic form** is the adult form of disease in which there is storage of glucocerebroside in the phagocytic cells of the body, principally involving the spleen, liver, bone marrow, and lymph nodes. This is the most common type comprising 80% of all cases of Gaucher's disease.

- ◆ **Type II** is the infantile form in which there is progressive involvement of the central nervous system.

- ◆ **Type III** is the juvenile form of the disease having features in between type I and type II i.e. they have systemic involvement like in type I and progressive involvement of the CNS as in type II.

The clinical features depend upon the clinical subtype of Gaucher's disease. In addition to involvement of different organs and systems (splenomegaly, hepatomegaly, lymphadenopathy, bone marrow and cerebral involvement), a few other features include pancytopenia, or thrombocytopenia secondary to hypersplenism, bone pains and pathologic fractures.

M/E It shows large number of characteristically distended and enlarged macrophages called *Gaucher cells* which are found in the spleen, liver, bone marrow and lymph nodes, and in the case of neuronal involvement, in the Virchow-Robin space. The cytoplasm of these cells is abundant, granular and fibrillar resembling crumpled tissue paper. They have mostly a single nucleus but occasionally may have two or three nuclei (**Web Image 10.5, A, C**).

Niemann-Pick Disease (p. 262)

This is also an autosomal recessive disorder characterised by accumulation of sphingomyelin and cholesterol due to defect in acid sphingomyelinase.

Two types have been described: type A and B.

◆ **Type A** is more common and typically presents in infancy and is characterised by hepatosplenomegaly, lymphadenopathy, rapidly progressive deterioration of CNS and physical underdevelopment.

◆ **Type B** develops later and has a progressive hepatosplenomegaly with development of cirrhosis due to replacement of the liver by foam cells, and impaired lung function due to infiltration in lung alveoli.

M/E It shows storage of sphingomyelin and cholesterol within the lysosomes, particularly in the cells of mononuclear phagocyte system. The cells of Niemann-Pick disease are somewhat smaller than Gaucher cells and their cytoplasm is not wrinkled but is instead foamy and vacuolated which stains positively with fat stains (**Web Image 10.5, B**).

MULTIFACTORIAL INHERITANCE (p. 263)

Some normal phenotypic characteristics have also multifactorial inheritance e.g. colour of hair, eye, skin, height and intelligence. Multifactorial disorders are those disorders which result from the combined effect of genetic composition and environmental influences. Some common examples of such disorders in which environmental influences mask the mutant genes are as under:

1. Cleft lip and cleft palate
2. Pyloric stenosis
3. Diabetes mellitus
4. Hypertension
5. Congenital heart disease
6. Coronary heart disease.

OTHER PAEDIATRIC DISEASES (p. 263)

□ TUMOURS OF INFANCY AND CHILDHOOD (p. 263)

Tumours of infancy and childhood comprise 2% of all malignant tumours but they are the leading cause of death in this age group exceeded only by accidents. Benign tumours are more common than malignant neoplasms but they are generally of little immediate consequence. Another aspect requiring consideration here is the difficulty in differentiating benign tumours from tumour-like lesions.

Histogenesis

◆ Some tumours have probably evolved *in utero* and are apparent at birth or in immediate postnatal period. Such tumours are termed *developmental tumours*.

◆ Many other tumours originate in abnormally developed organs and organ rests; they become apparent subsequently and are termed *embryonic tumours*.

◆ In embryonic tumours, proliferation of embryonic cells occurs which have not reached the *differentiation stage* essential for specialised functions i.e. the cells proliferate as *undifferentiated* or as *partially differentiated* stem cells and an embryonal tumour is formed.

◆ Tumours of infancy and childhood have *some features of normal embryonic or foetal cells* in them which proliferate under growth promoting influence of oncogenes and suffer from mutations which make them appear morphologically malignant.

◆ Under appropriate conditions, these malignant embryonal cells may *cease to proliferate* and transform into non-proliferating mature differentiated cells e.g. a neonatal neuroblastoma may mature and differentiate into benign ganglioneuroma; tissues in foetal sacrococcygeal teratoma may mature with age to adult tissues and is assigned better prognosis.

1. Hamartomas. Hamartomas are focal accumulations of cells normally present in that tissue but are arranged in an abnormal manner i.e. though present at normal site they do not reproduce normal architecture identical to adjacent tissues.

2. Choristoma (heterotopia). Choristoma or heterotopia is collection of normal cells and tissues at aberrant locations e.g. heterotopic pancreatic tissue in the wall of small bowel or stomach.

A list of common benign tumours and tumour-like lesions is presented in **Web Table 10.3**.

MALIGNANT TUMOURS (p. 264)

A few *generalisations* can be drawn about paediatric cancers:

- ◆ In infants and children under 4 years of age: the most common malignant tumours are various types of *blastomas*.
- ◆ Children between 5 to 9 years of age: *haematopoietic malignancies* are more common.
- ◆ In the age range of 10-14 years (prepubertal age): *soft tissue and bony sarcomas* are the prominent tumours.

Based on these broad guidelines, classification of common paediatric malignant tumours at different age groups is presented in **Web Table 10.4**. These have been discussed in related chapters later.

◆ SELF ASSESSMENT

- 1. Teratogens are defined as agents which induce:**

A. Mitosis	B. Carcinogenesis
C. Birth defects	D. Fallot's tetralogy
- 2. For chromosomal study, it is best to use the following nucleated cells:**

A. Polymorphs	B. Lymphocytes
C. Epithelial cells	D. Fibroblasts
- 3. For chromosomal study, the dividing cells are arrested by colchicine in the following phase of cell cycle:**

A. Prophase	B. Metaphase
C. Anaphase	D. Telophase
- 4. Denver classification divides chromosomes based on their length into the following groups:**

A. A to C (3 groups)	B. A to E (5 groups)
C. A to G (7 groups)	D. A to I (9 groups)
- 5. Polyploidy is generally not a feature of dividing cells of the following type:**

A. Megakaryocytes	B. Hepatocytes
C. Tubular cells	D. Conceptus of abortions
- 6. Numeric abnormality in chromosome occurs in the following conditions *except*:**

A. Ph chromosome in CML	B. Turner's syndrome
C. Klinefelter's syndrome	D. Down's syndrome
- 7. Mutations affecting germ cells produce:**

A. Cancers	B. Inherited diseases
C. Congenital malformations	D. Aneuploidy
- 8. In lysosomal storage diseases, the following cells are particularly involved:**

A. Hepatocytes	B. Skeletal muscle
C. Macrophages	D. White pulp of spleen

9. Out of the following glycogenosis, the following is example of lysosomal storage disease: 211
- A. von Gierke's disease
 - B. Pompe's disease
 - C. Forbe's disease
 - D. Anderson's disease
10. Blastomas are childhood tumours seen more often in the age range of:
- A. <4 years
 - B. 5-9 years
 - C. 10-14 years
 - D. 14-16 years
11. All of the following are X-linked recessive disorders *except*:
- A. Haemophilia A & B
 - B. Chronic granulomatous disease
 - C. G-6 PD deficiency
 - D. Sickle cell anaemia
12. Gaucher cells are positive for all *except*:
- A. PAS
 - B. Mucicarmine
 - C. Oil red O
 - D. Prussian blue

KEY

- | | | | |
|-------|--------|--------|--------|
| 1 = C | 2 = B | 3 = B | 4 = C |
| 5 = C | 6 = A | 7 = B | 8 = C |
| 9 = B | 10 = A | 11 = D | 12 = B |



Basic Diagnostic Cytology

In general, diagnostic cytology pertains to the interpretation of cells from the human body that either exfoliate (desquamate) spontaneously from epithelial surfaces, or the cells are obtained from various organs/tissues by different clinical procedures. While histopathologic diagnosis is based on interpretation of changes in tissue architecture, the cytopathologic diagnosis rests upon alterations in morphology observed in single cells or small groups of cells.

□ ROLE OF DIAGNOSTIC CYTOLOGY (p. 266)

1. Diagnosis and management of cancer e.g.:

- i) Cytodiagnosis in its traditional role is a *valuable adjunct* to histopathology for establishing the vital tissue diagnosis.
- ii) Cytologic techniques also provide a *preliminary diagnosis* of cancer for later confirmation by histopathology.
- iii) In some fields, cytodiagnosis has replaced histopathology as the *primary method* of establishing a tissue diagnosis e.g. in breast cancer.
- iv) Cytodiagnosis has a major role in the detection and diagnosis of clinically silent *early cancer* e.g. carcinoma *in situ* of the uterine cervix.
- v) Cytodiagnosis may help in assessing *response to therapy*.
- vi) In the *follow-up* of previously diagnosed cases of cancer, it is of particular value in detecting dissemination (metastasis) or recurrence of tumour.

2. Identification of benign neoplasms e.g. fibroadenoma of the breast versus carcinoma.

3. Intraoperative pathologic diagnosis e.g. imprint smears along with frozen section for breast lumps.

4. Diagnosis of non-neoplastic/inflammatory conditions e.g. Hashimoto's thyroiditis.

5. Diagnosis of specific infections A variety of bacterial, viral protozoae and fungal infections can be identified by cytologic methods.

6. Cytogenetics e.g. buccal smear for Barr body.

7. Assessment of hormonal status in women e.g. to confirm the onset of menopause.

8. Identification of cell of origin. For example, identification of spermatogenic elements in aspirates from the testes in cases of male infertility.

For cytomorphological *recognition of cancer, nuclear characteristics* are used to determine the presence or absence of malignancy (**Web Table 11.1**). *Cytoplasmic characteristics* help in *typing the malignancy* e.g. keratinisation in squamous cell carcinoma, mucin droplets in adenocarcinoma, melanin pigment in melanomas.

□ BRANCHES OF DIAGNOSTIC CYTOLOGY (p. 267)

EXFOLIATIVE CYTOLOGY. This is the older branch that essentially involves the study of cells spontaneously shed off (as a result of continuous growth of epithelial linings) from epithelial surfaces into body cavities or body fluids. Exfoliative cytology is facilitated by the fact that the rate of exfoliation is enhanced in disease-states thereby yielding a larger number of cells for study.

INTERVENTIONAL CYTOLOGY. This is the branch in which samples are obtained by clinical procedures or surgical intervention. It is dominated by, and is virtually synonymous with, Fine Needle Aspiration Cytology (FNAC) which is also known as Aspiration Biopsy Cytology (ABC).

Their contrasting features are presented in **Web Table 11.2**.

EXFOLIATIVE CYTOLOGY (p. 267)

Type of samples that can be obtained from different organ systems for exfoliative cytodagnosis are listed in **Web Table 11.3**.

□ I. FEMALE GENITAL TRACT (p. 267)

Smears from the female genital tract have traditionally been known as 'Pap smears'. These smears may be prepared by different methods depending upon the purpose for which they are intended:

- i) *Lateral vaginal smears (LVS)*
- ii) *Vaginal 'pool' or 'vault' smears*
- iii) *Cervical smears*
- iv) *Combined (Fast) smears*
- v) *Triple (cervical-vaginal-endocervical or CVE) smears*
- vi) *Endocervical and endometrial smears.*

CELLS IN NORMAL COMBINED SMEARS. Normally, combined smear contains two types of cells: epithelial and others (**Web Image 11.1**):

Epithelial cells. There are 4 types of squamous epithelial cells in the cervical smear: *superficial, intermediate, parabasal and basal cells*. Morphological features of these cells are summed up in **Web Table 11.4**. A few variants of morphological forms and other epithelial cells are as under:

◆ *Navicular cells* are boat-shaped intermediate cells with folded cell borders. These cells appear in latter half of the menstrual cycle, during pregnancy and menopause.

◆ *Lactation cells* are parabasal cells with strongly acidophilic cytoplasm. These cells are seen so long as lactation persists.

◆ *Endocervical cells* appear either as single dispersed nuclei due to degeneration, or as clusters of columnar cells giving it honey-combed appearance.

◆ *Endometrial cells* are seen up to 12th day of menstrual cycle. They are slightly smaller than endocervical cells.

◆ *Trophoblastic cells* are seen following abortion or after delivery.

Other cells. Besides epithelial cells, other cells in cervical smears are leucocytes and Döderlein bacilli:

APPLICATIONS OF PAP SMEAR (p. 269)

Cytohormonal Evaluation (p. 269)

Assessment of hormonal status is best carried out from lateral vaginal smears although vaginal 'pool' or fast smears may also be used.

Several indices are available for description of cytohormonal patterns. The most commonly used are as under:

- i) *Acidophilic index (AI)*
- ii) *Pyknotic index (PI)*
- iii) *Maturation index (MI):* Some representative MIs at different stages of life are listed in **Web Table 11.5**.

Abnormal Combined Smears (p. 269)

In order to evolve a system acceptable to clinicians and cytopathologists, National Cancer Institute Workshop in 1988 developed the *Bethesda System (TBS)* for uniformity in evaluation as well as limitations of reporting in

cervicovaginal cytopathology; this was subsequently modified in 1991 and further updated in 2001. Briefly, it has three basic components in recommendations:

1. **Specimen adequacy:** It is an important component of quality assurance and provides feedback regarding sampling technique. It implies properly labelled, adequately fixed smears having sufficient number of evenly spread, well preserved cells as evaluated microscopically.
2. **General categorisation:** It includes categorising the smear in one of the three broad categories: within normal limits, benign cellular changes, and epithelial cell abnormalities.
3. **Descriptive diagnosis:** Final aspect of the Bethesda system includes detailed description of the benign cellular changes or epithelial cell abnormalities in the smear.

NON-NEOPLASTIC (BENIGN) CELLULAR CHANGES

i) **NON-SPECIFIC INFLAMMATORY CHANGES.** Inflammatory changes not associated with any specific infection or identifiable infectious agent (i.e. non-specific inflammation) are commonly seen in smears of the female genital tract as under:

- ◆ *Acute inflammatory changes* are characterised by an increase in the number of parabasal cells (due to disruption of superficial layers of the epithelium resulting in exposure of deeper layers), cytoplasmic acidophilia and vacuolisation, leucocytic migration into cytoplasm, and perinuclear halos with nuclear pyknosis or enlargement.

- ◆ *Chronic inflammatory changes (Reactive changes)* manifest in squamous cells as nuclear enlargement, hyperchromatism, and nucleolar prominence, with multinucleation in some instances.

ii) **SPECIFIC INFLAMMATORY CHANGES.** Specific inflammatory changes may be associated with a variety of infectious agents, the common among which are listed in **Web Table 11.6**.

a) **Bacterial agents:**

- ◆ *N. gonorrhoeae* (the gonococcus)
- ◆ *Gardnerella vaginalis*
- ◆ Tuberculosis of the female genital tract

b) **Viral agents:**

- ◆ *Human papilloma virus (HPV)* Morphologically, smears from HPV-infected subjects show aggregates of rounded to oval squamous cells with blunted cell margins, peripheral cytoplasmic condensation and crisply outlined perinuclear halos, with dysplastic or degenerative changes of nuclei; these changes are collectively termed 'koilocytotic changes.' (see **Web Image 11.4**). HPV can also be identified by Southern blot, PCR, *in situ* hybridization and by hybrid capture.

- ◆ Genital infection by *herpes simplex virus (HSV)*.

c) **Fungal agents:**

- ◆ Moniliasis (infection by *Candida albicans*) (**Web Image 11.2**).
- ◆ *Torulopsis glabrata*.

d) **Parasitic agents:**

- ◆ *Trichomonas vaginalis* (**Web Image 11.3**).
- ◆ *Entamoeba histolytica*.

NEOPLASTIC EPITHELIAL CELL ABNORMALITIES

Carcinoma of the uterine cervix still ranks high in the list as the most frequent cancer in developing countries of the world and is the leading cause of cancer morbidity and mortality. Vast majority of cervical cancers are of the squamous cell type, and the diagnosis of squamous cell carcinoma of the cervix and its precursor lesions is considered as the most important application of exfoliative cytology.

1. SQUAMOUS CELL ABNORMALITIES: The fully-developed invasive squamous cell carcinoma of the uterine cervix is preceded by a pre-invasive intraepithelial neoplastic process that is recognisable on histologic and cytologic examination.

Morphogenesis and nomenclature. The earliest recognisable change is *hyperplasia* of basal or reserve cells which normally constitute a single layer at the deepest part of the epithelium. The proliferating reserve cells next develop certain atypical features i.e. hyperchromasia and increased nuclear size. The continued proliferation of these atypical cells with loss of polarity, a concomitant increase in mitotic activity, and progressive involvement of more and more layers of the epithelium is known as *dysplasia* (disordered growth). When dysplasia involves the full thickness of the epithelium and the lesion morphologically resembles squamous cell carcinoma without invasion of underlying stroma, it is termed *carcinoma in situ (CIS)*. CIS further evolves through the stage of *microinvasive carcinoma* (with depth of stromal invasion not exceeding 3 mm) into full-blown *invasive squamous cell carcinoma*.

Previously depending on the degree of epithelial involvement, three grades of dysplasia were recognised: mild, moderate and severe. As the stages of dysplasia and CIS represented a continuous spectrum of lesions seen in the precancerous state, they were collectively termed 'cervical intraepithelial neoplasia' (CIN) and categorised as under (also see Web Image 24.5):

CIN I	Mild dysplasia	Primitive (atypical) cells, proliferating in lower third of epithelium.
CIN II	Moderate dysplasia	Involvement up to middle-third of epithelium.
CIN III	Severe dysplasia	Involvement of upper-third of epithelium.
	Carcinoma <i>in situ</i> (CIS)	Involvement of full thickness of epithelium.

Presently, *the Bethesda system* divides squamous cell abnormalities into four categories:

- ◆ *Atypical squamous cells of undetermined significance (ASCUS)* which represents cellular changes falling short of intraepithelial lesion.
- ◆ *Low-grade squamous intraepithelial lesion (L-SIL)* that includes CIN-I and cellular changes associated with HPV infection.
- ◆ *High-grade squamous intraepithelial lesion (H-SIL)* includes CIN grade II, III and CIS.
- ◆ Squamous cell carcinoma.

Cells exfoliating from the surface, thus, display cytoplasmic maturation and differentiation with nuclear atypia and are known as *dyskaryotic cells*.

The character and type of dyskaryotic cells observed in smears reflect the severity of dysplasia:

- ◆ In mild dysplasia (CIN-I or L-SIL), maturation occurs in the upper two thirds of the epithelium and exfoliated dyskaryotic cells are of the superficial type. These cells show cytoplasmic vacuolation (koilocytosis) and nuclear enlargement (**Web Image 11.4**).
- ◆ With increasing dysplasia (CIN-II and CIN-III, or H-SIL), the proliferating primitive cells reach closer to the epithelial surface, less cytoplasmic maturation/differentiation occurs, and dyskaryotic intermediate and parabasal cells are observed in smears (**Web Image 11.5**).
- ◆ Progression to CIS (CIN-III or H-SIL) manifests as subtle alterations in cell arrangement and morphology (with predominantly basal and parabasal cells in smears).

◆ Onset of invasive carcinoma is heralded by the appearance of macronucleoli, cytoplasmic orangeophilia and presence of tumour diathesis (dirty, necrotic background) (**Web Image 11.6**).

2. GLANDULAR CELL ABNORMALITIES. The Bethesda system categorises glandular abnormalities as under:

◆ *Atypical glandular cells of undetermined significance (AGUS)* which represent nuclear atypia of endocervical and endometrial cells exceeding reparative changes.

◆ *Endocervical and endometrial adenocarcinoma*, both of which can be detected from Pap smears; cytomorphological features allowing distinction between these two types of malignancies are summed up in **Web Table 11.7**.

◆ Cells from *extrauterine cancers* may also be present in Pap smears, majority originating from the ovaries.

□ II. RESPIRATORY TRACT (p. 272)

1. SPUTUM EXAMINATION. Sputum is produced by a spontaneous deep cough bringing up material from small airways and alveoli.

2. BRONCHIAL ASPIRATION (WASHINGS) AND BRONCHIAL BRUSHING. Cellular material obtained by aspiration brushing or bronchial washing, or by bronchio-alveolar lavage (BAL) during bronchoscopy allows localisation of lesions to specific areas of the respiratory tract.

□ III. GASTROINTESTINAL TRACT (p. 273)

Lesions in the oral cavity may be sampled by scraping the surface with wooden and metal tongue-depressors. For the oesophagus and stomach, samples are obtained under direct vision by brushing or lavage through fiberoptic endoscopes.

□ IV. URINARY TRACT (p. 273)

1. URINARY SEDIMENT CYTOLOGY. Cytological evaluation of the urinary tract is most often carried out by examining the sediment of voided or catheterised specimens of urine.

2. BLADDER IRRIGATION (WASHINGS). Washings of the urinary bladder obtained at cystoscopy are preferred in symptomatic patients when bladder tumours are suspected.

3. RETROGRADE CATHETERISATION. For suspected lesions of the upper urinary tract, voided urine is usually satisfactory.

4. PROSTATIC MASSAGE. Prostatic secretions are obtained by prostatic massage and the sample is collected directly onto a glass slide and smeared.

Diagnostic Utility of Urinary Cytology (p. 273)

1. *Papillary tumours of low-grade* are lined by urothelium showing no morphological abnormalities or only slight cellular and nuclear abnormalities.

2. *High-grade papillary tumours*, sessile tumours and carcinoma *in situ* where urothelial cells exhibit cytomorphological abnormalities, are readily diagnosed by urinary cytology.

3. Urothelial tumours are often synchronous or metachronous and may involve *different regions of the urinary tract*.

□ V. BODY FLUIDS (p. 273)

A. EFFUSIONS (P. 273)

Effusion refers to the accumulation of fluid in any of the three body cavities (pleural, pericardial and peritoneal). An effusion in the peritoneal cavity is

also known as ascites. Effusions have traditionally been classed as transudates or exudates.

Cellular Components in Effusions (p. 273)

Two main primary component cells of effusions are mesothelial cells and macrophages or histiocytes.

In addition, the effusion may have the following cellular components:

CELLS IN BENIGN EFFUSIONS. These include reactive proliferations of mesothelial cells in inflammation, polymorphonuclear neutrophils in acute suppurative inflammation, and lymphocytes in chronic fluid collections.

CELLS IN MALIGNANT EFFUSIONS. Malignant cells in effusion may of origin from primary tumour (e.g. mesothelioma) or from secondary/metastatic tumour; the latter being more common the case (**Web Image 11.7**).

B. FLUIDS OF SMALL VOLUME (p. 274)

Cerebrospinal Fluid (CSF) (p. 274)

- i) Speed of delivery to the laboratory and immediate processing, as diagnostic material may disintegrate within an hour resulting in false-negative diagnosis.
- ii) Correct cytological processing and technique, since the cell yield of CSF is generally low and faulty technique may result in loss of cellular material or poor morphology.

Normal CSF. CSF is an ultrafiltrate of plasma with a total volume of about 150 ml (in the adult). Cell content is low (0-4/ μ l) comprising mainly lymphocytes or monocytes.

CSF in non-neoplastic diseases. Changes in CSF in various non-neoplastic diseases are discussed in Chapter 30 (see Web Table 30.1).

CSF in neoplastic disease. Neoplasms that are in direct contact with the CSF are most likely to shed cells which are recoverable for scrutiny. Metastatic cancers (leukaemia, lymphoma and adenocarcinoma), medulloblastomas, and ependymomas shed the greatest amount of material.

Seminal Fluid (Semen) (p. 274)

Examination of seminal fluid (semen analysis) is one of the tests for investigating infertile couples, and is also used to check the adequacy of vasectomy. Samples are obtained by masturbation or coitus interruptus after observing at least 4 days of sexual abstinence and assessed on the following lines:

1. **Volume.** Normal volume is between 2.5 and 5 ml.
2. **Viscosity and pH.** When ejaculated, semen is fairly viscid but liquefies in about 10 to 30 minutes. It is usually alkaline (pH about 8).
3. **Motility.** Normally, within 2 hours of ejaculation, at least 60% of the spermatozoa are vigorously motile; in 6 to 8 hours 25 to 40% are still motile.
4. **Count.** Counting is done in a Neubauer chamber after suitable dilution. Normally, 60 million or more spermatozoa are present per ml. Currently, automated counters for semen are also available.
5. **Morphology.** Stained smears are used to assess morphology. Normally, not more than 20% of spermatozoa are morphologically abnormal (e.g. double-head, pointed-head, or swollen).
6. **Fructose.** Seminal fructose estimation (normal levels 150-600 mg/dl) complements cytological analysis. Low levels of seminal fructose indicate obstruction at the level of ejaculatory ducts.

Sex-specific chromatin bodies are observed in interphase nuclei and comprise the Barr body (X chromatin) and the fluorescent or F body (Y chromatin). The number of Barr bodies observed in interphase nuclei is one less than the number of X chromosome ($n-1$), whereas the number of F bodies observed is equal to the number of Y chromosomes present (n). In effect, the Barr body is specific for females and the F body for males.

1. DEMONSTRATION OF BARR BODY (X CHROMATIN). In buccal smears, the Barr body appears as a plano-convex mass about $1\ \mu\text{m}$ in diameter applied to the inner surface of the nuclear membrane. The interphase nuclei of one hundred intermediate squamous epithelial cells are scrutinised. In normal females, Barr bodies are present in at least 20% of nuclei (**Web Image 11.8, A**). Males have a Barr body count of less than 2%. Vaginal smears may also be used for Barr body counts.

2. DEMONSTRATION OF THE F BODY (Y CHROMATIN). Demonstration of the F body requires fluorescent staining in contrast to the Barr body which may be observed on routine Papanicolaou-stained smears. On staining buccal smears with quinacrine mustard, the intensely fluorescent F body is observed in about 60% of interphase nuclei in males and in less than 8% of nuclei in females.

3. COUNTING OF DRUMSTICK APPENDAGE. The presence and frequency of drumstick appendages attached to nuclei of polymorphonuclear leucocytes on a peripheral blood film may also be used for determining sex. At least 500 neutrophilic leucocytes are scrutinised in a Romanowsky-stained blood film. Genetic females show drumsticks in 3-6% of neutrophils (**Web Image 11.8, B**). In males, the frequency of drumsticks is less than 0.3%.

□ TECHNIQUES IN EXFOLIATIVE CYTOLOGY (p. 275)

A. Collection of Samples (p. 275)

1. PREPARATION OF COMBINED (FAST) SMEARS. Smears should not be taken during menstrual bleeding. The patient should not douche for at least 24 hours before the smear is obtained.

- i) Smears are obtained under *direct vision*
- ii) Ideally, *lubricants* and medical jellies should not be used for introducing the speculum.
- iii) The posterior fornix of the vagina is aspirated with a *blunt-ended glass pipette* fitted with a rubber bulb.
- iv) The ectocervix is sampled with the *Ayre's spatula* (**Web Image 11.9**).
- v) Thin uniform smears should be prepared and the slide immediately *immersed in fixative* to avoid artefacts in cells caused by drying.
- vi) Smears should be *transported* to the laboratory in the fixative in a Coplin's jar.

2. LIQUID-BASED CYTOLOGY PREPARATIONS (THIN PREPS). This is a special technique for preparation of gynaecologic and non-gynaecologic samples which provides uniform monolayered dispersion of cells on smears, without overlapping or clump formation.

3. PREPARATION OF LATERAL VAGINAL SMEARS (LVS). The LVS is obtained by scraping the lateral walls of the upper third of the vagina (at the level of the cervical external os) with the flat surface of a wooden tongue depressor and smearing the material directly onto labelled slides.

4. COLLECTION OF SPUTUM. Fresh, unfixed, early morning specimens resulting from overnight accumulation of secretions are best for diagnostic

purposes. A minimum of at least three specimens collected on three successive days should be examined.

5. BRONCHIAL MATERIALS. All aspirated bronchial secretions, lavage, washings and brushings must be despatched to the laboratory without delay. If immediate despatch is not possible, the sample should be collected in fixative (50% ethanol in volumes equal to that of the sample).

6. BUCCAL SMEARS. The mouth is rinsed with water or normal saline and the buccal mucosa scraped vigorously with a wooden or metal tongue depressor.

7. G.I. CYTOLOGY. In a case of suspected malignancy or specific infections of GI tract, or for screening for Barrett's oesophagus, cytologic examination is indicated. The cytology specimen is collected during fibreoptic endoscopy of the part being visualised.

8. URINE. Fresh catheterised specimens are preferred in female patients while voided urine is satisfactory in males.

9. EFFUSIONS. Pericardial, pleural and peritoneal fluids are obtained by paracentesis.

10. CEREBROSPINAL FLUID (CSF). CSF samples should be despatched without delay to the laboratory for immediate processing as the cells contained are extremely fragile. A gap of even 1 hour between removal and processing may result in loss of diagnostic cellular material.

11. SEMEN. Samples of seminal fluid obtained by masturbation are best collected at the laboratory. Samples obtained by coitus interruptus are collected in clean, dry test tubes (or vials) and transported to the laboratory within 30 minutes. The patient is instructed to note the time of ejaculation.

B. Fixation and Fixatives (p. 276)

All material for cytological examination must be properly fixed to ensure preservation of cytomorphological details. Methods of fixation vary depending upon the type of staining employed:

- ◆ Material for exfoliative cytodiagnosis is usually *wet-fixed* i.e. smears are immersed in fixative without allowing them to dry. These smears are then stained with Papanicolaou (Pap) or haematoxylin and eosin (H & E) stains.

- ◆ Sometimes, exfoliative cytology smears are *air-dried* for use with the Romanowsky stains as are used in haematologic studies. In Romanowsky staining, fixation is effected during the staining procedure.

1. SPECIAL PURPOSE FIXATIVES. Buffered neutral formalin, Bouin's fluid and picric acid are used for specific purposes when required. Formalin vapour fixation is also employed for some staining procedures.

2. PRESERVATION OF FLUID SAMPLES. Samples of fluids are best submitted to the laboratory in a fresh state for immediate processing. Where a delay is anticipated in despatch to the laboratory or in processing, the sample is collected in a suitable preservative for 'refixation' so that cellular morphology is preserved.

The best *preservative for general use* is 50% ethanol in volumes equal to that of the fluid sample. Ninety-five per cent ethanol precipitates proteins and hardens the sediment making smear preparation difficult; it is used only for gastric aspirates. Pericardial, pleural and peritoneal fluids may be pre-fixed with an equal volume of 10% formalin if ethanol is not available.

C. Processing of Samples in the Laboratory (p. 277)

1. PREPARED SMEARS. Smears prepared at the bedside and wet-fixed in ethanol need no further processing in the laboratory prior to staining.

2. SPUTUM. The sample is prepared as under:

- i) The sample is placed in a petridish and inspected against a dark background.
- ii) Bloody, discoloured or solid particles are removed with wooden applicator sticks and placed on glass slides. Strands of ropy mucus are also selected (exfoliated cells adhere to mucus strands).
- iii) Clean glass slides are used to crush the particles/mucus and spread the material evenly.
- iv) Four such smears are prepared and immediately placed in 95% ethanol for fixation.

3. FLUID SPECIMENS. Large volumes of fluid received are allowed to stand in the refrigerator for half to one hour.

Sediment smears. The sample is poured into 50 ml centrifuge tubes and centrifuged at 600 g for 10 minutes.

Following centrifugation, the supernatant is decanted and smears prepared from the sediment or cell button by recovering the material with a glass pipette or a platinum wire loop.

Cytocentrifuge and membrane filter preparations. These methods are most useful for small volume fluids of low cell content. The interested reader is referred to specialised texts for descriptions of these methods.

D. Staining of Smears (p. 277)

Three staining procedures are commonly employed: Papanicolaou and H&E stains are used for *wet-fixed smears* while Romanowsky stains are used for *air-dried smears*.

1. PAPANICOLAOU STAIN. Papanicolaou staining is the best method for routine cytodiagnostic studies. Three solutions are used comprising a nuclear stain and two cytoplasmic counter-stains. Harris' haematoxylin is the nuclear stain. Orange G (OG-6) and eosin-alcohol (EA-65 or EA-50) are the two cytoplasmic counterstains which impart the orange and cyanophilic tints to cytoplasm respectively.

2. H & E STAIN. The stain is essentially the same as that used for histological sections. Harris' haematoxylin is the nuclear stain, and eosin is the cytoplasmic counterstain.

3. ROMANOWSKY STAINS. Romanowsky stains used in haematological preparations may also be used for cytological smear preparations. Leishman's, May-Grünwald-Giemsa (MGG) and Wright's stains are most commonly used.

INTERVENTIONAL CYTOLOGY (p. 277)

□ I. FINE NEEDLE ASPIRATION CYTOLOGY (p. 277)

Interventional cytology is virtually synonymous with Fine Needle Aspiration Cytology (FNAC). The technique has gained wide acceptance in the last four decades and is increasingly being used to sample a wide variety of body tissues. Almost all organ systems are accessible to the fine needle and versatility of the technique has enormously increased the scope of diagnostic cytology.

A. APPLICATIONS OF FNAC (p. 278)

In routine practice, FNAC is most often used for diagnosis of palpable mass lesions. Palpable lesions commonly sampled are: breast masses, enlarged lymph nodes, enlarged thyroid and superficial soft tissue masses. The salivary glands, palpable abdominal lesions and the testicles are also frequently sampled for FNAC.

B. ADVANTAGES OF FNAC (p. 278)

- i) *No hospitalisation*
- ii) *No anaesthesia*
- iii) *Quick, safe and painless.*
- iv) *Multiple attempts*
- v) *Results are obtained rapidly*
- vi) *It is a low-cost procedure which is cost-effective.*
- vii) *First-hand knowledge* of the clinical findings.

C. GENERAL PROCEDURE FOR FNAC (p. 278)**Materials (p. 278)**

For performing FNAC, a syringe with a well-fitting needle, syringe holder, some microscopic glass slides and a suitable fixative are the only material required in most instances (**Web Image 11.10**).

Method of Aspiration (p. 278)

Transcutaneous FNAC of palpable masses is routinely performed without anaesthesia as per the following procedure; aspiration of sites/lesions requiring anaesthesia or special technique are discussed separately (**Web Image 11.11**).

- i) The patient is asked to *lie down* in a position that best exposes the target area.
- ii) The target area is thoroughly *palpated* and the firmest portion of the lesion or mass delineated.
- iii) The skin is *cleaned* with an alcohol pad.
- iv) The mass is *fixed* by the palpating hand of the operator or by an assistant; gloves may be used for protection of the operator and the assistant.
- v) The needle is *inserted* into the target area. On reaching the lesion, the plunger of the syringe is retracted and at least 10 ml of suction applied while moving the needle back and forth within the lesion; the direction or angle of the needle may be changed to access different areas of the lesion.
- vi) Aspiration is *terminated* when aspirated material or blood becomes visible at the base or hub of the needle.
- vii) On completion of aspiration, suction is *released* and pressure within the syringe allowed to equalise before withdrawing the needle.
- viii) Following withdrawal of the needle from the lesion, *pressure* is applied to the site of puncture by the assistant or patient himself for 2 to 3 minutes in order to arrest bleeding and prevent haematoma formation.
- ix) Aspirated material is *recovered* by detaching the needle from the syringe and filling the syringe with air; the syringe and needle are then reconnected and the aspirate expressed onto one end of a glass slide.

Preparation of Smears (p. 279)

Preparation of smears is crucial to the success of FNAC. Poorly-prepared smears with distorted cellular morphology will frustrate the best efforts of the most competent cytopathologist, and often result in errors of interpretation or in failure to arrive at any specific diagnosis. The procedure consists of the following steps (**Web Image 11.12**):

- i) Aspirates deposited on the slide are *inspected* with the naked eye.
- ii) Semisolid particulate aspirates are *crush-smear*ed by flat pressure with a glass slide or a thick coverslip.
- iii) Prepared smears are either *wet-fixed* or *air-dried*. Half the number of smears are immediately immersed in 95% ethanol, transported to the laboratory in the fixative, and used for Papanicolaou or H&E staining. The remaining smears are air-dried, wrapped in tissue paper for transport to the laboratory, and stained by Romanowsky stains (e.g. Leishman's, May-

222 Grünwald-Giemsa). The general properties of wet-fixed and air-dried smears outlined in **Web Table 11.8**.

Special and Ancillary Studies (p. 279)

i) **SPECIAL STAINS.** Wet-fixed smears are used for a variety of special stains such as Alcian blue, mucicarmine and PAS (for mucin and carbohydrates); methyl violet or congo red (for amyloid); and bacterial and fungal stains (for microbial agents).

ii) **MICROBIOLOGICAL STUDIES.** Aspirates may also be submitted for viral, fungal, mycobacterial and bacterial culture. When infection is suspected, an additional aspirate is obtained and expressed into a sterile culture tube.

iii) **CELL BLOCK.** Aspirated material may be processed as surgical pathology material by preparing paraffin blocks from cell button of the centrifuged deposit.

iv) **IMMUNOCYTOCHEMICAL STUDIES.** The smears or cell block sections can be further evaluated by immunocytochemical stains by employing panel of antibodies selected on the basis of differential diagnosis made after routine morphologic examination of smears.

v) **IMAGE ANALYSIS AND MORPHOMETRY.** These techniques when applied to cytological smears bring quantitation and objectivity to cytodiagnosis. They determine the cellular parameters like N/C ratio, nuclear area, shape and size of nuclei and nucleoli etc.

vi) **FLOW CYTOMETRY.** Determination of ploidy status and S phase fraction of tumour cells using flow cytometry enhances the diagnostic and prognostic information available on routine cytology.

vii) **ULTRASTRUCTURAL STUDIES.** Aspirates obtained by FNAC are also suitable for electron microscopy (both TEM and SEM).

viii) **MOLECULAR BIOLOGIC TECHNIQUES.** These techniques are now being widely applied to cytopathology also. Detection of oncogenes like *ERBB-2* in breast cancer, *BCL-2* in lymphomas, DNA sequence analysis, gene expression profiling and fluorescence *in situ* hybridisation (FISH) can all be used for aspiration samples.

Radiological Imaging Aids for FNAC (p. 281)

Non-palpable lesions require some form of localisation by radiological aids for FNAC to be carried out. *Plain X-ray films* are usually adequate for lesions within bones and for some lesions within the chest. FNAC of the chest may also be attempted under *image amplified fluoroscopy* which allows visualisation of needle placement on the television monitor. *Computerised tomographic-(CT) guidance* is also used for lesions within the chest and abdomen. The most versatile radiological aid is *ultrasonographic (US)-guidance* which allows direct visualisation of needle placement in real time and is free from radiation hazards.

D. COMPLICATIONS AND HAZARDS OF FNAC (p. 281)

FNAC is associated with relatively few complications.

1. Haematomas.
2. Infection.
3. Pneumothorax.
4. Dissemination of tumour.

E. PRECAUTIONS AND CONTRAINDICATIONS OF FNAC (p. 281)

While FNAC is generally a safe procedure, precautions have to be taken when aspiration is contemplated of some sites under certain circumstances:

1. **Bleeding disorders.** Thrombocytopenia *per se* is not a contraindication to FNAC.
2. **Liver.** Estimation of prothrombin time is an essential pre-requisite for aspiration of the liver.
FNAC is not advisable if prothrombin index (PTI) is less than 80%.
3. **Lung.** FNAC of the lung should not be undertaken in elderly patients with emphysema or pulmonary hypertension because of the enhanced risk of pneumothorax and haemoptysis respectively.
4. **Pancreas.** FNAC is contraindicated in acute pancreatitis as it aggravates the inflammatory process.
5. **Prostate.** Transrectal aspiration in acute prostatitis may cause bacteraemia/septicaemia and is contraindicated.
6. **Testis.** Aspiration is extremely painful in acute epididymo-orchitis and should be deferred till such time the acute inflammatory process subsides.
7. **Adrenal.** FNAC of a suspected pheochromocytoma is inadvisable as it may sometimes provoke extreme fluctuations in blood pressure.

F. CYTOLOGIC DIAGNOSIS (p. 281)

The cytopathologist can render a preliminary diagnosis within one hour after the FNAC procedure when urgently required. Emphasis in FNA cytology is on pattern recognition or arrangement of cells, nuclear and cytoplasmic features of individual cells or groups of cells, and comment on the background morphology.

A few common and classical examples of FNAC applications in lymph node (tuberculous lymphadenitis, **Web Image 11.13**), thyroid (follicular neoplasm, **Web Image 11.14**), breast (fibroadenoma and infiltrating carcinoma, **Web Images 11.15 and 11.16**), abdominal fat (for amyloid, **Web Image 11.17**) and cell-block preparation along with immunocytochemistry (**Web Image 11.18**) are illustrated.

G. LIMITATIONS OF FNAC (p. 283)

The main limitation of FNAC lies in the fact that only a small population of cells is sampled by the procedure. The reliability of the test, thus, depends upon the adequacy of the sample and its representative character.

II. IMPRINT CYTOLOGY (p. 283)

In imprint cytology, touch preparations from cut surfaces of fresh unfixed surgically excised mass lesions are examined. Imprints may also be obtained from draining sinuses or ulcerated areas.

For surgically resected specimens (e.g. lymph nodes) smears are prepared by bisecting or slicing the specimen and lightly touching or pressing a glass slide onto the freshly exposed surface without smearing it.

III. CRUSH SMEAR CYTOLOGY (p. 283)

Crush smear preparations of tissue particles obtained by craniotomy have been used in the diagnosis of brain tumours. These smears are preferred by many workers as they allow recognition of tissue architecture to some degree, in addition to better cytological details.

IV. BIOPSY SEDIMENT CYTOLOGY (p. 283)

Biopsy sediment cytology entails the examination of sediment obtained by centrifugation of fixatives/fluids in which surgical biopsy specimens are despatched to the laboratory. The method may be useful in the rapid diagnosis of bone tumours as histological sections are usually obtained after many days on account of the delay necessitated by decalcification. For soft tissue specimens, the technique offers no particular advantage.

- For cytomorphological recognition of cancer, the following characteristics are used to determine the presence or absence of cancer **except**:
 - Cytoplasmic content
 - Nuclear size
 - N:C ratio
 - Mitoses
- The following statements are true for Bethesda system **except**:
 - It is employed for cytologic reporting of Pap smears
 - It divides dysplasias into three grades: mild, moderate and severe
 - All forms of dysplasias are graded into two grades—L-SIL and H-SIL
 - Bethesda system is current modification of reporting over conventional system
- The number of Barr bodies observed in interphase nuclei are:
 - Equal to the number of X chromosomes
 - One less than the number of X chromosomes
 - Equal to the number of Y chromosomes
 - One less than the number of Y chromosomes
- Drum-stick appendages seen in neutrophils in stained blood film in females are:
 - > 20%
 - 10-20 %
 - 3-6%
 - < 0.3%
- CSF cytology is not useful for the diagnosis of:
 - Leukemia
 - Medulloblastoma
 - Ependymoma
 - Meningioma
- For pleural effusion, if a delay of more than 12 hours is anticipated for processing, it should be fixed in:
 - 95% ethanol
 - Equal volume of 10% formalin
 - Bouin's fluid
 - Picric acid
- Haematoxylin and eosin staining is employed as cytologic stain for:
 - Wet-fixed smears
 - Air-dried smears
 - All FNAC smears only
 - All cases of crush smear only
- The following features characterise wet-fixed smears over air-dried smears **except**:
 - Pap and H & E stain are applied for the former
 - The nuclear details are better seen
 - Cytoplasmic details are better seen
 - Cell size is comparable to tissue section
- Liquid based cytology:
 - provides uniform monolayered cell dispersion
 - is useful only for gynaecological samples
 - is useful only for non-gynaecological samples
 - causes cellular clumping
- Imprint cytology is most useful in the lesions of following organ:
 - Bones
 - Breast
 - Lymph nodes
 - Brain tumours
- Navicular cells are:
 - Superficial squamous cells
 - Intermediate squamous cells
 - Parabasal cells
 - Basal cells

12. **Maturation index denotes:**
- A. Relative proportion of cells containing acidophilic cytoplasm
 - B. Relative proportion of cells containing basophilic cytoplasm
 - C. Percentage of cells having small shrunken nuclei
 - D. Relative proportion of various cell types in a smear
13. **Which of the following is automated cytological technique?**
- A. Membrane filtration
 - B. PapNet
 - C. Cell block technique
 - D. Cytospin
14. **F body is:**
- A. X chromatin
 - B. Y chromatin
 - C. Chromosome 1
 - D. Chromosome 21
15. **Abdominal fat aspiration is done for the diagnosis of:**
- A. Obesity
 - B. Amyloidosis
 - C. Metastatic cancer
 - D. Multiple myeloma

KEY

1 = A	2 = B	3 = B	4 = C
5 = D	6 = B	7 = A	8 = C
9 = A	10 = C	11 = B	12 = D
13 = B	14 = B	15 = B	



Introduction to Haematopoietic System and Disorders of Erythroid Series

In this edition, the present chapter encompasses basic introduction to the haematopoietic system and the bone marrow, followed by discussion on erythroid series of disorders. The disorders of leucocytes (myeloid and lymphoid series) and diseases of lymphoreticular tissues have been put together in Chapter 14. A separate chapter on disorders of platelets and bleeding along with transfusion medicine (Chapter 13) has been placed interposed between these two chapters.

Section II

Haematology and Lymphoreticular Tissues

The pluripotent stem cells in the bone marrow give rise to two types of multipotent stem cells: *non-lymphoid stem cells* which differentiate in the bone marrow, and *lymphoid stem cells* which differentiate in the bone marrow and then migrate to the lymphoid tissues. The non-lymphoid stem cells form the circulating erythrocytes, granulocytes, monocytes and platelets. Monocytes on entering the tissues form a variety of phagocytic macrophages, both of which together constitute mononuclear-phagocyte system. Lymphopoietic cells in the marrow undergo differentiation to form B, T and natural killer (NK) cells of the immune system.

Circulating blood normally contains 3 main types of mature cells—the red cells (erythrocytes), the white cells (leucocytes) and the platelets (thrombocytes). These blood cells perform their respective physiologic functions: *erythrocytes* are largely concerned with oxygen transport, *leucocytes* play various roles in body defense against infection and tissue injury, while *thrombocytes* are primarily involved in maintaining integrity of blood vessels and in preventing blood loss. The lifespan of these cells in circulating blood is variable—neutrophils have a lifespan of 6-8 hours, followed by platelets with a lifespan of 10 days, while the RBCs have the longest lifespan of 90-120 days.

□ HAEMATOPOIESIS (p. 284)

In the human embryo, the *yolk sac* is the main site of haematopoiesis in the first few weeks of gestation. By about 3rd month, however, the *liver and spleen* are the main sites of blood cell formation and continue to do so until about 2 weeks after birth. Haematopoiesis commences in the *bone marrow* by 4th and 5th month and becomes fully active by 7th and 8th month so that at birth practically all the bones contain active marrow. During normal childhood and adult life, therefore, the marrow is the only source of new blood cells. However, during childhood, there is progressive fatty replacement throughout the long bones so that by adult life the haematopoietic marrow is confined to the central skeleton (vertebrae, sternum, ribs, skull, sacrum and pelvis) and proximal ends of femur, tibia and humerus (**Web Image 12.1**). Even in these haematopoietic areas, about 50% of the marrow consists of fat (**Web Image 12.2**). Non-haematopoietic marrow in the adult is, however, capable of reverting to active haematopoiesis in certain pathologic conditions. The spleen and liver can also resume their foetal haematopoietic role in certain pathologic conditions and is called *extramedullary haematopoiesis*.

□ HAEMATOPOIETIC STEM CELLS (p. 285)

The stem cells express a variety of cell surface proteins such as CD34 and adhesion proteins which help the stem cells to “home” to the bone marrow when infused. The stem cells have the appearance of small or intermediate-sized lymphocytes and their presence in the marrow can be demonstrated by cell culture techniques by the growth of colony-forming units (CFU) pertaining to different cell lines. The stem cells have the capability of maintaining their progeny by self-replication. The bone marrow provides a suitable environment for growth and development of stem cells. For instance, if haematopoietic stem cells are infused intravenously into a suitably-prepared recipient, they seed the marrow successfully but do not thrive at other sites. This principle forms the basis of bone marrow (or stem cell) transplantation performed for various haematologic diseases.

The stem cells, after a series of divisions, differentiate into two types of progenitors—*lymphoid* (immune system) stem cells, and *non-lymphoid* or *myeloid* (trilineage) stem cells.

Myeloid haematopoiesis or myelopoiesis includes differentiation and maturation of granulocytes, monocytes, erythroid cells and megakaryocytes (**Web Image 12.3**). The differentiation and maturation of each series of these cells from stem cells are regulated by endogenous glycoproteins called as *growth factors, cytokines and hormones*. These are as under:

- ◆ Erythropoietin
- ◆ Granulocyte colony-stimulating factor (G-CSF)
- ◆ Granulocyte-macrophage colony-stimulating factor (GM-CSF)
- ◆ Thrombopoietin

□ BONE MARROW EXAMINATION (p. 285)

Examination of the bone marrow provides an invaluable diagnostic help in some cases, while in others it is of value in confirming a diagnosis suspected on clinical examination or on the blood film. A peripheral blood smear examination, however, must always precede bone marrow examination.

Bone marrow examination may be performed by two methods—*aspiration* and *trepphine biopsy*. A comparison of the two methods is summarised in **Web Table 12.1**.

BONE MARROW ASPIRATION. The method involves suction of marrow via a strong, wide bore, short-bevelled needle fitted with a stylet and an adjustable guard in order to prevent excessive penetration; for instance Salah bone marrow aspiration needle (**Web Image 12.4,A**). Smears are prepared immediately from the bone marrow aspirate and are fixed in 95% methanol after air-drying. The usual Romanowsky technique is employed for staining and a stain for iron is performed routinely so as to assess the reticuloendothelial stores of iron.

The marrow film provides assessment of cellularity, details of developing blood cells (i.e. normoblastic or megaloblastic, myeloid, lymphoid, macrophages and megakaryocytic), ratio between erythroid and myeloid cells, storage diseases, and for the presence of cells foreign to the marrow such as secondary carcinoma, granulomatous conditions, fungi (e.g. histoplasmosis) and parasites (e.g. malaria, leishmaniasis, trypanosomiasis). Estimation of the proportion of cellular components in the marrow, however, can be provided by doing a differential count of at least 500 cells (myelogram, **Web Table 12.2**).

TREPAPHINE BIOPSY. Trepphine biopsy is performed by a simple *Jamshidi trephine needle* by which a core of tissue from periosteum to bone marrow cavity is obtained (**Web Image 12.4,B**). The tissue is then fixed, soft decalcified and processed for histological sections and stained with haematoxylin and eosin and for reticulin. Trepphine biopsy is useful over aspiration since it provides an excellent view of the overall marrow

228 architecture, cellularity, and presence or absence of infiltrates, but is less valuable than aspiration as far as individual cell morphology is concerned.

□ ERYTHROPOIESIS (p. 287)

Although the stem cells which eventually form the mature erythrocytes of the peripheral blood cannot be recognised morphologically, there is a well-defined and readily recognisable lineage of nucleated red cells (i.e. the erythroid series) in the marrow (**Web Image 12.5**):

1. PROERYTHROBLAST. The earliest recognisable cell in the marrow is a proerythroblast or pronormoblast. It is a large cell, 15-20 μm in diameter having deeply basophilic cytoplasm and a large central nucleus containing nucleoli. The deep blue colour of the cytoplasm is due to high content of RNA which is associated with active protein synthesis. As the cells mature, the nuclei lose their nucleoli and become smaller and denser, while the cytoplasm on maturation leads to replacement of dense blue colour progressively by pink-staining haemoglobin. Each proerythroblast undergoes 4-5 replications and forms 16-32 mature RBCs.

2. BASOPHILIC (EARLY) ERYTHROBLAST. It is a round cell having a diameter of 12-16 μm with a large nucleus which is slightly more condensed than the proerythroblast and contains basophilic cytoplasm. Basophilic erythroblast undergoes rapid proliferation.

3. POLYCHROMATIC (INTERMEDIATE) ERYTHROBLAST. Next maturation stage has a diameter of 12-14 μm . The nucleus at this stage is coarse and deeply basophilic. The cytoplasm is characteristically polychromatic i.e. contains admixture of basophilic RNA and acidophilic haemoglobin. The cell at this stage ceases to undergo proliferative activity.

4. ORTHOCHROMATIC (LATE) ERYTHROBLAST. The final stage in the maturation of nucleated red cells is the orthochromatic or late erythroblast. The cell at this stage is smaller, 8-12 μm in diameter, containing a small and pyknotic nucleus with dark nuclear chromatin. The cytoplasm is characteristically acidophilic with diffuse basophilic hue due to the presence of large amounts of haemoglobin.

5. RETICULOCYTE. The nucleus is finally extruded from the late erythroblast within the marrow and a reticulocyte results. The reticulocytes are juvenile red cells devoid of nuclei but contain ribosomal RNA so that they are still able to synthesise haemoglobin. A reticulocyte spends 1-2 days in the marrow and circulates for 1-2 days in the peripheral blood before maturing in the spleen, to become a biconcave red cell. The reticulocytes in the peripheral blood are distinguished from mature red cells by slightly basophilic hue in the cytoplasm similar to that of an orthochromatic erythroblast. Reticulocytes can be counted in the laboratory by *vital staining* with dyes such as new methylene blue or brilliant cresyl blue. The reticulocytes by either of these staining methods contain deep blue reticulofilamentous material (**Web Image 12.6**). Normal range of reticulocyte count in health is 0.5-2.5% in adults and 2-6% in infants. Their proportion is increased in conditions of rapid red cell regeneration e.g. after haemorrhage, haemolysis and haematopoietic response of anaemia to treatment.

Erythropoietin (p. 288)

Erythropoietic activity in the body is regulated by the hormone, erythropoietin, which is produced in response to anoxia. The principal site of erythropoietin production is the kidney though there is evidence of its extra-renal production in certain unusual circumstances. Its levels are, therefore, lowered in chronic renal diseases, while a case of renal cell carcinoma may be associated with its increased production and erythrocytosis. Erythropoietin acts on the

marrow at the various stages of morphologically unidentifiable as well as identifiable erythroid precursors.

There is an increased production of erythropoietin in various types of anaemias but in anaemia of chronic diseases (e.g. in infections and neoplastic conditions) there is no such enhancement of erythropoietin. In polycythaemia rubra vera, there is erythrocytosis but depressed production of erythropoietin. This is because of an abnormality of the stem cell class which is not under erythropoietin control.

The Red Cell (p. 288)

The mature erythrocytes of the human peripheral blood are non-nucleated cells and lack the usual cell organelles. The normal human erythrocyte is a biconcave disc, 7.2 μm in diameter, and has a thickness of 2.4 μm at the periphery and 1 μm in the centre. The biconcave shape renders the red cells quite flexible so that they can pass through capillaries whose minimum diameter is 3.5 μm . More than 90% of the weight of erythrocyte consist of haemoglobin. The lifespan of red cells is 120 ± 30 days.

RED CELL MEMBRANE. The red cell membrane is a trilaminar structure having a bimolecular lipid layer interposed between two layers of proteins. The important *proteins* in red cell membrane are band 3 protein (named on the basis of the order in which it migrates during electrophoresis), glycoporphin and spectrin; important *lipids* are glycolipids, phospholipids and cholesterol; and *carbohydrates* form skeleton of erythrocytes having a lattice-like network which is attached to the internal surface of the membrane and is responsible for biconcave form of the erythrocytes.

NUTRITIONAL REQUIREMENTS FOR ERYTHROPOIESIS. New red cells are being produced each day for which the marrow requires certain essential substances. These substances are as under:

- 1. Metals.** Iron is essential for red cell production because it forms part of the haem molecule in haemoglobin. Its deficiency leads to iron deficiency anaemia. Cobalt and manganese are certain other metals required for red cell production.
- 2. Vitamins.** Vitamin B₁₂ and folate are essential for biosynthesis of nucleic acids. Deficiency of B₁₂ or folate causes megaloblastic anaemia. Vitamin C (ascorbic acid) plays an indirect role by facilitating the iron turnover in the body. Vitamin B₆ (pyridoxine), vitamin E (tocopherol) and riboflavin are the other essential vitamins required in the synthesis of red cells.
- 3. Amino acids.** Amino acids comprise the globin component of haemoglobin. Severe amino acid deficiency due to protein deprivation causes depressed red cell production.
- 4. Hormones.** As discussed above, erythropoietin plays a significant regulatory role in the erythropoietic activity. Besides erythropoietin, androgens and thyroxine also appear to be involved in the red cell production.

HAEMOGLOBIN. Haemoglobin consists of a basic protein, *globin*, and the iron-porphyrin complex, *haem*. The molecular weight of haemoglobin is 68,000. Normal adult haemoglobin (*HbA*) constitutes 96-98% of the total haemoglobin content and consists of four polypeptide chains, $\alpha_2\beta_2$. Small quantities of 2 other haemoglobins present in adults are: *HbF* containing $\alpha_2\gamma_2$ globin chains comprising 0.5-0.8% of total haemoglobin, and *HbA₂* having $\alpha_2\delta_2$ chains and constituting 1.5-3.2% of total haemoglobin. Most of the haemoglobin (65%) is synthesised by the nucleated red cell precursors in the marrow, while the remainder (35%) is synthesised at the reticulocyte stage.

Synthesis of haem occurs largely in the mitochondria by a series of biochemical reactions summarised in **Web Image 12.7**. Coenzyme, pyridoxal-6-phosphate, derived from pyridoxine (vitamin B₆) is essential for the

230 synthesis of amino levulinic acid (ALA) which is the first step in the biosynthesis of protoporphyrin. The reaction is stimulated by erythropoietin and inhibited by haem. Ultimately, protoporphyrin combines with iron supplied from circulating transferrin to form haem. Each molecule of haem combines with a globin chain synthesised by polyribosomes. A tetramer of 4 globin chains, each having its own haem group, constitutes the haemoglobin molecule (**Web Image 12.8, A**).

RED CELL FUNCTIONS. The essential function of the red cells is to carry oxygen from the lungs to the tissue and to transport carbon dioxide to the lungs. In order to perform these functions, the red cells have the ability to generate energy as ATP by anaerobic glycolytic pathway (Embden-Meyerhof pathway). This pathway also generates reducing power as NADH and NADPH by the hexose monophosphate (HMP) shunt.

1. Oxygen carrying. The normal adult haemoglobin, HbA, is an extremely efficient oxygen-carrier. The four units of tetramer of haemoglobin molecule take up oxygen in succession, which, in turn, results in stepwise rise in affinity of haemoglobin for oxygen. This is responsible for the *sigmoid shape* of the oxygen dissociation curve.

The extent to which oxygen is released from haemoglobin at pO_2 in tissue capillaries depends upon 3 factors—the nature of globin chains, the pH, and the concentration of 2,3-biphosphoglycerate (2,3-BPG) (**Web Image 12.8, B**).

2. CO₂ transport. Another important function of the red cells is the CO₂ transport. In the tissue capillaries, the pCO_2 is high so that CO₂ enters the erythrocytes where much of it is converted into bicarbonate ions which diffuse back into the plasma.

RED CELL DESTRUCTION. Red cells have a mean lifespan of 120 days, after which red cell metabolism gradually deteriorates as the enzymes are not replaced. The destroyed red cells are removed mainly by the macrophages of the reticuloendothelial (RE) system of the marrow, and to some extent by the macrophages in the liver and spleen (**Web Image 12.9**). The breakdown of red cells liberates iron for recirculation via plasma transferrin to marrow erythroblasts, and protoporphyrin which is broken down to bilirubin. Bilirubin circulates to the liver where it is conjugated to its diglucuronide which is excreted in the gut via bile and converted to stercobilinogen and stercobilin excreted in the faeces. Part of stercobilinogen and stercobilin is reabsorbed and excreted in the urine as urobilinogen and urobilin.

□ ANAEMIA—GENERAL CONSIDERATIONS (p. 291)

Anaemia is defined as a haemoglobin concentration in blood below the lower limit of the normal range for the age and sex of the individual. In adults, the lower extreme of the normal haemoglobin is taken as 13.0 g/dl for males and 11.5 g/dl for females. Newborn infants have higher haemoglobin level and, therefore, 15 g/dl is taken as the lower limit at birth, whereas at 3 months the normal lower level is 9.5 g/dl. Although haemoglobin value is employed as the major parameter for determining whether or not anaemia is present, the red cell counts, haematocrit (PCV) and absolute values (MCV, MCH and MCHC) provide alternate means of assessing anaemia.

Pathophysiology of Anaemia (p. 291)

Subnormal level of haemoglobin causes lowered oxygen-carrying capacity of the blood. This, in turn, initiates compensatory physiologic adaptations such as follows:

- ◆ increased release of oxygen from haemoglobin;
- ◆ increased blood flow to the tissues;
- ◆ maintenance of the blood volume; and
- ◆ redistribution of blood flow to maintain the cerebral blood supply.

Clinical Features of Anaemia (p. 291)

The haemoglobin level at which symptoms and signs of anaemia develop depends upon 4 main factors:

1. The speed of onset of anaemia
2. The severity of anaemia
3. The age of the patient
4. The haemoglobin dissociation curve.

SYMPTOMS. In symptomatic cases of anaemia, the presenting features are: tiredness, easy fatigability, generalised muscular weakness, lethargy and headache.

SIGNS. A few general signs common to all types of anaemias are:

1. **Pallor.** Pallor is the most common and characteristic sign which may be seen in the mucous membranes, conjunctivae and skin.
2. **Cardiovascular system.** A hyperdynamic circulation may be present with tachycardia, collapsing pulse, cardiomegaly, midsystolic flow murmur, dyspnoea on exertion, and in the case of elderly, congestive heart failure.
3. **Central nervous system.** The older patients may develop symptoms referable to the CNS such as attacks of faintness, giddiness, headache, tinnitus, drowsiness, numbness and tingling sensations of the hands and feet.
4. **Ocular manifestations.** Retinal haemorrhages may occur if there is associated vascular disease or bleeding diathesis.
5. **Reproductive system.** Menstrual disturbances such as amenorrhoea and menorrhagia and loss of libido are some of the manifestations involving the reproductive system in anaemic subjects.
6. **Renal system.** Mild proteinuria and impaired concentrating capacity of the kidney may occur in severe anaemia.
7. **Gastrointestinal system.** Anorexia, flatulence, nausea, constipation and weight loss may occur.

Investigations of the Anaemic Subject (p. 292)

In order to confirm or deny the presence of anaemia, its type and its cause, the following plan of investigations is generally followed, of which complete blood counts (CBC) with reticulocyte count is the basic test.

A. HAEMOGLOBIN ESTIMATION. The first and foremost investigation in any suspected case of anaemia is to carry out a haemoglobin estimation. Several methods are available but most reliable and accurate is the cyanmethaemoglobin (HiCN) method employing Drabkin's solution and a spectrophotometer. If the haemoglobin value is below the lower limit of the normal range for particular age and sex, the patient is said to be anaemic. In pregnancy, there is haemodilution and, therefore, the lower limit in normal pregnant women is less (10.5 g/dl) than in the non-pregnant state.

B. PERIPHERAL BLOOD FILM EXAMINATION. The haemoglobin estimation is invariably followed by examination of a peripheral blood film for morphologic features after staining it with the Romanowsky dyes (e.g. Leishman's stain, May-Grünwald-Giemsa's stain, Jenner-Giemsa's stain, Wright's stain etc). The blood smear is evaluated in an area where there is neither Rouleaux formation nor so thin as to cause red cell distortion. Such an area can usually be found at junction of the body with the tail of the film, but not actually at the tail. The following abnormalities in erythroid series of cells are particularly looked for in a blood smear:

1. **Variation in size (Anisocytosis).** Normally, there is slight variation in diameter of the red cells from 6.7-7.7 μm (mean value 7.2 μm). Increased variation in size of the red cell is termed anisocytosis. Anisocytosis may be

due to the presence of cells larger than normal (*macrocytosis*) or cells smaller than normal (*microcytosis*). Sometimes both microcytosis and macrocytosis are present (*dimorphic*).

2. Variation in shape (Poikilocytosis). Increased variation in shape of the red cells is termed poikilocytosis.

3. Inadequate haemoglobin formation (Hypochromasia). Normally, the intensity of pink staining of haemoglobin in a Romanowsky-stained blood smear gradually decreases from the periphery to the centre of the cell. Increased central pallor is referred to as *hypochromasia*. It may develop either from lowered haemoglobin content (e.g. in iron deficiency anaemia, chronic infections), or due to thinness of the red cells (e.g. in thalassaemia, sideroblastic anaemia).

4. Compensatory erythropoiesis. A number of changes are associated with compensatory increase in erythropoietic activity. These are as under:

- i) *Polychromasia* is defined as the red cells having more than one type of colour.
- ii) *Erythroblastaemia* is the presence of nucleated red cells in the peripheral blood film.
- iii) *Punctate basophilia* or *basophilic stippling* is diffuse and uniform basophilic granularity in the cell which does not stain positively with Perls' reaction (in contrast to Pappenheimer bodies which stain positively).
- iv) *Howell-Jolly bodies* are purple nuclear remnants, usually found singly, and are larger than basophilic stippling. They are present in megaloblastic anaemia and after splenectomy.

5. Miscellaneous changes. In addition to the morphologic changes of red cells described above, several other abnormal red cells may be found in different haematological disorders. Some of these are as follows (**Web Image 12.10**):

- i) *Spherocytosis*
- ii) *Schistocytosis*
- iii) *Irregularly contracted red cells*
- iv) *Leptocytosis*
- v) *Sickle cells or drepanocytes*
- vi) *Crenated red cells*
- vii) *Acanthocytosis*
- viii) *Burr cells*
- ix) *Stomatocytosis*
- x) *Ovalocytosis or elliptocytosis*.

C. RED CELL INDICES. An alternative method to diagnose and detect the severity of anaemia is by measuring the red cell indices:

- ◆ In iron deficiency and thalassaemia, MCV, MCH and MCHC are reduced.
- ◆ In anaemia due to acute blood loss and haemolytic anaemias, MCV, MCH and MCHC are all within normal limits.
- ◆ In megaloblastic anaemias, MCV is raised above the normal range.

D. LEUCOCYTE AND PLATELET COUNT. Measurement of leucocyte and platelet count helps to distinguish pure anaemia from pancytopenia in which red cells, granulocytes and platelets are all reduced. In anaemias due to haemolysis or haemorrhage, the neutrophil count and platelet counts are often elevated. In infections and leukaemias, the leucocyte counts are high and immature leucocytes appear in the blood.

E. RETICULOCYTE COUNT. Reticulocyte count (normal 0.5-2.5%) is done in each case of anaemia to assess the marrow erythropoietic activity. In acute haemorrhage and in haemolysis, the reticulocyte response is indicative of impaired marrow function.

F. ERYTHROCYTE SEDIMENTATION RATE. The ESR is a non-specific test used as a screening test for anaemia. It usually gives a clue to the

underlying organic disease but anaemia itself may also cause rise in the ESR.

G. BONE MARROW EXAMINATION. Bone marrow aspiration is done in cases where the cause for anaemia is not obvious. The procedures involved for marrow aspiration and trephine biopsy and their relative advantages and disadvantages have already been discussed.

Classification of Anaemias (p. 294)

Several types of classifications of anaemias have been proposed. Two of the widely accepted classifications are based on the pathophysiology and morphology (**Web Table 12.3**).

PATHOPHYSIOLOGIC CLASSIFICATION. Depending upon the pathophysiological mechanism, anaemias are classified into 3 groups:

I. Anaemia due to blood loss. This is further of 2 types:

- A. Acute post-haemorrhagic anaemia
- B. Anaemia of chronic blood loss

II. Anaemia due to impaired red cell formation. A disturbance due to impaired red cell production from various causes may produce anaemia. These are as under:

A. *Cytoplasmic maturation defects*

1. Deficient haem synthesis: iron deficiency anaemia
2. Deficient globin synthesis: thalassaemic syndromes

B. *Nuclear maturation defects*

Vitamin B₁₂ and/or folic acid deficiency: megaloblastic anaemia

C. *Haematopoietic stem cell proliferation and differentiation abnormality* e.g.

1. Aplastic anaemia
2. Pure red cell aplasia

D. *Bone marrow failure due to systemic diseases* (anaemia of chronic disorders) e.g.

1. Anaemia of inflammation/infections, disseminated malignancy
2. Anaemia in renal disease
3. Anaemia due to endocrine and nutritional deficiencies (hypometabolic states)
4. Anaemia in liver disease

E. *Bone marrow infiltration* e.g.

1. Leukaemias
2. Lymphomas
3. Myelosclerosis
4. Multiple myeloma

F. *Congenital anaemia* e.g.

1. Sideroblastic anaemia
2. Congenital dyserythropoietic anaemia.

III. Anaemia due to increased red cell destruction (haemolytic anaemias).

This is further divided into 2 groups:

- A. Intracorpuseular defect (hereditary and acquired).
- B. Extracorpuseular defect (acquired haemolytic anaemias).

MORPHOLOGIC CLASSIFICATION. Based on the red cell size, haemoglobin content and red cell indices, anaemias are classified into 3 types:

1. Microcytic, hypochromic: MCV, MCH, MCHC are all reduced e.g. in iron deficiency anaemia and in certain non-iron deficient anaemias (sideroblastic anaemia, thalassaemia, anaemia of chronic disorders).

2. Normocytic, normochromic: MCV, MCH, MCHC are all normal e.g. after acute blood loss, haemolytic anaemias, bone marrow failure, anaemia of chronic disorders.

234 **3. Macrocytic:** MCV is raised e.g. in megaloblastic anaemia due to deficiency of vitamin B₁₂ or folic acid.

ANAEMIA OF BLOOD LOSS (p. 294)

Depending upon the rate of blood loss due to haemorrhage, the effects of post-haemorrhagic anaemia appear.

ACUTE BLOOD LOSS. When the loss of blood occurs suddenly, the following events take place:

- i) Immediate threat to life due to hypovolaemia which may result in shock and death.
- ii) If the patient survives, shifting of interstitial fluid to intravascular compartment with consequent haemodilution with low haematocrit.
- iii) Hypoxia stimulates production of erythropoietin resulting in increased marrow erythropoiesis.

LABORATORY FINDINGS. These are as under:

- i) Normocytic and normochromic anaemia
- ii) Low haematocrit
- iii) Increased reticulocyte count in peripheral blood (10-15% after one week) reflecting accelerated marrow erythropoiesis.

CHRONIC BLOOD LOSS. When the loss of blood is slow and insidious, the effects of anaemia will become apparent only when the rate of loss is more than rate of production and the iron stores are depleted. This results in iron deficiency anaemia as seen in other clinical conditions discussed below.

HYPOCHROMIC ANAEMIA (p. 295)

Hypochromic anaemia due to iron deficiency is the commonest cause of anaemia the world over. It is estimated that about 20% of women in child-bearing age group are iron deficient, while the overall prevalence in adult males is about 2%. It is the most important, though not the sole, cause of microcytic hypochromic anaemia in which all the three red cell indices (MCV, MCH and MCHC) are reduced and occurs due to defective haemoglobin synthesis. Hypochromic anaemias, therefore, are classified into 2 groups:

- I. Hypochromic anaemia due to iron deficiency.
- II. Hypochromic anaemias other than iron deficiency.

The latter category includes 3 groups of disorders—sideroblastic anaemia, thalassaemia and anaemia of chronic disorders.

IRON DEFICIENCY ANAEMIA (p. 295)

The commonest nutritional deficiency disorder present throughout the world is iron deficiency but its prevalence is higher in the developing countries.

Iron Metabolism (p. 295)

The amount of iron obtained from the diet should replace the losses from the skin, bowel and genitourinary tract. These losses together are about 1 mg daily in an adult male or in a non-menstruating female, while in a menstruating woman there is an additional iron loss of 0.5-1 mg daily. The iron required for haemoglobin synthesis is derived from 2 primary sources—ingestion of foods containing iron (e.g. leafy vegetables, beans, meats, liver etc) and recycling of iron from senescent red cells (**Web Image 12.11**).

ABSORPTION. Iron is absorbed mainly in the duodenum and proximal jejunum. *Iron from diet containing haem is better absorbed than non-haem iron.* Absorption of non-haem iron is enhanced by factors such as ascorbic acid (vitamin C), citric acid, amino acids, sugars, gastric secretions and hydrochloric acid. Iron absorption is impaired by factors like medicinal

antacids, milk, pancreatic secretions, phytates, phosphates, ethylene diamine tetra-acetic acid (EDTA) and tannates contained in tea.

Non-haem iron is released as ferrous or ferric form but is absorbed almost exclusively as ferrous form; reduction of ferric to ferrous form when required takes place at the intestinal brush border by *ferric reductase*. Transport across the membrane is accomplished by divalent metal transporter 1 (DMT 1). Once inside the gut cells, ferric iron may be either stored as ferritin or further transported to transferrin by two vehicle proteins—*ferroportin* and *hephaestin*.

Major mechanism of maintaining iron balance in the body is by intestinal absorption of dietary iron. When the demand for iron is increased (e.g. during pregnancy, menstruation, periods of growth and various diseases), there is increased iron absorption, while excessive body stores of iron cause reduced intestinal iron absorption (**Web Image 12.12,A**).

TRANSPORT. Iron is transported in plasma bound to a β -globulin, *transferrin*, synthesised in the liver. Transferrin-bound iron is made available to the marrow where the developing erythroid cells having *transferring receptors* utilise iron for haemoglobin synthesis. It may be mentioned here that transferrin receptors are present on cells of many tissues of the body but their number is greatest in the developing erythroblasts. Transferrin is reutilised after iron is released from it. A small amount of transferrin iron is delivered to other sites such as parenchymal cells of the liver. Normally, transferrin is about one-third saturated. But in conditions where transferrin-iron saturation is increased, parenchymal iron uptake is increased.

EXCRETION. The body is unable to regulate its iron content by excretion alone. The amount of iron lost per day is 0.5-1 mg which is independent of iron intake. This loss is nearly twice more (i.e. 1-2 mg/day) in menstruating women. Iron is lost from the body in both sexes as a result of desquamation of epithelial cells from the gastrointestinal tract, from excretion in the urine and sweat, and loss via hair and nails.

DISTRIBUTION. In an adult, iron is distributed in the body as under:

1. **Haemoglobin**—present in the red cells, contains most of the body iron (65%).
2. **Myoglobin**—comprises a small amount of iron in the muscles (3.5%).
3. **Haem and non-haem enzymes**—e.g. cytochrome, catalase, peroxidases, succinic dehydrogenase and flavoproteins constitute a fraction of total body iron (0.5%).
4. **Transferrin-bound iron**—circulates in the plasma and constitutes another fraction of total body iron (0.5%).

All these forms of iron are in *functional form*.

5. **Ferritin and haemosiderin**—are the *storage forms* of excess iron (30%). They are stored in the mononuclear-phagocyte cells of the spleen, liver and bone marrow and in the parenchymal cells of the liver.

Pathogenesis (p. 296)

Iron deficiency anaemia develops when the supply of iron is inadequate for the requirement of haemoglobin synthesis. Initially, negative iron balance is covered by mobilisation from the tissue stores so as to maintain haemoglobin synthesis. It is only after the tissue stores of iron are exhausted that the supply of iron to the marrow becomes insufficient for haemoglobin formation and thus a state of iron deficiency anaemia develops. The development of iron deficiency depends upon one or more of the following factors:

1. Increased blood loss
2. Increased requirements
3. Inadequate dietary intake
4. Decreased intestinal absorption.

The relative significance of these factors varies with the age and sex of the patient (**Web Table 12.4**).

Etiology (p. 297)

Iron deficiency anaemia is always secondary to an underlying disorder. Correction of the underlying cause, therefore, is essential part of its treatment. Based on the above-mentioned pathogenetic mechanisms, following etiologic factors are involved in development of iron deficiency anaemia at different age and sex (**Web Table 12.4**):

1. FEMALES IN REPRODUCTIVE PERIOD OF LIFE. The highest incidence of iron deficiency anaemia is in women during their reproductive years of life. It may be from one or more of the following causes:

- i) Blood loss
- ii) Inadequate intake
- iii) Increased requirements

2. POST-MENOPAUSAL FEMALES. Though the physiological demand for iron decreases after cessation of menstruation, iron deficiency anaemia may develop in post-menopausal women due to chronic blood loss.

- i) *Post-menopausal uterine bleeding.*
- ii) *Bleeding from the alimentary tract.*

3. ADULT MALES. It is uncommon for adult males to develop iron deficiency anaemia in the presence of normal dietary iron content and iron absorption. The vast majority of cases of iron deficiency anaemia in adult males are due to chronic blood loss.

- i) *Gastrointestinal tract* is the usual source of bleeding which may be due to peptic ulcer, haemorrhoids, hookworm infestation, carcinoma of stomach and large bowel, oesophageal varices, hiatus hernia, chronic aspirin ingestion and ulcerative colitis. Other causes in the GIT are malabsorption and following gastrointestinal surgery.
- ii) *Urinary tract* e.g. due to haematuria and haemoglobinuria.
- iii) *Nose* e.g. in repeated epistaxis.
- iv) *Lungs* e.g. in haemoptysis from various causes.

4. INFANTS AND CHILDREN. Iron deficiency anaemia is fairly common during infancy and childhood with a peak incidence at 1-2 years of age. The principal cause for anaemia at this age is increased demand of iron which is not met by the inadequate intake of iron in the diet. Normal full-term infant has sufficient iron stores for the first 4-6 months of life, while premature infants have inadequate reserves because iron stores from the mother are mainly laid down during the last trimester of pregnancy.

Clinical Features (p. 298)

The clinical consequences of iron deficiency manifest in 2 ways—

1. ANAEMIA. The onset of iron deficiency anaemia is generally slow. The usual symptoms are weakness, fatigue, dyspnoea on exertion, palpitations and pallor of the skin, mucous membranes and sclerae. Older patients may develop angina and congestive cardiac failure. Patients may have unusual dietary cravings such as pica. Menorrhagia is a common symptom in iron deficient women.

2. EPITHELIAL TISSUE CHANGES. Long-standing chronic iron deficiency anaemia causes epithelial tissue changes in some patients. The changes occur in the nails (koilonychia or spoon-shaped nails), tongue (atrophic glossitis), mouth (angular stomatitis), and oesophagus causing dysphagia from development of thin, membranous webs at the postcricoid area (Plummer-Vinson syndrome).

Laboratory Findings (p. 299)

The following laboratory tests can be used to assess the varying degree of iron deficiency (**Web Image 12.13**):

1. BLOOD PICTURE AND RED CELL INDICES. The degree of anaemia varies. It is usually mild to moderate but occasionally it may be marked (haemoglobin less than 6 g/dl) due to persistent and severe blood loss. The salient haematological findings in these cases are as under.

i) Haemoglobin. The essential feature is a fall in haemoglobin concentration up to a variable degree.

ii) Red cells. The red cells in the blood film are hypochromic and microcytic, and there is anisocytosis and poikilocytosis (**Web Image 12.14,A**). Hypochromia generally precedes microcytosis. Target cells, elliptical forms and polychromatic cells are often present. RBC count is below normal but is generally not proportionate to the fall in haemoglobin value. When iron deficiency is associated with severe folate or vitamin B₁₂ deficiency, a *dimorphic* blood picture occurs with dual population of red cells—macrocytic as well as microcytic hypochromic.

iii) Reticulocyte count. The reticulocyte count is normal or reduced but may be slightly raised (2-5%) in cases after haemorrhage.

iv) Absolute values. The red cell indices reveal a diminished MCV (below 50 fl), diminished MCH (below 15 pg), and diminished MCHC (below 20 g/dl).

v) Leucocytes. The total and differential white cell counts are usually normal.

vi) Platelets. Platelet count is usually normal but may be slightly to moderately raised in patients who have had recent bleeding.

2. BONE MARROW FINDINGS. Bone marrow examination is not essential in such cases routinely but is done in complicated cases so as to distinguish from other hypochromic anaemias. The usual findings are as follows (**Web Image 12.14,B**):

i) Marrow cellularity. The marrow cellularity is increased due to erythroid hyperplasia (myeloid-erythroid ratio decreased).

ii) Erythropoiesis. There is normoblastic erythropoiesis with predominance of small polychromatic normoblasts (micronormoblasts). These normoblasts have a thin rim of cytoplasm around the nucleus and a ragged and irregular cell border. The *cytoplasmic maturation lags behind* so that the late normoblasts have pyknotic nucleus but persisting polychromatic cytoplasm (compared from megaloblastic anaemia in which the nuclear maturation lags behind).

iii) Other cells. Myeloid, lymphoid and megakaryocytic cells are normal in number and morphology.

iv) Marrow iron. Iron staining (Prussian blue reaction) carried out on bone marrow aspirate smear shows deficient reticuloendothelial iron stores and absence of siderotic iron granules from developing normoblasts.

3. BIOCHEMICAL FINDINGS. In addition to blood and bone marrow examination, the following biochemical tests are of value:

i) The *serum iron* level is low (normal 40-140 µg/dl); it is often under 50 µg/dl. When serum iron falls below 15 µg/dl, marrow iron stores are absent.

ii) *Total iron binding capacity (TIBC)* is high (normal 250-450 µg/dl) and rises to give less than 10% saturation (normal 33%). In anaemia of chronic disorders, however, serum iron as well as TIBC are reduced.

iii) *Serum ferritin* is very low (normal 30-250 ng/ml) indicating poor tissue iron stores.

iv) *Red cell protoporphyrin* is very low (normal 20-40 µg/dl) as a result of insufficient iron supply to form haem.

The management of iron deficiency anaemia consists of 2 essential principles:

1. CORRECTION OF THE DISORDER. The underlying cause of iron deficiency is established after thorough check-up and investigations. Appropriate surgical, medical or preventive measures are instituted to correct the cause of blood loss.

2. CORRECTION OF IRON DEFICIENCY. The lack of iron is corrected with iron therapy as under:

i) Oral therapy. Iron deficiency responds very effectively to the administration of oral iron salts such as ferrous sulfate, ferrous fumarate, ferrous gluconate and polysaccharide iron.

ii) Parenteral therapy. Parenteral iron therapy is indicated in cases who are intolerant to oral iron therapy, in GIT disorders such as malabsorption, or a rapid replenishment of iron stores is desired such as in women with severe anaemia a few weeks before expected date of delivery. Parenteral iron therapy is hazardous and expensive when compared with oral administration. The haematological response to parenteral iron therapy is no faster than the administration of adequate dose of oral iron but the stores are replenished much faster.

SIDEROBLASTIC ANAEMIA (p. 300)

The sideroblastic anaemias comprise a group of disorders of diverse etiology in which the nucleated erythroid precursors in the bone marrow, show characteristic 'ringed sideroblasts.'

Siderocytes and Sideroblasts (p. 300)

Siderocytes and sideroblasts are erythrocytes and normoblasts respectively which contain cytoplasmic granules of iron (**Web Image 12.15**).

SIDEROCYTES. These are red cells containing granules of non-haem iron. These granules stain positively with Prussian blue reaction as well as stain with Romanowsky dyes when they are referred to as *Pappenheimer bodies*. Siderocytes are normally not present in the human peripheral blood but a small number may appear following splenectomy.

SIDEROBLASTS. These are nucleated red cells (normoblasts) containing siderotic granules which stain positively with Prussian blue reaction. Depending upon the number, size and distribution of siderotic granules, sideroblasts may be normal or abnormal (**Web Image 12.16**).

Normal sideroblasts contain a few fine, scattered cytoplasmic granules representing iron which has not been utilised for haemoglobin synthesis. These cells comprise 30-50% of normoblasts in the normal marrow but are reduced or absent in iron deficiency.

Abnormal sideroblasts are further of 2 types:

- ◆ *One type* is a sideroblast containing numerous, diffusely scattered, coarse cytoplasmic granules and are seen in conditions such as dyserythropoiesis and haemolysis.

- ◆ The other type is *ringed sideroblast* in which haem synthesis is disturbed as occurs in sideroblastic anaemias. Ringed sideroblasts contain numerous large granules, often forming a complete or partial ring around the nucleus.

Types of Sideroblastic Anaemias (p. 301)

Based on etiology, sideroblastic anaemias are classified into hereditary and acquired types. The acquired type is further divided into primary and secondary forms:

I. HEREDITARY SIDEROBLASTIC ANAEMIA. This is a rare X-linked disorder associated with defective enzyme activity of *aminolevulinic acid (ALA) synthetase* required for haem synthesis. The affected males have moderate to marked anaemia while the females are carriers of the disorder and do not develop anaemia. The condition manifests in childhood or in early adult life.

II. ACQUIRED SIDEROBLASTIC ANAEMIA. The acquired sideroblastic anaemias are classified into primary and secondary types.

A. Primary acquired sideroblastic anaemia. Primary, idiopathic, or refractory acquired sideroblastic anaemia occurs spontaneously in middle-aged and older individuals of both sexes. The disorder has its pathogenesis in disturbed growth and maturation of erythroid precursors at the level of haematopoietic stem cell, possibly due to reduced activity of the enzyme, ALA synthetase. The anaemia is of moderate to severe degree and appears insidiously. Unlike other types of sideroblastic anaemia, this type is regarded as a myelodysplastic disorder in the FAB (French-American-British) classification and thus, can be a preleukaemic disorder. About 10% of individuals with refractory acquired sideroblastic anaemia develop acute myelogenous leukaemia.

B. Secondary acquired sideroblastic anaemia. Acquired sideroblastic anaemia may develop secondary to a variety of drugs, chemicals, toxins, haematological and various other diseases.

1. *Drugs, chemicals and toxins:* Isoniazid, an anti-tuberculous drug and a pyridoxine antagonist, is most commonly associated with development of sideroblastic anaemia by producing abnormalities in pyridoxine metabolism. Other drugs occasionally causing acquired sideroblastic anaemia are: cycloserine, chloramphenicol and alkylating agents (e.g. cyclophosphamide). Alcohol and lead also cause sideroblastic anaemia.
2. *Haematological disorders:* These include myelofibrosis, polycythaemia vera, acute leukaemia, myeloma, lymphoma and haemolytic anaemia.
3. *Miscellaneous:* Occasionally, secondary sideroblastic anaemia may occur in association with a variety of inflammatory, neoplastic and autoimmune diseases such as carcinoma, myxoedema, rheumatoid arthritis and SLE.

Laboratory Findings (p. 301)

1. There is generally moderate to severe degree of *anaemia*.
2. The *blood picture* shows hypochromic anaemia which may be microcytic, or there may be some normocytic red cells as well (dimorphic).
3. *Absolute values* (MCV, MCH and MCHC) are reduced in hereditary type but MCV is often raised in acquired type.
4. *Bone marrow examination* shows erythroid hyperplasia with usually macronormoblastic erythropoiesis. Marrow iron stores are raised and pathognomonic ring sideroblasts are present.
5. *Serum ferritin* levels are raised.
6. *Serum iron* is usually raised with almost complete saturation of TIBC.
7. There is increased *iron deposition* in the tissue.

Treatment (p. 302)

The treatment of secondary sideroblastic anaemia is primarily focussed on removal of the offending agent. No definite treatment is available for hereditary and idiopathic types of sideroblastic anaemias. However, pyridoxine is administered routinely to all cases of sideroblastic anaemia (200 mg per day for 2-3 months). Blood transfusions and other supportive therapy are indicated in all patients.

Differential diagnosis of various types of hypochromic anaemias by laboratory tests is summarised in **Web Table 12.5**.

240 □ ANAEMIA OF CHRONIC DISORDERS (p. 302)

One of the commonly encountered anaemia is in patients of a variety of chronic systemic diseases in which anaemia develops secondary to a disease process but there is no actual invasion of the bone marrow. A list of such chronic systemic diseases is given in **Web Table 12.6**.

Pathogenesis (p. 302)

A number of factors may contribute to the development of anaemia in chronic systemic disorders, and in many conditions, the anaemia is complicated by other causes such as iron, B₁₂ and folate deficiency, hypersplenism, renal failure with consequent reduced erythropoietic activity, endocrine abnormalities etc. However, in general, 2 factors appear to play significant role in the pathogenesis of anaemia in chronic disorders.

1. Defective red cell production. Though there is abundance of storage iron in these conditions but the amount of iron available to developing erythroid cells in the marrow is subnormal. The mononuclear phagocyte system is hyperplastic which traps all the available free iron due to the activity of iron binding protein, lactoferrin. A defect in the transfer of iron from macrophages to the developing erythroid cells in the marrow leads to reduced availability of iron for haem synthesis despite adequate iron stores, elevating serum ferritin levels. The defect lies in suppression of erythropoietin by inflammatory cytokines at some stage in erythropoiesis, and hepcidin which is the key iron regulatory hormone. These inflammatory cytokines include TNF and IFN- β released in bacterial infections and tumours, and IL-1 and IFN- γ released in patients of rheumatoid arthritis and autoimmune vasculitis (**Web Image 12.17**).

2. Reduced red cell lifespan. Decreased survival of circulating red cells in chronic renal disease is attributed to hyperplastic mononuclear phagocyte system.

Laboratory Findings (p. 302)

i) Haemoglobin. Anaemia is generally mild to moderate. A haemoglobin value of less than 8 g/dl suggests the presence of additional contributory factors.

ii) Blood picture. The type of anaemia in these cases is generally normocytic normochromic but may have slight microcytosis and hypochromia.

iii) Absolute values. Red cell indices indicate that in spite of normocytic normochromic anaemia, MCHC is slightly low.

iv) Reticulocyte count. The reticulocyte count is generally low.

v) Red cell survival. Measurement of erythrocyte survival generally reveals mild to moderate shortening of their lifespan.

vi) Bone marrow. Examination of the marrow generally reveals normal erythroid maturation. However, the red cell precursors have reduced stainable iron than normal, while macrophages in the marrow usually contain increased amount of iron.

vii) Serum iron and TIBC. Serum iron is characteristically *reduced* in this group of anaemias while TIBC is low-to-normal (in contrast to iron deficiency where there is reduction in serum iron but high TIBC).

viii) Serum ferritin. Serum ferritin levels are *increased* in these patients and is the most distinguishing feature between true iron-deficiency anaemia and iron-deficient erythropoiesis in anemia of chronic diseases.

ix) Other plasma proteins. In addition, certain other plasma proteins called '*phase reactants*' are raised in patients with chronic inflammation, probably under the stimulus of interleukin-1 released by activated macrophages. These proteins include γ -globulin, C3, haptoglobin, α_1 -antitrypsin and

fibrinogen. Elevation of these proteins is responsible for raised ESR commonly present in these patients.

□ **MEGALOBlastic ANAEMIA** (p. 303)

The megaloblastic anaemias are disorders caused by impaired DNA synthesis and are characterised by a distinctive abnormality in the haematopoietic precursors in the bone marrow in which the *maturation of the nucleus is delayed relative to that of the cytoplasm*. Since cell division is slow but cytoplasmic development progresses normally, the nucleated red cell precursors tend to be larger which Ehrlich in 1880 termed *megaloblasts*.

The underlying defect for the asynchronous maturation of the nucleus is defective DNA synthesis due to deficiency of vitamin B₁₂ (cobalamin) and/or folic acid (folate).

The salient nutritional aspects and metabolic functions of vitamin B₁₂ and folic acid are summarised in **Web Table 12.7**.

Vitamin B₁₂ Metabolism (p. 303)

BIOCHEMISTRY. In humans, there are 2 metabolically active forms of cobalamin—methyl-cobalamin and adenosyl-cobalamin, which act as coenzymes. The therapeutic vitamin B₁₂ preparation is called cyanocobalamin.

SOURCES. The only dietary sources of vitamin B₁₂ are foods of animal protein origin such as kidney, liver, heart, muscle meats, fish, eggs, cheese and milk. In contrast to folate, fruits and vegetables contain practically no vitamin B₁₂ unless contaminated with bacteria. Cooking has little effect on its activity. Vitamin B₁₂ is synthesised in the human large bowel by microorganisms but is not absorbed from this site and, thus, the humans are entirely dependent upon dietary sources. The average daily requirement for vitamin B₁₂ is 2-4 µg.

ABSORPTION. After ingestion, vitamin B₁₂ in food is released and forms a stable complex with gastric R-binder. R-binder is a form of glycoprotein found in various secretions (e.g. saliva, milk, gastric juice, bile), phagocytes and plasma. On entering the duodenum, the vitamin B₁₂-R-binder complex is digested releasing vitamin B₁₂ which then binds to intrinsic factor (IF). The vitamin B₁₂-IF complex, on reaching the distal ileum, binds to the specific receptors on the mucosal brush border, thereby enabling the vitamin to be absorbed. The IF, therefore, acts as cell-directed carrier protein similar to transferrin. The receptor-bound vitamin B₁₂-IF complex is taken into the ileal mucosal cells where after several hours the IF is destroyed, vitamin B₁₂ released and is transferred to another transport protein, transcobalamin (TC) II. The vitamin B₁₂-TC II complex is finally secreted into the portal circulation from where it is taken by the liver, bone marrow and other cells (see **Web Image 12.12,B**).

TISSUE STORES. Normally, the liver is the principal storage site of vitamin B₁₂ and stores about 2 mg of the vitamin, while other tissues like kidney, heart and brain together store about 2 mg. The body stores of vitamin B₁₂ are adequate for 2-4 years.

FUNCTIONS. Vitamin B₁₂ plays an important role in general cell metabolism, particularly essential for normal haematopoiesis and for maintenance of integrity of the nervous system. Vitamin B₁₂ acts as a co-enzyme for 2 main biochemical reactions in the body:

◆ *Firstly, as methyl cobalamin (methyl B₁₂) in the methylation of homocysteine to methionine by methyl tetrahydrofolate (THF). The homocysteine-methionine reaction is closely linked to folate metabolism (Web Image 12.18).*

When this reaction is impaired, folate metabolism is deranged and results in defective DNA synthesis responsible for megaloblastic maturation.

Secondly, as *adenosyl cobalamin (adenosyl B₁₂)* in propionate metabolism for the conversion of methyl malonyl co-enzyme A to succinyl co-enzyme A.

Lack of adenosyl B₁₂ leads to large increase in the level of methyl malonyl CoA and its precursor, propionyl CoA. This results in synthesis of certain fatty acids which are incorporated into the neuronal lipids. This biochemical abnormality may contribute to the neurologic complications of vitamin B₁₂ deficiency.

Folate Metabolism (p. 304)

BIOCHEMISTRY. Folate or folic acid, a yellow compound, is a member of water-soluble B complex vitamins with the chemical name of *pteroyl glutamic acid (PGA)*. Folic acid does not exist as such in nature but exists as folates in polyglutamate form (conjugated folates).

SOURCES. Folate exists in different plants, bacteria and animal tissues. Its main dietary sources are fresh green leafy vegetables, fruits, liver, kidney, and to a lesser extent, muscle meats, cereals and milk. Folate is labile and is largely destroyed by cooking and canning. Some amount of folate synthesised by bacteria in the human large bowel is not available to the body because its absorption takes place in the small intestine. Thus, humans are mainly dependent upon diet for its supply. The average daily requirement is 100-200 µg.

ABSORPTION AND TRANSPORT. Folate is normally absorbed from the duodenum and upper jejunum and to a lesser extent, from the lower jejunum and ileum. However, absorption depends upon the form of folate in the diet. Polyglutamate form in the foodstuffs is first cleaved by the enzyme, folate conjugase, in the mucosal cells to mono- and diglutamates which are readily assimilated. Mono- and diglutamates undergo further reduction in the mucosal cells to form tetrahydrofolate (THF), a monoglutamate. THF circulates in the plasma as methylated compound, methyl THF, bound to a protein (see **Web Image 12.12,C**).

TISSUE STORES. The liver and red cells are the main storage sites of folate, largely as methyl THF polyglutamate form. The total body stores of folate are about 10-12 mg enough for about 4 months. Normally, folate is lost from the sweat, saliva, urine and faeces.

FUNCTIONS. Folate plays an essential role in cellular metabolism. It acts as a co-enzyme for 2 important biochemical reactions:

- ◆ **Thymidylate synthetase reaction.** Formation of deoxy thymidylate monophosphate (dTMP) from its precursor form, deoxy uridylate monophosphate (dUMP).
- ◆ **Methylation of homocysteine to methionine.** This reaction is linked to vitamin B₁₂ metabolism (**Web Image 12.18**).

Biochemical Basis of Megaloblastic Anaemia (p. 305)

The basic biochemical abnormality common to both vitamin B₁₂ and folate deficiency is a block in the pathway of DNA synthesis and that there is an inter-relationship between vitamin B₁₂ and folate metabolism in the methylation reaction of homocysteine to methionine (**Web Image 12.18**).

Folate as co-enzyme methylene THF, is required for transfer of 1-carbon moieties (e.g. methyl and formyl) to form building blocks in DNA synthesis. The 1-carbon moieties are derived from serine or formiminoglutamic acid (FIGLU). Two of the important folate-dependent (1-carbon transfer) reactions for formation of building blocks in DNA synthesis are as under:

1. Thymidylate synthetase reaction. This reaction involves synthesis of deoxy thymidylate monophosphate (dTMP) from deoxy uridylate monophosphate (dUMP). The methyl group of dUMP \rightarrow dTMP reaction is supplied by the co-enzyme, methylene-THF. After the transfer of 1-carbon from methylene-THF, dihydrofolate (DHF) is produced which must be reduced to active THF by the enzyme DHF-reductase before it can participate in further 1-carbon transfer reaction. Drugs like methotrexate (anti-cancer) and pyrimethamine (antimalarial) are inhibitory to the enzyme, DHF-reductase, thereby inhibiting the DNA synthesis.

2. Homocysteine-methionine reaction. Homocysteine is converted into methionine by transfer of a methyl group from methylene-THF. After transfer of 1-carbon from methylene-THF, THF is produced. This reaction requires the presence of vitamin B₁₂ (methyl-B₁₂).

Deficiency of folate from any cause results in reduced supply of the coenzyme, methylene-THF, and thus interferes with the synthesis of DNA. Deficiency of vitamin B₁₂ traps folate as its transport form, methyl-THF, thereby resulting in reduced formation of the active form, methylene-THF, needed for DNA synthesis. This is referred to as *methyl-folate trap hypothesis*.

Etiology and Classification of Megaloblastic Anaemia (p. 305)

As outlined in **Web Table 12.8**, megaloblastic anaemia is classified into 3 broad groups: vitamin B₁₂ deficiency, folate deficiency, and deficiency from other causes.

1. VITAMIN B₁₂ DEFICIENCY. In Western countries, deficiency of vitamin B₁₂ is more commonly due to pernicious (Addisonian) anaemia. True vegetarians like traditional Indian Hindus and breast-fed infants have dietary lack of vitamin B₁₂. Gastrectomy by lack of intrinsic factor, and small intestinal lesions involving distal ileum where absorption of vitamin B₁₂ occurs, may cause deficiency of the vitamin. Deficiency of vitamin B₁₂ takes at least 2 years to develop when the body stores are totally depleted.

2. FOLATE DEFICIENCY. Folate deficiency is more often due to poor dietary intake. Other causes include malabsorption, excess folate utilisation such as in pregnancy and in various disease states, chronic alcoholism, and excess urinary folate loss. Folate deficiency arises more rapidly than vitamin B₁₂ deficiency since the body's stores of folate are relatively low which can last for up to 4 months only.

Patients with tropical sprue are often deficient in both vitamin B₁₂ and folate. Combined deficiency of vitamin B₁₂ and folate may occur from severe deficiency of vitamin B₁₂ because of the biochemical interrelationship with folate metabolism.

3. OTHER CAUSES. In addition to deficiency of vitamin B₁₂ and folate, megaloblastic anaemias may occasionally be induced by other factors unrelated to vitamin deficiency. These include many drugs which interfere with DNA synthesis, acquired defects of haematopoietic stem cells, and rarely, congenital enzyme deficiencies.

Clinical Features (p. 306)

1. Anaemia. Macrocytic megaloblastic anaemia is the cardinal feature of deficiency of vitamin B₁₂ and/or folate. The onset of anaemia is usually insidious and gradually progressive.

2. Glossitis. Typically, the patient has a smooth, beefy, red tongue.

3. Neurologic manifestations. Vitamin B₁₂ deficiency, particularly in patients of pernicious anaemia, is associated with significant neurological manifestations in the form of subacute combined, degeneration of the spinal cord and peripheral neuropathy, while folate deficiency may occasionally develop neuropathy only. The underlying pathologic process consists of demyelination of the peripheral nerves, the spinal cord and the cerebrum.

4. Others. In addition to the cardinal features mentioned above, patients may have various other symptoms. These include: mild jaundice, angular stomatitis, purpura, melanin pigmentation, symptoms of malabsorption, weight loss and anorexia.

Laboratory Findings (p. 306)

A. General Laboratory Findings (p. 306)

1. BLOOD PICTURE AND RED CELL INDICES. Estimation of haemoglobin, examination of a blood film and evaluation of absolute values are essential preliminary investigations (**Web Image 12.19**):

i) Haemoglobin. Haemoglobin estimation reveals values below the normal range. The fall in haemoglobin concentration may be of a variable degree.

ii) Red cells. Red blood cell morphology in a blood film shows the characteristic macrocytosis. In addition, the blood smear demonstrates marked anisocytosis, poikilocytosis and presence of macroovalocytes. Basophilic stippling and occasional normoblast may also be seen (**Web Image 12.20, A**).

iii) Reticulocyte count. The reticulocyte count is generally low to normal in untreated cases.

iv) Absolute values. The red cell indices reveal an elevated MCV (above 120 fl) proportionate to the severity of macrocytosis, elevated MCH (above 50 pg) and normal or reduced MCHC.

v) Leucocytes. The total white blood cell count may be reduced. Presence of characteristic hypersegmented neutrophils (having more than 5 nuclear lobes) in the blood film should raise the suspicion of megaloblastic anaemia. An occasional myelocyte may also be seen.

vi) Platelets. Platelet count may be moderately reduced in severely anaemic patients. Bizarre forms of platelets may be seen.

2. BONE MARROW FINDINGS. The bone marrow examination is very helpful in the diagnosis of megaloblastic anaemia (**Web Image 12.20, B**):

i) Marrow cellularity. The marrow is hypercellular with a decreased myeloid-erythroid ratio.

ii) Erythropoiesis. Erythroid hyperplasia is due to characteristic megaloblastic erythropoiesis. *Megaloblasts* are abnormal, large, nucleated erythroid precursors, having nuclear-cytoplasmic asynchrony i.e. the nuclei are less mature than the development of cytoplasm. The nuclei are large, having fine, reticular and open chromatin that stains lightly, while the haemoglobinisation of the cytoplasm proceeds normally or at a faster rate i.e. *nuclear maturation lags behind that of cytoplasm* (compared from iron deficiency anaemia in which cytoplasmic maturation lags behind). Megaloblasts with abnormal mitoses may be seen. Features of ineffective erythropoiesis such as presence of degenerated erythroid precursors may be present.

iii) Other cells. Granulocyte precursors are also affected to some extent. Giant forms of metamyelocytes and band cells may be present in the marrow. Megakaryocytes are usually present in normal number but may occasionally be decreased and show abnormal morphology such as hypersegmented nuclei and agranular cytoplasm.

iv) Marrow iron. Prussian blue staining for iron in the marrow shows an increase in the number and size of iron granules in the erythroid precursors. Ring sideroblasts are, however, rare. Iron in the reticulum cells is increased.

v) Chromosomes. Marrow cells may show variety of random chromosomal abnormalities such as chromosome breaks, centromere spreading etc.

3. BIOCHEMICAL FINDINGS. These are as under:

- i) There is rise in *serum unconjugated bilirubin and LDH*.
- ii) The *serum iron and ferritin* may be normal or elevated.

B. Special Tests for Cause of Specific Deficiency (p. 307)

In sophisticated clinical laboratories, currently automated multiparametric, random access analysers are employed based on separation techniques by chemiluminescence and enzyme-linked fluorescence detection systems which have largely replaced the traditional microbiologic assays for vitamin B₁₂ and folate.

TESTS FOR VITAMIN B₁₂ DEFICIENCY. The normal range of vitamin B₁₂ in serum is 280-1000 pg/ml. Values less than 100 pg/ml indicate clinically deficient stage. Traditional tests employed to establish vitamin B₁₂ deficiency are as under:

1. **SERUM VITAMIN B₁₂ ASSAY.** Assay of vitamin B₁₂ in blood can be done by 2 methods—microbiological assay and radioassay.

2. **SCHILLING TEST (24 HOUR URINARY EXCRETION TEST).** Schilling test is done to detect vitamin B₁₂ deficiency as well as to distinguish and detect lack of IF and malabsorption syndrome. The results of test also depend upon good renal function and proper urinary collection. Radioisotope used for labeling B₁₂ is either ⁵⁸Co or ⁵⁷Co. The test is performed in 3 stages as under:

Stage I: Without IF.

Stage II: With IF.

Stage III: Test for malabsorption of vitamin B₁₂.

3. **SERUM ENZYME LEVELS.** Serum levels of methylmalonic acid and homocysteine by sophisticated enzymatic assays are elevated in cobalamine deficiency, while in folate deficiency there is only elevation of homocysteine and not of methylmalonic acid.

TESTS FOR FOLATE DEFICIENCY. The normal range of serum folate is 6-18 ng/ml. Values of 4 ng/ml or less are generally considered to be diagnostic of folate deficiency. Measurement of *formiminoglutamic acid (FIGLU) urinary excretion* after histidine load was used formerly for assessing folate status but it is less specific and less sensitive than the serum assays. Currently, there are 3 tests used to detect folate deficiency.

1. **URINARY EXCRETION OF FIGLU.** Folic acid is required for conversion of formiminoglutamic acid (FIGLU) to glutamic acid in the catabolism of histidine. Thus, on oral administration of histidine, urinary excretion of FIGLU is increased if folate deficiency is present.

2. **SERUM FOLATE ASSAY.** The folate in serum can be estimated by 2 methods—microbiological assay and radioassay.

3. **RED CELL FOLATE ASSAY.** Red cells contain 20-50 times more folate than the serum; thus red cell folate assay is more reliable indicator of tissue stores of folate than serum folate assay. Microbiological radioassay and protein-binding assay methods can be used for estimation of red cell folate. Red cell folate values are decreased in patients with megaloblastic anaemia as well as in patients with pernicious anaemia.

Treatment (p. 309)

Most cases of megaloblastic anaemia need therapy with appropriate vitamin.

Treatment of megaloblastic anaemia is quite gratifying. The marrow begins to revert back to normal morphology within a few hours of initiating treatment and becomes normoblastic within 48 hours of start of treatment. Reticulocytosis appears within 4-5 days after therapy is started and peaks at day 7. Haemoglobin should rise by 2-3 g/dl each fortnight.

□ PERNICIOUS ANAEMIA (p. 309)

Pernicious anaemia (PA) was first described by Addison in 1855 as a chronic disorder of middle-aged and elderly individual of either sex in which

246 intrinsic factor (IF) secretion ceases owing to atrophy of the gastric mucosa. The condition is, therefore, also termed Addisonian megaloblastic anaemia. The average age at presentation is 60 years but rarely it can be seen in children under 10 years of age (juvenile pernicious anaemia).

Pathogenesis (p. 309)

The evidences in support of immunological abnormalities in pernicious anaemia are as under:

1. The incidence of PA is high in patients with *other autoimmune diseases* such as Graves' disease, myxoedema, thyroiditis, vitiligo, diabetes and idiopathic adrenocortical insufficiency.
2. Patients with PA have abnormal *circulating autoantibodies* such as anti-parietal cell antibody (90% cases) and anti-intrinsic factor antibody (50% cases).
3. *Relatives* of patients with PA have an increased incidence of the disease or increased presence of autoantibodies.
4. *Corticosteroids* have been reported to be beneficial in curing the disease both pathologically and clinically.
5. PA is more common in patients with *agammaglobulinaemia* supporting the role of cellular immune system in destruction of parietal cells.

Morphologic Features (p. 309)

The most characteristic pathologic finding in PA is gastric atrophy affecting the acid- and pepsin-secreting portion of the stomach and sparing the antrum. Gastric epithelium may show cellular atypia. About 2-3% cases of PA develop carcinoma of the stomach. Other pathologic changes are secondary to vitamin B₁₂ deficiency and include megaloblastoid alterations in the gastric and intestinal epithelium and neurologic abnormalities such as peripheral neuropathy and spinal cord damage.

Clinical Features (p. 309)

The disease has insidious onset and progresses slowly. The clinical manifestations are mainly due to vitamin B₁₂ deficiency. These include: anaemia, glossitis, neurological abnormalities (neuropathy, subacute combined degeneration of the spinal cord, retrobulbar neuritis), gastrointestinal manifestations (diarrhoea, anorexia, weight loss, dyspepsia), hepatosplenomegaly, congestive heart failure and haemorrhagic manifestations. Other autoimmune diseases such as autoimmune thyroiditis may be associated.

Diagnostic Criteria (p. 309)

Since diagnosis of PA requires the patient to receive lifelong parenteral B₁₂ therapy, the diagnosis of PA is made by combined clinical and laboratory evaluation as per following diagnostic criteria:

I. Major criteria:

- i) Low serum B₁₂ level in presence of normal renal function
- ii) Megaloblastic anaemia in bone marrow examination, which should not be due to folate deficiency
- iii) Positive test for IF antibody

II. Minor laboratory criteria:

- i) Macrocytosis in PBF
- ii) Anaemia of variable degree
- iii) Hypergastrinaemia
- iv) Positive gastric parietal cell antibody
- v) Raised plasma homocysteine level
- vi) Gastric pH above 6

III. Minor clinical criteria:

- i) Neurologic features of parasthaesia, numbness or ataxia

- ii) Hypothyroidism
- iii) Family history of PA or hypothyroidism
- iv) Vitiligo

IV. Reference standard criteria:

i) Schilling test showing malabsorption of oral cyanocobalamin corrected by simultaneous administration of IF.

□ HAEMOLYTIC ANAEMIAS (p. 310)

GENERAL ASPECTS (p. 310)

Definition and Classification (p. 310)

Haemolytic anaemias are defined as anaemias resulting from an increase in the rate of red cell destruction. Normally, effete red cells undergo lysis at the end of their lifespan of 120 ± 30 days within the cells of reticuloendothelial (RE) system in the spleen and elsewhere (extravascular haemolysis). The red cell lifespan is shortened in haemolytic anaemia i.e. there is accelerated haemolysis.

The premature destruction of red cells in haemolytic anaemia may occur by 2 mechanisms:

◆ **Firstly**, the red cells undergo lysis in the circulation and release their contents into plasma (*intravascular haemolysis*). In these cases the plasma haemoglobin rises substantially and part of it may be excreted in the urine (*haemoglobinuria*).

◆ **Secondly**, the red cells are taken up by cells of the RE system where they are destroyed and digested (*extravascular haemolysis*). In extravascular haemolysis, plasma haemoglobin level is, therefore, barely raised.

Haemolytic anaemias are broadly classified into 2 main categories:

- I. *Acquired haemolytic anaemias* caused by a variety of extrinsic environmental factors (*extracorporeal*).
- II. *Hereditary haemolytic anaemias* are usually the result of intrinsic red cell defects (*intracorporeal*).

A simplified classification based on these mechanisms is given in **Web Table 12.9** and diagrammatically represented in **Web Image 12.21**.

Features of Haemolysis (p. 310)

GENERAL CLINICAL FEATURES. Some of the general clinical features common to most congenital and acquired haemolytic anaemias are as under:

1. Presence of pallor of mucous membranes.
2. Positive family history with life-long anaemia in patients with congenital haemolytic anaemia.
3. Mild fluctuating jaundice due to unconjugated hyperbilirubinaemia.
4. Urine turns dark on standing due to excess of urobilinogen in urine.
5. Splenomegaly is found in most chronic haemolytic anaemias, both congenital and acquired.
6. Pigment gallstones are found in some cases.

LABORATORY EVALUATION OF HAEMOLYSIS. The laboratory findings are conveniently divided into the following 4 groups:

I. Tests of increased red cell breakdown:

1. *Serum bilirubin*—unconjugated (indirect) bilirubin is raised.
2. *Urine urobilinogen* is raised but there is no bilirubinuria.
3. *Faecal stercobilinogen* is raised.
4. *Serum haptoglobin* (α -globulin binding protein) is reduced or absent.
5. *Plasma lactic dehydrogenase* is raised.
6. *Evidences of intravascular haemolysis* in the form of haemoglobinaemia, haemoglobinuria, methaemoglobinaemia and haemosiderinuria.

248 II. Tests of increased red cell production:

1. *Reticulocyte count* reveals reticulocytosis which is generally early and is hence most useful initial test of marrow erythroid hyperplasia.
2. *Routine blood film* shows macrocytosis, polychromasia and presence of normoblasts.
3. *Bone marrow* shows erythroid hyperplasia with usually raised iron stores.
4. *X-ray of bones* shows evidence of expansion of marrow space, especially in tubular bones and skull.

III. Tests of damage to red cells:

1. *Routine blood film* shows a variety of abnormal morphological appearances of red cells (**Web Image 12.10**). A summary of contributory features of morphology of RBCs in arriving at the diagnosis of haemolytic anaemia and its cause is given in **Web Table 12.10**.
2. *Osmotic fragility* is increased or decreased.
3. *Autohaemolysis test* with or without addition of glucose.
4. *Coombs' antiglobulin test*.
5. *Electrophoresis* for abnormal haemoglobins.
6. *Estimation of HbA₂*.
7. *Estimation of HbF*.
8. *Tests for sickling*.
9. *Screening test for G6PD deficiency* and other enzymes (e.g. Heinz bodies test).

IV. Tests for shortened red cell lifespan. A shortened red cell survival is best tested by ⁵¹Cr labelling method. Normal RBC lifespan of 120 days is shortened to 20-40 days in moderate haemolysis and to 5-20 days in severe haemolysis.

□ I. ACQUIRED (EXTRACORPUSCULAR) HAEMOLYTIC ANAEMIAS (p. 311)

Acquired haemolytic anaemias are caused by a variety of extrinsic factors, namely: antibody (immunohaemolytic anaemia), mechanical factors (microangiopathic haemolytic anaemia), direct toxic effect (in malaria, clostridial infection etc), splenomegaly, and certain acquired membrane abnormalities (paroxysmal nocturnal haemoglobinuria). These are discussed below:

A. IMMUNOHAEMOLYTIC ANAEMIAS (p. 312)

Immunohaemolytic anaemias are a group of anaemias occurring due to antibody production by the body against its own red cells. Immune haemolysis in these cases may be induced by one of the following three types of antibodies:

1. *Autoimmune haemolytic anaemia (AIHA)* characterised by formation of autoantibodies against patient's own red cells. Depending upon the reactivity of autoantibody, AIHA is further divided into 2 types:
 - i) 'Warm' antibody AIHA in which the autoantibodies are reactive at body temperature (37°C).
 - ii) 'Cold' antibody AIHA in which the autoantibodies react better with patient's own red cells at 4°C.
2. *Drug-induced immunohaemolytic anaemia*.
3. *Isoimmune haemolytic anaemia* in which the antibodies are acquired by blood transfusions, pregnancies and haemolytic disease of the newborn.

An important diagnostic tool in all cases of immunohaemolytic anaemias is Coombs' antiglobulin test for detection of incomplete Rh-antibodies in saline directly (direct Coombs') or after addition of albumin (indirect Coombs').

Autoimmune Haemolytic Anaemia (AIHA) (p. 312)

'WARM' ANTIBODY AIHA (p. 312)

PATHOGENESIS. Warm antibodies reactive at body temperature and coating the red cells are generally IgG class antibodies and occasionally they are

IgA. Little is known about the origin of these acquired red blood cell antibodies in AIHA but the mechanism of destruction of red cells coated with IgG is better understood. Human red cells coated with IgG antibodies are bound to the surface of RE cells, especially splenic macrophages. The spleen is particularly efficient in trapping red cells coated with IgG antibodies. It is, thus, the major site of red cell destruction in warm antibody AIHA.

CLINICAL FEATURES. Warm antibody AIHA may occur at any age and in either sex. The disease may occur without any apparent cause (idiopathic) but about a quarter of patients develop this disorder as a complication of an underlying disease affecting the immune system such as SLE, chronic lymphocytic leukaemia, lymphomas and certain drugs such as methyl DOPA, penicillin etc (**Web Table 12.11**).

The disease tends to have remissions and relapses. The usual clinical features are as follows:

1. Chronic anaemia of varying severity with remissions and relapses.
2. Splenomegaly.
3. Occasionally hyperbilirubinaemia.

LABORATORY FINDINGS. These are as follows:

1. Mild to moderate chronic anaemia.
2. Reticulocytosis.
3. Prominent spherocytosis in the peripheral blood film.
4. Positive direct Coombs' (antiglobulin) test for presence of warm antibodies on the red cell, best detected at 37°C.
5. A positive indirect Coombs' (antiglobulin) test at 37°C may indicate presence of large quantities of warm antibodies in the serum.
6. Unconjugated (indirect) hyperbilirubinaemia.
7. Co-existent immune thrombocytopenia alongwith occasional venous thrombosis may be present (termed Evans' syndrome).
8. In more severe cases, haemoglobinaemia and haemoglobinuria may be present.

'COLD' ANTIBODY AIHA (p. 312)

PATHOGENESIS. Antibodies which are reactive in the cold (4°C) may induce haemolysis under 2 conditions:

1. Cold agglutinin disease. In cold agglutinin disease, the antibodies are IgM type which bind to the red cells best at 4°C. These cold antibodies are usually directed against the I antigen on the red cell surface. Agglutination of red blood cells by IgM cold agglutinins is most profound at very low temperature but upon warming to 37°C or above, disagglutination occurs quickly. Haemolytic effect is mediated through fixation of C3 to the red blood cell surface and not by agglutination alone. Most cold agglutinins affect juvenile red blood cells.

2. Paroxysmal cold haemoglobinuria (PCH). In PCH, cold antibody is an IgG antibody (Donath-Landsteiner antibody) which is directed against P blood group antigen and brings about complement-mediated haemolysis. Attacks of PCH are precipitated by exposure to cold.

CLINICAL FEATURES. These are as under:

1. Chronic anaemia which is worsened by exposure to cold.
2. Raynaud's phenomenon.
3. Cyanosis affecting the cold exposed regions such as tips of nose, ears, fingers and toes.
4. Haemoglobinaemia and haemoglobinuria occur on exposure to cold.

LABORATORY FINDINGS. The haematologic and biochemical findings are somewhat similar to those found in warm antibody AIHA except the thermal amplitude.

1. Chronic anaemia.

2. Low reticulocyte count since *young red cells are affected more*.
3. Spherocytosis is less marked.
4. Positive direct Coombs' test for detection of C3 on the red cell surface but IgM responsible for C3 coating on red cells is not found.
5. The cold antibody titre is very high at 4°C and very low at 37°C (Donath-Landsteiner test). IgM class cold antibody has specificity for *I* antigen, while the rare IgG class antibody of PCH has *P* blood group antigen specificity.

Drug-induced Immuno-haemolytic Anaemia (p. 313)

1. **α-METHYL DOPA TYPE ANTIBODIES.** A small proportion of patients receiving α-methyl dopa develop immuno-haemolytic anaemia which is identical in every respect to warm antibody AIHA described above.
2. **PENICILLIN-INDUCED IMMUNOHAEMOLYSIS.** Patients receiving large doses of penicillin or penicillin-type antibiotics develop antibodies against the red blood cell-drug complex which induces haemolysis.
3. **INNOCENT BYSTANDER IMMUNOHAEMOLYSIS.** Drugs such as quinidine form a complex with plasma proteins to which an antibody forms. This drug-plasma protein-antibody complex may induce lysis of bystander red blood cells or platelets.

Isoimmune Haemolytic Anaemia (p. 313)

Isoimmune haemolytic anaemias are caused by acquiring isoantibodies or alloantibodies by blood transfusions, pregnancies and in haemolytic disease of the newborn. These antibodies produced by one individual are directed against red blood cells of the other.

B. MICROANGIOPATHIC HAEMOLYTIC ANAEMIA (p. 313)

Microangiopathic haemolytic anaemia is caused by abnormalities in the microvasculature. It is generally due to mechanical trauma to the red cells in circulation and is characterised by red cell fragmentation (schistocytosis). There are 3 different ways by which microangiopathic haemolytic anaemia results:

1. **EXTERNAL IMPACT.** Direct external trauma to red blood cells when they pass through microcirculation, especially over the bony prominences, may cause haemolysis during various activities e.g. in prolonged marchers, joggers, karate players etc. These patients develop haemoglobinaemia, haemoglobinuria (*march haemoglobinuria*), and sometimes myoglobinuria as a result of damage to muscles.
2. **CARDIAC HAEMOLYSIS.** A small proportion of patients who received prosthetic cardiac valves or artificial grafts develop haemolysis. This has been attributed to direct mechanical trauma to the red cells or shear stress from turbulent blood flow.
3. **FIBRIN DEPOSIT IN MICROVASCULATURE.** Deposition of fibrin in the microvasculature exposes the red cells to physical obstruction and eventual fragmentation of red cells and trapping of the platelets. Fibrin deposits in the small vessels may occur in the following conditions:
 - i) *Abnormalities of the vessel wall* e.g. in hypertension, eclampsia, disseminated cancers, transplant rejection, haemangioma etc.
 - ii) *Thrombotic thrombocytopenic purpura*.
 - iii) *Haemolytic-uraemic syndrome*.
 - iv) *Disseminated intravascular coagulation (DIC)*
 - v) *Vasculitis in collagen diseases*.

C. HAEMOLYTIC ANAEMIA FROM DIRECT TOXIC EFFECTS (p. 313)

Haemolysis may result from direct toxic effects of certain agents. These include the following examples:

1. *Malaria* by direct parasitisation of red cells (black-water fever) (**Web Image 12.22**).
2. *Bartonellosis* by direct infection of red cells by the microorganisms.
3. *Septicaemia* with *Clostridium welchii* by damaging the red cells.
4. *Other microorganisms* such as pneumococci, staphylococci and *Escherichia coli*.
5. *Copper* by direct haemolytic effect on red cells in Wilson's disease and patients on haemodialysis.
6. *Lead poisoning* shows basophilic stippling of red blood cells.
7. *Snake and spider bites* cause haemolysis by their venoms.
8. *Extensive burns*.

D. PAROXYSMAL NOCTURNAL HAEMOGLOBINURIA (PNH) (p. 314)

PNH is a rare acquired disorder of red cell membrane in which there is chronic intravascular haemolysis due to undue sensitivity of red blood cells to complement due to defective synthesis of a red cell membrane protein. The defect affects all the cells of myeloid progenitor lineage (RBCs, WBCs, platelets) suggesting a deficient haematopoiesis.

PATHOGENESIS. PNH is considered as an acquired clonal disease of the cell membrane while normal clone also continues to proliferate. The defect is a mutation in the stem cells affecting myeloid progenitor cells that is normally required for the biosynthesis of glycosyl phosphatidyl inositol (GPI) essential for anchoring of the cell; the mutant form of the gene is an X-linked gene called PIG-A (phosphatidyl inositol glycan). Out of about 20 such proteins described so far, the lack of two of the proteins—*decay accelerating factor (DAF, CD55)* and a *membrane inhibitor of reactive lysis (MIRL, CD59)*, makes the RBCs unduly sensitive to the lytic effect of complement.

CLINICAL AND LABORATORY FINDINGS. These are:

- i) Haemolytic anaemia.
- ii) Pancytopenia (mild granulocytopenia and thrombocytopenia frequent).
- iii) Intermittent clinical haemoglobinuria; acute haemolytic episodes occur at night identified by passage of brown urine in the morning.
- iv) Haemosiderinuria very common.
- v) Venous thrombosis as a common complication.

The presence of inordinate sensitivity of red blood cells, leucocytes and platelets to complement in PNH can be demonstrated *in vitro* by *Ham's test* using red cell lysis at acidic pH or by sucrose haemolysis test.

E. HAEMOLYTIC ANAEMIA IN SPLENOMEGALY (p. 314)

Haemolytic anaemia is common in splenic enlargement from any cause. Normally, the spleen acts as a filter and traps the damaged red blood cells, destroys them and the splenic macrophages phagocytose the damaged red cells. A normal spleen poses no risk to normal red blood cells. But splenomegaly exaggerates the damaging effect to which the red cells are exposed. Besides haemolytic anaemia, splenomegaly is usually associated with pancytopenia. Splenectomy or reduction in size of spleen by appropriate therapy relieves the anaemia as well as improves the leucocyte and platelet counts.

□ II. HEREDITARY (INTRACORPUSCULAR) HAEMOLYTIC ANAEMIA (p. 314)

Hereditary haemolytic anaemias are usually the result of intracorporeal defects. Accordingly, they are broadly classified into 2 groups (see **Web Table 12.9**):

- ◆ Hereditary abnormalities of red cell membrane.
- ◆ Hereditary disorders of the interior of the red cells.

252 □ A. HEREDITARY ABNORMALITIES OF
RED CELL MEMBRANE (p. 314)

Hereditary Spherocytosis (p. 314)

Hereditary spherocytosis is a common type of hereditary haemolytic anaemia of autosomal dominant inheritance in which the red cell membrane is abnormal.

PATHOGENESIS. The molecular abnormality in hereditary spherocytosis is a defect in proteins which anchor the lipid bilayer to the underlying cytoskeleton. These protein abnormalities are as under and are schematically illustrated in **Web Image 12.23**:

1. **Spectrin deficiency.** Almost all cases have deficiency in the structural protein of the red cell membrane, spectrin. Spectrin deficiency correlates with the severity of anaemia.
2. **Ankyrin abnormality.** About half the cases of hereditary spherocytosis have defect in ankyrin, protein that binds protein 3 and spectrin.

Inherited mutation in spectrin or ankyrin causes defect in anchoring of lipid bilayer cell membrane. Red cells with such unstable membrane but with normal volume, when released in circulation, lose their membrane further, till they can accommodate the given volume. This results in formation of spheroidal contour and smaller size of red blood cells, termed *micro-spherocytes*.

CLINICAL FEATURES. The family history may be present. The major clinical features are as under:

1. *Anaemia* is usually mild to moderate.
2. *Splenomegaly* is a constant feature.
3. *Jaundice* occurs due to increased concentration of unconjugated (indirect) bilirubin in the plasma (also termed congenital haemolytic jaundice).
4. *Pigment gallstones* are frequent due to increased bile pigment production. Splenectomy offers the only reliable mode of treatment.

LABORATORY FINDINGS. These are as follows:

1. *Anaemia* of mild to moderate degree.
2. *Reticulocytosis*, usually 5-20%.
3. Blood film shows the characteristic abnormality of erythrocytes in the form of *microspherocytes* (**Web Image 12.24**).
4. MCV is usually normal or slightly decreased but *MCHC* is increased.
5. Osmotic fragility test is helpful in testing the spheroidal nature of red cells which lyse more readily in solutions of low salt concentration i.e. *osmotic fragility is increased* (**Web Image 12.25**).
6. *Autohaemolysis test* is similar to osmotic fragility test after incubation and shows increased spontaneous autohaemolysis (10-15% red cells) as compared to normal red cells (less than 4%). Autohaemolysis is correctable by addition of glucose.
7. *Direct Coombs' (antiglobulin) test* is negative so as to distinguish this condition from acquired spherocytosis of AIHA in which case it is positive.

Hereditary Elliptocytosis (Hereditary Ovalocytosis) (p. 315)

Hereditary elliptocytosis or hereditary ovalocytosis is another autosomal dominant disorder involving red cell membrane protein *spectrin*.

Acquired causes of elliptocytosis include iron deficiency and myeloproliferative disorders.

Hereditary Stomatocytosis (p. 316)

Stomatocytes are cup-shaped RBCs having one surface concave and the other side as convex. This causes a central slit-like or mouth-like appearance

of red cells. The underlying defect is in membrane protein, *stomatin*, having autosomal dominant pattern of inheritance.

□ B. HEREDITARY DISORDERS OF RED CELL INTERIOR (p. 316)

Inherited disorders involving the interior of the red blood cells are classified into 2 groups:

1. Red cell enzyme defects (Enzymopathies): These cause defective red cell metabolism involving 2 pathways (**Web Image 12.26**):

- i) *Defects in the hexose monophosphate shunt:* Common example is glucose-6-phosphate dehydrogenase (G6PD) deficiency.
- ii) *Defects in the Embden-Meyerhof (glycolytic) pathway:* Example is pyruvate kinase (PK) deficiency.

2. Disorders of haemoglobin (haemoglobinopathies): These are divided into 2 subgroups:

- i) *Structurally abnormal haemoglobin:* Examples are sickle syndromes and other haemoglobinopathies.
- ii) *Reduced globin chain synthesis:* Common examples are various types of thalassaemias.

RED CELL ENZYME DEFECTS (ENZYMOPATHIES) (p. 316)

G6PD DEFICIENCY

Among the defects in hexose monophosphate shunt, the most common is G6PD deficiency. G6PD gene is located on the X chromosome and its deficiency is, therefore, a sex (X)-linked trait affecting males, while the females are carriers and are asymptomatic. The most common and significant clinical variant is A–(negative) type found in black males. Like the HbS gene, the A–type G6PD variant confers protection against malaria. Individuals with A– G6PD variant have shortened red cell lifespan but without anaemia. However, these individuals develop haemolytic episodes on exposure to oxidant stress such as viral and bacterial infections, certain drugs (antimalarials, sulfonamides, nitrofurantoin, aspirin, vitamin K), metabolic acidosis and on ingestion of fava beans (favism).

PATHOGENESIS. Normally, red blood cells are well protected against oxidant stress because of adequate generation of reduced glutathione via the hexose monophosphate shunt. Individuals with inherited deficiency of G6PD, an enzyme required for hexose monophosphate shunt for glucose metabolism, fail to develop adequate levels of reduced glutathione in their red cells. This results in oxidation and precipitation of haemoglobin within the red cells forming Heinz bodies.

CLINICAL FEATURES. The clinical manifestations are those of an acute haemolytic anaemia within hours of exposure to oxidant stress. The haemolysis is, however, self-limiting even if the exposure to the oxidant is continued since it *affects the older red cells only*. Haemoglobin level may return to normal when the older population of red cells has been destroyed and only younger cells remain. Some patients may have only darkening of the urine from haemoglobinuria but more severely affected ones develop constitutional symptoms including jaundice.

LABORATORY FINDINGS. These are as under:

1. During the period of acute haemolysis, there is rapid fall in haematocrit by 25-30%, features of intravascular haemolysis such as rise in plasma haemoglobin, haemoglobinuria, rise in unconjugated bilirubin and fall in plasma haptoglobin. Formation of Heinz bodies is visualised by means of supravital stains such as crystal violet, also called *Heinz body haemolytic anaemia*.

254 2. Between the crises, the affected patient generally has no anaemia. The red cell survival is, however, shortened.

The diagnosis of G6PD enzyme deficiency is made by one of the screening tests (e.g. methaemoglobin reduction test, fluorescent screening test, ascorbate cyanide screening test), or by direct enzyme assay on red cells.

PK DEFICIENCY (p. 317)

Pyruvate kinase (PK) deficiency is the only significant enzymopathy of the Embden-Meyerhof glycolytic pathway. The disorder is inherited as an autosomal recessive pattern. Heterozygote state is entirely asymptomatic, while the homozygous individual presents during early childhood with anaemia, jaundice and splenomegaly.

LABORATORY FINDINGS: These are as under:

1. Normocytic and normochromic anaemia.
2. Reticulocytosis.
3. Blood film shows bizarre red cells.
4. Osmotic fragility is usually normal but after incubation it is increased.
5. Autohaemolysis is increased, but unlike hereditary spherocytosis, is not corrected by addition of glucose.
6. Direct specific enzyme assay on red cells is the only method of establishing the diagnosis.

HAEMOGLOBINOPATHIES (p. 317)

Haemoglobin in RBCs may be abnormally synthesised due to inherited defects. These disorders may be of two types:

- **Qualitative disorders** in which there is structural abnormality in synthesis of haemoglobin e.g. sickle cell syndrome, other haemoglobinopathies.
- **Quantitative disorders** in which there quantitatively decreased globin chain synthesis of haemoglobin e.g. thalassaemias.

There are geographic variations in the distribution of various haemoglobinopathies world over as shown in **Web Image 12.27**.

SICKLE SYNDROMES (p. 318)

The most important and widely prevalent type of haemoglobinopathy is due to the presence of sickle haemoglobin (HbS) in the red blood cells. The red cells with HbS develop 'sickling' when they are exposed to low oxygen tension. Sickle syndromes have the highest frequency in black race and in Central Africa where *falciparum* malaria is endemic. Patients with HbS are relatively protected against *falciparum* malaria. Sickle syndromes occur in 3 different forms:

Heterozygous State: Sickle Cell Trait

Sickle cell trait (AS) is a benign heterozygous state of HbS in which only one abnormal gene is inherited. Patients with AS develop no significant clinical problems except when they become severely hypoxic and may develop sickle cell crises.

LABORATORY FINDINGS. These patients have no anaemia and have normal appearance of red cells. But in hypoxic crisis, sickle cell crises develop. The diagnosis is made by 2 tests:

1. *Demonstration of sickling* done under condition of reduced oxygen tension by an oxygen consuming reagent, sodium metabisulfite.
2. *Haemoglobin electrophoresis* reveals 35-40% of the total haemoglobin as HbS.

Homozygous State: Sickle Cell Anaemia

Sickle cell anaemia (SS) is a homozygous state of HbS in the red cells in which an abnormal gene is inherited from each parent. SS is a severe

disorder associated with protean clinical manifestations and decreased life expectancy.

PATHOGENESIS. Following abnormalities are observed (**Web Image 12.28**):

1. Basic molecular lesion: In HbS, basic genetic defect is the *single point mutation* in one amino acid out of 146 in haemoglobin molecule— there is *substitution of valine for glutamic acid* at 6-residue position of the β -globin, producing Hb $\alpha_2\beta_2^S$.

2. Mechanism of sickling: During deoxygenation, the red cells containing HbS change from biconcave disc shape to an elongated crescent-shaped or sickle-shaped cell. This process termed *sickling* occurs both within the intact red cells and *in vitro* in free solution. The mechanism responsible for sickling upon deoxygenation of HbS-containing red cells is the polymerisation of deoxygenated HbS which aggregates to form elongated rod-like polymers. These elongated fibres align and distort the red cell into classic sickle shape.

3. Reversible-irreversible sickling: The oxygen-dependent sickling process is usually reversible. However, damage to red cell membrane leads to formation of irreversibly sickled red cells even after they are exposed to normal oxygen tension.

4. Factors determining rate of sickling: Following factors determine the rate at which the polymerisation of HbS and consequent sickling take place:

- i) *Presence of non-HbS haemoglobins.*
- ii) *Intracellular concentration of HbS.*
- iii) *Total haemoglobin concentration.*
- iv) *Extent of deoxygenation.*
- v) *Acidosis and dehydration.*
- vi) *Increased concentration of 2, 3-BPG in the red cells.*

CLINICAL FEATURES. The clinical manifestations of homozygous sickle cell disease are widespread. The symptoms begin to appear after 6th month of life when most of the HbF is replaced by HbS.

1. Anaemia. There is usually severe chronic haemolytic anaemia (primarily extravascular) with onset of aplastic crisis in between.

2. Vaso-occlusive phenomena. Patients of SS develop recurrent vaso-occlusive episodes throughout their lives due to obstruction to capillary blood flow by sickled red cells upon deoxygenation or dehydration. Vaso-obstruction affecting different organs and tissues results in infarcts which may be of 2 types:

- i) *Microinfarcts* affecting particularly the abdomen, chest, back and joints and are the cause of recurrent painful crises in SS.
- ii) *Macroinfarcts* involving most commonly the spleen (splenic sequestration, autosplenectomy), bone marrow (pains), bones (aseptic necrosis, osteomyelitis), lungs (pulmonary infections), kidneys (renal cortical necrosis), CNS (stroke), retina (damage) and skin (ulcers), and result in anatomic and functional damage to these organs.

3. Constitutional symptoms. In addition to the features of anaemia and infarction, patients with SS have impaired growth and development and increased susceptibility to infection due to markedly impaired splenic function.

LABORATORY FINDINGS. The diagnosis of SS is considered high in blacks with haemolytic anaemia (**Web Image 12.29**):

1. Moderate to severe anaemia (haemoglobin concentration 6-9 g/dl).
2. The blood film shows sickle cells and target cells and features of splenic atrophy such as presence of Howell-Jolly bodies.
3. A positive sickling test with a reducing substance such as sodium metabisulfite.
4. Haemoglobin electrophoresis shows no normal HbA but shows predominance of HbS and 2-20% HbF.

256 Double Heterozygous States

Double heterozygous conditions involving combination of HbS with other haemoglobinopathies may occur. Most common among these are sickle- β -thalassaemia ($\beta^S\beta^{\text{thal}}$), sickle C disease (SC), and sickle D disease (SD). All these disorders behave like mild form of sickle cell disease.

□ OTHER STRUCTURAL HAEMOGLOBINOPATHIES (p. 319)

Besides sickle haemoglobin, about 400 structurally different abnormal human haemoglobins have been discovered in different parts of the world. Some of them are associated with clinical manifestations.

HbC Haemoglobinopathy

HbC haemoglobinopathy is prevalent in West Africa and in American blacks. The molecular lesion in HbC is substitution of lysine for glutamic acid at β -6 globin chain position.

HbD Haemoglobinopathy

HbD occurs in North-West India, Pakistan and Iran. About 3% of Sikhs living in Punjab are affected with HbD haemoglobinopathy (called *HbD Punjab*, also known as *Hb-Los Angeles*). HbD Punjab arises from the substitution of glutamine for glutamic acid at β -121 globin chain position.

HbE Haemoglobinopathy

HbE is predominantly found in South-East Asia, India, Burma and Sri Lanka. HbE arises from the substitution of lysine for glutamic acid at β -26 globin chain position.

Haemoglobin O-Arab Disease

Hb O-Arab disease was first identified in an Arab family but has now been detected in American blacks too.

Unstable-Hb Haemoglobinopathy

The unstable haemoglobins are those haemoglobin variants which undergo denaturation and precipitation within the red cells as Heinz bodies. These give rise to what is known as *congenital non-spherocytic haemolytic anaemia* or *congenital Heinz body haemolytic anaemia*. These disorders have either autosomal dominant inheritance or develop from spontaneous mutations. The unstable haemoglobins arise from either a single amino acid substitution in the globin chain or due to deletion of one or more amino acids within the β -globin chain.

Over 100 unstable haemoglobins have been described.

THALASSAEMIAS (p. 320)

DEFINITION

The thalassaemias are a diverse group of hereditary disorders in which there is reduced synthesis of one or more of the globin polypeptide chains. Thus, thalassaemias, unlike haemoglobinopathies which are qualitative disorders of haemoglobin, are *quantitative abnormalities of polypeptide globin chain synthesis*. Thalassaemias were first described in people of Mediterranean countries (North Africa, Southern Europe) from where it derives its name 'Mediterranean anaemia.'

GENETICS AND CLASSIFICATION

Thalassaemias are genetically transmitted disorders. Normally, an individual inherits two β -globin genes located one each on two chromosomes 11, and

two α -globin genes one each on two chromosomes 16, from each parent i.e. normal adult haemoglobin (HbA) is $\alpha_2\beta_2^*$. Depending upon whether the genetic defect or deletion lies in transmission of α - or β -globin chain genes, thalassaemias are classified into α - and β -thalassaemias. Thus, patients with α -thalassaemia have structurally normal α -globin chains but their production is impaired. Similarly, in β -thalassaemia, β -globin chains are structurally normal but their production is decreased. Each of the two main types of thalassaemias may occur as heterozygous (called α - and β -thalassaemia minor or trait), or as homozygous state (termed α - and β -thalassaemia major). The former is generally asymptomatic, while the latter is a severe congenital haemolytic anaemia.

A classification of various types of thalassaemias along with the clinical syndromes produced and salient laboratory findings are given in **Web Table 12.12**.

PATHOPHYSIOLOGY OF ANAEMIA IN THALASSAEMIA

α -Thalassaemia: In α -thalassaemia major, the obvious cause of anaemia is the inability to synthesise adult haemoglobin, while in α -thalassaemia trait there is reduced production of normal adult haemoglobin.

β -Thalassaemia: In β -thalassaemia major, the most important cause of anaemia is premature red cell destruction brought about by erythrocyte membrane damage caused by the precipitated α -globin chains. Other contributory factors are: shortened red cell lifespan, ineffective erythropoiesis, and haemodilution due to increased plasma volume. A deficiency of β -globin chains in β -thalassaemia leads to large excess of α -chains within the developing red cells. Part of these excessive α -chains are removed by pairing with γ -globin chains as HbF, while the remainder unaccompanied α -chains precipitate rapidly within the red cell as *Heinz bodies*. The precipitated α -chains cause red cell membrane damage.

α -THALASSAEMIA (p. 321)

MOLECULAR PATHOGENESIS. α -thalassaemias are disorders in which there is defective synthesis of α -globin chains resulting in depressed production of haemoglobins that contain α -chains i.e. HbA, HbA₂ and HbF. The α -thalassaemias are most commonly due to deletion of one or more of the α -chain genes located on short arm of chromosome 16.

1. Four α -gene deletion: Hb Bart's hydrops foetalis.
2. Three α -gene deletion: HbH disease.
3. Two α -gene deletion: α -thalassaemia trait.
4. One α -gene deletion: α -thalassaemia trait (carrier).

***Hb Bart's Hydrops Foetalis* (p. 321)**

When there is deletion of all the four α -chain genes (homozygous state) it results in total suppression of α -globin chain synthesis causing the most severe form of α -thalassaemia called Hb Bart's hydrops foetalis. Hb Bart's is a gamma globin chain tetramer (γ_4) which has high oxygen affinity leading to severe tissue hypoxia.

CLINICAL FEATURES. Hb Bart's hydrops foetalis is incompatible with life due to severe tissue hypoxia. The condition is either fatal *in utero* or the infant dies shortly after birth. If born alive, the features similar to severe Rh haemolytic disease are present.

LABORATORY FINDINGS. Infants with Hb Bart's hydrops foetalis born alive may have the following laboratory findings:

*In a normal adult, distribution of haemoglobin is as under: HbA ($\alpha_2\beta_2$) = 95-98%, HbA₂ ($\alpha_2\delta_2$) (a minor variant of HbA) = 1.5-3.5%, HbF ($\alpha_2\gamma_2$) = less than 1%. But the level of HbF in children under 6 months is slightly higher.

1. Severe anaemia (haemoglobin below 6g/dl).
2. Blood film show marked anisopoikilocytosis, hypochromia, microcytosis, polychromasia, basophilic stippling, numerous normoblasts and target cells.
3. Reticulocyte count is high.
4. Serum bilirubin level is elevated.
5. Haemoglobin electrophoresis shows 80-90% Hb-Bart's and a small amount of Hb-H and Hb-Portland but no HbA, HbA₂ or HbF.

HbH Disease (p. 321)

Deletion of three α -chain genes produces HbH which is a β -globin chain tetramer (β_4) and markedly impaired α -chain synthesis. HbH is precipitated as Heinz bodies within the affected red cells. An elongated α -chain variant of HbH disease is termed *Hb Constant Spring*.

CLINICAL FEATURES. HbH disease is generally present as a well-compensated haemolytic anaemia. The features are intermediate between that of β -thalassaemia minor and major.

LABORATORY FINDINGS. These are:

1. Moderate anaemia (haemoglobin 8-9 g/dl).
2. Blood film shows severe microcytosis, hypochromia, basophilic stippling, target cells and normoblasts.
3. Mild reticulocytosis.
4. HbH inclusions as Heinz bodies can be demonstrated in mature red cells with brilliant cresyl blue stain.
5. Haemoglobin electrophoresis shows 2-4% HbH and the remainder consists of HbA, HbA₂ and HbF.

α -Thalassaemia Trait

α -thalassaemia trait may occur by the following molecular pathogenesis:

● By deletion of two of the four α -chain genes in homozygous form called *homozygous α -thalassaemia*, or in double heterozygous form termed *heterozygous α -thalassaemia*.

By deletion of a single α -chain gene causing heterozygous α thalassaemia trait called *heterozygous α -thalassaemia*.

CLINICAL FEATURES. α -thalassaemia trait due to two α -chain gene deletion is asymptomatic. It is suspected in a patient of refractory microcytic hypochromic anaemia in whom iron deficiency and β -thalassaemia minor have been excluded and the patient belongs to the high-risk ethnic group.

LABORATORY FINDINGS. These are:

1. Haemoglobin level normal or mildly reduced.
2. Blood film shows microcytic and hypochromic red cell morphology but no evidence of haemolysis or anaemia.
3. MCV, MCH and MCHC may be slightly reduced.
4. Haemoglobin electrophoresis reveals small amount of Hb-Bart's in neonatal period (1-2% in α -thalassaemia 2 and 5-6% in α -thalassaemia 1) which gradually disappears by adult life. HbA₂ is either normal or slightly decreased (contrary to the elevated HbA₂ levels in β -thalassaemia trait).

β -THALASSAEMIAS (p. 322)

MOLECULAR PATHOGENESIS. β -thalassaemias are caused by decreased rate of β -chain synthesis resulting in reduced formation of HbA in the red cells. The molecular pathogenesis of the β -thalassaemias is more complex than that of α -thalassaemias. In contrast to α -thalassaemia, gene deletion rarely ever causes β -thalassaemia and is only seen in an entity called *hereditary persistence of foetal haemoglobin (HPFH)*. Instead, most of β -thalassaemias arise from different types of mutations of β -globin gene resulting from single base changes. The symbol β° is used to indicate the

complete absence of β -globin chain synthesis while β^+ denotes partial synthesis of the β -globin chains. Some of the important ones having effects on β -globin chain synthesis are as under (**Web Image 12.30**):

- i) *Transcription defect*
- ii) *Translation defect*
- iii) *mRNA splicing defect.*

Depending upon the extent of reduction in β -chain synthesis, there are 3 types of β -thalassaemia:

1. Homozygous form: β -Thalassaemia major. It is the most severe form of congenital haemolytic anaemia. It is further of 2 types (**Web Image 12.31**):

- i) β^0 *thalassaemia major* characterised by complete absence of β -chain synthesis.
- ii) β^+ *thalassaemia major* having incomplete suppression of β -chain synthesis.

2. β -Thalassaemia intermedia: It is β -thalassaemia of intermediate degree of severity that does not require regular blood transfusions. These cases are genetically heterozygous (β^0/β or β^+/β).

3. Heterozygous form: β -Thalassaemia minor (trait). It is a mild asymptomatic condition in which there is moderate suppression of β -chain synthesis.

Besides β -thalassaemia minor, a few uncommon globin chain combinations resulting in β -thalassaemia trait are as under:

- i) $\delta\beta$ -*thalassaemia minor* in which there is total absence of both β and δ chain synthesis and is characterised by elevated HbF level but unlike β -thalassaemia minor there is normal or reduced HbA₂ level.
- ii) *Hb Lepore syndrome* characterised by nonhomologous fusion of β - and δ -genes forming an abnormal haemoglobin called Hb Lepore (named after a family called Lepore). There is total absence of normal β -chain synthesis.

An individual may inherit one β -chain gene from each parent and produce heterozygous, homozygous, or double heterozygous states. Statistically, 25% of offsprings born to two heterozygotes (i.e. β -thalassaemia trait) will have the homozygous state i.e. β -thalassaemia major.

β -Thalassaemia Major (p. 323)

β -thalassaemia major, also termed Mediterranean or Cooley's anaemia is the most common form of congenital haemolytic anaemia. β -thalassaemia major is a homozygous state with either complete absence of β -chain synthesis (β^0 *thalassaemia major*) or only small amounts of β -chains are formed (β^+ *thalassaemia major*). These result in excessive formation of alternate haemoglobins, HbF ($\alpha_2\gamma_2$) and HbA₂ ($\alpha_2\delta_2$).

CLINICAL FEATURES. Clinical manifestations appear insidiously (**Web Image 12.32**):

1. Anaemia starts appearing within the first 4-6 months of life when the switch over from γ -chain to β -chain production occurs.
2. Marked hepatosplenomegaly occurs due to excessive red cell destruction, extramedullary haematopoiesis and iron overload.
3. Expansion of bones occurs due to marked erythroid hyperplasia leading to thalassaemic facies and malocclusion of the jaw.
4. Iron overload due to repeated blood transfusions causes damage to the endocrine organs resulting in slow rate of growth and development, delayed puberty, diabetes mellitus and damage to the liver and heart.

LABORATORY FINDINGS. These are:

1. *Anaemia*, usually severe.
2. *Blood film* shows severe microcytic hypochromic red cell morphology, marked anisopoikilocytosis, basophilic stippling, presence of many target cells, tear drop cells and normoblasts (**Web Image 12.33**).
3. *Serum bilirubin* (unconjugated) is generally raised.

4. *Reticulocytosis* is generally present.
5. *MCV, MCH and MCHC* are significantly reduced.
6. *WBC count* is often raised with some shift to left of the neutrophil series, with presence of some myelocytes and metamyelocytes.
7. *Platelet count* is usually normal but may be reduced in patients with massive splenomegaly.
8. Osmotic fragility characteristically reveals increased resistance to saline haemolysis i.e. *decreased osmotic fragility (Web Image 12.34)*.
9. *Haemoglobin electrophoresis* shows presence of increased amounts of HbF, increased amount of HbA₂, and almost complete absence or presence of variable amounts of HbA. The increased level of HbA₂ has not been found in any other haemoglobin abnormality except β -thalassaemia.
10. *Bone marrow aspirate examination* shows normoblastic erythroid hyperplasia with predominance of intermediate and late normoblasts which are generally smaller in size than normal. Iron staining demonstrates siderotic granules in the cytoplasm of normoblasts, increased reticuloendothelial iron but ring sideroblasts are only occasionally seen.

Treatment (p. 324)

1. Anaemia is generally severe and patients require regular blood transfusions (4-6 weekly) to maintain haemoglobin above 8 g/dl.
2. In order to maintain increased demand of hyperplastic marrow, folic acid supplement is given.
3. Splenectomy is beneficial in children over 6 years of age since splenic sequestration contributes to shortened red cell lifespan.
4. Prevention and treatment of iron overload is done by chelation therapy (desferrioxamine). Oral chelation with kelfer or deferiprone is also available now.
5. Bone marrow transplantation from HLA-matched donor that provides stem cells which can form normal haemoglobin is being done in many centres with fair success rate, especially when done at an early stage before end-organ damage has supervened..
6. Some workers have found success with cord blood transfusion.
7. Gene therapy of thalassaemia involving genetic manipulation in haematopoietic stem cells may become an option for future.

Since these patients require multiple blood transfusions, they are at increased risk of developing AIDS. In general, patients with β -thalassaemia major have short life expectancy. The biggest problem is iron overload and consequent myocardial siderosis leading to cardiac arrhythmias, congestive heart failure, and ultimately death.

β -Thalassaemia Minor (p. 324)

The β -thalassaemia minor or β -thalassaemia trait, a heterozygous state, is a common entity characterised by moderate reduction in β -chain synthesis.

CLINICAL FEATURES. Clinically, the condition is usually asymptomatic and the diagnosis is generally made when the patient is being investigated for mild chronic anaemia. The spleen may be palpable.

LABORATORY FINDINGS. These are:

1. *Mild anaemia*; mean haemoglobin level is about 15% lower than in normal person for the age and sex.
2. *Blood film* shows mild anisopoikilocytosis, microcytosis and hypochromia, occasional target cells and basophilic stippling.
3. *Serum bilirubin* may be normal or slightly raised.
4. *Mild reticulocytosis* is often present.
5. *MCV, MCH and MCHC* may be slightly reduced.
6. Osmotic fragility test shows increased resistance to haemolysis i.e. *decreased osmotic fragility*.

7. *Haemoglobin electrophoresis* is confirmatory for the diagnosis and shows about two-fold increase in HbA₂ and a slight elevation in HbF (2-3%).

Treatment (p. 324)

Patients with β -thalassaemia minor do not require any treatment. But they should be explained about the genetic implications of the disorder, particularly to those of child-bearing age.

□ APLASTIC ANAEMIA AND OTHER PRIMARY BONE MARROW DISORDERS (p. 324)

'Bone marrow failure' is the term used for primary disorders of the bone marrow which result in impaired formation of the erythropoietic precursors and consequent anaemia. It includes the following disorders:

1. *Aplastic anaemia*, most importantly.
2. *Other primary bone marrow disorders* such as: myelophthisic anaemia, pure red cell aplasia, and myelodysplastic syndromes.

APLASTIC ANAEMIA (p. 325)

Aplastic anaemia is defined as pancytopenia (i.e. simultaneous presence of anaemia, leucopenia and thrombocytopenia) resulting from aplasia of the bone marrow. The underlying defect in all cases appears to be sufficient reduction in the number of haematopoietic pluripotent stem cells which results in decreased or total absence of these cells for division and differentiation.

ETIOLOGY AND CLASSIFICATION. Based on the etiology, aplastic anaemia is classified into 2 main types: primary and secondary. Various causes that may give rise to both these types of aplastic anaemia are summarised in **Web Table 12.13**:

A. Primary aplastic anaemia. Primary aplastic anaemia includes 2 entities: a congenital form called Fanconi's anaemia and an immunologically-mediated acquired form.

B. Secondary aplastic anaemia. Aplastic anaemia may occur secondary to a variety of industrial, physical, chemical, iatrogenic and infectious causes:

CLINICAL FEATURES. The onset of aplastic anaemia may occur at any age and is usually insidious.

1. Anaemia and its symptoms like mild progressive weakness and fatigue.
2. Haemorrhage from various sites due to thrombocytopenia such as from the skin, nose, gums, vagina, bowel, and occasionally in the CNS and retina.
3. Infections of the mouth and throat are commonly present.
4. The lymph nodes, liver and spleen are generally not enlarged.

LABORATORY FINDINGS. The diagnosis of aplastic anaemia is made by a thorough laboratory evaluation and excluding other causes of pancytopenia (**Web Table 12.14**).

1. Anaemia. Haemoglobin levels are moderately reduced. The blood picture generally shows normocytic normochromic anaemia but sometimes macrocytosis may be present. The reticulocyte count is reduced or zero.

2. Leucopenia. The absolute granulocyte count is particularly low (below 1500/ μ l) with relative lymphocytosis. The neutrophils are morphologically normal but their alkaline phosphatase score is high.

3. Thrombocytopenia. Platelet count is always reduced.

4. Bone marrow examination. A bone marrow aspirate may yield a 'dry tap'. A trephine biopsy is generally essential for making the diagnosis which reveals patchy cellular areas in a hypocellular or aplastic marrow due to replacement by fat. There is usually a severe depression of myeloid cells,

262 megakaryocytes and erythroid cells so that the marrow chiefly consists of lymphocytes and plasma cells (**Web Image 12.35**).

TREATMENT. The patients of mild aplasia may show spontaneous recovery, while the management of severe aplastic anaemia is a most challenging task.

A. General management: It consists of the following:

1. Identification and elimination of the possible cause.
2. Supportive care consisting of blood transfusions, platelet concentrates, and treatment and prevention of infections.

B. Specific treatment: The specific treatment has been attempted with varying success and includes the following:

1. Marrow stimulating agents
2. Immunosuppressive therapy
3. Bone marrow transplantation.

MYELOPHTHISIC ANAEMIA (p. 326)

Development of severe anaemia may result from infiltration of the marrow termed as myelophthistic anaemia. The causes for marrow infiltrations include the following (**Web Table 12.14**):

- ◆ Haematologic malignancies (e.g. leukaemia, lymphoma, myeloma).
- ◆ Metastatic deposits from non-haematologic malignancies (e.g. cancer breast, stomach, prostate, lung, thyroid).
- ◆ Advanced tuberculosis.
- ◆ Primary lipid storage diseases (Gaucher's and Niemann-Pick's disease).
- ◆ Osteopetrosis and myelofibrosis may rarely cause myelophthisis.

The type of anaemia in myelophthisis is generally normocytic normochromic with some fragmented red cells, basophilic stippling and normoblasts in the peripheral blood. Thrombocytopenia is usually present but the leucocyte count is increased with slight shift-to-left of myeloid cells i.e. a picture of *leucoerythroblastic reaction* consisting of immature myeloid cells and normoblasts is seen in the peripheral blood.

PURE RED CELL APLASIA (p. 326)

Pure red cell aplasia (PRCA) is a rare syndrome involving a selective failure in the production of erythroid elements in the bone marrow but with normal granulopoiesis and megakaryocytopoiesis. Patients have normocytic normochromic anaemia with normal granulocyte and platelet count. Reticulocytes are markedly decreased or are absent.

PRCA exists in the following forms:

- ◆ *Transient self-limited PRCA:* It is due to temporary marrow failure in aplastic crisis in haemolytic anemias and in acute B19 parvovirus infection and in transient erythroblastopenia in normal children.
- ◆ *Acquired PRCA:* It is seen in middle-aged adults in association with some other diseases, most commonly thymoma; others are connective tissue diseases (SLE, rheumatoid arthritis), lymphoid malignancies (lymphoma, T-cell chronic lymphocytic leukaemia) and solid tumours.
- ◆ *Chronic B19 parvovirus infections:* PRCA may occur from chronic B19 parvovirus infection in children and is common and treatable. B19 parvovirus produces cytopathic effects on the marrow erythroid precursor cells and are characteristically seen as giant pronormoblasts.
- ◆ *Congenital PRCA (Blackfan-Diamond syndrome)* is a rare chronic disorder detected at birth or in early childhood. It occurs due to mutation in a ribosomal RNA processing gene termed as *RPS19*.

1. During foetal life, haematopoiesis commences in the bone marrow by:

A. 2nd to 3rd month	B. 4th to 5th month
C. 6th to 7th month	D. 7th to 8th month
2. Bone marrow trephine biopsy has advantage over aspiration since:

A. The former method is less time-consuming	B. Romanowsky stains can be done in the former
C. Architectural pattern of marrow is better in the former	D. Cell morphology is better appreciated in the former
3. Erythroid cells continue to proliferate up to the stage of:

A. Reticulocytes	B. Late normoblasts
C. Intermediate normoblasts	D. Early normoblasts
4. Weight of haemoglobin in RBC is:

A. 50%	B. 70%
C. 90%	D. 99%
5. Red cell membrane defects include the following *except*:

A. Spherocytosis	B. Ovalocytosis
C. Leptocytosis	D. Echinocytosis
6. The following factors determine the release of oxygen from haemoglobin in tissue capillaries *except*:

A. Nature of globin chains in Hb	B. Bicarbonate ions in blood
C. pH of blood	D. Concentration of 2,3-BPG
7. Absorption of iron is enhanced by the following *except*:

A. Ascorbic acid	B. Citric acid
C. Tannates	D. Sugars
8. In iron deficiency anaemia, TIBC is:

A. Low	B. Normal
C. High	D. Borderline
9. Pappenheimer bodies are found in:

A. Sideroblasts	B. Siderocytes
C. Late normoblasts	D. Intermediate normoblasts
10. In anaemia of chronic disorders, serum ferritin is:

A. Normal	B. Low
C. Increased	D. Absent
11. Folate circulates in plasma as:

A. Methyl tetrahydrofolate	B. Polyglutamate
C. Monoglutamate	D. Diglutamate
12. Measurement of formiminoglutamic acid (FIGLU) for folate deficiency is done in:

A. Whole blood	B. Serum
C. Plasma	D. Urine
13. Pernicious anaemia causes pathologic changes in the anatomic region of stomach as under *except*:

A. Antrum	B. Body
C. Body-fundic area	D. Fundus
14. In warm antibody autoimmune haemolytic anaemias, the antibody is commonly:

A. IgA	B. IgG
C. IgM	D. IgD

15. Cold agglutinin antibody in autoimmune haemolytic anaemia affects:
- | | |
|------------------------|-----------------------|
| A. Mature erythrocytes | B. Reticulocytes |
| C. Siderocytes | D. Late erythroblasts |
16. In paroxysmal nocturnal haemoglobinuria (PNH), the undue sensitivity of red cells to complement can be detected by:
- | | |
|------------------------|--------------------------|
| A. Ham's test | B. Heinz body test |
| C. Direct Coombs' test | D. Indirect Coombs' test |
17. In hereditary spherocytosis, the following membrane structure is deficient:
- | | |
|-------------------|----------------|
| A. Band 3 protein | B. Glycophorin |
| C. Spectrin | D. Glycolipid |
18. G6PD deficiency has the following genetic basis of inheritance:
- | | |
|-----------------------|--------------------------|
| A. Autosomal dominant | B. Autosomal recessive |
| C. Sex-linked trait | D. Sex-linked homozygous |
19. The rate of sickling in sickle cell anaemia is directly correlated with the following factors *except*:
- | |
|--------------------------------|
| A. Higher concentration of HbS |
| B. Lower concentration of HbA |
| C. Higher concentration of HbF |
| D. Higher deoxygenation |
20. Molecular pathogenesis of α -thalassaemia involves:
- | |
|--|
| A. Mutation in transcription promoter sequence |
| B. Gene deletion |
| C. Codon termination mutation |
| D. mRNA splicing defect |
21. The pathognomonic abnormality in β -thalassaemia minor is:
- | |
|--|
| A. Marked rise in HbA ₂ |
| B. Marked rise in HbF |
| C. Marked unconjugated hyperbilirubinaemia |
| D. Marked anaemia |
22. In aplastic anaemia, there is generally:
- | |
|------------------------------|
| A. Relative neutrophilia |
| B. Relative lymphocytosis |
| C. Microcytosis |
| D. Reticulocyte count normal |
23. Erythropoietin is produced by:
- | | |
|----------------|-----------|
| A. Liver | B. Lungs |
| C. Bone marrow | D. Kidney |
24. Pappenheimer bodies represent:
- | | |
|------------------|-----------------|
| A. DNA | B. RNA |
| C. Non-haem iron | D. Mitochondria |
25. In Schilling's test 'hot' B₁₂ is given:
- | | |
|------------------|-----------------|
| A. Intramuscular | B. Subcutaneous |
| C. Intravenous | D. Oral |
26. All are major criteria for diagnosis of pernicious anaemia *except*:
- | |
|-----------------------------------|
| A. Low serum B ₁₂ |
| B. Megaloblastic anaemia |
| C. IF antibody |
| D. Gastric parietal cell antibody |
27. Antibody in paroxysmal cold haemoglobinuria is against:
- | | |
|--------------------------|---------------------------|
| A. P blood group antigen | B. I blood group antigen |
| C. A blood group antigen | D. Rh blood group antigen |
28. Which of the following G6PD variant provides protection against malaria?
- | | |
|-------------|-----------------------|
| A. Type B | B. Type A+ |
| C. Type A - | D. G6PD Mediterranean |

29. Which of the following is *not* microangiopathic haemolytic anaemia? 265
- A. March haemoglobinuria
 - B. TTP
 - C. HUS
 - D. Lead poisoning
30. Precipitated gamma chains are known as:
- A. Heinz bodies
 - B. Pappenheimer bodies
 - C. Hb Barts
 - D. Russel Bodies

KEY

1 = B	2 = C	3 = C	4 = C
5 = C	6 = B	7 = C	8 = C
9 = B	10 = C	11 = A	12 = D
13 = A	14 = B	15 = B	16 = A
17 = C	18 = C	19 = C	20 = B
21 = A	22 = B	23 = D	24 = C
25 = D	26 = D	27 = A	28 = C
29 = D	30 = A		



Disorders of Platelets, Bleeding Disorders and Basic Transfusion Medicine

Platelets are formed in the bone marrow by a process of fragmentation of the cytoplasm of megakaryocytes. Platelet production is under the control of thrombopoietin, the nature and origin of which are not yet established. The stages in platelet production are: megakaryoblast, promegakaryocyte, megakaryocyte, and discoid platelets (*Web Image 13.1*).

PLATELETS. Platelets are small (1-4 μm in diameter), discoid, non-nucleate structures containing red-purple granules. The normal platelet count ranges from 150,000-400,000/ μl and the lifespan of platelets is 7-10 days. About 70% of platelets are in circulation while remaining 30% lie sequestered in the spleen. Newly-formed platelets spend 24-36 hours in the spleen before being released into circulation but splenic stasis does not cause any injury to the platelets normally.

The main *functions* of platelets is in haemostasis which includes two closely linked processes:

1. Primary haemostasis. This term is used for platelet plug formation at the site of injury. It is an immediate phenomenon appearing within seconds of injury and is responsible for cessation of bleeding from microvasculature. Primary haemostasis involves three steps: platelet adhesion, platelet granule release and platelet aggregation which are regulated by changes in membrane phospholipids, and calcium (*Web Image 13.2*). At molecular level, these important events are depicted diagrammatically in *Web Image 13.3* and briefly outlined below:

- ◆ *Platelet adhesion:* Platelets adhere to collagen in the subendothelium due to presence of receptor on platelet surface, glycoprotein (Gp) Ia-IIa which is an integrin.

- ◆ *Platelet release:* After adhesion, platelets become activated and release three types of granules from their cytoplasm: dense granules, α -granules and lysosomal vesicles. Important products released from these granules are: ADP, ATP, calcium, serotonin, platelet factor 4, factor V, factor VIII, thrombospondin, platelet-derived growth factor (PDGF), von Willebrand factor (vWF), fibronectin, fibrinogen, plasminogen activator inhibitor -1 (PAI-1) and thromboxane A₂.

- ◆ *Platelet aggregation:* This process is mediated by fibrinogen which forms bridge between adjacent platelets via glycoprotein receptors on platelets, GpIIb-IIIa.

2. Secondary haemostasis. This involves plasma coagulation system resulting in fibrin plug formation and takes several minutes for completion.

BLEEDING DISORDERS (HAEMORRHAGIC DIATHESIS) (p. 328)

Bleeding disorders or haemorrhagic diatheses are a group of disorders characterised by defective haemostasis with abnormal bleeding.

The causes of haemorrhagic diatheses may or may not be related to platelet abnormalities. These causes are broadly divided into the following groups:

- I. Haemorrhagic diathesis due to vascular abnormalities.
- II. Haemorrhagic diathesis related to platelet abnormalities.
- III. Disorders of coagulation factors.
- IV. Haemorrhagic diathesis due to fibrinolytic defects.
- V. Combination of all these as occurs in disseminated intravascular coagulation (DIC).

□ INVESTIGATIONS OF HAEMOSTATIC FUNCTION (p. 328)

In general, the haemostatic mechanisms have 2 primary functions:

- ◆ To promote *local haemostasis* at the site of injured blood vessel.
- ◆ To ensure that the circulating blood remains in *fluid state* while in the vascular bed i.e. to prevent the occurrence of generalised thrombosis.

Formation of haemostatic plug is a complex mechanism and involves maintenance of a delicate balance among at least 5 components (**Web Image 13.4**): (i) blood vessel wall; (ii) platelets; (iii) plasma coagulation factors; (iv) inhibitors; and (v) fibrinolytic system.

Anything that interferes with any of these components results in defective haemostasis with abnormal bleeding.

A brief review of general principles of tests used to investigate haemostatic abnormalities is presented below and summarised in **Web Table 13.1**.

A. INVESTIGATION OF DISORDERED VASCULAR HAEMOSTASIS (p. 328)

1. BLEEDING TIME. This simple test is based on the principle of formation of haemostatic plug following a standard incision on the volar surface of the forearm and the time the incision takes to stop bleeding is measured. The test is dependent upon capillary function as well as on platelet number and ability of platelets to adhere to form aggregates. Normal range is 3-8 minutes. A prolonged bleeding time may be due to following causes:

- i) Thrombocytopenia.
- ii) Disorders of platelet function.
- iii) von Willebrand's disease.
- iv) Vascular abnormalities (e.g. in Ehlers-Danlos syndrome).
- v) Severe deficiency of factor V and XI.

2. HESS CAPILLARY RESISTANCE TEST (TOURNIQUET TEST). This test is done by tying sphygmomanometer cuff to the upper arm and raising the pressure in it between diastolic and systolic for 5 minutes. After deflation, the number of petechiae appearing in the next 5 minutes in 3 cm² area over the cubital fossa are counted. Presence of more than 20 petechiae is considered a positive test. The test is positive in increased capillary fragility as well as in thrombocytopenia.

B. INVESTIGATION OF PLATELETS AND PLATELET FUNCTION (p. 329)

1. SCREENING TESTS. The screening tests carried out for assessing platelet-related causes are:

- i) Peripheral blood platelet count.
- ii) Skin bleeding time.
- iii) Examination of fresh blood film to see the morphologic abnormalities of platelets.

2. SPECIAL TESTS. If these screening tests suggest a disorder of platelet function, the following platelet function tests may be carried out:

- i) *Platelet adhesion tests.*
- ii) *Aggregation tests.*
- iii) *Granular content.*
- iv) *Platelet coagulant activity.*

268 C. INVESTIGATION OF BLOOD COAGULATION (p. 329)

The normal blood coagulation system consists of cascade of activation of 13 coagulation factors. These form intrinsic, extrinsic and common pathways which culminate in formation of thrombin that acts on fibrinogen to produce fibrin. Fibrin clot so formed is strengthened by factor XIII which itself gets activated by thrombin. The process of fibrinolysis or clot dissolution and the role of platelets in activation of cascade and formation of haemostatic plug are illustrated in **Web Image 13.5**.

1. SCREENING TESTS. These are as under:

I. Whole blood coagulation time. The estimation of whole blood coagulation time done by various capillary and tube methods is of limited value since it is an insensitive and nonspecific test. Normal range is 4-9 minutes at 37°C.

II. Activated partial thromboplastin time (APTT) or partial thromboplastin time with kaolin (PTTK). This test is used to measure the intrinsic system factors (VIII, IX, XI and XII) as well as factors common to both intrinsic and extrinsic systems (factors X, V, prothrombin and fibrinogen). The normal range is 30-40 seconds. The common causes of a prolonged PTTK (or APTT) are:

- i) Parenteral administration of heparin.
- ii) Disseminated intravascular coagulation.
- iii) Liver disease.
- iv) Circulating anticoagulants.

III. One-stage prothrombin time (PT). PT measures the extrinsic system factor VII as well as factors in the common pathway. The normal PT in this test is 10-14 seconds. The common causes of prolonged one-stage PT are:

- i) Administration of oral anticoagulant drugs.
- ii) Liver disease, especially obstructive liver disease.
- iii) Vitamin K deficiency.
- iv) Disseminated intravascular coagulation.

IV. Measurement of fibrinogen. The *screening tests* for fibrinogen deficiency are semiquantitative fibrinogen titre and thrombin time (TT). The normal value of thrombin time is under 20 seconds, while a fibrinogen titre in plasma dilution up to 32 is considered normal. Following are the common causes for higher values in both these tests:

- i) Hypofibrinogenaemia (e.g. in DIC).
- ii) Raised concentration of FDP.
- iii) Presence of heparin.

2. SPECIAL TESTS. These include the following:

i) Coagulation factor assays. These bioassays are based on results of PTTK or PT tests and employ the use of substrate plasma that contains all other coagulation factors except the one to be measured. The unknown level of the factor activity is compared with a standard control plasma with a known level of activity. Results are expressed as percentage of normal activity.

ii) Quantitative assays. The coagulation factors can be quantitatively assayed by immunological and other chemical methods.

D. INVESTIGATION OF FIBRINOLYTIC SYSTEM (p. 331)

Increased levels of circulating plasminogen activator are present in patients with hyperfibrinolysis. Following *screening tests* are done to assess these abnormalities in fibrinolytic system:

1. Estimation of fibrinogen.
2. Fibrin degradation products (FDP) in the serum.
3. Ethanol gelation test.
4. Euglobin or whole blood lysis time.

More *specific tests* include: functional assays, immunological assays by ELISA, and chromogenic assays of plasminogen activators, plasminogen, plasminogen activator inhibitor, and FDP.

Common specific haemorrhagic disorders are as under:

- I. Haemostatic diatheses due to vascular disorders.
- II. Haemostatic diatheses due to platelet disorders.
- III. Coagulation disorders.
- IV. Haemostatic diatheses due to fibrinolytic defects.
- V. Disseminated intravascular coagulation (DIC)

□ **HAEMORRHAGIC DIATHESSES DUE TO VASCULAR DISORDERS** (p. 331)

Vascular bleeding disorders, also called non-thrombocytopenic purpuras or vascular purpuras, are normally mild and characterised by petechiae, purpuras or ecchymoses confined to the skin and mucous membranes. The pathogenesis of bleeding is poorly understood since majority of the standard screening tests of haemostasis including the bleeding time, coagulation time, platelet count and platelet function, are usually normal. Vascular purpuras arise from damage to the capillary endothelium, abnormalities in the subendothelial matrix or extravascular connective tissue that supports the blood vessels, or from formation of abnormal blood vessels.

Vascular bleeding disorders may be *inherited* or *acquired*.

A. INHERITED VASCULAR BLEEDING DISORDERS (p. 331)

1. Hereditary haemorrhagic telangiectasia (Osler-Weber-Rendu disease).

2. Inherited disorders of connective tissue matrix. These include Marfan's syndrome, Ehlers-Danlos syndrome and pseudoxanthoma elasticum.

B. ACQUIRED VASCULAR BLEEDING DISORDERS (p. 331)

1. Henoch-Schönlein purpura.
2. Haemolytic-uraemic syndrome.
3. Simple easy bruising (Devil's pinches).
4. Infection.
5. Drug reactions.
6. Steroid purpura.
7. Senile purpura.
8. Scurvy.

□ **HAEMORRHAGIC DIATHESSES DUE TO PLATELET DISORDERS** (p. 331)

Disorders of platelets produce bleeding disorders by one of the following 3 mechanisms:

- A. *Due to reduction in the number of platelets* i.e. various forms of thrombocytopenias.
- B. *Due to rise in platelet count* i.e. thrombocytosis.
- C. *Due to defective platelet functions.*

A. THROMBOCYTOPENIAS (p. 332)

Thrombocytopenia is defined as a reduction in the peripheral blood platelet count below the lower limit of normal i.e. below 150,000/ μ l. Thrombocytopenia is associated with abnormal bleeding that includes spontaneous skin purpura and mucosal haemorrhages as well as prolonged bleeding after trauma. However, spontaneous haemorrhagic tendency becomes clinically evident only after severe depletion of the platelet count to level below 20,000/ μ l.

Thrombocytopenia may result from 4 main groups of causes:

1. Impaired platelet production.
2. Accelerated platelet destruction.
3. Splenic sequestration.
4. Dilutional loss.

A list of causes of thrombocytopenia is given in **Web Table 13.2**.

Drug-induced Thrombocytopenia (p. 332)

Many commonly used drugs cause thrombocytopenia by depressing megakaryocyte production. In most cases, an immune mechanism by formation of drug-antibody complexes is implicated in which the platelet is damaged as an 'innocent bystander'. Drug-induced thrombocytopenia is associated with many commonly used drugs and includes: chemotherapeutic agents (alkylating agents, anthracyclines, antimetabolites), certain antibiotics (sulfonamides, PAS, rifampicin, penicillins), drugs used in cardiovascular diseases (digitoxin, thiazide diuretics), diclofenac, acyclovir, heparin and excessive consumption of ethanol.

Heparin-induced Thrombocytopenia (p. 332)

Thrombocytopenia due to administration of heparin is distinct from that caused by other drugs in following ways:

- i) Thrombocytopenia is generally not so severe to fall to level below 20,000/ μ l.
- ii) Unlike drug-induced thrombocytopenia, heparin-induced thrombocytopenia is not associated with bleeding but instead these patients are more prone to develop thrombosis.

The underlying mechanism of heparin-induced thrombocytopenia is formation of antibody against platelet factor 4 (PF-4)-heparin complex.

Immune Thrombocytopenic Purpura (ITP) (p. 332)

Idiopathic thrombocytopenic purpura or immune thrombocytopenic purpura (ITP), is characterised by immunologic destruction of platelets and normal or increased megakaryocytes in the bone marrow.

PATHOGENESIS. On the basis of duration of illness, ITP is classified into acute and chronic forms, both of which have different pathogenesis.

Acute ITP. This is a self-limited disorder, seen most frequently in children following recovery from a viral illness (e.g. hepatitis C, infectious mononucleosis, CMV infection, HIV infection) or an upper respiratory illness. The onset of acute ITP is sudden and severe thrombocytopenia but recovery occurs within a few weeks to 6 months. The mechanism of acute ITP is by formation of *immune complexes* containing viral antigens, and by formation of *antibodies* against viral antigens which crossreact with platelets and lead to their immunologic destruction.

Chronic ITP. Chronic ITP occurs more commonly in adults, particularly in women of child-bearing age (20-40 years). The disorder develops insidiously and persists for several years. Though chronic ITP is idiopathic, similar immunologic thrombocytopenia may be seen in association with SLE, AIDS and autoimmune thyroiditis. The pathogenesis of chronic ITP is explained by formation of *anti-platelet autoantibodies*, usually by platelet-associated IgG humoral antibodies synthesised mainly in the spleen. These antibodies are directed against target antigens on the platelet glycoproteins, Gp IIb-IIIa and Gp Ib-IX complex.

CLINICAL FEATURES. The clinical manifestation of ITP may develop abruptly in cases of acute ITP, or the onset may be insidious as occurs in majority of cases of chronic ITP. The usual manifestations are petechial haemorrhages, easy bruising, and mucosal bleeding such as menorrhagia

in women, nasal bleeding, bleeding from gums, melaena and haematuria. Intracranial haemorrhage is, however, rare. Splenomegaly and hepatomegaly may occur in cases with chronic ITP but lymphadenopathy is quite uncommon in either type of ITP.

LABORATORY FINDINGS. The diagnosis of ITP can be suspected on clinical features after excluding the known causes of thrombocytopenia:

1. *Platelet count* is markedly reduced, usually in the range of 10,000-50,000/ μ l.
2. *Blood film* shows only occasional platelets which are often large in size (**Web Image 13.6,A**).
3. *Bone marrow* shows increased number of megakaryocytes which have large non-lobulated single nuclei and may have reduced cytoplasmic granularity and presence of vacuoles (**Web Image 13.6, B**).
4. With sensitive techniques, *anti-platelet IgG antibody* can be demonstrated on platelet surface or in the serum of patients.
5. *Platelet survival studies* reveal markedly reduced platelet lifespan, sometimes less than one hour, as compared with normal lifespan of 7-10 days.

Thrombotic Thrombocytopenic Purpura (TTP) and Haemolytic-Uraemic Syndrome (HUS) (p. 334)

Thrombotic thrombocytopenic purpura (TTP) and haemolytic-uraemic syndrome (HUS) are a group of thrombotic microangiopathies which are essentially characterised by triad of *thrombocytopenia, microangiopathic haemolytic anaemia and formation of hyaline fibrin microthrombi* within the microvasculature throughout the body. These are often fulminant and lethal disorders occurring in young adults. The intravascular microthrombi are composed predominantly of platelets and fibrin. The widespread presence of these platelet microthrombi is responsible for thrombocytopenia due to increased consumption of platelets, microangiopathic haemolytic anaemia and protean clinical manifestations involving different organs and tissues throughout the body.

PATHOGENESIS. TTP is initiated by endothelial injury followed by release of von Willebrand factor and other procoagulant material from endothelial cells, leading to the formation of microthrombi. Trigger for the endothelial injury comes from immunologic damage by diverse conditions such as in pregnancy, metastatic cancer, high-dose chemotherapy, HIV infection, and mitomycin C.

CLINICAL FEATURES. The clinical manifestations of TTP are due to microthrombi in the arterioles, capillaries and venules throughout the body.

LABORATORY FINDINGS. The diagnosis can be made from the following findings:

1. Thrombocytopenia.
2. Microangiopathic haemolytic anaemia with negative Coombs' test.
3. Leucocytosis, sometimes with leukaemoid reaction.
4. Bone marrow examination reveals normal or slightly increased megakaryocytes accompanied with some myeloid hyperplasia.
5. Diagnosis is, however, established by examination of biopsy (e.g. from gingiva) which demonstrates typical microthrombi in arterioles, capillaries and venules, unassociated with any inflammatory changes in the vessel wall.

B. THROMBOCYTOSIS (p. 334)

Thrombocytosis is defined as platelet count in excess of 4,00,000/ μ l. While essential or primary thrombocytosis or thrombocythaemia is discussed under myeloproliferative disorders in the next chapter, secondary or reactive

- 272 thrombocytosis can occur following massive haemorrhage, iron deficiency, severe sepsis, marked inflammation, disseminated cancers, haemolysis, or following splenectomy. Thrombocytosis causes bleeding or thrombosis but how it produces is not clearly known.

C. DISORDERS OF PLATELET FUNCTIONS (p. 334)

Hereditary Disorders (p. 334)

Depending upon the predominant functional abnormality, inherited disorders of platelet functions are classified into the following 3 groups:

1. DEFECTIVE PLATELET ADHESION. These are:

- i) *Bernard-Soulier syndrome* is an autosomal recessive disorder with inherited deficiency of a platelet membrane glycoprotein which is essential for adhesion of platelets to vessel wall.
- ii) In *von Willebrand's disease*, there is defective platelet adhesion as well as deficiency of factor VIII.

2. DEFECTIVE PLATELET AGGREGATION. In *thrombasthenia* (*Glanzmann's disease*), there is failure of primary platelet aggregation with ADP or collagen due to inherited deficiency of two of platelet membrane glycoproteins.

3. DISORDERS OF PLATELET RELEASE REACTION. These disorders are characterised by normal initial aggregation of platelets with ADP or collagen but the subsequent release of ADP, prostaglandins and 5-HT is defective due to complex intrinsic deficiencies.

Acquired Disorders (p. 334)

1. ASPIRIN THERAPY. Prolonged use of aspirin leads to easy bruising and abnormal bleeding time. This is because aspirin inhibits the enzyme cyclooxygenase, and thereby suppresses the synthesis of prostaglandins which are involved in platelet aggregation as well as release reaction. The anti-platelet effect of aspirin is clinically applied in preventing major thrombo-embolic disease in recurrent myocardial infarction.

2. OTHERS. Several other acquired disorders are associated with various abnormalities in platelet functions at different levels. These include: uraemia, liver disease, multiple myeloma, Waldenström's macroglobulinaemia and various myeloproliferative disorders.

□ COAGULATION DISORDERS (p. 335)

A deficiency of each of the thirteen known plasma coagulation factors has been reported, which may be inherited or acquired. In general, coagulation disorders are less common as compared with other bleeding disorders. Instead of spontaneous appearance of petechiae and purpuras, the plasma coagulation defects manifest more often in the form of large ecchymoses, haematomas and bleeding into muscles, joints, body cavities, GIT and urinary tract. For establishing the diagnosis, *screening tests for coagulation* (whole blood coagulation time, bleeding time, activated partial thromboplastin time and prothrombin time) are carried out, followed by *coagulation factor assays*.

Disorders of plasma coagulation factors may have hereditary or acquired origin.

CLASSIC HAEMOPHILIA (HAEMOPHILIA A) (p. 335)

Classic haemophilia or haemophilia A is the second most common hereditary coagulation disorder next to von Willebrand's disease occurring due to deficiency or reduced activity of factor VIII (anti-haemophilic factor). The

disorder is inherited as a sex-(X-) linked recessive trait and, therefore, manifests clinically in males, while females are usually the carriers. However, occasional women carriers of haemophilia may produce factor VIII levels far below 50% and become symptomatic carriers, or rarely there may be true female haemophilics arising from consanguinity within the family (i.e. homozygous females). The chances of a proven carrier mother passing on the abnormality to her children is 50:50 for each son and 50:50 for each daughter. A haemophilic father will have normal sons as they inherit his Y chromosome only that does not carry the genetic abnormality.

The disease has been known since ancient times but Schönlein in 1839 gave this bleeder's disease its present name haemophilia.

The frequency of haemophilia varies in different races, the highest incidence being in populations of Britain, Northern Europe and Australia. Western literature reports give an overall incidence of haemophilia in 1 in 10,000 male births.

PATHOGENESIS. Haemophilia A is caused by quantitative reduction of factor VIII in 90% of cases, while 10% cases have normal or increased level of factor VIII with reduced activity. Factor VIII circulates in blood complexed to another larger protein, von Willebrand's factor (vWF), which comprises 99% of the factor VIII-vWF complex. Normal haemostasis requires 25% factor VIII activity. Though occasional patients with 25% factor VIII level may develop bleeding, most symptomatic haemophilic patients have factor VIII levels below 5%.

CLINICAL FEATURES. Patients of haemophilia suffer from bleeding for hours or days after the injury. The clinical severity of the disease correlates well with plasma level of factor VIII activity. Haemophilic bleeding can involve any organ but occurs most commonly as recurrent painful haemarthroses and muscle haematomas, and sometimes as haematuria.

LABORATORY FINDINGS. These are as under:

1. Whole blood coagulation time is prolonged in severe cases only.
2. Prothrombin time is usually normal.
3. Activated partial thromboplastin time (APTT or PTTK) is typically prolonged.
4. Specific assay for factor VIII shows lowered activity. The diagnosis of *female carriers* is made by the findings of about half the activity of factor VIII, while the *manifest disease* is associated with factor VIII activity below 25%.

CHRISTMAS DISEASE (HAEMOPHILIA B) (p. 336)

Inherited deficiency of factor IX (Christmas factor or plasma thromboplastin component) produces Christmas disease or haemophilia B. Haemophilia B is rarer than haemophilia A; its estimated incidence is 1 in 100,000 male births.

VON WILLEBRAND'S DISEASE (p. 336)

DEFINITION AND PATHOGENESIS. von Willebrand's disease (vWD) is the most common hereditary coagulation disorder occurring due to qualitative or quantitative defect in von Willebrand's factor (vWF). Its incidence is estimated to be 1 in 1,000 individuals of either sex. The vWF comprises the larger fraction of factor VIII-vWF complex which circulates in the blood.

1. The *gene* for vWF is located at chromosome 12, while that of factor VIII is in X-chromosome. Thus, vWD is inherited as an autosomal dominant trait which may occur in either sex, while factor VIII deficiency (haemophilia A) is a sex (X-)-linked recessive disorder.
2. The vWF is *synthesised* in the endothelial cells, megakaryocytes and platelets but not in the liver cells, while the principal site of synthesis of factor VIII is the liver.
3. The main *function* of vWF is to facilitate the adhesion of platelets to subendothelial collagen, while factor VIII is involved in activation of factor X in the intrinsic coagulation pathway.

274 CLINICAL FEATURES. Clinically, the patients of vWD are characterised by spontaneous bleeding from mucous membranes and excessive bleeding from wounds.

LABORATORY FINDINGS. These are:

1. Prolonged bleeding time.
2. Normal platelet count.
3. Reduced plasma vWF concentration.
4. Defective platelet aggregation with ristocetin, an antibiotic.
5. Reduced factor VIII activity.

VITAMIN K DEFICIENCY (p. 336)

Vitamin K is a fat-soluble vitamin which plays important role in haemostasis since it serves as a cofactor in the formation of 6 prothrombin complex proteins (*vitamin K-dependent coagulation factors*) synthesised in the liver: factor II, VII, IX, X, protein C and protein S. Vitamin K is obtained from green vegetables, absorbed in the small intestine and stored in the liver. Some quantity of vitamin K is endogenously synthesised by the bacteria in the colon.

Vitamin K deficiency may present in the newborn or in subsequent childhood or adult life:

◆ **Neonatal vitamin K deficiency.** Deficiency of vitamin K in the newborn causes haemorrhagic disease of the newborn. Liver cell immaturity, lack of gut bacterial synthesis of the vitamin and low quantities in breast milk, all contribute to vitamin K deficiency in the newborn and may cause haemorrhage on 2nd to 4th day of life. Routine administration of vitamin K to all newly born infants has led to disappearance of neonatal vitamin K deficiency.

◆ **Vitamin K deficiency in children and adult.** There are 3 major causes of vitamin K deficiency in childhood or adult life:

1. Inadequate dietary intake.
2. Intestinal malabsorption.
3. Loss of storage site due to hepatocellular disease.

COAGULATION DISORDERS IN LIVER DISEASE (p. 336)

Since liver is the major site for synthesis and metabolism of coagulation factors, liver disease often leads to multiple haemostatic abnormalities. The liver also produces inhibitors of coagulation such as antithrombin III and protein C and S and plays a role in the clearance of activated factors and fibrinolytic enzymes. Thus, patients with liver disease may develop hypercoagulability and are predisposed to develop DIC and systemic fibrinolysis.

The major causes of bleeding in liver diseases are as under:

A. Morphologic lesions:

1. Portal hypertension e.g. varices, splenomegaly with secondary thrombocytopenia.
2. Peptic ulceration.
3. Gastritis.

B. Hepatic dysfunctions:

1. Impaired hepatic synthesis of coagulation factors.
2. Impaired hepatic synthesis of coagulation inhibitors: protein C, protein S and antithrombin III.
3. Impaired absorption and metabolism of vitamin K.
4. Failure to clear activated coagulation factors causing DIC and systemic fibrinolysis.

C. Complications of therapy:

1. Following massive transfusion leading to dilution of platelets and coagulation factors.

2. Infusion of activated coagulation proteins.
3. Following heparin therapy.

□ **HAEMORRHAGIC DIATHESIS DUE TO FIBRINOLYTIC DEFECTS** (p. 337)

Normally, fibrinolysis consisting of plasminogen-plasmin and fibrin degradation products (FDPs) is an essential protective physiologic mechanism to limit the blood coagulation in the body. However, unchecked and excessive fibrinolysis may sometimes be the cause of bleeding. The causes of *primary pathologic fibrinolysis* leading to haemorrhagic defects are as under:

1. Deficiency of α_2 -plasmin inhibitor following trauma or surgery.
2. Impaired clearance of tissue plasminogen activator such as in cirrhosis of liver.

□ **DISSEMINATED INTRAVASCULAR COAGULATION (DIC)** (p. 337)

Disseminated intravascular coagulation (DIC), also termed defibrination syndrome or consumption coagulopathy, is a complex thrombo-haemorrhagic disorder (intravascular coagulation and haemorrhage) occurring as a secondary complication in some systemic diseases.

ETIOLOGY. Although there are numerous conditions associated with DIC, most frequent causes are listed below:

1. **Massive tissue injury**
2. **Infections**
3. **Widespread endothelial damage**
4. **Miscellaneous:** snake bite, shock, acute intravascular haemolysis, heat stroke.

PATHOGENESIS. Although in each case, a distinct triggering mechanism has been identified, the sequence of events, in general, can be summarised as under (*Web Image 13.7*):

1. **Activation of coagulation.** The etiologic factors listed above initiate widespread activation of coagulation pathway by release of tissue factor.
2. **Thrombotic phase.** Endothelial damage from the various thrombogenic stimuli causes generalised platelet aggregation and adhesion with resultant deposition of small thrombi and emboli throughout the microvasculature.
3. **Consumption phase.** The early thrombotic phase is followed by a phase of consumption of coagulation factors and platelets.
4. **Secondary fibrinolysis.** As a protective mechanism, fibrinolytic system is secondarily activated at the site of intravascular coagulation. Secondary fibrinolysis causes breakdown of fibrin resulting in formation of FDPs in the circulation.

Pathophysiology of DIC is summed up schematically in *Web Image 13.8*.

CLINICAL FEATURES. There are 2 main features of DIC—*bleeding* as the most common manifestation, and *organ damage* due to ischaemia caused by the effect of widespread intravascular thrombosis such as in the kidney and brain.

LABORATORY FINDINGS. These are as under:

1. The platelet count is low.
2. Blood film shows the features of microangiopathic haemolytic anaemia. There is presence of schistocytes and fragmented red cells due to damage caused by trapping and passage through the fibrin thrombi.
3. Prothrombin time, thrombin time and activated partial thromboplastin time, are all prolonged.
4. Plasma fibrinogen levels are reduced due to consumption in microvascular coagulation.

- 276 5. Fibrin degradation products (FDPs) are raised due to secondary fibrinolysis.

A summary of important laboratory findings in common causes of haemostatic abnormalities is summed up in **Web Table 13.3**.

BLOOD GROUPS AND BLOOD TRANSFUSION (p. 339)

□ BLOOD GROUP ANTIGENS AND ANTIBODIES (p. 339)

Karl Landsteiner described the existence of major human blood groups in 1900 and was awarded Nobel Prize in 1930. The term *blood group* is applied to any well-defined system of red blood cell antigens which are inherited characteristics. Over 20 blood group systems having approximately 400 blood group antigens are currently recognised. The ABO and Rhesus (Rh) blood group systems are of major clinical significance. Other minor and clinically less important blood group systems are: Lewis system, P system, I system, MNS system, Kell and Duffy system, and Luthern system.

Individuals who lack the corresponding antigen and have not been previously transfused have *naturally-occurring antibodies* in their serum. The most important are anti-A and anti-B antibodies, usually of IgM class. *Immune antibodies*, on the other hand, are acquired in response to transfusion and by transplacental passage during pregnancy. These are warm antibodies, usually of IgG class.

ABO SYSTEM. This system consists of 3 major allelic genes: A, B and O, located on the long arm of chromosome 9. These genes control the synthesis of blood group antigens A and B. The serum of an individual contains naturally-occurring antibodies to A and/or B antigen, whichever antigen is lacking in the person's red cells (**Web Table 13.4**). Two subgroups of A—A₁ and A₂, and thus of AB also, A₁B and A₂B, are recognised but are of minor clinical significance. In routine practice, the ABO type is determined by testing the red blood cells with anti-A and anti-B and by testing the serum against A, B and O red blood cells.

Red blood cells of type O and A₂ have large amounts of another antigen called *H substance* which is genetically different from ABO but is a precursor of A and B antigens. An O group individual who inherits A or B genes but fails to inherit H gene from either parent is called O_H *phenotype* or *Bombay blood group*. In such rare individual, despite the presence of all the three antibodies in serum (anti-A, anti-B and anti-H), the red cells are not agglutinated by the antisera.

RHESUS SYSTEM. The Rhesus (Rh) blood group system was first discovered on human red cells by the use of antiserum prepared by immunising rabbits with red cells from a Rhesus monkey. The Rh allelic genes are *C* or *c*, *D* or *d* and *E* or *e*, located on chromosome 1.

However, out of all these, *D* antigen is most strongly immunogenic and, therefore, clinically most important. In practice, Rh grouping is performed with anti-D antiserum. Individuals who are D-positive are referred to as *Rh-positive* and those who lack D antigen are termed *Rh-negative*.

Practically, there are no naturally-occurring Rh antibodies. All Rh antibodies in Rh-negative individuals are acquired from immunisation such as by transfusion and during pregnancy, resulting in fatal haemolytic transfusion reaction and haemolytic disease of the newborn.

□ BLOOD TRANSFUSION (p. 339)

A pre-transfusion compatibility testing is essential prior to any blood transfusion. The procedure consists of the following:

1. ABO and Rh(D) grouping of the patient (*recipient*).
2. *Antibody screening* of the patient's serum to detect the presence of clinically significant antibodies.

3. Selecting the *donor* blood of the same ABO and Rh group.
4. *Cross-matching* the patient's serum against donor red cells to confirm donor-recipient compatibility.

The indications for blood transfusion are acute blood loss and various haematologic disorders considered already. In addition to the whole blood transfusion, the modern blood-banking techniques have made it possible to transfuse blood components such as packed red blood cells, platelets, white blood cell concentrates, plasma components and plasmapheresis in specific situations.

COMPLICATIONS OF BLOOD TRANSFUSION (p. 339)

A carefully prepared and supervised blood transfusion is quite safe. However, in 5-6% of transfusions, untoward complications occur, some of which are minor while others are more serious and at times fatal.

These transfusion reactions are considered below.

I. IMMUNOLOGIC TRANSFUSION REACTIONS. These are:

1. Haemolytic transfusion reactions. Haemolytic transfusion reaction may be *immediate* or *delayed*, *intravascular* or *extravascular*.

● Very rapid cell destruction associated with *intravascular haemolysis* is usually due to ABO incompatibility since both naturally-occurring antibodies, anti-A and anti-B, are capable of fixing complement.

● *Extravascular haemolysis* is more often due to immune antibodies of the Rh system.

2. Transfusion-related acute lung injury (TRALI). This is an uncommon reaction resulting from transfusion of donor plasma containing high levels of anti-HLA antibodies which bind to leucocytes of recipient.

3. Other allergic reactions.

- i) *Febrile reaction* which is usually attributed to immunologic reaction against white blood cells, platelets, or IgA class immunoglobulins.
- ii) Patients with antibodies against IgA molecule sometimes develop *anaphylactic shock* on transfusion of blood from other human subjects.
- iii) *Allergic reactions* such as urticaria may occur.
- iv) Transfusion-related *graft-versus-host disease* mediated by donor T lymphocytes may occur.

II. NONIMMUNE TRANSFUSION REACTIONS. This category includes the following adverse effects:

1. Circulatory overload
2. Massive transfusion
3. Transmission of infection
4. Air embolism
5. Thrombophlebitis
6. Transfusion haemosiderosis.

BLOOD COMPONENTS (p. 340)

Blood from donors is collected as whole blood in a suitable anticoagulant. Nowadays it is a common practice to divide whole blood into components which include: packed RBCs, platelets, fresh-frozen plasma (FFP) and cryoprecipitate.

The procedure consists of initial centrifugation at low speed to separate whole blood into two parts: *packed RBCs* and *platelet-rich plasma (PRP)*. Subsequently, PRP is centrifuged at high speed to yield two parts: *random donor platelets* and *FFP*. *Cryoprecipitates* are obtained by thawing of FFP followed by centrifugation. *Apheresis* is the technique of direct collection of large excess of platelets from a single donor.

Applications of these blood components in clinical use are as under:

- 1. Packed RBCs.** These are used to raise the oxygen-carrying capacity of blood and are used in normovolaemic patients of anaemia without cardiac disease. One unit of packed RBCs may raise haemoglobin by 1 g/dl.
- 2. Platelets.** Transfusion of platelets is done in patients of thrombocytopenia who have haemorrhage. Optimally, platelet transfusions can be given to a patient with platelet count below 10,000/ μ l. Each unit of platelets can raise platelet count by 5,000 to 10,000/ μ l.
- 3. Fresh frozen plasma.** FFP contains plasma proteins and coagulation factors that include albumin, protein C and S and antithrombin. FFP transfusion is indicated in patients of coagulation failure and TTP. Each unit of FFP raises coagulation factors by about 2%.
- 4. Cryoprecipitate.** Cryoprecipitate is a source of insoluble plasma proteins, fibrinogen, factor VIII and vWF. Indications for transfusion of cryoprecipitate are for patients requiring fibrinogen, factor VIII and vWF. Transfusion of single unit of cryoprecipitate yields about 80 IU of factor VIII.

HAEMOLYTIC DISEASE OF NEWBORN (p. 340)

Haemolytic disease of the newborn (HDN) results from the passage of IgG antibodies from the maternal circulation across the placenta into the circulation of the foetal red cells. Besides pregnancy, sensitisation of the mother may result from previous abortions and previous blood transfusion.

HDN can occur from incompatibility of ABO or Rh blood group system. ABO incompatibility is much more common but the HDN in such cases is usually mild, while Rh-D incompatibility results in more severe form of the HDN.

PATHOGENESIS. The pathogenesis of the two main forms of HDN is different.

HDN due to Rh-D incompatibility. Rh incompatibility occurs when a Rh-negative mother is sensitised to Rh-positive blood. This results most often from a Rh-positive foetus by passage of Rh-positive red cells across the placenta into the circulation of Rh-negative mother. Normally, during pregnancy very few foetal red cells cross the placenta but haemorrhage during parturition causes significant sensitisation of the mother. Sensitisation is more likely if the mother and foetus are ABO compatible rather than ABO incompatible. Though approximately 95% cases of Rh-HDN are due to anti-D, some cases are due to combination of anti-D with other immune antibodies of the Rh system such as anti-C and anti-E, and rarely anti-c alone.

It must be emphasised here that the risk of sensitisation of a Rh-negative woman married to Rh-positive man is small in first pregnancy but increases during successive pregnancies if prophylactic anti-D immunoglobulin is not given within 72 hours after the first delivery.

HDN due to ABO incompatibility. About 20% pregnancies with ABO incompatibility between the mother and the foetus develop the HDN. Naturally-occurring anti-A and anti-B antibodies' which are usually of IgM class do not cross the placenta, while immune anti-A and anti-B antibodies which are usually of IgG class may cross the placenta into foetal circulation and damage the foetal red cells. ABO HDN occurs most frequently in infants born to group O mothers who possess anti-A and/or anti-B IgG antibodies.

CLINICAL FEATURES. The HDN due to Rh-D incompatibility in its *severest form* may result in intrauterine death from *hydrops foetalis*. *Moderate disease* produces a baby born with severe anaemia and jaundice due to unconjugated hyperbilirubinaemia. When the level of unconjugated bilirubin exceeds 20 mg/dl, it may result in deposition of bile pigment in the basal ganglia of the

CNS called *kernicterus* and result in permanent brain damage. *Mild disease*, however, causes only severe anaemia with or without jaundice.

LABORATORY FINDINGS. These are:

1. *Cord blood* shows variable degree of anaemia, reticulocytosis, elevated serum bilirubin and a positive direct Coombs' test if the cord blood is Rh-D positive.
2. Mother's blood is Rh-D negative with high plasma titre of anti-D.

COURSE AND PROGNOSIS. The course in HDN may range from death, to minimal haemolysis, to mental retardation. The practice of administration of anti-Rh immunoglobulin to the mother before or after delivery has reduced the incidence of HDN as well as protects the mother before the baby's RBCs sensitise the mother's blood. Exchange transfusion of the baby is done to remove the antibodies, remove red cells susceptible to haemolysis and also to lower the bilirubin level.

SELF ASSESSMENT

1. If a patient is on parenteral heparin therapy, the following test is used to monitor the administration:
 - A. Whole blood coagulation time
 - B. Prothrombin time
 - C. Thrombin time
 - D. Activated partial thromboplastin time
2. Chronic ITP is characterised by the following features *except*:
 - A. Splenomegaly
 - B. Reduced platelet lifespan
 - C. Reduced number of megakaryocytes in the bone marrow
 - D. Demonstration of anti-platelet IgG antibody
3. For manifest bleeding haemophilia, the activity of factor VIII is generally:

A. More than 75%	B. 50-75%
C. 25-50%	D. Below 25%
4. Disseminated intravascular coagulation (DIC) is characterised by the following *except*:
 - A. Thrombocytopenia
 - B. Microangiopathic haemolytic anaemia
 - C. Presence of FDPs in the blood
 - D. Normal prothrombin time
5. Naturally-occurring antibodies in the serum of a non-transfused person are:

A. IgA	B. IgD
C. IgG	D. IgM
6. Tests for platelet function include all *except*:
 - A. Platelet adhesion tests
 - B. Ethanol gelation test
 - C. Aggregation test
 - D. Granular content of platelets
7. Heparin induced thrombocytopenia causes:

A. Bleeding	B. Thrombosis
C. Both bleeding and thrombosis	D. No symptoms
8. Antibodies in chronic ITP are:

A. IgA	B. IgM
C. IgE	D. IgG
9. Which of the following is not included in TTP triad?
 - A. DIC
 - B. Thrombocytopenia
 - C. Microangiopathic haemolytic anaemia
 - D. Fibrin microthrombi

10. **Bernard Soulier Syndrome is a defect in:**
 A. Platelet aggregation B. Platelet adhesion
 C. Platelet release reaction D. Platelet morphology
11. **Most common hereditary coagulation disorder is:**
 A. Haemophilia A B. Haemophilia B
 C. von Willebrand's disease D. Protein C deficiency
12. **Most common manifestation of DIC is:**
 A. Bleeding
 B. Thrombosis
 C. Microangiopathic haemolytic anaemia
 D. Organ damage
13. **Bombay blood group is characterised by:**
 A. Absence of A gene
 B. Absence of B gene
 C. Absence of both A & B genes
 D. Absence of H gene
14. **Hemolytic disease of newborn occurs:**
 A. Mother Rh+ve, foetus Rh -ve
 B. Mother Rh-ve, foetus Rh +ve
 C. Both mother and foetus Rh -ve
 D. Both mother and foetus Rh +ve

KEY

1 = D	2 = C	3 = D	4 = D
5 = D	6 = B	7 = B	8 = D
9 = A	10 = B	11 = C	12 = A
13 = D	14 = B		



Disorders of Leucocytes and Lymphoreticular Tissues

In this chapter, the abnormalities pertaining to the remaining two cell lines—granulocyte-monocyte cell line and the lymphoid cell lines, will be discussed besides discussion on all haematopoietic neoplasms. Both these cell lines constitute leucocyte pool in the body at two distinct locations: in circulating blood and in the tissues. This concept holds more true for lymphoid cells in particular, which are present in circulation as well as are distributed in the lymphoid tissues of the body (lymph nodes, spleen, mucosa-associated lymphoid tissue—MALT, pharyngeal lymphoid tissue). B, T and NK lymphoid cells are formed after differentiation from lymphopoietic precursor cells in the bone marrow undergo further maturation in peripheral lymphoid organs and thymus. Thus, relationship of haematopoietic tissues and lymphoreticular tissues is quite close.

□ NORMAL STRUCTURE (p. 342)

The inner structure of the lymph node is divided into a peripheral cortex and central medulla. The *cortex* consists of several rounded aggregates of lymphocytes called *lymphoid follicles*. The follicle has a pale-staining germinal centre surrounded by small dark-staining lymphocytes called the mantle zone. The deeper region of the cortex or *paracortex* is the zone between the peripheral cortex and the inner medulla. The *medulla* is predominantly composed of cords of plasma cells and some lymphocytes. The capsule and the structure within the lymph node are connected by supportive delicate reticulin framework (**Web Image 14.1,A**).

Functionally, the lymph node is divided into T and B lymphocyte zones:

◆ *B-cell zone* lies in the follicles in the cortex, the mantle zone and the interfollicular space, while *plasma cells* are also present in the interfollicular zone.

◆ *T-cell zone* is predominantly present in the medulla.

There are two main functions of the lymph node—to mount immune response in the body, and to perform the function of active phagocytosis for particulate material. Besides T and B-cells, the follicular centre has *dendritic histiocytes* and antigen-presenting *Langerhans' histiocytes* (formerly together called tingible body macrophages due to engulfment of particulate material by them) and *endothelial cells*. The follicular centre is a very active zone where lymphocytes from peripheral blood continuously enter and leave, interact with macrophage-histiocytes and endothelial cells and undergo maturation and transformation. Lymphocytes and endothelial cells have surface molecules which interact and serve as 'addresses' so that endothelial cells can direct the lymphocytes; these molecules are appropriately termed as *addressins* or *homing receptors*. Peripheral blood B and T lymphocytes on entering the lymph node are stimulated immunologically which transforms them to undergo cytoplasmic and nuclear maturation which may be in the follicular centre or paracortex as per following sequence and schematically depicted in **Web Image 14.1,B**:

- i) Follicular centre, small non-cleaved cells or centroblasts
- ii) Follicular centre, small cleaved cells or centrocytes

- 282 iii) Follicular centre, large cleaved cells
iv) Follicular centre, large non-cleaved cells
v) Immunoblasts (in paracortex)
vi) Convuluted cells or lymphoblasts (in paracortex)
vii) Plasma cells.

□ **REACTIVE LYMPHADENITIS** (p. 343)

Lymph nodes undergo reactive changes in response to a wide variety of stimuli which include microbial infections, drugs, environmental pollutants, tissue injury, immune-complexes and malignant neoplasms. However, the most common causes of lymph node enlargement are inflammatory and immune reactions, aside from primary malignant neoplasms and metastatic tumour deposits. Those due to primary inflammatory reaction are termed *reactive lymphadenitis*, and those due to primary immune reactions are referred to as *lymphadenopathy*.

Reactive lymphadenitis is a nonspecific response and is categorised into acute and chronic types, each with a few variant forms.

ACUTE NONSPECIFIC LYMPHADENITIS (p. 343)

All kinds of acute inflammations may cause acute nonspecific lymphadenitis in the nodes draining the area of inflamed tissue. Most common causes are microbiologic infections or their breakdown products, and foreign bodies in the wound or into the circulation etc. Most frequently involved lymph nodes are: *cervical* (due to infections in the oral cavity), *axillary* (due to infection in the arm), *inguinal* (due to infection in the lower extremities), and *mesenteric* (due to acute appendicitis, acute enteritis etc).

G/A The affected lymph nodes are enlarged 2-3 times their normal size and may show abscess formation if the involvement is extensive.

M/E The sinusoids are congested, widely dilated and oedematous and contain numerous neutrophils. The lymphoid follicles are prominent with presence of many mitoses and phagocytosis. In more severe cases, necrosis may occur and neutrophil abscesses may form.

CHRONIC NONSPECIFIC LYMPHADENITIS (p. 343)

Chronic nonspecific lymphadenitis, commonly called *reactive lymphoid hyperplasia*, is a common form of inflammatory reaction of draining lymph nodes as a response to antigenic stimuli such as repeated attacks of acute lymphadenitis and lymph from malignant tumours.

Depending upon the pattern in chronic nonspecific lymphadenitis, three types are distinguished, each having its own set of causes. These are: *follicular hyperplasia*, *paracortical hyperplasia* and *sinus histiocytosis*. However, mixed patterns may also be seen in which case one of the patterns predominates over the others.

G/A The affected lymph nodes are usually enlarged, firm and non-tender.

M/E The features of 3 patterns of reactive lymphoid hyperplasia are as under:

1. Follicular hyperplasia is the most frequent pattern, particularly encountered in children. Besides nonspecific stimulation, a few specific causes are: rheumatoid arthritis, toxoplasmosis, syphilis and AIDS. The microscopic features are as follows (**Web Image 14.2**):

- i) There is marked enlargement and prominence of the germinal centres of lymphoid follicles (proliferation of B-cell areas) due to the presence of numerous mitotically active lymphocytes and proliferation of phagocytic cells containing phagocytosed material.
- ii) Parafollicular and medullary regions are more cellular and contain plasma cells, histiocytes, and some neutrophils and eosinophils.

iii) There is hyperplasia of mononuclear phagocytic cells lining the lymphatic sinuses in the lymph node.

◆ **Angiofollicular lymphoid hyperplasia** or *Castleman's disease* is a clinicopathologic variant of follicular hyperplasia. The condition may occur at any age and possibly has an association with Epstein-Barr virus infection. Two histologic forms are distinguished:

- i) *Hyaline-vascular type* is more common (90% cases)
- ii) *Plasma cell form* is less common and is characterised by plasma cell hyperplasia and vascular proliferation.

2. Paracortical lymphoid hyperplasia is due to hyperplasia of T-cell-dependent area of the lymph node. Amongst the important causes are immunologic reactions caused by drugs (e.g. dilantin), vaccination, viruses (e.g. infectious mononucleosis) and autoimmune disorders. Its histologic features are as follows:

- i) Expansion of the paracortex (T-cell area) with increased number of T-cell transformed immunoblasts.
- ii) Encroachment by the enlarged paracortex on the lymphoid follicles, sometimes resulting in their effacement.
- iii) Hyperplasia of the mononuclear phagocytic cells in the lymphatic sinuses.

Variants of paracortical lymphoid hyperplasia are angio-immunoblastic lymphadenopathy, dermatopathic lymphadenopathy, dilantin lymphadenopathy and post-vaccinial lymphadenopathy.

3. Sinus histiocytosis or sinus hyperplasia is a very common type found in regional lymph nodes draining inflammatory lesions, or as an immune reaction of the host to a draining malignant tumour or its products. The hallmark of histologic diagnosis is the expansion of the sinuses by proliferating large histiocytes containing phagocytosed material (**Web Image 14.3**). The presence of sinus histiocytosis in the draining lymph nodes of carcinoma such as in breast carcinoma has been considered by some workers to confer better prognosis in such patients due to good host immune response.

◆ *Sinus histiocytosis with massive lymphadenopathy* is characterised by marked enlargement of lymph nodes, especially of the neck, in young adolescents.

HIV-RELATED LYMPHADENOPATHY (p. 344)

The presence of enlarged lymph nodes of more than 1 cm diameter at two or more extra-inguinal sites for more than 3 months without any other obvious cause is frequently the earliest symptom of primary HIV infection.

M/E The findings at biopsy of involved lymph node vary depending upon the stage of HIV infection:

1. *In the early stage* marked follicular hyperplasia is the dominant finding and reflects the polyclonal B-cell proliferation.
2. *In the intermediate stage*, there is a combination of follicular hyperplasia and follicular involution. However, adenopathic form of Kaposi's sarcoma too may develop at this stage.
3. *In the last stage*, there is decrease in the lymph node size indicative of prognostic marker of disease progression. Microscopic findings of node at this stage reveal follicular involution and lymphocyte depletion. At this stage, other stigmata of AIDS in the lymph node may also appear e.g. lymphoma, mycobacterial infection, toxoplasmosis, systemic fungal infections etc.

WHITE BLOOD CELLS: NORMAL AND REACTIVE (p. 345)

The leucocytes of the peripheral blood are of 2 main varieties, distinguished by the presence or absence of granules: *granulocytes* and *nongranular leucocytes*. The granulocytes, according to the appearance of nuclei, are subdivided into polymorphonuclear leucocytes and monocytes. Further, depending upon the colour of granules, polymorphonuclear leucocytes are

284 of 3 types: neutrophils, eosinophils and basophils. The nongranular leucocytes are 3 types of lymphocytes: T, B and natural killer (NK) cells.

□ **GRANULOPOIESIS** (p. 345)

SITE OF FORMATION AND KINETICS (p. 345)

All forms of granulocytes are produced in the bone marrow and are termed, '*myeloid series*'. Myeloid series include maturing stages: myeloblast (most primitive precursor), promyelocyte, myelocyte, metamyelocyte, band forms and segmented granulocyte (mature form). The myeloblast, promyelocyte and myelocyte form a '*proliferative or mitotic pool*', while the remainder (i.e. metamyelocyte, band forms and segmented granulocytes) make up a '*mature or post-mitotic pool*'. It takes about 12 days for formation of mature granulocytes from the myeloblast. Normally the bone marrow contains more myeloid cells than the erythroid cells in the ratio of 2:1 to 15:1 (average 3:1), the largest proportion being that of metamyelocytes, band forms and segmented neutrophils.

Normally, the bone marrow storage compartment contains about 10-15 times the number of granulocytes found in the peripheral blood. Following their release from the bone marrow, granulocytes spend about 10 hours in the circulation before they move into the tissues, where they perform their respective functions. The blood pool of granulocytes consists of 2 components of about equal size—the *circulating pool* that is included in the blood count, and the *marginating pool* that is not included in the blood count. Granulocytes spend about 4-5 days in the tissues before they are either destroyed during phagocytosis or die due to senescence. The presence of a humoral regulatory substance, 'granulopoietin' analogous to erythropoietin has also been identified by *in vitro* studies of colony-forming units (CFU) and is characterised as G-CSF (granulocyte colony-stimulating factor) and GM-CSF (granulocyte-monocyte colony-stimulating factor).

The kinetics of monocytes is less well understood than that of other myeloid cells. Monocytes spend about 20-40 hours in the circulation after which they leave the blood to enter extravascular tissues where they perform their main function of active phagocytosis. The extravascular lifespan of tissue macrophages which are the transformed form of blood monocytes, may vary from a few months to a few years.

MYELOID SERIES (p. 345)

The development of myeloid cells from myeloblast takes place in the following sequence (**Web Image 14.4**):

1. Myeloblast
2. Promyelocyte
3. Myelocyte
4. Metamyelocyte
5. Band forms
6. Segmented granulocytes.

Common surface markers for all stages of myeloid series of cells are CD33, CD13 and CD15. However, stages from myelocytes to mature neutrophils also carry CD11b and CD14. Band forms and mature neutrophils have further CD 10 and CD16.

MONOCYTE-MACROPHAGE SERIES (p. 346)

The monocyte-macrophage series of cells, though comprise a part of myeloid series alongwith other granulocytic series, but are described separately here in view of different morphologic stages in their maturation (**Web Image 14.4**).

1. Monoblast
2. Promonocyte
3. Monocyte

Monocyte-macrophage series having specialised function of phagocytosis secrete active products such as lysozyme, neutral proteases, acid hydrolases, components of complement, transferrin, fibronectin, nucleosides and several cytokines (TNF- α , IL-1, IL-8, IL-12, IL-18). They express lineage-specific molecules CD 14, cell surface LPS receptors etc.

□ **LYMPHOPOIESIS** (p. 346)

SITES OF FORMATION AND KINETICS (p. 346)

The lymphocytes and the plasma cells are immunocompetent cells of the body. In man, the bone marrow and the thymus are the *primary lymphopoietic organs* where lymphoid stem cells undergo spontaneous division independent of antigenic stimulation. The *secondary or reactive lymphoid tissue* is comprised by the lymph nodes, spleen and gut-associated lymphoid tissue (GALT). These sites actively produce lymphocytes from the germinal centres of lymphoid follicles as a response to antigenic stimulation. Lymphocytes pass through a series of developmental changes in the course of their evolution into lymphocyte subpopulations and subsets. It includes migration of immature lymphocytes to other organs such as the thymus where locally-produced factors act on them.

Functionally, the lymphocytes are divided into T, B and natural killer (NK) cells depending upon whether they are immunologically active in cell-mediated immunity (T cells), in humoral antibody response (B cells) or form part of the natural or innate immunity and act as killer of some viruses (NK cells). In man, the B cells are derived from the bone marrow stem cells, while in birds they mature in the bursa of Fabricius. After antigenic activation, B cells proliferate and mature into plasma cells which secrete specific immunoglobulin antibodies. The T cells are also produced in the bone marrow and possibly in the thymus. NK cells do not have B or T cell markers, nor are these cells dependent upon thymus for development.

LYMPHOID SERIES (p. 347)

The maturation stages in production of lymphocytes are illustrated in **Web Image 14.5** and are as under:

1. Lymphoblast
2. Prolymphocyte
3. Lymphocyte

The distinguishing morphologic features between the myeloblast and lymphoblast are summarised in **Web Table 14.1**.

□ **MATURE LEUCOCYTES IN HEALTH AND REACTION IN DISEASE** (p. 347)

Normally, only mature leucocytes namely: polymorphs, lymphocytes, monocytes, eosinophils and basophils, are found in the peripheral blood. The normal range of total and differential leucocyte count (TLC and DLC expressed sequentially as P, L, M, E, B) in health in adults and children is given in **Web Table 14.2**. White cell count tends to be higher in infants and children than in adults. It also normally undergoes minor degree of diurnal variation with a slight rise in the afternoon. The total white cell count is normally high in pregnancy and following delivery, usually returning to normal within a week. The pathological variations in white cell values together with brief review of their morphology and functions are considered below (**Web Image 14.6**):

POLYMORPHS (NEUTROPHILS) (p. 347)

MORPHOLOGY. A polymorphonuclear neutrophil (PMN), commonly called polymorph or neutrophil, is 12-15 μm in diameter. It consists of a characteristic

286 dense nucleus, having 2-5 lobes and pale cytoplasm containing numerous fine violet-pink granules. These lysosomal granules contain several enzymes and are of 2 types:

Primary or azurophilic granules are large and coarse and appear early at the promyelocyte stage. These granules contain hydrolases, elastase, myeloperoxidase, cathepsin-G, cationic proteins, permeability increasing protein, and microbicidal protein called defensins.

Secondary or specific granules are smaller and more numerous. These appear later at myelocyte stage, are MPO-negative and contain lactoferrin, NADPH oxidase, histaminase, vitamin B₁₂ binding protein, and receptors for chemoattractants and for laminin.

The normal **functions** of neutrophils are: chemotaxis, phagocytosis and killing of the microorganism.

PATHOLOGIC VARIATIONS. These are as under:

Variation in count. An increase in neutrophil count (*neutrophil leucocytosis* or *neutrophilia*) or a decrease in count (*neutropenia*) may occur in various diseases.

Neutrophil leucocytosis. An increase in circulating neutrophils above 7,500/ μ l is the commonest type of leucocytosis and occurs most commonly as a response to acute bacterial infections. Some common causes of neutrophilia are as under:

1. *Acute infections, local or generalised*
2. *Other inflammations*
3. *Intoxication*
4. *Acute haemorrhage*, internal or external.
5. *Acute haemolysis.*
6. *Disseminated malignancies.*
7. *Myeloproliferative disorders*
8. *Miscellaneous* e.g. following corticosteroid therapy, idiopathic neutrophilia.

Neutropenia. When the absolute neutrophil count falls below 2,500/ μ l, the patient is said to have neutropenia and is prone to develop recurrent infections. Some common causes of neutropenia (and hence leucopenia) are as follows:

1. *Certain infections* e.g. typhoid, paratyphoid, brucellosis, influenza, measles, viral hepatitis, malaria, kala-azar etc.
2. *Overwhelming bacterial infections.*
3. *Drugs, chemicals and physical agents.*
4. *Certain haematological and other diseases.*
5. *Cachexia and debility.*
6. *Anaphylactoid shock.*
7. *Certain rare hereditary, congenital or familial disorders.*

VARIATIONS IN MORPHOLOGY. Some of the common variations in neutrophil morphology are shown in **Web Image 14.7**. These are as under:

1. Toxic Granules.
2. Vacuoles.
3. Döhle bodies.
4. Nuclear abnormalities
 - i) *Sex chromatin* is a normal finding in 2-3% of neutrophils in female sex.
 - ii) A '*shift-to-left*' is the term used for appearance of neutrophils with decreased number of nuclear lobes in the peripheral blood.
 - iii) A '*shift-to-right*' is appearance of hypersegmented (more than 5 nuclear lobes) neutrophils in the peripheral blood.
 - iv) *Pelger-Huët anomaly* is an uncommon autosomal dominant inherited disorder in which nuclei in majority of neutrophils are distinctively bilobed (spectacle-shaped) and coarsely staining chromatin.

DEFECTIVE FUNCTIONS. The following abnormalities in neutrophil function may sometimes be found:

1. Defective chemotaxis
2. Defective phagocytosis
3. Defective killing.

LYMPHOCYTES (p. 349)

MORPHOLOGY. Majority of lymphocytes in the peripheral blood are *small* (9-12 μm in diameter) but *large* lymphocytes (12-16 μm in diameter) are also found. Both small and large lymphocytes have round or slightly indented nucleus with coarsely-clumped chromatin and scanty basophilic cytoplasm. Plasma cells are derived from B lymphocytes under the influence of appropriate stimuli.

Functionally, there are 3 types of lymphocytes and possess distinct surface markers called clusters of differentiation (CD) which aid in identification of stage of their differentiation:

T lymphocytes i.e. thymus-dependent lymphocytes, which mature in the thymus and are also known as thymocytes. They are mainly involved in direct action on antigens and are therefore involved in *cell-mediated immune (CMI)* reaction by its subsets such as cytotoxic (killer) T cells (CD3+), CD8+ T cells, and *delayed hypersensitivity reaction* by CD4+ T cells.

B lymphocytes i.e. bone marrow-dependent or bursa-equivalent lymphocytes as well as their derivatives, plasma cells, are the source of specific immunoglobulin antibodies. They are, therefore, involved in *humoral immunity (HI)* or *circulating immune reactions*.

NK cells i.e. natural killer cells are those lymphocytes which morphologically have appearance of lymphocytes but do not possess functional features of T or B cells. As the name indicates they are identified with '*natural*' or innate immunity and bring about direct '*killing*' of microorganisms (particularly certain viruses) or lysis of foreign body.

PATHOLOGIC VARIATIONS. A rise in the absolute count of lymphocytes exceeding the upper limit of normal (above 4,000/ μm) is termed *lymphocytosis*, while absolute lymphocyte count below 1,500/ μm is referred to as *lymphopenia*.

Lymphocytosis:

1. *Certain acute infections* e.g. pertussis, infectious mononucleosis, viral hepatitis, infectious lymphocytosis.
2. *Certain chronic infections* e.g. brucellosis, tuberculosis, secondary syphilis.
3. *Haematopoietic disorders* e.g. lymphocytic leukaemias, lymphoma, heavy chain disease.
4. *Relative lymphocytosis* is found in viral exanthemas, convalescence from acute infections, thyrotoxicosis, conditions causing neutropenia.

Lymphopenia:

1. Most acute infections.
2. Severe bone marrow failure.
3. Corticosteroid and immunosuppressive therapy.
4. Widespread irradiation.

MONOCYTES (p. 349)

MORPHOLOGY. The monocyte is the largest mature leucocyte in the peripheral blood measuring 12-20 μm in diameter. It possesses a large, central, oval, notched or indented or horseshoe-shaped nucleus which has characteristically fine reticulated chromatin network. The cytoplasm is abundant, pale blue and contains many fine dust-like granules and vacuoles.

The main **functions** of monocytes are: Phagocytosis, immunologic function as *antigen-presenting cells* and as *mediator of inflammation*.

PATHOLOGIC VARIATIONS. A rise in the blood monocytes above 800/ μ l is termed *monocytosis*. Some common causes of monocytosis are:

1. *Certain bacterial infections* e.g. tuberculosis, subacute bacterial endocarditis, syphilis.
2. *Viral infections.*
3. *Protozoal and rickettsial infections* e.g. malaria, typhus, trypanosomiasis, kala-azar.
4. *Convalescence from acute infection.*
5. *Haematopoietic disorders* e.g. monocytic leukaemia, lymphomas, myeloproliferative disorders, multiple myeloma, lipid storage disease.
6. *Malignancies* e.g. cancer of the ovary, stomach, breast.
7. *Granulomatous diseases* e.g. sarcoidosis, inflammatory bowel disease.
8. *Collagen-vascular diseases.*

EOSINOPHILS (p. 350)

MORPHOLOGY. Eosinophils are similar to segmented neutrophils in size (12-15 μ m in diameter), and have coarse, deep red staining granules in the cytoplasm and have usually two nuclear lobes. Granules in eosinophils contain basic protein and stain more intensely for peroxidase than granules in the neutrophils. In addition, eosinophils also contain cell adhesion molecules, cytokines (IL-3, IL-5), and a protein that precipitates Charcot-Leyden crystals in lung tissues in asthmatic patients.

Eosinophils are involved in reactions to foreign proteins and to antigen-antibody reactions.

PATHOLOGIC VARIATIONS. An increase in the number of eosinophilic leucocytes above 400/ μ l is referred to as *eosinophilia* and below 40/ μ l is termed as *eosinopenia*.

Eosinophilia. The cases are as under:

1. Allergic disorders e.g. bronchial asthma, urticaria, angioneurotic oedema, hay fever, drug hypersensitivity.
2. *Parasitic infestations* e.g. trichinosis, echinococcosis, intestinal parasitism.
3. *Skin diseases* e.g. pemphigus, dermatitis herpetiformis, erythema multiforme.
4. *Löffler's syndrome.*
5. *Pulmonary infiltration with eosinophilia (PIE) syndrome.*
6. *Tropical eosinophilia.*
7. *Haematopoietic diseases* e.g. CML, polycythaemia vera, pernicious anaemia, Hodgkin's disease, following splenectomy.
8. *Malignant diseases with metastases.*
9. *Irradiation.*
10. *Miscellaneous disorders* e.g. polyarteritis nodosa, rheumatoid arthritis, sarcoidosis.

Eosinopenia. Adrenal steroids and ACTH induce eosinopenia in man.

BASOPHILS (p. 350)

MORPHOLOGY. Basophils resemble the other mature granulocytes but are distinguished by coarse, intensely basophilic granules which usually fill the cytoplasm and often overlie and obscure the nucleus.

The granules of circulating basophils (as well as their tissue counterparts as mast cells) contain heparin, histamine and 5-HT. Mast cells or basophils on degranulation are associated with histamine release.

PATHOLOGIC VARIATIONS. Basophil leucocytosis or *basophilia* refers to an increase in the number of basophilic leucocytes above 100/ μ l. Basophilia is unusual and is found in the following conditions:

1. Chronic myeloid leukaemia
2. Polycythaemia vera
3. Myelosclerosis
4. Myxoedema
5. Ulcerative colitis
6. Following splenectomy
7. Hodgkin's disease
8. Urticaria pigmentosa.

□ **INFECTIOUS MONONUCLEOSIS** (p. 350)

Infectious mononucleosis (IM) or glandular fever is a benign, self-limiting lymphoproliferative disease caused by Epstein-Barr virus (EBV), one of the herpesviruses. Infection may occur from childhood to old age but the classical acute infection is more common in teenagers and young adults. The infection is transmitted by person-to-person contact such as by kissing with transfer of virally-contaminated saliva. Groups of cases occur particularly in young people living together in boarding schools, colleges, camps and military institutions. It may be mentioned here that EBV is oncogenic as well and is strongly implicated in the African (endemic) Burkitt's lymphoma and nasopharyngeal carcinoma.

PATHOGENESIS (p. 350)

EBV, the etiologic agent for IM, is a B lymphotropic herpesvirus. The disease is characterised by fever, generalised lymphadenopathy, hepatosplenomegaly, sore throat, and appearance in blood of atypical 'mononucleosis cells'. The pathogenesis of these pathologic features is outlined below:

1. In a susceptible sero-negative host who lacks antibodies, the virus in the contaminated saliva *invades and replicates within epithelial cells* of the salivary gland and then enters B cells in the lymphoid tissues which possess receptors for EBV.
2. Viraemia and death of infected B cells cause an acute febrile illness and appearance of specific humoral antibodies which peak about 2 weeks after the infection and persist throughout life. The appearance of antibodies marks the *disappearance of virus from the blood*.
3. Though the viral agent has disappeared from the blood, the EBV-infected B cells continue to be present in the circulation as latent infection. *EBV-infected B cells undergo polyclonal activation and proliferation*. These cells perform two important roles which are the characteristic diagnostic features of IM:
 - i) They secrete *antibodies*—initially IgM but later IgG class antibodies appear. IgM antibody is the heterophile anti-sheep antibody used for diagnosis of IM while IgG antibody persists for life and provides immunity against re-infection.
 - ii) They *activate CD8+ T lymphocytes*— also called cytotoxic T cells (or CTL) or suppressor T cells. CD8+ T cells bring about killing of B cells and are pathognomonic atypical lymphocytes seen in blood in IM.
4. The proliferation of these cells is responsible for *generalised lymphadenopathy and hepatosplenomegaly*.
5. The *sore throat* in IM may be caused by either necrosis of B cells or due to viral replication within the salivary epithelial cells in early stage.

Besides the involvement of EBV in the pathogenesis of IM, its role in neoplastic transformation in nasopharyngeal carcinoma and Burkitt's lymphoma is diagrammatically depicted in **Web Image 14.8**.

290 Clinical Features (p. 351)

The incubation period of IM is 30-50 days in young adults, while children have shorter incubation period.

- 1. During prodromal period (first 3-5 days),** the symptoms are mild such as malaise, myalgia, headache and fatigue.
- 2. Frank clinical features (next 7-21 days)** commonly are fever, sore throat and bilateral cervical lymphadenopathy. Less commonly, splenomegaly (50% patients), hepatomegaly (10% cases), transient erythematous maculopapular eruption on the trunk and extremities, and neurologic manifestations are found.

LABORATORY FINDINGS (p. 352)

1. HAEMATOLOGIC FINDINGS. These are as under:

i) TLC: There is a moderate rise in total white cell count (10,000-20,000/ μ l) during 2nd to 3rd week after infection.

ii) DLC: There is an absolute lymphocytosis. The lymphocytosis is due to rise in normal as well as atypical T lymphocytes. There is relative neutropenia.

iii) Atypical T cells: Out of the total lymphocytes in the peripheral blood, essential to the diagnosis of IM is the presence of at least 10-12% *atypical T cells (or mononucleosis cells)* (**Web Image 14.9**). The mononucleosis cells are variable in appearance and are classed as Downey type I, II and III, of which Downey type I are found most frequently. The greatest number of atypical lymphocytes is found between 7th to 10th day of the illness and these cells may persist in the blood for up to 2 months.

iv) CD 4+ and CD8+ T cell counts. There is reversal of CD4+/CD8+ T cell ratio. There is marked decrease in CD4+ T cells while there is substantial rise in CD8+ T cells.

v) Platelets. There is generally thrombocytopenia in the first 4 weeks of illness.

2. SEROLOGIC DIAGNOSIS. The second characteristic laboratory finding is the demonstration of antibodies in the serum of infected patient.

i) Test for heterophile antibodies. Heterophile antibody test (Paul-Bunnell test) is used for making the diagnosis of IM. Currently, more sensitive and rapid kit-based test for heterophile antibodies, monospot, is also available.

ii) EBV-specific antibody tests. Specific antibodies against the viral capsid and nucleus of EBV can be demonstrated in patients who are negative for heterophile antibody test:

a) Specific antibody against EBV capsid antigen show elevated titers in over 90% cases during acute infection. IgM class antibody appears early and is thus most useful for diagnosis of acute infection. IgG class antibody appears later and persists throughout life.

b) Antibodies against EBV nuclear antigen are detected 3 to 6 weeks after infection and, like IgG class antibodies, persist throughout life.

c) Antibodies to early antigens may be elevated but are less useful for making diagnosis of IM.

d) IgA antibodies to EBV antigen are seen in patients of nasopharyngeal carcinoma or those who are at high risk of developing this EBV-induced cancer.

iii) EBV antigen detection. Detection of EBV DNA or proteins can be done in blood or CSF by PCR method.

3. LIVER FUNCTION TESTS. In addition, abnormalities of the liver function test are found in about 90% of cases. These include elevated serum levels of transaminases (SGOT and SGPT), rise in serum alkaline phosphatase and mild elevation of serum bilirubin.

□ LEUKAEMOID REACTIONS (p. 352)

Leukaemoid reaction is defined as a reactive excessive leucocytosis in the peripheral blood resembling that of leukaemia in a subject who does not have leukaemia. In spite of confusing blood picture, the clinical features of leukaemia such as splenomegaly, lymphadenopathy and haemorrhages are usually absent and the features of underlying disorder causing the leukaemoid reaction are generally obvious.

Leukaemoid reaction may be myeloid or lymphoid; the former is much more common.

MYELOID LEUKAEMOID REACTION (p. 353)

CAUSES. Majority of leukaemoid reactions involve the granulocyte series. It may occur in association with a wide variety of diseases. These are: Infections, intoxication, malignant diseases and severe haemorrhage and severe haemolysis.

LABORATORY FINDINGS. Myeloid leukaemoid reaction is characterised by the following laboratory features:

1. *Leucocytosis*, usually moderate, not exceeding 100,000/ μ l.
2. Proportion of *immature cells* mild to moderate, comprised by metamyelocytes, myelocytes (5-15%), and blasts fewer than 5% i.e. the blood picture simulates somewhat with that of CML (**Web Image 14.10, A**).
3. Infective cases may show *toxic granulation and Döhle bodies* in the cytoplasm of neutrophils.
4. *Neutrophil (or Leucocyte) alkaline phosphatase (NAP or LAP) score* in the cytoplasm of mature neutrophils in leukaemoid reaction is characteristically high and is very useful to distinguish it from chronic myeloid leukaemia in doubtful cases (**Web Image 14.10, B**).
5. *Cytogenetic studies* may be helpful in exceptional cases which reveal negative Philadelphia chromosome in myeloid leukaemoid reaction but positive in cases of CML.
6. *Additional features* include anaemia, normal-to-raised platelet count, myeloid hyperplasia of the marrow and absence of infiltration by immature cells in organs and tissues.

Web Table 14.3 sums up the features to distinguish myeloid leukaemoid reaction from chronic myeloid leukaemia.

LYMPHOID LEUKAEMOID REACTION (p. 353)

CAUSES. Lymphoid leukaemoid reaction may be found in the following conditions:

1. *Infections* e.g. infectious mononucleosis, cytomegalovirus infection, pertussis (whooping cough), chickenpox, measles, infectious lymphocytosis, tuberculosis.
2. *Malignant diseases* may rarely produce lymphoid leukaemoid reaction.

LABORATORY FINDINGS. These are:

1. Leucocytosis not exceeding 100,000/ μ l.
2. The differential white cell count reveals mostly mature lymphocytes simulating the blood picture found in cases of CLL.

HAEMATOLOGIC NEOPLASMS (LEUKAEMIAS-LYMPHOMAS): GENERAL (p. 353)

□ CLASSIFICATION: CURRENT CONCEPTS (p. 353)

Neoplastic proliferations of white blood cells—leukaemias and lymphomas, are the most important group of leucocyte disorders.

Historically, **leukaemias** have been classified on the basis of cell types predominantly involved into *myeloid* and *lymphoid*, and on the basis of

natural history of the disease, into *acute* and *chronic*. Thus, the main types of leukaemias have been: *acute myeloblastic leukaemia* and *acute lymphoblastic leukaemia* (AML and ALL), and *chronic myeloid leukaemia* and *chronic lymphocytic leukaemias* (CML and CLL); besides there are some other uncommon variants. In general, acute leukaemias are characterised by predominance of undifferentiated leucocyte precursors or leukaemic blasts and have a rapidly downhill course. Chronic leukaemias, on the other hand, have easily recognisable late precursor series of leucocytes circulating in large number as the predominant leukaemic cell type and the patients tend to have more indolent behaviour. The incidence of both acute and chronic leukaemias is higher in men than in women. ALL is primarily a disease of children and young adults, whereas AML occurs at all ages. CLL tends to occur in the elderly, while CML is found in middle age.

Similarly, over the years, **lymphomas** which are malignant tumours of lymphoreticular tissues have been categorised into two distinct clinicopathologic groups: *Hodgkin's lymphoma* or *Hodgkin's disease (HD)* characterised by pathognomonic presence of Reed-Sternberg cells, and a heterogenous group of *non-Hodgkin's lymphomas (NHL)*.

In the last 50 years, several classification systems have been proposed for leukaemias and lymphomas—clinicians favouring an approach based on clinical findings while pathologists have been interested in classifying them on morphologic features. More recent classification schemes have been based on cytochemistry, immunophenotyping, cytogenetics and molecular markers which have become available to pathologists and haematologists. The most recent classification scheme proposed by the World Health Organisation (WHO) in 2002 combines all tumours of haematopoietic and lymphoid tissues together. The basis of the WHO classification is the *cell type of the neoplasm* as identified by combined approach of clinical features and morphologic, cytogenetic and molecular characteristics, *rather than location of the neoplasm* (whether in blood or in tissues) because of the fact that haematopoietic cells are present in circulation as well as in tissues in general, and lymphoreticular tissues in particular.

Currently, neoplasms of haematopoietic and lymphoid tissues are considered as a unified group and are divided into 3 broad categories:

I. Myeloid neoplasms: This group includes neoplasms of myeloid cell lineage and therefore includes neoplastic proliferations of red blood cells, platelets, granulocytes and monocytes. There are 5 categories under myeloid series of neoplasms: myeloproliferative disorders, myeloproliferative/myelodysplastic diseases, myelodysplastic syndromes (MDS), and acute myeloid leukaemia (AML), acute biphenotypic leukaemias.

II. Lymphoid neoplasms: Neoplasms of lymphoid lineage include leukaemias and lymphomas of B, T or NK cell origin. This group thus includes B cell neoplasms (including plasma cell disorders), T cell neoplasms, NK cell neoplasms and Hodgkin's disease.

III. Histiocytic neoplasms: This group is of interest mainly due to neoplastic proliferations of histiocytes in Langerhans cell histiocytosis.

Besides the WHO classification, the FAB (French-American-British) Cooperative Group classification of lymphomas and leukaemias based on morphology and cytochemistry is also widely used.

□ **ETIOLOGY** (p. 354)

Like in most cancers, the exact etiology of leukaemias and lymphomas is not known. However, a number of factors have been implicated:

1. HEREDITY. There is evidence to suggest that there is role of family history, occurrence in identical twins and predisposition of these malignancies in certain genetic syndromes:

i) Identical twins: There is high concordance rate among identical twins if acute leukaemia develops in the first year of life. Hodgkin's disease is 99 times more common in identical twin of an affected case compared with general population, implicating genetic origin strongly.

ii) Family history. Families with excessive incidence of leukaemia have been identified.

iii) Genetic disease association. Acute leukaemia occurs with increased frequency with a variety of congenital disorders such as Down's, Bloom's, Klinefelter's and Wiskott-Aldrich's syndromes, Fanconi's anaemia and ataxia telangiectasia. Hodgkin's disease has familial incidence and with certain HLA type.

2. INFECTIONS. There is evidence to suggest that certain infections, particularly viruses, are involved in development of lymphomas and leukaemias:

i) Human T cell leukaemia-lymphoma virus I (HTLV-I) implicated in etiology of adult T cell leukaemia-lymphoma (ATLL).

ii) HTLV II for T cell variant of hairy cell leukaemia.

iii) Epstein-Barr virus (EBV) implicated in the etiology of Hodgkin's disease (mixed cellularity type and nodular sclerosis type), endemic variety of Burkitt's lymphoma, post-transplant lymphoma,

iv) HIV in diffuse large B-cell lymphoma and Burkitt's lymphoma.

v) Hepatitis C virus (HCV) in lymphoplasmacytic lymphoma.

vi) Human herpes virus 8 (HHV-8) in primary effusion lymphoma.

vii) Helicobacter pylori bacterial infection of gastric mucosa in MALT lymphoma of the stomach.

3. ENVIRONMENTAL FACTORS. Certain environmental factors are known to play a role in the etiology of leukaemias and lymphomas: Ionising radiation, chemical carcinogens and certain drugs.

4. ASSOCIATION WITH DISEASES OF IMMUNITY. Since lymphoid cells are the immune cells of the body, diseases with derangements of the immune system have higher incidence of haematopoietic malignancies e.g. Immunodeficiency diseases and autoimmune disease association.

□ PATHOGENESIS (p. 355)

It needs to be emphasised that since haematopoietic cells have a rapid turnover, they are more vulnerable to chromosomal damages and cytogenetic changes under influence of various etiologic factors listed above.

1. Genetic damage to single clone of target cells. Leukaemias and lymphomas arise following malignant transformation of a single clone of cells belonging to myeloid or lymphoid series, followed by proliferation of the transformed clone. Basic mechanism of malignant transformation is genetic damage to the DNA of the target white cells followed by proliferation, disrupting normal growth and differentiation.

2. Chromosomal translocations. A number of cytogenetic abnormalities have been detected in cases of leukaemias-lymphomas, most consistent of which are chromosomal translocations. In NHL, translocation involving antigen receptor genes, immunoglobulin genes, or overexpression of *BCL-2* protein may be seen. The most consistent chromosomal abnormality in various forms of acute and chronic leukaemias is Philadelphia (Ph) chromosome seen in 70-90% cases with CML, involving reciprocal translocation of parts of long arm of chromosome 22 to the long arm of chromosome 9 i.e. t(9;22) (**Web Image 14.11**).

3. Maturation defect. In acute leukaemia, the single most prominent characteristic of the leukaemic cells is a defect in maturation beyond the myeloblast or promyelocyte level in AML, and the lymphoblast level in ALL.

4. Myelosuppression. As the leukaemic cells accumulate in the bone marrow, there is suppression of normal haematopoietic stem cells, partly by physically replacing the normal marrow precursors, and partly by inhibiting normal haematopoiesis via cell-mediated or humoral mechanisms.

5. Organ infiltration. The leukaemic cells proliferate primarily in the bone marrow, circulate in the blood and infiltrate into other tissues such as lymph nodes, liver, spleen, skin, viscera and the central nervous system.

6. Cytokines. Presence of reactive inflammatory cells in the Hodgkin's disease is due to secretion of cytokines from the Reed Sternberg cells e.g. IL-5 (growth factor for eosinophils), IL-13 (for autocrine stimulation of RS cells) and transforming growth factor- β (for fibrogenesis).

Since myeloid trilineage stem cells further differentiate into 3 series of progenitor cells: erythroid, granulocyte-monocyte, and megakaryocytic series, therefore all examples of myeloid neoplasms fall into these three categories of cell-lines. Based on this concept, the WHO classification of myeloid neoplasms includes following 5 groups (**Web Image 14.12**):

- I. Myeloproliferative diseases
- II. Myelodysplastic/myeloproliferative diseases
- III. Myelodysplastic syndrome (MDS)
- IV. Acute myeloid leukaemia (AML)
- V. Acute biphenotypic leukaemia

Each of these groups is subclassified into further types as shown in **Web Table 14.4**.

MYELOPROLIFERATIVE DISEASES (p. 356)

The myeloproliferative disorders are a group of neoplastic proliferation of multipotent haematopoietic stem cells. Besides their common stem cell origin, these disorders are closely related, occasionally leading to evolution of one entity into another during the course of the disease.

CHRONIC MYELOID LEUKAEMIA (CML) (p. 357)

Definition and Pathophysiology (p. 357)

By WHO definition, CML is established by identification of the clone of haematopoietic stem cell that possesses the reciprocal translocation between chromosomes 9 and 22, forming Philadelphia chromosome. The t(9;22) involves fusion of BCR (breakpoint cluster region) gene on chromosome 22q11 with ABL (named after Abelson murine leukaemia virus) gene located on chromosome 9q34. The fusion product so formed is termed "Ph chromosome t(9;22)(q34;11), BCR/ABL" which should be positive for making the diagnosis of CML. This identification may be done by microsatellite PCR or by FISH. The underlying pathophysiologic mechanism of human CML is based on the observation that BCR/ABL fusion product proteins are capable of transforming haematopoietic progenitor cells *in vitro* and form malignant clone.

Clinical Features (p. 357)

Chronic myeloid (myelogenous, granulocytic) leukaemia comprises about 20% of all leukaemias and its peak incidence is seen in 3rd and 4th decades of life. A distinctive variant of CML seen in children is called juvenile CML. Both sexes are affected equally. The onset of CML is generally insidious. Some of the common presenting manifestations are: Anaemia, hypermetabolism, splenomegaly, bleeding tendencies, less common features include gout, visual disturbance, neurologic manifestations and priapism and juvenile CML is more often associated with lymph node enlargement

than splenomegaly. Other features are frequent infections, haemorrhagic manifestations and facial rash.

Laboratory Findings (p. 357)

I. BLOOD PICTURE. The typical blood picture in a case of CML at the time of presentation shows the following features (**Web Image 14.13**):

1. Anaemia. Anaemia is usually of moderate degree and is normocytic normochromic in type. Occasional normoblasts may be present.

2. White blood cells. Characteristically, there is marked leucocytosis (approximately 200,000/ μ l or more at the time of presentation). The natural history of CML consists of 3 phases—chronic, accelerated, and blastic.

◆ *Chronic phase of CML* begins as a myeloproliferative disorder and consists of excessive proliferation of myeloid cells of intermediate grade (i.e. myelocytes and metamyelocytes) and mature segmented neutrophils. Myeloblasts usually do not exceed 10% of cells in the peripheral blood and bone marrow. An increase in the proportion of basophils up to 10% is a characteristic feature of CML. A rising *basophilia* is indicative of impending blastic transformation. An *accelerated phase of CML* is also described in which there is progressively rising leucocytosis associated with thrombocytosis or thrombocytopenia and splenomegaly.

◆ *Accelerated phase* is defined as increasing degree of anaemia, blast count in blood or marrow between 10-20%, marrow basophils 20% or more, and platelet count falling below 1,00,000/ μ l.

◆ *Blastic phase or blast crisis in CML* fulfills the definition of acute leukaemia in having blood or marrow blasts \geq 20%. These blast cells may be myeloid, lymphoid, erythroid or undifferentiated and are established by morphology, cytochemistry, or immunophenotyping. Myeloid blast crisis in CML is more common and resembles AML. However, unlike AML, Auer rods are not seen in myeloblasts of CML in blast crisis.

3. Platelets. Platelet count may be normal but is raised in about half the cases.

II. BONE MARROW EXAMINATION. The findings are:

1. Cellularity. Generally, there is hypercellularity with total or partial replacement of fat spaces by proliferating myeloid cells.

2. Myeloid cells. The myeloid cells predominate in the bone marrow with increased myeloid-erythroid ratio. The differential counts of myeloid cells in the marrow show similar findings as seen in the peripheral blood with predominance of myelocytes.

3. Erythropoiesis. Erythropoiesis is normoblastic but there is reduction in erythropoietic cells.

4. Megakaryocytes. Megakaryocytes are conspicuous but are usually smaller in size than normal.

5. Cytogenetics. Cytogenetic studies on blood and bone marrow cells show the characteristic chromosomal abnormality called Philadelphia (Ph) chromosome seen in 90-95% cases of CML. Ph chromosome is formed by reciprocal balanced translocation between part of long arm of chromosome 22 and part of long arm of chromosome 9{(t(9;22) (q34;11))} forming product of fusion gene, BCR/ABL (see **Web Image 14.11**).

III. CYTOCHEMISTRY. The only significant finding on cytochemical stains is reduced scores of *neutrophil alkaline phosphatase (NAP)* which helps to distinguish CML from myeloid leukaemoid reaction in which case NAP scores are elevated (see **Web Image 14.10,B**, and **Web Table 14.3**).

Treatment and Complications (p. 358)

Insight into molecular mechanism of CML has brought about major changes in its therapy. The approach of modern therapy in CML is targeted at

296 removal of all malignant clones of cells bearing BCR/ABL fusion protein, so that patient reverts back to prolonged non-clonal haematopoiesis i.e. molecular remission from disease. This is achievable by the following approaches: Imatinib oral therapy, allogenic bone marrow (stem cell) transplantation, interferon- α and chemotherapy.

POLYCYTHAEMIA VERA (p. 359)

Definition and Pathophysiology (p. 359)

Polycythaemia vera (PV) is a clonal disorder characterised by increased production of all myeloid elements resulting in pancytosis (i.e. increased red cells, granulocytes, platelets) in the absence of any recognisable cause. The term 'polycythaemia vera' or 'polycythaemia rubra vera' is used for *primary or idiopathic polycythaemia* only and is the most common of all the myeloproliferative disorders. *Secondary polycythaemia or erythrocytosis*, on the other hand, may occur secondary to several causes e.g. high altitude, cardiovascular disease, pulmonary disease with alveolar hypoventilation, heavy smoking, inappropriate increase in erythropoietin (renal cell carcinoma, hydronephrosis, hepatocellular carcinoma, cerebellar haemangioblastoma, massive uterine leiomyoma).

The exact etiology of PV is not known but about a third of cases show inconsistent and varied chromosomal abnormalities.

Clinical Features (p. 359)

PV is a disease of late middle life and is slightly more common in males. The disease generally runs a chronic but slowly progressive course. Clinical features are the result of hyperviscosity, hypervolaemia, hypermetabolism and decreased cerebral perfusion.

1. Headache, vertigo, tinnitus, visual alterations syncope or even coma.
2. Increased risk of thrombosis due to accelerated atherosclerosis.
3. Increased risk of haemorrhages due to increased blood volume and intrinsic platelet dysfunction e.g. epistaxis, peptic ulcer disease.
4. Splenomegaly producing abdominal fullness.
5. Pruritus, especially after a bath.
6. Increased risk of urate stones and gout due to hyperuricaemia.

Laboratory Findings (p. 359)

1. Raised haemoglobin concentration (above 17.5 g/dl in males and 15.5 g/dl in females).
2. Erythrocytosis (above 6 million/ μ l in males and 5.5 million/ μ l in females).
3. Haematocrit (PCV) above 55% in males and above 47% in females.
4. Mild to moderate leucocytosis (15,000-25,000/ μ l) with basophilia and raised neutrophil alkaline phosphatase scores.
5. Thrombocytosis with defective platelet function.
6. Bone marrow examination reveals erythroid hyperplasia or panhyperplasia.
7. Cytogenetic abnormalities such as 20q, trisomy 8 and 9p are found in 30% cases of PV.
8. In PV, unlike secondary polycythaemia, erythropoietin levels in serum and urine are reduced.

Treatment and Complications (p. 359)

Since PV runs an indolent course, therapy is aimed at maintaining normal blood counts and relieve the patient of symptoms: Phlebotomy (venesection) by blood letting, anticoagulant therapy, chemotherapy, uricosuric drugs and interferon- α .

ESSENTIAL THROMBOCYTHAEMIA (p. 360)**Definition and Pathophysiology** (p. 360)

Essential thrombocythaemia (ET), also termed essential thrombocytosis or primary (idiopathic) thrombocythaemia is a clonal disorder characterised by markedly elevated platelet count in the absence of any recognisable stimulus. *Secondary or reactive thrombocytosis*, on the other hand, occurs in response to known stimuli such as: chronic infection, haemorrhage, postoperative state, chronic iron deficiency, malignancy, rheumatoid arthritis and postsplenectomy.

ET is an uncommon disorder and represents an overproduction of platelets from megakaryocyte colonies without any added stimulus but no clonal marker is available to distinguish primary from secondary thrombocytosis.

The underlying pathophysiologic mechanism in ET is the absence of control by thrombopoietin that regulates endomitosis in the megakaryocytes to produce platelets.

Clinical Features (p. 360)

1. Arterial or venous thrombosis.
2. Easy bruisability following minor trauma.
3. Spontaneous bleeding.
4. Transient ischaemic attack or frank stroke due to platelet aggregation in microvasculature of the CNS.

Laboratory Findings (p. 360)

1. Sustained elevation in platelet count (above 400,000 μl).
2. Blood film shows many large platelets, megakaryocyte fragments and hypogranular forms.
3. Consistently abnormal platelet functions, especially abnormality in platelet aggregation.
4. Bone marrow examination reveals a large number of hyperdiploid megakaryocytes and variable amount of increased fibrosis.

Treatment and Complications (p. 360)

ET runs a benign course and may not require any therapy.

CHRONIC IDIOPATHIC MYELOFIBROSIS (p. 360)**Definition and Pathophysiology** (p. 360)

Chronic idiopathic myelofibrosis (IMF), also called agnogenic (of unknown origin) myeloid metaplasia, primary myelofibrosis and myelosclerosis, is a clonal disorder characterised by proliferation of neoplastic stem cells at multiple sites outside the bone marrow (i.e. extramedullary haematopoiesis), especially in the liver and spleen, without an underlying etiology. Secondary myelofibrosis, on the other hand, develops in association with certain well-defined marrow disorders, or it is the result of toxic action of chemical agents or irradiation.

The exact etiology is not known. Several chromosomal abnormalities have been reported but without a specific cytogenetic abnormality.

Clinical Features (p. 360)

1. Anaemia with constitutional symptoms such as fatigue, weakness and anorexia.
2. Massive splenomegaly producing abdominal discomfort, pain and dyspnoea.
3. Hepatomegaly is present in half the cases.

4. Petechial and other bleeding problems are found in about 20% cases.
5. Less common findings are lymphadenopathy, jaundice, ascites, bone pain and hyperuricaemia.

Laboratory Findings (p. 360)

- i) Mild anaemia, leucocytosis and thrombocytosis.
- ii) Peripheral blood smear shows bizarre red cell shapes, tear drop poikilocytes, basophilic stippling, nucleated red cells, immature leucocytes (i.e. leucoerythroblastic reaction), basophilia and giant platelet forms.
- iii) Bone marrow aspiration is generally unsuccessful and yields 'dry tap'.
- iv) Examination of trephine biopsy shows focal areas of hypercellularity and increased reticulin network and variable amount of collagen in which clusters of megakaryocytes are seen well preserved.
- v) Extramedullary haematopoiesis can be documented by liver biopsy or splenic aspiration.

Treatment and Complications (p. 360)

Chronic idiopathic myelofibrosis does not require any specific therapy.

MYELOYDYSPLASTIC SYNDROMES (p. 361)

Definition and Classification (p. 361)

Myelodysplastic syndromes (MDS) are a heterogeneous group of haematopoietic clonal stem cell disorders having abnormal development of different marrow elements (i.e. dysmyelopoiesis), usually characterised by cytopenias, associated with cellular marrow and ineffective blood cell formation. These conditions are, therefore, also termed as preleukaemic syndromes or dysmyelopoietic syndromes.

There have been two main classification schemes for MDS:

FAB CLASSIFICATION OF MDS (1983): FAB (French-American-British) Cooperative Group classified MDS into the following 5 groups:

1. Refractory anaemia (RA).
2. Refractory anaemia with ringed sideroblasts (primary acquired sideroblastic anaemia) (RARS).
3. Refractory anaemia with excess blasts (RAEB).
4. Chronic myelomonocytic leukaemia (CMML).
5. Refractory anaemia with excess of blasts in transformation (RAEB-t).

As per FAB classification, the marrow may contain <30% myeloblasts in MDS and this was considered as the dividing line for distinguishing cases of AML (blasts >30%) from MDS.

WHO CLASSIFICATION OF MDS (2002): According to the WHO classification, patients with blast count of 20-30% and labelled as RAEB-t (group 5 above) in FAB classification have prognosis similar to patients with blast count above 30% (i.e. AML cases). Thus, as per WHO classification, marrow blast count for making the diagnosis of AML has been revised and brought down to 20%. Thus, patients with FAB category of RAEB-t (i.e. group 5 above) are currently considered and treated as cases of AML and therefore the term RAEB-t stands excluded from WHO MDS classification. Besides, the WHO classification excludes CMML (FAB category 4) from MDS and puts in the hybrid category of myelodysplastic/myeloproliferative disorder since CMML behaves like a myeloproliferative disorder; moreover refractory anaemia in it is not due to erythroid lineage which was considered as an inclusion criteria for MDS. Thus, the WHO classification of MDS consists of following 8 categories:

1. Refractory anaemia (RA)
2. Refractory anaemia with ringed sideroblasts (RARS)
3. Refractory cytopenia with multilineage dysplasia (RCMD)

4. RCMD with ringed sideroblasts (RCMD-RS).
5. Refractory anaemia with excess blasts (RAEB-1).
6. RAEB-2.
7. Myelodysplastic syndrome unclassified (MDS-U).
8. MDS with isolated del (5q).

Pathophysiology (p. 361)

Primary MDS is idiopathic but factors implicated in etiology are radiation exposure and benzene carcinogen. Secondary (therapy-related) MDS may occur following earlier anti-cancer treatment, aplastic anaemia treated with immunosuppressive therapy and in Fanconi's anaemia.

Clinical Features (p. 361)

In general, MDS is found more frequently in older people past 6th decade of life, with slight male preponderance. Therapy-related MDS is generally not age-related and may occur about a decade after anti-cancer therapy. At presentation the patient may have following features:

1. Anaemia appreciated by pallor, fatigue and weakness.
2. Fever.
3. Weight loss.
4. Sweet syndrome having neutrophilic dermatosis seen in some cases.
5. Splenomegaly seen in 20% cases of MDS.

Laboratory Findings (p. 361)

BLOOD FINDINGS. There is cytopenia affecting two (bi-) or all the three blood cell lines (pancytopenia):

1. *Anaemia:* Generally macrocytic or dimorphic.
2. *TLC:* Usually normal; cases of CMML may have high TLC but these cases in WHO classification of myeloid neoplasms have been put in a separate group of myelodysplastic/myeloproliferative diseases and not in MDS.
3. *DLC:* Neutrophils are hyposegmented and hypogranulated. Myeloblasts may be seen in PBF and their number correlates with marrow blasts count.
4. *Platelets:* Thrombocytopenia with large agranular platelets.

BONE MARROW FINDINGS. These are:

1. *Cellularity:* Normal to hypercellular to hypocellular.
2. *Erythroid series:* Dyserythropoiesis as seen by abnormally appearing nuclei and ring sideroblasts. Megaloblasts may be seen.
3. *Myeloid series:* Hypogranular and hyposegmented myeloid precursor cells. Myeloblasts increased depending upon the type of MDS.
4. *Megakaryocyte series:* Reduced in number and having abnormal nuclei.

Treatment and Complications (p. 362)

MDS is difficult to treat and may not respond to cytotoxic chemotherapy. Stem cell transplantation offers cure and longer survival.

ACUTE MYELOID LEUKAEMIA (p. 362)

Definition and Pathophysiology (p. 362)

Acute myeloid leukaemia (AML) is a heterogeneous disease characterised by infiltration of malignant myeloid cells into the blood, bone marrow and other tissues. AML is mainly a disease of adults (median age 50 years), while children and older individuals may also develop it.

AML develops due to inhibition of maturation of myeloid stem cells due to mutations. These mutations may be induced by several etiologic factors—heredity, radiation, chemical carcinogens (tobacco smoking, rubber, plastic, paint, insecticides etc) and long-term use of anti-cancer drugs but viruses do

300 not appear to have role in the etiology of AML. The defect induced by mutations causes accumulation of precursor myeloid cells of the stage at which the myeloid maturation and differentiation is blocked.

Classification (p. 362)

Currently, two main classification schemes for AML are followed:

FAB CLASSIFICATION. According to revised FAB classification system, a leukaemia is acute if the bone marrow consists of more than 30% blasts. Based on morphology and cytochemistry, FAB classification divides AML into 8 subtypes (M0 to M7) (**Web Table 14.5**).

WHO CLASSIFICATION (2002). WHO classification for AML differs from revised FAB classification in the following 2 ways:

1. It places limited reliance on cytochemistry for making the diagnosis of subtype of AML but instead takes into consideration *clinical, cytogenetic and molecular abnormalities* in different types. These features can be studied by multiparametric flow cytometry.
2. WHO classification for AML has revised and lowered the cut off percentage of *marrow blasts to 20%* from 30% in the FAB classification for making the diagnosis of AML. WHO classification of AML is included in Web Table 14.4.

Both FAB as well as WHO classification schemes for AML are followed in different settings depending upon the laboratory facilities available in various centres.

Clinical Features (p. 363)

AML and ALL share many clinical features and the two are difficult to distinguish on clinical features alone.

Clinical manifestations of AML are divided into 2 groups: those *due to bone marrow failure*, and those *due to organ infiltration*.

I. DUE TO BONE MARROW FAILURE. These are: Anaemia, bleeding manifestations, infections, and fever.

II. DUE TO ORGAN INFILTRATION. The clinical manifestations of AML are more often due to replacement of the marrow and other tissues by leukaemic cells. These features are: Pain and tenderness of bones (e.g. sternal tenderness), lymphadenopathy and enlargement of the tonsils, splenomegaly of moderate grade, hepatomegaly, leukaemic infiltration of the kidney, gum hypertrophy, chloroma or granulocytic sarcoma, meningeal involvement and other organ infiltrations include testicular swelling and mediastinal compression.

Laboratory Findings (p. 363)

I. BLOOD PICTURE. Findings of routine haematologic investigations are as under (**Web Image 14.14**):

1. Anaemia. Anaemia is almost always present in AML. It is generally severe, progressive and normochromic. A moderate reticulocytosis up to 5% and a few nucleated red cells may be present.

2. Thrombocytopenia. The platelet count is usually moderately to severely reduced (below 50,000/ μ l) but occasionally it may be normal. Bleeding tendencies in AML are usually correlated with the level of thrombocytopenia but most serious spontaneous haemorrhagic episodes develop in patients with fewer than 20,000/ μ l platelets. Acute promyelocytic leukaemia (M3) may be associated with a serious coagulation abnormality, disseminated intravascular coagulation (DIC).

3. White blood cells. The total WBC count ranges from subnormal-to-markedly elevated values. In 25% of patients, the total WBC count at

presentation is reduced to 1,000-4,000 / μ l. More often, however, there is progressive rise in white cell count which may exceed 100,000/ μ l in more advanced disease. Majority of leucocytes in the peripheral blood are blasts and there is often neutropenia due to marrow infiltration by leukaemic cells. The basic morphologic features of myeloblasts and lymphoblasts are summed up in Web Table 14.1. Typical characteristics of different forms of AML (M0 to M7) are given in Web Table 14.5. In some instances, the *identification of blast cells is greatly aided by the company they keep*. Some 'smear cells' in the peripheral blood representing degenerated leucocytes may be seen.

II. BONE MARROW EXAMINATION. The findings are:

1. Cellularity. Typically, the marrow is hypercellular but sometimes a 'blood tap' or 'dry tap' occurs. A dry tap in AML may be due to pancytopenia, but sometimes even when the marrow is so much filled with leukaemic cells that they cannot be aspirated because the cells are adhesive and enmeshed in reticulin fibres. In such cases, trephine biopsy should be done.

2. Leukaemic cells. The bone marrow is generally tightly packed with leukaemic blast cells. The diagnosis of the type of leukaemic cells, according to FAB classification, is generally possible with routine Romanowsky stains but cytochemical stains may be employed as an adjunct to Romanowsky staining for determining the type of leukaemia. The essential criteria for diagnosis of AML, as per FAB classification, was the presence of at least 30% blasts in the bone marrow. However, as per WHO classification, these criteria have been revised and lowered to 20% blasts in the marrow for labelling and treating a case as AML.

3. Erythropoiesis. Erythropoietic cells are reduced. Dyserythropoiesis, megaloblastic features and ring sideroblasts are commonly present.

4. Megakaryocytes. They are usually reduced or absent.

5. Cytogenetics. Chromosomal analysis of dividing leukaemic cells in the marrow shows karyotypic abnormalities in 75% of cases which may have a relationship to prognosis.

6. Immunophenotyping. AML cells express CD13 and CD33 antigens. M7 shows CD41 and CD42 positivity.

III. CYTOCHEMISTRY. Some of the commonly employed cytochemical stains, as an aid to classify the type of AML are as under:

1. Myeloperoxidase: Positive in immature myeloid cells containing granules and Auer rods but negative in M0 myeloblasts.

2. Sudan Black: Positive in immature cells in AML.

3. Periodic acid-Schiff (PAS): Positive in immature lymphoid cells and in erythroleukaemia (M6).

4. Non-specific esterase (NSE): Positive in monocytic series (M4 and M5).

5. Acid phosphatase: Focal positivity in leukaemic blasts in ALL and diffuse reaction in monocytic cells (M4 and M5).

IV. BIOCHEMICAL INVESTIGATIONS. These may be of some help:

1. Serum muramidase. Serum levels of lysozyme (i.e. muramidase) are elevated in myelomonocytic (M4) and monocytic (M5) leukaemias.

2. Serum uric acid. Because of rapidly growing number of leukaemic cells, serum uric acid level is frequently increased. The levels are further raised after treatment with cytotoxic drugs because of increased cell breakdown.

Treatment and Complications (p. 364)

The management of acute leukaemia involves the following aspects: (1) Treatment of anaemia and haemorrhage (2) Treatment and prophylaxis of infection (3) Cytotoxic drug therapy and (4) Bone marrow transplantation.

Remission rate with AML is lower (50-70%) than in ALL, often takes longer to achieve remission, and disease-free intervals are shorter. AML is most malignant of all leukaemias; median survival with treatment is 12-18 months.

LYMPHOID NEOPLASMS (p. 365)

Lymphoid cells constitute the immune system of the body. These cells circulate in the blood and also lie in the lymphoid tissues and undergo differentiation and maturation in these organs. The haematopoietic stem cells which form myeloid and lymphoid series, undergo further differentiation of lymphoid cells into B cells (including formation of plasma cells), T cells and NK cells. Lymphoid malignancies can be formed by malignant transformation of each of these cell lines. These lymphoid malignancies can range from indolent to highly aggressive human cancers.

Conventionally, malignancies of lymphoid cells in blood have been termed as lymphatic leukaemias and those of lymphoid tissues as lymphomas. Just like myeloid leukaemias discussed earlier, lymphoid leukaemias have been classified on the basis of survival and biologic course, into chronic and acute (*CLL and ALL*). Similarly, two clinicopathologically distinct groups of lymphomas are distinguished: *Hodgkin's lymphoma* or *Hodgkin's disease (HD)* and *non-Hodgkin's lymphomas (NHL)*.

However, while HD can be identified by the pathognomonic presence of Reed-Sternberg cells, there have been controversies and confusion in classification of other lymphoid cancers (i.e. NHL and lymphoid leukaemias). In order to resolve the issue, over the years several classification schemes have emerged for lymphoid cancers due to following two main reasons:

1. Biologic course of lymphoma-leukaemia. While some of the lymphoid malignancies initially present as leukaemias (i.e. in the blood and bone marrow), many others present as solid masses in the lymphoid tissues or in various other tissues, especially in the spleen, liver, bone marrow and other tissues. Still others may have initial presentation as either leukaemia or lymphomas. In fact, the line of demarcation for lymphoid malignancies is so blurred that during the biologic course of the disease, lymphoid leukaemia or lymphoma may spill over and transform to the other.

2. Technological advances. In recent times, modern diagnostic tools have become available to pathologists and haematologists which go much beyond making the diagnosis of lymphomas and leukaemias on clinical grounds combined with morphology and cytochemical stains alone. This includes methods for immunophenotyping, cytogenetics and molecular markers for the stage of differentiation of the cell of origin rather than location of the cell alone.

These aspects form the basis of current concept for WHO classification of malignancies of lymphoid cells of blood and lymphoreticular tissues as 'lymphoid neoplasms' as a unified group. However, it needs to be appreciated that in several centres in developing countries of the world, limited laboratory facilities are available. Thus, judiciously speaking, some of the older classification schemes for lymphoid malignancies need to be retained, while others can be dumped as historical.

I. HISTORICAL CLASSIFICATIONS. These classifications can be traced as under:

Morphologic classification. *Rappaport classification (1966)* proposed a clinically relevant morphologic classification based on two main features: *low-power microscopy* of the overall pattern of the lymph node architecture, and *high-power microscopy* revealing the cytology of the neoplastic cells. Based on these two features, Rappaport divided NHL into two major subtypes:

1. Nodular or follicular lymphomas
2. Diffuse lymphomas

Immunologic classifications. *Lukes-Collins classification (1974)* was proposed to correlate the type of NHL with the immune system because the identification of T and B-cells and their subpopulations had become possible in early 70s. Its subsequent modification was *Kiel classification (1981)*. The majority of NHL were B lymphocyte derivatives and arise from follicular centre cells (FCC). The FCC in the germinal centre undergo transformation to become large immunoblasts and pass through the four stages—*small cleaved cells* and *large cleaved cells*, *small non-cleaved cells* and *large non-cleaved cells*.

II. OLD CLINICOPATHOLOGIC CLASSIFICATIONS. Three clinically relevant classifications were proposed which cannot be readily abandoned:

FAB classification of lymphoid leukaemia. Although old, FAB classification for lymphoid leukaemia was initially based on morphology and cytochemistry into 3 types of ALL (L1 to L3), but was subsequently revised to include cytogenetic and immunologic features as well (**Web Table 14.6**).

Working Formulations for Clinical Usage (1982). This classification proposed by a panel of experts from National Cancer Institute of the US incorporates the best features of all previous classification systems, and as the name implies, has strong clinical relevance. Based on the natural history of disease and long-term survival studies, Working Formulations divides all NHLs into following 3 prognostic groups:

- ◆ *Low-grade NHL:* 5-year survival 50-70%
- ◆ *Intermediate-grade NHL:* 5-year survival 35-45%
- ◆ *High-grade NHL:* 5-year survival 25-35%.

Working Formulations still has many takers in several centres and is retained in **Web Table 14.7**.

REAL classification (1994). International Lymphoma Study Group (Harris et al) proposed another classification called *revised European-American classification of lymphoid neoplasms* abbreviated as REAL classification. This classification was based on the hypothesis that all forms of lymphoid malignancies (NHLs as well as lymphoblastic leukaemias) represent malignant counterparts of normal population of immune cells (B-cells, T-cells and histiocytes) present in the lymph node and bone marrow. Accordingly, it is considered essential to understand and correlate the differentiation stages of B and T-cells with various lymphoid malignancies (**Web Image 14.15**). REAL classification divides all lymphoid malignancies into two broad groups, each having further subtypes:

- ◆ Leukaemias and lymphomas of B-cell origin
- ◆ Leukaemias and lymphomas of T-cell origin

III. WHO CLASSIFICATION OF LYMPHOID NEOPLASMS (1999): In view of confusion surrounding the classification schemes of lymphoid cancer, Harris et al, who described REAL classification, evolved a consensus international classification of all lymphoid neoplasms together as a unified group (lymphoid leukaemias-lymphomas) under the aegis of the WHO. Although this classification has many similarities with REAL classification as regards identification of B and T cell types (**Web Image 14.15**), WHO classification has more classes. WHO classification takes into account morphology, clinical features, immunophenotyping, and cytogenetic of the tumour cells. Hence, on this basis, it is possible to know the stage of maturity of the neoplastic cell and thus has a better clinical and therapeutic relevance.

As per WHO classification scheme (**Web Table 14.8**), all lymphoid neoplasms (i.e. lymphoid leukaemias and lymphomas) fall into following 5 categories:

- I. Hodgkin's disease
- II. Precursor (Immature) B-cell malignancies
- III. Peripheral (Mature) B-cell malignancies

IV. Precursor (Immature) T-cell malignancies

V. Peripheral (Mature) T-cell and NK-cell malignancies

Thus, in the WHO classification of lymphoid neoplasms, Hodgkin's disease stands distinctive; remaining four categories listed above fall into 2 groups:

- 1) Precursor or immature lymphoid malignancies of B or T cell origin, meaning blastic type of leukaemias-lymphomas (mainly B or T-cell ALL); and
- 2) Peripheral or mature malignancies of B or T cell origin (meaning CLL and other lymphomas).

□ **GENERAL COMMENTS ON LYMPHOID MALIGNANCIES** (p. 368)

1. Overall frequency: Five major forms of lymphoid malignancies and their relative frequency are as under:

- i) NHL= 62%, *most common lymphoma*
- ii) HD= 8%
- iii) Plasma cell disorders = 15%
- iv) CLL= 9%, *most common lymphoid leukaemia*
- v) ALL= 4%

2. Incidence of B, T, NK cell malignancies: Majority of lymphoid malignancies are of B cell origin (75% of lymphoid leukaemias and 90% of lymphomas) while remaining are T cell malignancies; NK-cell lymphomas-leukaemias are rare.

3. Diagnosis: The diagnosis of lymphoma (both Hodgkin's and non-Hodgkin's) can only be reliably made on examination of lymph node biopsy. While the initial diagnosis of ALL and CLL can be made on CBC examination, bone marrow biopsy is done for genetic and immunologic studies.

4. Staging: In both HD and NHL, Ann Arbor staging is done for proper evaluation and planning treatment.

5. Ancillary studies: CT scan, PET scan and gallium scan are additional imaging modalities which can be used in staging HD and NHL cases.

6. Immune abnormalities: Since lymphoid neoplasms arise from immune cells of the body, immune derangements pertaining to the cell of origin may accompany these cancers. This is particularly so in B-cell malignancies and include occurrence of autoimmune haemolytic anaemia, autoimmune thrombocytopenia and hypogammaglobulinaemia.

□ **HODGKIN'S DISEASE** (p. 369)

Hodgkin's disease (HD) primarily arises within the lymph nodes and involves the extranodal sites secondarily. This group comprises about 8% of all cases of lymphoid neoplasms. The incidence of the disease has bimodal peaks—one in young adults between the age of 15 and 35 years and the other peak after 5th decade of life. The HD is more prevalent in young adult males than females. The classical diagnostic feature is the presence of *Reed-Sternberg (RS) cell* (or *Dorothy-Reed-Sternberg cell*).

CLASSIFICATION (p. 369)

Unlike NHL, there is only one universally accepted classification of HD i.e. *Rye classification* adopted since 1966. Rye classification divides HD into the following 4 subtypes:

1. Lymphocyte-predominance type
2. Nodular-sclerosis type
3. Mixed-cellularity type
4. Lymphocyte-depletion type.

However, the WHO classification of lymphoid neoplasms divides HD into 2 main groups:

- I. Nodular lymphocyte-predominant HD (a new type).
- II. Classic HD (includes all the 4 above subtypes in the Rye classification).
Central to the diagnosis of HD is the essential identification of *Reed-Sternberg cell* though this is not the sole criteria (see below).

The salient features of the 4 histologic subtypes of HD are summarised in **Web Table 14.9**.

REED-STERNBERG CELL (p. 369)

The diagnosis of Hodgkin's disease rests on identification of RS cells, though uncommonly similar cells can occur in infectious mononucleosis and other forms of lymphomas. Therefore, additional cellular and architectural features of the biopsy must be given due consideration for making the histologic diagnosis.

There are several morphologic variants of RS cells which characterise different histologic subtypes of HD (**Web Image 14.16**):

1. **Classic RS cell** is a large cell which has characteristically a bilobed nucleus appearing as mirror image of each other but occasionally the nucleus may be multilobed. Each lobe of the nucleus contains a prominent, eosinophilic, inclusion-like nucleolus with a clear halo around it, giving an owl-eye appearance. The cytoplasm of cell is abundant and amphophilic.
2. **Lacunar type RS cell** is smaller and in addition to above features has a pericellular space or lacuna in which it lies, which is due to artefactual shrinkage of the cell cytoplasm. It is characteristically found in nodular sclerosis variety of HD.
3. **Polyploid type (or popcorn or lymphocytic-histiocytic i.e. L and H) RS cells** are seen in lymphocyte predominance type of HD. This type of RS cell is larger with lobulated nucleus in the shape of popcorn.
4. **Pleomorphic RS cells** are a feature of lymphocyte depletion type. These cells have pleomorphic and atypical nuclei.

In general, the number of RS cells is inversely proportional to the number of lymphocytes in a particular histologic subtype of HD.

Immunophenotyping of RS cells reveals monoclonal lymphoid cell origin of RS cell from B-cells of the germinal centre in most subtypes of Hodgkin's disease. RS cells in all types of Hodgkin's diseases, except in lymphocyte predominance type, express immunoreactivity for CD15 and CD30 (**Web Image 14.17**). RS cells in lymphocyte predominance type, however, are negative for both CD15 and CD30, but positive for CD20.

RS cells are invariably accompanied by variable number of *atypical Hodgkin cells* which are believed to be precursor RS cells.

Morphologic Features (p. 370)

G/A The gross appearance of Hodgkin's and non-Hodgkin's lymphoma is much the same. Any lymph node group may be involved but most commonly affected are the cervical, supraclavicular and axillary groups. Initially, the lymph nodes are discrete and separate from one another but later the lymph nodes form a large matted mass due to infiltration into the surrounding connective tissue. Extranodal involvements produce either a discrete tumour or diffuse enlargement of the affected organ. The sectioned surface of the involved lymph nodes or extranodal organ involved appears grey-white and fishflesh-like. *Nodular sclerosis type HD* may show formation of nodules due to scarring while *mixed cellularity* and *lymphocyte depletion types HD* may show abundance of necrosis. Lymphomatous involvement of the liver, spleen and other organs may be diffuse or may form spherical masses similar to metastatic carcinoma.

M/E

I. CLASSIC HD:

As per WHO classification, classic group of HD includes 4 types of HD of older Rye classification:

1. Lymphocyte-predominance type. The lymphocyte-predominance type of HD is characterised by proliferation of small lymphocytes admixed with a varying number of histiocytes forming nodular or diffuse pattern.

- i) *Nodular form* is characterised by replacement of nodal architecture by numerous large neoplastic nodules.
- ii) *Diffuse form* does not have discernible nodules but instead there is diffuse proliferation of cells.

However, currently nodular form of lymphocyte predominant HD has been categorised separately due to its distinct immunophenotyping features and prognosis (discussed below).

For making the diagnosis, definite demonstration of RS cells is essential which are few in number, requiring a thorough search. In addition to typical RS cells, *polypliod variant* having polypliod, and twisted nucleus (popcorn-like) may be found in some cases.

2. Nodular-sclerosis type. Nodular sclerosis is the most frequent type of HD, seen more commonly in women than in men. It is characterised by two essential features (**Web Image 14.18, A**):

- i) *Bands of collagen*: Variable amount of fibrous tissue is characteristically present in the involved lymph nodes.
- ii) *Lacunar type RS cells*: Characteristic lacunar type of RS cells with distinctive pericellular halo are present. These cells appear lacunar due to the shrinkage of cytoplasm in formalin-fixed tissue. The pericellular halo is not seen if the tissue is fixed in Zenker's fluid.

3. Mixed-cellularity type. This form of HD generally replaces the entire affected lymph nodes by heterogeneous mixture of various types of apparently normal cells. These include proliferating lymphocytes, histiocytes, eosinophils, neutrophils and plasma cells. Some amount of fibrosis and focal areas of necrosis are generally present. Typical RS cells are frequent (**Web Image 14.18, B**).

4. Lymphocyte-depletion type. In this type of HD, the lymph node is depleted of lymphocytes. There are two variants of lymphocyte-depletion HD:

- i) *Diffuse fibrotic variant* is hypocellular and the entire lymph node is replaced by diffuse fibrosis, appearing as homogeneous, fibrillar hyaline material. The area of hyalinosis contains some lymphocytes, atypical histiocytes (Hodgkin cells), and numerous typical and atypical (pleomorphic) RS cells.
- ii) *Reticular variant* is much more cellular and consists of large number of atypical pleomorphic histiocytes, scanty lymphocytes and a few typical RS cells.

II. NODULAR LYMPHOCYTE-PREDOMINANT HD:

This is a newly described entity which is distinct from the classic HD described above. Its peculiarities are as under:

- i) These cases of HD have a nodular growth pattern (similar to nodular sclerosis type).
- ii) Like lymphocyte-predominant pattern of classic type, there is predominance of small lymphocytes with sparse number of RS cells.
- iii) These cases of HD have distinctive immunophenotyping—CD45 positive, epithelial membrane antigen (EMA) positive but negative for the usual markers for RS cells (CD15 and CD30 negative).
- iv) Though generally it has a chronic relapsing course, but some cases of this type of HD may transform into large B-cell NHL.

Clinical Features (p. 371)

Hodgkin's disease is particularly frequent among young and middle-aged adults. All histologic subtypes of HD, except the nodular sclerosis variety, are more common in males. The disease usually begins with superficial

lymph node enlargement and subsequently spreads to other lymphoid and non-lymphoid structures.

1. Most commonly, patients present with painless, movable and firm *lymphadenopathy*. The cervical and mediastinal lymph nodes are involved most frequently.
2. Approximately half the patients develop *splenomegaly* during the course of the disease. *Liver enlargement* too may occur.
3. *Constitutional symptoms* (type B symptoms) are present in 25-40% of patients. The most common is low-grade fever with night sweats and weight loss.

Other Laboratory Findings (p. 372)

Haematologic abnormalities:

1. A moderate, normocytic and normochromic *anaemia* is often present.
2. *Serum iron and TIBC* are low but marrow iron stores are normal or increased.
3. *Marrow infiltration* by the disease may produce marrow failure with leucoerythroblastic reaction.
4. *Routine blood counts* reveal moderate leukaemoid reaction. Cases with pruritus frequently show peripheral eosinophilia. Advanced disease is associated with absolute lymphopenia.
5. *Platelet count* is normal or increased.
6. *ESR* is invariably elevated.

Immunologic abnormalities:

1. There is progressive fall in immunocompetent T-cells with *defective cellular immunity*. There is reversal of CD4: CD8 ratio and anergy to routine skin tests.
2. *Humoral antibody production* is normal in untreated patients until late in the disease.

Staging (p. 327)

Following biopsy and histopathologic classification of HD, the extent of involvement of the disease (i.e. staging) is studied in order to select proper treatment and assess the prognosis. *Ann Arbor staging classification* takes into account both clinical and pathologic stage of the disease.

The suffix *A* or *B* are added to the above stages depending upon whether the three constitutional symptoms (fever, night sweats and unexplained weight loss exceeding 10% of normal) are absent (*A*) or present (*B*). The suffix *E* or *S* are used for extranodal involvement and splenomegaly respectively (**Web Table 14.10**).

Prognosis (p. 373)

With use of aggressive radiotherapy and chemotherapy, the outlook for Hodgkin's disease has improved significantly. Although several factors affect the prognosis, two important considerations in evaluating its outcome are the *extent of involvement by the disease (i.e. staging)* and the *histologic subtype*.

- ◆ With appropriate treatment, the overall 5 years survival rate for *stage I and II A* is as high as about 100%, while the advanced stage of the disease may have upto 50% 5-year survival rate.
- ◆ Patients with *lymphocyte-predominance type* of HD tend to have localised form of the disease and have excellent prognosis.
- ◆ *Nodular sclerosis* variety too has very good prognosis but those patients with larger mediastinal mass respond poorly to both chemotherapy and radiotherapy.

◆ *Mixed cellularity type* occupies intermediate clinical position between the lymphocyte predominance and the lymphocyte-depletion type, but patients with disseminated disease and systemic manifestations do poorly.

◆ *Lymphocyte-depletion type* is usually disseminated at the time of diagnosis and is associated with constitutional symptoms. These patients usually have the most aggressive form of the disease.

The salient features to distinguish Hodgkin's disease and non-Hodgkin's lymphoma are summarised in **Web Table 14.11**.

□ PRECURSOR (IMMATURE) B- AND T-CELL LEUKAEMIA/LYMPHOMA (SYNONYM: ACUTE LYMPHOBLASTIC LEUKAEMIA) (p. 373)

Lymphoid malignancy originating from precursor series of B or T cell (i.e. pre-B and pre-T) is the most common form of cancer of children under 4 years of age, together constituting 4% of all lymphoid malignancies. Pre-B cell ALL constitutes 90% cases while pre-T cell lymphoid malignancies comprise the remaining 10%. This group of lymphoid malignancies arise from more primitive stages of B or T cells but the stage of differentiation is not related to aggressiveness. Because of morphologic similarities, both these are presented together.

Clinical Features (p. 373)

PRECURSOR B-CELL LYMPHOBLASTIC LEUKAEMIA/LYMPHOMA. Most often, it presents as ALL in children; rarely presentation may be in the form of lymphoma in children or adults and it rapidly transforms into leukaemia.

PRECURSOR T-CELL LYMPHOBLASTIC LEUKAEMIA/LYMPHOMA. As the name implies, these cases may present as ALL or as lymphoma. Since the precursor T-cells differentiate in the thymus, this tumour often presents as mediastinal mass and pleural effusion and progresses rapidly to develop leukaemia in the blood and bone marrow.

Precursor T-cell lymphoma-leukaemia is, however, more aggressive than its B-cell counterpart.

Morphologic Features (p. 373)

Precursor B and T-cell ALL/lymphoma are indistinguishable on routine morphology. The diagnosis is made by following investigations:

1. Blood examination. Peripheral blood generally shows anaemia and thrombocytopenia, and may show leucopenia-to-normal TLC-to-leucocytosis. DLC shows large number of circulating lymphoblasts having round to convoluted nuclei, high nucleo-cytoplasmic ratio and absence of cytoplasmic granularity. It is important to distinguish AML from ALL; the morphologic features of myeloblasts and lymphoblasts are contrasted in **Web Table 14.1** for comparison (**Web Image 14.19**). Typical characteristics of different forms of ALL (L1 to L3) are given in **Web Table 14.6**.

2. Bone marrow examination. Marrow examination shows malignant undifferentiated cells of precursor B or T cell origin as demonstrated by immunophenotyping. Megakaryocytes are usually reduced or absent.

3. Cytochemistry. The findings are:

i) *Periodic acid-Schiff (PAS)*: Positive in immature lymphoid cells in ALL.

ii) *Acid phosphatase*: Focal positivity in leukaemic blasts in ALL.

iii) *Myeloperoxidase*: Negative in immature cells in ALL.

iv) *Sudan Black*: Negative in immature cells in ALL.

v) *Non-specific esterase (NSE)*: Negative in ALL.

Immunophenotyping. TdT (terminal deoxynucleotidyl transferase) is expressed by the nuclei of both pre-B and pre-T stages of differentiation of lymphoid cells. Specific diagnosis is established by following immunophenotyping:

Pre-B-cell type: Typically positive for pan-B cell markers CD19, CD10, CD9a.

Pre-T-cell type: Typically positive for CD1, CD2, CD3, CD5, CD7.

Cytogenetic analysis: Leukaemic blasts in pre-B-cell ALL show characteristic cytogenetic abnormality of t(9;22) i.e. Philadelphia positive-ALL.

Treatment (p. 374)

Treatment plan for children with pre-B or pre-T cell ALL is intensive remission induction with combination therapy. Patients presenting with pre-B or pre-T cell lymphoma are treated as a case of ALL.

The salient differences between the two main forms of acute leukaemia (AML and ALL) are summarised in **Web Table 14.12**.

□ PERIPHERAL(MATURE) B-CELL MALIGNANCIES (p. 374)

Peripheral or mature B-cell cancers are the most common lymphoid malignancies. These arise from the stage of lymphoid cells at which they become committed to B cell development, acquire surface characteristics and begin to secrete immunoglobulins. It includes following common examples.

B-CELL CLL/SLL (CHRONIC LYMPHOCYTIC LEUKAEMIA/ SMALL LYMPHOCYTIC LYMPHOMA) (p. 375)

As the name implies, this subtype may present as leukaemia or lymphoma constituting 9% of all lymphoid neoplasms. As lymphoid leukaemia (CLL), this is the most common form while as SLL it constitutes 7% of all NHLs. B-cell CLL/SLL occurs more commonly in middle and older age groups (over 50 years of age) with a male preponderance (male-female ratio 2:1).

Clinical Features

1. Features of *anaemia* such as gradually increasing weakness, fatigue and dyspnoea.
2. Enlargement of superficial *lymph nodes* is a very common finding. The lymph nodes are usually symmetrically enlarged, discrete and non-tender.
3. *Splenomegaly* and *hepatomegaly* are usual.
4. *Haemorrhagic manifestations* are found in case of CLL with thrombocytopenia.
5. *Susceptibility to Infections*, particularly of respiratory tract, are common in CLL.
6. *Less common findings* are: mediastinal pressure, tonsillar enlargement, disturbed vision, and bone and joint pains.

Morphologic Features

The diagnosis of CLL can usually be made on the basis of physical findings and blood smear examination (**Web Image 14.20**):

I. BLOOD PICTURE: The findings are:

1. **Anaemia.** Anaemia is usually mild to moderate and normocytic normochromic in type.
2. **White blood cells.** Typically, there is marked leucocytosis but less than that seen in CML (50,000-200,000/ μ l). Usually, more than 90% of leucocytes are mature small lymphocytes. Smudge or basket cells (degenerated forms) are present due to damaged nuclei of fragile malignant lymphocytes.
3. **Platelets.** The platelet count is normal or moderately reduced as an autoimmune phenomenon.

II. BONE MARROW EXAMINATION: The findings are:

1. Increased lymphocyte count (25-95%).
2. Reduced myeloid precursors.
3. Reduced erythroid precursors.

310 III. LYMPH NODE BIOPSY. Cases with lymphadenopathy at presentation show replacement of the lymph node by diffuse proliferation of well-differentiated, mature, small and uniform lymphocytes without any cytologic atypia or significant mitoses (**Web Image 14.21,B**). These cells are of monoclonal B-cell origin having immunologic features of mantle zone B-cells.

IV. OTHER INVESTIGATIONS: These are:

1. *Erythrocyte rosette test* with mouse red cells is positive in more than 95% of cases indicating that CLL is a monoclonal B cell neoplasm.
2. *Positive for B-cell markers* e.g. typically CD5 positive; other pan-B cell markers are CD19, CD20, CD23, surface immunoglobulins of various classes, monoclonal light chains (λ or κ type).
3. *Serum immunoglobulin levels* are generally reduced.
4. *Coombs' test* is positive in 20% cases.
5. *Cytogenetic abnormalities*, most commonly trisomy 12 seen in about 25% cases.

Treatment and Prognosis (p. 376)

Unlike other leukaemias, none of the available drugs and radiation therapy are capable of eradicating CLL and induce true complete remission. Treatment is, therefore, palliative and symptomatic, and with optimal management patient can usually lead a relatively normal life for several years.

Prognosis of CLL/SLL is generally better than CML since *blastic transformation seldom occurs*. Prognosis generally correlates with the stage of disease.

Generally, the course is indolent.

FOLLICULAR LYMPHOMA (p. 377)

In the earlier classification schemes, follicular lymphoma was known as nodular (poorly-differentiated) or follicular lymphoma (predominantly small/large cleaved cell type). Follicular lymphomas comprise approximately 22% of all NHLs. Follicular lymphomas occur in older individuals, most frequently presenting with painless peripheral lymphadenopathy which is usually waxing and waning type.

MORPHOLOGIC FEATURES. Following features are seen:

Lymph node biopsy: As the name suggests, follicular lymphoma is characterised by follicular or nodular pattern of growth. The nuclei of tumour cells may vary from predominantly small cleaved (or indented) to predominantly large cleaved variety (**Web Image 14.21,C**). In all follicular lymphomas, the tumour cells are positive for pan-B markers such as CD19 and CD20 along with expression of *BCL-2* protein (for distinction from normal germinal centre which is *BCL-2* negative).

Blood and bone marrow: Peripheral blood involvement as occurs in SLL is uncommon in this variety. Infiltration in the bone marrow is typically paratrabecular.

Diffuse Large B-cell Lymphoma (p. 377)

Diffuse large B-cell lymphoma, earlier termed as diffuse poorly-differentiated lymphocytic lymphoma or follicular centre cell diffuse large, cleaved/non-cleaved lymphoma, is the most common comprising about 31% of all NHLs. It occurs in older patients with mean age of 60 years. It may present primarily as a lymph node disease or at extranodal sites. Primary diffuse large B-cell lymphoma of CNS may also occur.

MORPHOLOGIC FEATURES. This variety is the diffuse counterpart of follicular large cleaved cell lymphoma i.e. it is composed of large cleaved

cells spread in a diffuse pattern. Immunophenotypic markers for pan-B cells (CD19, CD20) are positive, besides overexpression of surface immunoglobulins (IgM, IgG and light chains) and of *BCL-2* protein.

BURKITT'S LYMPHOMA/LEUKAEMIA (p. 377)

Burkitt's lymphoma/leukaemia is an uncommon tumour in adults but comprises about 30% of childhood NHLs. Burkitt's leukaemia corresponds to L3 ALL of FAB grouping and is uncommon. Three subgroups of Burkitt's lymphoma are recognised: *African endemic, sporadic and immunodeficiency-associated*.

M/E Tumour cells are intermediate in size, non-cleaved, and homogeneous in size and shape. The nuclei are round to oval and contain 2-5 nucleoli. The cytoplasm is basophilic and contains lipid vacuolation. The tumour cells have a very high mitotic rate, and therefore high cell death. This feature accounts for presence of numerous macrophages in the background of this tumour containing phagocytosed tumour debris giving it a 'starry sky' appearance (**Web Image 14.22**).

Burkitt's leukaemia is identified by classical appearance of monomorphic medium-sized cells having round nuclei, frequent mitoses, multiple nucleoli, and basophilic cytoplasm with vacuoles.

Burkitt's lymphoma is a high-grade tumour and is a very rapidly progressive human tumour.

EXTRANODAL MARGINAL ZONE B-CELL LYMPHOMA OF MALT TYPE (SYNONYM: MALTOMA) (p. 378)

This type comprises about 8% of all NHLs. In the earlier classification, it was included under SLL, but in the WHO scheme it is categorised separately for 2 reasons: etiologic association with *H. pylori* infection and occurrence at extranodal sites. Most frequent is gastric lymphoma of MALT type with its characteristic etiologic association with *H. pylori*; other extranodal sites for this subtype of NHL are intestine, orbit, lung, thyroid, salivary glands and CNS.

M/E It is characterised by diffuse infiltration by monoclonal small B lymphocytes which are negative for CD5.

MALT lymphoma has a good prognosis. Rarely, it may be more aggressive and may metastasise, or transform into diffuse large B-cell lymphoma.

MANTLE CELL LYMPHOMA (p. 378)

This subtype of NHL comprises about 8% of all NHLs. It was earlier included in SLL but has been identified as a separate subtype due to characteristic chromosomal translocation, t(11;14) and overexpression of *BCL-1* and surface immunoglobulins IgM and IgD protein.

M/E Mantle cell lymphoma arises from B-cells of mantle zone of normal lymphoid follicle.

HAIRY CELL LEUKAEMIA (p. 378)

Hairy cell leukaemia (HCL) is an unusual and uncommon form of B-cell malignancy characterised by presence of hairy cells in the blood and bone marrow and splenomegaly. It occurs in the older males. HCL is characterised clinically by the manifestations due to infiltration of reticuloendothelial organs (bone marrow, liver and spleen) and, hence, its previous name as *leukaemic reticuloendotheliosis*. Patients have susceptibility to infection with *M. avium intercellulare*.

M/E Laboratory diagnosis is made by the presence of pancytopenia due to marrow failure and splenic sequestration, and identification of characteristic

312 hairy cells in the blood and bone marrow. Hairy cells are abnormal mononuclear cells with hairy cytoplasmic projections which are seen in the bone marrow, peripheral blood and spleen. These cells are best recognised under phase contrast microscopy but may also be visible in routine blood smears (**Web Image 14.23**). These leukaemic 'hairy cells' have characteristically positive cytochemical staining for *tartrate-resistant acid phosphatase (TRAP)*.

□ **PERIPHERAL(MATURE) T-CELL MALIGNANCIES** (p. 379)

Peripheral or mature T-cell lymphoid malignancies are relatively less common compared to mature B cell cancers. These arise at the stage when the lymphoid cells migrate to thymus and become committed to T-cell differentiation by acquiring T cell antigen receptor genes.

MYCOSIS FUNGOIDES/SÉZARY SYNDROME (p. 379)

Mycosis fungoides is a slowly evolving cutaneous T-cell lymphoma occurring in middle-aged adult males.

MORPHOLOGICAL FEATURES. The condition is often preceded by eczema or dermatitis for several years (*premycotic stage*). This is followed by infiltration by CD4+T-cells in the epidermis and dermis as a plaque (*plaque stage*) and eventually as *tumour stage*. The disease may spread to viscera and to peripheral blood as a leukaemia characterised by Sézary cells having cerebriform nuclei termed as Sézary syndrome.

ADULT T-CELL LYMPHOMA/LEUKAEMIA (ATLL) (p. 379)

This is an uncommon T-cell malignancy but has gained much prominence due to association with retrovirus, human T-cell lymphotropic virus-1 (HTLV-1). The infection is acquired by blood transfusion, breast milk, sexual route or transplacentally. ATLL is common in Japan, the Caribbean and parts of the US but is rare in rest of the world.

MORPHOLOGICAL FEATURES. The involved lymph nodes have proliferation of CD4 positive large atypical T-cells with indented nuclei, called 'flower cells', most prominent in the paracortical zone. The blood also shows large pleomorphic T-cell leukaemia.

ANAPLASTIC LARGE T/NK CELL LYMPHOMA (p. 380)

This relatively newer entity is the T-cell counterpart of diffuse large B-cell lymphoma and was previously included under malignant histiocytosis or diagnosed as anaplastic carcinoma.

PERIPHERAL T-CELL LYMPHOMAS (p. 380)

This group includes a variety of aggressive T-cell lymphomas which are morphologically heterogeneous but have common immunotypic features of mature T-cells (CD4+, CD8+, or both). These are more common in young adults and often have bone marrow involvement at presentation. Subtypes of peripheral T-cell lymphomas include the following syndromes:

- i) Angioimmunoblastic T-cell lymphoma
- ii) Extranodal T/NK cell lymphoma of nasal type
- iii) Enteropathy type T-cell lymphoma
- iv) Hepatosplenic T-cell lymphoma.

□ **PLASMA CELL DISORDERS** (p. 380)

The plasma cell disorders are characterised by abnormal proliferation of immunoglobulin-producing cells and result in accumulation of monoclonal immunoglobulin in serum and urine. The group as a whole is known by

various synonyms such as *plasma cell dyscrasias*, *paraproteinaemias*, *dysproteinaemias* and *monoclonal gammopathies*.

The feature common to all plasma cell disorders is the neoplastic proliferation of cells derived from B-lymphocyte lineage. These disorders constitute 16% of all B-cell malignancies. Normally B lymphocytes have surface immunoglobulin molecules of both M and G heavy chains. However, in plasma cell disorders, the control over this process is lost and results in abnormal production of immunoglobulin that appears in the blood and urine. These disorders differ from other B-cell lymphoid malignancies in having monoclonal synthesis of immunoglobulins and lack of prominent lymphadenopathy.

MULTIPLE MYELOMA (p. 380)

Multiple myeloma is a multifocal malignant proliferation of plasma cells derived from a single clone of cells (i.e. monoclonal). The terms multiple myeloma is used interchangeably with myeloma. The tumour, its products (M component), and the host response result in the most important and most common syndrome in the group of plasma cell disorders that produces osseous as well as extraosseous manifestations. Multiple myeloma primarily affects the elderly (peak incidence in 5th-6th decades) and increases in incidence with age. It is rare under the age of 40. Myeloma is more common in males than females.

Etiology and Pathogenesis (p. 381)

Myeloma is a monoclonal proliferation of B-cells. The etiology of myeloma remains unknown. However, following factors and abnormalities have been implicated:

1. Radiation exposure
2. Epidemiologic factors
3. Karyotypic abnormalities
4. Oncogenes-antioncogenes
 - i) Overexpression of MYC and RAS
 - ii) Mutation in *p53* and *RB* growth-suppressing antioncogene.

Based on above, the **molecular pathogenesis** of multiple myeloma and its major manifestations can be explained as under and is schematically illustrated in **Web Image 14.24**:

1. Cell-surface *adhesion molecules* bind myeloma cells to bone marrow stromal cells and extracellular matrix proteins.
2. This binding triggers *adhesion-mediated signaling* and mediates *production of several cytokines* by fibroblasts and macrophages of the marrow. These include: IL-6, VEGF, TGF β , TNF- α IL-1, lymphotoxin, macrophage inhibitory factor-1 α (MIP-1 α) and receptor activator of nuclear factor- κ B (RANK) ligand.
3. Adhesion-mediated signaling affects the cell cycle via cyclin-D and p21 causing abnormal production of *myeloma (M) proteins*.
4. *IL-6 cytokine* plays a central role in cytokine-mediated signaling and causes proliferation as well as cell survival of tumour cells via its antiapoptotic effects on tumour cells.
5. Certain cytokines produced by myeloma cells bring about bony destruction by acting as *osteoclast-activating factor (OAF)*. These are: IL-1, lymphotoxin, VEGF, macrophage inhibitory factor-1 α (MIP-1 α), receptor activator of NF- κ B ligand, and tumour necrosis factor (TNF).
6. Other effects of adhesion-mediated and cytokine-mediated signaling are development of *drug resistance and migration* of tumour cells in the bone marrow milieu.

A. OSSEOUS (BONE MARROW) LESIONS. In more than 95% of cases, multiple myeloma begins in the bone marrow. In majority of cases, the disease involves multiple bones. By the time the diagnosis is made, most of the bone marrow is involved. Most commonly affected bones are those with red marrow i.e. skull, spine, ribs and pelvis, but later long bones of the limbs are also involved (**Web Image 14.25**).

G/A The normal bone marrow is replaced by soft, gelatinous, reddish-grey tumours. The affected bone usually shows focal or diffuse osteoporosis.

M/E The diagnosis of multiple myeloma can be usually established by examining bone marrow aspiration from an area of bony rarefaction. However, if the bone marrow aspiration yields dry tap or negative results, biopsy of radiologically abnormal or tender site is usually diagnostic. The following features characterise a case of myeloma:

i) **Cellularity:** There is usually hypercellularity of the bone marrow.

ii) **Myeloma cells:** Myeloma cells constitute $\geq 10\%$ of the marrow cellularity. These cells may form clumps or sheets, or may be scattered among the normal haematopoietic cells. Myeloma cells may vary in size from small, differentiated cells resembling normal plasma cells to large, immature and undifferentiated cells. Binucleate and multinucleate cells are sometimes present. The nucleus of myeloma cell is commonly eccentric similar to plasma cells but usually lacks the cart-wheel chromatin pattern seen in classical plasma cells. Nucleoli are frequently present. The cytoplasm of these cells is abundant and basophilic with perinuclear halo, vacuolisation and contains Russell bodies consisting of hyaline globules composed of synthesised immunoglobulin (**Web Image 14.26**).

B. EXTRAOSSEOUS LESIONS. Some of the commonly involved sites are as under:

1. **Blood.** Approximately 50% of patients with multiple myeloma have a few atypical plasma cells in the blood. Other changes in the blood in myeloma are the presence of anaemia (usually normocytic normochromic type), marked red cell rouleaux formation due to hyperviscosity of blood, and an elevated ESR.

2. **Myeloma kidney.** Renal involvement in myeloma called myeloma nephrosis occurs in many cases. The main mechanism of myeloma kidney is by filtration of light chain proteins (Bence Jones proteins) which are precipitated in the distal convoluted tubules in combination with Tamm-Horsfall proteins as tubular casts. The casts may be surrounded by some multinucleate giant-cells and a few inflammatory cells.

3. **Myeloma neuropathy.** Infiltration of the nerve trunk roots by tumour cells produces nonspecific polyneuropathy. Pathologic fractures, particularly of the vertebrae, may occur causing neurologic complications.

4. **Systemic amyloidosis.** Systemic primary generalised amyloidosis (AL amyloid) may occur in 10% cases of multiple myeloma and involve multiple organs and systems.

Clinical Features (p. 383)

Bone pain is the most common symptom. *Susceptibility to infections, renal failure* occurs in about 25% of patients. *Anaemia* occurs in about 80% of patients. *Bleeding tendencies* may appear in some patients. *Hyperviscosity syndrome* owing to hyperglobulinaemia may produce headache, fatigue, visual disturbances and haemorrhages. *Neurologic symptoms* occur in a minority of patients.

Biochemical abnormalities: These include the following:

- i) hypercalcaemia due to destruction of bone;
- ii) hyperuricaemia from necrosis of tumour mass and from uraemia related to renal failure; and
- iii) increased β -2 microglobulins and other globulins in urine and serum.

POEMS syndrome is seen in about 1% cases of myeloma and includes simultaneous manifestations of *polyneuropathy, organomegaly, endocrinopathy, multiple myeloma and skin changes*.

Diagnosis (p. 383)

The diagnosis of myeloma is made by classic *triad* of features:

1. *Marrow plasmacytosis* of more than 10%
2. Radiologic evidence of *lytic bony lesions*
3. Demonstration of serum and/or urine *M component*.

There is rise in the total serum protein concentration due to *paraproteinaemia* but normal serum immunoglobulins (IgG, IgA and IgM) and albumin are depressed. Paraproteins are abnormal immunoglobulins or their parts circulating in plasma and excreted in urine. About two-third cases of myeloma excrete Bence Jones (light chain) proteins in the urine, consisting of either kappa (κ) or lambda (λ) light chains, along with presence of Bence Jones paraproteins in the serum. On serum electrophoresis, the paraprotein usually appears as a single narrow homogeneous *M-band* component, most commonly in the region of γ -globulin (**Web Image 14.27**). Most frequent paraprotein is *IgG* seen in about 50% cases of myeloma, *IgA* in 25%, and *IgD* in 1%, while about 20% patients have only light chains in serum and urine (*light chain myeloma*). *Non-secretory myeloma* is absence of M-band on serum and/or electrophoresis but presence of other two features out of triad listed above. Though the commonest cause of paraproteinaemias is multiple myeloma, certain other conditions which may produce serum paraproteins need to be distinguished. These are as under:

- ◆ Monoclonal gammopathy of undetermined significance (MGUS)
- ◆ Waldenström's macroglobulinaemia
- ◆ Benign monoclonal gammopathy
- ◆ B-cell lymphomas
- ◆ CLL
- ◆ Light chain disease
- ◆ Heavy chain disease
- ◆ Cryoglobulinaemia.

LOCALISED PLASMACYTOMA (p. 384)

Two variants of myeloma which do not fulfil the criteria of classical triad are the localised form of *solitary bone plasmacytoma* and *extramedullary plasmacytoma*. Both these are associated with M component in about a third of cases and occur in young individuals. Solitary bone plasmacytoma is a lytic bony lesion without marrow plasmacytosis. Extramedullary plasmacytoma involves most commonly the submucosal lymphoid tissue of nasopharynx or paranasal sinuses. Both variants have better prognosis than the classic multiple myeloma. *Plasma cell granuloma*, on the other hand, is an inflammatory condition having admixture of other inflammatory cells with mature plasma cells, which can be easily distinguished by a discernible observer.

WALDENSTRÖM'S MACROGLOBULINAEMIA (p. 384)

Waldenström's macroglobulinaemia is an uncommon malignant proliferation of monoclonal B lymphocytes which secrete IgM paraproteins called macroglobulins as they have high molecular weight. The condition is more common in men over 50 years of age and behaves clinically like a slowly progressive lymphoma.

The exact etiology is not known but a possible relationship of IgM macroglobulin with myelin-associated glycoprotein which is lost in degenerating diseases has been suggested.

Morphologic Features

◆ *Like myeloma*, the disease involves the bone marrow, but unlike myeloma it usually does not cause extensive bony lesions or hypercalcaemia.

◆ *Unlike myeloma and more like small lymphocytic lymphoma*, enlargement of lymph nodes, spleen and liver due to infiltration by similar type of cells is present more frequently.

Clinical Features

1. *Hyperviscosity syndrome*
2. *Moderate organomegaly*
3. *Anaemia*
4. *Bleeding tendencies.*

Diagnosis

1. Pleomorphic bone marrow infiltration
2. Raised total serum protein concentration
3. Raised serum monoclonal M component which is due to IgM paraprotein
4. Elevated ESR
5. Normocytic normochromic anaemia.

HEAVY CHAIN DISEASES (p. 384)

Heavy chain diseases are rare malignant proliferations of B-cells accompanied by monoclonal excess of one of the heavy chains. Depending upon the type of excessive heavy chain, three types— γ , α and μ , of heavy chain diseases are distinguished:

MONOCLONAL GAMMOPATHY OF UNDETERMINED SIGNIFICANCE (MGUS) (p. 384)

A relatively recently described entity, monoclonal gammopathy of undetermined significance (MGUS), is increasingly diagnosed in asymptomatic healthy aging population—1% at 50 years of age and in 10% individuals older than 75 years. This makes it the most common form of plasma cell dyscrasia. The defining criteria for MGUS are as under:

- i) M-protein in serum <3 gm/dl
- ii) Marrow plasmacytosis <10%
- iii) No evidence of other B-cell proliferative disorder
- iv) Absence of myeloma-related end-organ tissue damage (i.e. absence of lytic bone lesions, high calcium level, anaemia).

The condition needs to be cautiously distinguished from myeloma and long term follow-up is required. In fact, MGUS has been considered as a forerunner of multiple myeloma in many studies because MGUS has been found to have the same chromosomal abnormalities as in myeloma.

□ LYMPH NODE METASTATIC TUMOURS (p. 385)

The regional lymph nodes draining the site of a primary malignant tumour are commonly enlarged. This enlargement may be due to benign *reactive hyperplasia* or *metastatic tumour deposits*.

1. **Benign reactive hyperplasia**, is due to immunologic reaction by the lymph node in response to tumour-associated antigens. It may be expressed as sinus histiocytosis, follicular hyperplasia, plasmacytosis and occasionally may show non-caseating granulomas.

2. **Metastatic deposits** in regional lymph nodes occur most commonly from carcinomas and malignant melanoma. Sarcomas often disseminate via haematogenous route but uncommonly may metastasise to the regional

lymph nodes. The pushing margins of advancing metastatic tumour in stroma of lymph node is characteristically well demarcated. Areas of necrosis are frequent in metastatic carcinomas (**Web Image 14.28**).

Langerhans' cell histiocytosis (LCH) is a group of rare malignant proliferations of dendritic cells or macrophages and includes three clinicopathologically related conditions occurring in children: eosinophilic granuloma, Hand-Schüller-Christian disease and Letterer-Siwe syndrome. Earlier, this group was referred to as histiocytosis-X but now following facts about this group are known:

◆ **Firstly**, histiocytosis-X are not proliferations of unknown origin (X-for unknown) but proliferating cells are actually Langerhans' cells of marrow origin. Langerhans' cells are normally present mainly in the epidermis of the skin but also in some other organs.

◆ **Secondly**, the three conditions included under histiocytosis-X are actually different expression of the same basic disorder. This concept has emerged from 2 features:

- i) Demonstration of common antigens on these cells by *immunohistochemical stains* for S-100 protein, CD1a and HLA-DR.
- ii) Electron microscopic demonstration of *histiocytosis-X bodies* or *Birbeck granules* in the cytoplasm. These are rod-shaped structures having dilated tennis-racket like terminal end. Their function is not known but they arise from receptor-mediated endocytosis of langerin found in human epidermal cells, a protein involved in Birbeck granule biosynthesis.

EOSINOPHILIC GRANULOMA (p. 385)

Unifocal eosinophilic granuloma is more common (60%) than the multifocal variety which is often a component of Hand-Schüller-Christian disease (described below). Most of the patients are children and young adults, predominantly males.

M/E The lesion consists largely of closely-packed aggregates of macrophages admixed with variable number of eosinophils (**Web Image 14.29**). The cytoplasm of these macrophages may contain rod-shaped inclusions called *histiocytosis-X bodies* or Birbeck granules, best seen by electron microscopy.

HAND-SCHÜLLER-CHRISTIAN DISEASE (p. 385)

A triad of features consisting of *multifocal bony defects*, *diabetes insipidus* and *exophthalmos* is termed Hand-Schüller-Christian disease. The disease develops in children under 5 years of age. The multifocal lytic bony lesions may develop at any site.

LETTERER-SIWE DISEASE (p. 386)

Letterer-Siwe disease is an acute disseminated form of LCH occurring in infants and children under 2 years of age. The disease is characterised by hepatosplenomegaly, lymphadenopathy, thrombocytopenia, anaemia and leucopenia. There is generalised hyperplasia of tissue macrophages in various organs.

□ **NORMAL STRUCTURE** (p. 386)

The spleen is the largest lymphoid organ of the body. Under normal conditions, the average weight of the spleen is about 150 gm in the adult.

318 G/A The spleen consists of homogeneous, soft, dark red mass called the *red pulp* and long oval grey-white nodules called the *white pulp (malpighian bodies)*.

M/E The red pulp consists of a network of thin-walled venous sinuses and adjacent blood spaces. The blood spaces contain blood cells, lymphocytes and macrophages and appear to be arranged in cords called *splenic cords* or *cords of Billroth*. The white pulp is made up of lymphocytes surrounding an eccentrically placed arteriole. The periarteriolar lymphocytes are mainly T-cells, while at other places the lymphocytes have a germinal centre composed principally of B-cells surrounded by densely packed lymphocytes.

The spleen is a lymphoreticular organ that performs at least the following four functions:

1. *Immune responses.*
2. *Sequestering* and removing normal and abnormal blood cells.
3. *Regulating portal blood flow.*
4. *Extramedullary haematopoiesis.*

□ **SPLENOMEGALY** (p. 386)

Enlargement of the spleen termed splenomegaly, occurs in a wide variety of disorders which increase the cellularity and vascularity of the organ. Many of the causes are exaggerated forms of normal splenic function. Splenic enlargement may occur as a result of one of the following pathophysiological mechanisms:

- I. Infections
- II. Disordered immunoregulation
- III. Altered splenic blood flow
- IV. Lymphohaematogenous malignancies
- V. Diseases with abnormal erythrocytes
- VI. Storage diseases
- VII. Miscellaneous causes.

Based on these mechanisms, an abbreviated list of causes of splenomegaly is given in **Web Table 14.13**. Most of these conditions have been discussed elsewhere.

The **degree of splenomegaly** varies with the disease entity:

◆ **Mild enlargement (upto 5 cm)** occurs in CVC of spleen in CHF, acute malaria, typhoid fever, bacterial endocarditis, SLE, rheumatoid arthritis and thalassaemia minor.

◆ **Moderate enlargement (upto umbilicus)** occurs in hepatitis, cirrhosis, lymphomas, infectious mononucleosis, haemolytic anaemia, splenic abscesses and amyloidosis.

◆ **Massive enlargement (below umbilicus)** occurs in CML, myeloid metaplasia with myelofibrosis, storage diseases, thalassaemia major, chronic malaria, leishmaniasis and portal vein obstruction.

Mild to moderate splenomegaly is usually symptomless, while a massively enlarged spleen may cause dragging sensation in the left hypochondrium. Spleen becomes palpable only when it is enlarged.

□ **HYPERSPLENISM** (p. 387)

The term hypersplenism is used for conditions which cause excessive removal of erythrocytes, granulocytes or platelets from the circulation. The mechanism for excessive removal could be due to increased sequestration of cells in the spleen by altered splenic blood flow or by production of antibodies against respective blood cells. The criteria for hypersplenism are as under:

1. Splenomegaly.
2. Splenic destruction of one or more of the cell types in the peripheral blood causing anaemia, leucopenia, thrombocytopenia, or pancytopenia.

3. Bone marrow cellularity is normal or hyperplastic.
4. Splenectomy is followed by improvement in the severity of blood cytopenia.

□ EFFECTS OF SPLENECTOMY (p. 387)

In view of the prominent role of normal spleen in sequestration of blood cells, splenectomy in a normal individual is followed by significant haematologic alterations. Induction of similar haematologic effects is made use in the treatment of certain pathologic conditions. The blood changes following splenectomy are as under:

1. **Red cells:** There is appearance of target cells in the blood film. Howell-Jolly bodies are present in the red cells as they are no longer cleared by the spleen.
2. **White cells:** There is leucocytosis reaching its peak in 1-2 days after splenectomy. There is shift-to-left of the myeloid cells with appearance of some myelocytes.
3. **Platelets:** Within hours after splenectomy, there is rise in platelet count upto 3-4 times normal.

□ SPLENIC RUPTURE (p. 388)

The most common cause of splenic rupture or laceration is blunt trauma. The trauma may be direct or indirect. Non-traumatic or spontaneous rupture occurs in an enlarged spleen but almost never in a normal spleen. In acute infections, the spleen can enlarge rapidly to 2 to 3 times its normal size causing acute splenic enlargement termed *acute splenic tumour* e.g. in pneumonias, septicaemia, acute endocarditis etc. Some of the other common causes of spontaneous splenic rupture are splenomegaly due to chronic malaria, infectious mononucleosis, typhoid fever, splenic abscess, thalassaemia and leukaemias.

□ TUMOURS (p. 388)

◆ **Primary tumours** of the spleen are extremely rare. The only notable benign tumours are haemangiomas and lymphangioma, while examples of primary malignant neoplasms of haematopoietic system i.e. Hodgkin's disease and non-Hodgkin's lymphomas. Non-haematopoietic tumours of the spleen such as angiosarcoma are rare.

◆ **Secondary tumours** occur late in the course of disease and represent haematogenous dissemination of the malignant tumour. Splenic metastases appear as multiple nodules. The most frequent primary sites include: lung, breast, prostate, colon and stomach. Rarely, direct extension from an adjacent malignant neoplasm may occur.

THYMUS (p. 388)

□ NORMAL STRUCTURE (p. 388)

The thymus gland is a complex lymphoreticular organ lying buried within the mediastinum. At birth, the gland weighs 10-35 gm and grows in size upto puberty, following which there is progressive involution in the elderly. In the adult, thymus weighs 5-10 gm.

The histologic structure of the lobule shows *outer cortex* and *inner medulla*. Both cortex and medulla contain two types of cells: epithelial cells and lymphocytes (thymocytes).

The main **function** of the thymus is in the cell-mediated immunity by T-cells and by secretion of thymic hormones such as *thymopoietin* and *thymosin- α_1* .

320 □ **THYMIC HYPOPLASIA AND AGENESIS** (p. 388)

Thymic hypoplasia and agenesis are acquired and congenital disorders respectively in which the gland is either unusually small or absent. These conditions are various types of hereditary (primary) immunodeficiency diseases such as DiGeorge's syndrome, severe combined immunodeficiency and reticular dysgenesis.

□ **THYMIC HYPERPLASIA** (p. 388)

Enlargement of the thymus or failure to involute produces thymic hyperplasia. Hyperplasia is usually associated with appearance of lymphoid follicles in the medulla of the thymus and is called *thymic follicular hyperplasia*. Most common cause of follicular hyperplasia of the thymus is myasthenia gravis.

□ **THYMOMA** (p. 388)

Most common primary tumour present in the anterosuperior mediastinum is thymoma. Although thymus is a lymphoepithelial organ, the term thymoma is used for the tumour of epithelial origin. Most of the patients are adults.

G/A The tumour is spherical, measuring 5-10 cm in diameter with an average weight of 150 gm. Sectioned surface is soft, yellowish, lobulated and may be either homogeneous or contain cysts due to the presence of haemorrhage and necrosis.

M/E The tumour has a thick fibrous capsule from which extend collagenous septa into the tumour dividing it into lobules. The histology of lobule shows various patterns. The tumour consists of neoplastic epithelial cells and variable number of non-neoplastic lymphocytes. Thymoma may be of following types:

Benign thymoma is more common.

Malignant thymoma is less common and is further of 2 types:

Type 1 is cytologically benign looking but aggressive and invades the mediastinal structures locally.

Type 2 is also called thymic carcinoma and has cytologic features of cancer.

◆ **SELF ASSESSMENT**

- The following myeloid cells partake in mitosis except:**
 - Myelocytes
 - Metamyelocytes
 - Promyelocytes
 - Myeloblast
- Basophils are increased in:**
 - Bronchial asthma
 - CML
 - Angioneurotic oedema
 - Corticosteroid therapy
- Heterophile antibody used to detect EBV infection in infectious mononucleosis is:**
 - IgA
 - IgD
 - IgG
 - IgM
- Atypical lymphoid cells (mononucleosis cells) in infectious mononucleosis are:**
 - Monocytes
 - CD8 + T lymphocytes
 - Killer T cells
 - B-lymphocytes
- Leucocyte alkaline phosphatase (LAP) scores are elevated in:**
 - AML
 - CML
 - Myeloid metaplasia
 - Myeloid leukaemoid reaction
- Radiation exposure is related to the following types of leukaemias except:**
 - AML
 - CML
 - ALL
 - CLL

7. Gum hypertrophy is a feature of the following FAB type of AML: 321
 A. FAB type M1 B. FAB type M2
 C. FAB type M3 D. FAB type M4
8. Which of the following is *not* a type of paracortical lymphoid hyperplasia:
 A. Castleman's disease
 B. Angioimmunoblastic lymphadenopathy
 C. Dermatopathic lymphadenopathy
 D. Dilantin lymphadenopathy
9. Auer rods are derived from:
 A. RNA B. DNA
 C. Primary granules D. Secondary granules
10. What is *not* true about Pelger Huet anomaly:
 A. Autosomal dominant
 B. May be acquired
 C. Is characterised by bilobed neutrophils
 D. Causes severe impairment of neutrophil function
11. Philadelphia chromosome is characterised by:
 A. t(8;14) B. t(9;22)
 C. t(22;9) D. t(14;8)
12. Tumours causing secondary polycythaemia include all except:
 A. Renal cell carcinoma
 B. Hepatocellular carcinoma
 C. Oat cell carcinoma
 D. Uterine leiomyoma
13. Mutation characteristic for polycythaemia vera is:
 A. JAK2 mutation B. Bcr-abl mutation
 C. p53 mutation D. RAS mutation
14. Difference between RAEB-1 and RAEB-2 is:
 A. Blood cytopenia in RAEB-2
 B. Marrow blasts 5-9% in RAEB-2
 C. Marrow blasts 10-19% in RAEB-2
 D. Presence of ringed sideroblasts in RAEB-2
15. Isotretinoin treatment is effective in which acute leukemia:
 A. ALL B. AML-M2
 C. AML-M6 D. AML-M3
16. Which of the following is *not* included in classic Hodgkin's disease:
 A. Nodular lymphocyte predominant HD
 B. Lymphocyte depletion HD
 C. Mixed cellularity HD
 D. Nodular sclerosis HD
17. Which of the following is a specific marker for hairy cell?
 A. CD22 B. CD5
 C. CD103 D. CD8
18. Leukemic stage of cutaneous T cell lymphoma is called:
 A. Hairy cell leukemia B. Adult T cell leukemia
 C. Mycosis fungoides D. Sezary syndrome

KEY

- | | | | |
|--------|--------|--------|--------|
| 1 = B | 2 = B | 3 = D | 4 = C |
| 5 = D | 6 = D | 7 = D | 8 = A |
| 9 = C | 10 = D | 11 = B | 12 = C |
| 13 = A | 14 = C | 15 = D | 16 = A |
| 17 = C | 18 = D | | |



The Blood Vessels and Lymphatics

□ NORMAL STRUCTURE (p. 390)

Depending upon the calibre and certain histologic features, arteries are divided into 3 types: large (elastic) arteries, medium-sized (muscular) arteries and the smallest arterioles.

M/E All the arteries of the body have 3 layers in their walls: the tunica intima, the tunica media and the tunica adventitia. These layers progressively decrease with diminution in the size of the vessels.

The layers of arterial wall receive nutrition and oxygen from 2 sources:

1. Tunica intima and inner third of the media are nourished by *direct diffusion* from the blood present in the lumen.
2. Outer two-thirds of the media and the adventitia are supplied by *vasa vasora* (i.e. vessels of vessels), the nutrient vessels arising from the parent artery.

As the calibre of the artery decreases, the three layers progressively diminish. Thus, there are structural variations in the three types of arteries:

◆ **Large, elastic arteries** such as the aorta, innominate, common carotid, major pulmonary, and common iliac arteries have very high content of elastic tissue in the media and thick elastic laminae and hence the name.

◆ **Medium-sized, muscular arteries** are the branches of elastic arteries. All the three layers of arterial wall are thinner than in the elastic arteries. The internal elastic lamina appears as a single wavy line while the external elastic lamina is less prominent. The media primarily consists of smooth muscle cells and some elastic fibres (**Web Image 15.1**).

◆ **Arterioles** are the smallest branches with internal diameter 20-100 μm . Structurally, they consist of the three layers as in muscular arteries but are much thinner and cannot be distinguished. The arterioles consist of a layer of endothelial cells in the intima, one or two smooth muscle cells in the media and small amount of collagen and elastic tissue comprising the adventitia. The elastic laminae are virtually lost.

◆ **Capillaries** are about the size of an RBC (7-8 μm) and have a layer of endothelium but no media. Blood from capillaries returns to the heart via *post-capillary venules* and thence into venules and then veins.

□ ARTERIOSCLEROSIS (p. 391)

Arteriosclerosis is a general term used to include all conditions with thickening and hardening of the arterial walls. The following morphologic entities are included under arteriosclerosis:

SENILE ARTERIOSCLEROSIS (p. 391)

Senile arteriosclerosis is the thickening of media and intima of the arteries seen due to aging. The changes are non-selective and affect most of the arteries. These are possibly induced by stress and strain on vessel wall during life.

M/E

1. **Fibroelastosis:** The intima and media are thickened due to increase in elastic and collagen tissue.
2. **Elastic reduplication:** The internal elastic lamina is split or reduplicated so that two wavy layers are seen.

HYPERTENSIVE ARTERIOLOSCLEROSIS (p. 391)

Hypertension is the term used to describe an elevation in blood pressure.

Arteriosclerosis is the term used to describe 3 morphologic forms of vascular disease affecting arterioles and small muscular arteries. These are: hyaline arteriosclerosis, hyperplastic arteriosclerosis and necrotising arteriolitis. All the three types are common in hypertension but may occur due to other causes as well.

Hyaline Arteriosclerosis (p. 391)

Hyaline sclerosis is a common arteriolar lesion that may be seen *physiologically* due to aging, or may occur *pathologically* in benign nephrosclerosis in hypertensives and as a part of microangiopathy in diabetics.

PATHOGENESIS. The exact pathogenesis is not known. However, the following hypotheses have been proposed:

- i) The lesions result most probably from *leakage of components of plasma* across the vascular endothelium.
- ii) An alternate possibility is that the lesions may be due to *immunologic reaction*.
- iii) Some have considered it to be *normal aging process* that is exaggerated in hypertension and diabetes mellitus.

M/E The thickened vessel wall shows structureless, eosinophilic, hyaline material in the intima and media (**Web Image 15.2,A**).

Hyperplastic Arteriosclerosis (p. 391)

The hyperplastic or proliferative type of arteriosclerosis is a characteristic lesion of malignant hypertension; other causes include haemolytic-uraemic syndrome, scleroderma and toxæmia of pregnancy.

M/E Three types of intimal thickening may occur.

- i) *Onion-skin lesion* consists of loosely-placed concentric layers of hyperplastic intimal smooth muscle cells like the bulb of an onion. The basement membrane is also thickened and reduplicated (**Web Image 15.2, B**).
- ii) *Mucinous intimal thickening* is the deposition of amorphous ground substance, probably proteoglycans, with scanty cells.
- iii) *Fibrous intimal thickening* is less common and consists of bundles of collagen, elastic fibres and hyaline deposits in the intima.

Necrotising Arteriolitis (p. 392)

In cases of severe hypertension and malignant hypertension, parts of small arteries and arterioles show changes of hyaline sclerosis and parts of these show necrosis, or necrosis may be superimposed on hyaline sclerosis. However, hyaline sclerosis may not be always present in the vessel wall.

M/E Besides the changes of hyaline sclerosis, the changes of necrotising arteriolitis include fibrinoid necrosis of vessel wall, acute inflammatory infiltrate of neutrophils in the adventitia (**Web Image 15.2,C**).

MÖNCKEBERG'S ARTERIOSCLEROSIS (MEDIAL CALCIFIC SCLEROSIS) (p. 392)

Mönckeberg's arteriosclerosis is calcification of the media of large and medium-sized muscular arteries, especially of the extremities and of the genital tract, in persons past the age of 50. The condition occurs as an age-related degenerative process, and therefore, an example of dystrophic calcification, and has little or no clinical significance.

M/E Mönckeberg's arteriosclerosis is characterised by deposits of calcium salts in the media without associated inflammatory reaction while the intima

324 and the adventitia are spared (**Web Image 15.3**). Often, coexistent changes of atherosclerosis are present altering the histologic appearance.

□ **ATHEROSCLEROSIS** (p. 393)

DEFINITION (p. 393)

Atherosclerosis is a specific form of arteriosclerosis affecting primarily the intima of large and medium-sized muscular arteries and is characterised by fibrofatty plaques or atheromas. The term atherosclerosis is derived from *athero*- (meaning porridge) referring to the soft lipid-rich material in the centre of atheroma, and *sclerosis* (scarring) referring to connective tissue in the plaques. Atherosclerosis is the commonest and the most important of the arterial diseases. Though any large and medium-sized artery may be involved in atherosclerosis, the most commonly affected are the aorta, the coronary and the cerebral arterial systems. Therefore, the major clinical syndromes resulting from ischaemia due to atherosclerosis pertain to the heart (angina and myocardial infarcts or *heart attacks*), and the brain (transient cerebral ischaemia and cerebral infarcts or *strokes*).

ETIOLOGY (p. 393)

Atherosclerosis is widely prevalent in industrialised countries. However, majority of the data on etiology are based on the animal experimental work and epidemiological studies. Cardiovascular disease, mostly related to atherosclerotic coronary heart disease or ischaemic heart disease (IHD) is the most common cause of premature death in the developed countries of the world. It is estimated that by the year 2020, cardiovascular disease, mainly atherosclerosis, will become the leading cause of total global disease burden.

Systematic large scale studies of investigations on living populations have revealed a number of *risk factors* which are associated with increased risk of developing clinical atherosclerosis. Often, they are acting in combination rather than singly. These risk factors are divided into two groups (**Web Table 15.1**):

I. Major risk factors. These are further considered under 2 headings:

- A) *Major risk factors modifiable by life style and/or therapy.*
- B) *Constitutional risk factors.*

II. Non-traditional emerging risk factors. This includes a host of factors whose role in atherosclerosis is minimal, and in some cases, even uncertain.

MAJOR RISK FACTORS MODIFIABLE BY LIFE STYLE AND/OR THERAPY (p. 393)

There are four major risk factors in atherogenesis—lipid disorders, hypertension, cigarette smoking and diabetes mellitus.

1. DYSLIPIDAEMIAS. Abnormalities in plasma lipoproteins have been firmly established as the most important major risk factor for atherosclerosis. It has been firmly established that hypercholesterolaemia has directly proportionate relationship with atherosclerosis and IHD. The following evidences are cited in support of this:

- i) The atherosclerotic plaques contain cholesterol and cholesterol esters, largely derived from the lipoproteins in the blood.
- ii) The lesions of atherosclerosis can be induced in experimental animals by feeding them with diet rich in cholesterol.
- iii) Individuals with hypercholesterolaemia due to various causes such as in diabetes mellitus, myxoedema, nephrotic syndrome, von Gierke's disease, xanthomatosis and familial hypercholesterolaemia have increased risk of developing atherosclerosis and IHD.

iv) Populations having hypercholesterolaemia have higher mortality from IHD. Dietary regulation and administration of cholesterol-lowering drugs have beneficial effect on reducing the risk of IHD.

The lipoproteins are divided into classes according to the density of solvent in which they remain suspended on centrifugation at high speed. The major classes of lipoprotein particles are *chylomicrons*, *very-low density lipoproteins (VLDL)*, *low-density lipoproteins (LDL)*, and *high-density lipoproteins (HDL)*. Lipids are insoluble in blood and therefore are carried in circulation and across the cell membrane by carrier proteins called *apoproteins*. Apoprotein surrounds the lipid for carrying it.

The major fractions of lipoproteins tested in blood lipid profile and their varying effects on atherosclerosis and IHD are as under (**Web Table 15.2**):

i) Total cholesterol: Desirable normal serum level is 140-200 mg/dl, while levels of borderline high are considered between 200-240 mg/dl. An elevation of total serum cholesterol levels above 260 mg/dl in men and women between 30 and 50 years of age has three times higher risk of developing IHD as compared with people with total serum cholesterol levels within normal limits.

ii) Triglycerides: Normal serum level is below 160 mg/dl.

iii) Low-density lipoproteins (LDL) cholesterol: Normal optimal serum level is <130 mg/dl. LDL is richest in cholesterol and has the *maximum association* with atherosclerosis.

iv) Very-low-density lipoprotein (VLDL): VLDL carries much of the triglycerides and its blood levels therefore parallel with that of triglycerides; VLDL has *less marked* effect than LDL.

v) High-density lipoproteins (HDL) cholesterol: Normal desirable serum level is <60 mg/dl. HDL is *protective* ('good cholesterol') against atherosclerosis.

Many studies have demonstrated the harmful effect of diet containing larger quantities of saturated fats (e.g. in eggs, meat, milk, butter etc) and trans fats (i.e. unsaturated fats produced by artificial hydrogenation of polyunsaturated fats) which raise the plasma cholesterol level. This type of diet is consumed more often by the affluent societies who are at greater risk of developing atherosclerosis. On the contrary, a diet low in saturated fats and high in poly-unsaturated fats and having omega-3 fatty acids (e.g. in fish, fish oils etc) lowers the plasma cholesterol levels.

Besides above, *familial hypercholesterolaemia*, an autosomal codominant disorder, is characterised by elevated LDL cholesterol and normal triglycerides and occurrence of xanthomas and premature coronary artery disease. It occurs due to mutations in LDL receptor gene.

Currently, management of dyslipidaemia is directed at *lowering LDL* in particular and total cholesterol in general by use of statins, and for *raising HDL* by weight loss, exercise and use of nicotinic acid. Thus presently, preferred term for hyperlipidaemia is dyslipidaemia because one risky plasma lipoprotein (i.e. LDL) is elevated and needs to be brought down, while the other good plasma lipoprotein (i.e. HDL) when low requires to be raised.

2. HYPERTENSION. Hypertension is a risk factor for all clinical manifestations of atherosclerosis. Hypertension doubles the risk of all forms of cardiovascular disease. It acts probably by mechanical injury to the arterial wall due to increased blood pressure. Elevation of systolic pressure of over 160 mmHg or a diastolic pressure of over 95 mmHg is associated with five times higher risk of developing IHD than in people with blood pressure within normal range (140/90 mmHg or less).

3. SMOKING. The extent and severity of atherosclerosis are much greater in smokers than in non-smokers. Cigarette smoking is associated with higher risk of atherosclerotic IHD and sudden cardiac death. Men who

326 smoke a pack of cigarettes a day are 3-5 times more likely to die of IHD than non-smokers. The increased risk and severity of atherosclerosis in smokers is due to reduced level of HDL, deranged coagulation system and accumulation of carbon monoxide in the blood that produces carboxy-haemoglobin and eventually hypoxia in the arterial wall favouring atherosclerosis.

4. DIABETES MELLITUS. Clinical manifestations of atherosclerosis are far more common and develop at an early age in people with both type 1 and type 2 diabetes mellitus. In particular, association of type 2 diabetes mellitus characterised by metabolic (insulin resistance) syndrome and abnormal lipid profile termed 'diabetic dyslipidaemia' is common and heightens the risk of cardiovascular disease. The risk of developing IHD is doubled, tendency to develop cerebrovascular disease is high, and frequency to develop gangrene of foot is about 100 times increased.

CONSTITUTIONAL RISK FACTORS (p. 394)

1. AGE. Atherosclerosis is an age-related disease. Though early lesions of atherosclerosis may be present in childhood, clinically significant lesions are found with increasing age. Fully-developed atheromatous plaques usually appear in the 4th decade and beyond. Evidence in support comes from the high death rate from IHD in this age group.

2. SEX. The incidence and severity of atherosclerosis are more in men than in women and the changes appear a decade earlier in men (≥ 45 years) than in women (≥ 55 years). The prevalence of atherosclerotic IHD is about three times higher in men in 4th decade than in women and the difference slowly declines with age but remains higher at all ages in men. The lower incidence of IHD in women, especially in premenopausal age, is probably due to high levels of oestrogen and high-density lipoproteins, both of which have anti-atherogenic influence.

3. GENETIC FACTORS. Genetic factors play a significant role in atherogenesis. Hereditary genetic derangements of lipoprotein metabolism predispose the individual to high blood lipid level and familial hypercholesterolaemia.

4. FAMILIAL AND RACIAL FACTORS: The familial predisposition to atherosclerosis may be related to other risk factors like diabetes, hypertension and hyperlipoproteinaemia. Racial differences too exist; Blacks have generally less severe atherosclerosis than Whites.

EMERGING RISK FACTORS (p. 395)

1. Higher incidence of atherosclerosis in developed countries and low prevalence in underdeveloped countries, suggesting the role of *environmental influences*.

2. *Obesity*, if the person is overweight by 20% or more, is associated with increased risk.

3. Use of *exogenous hormones* (e.g. oral contraceptives) by women or *endogenous oestrogen deficiency* (e.g. in post-menopausal women) has been shown to have an increased risk of developing myocardial infarction or stroke.

4. *Physical inactivity* and lack of exercise are associated with the risk of developing atherosclerosis and its complications.

5. *Stressful life style*, termed as 'type A' behaviour pattern, characterised by aggressiveness, competitive drive, ambitiousness and a sense of urgency, is associated with enhanced risk of IHD compared with 'type B' behaviour of relaxed and happy-go-lucky type.

6. Patients with *homocystinuria*, an uncommon inborn error of metabolism, have been reported to have early atherosclerosis and coronary artery disease.

7. There are some reports which suggest that moderate consumption of *alcohol* has slightly beneficial effect by raising the level of HDL cholesterol.
8. *Prothrombotic factors* and elevated fibrinogen levels favour formation of thrombi which is the gravest complication of atherosclerosis.
9. Role of *infections*, particularly of *Chlamydia pneumoniae* and viruses such as herpesvirus and cytomegalovirus, has been found in coronary atherosclerotic lesions by causing inflammation. Possibly, infections may be acting in combination with some other factors.
10. Markers of inflammation such as *elevated C reactive protein*, an acute phase reactant, correlate with risk of developing atherosclerosis.

PATHOGENESIS (p. 395)

As stated above, atherosclerosis is not caused by a single etiologic factor but is a multifactorial process whose exact pathogenesis is still not known. Since the times of Virchow, a number of theories have been proposed.

◆ **Insudation hypothesis.** The concept hypothesised by *Virchow in 1856* that atherosclerosis is a form of cellular proliferation of the intimal cells resulting from increased imbibing of lipids from the blood came to be called the '*lipid theory*'.

◆ **Encrustation hypothesis.** The proposal put forth by *Rokitansky in 1852* that atheroma represented a form of encrustation on the arterial wall from the components in the blood forming thrombi composed of platelets, fibrin and leucocytes, was named as '*encrustation theory*' or '*thrombogenic theory*'.

Though, there is no consensus regarding the origin and progression of lesion of atherosclerosis, the role of four key factors—arterial smooth muscle cells, endothelial cells, blood monocytes and dyslipidaemia, is accepted by all. However, the areas of disagreement exist in the mechanism and sequence of events involving these factors in initiation, progression and complications of disease. Currently, pathogenesis of atherosclerosis is explained on the basis of the following two theories:

1. REACTION-TO-INJURY HYPOTHESIS. This theory is most widely accepted and incorporates aspects of two older historical theories of atherosclerosis—the lipid theory of Virchow and thrombogenic (encrustation) theory of Rokitansky.

◆ The *original response to injury theory* was first described in 1973 according to which the initial event in atherogenesis was considered to be endothelial injury followed by smooth muscle cell proliferation so that the early lesions, according to this theory, consist of smooth muscle cells mainly.

◆ The *modified response-to-injury hypothesis* described subsequently in 1993 implicates lipoprotein entry into the intima as the initial event followed by lipid accumulation in the macrophages (foam cells now) which according to modified theory, are believed to be the dominant cells in early lesions.

Both these theories—original and modified, have attracted support and criticism. However, following is the generally accepted role of key components involved in atherogenesis, diagrammatically illustrated in **Web Image 15.4**.

i) Endothelial injury. It has been known for many years that endothelial injury is the initial triggering event in the development of lesions of atherosclerosis. Actual endothelial denudation is not an essential requirement, but endothelial dysfunction may initiate the sequence of events.

In man, two of the major risk factors which act together to produce endothelial injury are: *haemodynamic stress from hypertension and chronic dyslipidaemia*. The role of haemodynamic forces in causing endothelial injury is further supported by the distribution of atheromatous plaques at points of bifurcation or branching of blood vessels which are under greatest shear stress.

ii) Intimal smooth muscle cell proliferation. Endothelial injury causes adherence, aggregation and platelet release reaction at the site of exposed subendothelial connective tissue and infiltration by inflammatory cells. Proliferation of intimal smooth muscle cell and production of extracellular matrix are stimulated by various cytokines such as IL-1 and TNF- α released from invading monocyte-macrophages and by activated platelets at the site of endothelial injury.

- ◆ Platelet-derived growth factor (*PDGF*) and fibroblast growth factor (*FGF*) stimulate proliferation and migration of smooth muscle cells from their usual location in the media into the intima.

- ◆ Transforming growth factor- β (*TGF- β*) and interferon- (*IFN*)- γ derived from activated T lymphocytes within lesions regulate the synthesis of collagen by smooth muscle cells.

Smooth muscle cell proliferation is also facilitated by biomolecules such as nitric oxide and *endothelin* released from endothelial cells.

iii) Role of blood monocytes. Though blood monocytes do not possess receptors for normal LDL, LDL does appear in the monocyte cytoplasm to form foam cell by mechanism illustrated in **Web Image 15.5**. Plasma LDL on entry into the intima undergoes oxidation. The 'oxidised LDL' formed in the intima performs the following all-important functions on monocytes and endothelium:

- ◆ *For monocytes:* Oxidised LDL acts to attract, proliferate, immobilise and activate them as well as is readily taken up by scavenger receptor on the monocyte to transform it to a lipid-laden foam cell.

- ◆ *For endothelium:* Oxidised LDL is cytotoxic.

iv) Role of dyslipidaemia. As stated already, chronic dyslipidaemia in itself may initiate endothelial injury and dysfunction by causing increased permeability. In particular, hypercholesterolaemia with increased serum concentration of LDL promotes formation of foam cells, while high serum concentration of HDL has anti-atherogenic effect.

v) Thrombosis. As apparent from the foregoing, endothelial injury exposes subendothelial connective tissue resulting in formation of small platelet aggregates at the site and causing proliferation of smooth muscle cells. This causes mild inflammatory reaction which together with foam cells is incorporated into the atheromatous plaque.

2. MONOCLONAL HYPOTHESIS. This hypothesis is based on the postulate that proliferation of smooth muscle cells is the primary event and that this proliferation is monoclonal in origin similar to cellular proliferation in neoplasms. The evidence cited in support of monoclonal hypothesis is the observation on proliferated smooth muscle cells in atheromatous plaques which have only one of the two forms of glucose-6-phosphate dehydrogenase (G6PD) isoenzymes, suggesting monoclonality in origin. The monoclonal proliferation of smooth muscle cells in atherosclerosis may be initiated by mutation caused by exogenous chemicals (e.g. cigarette smoke), endogenous metabolites (e.g. lipoproteins) and some viruses.

Morphologic Features (p. 397)

Early lesions in the form of diffuse intimal thickening, fatty streaks and gelatinous lesions are often the forerunners in the evolution of atherosclerotic lesions. The clinical disease states due to luminal narrowing in atherosclerosis are caused by fully developed atheromatous plaques and complicated plaques (**Web Image 15.6**).

1. FATTY STREAKS AND DOTS. Fatty streaks and dots on the intima by themselves are harmless but may be the precursor lesions of atheromatous plaques. They are seen in all races of the world and begin to appear in the first year of life.

G/A The lesions may appear as flat or slightly elevated and yellow. They may be either in the form of small, multiple dots, about 1 mm in size, or in the form of elongated, beaded streaks.

M/E Fatty streaks lying under the endothelium are composed of closely-packed foam cells, lipid-containing elongated smooth muscle cells and a few lymphoid cells.

2. GELATINOUS LESIONS. Gelatinous lesions develop in the intima of the aorta and other major arteries in the first few months of life. Like fatty streaks, they may also be precursors of plaques. They are round or oval, circumscribed grey elevations, about 1 cm in diameter.

M/E Gelatinous lesions are foci of increased ground substance in the intima with thinned overlying endothelium.

3. ATHEROMATOUS PLAQUES. A fully developed atherosclerotic lesion is called atheromatous plaque, also called *fibrous plaque*, *fibrofatty plaque* or *atheroma*. Unlike fatty streaks, atheromatous plaques are selective in different geographic locations and races and are seen in advanced age. These lesions may develop from progression of early lesions of the atherosclerosis described above. *Most often and most severely affected is the abdominal aorta*, though smaller lesions may be seen in descending thoracic aorta and aortic arch. The major branches of the aorta around the ostia are often severely involved, especially the iliac, femoral, carotid, coronary, and cerebral arteries.

G/A Atheromatous plaques are white to yellowish-white lesions, varying in diameter from 1-2 cm and raised on the surface by a few millimetres to a centimetre in thickness (**Web Image 15.7**). Cut section of the plaque reveals the luminal surface as a firm, white *fibrous cap* and a *central core* composed of yellow to yellow-white, soft, porridge-like material and hence the name atheroma.

M/E The appearance of plaque varies depending upon the age of the lesion. However, the following features are invariably present (**Web Image 15.8**):

- ◆ Superficial luminal part of the *fibrous cap* is covered by endothelium, and is composed of smooth muscle cells, dense connective tissue and extracellular matrix containing proteoglycans and collagen.
- ◆ *Cellular area* under the fibrous cap is comprised by a mixture of macrophages, foam cells, lymphocytes and a few smooth muscle cells which may contain lipid.
- ◆ Deeper *central soft core* consists of extracellular lipid material, cholesterol clefts, fibrin, necrotic debris and lipid-laden foam cells.
- ◆ In older and *more advanced lesions*, the collagen in the fibrous cap may be dense and hyalinised, smooth muscle cells may be atrophic and foam cells are fewer.

4. COMPLICATED PLAQUES. Various pathologic changes that occur in fully-developed atheromatous plaques are called the complicated lesions. These account for the most serious harmful effects of atherosclerosis and even death.

i) Calcification. Calcification occurs more commonly in advanced atheromatous plaques, especially in the aorta and coronaries. The diseased intima cracks like an egg-shell when the vessel is incised and opened.

M/E The calcium salts are deposited in the vicinity of necrotic area and in the soft lipid pool deep in the thickened intima (**Web Image 15.9**). This form of atherosclerotic *intimal* calcification differs from Mönckeberg's *medial* calcific arteriosclerosis that affects only the tunica media.

ii) Ulceration. The layers covering the soft pultaceous material of an atheroma may ulcerate as a result of haemodynamic forces or mechanical trauma. This results in discharge of emboli composed of lipid material and debris into the blood stream, leaving a shallow, ragged ulcer with yellow lipid debris in the base of the ulcer.

iii) Thrombosis. The ulcerated plaque and the areas of endothelial damage are vulnerable sites for formation of superimposed thrombi. These thrombi

330 may get dislodged to become emboli and lodge elsewhere in the circulation, or may get organised and incorporated into the arterial wall as mural thrombi.

iv) Haemorrhage. Intimal haemorrhage may occur in an atheromatous plaque either from the blood in the vascular lumen through an ulcerated plaque, or from rupture of thin-walled capillaries that vascularise the atheroma from adventitial vasa vasorum.

v) Aneurysm formation. Though atherosclerosis is primarily an intimal disease, advanced lesions are associated with secondary changes in the media and adventitia. The changes in media include atrophy and thinning of the media and fragmentation of internal elastic lamina. These changes cause weakening in the arterial wall resulting in aneurysmal dilatation.

CLINICAL EFFECTS (p. 399)

The clinical effects of atherosclerosis depend upon the size and type of arteries affected. In general, the clinical effects result from the following:

1. Slow luminal narrowing causing ischaemia and atrophy.
2. Sudden luminal occlusion causing infarction necrosis.
3. Propagation of plaque by formation of thrombi and emboli.
4. Formation of aneurysmal dilatation and eventual rupture.

The symptomatic atherosclerotic disease involves most often the heart, brain, kidneys, small intestine and lower extremities (**Web Image 15.10**). The effects pertaining to these organs are described in relevant chapters later while the major effects are listed below (**Web Image 15.11**):

- i) *Aorta*—Aneurysm formation, thrombosis and embolisation to other organs.
- ii) *Heart*—Myocardial infarction, ischaemic heart disease.
- iii) *Brain*—Chronic ischaemic brain damage, cerebral infarction.
- iv) *Small intestine*—Ischaemic bowel disease, infarction.
- v) *Lower extremities*—Intermittent claudication, gangrene.

ARTERITIS (p. 400)

Arteritis, angiitis and vasculitis are the common terms used for inflammatory process in an artery or an arteriole. It may occur following invasion of the vessel by infectious agents, or may be induced by non-infectious injuries such as chemical, mechanical, immunologic and radiation injury. The non-infectious group is more important than the infectious type (**Web Table 15.3**).

I. INFECTIOUS ARTERITIS (p. 400)

Endarteritis Obliterans (p. 400)

Endarteritis obliterans is not a disease entity but a pathologic designation used for non-specific inflammatory response of arteries and arterioles to a variety of irritants. It is commonly seen close to the lesions of peptic ulcers of the stomach and duodenum, tuberculous and chronic abscesses in the lungs, chronic cutaneous ulcers, chronic meningitis, and in post-partum and post-menopausal uterine arteries.

M/E The obliteration of the lumen is due to concentric and symmetric proliferation of cellular fibrous tissue in the intima. Though the condition has suffix—*itis* attached to it, there is minimal or no inflammatory cell infiltrate.

Non-syphilitic Infective Arteritis (p. 401)

Various forms of invasions of the artery by bacteria, fungi, parasites or viruses, either directly or by haematogenous route, cause non-syphilitic infective arteritis.

M/E The inflammatory infiltrate is present in the vessel wall. The vascular lumen may get occluded by thrombi and result in ischaemic necrosis of the affected tissue.

Syphilitic Arteritis (p. 401)

Syphilitic or luetic vascular involvement occurs in all stages of syphilis but is more prominent in the tertiary stage. The changes that are found in the syphilitic arteritis are seen within the arterial tissue (*syphilitic endarteritis*) and in the periarterial tissues (*syphilitic periarteritis*). Manifestations of the disease are particularly prominent at two sites—the aorta and the cerebral arteries.

SYPHILITIC AORTITIS. Syphilitic involvement of the ascending aorta and the aortic arch is the commonest manifestation of cardiovascular syphilis.

G/A The affected part of the aorta may be dilated, and its wall somewhat thickened and adherent to the neighbouring mediastinal structures. Longitudinally opened vessels show intimal surface studded with pearly-white thickenings, varying from a few millimeters to a centimeter in diameter. These lesions are separated by wrinkled normal intima, giving it characteristic *tree-bark appearance*.

M/E The conspicuous features are as under (**Web Image 15.12**):

- ◆ Enderteritis and periarteritis of the vasa vasorum located in the media and adventitia.
- ◆ Perivascular accumulation of plasma cells, lymphocytes and macrophages that may form miliary gummas which undergo necrosis and are replaced by scar tissue.
- ◆ Intimal thickenings consist of dense avascular collagen that may undergo hyalinisation and calcification.

The *effects* of syphilitic aortitis may vary from trivial to catastrophic. These are as follows:

- a) *Aortic aneurysm*
- b) *Aortic valvular incompetence*
- c) *Stenosis of coronary ostia*

The features distinguishing syphilitic aortitis from aortic atheroma are given in **Web Table 15.4**.

CEREBRAL SYPHILITIC ARTERITIS (HEUBNER'S ARTERITIS). Syphilitic involvement of small and medium-sized cerebral arteries occurs during the tertiary syphilis. The changes may accompany syphilitic meningitis.

M/E Changes of endarteritis and periarteritis similar to those seen in syphilitic aortitis are found. There is atrophy of muscle in the media and replacement by fibrosis. This results in ischaemic atrophy of the brain.

II. NON-INFECTIOUS ARTERITIS (p. 402)

This group consists of most of the important forms of vasculitis, more often affecting arterioles, venules and capillaries, and hence also termed as *small vessel vasculitis*. Their exact etiology is not known but available evidence suggests that many of them have immunologic origin. Serum from many of patients with vasculitis of immunologic origin show the presence of following immunologic features:

1. Anti-neutrophil cytoplasmic antibodies (ANCA). Neutrophil immunofluorescence is used to demonstrate their presence, of which two distinct patterns of ANCA are seen:

- ◆ *Cytoplasmic ANCA (c-ANCA) pattern* is specific for proteinase-3 (PR-3).
- ◆ *Perinuclear ANCA (p-ANCA) pattern* is specific for myeloperoxidase enzyme.

332 2. Anti-endothelial cell antibodies (AECAs). These antibodies are demonstrable in cases of SLE, Kawasaki disease and Buerger's disease.

3. Pauci-immune vasculitis. While most cases of immunologic vasculitis have immune complex deposits in the vessel wall, there are some cases which do not have such immune deposits and are termed as cases of pauci-immune vasculitis.

Polyarteritis Nodosa (p. 402)

Polyarteritis nodosa (PAN) is a necrotising vasculitis involving small and medium-sized muscular arteries of multiple organs and tissues. 'Polyarteritis' is the preferred nomenclature over 'periarteritis' because inflammatory involvement occurs in all the layers of the vessel wall.

The disease occurs more commonly in adult males than females. Most commonly affected organs, in descending order of frequency of involvement, are the kidneys, heart, liver, gastrointestinal tract, muscle, pancreas, testes, nervous system and skin.

G/A The lesions of PAN involve segments of vessels, especially at the bifurcations and branchings, as tiny beaded nodules.

M/E There are 3 sequential stages in the evolution of lesions in PAN:

- i) *Acute stage*—There is fibrinoid necrosis in the centre of the nodule located in the media. An acute inflammatory response develops around the focus of fibrinoid necrosis.
- ii) *Healing stage*—This is characterised by marked fibroblastic proliferation producing firm nodularity. The inflammatory infiltrate now consists mainly of lymphocytes, plasma cells and macrophages.
- iii) *Healed stage*—In this stage, the affected arterial wall is markedly thickened due to dense fibrosis. The internal elastic lamina is fragmented or lost.

Hypersensitivity Vasculitis (p. 402)

Hypersensitivity vasculitis, also called as allergic or leucocytoclastic vasculitis or microscopic polyarteritis, is a group of clinical syndromes differing from PAN in having inflammatory involvement of venules, capillaries and arterioles. The condition results from immunologic response to an identifiable antigen that may be bacteria (e.g. streptococci, staphylococci, mycobacteria), viruses (e.g. hepatitis B virus, influenza virus, CMV), malarial parasite, certain drugs and chemicals. Hypersensitivity vasculitis includes clinicopathologic entities such as serum sickness, Henoch-Schönlein purpura, mixed cryoglobulinaemia, vasculitis associated with malignancy, and vasculitis associated with connective tissue diseases like rheumatoid arthritis and SLE.

M/E The lesions characteristically involve smallest vessels, sparing medium-sized and larger arteries. Two histologic forms are described:

- i) *Leucocytoclastic vasculitis*, characterised by fibrinoid necrosis with neutrophilic infiltrate in the vessel wall. Many of the neutrophils are fragmented (**Web Image 15.13**).
- ii) *Lymphocytic vasculitis*, in which the involved vessel shows predominant infiltration by lymphocytes.

Wegener's Granulomatosis (p. 403)

Wegener's granulomatosis is another form of necrotising vasculitis characterised by a *clinicopathologic triad* consisting of the following:

- i) Acute necrotising granulomas of the upper and lower respiratory tracts involving nose, sinuses and lungs;
- ii) focal necrotising vasculitis, particularly of the lungs and upper airways; and
- iii) focal or diffuse necrotising glomerulonephritis.

A *limited form* of Wegener's granulomatosis is the same condition without renal involvement. Most commonly involved organs are the lungs, paranasal sinuses, nasopharynx and kidneys. The etiology is not known but possibly the lesions occur due to the presence of circulating immune complexes. The serum of these patients shows c-ANCA positivity. Disseminated form of Wegener's granulomatosis differs from a related entity, *idiopathic lethal midline granuloma*, in the sense that the latter condition is highly destructive and progressively necrotic disease of the upper airways.

M/E The characteristic feature of Wegener's granulomatosis is the presence of necrotising granulomatous inflammation of the tissues and necrotising vasculitis with or without granulomas:

- ◆ The granulomas consist of fibrinoid necrosis with extensive infiltration by neutrophils, mononuclear cells, epithelioid cells, multinucleate giant cells and fibroblastic proliferation.
- ◆ The necrotising vasculitis may be segmental or circumferential.
- ◆ The renal lesions are those of focal or diffuse necrotising glomerulonephritis.

Temporal (Giant Cell) Arteritis (p. 403)

This is a form of granulomatous inflammation of medium-sized and large arteries. Preferential sites of involvement are the cranial arteries, especially the temporal, and hence the name. However, the aorta and other major arteries like common carotid, axillary, brachial, femoral and mesenteric arteries are also involved, and therefore, it is preferable to call the entity as '*giant cell arteritis*'. The patients are generally over the age of 70 years with slight female preponderance.

G/A The affected artery is thickened, cord-like and the lumen is usually reduced to a narrow slit.

M/E The features are as under:

- i) There is chronic granulomatous reaction, usually around the internal elastic lamina and typically involves the entire circumference of the vessel.
- ii) Giant cells of foreign body or Langhans' type are found in two-third of cases.
- iii) The internal elastic lamina is often fragmented.
- iv) There is eccentric or concentric intimal cellular proliferation causing marked narrowing of the lumen. The narrowed lumen may contain thrombus.
- v) Occasionally, only nonspecific inflammatory cell infiltrate consisting of neutrophils, lymphocytes and eosinophils is found throughout the arterial wall.

Takayasu's Arteritis (Pulseless Disease) (p. 404)

This is a form of granulomatous vasculitis affecting chiefly the aorta and its major branches and hence is also referred to as *aortic arch syndrome*. The disease affects chiefly young women and is typically characterised by absence of pulse in both arms and presence of ocular manifestations. The etiology of Takayasu's arteritis is not known but the autoimmune reaction to aortic tissue has been suggested as the possible cause.

M/E The features are as under:

- i) There is severe mononuclear inflammatory infiltrate involving the full thickness of the affected vessel wall.
- ii) The inflammatory changes are more severe in the adventitia and media and there is perivascular infiltration of the vasa vasorum.
- iii) Granulomatous changes in the media with central necrosis and Langhans' giant cells are found in many cases.
- iv) Advanced lesions show extensive fibrosis of the media and adventitia causing thickening in the vessel wall.

334 Kawasaki's Disease (p. 404)

Also known by more descriptive name of 'mucocutaneous lymph node syndrome', it is an acute and subacute illness affecting mainly young children and infants. Kawasaki's disease is a febrile illness with mucocutaneous symptoms like erosions of oral mucosa and conjunctiva, skin rash and lymphadenopathy. The most characteristic finding is the presence of multiple aneurysms of the coronaries detected by angiography during life or observed at autopsy.

M/E The picture is of panarteritis resembling PAN, characterised by necrosis and inflammation of the entire thickness of the vessel wall. Therefore, some consider Kawasaki's disease as an infantile form of PAN.

Buerger's Disease (Thromboangiitis Obliterans) (p. 404)

Buerger's disease is a specific disease entity affecting chiefly small and medium-sized arteries and veins of the extremities and characterised by acute and chronic occlusive inflammatory involvement. The disease affects chiefly men under the age of 35 years who are heavy cigarette smokers. The symptom-complex consists of intermittent claudication due to ischaemia manifested by intense pain affecting the limbs, more commonly the legs. Eventually, gangrene of the affected extremities occurs requiring amputation.

ETIOPATHOGENESIS. It is as under:

◆ There is consistent association with heavy cigarette smoking. This has led to the hypothesis that *tobacco products* cause either direct endothelial damage leading to hypercoagulability and thrombosis, or it is a result in hypersensitivity to tobacco products.

◆ *Genetic factors* play a role as the disease has familial occurrence and has HLA association. An increased prevalence is seen in individuals with HLA-A9 and HLA-B5 antigens.

G/A The lesions are typically segmental affecting small and medium-sized arteries, especially of the lower extremities. Involvement of the arteries is often accompanied with involvement of adjacent veins and nerves. Mural thrombi are frequently present in the vessels.

M/E The features are as under:

i) In *early stage*, there is infiltration by polymorphs in all the layers of vessels and there is invariable presence of mural or occlusive thrombosis of the lumen (**Web Image 15.14**).

ii) In *advanced stage*, the cellular infiltrate is predominantly mononuclear and may contain an occasional epithelioid cell granuloma with Langhans' giant cells. The thrombi undergo organisation and recanalisation. In more chronic cases, marked fibrosis of the media is present.

Raynaud's Disease and Raynaud's Phenomenon (p. 405)

Raynaud's disease is not a vasculitis but is a functional vasospastic disorder affecting chiefly small arteries and arterioles of the extremities, occurring in otherwise young healthy females. The disease affects most commonly the fingers and hands. The ischaemic effect is provoked primarily by cold but other stimuli such as emotions, trauma, hormones and drugs also play a role. Clinically, the affected digits show *pallor*, followed by *cyanosis*, and then *redness*, corresponding to *arterial ischaemia*, *venostasis* and *hyperaemia* respectively. Long-standing cases may develop ulceration and necrosis of digits but occurrence of true gangrene is rare. The cause of the disease is unknown but probably occurs due to vasoconstriction mediated by autonomic stimulation of the affected vessels.

Raynaud's phenomenon differs from Raynaud's disease in having an underlying cause e.g. secondary to atherosclerosis, connective tissue

diseases like scleroderma and SLE, Buerger's disease, multiple myeloma, pulmonary hypertension and ingestion of ergot group of drugs.

□ **ANEURYSMS** (p. 405)

DEFINITION (p. 405)

An aneurysm is defined as a permanent abnormal dilatation of a blood vessel occurring due to congenital or acquired weakening or destruction of the vessel wall. Most commonly, aneurysms involve large elastic arteries, especially the aorta and its major branches.

CLASSIFICATION (p. 405)

A. Depending upon the composition of the wall:

1. *True aneurysm* composed of all the layers of a normal vessel wall.
2. *False aneurysm* having fibrous wall and occurring often from trauma to the vessel.

B. Depending upon the shape: These are as under (*Web Image 15.15*):

1. *Saccular* having large spherical outpouching.
2. *Fusiform* having slow spindle-shaped dilatation.
3. *Cylindrical* with a continuous parallel dilatation.
4. *Serpentine or varicose* which has tortuous dilatation of the vessel.
5. *Racemose or circoid* having mass of intercommunicating small arteries and veins.

C. Based on pathogenetic mechanisms: (*Web Image 15.16*):

1. *Atherosclerotic (arteriosclerotic) aneurysms* are the most common type.
2. *Syphilitic (luetetic) aneurysms* found in the tertiary stage of the syphilis.
3. *Dissecting aneurysms (Dissecting haematoma)* in which the blood enters the separated or dissected wall of the vessel.
4. *Mycotic aneurysms* which result from weakening of the arterial wall by microbial infection.
5. *Berry aneurysms* which are small dilatations especially affecting the circle of Willis in the base of the brain.

Atherosclerotic Aneurysms (p. 406)

Atherosclerotic aneurysms are the most common form of aortic aneurysms. They are seen more commonly in males and the frequency increases after the age of 50 years when the incidence of complicated lesions of advanced atherosclerosis is higher. They are most common in the abdominal aorta, so much so that all forms of aneurysms of abdominal aorta (fusiform, cylindrical and saccular) should be considered atherosclerotic until proved otherwise. Other locations include thoracic aorta (essentially the ascending part and arch of aorta), iliac arteries and other large systemic arteries.

PATHOGENESIS. Obviously, severe atherosclerotic lesions are the basic problem which cause thinning and destruction of the medial elastic tissue resulting in atrophy and weakening of the wall. Since atherosclerotic lesions are most common and severe in the abdominal aorta, atherosclerotic aneurysms occur most frequently here. In the thoracic aorta, besides atherosclerotic lesions, medial degeneration is another additional factor implicated in pathogenesis.

MORPHOLOGIC FEATURES. Atherosclerotic aneurysms of the abdominal aorta are most frequently infra-renal, above the bifurcation of the aorta but may extend into common iliac arteries.

M/E The wall of atherosclerotic aneurysm loses its normal arterial structure. Instead, there is predominance of fibrous tissue in the media and adventitia with mild chronic inflammatory reaction. The intima and inner part of the media show remnants of atheromatous plaques and mural thrombus.

336 EFFECTS. The clinical effects of atherosclerotic aneurysms are due to complications. These are: Rupture, compression and arterial occlusion.

Syphilitic (Luetic) Aneurysms (p. 406)

Cardiovascular syphilis occurs in about 10% cases of syphilis. It causes arteritis—syphilitic aortitis and cerebral arteritis. One of the major complications of syphilitic aortitis is syphilitic or luetic aneurysm that develops in the tertiary stage of syphilis. It usually manifests after the age of 50 years and is more common in men. The predominant site of involvement is the thoracic aorta, especially in the ascending part and arch of aorta. It may extend proximally into the aortic valve causing aortic incompetence and may lead to syphilitic heart disease.

PATHOGENESIS. About 40% cases of syphilitic aortitis develop syphilitic aneurysms. The process begins from inflammatory infiltrate around the vasa vasorum of the adventitia, followed by endarteritis obliterans. This results in ischaemic injury to the media causing destruction of the smooth muscle and elastic tissue of the media and scarring. Since syphilitic aortitis involves the proximal aorta maximally, aortic aneurysm is found most frequently in the ascending aorta and in the aortic arch.

MORPHOLOGIC FEATURES. Syphilitic aneurysms occurring most often in the ascending part and the arch of aorta are saccular in shape and usually 3-5 cm in diameter. Less often, they are fusiform or cylindrical. The intimal surface is wrinkled and shows *tree-bark appearance*.

M/E The features of healed syphilitic aortitis are seen. The adventitia shows fibrous thickening with endarteritis obliterans of vasa vasorum. The fibrous scar tissue may extend into the media and the intima.

EFFECTS. The clinical manifestations are found much more frequently in syphilitic aneurysms than in atherosclerotic aneurysms. The effects include: Rupture, compression and cardiac dysfunction. The effects include rupture, compression and cardiac dysfunction.

Dissecting Aneurysms and Cystic Medial Necrosis (p. 407)

The term dissecting aneurysm is applied for a dissecting haematoma in which the blood enters the separated (dissected) wall of the vessel and spreads for varying distance longitudinally. The most common site is the aorta and is an acute catastrophic aortic disease. The condition occurs most commonly in men in the age range of 50 to 70 years. In women, dissecting aneurysms may occur during pregnancy.

PATHOGENESIS. The pathogenesis of dissecting aneurysm is explained on the basis of weakened aortic media. Various conditions causing weakening in the aortic wall resulting in dissection are as under:

- i) Hypertensive state.** About 90% cases of dissecting aneurysm have hypertension.
- ii) Non-hypertensive cases.** These are cases in whom there is some local or systemic connective tissue disorder e.g. *Marfan's syndrome, cystic medial necrosis of Erdheim, iatrogenic trauma and pregnancy*.

MORPHOLOGIC FEATURES. Dissecting aneurysm differs from atherosclerotic and syphilitic aneurysms in having no significant dilatation. Therefore, it is currently referred to as '*dissecting haematoma*'. Dissecting aneurysm classically begins in the arch of aorta. In 95% of cases, there is a sharply-incised, transverse or oblique intimal tear, 3-4 cm long, most often located in the ascending part of the aorta. The dissection is seen most characteristically between the outer and middle third of the aortic media so that the column of blood in the dissection separates the *intima and inner two-third of the media*

on one side from the *outer one-third of the media and the adventitia* on the other. The dissection extends proximally into the aortic valve ring as well as distally into the abdominal aorta (**Web Image 15.17**).

In about 10% of dissecting aneurysms, a second intimal tear is seen in the distal part of the dissection so that the blood enters the false lumen through the proximal tear and re-enters the true lumen through the distal tear. If the patient survives, the false lumen may develop endothelial lining and 'double-barrel aorta' is formed.

Two **classification schemes** for dissections of thoracic aorta and intramural haematoma have been described (**Web Image 15.18**):

I. DeBakey classification. Depending upon the extent of aortic dissection, three types are described:

Type I: Comprises 75% of cases

Type II: Comprises 5%

Type III: Constitutes the remaining 20% cases.

II. Stanford classification. Depending upon clinical management, these are divided into 2 types:

Type A (Proximal dissection): Involves the ascending aorta and includes type I and II of the above scheme because clinical management of DeBakey type I and II is not different.

Type B (Distal dissection): Limited to descending aorta and sparing the ascending aorta; it corresponds to DeBakey type III.

M/E The characteristic features of cystic medial necrosis are found. These are as under:

- ◆ Focal separation of the fibromuscular and elastic tissue of the media.
- ◆ Numerous cystic spaces in the media containing basophilic ground substance.
- ◆ Fragmentation of the elastic tissue.
- ◆ Increased fibrosis of the media.

EFFECTS. The classical clinical manifestation of a dissecting aneurysm is excruciating tearing pain in the chest moving downwards. The complications arising from dissecting aneurysms are: Rupture, cardiac disease and ischaemia.

FIBROMUSCULAR DYSPLASIA (p. 409)

Fibromuscular dysplasia first described in 1976, is a non-atherosclerotic and non-inflammatory disease affecting arterial wall, most often renal artery. Though the process may involve intima, media or adventitia, medial fibroplasia is the most common.

M/E The beaded areas show collections of smooth muscle cells and connective tissue. There is often rupture and retraction of internal elastic lamina.

The main **effects** of renal fibromuscular dysplasia, depending upon the region of involvement, are renovascular hypertension and changes of renal atrophy.

VEINS (p. 409)

□ **NORMAL STRUCTURE** (p. 409)

The structure of normal veins is basically similar to that of arteries. The walls of the veins are thinner, the three tunicae (intima, media and adventitia) are less clearly demarcated, elastic tissue is scanty and not clearly organised into internal and external elastic laminae. The media contains very small amount of smooth muscle cells with abundant collagen. All veins, except vena cavae and common iliac veins, have valves best developed in veins of

338 the lower limbs. The valves are delicate folds of intima, located every 1-6 cm, often next to the point of entry of a tributary vein. They prevent any significant retrograde venous blood flow.

□ **VARICOSITIES** (p. 409)

Varicosities are abnormally dilated and tortuous veins. The veins of lower extremities are involved most frequently, called *varicose veins*. The veins of other parts of the body which are affected are the lower oesophagus (*oesophageal varices*, Chapter 19), the anal region (*haemorrhoids*, Chapter 20) and the spermatic cord (*varicocele*, Chapter 23).

VARICOSE VEINS (p. 409)

Varicose veins are permanently dilated and tortuous superficial veins of the lower extremities, especially the long saphenous vein and its tributaries. About 10-12% of the general population develops varicose veins of lower legs, with the peak incidence in 4th and 5th decades of life. Adult females are affected more commonly than the males, especially during pregnancy. This is attributed to venous stasis in the lower legs because of compression on the iliac veins by pregnant uterus.

ETIOPATHOGENESIS. A number of etiologic and pathogenetic factors are involved in causing varicose veins. These are as follows:

- i) Familial weakness of vein walls and valves is the most common cause.
- ii) Increased intraluminal pressure due to prolonged upright posture e.g. in nurses, policemen, surgeons etc.
- iii) Compression of iliac veins e.g. during pregnancy, intravascular thrombosis, growing tumour etc.
- iv) Hormonal effects on smooth muscle.
- v) Obesity.
- vi) Chronic constipation.

M/E There is variable fibromuscular thickening of the wall of the veins due to alternate dilatation and hypertrophy. Degeneration of the medial elastic tissue may occur which may be followed by calcific foci. Mural thrombosis is commonly present which may get organised and hyalinised leading to irregular intimal thickening.

EFFECTS. Varicose veins of the legs result in venous stasis which is followed by congestion, oedema, thrombosis, stasis, dermatitis, cellulitis and ulceration. Secondary infection results in chronic varicose ulcers.

□ **PHLEBOTHROMBOSIS AND THROMBOPHLEBITIS** (p. 409)

The terms '*phlebothrombosis*' or thrombus formation in veins, and '*thrombophlebitis*' or inflammatory changes within the vein wall, are currently used synonymously.

ETIOPATHOGENESIS. Venous thrombosis that precedes thrombophlebitis is initiated by *triad* of changes: endothelial damage, alteration in the composition of blood and venous stasis. The factors that predispose to these changes are cardiac failure, malignancy, use of oestrogen-containing compounds, postoperative state and immobility due to various reasons.

MORPHOLOGIC FEATURES. The most common locations for phlebothrombosis and thrombophlebitis are the deep veins of legs accounting for 90% of cases; it is commonly termed as *deep vein thrombosis (DVT)*. Other locations are periprostatic venous plexus in males, pelvic veins in the females, and near the foci of infection in the abdominal cavity such as acute appendicitis, peritonitis, acute salpingitis and pelvic abscesses.

G/A The affected veins may appear normal or may be distended and firm. Often, a mural or occlusive thrombus is present.

M/E The thrombus that is attached to the vein wall induces inflammatory-reparative response beginning from the intima and infiltrating into the thrombi. The response consists of mononuclear inflammatory cells and fibroblastic proliferation.

EFFECTS. The clinical effects due to phlebothrombosis and thrombophlebitis may be local or systemic.

Local effects are oedema distal to occlusion, heat, swelling, tenderness, redness and pain.

Systemic effects are more severe and occur due to embolic phenomena, pulmonary thromboembolism being the most common and most important. Other systemic manifestations include bacteraemia and septic embolisation to brain, meninges, liver etc.

SPECIAL TYPES OF PHLEBOTHROMBOSIS (p. 410)

1. THROMBOPHLEBITIS MIGRANS. Thrombophlebitis migrans or migratory thrombophlebitis or Trousseau's syndrome is the term used for multiple venous thrombi that disappear from one site so as to appear at another site.

2. PHLEGMASIA ALBA DOLENS. This term meaning 'painful white leg' refers to extensive swelling of the leg, occurring most frequently due to iliofemoral venous thrombosis.

3. PHLEGMASIA CERULEA DOLENS. This term meaning 'painful blue leg' refers to markedly swollen bluish skin with superficial gangrene.

4. SUPERIOR VENA CAVAL SYNDROME. Superior vena caval syndrome refers to obstruction of the superior vena cava. The obstruction results most often from external compression or from thrombosis.

5. INFERIOR VENA CAVAL SYNDROME. Inferior vena caval syndrome is the obstruction of the inferior vena cava. Most often, obstruction results from thrombosis by extension from iliofemoral veins.

NORMAL STRUCTURE (p. 410)

Lymphatic capillaries, lymphatic vessels and lymph nodes comprise the lymphatic system. Lymphatic capillaries resemble blood capillaries, and larger lymphatics are identical to veins. However, lymphatics lined by a single layer of endothelium have thin muscle in their walls than in veins of the same size and the valves are more numerous.

LYMPHANGITIS (p. 410)

Inflammation of the lymphatics or lymphangitis may be acute or chronic.

Acute lymphangitis occurs in the course of many bacterial infections. The most common organisms are (β -haemolytic streptococci and staphylococci). Acute lymphangitis is often associated with lymphadenitis.

Chronic lymphangitis occurs due to persistent and recurrent acute lymphangitis or from chronic infections like tuberculosis, syphilis and actinomycosis.

LYMPHOEDEMA (p. 410)

Lymphoedema is swelling of soft tissues due to localised increase in the quantity of lymph. It may be primary (idiopathic) or secondary (obstructive).

I. PRIMARY (IDIOPATHIC) LYMPHOEDEMA. Lymphoedema occurring without underlying secondary cause is called primary or idiopathic lymphoedema. Its various types are as under:

340 1. Congenital lymphoedema. Congenital lymphoedema has further 2 subtypes—familial hereditary form (Milroy's disease) and non-familial (simple) form.

i) *Milroy's disease* is a form of congenital and familial oedema generally affecting one limb but at times may be more extensive and involve the eyelids and lips. The disease is inherited as an autosomal dominant trait and is often associated with other congenital anomalies.

ii) *Simple congenital lymphoedema* is non-familial form with unknown etiology. It is often associated with Turner's syndrome and affects one member of the family.

2. Lymphoedema praecox. This is a rare form of lymphoedema affecting chiefly young females. The oedema usually begins in the foot and progresses slowly upwards to involve the whole extremity. With passage of time, the affected area becomes rough and the oedema is non-pitting. The etiology is unknown but probably the condition is related to female reproductive system because of preponderance in females and aggravation during menses.

II. SECONDARY (OBSTRUCTIVE) LYMPHOEDEMA. This is more common form of lymphoedema. Various causes of lymphatic obstruction causing lymphoedema are as under:

- i) Lymphatic invasion by malignant tumour.
- ii) Surgical removal of lymphatics e.g. in radical mastectomy.
- iii) Post-irradiation fibrosis.
- iv) Parasitic infestations e.g. in filariasis of lymphatics producing elephantiasis.
- v) Lymphangitis causing scarring and obstruction.

Obstructive lymphoedema occurs only when the obstruction is widespread as otherwise collaterals develop. With passage of time, there is inflammatory scarring and the lymphatics become fibrosed with enlargement of the affected part. Rupture of dilated large lymphatics may result in escape of milky chyle into the peritoneum (*chyloperitoneum*), into the pleural cavity (*chylothorax*), into pericardial cavity (*chylopericardium*) and into the urinary tract (*chyluria*).

A classification of vascular tumours and tumour-like conditions is given in **Web Table 15.5**.

□ **A. BENIGN TUMOURS AND HAMARTOMAS (p. 411)**

HAEMANGIOMA (p. 411)

Haemangiomas are quite common lesions, especially in infancy and childhood. The most common site is the skin of the face.

CAPILLARY HAEMANGIOMA. These are the most common type. Clinically, they appear as small or large, flat or slightly elevated, red to purple, soft and lobulated lesions, varying in size from a few millimeters to a few centimeters in diameter. They may be present at birth or appear in early childhood. Strawberry birthmarks and 'port-wine mark' are some good examples. The common sites are the skin, subcutaneous tissue and mucous membranes of oral cavity and lips. Less common sites are internal visceral organs like liver, spleen and kidneys.

M/E Capillary haemangiomas are well-defined but unencapsulated lobules. These lobules are composed of capillary-sized, thin-walled, blood-filled vessels. These vessels are lined by single layer of plump endothelial cells surrounded by a layer of pericytes. The vessels are separated by some connective tissue stroma (**Web Image 15.19**).

CAVERNOUS HAEMANGIOMA. Cavernous haemangiomas are single or multiple, discrete or diffuse, red to blue, soft and spongy masses. They are often 1 to 2 cm in diameter. They are most common in the skin (especially of the face and neck); other sites are mucosa of the oral cavity, stomach and small intestine, and internal visceral organs like the liver and spleen.

M/E Cavernous haemangiomas are composed of thin-walled cavernous vascular spaces, filled partly or completely with blood. The vascular spaces are lined by flattened endothelial cells. They are separated by scanty connective tissue stroma (**Web Image 15.20**).

GRANULOMA PYOGENICUM. Granuloma pyogenicum is also referred to as *haemangioma of granulation tissue type*. True to its name, it appears as exophytic, red granulation tissue just like a nodule, commonly on the skin and mucosa of gingiva or oral cavity. *Pregnancy tumour* or *granuloma gravidarum* is a variant occurring on the gingiva during pregnancy and regresses after delivery.

M/E It shows proliferating capillaries similar to capillary haemangioma but the capillaries are separated by abundant oedema and inflammatory infiltrate, thus resembling inflammatory granulation tissue.

LYMPHANGIOMA (p. 412)

Lymphangiomas are lymphatic counterparts of vascular angiomas.

CAPILLARY LYMPHANGIOMA. It is also called as lymphangioma simplex. It is a small, circumscribed, slightly elevated lesion measuring 1 to 2 cm in diameter. The common locations are the skin of head and neck, axilla and mucous membranes.

M/E Capillary lymphangioma is composed of a network of endothelium-lined, capillary-sized spaces containing lymph and often separated by lymphoid aggregates.

CAVERNOUS LYMPHANGIOMA. It is more common than the capillary type. The common sites are in the region of head and neck or axilla. A large cystic variety called *cystic hygroma* occurs in the neck producing gross deformity in the neck.

M/E Cavernous lymphangioma consists of large dilated lymphatic spaces lined by flattened endothelial cells and containing lymph. Scanty intervening stromal connective tissue is present (**Web Image 15.21**).

GLOMUS TUMOUR (GLOMANGIOMA) (p. 412)

Glomus tumour is an uncommon true benign tumour arising from contractile glomus cells that are present in the arteriovenous shunts (Sucquet-Hoyer anastomosis). These tumours are found most often in the dermis of the fingers or toes under a nail; other sites are mucosa of the stomach and nasal cavity. These lesions are characterised by extreme pain.

M/E The tumours are composed of small blood vessels lined by endothelium and surrounded by aggregates, nests and masses of glomus cells. The glomus cells are round to cuboidal cells with scanty cytoplasm (**Web Image 15.22**). The intervening connective tissue stroma contains some non-myelinated nerve fibres.

ARTERIOVENOUS MALFORMATIONS (p. 413)

An arteriovenous (AV) malformation is a communication between an artery and vein without an intervening capillary bed. It may be congenital or acquired type. Congenital AV malformations have thick-walled vessels with hyalinisation and calcification. Acquired AV malformations reveal changes mainly in the veins which are dilated and thick-walled.

342 BACILLARY ANGIOMATOSIS AND PELIOSIS HEPATIS (p. 413)

Bacillary angiomatosis is a tumour-like lesion reported in association with HIV-AIDS with CD4+ T cell counts below 100/ μ l. In fact, it is an opportunistic infection with gram-negative bacilli of *Bartonella* genus. Most common site of involvement is the skin and bones while a closely related condition peliosis hepatis is seen in the liver.

M/E Lobules of proliferating blood vessels are seen lined by epithelioid endothelial cells having mild atypia. Mixed inflammatory cell infiltrate with nuclear debris of neutrophils is present in these areas.

□ B. INTERMEDIATE GRADE TUMOURS (p. 413)

HAEMANGIOENDOTHELIOMA (p. 413)

Haemangioendothelioma is a true tumour of endothelial cells, the behaviour of which is intermediate between a haemangioma and haemangiosarcoma. It is found most often in the skin and subcutaneous tissue in relation to medium-sized and large veins. *Haemangioblastoma* is the term used for similar tumour occurring in the cerebellum.

G/A The tumour is usually well-defined, grey-red, polypoid mass.

M/E There is active proliferation of endothelial cells forming several layers around the blood vessels so that vascular lumina are difficult to identify. These cells may have variable mitotic activity. Reticulin stain delineates the pattern of cell proliferation inner to the basement membrane (**Web Image 15.23**).

□ C. MALIGNANT TUMOURS (p. 414)

HAEMANGIOPERICYTOMA (p. 414)

Haemangiopericytoma is an uncommon tumour arising from pericytes. Pericytes are cells present external to the endothelial cells of capillaries and venules.

M/E The tumour is composed of capillaries surrounded by spindle-shaped pericytes outside the vascular basement membrane forming whorled arrangement. These tumour cells may have high mitotic rate and areas of necrosis. Silver impregnation stain (i.e. reticulin stain) is employed to confirm the presence of pericytes outside the basement membrane of capillaries and to distinguish it from haemangioendothelioma (**Web Image 15.24**).

ANGIOSARCOMA (p. 414)

Also known as haemangiosarcoma and malignant haemangioendothelioma, it is a malignant vascular tumour occurring most frequently in the skin, subcutaneous tissue, liver, spleen, bone, lung and retroperitoneal tissues. It can occur in both sexes and at any age. *Hepatic angiosarcomas* are of special interest in view of their association with carcinogens like polyvinyl chloride, arsenical pesticides and radioactive contrast medium, thorotrast, used in the past.

G/A The tumours are usually bulky, pale grey-white, firm masses with poorly-defined margins. Areas of haemorrhage, necrosis and central softening are frequently present.

M/E The tumours may be well-differentiated masses of proliferating endothelial cells around well-formed vascular channels, to poorly-differentiated lesions composed of plump, anaplastic and pleomorphic cells in solid clusters with poorly identifiable vascular channels (**Web Image 15.25**).

Kaposi's sarcoma is a malignant angiomatous tumour, first described by Kaposi, Hungarian dermatologist, in 1872. However, the tumour has attracted greater attention in the last two decades due to its frequent occurrence in patients with HIV/AIDS.

CLASSIFICATION. Presently, four forms of Kaposi's sarcoma are described:

- 1. Classic (European) Kaposi's sarcoma.** This is the form which was first described by Kaposi. It is more common in men over 60 years of age of Eastern European descent.
- 2. African (Endemic) Kaposi's sarcoma.** This form is common in equatorial Africa.
- 3. Epidemic (AIDS-associated) Kaposi's sarcoma.** This form is seen in about 30% cases of AIDS, especially in young male homosexuals than the other high-risk groups.
- 4. Kaposi's sarcoma in renal transplant cases.** This form is associated with recipients of renal transplants who have been administered immunosuppressive therapy for a long time.

PATHOGENESIS. Pathogenesis of Kaposi's sarcoma is complex. It is an opportunistic neoplasm in immunosuppressed patients which has excessive proliferation of spindle cells of vascular origin having features of both endothelium and smooth muscle cells:

- ◆ Epidemiological studies have suggested a *viral association* implicating HIV and human herpesvirus 8 (HSV 8, also called Kaposi's sarcoma-associated herpesvirus or KSHV).
- ◆ Occurrence of Kaposi's sarcoma involves interplay of HIV-1 infection, HHV-8 infection, activation of the immune system and secretion of cytokines (IL-6, TNF- α , GM-CSF, basic fibroblast factor, and oncostain M). Higher incidence of Kaposi's sarcoma in male homosexuals is explained by increased secretion of cytokines by their activated immune system.
- ◆ Defective immunoregulation plays a role in its pathogenesis is further substantiated by observation of *second malignancy* (e.g. leukaemia, lymphoma and myeloma) in about one-third of patients with Kaposi's sarcoma.

MORPHOLOGIC FEATURES. Pathologically, all forms of Kaposi's sarcoma are similar.

G/A The lesions in the skin, gut and other organs form prominent, irregular, purple, dome-shaped plaques or nodules.

M/E The changes are nonspecific in the *early patch stage* and more characteristic in the *late nodular stage*.

- ◆ **Early patch stage:** There are irregular vascular spaces separated by interstitial inflammatory cells and extravasated blood and haemosiderin.
- ◆ **Late nodular stage:** There are slit-like vascular spaces containing red blood cells and separated by spindle-shaped, plump tumour cells. These spindle-shaped tumour cells are probably of endothelial origin (**Web Image 15.26**).

◆ **SELF ASSESSMENT**

- 1. Vasa vasora perfuse the vessel wall as follows:**
 - A.** Whole thickness of vessel wall
 - B.** Whole of adventitia and media
 - C.** Adventitia and outer half of media
 - D.** Adventitia and outer two-third of media

2. **Medial calcification of arteries is seen in the following except:**
 - A. Mönckeberg's arteriosclerosis
 - B. Atherosclerosis
 - C. Pseudoxanthoma elasticum
 - D. Idiopathic calcification of infancy
3. **Atherosclerosis is predominantly a disease of:**
 - A. Intima
 - B. Media
 - C. Adventitia
 - D. Entire vessel wall
4. **The following lipid has highest association with atherosclerosis:**
 - A. Triglycerides
 - B. Low-density lipoproteins
 - C. Very-low density lipoproteins
 - D. High density lipoproteins
5. **Hypertension with systolic pressure of 160 mmHg has greater risk of causing atherosclerosis as under:**
 - A. 2-times
 - B. 3-times
 - C. 4-times
 - D. 5-times
6. **The most important mitogen for smooth muscle proliferation in atherosclerosis is:**
 - A. Platelet-derived growth factor
 - B. Fibroblast growth factor
 - C. Epidermal growth factor
 - D. Transforming growth factor- α
7. **Cytoplasmic anti-neutrophil cytoplasmic antibodies (C-ANCA) is seen in:**
 - A. Polyarteritis nodosa
 - B. Wegener's granulomatosis
 - C. Leucocytoclastic vasculitis
 - D. Giant cell arteritis
8. **Biopsy of affected artery in the following condition is not only of diagnostic value but also cures the main symptom of the patient:**
 - A. Giant cell arteritis
 - B. Takayasu's arteritis
 - C. Kawasaki disease
 - D. Raynaud's disease
9. **The most common site of involvement of atherosclerotic aneurysm is:**
 - A. Arch of aorta
 - B. Thoracic aorta
 - C. Suprarenal abdominal aorta
 - D. Infrarenal abdominal aorta
10. **The most common cause of dissecting haematoma is:**
 - A. Cystic medial necrosis of Erdheim
 - B. Trauma during cardiac catheterisation
 - C. Systemic hypertension
 - D. Marfan syndrome
11. **Dissecting haematoma causes separation of aortic wall as under:**
 - A. Between intima and media
 - B. Between inner third of media and outer two-third of media
 - C. Between inner two-third of media and outer one-third
 - D. Between media and adventitia
12. **In Kaposi's sarcoma, the lesions are more extensively distributed at different body sites and visceral organs in:**
 - A. Classic (European) type
 - B. African (Endemic) type
 - C. AIDS-associated
 - D. Renal transplant-associated
13. **Hyperplastic arteriosclerosis is seen in all except:**
 - A. Haemolytic uraemic syndrome
 - B. Benign nephrosclerosis
 - C. Toxaemia of pregnancy
 - D. Scleroderma

14. **Medial calcific sclerosis is a type of:**
 A. Dystrophic calcification
 B. Metastatic calcification
 C. Both metastatic and dystrophic calcification
 D. Neither metastatic nor dystrophic calcification
15. **Familial Hypercholesterolaemia is:**
 A. Autosomal recessive
 B. X-linked recessive
 C. Autosomal co-dominant
 D. Non-Mendelian disorder
16. **According to monoclonal hypothesis, the primary event in atherosclerosis is:**
 A. Monoclonal proliferation of endothelial cells
 B. Monoclonal proliferation of smooth muscle cells
 C. Monoclonal proliferation of monocytes
 D. Monoclonal proliferation of foam cells
17. **All of the following may act as precursor of atheromatous plaque except:**
 A. Fatty streak
 B. Fatty dots
 C. Gelatinous lesions
 D. Fibrous plaque
18. **Huebner's arteritis is:**
 A. Endarteritis obliterans
 B. Cerebral syphilitic arteritis
 C. Hypersensitivity vasculitis
 D. Giant cell arteritis
19. **Pulseless disease is:**
 A. Temporal arteritis
 B. Kawasaki's disease
 C. Takayasu arteritis
 D. Buerger's disease
20. **Debakey and Stanford classification systems are used for the categorisation of:**
 A. Arteritis
 B. Dissecting aneurysm
 C. Vascular tumours
 D. Arteriosclerosis

KEY

1 = D	2 = B	3 = A	4 = B
5 = D	6 = A	7 = B	8 = A
9 = D	10 = C	11 = C	12 = C
13 = B	14 = A	15 = C	16 = B
17 = D	18 = B	19 = C	20 = B

The Heart

ANATOMY AND PHYSIOLOGY. The heart is a muscular pump that ejects blood into the vascular tree with sufficient pressure to maintain optimal circulation. Average weight of the heart in an adult male is 300-350 gm while that of an adult female is 250-300 gm. Heart is divided into four chambers: a right and a left atrium both lying superiorly, and a right and a left ventricle both lying inferiorly and are larger. The atria are separated by a thin interatrial partition called *interatrial septum*, while the ventricles are separated by thick muscular partition called *interventricular septum*. The thickness of the right ventricular wall is 0.3 to 0.5 cm while that of the left ventricular wall is 1.3 to 1.5 cm. The blood in the heart chambers moves in a carefully prescribed pathway: venous blood from systemic circulation → right atrium → right ventricle → pulmonary arteries → lungs → pulmonary veins → left atrium → left ventricle → aorta → systemic arterial supply (**Web Image 16.1**).

The transport of blood is regulated by cardiac valves: two loose flap-like atrioventricular valves, tricuspid on the right and mitral (bicuspid) on the left; and two semilunar valves with three leaflets each, the pulmonary and aortic valves, guarding the outflow tracts. The normal circumference of the valvular openings measures about 12 cm in tricuspid, 8.5 cm in pulmonary, 10 cm in mitral and 7.5 cm in aortic valve.

Wall of the heart consists mainly of the *myocardium* which is covered externally by thin membrane, the *epicardium* or visceral pericardium, and lined internally by another thin layer, the *endocardium*.

The **myocardium** is the muscle tissue of the heart composed of syncytium of branching and anastomosing, transversely striated muscle fibres arranged in parallel fashion. The myocardial fibres are connected to each other by irregular joints called as *intercalated* discs. Transverse lines divide each fibre into *sarcomeres* which act as structural and functional subunits. Each sarcomere consists of prominent central *dark A-band* attributed to thick myosin filaments and flanked on either side by *light I-bands* consisting of thin actin filament. The actin bands are in the form of twisted rods overlying protein molecules called *tropomyosin*. These protein molecules are of 3 types: *troponin-I*, *troponin-T*, and *troponin-C*.

The **conduction system** of the heart located in the myocardium is responsible for regulating rate and rhythm of the heart. It is composed of specialised Purkinje fibres which contain some contractile myofilaments and conduct action potentials rapidly. The conduction system consists of 4 major components: *Sinoatrial (SA) node*, *atrioventricular (AV) bundle*, *atrioventricular (AV) node* and *bundle of His*.

The **pericardium** consists of a closely apposed layer, *visceral pericardium* or *epicardium*, and an outer fibrous sac, the *parietal pericardium*. The two layers enclose a narrow pericardial cavity which is lined by mesothelial cells and normally contains 10-30 ml of clear, watery serous fluid. This fluid functions as lubricant and shock absorbant to the heart.

The **endocardium** is the smooth shiny inner lining of the myocardium that covers all the cardiac chambers, the cardiac valves, the chordae tendineae and the papillary muscles. It is lined by endothelium with connective tissue and elastic fibres in its deeper part.

The **valve cusps and semilunar leaflets** are delicate and translucent structures. The valves are strengthened by collagen and elastic tissue and covered by a layer of endothelium (valvular endocardium).

MYOCARDIAL BLOOD SUPPLY. The cardiac muscle, in order to function properly, must receive adequate supply of oxygen and nutrients. Blood is transported to myocardial cells by the coronary arteries which originate immediately above the aortic semilunar valve. There are three major coronary trunks, each supplying blood to specific segments of the heart (**Web Image 16.2**):

1. The **anterior descending branch of the left coronary artery** supplies most of the apex of the heart, the anterior surface of the left ventricle, the adjacent third of the anterior wall of the right ventricle, and the anterior two-third of the interventricular septum.
2. The **circumflex branch of the left coronary artery** supplies the left atrium and a small portion of the lateral aspect of the left ventricle.
3. The **right coronary artery** supplies the right atrium, the remainder of the anterior surface of the right ventricle, the adjacent half of the posterior wall of the left ventricle and the posterior third of the interventricular septum.

There are 3 anatomic patterns of distribution of the coronary blood supply, depending upon which of the coronary arteries crosses the crux. *Crux* is the region on the posterior surface of the heart where all the four cardiac chambers and the interatrial and interventricular septa meet. These patterns are as under:

- ◆ Right coronary artery preponderance is the most common pattern.
- ◆ Balanced cardiac circulation .
- ◆ Left coronary preponderance.

DEFINITION (p. 419)

Heart failure is defined as the pathophysiologic state in which impaired cardiac function is unable to maintain an adequate circulation for the metabolic needs of the tissues of the body. It may be *acute* or *chronic*. The term congestive heart failure (CHF) is used for the chronic form of heart failure in which the patient has evidence of congestion of peripheral circulation and of lungs. CHF is the end-result of various forms of serious heart diseases.

ETIOLOGY (p. 419)

1. **INTRINSIC PUMP FAILURE.** The most common and most important cause of heart failure is weakening of the ventricular muscle due to disease so that the heart fails to act as an efficient pump, e.g.
 - i) Ischaemic heart disease
 - ii) Myocarditis
 - iii) Cardiomyopathies
 - iv) Metabolic disorders e.g. beriberi
 - v) Disorders of the rhythm e.g. atrial fibrillation and flutter.
2. **INCREASED WORKLOAD ON THE HEART.** Increased mechanical load on the heart results in increased myocardial demand resulting in myocardial failure. Increased load on the heart may be in the form of pressure load or volume load.
 - i) **Increased pressure load** from:
 - a) Systemic and pulmonary arterial hypertension.
 - b) Valvular disease e.g. mitral stenosis, aortic stenosis, pulmonary stenosis.
 - c) Chronic lung diseases.
 - ii) **Increased volume load** occurs when a ventricle is required to eject more than normal volume of the blood resulting in cardiac failure, e.g.

- 348 a) Valvular insufficiency
b) Severe anaemia
c) Thyrotoxicosis
d) Arteriovenous shunts
e) Hypoxia due to lung diseases.

3. IMPAIRED FILLING OF CARDIAC CHAMBERS. This could be due to:

- a) Cardiac tamponade e.g. haemopericardium, hydropericardium
b) Constrictive pericarditis.

TYPES OF HEART FAILURE (p. 419)

Heart failure may be acute or chronic, right-sided or left-sided, and forward or backward failure.

ACUTE AND CHRONIC HEART FAILURE. Depending upon whether the heart failure develops rapidly or slowly, it may be acute or chronic.

Acute heart failure. Sudden and rapid development of heart failure occurs in the following conditions:

- i) Larger myocardial infarction
ii) Valve rupture
iii) Cardiac tamponade
iv) Massive pulmonary embolism
v) Acute viral myocarditis
vi) Acute bacterial toxæmia.

In acute heart failure, there is sudden reduction in cardiac output resulting in systemic hypotension but oedema does not occur. Instead, a state of cardiogenic shock and cerebral hypoxia develops.

Chronic heart failure. More often, heart failure develops slowly as observed in the following states:

- i) Myocardial ischaemia from atherosclerotic coronary artery disease
ii) Multivalvular heart disease
iii) Systemic arterial hypertension
iv) Chronic lung diseases resulting in hypoxia and pulmonary arterial hypertension
v) Progression of acute into chronic failure.

In chronic heart failure, compensatory mechanisms like tachycardia, cardiac dilatation and cardiac hypertrophy try to make adjustments so as to maintain adequate cardiac output. This often results in well-maintained arterial pressure and there is accumulation of oedema.

LEFT-SIDED AND RIGHT-SIDED HEART FAILURE. Though heart as an organ eventually fails as a whole, but functionally, the left and right heart act as independent units. From clinical point of view, therefore, it is helpful to consider failure of the left and right heart separately. The clinical manifestations of heart failure result from accumulation of excess fluid *upstream* to the left or right cardiac chamber whichever is initially affected (**Web Image 16.3**):

Left-sided heart failure. It is initiated by stress to the left heart. The major causes are as follows:

- i) Systemic hypertension
ii) Mitral or aortic valve disease (stenosis)
iii) Ischaemic heart disease
iv) Myocardial diseases e.g. cardiomyopathies, myocarditis.
v) Restrictive pericarditis.

The clinical manifestations of left-sided heart failure result from decreased left ventricular output and hence there is accumulation of fluid *upstream* in the lungs. Accordingly, the major pathologic changes are as under:

- i) Pulmonary congestion and oedema causes dyspnoea and orthopnoea.
ii) Decreased left ventricular output causing hypoperfusion and diminished oxygenation of tissues e.g. in kidneys causing ischaemic acute tubular

necrosis, in brain causing hypoxic encephalopathy, and in skeletal muscles causing muscular weakness and fatigue.

Right-sided heart failure. Right-sided heart failure occurs more often as a consequence of left-sided heart failure. However, some conditions affect the right ventricle primarily, producing right-sided heart failure, e.g.

- i) As a consequence of left ventricular failure.
- ii) Cor pulmonale in which right heart failure occurs due to intrinsic lung diseases (Chapter 17).
- iii) Pulmonary or tricuspid valvular disease.
- iv) Pulmonary hypertension secondary to pulmonary thromboembolism.
- v) Myocardial disease affecting right heart.
- vi) Congenital heart disease with left-to-right shunt.

Whatever be the underlying cause, the clinical manifestations of right-sided heart failure are *upstream* of the right heart such as systemic (due to caval blood) and portal venous congestion, and reduced cardiac output. Accordingly, the pathologic changes are as under:

- i) Systemic venous congestion in different tissues and organs e.g. subcutaneous oedema on dependent parts, passive congestion of the liver, spleen, and kidneys, ascites, hydrothorax, congestion of leg veins and neck veins.
- ii) Reduced cardiac output resulting in circulatory stagnation causing anoxia, cyanosis and coldness of extremities.

BACKWARD AND FORWARD HEART FAILURE. The mechanism of clinical manifestations resulting from heart failure can be explained on the basis of mutually interdependent backward and forward failure.

Backward heart failure. According to this concept, either of the ventricles fails to eject blood normally, resulting in rise of end-diastolic volume in the ventricle and increase in volume and pressure in the atrium which is transmitted *backward* producing elevated pressure in the veins.

Forward heart failure. According to this hypothesis, clinical manifestations result directly from failure of the heart to pump blood causing diminished flow of blood to the tissues, especially diminished renal perfusion and activation of renin-angiotensin-aldosterone system.

□ COMPENSATORY MECHANISMS: CARDIAC HYPERTROPHY AND DILATATION (p. 420)

In order to maintain normal cardiac output, several compensatory mechanisms play a role as under:

- ◆ Compensatory enlargement in the form of *cardiac hypertrophy, cardiac dilatation, or both.*
- ◆ *Tachycardia* (i.e. increased heart rate) due to activation of neurohumoral system e.g. release of norepinephrine and atrial natriuretic peptide, activation of renin-angiotensin-aldosterone mechanism.

Ultimately, however, dilatation decreases the force of contraction and leads to residual volume in the cardiac chambers causing volume overload resulting in cardiac failure that ends in death (**Web Image 16.4**).

CARDIAC HYPERTROPHY (p. 421)

Hypertrophy of the heart is defined as an increase in size and weight of the myocardium. It generally results from increased pressure load while increased volume load (e.g. valvular incompetence) results in hypertrophy with dilatation of the affected chamber due to regurgitation of the blood through incompetent valve. The atria may also undergo compensatory changes due to increased workload.

CAUSES. Hypertrophy with or without dilatation may involve predominantly the left or the right heart, or both sides.

350 Left ventricular hypertrophy:

- i) Systemic hypertension
- ii) Aortic stenosis and insufficiency
- iii) Mitral insufficiency
- iv) Coarctation of the aorta
- v) Occlusive coronary artery disease
- vi) Congenital anomalies like septal defects and patent ductus arteriosus
- vii) Conditions with increased cardiac output e.g. thyrotoxicosis, anaemia, arteriovenous fistulae.

Right ventricular hypertrophy:

- i) Pulmonary stenosis and insufficiency
- ii) Tricuspid insufficiency
- iii) Mitral stenosis and/or insufficiency
- iv) Chronic lung diseases e.g. chronic emphysema, bronchiectasis, pneumoconiosis, pulmonary vascular disease etc.
- v) Left ventricular hypertrophy and failure of the left ventricle.

CARDIAC DILATATION (p. 421)

Quite often, hypertrophy of the heart is accompanied by cardiac dilatation. Stress leading to accumulation of excessive volume of blood in a chamber of the heart causes increase in length of myocardial fibres and hence cardiac dilatation as a compensatory mechanism.

CAUSES. Accumulation of excessive volume of blood within the cardiac chambers from the following causes may result in dilatation of the respective ventricles or both:

- i) Valvular insufficiency (mitral and/or aortic insufficiency in left ventricular dilatation, tricuspid and/or pulmonary insufficiency in right ventricular dilatation)
- ii) Left-to-right shunts e.g. in VSD
- iii) Conditions with high cardiac output e.g. thyrotoxicosis, arteriovenous shunt
- iv) Myocardial diseases e.g. cardiomyopathies, myocarditis
- v) Systemic hypertension.

MORPHOLOGIC FEATURES. Hypertrophy of the myocardium without dilatation is referred to as *concentric*, and when associated with dilatation is called *eccentric (Web Image 16.5)*. The weight of the heart is increased above normal, often over 500 gm. However, excessive epicardial fat is not indicative of true hypertrophy.

G/A Thickness of the left ventricular wall (excluding trabeculae carneae and papillary muscles) above 15 mm is indicative of significant hypertrophy. In concentric hypertrophy, the lumen of the chamber is smaller than usual, while in eccentric hypertrophy the lumen is dilated (**Web Image 16.6**).

M/E There is increase in size of individual muscle fibres. There may be multiple minute foci of degenerative changes and necrosis in the hypertrophied myocardium (**Web Image 16.7**).

CONGENITAL HEART DISEASE (p. 422)

Congenital heart disease is the abnormality of the heart present from birth. It is the most common and important form of heart disease in the early years of life and is present in about 0.5% of newborn children. The incidence is higher in premature infants.

CLASSIFICATION. Congenital anomalies of the heart may be either *shunts* (left-to-right or right-to-left), or defects causing *obstructions* to flow. However, complex anomalies involving *combinations* of shunts and obstructions are also often present (**Web Table 16.1**).

□ **I. MALPOSITIONS OF THE HEART** (p. 423)

Dextrocardia is the condition when the apex of the heart points to the right side of the chest. It may be accompanied by *situs inversus* so that all other organs of the body are also transposed in similar way and thus heart is in normal position in relation to them.

□ **II. SHUNTS (CYANOTIC CONGENITAL HEART DISEASE)** (p. 423)

**A. LEFT-TO-RIGHT SHUNTS
(ACYANOTIC OR LATE CYANOTIC GROUP)** (p. 423)

In conditions where there is shunting of blood from left-to-right side of the heart, there is volume overload on the right heart producing pulmonary hypertension and right ventricular hypertrophy. At a later stage, the pressure on the right side is higher than on the left side creating late cyanotic heart disease.

VENTRICULAR SEPTAL DEFECT (VSD). VSD is the most common congenital anomaly of the heart and comprises about 30% of all congenital heart diseases. The condition is recognised early in life. The smaller defects often close spontaneously, while larger defects remain patent and produce significant effects.

Depending upon the location of the defect, VSD may be of the following types:

1. In 90% of cases, the defect involves *membranous septum* and is very close to the bundle of His (**Web Image 16.8**).
2. The remaining 10% cases have VSD immediately below the pulmonary valve (*subpulmonic*), below the aortic valve (*subaortic*), or exist in the form of multiple defects in the muscular septum.

ATRIAL SEPTAL DEFECT (ASD). Isolated ASD comprises about 10% of congenital heart diseases. The condition remains unnoticed in infancy and childhood till pulmonary hypertension is induced causing late cyanotic heart disease and right-sided heart failure.

Depending upon the location of the defect, there are 3 types of ASD:

- i) Fossa ovalis type or ostium secundum type** is the most common form comprising about 90% cases of ASD. The defect is situated in the region of the fossa ovalis (**Web Image 16.9**).
- ii) Ostium primum type** comprises about 5% cases of ASD. The defect lies low in the interatrial septum adjacent to atrioventricular valves. There may be cleft in the aortic leaflet of the mitral valve producing mitral insufficiency.
- iii) Sinus venosus type** accounts for about 5% cases of ASD. The defect is located high in the interatrial septum near the entry of the superior vena cava.

PATENT DUCTUS ARTERIOSUS (PDA). The ductus arteriosus is a normal vascular connection between the aorta and the bifurcation of the pulmonary artery. Normally, the ductus closes functionally within the first or second day of life. Its persistence after 3 months of age is considered abnormal. PDA constitutes about 10% of congenital malformations of the heart and great vessels. In about 90% of cases, it occurs as an isolated defect, while in the remaining cases it may be associated with other anomalies like VSD, coarctation of aorta and pulmonary or aortic stenosis. A patent ductus may be upto 2 cm in length and upto 1 cm in diameter (**Web Image 16.10**).

B. RIGHT-TO-LEFT SHUNTS (CYANOTIC GROUP) (p. 424)

In conditions where there is shunting of blood from right side to the left side of the heart, there is entry of poorly-oxygenated blood into systemic circulation resulting in early cyanosis. The examples described below are not pure shunts but are combinations of shunts with obstructions but are described

352 here since there is functional shunting of blood from one to the other side of circulation.

TETRALOGY OF FALLOT. Tetralogy of Fallot is the most common cyanotic congenital heart disease, found in about 10% of children with anomalies of the heart.

The four features of tetralogy are as under (**Web Image 16.11**):

- i) Ventricular septal defect (VSD) ('shunt').
- ii) Displacement of the aorta to right so that it overrides the VSD.
- iii) Pulmonary stenosis ('obstruction').
- iv) Right ventricular hypertrophy.

The severity of the clinical manifestations is related to two factors: extent of pulmonary stenosis and the size of VSD. Accordingly, there are two forms of tetralogy: cyanotic and acyanotic:

a) Cyanotic tetralogy: Pulmonary stenosis is greater and the VSD is mild so that there is more resistance to the outflow of blood from right ventricle resulting in right-to-left shunt at the ventricular level and cyanosis.

b) Acyanotic tetralogy: The VSD is larger and pulmonary stenosis is mild so that there is mainly left-to-right shunt with increased pulmonary flow and increased volume in the left heart but no cyanosis.

TRANSPOSITION OF GREAT ARTERIES. The term transposition is used for complex malformations as regards position of the aorta, pulmonary trunk, atrioventricular orifices and the position of atria in relation to ventricles.

There are several forms of transpositions. The common ones are described below:

i) Regular transposition is the most common type. In this, the aorta which is normally situated to the right and posterior with respect to the pulmonary trunk, is instead displaced anteriorly and to right.

ii) Corrected transposition is an uncommon anomaly. There is complete transposition of the great arteries with aorta arising from the right ventricle and the pulmonary trunk from the left ventricle, as well as transposition of the great veins.

PERSISTENT TRUNCUS ARTERIOSUS. Persistent truncus arteriosus (PTA) is a rare anomaly.

In PTA, the arch that normally separates the aorta from the pulmonary artery fails to develop. This results in a single large common vessel receiving blood from the right as well as left ventricle.

TRICUSPID ATRESIA AND STENOSIS. Tricuspid atresia and stenosis are rare anomalies. There is often associated pulmonary stenosis or pulmonary atresia.

□ III. OBSTRUCTIONS (OBSTRUCTIVE CONGENITAL HEART DISEASE) (p. 426)

COARCTATION OF AORTA. The word 'coarctation' means contracted or compressed. Coarctation of aorta is localised narrowing in any part of aorta, but the constriction is more often just distal to ductus arteriosus (*postductal or adult*), or occasionally proximal to the ductus arteriosus (*preductal or infantile type*) in the region of transverse aorta:

The two common forms of coarctation of the aorta are as under:

i) Postductal or adult type: The obstruction is just distal to the point of entry of ductus arteriosus which is often closed (**Web Image 16.12**).

ii) Preductal or infantile type: The manifestations are produced early in life. The narrowing is proximal to the ductus arteriosus which usually remains patent.

AORTIC STENOSIS AND ATRESIA. The most common congenital anomaly of the aorta is bicuspid aortic valve which does not have much functional

significance but predisposes it to calcification. Congenital aortic atresia is rare and incompatible with survival. Aortic stenosis may be acquired (e.g. in rheumatic heart disease, calcific aortic stenosis) or congenital.

PULMONARY STENOSIS AND ATRESIA. The features are:

Pulmonary stenosis: It is the commonest form of obstructive congenital heart disease comprising about 7% of all congenital heart diseases.

Pulmonary atresia: There is no communication between the right ventricle and lungs so that the blood bypasses the right ventricle through an interatrial septal defect.

Ischaemic heart disease (IHD) is defined as acute or chronic form of cardiac disability arising from imbalance between the myocardial supply and demand for oxygenated blood. Since narrowing or obstruction of the coronary arterial system is the most common cause of myocardial anoxia, the alternate term '*coronary artery disease (CAD)*' is used synonymously with IHD. IHD or CAD is the leading cause of death in most developed countries (about one-third of all deaths) and somewhat low incidence is observed in the developing countries. Men develop IHD earlier than women and death rates are also slightly higher for men than for women until the menopause.

□ ETIOPATHOGENESIS (p. 427)

IHD is invariably caused by disease affecting the coronary arteries, the most prevalent being atherosclerosis accounting for more than 90% cases, while other causes are responsible for less than 10% cases of IHD.

I. CORONARY ATHEROSCLEROSIS (p. 427)

Coronary atherosclerosis resulting in 'fixed' obstruction is the major cause of IHD in more than 90% cases. A brief account of the specific features in pathology of lesions in *atherosclerotic coronary artery disease* in particular are presented.

1. Distribution. Atherosclerotic lesions in coronary arteries are distributed in one or more of the three major coronary arterial trunks, the highest incidence being in the anterior descending branch of the left coronary, followed in decreasing frequency, by the right coronary artery and still less in circumflex branch of the left coronary. About one-third of cases have *single-vessel disease*, most often left anterior descending arterial involvement; another one-third have *two-vessel disease*, and the remainder have *three major vessel disease*.

2. Location. Almost all adults show atherosclerotic plaques scattered throughout the coronary arterial system. However, significant stenotic lesions that may produce chronic myocardial ischaemia show more than 75% (three-fourth) reduction in the cross-sectional area of a coronary artery or its branch.

3. Fixed atherosclerotic plaques. The atherosclerotic plaques in the coronaries are more often eccentrically located bulging into the lumen from one side (**Web Image 16.13**). Occasionally, there may be concentric thickening of the wall of the artery. Atherosclerosis produces gradual luminal narrowing that may eventually lead to 'fixed' coronary obstruction.

II. SUPERADDED CHANGES IN CORONARY ATHEROSCLEROSIS (p. 427)

1. Acute changes in chronic atheromatous plaque. Though chronic fixed obstructions are the most frequent cause of IHD, acute coronary episodes are often precipitated by sudden changes in chronic plaques such as plaque haemorrhage, fissuring, or ulceration that results in thrombosis and embolisation of atheromatous debris.

2. Coronary artery thrombosis. Transmural acute myocardial infarction is often precipitated by partial or complete coronary thrombosis. The initiation of thrombus occurs due to surface ulceration of fixed chronic atheromatous plaque, ultimately causing complete luminal occlusion. The lipid core of plaque, in particular, is highly thrombogenic.

3. Local platelet aggregation and coronary artery spasm. Some cases of acute coronary episodes are caused by local aggregates of platelets on the atheromatous plaque, short of forming a thrombus. The aggregated platelets release vasospastic mediators such as thromboxane A_2 which may probably be responsible for coronary vasospasm in the already atherosclerotic vessel.

Based on progressive pathological changes and clinical correlation, American Heart Association (1995) has classified human coronary atherosclerosis into 6 sequential types in ascending order of grades of lesions as shown in **Web Table 16.2**.

III. NON-ATHEROSCLEROTIC CAUSES (p. 428)

These are: Vasospasm, Stenosis of coronary ostia, Arteritis, Embolism, Thrombotic diseases, Trauma, Aneurysms and Compression.

□ EFFECTS OF MYOCARDIAL ISCHAEMIA (p. 428)

Development of lesions in the coronaries is not always accompanied by cardiac disease. Depending upon the suddenness of onset, duration, degree, location and extent of the area affected by myocardial ischaemia, the range of changes and clinical features may vary from an asymptomatic state at one extreme to immediate mortality at another (**Web Image 16.14**):

- A. Asymptomatic state
- B. Angina pectoris (AP)
- C. Acute myocardial infarction (MI)
- D. Chronic ischaemic heart disease (CIHD)/ Ischaemic cardiomyopathy/ Myocardial fibrosis
- E. Sudden cardiac death

The term *acute coronary syndromes* include a triad of acute myocardial infarction, unstable angina and sudden cardiac death.

ANGINA PECTORIS (p. 429)

Angina pectoris is a clinical syndrome of IHD resulting from transient myocardial ischaemia. It is characterised by paroxysmal pain in the substernal or precordial region of the chest which is aggravated by an increase in the demand of the heart and relieved by a decrease in the work of the heart. Often, the pain radiates to the left arm, neck, jaw or right arm. It is more common in men past 5th decade of life.

There are 3 overlapping clinical patterns of angina pectoris with some differences in their pathogenesis:

STABLE OR TYPICAL ANGINA. This is the most common pattern. Stable or typical angina is characterised by attacks of pain following physical exertion or emotional excitement and is relieved by rest. The pathogenesis of condition lies in *chronic stenosing coronary atherosclerosis* that cannot perfuse the myocardium adequately when the workload on the heart increases. During the attacks, there is depression of ST segment in the ECG due to poor perfusion of the subendocardial region of the left ventricle but there is no elevation of enzymes in the blood as there is no irreversible myocardial injury.

PRINZMETAL'S VARIANT ANGINA. This pattern of angina is characterised by pain at rest and has no relationship with physical activity. The exact pathogenesis of Prinzmetal's angina is not known. It may occur due to *sudden vasospasm* of a coronary trunk induced by coronary atherosclerosis,

or may be due to release of humoral vasoconstrictors by mast cells in the coronary adventitia. ECG shows ST segment elevation due to transmural ischaemia. These patients respond well to vasodilators like nitroglycerin.

UNSTABLE OR CRESCENDO ANGINA. Also referred to as 'pre-infarction angina' or 'acute coronary insufficiency', this is the most serious pattern of angina. It is characterised by more frequent onset of pain of prolonged duration and occurring often at rest. It is thus indicative of an impending acute myocardial infarction. Distinction between unstable angina and acute MI is made by ST segment changes on ECG—acute MI characterised by ST segment elevation while unstable angina may have non-ST segment elevation MI. *Multiple factors* are involved in the pathogenesis of unstable angina which include: stenosing coronary atherosclerosis, complicated coronary plaques (e.g. superimposed thrombosis, haemorrhage, rupture, ulceration etc), platelet thrombi over atherosclerotic plaques and vasospasm of coronary arteries.

ACUTE MYOCARDIAL INFARCTION (p. 429)

Acute myocardial infarction (MI) is the most important and feared consequence of coronary artery disease. Many patients may die within the first few hours of the onset, while remainder suffer from effects of impaired cardiac function.

INCIDENCE. In developed countries, acute MI accounts for 10-25% of all deaths. Due to the dominant etiologic role of coronary atherosclerosis in acute MI, the incidence of acute MI correlates well with the incidence of atherosclerosis in a geographic area.

Age. Acute MI may virtually occur at all ages, though the incidence is higher in the elderly. About 5% of heart attacks occur in young people under the age of 40 years, particularly in those with major risk factors to develop atherosclerosis like hypertension, diabetes mellitus, cigarette smoking and dyslipidaemia with familial hypercholesterolaemia.

Sex. Males throughout their life are at a significantly higher risk of developing acute MI as compared to females. Women during reproductive period have remarkably low incidence of acute MI, probably due to the protective influence of oestrogen. After menopause, this sex difference gradually declines but the incidence of disease among women never reaches that among men of the same age.

ETIOPATHOGENESIS. The etiologic role of severe coronary atherosclerosis (more than 75% compromise of lumen) of one or more of the three major coronary arterial trunks in the pathogenesis of about 90% cases of acute MI is well documented by autopsy studies as well as by coronary angiographic studies. A few notable features in the development of acute MI are as under:

1. Myocardial ischaemia. Myocardial ischaemia is brought about by one or more of the following mechanisms:

- i) Diminished coronary blood flow e.g. in coronary artery disease, shock.
- ii) Increased myocardial demand e.g. in exercise, emotions.
- iii) Hypertrophy of the heart without simultaneous increase of coronary blood flow e.g. in hypertension, valvular heart disease.

2. Role of platelets. Rupture of an atherosclerotic plaque exposes the subendothelial collagen to platelets which undergo aggregation, activation and release reaction. These events contribute to the build-up of the platelet mass that may give rise to emboli or initiate thrombosis.

3. Acute plaque rupture. In general, slowly-developing coronary ischaemia from stenosing coronary atherosclerosis of high-grade may not cause acute MI but continue to produce episodes of angina pectoris. But acute complications in coronary atherosclerotic plaques in the form of superimposed coronary thrombosis due to plaque rupture and plaque haemorrhage is frequently encountered in cases of acute MI.

Plaque haemorrhage and thrombosis may occur together in some cases.

4. Non-atherosclerotic causes. About 10% cases of acute MI are caused by non-atherosclerotic factors such as coronary vasospasm, arteritis, coronary ostial stenosis, embolism, thrombotic diseases, trauma and outside compression as already described.

5. Transmural versus subendocardial infarcts. There are some differences in the pathogenesis of the *transmural infarcts* involving the full thickness of ventricular wall and the *subendocardial (laminar) infarcts* affecting the inner subendocardial one-third to half. These are as under (**Web Table 16.3**):

i) *Transmural (full thickness) infarcts* are the most common type seen in 95% cases. Critical coronary narrowing (more than 75% compromised lumen) is of great significance in the causation of such infarcts. Atherosclerotic plaques with superimposed thrombosis and intramural haemorrhage are significant in about 90% cases, and non-atherosclerotic causes in the remaining 10% cases.

ii) *Subendocardial (laminar) infarcts* have their genesis in reduced coronary perfusion due to coronary atherosclerosis but without critical stenosis (not necessarily 75% compromised lumen), aortic stenosis or haemorrhagic shock. This is because subendocardial myocardium is normally least well perfused by coronaries and thus is more vulnerable to any reduction in the coronary flow.

TYPES OF INFARCTS. Infarcts have been classified in a number of ways by the physicians and the pathologists:

1. *According to the anatomic region of the left ventricle involved*, they are called anterior, posterior (inferior), lateral, septal and circumferential, and their combinations like anterolateral, posterolateral (or inferolateral) and antero-septal.

2. *According to the degree of thickness of the ventricular wall involved*, infarcts are of two types (**Web Image 16.15**):

i) Full-thickness or transmural, when they involve the entire thickness of the ventricular wall.

ii) Subendocardial or laminar, when they occupy the inner subendocardial half of the myocardium.

3. *According to the age of infarcts*, they are of two types:

i) Newly-formed infarcts called as acute, recent or fresh.

ii) Advanced infarcts called as old, healed or organised.

LOCATION OF INFARCTS. Infarcts are most frequently located in the left ventricle. Right ventricle is less susceptible to infarction due to its thin wall, having less metabolic requirements and is thus adequately nourished by the thebesian vessels. Atrial infarcts, whenever present, are more often in the right atrium, usually accompanying the infarct of the left ventricle. Left atrium is relatively protected from infarction because it is supplied by the oxygenated blood in the left atrial chamber.

The region of infarction depends upon the area of obstructed blood supply by one or more of the three coronary arterial trunks. Accordingly, there are three regions of myocardial infarction (**Web Image 16.16**):

1. *Stenosis of the left anterior descending coronary artery* is the most common (40-50%). The region of infarction is the anterior part of the left ventricle including the apex and the anterior two-thirds of the interventricular septum.

2. *Stenosis of the right coronary artery* is the next most frequent (30-40%). It involves the posterior part of the left ventricle and the posterior one-third of the interventricular septum.

3. *Stenosis of the left circumflex coronary artery* is seen least frequently (15-20%). Its area of involvement is the lateral wall of the left ventricle.

MORPHOLOGIC FEATURES. The gross and microscopic changes in the myocardial infarction vary according to the age of the infarct and are therefore described sequentially (**Web Table 16.4**).

G/A Most infarcts occur singly and vary in size from 4 to 10 cm. They are found most often in the left ventricle. Less often, there are multifocal lesions. The transmural infarcts, which by definition involve the entire thickness of the ventricular wall, usually have a thin rim of preserved subendocardial myocardium which is perfused directly by the blood in the ventricular chamber. The subendocardial infarcts which affect the inner subendocardial half of the myocardium produce less well-defined gross changes than the transmural infarcts. The sequence of macroscopic changes in all myocardial infarcts is as under:

1. *In 6 to 12 hours old infarcts*, no striking gross changes are discernible except that the affected myocardium is slightly paler and drier than normal. However, the early infarcts (3 to 6 hours old) can be detected by histochemical staining for *dehydrogenases* on unfixed slice of the heart. This consists of immersing a slice of unfixed heart in the solution of triphenyltetrazolium chloride (TTC) which imparts red brown colour to the normal heart muscle, while the area of infarcted muscle fails to stain due to lack of dehydrogenases.
2. *By about 24 hours*, the infarct develops cyanotic, red-purple, blotchy areas of haemorrhage due to stagnation of blood.
3. *During the next 48 to 72 hours*, the infarct develops a yellow border due to neutrophilic infiltration and thus becomes more well-defined.
4. *In 3-7 days*, the infarct has hyperaemic border while the centre is yellow and soft.
5. *By 10 days*, the periphery of the infarct appears reddish-purple due to growth of granulation tissue.
6. *By the end of 6 weeks*, the infarcted area is replaced by a thin, grey-white, hard, shrunken fibrous scar which is well developed in about 2 to 3 months. However, the time taken by an infarct to heal by fibrous scar may vary depending upon the size of the infarct and adequacy of collateral circulation (**Web Image 16.17**).

M/E The changes are similar in both transmural and subendocardial infarcts. As elsewhere in the body, myocardial ischaemia induces ischaemic coagulative necrosis of the myocardium which eventually heals by fibrosis. However, sequential light microscopic changes are observed as described below and diagrammatically shown in **Web Image 16.18**.

1. **First week:** The progression of changes takes place in the following way:
 - i) *In the first 6 hours* after infarction, usually no detectable histologic change is observed in routine light microscopy.
 - ii) *After 6 hours*, there is appearance of some oedema fluid between the myocardial fibres.
 - iii) *By 12 hours*, coagulative necrosis of the myocardial fibres sets in and neutrophils begin to appear at the margin of the infarct. Coagulative necrosis of fibres is characterised by loss of striations and intense eosinophilic, hyaline appearance and may show nuclear changes like karyolysis, pyknosis and karyorrhexis.
 - iv) *During the first 24 hours*, coagulative necrosis progresses further as evidenced by shrunken eosinophilic cytoplasm and pyknosis of the nuclei.
 - v) *During the first 48 to 72 hours*, coagulative necrosis is complete with loss of nuclei. The neutrophilic infiltrate is well developed and extends centrally into the interstitium.
 - vi) *In 3-7 days*, neutrophils are necrosed and gradually disappear. The process of resorption of necrosed muscle fibres by macrophages begins. Simultaneously, there is onset of proliferation of capillaries and fibroblasts from the margins of the infarct (**Web Image 16.19**).

358 **2. Second week:** The changes are as under:

- i) By *10th day*, most of the necrosed muscle at the periphery of infarct is removed. The fibrovascular reaction at the margin of infarct is more prominent.
- ii) By the *end of the 2nd week*, most of the necrosed muscle in small infarcts is removed, neutrophils have almost disappeared, and newly laid collagen fibres replace the periphery of the infarct.

3. Third week: Necrosed muscle fibres from larger infarcts continue to be removed and replaced by ingrowth of newly formed collagen fibres.

4. Fourth to sixth week: With further removal of necrotic tissue, there is increase in collagenous connective tissue, decreased vascularity and fewer pigmented macrophages, lymphocytes and plasma cells. Thus, at the end of 6 weeks, a contracted fibrocollagenic scar with diminished vascularity is formed.

SALVAGE IN EARLY INFARCTS AND REPERFUSION INJURY. In vast majority of cases of acute MI, occlusive coronary artery thrombosis has been demonstrated superimposed on fibrofatty plaque. The ischaemic injury to myocardium is reversible if perfusion is restored within the first 30 minutes of onset of infarction failing which irreversible ischaemic necrosis of myocardium sets in. The salvage in early infarcts can be achieved by the following interventions:

1. Institution of *thrombolytic therapy* with thrombolytic agents such as streptokinase and tissue plasminogen activator (door-to-needle time ≤ 30 minutes).
2. *Percutaneous transluminal coronary angioplasty (PTCA)*.
3. *Coronary artery stenting*.
4. *Coronary artery bypass surgery*.

However, attempt at reperfusion is fraught with the risk of ischaemic reperfusion injury. Further myonecrosis during reperfusion occurs due to rapid influx of calcium ions and generation of toxic oxygen free radicals.

CHANGES IN EARLY INFARCTS. These are as follows:

1. Electron microscopic changes. Changes by EM examination are evident in less than half an hour on onset of infarction. These changes are:

- i) Disappearance of perinuclear glycogen granules within 5 minutes of ischaemia.
- ii) Swelling of mitochondria in 20 to 30 minutes.
- iii) Disruption of sarcolemma.
- iv) Nuclear alterations like peripheral clumping of nuclear chromatin.

2. Chemical and histochemical changes. Analysis of tissues from early infarcts by chemical and histochemical techniques has shown a number of findings. These are as follows:

- i) Glycogen depletion in myocardial fibres within 30 to 60 minutes of infarction.
- ii) Increase in lactic acid in the myocardial fibres.
- iii) Loss of K^+ from the ischaemic fibres.
- iv) Increase of Na^+ in the ischaemic cells.
- v) Influx of Ca^{++} into the cells causing irreversible cell injury.

DIAGNOSIS. The diagnosis of acute MI is made on the observations of 3 types of features—clinical features, ECG changes, and serum enzyme determinations.

1. Clinical features. Typically, acute MI has a sudden onset. The following clinical features usually characterise a case of acute MI.

i) *Pain*, ii) *Indigestion*, iii) *Apprehension*, iv) *Shock*, v) *Oliguria*, vi) *Low grade fever* and vii) *Acute pulmonary oedema*.

2. ECG changes. The ECG changes are one of the most important parameters. Most characteristic ECG change is ST segment elevation in

acute MI (termed as STEMI); other changes include T wave inversion and appearance of wide deep Q waves (**Web Image 16.20**).

3. Serum cardiac markers. Certain proteins and enzymes are released into the blood from necrotic heart muscle after acute MI. Measurement of their levels in serum is helpful in making a diagnosis and plan management. Rapid assay of some more specific cardiac proteins is available rendering the estimation of non-specific estimation of SGOT of historical importance only in current practice. Important myocardial markers in use nowadays are as under (**Web Image 16.21**):

- i) *Creatine phosphokinase (CK) and CK-MB*: CK has three forms—
- CK-MM derived from skeletal muscle;
 - CK-BB derived from brain and lungs; and
 - CK-MB, mainly from cardiac muscles and insignificant amount from extracardiac tissue.

Thus total CK estimation lacks specificity while elevation of CK-MB isoenzyme is considerably specific for myocardial damage. CK-MB has further 2 forms—CK-MB2 is the myocardial form while CK-MB1 is extracardiac form. A ratio of CK-MB2: CK-MB1 above 1.5 is highly sensitive for the diagnosis of acute MI after 4-6 hours of onset of myocardial ischaemia. CK-MB disappears from blood by 48 hours.

- ii) *Lactic dehydrogenase (LDH)*. Total LDH estimation also lacks specificity since this enzyme is present in various tissues besides myocardium such as in skeletal muscle, kidneys, liver, lungs and red blood cells. However, like CK, LDH too has two isoforms of which LDH-1 is myocardial-specific. Estimation of ratio of LDH-1: LDH-2 above 1 is reasonably helpful in making a diagnosis. LDH levels begin to rise after 24 hours, reach peak in 3 to 6 days and return to normal in 14 days.

- iii) *Cardiac-specific troponins (cTn)*: Immunoassay of cTn as a serum cardiac marker has rendered LDH estimation obsolete. Troponins are contractile muscle proteins present in human cardiac and skeletal muscle but cardiac troponins are specific for myocardium. There are two types of cTn:

- cardiac troponin T (cTnT); and
- cardiac troponin I (cTnI).

Both cTnT and cTnI are not found in the blood normally, but after myocardial injury their levels rise very high around the same time when CK-MB is elevated (i.e. after 4-6 hours). Both troponin levels remain high for much longer duration; cTnI for 7-10 days and cTnT for 10-14 days.

- iv) *Myoglobin*: Though myoglobin is the first cardiac marker to become elevated after myocardial infarction, it lacks cardiac specificity and is excreted in the urine rapidly. Its levels, thus, return to normal within 24 hours of attack of acute MI.

COMPLICATIONS. Following an attack of acute MI, only 10-20% cases do not develop major complications and recover. The remainder 80-90% cases develop one or more major complications, some of which are fatal. The immediate mortality from acute MI (sudden cardiac death) is about 25%. The important complications which may develop following acute MI are: (i) Arrhythmias, (ii) Congestive heart failure, (iii) Cardiogenic shock, (iv) Mural thrombosis and thromboembolism, (v) Rupture, (vi) Cardiac aneurysm, (vii) Pericarditis and (viii) Postmyocardial infarction syndrome.

CHRONIC ISCHAEMIC HEART DISEASE (p. 436)

Chronic ischaemic heart disease, ischaemic cardiomyopathy or myocardial fibrosis, are the terms used for focal or diffuse fibrosis in the myocardium characteristically found in elderly patients of progressive IHD. Such small areas of fibrous scarring are commonly found in the heart of patients who have history of episodes of angina and attacks of MI some years back.

360 ETIOPATHOGENESIS. In majority of cases, coronary atherosclerosis causes progressive ischaemic myocardial damage and replacement by myocardial fibrosis. A small percentage of cases may result from other causes such as emboli, coronary arteritis and myocarditis.

G/A The heart may be normal in size or hypertrophied. The left ventricular wall generally shows foci of grey-white fibrosis in brown myocardium. Healed scars of previous MI may be present.

M/E (Web Image 16.22):

- i) There are scattered areas of diffuse myocardial fibrosis, especially around the small blood vessels in the interstitial tissue of the myocardium.
- ii) Intervening single fibres and groups of myocardial fibres show variation in fibre size and foci of myocytolysis.
- iii) Areas of brown atrophy of the myocardium may also be present.
- iv) Coronary arteries show atherosclerotic plaques and may have complicated lesions in the form of superimposed thrombosis.

SUDDEN CARDIAC DEATH (p. 436)

Sudden cardiac death is defined as sudden death within 24 hours of the onset of cardiac symptoms. The most important cause is coronary atherosclerosis; less commonly it may be due to coronary vasospasm and other non-ischaemic causes. These include: calcific aortic stenosis, myocarditis of various types, hypertrophic cardiomyopathy, mitral valve prolapse, endocarditis, and hereditary and acquired defects of the conduction system. The mechanism of sudden death by myocardial ischaemia is almost always by fatal arrhythmias, chiefly ventricular asystole or fibrillation.

At autopsy, such cases reveal most commonly critical atherosclerotic coronary narrowing (more than 75% compromised lumen) in one or more of the three major coronary arterial trunks with superimposed thrombosis or plaque-haemorrhage.

Web Table 16.5 lists the important forms of coronary artery pathology in various types of IHD.

HYPERTENSIVE HEART DISEASE (p. 437)

Hypertensive heart disease or hypertensive cardiomyopathy is the disease of the heart resulting from systemic hypertension of prolonged duration and manifesting by left ventricular hypertrophy. Even mild hypertension (blood pressure higher than 140/90 mmHg) of sufficient duration may induce hypertensive heart disease. It is the second most common form of heart disease after IHD. As already pointed out, hypertension predisposes to atherosclerosis. Therefore, most patients of hypertensive heart disease have advanced coronary atherosclerosis and may develop progressive IHD.

PATHOGENESIS. Stimulus to LVH is pressure overload in systemic hypertension. Both genetic and haemodynamic factors contribute to LVH. The stress of pressure on the ventricular wall causes increased production of myofilaments, myofibrils, other cell organelles and nuclear enlargement. Since the adult myocardial fibres do not divide, the fibres are hypertrophied. However, the sarcomeres may divide to increase the cell width.

G/A The most significant finding is marked hypertrophy of the heart, chiefly of the left ventricle (see Web Image 16.5). The weight of the heart increases to 500 gm or more (normal weight about 300 gm). The thickness of the left ventricular wall increases from its normal 13 to 15 mm up to 20 mm or more. The papillary muscles and trabeculae carneae are rounded and prominent. Initially, there is *concentric hypertrophy* of the left ventricle (without dilatation). But when decompensation and cardiac failure supervene, there is *eccentric hypertrophy* (with dilatation) with thinning of the ventricular wall and there may be dilatation and hypertrophy of right heart as well.

M/E The features are not as prominent as macroscopic appearance. The changes include enlargement and degeneration of myocardial fibres with focal areas of myocardial fibrosis. In advanced cases, there may be myocardial oedema and foci of necrosis in the myocardium.

Cor pulmonale (*cor*= heart; *pulmonale*= lung) or pulmonary heart disease is the disease of right side of the heart resulting from disorders of the lungs. It is characterised by right ventricular dilatation or hypertrophy, or both. Thus, cor pulmonale is the right-sided counterpart of the hypertensive heart disease described above.

Depending upon the rapidity of development, cor pulmonale may be acute or chronic:

◆ **Acute cor pulmonale** occurs following massive pulmonary embolism resulting in sudden dilatation of the pulmonary trunk, conus and right ventricle.

◆ **Chronic cor pulmonale** is more common and is often preceded by chronic pulmonary hypertension. Following chronic lung diseases can cause chronic pulmonary hypertension and subsequent cor pulmonale:

- i) Chronic emphysema
- ii) Chronic bronchitis
- iii) Pulmonary tuberculosis
- iv) Pneumoconiosis
- v) Cystic fibrosis
- vi) Hyperventilation in marked obesity (Pickwickian syndrome)
- vii) Multiple organised pulmonary emboli.

PATHOGENESIS. Chronic lung diseases as well as diseases of the pulmonary vessels cause increased pulmonary vascular resistance. The most common underlying mechanism causing increased pulmonary blood pressure (pulmonary hypertension) is by pulmonary vasoconstriction, activation of coagulation pathway and obliteration of pulmonary arterial vessels. Pulmonary hypertension causes pressure overload on the right ventricle and hence right ventricular enlargement. Initially, there is right ventricular hypertrophy, but as cardiac decompensation sets in and right heart failure ensues, dilatation of right ventricle occurs.

The sequence of events involved in the pathogenesis of cor pulmonale is summarised in **Web Image 16.23**.

MORPHOLOGIC FEATURES. In *acute cor pulmonale*, there is characteristic ovoid dilatation of the right ventricle, and sometimes of the right atrium. In *chronic cor pulmonale*, there is increase in thickness of the right ventricular wall from its normal 3 to 5 mm up to 10 mm or more. Often, there is dilatation of the right ventricle too.

RHEUMATIC FEVER AND RHEUMATIC HEART DISEASE (p. 438)

□ DEFINITION (p. 438)

Rheumatic fever (RF) is a systemic, post-streptococcal, non-suppurative inflammatory disease, principally affecting the heart, joints, central nervous system, skin and subcutaneous tissues. The chronic stage of RF involves all the layers of the heart (pancarditis) causing major cardiac sequelae referred to as rheumatic heart disease (RHD). In spite of its name suggesting an acute arthritis migrating from joint to joint, it is well known that it is the heart rather than the joints which is first and major organ affected. William Boyd years ago gave the dictum '*rheumatism licks the joint, but bites the whole heart*'.

362 □ **INCIDENCE** (p. 438)

The disease appears most commonly in children between the age of 5 to 15 years when the streptococcal infection is most frequent and intense. Both the sexes are affected equally, though some investigators have noted a slight female preponderance.

□ **ETIOPATHOGENESIS** (p. 438)

After a long controversy, the etiologic role of preceding throat infection with β -haemolytic streptococci of group A in RF is now well accepted. However, the mechanism of lesions in the heart, joints and other tissues is not by direct infection but by induction of hypersensitivity or autoimmunity. Thus, there are 2 types of evidences in the etiology and pathogenesis of RF and RHD: the *epidemiologic evidence* and the *immunologic evidence*.

A. EPIDEMIOLOGIC EVIDENCE. These evidences are as under:

1. There is often a *history* of infection of the pharynx and upper respiratory tract with this microorganism about 2 to 3 weeks prior to the attack of RF.
2. *Subsequent attacks* of streptococcal infection are generally associated with exacerbations of RF.
3. A higher incidence of RF has been observed after outbreaks and *epidemics* of streptococcal infection of throat in children from schools or in young men from training camps.
4. Administration of *antibiotics* leads to lowering of the incidence as well as severity of RF and its recurrences.
5. Cardiac lesions similar to those seen in RHD have been produced in experimental animals by *induction* of repeated infection with β -haemolytic streptococci of group A.
6. Patients with RF have *elevated titres* of antibodies to the antigens of β -haemolytic streptococci of group A such as anti-streptolysin O (ASO) and S, anti-streptokinase, anti-streptohyaluronidase and anti-DNAase B.
7. *Socioeconomic factors* like poverty, poor nutrition, density of population, overcrowding in quarters for sleeping etc are associated with spread of infection.
8. The *geographic distribution* of the disease shows higher frequency and severity of the disease in the developing countries of the world where the living conditions are substandard and medical facilities are insufficient.
9. The role of *climate* in the development of RF has been reported by some workers. The incidence of the disease is higher in subtropical and tropical regions with cold, damp climate near the rivers and waterways which favour the spread of infection.
10. There is evidence to support the role of *heredity*. Susceptibility to develop RF in families, occurrence in identical twins and in individuals with HLA class II alleles supports the inherited characteristic of the disease.

Despite all these evidences, only a small proportion of patients with streptococcal pharyngeal infection develop RF—the attack rate is less than 3%. There is a suggestion that a *concomitant virus* enhances the effect of streptococci in individuals who develop RF.

B. IMMUNOLOGIC EVIDENCE. It has been observed that though throat of patients during acute RF contain streptococci, the clinical symptoms of RF appear after a delay of 2-3 weeks and the organisms cannot be grown from the lesions in the target tissues. This has led to the concept that lesions have immune pathogenesis.

A susceptible host, on being encountered with group A streptococcus infection, mounts an autoimmune reaction by formation of autoantibodies against bacteria. These autoantibodies cause damage to human tissues due to cross-reactivity between epitopes in the components of bacteria and the host. Streptococcal epitopes present on the bacterial cell wall, cell membrane and the streptococcal M protein, are immunologically identical to

human molecules on myosin, keratin, actin, laminin, vimentin and N-acetylglucosamine. Further evidences in support are as under:

1. *Cell wall polysaccharide* of group A streptococcus forms antibodies which are reactive against cardiac valves.
2. *Hyaluronate capsule* of group A streptococcus is identical to human hyaluronate present in joint tissues and thus these tissues are the target of attack.
3. *Membrane antigens* of group A streptococcus react with sarcolemma of smooth and cardiac muscle, dermal fibroblasts and neurons of caudate nucleus.

□ MORPHOLOGIC FEATURES

A. Cardiac Lesions (p. 439)

The cardiac manifestations of RF are in the form of focal inflammatory involvement of the interstitial tissue of all the three layers of the heart, the so-called *pancarditis*. The pathognomonic feature of pancarditis in RF is the presence of distinctive *Aschoff nodules* or *Aschoff bodies*.

THE ASCHOFF NODULES OR BODIES. The Aschoff nodules or the Aschoff bodies are spheroidal or fusiform distinct tiny structures, 1-2 mm in size, occurring in the interstitium of the heart in RF and may be visible to naked eye. They are especially found in the vicinity of small blood vessels in the myocardium and endocardium and occasionally in the pericardium and the adventitia of the proximal part of the aorta. Lesions similar to the Aschoff nodules may be found in the extracardiac tissues.

Evolution of fully-developed Aschoff bodies involves 3 stages all of which may be found in the same heart at different stages of development.

1. Early (exudative or degenerative) stage. The earliest sign of injury in the heart in RF is apparent by *about 4th week* of illness. Initially, there is oedema of the connective tissue and increase in acid mucopolysaccharide in the ground substance. This results in separation of the collagen fibres by accumulating ground substance. Eventually, the collagen fibres are fragmented and disintegrated and the affected focus takes the appearance and staining characteristics of fibrin. This change is referred to as *fibrinoid degeneration*.

2. Intermediate (proliferative or granulomatous) stage. It is this stage of the Aschoff body which is pathognomonic of rheumatic conditions (**Web Image 16.24**). This stage is apparent in 4th to 13th week of illness. The early stage of fibrinoid change is followed by proliferation of cells that includes infiltration by lymphocytes (mostly T cells), plasma cells, a few neutrophils and the characteristic *cardiac histiocytes (Anitschkow cells)* at the margin of the lesion. Cardiac histiocytes or Anitschkow cells are present in small numbers in normal heart but their number is increased in the Aschoff bodies. These are large mononuclear cells having central round nuclei and contain moderate amount of amphophilic cytoplasm. The nuclei are vesicular and contain prominent central chromatin mass which in longitudinal section appears serrated or caterpillar-like, while in cross-section the chromatin mass appears as a small rounded body in the centre of the vesicular nucleus, just like an owl's eye. Some of these modified cardiac histiocytes become multinucleate cells containing 1 to 4 nuclei and are called *Aschoff cells* and are pathognomonic of RHD.

3. Late (healing or fibrous) stage. The stage of healing by fibrosis of the Aschoff nodule occurs in about *12 to 16 weeks* after the illness. The nodule becomes oval or fusiform in shape, about 200 μm wide and 600 μm long. The Anitschkow cells in the nodule become spindle-shaped with diminished cytoplasm and the nuclei stain solidly rather than showing vesicular character.

364 RHEUMATIC PANCARDITIS. Although all the three layers of the heart are affected in RF, the intensity of their involvement is variable.

1. RHEUMATIC ENDOCARDITIS. Endocardial lesions of RF may involve the valvular and mural endocardium, causing *rheumatic valvulitis* and *mural endocarditis*, respectively.

□ RHEUMATIC VALVULITIS. G/A The valves in **acute RF** show thickening and loss of translucency of the valve leaflets or cusps. This is followed by the formation of characteristic, small (1 to 3 mm in diameter), multiple, warty *vegetations* or *verrucae*, chiefly along the line of closure of the leaflets and cusps. The vegetations in RF appear grey-brown, translucent and are firmly attached so that they are not likely to get detached to form emboli, unlike the friable vegetations of infective endocarditis.

Though all the four heart valves are affected, their frequency and severity of involvement varies: mitral valve alone being the most common site, followed in decreasing order of frequency, by combined mitral and aortic valve (**Web Image 16.25**). The higher incidence of vegetations on left side of the heart is possibly because of the greater mechanical stresses on the valves of the left heart, especially along the line of closure of the valve cusps (**Web Image 16.26, A**).

The **chronic stage of RHD** is characterised by permanent deformity of one or more valves, especially the mitral (in 98% cases alone or along with other valves) and aortic. The approximate frequency of deformity of various valves is as under:

- Mitral alone = 37% cases.
- Mitral + aortic = 27% cases.
- Mitral + aortic + tricuspid = 22% cases.
- Mitral + tricuspid = 11% cases.
- Aortic alone = 2%.
- Mitral + aortic + tricuspid + pulmonary = less than 1% cases.

Thus, mitral valve is almost always involved in RHD. Gross appearance of chronic healed mitral valve in RHD is characteristically '*fish mouth*' or '*button hole*' stenosis. Mitral stenosis and insufficiency are commonly combined in chronic RHD; calcific aortic stenosis may also be found. Thickening, shortening and fusion of the chordae tendineae further contribute to the chronic valvular lesions (**Web Image 16.26, B**).

M/E The inflammatory changes begin in the region of the valve rings (where the leaflets are attached to the fibrous annulus) and then extend throughout the entire leaflet, whereas vegetations are usually located on the free margin of the leaflets and cusps.

- i) In the **early (acute) stage**, the histological changes are oedema of the valve leaflet, presence of increased number of capillaries and infiltration with lymphocytes, plasma cells, histiocytes with many Anitschkow cells and a few polymorphs. Vegetations present at the free margins of cusps appear as eosinophilic, tiny structures mainly consisting of fibrin with superimposed platelet-thrombi and do not contain bacteria (**Web Image 16.27, A**).
- ii) In the **healed (chronic) stage**, the vegetations have undergone organisation. The valves show diffuse thickening as a result of fibrous tissue with hyalinisation, and often calcification (**Web Image 16.27, B**).

□ RHEUMATIC MURAL ENDOCARDITIS. Mural endocardium may also show features of rheumatic carditis though the changes are less conspicuous as compared to valvular changes.

G/A The lesions are seen most commonly as *MacCallum's patch* which is the region of endocardial surface in the posterior wall of the left atrium just above the posterior leaflet of the mitral valve. MacCallum's patch appears as a map-like area of thickened, roughened and wrinkled part of the endocardium (*see Web Image 16.25*).

M/E The appearance of MacCallum's patch is similar to that seen in rheumatic valvulitis. The affected area shows oedema, fibrinoid change in the collagen, and cellular infiltrate of lymphocytes, plasma cells and macrophages with many Anitschkow cells.

2. RHEUMATIC MYOCARDITIS. G/A In the *early (acute) stage*, the myocardium, especially of the left ventricle, is soft and flabby. In the *intermediate stage*, the interstitial tissue of the myocardium shows small foci of necrosis. Later, tiny pale foci of the Aschoff bodies may be visible throughout the myocardium.

M/E The most characteristic feature of rheumatic myocarditis is the presence of distinctive Aschoff bodies. These diagnostic nodules are scattered throughout the interstitial tissue of the myocardium and are most frequent in the interventricular septum, left ventricle and left atrium. Derangements of the conduction system may, thus, be present.

3. RHEUMATIC PERICARDITIS. Inflammatory involvement of the pericardium commonly accompanies RHD.

G/A The usual finding is fibrinous pericarditis in which there is loss of normal shiny pericardial surface due to deposition of fibrin on its surface and accumulation of slight amount of fibrinous exudate in the pericardial sac. If the parietal pericardium is pulled off from the visceral pericardium, the two separated surfaces are shaggy due to thick fibrin covering them. This appearance is often likened to '*bread and butter appearance*'.

M/E Fibrin is identified on the surfaces. The subserosal connective tissue is infiltrated by lymphocytes, plasma cells, histiocytes and a few neutrophils.

B. EXTRACARDIAC LESIONS (p. 442)

1. POLYARTHRITIS. Acute and painful inflammation of the synovial membranes of some of the joints, especially the larger joints of the limbs, is seen in about 90% cases of RF in adults and less often in children. As pain and swelling subside in one joint, others tend to get involved, producing the characteristic '*migratory polyarthritis*' involving two or more joints at a time.

2. SUBCUTANEOUS NODULES. The subcutaneous nodules of RF occur more often in children than in adult. These nodules are small (0.5 to 2 cm in diameter), spherical or ovoid and painless. They are attached to deeper structures like tendons, ligaments, fascia or periosteum and therefore often remain unnoticed by the patient. Characteristic locations are extensor surfaces of the wrists, elbows, ankles and knees.

3. ERYTHEMA MARGINATUM. This non-pruritic erythematous rash is characteristic of RF. The lesions occur mainly on the trunk and proximal parts of the extremities.

4. RHEUMATIC ARTERITIS. Arteritis in RF involves not only the coronary arteries and the aorta but also occurs in arteries of various other organs such as renal, mesenteric and cerebral arteries. The lesions in the coronaries are seen mainly in the small intramyocardial branches.

5. CHOREA MINOR. Chorea minor or Sydenham's chorea or Saint Vitus' dance is a delayed manifestation of RF as a result of involvement of the central nervous system.

6. RHEUMATIC PNEUMONITIS AND PLEURITIS. Involvement of the lungs and pleura occurs rarely in RF. Pleuritis is often accompanied with serofibrinous pleural effusion but definite Aschoff bodies are not present.

□ CLINICAL FEATURES (p. 443)

The first attack of acute RF generally appears 2 to 3 weeks after streptococcal pharyngitis, most often in children between the age of 5 to 15 years. With

366 subsequent streptococcal pharyngitis, there is reactivation of the disease and similar clinical manifestations appear with each recurrent attack. The disease generally presents with migratory polyarthritis and fever. However, RF has widespread systemic involvement and no single specific laboratory diagnostic test is available. As per revised WHO criteria (2004) based on revised Jones' criteria (first described by Dr. TD Jones in 1944, and last revised in 1992), following major and minor criteria are included for diagnosis:

A. Major criteria:

1. Carditis
2. Polyarthritis
3. Chorea (Sydenham's chorea)
4. Erythema marginatum
5. Subcutaneous nodules

B. Minor criteria:

1. Fever
2. Arthralgia
3. Previous history of RF
4. Laboratory findings of elevated ESR, raised C-reactive protein, and leucocytosis
5. ECG finding of prolonged PR interval.

C. Supportive evidence of preceding group A streptococcal infection include: positive throat culture for group A streptococci, raised titres of streptococcal antibodies (antistreptolysin O and S, antistreptokinase, anti-streptohyaluronidase and anti DNAase B).

Clinical **diagnosis of RF** and RHD is made in a case with antecedent laboratory evidence of streptococcal throat infection in the presence of *any two of the major criteria, or occurrence of one major and two minor criteria.*

The long-term sequelae or **stigmata** are the chronic valvular deformities, especially the mitral stenosis.

The major **causes of death** in RHD are cardiac failure, bacterial endocarditis and embolism.

Endocarditis can be broadly grouped into *non-infective* and *infective* types (**Web Table 16.6**). Most types of endocarditis are characterised by the presence of 'vegetations' or 'verrucae' which have distinct features.

ATYPICAL VERRUCOUS (LIBMAN-SACKS) ENDOCARDITIS (p. 444)

Libman and Sacks, two American physicians, described a form of endocarditis in 1924 that is characterised by sterile endocardial vegetations which are distinguishable from the vegetations of RHD and bacterial endocarditis.

ETIOPATHOGENESIS. Atypical verrucous endocarditis is one of the manifestations of 'collagen diseases'. Characteristic lesions of Libman-Sacks endocarditis are seen in 50% cases of *acute systemic lupus erythematosus (SLE)*; other diseases associated with this form of endocarditis are systemic sclerosis, thrombotic thrombocytopenic purpura (TTP) and other collagen diseases.

G/A Characteristic vegetations occur most frequently on the mitral and tricuspid valves. The vegetations of atypical verrucous endocarditis are small (1 to 4 mm in diameter), granular, multiple and tend to occur on both surfaces of affected valves, in the valve pockets and on the adjoining ventricular and atrial endocardium. The vegetations are sterile unless superimposed by bacterial endocarditis. Unlike vegetations of RHD, the healed vegetations of Libman-Sacks endocarditis do not produce any significant valvular deformity.

M/E The verrucae of Libman-Sacks endocarditis are composed of fibrinoid material with superimposed fibrin and platelet thrombi. The endocardium underlying the verrucae shows characteristic histological changes which include fibrinoid necrosis, proliferation of capillaries and infiltration by histiocytes, plasma cells, lymphocytes, neutrophils and the pathognomonic *haematoxylin bodies* of Gross which are counterparts of LE cells of the blood.

□ **NON-BACTERIAL THROMBOTIC (CACHECTIC, MARANTIC) ENDOCARDITIS** (p. 444)

Non-bacterial thrombotic, cachectic, marantic or terminal endocarditis or endocarditis simplex is an involvement of the heart valves by sterile thrombotic vegetations.

ETIOPATHOGENESIS. The exact pathogenesis of lesions in non-bacterial thrombotic endocarditis (NBTE) is not clear. Vegetations are found at autopsy in 0.5 to 5% of cases. The following diseases and conditions are frequently associated with their presence:

1. In patients having hypercoagulable state from various etiologies e.g. advanced cancer (in 50% case of NBTE) especially mucinous adenocarcinomas, chronic tuberculosis, renal failure and chronic sepsis. In view of its association with chronic debilitating and wasting diseases, alternate names for NBTE such as 'cachectic', 'marantic' and 'terminal' endocarditis are used synonymously.
2. Occurrence of these lesions in young and well-nourished patients is explained on the basis of *alternative hypothesis* such as allergy, vitamin C deficiency, deep vein thrombosis, and endocardial trauma (e.g. due to catheter in pulmonary artery and haemodynamic trauma to the valves).

G/A The verrucae of NBTE are located on cardiac valves, chiefly mitral, and less often aortic and tricuspid valve. These verrucae are usually small (1 to 5 mm in diameter), single or multiple, brownish and occur along the line of closure of the leaflets but are more friable than the vegetations of RHD.

M/E The vegetations in NBTE are composed of fibrin along with entangled RBCs, WBCs and platelets. Vegetations in NBTE are sterile, bland and do not cause tissue destruction.

□ **INFECTIVE (BACTERIAL) ENDOCARDITIS** (p. 445)

DEFINITION. Infective or bacterial endocarditis (IE or BE) is serious infection of the valvular and mural endocardium caused by different forms of microorganisms and is characterised by typical infected and friable vegetations. Depending upon the severity of infection, BE is subdivided into 2 clinical forms:

1. **Acute bacterial endocarditis (ABE)** is fulminant and destructive acute infection of the endocardium by highly virulent bacteria in a previously normal heart and almost invariably runs a rapidly fatal course in a period of 2-6 weeks.
2. **Subacute bacterial endocarditis (SABE) or endocarditis lenta** (*lenta* = slow) is caused by less virulent bacteria in a previously diseased heart and has a gradual downhill course in a period of 6 weeks to a few months and sometimes years.

Although classification of bacterial endocarditis into acute and subacute forms has been largely discarded because the clinical course is altered by antibiotic treatment, still a few important distinguishing features are worth describing (**Web Table 16.7**).

INCIDENCE. Introduction of antibiotic drugs has helped greatly in lowering the incidence of BE as compared with its incidence in the pre-antibiotic era.

368 Though BE may occur at any age, most cases of ABE as well as SABE occur over 50 years of age. Males are affected more often than females.

ETIOLOGY. All cases of BE are caused by *infection with microorganisms* in patients having certain predisposing factors.

A. Infective agents. About 90% cases of BE are caused by streptococci and staphylococci.

◆ *In ABE*, the most common causative organisms are virulent strains of staphylococci, chiefly *Staphylococcus aureus*. Others are pneumococci, gonococci, β -streptococci and enterococci.

◆ *In SABE*, the commonest causative organisms are the streptococci with low virulence, predominantly *Streptococcus viridans*, which forms part of normal flora of the mouth and pharynx. Other less common etiologic agents include other strains of streptococci and staphylococci (e.g. *Streptococcus bovis* which is the normal inhabitant of gastrointestinal tract, *Streptococcus pneumoniae*, and *Staphylococcus epidermidis* which is a commensal of the skin), gram-negative enteric bacilli (e.g. *E. coli*, *Klebsiella*, *Pseudomonas* and *Salmonella*), pneumococci, gonococci and *Haemophilus influenzae*.

B. Predisposing factors. There are 3 main factors which predispose to the development of both forms of BE:

1. *Bacteraemia, septicaemia and pyaemia:* Bacteria gain entrance to the bloodstream causing transient and clinically silent bacteraemia in a variety of day-to-day procedures as well as from other sources of infection. Some of the common examples are:

- i) Periodontal infections such as trauma from vigorous brushing of teeth, hard chewing, tooth extraction and other dental procedures.
- ii) Infections of the genitourinary tract such as in catheterisation, cystoscopy, obstetrical procedures including normal delivery and abortions.
- iii) Infections of gastrointestinal and biliary tract.
- iv) Surgery of the bowel, biliary tract and genitourinary tracts.
- v) Skin infections such as boils, carbuncles and abscesses.
- vi) Upper and lower respiratory tract infections including bacterial pneumonias.
- vii) Intravenous drug abuse.
- viii) Cardiac catheterisation and cardiac surgery for implantation of prosthetic valves.

2. *Underlying heart disease:* SABE occurs much more frequently in previously diseased heart valves, whereas the ABE is common in previously normal heart. Amongst the commonly associated underlying heart diseases are the following:

- i) Chronic rheumatic valvular disease in about 50% cases.
- ii) Congenital heart diseases in about 20% cases. These include VSD, subaortic stenosis, pulmonary stenosis, bicuspid aortic valve, coarctation of the aorta, and PDA.
- iii) Other causes are syphilitic aortic valve disease, atherosclerotic valvular disease, floppy mitral valve, and prosthetic heart valves.

3. *Impaired host defenses:* All conditions in which there is depression of specific immunity, deficiency of complement and defective phagocytic function, predispose to BE. Following are some of the examples of such conditions:

- i) Impaired specific immunity in lymphomas.
- ii) Leukaemias.
- iii) Cytotoxic therapy for various forms of cancers and transplant patients.
- iv) Deficient functions of neutrophils and macrophages.

PATHOGENESIS. Bacteria causing BE on entering the bloodstream from any of the above-mentioned routes are implanted on the cardiac valves or mural endocardium because they have surface adhesion molecules which

mediate their adherence to injured endocardium. There are several predisposing conditions which explain the development of bacterial implants on the valves, e.g. *previously damaged valves*, *haemodynamic stress* and *non-bacterial thrombotic endocarditis*.

MORPHOLOGIC FEATURES. The characteristic pathologic feature in both ABE and SABE is the presence of typical vegetations or verrucae on the valve cusps or leaflets, and less often, on mural endocardium, which are quite distinct for other types. A summary of the distinguishing features of the principal types of vegetations is presented in **Web Table 16.8**.

G/A The lesions are found commonly on the valves of the left heart, most frequently on the mitral, followed in descending frequency, by the aortic, simultaneous involvement of both mitral and aortic valves, and quite rarely on the valves of the right heart. The vegetations in SABE are more often seen on previously diseased valves, whereas the vegetations of ABE are often found on previously normal valves. Like in RHD, the vegetations are often located on the atrial surface of atrioventricular valves and ventricular surface of the semilunar valves. They begin from the contact areas of the valve and may extend along the surface of the valves and on to the adjacent endocardium (**Web Image 16.28**).

The *vegetations* of BE vary in size from a few millimeters to several centimeters, grey-tawny to greenish, irregular, single or multiple, and typically *friable*. They may appear flat, filiform, fungating or polypoid.

M/E The vegetations of BE consist of 3 zones (**Web Image 16.29**):

- i) The *outer layer or cap* consists of eosinophilic material composed of fibrin and platelets.
- ii) Underneath this layer is the *basophilic zone* containing colonies of bacteria. However, bacterial component of the vegetations may be lacking in treated cases.
- iii) The *deeper zone* consists of non-specific inflammatory reaction in the cusp itself, and in the case of SABE there may be evidence of repair.

COMPLICATIONS AND SEQUELAE. Most cases of BE present with fever. The acute form of BE is characterised by high grade fever, chills, weakness and malaise while the subacute form of the disease has non-specific manifestations like slight fever, fatigue, loss of weight and flu-like symptoms. In the early stage, the lesions are confined to the heart, while subsequent progression of the disease leads to involvement of extra-cardiac organs (**Web Image 16.30**):

A. Cardiac complications. These include the following:

- i) Valvular stenosis or insufficiency
- ii) Perforation, rupture, and aneurysm of valve leaflets
- iii) Abscesses in the valve ring
- iv) Myocardial abscesses
- v) Suppurative pericarditis
- vi) Cardiac failure from one or more of the foregoing complications.

B. Extracardiac complications. Since the vegetations in BE are typically friable, they tend to get dislodged due to rapid stream of blood and give rise to embolism which is responsible for very common and serious extra-cardiac complications. These are as under:

- i) Emboli originating from the *left side of the heart* and entering the systemic circulation affect organs like the spleen, kidneys, and brain causing infarcts, abscesses and mycotic aneurysms.
- ii) Emboli arising from *right side of the heart* enter the pulmonary circulation and produce pulmonary abscesses.
- iii) *Petechiae* may be seen in the skin and conjunctiva due to either emboli or toxic damage to the capillaries.
- iv) In SABE, there are painful, tender nodules on the finger tips of hands and feet called *Osler's nodes*, while in ABE there is appearance of painless, non-tender subcutaneous maculopapular lesions on the pulp of the fingers

370 called *Janeway's spots*. In either case, their origin is due to toxic or allergic inflammation of the vessel wall.

v) *Focal necrotising glomerulonephritis* is seen more commonly in SABE than in ABE. Occasionally diffuse glomerulonephritis may occur.

□ **SPECIFIC TYPES OF INFECTIVE ENDOCARDITIS** (p. 448)

1. **Tuberculous endocarditis.** Though tubercle bacilli are bacteria, tuberculous endocarditis is described separate from the bacterial endocarditis due to specific granulomatous inflammation found in tuberculosis. It is characterised by presence of typical tubercles on the valvular as well as mural endocardium and may form tuberculous thromboemboli.

2. **Syphilitic endocarditis.** The endocardial lesions in syphilis have already been described in relation to syphilitic aortitis. The severest manifestation of cardiovascular syphilis is aortic valvular incompetence.

3. **Fungal endocarditis.** Rarely, endocardium may be infected with fungi such as from *Candida albicans*, *Histoplasma capsulatum*, *Aspergillus*, *Mucor*, coccidioidomycosis, cryptococcosis, blastomycosis and actinomycosis. Opportunistic fungal infections like candidiasis and aspergillosis are seen more commonly in patients receiving long-term antibiotic therapy, intravenous drug abusers and after prosthetic valve replacement.

4. **Viral endocarditis.** There is only experimental evidence of existence of this entity.

5. **Rickettsial endocarditis.** Another rare cause of endocarditis is from infection with rickettsiae in Q fever.

Valvular diseases are various forms of congenital and acquired diseases which cause valvular deformities. Many of them result in cardiac failure. Rheumatic heart disease is the most common form of acquired valvular disease. Valves of the left side of the heart are involved much more frequently than those of the right side of the heart. The mitral valve is affected most often, followed in descending frequency, by the aortic valve, and combined mitral and aortic valves. The valvular deformities may be of 2 types: stenosis and insufficiency:

◆ *Stenosis* is the term used for failure of a valve to open completely during diastole resulting in obstruction to the forward flow of the blood.

◆ *Insufficiency or incompetence or regurgitation* is the failure of a valve to close completely during systole resulting in back flow or regurgitation of the blood.

□ **MITRAL STENOSIS** (p. 449)

Mitral stenosis occurs in approximately 40% of all patients with RHD. About 70% of the patients are women. The latent period between the rheumatic carditis and development of symptomatic mitral stenosis is about two decades.

ETIOLOGY. Mitral stenosis is generally rheumatic in origin. Less common causes include bacterial endocarditis, Libman-Sacks endocarditis, endocardial fibroelastosis and congenital parachute mitral valve.

MORPHOLOGIC FEATURES. The appearance of the mitral valve in stenosis varies according to the extent of involvement. Generally, the valve leaflets are diffusely thickened by fibrous tissue and/or calcific deposits, especially towards the closing margin. There are fibrous adhesions of mitral commissures and fusion and shortening of chordae tendineae. In less extensive involvement, the bases of the leaflets of mitral valve are mobile while the free margins have puckered and thickened tissue with narrowed orifice; this is called as '*purse-string puckering*'. The more advanced cases have rigid, fixed and immobile diaphragm-like valve leaflets with narrow, slit-

like or oval mitral opening, commonly referred to as 'button-hole' or 'fish-mouth' mitral orifice (**Web Image 16.31,B**).

EFFECTS. These are as under:

1. Dilatation and hypertrophy of the left atrium.
2. Normal-sized or atrophic left ventricle due to reduced inflow of blood.
3. Pulmonary hypertension resulting from passive backward transmission of elevated left arterial pressure which causes:
 - i) chronic passive congestion of the lungs;
 - ii) hypertrophy and dilatation of the right ventricle; and
 - iii) dilatation of the right atrium when right heart failure supervenes.

□ **MITRAL INSUFFICIENCY** (p. 450)

Mitral insufficiency is caused by RHD in about 50% of patients but in contrast to mitral stenosis, pure mitral insufficiency occurs more often in men (75%). Subsequently, mitral insufficiency is associated with some degree of mitral stenosis.

ETIOLOGY. All the causes of mitral stenosis may produce mitral insufficiency, RHD being the most common cause. In addition, mitral insufficiency may result from non-inflammatory calcification of mitral valve annulus (in the elderly), myxomatous transformation of mitral valve (floppy valve syndrome), rupture of a leaflet or of the chordae tendineae or of a papillary muscle.

MORPHOLOGIC FEATURES. The appearance of the mitral valve in insufficiency varies according to the underlying cause. The rheumatic process produces rigidity, deformity and retraction of the valve leaflets and fusion of commissures as well as shortening and fusion of chordae tendineae (**Web Image 16.31,C**).

◆ In *myxomatous degeneration* of the mitral valve leaflets (floppy valve syndrome), there is prolapse of one or both leaflets into the left atrium during systole.

◆ In *non-inflammatory calcification* of mitral annulus seen in the aged, there is irregular, stony-hard, bead-like thickening in the region of mitral annulus without any associated inflammatory changes. It is thought to reflect degenerative changes of aging.

EFFECTS. These are:

1. Dilatation and hypertrophy of the left ventricle.
2. Marked dilatation of the left atrium.
3. Features of pulmonary hypertension such as:
 - i) chronic passive congestion of the lungs;
 - ii) hypertrophy and dilatation of the right ventricle; and
 - iii) dilatation of the right atrium when right heart failure supervenes.

□ **AORTIC STENOSIS** (p. 450)

Aortic stenosis comprises about one-fourth of all patients with chronic valvular heart disease. About 80% patients of symptomatic aortic stenosis are males. It is of 2 main types:

1. Non-calcific aortic stenosis. The most common cause of non-calcific aortic stenosis is chronic RHD. Other causes are congenital valvular and subaortic stenosis and congenitally bicuspid aortic valve.

2. Calcific aortic stenosis. Calcific aortic stenosis is more common type. Various causes have been ascribed to it. These include healing by scarring followed by calcification of aortic valve such as in RHD, bacterial endocarditis, *Brucella* endocarditis, Monckeberg's calcific aortic stenosis, healed congenital malformation and familial hypercholesterolaemic xanthomatosis.

MORPHOLOGIC FEATURES. The aortic cusps show characteristic fibrous thickening and calcific nodularity of the closing edges. Calcified nodules are often found in the sinuses of Valsalva. In rheumatic aortic stenosis, the

372 commissures are fused and calcified, while in non-rheumatic aortic stenosis there is no commissural fusion (**Web Image 16.32,B**).

EFFECTS. The major effect of aortic stenosis is obstruction to the outflow resulting in concentric hypertrophy of the left ventricle. Later, when cardiac failure supervenes, there is dilatation as well as hypertrophy of the left ventricle (eccentric hypertrophy).

The *three cardinal symptoms* of aortic stenosis are: exertional dyspnoea, angina pectoris and syncope.

□ **AORTIC INSUFFICIENCY** (p. 451)

About three-fourth of all patients with aortic insufficiency are males with some having family history of Marfan's syndrome.

ETIOLOGY. In about 75% of patients, the cause is chronic RHD. However, isolated aortic insufficiency is less often due to rheumatic etiology. Other causes include syphilitic valvulitis, infective endocarditis, congenital subaortic stenosis (congenitally bicuspid aortic valve), myxomatous degeneration of aortic valve (floppy valve syndrome), traumatic rupture of the valve cusps, dissecting aneurysm, Marfan's syndrome and ankylosing spondylitis.

MORPHOLOGIC FEATURES. The aortic valve cusps are thickened, deformed and shortened and fail to close. There is generally distension and distortion of the ring (**Web Image 16.31,C**).

EFFECTS. As a result of regurgitant aortic orifice, there is increase of the left ventricular end-diastolic volume. This leads to hypertrophy and dilatation of the left ventricle producing massive cardiac enlargement so that the heart may weigh as much as 1000 gm.

The characteristic physical findings in a patient of aortic insufficiency are awareness of the beatings of the heart, poundings in the head with each heartbeat, low diastolic and high pulse pressure, rapidly rising and collapsing water hammer pulse (Corrigan's pulse), booming 'pistol shot' sound over the femoral artery.

□ **CARCINOID HEART DISEASE** (p. 451)

ETIOLOGY. Carcinoid syndrome developing in patients with extensive hepatic metastases from a carcinoid tumour is characterised by cardiac manifestations in about half the cases. The lesions are characteristically located in the valves and endocardium of the right side of the heart. The pathogenesis of the cardiac lesions is not certain. But in carcinoid tumour with hepatic metastasis, there is increased blood level of serotonin secreted by the tumour. The increased concentration of serotonin reaches the right side of the heart and causes the lesions but serotonin is inactivated on passage of the blood through the lungs and hence the left heart is relatively spared.

MORPHOLOGIC FEATURES. In majority of cases, the lesions are limited to the right side of the heart. Both pulmonary and tricuspid valves as well as the endocardium of the right chambers show characteristic cartilage-like fibrous plaques.

□ **MYXOMATOUS DEGENERATION OF MITRAL VALVE (MITRAL VALVE PROLAPSE)** (p. 451)

Myxomatous or mucoid degeneration of the valves of the heart is a peculiar condition occurring in young patients between the age of 20 and 40 years and is more common in women. The condition is common and seen in 5% of general adult population. The condition is also known by other synonyms like 'floppy valve syndrome' or 'mitral valve prolapse'.

ETIOLOGY. The cause of the condition is not known but in some cases it may be genetically determined collagen disorder. Association with Marfan's syndrome has been observed in 90% of patients. Others have noted

myxomatous degeneration in cases of Ehlers-Danlos syndrome and in myotonic dystrophy.

MORPHOLOGIC FEATURES. Any cardiac valve may be involved but mitral valve is affected most frequently. The disease is usually most severe and most common in the posterior leaflet of the mitral valve. The affected leaflet shows either excessive or redundant leaflet tissue, which is opaque white, soft and floppy. Cut section of the valve reveals mucoid or myxoid appearance. A significant feature is the ballooning or aneurysmal protrusion of the affected leaflet and hence the name 'mitral valve prolapse' and 'floppy valve syndrome'.

There are two other broad groups of isolated myocardial diseases:

- I. *Myocarditis* i.e. inflammatory involvement of the myocardium; and
- II. *Cardiomyopathy* i.e. a non-inflammatory myocardial involvement with unknown (primary) or known (secondary) etiology.

□ MYOCARDITIS (p. 452)

Inflammation of the heart muscle is called myocarditis. It is a rather common form of heart disease that can occur at any age. Its exact incidence is difficult to ascertain as the histological examination has been largely confined to autopsy material. Reports from different studies have estimated the incidence of myocarditis in 1 to 4% of all autopsies.

A number of classifications of myocarditis have been proposed in the past as follows:

- ◆ *Interstitial and parenchymatous type*, depending upon whether the inflammation is confined to interstitial tissue or the parenchyma.
- ◆ *Specific and non-specific type*, depending upon whether the inflammation is granulomatous or non-specific type.
- ◆ *Acute, subacute and chronic type*, depending upon the duration of inflammatory response.

However, currently most commonly used is *etiologic classification* given in **Web Table 16.9**.

According to this classification, myocarditis is divided into 4 main etiologic types described below.

I. INFECTIVE MYOCARDITIS (p. 452)

1. VIRAL MYOCARDITIS. A number of viral infections are associated with myocarditis. Some of the common examples are influenza, poliomyelitis, infectious mononucleosis, hepatitis, smallpox, chickenpox, measles, mumps, rubella, viral pneumonias, coxsackievirus and HIV infections. Cardiac involvement occurs in about 5% of viral infections.

G/A The myocardium is pale and flabby with dilatation of the chambers. There may be focal or patchy areas of necrosis.

M/E There are changes of acute myocarditis. Initially, there is oedema and infiltration of the interstitial tissue by neutrophils and lymphocytes. Later, there is necrosis of individual myocardial fibres and the infiltrate consists of lymphocytes and macrophages.

2. SUPPURATIVE MYOCARDITIS. Pyogenic bacteria, chiefly *Staphylococcus aureus* or *Streptococcus pyogenes*, which cause septicaemia and pyaemia may produce suppurative myocarditis.

G/A There are either abscesses in the myocardium or there is diffuse myocardial involvement.

M/E The exudate chiefly consists of neutrophils, admixed with lymphocytes, plasma cells and macrophages.

374 3. TOXIC MYOCARDITIS. A number of acute bacterial infections produce myocarditis by toxins e.g. in diphtheria, typhoid fever and pneumococcal pneumonia.

4. INFECTIVE GRANULOMATOUS MYOCARDITIS. Tuberculosis, brucellosis and tularaemia are some examples of bacterial infections characterised by granulomatous inflammation in the myocardium. Sarcoidosis, though not a bacterial infection, has histological resemblance to other granulomatous myocarditis.

5. SYPHILITIC MYOCARDITIS. Syphilitic involvement of the myocardium may occur in 2 forms—a *gummatous lesion* consisting of granulomatous inflammation which is more common, and a *primary non-specific myocarditis* which is rare.

6. RICKETTSIAL MYOCARDITIS. Myocarditis occurs quite frequently in scrub typhus (*R. tsutsugamushi*) and Rocky Mountain typhus fever caused by spotted rickettsii.

7. PROTOZOAL MYOCARDITIS. Chagas' disease and toxoplasmosis are the two protozoal diseases causing myocarditis. Chagas' disease caused by *Trypanosoma cruzi* frequently attacks myocardium besides involving the skeletal muscle and the central nervous system. Toxoplasmosis caused by intracellular protozoan, *Toxoplasma gondii*, sometimes causes myocarditis in children and adults.

8. HELMINTHIC MYOCARDITIS. *Echinococcus granulosus* and *Trichinella spiralis* are the two intestinal helminths which may cause myocarditis. *Echinococcus* rarely produces hydatid cyst in the myocardium while the larvae of *Trichinella* in trichinosis cause heavy inflammation in the myocardium as well as in the interstitial tissue.

9. FUNGAL MYOCARDITIS. Patients with immunodeficiency, cancer and other chronic debilitating diseases are more prone to develop fungal myocarditis. These include: candidiasis, aspergillosis, blastomycosis, actinomycosis, cryptococcosis, coccidioidomycosis and histoplasmosis.

II. IDIOPATHIC (FIEDLER'S) MYOCARDITIS (p. 453)

Idiopathic or Fiedler's myocarditis is an isolated myocarditis unaccompanied by inflammatory changes in the endocardium or pericardium and occurs without the usual apparent causes. The condition is rapidly progressive and causes sudden severe cardiac failure or sudden death.

G/A The heart is soft and flabby. The cardiac chambers are generally dilated and sometimes show hypertrophy. There are yellow-grey focal lesions throughout the myocardium.

M/E Two forms of idiopathic myocarditis are described:

i) Diffuse type is more common of the two. It is characterised by diffuse non-specific inflammatory infiltrate consisting of lymphocytes, plasma cells, macrophages, eosinophils and a few polymorphs in the interstitial tissue without formation of granulomas.

ii) Giant cell type or idiopathic granulomatous type is characterised by formation of non-caseating granulomas consisting of macrophages, lymphocytes, plasma cells and multinucleate giant cells. The giant cells are of foreign body or Langhans' type or of myogenic origin.

III. MYOCARDITIS IN CONNECTIVE TISSUE DISEASES (p. 453)

Inflammatory involvement of the myocardium occurs in a number of connective tissue diseases such as rheumatoid arthritis, lupus erythematosus, polyarteritis nodosa, dermatomyositis and scleroderma. The pathologic changes in the heart muscle are similar to the changes seen in other organs in these conditions as described elsewhere in relevant chapters.

IV. MISCELLANEOUS TYPES OF MYOCARDITIS (p. 453)

1. Physical agents. Physical agents like contusion of the myocardium, heat stroke, cardiac surgery and irradiation can initiate non-specific myocarditis. The features consist of an infiltrate of neutrophils, eosinophils and mononuclear cells and shows contraction-band necrosis of the myocardial fibres.

2. Chemical agents. Toxic chemicals such as arsenic, phosphorus and carbon monoxide cause focal areas of degeneration and necrosis of myocardial fibres and non-specific inflammatory reaction, chiefly consisting of lymphocytes and macrophages.

3. Drugs. Changes similar to those induced by chemical poisons are produced by certain drugs such as phenothiazine compounds, sulfonamides, catecholamines and cytotoxic compounds.

4. Immunologic agents. Myasthenia gravis, Friedreich's ataxia, and progressive muscular dystrophies initiate a state of autoimmunisation against the myocardium resulting in focal myocardial degeneration and necrosis with secondary inflammatory reaction.

5. Metabolic derangements. Uraemia, hypokalaemia and shock are associated with degeneration and necrosis of the myocardial fibres, oedema of the interstitial tissue and non-specific inflammatory reaction.

□ CARDIOMYOPATHY (p. 454)

Cardiomyopathy literally means disease of the heart muscle but the term was originally coined to restrict its usage to *myocardial disease of unknown cause*. The WHO definition of cardiomyopathy also excludes heart muscle diseases of known etiologies. However, the term cardiomyopathy has been loosely used by various workers for myocardial diseases of known etiology as well e.g. alcoholic cardiomyopathy, amyloid cardiomyopathy, ischaemic cardiomyopathy etc. This controversy is resolved by classifying all cardiomyopathies into two broad groups:

- a) *primary cardiomyopathy*; and
- b) *secondary cardiomyopathy* i.e. myocardial disease with known underlying cause.

Based on these principles, a classification of primary cardiomyopathy and its subtypes is presented in **Web Table 16.10**.

A. PRIMARY CARDIOMYOPATHY (p. 454)

This is a group of myocardial diseases of unknown cause. It is subdivided into the following 3 pathophysiologic categories (**Web Image 16.33**):

Idiopathic Dilated (Congestive) Cardiomyopathy (p. 454)

This type of cardiomyopathy is characterised by gradually progressive cardiac failure along with dilatation of all the four chambers of the heart. The condition occurs more often in adults and the average survival from onset to death is less than 5 years. Though the etiology is unknown, a few hypotheses based on associations with the following conditions have been proposed:

- i) Possible association of *viral myocarditis* (especially coxsackievirus B).
- ii) Association with *toxic damage* from cobalt and chemotherapy.
- iii) *Inherited mutations*.
- iv) *Chronic alcoholism*.
- v) *Peripartum association*.

G/A The heart is enlarged and increased in weight (up to 1000 gm). The most characteristic feature is prominent dilatation of all the four chambers giving the heart typical globular appearance. Thickening of the ventricular walls even if present is masked by the ventricular dilatation

376 (Web Image 16.33,A). The endocardium is thickened and mural thrombi are often found in the ventricles and atria. The cardiac valves are usually normal.

M/E The endomyocardial biopsies or autopsy examination of the heart reveal non-specific and variable changes. There may be hypertrophy of some myocardial fibres and atrophy of others.

Idiopathic Hypertrophic Cardiomyopathy (p. 455)

This form of cardiomyopathy is known by various synonyms like asymmetrical hypertrophy, hypertrophic subaortic stenosis and Teare's disease. The disease occurs more frequently between the age of 25 and 50 years. It is often asymptomatic but becomes symptomatic due to heavy physical activity causing dyspnoea, angina, congestive heart failure and even sudden death. Though idiopathic, following factors have been implicated:

- i) *Autosomal dominant inheritance* of the disease is available in about half the cases suggesting genetic factors in its causation.
- ii) *Inherited mutations* in genes encoding for sarcomere proteins have been reported in much larger number of cases of hypertrophic cardiomyopathy than those of dilated cardiomyopathy.
- iii) *Other contributory factors* are: increased circulating level of catecholamines, myocardial ischaemia as a result of thickened vasculature of the myocardium and abnormally increased fibrous tissue in the myocardium due to hypertrophy.

G/A The characteristic features are cardiac enlargement, increase in weight, normal or small ventricular cavities and myocardial hypertrophy. The hypertrophy of the myocardium is typically asymmetrical and affects the interventricular septum more than the free walls of the ventricles (**Web Image 16.33,B**). This asymmetric septal hypertrophy may be confined to the apical region of the septum (*non-obstructive type*) or may extend up to the level of the mitral valve causing obstruction to left ventricular outflow in the form of subaortic stenosis (*obstructive type*). The designation of *rhabdomyoma of the septum* was applied to this form of cardiomyopathy in the old literature.

M/E The classical feature is the myocardial cell disorganisation in the ventricular septum. The bundles of myocardial fibres are irregularly and haphazardly arranged rather than the usual parallel pattern and are separated by bands of interstitial fibrous tissue.

Idiopathic Restrictive (Obliterative or Infiltrative) Cardiomyopathy (p. 455)

This form of cardiomyopathy is characterised by restriction in ventricular filling due to reduction in the volume of the ventricles. The common feature in this heterogeneous group of conditions producing restrictive cardiomyopathy is abnormal diastolic function. Restrictive cardiomyopathy includes the following entities:

I) CARDIAC AMYLOIDOSIS. Amyloidosis of the heart may occur in any form of systemic amyloidosis or may occur as isolated organ amyloidosis in amyloid of aging and result in subendocardial deposits.

II) ENDOCARDIAL FIBROELASTOSIS. This is an unusual and uncommon form of heart disease occurring predominantly in infants and children under 2 years of age and less often in adults. The etiology of the condition remains obscure. However, a number of theories have been proposed.

a) The infantile form is believed to be congenital in origin occurring due to the effect of intrauterine *endocardial anoxia*. The adult form may also be

induced by anoxia-causing lesions such as anomalous coronary arteries, metabolic derangements influencing myocardial function etc.

- b) It may occur due to *haemodynamic pressure overload* such as in congenital septal defects and coarctation of the aorta.
- c) It may be an expression of *genetic disorder* as noticed in twins, triplets and siblings.
- d) Some workers consider this disease a form of *connective tissue disorder*.
- e) Certain factors causing *myocardial injury* may initiate the endocardial disease such as in thiamine deficiency (beri-beri heart disease) or from preceding idiopathic myocarditis.
- f) *Lymphatic obstruction* of the heart has been suggested by some as the causative mechanism.

G/A The characteristic feature is the diffuse or patchy, rigid, pearly-white thickening of the mural endocardium (**Web Image 16.33,C**). Left ventricle is predominantly involved, followed in decreasing frequency by the left atrium, right ventricle and right atrium.

M/E The typical finding is the proliferation of the collagen and elastic tissue (fibroelastosis) comprising the thickened endocardium.

III) ENDOMYOCARDIAL FIBROSIS. This form of restrictive cardiomyopathy is a tropical condition prevalent in Africa, especially in Uganda and Nigeria, but some cases occur in South India, Sri Lanka, Malaysia and tropical South America. It is seen in children and young adults. The etiology of the condition remains obscure but the geographic distribution suggests the role of certain factors like malnutrition, viral infections and heavy consumption of banana (rich in serotonin).

G/A Endomyocardial fibrosis is characterised by fibrous scarring of the ventricular endocardium that extends to involve the inner third of the myocardium. The atrioventricular valve leaflets are often affected but the semilunar valves are uninvolved. Mural thrombi may be present. The heart may be normal-sized or hypertrophied but the volume of the affected chambers is diminished due to fibrous scarring.

M/E The endocardium and parts of inner third of the myocardium show destruction of normal tissue and replacement by fibrous tissue.

IV) LÖEFFLER'S ENDOCARDITIS. Also known by the more descriptive term of 'fibroplastic parietal endocarditis with peripheral blood eosinophilia', the condition is considered by some as a variant of the entity described above, endomyocardial fibrosis. However, it differs from the latter in following respects:

- a) There is generally a peripheral blood eosinophilic leucocytosis.
- b) The inflammatory infiltrate in the endocardium and in the part of affected myocardium chiefly consists of eosinophils.
- c) The condition has a worse prognosis.

V) OTHER FORMS OF RESTRICTIVE CARDIOMYOPATHY. Besides above, restrictive cardiomyopathy may result from various diverse causes as under:

- i) Haemochromatosis due to iron overload from multiple transfusions, haemoglobinopathies.
- ii) Myocardial sarcoidosis.
- iii) Carcinoid syndrome.
- iv) Scleroderma.
- v) Neoplastic infiltration in the heart.

B. SECONDARY CARDIOMYOPATHY (p. 456)

This is a group of myocardial diseases of known etiologies or having clinical associations. This, however, excludes well-defined entities such as ischaemic,

378 hypertensive, valvular, pericardial, congenital and inflammatory involvements of the heart. The main entities included in this group are described elsewhere in the text and are listed below:

1. *Nutritional disorders* e.g. chronic alcoholism, thiamine deficiency causing beri-beri heart disease.
2. *Toxic chemicals* e.g. cobalt, arsenic, lithium and hydrocarbons.
3. *Drugs* e.g. cyclophosphamide, adriamycin, catecholamines.
4. *Metabolic diseases* e.g. amyloidosis, haemochromatosis, glycogen storage diseases, hypo- and hyperthyroidism, hypo- and hyperkalaemia.
5. *Neuromuscular diseases* e.g. Friedreich's ataxia, muscular dystrophies.
6. *Infiltrations* e.g. from leukaemia and carcinoma.
7. *Connective tissue diseases* e.g. rheumatoid arthritis, systemic sclerosis, dermatomyositis, lupus erythematosus.

PERICARDIAL DISEASE (p. 456)

□ PERICARDIAL FLUID ACCUMULATIONS (p. 456)

Accumulation of fluid in the pericardial sac may be watery or pure blood. Accordingly, it is of 2 types: hydropericardium (pericardial effusion) and haemopericardium.

A. HYDROPERICARDIUM (PERICARDIAL EFFUSION). Accumulation of fluid in the pericardial cavity due to non-inflammatory causes is called hydropericardium or pericardial effusion. Normally, the pericardial cavity contains 30 to 50 ml of clear watery fluid. Considerable quantities of fluid (up to 1000 ml) can be accommodated in the pericardial cavity without seriously affecting the cardiac function if the accumulation is slow. But sudden accumulation of a smaller volume (up to 250 ml) may produce deficient diastolic filling of the cardiac chambers (cardiac tamponade). Pericardial effusion is detected by cardiac enlargement in the X-rays and by faint apex beat.

The various types of effusions and their causes are: Serous effusions, Serosanguineous effusion, Chylous effusion and Cholesterol effusion.

B. HAEMOPERICARDIUM. Accumulation of pure blood in the pericardial sac is termed haemopericardium. The condition must be distinguished from haemorrhagic pericarditis in which there is escape of small quantities of blood into the pericardial cavity. Massive and sudden bleeding into the sac causes compression of the heart leading to cardiac tamponade. The causes of haemopericardium are as under:

- i) Rupture of the heart through a myocardial infarct.
- ii) Rupture of dissecting aneurysm.
- iii) Bleeding diathesis such as in scurvy, acute leukaemias, thrombocytopenia.
- iv) Trauma following cardiopulmonary resuscitation or by laceration of a coronary artery.

□ PERICARDITIS (p. 457)

Pericarditis is the inflammation of the pericardial layers and is generally secondary to diseases in the heart or caused by systemic diseases. Primary or idiopathic pericarditis is quite rare. Based on the morphologic appearance, pericarditis is classified into acute and chronic types, each of which may have several etiologies (**Web Table 16.11**).

A. ACUTE PERICARDITIS (p. 457)

Acute bacterial and non-bacterial pericarditis are the most frequently encountered forms of pericarditis. These may have the following subtypes:

1. SEROUS PERICARDITIS. Acute pericarditis may be accompanied by accumulation of serous effusion which differs from transudate of

hydropericardium in having increased protein content and higher specific gravity. Its various causes are as under:

- i) Viral infection e.g. coxsackie A or B viruses, influenza virus, mumps virus, adenovirus and infectious mononucleosis.
- ii) Rheumatic fever.
- iii) Rheumatoid arthritis.
- iv) Systemic lupus erythematosus.
- v) Involvement of the pericardium by malignant tumour in the vicinity e.g. carcinoma lung, mesothelioma and mediastinal tumours.
- vi) Tuberculous pericarditis in the early stage.

The fluid accumulation is generally not much and ranges from 50 to 200 ml but may rarely be large enough to cause cardiac tamponade.

2. FIBRINOUS AND SEROFIBRINOUS PERICARDITIS. The response of the pericardium by fibrinous exudate is the most common type of pericarditis. Quite often, there is admixture of fibrinous exudate with serous fluid. The various causes of this type of pericarditis are as follows:

- i) Uraemia
- ii) Myocardial infarction
- iii) Rheumatic fever
- iv) Trauma such as in cardiac surgery
- v) Acute bacterial infections.

The amount of fluid accumulation is variable. The cardiac surface is characteristically covered by dry or moist, shaggy, fibrinous exudate which gives 'bread and butter' appearance.

3. PURULENT OR FIBRINOPURULENT PERICARDITIS. Purulent or fibrinopurulent pericarditis is mainly caused by pyogenic bacteria (e.g. staphylococci, streptococci and pneumococci) and less frequently by fungi and parasites. The infection may spread to the pericardium by the following routes:

- i) By direct extension from neighbouring inflammation e.g. in empyema of the pleural cavity, lobar pneumonia, infective endocarditis and mediastinal infections.
- ii) By haematogenous spread.
- iii) By lymphatic permeation.
- iv) Direct implantation during cardiac surgery.

Generally, fibrinous or serofibrinous pericarditis precedes the development of purulent pericarditis. The amount of exudate is variable and is generally thick, creamy pus, coating the pericardial surfaces.

M/E Besides the purulent exudate on the pericardial surfaces, the serosal layers show dense infiltration by neutrophils (**Web Image 16.34**).

4. HAEMORRHAGIC PERICARDITIS. Haemorrhagic pericarditis is the one in which the exudate consists of admixture of an inflammatory effusion of one of the foregoing types alongwith blood. The causes are as under:

- i) Neoplastic involvement of the pericardium
- ii) Haemorrhagic diathesis with effusion
- iii) Tuberculosis
- iv) Severe acute infections

B. CHRONIC PERICARDITIS (p. 458)

1. TUBERCULOUS PERICARDITIS. Tuberculous pericarditis is the most frequent form of granulomatous inflammation of the pericardium. The lesions may occur by one of the following mechanisms:

- i) Direct extension from an adjacent focus of tuberculosis.
- ii) By lymphatic spread e.g. from tracheobronchial lymph nodes, chronic pulmonary tuberculosis or infected pleura.

The exudate is slightly turbid, caseous or blood-stained with sufficient fibrin. Tubercles are generally visible on the pericardial surfaces and sometimes caseous areas are also visible to the naked eye.

2. CHRONIC ADHESIVE PERICARDITIS. Chronic adhesive pericarditis is the stage of organisation and healing by formation of fibrous adhesions in the pericardium following preceding fibrinous, suppurative or haemorrhagic pericarditis. The process begins by formation of granulation tissue and neovascularisation. Subsequently, fibrous adhesions develop between the parietal and the visceral layers of the pericardium and obliterate the pericardial space (**Web Image 16.35,A**).

3. CHRONIC CONSTRICTIVE PERICARDITIS. This is a rare condition characterised by dense fibrous or fibrocalcific thickening of the pericardium resulting in mechanical interference with the function of the heart and reduced cardiac output. The condition usually results from a long-standing preceding causes, e.g.

- i) Tuberculous pericarditis
- ii) Purulent pericarditis
- iii) Haemopericardium
- iv) Concato's disease (polyserositis)
- v) Rarely, acute non-specific and viral pericarditis.

The heart is encased in 0.5 to 1 cm thick and dense collagenous scar which may be calcified. As a result, the heart fails to dilate during diastole. In contrast to chronic adhesive pericarditis, hypertrophy and dilatation do not occur due to dense fibrous scarring. Instead, the heart size is normal or smaller (**Web Image 16.35,B**).

4. PERICARDIAL PLAQUES (MILK SPOTS, SOLDIERS' SPOTS). These are opaque, white, shining and well-circumscribed areas of organisation with fibrosis in the pericardium measuring 1 to 3 cm in diameter. They are seen most frequently on the anterior surface of the right ventricle. The exact cause is not known but they are generally believed to arise from healing of preceding pericarditis. The plaque-like lesions of pericardial thickenings are also termed *milk spots* or *soldiers' spots* as they were often found at autopsy in the soldiers in World War I.

□ PRIMARY TUMOURS (p. 459)

Primary tumours of the heart are quite rare, found in 0.04% of autopsies. In decreasing order of frequency, the benign tumours encountered in the heart are: myxoma, lipoma, fibroelastoma, rhabdomyoma, haemangioma and lymphangioma. The malignant tumours are still rarer, the important ones are: rhabdomyosarcoma, angiosarcoma and malignant mesothelioma. Out of all these, only myxoma of the heart requires elaboration.

MYXOMA. This is the most common primary tumour of the heart comprising about 50% of all primary cardiac tumours. Majority of them occur in the age range of 30 to 60 years. Myxomas may be located in any cardiac chamber or the valves, but 90% of them are situated in the left atrium.

G/A They are often single but may be multiple. They range in size from less than 1 to 10 cm, polypoid, pedunculated, spherical, soft and haemorrhagic masses resembling an organising mural thrombus.

M/E The tumour shows the following features:

- i) There is abundant myxoid or mucoid intercellular stroma positive for mucin.
- ii) The cellularity is sparse. The tumour cells are generally stellate-shaped, spindle and polyhedral, scattered in the stroma. Occasional multinucleate tumour giant cells are present.
- iii) Numerous capillary-sized blood vessels are found and the tumour cells may be aggregated around them.
- iv) A few lymphocytes, plasma cells and macrophages are seen.

v) Foci of haemorrhage and deposits of haemosiderin granules are often present.

□ **SECONDARY TUMOURS** (p. 459)

Metastatic tumours of the heart are more common than the primary tumours. About 10% cases with disseminated cancer have metastases in the heart. Most of these result from haematogenous or lymphatic spread. In descending order of frequency, primary sites of origin are: carcinoma of the lung, breast, malignant lymphoma, leukaemia and malignant melanoma.

PATHOLOGY OF CARDIOVASCULAR INTERVENTIONS (p. 459)

Nowadays, with the development of surgical and non-surgical coronary revascularisation procedures in coronary artery disease, it has been possible to study the pathology of native as well as grafted vessel. However, these invasive therapeutic interventions are done in conjunction with life style changes for modifying the risk factors. Besides, the myocardial tissue by endomyocardial biopsy is also accessible for histopathologic study.

□ **ENDOMYOCARDIAL BIOPSY** (p. 459)

Currently, it is possible to perform endomyocardial biopsy (EMB) for making a final histopathologic diagnosis in certain cardiac diseases. The main *indications* for EMB are: myocarditis, cardiac transplant cases, restrictive heart disease, infiltrative heart diseases such as in amyloidosis, storage disorders etc.

□ **BALLOON ANGIOPLASTY** (p. 459)

Balloon angioplasty or percutaneous coronary intervention (PCI) is a non-surgical procedure that employs percutaneous insertion and manipulation of a balloon catheter into the occluded coronary artery. The balloon is inflated to dilate the stenotic artery which causes endothelial damage, plaque fracture, medial dissection and haemorrhage in the affected arterial wall. PCI is accompanied with insertion of coronary stents in the blocked coronaries with a success rate of symptoms in over 95% cases. PCI is followed by administration of anti-platelet (oral aspirin) and antithrombin therapy to avoid occurrence of coronary thrombosis.

□ **CORONARY ARTERY BYPASS GRAFTING** (p. 460)

Coronary artery bypass grafting (CABG) employs the use of autologous grafts to replace or bypass the blocked coronary arteries. Most frequently used is autologous graft of saphenous vein which is reversed (due to valves in the vein) and transplanted, or left internal mammary artery may be used being in the operative area of the heart. Long-term follow-up of CABG surgery has yielded following observations on pathology of grafted vessel:

1. In a reversed saphenous vein graft, long-term luminal patency is 50% after 10 years. Pathologic changes which develop in grafted vein include thrombosis in early stage, intimal thickening and graft atherosclerosis with or without complicated lesions.
2. Internal mammary artery graft, however, has a patency of more than 90% after 10 years.
3. Atherosclerosis with superimposed complications may develop in native coronary artery distal to the grafted vessel as well as in the grafted vessel.

□ **CARDIAC TRANSPLANTATION** (p. 460)

Since the first human-to-human cardiac transplant was carried out successfully by South African surgeon Dr Christian Barnard in 1967, cardiac transplantation and prolonged assisted circulation is being done in many

382 countries in end-stage cardiac diseases, most often in idiopathic dilated cardiomyopathy, heart failure and IHD. Worldwide, about 3,000 cardiac transplants are performed annually. The survival following heart transplants is reported as: 1 year in 85%, 5 years in 65% and 10 years in 45% cases. Major complications are transplant rejection reaction, infections (particularly with *Toxoplasma gondii* and cytomegaloviruses), graft coronary atherosclerosis and higher incidence of malignancy due to long-term administration of immunosuppressive therapy.

◆ SELF ASSESSMENT

1. **The most common anatomic pattern of distribution of coronary blood supply is:**
 - A. Left coronary preponderance
 - B. Right coronary preponderance
 - C. Circumflex preponderance
 - D. Balanced circulation
2. **Right heart failure is predominantly characterised by the following except:**
 - A. Chronic venous congestion liver
 - B. Chronic venous congestion spleen
 - C. Chronic venous congestion kidney
 - D. Pulmonary congestion
3. **The thickness of left ventricular wall in left ventricular hypertrophy is at least:**

A. 13 mm	B. 15 mm
C. 17 mm	D. 19 mm
4. **The features of tetralogy of Fallot are as under except:**
 - A. VSD
 - B. Displacement of aorta to right to override the VSD
 - C. Pulmonary stenosis
 - D. Left ventricular hypertrophy
5. **Post-ductal coarctation of aorta has following features except:**
 - A. Hypertension in upper extremities
 - B. Weak pulses
 - C. High blood pressure in lower extremities
 - D. Claudication in lower legs
6. **Non-infarct effects of myocardial ischaemia are as under except:**

A. Sudden cardiac death	B. Angina pectoris
C. Subendocardial infarcts	D. Chronic ischaemic heart disease
7. **The most thrombogenic constituent of atheroma is:**

A. Fibrous cap	B. Lipid core
C. Foam cells	D. Smooth muscle cells
8. **The most important and common complicated atheromatous lesion in coronary artery in acute myocardial infarction is:**

A. Calcification	B. Coronary thrombosis
C. Aneurysm	D. Ulceration
9. **Infarcts are least common in:**

A. Left ventricle	B. Right ventricle
C. Left atrium	D. Right atrium
10. **CKMB2:CKMB1 ratio sensitive for the diagnosis of acute MI is:**

A. >0.5	B. >1.0
C. 1.5	D. >2.0
11. **Chronic ischaemic heart disease is most often due to:**
 - A. Coronary atherosclerosis
 - B. Repetitive coronary vasospasm
 - C. Embolisation to coronary branches
 - D. Stenosis of coronary ostia

12. In hypertensive heart disease left ventricular hypertrophy is correlated with:
- Duration of hypertension
 - Severity of hypertension
 - Cause of hypertension
 - Severity of coronary atherosclerosis
13. In rheumatic heart disease, antibodies against the following streptococcal products are seen in the serum *except*:
- DNAase B
 - Streptokinase
 - Streptolysin S
 - Streptohyaluronidase
14. Anitschkow cells are believed to be derivative of:
- Cardiac myocyte
 - Cardiac histiocyte
 - Endocardial smooth muscle cells
 - Endothelial cells of lymphatics
15. In chronic RHD, the most common valvular deformities are:
- Mitral stenosis and insufficiency
 - Mitral stenosis alone
 - Mitral insufficiency alone
 - Mitral and aortic stenosis combined
16. MacCallum's patch appears in the region of:
- Pericardial surface in the posterior wall of left atrium
 - Pericardial surface in the posterior wall of left ventricle
 - Endocardial surface in the posterior wall of left atrium
 - Endocardial surface in the posterior wall of left ventricle
17. Major criteria in the modified Jones' criteria include the following *except*:
- Carditis
 - Polyarthritis
 - Raised C-reactive proteins
 - Subcutaneous nodules
18. Haematoxylin bodies of Gross may be seen in vegetations of:
- Rheumatic valvulitis
 - Libman-Sacks endocarditis
 - Non-bacterial thrombotic endocarditis
 - Subacute bacterial valvulitis
19. Most frequent underlying heart disease in causation of SABE is:
- Ventricular septal defect
 - Chronic rheumatic valvular disease
 - Floppy mitral valve
 - Atherosclerotic valvular disease
20. Vegetations of the following types of endocarditis are generally not friable *except* that of:
- Rheumatic endocarditis
 - Libman-Sacks endocarditis
 - Subacute bacterial endocarditis
 - Non-bacterial thrombotic endocarditis
21. Mitral stenosis causes the following effects on the heart *except*:
- Dilatation and hypertrophy of left atrium
 - Dilatation and hypertrophy of left ventricle
 - Dilatation and hypertrophy of right ventricle
 - Dilatation of right atrium
22. In the following heart disease, there is generally involvement of valves of right heart:
- Heart disease in SLE
 - Carcinoid heart disease
 - Non-bacterial thrombotic endocarditis
 - Subacute bacterial endocarditis

23. The following type of cardiomyopathy is classically characterised by four chamber dilatation:
- Idiopathic congestive cardiomyopathy
 - Idiopathic hypertrophic cardiomyopathy
 - Endomyocardial fibrosis
 - Loeffler's endocarditis
24. All of the following cause left-sided heart failure *except*:
- Cor pulmonale
 - Systemic hypertension
 - Mitral stenosis
 - Aortic stenosis
25. The most common location for myxoma of heart is:
- Left ventricle
 - Right ventricle
 - Left atrium
 - Interventricular septum
26. An important protein from bacterial cell surface implicated in pathogenesis of RHD is:
- G-protein
 - M-protein
 - L-protein
 - X-protein
27. For endomyocardial biopsy, the safest site for biopsy is:
- Left ventricle
 - Left atrium
 - Right ventricle
 - Right atrium
28. Which of the following produces right ventricular hypertrophy:
- Coarctation of aorta
 - Aortic stenosis
 - Pulmonary insufficiency
 - Systemic hypertension
29. Most common congenital anomaly of the heart is:
- VSD
 - ASD
 - PDA
 - Tetralogy of Fallot
30. Acronym "STEMI" stands for:
- Standard Treatment and Evaluation in MI
 - Serial Testing of Enzyme levels in MI
 - ST segment Elevation in acute MI
 - Steps Taken in Emergency in case of Multiple Infarcts
31. Reported incidence of RHD in school going children by the Indian Council of Medical Research is:
- 1 to 5.5 per 100 children
 - 5.5 to 10 per 100 children
 - 10 to 15.5 per 100 children
 - 15.5 to 20 per 100 children
32. MacCallum's patch is seen in:
- Right atrium
 - Right ventricle
 - Left atrium
 - Left ventricle
33. Chronic alcoholism is associated with:
- Hypertrophic cardiomyopathy
 - Dilated cardiomyopathy
 - Restrictive cardiomyopathy
 - Infiltrative cardiomyopathy
34. Most common location for performing endomyocardial biopsy is:
- Right atrium
 - Right ventricle
 - Left atrium
 - Left ventricle

KEY

1 = B	2 = D	3 = B	4 = D
5 = C	6 = C	7 = B	8 = B
9 = C	10 = C	11 = A	12 = A
13 = C	14 = B	15 = A	16 = C
17 = C	18 = B	19 = B	20 = C
21 = B	22 = B	23 = A	24 = A
25 = C	26 = B	27 = C	28 = C
29 = A	30 = C	31 = A	32 = C
33 = B	34 = B		



The Respiratory System

□ NORMAL STRUCTURE (p. 461)

ANATOMY. The normal *adult right lung* weighs 375 to 550 gm (average 450 gm) and is divided by two fissures into three lobes—the upper, middle and lower lobes. The weight of the normal *adult left lung* is 325 to 450 gm (average 400 gm) and has one fissure dividing it into two lobes—the upper and lower lobes, while the middle lobe is represented by the lingula. The airways of the lungs arise from the trachea by its division into right and left main bronchi which continue to divide and subdivide further, eventually terminating into the alveolar sacs (**Web Image 17.1**).

Between the tracheal bifurcation and the smallest bronchi, about 8 divisions take place. The *bronchioles* so formed further undergo 3 to 4 divisions leading to the *terminal bronchioles* which are less than 2 mm in diameter. The part of the lung tissue distal to a terminal bronchiole is called an *acinus*. A cluster of about 5 acini supplied by terminal bronchioles and enclosed by visible fibrous septa is termed as the *pulmonary lobule*. An **acinus** consists of 3 parts:

1. Several (usually 3 to 5 generations) *respiratory bronchioles* originate from a terminal bronchiole.
2. Each respiratory bronchiole divides into several *alveolar ducts*.
3. Each alveolar duct opens into many *alveolar sacs (alveoli)* which are blind ends of the respiratory passages.

The lungs have double blood supply—oxygenated blood from the bronchial arteries and venous blood from the pulmonary arteries, and there is mixing of the blood to some extent. In case of blockage of one side of circulation, the supply from the other can maintain the vitality of pulmonary parenchyma. The bronchial veins drain the blood supplied by the bronchial arteries. The lungs have abundant intercommunicating lymphatics on the surface which drain into the subpleural plexus. Hilar and tracheobronchial lymph nodes receive the lymph and drain into the thoracic duct.

HISTOLOGY. The bronchi and their subdivisions up to bronchioles are lined by pseudostratified columnar ciliated epithelial cells, also called *respiratory epithelium*. These cells are admixed with mucus-secreting goblet cells which decrease in number as the bronchioles are approached. The mucosa of bronchi contains numerous submucosal mucous glands and neuroendocrine cells which are bronchial counterparts of the argentaffin cells of the alimentary tract. The structure of bronchioles differs from that of bronchi and its subdivisions as well as from alveoli. They are lined by a single layer of pseudostratified columnar ciliated epithelium but no mucus cells and hence, unlike the bronchi, contain no mucus secretion on the surface. They contain some nonciliated Clara cells which secrete protein rich in lysozyme and immunoglobulins but unlike the alveoli contain no surfactant.

The **alveolar walls or alveolar septa** are the sites of exchange between the blood and air and have the following microscopic features (**Web Image 17.2**):

1. The *capillary endothelium* lines the anastomotic capillaries in the alveolar walls.
2. The capillary endothelium and the, alveolar lining epithelial cells are separated by the *capillary basement membrane and some interstitial tissue*.

3. The *alveolar epithelium* consists of 2 types of cells: *type I* or *membranous pneumocytes* are the most numerous covering about 95% of alveolar surface, while *type II* or *granular pneumocytes* project into the alveoli and are covered by microvilli. Type II pneumocytes are essentially reserve cells which undergo compensatory hyperplasia when type I pneumocytes are injured and are also the source of pulmonary surfactant rich in lecithin. The main functions of coating of surfactant are to lower the surface tension of the alveolar lining cells and in maintaining the stability of the alveoli.

4. The *alveolar macrophages* belonging to mononuclear-phagocyte system are present either free in the alveolar spaces or are attached to the alveolar cells.

5. The *pores of Kohn* are the sites of alveolar connections between the adjacent alveoli and allow the passage of bacteria and exudate.

FUNCTIONS. The primary functions of lungs is oxygenation of the blood and removal of carbon dioxide. The respiratory tract is particularly exposed to infection as well as to the hazards of inhalation of pollutants from the inhaled air and cigarette smoke. There exists a natural mechanism of filtering and clearing of such pollutants through respiratory epithelium, tracheobronchial lymphatics and alveolar macrophages.

□ PAEDIATRIC LUNG DISEASE (p. 462)

CONGENITAL CYSTS (p. 462)

Developmental defects involving deficiency of bronchial or bronchiolar cartilage, elastic tissue and muscle result in congenital cystic disease of lungs. A single large cyst of this type occupying almost a lobe is called *pneumatocele*. Multiple small cysts are more common and give sponge-like appearance to the lung. The cysts are thin-walled and dilated and generally lined by flattened ciliated epithelium overlying a thin layer of supportive connective tissue.

BRONCHOPULMONARY SEQUESTRATION (p. 462)

Sequestration is the presence of lobes or segments of lung tissue which are not connected to the airway system. The blood supply of the sequestered area is not from the pulmonary arteries but from the aorta or its branches. Sequestration may be intralobar or extralobar.

◆ **Intralobar sequestration** is the sequestered bronchopulmonary mass within the pleural covering of the affected lung.

◆ **Extralobar sequestration** is the sequestered mass of lung tissue lying outside the pleural investing layer such as in the base of left lung or below the diaphragm.

□ ACUTE RESPIRATORY DISTRESS SYNDROME (HYALINE MEMBRANE DISEASE) (p. 462)

Acute respiratory distress syndrome (ARDS) is a severe, at times life-threatening, form of progressive respiratory insufficiency which involves pulmonary tissues diffusely i.e. involvement of the alveolar epithelium, alveolar lumina and interstitial tissue. ARDS exists in 2 forms: neonatal and adult type. Both have the common morphological feature of formation of hyaline membrane in the alveoli and hence is also termed as hyaline membrane disease (HMD). The two forms of ARDS have different clinical settings, response to treatment and consequences, etiology, pathogenesis but have similar morphology.

CLINICAL FEATURES AND CONSEQUENCES

◆ **Neonatal ARDS** occurring in newborn infants begins with dyspnoea within a few hours after birth with tachypnoea, hypoxia and cyanosis; in severe cases death may occur within a few hours.

◆ **Adult ARDS** is known by various synonyms such as shock-lung syndrome, diffuse alveolar damage (DAD), acute alveolar injury, traumatic wet lungs and post-traumatic respiratory insufficiency. The condition was first recognised in adults during World War II in survivors of non-thoracic injuries with shock. Adult ARDS also presents clinically by sudden and severe respiratory distress, tachypnoea, tachycardia, cyanosis and severe hypoxaemia.

ETIOLOGY

◆ Neonatal ARDS

1. Preterm infants
2. Infants born to diabetic mothers
3. Delivery by caesarean section
4. Infants born to mothers with previous premature infants
5. Excessive sedation of the mother causing depression in respiration of the infant
6. Birth asphyxia from various causes such as coils of umbilical cord around the neck
7. Male preponderance (1.5 to 2 times) over female babies due to early maturation of female lungs
8. Finally, many cases of neonatal ARDS remain idiopathic.

◆ Adult ARDS

1. Shock due to sepsis, trauma, burns
2. Diffuse pulmonary infections, chiefly viral pneumonia
3. Pancreatitis
4. Oxygen toxicity
5. Inhalation of toxins and irritants e.g. smoke, war gases, nitrogen dioxide, metal fumes etc.
6. Narcotic overdose
7. Drugs e.g. salicylates, colchicine
8. Aspiration pneumonitis
9. Fat embolism
10. Radiation.

PATHOGENESIS

In both neonatal and adult type ARDS, there is damage to alveolocapillary wall triggered by etiologic factors listed above, and the final pathologic consequence of formation of hyaline membrane is also similar. However, how it occurs is different in the neonates than in adults. The sequence of events in the pathogenesis of both neonatal and adult ARDS is schematically illustrated in **Web Image 17.3** and is outlined below:

◆ **Neonatal ARDS.** *Entry of air into alveoli is essential for formation of hyaline membrane i.e. dead born infants do not develop HMD.*

- i) The basic defect in neonatal ARDS is a *deficiency of pulmonary surfactant*, normally synthesised by type II alveolar cells. The production of surfactant is normally increased shortly before birth but in prematurity and in neonatal hypoxia from any of the foregoing causes, its synthesis is decreased. Its deficiency leads to increased alveolar surface tension which in turn causes *atelectasis*.
- ii) Atelectasis of the lungs results in hypoventilation, pulmonary hypoperfusion and ischaemic damage to capillary endothelium.
- iii) This results in *ischaemic necrosis* of the alveolocapillary wall, exudation of plasma proteins including fibrinogen into the alveoli and eventually formation of hyaline membrane on the alveolar surface containing largely fibrin.

◆ **Adult ARDS.** The mechanism of acute injury by etiologic agents listed above depends upon the *imbalance between pro-inflammatory and anti-inflammatory cytokines*:

- i) Activated pulmonary macrophages release *proinflammatory cytokines* such as IL8, IL1, and tumour necrosis factor (TNF), while macrophage

388 inhibitory factor (MIF) helps to sustain inflammation in the alveoli. Number of neutrophils in the alveoli is increased in acute injury. Neutrophils on activation release products which cause active tissue injury e.g. proteases, platelet activating factor, oxidants and leukotrienes.

ii) Besides the role of cytokines in acute injury, a few *fibrogenic cytokines* such as transforming growth factor- α (TGF- α) and platelet-derived growth factor (PDGF) play a role in repair process by stimulation of proliferation of fibroblast and collagen.

In either case, injury to the capillary endothelium leads to increased vascular permeability while injured pneumocytes, especially type 1, undergo necrosis. The net effect of injury to both capillary endothelium and alveolar epithelium is interstitial and intra-alveolar oedema, congestion, fibrin deposition and formation of hyaline membranes.

MORPHOLOGIC FEATURES

G/A The lungs are normal in size. They are characteristically stiff, congested, heavy and airless so that they sink in water.

M/E (Web Image 17.4):

1. There is presence of collapsed alveoli (atelectasis) alternating with dilated alveoli.
2. Necrosis of alveolar epithelial cells and formation of characteristic eosinophilic hyaline membranes lining the respiratory bronchioles, alveolar ducts and the proximal alveoli. The membrane is largely composed of fibrin admixed with cell debris derived from necrotic alveolar cells.
3. Interstitial and intra-alveolar oedema, congestion and intra-alveolar haemorrhages.
4. Changes of bronchopneumonia may supervene.
5. With time, compensatory proliferation of pneumocytes into alveolar lumen may be seen as tufts of alveolar epithelium.
6. In organising stage, there is interstitial fibrosis obliterating alveolar spaces.

CONSEQUENCES

1. Death. The mortality rate in neonatal ARDS is high (20 to 30%) and is still higher in babies under 1 kg of body weight. The stiff lung in adult ARDS fails to respond to oxygen therapy and is acutely serious and severe respiratory problem which may be fatal.

2. Resolution. Milder cases of neonatal ARDS recover with adequate oxygen therapy by ventilator-assist methods in a few days, while in adult ARDS control of the trigger which initiated it may result in resolution. The hyaline membrane is liquefied by the neutrophils and macrophages and thus absorbed.

3. Other sequelae. Besides the two extremes—death and recovery, other long-term sequelae of ARDS are as under:

- i) *Bronchopulmonary dysplasia*
- ii) *Desquamative interstitial pneumonia (DIP)*
- iii) *Diffuse fibrosing alveolitis (Hamman Rich syndrome).*

□ BRONCHOPULMONARY DYSPLASIA (p. 465)

Bronchopulmonary dysplasia occurs as a complication in infants treated for neonatal ARDS with oxygen and assisted ventilation. The toxicity of oxygen and barotrauma from high pressure of oxygen give rise to subacute or chronic fibrosing condition of the lungs termed bronchopulmonary dysplasia.

M/E There is organisation of hyaline membranes resulting in fibrous thickening of the alveolar walls, bronchiolitis, peribronchial fibrosis, and development of emphysema due to alveolar dilatation.

□ ATELECTASIS AND COLLAPSE (p. 465)

Atelectasis in the newborn or *primary atelectasis* is defined as incomplete expansion of a lung or part of a lung, while pulmonary collapse or *secondary atelectasis* is the term used for reduction in lung size of a previously expanded and well-aerated lung. Obviously, the former occurs in newborn whereas the latter may occur at any age.

ATELECTASIS. Stillborn infants have total atelectasis, while the newborn infants with weak respiratory action develop incomplete expansion of the lungs and clinical atelectasis. The common causes are prematurity, cerebral birth injury, CNS malformations and intrauterine hypoxia.

G/A The lungs are small, dark blue, fleshy and non-crepitant

M/E The alveolar spaces in the affected area are small with thick interalveolar septa. The alveolar spaces contain proteinaceous fluid with a few epithelial squames and meconium.

COLLAPSE. Pulmonary collapse or secondary atelectasis in children and adults may occur from various causes such as compression, obstruction, contraction and lack of pulmonary surfactant. Accordingly, collapse may be of the following types:

1. Compressive collapse. Pressure from outside causes compressive collapse e.g. by massive pleural effusion, haemothorax, pneumothorax, intrathoracic tumour, high diaphragm and spinal deformities.

2. Obstructive/absorptive collapse. Obstruction of a bronchus or many bronchioles causes absorption of oxygen in the affected alveoli followed by collapse e.g. by viscid mucus secretions in bronchial asthma, chronic bronchitis, bronchiectasis, bronchial tumours and aspiration of foreign bodies.

3. Contraction collapse. This type occurs due to localised fibrosis in lung causing contraction followed by collapse.

□ BRONCHIOLITIS AND BRONCHIOLITIS OBLITERANS (p. 465)

Bronchiolitis and bronchiolitis obliterans are the inflammatory conditions affecting the small airways occurring predominantly in older paediatric age group and in quite elderly persons. A number of etiologic factors have been stated to cause this condition. These include viral infection (frequently adenovirus and respiratory syncytial virus), bacterial infection, fungal infection, inhalation of toxic gases (e.g. in silo-fillers' disease) and aspiration of gastric contents.

M/E The lumina of affected bronchioles are narrow and occluded by fibrous plugs. The bronchiolar walls are inflamed and are infiltrated by lymphocytes and plasma cells. There are changes of interstitial pneumonitis and fibrosis in the alveoli around the affected bronchioles.

□ SUDDEN INFANT DEATH SYNDROME (p. 465)

Sudden infant death syndrome (SIDS) or crib death is an uncommon condition seen mainly in the western countries. It affects infants in the age group of 2 to 6 months. The condition is seen in premature babies born to mothers who have been smokers and indulged in drug abuse.

M/E At autopsy the upper respiratory airways and lungs invariably show petechial haemorrhages.

□ PULMONARY VASCULAR DISEASE (p. 465)

PULMONARY HYPERTENSION (p. 466)

Normally, the pulmonary arterial circulation is high-flow and low-pressure system with much lower blood pressure than the systemic blood pressure; it does not exceed 30/15 mmHg even during exercise (normally, blood pressure

390 in the pulmonary veins is between 3 and 8 mmHg). Pulmonary hypertension is defined as a systolic blood pressure in the pulmonary arterial circulation above 30 mmHg. Pulmonary hypertension is broadly classified into 2 groups:

Primary (Idiopathic) Pulmonary Hypertension (p. 466)

Primary or idiopathic pulmonary hypertension is an uncommon condition of unknown cause. The diagnosis can be established only after a thorough search for the usual causes of secondary pulmonary hypertension (discussed below). The patients are usually young females between the age of 20 and 40 years, or children around 5 years of age.

ETIOPATHOGENESIS. A number of etiologic factors have been suggested to explain its pathogenesis: *Neurohumoral vasoconstrictor mechanism, unrecognised thromboemboli or amniotic fluid emboli, collagen vascular disease, pulmonary veno-occlusive disease, ingestion of substances like 'bush tea', oral contraceptives and familial occurrence.*

Secondary Pulmonary Hypertension (p. 466)

When pulmonary hypertension occurs secondary to a recognised lesion in the heart or lungs, it is termed as secondary pulmonary hypertension. It is the more common type and may be encountered at any age, but more frequently over the age of 50 years.

ETIOPATHOGENESIS. It includes following:

A. Passive pulmonary hypertension. This is the commonest and is produced by diseases raising pressure in the pulmonary veins e.g.

1. Mitral stenosis.
2. Chronic left ventricular failure (e.g. in severe systemic hypertension, aortic stenosis, myocardial fibrosis).

B. Hyperkinetic (Reactive) pulmonary hypertension. In this group are included causes in which the blood enters the pulmonary arteries in greater volume or at a higher pressure, e.g.

1. Patent ductus arteriosus.
2. Atrial or ventricular septal defects.

C. Vaso-occlusive pulmonary hypertension. All such conditions which produce progressive diminution of the vascular bed in the lungs are included in this group. Vaso-occlusive causes may be further sub-divided into 3 types:

1. *Obstructive type* e.g. i) Multiple emboli or thrombi, ii) Sickle cell disease and iii) Schistosomiasis.
2. *Obliterative type*, e.g. i) Chronic emphysema, ii) Chronic bronchitis, iii) Bronchiectasis, iv) Pulmonary tuberculosis and v) Pneumoconiosis.
3. *Vasoconstrictive type*, e.g. i) In residents at high altitude, ii) Pathologic obesity (Pickwickian disease), iii) Upper airway disease such as tonsillar hypertrophy, iv) Neuromuscular diseases such as poliomyelitis and v) Severe kyphoscoliosis.

MORPHOLOGIC FEATURES. Irrespective of the type of pulmonary hypertension (primary or secondary), chronic cases invariably lead to cor pulmonale. The pathologic changes are confined to the right side of the heart and pulmonary arterial tree in the lungs. There is hypertrophy of the right ventricle and dilatation of the right atrium. The vascular changes are similar in primary and secondary types and involve the entire arterial tree from the main pulmonary arteries down to the arterioles (**Web Image 17.5**):

1. Arterioles and small pulmonary arteries: These branches show most conspicuous changes.

- i) Medial hypertrophy.
- ii) Thickening and reduplication of elastic laminae.

iii) Plexiform pulmonary arteriopathy in which there is intraluminal tuft of capillary formation in dilated thin-walled arterial branches.

2. Medium-sized pulmonary arteries:

- i) Medial hypertrophy, which is not so marked in secondary pulmonary hypertension.
- ii) Concentric intimal thickening.
- iii) Adventitial fibrosis.
- iv) Thickening and reduplication of elastic laminae.

3. Large pulmonary arteries:

- i) Atheromatous deposits.

□ PULMONARY INFECTIONS (p. 467)

Important and common examples of acute pulmonary infectious diseases discussed here are *pneumonias*, *lung abscess* and *fungal infections*, while *pulmonary tuberculosis*, is generally regarded as an example of chronic lung infections.

PNEUMONIAS (p. 467)

Pneumonia is defined as acute inflammation of the lung parenchyma distal to the terminal bronchioles (consisting of the respiratory bronchiole, alveolar ducts, alveolar sacs and alveoli). The terms 'pneumonia' and 'pneumonitis' are often used synonymously for inflammation of the lungs, while 'consolidation' (meaning solidification) is the term used for gross and radiologic appearance of the lungs in pneumonia.

PATHOGENESIS. The microorganisms gain entry into the lungs by one of the following four routes: *Inhalation, aspiration, haematogenous spread* and *direct spread*.

Failure of defense mechanisms and presence of certain predisposing factors result in pneumonias. These conditions are: Altered consciousness, depressed cough and glottic reflexes, impaired mucociliary transport, impaired alveolar macrophage function, endobronchial obstruction and leucocyte dysfunctions.

CLASSIFICATION. On the basis of the anatomic part of the lung parenchyma involved, pneumonias are traditionally classified into 3 main types:

1. Lobar pneumonia
2. Bronchopneumonia (or Lobular pneumonia)
3. Interstitial pneumonia.

However, now that much is known about etiology and pathogenesis of pneumonias, current practice is to follow the etiologic classification (**Web Table 17.1**) which divides pneumonias into following 3 main groups:

- A. Bacterial pneumonia
- B. Viral pneumonia
- C. Pneumonias from other etiologies.

A. BACTERIAL PNEUMONIA (p. 468)

Two types of acute bacterial pneumonias are distinguished—lobar pneumonia and broncho-(lobular-) pneumonia, each with distinct etiologic agent and morphologic changes.

Lobar Pneumonia (p. 468)

Lobar pneumonia is an acute bacterial infection of a part of a lobe, the entire lobe, or even two lobes of one or both the lungs.

ETIOLOGY. Based on the etiologic microbial agent causing lobar pneumonia, following types of lobar pneumonia are described:

1. **Pneumococcal pneumonia.** More than 90% of all lobar pneumonias are caused by *Streptococcus pneumoniae*, a lancet-shaped diplococcus.

392 Out of various types, type 3-*S. pneumoniae* causes particularly virulent form of lobar pneumonia. Pneumococcal pneumonia in majority of cases is community-acquired infection.

2. Staphylococcal pneumonia. *Staphylococcus aureus* causes pneumonia by haematogenous spread of infection from another focus or after viral infections.

3. Streptococcal pneumonia. β -haemolytic streptococci may rarely cause pneumonia such as in children after measles or influenza, in severely debilitated elderly patients and in diabetics.

4. Pneumonia by gram-negative aerobic bacteria. Less common causes of lobar pneumonia are gram-negative bacteria like *Haemophilus influenzae*, *Klebsiella pneumoniae* (*Friedlander's bacillus*), *Pseudomonas*, *Proteus* and *Escherichia coli*. *H. influenzae* commonly causes pneumonia in children below 3 years of age after a preceding viral infection.

MORPHOLOGIC FEATURES. In lobar pneumonia, as the name suggests, part of a lobe, a whole lobe, or two lobes are involved, sometimes bilaterally. The lower lobes are affected most commonly. The sequence of pathologic changes described below represents the inflammatory response of lungs in bacterial infection.

1. STAGE OF CONGESTION: INITIAL PHASE (Web Image 17.6,A). The initial phase represents the early acute inflammatory response to bacterial infection and lasts for 1 to 2 days.

G/A The affected lobe is enlarged, heavy, dark red and congested. Cut surface exudes blood-stained frothy fluid.

M/E (Web Image 17.7): The features are as under:

- i) Dilatation and congestion of the capillaries in the alveolar walls.
- ii) Pale eosinophilic oedema fluid in the air spaces.
- iii) A few red cells and neutrophils in the intra-alveolar fluid.
- iv) Numerous bacteria demonstrated in the alveolar fluid by Gram's staining.

2. RED HEPATISATION: EARLY CONSOLIDATION (Web Image 17.6,B).

This phase lasts for 2 to 4 days. The term hepatisation in pneumonia refers to liver-like consistency of the affected lobe on cut section.

G/A The affected lobe is red, firm and consolidated. The cut surface of the involved lobe is airless, red-pink, dry, granular and has liver-like consistency. The stage of red hepatisation is accompanied by serofibrinous pleurisy.

M/E (Web Image 17.8): The features are as under:

- i) The oedema fluid of the preceding stage is replaced by strands of fibrin.
- ii) There is marked cellular exudate of neutrophils and extravasation of red cells.
- iii) Many neutrophils show ingested bacteria.
- iv) The alveolar septa are less prominent than in the first stage due to cellular exudation.

3. GREY HEPATISATION: LATE CONSOLIDATION (Web Image 17.6,C).

This phase lasts for 4 to 8 days.

G/A The affected lobe is firm and heavy. The cut surface is dry, granular and grey in appearance with liver-like consistency (**Web Image 17.9, A**). The change in colour from red to grey begins at the hilum and spreads towards the periphery. Fibrinous pleurisy is prominent.

M/E (Web Image 17.9,B): The features are as under:

- i) The fibrin strands are dense and more numerous.
- ii) The cellular exudate of neutrophils is reduced due to disintegration of many inflammatory cells as evidenced by their pyknotic nuclei. The red cells are also fewer. The macrophages begin to appear in the exudate.
- iii) The cellular exudate is often separated from the septal walls by a thin clear space.
- iv) The organisms are less numerous and appear as degenerated forms.

4. RESOLUTION (Web Image 17.6,D). This stage begins by 8th to 9th day if no chemotherapy is administered and is completed in 1 to 3 weeks. However, antibiotic therapy induces resolution on about 3rd day.

G/A The previously solid fibrinous constituent is liquefied by enzymatic action, eventually restoring the normal aeration in the affected lobe. The process of softening begins centrally and spreads to the periphery. The cut surface is grey-red or dirty brown and frothy, yellow, creamy fluid can be expressed on pressing.

M/E The features are as under:

- i) Macrophages are the predominant cells in the alveolar spaces, while neutrophils diminish in number. Many of the macrophages contain engulfed neutrophils and debris.
- ii) Granular and fragmented strands of fibrin in the alveolar spaces are seen due to progressive enzymatic digestion.
- iii) Alveolar capillaries are engorged.
- iv) There is progressive removal of fluid content as well as cellular exudate from the air spaces, partly by expectoration but mainly by lymphatics, resulting in restoration of normal lung parenchyma with aeration.

COMPLICATIONS. Since the advent of antibiotics, serious complications of lobar pneumonia are uncommon. However, they may develop in neglected cases and in patients with impaired immunologic defenses. These are: (i) Organisation, (ii) pleural effusion, (iii) empyema, (iv) lung abscess and (v) metastatic infection.

CLINICAL FEATURES. Classically, the onset of lobar pneumonia is sudden. The major symptoms are: shaking chills, fever, malaise with pleuritic chest pain, dyspnoea and cough with expectoration which may be mucoid, purulent or even bloody. The common physical findings are fever, tachycardia, and tachypnoea, and sometimes cyanosis if the patient is severely hypoxaemic. There is generally a marked neutrophilic leucocytosis. Blood cultures are positive in about 30% of cases. Chest radiograph may reveal consolidation. Culture of the organisms in the sputum and antibiotic sensitivity are most significant investigations for institution of specific antibiotics.

Bronchopneumonia (Lobular Pneumonia) (p. 471)

Bronchopneumonia or lobular pneumonia is infection of the terminal bronchioles that extends into the surrounding alveoli resulting in patchy consolidation of the lung. The condition is particularly frequent at the extremes of life (i.e. in infancy and old age), as a terminal event in chronic debilitating diseases and as a secondary infection following viral respiratory infections such as influenza, measles etc.

ETIOLOGY. The common organisms responsible for bronchopneumonia are staphylococci, streptococci, pneumococci, *Klebsiella pneumoniae*, *Haemophilus influenzae*, and gram-negative bacilli like *Pseudomonas* and coliform bacteria.

G/A Bronchopneumonia is identified by patchy areas of red or grey consolidation affecting one or more lobes, frequently found bilaterally and more often involving the lower zones of the lungs due to gravitation of the secretions. On cut surface, these patchy consolidated lesions are dry, granular, firm, red or grey in colour, 3 to 4 cm in diameter, slightly elevated over the surface and are often centred around a bronchiole (**Web Image 17.10**).

M/E (Web Image 17.11): The features are:

- i) Acute bronchiolitis.
- ii) Suppurative exudate, consisting chiefly of neutrophils, in the peribronchiolar alveoli.

- 394 iii) Thickening of the alveolar septa by congested capillaries and leucocytic infiltration.
iv) Less involved alveoli contain oedema fluid.

COMPLICATIONS. The complications of lobar pneumonia may occur in bronchopneumonia as well. However, complete resolution of bronchopneumonia is uncommon. There is generally some degree of destruction of the bronchioles resulting in foci of bronchiolar fibrosis that may eventually cause bronchiectasis.

CLINICAL FEATURES. The patients of bronchopneumonia are generally infants or elderly individuals. There may be history of preceding bed-ridden illness, chronic debility, aspiration of gastric contents or upper respiratory infection. For initial 2 to 3 days, there are features of acute bronchitis but subsequently signs and symptoms similar to those of lobar pneumonia appear. Blood examination usually shows a neutrophilic leucocytosis. Chest radiograph shows mottled, focal opacities in both the lungs, chiefly in the lower zones.

The salient features of the two main types of bacterial pneumonias are contrasted in **Web Table 17.2**.

B. VIRAL AND MYCOPLASMAL PNEUMONIA (PRIMARY ATYPICAL PNEUMONIA) (p. 472)

Viral and mycoplasmal pneumonia is characterised by patchy inflammatory changes, largely confined to interstitial tissue of the lungs, without any alveolar exudate. Other terms used for these respiratory tract infections are *interstitial pneumonitis*, reflecting the interstitial location of the inflammation, and *primary atypical pneumonia*, atypicality being the absence of alveolar exudate commonly present in other pneumonias.

ETIOLOGY. Interstitial pneumonitis is caused by a wide variety of agents, the most common being *respiratory syncytial virus* (RSV). Others are *Mycoplasma pneumoniae* and many viruses such as influenza and parainfluenza viruses, adenoviruses, rhinoviruses, coxsackieviruses and cytomegaloviruses (CMV). Occasionally, psittacosis (*Chlamydia*) and Q fever (*Coxiella*) are associated with interstitial pneumonitis.

G/A Depending upon the severity of infection, the involvement may be patchy to massive and widespread consolidation of one or both the lungs. The lungs are heavy, congested and subcrepitant. Sectioned surface of the lung exudes small amount of frothy or bloody fluid. The pleural reaction is usually infrequent and mild.

M/E Hallmark of viral pneumonias is the interstitial nature of the inflammatory reaction (**Web Image 17.12**):

- i) **Interstitial inflammation:** There is thickening of alveolar walls due to congestion, oedema and mononuclear inflammatory infiltrate comprised by lymphocytes, macrophages and some plasma cells.
- ii) **Necrotising bronchiolitis:** This is characterised by foci of necrosis of the bronchiolar epithelium, inspissated secretions in the lumina and mononuclear infiltrate in the walls and lumina.
- iii) **Reactive changes:** The lining epithelial cells of the bronchioles and alveoli proliferate in the presence of virus and may form multinucleate giant cells and syncytia in the bronchiolar and alveolar walls.
- iv) **Alveolar changes:** In severe cases, the alveolar lumina may contain oedema fluid, fibrin, scanty inflammatory exudate and coating of alveolar walls by pink, hyaline membrane similar to the one seen in respiratory distress syndrome.

COMPLICATIONS. The major complication of interstitial pneumonitis is superimposed bacterial infection and its complications. Most cases of interstitial pneumonitis recover completely. In more severe cases, there may be interstitial fibrosis and permanent damage.

CLINICAL FEATURES. Majority of cases of interstitial pneumonitis initially have upper respiratory symptoms with fever, headache and muscle-aches. A few days later appears dry, hacking, non-productive cough with retrosternal burning due to tracheitis and bronchitis. Blood film shows characteristic neutrophilic leucocytosis. Chest radiograph may show patchy or diffuse consolidation.

C. OTHER TYPES OF PNEUMONIAS (p. 474)

Pneumocystis carinii Pneumonia (p. 474)

Pneumocystis carinii, a protozoon widespread in the environment, causes pneumonia by inhalation of the organisms as an opportunistic infection in neonates and immunosuppressed people. Almost 100% cases of HIV/AIDS develop opportunistic infection during the course of disease, most commonly *Pneumocystis carinii* pneumonia. **Web Table 17.3** lists the various etiologic types of pneumonias associated with HIV infection due to profound immunosuppression. Other immunosuppressed groups are patients on chemotherapy for organ transplant and tumours, malnutrition, agammaglobulinaemia etc.

G/A The affected parts of the lung are consolidated, dry and grey.

M/E The features are as under:

- i) Interstitial pneumonitis with thickening and mononuclear infiltration of the alveolar walls.
- ii) Alveolar lumina contain pink frothy fluid containing the organisms.
- iii) By Gomori's methenamine-silver (GMS) stain, the characteristic oval or crescentic cysts, about 5 μm in diameter and surrounded by numerous tiny black dot-like trophozoites of *P. carinii* are demonstrable in the frothy fluid.
- iv) No significant inflammatory exudate is seen in the air spaces.

CLINICAL FEATURES. There is rapid onset of dyspnoea, tachycardia, cyanosis and non-productive cough. If untreated, it causes death in one or two weeks. Chest radiograph shows diffuse alveolar and interstitial infiltrate.

Legionella Pneumonia (p. 474)

Legionella pneumonia or Legionnaire's disease is an epidemic illness caused by gram-negative bacilli, *Legionella pneumophila* that thrives in aquatic environment. It was first recognised following investigation into high mortality among those attending American Legion Convention in Philadelphia in July 1976. The epidemic occurs in summer months by spread of organisms through contaminated drinking water or in air-conditioning cooling towers. Impaired host defenses in the form of immunodeficiency, corticosteroid therapy, old age and cigarette smoking play important roles.

Aspiration (Inhalation) Pneumonia (p. 474)

Aspiration or inhalation pneumonia results from inhalation of different agents into the lungs. These substances include food, gastric contents, foreign body and infected material from oral cavity. A number of factors predispose to inhalation pneumonia which include: unconsciousness, drunkenness, neurological disorders affecting swallowing, drowning, necrotic oropharyngeal tumours, in premature infants and congenital tracheo-oesophageal fistula.

MORPHOLOGIC FEATURES. Pathologic changes vary depending upon the particulate matter aspirated but in general right lung is affected more often due to direct path from the main bronchus:

1. Aspiration of small amount of **sterile foreign matter** such as acidic gastric contents produce *chemical pneumonitis*.
2. **Non-sterile aspirate** causes widespread *bronchopneumonia* with multiple areas of necrosis and suppuration. A granulomatous reaction with foreign body giant cells may surround the aspirated vegetable matter.

396 Hypostatic Pneumonia (p. 475)

Hypostatic pneumonia is the term used for collection of oedema fluid and secretions in the dependent parts of the lungs in severely debilitated, bed-ridden patients. The accumulated fluid in the basal zone and posterior part of lungs gets infected by bacteria from the upper respiratory tract and sets in bacterial pneumonia. Hypostatic pneumonia is a common terminal event in the old, feeble, comatose patients.

Lipid Pneumonia (p. 475)

Another variety of non-infective pneumonia is lipid pneumonia which is of 2 types:

1. Exogenous lipid pneumonia. This is caused by aspiration of a variety of oily materials. These are: inhalation of oily nasal drops, regurgitation of oily medicines from stomach (e.g. liquid paraffin), administration of oily vitamin preparation to reluctant children or to debilitated old patients.

2. Endogenous lipid pneumonia. Endogenous origin of lipids causing pneumonic consolidation is more common. The sources of origin are tissue breakdown following obstruction to airways e.g. obstruction by bronchogenic cancer, tuberculosis and bronchiectasis.

G/A The exogenous lipid pneumonia affects the right lung more frequently due to direct path from the main bronchus. Quite often, the lesions are bilateral. The affected part of the lungs is consolidated. Cut surface is characteristically 'golden yellow'.

M/E

- i) Lipid is finely dispersed in the cytoplasm of macrophages forming foamy macrophages within the alveolar spaces.
- ii) There may be formation of cholesterol clefts due to liberation of cholesterol and other lipids.
- iii) Formation of granulomas with foreign body giant cells may be seen around the large lipid droplets.

LUNG ABSCESS (p. 475)

Lung abscess is a localised area of necrosis of lung tissue with suppuration. It is of 2 types (**Web Image 17.13**):

- ◆ **Primary lung abscess** that develops in an otherwise normal lung. The commonest cause is aspiration of infected material.
- ◆ **Secondary lung abscess** that develops as a complication of some other disease of the lung or from another site.

ETIOPATHOGENESIS. The microorganisms commonly isolated from the lungs in lung abscess are streptococci, staphylococci and various gram-negative organisms. These are introduced into the lungs from one of the following mechanisms: Aspiration of infected foreign material, preceding bacterial infection, bronchial obstruction, septic embolism and miscellaneous:

- i) Infection in pulmonary infarcts.
- ii) Amoebic abscesses due to infection with *Entamoeba histolytica*.
- iii) Trauma to the lungs.
- iv) Direct extension from a suppurative focus in the mediastinum, oesophagus, subphrenic area or spine.

MORPHOLOGIC FEATURES. Abscesses due to aspiration are more likely to be in right lung due to more vertical main bronchus and are frequently single. They are commonly located in the lower part of the right upper lobe or apex of right lower lobe. Abscesses developing from preceding pneumonia and septic or pyaemic abscesses are often multiple and scattered throughout the lung.

G/A Abscesses may be of variable size from a few millimeters to large cavities, 5 to 6 cm in diameter. The cavity often contains exudate. An acute

lung abscess is initially surrounded by acute pneumonia and has poorly-defined ragged wall. With passage of time, the abscess becomes chronic and develops fibrous wall (**Web Image 17.14,A**).

M/E The characteristic feature is the destruction of lung parenchyma with suppurative exudate in the lung cavity. The cavity is initially surrounded by acute inflammation in the wall but later there is replacement by chronic inflammatory cell infiltrate composed of lymphocytes, plasma cells and macrophages. In more chronic cases, there is considerable fibroblastic proliferation forming a fibrocollagenic wall (**Web Image 17.14,B**).

CLINICAL FEATURES. The clinical manifestations are fever, malaise, loss of weight, cough, purulent expectoration and haemoptysis in half the cases. Clubbing of the fingers and toes appears in about 20% of patients. Secondary amyloidosis may occur in chronic long-standing cases.

FUNGAL INFECTIONS OF LUNG (p. 476)

Fungal infections of the lung are more common than tuberculosis in the US. These infections in healthy individuals are rarely serious but in immunosuppressed individuals may prove fatal.

1. Aspergillosis. Aspergillosis is the most common fungal infection of the lung caused by *Aspergillus fumigatus* that grows best in cool, wet climate. The infection may result in *allergic bronchopulmonary aspergillosis*, *aspergilloma* and *necrotising bronchitis*. Immunocompromised persons develop more serious manifestations of aspergillus infection, especially in leukaemic patients on cytotoxic drug therapy and HIV/AIDS.

G/A Pulmonary aspergillosis may occur within preexisting pulmonary cavities or in bronchiectasis as fungal ball.

M/E The fungus may appear as a tangled mass within the cavity. The organisms are identified by their characteristic morphology—thin septate hyphae with dichotomous branching at acute angles which stain positive for fungal stains such as PAS and silver impregnation technique (**Web Image 17.15**).

2. Mucormycosis. Mucormycosis is more often angioinvasive.

3. Candidiasis. Candidiasis or moniliasis caused by *Candida albicans* is a normal commensal in oral cavity, gut and vagina but attains pathologic form in immunocompromised host.

4. Histoplasmosis. It is caused by oval organism, *Histoplasma capsulatum*, by inhalation of infected dust or bird droppings.

5. Cryptococcosis. It is caused by *Cryptococcus neoformans* which is round yeast having a halo around it due to shrinkage in tissue sections. The infection occurs from infection by inhalation of pigeon droppings.

6. Coccidioidomycosis. Coccidioidomycosis is caused by *Coccidioides immitis* which are spherical spores.

7. Blastomycosis. It is an uncommon condition caused by *Blastomyces dermatitidis*.

CHRONIC OBSTRUCTIVE PULMONARY DISEASE (p. 477)

Chronic obstructive pulmonary disease (COPD) or chronic obstructive airway disease (COAD) are commonly used clinical terms for a group of pathological conditions in which there is chronic, partial or complete, obstruction to the airflow at any level from trachea to the smallest airways resulting in functional disability of the lungs i.e. they are diffuse lung diseases. The following 4 entities are included in COPD:

- I. Chronic bronchitis
- II. Emphysema
- III. Bronchial asthma
- IV. Bronchiectasis

Chronic bronchitis is a common condition defined clinically as persistent cough with expectoration on most days for at least three months of the year for two or more consecutive years. The cough is caused by oversecretion of mucus. In spite of its name, chronic inflammation of the bronchi is not a prominent feature. The condition is more common in middle-aged males than females; approximately 20% of adult men and 5% of adult women have chronic bronchitis, but only a minority of them develop serious disabling COPD or cor pulmonale. Quite frequently, chronic bronchitis is associated with emphysema.

ETIOPATHOGENESIS. The two most important etiologic factors responsible for majority of cases of chronic bronchitis are: cigarette smoking and atmospheric pollution. Other contributory factors are occupation, infection, familial and genetic factors.

G/A The bronchial wall is thickened, hyperaemic and oedematous. Lumina of the bronchi and bronchioles may contain mucus plugs and purulent exudate.

M/E Just as there is clinical definition, there is histologic definition of chronic bronchitis by increased Reid index. *Reid index* is the ratio between thickness of the submucosal mucus glands (i.e. hypertrophy and hyperplasia) in the cartilage-containing large airways to that of the total bronchial wall (**Web Image 17.16**).

CLINICAL FEATURES. There is considerable overlap of clinical features of chronic bronchitis and pulmonary emphysema (discussed below) as quite often the two coexist. The contrasting features of 'predominant emphysema' and 'predominant bronchitis' are presented in **Web Table 17.5**.

EMPHYSEMA (p. 478)

The WHO has defined pulmonary emphysema as combination of permanent dilatation of air spaces distal to the terminal bronchioles and the destruction of the walls of dilated air spaces. *Thus, emphysema is defined morphologically, while chronic bronchitis is defined clinically.* Since the two conditions coexist frequently and show considerable overlap in their clinical features, it is usual to label patients as 'predominant emphysema' and 'predominant bronchitis'.

CLASSIFICATION. As per WHO definition of pulmonary emphysema, it is classified according to the portion of the acinus involved, into 5 types: centriacinar, panacinar (panlobular), para-septal (distal acinar), irregular (para-cicatrical) and mixed (unclassified) emphysema. A number of other conditions to which the term 'emphysema' is loosely applied are, in fact, examples of 'overinflation'. A classification based on these principles is outlined in **Web Table 17.4**.

ETIOPATHOGENESIS. The commonest form of COPD is the combination of chronic bronchitis and pulmonary emphysema. Chronic bronchitis, however, does not always lead to emphysema nor all cases of emphysema have changes of chronic bronchitis. The association of the two conditions is principally linked to the common etiologic factors— most importantly *tobacco smoke* and *air pollutants*. Other less significant contributory factors are occupational exposure, infection and somewhat poorly-understood familial and genetic influences.

However, pathogenesis of the most significant event in emphysema, the *destruction of the alveolar walls*, is not linked to bronchial changes but is closely related to deficiency of serum alpha-1-antitrypsin (α 1-protease inhibitor) commonly termed *protease-antiprotease hypothesis*.

Protease-antiprotease hypothesis. Alpha-1-antitrypsin (α 1-AT), also called α 1-protease inhibitor (α 1-Pi), is a glycoprotein that forms the normal

constituent of the α 1-globulin fraction of the plasma proteins on serum electrophoresis. The single gene locus that codes for α -1-AT is located on the long arm of chromosome 15. It is normally synthesised in the liver and is distributed in the circulating blood, tissue fluids and macrophages. The normal function of α 1-AT is to inhibit proteases and hence its name α 1-protease inhibitor. The proteases (mainly elastases) are derived from neutrophils. Neutrophil elastase has the capability of digesting lung parenchyma but is inhibited from doing so by anti-elastase effect of α 1-AT.

There are several known alleles of α 1-AT which have an autosomal codominant inheritance pattern and are classified as normal (*PiMM*), deficient (*PiZZ*), null type (*Pi null null*) having no detectable level, and dysfunctional (*PiSS*) type having about half the normal level.

- ◆ The most common abnormal phenotype in classic α 1-AT deficiency is *homozygous state PiZZ* resulting from a single amino acid substitution Glu→Lys.

- ◆ Clinically significant deficiency is also associated with *homozygous Pi null null* and *heterozygous Pi nullZ*.

The *heterozygote pattern* of *PiMZ* has intermediate levels which is not sufficient to produce clinical deficiency, but heterozygote individuals who smoke heavily have higher risk of developing emphysema.

The other organ showing effects of α 1-AT deficiency is the liver which may develop obstructive jaundice early in infancy, and cirrhosis and hepatoma late in adulthood.

The mechanism of alveolar wall destruction in emphysema by elastolytic action is based on the imbalance between proteases (chiefly *elastase*) and anti-proteases (chiefly *anti-elastase*):

- ◆ By decreased anti-elastase activity i.e. deficiency of α -1 antitrypsin.
- ◆ By increased activity of elastase i.e. increased neutrophilic infiltration in the lungs causing excessive elaboration of neutrophil elastase.

There are enough evidences to suggest that smoking promotes emphysema by both decreasing the amount of anti-elastase as well as by increasing the elastolytic protease in the lungs e.g.

1. Oxidant in cigarette smoke has inhibitory influence on α -1-antitrypsin, thus lowering the level of anti-elastase activity.
2. Smokers have up to ten times more phagocytes and neutrophils in their lungs than nonsmokers; thus they have very high elastase activity.

Pathogenesis of emphysema by protease-antiprotease mechanism is diagrammatically illustrated in **Web Image 17.17**.

MORPHOLOGIC FEATURES. Emphysema can be diagnosed with certainty only by gross and histologic examination of sections of whole lung.

G/A The lungs are voluminous, pale with little blood. The edges of the lungs are rounded. Mild cases show dilatation of air spaces visible with hand lens. Advanced cases show subpleural bullae and blebs bulging outwards from the surface of the lungs with rib markings between them. The *bullae* are air-filled cyst-like or bubble-like structures, larger than 1 cm in diameter (**Web Image 17.18**).

M/E Depending upon the type of emphysema, there is dilatation of air spaces and destruction of septal walls of part of acinus involved i.e. respiratory bronchioles, alveolar ducts and alveolar sacs. Changes of bronchitis may be present.

CLINICAL FEATURES. Cases of 'predominant emphysema' develop clinical features after about one-third of the pulmonary parenchyma is damaged which occurs most severely in panacinar emphysema. The age at the time of diagnosis is often a decade later (about 60 years) than the age for predominant bronchitis (about 50 years). Though there is considerable overlap between the clinical features of chronic bronchitis and emphysema, the following features generally characterise 'predominant emphysema' (**Web Table 17.5**):

400 Morphology of Individual Types of Emphysema (p. 481)

1. CENTRIACINAR (CENTRILOBULAR) EMPHYSEMA. Centriacinar or centrilobular emphysema is one of the common types. It is characterised by initial involvement of respiratory bronchioles i.e. the central or proximal part of the acinus (**Web Image 17.19,B**).

G/A The lesions are more common and more severe in the upper lobes of the lungs. The characteristic appearance is obvious in cut surface of the lung. It shows distended air spaces in the centre of the lobules surrounded by a rim of normal lung parenchyma in the same lobule.

M/E There is distension and destruction of the respiratory bronchiole in the centre of lobules, surrounded peripherally by normal uninvolved alveoli.

2. PANACINAR (PANLOBULAR) EMPHYSEMA. Panacinar or panlobular emphysema is the other common type. In this type, all portions of the acinus are affected but not of the entire lung (**Web Image 17.19,C**). Panacinar emphysema is most often associated with α 1-antitrypsin deficiency in middle-aged smokers and is the one that produces the most characteristic anatomical changes in the lung in emphysema.

G/A In contrast to centriacinar emphysema, the panacinar emphysema involves lower zone of lungs more frequently and more severely than the upper zone. The involvement may be confined to a few lobules, or may be more widespread affecting a lobe or part of a lobe of the lung.

M/E Usually all the alveoli within a lobule are affected to the same degree. All portions of acini are distended—respiratory bronchioles, alveolar ducts and alveoli, are all dilated and their walls stretched and thin. Ruptured alveolar walls and spurs of broken septa are seen between the adjacent alveoli. The capillaries are stretched and thinned. Inflammatory changes are usually absent (**Web Image 17.20**).

3. PARASEPTAL (DISTAL ACINAR) EMPHYSEMA. This type of emphysema involves distal part of acinus while the proximal part is normal. Paraseptal or distal acinar emphysema is localised along the pleura and along the perilobular septa.

4. IRREGULAR (PARA-CICATRICAL) EMPHYSEMA. This is the most common form of emphysema, seen surrounding scars from any cause. The involvement is irregular as regards the portion of acinus involved as well as within the lung as a whole.

5. MIXED (UNCLASSIFIED) EMPHYSEMA. Quite often, the same lung may show more than one type of emphysema. It is usually due to more severe involvement resulting in loss of clearcut distinction between one type of emphysema and the other. Thus, the lungs of an elderly smoker at autopsy may show continuation of centriacinar emphysema in the upper lobes, panacinar in the lower lobes, and paraseptal emphysema in the subpleural region.

Morphology of Types of Overinflation (p. 482)

1. COMPENSATORY OVERINFLATION (COMPENSATORY EMPHYSEMA). When part of a lung or a lobe of lung is surgically removed, the residual lung parenchyma undergoes compensatory hyperinflation so as to fill the pleural cavity. Histologic examination shows dilatation of alveoli but no destruction of septal walls.

2. SENILE HYPERINFLATION (AGING LUNG, SENILE EMPHYSEMA). In old people, the lungs become voluminous due to loss of elastic tissue, thinning and atrophy of the alveolar ducts and alveoli. The alveoli are thin-walled and distended throughout the lungs but there is no significant destruction of the septal walls.

3. OBSTRUCTIVE OVERINFLATION (INFANTILE LOBAR EMPHYSEMA). Partial obstruction to the bronchial tree such as by a tumour or a foreign body causes overinflation of the region supplied by obstructed bronchus. Infantile lobar emphysema is a variant of obstructive overinflation occurring in infants in the first few days of life who develop respiratory distress or who have congenital hypoplasia of bronchial cartilage.

4. UNILATERAL TRANSLUCENT LUNG (UNILATERAL EMPHYSEMA). This is a form of overinflation in which one lung or one of its lobes or segments of a lobe are radiolucent. The condition occurs in adults and there is generally a history of serious pulmonary infection in childhood, probably bronchiolitis obliterans. The affected lung is grossly overinflated.

5. INTERSTITIAL EMPHYSEMA (SURGICAL EMPHYSEMA). The entry of air into the connective tissue framework of the lung is called interstitial or surgical emphysema. The usual sources of entry of air into stroma of the lung are rupture of alveoli or of larger airways. The causes are as under:

- i) Violent coughing with bronchiolar obstruction e.g. in children with whooping cough, bronchitis, in patients with obstruction to the airways by foreign bodies, blood clots and exposure to irritant gases.
- ii) Rupture of the oesophagus, trauma to the lung, or major bronchus and trachea.
- iii) Entry of air through surgical incision.
- iv) Fractured rib puncturing the lung parenchyma.
- v) Sudden change in atmospheric pressure e.g. in decompression sickness.

The condition may affect patients of all ages. On rupture of alveoli, the leaked air enters the fibrous connective tissue of the alveolar walls from where it extends into the fibrous septa of the lung, into the mediastinum, the pleura, and even the subcutaneous tissues. Escape of air into the pleural cavity may cause pneumothorax. Extensive accumulation of air in surgical emphysema may produce impaired blood flow in the lungs. *Pneumo-mediastinum* may produce symptoms resembling myocardial infarction.

BRONCHIAL ASTHMA (p. 483)

Asthma is a disease of airways that is characterised by increased responsiveness of the tracheobronchial tree to a variety of stimuli resulting in widespread spasmodic narrowing of the air passages which may be relieved spontaneously or by therapy. Asthma is an episodic disease manifested clinically by paroxysms of dyspnoea, cough and wheezing. However, a severe and unremitting form of the disease termed *status asthmaticus* may prove fatal.

Bronchial asthma is common and prevalent worldwide; in the United States about 4% of population is reported to suffer from this disease. It occurs at all ages but nearly 50% of cases develop it before the age of 10 years.

ETIOPATHOGENESIS AND TYPES. Based on the stimuli initiating bronchial asthma, two broad etiologic types are traditionally described: The contrasting features of the two main types are summed up in **Web Table 17.6**.

1. Extrinsic (atopic, allergic) asthma. This is the most common type of asthma. It usually begins in childhood or in early adult life. Most patients of this type of asthma have personal and/or family history of preceding allergic diseases such as rhinitis, urticaria or infantile eczema. Hypersensitivity to various extrinsic antigenic substances or 'allergens' is usually present in these cases. Most of these allergens cause ill-effects by inhalation e.g. house dust, pollens, animal danders, moulds etc. Occupational asthma stimulated by fumes, gases and organic and chemical dusts is a variant of extrinsic asthma. There are increased levels of IgE in the serum and positive skin test with the specific offending inhaled antigen representing an IgE-

402 mediated type I hypersensitivity reaction which includes an 'acute immediate response' and a 'late phase reaction':

2. Intrinsic (idiosyncratic, non-atopic) asthma. This type of asthma develops later in adult life with negative personal or family history of allergy, negative skin test and normal serum levels of IgE. Most of these patients develop typical symptom-complex after an upper respiratory tract infection by viruses. Associated nasal polypi and chronic bronchitis are commonly present. There are no recognisable allergens but about 10% of patients become hypersensitive to drugs, most notably to small doses of aspirin (aspirin-sensitive asthma).

3. Mixed type. Many patients do not clearly fit into either of the above two categories and have mixed features of both. Those patients who develop asthma in early life have strong allergic component, while those who develop the disease late tend to be non-allergic.

G/A The lungs are overdistended due to over-inflation. The cut surface shows characteristic occlusion of the bronchi and bronchioles by viscid mucus plugs.

M/E (Web Image 17.21): The features are as under:

1. The mucus plugs contain normal or degenerated respiratory epithelium forming twisted strips called *Curschmann's spirals*.
2. The sputum usually contains numerous eosinophils and diamond-shaped crystals derived from eosinophils called *Charcot-Leyden crystals*.
3. The bronchial wall shows thickened basement membrane of the bronchial epithelium, submucosal oedema and inflammatory infiltrate consisting of lymphocytes and plasma cells with prominence of eosinophils.
4. Changes of bronchitis and emphysema may supervene, especially in intrinsic asthma.

CLINICAL FEATURES. Asthmatic patients suffer from episodes of acute exacerbations interspersed with symptom-free periods. Characteristic clinical features are paroxysms of dyspnoea, cough and wheezing. Most attacks typically last for a few minutes to hours. When attacks occur continuously it may result in more serious condition called *status asthmaticus*. The clinical diagnosis is supported by demonstration of circulation eosinophilia and sputum demonstration of Curschmann's spirals and Charcot-Leyden crystals.

BRONCHIECTASIS (p. 484)

Bronchiectasis is defined as abnormal and irreversible dilatation of the bronchi and bronchioles (greater than 2 mm in diameter) developing secondary to inflammatory weakening of the bronchial walls. The most characteristic clinical manifestation of bronchiectasis is persistent cough with expectoration of copious amounts of foul-smelling, purulent sputum. Post-infectious cases commonly develop in childhood and in early adult life.

ETIOPATHOGENESIS. The origin of inflammatory destructive process of bronchial walls is nearly always a result of two basic mechanisms: endobronchial obstruction and infection.

These 2 mechanisms are seen in a number of clinical settings as under:

1. Hereditary and congenital factors e.g. *congenital bronchiectasis, cystic fibrosis, hereditary immune deficiency diseases, immotile cilia syndrome and atopic bronchial asthma*.

2. Obstruction. Post-obstructive bronchiectasis, unlike the congenital-hereditary forms, is of the localised variety, usually confined to one part of the bronchial system. The causes of endobronchial obstruction include foreign bodies, endobronchial tumours, compression by enlarged hilar lymph nodes and post-inflammatory scarring (e.g. in healed tuberculosis) all of which favour the development of post-obstructive bronchiectasis.

3. As secondary complication. *Necrotising pneumonias* such as in staphylococcal suppurative pneumonia and *tuberculosis* may develop bronchiectasis as a complication.

G/A The lungs may be involved diffusely or segmentally. Bilateral involvement of lower lobes occurs most frequently. More vertical air passages of left lower lobe are more often involved than the right. The pleura is usually fibrotic and thickened with adhesions to the chest wall. The dilated airways, depending upon their gross or bronchographic appearance, have been subclassified into the following different types (**Web Image 17.22**):

- i) *Cylindrical*: the most common type characterised by tube-like bronchial dilatation.
- ii) *Fusiform*: having spindle-shaped bronchial dilatation.
- iii) *Saccular*: having rounded sac-like bronchial distension.
- iv) *Varicose*: having irregular bronchial enlargements.

Cut surface of the affected lobes, generally the lower zones, shows characteristic honey-combed appearance. The bronchi are extensively dilated nearly to the pleura, their walls are thickened and the lumina are filled with mucus or muco-pus (**Web Image 17.23**).

M/E (**Web Image 17.24**): The features are as under:

- i) The bronchial epithelium may be normal, ulcerated or may show squamous metaplasia.
- ii) The bronchial wall shows infiltration by acute and chronic inflammatory cells and destruction of normal muscle and elastic tissue with replacement by fibrosis.
- iii) The intervening lung parenchyma shows fibrosis, while the surrounding lung tissue shows changes of interstitial pneumonia.
- iv) The pleura in the affected area is adherent and shows bands of fibrous tissue between the bronchus and the pleura.

CLINICAL FEATURES. The clinical manifestations of bronchiectasis typically consist of chronic cough with foul-smelling sputum production, haemoptysis and recurrent pneumonia. Sinusitis is a common accompaniment of diffuse bronchiectasis. Late complications occurring in cases uncontrolled for years include development of clubbing of the fingers, metastatic abscesses (often to the brain), amyloidosis and cor pulmonale.

□ **CHRONIC RESTRICTIVE PULMONARY DISEASE** (p. 486)

The second large group of diffuse lung disease is 'chronic restrictive pulmonary disease' characterised by reduced expansion of lung parenchyma with decreased total lung capacity. This group of diseases must be distinguished from the foregoing COPD (**Web Table 17.7**).

Restrictive lung disease includes 2 types of conditions:

A. Restriction due to chest wall disorder: It includes following conditions:

1. Kyphoscoliosis
2. Poliomyelitis
3. Severe obesity
4. Pleural diseases.

B. Restriction due to interstitial and infiltrative diseases. Commonly called as '*interstitial lung diseases (ILDs)*', these are diseases characterised by non-infectious diffuse parenchymal involvement of the lung i.e. the alveolar lumina and alveolar epithelium, capillary basement membrane, the intervening space, perivascular tissue and lymphatic tissue. Diffuse lung parenchymal involvement may be primary, or it may be involved secondarily as a part of some other multi-organ disease process. The term 'infiltrative' is used here to denote the radiologic appearance of lungs in chest radiographs which show characteristic diffuse interstitial ground-glass opacities. The

ILDs consist of more than 200 heterogeneous conditions which have common clinical, radiologic, and functional manifestations but diverse pathological features. Depending upon the underlying pathologic findings, ILDs have been broadly classified into 2 groups, each further subdivided into those with known and unknown causes:

- ◆ Conditions with predominant non-specific inflammation (alveolitis, interstitial inflammation, and fibrosis).
- ◆ Conditions with predominant granulomatous inflammation.

Based on this, an abbreviated classification of ILDs is given in **Web Table 17.8**.

The exact **pathogenesis** of ILDs from injury to fibrosis is not known. However, it can be explained on immune basis as under (**Web Image 17.25**):

- i) There is *local inflammatory reaction* in the alveoli in response to various exogenous and endogenous stimuli in the form of lymphocytes (both B and T) and macrophages.
- ii) Activated macrophages cause recruitment of neutrophils and also produce fibrogenic and chemotactic *cytokines*. Neutrophils liberate proteases and oxidants which injure the type I pneumocytes resulting in initial microscopic alveolitis, while cytokines cause subsequent proliferation of type II pneumocytes and fibrosis.
- iii) The result is *inflammatory destruction* of the pulmonary parenchyma followed by fibrosis. Eventually, there is widespread destruction of alveolar capillary walls resulting in end-stage lung or 'honeycomb lung'.

PNEUMOCONIOSES (p. 487)

Pneumoconiosis is the term used for lung diseases caused by inhalation of dust, mostly at work (*pneumo* = lung; *conis* = dust in Greek). These diseases are, therefore, also called 'dust diseases' or 'occupational lung diseases'.

The type of lung disease varies according to the nature of inhaled dust. Some dusts are inert and cause no reaction and no damage at all, while others cause immunologic damage and predispose to tuberculosis or to neoplasia. The factors which determine the extent of damage caused by inhaled dusts are as under:

1. size and shape of the particles;
2. their solubility and physicochemical composition;
3. the amount of dust retained in the lungs;
4. the additional effect of other irritants such as tobacco smoke; and
5. host factors such as efficiency of clearance mechanism and immune status of the host.

In general, most of the inhaled dust particles larger than 5 μm reach the terminal airways where they are ingested by alveolar macrophages. Most of these too are eliminated by expectoration but the remaining accumulate in alveolar tissue. Of particular interest are the particles smaller than 1 μm which are deposited in the alveoli most efficiently. The tissue response to inhaled dust may be one of the following three types:

- ◆ *Fibrous nodules* e.g. in coal-workers' pneumoconiosis and silicosis.
- ◆ *Interstitial fibrosis* e.g. in asbestosis.
- ◆ *Hypersensitivity reaction* e.g. in berylliosis.

A comprehensive list of various types of occupational lung diseases caused by inorganic (mineral) dusts and organic dusts is presented in **Web Table 17.9**.

Coal-Workers' Pneumoconiosis (p. 488)

This is the commonest form of pneumoconiosis and is defined as the lung disease resulting from inhalation of coal dust particles, especially in coal-miners engaged in handling soft bituminous coal for a number of years,

often 20 to 30 years. It exists in 2 forms—a milder form of the disease called *simple coal workers' pneumoconiosis* and an advanced form termed *progressive massive fibrosis* (complicated coal-miners' pneumoconiosis). *Anthraco-sis*, on the other hand, is not a lung disease in true sense but is the common, benign and asymptomatic accumulation of carbon dust in the lungs of most urban dwellers due to atmospheric pollution and cigarette smoke (*anthracite* refers to coal).

PATHOGENESIS. Pathogenetically, it appears that anthracosis, simple coal-workers' pneumoconiosis and progressive massive fibrosis are different stages in the evolution of fully-developed coal-workers' pneumoconiosis. A number of predisposing factors have been implicated in this transformation as follows:

1. Older age of the miners.
2. Severity of coal dust burden engulfed by macrophages.
3. Prolonged exposure (20 to 30 years) to coal dust.
4. Concomitant tuberculosis.
5. Additional role of silica dust.

Activation of alveolar macrophage plays the most significant role in the pathogenesis of progressive massive fibrosis by release of various mediators (**Web Image 17.26,A**):

- i) *Free radicals* which are reactive oxygen species which damage the lung parenchyma.
- ii) *Chemotactic factors* for various leucocytes (leukotrienes, TNF, IL-8 and IL-6) resulting in infiltration into pulmonary tissues by these inflammatory cells which on activation cause further damage.
- iii) *Fibro-genic cytokines* such as IL-1, TNF and platelet derived growth factor (PDGF) which stimulate healing by fibrosis due to proliferation of fibroblasts at the damaged tissue site.

MORPHOLOGIC FEATURES. The pathologic findings at autopsy of lungs in the major forms of coal-workers' pneumoconiosis are considered below under 3 headings:

SIMPLE COAL-WORKERS' PNEUMOCONIOSIS. G/A The lung parenchyma shows small, black focal lesions, measuring less than 5 mm in diameter and evenly distributed throughout the lung but have a tendency to be more numerous in the upper lobes. These are termed *coal macules*, and if palpable are called *nodules*. The air spaces around coal macules are dilated with little destruction of alveolar walls (**Web Image 17.26,A**). Similar blackish pigmentations are found on the pleural surface and in the regional lymph nodes (**Web Image 17.27**).

M/E (Web Image 17.28): The features are as under:

1. Coal macules are composed of aggregates of dust-laden macrophages. These are present in the alveoli and in the bronchiolar and alveolar walls.
2. There is some increase in the network of reticulin and collagen in the coal macules.
3. Respiratory bronchioles and alveoli surrounding the macules are distended without significant destruction of the alveolar walls.

PROGRESSIVE MASSIVE FIBROSIS. G/A Besides the coal macules and nodules of simple pneumoconiosis, there are larger, hard, black scattered areas measuring more than 2 cm in diameter and sometimes massive. They are usually bilateral and located more often in the upper parts of the lungs posteriorly. Sometimes, these masses break down centrally due to ischaemic necrosis or due to tuberculosis forming cavities filled with black semifluid resembling India ink (**Web Image 17.27**).

M/E The features are as under:

1. The fibrous lesions are composed almost entirely of dense collagen and carbon pigment.

2. The wall of respiratory bronchioles and pulmonary vessels included in the massive scars are thickened and their lumina obliterated.
3. There is scanty inflammatory infiltrate of lymphocytes and plasma cells around the areas of massive scars.
4. The alveoli surrounding the scars are markedly dilated.

RHEUMATOID PNEUMOCONIOSIS (CAPLAN'S SYNDROME). The development of rheumatoid arthritis in a few cases of coal-workers' pneumoconiosis, silicosis or asbestosis is termed rheumatoid pneumoconiosis or Caplan's syndrome.

G/A The lungs have rounded, firm nodules with central necrosis, cavitation or calcification.

M/E The lung lesions are modified rheumatoid nodules with central zone of dust-laden fibrinoid necrosis enclosed by palisading fibroblasts and mononuclear cells.

CLINICAL FEATURES. Simple coal-workers' pneumoconiosis is the mild form of disease characterised by chronic cough with black expectoration. The radiological findings of nodularities in the lungs appear after working for several years in coal-mines. Progressive massive fibrosis is, however, a serious disabling condition manifested by progressive dyspnoea and chronic cough with jet-black sputum. More advanced cases develop pulmonary hypertension and right ventricular hypertrophy (cor pulmonale). Coal workers have increased risk of developing carcinomas of the stomach, probably due to swallowing of coal dust containing carcinogens. But bronchogenic carcinoma does not appear to be more common in coal-miners than in other groups.

Silicosis (p. 490)

Historically, silicosis used to be called 'knife grinders' lung. Silicosis is caused by prolonged inhalation of silicon dioxide, commonly called silica. Silica constitutes about one-fourth of earth's crust. Therefore, a number of occupations engaged in siliceous rocks or sand and products manufactured from them are at increased risk. These include miners (e.g. of granite, sandstone, slate, coal, gold, tin and copper), quarry workers, tunnellers, sandblasters, grinders, ceramic workers, foundry workers and those involved in the manufacture of abrasives containing silica. Peculiar to India are the occupational exposure to pencil, slate and agate-grinding industry carrying high risk of silicosis (agate = very hard stone containing silica). According to an Indian Council of Medical Research report, it is estimated that about 3 million workers in India are at high potential risk of silica exposure employed in a variety of occupations including construction workers.

PATHOGENESIS. Silicosis appears after prolonged exposure to silica dust, often a few decades. Besides, it depends upon a number of other factors such as total dose, duration of exposure, the type of silica inhaled and individual host factors. The following sequence of events has been proposed and schematically illustrated in **Web Image 17.26, B**:

1. Silica particles between 0.5 to 5 μm size on reaching the alveoli are taken by the macrophages which undergo necrosis. New macrophages engulf the debris and thus a repetitive cycle of *phagocytosis and necrosis* is set up.
2. Some of the silica dust is transported to the subpleural and interlobar lymphatics and into the regional lymph nodes. The *cellular aggregates* containing silica become associated with lymphocytes, plasma cells, mast cells and fibroblasts.
3. Silica dust is *fibrogenic*. Crystalline form, particularly quartz, is more fibrogenic than non-crystalline form of silica.

4. Simultaneously, there is *activation of T and B lymphocytes*. This results in increased serum levels of immunoglobulins (IgG and IgM), antinuclear antibodies, rheumatoid factor and circulating immune complexes as well as proliferation of T cells.
5. As noted above, silica is *cytotoxic* and kills the macrophages which engulf it. The released silica dust activates viable macrophages leading to secretion of macrophage-derived growth factors such as interleukin-1 that favour fibroblast proliferation and collagen synthesis.

G/A The chronic silicotic lung is studded with well-circumscribed, hard, fibrotic nodules, 1 to 5 mm in diameters. They are scattered throughout the lung parenchyma but are initially more often located in the upper zones of the lungs. These nodular lesions frequently have simultaneous deposition of coal-dust and may develop calcification. The pleura is grossly thickened and adherent to the chest wall. The lesions may undergo ischaemic necrosis and develop cavitation, or be complicated by tuberculosis and rheumatoid pneumoconiosis (**Web Image 17.29**).

M/E (Web Image 17.30): The features are as under:

1. The silicotic nodules are located in the region of respiratory bronchioles, adjacent alveoli, pulmonary arteries, in the pleura and the regional lymph nodes.
2. The *silicotic nodules* consist of central hyalinised material with scanty cellularity and some amount of dust. The hyalinised centre is surrounded by concentric laminations of collagen which is further enclosed by more cellular connective tissue, dust-filled macrophages and a few lymphocytes and plasma cells.
3. The collagenous nodules have cleft-like spaces between the lamellae of collagen which when examined polariscopically may demonstrate numerous birefringent particles of silica.
4. The severe and progressive form of the disease may result in coalescence of adjacent nodules and cause complicated silicosis.

CLINICAL FEATURES. The functional effects of silicosis develop slowly and insidiously. The main presenting complaint is dyspnoea. In time, the patient may develop features of obstructive or restrictive pattern of disease. Other complications such as pulmonary tuberculosis, rheumatoid arthritis (Caplan's syndrome) and cor pulmonale may occur. The chest radiograph initially shows fine nodularity, while later there are larger and coalescent nodules. Silicosis does not carry increased risk of developing bronchogenic carcinoma.

Asbestos Disease (p. 492)

Asbestos as a mineral is known to mankind for more than 4000 years but its harmful effects have come to light during the last few decades. In general, if *coal is lot of dust and little fibrosis, asbestos is little dust and a lot of fibrosis*. In nature, asbestos exists as long thin fibrils which are fire-resistant and can be spun into yarns and fabrics suitable for thermal and electrical insulation and has many applications in industries. Particularly at risk are workers engaged in mining, fabrication and manufacture of a number of products from asbestos such as asbestos pipes, tiles, roofs, textiles, insulating boards, sewer and water conduits, brake lining, clutch castings etc.

There are two major geometric forms of asbestos:

- ◆ **Serpentine** consisting of curly and flexible fibres. It includes the most common chemical form *chrysotile* (white asbestos) comprising more than 90% of commercially used asbestos.
- ◆ **Amphibole** consists of straight, stiff and rigid fibres. It includes the less common chemical forms *crocidolite* (blue asbestos), *amosite* (brown asbestos), *tremolite*, *anthophyllite* and *actinolite*. However, the group of amphibole, though less common, is more important since it is associated

408 with induction of malignant pleural tumours, particularly in association with crocidolite.

PATHOGENESIS. Overexposure to asbestos for more than a decade may produce asbestosis of the lung, pleural lesions and certain tumours. How asbestos causes all these lesions is not clearly understood but the following mechanisms have been suggested (**Web Image 17.26,C**):

1. The inhaled asbestos fibres are *phagocytosed by alveolar macrophages* from where they reach the interstitium.
2. The asbestos-laden macrophages release *chemo-attractants* for neutrophils and for more macrophages, thus inciting cellular reaction around them.
3. Asbestos fibres are coated with glycoprotein and endogenous haemosiderin to produce characteristic beaded or dumbbell-shaped *asbestos bodies*.
4. All types of asbestos are *fibrogenic* and result in interstitial fibrosis. Fibroblastic proliferation may occur via macrophage-derived growth factor such as interleukin-1.
5. A few *immunological abnormalities* such as antinuclear antibodies and rheumatoid factor have been found in cases of asbestosis but their role in the genesis of disease is not clear.
6. Asbestos fibres are *carcinogenic*, the most carcinogenic being crocidolite.

MORPHOLOGIC FEATURES. Over-exposure to asbestos is associated with 3 types of lesions: asbestosis, pleural disease and certain tumours.

A. ASBESTOSIS. The gross pulmonary fibrosis caused by asbestos exposure and histologic demonstration of asbestos bodies on asbestos fibres is termed asbestosis.

G/A The affected lungs are small and firm with cartilage-like thickening of the pleura. The sectioned surface shows variable degree of pulmonary fibrosis, especially in the subpleural areas and in the bases of lungs (**Web Image 17.31**).

M/E

1. There is non-specific interstitial fibrosis.
2. There is presence of characteristic *asbestos bodies* in the involved areas (**Web Image 17.32**). These are asbestos fibres coated with glycoprotein and haemosiderin and appear beaded or dumbbell-shaped. The coating stains positively for Prussian blue reaction.
3. There may be changes of emphysema in the pulmonary parenchyma between the areas of interstitial fibrosis.
4. The involvement of hilar lymph nodes in asbestosis is not as significant as in silicosis.

B. PLEURAL DISEASE. Pleural disease in asbestos exposure may produce one of the following 3 types of lesions:

1. **Pleural effusion.** It develops in about 5% of asbestos workers and is usually serious type. Pleural effusion is generally accompanied by subpleural asbestosis.
2. **Visceral pleural fibrosis.** Quite often, asbestosis is associated with dense fibrous thickening of the visceral pleura encasing the lung.
3. **Pleural plaques.** Fibrocalcific pleural plaques are the most common lesions associated with asbestos exposure.

G/A The lesions appear as circumscribed, flat, small (upto 1 cm in diameter), firm or hard, bilateral nodules. They are seen more often on the posterolateral part of parietal pleura and on the pleural surface of the diaphragm.

M/E They consist of hyalinised collagenous tissue which may be calcified so that they are visible on chest X-ray.

C. TUMOURS. Asbestos exposure predisposes to a number of cancers, most importantly bronchogenic carcinoma and malignant mesothelioma.

1. Bronchogenic carcinoma is the most common malignancy in asbestos workers. Its incidence is 5 times higher in non-smoker asbestos workers than the non-smoker general population and 10 times higher in smoker asbestos workers than the other smokers.

2. Malignant mesothelioma is an uncommon tumour but association with asbestos exposure is present in 30 to 80% of cases with mesothelioma. The exposure need not be heavy because mesothelioma is known to develop in people living near asbestos plants or in wives of asbestos workers.

CLINICAL FEATURES. Asbestosis is a slow and insidious illness. The patient may remain asymptomatic for a number of years in spite of radiological evidence of calcific pleural plaques and parenchymatous changes. More advanced cases show development of Caplan's syndrome, pulmonary hypertension, cor pulmonale and various forms of cancers.

Berylliosis (p. 493)

Berylliosis is caused by heavy exposure to dust or fumes of metallic beryllium or its salts. Beryllium was used in the past in fluorescent tubes and light bulbs but currently it is principally used in nuclear and aerospace industries and in the manufacture of electrical and electronic equipments. Two forms of pulmonary berylliosis are recognised.

ACUTE BERYLLIOSIS. Acute berylliosis occurs in individuals who are unusually sensitive to it and are heavily exposed to it for 2 to 4 weeks. The pulmonary reaction is in the form of an exudative chemical pneumonitis.

CHRONIC BERYLLIOSIS. Chronic berylliosis develops in individuals who are sensitised to it for a number of years, often after a delay of 20 or more years. The disease is a cell-mediated hypersensitivity reaction in which the metal beryllium acts as a hapten. The condition is characterised by development of non-caseating epithelioid granulomas like those of sarcoidosis. The granulomas have giant cells which frequently contain 3 types of inclusions:

1. Birefringent crystals.
2. Concentrically-laminated haematoxyphilic Schaumann or conchoid bodies.
3. Acidophilic stellate-shaped asteroid bodies.

ILD ASSOCIATED WITH IMMUNOLOGIC LUNG DISEASES (p. 493)

Hypersensitivity (Allergic) Pneumonitis (p. 493)

Hypersensitivity pneumonitis is a group of immunologically-mediated ILDs occurring in workers inhaling a variety of organic (biologic) antigenic materials. The condition may have an *acute* onset due to isolated exposure or may be *chronic* due to repeated low-dose exposure.

ETIOPATHOGENESIS. A list of important organic (biologic) dusts which may be inhaled to produce hypersensitivity pneumonitis is already given in Web Table 17.9. The immunologic mechanisms underlying hypersensitivity pneumonitis from any of these causes appear to be either type III immune-complex disease or type IV delayed-hypersensitivity reaction.

1. **Farmers' lung** is the classic example resulting from exposure to thermophilic actinomycetes generated by humid and warm mouldy hay.
2. **Bagassosis** occurs in individuals engaged in manufacture of paper and cardboard from sugarcane bagasse. Spores of thermophilic actinomycetes grow rapidly in mouldy sugarcane bagasse which are inhaled.
3. **Byssinosis** is an occupational lung disease occurring in workers exposed to fibres of cotton, flax and hemp for a number of years. The role of

410 immunologic mechanisms in byssinosis is not as clear as in exposure to other organic dusts.

4. **Bird-breeders' (Bird-fanciers') lung** occurs in pigeon breeders, parrot breeders, chicken farmers and bird-fanciers who are exposed to bird-droppings and danders from their feathers.

5. **Mushroom-workers' lung** is found in mushroom cultivators exposed to mushroom compost dust.

6. **Malt-workers' lung** is seen in distillery and brewery workers who are exposed to mouldy barley and malt dust.

7. **Maple-bark disease** occurs in those involved in stripping of maple bark and inhale mouldy maple bark.

8. **Silo-fillers' disease** occurs in individuals who enter the *silo* (silo is an airtight store-house of fodder for farm animals) in which toxic fumes of nitric oxide and nitrogen dioxide are formed due to fermentation of silage.

MORPHOLOGIC FEATURES. *In early stage*, the alveolar walls are diffusely infiltrated with lymphocytes, plasma cells and macrophages. A proportion of cases show granulomas consisting of histiocytes and giant cells of foreign body or Langhans' type.

In chronic cases, the lungs show interstitial fibrosis with some inflammatory infiltrate. Honeycombing of the lung may be present.

CLINICAL FEATURES. The clinical features vary according to the stage. In acute cases, there is generally sudden attack of fever, myalgia, dyspnoea, cough and leucocytosis. In more chronic cases, there are signs of slowly progressive respiratory failure, dyspnoea and cyanosis as seen in other interstitial lung diseases.

Pulmonary Infiltrates with Eosinophilia (p. 494)

Pulmonary eosinophilia, eosinophilic pneumonias or pulmonary infiltration with eosinophilia (PIE) syndrome are a group of immunologically-mediated lung diseases characterised by combination of 2 features:

- ◆ Infiltration of the lungs in chest radiographs.
- ◆ Elevated eosinophil count in the peripheral blood.

ETIOPATHOGENESIS. PIE syndrome has a number of diverse causes and pathogenesis. These are: Löeffler's syndrome, tropical pulmonary eosinophilia, secondary chronic pulmonary eosinophilia, idiopathic chronic eosinophilic pneumonia and hypereosinophilic syndrome.

G/A The lungs usually show patchy consolidation.

M/E There is thickening of the alveolar walls by oedema and exudate, chiefly of eosinophils, and some lymphocytes and plasma cells. The alveolar lumina also contain eosinophils.

Goodpasture's Syndrome (p. 494)

Goodpasture's syndrome or pulmonary haemorrhage syndrome is combination of necrotising haemorrhagic interstitial pneumonitis and rapidly progressive glomerulonephritis. The renal lesions of Goodpasture's syndrome are described in Chapter 22.

ETIOPATHOGENESIS. The condition results from immunologic damage produced by anti-basement membrane antibodies formed against antigens common to the glomerular and pulmonary basement membranes. The trigger for initiation of this autoimmune response is not clear; it could be virus infection, exposure to hydrocarbons and smoking.

G/A The lungs are heavy with red-brown areas of consolidation.

M/E

◆ *In acute stage*, there are focal areas of haemorrhages in the alveoli and focal necrosis in the alveolar walls.

◆ *In more chronic cases*, there is organisation of the haemorrhage leading to interstitial fibrosis and filling of alveoli with haemosiderin-laden macrophages.

CLINICAL FEATURES. The condition occurs commonly in 2nd or 3rd decades of life with preponderance in males. The pulmonary manifestations generally precede the renal disease. Most cases present with haemoptysis accompanied with dyspnoea, fatigue, weakness and anaemia. Renal manifestations soon appear which include haematuria, proteinuria, uraemia and progressive renal failure.

Pulmonary Alveolar Proteinosis (p. 494)

Pulmonary alveolar proteinosis is a rare chronic disease in which the distal airspaces of the lungs are filled with granular, PAS-positive, eosinophilic material with abundant lipid in it. The condition can occur at any age from infancy to old age.

ETIOPATHOGENESIS. The etiology and pathogenesis of alveolar proteinosis are unknown. A number of possibilities have been suggested:

- ◆ Since the alveolar material is combination of lipid and protein, it is not simply an overproduction of surfactant.
- ◆ Alveolar proteinosis may have an occupational etiology as seen in patients heavily exposed to silica.
- ◆ It may have an etiologic association with haematologic malignancies.
- ◆ There may be defective alveolar clearance of debris.

G/A Usually both lungs are involved, particularly the lower lobes. The lungs are heavier with areas of consolidation. Sectioned surface exudes abundant turbid fluid.

M/E The hallmark of the condition is presence of homogeneous, granular, eosinophilic material which stains brightly with PAS. Often, the material contains cholesterol clefts. There is no significant inflammatory infiltrate in the affected alveoli.

CLINICAL FEATURES. The condition is manifested clinically by dyspnoea, cough, chest pain, pyrexia, fatigue and loss of weight. Chest X-ray shows confluent areas of consolidation.

ILD ASSOCIATED WITH CONNECTIVE TISSUE DISEASES (p. 495)

A number of connective tissue diseases or collagen diseases may result in chronic interstitial fibrosis and destruction of blood vessels.

- 1. SCLERODERMA (PROGRESSIVE SYSTEMIC SCLEROSIS).** The lungs are involved in 80% cases of scleroderma. Interstitial pulmonary fibrosis is the most common form of pulmonary involvement. The disease usually involves the lower lobes and subpleural regions of the lungs and may lead to honeycombing of the lung. There is increased risk of development of cancer of the lung in pulmonary fibrosis in scleroderma.
- 2. RHEUMATOID ARTHRITIS.** Pulmonary involvement in rheumatoid arthritis may result in pleural effusion, interstitial pneumonitis, necrobiotic nodules and rheumatoid pneumoconiosis. The parenchymatous lesions in rheumatoid arthritis are most commonly seen in the lower lobe.
- 3. SYSTEMIC LUPUS ERYTHEMATOSUS.** Patients with systemic lupus erythematosus (SLE) commonly develop some form of lung disease during the course. The most common manifestation of SLE is pleurisy with small amount of pleural effusion that may contain LE cells.
- 4. SJÖGREN'S SYNDROME.** Patients with Sjögren's syndrome often have rheumatoid arthritis and associated pulmonary changes.

412 **5. DERMATOMYOSITIS AND POLYMYOSITIS.** Interstitial pneumonitis and interstitial fibrosis commonly accompany dermatomyositis and polymyositis.

6. WEGENER'S GRANULOMATOSIS. Wegener's granulomatosis is an necro-inflammatory lesion having 4 components—granulomas of the upper respiratory tract, granulomas of the lungs, systemic vasculitis and focal necrotising glomerulonephritis. *Localised or limited form* of the disease occurs in the lungs without involvement of other organs.

IDIOPATHIC PULMONARY FIBROSIS (p. 495)

Idiopathic pulmonary fibrosis is the most common form of diffuse interstitial pneumonia and has bad prognosis compared with other forms of lung fibrosis. Diffuse interstitial fibrosis can occur as a result of a number of pathologic entities such as pneumoconiosis, hypersensitivity pneumonitis and collagen-vascular disease. However, in half the cases of diffuse interstitial fibrosis, no apparent cause or underlying disease is identifiable. Such cases are included under the entity '*idiopathic pulmonary fibrosis*' in the United States and '*cryptogenic fibrosing alveolitis*' in Britain.

PATHOGENESIS. The pathogenesis of idiopathic pulmonary fibrosis is unknown and the condition is diagnosed by excluding all known causes of interstitial fibrosis. However, a few evidences point toward immunologic mechanism:

1. High levels of autoantibodies such as rheumatoid factor and antinuclear antibodies.
2. Elevated titres of circulating immune complexes.
3. Immunofluorescent demonstration of the deposits of immunoglobulins and complement on the alveolar walls in biopsy specimens.

G/A The lungs are firm, heavier with reduced volume. Honeycombing (i.e. enlarged, thick-walled air spaces) develops in parts of lung, particularly in the subpleural region.

M/E The changes vary according to the stage of the disease.

◆ **In early stage**, there is widening of the alveolar septa by oedema and cellular infiltrate by mononuclear inflammatory cells. The alveolar lining cells may show hyperplasia at places and are flattened at other places. There is often formation of hyaline membranes. The alveolar spaces contain exudate consisting of macrophages, lymphocytes and neutrophils. Many of the macrophages contain lamellar bodies derived from surfactant of the necrotic alveolar lining epithelial cells. Based on the observation of desquamative component in the cellular exudate, some authors label the early stage of idiopathic pulmonary fibrosis as '*desquamative interstitial pneumonitis*'.

◆ **In advanced stage**, there is organisation of the alveolar exudate and replacement fibrosis in the alveoli as well as in the interstitial septal wall with variable amount of inflammation. Eventually, there are small cystic areas (honeycomb lung) with alternating areas of fibrosis containing thick-walled and narrowed vessels. This stage is often referred to as '*chronic interstitial pneumonitis*' or '*usual interstitial pneumonitis*'.

CLINICAL FEATURES. Middle-aged males are affected more frequently. The usual features are of respiratory difficulty beginning with dry cough and slowly progressing dyspnoea. More advanced cases may develop clubbing of fingers and cor pulmonale. A rapidly progressive form of the idiopathic pulmonary fibrosis with death within 6 weeks to 6 months is termed Hamman-Rich syndrome.

ILD ASSOCIATED WITH SMOKING (p. 496)

Long-term consequences of smoking is associated with following non-neoplastic respiratory insufficiency:

- ◆ **Smoking-related COPD:** due to chronic bronchitis and emphysema.
- ◆ **Smoking-related ILD:** i.e. chronic restrictive pulmonary disease due to desquamative interstitial pneumonia (DIP), respiratory bronchiolitis-associated ILD, and pulmonary Langerhans cell histiocytosis (eosinophilic granuloma of the lung).

DESQUAMATIVE INTERSTITIAL PNEUMONIA (DIP). It is an uncommon condition occurring exclusively in smokers in 4th to 5th decades of life and is more common in males. Most patients present with dyspnoea and cough. Chest X-ray shows peculiar diffuse hazy opacities which characterize all ILDs. DIP was earlier thought to represent forerunner lesion in the sequence of development of idiopathic pulmonary fibrosis. However, DIP has minimal fibrosis and has a far better prognosis on cessation of smoking compared to idiopathic pulmonary fibrosis.

M/E

- i) Hallmark finding is collections of large number of intraalveolar macrophages having abundant cytoplasm and containing brown-black pigment and are termed as smokers' macrophages.
- ii) The intervening septa contain a few lymphocytes, plasma cells and an occasional eosinophil.
- iii) Late cases show mild interstitial fibrosis.

RESPIRATORY BRONCHIOLITIS-ASSOCIATED ILD. Respiratory bronchiolitis is a far more common lesion in chronic smokers than DIP and is considered a milder form of DIP having similar clinical presentation. Respiratory bronchiolitis-associated ILD is the term used for advanced cases who develop impaired pulmonary function and radiologic features.

M/E

- i) Patchy and bronchiolocentric location of similar smokers' macrophages as are seen in DIP.
- ii) Peribronchial infiltrate of lymphocytes and histiocytes.
- iii) There may be mild peribronchial fibrosis.
- iv) Centriacinar emphysema may coexist.

PULMONARY LANGERHANS CELL HISTIOCYTOSIS. This is an uncommon smoking-related ILD occurring in younger men (20-40 years). Clinically, the features may vary from an asymptomatic state to a rapidly progressive course. Symptomatic cases present with cough, dyspnoea, weight loss and fever.

M/E

- i) There is presence of poorly-defined nodules distributed in peribronchiolar location while intervening lung parenchyma is uninvolved.
- ii) Characteristically, these nodules are sclerosing and contain Langerhans cells along with other inflammatory cells.
- iii) Progressive cases have fibrosis with concomitant cystic change.

□ **TUMOURS OF LUNGS (p. 496)**

A number of benign and malignant tumours occur in the lungs but the primary lung cancer, commonly termed bronchogenic carcinoma, is the most common (95% of all primary lung tumours). The lung is also the commonest site for metastasis from carcinomas and sarcomas. A histologic classification of various benign and malignant tumours of lungs as recommended by the World Health Organisation is given in **Web Table 17.10**.

BRONCHOGENIC CARCINOMA (p. 496)

The term bronchogenic carcinoma is commonly used for cancer of the lungs which includes carcinomas arising from the respiratory epithelium lining the bronchi, bronchioles and alveoli.

414 INCIDENCE AND CLASSIFICATION. Lung cancer is the most common primary malignant tumour in men and accounts for nearly 30% of all cancer deaths in both sexes in developing countries. Currently, the incidence of lung cancer in females in the United States has already exceeded breast cancer as a cause of death in women. Cancer of the lung is a disease of middle and late life with peak incidence in 55-65 years of age, after which there is gradual fall in its incidence. Of late, there has been slight decline in lung cancer deaths in males due to smoking cessation efforts which started in the West 4 decades back and has started yielding results. However, worldwide the scene on its incidence and prognosis are quite grim.

There are 5 main histologic types of lung cancer:

- i) Squamous cell or epidermoid carcinoma
- ii) Small cell carcinoma
- iii) Adenocarcinoma (including bronchioalveolar carcinoma)
- iv) Large cell carcinoma
- v) Combined squamous cell carcinoma and adenocarcinoma (adenosquamous carcinoma).

As per reports on international data for the last 25 years, while there has been decline in the incidence of small cell carcinoma, incidence of adenocarcinoma of the lung has risen and has surpassed squamous cell carcinoma as the most frequent histologic subtype of lung cancer.

However, for therapeutic purposes, bronchogenic carcinoma can be classified into 3 groups:

1. Small cell carcinomas, SCC (20-25%)
2. Non-small cell carcinomas, NSCC (70-75%) (includes squamous cell carcinoma, adenocarcinoma, and large cell carcinoma)
3. Combined/mixed patterns (5-10%).

ETIOLOGY. The high incidence of lung cancer is associated with a number of etiologic factors, most important of which is *cigarette smoking*.

1. Smoking. The most important factor for high incidence of all forms of bronchogenic carcinoma is tobacco smoking. About 80% of the lung cancer occurs in active smokers. A number of evidences support the positive relationship of lung cancer with tobacco smoking:

i) Total dose: There is a direct statistical correlation between death rate from lung cancer and the total amount of cigarettes smoked e.g.

◆ An average regular smoker has 10 times greater risk of developing lung cancer than a non-smoker.

◆ The risk of smokers of more than 2 packs (40 cigarettes) per day for 20 years is 60-70 times greater than a non-smoker.

◆ Cessation of smoking by a regular smoker results in gradual decline in the chances of developing lung cancer. After 10 years of abstinence from smoking, the risk declines but never returns to the non-smoker level.

◆ Pipe and cigar smokers, though have higher risk than non-smokers but are at lesser risk than cigarette smokers.

ii) Histologic alterations: The association of tobacco smoking is strongest for squamous cell carcinoma and small cell carcinoma of the lung. More than 90% of smokers have sequential epithelial changes in the respiratory tract in the form of squamous metaplasia, dysplasia and carcinoma *in situ* (**Web Image 17.33**).

iii) Mechanism: How tobacco smoking causes lung cancer is not quite clear. However, following facts have been observed:

◆ Analysis of the tar from cigarette smoke has revealed a number of known carcinogens (e.g. polycyclic aromatic hydrocarbons, nitrosamines) and tumour promoters (e.g. phenol derivatives).

◆ In experimental animal studies, it has been possible to induce cancer by skin painting experiments with smoke-tar.

2. Other factors. Although smoking is the dominant etiologic factor in lung cancer, 15% cases of lung cancer occur in non-smokers, more so in women probably related to hormonal factors. A few other factors implicated in lung cancer are as follows: (i) Atmospheric pollution, (ii) Occupational causes, (iii) Dietary factors and (iv) Chronic scarring.

MOLECULAR PATHOGENESIS. Molecular studies have revealed that there are several genetic alterations in cancer stem cells which produce clones of malignant cells to form tumour mass. Following genetic changes have been found:

1. Activation of growth-promoting oncogenes: Mutation in *K-RAS* oncogene has been seen as the dominant change in lung cancer. Besides, there is mutation in tyrosine kinase domain of *EGFR* oncogene in cases of adenocarcinoma lung in non-smokers. Other mutations include *BRAF*, *PIK3CA* and *MYC* family, and overexpression of *bcl-2* and other antiapoptotic proteins.

2. Inactivation of tumour-suppressor genes. Inactivation of tumour suppressor genes has been found as another molecular mechanism in lung cancer. Many tumour suppressor genes have been found on chromosome 3p in lung cancer cases. These include inactivation of *p53* and *Rb* gene. Besides, some tumour-acquired promoter genes have been identified in lung cancer e.g. *p16*, *RASSF1A* etc, which cause loss of normal function of growth-regulatory tumour suppressor genes.

3. Autocrine growth factors. Studies have shown that lung cancer is a multistep process—initiator carcinogen causing mutation, followed by action of tumour promoters. Nicotine acts as both initiator as well as promoter carcinogen. Derivatives of nicotine in smoke unmask and expresses nicotine acetylcholine receptors which activate the signaling pathway in tumour, blocking the apoptosis.

4. Inherited predisposition. Although not common, but there are a few examples of inheritance of lung cancer as under:

- i) Patients of Li-Fraumeni syndrome who inherit *p53* mutation may develop lung cancer.
- ii) Clinical cases of retinoblastoma having mutation in *Rb* gene are predisposed to develop lung cancer if they live up to adulthood.
- iii) First-degree relatives of lung cancer patients have a 2-3 fold higher risk of developing lung cancer in their lifetime.
- iv) Mutations of cytochrome P450 system have been identified in lung cancer patients; P450 metabolises chemical carcinogen in tobacco smoke.

G/A

1. Hilar type (Web Image 17.34,A): Most commonly, the lung cancer arises in the main bronchus or one of its segmental branches in the hilar parts of the lung, more often on the right side. The tumour begins as a small roughened area on the bronchial mucosa at the bifurcation. As the tumour enlarges, it thickens the bronchial mucosa producing nodular or ulcerated surface. As the nodules coalesce, the carcinoma grows into a friable spherical mass, 1 to 5 cm in diameter, narrowing and occluding the lumen. The cut surface of the tumour is yellowish-white with foci of necrosis and haemorrhages which may produce cavitory lesions (**Web Table 17.11** sums up a list of common conditions having *pulmonary cavitory lesions* or 'honey-comb lung' during the course of different lung diseases).

2. Peripheral type (Web Image 17.34,B): A small proportion of lung cancers, chiefly adenocarcinomas including bronchioloalveolar carcinomas, originate from a small peripheral bronchiole but the exact site of origin may not be discernible. The tumour may be a single nodule or multiple nodules in the periphery of the lung producing pneumonia-like consolidation of a large part of the lung.

As per the WHO classification outlined in Web Table 17.10, five main histologic types of bronchogenic carcinoma are distinguished which is important because of prognostic and therapeutic considerations. However, from clinical point of view, distinction between small cell (SCC) and non-small cell carcinomas (NSCC) is important because the two not only differ in morphology, but there are major differences in immunophenotyping and response to treatment discussed above. The major differences between SCC and NSCC of the lung are summed up in **Web Table 17.12**.

1. Squamous cell (epidermoid) carcinoma: This has been the most common histologic subtype of bronchogenic carcinoma until recently and is found more commonly in men, often with history of tobacco smoking. These tumours usually arise in a large bronchus and are prone to massive necrosis and cavitation (**Web Image 17.35**). The tumour is diagnosed microscopically by identification of either intercellular bridges or keratinisation. The tumour may show varying histologic grades of differentiation such as well-differentiated, moderately-differentiated and poorly-differentiated (**Web Image 17.36**).

Usually the spread of squamous cell carcinoma is more rapid than the other histologic types of NSCC.

2. Small cell carcinoma: Small cell carcinomas are frequently hilar or central in location, have strong relationship to cigarette smoking and are highly malignant tumours. They are most often associated with ectopic hormone production because of the presence of neurosecretory granules in majority of tumour cells which are similar to those found in argentaffin or Kulchitsky cells normally found in bronchial epithelium. Small cell carcinomas have 3 subtypes:

i) *Oat cell carcinoma* is composed of uniform, small cells, larger than lymphocytes with dense, round or oval nuclei having diffuse chromatin, inconspicuous nucleoli and very sparse cytoplasm (*oat* = a form of grain). These cells are organised into cords, aggregates and ribbons or around small blood vessels forming pseudorosettes (**Web Image 17.37**).

ii) *Small cell carcinoma, intermediate cell type* is composed of cells slightly larger than those of oat cell carcinoma and have similar nuclear characteristics but have more abundant cytoplasm. These cells are organised into lobules.

iii) *Combined oat cell carcinoma* is a tumour in which there is a definite component of oat cell carcinoma with squamous cell and/or adenocarcinoma.

3. Adenocarcinoma: Adenocarcinoma, also called *peripheral carcinoma* due to its location and *scar carcinoma* due to its association with areas of chronic scarring, is the most common bronchogenic carcinoma in women and is slow-growing. Recent estimates on adenocarcinoma place this as the most frequent histologic subtype of lung cancer. Adenocarcinoma is further subclassified into 4 types:

i) *Acinar adenocarcinoma* which has predominance of glandular structure and often occurs in the larger bronchi.

ii) *Papillary adenocarcinoma* which has a pronounced papillary configuration and is frequently peripherally located in the lungs and is found in relation to pulmonary scars (scar carcinoma).

iii) *Bronchiolo-alveolar carcinoma* is characterised by cuboidal to tall columnar and mucus-secreting epithelial cells growing along the existing alveoli and forming numerous papillary structures (**Web Image 17.38**). Ultrastructurally, these tumour cells resemble Clara cells or less often type II pneumocytes.

iv) *Solid carcinoma* is a poorly-differentiated adenocarcinoma lacking acini, tubules or papillae but having mucus-containing vacuoles in many tumour cells.

4. Large cell carcinoma: These are undifferentiated carcinomas which lack the specific features by which they could be assigned into squamous

cell carcinoma or adenocarcinoma. Large cell carcinomas are more common in men, have strong association with cigarette smoking and are highly malignant tumours. The tumour cells have large nuclei, prominent nucleoli, abundant cytoplasm and well-defined cell borders.

5. Adenosquamous carcinoma: These are a small proportion of peripheral scar carcinomas having clear evidence of both keratinisation and glandular differentiation.

SPREAD. Bronchogenic carcinoma can invade the adjoining structures directly, or may spread by lymphatic and haematogenous routes.

1. Direct spread. The tumour extends directly by invading through the wall of the bronchus and destroys and replaces the peribronchial lung tissue. As it grows further, it spreads to the opposite bronchus and lung, into the pleural cavity, the pericardium and the myocardium and along the great vessels of the heart causing their constriction.

2. Lymphatic spread. Initially, hilar lymph nodes are affected. Later, lymphatic metastases occur to the other groups leading to spread to mediastinal, cervical, supraclavicular and para-aortic lymph nodes. Invasion of the thoracic duct may produce chylous ascites.

3. Haematogenous spread. Distant metastases via blood stream are widespread and early. The sites affected, in descending order of involvement, are: the liver, adrenals, bones, pancreas, brain, opposite lung, kidneys and thyroid.

CLINICAL FEATURES. Symptoms of lung cancer are quite variable and result from local effects, effects due to occlusion of a bronchus, direct and distant metastases, and paraneoplastic syndromes.

1. Local symptoms. Most common local complaints are cough, chest pain, dyspnoea and haemoptysis. (A list of various causes of haemoptysis is summed up in **Web Table 17.13**).

2. Bronchial obstructive symptoms. Occlusion of a bronchus may result in bronchopneumonia, lung abscess and bronchiectasis in the lung tissue distal to the site of obstruction and cause their attendant symptoms like fever, productive cough, pleural effusion and weight loss.

3. Symptoms due to metastases. Distant spread may produce varying features and sometimes these are the first manifestation of lung cancer. These include: superior vena caval syndrome, painful bony lesions, paralysis of recurrent nerve and other neurologic manifestations resulting from brain metastases.

4. Paraneoplastic syndromes. A number of paraneoplastic syndromes are associated with lung cancer. These include the following:

i) Ectopic hormone production e.g. (a) ACTH, producing Cushing's syndrome, (b) ADH, inducing hyponatraemia, (c) parathormone, causing hypercalcaemia, (d) calcitonin, producing hypocalcaemia, (e) gonadotropins, causing gynaecomastia and (f) serotonin, associated with carcinoid syndrome.

ii) Other systemic manifestations: These include the following: (a) *Neuromuscular*, (b) *Skeletal*, (c) *cutaneous*, (d) *cardiovascular* and (e) *haematologic*.

STAGING AND PROGNOSIS. The widely accepted clinical staging of lung cancer is according to the TNM classification, combining features of primary Tumours, Nodal involvement and distant Metastases. TNM staging divides all lung cancers into the following 4 stages:

Occult: Malignant cells in the bronchopulmonary secretions but no evidence of primary tumour or metastasis.

Stage I: Tumour less than 3 cm, with or without ipsilateral nodal involvement, no distant metastasis.

418 *Stage II:* Tumour larger than 3 cm, with ipsilateral hilar lymph node involvement, no distant metastasis.

Stage III: Tumour of any size, involving adjacent structures, involving contralateral lymph nodes or distant metastasis.

In general, tumour size larger than 5 cm has worse prognosis. *Small cell carcinoma has the worst prognosis* since surgical treatment is ineffective though the tumour is sensitive to radiotherapy and chemotherapy.

BRONCHIAL CARCINOID AND OTHER NEUROENDOCRINE TUMOURS (p. 503)

Neuroendocrine tumours of the lung represent a continuum spectrum of lung tumours with progressively increasing aggressiveness which include: typical carcinoid (*least aggressive*), atypical carcinoid, and large cell endocrine carcinoma, and also small cell carcinoma (*most aggressive*). All these tumours arise from neuroendocrine (Kulchitsky) cells of bronchial mucosa. Formerly, bronchial carcinoids used to be classified as 'bronchial adenomas' but now it is known that they are locally invasive and have the capacity to metastasise.

G/A Bronchial carcinoids most commonly arise from a major bronchus and project into the bronchial lumen as a spherical polypoid mass, 3-4 cm in diameter. Less commonly, the tumour may grow into the bronchial wall and produce collar-button like lesion. The overlying bronchial mucosa is usually intact. Cut surface of the tumour is yellow-tan in colour.

M/E The tumour is composed of uniform cuboidal cells forming aggregates, trabeculae or ribbons separated by fine fibrous septa. The tumour cells have abundant, finely granular cytoplasm and oval central nuclei with clumped nuclear chromatin. Mitoses are rare and necrosis is uncommon (**Web Image 17.39**). The secretory granules of bronchial carcinoids resemble those of other foregut carcinoids and stain positively with argyrophilic stains in which exogenous reducing agent is added for the reaction. Immunohistochemically, markers for neuroendocrine stain positive and include NSE, chromogranin, synaptophysin and neurofilaments.

CLINICAL FEATURES. Bronchial carcinoids occur at a relatively early age and have equal sex incidence. Most of the symptoms in bronchial carcinoids occur as a result of bronchial obstruction such as cough, haemoptysis, atelectasis and secondary infection. About 5-10% of bronchial carcinoids metastasise to the liver and these cases are capable of producing carcinoid syndrome.

HAMARTOMA (p. 503)

Hamartoma is a tumour-like lesion composed of an abnormal admixture of pulmonary tissue components and is discovered incidentally as a coin-lesion in the chest-X-ray. Pulmonary hamartomas are of 2 types: chondromatous and leiomyomatous.

- ◆ Chondromatous hamartoma
- ◆ Leiomyomatous hamartoma.

METASTATIC LUNG TUMOURS (p. 504)

Secondary tumours of the lungs are more common than the primary pulmonary tumours. Metastases from carcinomas as well as sarcomas arising from anywhere in the body may spread to the lung by haematogenous or lymphatic routes, or by direct extension. Blood-borne metastases are the most common since emboli of tumour cells from any malignant tumour entering the systemic venous circulation are likely to be lodged in the lungs. Metastases are most common in the peripheral part of the lung forming single or multiple, discrete nodular lesions which appear radiologically as '*cannon-ball secondaries*' (**Web Image 17.40**).

Most common sources of metastases in the lungs are: carcinomas of the bowel, breast, thyroid, kidney, pancreas, lung (ipsilateral or contralateral) and liver. Other tumours which frequently metastasise to the lungs are osteogenic sarcoma, neuroblastoma, Wilms' tumour, melanoma, lymphomas and leukaemias.

□ **NORMAL STRUCTURE** (p. 504)

Visceral pleura covers the lungs and extends into the fissures while the parietal pleura limits the mediastinum and covers the dome of the diaphragm and inner aspect of the chest wall. The two layers between them enclose pleural cavity which contains less than 15 ml of clear serous fluid.

M/E Both the pleural layers are lined by a single layer of flattened mesothelial cells facing each other. Underneath the lining cells is a thin layer of connective tissue.

□ **INFLAMMATIONS** (p. 504)

Inflammatory involvement of the pleura is commonly termed *pleuritis* or *pleurisy*.

1. SEROUS, FIBRINOUS AND SEROFIBRINOUS PLEURITIS. Acute inflammation of the pleural sac (acute pleuritis) can result in serous, serofibrinous and fibrinous exudate. Most of the causes of such pleuritis are infective in origin, particularly within the lungs, such as tuberculosis, pneumonias, pulmonary infarcts, lung abscess and bronchiectasis. Other causes include a few collagen diseases (e.g. rheumatoid arthritis and disseminated lupus erythematosus), uraemia, metastatic involvement of the pleura, irradiation of lung tumours and diffuse systemic infections (e.g. typhoid fever, tularaemia, blastomycosis and coccidioidomycosis).

2. SUPPURATIVE PLEURITIS (EMPYEMA THORACIS). Bacterial or mycotic infection of the pleural cavity that converts a serofibrinous effusion into purulent exudate is termed suppurative pleuritis or empyema thoracis. The most common cause is direct spread of pyogenic infection from the lung. Other causes are direct extension from subdiaphragmatic abscess or liver abscess and penetrating injuries to the chest wall. Occasionally, the spread may occur by haematogenous or lymphatic routes.

3. HAEMORRHAGIC PLEURITIS. Haemorrhagic pleuritis differs from haemothorax in having inflammatory cells or exfoliated tumour cells in the exudate. The causes of haemorrhagic pleuritis are metastatic involvement of the pleura, bleeding disorders and rickettsial diseases.

□ **NON-INFLAMMATORY PLEURAL EFFUSIONS** (p. 505)

1. HYDROTHORAX. Hydrothorax is non-inflammatory accumulation of serous fluid within the pleural cavities. Hydrothorax may be unilateral or bilateral depending upon the underlying cause. Occasionally, an effusion is limited to part of a pleural cavity by preexisting pleural adhesions.

The most common cause of hydrothorax, often bilateral, is congestive heart failure. Other causes are renal failure, cirrhosis of liver, Meig's syndrome, pulmonary oedema and primary and secondary tumours of the lungs.

The non-inflammatory serous effusion in hydrothorax is clear and straw-coloured and has the characteristics of transudate with a specific gravity of under 1.012, protein content below 1 gm/dl and little cellular content.

2. HAEMOTHORAX. Accumulation of pure blood in the pleural cavity is termed as haemothorax. The most common causes of haemothorax are trauma to the chest wall or to the thoracic viscera and rupture of aortic aneurysm.

420 3. CHYLOTHORAX. Chylothorax is an uncommon condition in which there is accumulation of milky fluid of lymphatic origin into the pleural cavity. Chylothorax results most commonly from rupture of the thoracic duct by trauma or obstruction of the thoracic duct such as by malignant tumours, most often malignant lymphomas.

PNEUMOTHORAX (p. 505)

An accumulation of air in the pleural cavity is called pneumothorax. It may occur in one of the three circumstances:

i) Spontaneous pneumothorax occurs due to spontaneous rupture of alveoli in any form of pulmonary disease. Most commonly, spontaneous pneumothorax occurs in association with emphysema, asthma and tuberculosis. Other causes include chronic bronchitis in an old patient, bronchiectasis, pulmonary infarction and bronchial cancer.

ii) Traumatic pneumothorax is caused by trauma to the chest wall or lungs, ruptured oesophagus or stomach, and surgical operations of the thorax.

iii) Therapeutic (artificial) pneumothorax used to be employed formerly in the treatment of chronic pulmonary tuberculosis in which air was introduced into the pleural sac so as to collapse the lung and limit its respiratory movements.

TUMOURS OF PLEURA (p. 505)

Pleural tumours may be primary or secondary. In line with pulmonary tumours, the secondary tumours in the pleura are more common.

MESOTHELIOMA (p. 505)

Mesothelioma is an uncommon tumour arising from mesothelial lining of serous cavities, most often in pleural cavity, and rarely in peritoneal cavity and pericardial sac. Mesotheliomas are of 2 types—*benign (solitary) and malignant (diffuse)*. The biologic behaviour of pleural mesotheliomas is usually predicted by their gross appearance—those forming solitary, discrete masses are generally benign, whereas those which grow diffusely are usually malignant.

Benign (Solitary) Mesothelioma (p. 505)

Benign or solitary mesothelioma is also called as pleural fibroma. *Asbestos exposure plays no role in etiology of benign mesothelioma.*

G/A It consists of a solitary, circumscribed, small, firm mass, generally less than 3 cm in diameter. Cut surface shows whorls of dense fibrous tissue.

M/E The tumour is predominantly composed of whorls of collagen fibres and reticulin with interspersed fibroblasts. Rarely, mesothelial-lined clefts are seen in the tumour.

Malignant (Diffuse) Mesothelioma (p. 506)

Malignant or diffuse mesothelioma is rare. It is a highly malignant tumour associated with high mortality. The tumour is significant in view of its *recognised association with occupational exposure to asbestos* (particularly crocidolite) for a number of years, usually 20 to 40 years. About 90% of malignant mesotheliomas are asbestos-related. Mechanism of carcinogenicity by asbestos is not quite clear but it appears that prolonged exposure of amphibole type of asbestos is capable of inducing oncogenic mutation in the mesothelium. However, prolonged asbestos-exposure is considered more significant rather than heavy exposure as documented by occurrence of malignant mesothelioma in the family members of asbestos workers.

Although combination of cigarette smoking and asbestos exposure greatly increases risk to develop bronchogenic carcinoma, there is no such extra increased risk of developing mesothelioma in asbestos workers who smoke.

G/A The tumour is characteristically diffuse, forming a thick, white, fleshy coating over the parietal and visceral surfaces (**Web Image 17.41**).

M/E Malignant mesothelioma may have epithelial, sarcomatoid or biphasic patterns.

i) Epithelial pattern resembles an adenocarcinoma, consisting of tubular and tubulo-papillary formations.

ii) Sarcomatoid pattern consists of spindle cell sarcoma resembling fibrosarcoma.

iii) Biphasic pattern shows mixed growth having epithelial as well as sarcomatoid pattern. Usually, there are slit-like or gland-like spaces lined by neoplastic mesothelial cells separated by proliferating spindle-shaped tumour cells (**Web Image 17.42**).

SECONDARY PLEURAL TUMOURS (p. 506)

Metastatic malignancies in the pleura are more common than the primary tumours and appear as small nodules scattered over the lung surface. The most frequent primary malignant tumours metastasising to the pleura are of the lung and breast through lymphatics, and ovarian cancers via haematogenous route.

◆ SELF ASSESSMENT

- Source of pulmonary surfactant is:**
 - Alveolar macrophages
 - Type I pneumocytes
 - Type II pneumocytes
 - Capillary basement membrane
- The basic defect in neonatal hyaline membrane disease is:**
 - Shock due to sepsis
 - Deficient production of surfactant
 - Inhalation of toxins
 - Aspiration pneumonitis
- Adult respiratory distress syndrome occurs from the following causes except:**
 - Pancreatitis
 - Oxygen toxicity
 - Deficiency of surfactant
 - Diffuse pulmonary infections
- Primary atelectasis is defined as:**
 - Incomplete expansion of a previously unexpanded lung
 - Reduction in size of a previously expanded lung due to compression
 - Reduction in size of a lung due to obstruction
 - Reduction in lung size due to contraction
- Pulmonary hypertension is defined as systolic blood pressure in the pulmonary arterial circulation above the following cut off figure:**

A. 120 mmHg	B. 90 mmHg
C. 60 mmHg	D. 30 mmHg
- Bronchopneumonia is grossly characterised by:**
 - Diffuse consolidation of a lobe or lobes of one or both lungs
 - Diffuse consolidation of a lobe of one lung
 - Diffuse consolidation of a lobe of both lungs
 - Patchy consolidation of a lobe or lobes of one or both lungs

7. The most common causative organism for lobar pneumonia is:
 - A. Staphylococci
 - B. Streptococci
 - C. Pneumococci
 - D. Haemophilus
8. Viral pneumonias are characterised by the following features **except**:
 - A. Presence of interstitial inflammation
 - B. Presence of alveolar exudate
 - C. Necrotising bronchiolitis
 - D. Multinucleate giant cells in the bronchiolar wall
9. The organism in *Pneumocystis carinii* pneumonia is:
 - A. Mycoplasma
 - B. Fungus
 - C. Protozoa
 - D. Chlamydia
10. Lung abscess secondary to aspiration pneumonia develops more often in:
 - A. Lower lobe of right lung
 - B. Lower lobe of left lung
 - C. Upper lobe of either lung
 - D. Middle lobe of right lung
11. Reid index used as a criteria of quantitation in chronic bronchitis is the ratio of thickness of:
 - A. Bronchial mucosa to that of bronchial wall
 - B. Submucosal glands to that of bronchial wall
 - C. Bronchial cartilage to that of bronchial wall
 - D. Inflammatory infiltrate to that of bronchial wall
12. The most fibrogenic dust in pneumoconiosis is:
 - A. Coal
 - B. Asbestos
 - C. Silica
 - D. Beryllium
13. Classic α -1 antitrypsin deficiency in emphysema has the following phenotype of protease inhibitor:
 - A. PiMM
 - B. PiZZ
 - C. PiMZ
 - D. PiMO
14. The extent of damage to pulmonary parenchyma is severest in the following type of emphysema:
 - A. Centriacinar
 - B. Panacinar
 - C. Distal acinar
 - D. Irregular
15. Emphysema associated most often with α 1 antitrypsin deficiency is:
 - A. Panacinar
 - B. Centriacinar
 - C. Distal acinar
 - D. Irregular
16. Serum IgE levels are elevated in:
 - A. Intrinsic bronchial asthma
 - B. Extrinsic bronchial asthma
 - C. Predominant chronic bronchitis
 - D. Predominant emphysema
17. Bronchiectasis commonly develops in the following microanatomic zone of bronchial tree:
 - A. Acini beyond respiratory bronchioles
 - B. Acini beyond terminal bronchioles
 - C. Terminal bronchioles less than 2 mm diameter
 - D. Bronchioles more than 2 mm diameter
18. Restrictive lung disease is characterised by the following features **except**:
 - A. Dyspnoea
 - B. Tachypnoea
 - C. Cyanosis
 - D. Wheezing
19. Inhaled dust particles of the following size are generally eliminated by expectoration:
 - A. Smaller than 1 μ m
 - B. 1-3 μ m
 - C. 3-5 μ m
 - D. Larger than 5 μ m
20. Bronchogenic carcinoma has increased incidence in the following pneumoconiosis:
 - A. Coal workers' pneumoconiosis
 - B. Silicosis
 - C. Asbestosis
 - D. Berylliosis

21. **Silicosis occurs in following occupational exposure except:**
 - A. Ceramic workers
 - B. Foundry workers
 - C. Textile workers
 - D. Construction workers
22. **Out of various forms of asbestos, the following type is implicated in etiology of malignant pleural tumour:**
 - A. Chrysotile
 - B. Crocidolite
 - C. Amosite
 - D. Anthophyllite
23. **Caplan's syndrome may develop in the following types of pneumoconiosis except:**
 - A. Coal-workers' pneumoconiosis
 - B. Asbestosis
 - C. Berylliosis
 - D. Silicosis
24. **Non-caseating sarcoid-like epithelioid cell granulomas are seen in:**
 - A. Silicosis
 - B. Asbestosis
 - C. Coal-workers' pneumoconiosis
 - D. Chronic berylliosis
25. **The following histologic types of bronchogenic carcinoma have strong association with cigarette smoking except:**
 - A. Squamous cell carcinoma
 - B. Small cell carcinoma
 - C. Large cell carcinoma
 - D. Adenocarcinoma
26. **The following type of bronchogenic carcinoma has worst prognosis:**
 - A. Squamous cell carcinoma
 - B. Small cell carcinoma
 - C. Large cell carcinoma
 - D. Adenocarcinoma
27. **Bronchial carcinoid arises from:**
 - A. Columnar ciliated epithelium
 - B. Goblet cells
 - C. Kulchitsky cells
 - D. Alveolar lining cells
28. **The following tumour does not have association with occupational exposure to asbestos:**
 - A. Benign mesothelioma
 - B. Malignant mesothelioma
 - C. Bronchogenic carcinoma
 - D. Laryngeal carcinoma
29. **Macrophage-derived fibrogenic cytokine is:**
 - A. IL-1
 - B. IL-8
 - C. TNF
 - D. TGF α
30. **The most important mutation in small cell carcinoma is in the following gene:**
 - A. *RB* gene
 - B. *MYC* gene
 - C. *CDK* gene
 - D. *RAS* gene
31. **Hamman-Rich syndrome is:**
 - A. Bronchopulmonary dysplasia
 - B. Desquamative interstitial pneumonia
 - C. Diffuse fibrosing alveolitis
 - D. ARDS
32. **Most common etiologic factor implicated in chronic bronchitis is:**
 - A. Atmospheric pollution
 - B. Cotton mills
 - C. Mycoplasma infection
 - D. Cigarette smoking
33. **Which type of asthma occurs in late adult life:**
 - A. Atopic asthma
 - B. Intrinsic asthma
 - C. Mixed asthma
 - D. Allergic asthma
34. **Asbestos exposure results in all of the following changes except:**
 - A. Interstitial pneumonia
 - B. Pleural effusion
 - C. Malignant mesothelioma
 - D. Pleural fibrosis
35. **All are types of allergic pneumonitis except:**
 - A. Bagassosis
 - B. Byssinosis
 - C. Berylliosis
 - D. Farmer's lung
36. **Which of the following mutation is being used to develop targeted molecular therapy in non-small cell cancer of lung:**
 - A. EGFR mutation
 - B. p53 mutation
 - C. K-RAS mutation
 - D. p16 mutation

KEY

1 = C	2 = B	3 = C	4 = A
5 = D	6 = D	7 = C	8 = B
9 = C	10 = A	11 = B	12 = C
13 = B	14 = B	15 = A	16 = B
17 = D	18 = D	19 = D	20 = C
21 = C	22 = B	23 = C	24 = D
25 = D	26 = B	27 = C	28 = A
29 = D	30 = A	31 = C	32 = D
33 = B	34 = A	35 = C	36 = A



The Eye, ENT and Neck

□ NORMAL STRUCTURE (p. 507)

The structure of the eye is shown diagrammatically in **Web Image 18.1**. The *eyelids* are covered externally by the skin and internally by *conjunctiva* which is reflected over the globe of the eye. The *lacrimal glands* which are compound racemose glands are situated at the outer upper angle of the orbit. The *globe of the eye* is composed of 3 layers: the cornea-sclera, choroid-iris, and retina.

The **uveal tract** consists of 3 parts—the choroid and ciliary body posteriorly, and the iris anteriorly.

The **retina** is part of the central nervous system and corresponds in extent to the choroid which it lines internally. The retina is composed of a number of layers of cells and their synapses which are of 3 types—external photoreceptor cells (rods and cones), intermediate relay layer of bipolar cells, and internal layer of ganglion cells with their axons running into the central nervous system.

The **lens** is the biconvex mass of laminated transparent tissue with elastic capsule.

The **anterior chamber** is the space filled with the aqueous humour, and is bounded by the cornea in front and the iris behind, with anterior surface of the lens exposed in the pupil.

The **posterior chamber** containing aqueous humour is the triangular space between the back of the iris, the anterior surface of the lens and ciliary body forming its apex at the pupillary margin.

The **vitreous chamber** is the large space behind the lens containing gelatinous material, the vitreous humour.

CONGENITAL LESIONS (p. 507)

RETROLENTAL FIBROPLASIA (RETINOPATHY OF PREMATUREITY).

This is a developmental disorder occurring in premature infants who have been given oxygen-therapy at birth. The basic defect lies in the developmental prematurity of the retinal blood vessels which are extremely sensitive to high dose of oxygen-therapy. The peripheral retina is incompletely vascularised in such infants and exposure to oxygen results in vaso-obliteration.

RETINITIS PIGMENTOSA. Retinitis pigmentosa is a group of systemic and ocular diseases of unknown etiology, characterised by degeneration of the retinal pigment epithelium. The condition can have various inheritance patterns—autosomal dominant, autosomal recessive trait, or sex-linked recessive trait.

M/E There is disappearance of rods and cones of the photoreceptor layer of the retina, degeneration of retinal pigment epithelium and ingrowth of glial membrane on the optic disc.

□ INFLAMMATORY CONDITIONS (p. 508)

'Uveitis' is the commonly used term for the ocular inflammation of the uveal tract which is the most vascular tissue of the eye. However, specific designation is used for the type of tissue of eye inflamed.

426 STYE (HORDEOLUM). Stye or 'external hordeolum' is an acute suppurative inflammation of the sebaceous glands of Zeis, the apocrine glands of Moll and the eyelash follicles.

CHALAZION. Chalazion is a very common lesion and is the chronic inflammatory process involving the meibomian glands. It occurs as a result of obstruction to the drainage of secretions.

M/E The chalazion gives the appearance of a chronic inflammatory granuloma located in the tarsus and contains fat globules in the centre of the granulomas i.e. appearance of a lipogranuloma (**Web Image 18.2**).

ENDOPHTHALMITIS. Endophthalmitis is an acute suppurative intraocular inflammation which may be of exogenous or endogenous origin. The exogenous agents may be bacteria, viruses or fungi introduced into the eye during an accidental or surgical perforating wound. The endogenous agents include opportunistic infections which may cause endophthalmitis via haematogenous route e.g. candidiasis, toxoplasmosis, nocardiosis, aspergillosis and cryptococcosis.

CONJUNCTIVITIS AND KERATOCONJUNCTIVITIS. Conjunctiva and cornea are constantly exposed to various types of physical, chemical, microbial (bacteria, fungi, viruses) and allergic agents and hence prone to develop acute, subacute and chronic inflammations. In the acute stage, there is corneal oedema and infiltration by inflammatory cells, affecting the transparency of the cornea. In the more chronic form of inflammation, there is proliferation of small blood vessels in the normally avascular cornea and infiltration by lymphocytes and plasma cells (pannus formation).

TRACHOMA AND INCLUSION CONJUNCTIVITIS. Both these conditions are caused by *Chlamydia* or TRIC agents. Trachoma is caused by *C. trachomatis* while inclusion conjunctivitis is caused by *C. oculogenitalis*. Trachoma is widely prevalent in the underdeveloped and developing countries of the world and is responsible for blindness on a large scale. Later, the conjunctiva thickens due to dense chronic inflammatory cell infiltrate along with lymphoid follicles and macrophages. The end-result is extensive corneal and conjunctival cicatrization accounting for blindness in trachoma.

GRANULOMATOUS UVEITIS. A number of chronic granulomatous conditions may cause granulomatous uveitis. These include bacteria (e.g. tuberculosis, leprosy, syphilis), viruses (e.g. CMV disease, herpes zoster), fungi (e.g. aspergillosis, blastomycosis, phycomycosis, histoplasmosis), and certain parasites (e.g. toxoplasmosis, onchocerciasis). Granulomatous uveitis is common in sarcoidosis as well.

SYMPATHETIC OPHTHALMIA (SYMPATHETIC UVEITIS). This is an uncommon condition in which there is bilateral diffuse granulomatous uveitis following penetrating injury to one eye. The condition probably results from an autosensitivity reaction to injured uveal tissue.

M/E There is granulomatous uveal inflammation consisting of epithelioid cells and lymphocytes affecting both the eyes. There is no necrosis and no neutrophilic or plasma cell infiltration. If lens is also injured, it results in phacoanaphylactic endophthalmitis.

□ **VASCULAR LESIONS** (p. 508)

DIABETIC RETINOPATHY. Diabetic retinopathy is an important cause of blindness. It is related to the degree and duration of glycaemic control. The condition develops in more than 60% of diabetics 15-20 years after the onset of disease, and in about 2% of diabetics causes blindness. Other ocular complications of diabetes include glaucoma, cataract and corneal disease. Most cases of diabetic retinopathy occur over the age of 50 years. The risk is greater in type 1 diabetes mellitus than in type 2 diabetes mellitus,

although in clinical practice there are more patients of diabetic retinopathy due to type 2 diabetes mellitus because of its higher prevalence. Women are more prone to diabetes as well as diabetic retinopathy. Diabetic retinopathy is directly correlated with Kimmelstiel-Wilson nephropathy.

M/E Two types of changes are described in diabetic retinopathy.

1. Background (non-proliferative) retinopathy. This is the initial retinal capillary microangiopathy. The following changes are seen:

- i) Basement membrane shows varying thickness due to increased synthesis of basement membrane substance.
- ii) Degeneration of pericytes and some loss of endothelial cells are found.
- iii) Capillary microaneurysms appear which may develop thrombi and get occluded.
- iv) 'Waxy exudates' accumulate in the vicinity of microaneurysms especially in the elderly diabetics because of hyperlipidaemia.
- v) 'Dot and blot haemorrhages' in the deeper layers of retina are produced due to diapedesis of erythrocytes.
- vi) Soft 'cotton-wool spots' appear on the retina which are microinfarcts of nerve fibre layers. 'Scotomas' appear from degeneration of nerve fibres and ganglion cells.

2. Proliferative retinopathy (retinitis proliferans). After many years, retinopathy becomes proliferative. Severe ischaemia and chronic hypoxia for long period leads to secretion of angiogenic factor by retinal cells and results in the following changes:

- i) Neovascularisation of the retina at the optic disc.
- ii) Friability of newly-formed blood vessels causes them to bleed easily and results in vitreous haemorrhages.
- iii) Proliferation of astrocytes and fibrous tissue around the new blood vessels.
- iv) Fibrovascular and gliotic tissue contracts to cause retinal detachment and blindness.

The pathogenesis of blindness in diabetes mellitus is schematically outlined in **Web Image 18.3**.

HYPERTENSIVE RETINOPATHY. In hypertensive retinopathy, the retinal arterioles are reduced in their diameter leading to retinal ischaemia. In acute severe hypertension as happens at the onset of malignant hypertension and in toxemia of pregnancy, the vascular changes are in the form of spasms, while in chronic hypertension the changes are diffuse in the form of onion-skin thickening of the arteriolar walls with narrowing of the lumina.

Features of hypertensive retinopathy include the following (**Web Image 18.4**):

- i) Variable degree of arteriolar narrowing due to arteriosclerosis.
- ii) 'Flame-shaped' haemorrhages in the retinal nerve fibre layer.
- iii) Macular star i.e. exudates radiating from the centre of macula.
- iv) Cotton-wool spots i.e. fluffy white bodies in the superficial layer of retina.
- v) Microaneurysms.
- vi) Arteriovenous nicking i.e. kinking of veins at sites where sclerotic arterioles cross veins.
- vii) Hard exudates due to leakage of lipid and fluid into macula.

Hypertensive retinopathy is classified according to the severity of above lesions from grade I to IV. More serious and severe changes with poor prognosis occur in higher grades of hypertensive retinopathy. Malignant hypertension is characterised by necrotising arteriolitis and fibrinoid necrosis of retinal arterioles.

RETINAL INFARCTS. Infarcts of the retina may result from thrombosis or embolism in central artery of the retina, causing ischaemic necrosis of the inner two-third of the retina while occlusion of the posterior ciliary arteries causes ischaemia of the inner photoreceptor layer only. The usual causes of thrombosis and embolism are atherosclerosis, hypertension and diabetes.

PINGUECULA AND PTERYGIUM. Pterygium is a degenerative condition of the collagen of the bulbar conjunctiva. Clinically, the condition appears as raised yellowish lesions on the interpalpebral bulbar conjunctiva of both eyes in middle-aged and elderly patients.

M/E There is characteristic basophilic degeneration of the subepithelial collagen of the conjunctiva.

Pterygium is a lesion closely related to pinguecula but differs from the latter by being located at the limbus and often involves the cornea; hence the lesion is more important clinically.

SENILE MACULAR DEGENERATION. Age-related degeneration of the macular region of the retina is an important cause of bilateral central visual loss in the elderly people.

M/E In the early stage, there is irregular thickening of the Bruch's membrane that separates retinal pigment epithelium from the choroid, and there is degeneration of the photoreceptor and pigment epithelium. Later, there is ingrowth of capillaries into the choroid, exudation and haemorrhage under the retina which may eventually get organised and heal by fibrosis.

RETINAL DETACHMENT. Retinal detachment is the separation of the neurosensory retina from the retinal pigment epithelium. It may occur spontaneously in older individuals past 50 years of age, or may be secondary to trauma in the region of head and neck. There are 3 pathogenetic mechanisms of retinal detachment:

- i) Pathologic processes in the vitreous or anterior segment, causing traction on the retina.
- ii) Collection of serous fluid in the sub-retinal space from inflammation or tumour in the choroid.
- iii) Accumulation of vitreous under the retina through a hole or a tear in the retina.

PHTHISIS BULBI. Phthisis bulbi is the end-stage of advanced degeneration and disorganisation of the entire eyeball in which the intraocular pressure is decreased and the eyeball shrinks. The causes of such end-stage blind eye are trauma, glaucoma and intraocular inflammations.

M/E There is marked atrophy and disorganisation of all the ocular structures, and markedly thickened sclera. Even osseous metaplasia may occur.

CATARACT. The cataract is the opacification of the normally crystalline lens which leads to gradual painless blurring of vision. The various causes of cataract are: senility, congenital (e.g. Down syndrome, rubella, galactosaemia), traumatic (e.g. penetrating injury, electrical injury), metabolic (e.g. diabetes, hypoparathyroidism), and associated with drugs (e.g. long-term corticosteroid therapy), smoking and heavy alcohol consumption. The most common is, however, idiopathic senile cataract.

GLAUCOMA. Glaucoma is a group of ocular disorders that have in common increased intraocular pressure. Glaucoma is one of the leading causes of blindness because of the ocular tissue damage produced by raised intraocular pressure. In almost all cases, glaucoma occurs due to impaired outflow of aqueous humour, though there is a theoretical possibility of increased production of aqueous by the ciliary body causing glaucoma. The obstruction to the aqueous flow may occur as a result of developmental malformations (**congenital glaucoma**); or due to complications of some other diseases such as uveitis, trauma, intraocular haemorrhage and tumours (**secondary glaucoma**); or may be **primary glaucoma** which is typically bilateral and is the most common type.

In all types of glaucoma, degenerative changes appear after some duration and eventually damage to the optic nerve and retina occurs.

PAPILLOEDEMA. Papilloedema is oedema of the optic disc resulting from increased intracranial pressure. This is due to anatomic continuation of the subarachnoid space of the brain around the optic nerve so that raised intracranial pressure is passed onto the optic disc area. In *acute papilloedema*, there is oedema, congestion and haemorrhage at the optic disc. In *chronic papilloedema*, there is degeneration of nerve fibres, gliosis and optic atrophy.

SJÖGREN'S SYNDROME. Sjögren's syndrome is characterised by triad of keratoconjunctivitis sicca, xerostomia (sicca syndrome) and rheumatoid arthritis. The condition occurs due to immunologically-mediated destruction of the lacrimal and salivary glands.

MIKULICZ'S SYNDROME. This is characterised by inflammatory enlargement of lacrimal and salivary glands. The condition may occur with Sjögren's syndrome, or with some diseases like sarcoidosis, leukaemia, lymphoma and macroglobulinaemia.

□ **TUMOURS AND TUMOUR-LIKE LESIONS** (p. 511)

The eye and its adnexal structures are the site of a variety of benign and malignant tumours as well as tumour-like lesions. A brief list of such lesions is given in **Web Table 18.1**.

INFLAMMATORY PSEUDOTUMOURS (p. 511)

These are a group of inflammatory enlargements, especially in the orbit, which clinically look like tumours but surgical exploration and pathologic examination fail to reveal any evidence of neoplasm.

G/A These lesions are circumscribed and sometimes have fibrous capsule.

M/E Many of the lesions can be placed in well-established categories such as tuberculous, syphilitic, mycotic, parasitic, foreign-body granuloma etc, while others show non-specific histologic appearance having abundant fibrous tissue, lymphoid follicles and inflammatory infiltrate with prominence of eosinophils.

SEBACEOUS CARCINOMA (p. 511)

This is the *most frequent tumour of the eyelid* next only to basal cell carcinoma, although it is very rare tumour elsewhere in the body. It arises either from the meibomian glands in the tarsus or from Zeis' glands of eyelash follicles. The tumour is seen more commonly in the upper eyelid (basal cell carcinoma is seen more frequently in the lower eyelid).

G/A The tumour appears as a localised or diffuse swelling of the tarsus, or may be in the form of ulcerated or papillomatous tumour at the lid margin.

M/E The tumour may show well-differentiated lobules of tumour cells with sebaceous differentiation, or may be poorly-differentiated tumour requiring confirmation by fat stains (**Web Image 18.5**). These tumours can metastasise to the regional lymph nodes as well as to distant sites.

UVEAL MALIGNANT MELANOMA (p. 512)

Malignant melanomas arising from neural crest-derived pigment epithelium of the uvea is the most common primary ocular malignancy in the white adults in North America and Europe.

G/A The malignant melanoma appears as a pigmented mass, most commonly in the posterior choroid, and less often in the ciliary body and iris. The mass projects into the vitreous cavity with retina covering it (**Web Image 18.6**).

M/E Age-old classification of Callender (1931) which has prognostic significance is still followed with some modifications:

430 1. Spindle A melanoma is composed of uniform, spindle-shaped cells containing spindled nuclei. Nucleoli are indistinct and mitotic figures are rare. Tumours of this type have the most favourable prognosis (85% 10-year survival).

2. Spindle B melanoma is composed of larger and plump spindle-shaped cells with ovoid nuclei. Nucleoli are conspicuous and a few mitotic figures are present. These tumours carry slightly worse prognosis (80% 10-year survival).

3. Epithelioid melanoma consists of larger, irregular and pleomorphic cells with larger nuclei and abundant acidophilic cytoplasm (**Web Image 18.7**). These tumours are the most malignant of the uveal melanomas and have poor prognosis (35% 10-year survival).

4. Mixed cell type melanomas have features of spindle cell type as well as of epithelioid cell type. These are more common tumours and carry an intermediate prognosis (45% 10-year survival).

In general, uveal malignant melanomas are usually slow-growing, late metastasising and have a better prognosis than malignant melanoma of the skin. Uveal melanomas spread via haematogenous route and liver is eventually involved in 90% of cases. Various indicators of bad prognosis include large tumour size and epithelioid cell type.

RETINOBLASTOMA (p. 512)

This is the most common malignant ocular tumour in children. It may be present at birth or recognised in early childhood before the age of 4 years. Retinoblastoma has some peculiar features. About 60% cases of retinoblastoma are sporadic and the remaining 40% are familial. Familial tumours are often multiple and multifocal and transmitted as an autosomal dominant trait by retinoblastoma susceptibility gene (*RB*) located on chromosome 13. Such individuals have a higher incidence of bilateral tumours and have increased risk of developing second primary tumour, particularly osteogenic sarcoma.

G/A The tumour characteristically appears as a white mass within the retina which may be partly solid and partly necrotic. The tumour may be *endophytic* when it protrudes into the vitreous, or *exophytic* when it grows between the retina and the pigment epithelium (**Web Image 18.8**).

M/E The tumour is composed of undifferentiated retinal cells with tendency towards formation of photo-receptor elements. In the better differentiated area, the tumour cells are characteristically arranged in rosettes. The rosettes may be of 2 types—*Flexner-Wintersteiner rosettes* characterised by small tumour cells arranged around a lumen with their nuclei away from the lumen, and *Homer-Wright rosettes* having radial arrangement of tumour cells around the central neurofibrillar structure (**Web Image 18.9**).

Salient features of retinoblastoma are contrasted with those of uveal melanoma in **Web Table 18.2**.

METASTATIC TUMOURS (p. 513)

Ocular metastatic tumours are far more common than primary ocular malignant tumours, choroid and iris being the preferential site for metastasis. Common primary tumours that metastasise in the eye are cancers of the breast in women and lung in men. Leukaemia and malignant lymphoma also commonly invade ocular tissues.

NORMAL STRUCTURE (p. 513)

The ear is divided into 3 parts—the external, middle and inner ear.

The **external ear** comprises the auricle or pinna composed of cartilage, the external cartilaginous meatus and the external bony meatus. The external meatus is lined by stratified epithelium which is continued on to the external layer of the tympanic membrane. The tympanic membrane has middle layer of elastic fibrous tissue and the inner layer of mucous membrane and is supported around the periphery by the annulus.

The **middle ear** consists of 3 parts—the uppermost portion is the *attic*, the middle portion is *mesotympanum*, and the lowermost portion is the *hypotympanum*. The middle ear is lined by a single layer of flat ciliated and nonciliated epithelium.

The **inner ear** or labyrinth consists of bony capsule embedded in the petrous bone and contains the membranous labyrinth. The bony capsule consists of 3 parts—posteriorly three semicircular canals, in the middle is the vestibule, and anteriorly contains snail-like cochlea.

□ INFLAMMATORY LESIONS (p. 514)

OTITIS MEDIA. This is the term used for inflammatory involvement of the middle ear. It may be acute or chronic. The usual source of infection is via the eustachian tube and the common causative organisms are *Streptococcus pneumoniae*, *Haemophilus influenzae* and β -*Streptococcus haemolyticus*. Otitis media may be suppurative, serous or mucoid. Acute suppurative otitis media (SOM) clinically presents as tense and hyperaemic tympanic membrane along with pain and tenderness and sometimes mastoiditis as well. Chronic SOM manifests clinically as draining ear with perforated tympanic membrane and partially impaired hearing.

RELAPSING POLYCHONDritis. This is an uncommon autoimmune disease characterised by complete loss of glycosaminoglycans resulting in destruction of cartilage of the ear, nose, eustachian tube, larynx and lower respiratory tract.

CHONDRODERMATITIS NODULARIS CHRONICA HELICIS. This condition involves the external ear superficially and presents as a 'painful nodule of the ear'. The skin in this location is in direct contact with the cartilage without protective subcutaneous layer.

□ MISCELLANEOUS CONDITIONS (p. 514)

CAULIFLOWER EAR. This is an acquired deformity of the external ear due to degeneration of cartilage as a result of repeated trauma as occurs in boxers and wrestlers.

OTOSCLEROSIS. This is a dystrophic disease of labyrinth of the temporal bone. The footplate of stapes first undergoes fibrous replacement and is subsequently replaced by sclerotic bone. It is seen more commonly in young males as a cause for sensori-neural type of deafness.

□ TUMOURS AND TUMOUR-LIKE LESIONS (p. 514)

Tumours and tumour-like conditions are relatively more common in the external than the middle and inner ear. The lesions seen in the external ear are similar to those seen in the skin e.g. *tumour-like lesions* such as epidermal cyst; *benign tumours* like naevi and squamous cell papilloma; and *malignant tumours* such as basal cell carcinoma, squamous cell carcinoma and malignant melanoma. However, tumours and tumour-like lesions which are specific to the ear are described below.

AURAL (OTIC) POLYPS. Aural or otic polyps are tumour-like lesions arising from the middle ear as a complication of the chronic otitis media and project into the external auditory canal.

M/E They are composed of chronic inflammatory granulation tissue and are often covered by metaplastic squamous epithelium or pseudostratified columnar epithelium.

432 CERUMEN-GLAND TUMOURS. Tumours arising from cerumen-secreting apocrine sweat glands of the external auditory canal are cerumen-gland adenomas or cerumen-gland adenocarcinomas and are counter-parts of sweat gland tumours (hidradenoma and adenocarcinoma).

CHOLESTEATOMA (KERATOMA). This is a post-inflammatory 'pseudotumour' found in the middle ear or mastoid air cells. There is invariable history of acute or chronic otitis media. A marginal perforation is generally present through which the squamous epithelium enters the middle ear and results in exfoliation of squamous and formation of the keratin.

M/E The lesion consists of cyst containing abundant keratin material admixed with cholesterol crystals and large number of histiocytes (**Web Image 18.10**).

JUGULAR PARAGANGLIOMA (GLOMUS JUGULARE TUMOUR, NON-CHROMAFFIN PARAGANGLIOMA). Tumours originating from parasympathetic ganglia are called 'paraganglioma' and are named according to the location of the tissue of origin. The one arising from glomus jugulare bodies of the middle ear (jugulotympanic bodies) is called jugular paraganglioma or chemodectoma or non-chromaffin paraganglioma and is the most common benign tumour of the middle ear.

M/E The tumour cells containing neurosecretory granules are arranged in typical organoid pattern or nests. The tumour may extend locally to involve the skull and brain but may rarely metastasise.

ACOUSTIC NEUROMA (ACOUSTIC SCHWANNOMA). This is a tumour of Schwann cells of 8th cranial nerve. It is usually located in the internal auditory canal and cerebellopontine angle. It is a benign tumour similar to other schwannomas but by virtue of its location and large size, may produce compression of the important neighbouring tissues leading to deafness, tinnitus, paralysis of 5th and 7th nerves, compression of the brainstem and hydrocephalus.

□ **NORMAL STRUCTURE** (p. 515)

The external nose and the septum are composed of bone and cartilage. On the lateral wall of the nasal cavity, there is a system of 3 ridges on each side known as conchae or turbinates—the inferior, middle and superior. They are the frontal air sinus, maxillary air sinus and the anterior ethmoid air cells, comprising the *anterior group*, while posterior ethmoidal cells and sphenoidal sinus form the *posterior group*. Nasal mucous membranes as well as the lining of the nasal sinus are lined by respiratory epithelium (pseudostratified columnar ciliated cells).

□ **INFLAMMATORY CONDITIONS** (p. 515)

ACUTE RHINITIS (COMMON COLD). Acute rhinitis or common cold is the common inflammatory disorder of the nasal cavities that may extend into the nasal sinuses. It begins with rhinorrhoea, nasal obstruction and sneezing. Initially, the nasal discharge is watery, but later it becomes thick and purulent. The etiologic agents are generally adenoviruses that evoke catarrhal discharge.

ALLERGIC RHINITIS (HAY FEVER). Allergic rhinitis occurs due to sensitivity to allergens such as pollens. It is an IgE-mediated immune response consisting of an early acute response due to degranulation of mast cells, and a delayed prolonged response in which there is infiltration by leucocytes such as eosinophils, basophils, neutrophils and macrophages accompanied with oedema.

SINUSITIS. Acute sinusitis is generally a complication of acute or allergic rhinitis and rarely secondary to dental sepsis. The ostia are occluded due to inflammation and oedema and the sinuses are full. 'Mucocele' is filling up of the sinus with mucus while 'empyema' of the sinus occurs due to collection of pus. Acute sinusitis may become chronic due to incomplete resolution of acute inflammation and from damage to the mucous membrane.

NASAL POLYPS. Nasal polyps are common and are pedunculated grape-like masses of tissue. They are the end-result of prolonged chronic inflammation causing polypoid thickening of the mucosa. They may be *allergic or inflammatory*. They are frequently bilateral and the middle turbinate is the common site. *Antrochoanal polyps* originate from the mucosa of the maxillary sinus and appear in the nasal cavity. Morphologically, nasal and antro-choanal polyps are identical.

G/A They are gelatinous masses with smooth and shining surface.

M/E They are composed of loose oedematous connective tissue containing some mucous glands and varying number of inflammatory cells like lymphocytes, plasma cells and eosinophils. Allergic polyps have plenty of eosinophils and hyperplasia of mucous glands. Both inflammatory and allergic polyps are covered by respiratory epithelium which may show squamous metaplasia (**Web Image 18.11**).

RHINOSPORIDIOSIS. Rhinosporidiosis is caused by a fungus, *Rhinosporidium seeberi*. Typically it occurs in a nasal polyp but may be found in other locations like nasopharynx, larynx and conjunctiva. The disease is common in India and Sri Lanka and sporadic in other parts of the world.

M/E Besides the structure of inflammatory or allergic polyp, large number of organisms of the size of erythrocytes with chitinous wall are seen in the thick-walled *sporangia*. Each sporangium may contain a few thousand spores. On rupture of a sporangium, the spores are discharged into the submucosa or on to the surface of the mucosa (**Web Image 18.12**).

RHINOSCLEROMA. This is a chronic destructive inflammatory lesion of the nose and upper respiratory airways caused by diplobacilli, *Klebsiella rhinoscleromatis*. The condition is endemic in parts of Africa, America, South Asia and Eastern Europe.

M/E There is extensive infiltration by foamy histiocytes containing the organisms (Mikulicz cells) and other chronic inflammatory cells like lymphocytes and plasma cells.

GRANULOMAS. Many granulomatous inflammations may involve the nose. These include: tuberculosis, leprosy, syphilis, aspergillosis, mucormycosis, Wegener's granulomatosis and lethal midline granuloma.

□ TUMOURS (p. 517)

BENIGN TUMOURS (p. 517)

1. CAPILLARY HAEMANGIOMA. Capillary haemangioma of the septum of nose is a common benign lesion. If the surface is ulcerated and the lesion contains inflammatory cell infiltrate, it resembles inflammatory granulation tissue and is called '*haemangioma of granulation tissue type*' or '*granuloma pyogenicum*'.

2. SINONASAL PAPILOMAS. Papillomas may occur in the nasal vestibule, nasal cavity and paranasal sinuses. They are mainly of 2 types—*fungiform papilloma* with exophytic growth, and *inverted papilloma* with everted growth, also called Schneiderian papilloma.

MALIGNANT TUMOURS (p. 517)

1. OLFACTORY NEUROBLASTOMA OR ESTHESIONEUROBLASTOMA. It occurs over the olfactory mucosa as a polypoid mass that may invade the

434 paranasal sinuses or skull. It is a highly malignant small cell tumour of neural crest origin that may, at times, be indistinguishable from other small cell malignancies like rhabdomyosarcoma, undifferentiated carcinoma, lymphoma or Ewing's sarcoma. Rosettes are found in about 10% of tumours.

2. CARCINOMAS. Majority of carcinomas of the nasal cavity and paranasal sinuses are squamous cell carcinomas, commonly called *sinonasal carcinomas*. They are seen more commonly in the elderly with history of heavy smoking and severe chronic sinusitis, in nickel refinery workers and in wood workers. The tumour extends locally to involve the surrounding bone and soft tissues and also metastasises widely.

□ **NORMAL STRUCTURE** (p. 517)

The pharynx has 3 parts—the nasopharynx, oropharynx (pharynx proper) and the laryngopharynx. The whole of pharynx is lined by stratified squamous epithelium. The lymphoid tissue of the pharynx is comprised by the tonsils and adenoids.

□ **INFLAMMATORY CONDITIONS** (p. 517)

LUDWIG'S ANGINA. This is a severe, acute streptococcal cellulitis involving the neck, tongue and back of the throat. The condition was more common in the pre-antibiotic era as a complication of compound fracture of the mandible and periapical infection of the molars.

VINCENT'S ANGINA. Vincent's angina is a painful condition of the throat characterised by local ulceration of the tonsils, mouth and pharynx. The causative organism is *Vincent's bacillus*.

DIPHTHERIA. Diphtheria is an acute communicable disease caused by *Corynebacterium diphtheriae*. It usually occurs in children and results in the formation of a yellowish-grey *pseudomembrane* in the mucosa of nasopharynx, oropharynx, tonsils, larynx and trachea. *C. diphtheriae* elaborates an exotoxin that causes necrosis of the epithelium which is associated with abundant fibrinopurulent exudate resulting in the formation of pseudomembrane. Absorption of the exotoxin in the blood may lead to more distant injurious effects such as myocardial necrosis, polyneuritis, parenchymal necrosis of the liver, kidney and adrenals.

TONSILLITIS. Tonsillitis caused by staphylococci or streptococci may be acute or chronic. *Acute tonsillitis* is characterised by enlargement, redness and inflammation. Acute tonsillitis may progress to acute follicular tonsillitis in which crypts are filled with debris and pus giving it follicular appearance. *Chronic tonsillitis* is caused by repeated attacks of acute tonsillitis in which case the tonsils are small and fibrosed.

PERITONSILLAR ABSCESS (QUINSY). Peritonsillar abscess or quinsy occurs as a complication of acute tonsillitis. The causative organisms are staphylococci or streptococci which are associated with infection of the tonsils. The glands behind the angle of the mandible are enlarged and tender. Besides the surgical management of the abscess, the patient must be advised tonsillectomy because quinsy is frequently recurrent.

RETROPHARYNGEAL ABSCESS. Formation of abscess in the soft tissue between the posterior wall of the pharynx and the vertebral column is called retropharyngeal abscess. It occurs due to infection of the retropharyngeal lymph nodes. A chronic form of the abscess in the same location is seen in tuberculosis of the cervical spine (*cold abscess*).

□ **TUMOURS** (p. 518)

NASOPHARYNGEAL ANGIOFIBROMA. This is a peculiar tumour that occurs exclusively in adolescent males (10-20 years of age) suggesting the

role of testosterone hormone in its production. Though a benign tumour of the nasopharynx, it may grow into paranasal sinuses, cheek and orbit but does not metastasise.

M/E The tumour is composed of 2 components as the name suggests—numerous small endothelium-lined vascular spaces and the stromal cells which are myofibroblasts (**Web Image 18.13**).

NASOPHARYNGEAL CARCINOMA. Nasopharyngeal carcinoma is a common cancer in South-East Asia, especially prevalent in people of Chinese descent under 45 years of age. Genetic susceptibility and role of Epstein-Barr virus are considered important factors in its etiology. In fact, EBV-genome is found virtually in all cases of nasopharyngeal carcinoma.

M/E Nasopharyngeal carcinoma has 3 histologic variants:

- i) Non-keratinising squamous cell carcinoma
- ii) Keratinising squamous cell carcinoma
- iii) Undifferentiated (transitional cell) carcinoma

Non-keratinising and keratinising squamous cell carcinomas are identical in morphology to typical tumours in other locations. The undifferentiated carcinoma, also called as transitional cell carcinoma, is characterised by masses and cords of cells which are polygonal to spindled and have large vesicular nuclei. A variant of undifferentiated carcinoma is 'lymphoepithelioma' in which undifferentiated carcinoma is infiltrated by abundant non-neoplastic mature lymphocytes (**Web Image 18.14**).

EMBRYONAL RHABDOMYOSARCOMA. Also termed as botryoid rhabdomyosarcoma, this is one of the common malignant tumours in children but can also occur in adults. The lesion is highly cellular and mitotically active. Other locations include vagina, orbit, middle ear, oral cavity, retroperitoneum and bile duct.

MALIGNANT LYMPHOMA. The lymphoid tissue of the nasopharynx and tonsils may be the site for development of malignant lymphomas which resemble similar tumours elsewhere in the body.

□ **NORMAL STRUCTURE** (p. 519)

The larynx is composed of cartilages which are bound together by ligaments and muscles and is covered by mucous membrane. The cartilages of the larynx are of 2 types—unpaired and paired.

The larynx as well as trachea are lined by respiratory epithelium, except over the true vocal cords and the epiglottis, which are lined by stratified squamous epithelium.

□ **INFLAMMATORY CONDITIONS** (p. 519)

ACUTE LARYNGITIS. This may occur as a part of the upper or lower respiratory tract infection. Atmospheric pollutants like cigarette smoke, exhaust fumes, industrial and domestic smoke etc predispose the larynx to acute bacterial and viral infections. *Streptococci* and *H. influenzae* cause acute epiglottitis which may be life-threatening.

CHRONIC LARYNGITIS. Chronic laryngitis may occur from repeated attacks of acute inflammation, excessive smoking, chronic alcoholism or vocal abuse.

TUBERCULOUS LARYNGITIS. Tuberculous laryngitis occurs secondary to pulmonary tuberculosis. Typical caseating tubercles are present on the surface of the larynx.

ACUTE OEDEMA OF THE LARYNX. This hazardous condition is an acute inflammatory condition, causing swelling of the larynx that may lead to airway obstruction and death by suffocation.

436 □ TUMOURS (p. 519)

LARYNGEAL PAPILOMA AND PAPILOMATOSIS. Juvenile laryngeal papillomas are found in children or adolescents and are often multiple, while the adults have usually a single lesion. Multiple juvenile papillomas may undergo spontaneous regression at puberty. Human papilloma virus (HPV type 11 and 6) has been implicated in the etiology of papillomas of the larynx.

G/A The lesions appear as warty growths on the true vocal cords, epiglottis and sometimes extend to the trachea and bronchi.

M/E Papillomas are composed of finger-like papillae, each papilla contains fibrovascular core covered by stratified squamous epithelium (**Web Image 18.15**).

LARYNGEAL NODULES. Laryngeal nodules or polyps are seen mainly in adults and are found more often in heavy smokers and in individuals subjected to vocal abuse. Therefore, they are known by various synonyms like singers' nodes, preachers' node, and screamers' nodes. The patients have characteristic progressive hoarseness.

G/A It is a small lesion, less than 1 cm in diameter, rounded, smooth, usually sessile and polypoid swelling on the true vocal cords.

M/E The nodules have prominent oedema with sparse fibrous tissue and numerous irregular and dilated vascular channels. Sometimes, the subepithelial basement membrane is thickened, resembling amyloid material (**Web Image 18.16**).

LARYNGEAL CARCINOMA. Cancer of the larynx in 99% of cases is squamous cell carcinoma. Rarely, adenocarcinoma and sarcoma are encountered. Squamous carcinoma of the larynx occurs in males beyond 4th decade of life. Important etiologic factor is heavy smoking of cigarettes, cigar or pipe; other factors include excessive alcohol consumption, radiation and asbestos exposure. However, based on the anatomic location, laryngeal carcinoma is classified as under:

1. *Glottic* is the most common location, found in the region of true vocal cords and anterior and posterior commissures.
2. *Supraglottic* involving ventricles and arytenoids.
3. *Subglottic* in the walls of subglottis.
4. *Marginal zone* between the tip of epiglottis and ary-epiglottic folds.
5. *Laryngo-(hypo-) pharynx* in the pyriform fossa, postcricoid fossa and posterior pharyngeal wall.

G/A The glottic carcinoma is the most common form and appears as a small, pearly white, plaque-like thickening that may be ulcerated or fungated.

M/E Keratinising and non-keratinising squamous carcinomas of varying grades are found. Generally, carcinoma of the supraglottic and subglottic regions tends to be more poorly-differentiated than the glottic tumour. Besides the keratinising and non-keratinising squamous carcinoma, 2 special varieties of squamous carcinoma in the larynx are: *verrucous carcinoma* (or Ackerman's tumour) which is a variant of well-differentiated squamous carcinoma, and *spindle cell carcinoma* which has elongated tumour cells resembling sarcoma (pseudosarcoma) at the other extreme of prognosis.

□ CYSTS OF NECK (p. 520)

The cysts of neck may be medial (midline) or lateral (**Web Table 18.3**).

MEDIAL (MIDLINE) CERVICAL CYSTS (p. 520)

THYROGLOSSAL CYST. Thyroglossal cyst arises from the vestiges of thyroglossal duct that connects the foramen caecum at the base of the tongue with the normally located thyroid gland. The cyst is located in the

midline, generally at the level of hyoid bone, and rarely at the base of the tongue.

MIDLINE DERMOID CYST. Dermoid cyst located in the midline of the neck occurs due to sequestration of dermal cells along the lines of closure of embryonic clefts. The cyst contains paste-like pultaceous material.

LATERAL CERVICAL CYSTS (p. 520)

BRANCHIAL (LYMPHOEPITHELIAL) CYST. Branchial or lymphoepithelial cyst arises from incomplete closure of 2nd or 3rd branchial clefts. The cyst is generally located anterior to the sternocleidomastoid muscle near the angle of the mandible. The cyst is 1-3 cm in diameter and is filled with serous or mucoid material.

M/E The cyst is lined by stratified squamous or respiratory epithelium, covering subepithelial lymphoid tissue aggregates or follicles with germinal centres.

PARATHYROID CYST. Parathyroid cyst is a lateral cyst of the neck usually located deep to the sternocleidomastoid muscle at the angle of the mandible. These may be microscopic cysts or larger.

M/E Parathyroid cyst is lined by flattened cuboidal to low columnar epithelium and the cyst wall may contain any type of parathyroid cells.

CERVICAL THYMIC CYST. Cervical thymic cyst originates from cystic degeneration of Hassall's corpuscles. It is generally located in the left lateral side of the neck.

CYSTIC HYGROMA. Cystic hygroma is a lateral swelling at the root of the neck, usually located behind the sternocleidomastoid muscle. It may be present congenitally or may manifest in the first 2 years of life. It is usually multilocular and may extend into the mediastinum and pectoral region.

M/E Cystic hygroma is a diffuse lymphangioma containing large cavernous spaces lined by endothelium and containing lymph fluid.

□ TUMOURS (p. 521)

PRIMARY TUMOURS (p. 521)

CAROTID BODY TUMOUR (CHEMODECTOMA, CAROTID BODY PARAGANGLIOMA). Carotid body tumour arises in the carotid bodies which are situated at the bifurcation of the common carotid arteries. Carotid bodies are normally part of the chemoreceptor system and the cells of this system are sensitive to changes in the pH and arterial oxygen tension and are also the storage site for catecholamines. Histologically similar tumours are found in other parasympathetic ganglia represented by the vagus and glomus jugulare.

G/A They are small, firm, dark tan, encapsulated nodules.

M/E Well-differentiated tumour cells form characteristic organoid or alveolar pattern, as is the case with all other neuroendocrine tumours. The tumour cells contain dark neurosecretory granules containing catecholamines.

TORTICOLLIS (FIBROMATOSIS COLLI, WRY NECK). This is a deformity in which the head is bent to one side while the chin points to the other side. The deformity may occur as congenital torticollis or may be an acquired form. The *acquired form* may occur secondary to fracture dislocation of the cervical spine, Pott's disease of the cervical spine, scoliosis, spasm of the muscles of neck, exposure to chill causing myositis, and contracture following burns or wound healing. The *congenital or primary torticollis* appears at birth or within the first few weeks of life as a firm swelling in the lower third of the sternocleidomastoid muscle. The etiology is unknown but about half the cases are associated with breech delivery.

438 MALIGNANT LYMPHOMAS. Various forms of non-Hodgkin's lymphomas and Hodgkin's disease occur in the cervical lymph nodes.

SECONDARY TUMOURS (p. 521)

Cervical lymph nodes are common site for metastases of a large number of carcinomas. These include: squamous cell carcinoma of the lips, mouth, tongue, larynx and oesophagus; transitional cell carcinoma of the pharynx and nasopharynx; thoracic and abdominal cancers such as of the stomach, lungs, ovaries, uterus and testis.

SELF ASSESSMENT

- Chalazion is chronic inflammatory process involving:**
 - Sebaceous gland of Zeis
 - Apocrine gland of Moll
 - Meibomian glands
 - Eyelash follicle
- Proliferative retinopathy consists of the following lesions except:**
 - Capillary microaneurysms
 - Neovascularisation of the retina at optic disc
 - Vitreous haemorrhages
 - Proliferation of astrocytes and fibrous tissue around blood vessels
- Hypertensive retinopathy has the following features except:**
 - Flame-shaped haemorrhages in retinal nerve layer
 - Arteriolosclerosis
 - Vitreous haemorrhages
 - Microaneurysm
- Mikulicz's syndrome is inflammatory enlargement of lacrimal and salivary glands which may occur with following conditions except:**
 - Sjögren's syndrome
 - Sarcoidosis
 - Tuberculosis
 - Lymphoma
- Sebaceous carcinoma occurs most commonly at:**
 - Axilla
 - Groin
 - Upper eyelid
 - Lower eyelid
- Following histologic type of uveal malignant melanoma has the worst prognosis:**
 - Spindle A
 - Spindle B
 - Epithelioid
 - Mixed
- The most common ocular metastatic tumour is from the following primary cancer:**
 - Melanoma
 - Breast
 - Epidermoid
 - Neuroblastoma
- Sjögren's syndrome produces the following pathological change in the eye:**
 - Uveitis
 - Phthisis bulbi
 - Keratoconjunctivitis
 - Glaucoma
- Most common eyelid tumour is:**
 - Sebaceous carcinoma
 - Squamous cell carcinoma
 - Malignant melanoma
 - Basal cell carcinoma
- What is true about retinoblastoma:**
 - 60% cases are sporadic and 40% are familial
 - 40% cases are sporadic and 60% are familial
 - 80% cases are sporadic and 20% are familial
 - 20% cases are sporadic and 80% are familial
- Wegener's granulomatosis generally produces lesions in the following tissues except:**
 - Nose
 - Ears
 - Lungs
 - Kidneys

12. **Nasopharyngeal angiofibroma has the following features except:** 439
 A. It is endemic in people of South-East Asia
 B. It occurs exclusively in adolescent males
 C. It is a benign nasopharyngeal tumour
 D. Testosterone hormone plays a role in its etiology
13. **Nasopharyngeal carcinoma has the following features except:**
 A. It is common cancer in South-East Asia
 B. It occurs in males exclusively
 C. EB virus plays a role in its etiology
 D. The prognosis is usually fatal
14. **Subaceous carcinoma is commonest tumour in the following location:**
 A. Upper eyelid
 B. Lower eyelid
 C. External auditory canal
 D. Lip
15. **Lateral cervical cysts of the neck include the following examples except:**
 A. Branchial cyst
 B. Thyroglossal cyst
 C. Cervical thymic cyst
 D. Parathyroid cyst
16. **Which of the following is post-inflammatory pseudotumour of ear:**
 A. Chondrodermatitis nodularis
 B. Cauliflower ear
 C. Otosclerosis
 D. Cholesteatoma
17. **Characteristic cells seen in rhinoscleroma are known as:**
 A. Mikulicz cells
 B. Dendritic cells
 C. Langerhans cells
 D. Touton cells
18. **Which HPV types are implicated in causation of laryngeal papilloma:**
 A. HPV type 6 and 11
 B. HPV type 8 and 16
 C. HPV type 33 and 36
 D. HPV type 46 and 52
19. **Ackerman's tumour is:**
 A. Spindle cell carcinoma of larynx
 B. Verrucous carcinoma of larynx
 C. Adenocarcinoma of larynx
 D. Sarcoma of larynx

KEY

1 = C	2 = A	3 = C	4 = C
5 = C	6 = C	7 = B	8 = C
9 = A	10 = A	11 = B	12 = A
13 = B	14 = A	15 = B	16 = D
17 = B	18 = A	19 = B	



The Oral Cavity and Salivary Glands

□ NORMAL STRUCTURE (p. 522)

The oral cavity is the point of entry for digestive and respiratory tracts. The mucous membrane of the mouth consists of squamous epithelium covering vascularised connective tissue. The epithelium is keratinised over the hard palate, lips and gingiva, while elsewhere it is non-keratinised. Mucous glands (minor salivary glands) are scattered throughout the oral mucosa. Sebaceous glands are present in the region of the lips and the buccal mucosa only. Lymphoid tissue is present in the form of tonsils and adenoids.

□ DEVELOPMENTAL ANOMALIES (p. 522)

1. FACIAL CLEFTS. *Cleft upper lip (harelip) and cleft palate*, alone or in combination, are the commonest developmental anomalies of the face. These occur from the failure of fusion of facial processes.

2. FORDYCE'S GRANULES. Fordyce's granules are symmetric, small, light yellow macular spots on the lips and buccal mucosa and represent collections of sebaceous glands.

3. LEUKOEDEMA. This is an asymptomatic condition occurring in children and is characterised by symmetric, grey-white areas on the buccal mucosa.

4. DEVELOPMENTAL DEFECTS OF THE TONGUE

i) Macroglossia is the enlargement of the tongue, usually due to lymphangioma or haemangioma, and sometimes due to amyloid tumour.

ii) Microglossia and aglossia are rare congenital anomalies representing small-sized and absence of tongue respectively.

iii) Fissured tongue (scrotal, furrowed or grooved tongue) is a genetically-determined condition characterised by numerous small furrows or grooves on the dorsum of the tongue.

iv) Bifid tongue is a rare condition occurring due to failure of the two lateral halves of the tongue to fuse in the midline.

v) Tongue tie occurs when the lingual fraenum is quite short, or when the fraenum is attached near the tongue tip.

vi) Hairy tongue is not a true developmental defect, but is mentioned here because of its similarity with other conditions discussed here. The filiform papillae are hypertrophied and elongated. These 'hairs' (papillae) are stained black, brown or yellowish-white by food, tobacco, oxidising agents or by oral flora.

□ MUCOCUTANEOUS LESIONS (p. 522)

LICHEN PLANUS. Characteristically, oral lichen planus appears as interlacing network of whitening or keratosis on the buccal mucosa but other oral tissues such as gingival, tongue and palate may also be involved.

VESICULAR LESIONS. A number of vesicular or bullous diseases of the skin have oral lesions.

i) Pemphigus vulgaris. Vesicular oral lesions appear invariably in all cases at some time in the course of pemphigus vulgaris.

ii) **Pemphigoid.** Vesicles or bullae appear on oral mucosa as well as on conjunctiva in pemphigoid and are seen more often in older women.

iii) **Erythema multiforme.** Subepithelial vesicles may occur on the skin as well as mucosae.

iv) **Stevens-Johnson syndrome** is a rather fatal and severe form of erythema multiforme involving oral and other mucous membranes occurring following ingestion of sulfa drugs.

v) **Epidermolysis bullosa** is a hereditary condition having subepidermal bullae on the skin as well as has oral lesions.

□ INFLAMMATORY DISEASES (p. 522)

STOMATITIS. Inflammation of the mucous membrane of the mouth is called stomatitis. It can occur in the course of several different diseases.

i) **Apthous ulcers (Canker sores)** is the commonest form of oral ulceration. The etiology is unknown but may be precipitated by emotional factors, stress, allergy, hormonal imbalance, nutritional deficiencies, gastrointestinal disturbances, trauma etc.

ii) **Herpetic stomatitis** is an acute disease occurring in infants and young children. It is the most common manifestation of primary infection with herpes simplex virus. The lesions are in the form of vesicles around the lips. Similar lesions may appear on the genital skin. Recurrent attacks occur due to stress, emotional upsets and upper respiratory infections.

iii) **Necrotising stomatitis (Noma or Cancrum oris)** occurs more commonly in poorly-nourished children like in kwashiorkor; infectious diseases such as measles, immunodeficiencies and emotional stress. The lesions are characterised by necrosis of the marginal gingiva and may extend on to oral mucosa, causing cellulitis of the tissue of the cheek.

iv) **Mycotic infections** commonly involving the oral mucosa are actinomycosis and candidiasis.

GLOSSITIS. **Acute glossitis** characterised by swollen papillae occurs in eruptions of measles and scarlet fever. In **chronic glossitis**, the tongue is raw and red without swollen papillae and is seen in malnutrition such as in pellagra, ariboflavinosis and niacin deficiency. In iron deficiency anaemia, pernicious anaemia and sprue, there is *chronic atrophic glossitis* characterised by atrophied papillae and smooth raw tongue.

SYPHILITIC LESIONS. These are as under:

i) Extragenital chancre of *primary syphilis* occurs most commonly on the lips.

ii) *Secondary syphilis* shows maculopapular eruptions and mucous patches in the mouth.

iii) In the *tertiary syphilis*, gummas or diffuse fibrosis may be seen on the hard palate and tongue.

iv) Oral lesions of the *congenital syphilis* are fissures at the angles of mouth and characteristic peg-shaped notched Hutchinson's incisors.

TUBERCULOUS LESIONS. Involvement of the mouth in tuberculosis is rare. The lesions are in the form of ulcers or elevated nodules.

HIV INFECTION. HIV infection of low grade as well as full-blown acquired immunodeficiency syndrome (AIDS) are associated with oral manifestations such as opportunistic infections, malignancy, hairy leukoplakia and others; these are listed in **Web Table 19.1**. About half the cases of Kaposi's sarcoma have intraoral lesions as part of systemic involvement.

□ PIGMENTARY LESIONS (p. 523)

Oral and labial melanotic pigmentation may be observed in certain systemic and metabolic disorders such as Addison's disease, Albright syndrome,

442 Peutz-Jeghers syndrome and haemochromatosis. All types of pigmented naevi as well as malignant melanoma can occur in oral cavity.

□ **TUMOURS AND TUMOUR-LIKE LESIONS** (p. 523)

Benign and malignant tumours as also a number of tumour-like lesions and premalignant lesions are encountered in the oral soft tissues **Web Table 19.2**.

A. TUMOUR-LIKE LESIONS (p. 524)

FIBROUS GROWTHS. Fibrous growths of the oral soft tissues are very common. These are not true tumours (unlike intraoral fibroma and papilloma), but are instead inflammatory or irritative in origin. A few common varieties are as under:

i) **Fibroepithelial polyps** occur due to irritation or chronic trauma. These are composed of reparative fibrous tissue, covered by a thin layer of stratified squamous epithelium.

ii) **Fibrous epulis** is a lesion occurring on the gingiva and is localised hyperplasia of the connective tissue following trauma or inflammation in the area (**Web Image 19.1**). *Giant cell epulis* is a variant seen more commonly in females as reactive change to trauma; the lesion shows numerous osteoclast-like giant cells and vascular stroma.

iii) **Denture hyperplasia** occurs in edentulous or partly edentulous patients. The lesion is an inflammatory hyperplasia in response to local irritation by ill-fitting denture or an elongated tooth.

PYOGENIC GRANULOMA. This is an elevated, bright red swelling of variable size occurring on the lips, tongue, buccal mucosa and gingiva. It is a vasoproliferative inflammatory lesion. *Pregnancy tumour* is a variant of pyogenic granuloma.

MUCOCELE. Also called mucous cyst or retention cyst, it is a cystic dilatation of the mucous glands of the oral mucosa. The cyst often ruptures on distension and incites inflammatory reaction due to mucous extravasation (**Web Image 19.2**).

RANULA. It is a large mucocele located on the floor of the mouth. The cyst is lined by true epithelial lining.

DERMOID CYST. This tumour-like mass in the floor of the mouth represents a developmental malformation. The cyst is lined by stratified squamous epithelium. The cyst wall contains sebaceous glands, sweat glands, hair follicles and other mature tissues.

B. BENIGN TUMOURS (p. 524)

SQUAMOUS PAPILLOMA. Papilloma can occur anywhere in the mouth and has the usual papillary or finger-like projections.

M/E Each papilla is composed of vascularised connective tissue covered by squamous epithelium.

HAEMANGIOMA. Haemangioma can occur anywhere in the mouth; when it occurs on the tongue it may cause macroglossia. It is most commonly capillary type, although cavernous and mixed types may also occur.

LYMPHANGIOMA. Lymphangioma may develop most commonly on the tongue producing macroglossia; on the lips producing macrocheilia, and on the cheek. *Cystic hygroma* is a special variety of lymphangioma occurring in children on the lateral side of neck.

FIBROMA. Although most common benign oral mucous membrane mass is fibroma appearing as a discrete superficial pedunculated mass, it appears to be nonneoplastic in nature. It probably arises as a response physical trauma.

M/E Fibroma is composed of collagenic fibrous connective tissue covered by stratified squamous epithelium.

FIBROMATOSIS GINGIVAE. This is a fibrous overgrowth of unknown etiology involving the entire gingiva. Sometimes the fibrous overgrowth is so much that the teeth are covered by fibrous tissue.

TUMOURS OF MINOR SALIVARY GLANDS. Minor salivary glands present in the oral cavity may sometimes be the site of origin of salivary tumours similar to those seen in the major salivary glands. Pleomorphic adenoma is a common example.

GRANULAR CELL TUMOUR. Earlier called as granular cell myoblastoma, it is benign tumour which now by electron microscopic studies is known to be mesenchymal in origin than odontogenic. The most common location is the tongue but may occur in any other location on the oral cavity. It occurs exclusively in females.

M/E The tumour is composed of large polyhedral cells with granular, acidophilic cytoplasm. The covering epithelium usually shows pronounced pseudoepitheliomatous hyperplasia.

C. ORAL LEUKOPLAKIA (WHITE LESIONS) (p. 525)

DEFINITION. Leukoplakia (*white plaque*) may be clinically defined as a white patch or plaque on the oral mucosa, exceeding 5 mm in diameter, which cannot be rubbed off nor can be classified into any other diagnosable disease. A number of other lesions are characterised by the formation of white patches listed in **Web Table 19.3**. However, from the pathologist's point of view, the term 'leukoplakia' is reserved for epithelial thickening which may range from completely benign to atypical and to premalignant cellular changes.

INCIDENCE. It occurs more frequently in males than females. The lesions may be of variable size and appearance. The sites of predilection, in descending order of frequency, are: cheek mucosa, angles of mouth, alveolar mucosa, tongue, lip, hard and soft palate, and floor of the mouth. In about 4-6% cases of leukoplakia, carcinomatous change is reported. However, it is difficult to decide which white lesions may undergo malignant transformation, but speckled or nodular form is more likely to progress to malignancy.

ETIOLOGY. The etiological factors are similar to those suggested for carcinoma of the oral mucosa. *It has the strongest association with the use of tobacco in various forms*, e.g. in heavy smokers (especially in pipe and cigar smokers) and improves when smoking is discontinued, and in those who chew tobacco as in paan, paan masaala, zarda, gutka etc. The condition is also known by other names such as *smokers keratosis* and *stomatitis nicotina*. Other etiological factors implicated are chronic friction such as with ill-fitting dentures or jagged teeth, and local irritants like excessive consumption of alcohol and very hot and spicy foods and beverages.

G/A The lesions of leukoplakia may appear white, whitish-yellow, or red-velvety of more than 5 mm diameter and variable in appearance. They are usually circumscribed, slightly elevated, smooth or wrinkled, speckled or nodular.

M/E Leukoplakia is of 2 types:

1. Hyperkeratotic type. This is characterised by an orderly and regular hyperplasia of squamous epithelium with hyperkeratosis on the surface (**Web Image 19.3, A**).

2. Dysplastic type. When the changes such as irregular stratification of the epithelium, focal areas of increased and abnormal mitotic figures, hyperchromatism, pleomorphism, loss of polarity and individual cell keratinisation are present, the lesion is considered as epithelial dysplasia.

444 The subepithelial tissues usually show an inflammatory infiltrate composed of lymphocytes and plasma cells. Usually, mild dysplasia may revert back to normal if the offending etiologic factor is removed, whereas severe dysplasia indicates that the case may progress to carcinoma. *Erythroplasia* is a form of dysplastic leukoplakia in which the epithelial atypia is more marked and thus has higher risk of developing malignancy. If the epithelial dysplasia is extensive so as to involve the entire thickness of the epithelium, the lesion is called carcinoma *in situ* which may progress to invasive carcinoma (**Web Image 19.3, B**).

D. MALIGNANT TUMOURS (p. 526)

Squamous Cell (Epidermoid) Carcinoma (p. 526)

INCIDENCE. Squamous cell (epidermoid) carcinoma comprises 90% of all oral malignant tumours and 5% of all human malignancies. The peak incidence in the UK and the USA is from 55 to 75 years of age, whereas in India it is from 40 to 45 years of age. Oral cancer is a very frequent malignancy in India, Sri Lanka and some Eastern countries, probably related to habits of betel-nut chewing and reversed smoking. There is a definite male preponderance. It can occur anywhere in the mouth but certain sites are more commonly involved. These sites, in descending order of frequency, are: the lips (more commonly lower), tongue, anterior floor of mouth, buccal mucosa in the region of alveolar lingual sulcus, and palate (**Web Image 19.4**).

Strong association:

- i) Tobacco smoking and tobacco chewing causing leukoplakia is the most important factor as discussed above.
- ii) Chronic alcohol consumption.
- iii) Human papilloma virus infection, particularly HPV 16, 18 and 33 types.

Weak association:

- i) Chronic irritation from ill-fitting denture or jagged teeth.
- ii) Submucosal fibrosis as seen in Indians consuming excess of chillies.
- iii) Poor orodental hygiene.
- iv) Nutritional deficiencies.
- v) Exposure to sunlight (in relation to lip cancer).
- vi) Exposure to radiation.
- vii) Plummer-Vinson syndrome, characterised by atrophy of the upper alimentary tract.

The most common molecular alterations in oncogenes seen in squamous cell carcinoma of the oral cavity are in *p16*, *p53*, *cyclin D*, *p63*, *PTEN*, and *EGFR*.

G/A Squamous cell carcinoma of oral cavity may have the following types (**Web Image 19.5**): (i) Ulcerative type, (ii) Papillary or verrucous type, (iii) Nodular type and (iv) Scirrhou type.

M/E Squamous cell carcinoma ranges from well-differentiated keratinising carcinoma to highly-undifferentiated neoplasm. Changes of epithelial dysplasia are often present in the surrounding areas of the lesion. Carcinoma of the lip and intraoral squamous carcinoma are usually always well-differentiated (**Web Image 19.6**).

Carcinoma of the lip has a more favourable prognosis due to visible and easily accessible location and less frequent metastasis to the regional lymph nodes. However, intraoral squamous carcinomas have poor prognosis because they are detected late and metastasis to regional lymph nodes occur early, especially in the case of carcinoma of tongue and soft palate. *Verrucous carcinoma*, on the other hand, is composed of very well-differentiated squamous epithelium with minimal atypia and hence has very good prognosis.

□ NORMAL STRUCTURE (p. 527)

The teeth are normally composed of 3 calcified tissues, namely: *enamel*, *dentin* and *cementum*; and the *pulp* which is composed of connective tissue. The teeth are peculiar than other calcified tissues of the body by being surrounded by the portion of oral mucosa called the gingiva or gum, and that they are part of a highly specialised odontogenic apparatus; other parts of this apparatus being the mandible and maxilla.

Embryologically, odontogenic development takes place from primitive structure, the *dental lamina* or primitive oral cavity, as follows:

- ◆ Inner epithelial layer of the dental lamina is ectoderm-derived columnar to cuboidal oral epithelium called **ameloblasts** which secrete enamel matrix, also called enamel organ.

- ◆ Mesoderm-derived connective tissue gives rise to structures in the **dental papilla** (i.e. dental pulp or core of loose connective tissue, blood vessels and nerves).

- ◆ Outer margin of the dental papilla differentiates into **odontoblasts**, which continue with ameloblastic epithelium; odontoblasts secrete dentin.

The normal structure of tooth in an adult is as follows (**Web Image 19.7**):

Enamel is the outer covering of teeth composed almost entirely of inorganic material.

Dentin lies under the enamel and comprises most of the tooth substance. It is composed of organic material in the form of collagen fibrils as well as inorganic material in the form of calcium phosphates as in bone.

Cementum is the portion of tooth which covers the dentin at the root of tooth and is the site where periodontal ligament is attached.

Dental pulp is inner to dentine and occupies the pulp cavity and root canal. It consists of connective tissue, blood vessels and nerves.

Nests of odontogenic epithelium are normally present in the jaw and may develop into cysts and tumours.

□ DENTAL CARIES (p. 528)

Dental caries is the most common disease of dental tissues, causing destruction of the calcified tissues of the teeth.

ETIOPATHOGENESIS. Dental caries is essentially a disease of modern society, associated with diet containing high proportion of refined carbohydrates. It has been known for almost 100 years that mixture of sugar or bread with saliva in the presence of acidogenic bacteria of the mouth, especially streptococci, produces organic acids which can decalcify enamel and dentin. Enamel is largely composed of inorganic material which virtually disintegrates. Dentin contains organic material also which is left after decalcification. Bacteria present in the oral cavity cause proteolysis of the remaining organic material of dentin, completing the process of destruction. 'Bacterial plaques' are formed in such stagnation areas. If these plaques are not removed by brushing or by vigorous chewing of fibrous foods, the process of tooth decay begins. There is evidence that consumption of water containing one part per million (ppm) fluoride is sufficient to reduce the rate of tooth decay in children.

MORPHOLOGIC FEATURES. Caries occurs chiefly in the areas of pits and fissures, mainly of the molars and premolars, where food retention occurs, and in the cervical part of the tooth.

G/A The earliest change is the appearance of a small, chalky-white spot on the enamel which subsequently enlarges and often becomes yellow or brown and breaks down to form carious cavity. Eventually, the cavity becomes larger due to fractures of enamel. Once the lesion reaches enamel-dentin junction, destruction of dentine also begins.

446 **M/E** Inflammation (pulpitis) and necrosis of pulp take place. There is evidence of reaction of the tooth to the carious process in the form of *secondary dentin*, which is a layer of odontoblasts laid down under the original dentine (**Web Image 19.8**).

SEQUELAE OF CARIES. Carious destruction of dental hard tissues frequently produces pulpitis and other inflammatory lesions like apical granuloma and apical abscess. Less common causes of these lesions are fracture of tooth and accidental exposure of pulp by the dentist.

1. **Pulpitis.** Pulpitis may be acute or chronic.
2. **Apical granuloma.** Pulpitis may lead to spread of infection through the apical foramen into the tissues surrounding the root of the tooth.
3. **Apical abscess.** An apical granuloma or acute pulpitis may develop into apical abscess.

□ **PERIODONTAL DISEASE** (p. 529)

Chronic inflammation and degeneration of the supporting tissues of teeth resulting in teeth loss is a common condition. Besides inflammation, other diseases associated with gingival swelling are leukaemia, scurvy, fibrous hyperplasia and epulis.

The inflammatory periodontal disease affects adults more commonly. Pregnancy, puberty and use of drugs like dilantin are associated with periodontal disease more often. The disease begins as *chronic marginal gingivitis*, secondary to bacterial plaques around the teeth such as due to calculus (tartar) on the tooth surface, impacted food, uncontrolled diabetes, tooth-decay and ill-fitting dental appliances.

M/E Chronic marginal gingivitis is characterised by heavy chronic inflammatory cell infiltrate, destruction of collagen, and epithelial hyperplasia so as to line the pocket. Untreated chronic marginal gingivitis slowly progresses to *chronic periodontitis* or *pyorrhoea*.

□ **EPITHELIAL CYSTS OF THE JAW** (p. 529)

The epithelium-lined cysts of dental tissue can have inflammatory or developmental origin (**Web Table 19.4**).

A. INFLAMMATORY CYSTS (p. 529)

Radicular Cyst (p. 529)

Radicular cyst, also called as apical, periodontal or simply dental cyst, is the most common cyst originating from the dental tissues. It arises consequent to inflammation following destruction of dental pulp such as in dental caries, pulpitis, and apical granuloma. The epithelial cells of Mallasez, which are nests of odontogenic epithelium embedded in the periodontium, proliferate within apical granuloma under the influence of inflammation, leading to the formation of an epithelium-lined cystic cavity. Most often, radicular cyst is observed at the apex of an erupted tooth and sometimes contains thick pultaceous material.

M/E The radicular cyst is lined by nonkeratinised squamous epithelium. Epithelial rete processes may penetrate the underlying connective tissues. Radicular cyst of the maxilla may be lined by respiratory epithelium. The cyst wall is fibrous and contains chronic inflammatory cells (lymphocytes, plasma cells with Russell bodies and macrophages) hyaline bodies and deposits of cholesterol crystals which may be associated with foreign body giant cells (**Web Image 19.9**).

B. DEVELOPMENTAL CYSTS (p. 530)**Odontogenic Cysts** (p. 530)

DENTIGEROUS (FOLLICULAR) CYST. Dentigerous cyst arises from enamel of an unerupted tooth. The mandibular third molars and the maxillary canines are most often involved. Dentigerous cysts are less common than radicular cysts and occur more commonly in children and young individuals.

M/E Dentigerous cyst is composed of a thin fibrous tissue wall lined by stratified squamous epithelium. Thus, the cyst may resemble radicular cyst, except that chronic inflammatory changes so characteristic of radicular cyst, are usually absent in dentigerous cyst (**Web Image 19.10**).

ERUPTION CYST. This is a cyst lying over the crown of an unerupted tooth and is lined by stratified squamous epithelium. It is thus a form of dentigerous cyst.

GINGIVAL CYST. It arises from the epithelial rests in the gingiva and is lined by keratinising squamous epithelium.

PRIMORDIAL CYST (ODONTOGENIC KERATOCYST). Primordial cyst, like dentigerous cyst, also arises from tooth-forming epithelium. The common location is mandibular third molar.

Non-odontogenic and Fissural Cysts (p. 530)

NASOPALATINE DUCT (INCISIVE CANAL, MEDIAN, ANTERIOR MAXILLARY) CYST. This is the most common non-odontogenic (fissural) cyst and arises from the epithelial remnants of the nasopalatine duct.

NASOLABIAL (NASOALVEOLAR) CYST. This cyst is situated in the soft tissues at the junction of median nasal, lateral nasal and maxillary processes, at the ala of the nose, and sometimes extending into the nostril.

GLOBULOMAXILLARY CYST. This is an intraosseous cyst and is rare.

DERMOID CYST. The dermoid cyst is common in the region of head or neck, especially in the floor of the mouth. The cyst arises from remains in the midline during closure of mandibular and branchial arches.

□ ODONTOGENIC TUMOURS (p. 531)

Odontogenic tumours are a group of uncommon lesions of the jaw derived from the odontogenic apparatus. These tumours are usually benign but some have malignant counterparts (**Web Table 19.5**).

A. BENIGN ODONTOGENIC TUMOURS (p. 531)**Ameloblastoma** (p. 531)

Ameloblastoma is the most common benign but locally invasive epithelial odontogenic tumour. It is most frequent in the 3rd to 5th decades of life. Preferential sites are the mandible in the molar-ramus area and the maxilla. The tumour originates from dental epithelium of the enamel itself or its epithelial residues. Sometimes, the tumour may arise from the epithelial lining of a dentigerous cyst or from basal layer of oral mucosa. Radiologically, typical picture is of a multilocular destruction of the bone.

G/A The tumour is greyish-white, usually solid, sometimes cystic, replacing and expanding the affected bone.

M/E Ameloblastoma can show different patterns as follows:

- i) *Follicular pattern* is the most common. The central stellate areas may show cystic changes (**Web Image 19.11**).
- ii) *Plexiform pattern* is the next common pattern.
- iii) *Acanthomatous pattern* is squamous metaplasia within the islands of tumour cells.

- 448 iv) *Basal cell pattern* of ameloblastoma is similar to basal cell carcinoma of the skin.
v) *Granular cell pattern* is characterised by appearance of acidophilic granularity in the cytoplasm of tumour cells.

Odontogenic Adenomatoid Tumour (Adeno-ameloblastoma) (p. 532)

This is a benign tumour seen more often in females in their 2nd decade of life. The tumour is commonly associated with an unerupted tooth and thus closely resembles dentigerous cyst radiologically. Unlike ameloblastoma, adenomatoid odontogenic tumour is not invasive nor does it recur after enucleation.

Calcifying Epithelial Odontogenic Tumour (p. 532)

This is a rare lesion which is locally invasive and recurrent like ameloblastoma. It is seen commonly in 4th and 5th decades and occurs more commonly in the region of mandible.

Odontogenic Myxoma (Myxofibroma) (p. 532)

Odontogenic myxoma is a locally invasive and recurring tumour.

Ameloblastic Fibroma (p. 532)

This is a benign tumour consisting of epithelial and connective tissues derived from odontogenic apparatus. It resembles ameloblastoma but can be distinguished from it because ameloblastic fibroma occurs in younger age group (below 20 years) and the clinical behaviour is always benign.

Odontomas (p. 532)

Odontomas are hamartomas that contain both epithelial and mesodermal dental tissue components. There are 3 subtypes:

- i) Complex odontoma
- ii) Compound odontoma
- iii) Ameloblastic fibro-odontoma .

Cementomas (p. 532)

Cementomas are a variety of benign lesions which are characterised by the presence of cementum or cementum-like tissue. Five types of cementomas are described:

- i) Benign cementoblastoma (true cementoma)
- ii) Cementifying fibroma
- iii) Periapical cemental dysplasia (Periapical fibrous dysplasia)
- iv) Multiple apical cementomas
- v) Gigantiform cementoma.

B. MALIGNANT ODONTOGENIC TUMOURS (p. 532)

Odontogenic Carcinoma (p. 532)

- i) *Malignant ameloblastoma* is the term used for the uncommon metastasising ameloblastic.
- ii) *Ameloblastic carcinoma* is the term employed for the ameloblastic tumour having cytologic features of malignancy in the primary tumour.
- iii) *Primary intraosseous carcinoma* may develop within the jaw from the rests of odontogenic epithelium.
- iv) Rarely, carcinomas may arise from the odontogenic epithelium lining the *odontogenic cysts*.

Odontogenic Sarcomas (p. 532)

The only example of odontogenic sarcoma is a rare ameloblastic fibrosarcoma.

□ **NORMAL STRUCTURE** (p. 533)

There are two main groups of salivary glands—major and minor. The major salivary glands are the three paired glands: parotid, submandibular and sublingual. The minor salivary glands are numerous and are widely distributed in the mucosa of oral cavity.

M/E The salivary glands are tubuloalveolar glands and may contain mucous cells, serous cells, or both.

The secretory acini of the major salivary glands are drained by ducts lined by:

- ◆ low cuboidal epithelium in the intercalated portion,
- ◆ tall columnar epithelium in the intralobular ducts, and
- ◆ simpler epithelium in the secretory ducts.

The product of major salivary glands is *saliva* which performs various functions such as lubrication for swallowing and speech, and has enzyme amylase and antibacterial properties too.

□ **SALIVARY FLOW DISTURBANCES** (p. 533)

SIALORRHOEA (PTYALISM). Increased flow of saliva is termed sialorrhoea or ptyalism. It occurs commonly due to: stomatitis, teething, mentally retarded state, schizophrenia, neurological disturbances, increased gastric secretion and sialosis (i.e. uniform, symmetric, painless hypertrophy of salivary glands).

XEROSTOMIA. Decreased salivary flow is termed xerostomia. It is associated with the following conditions: Sjögren's syndrome, sarcoidosis, mumps parotitis, Mikulicz's syndrome, megaloblastic anaemia, dehydration, drug intake (e.g. antihistamines, antihypertensives, antidepressants).

□ **SIALADENITIS** (p. 533)

ETIOLOGY. Sialadenitis can occur due to the following causes:

1. Viral infections. The most common inflammatory lesion of the salivary glands particularly of the parotid glands, is mumps occurring in children of school-age. It is characterised by triad of pathological involvement—*epidemic parotitis (mumps), orchitis-oophoritis, and pancreatitis (Web Image 19.12).*

2. Bacterial and mycotic infections. Bacterial infections may cause acute sialadenitis more often. Sometimes there are recurrent attacks of acute parotitis when parotitis becomes chronic.

i) **Acute sialadenitis:**

- a) Acute infectious fevers
- b) Acute postoperative parotitis (ascent of microorganisms up the parotid duct from the mouth)
- c) General debility
- d) Old age
- e) Dehydration.

ii) **Chronic sialadenitis:**

- a) *Recurrent obstructive type.* Recurrent obstruction due to calculi (sialolithiasis), stricture, surgery, injury etc. may cause repeated attacks of acute sialadenitis by ascending infection and then chronicity.
- b) *Recurrent non-obstructive type.* Recurrent mild ascending infection of the parotid gland may occur due to non-obstructive causes which reduce

450 salivary secretion like due to intake of drugs causing hyposalivation (e.g. antihistamines, antihypertensives, antidepressants), effect of irradiation and congenital malformations of the duct system.

c) *Chronic inflammatory diseases.* Tuberculosis, actinomycosis and other mycoses may rarely occur in the salivary glands.

3. Autoimmune disease. Inflammatory changes are seen in salivary glands in 2 autoimmune diseases:

i) *Sjögren's syndrome* characterised by triad of dry eyes (keratoconjunctivitis sicca), dry mouth (xerostomia) and rheumatoid arthritis.

ii) *Mikulicz's syndrome* is the combination of inflammatory enlargement of salivary and lacrimal glands with xerostomia.

MORPHOLOGIC FEATURES. Late chronic cases may be replaced by firm fibrous swelling.

M/E *Acute viral sialadenitis* in mumps shows swelling and cytoplasmic vacuolation of the acinar epithelial cells and degenerative changes in the ductal epithelium. There is interstitial oedema, fibrinoid degeneration of the collagen and dense infiltration by mononuclear cells (lymphocytes, plasma cells and macrophages). *Chronic and recurrent sialadenitis* is characterised by increased lymphoid tissue in the interstitium, progressive loss of secretory tissue and replacement by fibrosis.

□ TUMOURS OF SALIVARY GLANDS (p. 534)

The major as well as minor salivary glands can give rise to a variety of benign and malignant tumours (**Web Table 19.6**). The major glands, particularly the parotid glands (85%), are the most common sites. Majority of parotid gland tumour (65-85%) are benign, while in the other major and minor salivary glands 35-50% of the tumours are malignant. Most of the salivary gland tumours originate from the ductal lining epithelium and the underlying myoepithelial cells; a few arise from acini. Recurrent tumours of the parotid glands, due to their location, are often associated with facial palsy and obvious scarring following surgical treatment.

A. BENIGN SALIVARY GLAND TUMOURS (p. 534)

ADENOMAS (p. 534)

The adenomas of the salivary glands are benign epithelial tumours. They are broadly classified into 2 major groups—pleomorphic and monomorphic adenomas.

Pleomorphic Adenoma (Mixed Salivary Tumour) (p. 534)

This is the most common tumour of major (60-75%) and minor (50%) salivary glands. Pleomorphic adenoma is the commonest tumour in the parotid gland and occurs less often in other major and minor salivary glands. The tumour is commoner in women and is seen more frequently in 3rd to 5th decades of life. The tumour is solitary, smooth-surfaced but sometimes nodular, painless and slow-growing. It is often located below and in front of the ear (**Web Image 19.13**).

G/A Pleomorphic adenoma is a circumscribed, pseudoencapsulated, rounded, at times multilobulated, firm mass, 2-5 cm in diameter, with bosselated surface. The cut surface is grey-white and bluish, variegated, semitranslucent, usually solid but occasionally may show small cystic spaces. The consistency is soft and mucoid.

M/E The pleomorphic adenoma is characterised by pleomorphic or 'mixed' appearance in which there are epithelial elements present in a matrix of mucoid, myxoid and chondroid tissue (**Web Image 19.14**):

◆ **Epithelial component** may form various patterns like ducts, acini, tubules, sheets and strands of cells of ductal or myoepithelial origin. The

ductal cells are cuboidal or columnar, while the underlying myoepithelial cells may be polygonal or spindle-shaped resembling smooth muscle cells.

◆ **Mesenchymal elements** are present as loose connective tissue, and as myxoid, mucoid and chondroid matrix, which simulates cartilage (*pseudocartilage*) but is actually connective tissue mucin. The matrix of the tumour has been characterised as a product of myoepithelial cells as seen by S-100 immunostain positivity.

PROGNOSIS. Pleomorphic adenoma is notorious for recurrences, sometimes after many years. The main factors responsible for the tendency to recur are incomplete surgical removal due to proximity to the facial nerve, multiple foci of tumour, pseudoencapsulation, and implantation in the surgical field.

Monomorphic Adenomas (p. 534)

WARTHIN'S TUMOUR (PAPILLARY CYSTADENOMA LYMPHOMATOSUM, ADENOLYMPHOMA). It is a benign tumour of the parotid gland comprising about 8% of all parotid neoplasms, seen more commonly in men from 4th to 7th decades of life. Rarely, it may arise in the submandibular gland or in minor salivary glands. *Histogenesis* of the tumour has been much debated; most accepted theory is that the tumour develops from parotid ductal epithelium present in lymph nodes adjacent to or within parotid gland.

G/A The tumour is encapsulated, round or oval with smooth surface. The cut surface shows characteristic slit-like or cystic spaces, containing milky fluid and having papillary projections.

M/E The tumour shows 2 components: (**Web Image 19.15**):

◆ **Epithelial parenchyma** is composed of glandular and cystic structures having papillary arrangement and is lined by characteristic eosinophilic epithelium. Variants of epithelial patterns include presence of mucous goblet cells and sebaceous differentiation.

◆ **Lymphoid stroma** is present under the epithelium in the form of prominent lymphoid tissue, often with germinal centres.

OXYPHIL ADENOMA (ONCOCYTOMA). It is a benign slow-growing tumour of the major salivary glands. The tumour consists of parallel sheets, acini or tubules of large cells with glandular eosinophilic cytoplasm (oncocytes).

OTHER TYPES OF MONOMORPHIC ADENOMAS. There are some uncommon forms of monomorphic adenomas, e.g.: (i) Myoepithelioma, (ii) Basal cell adenoma and (iii) Clear cell adenoma.

B. MALIGNANT SALIVARY GLAND TUMOURS (p. 536)

Mucoepidermoid Carcinoma (p. 536)

The status of 'mucoepidermoid tumour' as an intermediate grade tumour in the previous classification has undergone upgradation to mucoepidermoid carcinoma now having the following peculiar features:

◆ It is the most *common malignant* salivary gland tumour (both in the major and minor glands).

◆ The *parotid gland* amongst the major salivary glands and the minor salivary glands in the *palate* are the most common sites.

◆ Common age group affected is 30-60 years but it is also the most common malignant salivary gland tumour affecting *children and adolescents*.

◆ It is the most common example of *radiation-induced* malignant tumour, especially therapeutic radiation.

G/A The tumour is usually circumscribed but not encapsulated. It varies in size from 1 to 4 cm.

M/E The tumour is classified into low, intermediate and high grade depending upon the degree of differentiation and tumour invasiveness. The tumour is

452 composed of combination of 4 types of cells: mucin-producing, squamous, intermediate and clear cells. Well-differentiated tumours have predominance of mucinous cells, while poorly differentiated have more solid and infiltrative pattern (**Web Image 19.16**).

Malignant Mixed Tumour (p. 537)

Malignant mixed tumour comprises three distinct clinicopathologic entities:

- ◆ Carcinoma arising in benign mixed salivary gland tumour (carcinoma ex pleomorphic adenoma);
- ◆ Carcinosarcoma; and
- ◆ Metastasising mixed salivary tumour.

Carcinoma ex pleomorphic adenoma is more common while the other two are rare tumours. Approximately 2 to 5% of pleomorphic adenomas reveal areas of frank malignancy. The slow-growing adenoma may have been present for a number of years when suddenly it undergoes rapid increase in its size, becomes painful and the individual may develop facial palsy.

G/A The tumour is poorly-circumscribed with irregular infiltrating margin. Cut section may show haemorrhages, necrosis and cystic degeneration.

M/E Besides the typical appearance of pleomorphic adenoma, malignant areas show cytologic features of carcinoma such as anaplasia, nuclear hyperchromatism, large nucleolisation, mitoses and evidence of invasive growth. All types of usual salivary gland carcinomas may develop in pleomorphic adenoma.

Adenoid Cystic Carcinoma (Cylindroma) (p. 537)

This is a highly malignant tumour due to its typical infiltrative nature, especially along the nerve sheaths. Adenoid cystic carcinoma is histologically characterised by cribriform appearance i.e. the epithelial tumour cells of duct-lining and myoepithelial cells are arranged in duct-like structures or masses of cells, having typical fenestrations or cyst-like spaces and hence the name 'adenoid cystic'. These cystic spaces contain PAS-positive basophilic material (**Web Image 19.17**).

Acinic Cell Carcinoma (p. 537)

This is a rare tumour composed of acinic cells resembling serous cells of normal salivary gland. These cells are arranged in sheets or acini and have characteristic basophilic granular cytoplasm. The degree of atypia may vary from a benign cytologic appearance to cellular features of malignancy.

Adenocarcinoma (p. 537)

Adenocarcinoma of the salivary gland does not differ from adenocarcinoma elsewhere in the body. It may have some variants such as mucoid adenocarcinoma, clear-cell adenocarcinoma and papillary cystadenocarcinoma.

Epidermoid Carcinoma (p. 537)

This rare tumour has features of squamous cell carcinoma with keratin formation and has intercellular bridges. The tumour commonly infiltrates the skin and involves the facial nerve early.

Undifferentiated Carcinoma (p. 537)

This highly malignant tumour consists of anaplastic epithelial cells which are too poorly differentiated to be placed in any other known category.

1. **The following tissues are lined by keratinised stratified squamous epithelium except:**
 - A. Hard palate
 - B. Soft palate
 - C. Lips
 - D. Gingiva
2. **Fordyce's granules are composed of the following:**
 - A. Sebaceous glands
 - B. Sweat glands
 - C. Fibrous tissue
 - D. Epithelial hyperplasia
3. **Patients of AIDS have the following type of oral leukoplakia:**
 - A. Speckled
 - B. Nodular
 - C. Hairly
 - D. Wrinkled
4. **The most common gross pattern of carcinoma of oral cavity is:**
 - A. Papillary
 - B. Nodular
 - C. Ulcerative
 - D. Scirrhus
5. **The following type of dental cyst is more often associated with development of ameloblastoma:**
 - A. Radicular cyst
 - B. Dentigerous cyst
 - C. Primordial cyst
 - D. Gingival cysts
6. **Which of the following conditions is not associated with oral pigmentation?**
 - A. Addison's disease
 - B. Lichen planus
 - C. Albright syndrome
 - D. Haemochromatosis
7. **The pseudocartilage or matrix in mixed salivary tumour is a product of:**
 - A. Connective tissue mucin
 - B. Ductal epithelial cell origin
 - C. Myoepithelial cell origin
 - D. Combination of all mucins
8. **Most common malignant salivary gland tumour is:**
 - A. Malignant mixed tumour
 - B. Mucoepidermoid carcinoma
 - C. Adenoid cyst carcinoma
 - D. Adenocarcinoma
9. **The most common malignant salivary gland tumour in children is:**
 - A. Acinic cell tumour
 - B. Adenoid cystic carcinoma
 - C. Mucoepidermoid carcinoma
 - D. Adenocarcinoma
10. **Malignant salivary gland tumour that commonly spreads along the nerves is:**
 - A. Malignant mixed salivary tumour
 - B. Mucoepidermoid carcinoma
 - C. Acinic cell carcinoma
 - D. Adenoid cystic carcinoma
11. **All of the following have strong association with oral squamous cell carcinoma except:**
 - A. Tobacco smoking
 - B. Chronic alcoholism
 - C. Submucosal fibrosis
 - D. HPV 16 and 18
12. **Secondary dentin is:**
 - A. Reaction of the tooth to carious process
 - B. Mature form of dentin
 - C. Dentin formed with aging
 - D. Mineralised primary dentin
13. **Most common cyst arising from dental tissues is:**
 - A. Radicular cyst
 - B. Dentigerous cyst
 - C. Eruption cyst
 - D. Gingival cyst

- 454 14. All the following are patterns of ameloblastoma *except*:
- A. Follicular
 - B. Plexiform
 - C. Granular
 - D. Spindle

KEY

1 = B	2 = A	3 = C	4 = C
5 = B	6 = B	7 = C	8 = B
9 = C	10 = D	11 = C	12 = A
13 = A	14 = D		



The Gastrointestinal Tract

□ NORMAL STRUCTURE (p. 538)

The oesophagus is a muscular tube extending from the pharynx to the stomach. In an adult, this distance measures 25 cm. However, from the clinical point of view, the distance from the incisor teeth to the gastro-oesophageal (GE) junction is about 40 cm. The region of proximal oesophagus at the level of cricopharyngeus muscle is called the *upper oesophageal sphincter*, while the portion adjacent to the anatomic gastro-oesophageal junction is referred to as *lower oesophageal sphincter*.

M/E The wall of the oesophagus consists of mucosa, submucosa, muscularis propria and adventitia/serosa.

- ◆ The **mucosa** is composed of non-keratinising stratified squamous epithelium overlying lamina propria except at the lower end for a distance of 0.5 to 1.5 cm. At the lower end of the oesophagus, there is sudden change from stratified squamous epithelium to mucin-secreting columnar epithelium; this is called the *junctional mucosa*.

- ◆ The **submucosa** consists of loose connective tissue with sprinkling of lymphocytes, plasma cells, and occasional eosinophil and mast cell.

- ◆ The **muscularis propria** is composed of 2 layers of smooth muscle—an inner circular coat and an outer longitudinal coat.

- ◆ The **adventitia/serosa** is the outer covering of oesophagus. Serosa is present in intra-abdominal part of oesophagus only, while elsewhere the perioesophageal adventitia covers it.

□ CONGENITAL ANOMALIES (p. 538)

OESOPHAGEAL ATRESIA AND TRACHEO-OESOPHAGEAL FISTULA.

In about 85% of cases, congenital atresia of the oesophagus is associated with tracheo-oesophageal fistula, usually at the level of tracheal bifurcation. For survival, the condition must be recognised and corrected surgically within 48 hours of birth of the newborn. Clinically, the condition is characterised by regurgitation of every feed, hypersalivation, attacks of cough and cyanosis. Death usually results from asphyxia, aspiration pneumonia and fluid-electrolyte imbalance.

□ MUSCULAR DYSFUNCTIONS (p. 538)

ACHALASIA (CARDIOSPASM) (p. 538)

Achalasia of the oesophagus is a neuromuscular dysfunction due to which the cardiac sphincter fails to relax during swallowing and results in progressive dysphagia and dilatation of the oesophagus (*mega-oesophagus*).

ETIOLOGY. There is loss of intramural neurons in the wall of the oesophagus. Most cases are of primary idiopathic achalasia which may be congenital. Secondary achalasia may occur from some other causes which includes: Chagas' disease (an epidemic parasitosis with *Trypanosoma cruzi*), infiltration into oesophagus by gastric carcinoma or lymphoma, certain viral infections, and neurodegenerative diseases.

456 MORPHOLOGIC FEATURES. There is dilatation above the short contracted terminal segment of the oesophagus. Muscularis propria of the wall may be of normal thickness, hypertrophied as a result of obstruction, or thinned out due to dilatation.

HIATUS HERNIA (p. 538)

Hiatus hernia is the herniation or protrusion of part of the stomach through the oesophageal hiatus of the diaphragm. Oesophageal hiatal hernia is the cause of diaphragmatic hernia in 98% of cases. The condition is diagnosed radiologically in about 5% of apparently normal asymptomatic individuals. In symptomatic cases, especially the elderly women, the clinical features are heartburn (retrosternal burning sensation) and regurgitation of gastric juice into the mouth.

ETIOLOGY. The basic defect is the failure of the muscle fibres of the diaphragm that form the margin of the oesophageal hiatus. This occurs due to shortening of the oesophagus which may be congenital or acquired.

◆ **Congenitally short oesophagus** may be the cause of hiatus hernia in a small proportion of cases.

◆ More commonly, it is **acquired** due to secondary factors which cause fibrous scarring of the oesophagus as follows:

- Degeneration of muscle due to aging.
- Increased intra-abdominal pressure such as in pregnancy, abdominal tumours etc.
- Recurrent oesophageal regurgitation and spasm causing inflammation and fibrosis.
- Increase in fatty tissue in obese people causing decreased muscular elasticity of diaphragm.

MORPHOLOGIC FEATURES. There are 3 patterns in hiatus hernia (**Web Image 20.1**):

i) **Sliding or oesophago-gastric hernia** is the most common, occurring in 85% of cases. The herniated part of the stomach appears as supradiaphragmatic bell due to sliding up on both sides of the oesophagus.

ii) **Rolling or para-oesophageal hernia** is seen in 10% of cases. This is a true hernia in which cardiac end of the stomach rolls up para-oesophageally, producing an intrathoracic sac.

iii) **Mixed or transitional hernia** constitutes the remaining 5% cases in which there is combination of sliding and rolling hiatus hernia.

OESOPHAGEAL DIVERTICULA (p. 539)

Diverticula are the outpouchings of oesophageal wall at the point of weakness. They may be congenital or acquired.

◆ **Congenital diverticula** occur either at the upper end of the oesophagus or at the bifurcation of trachea.

◆ **Acquired diverticula** may be of 2 types:

a) **Pulsion (Zenker's) type**—is seen in the region of hypopharynx and occurs due to oesophageal obstruction such as due to chronic oesophagitis, carcinoma etc.

b) **Traction type**—occurs in the lower third of oesophagus from contraction of fibrous tissue such as from pleural adhesions, scar tissue of healed tuberculous lesions in the hilum, silicosis etc.

OESOPHAGEAL WEBS AND RINGS (p. 539)

WEBS. Those located in the upper oesophagus, seen more commonly in adult women, and associated with dysphagia, iron deficiency anaemia and chronic atrophic glossitis (Plummer-Vinson syndrome) are called 'webs'.

RINGS. Those located in the lower oesophagus, not associated with iron-deficiency anaemia, nor occurring in women alone, are referred to as 'Schatzki's rings'.

MORPHOLOGIC FEATURES. The rings and webs are transverse folds of mucosa and submucosa encircling the entire circumference, or are localised annular thickenings of the muscle (**Web Image 20.2**). These give characteristic radiological shadows.

□ **HAEMATEMESIS OF OESOPHAGEAL ORIGIN** (p. 539)

Massive haematemesis (vomiting of blood) may occur due to vascular lesions in the oesophagus. These lesions are as under:

1. OESOPHAGEAL VARICES. Oesophageal varices are tortuous, dilated and engorged oesophageal veins, seen along the longitudinal axis of oesophagus. They occur as a result of elevated pressure in the portal venous system, most commonly in cirrhosis of the liver (Chapter 22). Less common causes are: portal vein thrombosis, hepatic vein thrombosis (Budd-Chiari syndrome) and pylephlebitis.

2. MALLORY-WEISS SYNDROME. In this condition, there is lacerations of mucosa at the gastro-oesophageal junction following minor trauma such as by vomiting, retching or vigorous coughing.

3. RUPTURE OF THE OESOPHAGUS. Rupture of the oesophagus may occur following trauma, during oesophagoscopy, indirect injury (e.g. due to sudden acceleration and deceleration of the body) and spontaneous rupture (e.g. after overeating, extensive aerophagy etc).

4. OTHER CAUSES

- i) Bursting of aortic aneurysm into the lumen of oesophagus
- ii) Vascular erosion by malignant growth in the vicinity
- iii) Hiatus hernia
- iv) Oesophageal cancer
- v) Purpuras
- vi) Haemophilia.

□ **INFLAMMATORY LESIONS** (p. 540)

REFLUX (PEPTIC) OESOPHAGITIS (p. 540)

Reflux of the gastric juice is the commonest cause of oesophagitis.

PATHOGENESIS. Gastro-oesophageal reflux, to an extent, may occur in normal healthy individuals after meals and in early pregnancy. However, in some clinical conditions, the gastro-oesophageal reflux is excessive, resulting in inflammation of the lower oesophagus e.g: sliding hiatus hernia, chronic gastric and duodenal ulcers, nasogastric intubation, persistent vomiting, surgical vagotomy, neuropathy in alcoholics, diabetics and oesophagostomy.

Endoscopically, the demarcation between normal squamous and columnar epithelium at the junctional mucosa is lost. The affected distal oesophageal mucosa is red, erythematous, friable and bleeds on touch. In advanced cases, there are features of chronic disease such as nodularity, strictures, ulcerations and erosions.

M/E the reflux changes in the distal oesophagus include basal cell hyperplasia and deep elongation of the papillae touching close to the surface epithelium. Inflammatory changes vary according to the stage of the disease. *In early stage,* mucosa and submucosa are infiltrated by some polymorphs and eosinophils; *in chronic stage,* there is lymphocytic infiltration and fibrosis of all the layers of the oesophageal wall.

BARRETT'S OESOPHAGUS (p. 540)

This is a condition in which, following reflux oesophagitis, stratified squamous epithelium of the lower oesophagus is replaced by columnar epithelium

458 (columnar metaplasia). The condition is seen more commonly in later age and is caused by factors producing gastro-oesophageal reflux disease (described above). Barrett's oesophagus is a premalignant condition evolving sequentially from Barrett's epithelium (columnar metaplasia) → dysplasia → carcinoma *in situ* → oesophageal adenocarcinoma.

Endoscopically, The affected area is red and velvety. Hiatus hernia and peptic ulcer at squamocolumnar junction (Barrett's ulcer) are frequently associated.

M/E The most common finding is the replacement of squamous epithelium by metaplastic columnar cells. Barrett's oesophagus may be composed of intestinal epithelium, fundic gastric glands, or cardiac mucous glands (**Web Image 20.3**). Other cells present in the glands may be Paneth cells, goblet cells, chief cells, parietal cells, mucus-secreting cells and endocrine cells.

INFECTIOUS OESOPHAGITIS (p. 541)

A number of opportunistic infections in immunosuppressed individuals can cause oesophagitis. Some of these agents are: Candida (Monilial) oesophagitis, herpes simplex (Herpetic) oesophagitis, cytomegalovirus and tuberculosis.

OTHER CAUSES OF OESOPHAGITIS (p. 541)

- i) Eosinophilic oesophagitis caused by radiation, corrosives
- ii) Intake of certain drugs (anticholinergic drugs, doxycycline, tetracycline)
- iii) Ingestion of hot, irritating fluids
- iv) Crohn's disease
- v) Various vesiculobullous skin diseases.

TUMOURS OF OESOPHAGUS (p. 541)

CARCINOMA OF OESOPHAGUS (p. 541)

Carcinoma of the oesophagus is diagnosed late, after symptomatic oesophageal obstruction (dysphagia) has developed and the tumour has transgressed the anatomical limits of the organ. The tumour occurs more commonly in men over 50 years of age. Prognosis is dismal: with standard methods of therapy (surgical resection and/or irradiation), 70% of the patients die within one year of diagnosis. Five-year survival rate is 5-10%.

ETIOLOGY. Although exact etiology of carcinoma of the oesophagus is not known, a number of conditions and factors have been implicated as under:

1. Diet and personal habits:

- i) Heavy smoking
- ii) Alcohol consumption
- iii) Intake of foods contaminated with fungus
- iv) Nutritional deficiency of vitamins and trace elements.

2. Oesophageal disorders:

- i) Oesophagitis (especially Barrett's oesophagus in adenocarcinoma)
- ii) Achalasia
- iii) Hiatus hernia
- iv) Diverticula
- v) Plummer-Vinson syndrome.

3. Other factors:

- i) *Race*—more common in the Chinese and Japanese than in Western races; more frequent in blacks than whites.
- ii) *Family history*—association with tylosis (keratosis palmaris et plantaris).
- iii) *Genetic factors*—predisposition with coeliac disease, epidermolysis bullosa, tylosis.
- iv) *HPV infection*—is the recent addition in etiologic factors.

At molecular level, abnormality of *p53* tumour suppressor gene has been found associated with a number of above risk factors, notably with consumption of tobacco and alcohol, and in cases having proven Barrett's oesophagus.

MORPHOLOGIC FEATURES. Carcinoma of the oesophagus is mainly of 2 types—squamous cell (epidermoid) and adenocarcinoma. The sites of predilection for each of these 2 forms is shown in **Web Image 20.4,A**.

SQUAMOUS CELL (EPIDERMOID) CARCINOMA. Squamous cell or epidermoid carcinoma comprises 90% of primary oesophageal cancers. The disease occurs in 6th to 7th decades of life and is more common in men than women. The sites of predilection are the three areas of oesophageal constrictions. Half of the squamous cell carcinomas of oesophagus occur in the middle third, followed by lower third, and the upper third of oesophagus in that order of frequency.

G/A 3 types of patterns are recognised (**Web Image 20.4,B**):

- i) *Polypoid fungating type*
- ii) *Ulcerating type* (**Web Image 20.5, A**).
- iii) *Diffuse infiltrating type*.

M/E Majority of the squamous cell carcinomas of the oesophagus are well-differentiated or moderately-differentiated (**Web Image 20.5, B**). An exophytic, slow-growing, extremely well-differentiated variant, *verruccous squamous cell carcinoma*, has also been reported in the oesophagus.

ADENOCARCINOMA. Adenocarcinoma of the oesophagus constitutes less than 10% of primary oesophageal cancer. It occurs predominantly in men in their 4th to 5th decades. The common locations are lower and middle third of the oesophagus. These tumours have a strong and definite association with Barrett's oesophagus in which there are foci of gastric or intestinal type of epithelium.

G/A Oesophageal adenocarcinoma appears as nodular, elevated mass in the lower oesophagus.

M/E Adenocarcinoma of the oesophagus can have 3 patterns: (i) Intestinal type, (ii) Adenosquamous type, (iii) Adenoid cystic type.

OTHER CARCINOMAS. Besides the two main histological types of oesophageal cancer, a few other varieties are: Mucoepidermoid carcinoma, malignant melanoma, oat cell carcinoma, undifferentiated carcinoma, carcinosarcoma and secondary tumours.

SPREAD. The oesophageal cancer spreads locally as well as to distant sites.

- i) Local spread.** This is the most important mode of spread and is of great importance for surgical treatment. The local spread may occur in the transverse as well as longitudinal direction.
- ii) Lymphatic spread.** Submucosal lymphatic permeation may lead to multiple satellite nodules away from the main tumour.
- iii) Haematogenous spread.** Blood-borne metastases from the oesophageal cancer are rare, probably because the death occurs early due to invasion of important structures by other modes of spread. However, metastatic deposits by haematogenous route can occur in the lungs, liver and adrenals.

STOMACH (p. 543)

□ NORMAL STRUCTURE (p. 543)

The stomach is 'gland with cavity', extending from its junction with lower end of the oesophagus (cardia) to its junction with the duodenum (pylorus). The *lesser curvature* is inner concavity on the right, while the *greater curvature* is the outer convexity on the left side of the stomach.

The stomach has 5 anatomical regions (**Web Image 20.6**): (1) cardia, (2) fundus, (3) body, (4) pyloric antrum and (5) pylorus.

The mucosal folds in the region of the body and the fundus are loose (rugae), while the antral mucosa is somewhat flattened. *Gastric canal* is the relatively fixed portion of the pyloric antrum and the adjoining lesser curvature; it is the site for numerous pathological changes such as gastritis, peptic ulcer and gastric carcinoma.

The stomach receives its blood supply from the left gastric artery and the branches of the hepatic and splenic arteries with widespread anastomoses.

M/E The wall of the stomach consists of 4 layers—

1. **Serosa** is derived from the peritoneum which is deficient in the region of lesser and greater curvatures.
2. **Muscularis** consists of 3 layers of smooth muscle fibres—the outer longitudinal, the middle circular and the inner oblique.
3. **Submucosa** is a layer of loose fibroconnective tissue binding the mucosa to the muscularis loosely and contains branches of blood vessels, lymphatics and nerve plexuses and ganglion cells.
4. **Mucosa** consists of 2 layers—superficial and deep.

i) Superficial layer. It consists of a single layer of surface epithelium composed of regular, mucin-secreting, tall columnar cells with basal nuclei.

◆ *Cardiac mucosa* is the transition zone between the oesophageal squamous mucosa and the oxyntic mucosa of the fundus and body with which it gradually merges.

◆ *Oxyntic mucosa* lines both gastric fundus and body.

◆ *Antral mucosa* lines the pyloric antrum.

ii) Deep layer: It consists of glands that open into the bottom of the crypts. Depending upon the structure, these glands are of 3 types:

- a) *Glands of the cardia* are simple tubular or compound tubulo-racemose, lined by mucin secreting cells.
- b) *Glands of the body-fundus* are long, tubular and tightly packed which may be coiled or dilated. There are 4 types of cells present in the glands of body-fundic mucosa: Parietal (Oxyntic) cells, chief (Peptic) cells, mucin-secreting neck cells and endocrine (Kulchitsky or Enterochromaffin) cells.
- c) *Glands of the pylorus* are much longer than the body-fundic glands.

The secretory products of the gastric mucosa are the *gastric juice* and the *intrinsic factor*, required for absorption of vitamin B₁₂. The degree of gastric activity is correlated with the 'total parietal cell mass'. Injection of histamine can stimulate the production of acid component of the gastric juice, while the pepsin-secreting chief cells do not respond to histamine.

□ GASTRIC ANALYSIS (p. 544)

In various diseases of the stomach, the laboratory tests to measure gastric secretions (consisting of gastric acid, pepsin, mucus and intrinsic factor) and serum gastrin are of particular significance (**Web Table 20.1**).

A. TESTS FOR GASTRIC SECRETIONS (p. 544)

1. Tests for Gastric Acid Secretions (p. 544)

The conventional fractional test meal (FTM) has been totally superseded by newer tests. These tests are based on the principle of measuring basal acid output (BAO) and maximal acid output (MAO) produced by the stomach under the influence of a variety of stimulants, and then comparing the readings of BAO and MAO with the normal values.

The tests for gastric acid secretion are named after the stimulants used for MAO. Some of the commonly used substances are as under: (i) Histamine, (ii) histalog (betazole), (iii) pentagastrin (peptavlon), (iv) insulin meal (Hollander test) and (v) tubeless analysis.

SIGNIFICANCE

Normal value for BAO is 1.5-2.0 mEq 1-hour and for MAO is 12-40 mEq 1-hour. In gastric ulcer, the values of BAO and MAO are usually normal or slightly below normal.

Higher values are found in:

- ◆ duodenal ulcer;
- ◆ Zollinger-Ellison syndrome (gastrinoma); and
- ◆ anastomotic ulcer.

Low value or achlorhydria are observed in:

- ◆ pernicious anaemia (atrophic gastritis); and
- ◆ achlorhydria in the presence of gastric ulcer is highly suggestive of gastric malignancy.

2. Tests for Pepsin (p. 545)

Pepsin inhibitors are used for analysis of pepsin derived from pepsinogen for research purposes. The levels of pepsin are low in atrophic gastritis.

3. Tests for Mucus (p. 545)

Protein content of gastric mucus is measured, normal value being 1.8 mg/ml. The level is increased in chronic hypertrophic gastritis (Ménétrier's disease).

4. Test for Intrinsic Factor (p. 545)

Intrinsic factor (IF) is essential for vitamin B₁₂ absorption from the small intestine. In its absence, the absorption of vitamin B₁₂ is impaired as occurs in chronic atrophic gastritis and gastric atrophy. *Schilling test* is used for evaluation of patients with suspected pernicious anaemia but can also be used as a diagnostic test for pancreatic insufficiency resulting in impaired absorption of vitamin B₁₂ since gastric R-binder protein is not cleared from intrinsic factor due to reduced pancreatic proteolytic activity.

B. TESTS FOR GASTRIN (p. 545)**1. Serum Gastrin Levels (p. 545)**

Radioimmunoassay (RIA) is the commonly used method of measurement of serum gastrin levels. Normal fasting values are 20-150 pg/ml. The levels are high in:

- ◆ atrophic gastritis (with low gastric acid secretion);
- ◆ Zollinger-Ellison syndrome or gastrinoma (with high gastric acid secretion); and
- ◆ following surgery on the stomach.

2. Gastrin Provocation Tests (p. 545)

i) SECRETIN TEST. An intravenous injection of secretin (1 unit/kg body weight) is given. If the serum gastrin levels rise by more than 50% of basal value in 5-15 minutes, it is diagnostic of Zollinger-Ellison syndrome (gastrinoma). This rise does not occur in other conditions.

ii) CALCIUM INFUSION TEST. Intravenous infusion of calcium (5 mg/kg per hour) is given for 3 hour. Rise in serum gastrin levels by more than 50% of basal value is diagnostic of Zollinger-Ellison syndrome (gastrinoma).

□ CONGENITAL ANOMALIES (p. 545)**PANCREATIC HETEROTOPIA (p. 545)**

Heterotopic pancreatic tissue may present clinically as a gastric mass or may be an incidental finding. Symptomatic cases may present in newborn or later in life.

462 G/A It is seen as a mass projecting into the gastric lumen, generally in the region of submucosa and less often in the muscular layer. In most cases, the mass is located in the region of antrum or pylorus.

M/E Both normal mature pancreatic acinar and ductal tissue are seen. Islets are seen in about a third of cases.

PYLORIC STENOSIS (p. 546)

Hypertrophy and narrowing of the pyloric lumen occurs predominantly in male children as a congenital defect (*infantile pyloric stenosis*). The *adult form* is rarely seen, either as a result of late manifestation of mild congenital anomaly or may be acquired type due to inflammatory fibrosis or invasion by tumours.

ETIOLOGY. The exact cause of *congenital (infantile)* pyloric stenosis is not known but it appears to have familial clustering and recessive genetic origin. The *acquired (adult)* pyloric stenosis is related to antral gastritis, and tumours in the region (gastric carcinoma, lymphoma, pancreatic carcinoma).

G/A and M/E There is hypertrophy as well as hyperplasia of the circular layer of muscularis in the pyloric sphincter accompanied by mild degree of fibrosis (**Web Image 20.7**).

CLINICAL FEATURES. The patient, usually a first born male infant 3 to 6 weeks old, presents with the following clinical features:

1. Vomiting, which may be projectile and occasionally contains bile or blood.
2. Visible peristalsis, usually noticed from left to right side of the upper abdomen.
3. Palpable lump, better felt after an episode of vomiting.
4. Constipation.
5. Loss of weight.

MISCELLANEOUS ACQUIRED CONDITIONS (p. 546)

BEZOARS (p. 546)

Bezoars are foreign bodies in the stomach, usually in patients with mental illness who chew these substances e.g.

- ◆ *Trichobezoars* composed of a ball of hair.
- ◆ *Phytobezoars* composed of vegetable fibres, seeds or fruit skin.
- ◆ *Trichophytobezoars* combining both hair and vegetable matter.

ACUTE DILATATION (p. 546)

Sudden and enormous dilatation of the stomach by gas or fluids due to paralysis of the gastric musculature may occur after abdominal operations, generalised peritonitis, and, in pyloric stenosis.

GASTRIC RUPTURE (p. 546)

The stomach may rupture rarely and prove fatal e.g. due to blunt trauma, external cardiac massage, ingestion of heavy meal or large quantity of liquid intake like beer.

INFLAMMATORY CONDITIONS (p. 546)

The two important inflammatory conditions of the stomach are *gastritis* and *peptic ulcer*. Rarely, stomach may be involved in tuberculosis, sarcoidosis and Crohn's disease.

GASTRITIS (p. 546)

The term 'gastritis' is commonly employed for any clinical condition with upper abdominal discomfort like indigestion or dyspepsia in which the specific clinical signs and radiological abnormalities are absent.

ACUTE GASTRITIS (p. 546)

Acute gastritis is a transient acute inflammatory involvement of the stomach, mainly mucosa.

ETIOPATHOGENESIS. A variety of etiologic agents have been implicated in the causation of acute gastritis. These are as follows:

1. Diet and personal habits:

- ◆ Highly spiced food
- ◆ Excessive alcohol consumption
- ◆ Malnutrition
- ◆ Heavy smoking.

2. Infections:

- ◆ *Bacterial infections* e.g. *Helicobacter pylori*, diphtheria, salmonellosis, pneumonia, staphylococcal food poisoning.
- ◆ *Viral infections* e.g. viral hepatitis, influenza, infectious mononucleosis.

3. Drugs:

- ◆ Intake of drugs like non-steroidal anti-inflammatory drugs (NSAIDs), aspirin, cortisone, phenylbutazone, indomethacin, preparations of iron, chemotherapeutic agents.

4. Chemical and physical agents:

- ◆ Intake of corrosive chemicals such as caustic soda, phenol, lysol
- ◆ Gastric irradiation
- ◆ Freezing.

5. Severe stress:

- ◆ Emotional factors like shock, anger, resentment etc.
- ◆ Extensive burns
- ◆ Trauma
- ◆ Surgery.

The mucosal injury and subsequent acute inflammation in acute gastritis occurs by one of the following mechanisms:

1. *Reduced blood flow*, resulting in mucosal hypoperfusion due to ischaemia.
2. *Increased acid secretion* and its accumulation due to *H. pylori* infection resulting in damage to epithelial barrier.
3. *Decreased production of bicarbonate buffer.*

G/A The gastric mucosa is oedematous with abundant mucus and haemorrhagic spots.

M/E Depending upon the stage, there is variable amount of oedema and infiltration by neutrophils in the lamina propria. In acute haemorrhagic and erosive gastritis, the mucosa is sloughed off and there are haemorrhages on the surface.

CHRONIC GASTRITIS (p. 547)

Chronic gastritis is the commonest histological change observed in biopsies from the stomach. The condition occurs more frequently with advancing age; average age for symptomatic chronic gastritis being 45 years which corresponds well with the age incidence of gastric ulcer.

ETIOPATHOGENESIS. All the causative factors of acute gastritis described above may result in chronic gastritis too. Recurrent attacks of acute gastritis may result in chronic gastritis. Some additional causes are as under:

1. Reflux of duodenal contents into the stomach
2. Infection with *H. pylori*
3. Associated disease of the stomach and duodenum
4. Chronic hypochromic anaemia
5. Immunological factors.

464 CLASSIFICATION. Based on the type of mucosa affected (i.e. cardiac, body, pyloric, antral or transitional), a clinicopathologic classification has been proposed (**Web Table 20.2**).

1. Type A gastritis (Autoimmune gastritis). Type A gastritis involves mainly the body-fundic mucosa. It is also called autoimmune gastritis due to the presence of circulating antibodies and is sometimes associated with other autoimmune diseases such as Hashimoto's thyroiditis and Addison's disease.

2. Type B gastritis (*H. pylori*-related). Type B gastritis mainly involves the region of antral mucosa and is more common. It is also called hypersecretory gastritis due to excessive secretion of acid, commonly due to infection with *H. pylori*.

3. Type AB gastritis (Mixed gastritis, Environmental gastritis, Chronic atrophic gastritis). Type AB gastritis affects the mucosal region of A as well as B types (body-fundic and antral mucosa). This is the most common type of gastritis in all age groups. It is also called environmental gastritis because a number of unidentified environmental factors have been implicated in its etiopathogenesis.

G/A The features of all forms of gastritis are inconclusive. The gastric mucosa may be normal, atrophied, or oedematous.

M/E Following simple morphologic classification has been proposed:

1. Chronic superficial gastritis
2. Chronic atrophic gastritis
3. Gastric atrophy
4. Chronic hypertrophic gastritis (Ménétrier's disease)
5. Uncommon forms of chronic gastritis.

However, *Sydney system* of recording of histologic changes in gastritis is more acceptable since it takes into account following multiple parameters as well:

- i) *Etiology* (*H. pylori*, autoimmune, NSAIDs, infections).
- ii) *Location* (pangastritis, predominant antral, predominant body-fundic).
- iii) *Morphology* (depth of inflammation—superficial or deep, severity of inflammation, type of inflammation, atrophy, metaplasia).
- iv) *Some special features* (e.g. granulomas, eosinophilic gastritis, erosions, necrosis, haemorrhages).

1. CHRONIC SUPERFICIAL GASTRITIS. As the name suggests there is inflammatory infiltrate consisting of plasma cells and lymphocytes in the superficial layer of the gastric mucosa, *but there are no histological changes in the deep layer of mucosa containing gastric glands*. Chronic superficial gastritis may resolve completely or may progress to chronic gastric atrophy.

H. pylori, a spiral-shaped bacteria, was first reported by Warren and Marshall in Australia in 1984 as inhabitant of the acid environment of the stomach causing gastritis. It is now known that *H. pylori* is causative for almost all active cases of chronic superficial gastritis and about 65% of quiescent cases. The organism is identified on the epithelial layer on the luminal surface and does not invade the mucosa (**Web Image 20.8**). It is not seen on areas with intestinal metaplasia. *H. pylori* gastritis can be diagnosed by the following techniques:

Although most patients of chronic superficial gastritis due to *H. pylori* remain asymptomatic, they may develop chronic atrophic gastritis, gastric atrophy, peptic ulcer disease. *H. pylori* infection is now considered an independent risk factor for gastric cancer: 3-6 fold increased risk for gastric adenocarcinoma and 6-50 times risk of MALT lymphoma (**Web Image 20.9**).

2. CHRONIC ATROPHIC GASTRITIS. In this stage, *there is inflammatory cell infiltrate in the deeper layer of the mucosa and atrophy of the epithelial elements including destruction of the glands*. Two types of metaplasia are commonly associated with atrophic gastritis:

i) Intestinal metaplasia. Intestinal metaplasia is more common and involves antral mucosa more frequently (**Web Image 20.10**). Intestinal metaplasia, focal or extensive, in atrophic gastritis is significant because its incidence is high in populations having high prevalence rate of gastric cancer like in Japan. However, areas of intestinal metaplasia are not colonised by *H. pylori*.

ii) Pseudopyloric metaplasia. It involves the body glands which are replaced by proliferated mucus neck cells, conforming in appearance to normal pyloric glands.

3. GASTRIC ATROPHY. In this, there is thinning of the gastric mucosa with loss of glands but no inflammation though lymphoid aggregates may be present.

4. CHRONIC HYPERTROPHIC GASTRITIS (MÉNÉTRIER'S DISEASE). This is an uncommon condition characterised pathologically by enormous thickening of gastric rugal folds resembling cerebral convolutions, affecting mainly the region of fundic-body mucosa and characteristically sparing antral mucosa.

M/E The gastric pits are elongated and are tortuous. The mucosa is markedly thickened and parts of muscularis mucosae may extend into the thickened folds. The condition is considered significant in view of the risk of developing cancer.

5. MISCELLANEOUS FORMS OF CHRONIC GASTRITIS. A few other types of gastritis which do not fit into the description of the types of gastritis described above are as under:

i) Eosinophilic gastritis, ii) Chronic follicular gastritis, iii) Haemorrhagic (Erosive) gastritis, iv) Granulomatous gastritis.

PEPTIC ULCERS (p. 549)

Peptic ulcers are the areas of degeneration and necrosis of gastrointestinal mucosa exposed to acid-peptic secretions. Though they can occur at any level of the alimentary tract that is exposed to hydrochloric acid and pepsin, they occur most commonly (98-99%) in either the duodenum or the stomach in the ratio of 4:1. Each of the two main types may be acute or chronic.

ACUTE PEPTIC (STRESS) ULCERS (p. 550)

Acute peptic ulcers or stress ulcers are multiple, small mucosal erosions, seen most commonly in the stomach but occasionally involving the duodenum.

ETIOLOGY. These ulcers occur following severe stress. The causes are as follows:

- i) *Psychological stress*
- ii) *Physiological stress* as in the following:
 - ◆ Shock
 - ◆ Severe trauma
 - ◆ Septicaemia
 - ◆ Extensive burns (Curling's ulcers in the posterior aspect of the first part of the duodenum).
 - ◆ Intracranial lesions (Cushing's ulcers developing from hyperacidity following excessive vagal stimulation).
 - ◆ Drug intake (e.g. aspirin, steroids, butazolidine, indomethacin).
 - ◆ Local irritants (e.g. alcohol, smoking, coffee etc).

PATHOGENESIS. It is not clear how the mucosal erosions occur in stress ulcers because actual hypersecretion of gastric acid is demonstrable in only Cushing's ulcers occurring from intracranial conditions such as due to brain trauma, intracranial surgery and brain tumours. In all other etiologic factors, gastric acid secretion is normal or below normal. In these conditions, the possible hypotheses for genesis of stress ulcers are as under:

1. Ischaemic hypoxic injury to the mucosal cells.
2. Depletion of the gastric mucus 'barrier' rendering the mucosa susceptible to attack by acid-peptic secretions.

G/A Acute stress ulcers are multiple (more than three ulcers in 75% of cases). They are more common anywhere in the stomach, followed in decreasing frequency by occurrence in the first part of duodenum. They may be oval or circular in shape, usually less than 1 cm in diameter.

M/E The stress ulcers are shallow and do not invade the muscular layer. The margins and base may show some inflammatory reaction depending upon the duration of the ulcers. These ulcers commonly heal by complete re-epithelialisation without leaving any scars. Complications such as haemorrhage and perforation may occur.

Chronic Peptic Ulcers (Gastric and Duodenal Ulcers) (p. 550)

If not specified, chronic peptic ulcers would mean gastric and duodenal ulcers, the two major forms of 'peptic ulcer disease' of the upper GI tract in which the acid-pepsin secretions are implicated in their pathogenesis. Peptic ulcers are common in the present-day life of the industrialised and civilised world.

Gastric and duodenal ulcers represent two distinct diseases as far as their etiology, pathogenesis and clinical features are concerned. However, morphological findings in both are similar and quite diagnostic. The features of gastric and duodenal peptic ulcers are described together below while their contrasting features are presented in **Web Table 20.3**.

INCIDENCE. Peptic ulcers are more frequent in middle-aged adults. The peak incidence for duodenal ulcer is 5th decade, while for gastric ulcer it is a decade later (6th decade). Duodenal as well as gastric ulcers are more common in males than in females. Duodenal ulcer is almost four times more common than gastric ulcer; the overall incidence of gastroduodenal ulcers being approximately 10% of the male population.

ETIOLOGY. The immediate cause of peptic ulcer disease is disturbance in normal protective mucosal 'barrier' by acid-pepsin, resulting in digestion of the mucosa. However, in contrast to duodenal ulcers, *the patients of gastric ulcer have low-to-normal gastric acid secretions, though true achlorhydria in response to stimulants never occurs in benign gastric ulcer.* These factors are discussed below but the first two—*H. pylori* gastritis and NSAIDs-induced injury are considered most important.

1. ***Helicobacter pylori* gastritis.** About 15-20% cases infected with *H. pylori* in the antrum develop duodenal ulcer in their life time while gastric colonisation by *H. pylori* never develops ulceration and remain asymptomatic. *H. pylori* can be identified in mucosal samples by histologic examination, culture and serology.
2. **NSAIDs-induced mucosal injury.** Non-steroidal anti-inflammatory drugs are most commonly used medications in the developed countries and are responsible for direct toxicity, endothelial damage and epithelial injury to both gastric as well as duodenal mucosa.
3. **Acid-pepsin secretions.** There is conclusive evidence that some level of acid-pepsin secretion is essential for the development of duodenal as well as gastric ulcer.
4. **Gastritis.** Some degree of gastritis is always present in the region of gastric ulcer, though it is not clear whether it is the cause or the effect of ulcer.
5. **Other local irritants.** Pyloric antrum and lesser curvature of the stomach are the sites most exposed for longer periods to local irritants and thus are the common sites for occurrence of gastric ulcers. Some of the local irritating substances implicated in the etiology of peptic ulcers are heavily spiced foods, alcohol, cigarette smoking, unbuffered aspirin.

6. Dietary factors. Nutritional deficiencies have been regarded as etiologic factors in peptic ulcers e.g. occurrence of gastric ulcer in poor socioeconomic strata, higher incidence of duodenal ulcer in parts of South India.

7. Psychological factors. Psychological stress, anxiety, fatigue and ulcer-type personality may exacerbate as well as predispose to peptic ulcer disease.

8. Genetic factors. People with blood group O appear to be more prone to develop peptic ulcers than those with other blood groups. Genetic influences appear to have greater role in duodenal ulcers as evidenced by their occurrence in families, monozygotic twins and association with HLA-B5 antigen.

9. Hormonal factors. Secretion of certain hormones by tumours is associated with peptic ulceration e.g. elaboration of gastrin by islet-cell tumour in Zollinger-Ellison syndrome, endocrine secretions in hyperplasia and adenomas of parathyroid glands.

10. Miscellaneous. Duodenal ulcers have been observed to occur in association with various other conditions such as alcoholic cirrhosis, chronic renal failure, hyperparathyroidism, chronic obstructive pulmonary disease, and chronic pancreatitis.

PATHOGENESIS. Although the role of various etiologic factors just described is well known in ulcerogenesis, two most important factors in peptic ulcer are as under:

- ◆ Exposure of mucosa to gastric acid and pepsin secretion.
- ◆ Strong etiologic association with *H. pylori* infection.

Duodenal ulcer. There is conclusive evidence to support the role of high acid-pepsin secretions in the causation of duodenal ulcers. Besides this, a few other noteworthy features in the pathogenesis of duodenal ulcers are as follows:

1. There is generally *hypersecretion of gastric acid* into the fasting stomach at night which takes place under the influence of vagal stimulation.
2. Patients of duodenal ulcer have *rapid emptying* of the stomach so that the food which normally buffers and neutralises the gastric acid, passes down into the small intestine, leaving the duodenal mucosa exposed to the aggressive action of gastric acid.
3. *Helicobacter gastritis* caused by *H. pylori* is seen in 95-100% cases of duodenal ulcers. The underlying mechanisms are as under:
 - i) Gastric *mucosal defense is broken* by bacterial elaboration of urease, protease, catalase and phospholipase.
 - ii) *Host factors:* *H. pylori*-infected mucosal epithelium releases *proinflammatory cytokines* such as IL-1, IL-6, IL-8 and tumour necrosis factor- α , all of which incite intense inflammatory reaction.
 - iii) *Bacterial factors:* Epithelial injury is also induced by cytotoxin-associated gene protein (*CagA*), while vacuolating cytotoxin (*VacA*) induces elaboration of cytokines.

Gastric ulcer. The pathogenesis of gastric ulcer is mainly explained on the basis of impaired gastric mucosal defenses against acid-pepsin secretions. Some other features in the pathogenesis of gastric ulcer are as follows:

1. Hyperacidity may occur in gastric ulcer due to *increased serum gastrin* levels in response to ingested food in an atonic stomach.
2. Ulcerogenesis in such patients is explained on the basis of damaging influence of *other factors* such as gastritis, bile reflux, cigarette smoke etc.
3. The normally protective *gastric mucus 'barrier'* against acid-pepsin is deranged in gastric ulcer. There is depletion in the quantity as well as quality of gastric mucus. One of the mechanisms for its depletion is colonisation of the gastric mucosa by *H. pylori* seen in 75-80% patients of gastric ulcer.

MORPHOLOGIC FEATURES. Gross and microscopic changes in gastric and duodenal ulcers are similar and quite characteristic. *Gastric ulcers* are

468 found predominantly along the lesser curvature in the region of pyloric antrum, more commonly on the posterior than the anterior wall. Most *duodenal ulcers* are found in the first part of the duodenum, usually immediate post-pyloric, more commonly on the anterior than the posterior wall. Uncommon locations include ulcer in the cardia, marginal ulcer and in the Meckel's diverticulum (**Web Image 20.11**).

G/A Typical peptic ulcers are commonly solitary (80%), small (1-2.5 cm in diameter), round to oval and characteristically 'punched out'. Benign ulcers usually have flat margins in level with the surrounding mucosa. The mucosal folds converge towards the ulcer. The ulcers may vary in depth from being superficial (confined to mucosa) to deep ulcers (penetrating into the muscular layer) (**Web Image 20.12**). *Chronic duodenal ulcer never turns malignant*, while chronic gastric ulcer may develop carcinoma in less than 1% of cases. Malignant gastric ulcers are larger, bowl-shaped with elevated and indurated mucosa at the margin (**Web Image 20.13**).

M/E Chronic peptic ulcers have 4 histological zones. From within outside, these are as under (**Web Image 20.14**):

1) Necrotic zone, 2) Superficial exudative zone, 3) Granulation tissue zone and 4) Zone of cicatrisation.

COMPLICATIONS. Acute and subacute peptic ulcers usually heal without leaving any visible scar. However, healing of chronic, larger and deeper ulcers may result in complications. These are as follows: 1) Obstruction, 2) Haemorrhage, 3) Perforation and 4) Malignant transformation.

CLINICAL FEATURES. Peptic ulcers are remitting and relapsing lesions. Their chronic and recurrent behaviour is summed up the saying: '*once a peptic ulcer patient, always a peptic ulcer patient.*' The two major forms of chronic peptic ulcers show variations in clinical features which are as follows:

- 1. Age.** The peak incidence of duodenal ulcer is in 5th decade while that for gastric ulcer is a decade later.
- 2. People at risk.** Duodenal ulcer occurs more commonly in people faced with more stress and strain of life (e.g. executives, leaders), while gastric ulcer is seen more often in labouring groups.
- 3. Periodicity.** The attacks in gastric ulcers last from 2-6 weeks, with interval of freedom from 1-6 months. The attacks of duodenal ulcer, are classically worsened by '*work, worry and weather.*'
- 4. Pain.** In gastric ulcer, epigastric pain occurs immediately or within 2 hours after food and never occurs at night. In duodenal ulcer, pain is severe, occurs late at night ('hunger pain') and is usually relieved by food.
- 5. Vomiting.** Vomiting which relieves the pain is a conspicuous feature in patients of gastric ulcer. Duodenal ulcer patients rarely have vomiting but instead get heart-burn (retrosternal pain) and 'water brash' (burning fluid into the mouth).
- 6. Haematemesis and melaena.** Haematemesis and melaena occur in gastric ulcers in the ratio of 60:40, while in duodenal ulcers in the ratio of 40:60.
- 7. Appetite.** The gastric ulcer patients, though have good appetite but are afraid to eat, while duodenal ulcer patients have very good appetite.
- 8. Diet.** Patients of gastric ulcer commonly get used to a bland diet consisting of milk, eggs etc and avoid taking fried foods, curries and heavily spiced foods. In contrast, duodenal ulcer patients usually take all kinds of diets.
- 9. Weight.** Loss of weight is a common finding in gastric ulcer patients while patients of duodenal ulcer tend to gain weight due to frequent ingestion of milk to avoid pain.

10. Deep tenderness. Deep tenderness is demonstrable in both types of peptic ulcers.

□ **HAEMATEMESIS AND MELAENA OF GASTRIC ORIGIN** (p. 554)

- i) Chronic peptic ulcers (gastric as well as duodenal)
- ii) Acute peptic ulcers (stress ulcers)
- iii) Multiple gastric and duodenal erosions
- iv) Carcinoma of the stomach
- v) Peptic ulcer in Meckel's diverticulum
- vi) Mallory-Weiss syndrome
- vii) Anaemias
- viii) Purpuras
- ix) Haemophilia.

□ **TUMOURS AND TUMOUR-LIKE LESIONS** (p. 554)

The various types of tumour-like lesions (polyps) and benign and malignant tumours of the stomach are given in **Web Table 20.4**.

A. TUMOUR-LIKE LESIONS (POLYPS) (p. 554)

Hyperplastic (Inflammatory) Polyps (p. 554)

Hyperplastic or inflammatory polyps are regenerative, non-neoplastic lesions which are the most common type (90%). They may be single or multiple and are more often located in the pyloric antrum.

G/A The lesions may be sessile or pedunculated, 1 cm or larger in size, smooth and soft. The surface may be ulcerated or haemorrhagic.

M/E They are composed of irregular hyperplastic glands, which may show cystic change. The lining epithelium is mostly superficial gastric type but antral glands, chief cells and parietal cells may be present.

Hamartomatous Polyps (p. 554)

Hamartomatous polyps are not true neoplasms but are malformations. They are of various types such as gastric polyps of the Peutz-Jeghers syndrome, juvenile polyp, pancreatic heterotopia, heterotopia of Brunner's glands and inflammatory fibroid polyps (eosinophilic granulomatous polyps).

B. BENIGN TUMOURS (p. 554)

Adenomas (Adenomatous or Neoplastic Polyps) (p. 554)

Adenomas, also, referred to as adenomatous or neoplastic polyps, are true benign epithelial neoplasms and are much rare in the stomach than in the large intestine. They are also found more often in the region of pyloric antrum. They are commonly associated with atrophic gastritis and pernicious anaemia.

Stromal Tumours (p. 554)

Stomach may be the site for occurrence of various uncommon benign tumours of stromal cell origin e.g. leiomyomas (being the most common); others are neurofibromas, schwannomas and lipomas. They are usually firm, circumscribed nodules, less than 4 cm in size and appear as submucosal nodules.

Currently, the term *gastrointestinal stromal tumours (GISTs)* is used for a group of uncommon benign tumours composed of spindle cells or stromal cells but lacking the true phenotypic features of smooth muscle cells, neural cells or Schwann cells. They are uncommon but as compared to other sites in the GIT, are most common in the stomach.

Gastric Carcinoma (p. 555)

INCIDENCE. Carcinoma of the stomach comprises more than 90% of all gastric malignancies and is the leading cause of cancer-related deaths in countries where its incidence is high. The highest incidence is between 4th to 6th decades of life and is twice more common in men than in women.

ETIOLOGY. A number of etiologic factors have been implicated in causation of gastric cancer. These are as under:

1. ***H. pylori* infection.** *H. pylori* infection of the stomach is an important risk factor for the development of gastric cancer. Epidemiologic studies throughout world have shown that a seropositivity with *H. pylori* is associated with 3 to 6 times higher risk of development of gastric cancer.

2. **Dietary factors.** Epidemiological studies suggest that dietary factors are most significant in the etiology of gastric cancer. The evidences in support of this are multifold:

- i) Occurrence of gastric cancer in the region of gastric canal (i.e. along the lesser curvature and the pyloric antrum) where irritating foods exert their maximum effect.
- ii) Populations consuming certain foodstuffs have high risk of developing gastric cancer e.g. ingestion of smoked foods, high intake of salt, pickled raw vegetables, high intake of carcinogens as nitrates in foods and drinking water, nitrites as preservatives for certain meats etc.
- iii) Tobacco smoke, tobacco juice and consumption of alcohol have all been shown to have carcinogenic effect on gastric mucosa.

3. **Geographical factors.** There are geographic variations in the incidence of gastric cancer. Japan, Chile and Italy have the highest recorded death rate from gastric cancer, while the incidence is considerably low in the US, UK and Canada.

4. **Racial factors.** Within the country, different ethnic groups may have variations in incidence of gastric cancer e.g. incidence is higher in Blacks, American Indians, Chinese in Indonesia, North Wales than other parts of Wales.

5. **Genetic factors.** Genetic influences have some role in the etiology of gastric cancer. Not more than 4% of patients of gastric cancer have a family history of this disease. Individuals with blood group A have higher tendency to develop gastric cancer

6. **Pre-malignant changes in the gastric mucosa.** There are some conditions of gastric mucosa which have increased risk to development of gastric cancer:

- i) Hypo- or achlorhydria in atrophic gastritis of gastric mucosa with intestinal metaplasia.
- ii) Adenomatous (neoplastic) polyps of the stomach.
- iii) Chronic gastric ulcer (ulcer-cancer), and its association with achlorhydria.
- iv) Stump carcinoma in patients who have undergone partial gastrectomy.

MORPHOLOGIC FEATURES. Gastric carcinoma is most commonly located in the region of gastric canal (prepyloric region) formed by lesser curvature, pylorus and antrum. Other less common locations are the body, cardia and fundus (**Web Image 20.15**).

Pathogenetically, a sequential evolution of all gastric carcinomas from an initial stage of *in situ* carcinoma confined to mucosal layers called early gastric carcinoma (EGC) has been found. Accordingly, gastric carcinomas are broadly classified into 2 main groups:

- I. **Early gastric carcinoma (EGC).**
- II. **Advanced gastric carcinoma**, which has 5 further major gross subtypes:
 - i) Ulcerative carcinoma
 - ii) Fungating (Polypoid) carcinoma

- iii) Scirrhus carcinoma (Linitis plastica)
- iv) Colloid (Muroid) carcinoma
- v) Ulcer-cancer

These classifications are summarised in **Web Image 20.16** and comparative morphology of various types is shown diagrammatically in **Web Image 20.18**.

I. EARLY GASTRIC CARCINOMA (EGC) (Web Image 20.18,A). EGC is the term used to describe cancer limited to the mucosa and submucosa. In Japan, EGC comprises 35% of newly-diagnosed cases of gastric cancer.

G/A The lesion of EGC may have 3 patterns—polypoid (protruded), superficial and ulcerated (**Web Image 20.17**):

M/E EGC is a typical glandular adenocarcinoma, usually well-differentiated type.

Prognosis of EGC after surgical resection is quite good; 5-year survival rate being 93-99%.

II. ADVANCED GASTRIC CARCINOMA. Advanced gastric carcinoma has following 5 patterns:

i) Ulcerative carcinoma (Web Image 20.18,B). This is the most common pattern. The tumour appears as a flat, infiltrating and ulcerative growth with irregular necrotic base and raised margin. It is seen more commonly in the region of gastric canal (**Web Image 20.19,A**).

M/E Ulcerative carcinomas are poorly-differentiated adenocarcinomas, which invade deeply into the stomach wall. Tubular and acinar patterns are seen more commonly (**Web Image 20.19, B**).

ii) Fungating (polypoid) carcinoma (Web Image 20.18,C). The second common pattern is a cauliflower growth projecting into the lumen, similar to what is commonly seen in the large intestine. It is seen more often in the fundus. The tumour undergoes necrosis and infection commonly.

M/E Fungating or polypoid carcinomas are well-differentiated adenocarcinomas, commonly papillary type.

iii) Scirrhus carcinoma (Linitis plastica) (Web Image 20.18,D). In this pattern, the stomach wall is thickened due to extensive desmoplasia giving the appearance as 'leather-bottle stomach' or 'linitis plastica'. The involvement may be localised to pyloric antrum, or diffuse affecting whole of the stomach from the cardia to pylorus. The lumen of the stomach is reduced (**Web Image 20.19,C**).

M/E It may be an adenocarcinoma or signet-ring cell carcinoma, extensively infiltrating the stomach wall, but due to marked desmoplasia cancer cells may be difficult to find (**Web Image 20.19,D**).

iv) Colloid (Muroid) carcinoma (Web Image 20.18,E). This pattern is usually seen in the fundus. The tumour grows like masses having gelatinous appearance due to secretion of large quantities of mucus.

M/E Muroid carcinoma contains abundant pools of mucin in which are seen a small number of tumour cells, sometimes having signet-ring appearance.

v) Ulcer-cancer (Web Image 20.18,F). Development of cancer in chronic gastric ulcer is a rare occurrence (less than 1%). Majority of ulcer-cancers are malignant lesions from the beginning.

M/E Ulcer-cancers are adenocarcinomas without any specific features. The differences between a benign and malignant gastric ulcer are summarised in **Web Table 20.5** (also see **Web Image 20.13**).

SPREAD. Carcinoma of the stomach may spread by the following routes:

1. Direct spread. Direct spread by local extension is the most common feature of gastric carcinoma. The spread occurs mainly from the loose submucosal layer but eventually muscularis and serosa are also invaded. After the peritoneal covering of the stomach has been invaded, transcoelomic

472 dissemination may occur in any other part of the peritoneal cavity but ovarian masses (one sided or both-sided) occur more commonly, referred to as *Krukenberg tumours*.

2. Lymphatic spread. Metastases to regional lymph nodes occur early, especially in the scirrhus carcinoma. The groups of lymph nodes involved are along the lesser and greater curvature around the cardia and suprapancreatic lymph nodes. Involvement of left supraclavicular lymph node, *Virchow or Troisier's sign*, is sometimes the presenting feature of gastric carcinoma.

3. Haematogenous spread. Blood spread of gastric carcinoma may occur to the liver, lungs, brain, bones, kidneys and adrenals. It occurs more commonly with the poorly-differentiated carcinoma.

CLINICAL FEATURES. i) Persistent abdominal pain, ii) Gastric distension and vomiting, iii) Loss of weight (cachexia), iv) Loss of appetite (anorexia) and v) Anaemia, weakness, malaise.

The most common complication of gastric cancer is haemorrhage (in the form of haematemesis and/or melaena); others are obstruction, perforation and jaundice.

Leiomyosarcoma (p. 559)

Leiomyosarcoma, though rare, is the commonest soft tissue sarcoma, the stomach being the more common site in the gastrointestinal tract.

Leiomyoblastoma (Epithelioid Leiomyoma) (p. 559)

This is a rare tumour, the behaviour of which is intermediate between clearly benign and malignant tumour.

Carcinoid Tumour (p. 559)

Carcinoid tumours are rare in the stomach and are usually non-argentaffin type but argentaffinomas also occur. Their behaviour is usually malignant.

Lymphomas of Gut (p. 559)

Primary gastrointestinal lymphomas are defined as lymphomas arising in the gut without any evidence of systemic involvement at the time of presentation.

Secondary gastrointestinal lymphomas, on the other hand, appear in the gut after dissemination from other primary site.

Gastric lymphomas constitute over 50% of all bowel lymphomas; other sites being small and large bowel in decreasing order of frequency. Prognosis of primary gastric lymphoma is better than for intestinal lymphomas. Primary lymphoma of stomach is the most common malignant gastric tumour (4%) next to carcinoma.

Clinical manifestations of gastric lymphomas may be similar to gastric carcinoma. Age incidence for lymphomas of the gastrointestinal tract is usually lower than that for carcinoma (30-40 years as compared to 40-60 years in gastric carcinoma) and may occur even in childhood. Relationship with long-standing chronic *H. pylori* gastritis with lymphoid hyperplasia has been strongly suggested.

G/A Gastric lymphomas have 2 types of appearances:

1) *Diffusely infiltrating type*, 2) *Polypoid type*.

M/E Gastric lymphomas are most often non-Hodgkin's lymphomas of the following types:

◆ *High-grade large cell immunoblastic lymphoma* being the most common.

◆ **Low-grade** small lymphocytic well-differentiated B-cell lymphoma referred to as **MALToma** is the next in frequency (arising from **Mucosa Associated Lymphoid Tissue**). The term **pseudolymphoma** is sometimes used for non-invasive stage of MALToma.

SMALL INTESTINE (p. 560)

□ **NORMAL STRUCTURE** (p. 560)

Anatomically, the small bowel having a length of 550-650 cm, includes the duodenum, jejunum and ileum and tends to become narrower throughout its course.

M/E The small bowel is identified by recognition of villi. The wall of the small intestine consists of 4 layers:

1. The **serosa** is the outer covering of the small bowel which is complete except over a part of the duodenum.
2. The **muscularis propria** is composed of 2 layers of smooth muscle tissue—outer thinner longitudinal and inner thicker circular layer. These muscles are functionally important for peristalsis.
3. The **submucosa** is composed of loose fibrous tissue with blood vessels and lacteals in it. It contains a gangliated plexus, Meissner's plexus, having fewer and smaller cells than the Auerbach's plexus.
4. The **mucosa** consists of glandular epithelium overlying the lamina propria composed of loose connective tissue and contains phagocytic cells and abundance of lymphoid cells (Peyer's patches in the ileum) and plasma cells. The absorptive surface is further increased by the intestinal villi. *Villi* are finger-like or leaf-like projections which contain 3 types of cells:
 - i) Simple columnar cells, ii) Goblet cells, iii) Endocrine cells (synonyms: Kulchitsky cells, Enterochromaffin cells, Argentaffin cells).

The blood supply of the whole of small intestine, except the first part of the duodenum, is by the superior mesenteric artery which supplies blood by mesenteric arterial arcades and the straight arteries.

The main *functions* of the small intestine are digestion and absorption so that ultimately nutrients passing into the bloodstream are utilised by the cells in metabolism.

□ **CONGENITAL ANOMALIES** (p. 561)

INTESTINAL ATRESIA AND STENOSIS (p. 561)

◆ **Intestinal atresia** is congenital absence of lumen, most commonly affecting the ileum or duodenum. The proximal segment has a blind end which is separated from distal segment freely, or the two segments are joined by a fibrous cord.

◆ **Intestinal stenosis** is congenital narrowing of the lumen affecting a segment of the small intestine. Intestinal segment above the level of obstruction is dilated and that below it is collapsed.

MECKEL'S DIVERTICULUM (p. 561)

Meckel's diverticulum is the most common congenital anomaly of the gastrointestinal tract, occurring in 2% of population. It is more common in males. The anomaly is commonly situated on the antimesenteric border of the ileum, about 1 meter above the ileocaecal valve. Like other true diverticula, Meckel's diverticulum is an outpouching containing all the layers of the intestinal wall in their normal orientation (**Web Image 20.20**). It is almost always lined by small intestinal type of epithelium; rarely it may contain islands of gastric mucosa and ectopic pancreatic tissue. Embryologic origin of Meckel's diverticulum is from incomplete obliteration of vitellointestinal duct.

474 The common *complications* of Meckel's diverticulum are perforation, haemorrhage and diverticulitis.

INTESTINAL MALROTATION (p. 561)

Malrotation is a developmental abnormality of the midgut (i.e. the portion of intestine between the duodenojejunal flexure and the middle of transverse colon). Due to failure of normal rotation of midgut, the following consequences can occur:

- i) Exomphalos i.e. intestinal eventration at the umbilicus.
- ii) Misplacement of the caecum, appendix and ascending colon.
- iii) Mobile caecum.

INTESTINAL OBSTRUCTION (p. 562)

The causes of intestinal obstruction can be classified under the following 3 broad groups:

1. Mechanical obstruction:

i) *Internal obstruction (intramural and intraluminal):*

- ◆ Inflammatory strictures (e.g. Crohn's disease)
Congenital stenosis, atresia, imperforate anus
- ◆ Tumours
- ◆ Meconium in mucoviscidosis
- ◆ Roundworms
- ◆ Gallstones, faecoliths, foreign bodies
- ◆ Ulceration induced by potassium chloride tablets prescribed to counter hypokalaemia.

ii) *External compression:*

- ◆ Peritoneal adhesions and bands
- ◆ Strangulated hernias
- ◆ Intussusception
- ◆ Volvulus
- ◆ Intra-abdominal tumour.

2. Neurogenic obstruction: It occurs due to paralytic ileus i.e. paralysis of muscularis of the intestine as a result of shock after abdominal operation or by acute peritonitis.

3. Vascular obstruction:

- ◆ Thrombosis
- ◆ Embolism
- ◆ Accidental ligation.

Out of the various causes listed above, conditions producing external compression on the bowel wall are the most common causes of intestinal obstruction (80%).

PERITONEAL ADHESIONS AND BANDS (p. 562)

Adhesions and bands in the peritoneum composed of fibrous tissue result following healing in peritonitis. Rarely, such fibrous adhesions and bands may be without any preceding peritoneal inflammation and are of congenital origin.

HERNIAS (p. 562)

Hernia is protrusion of portion of a viscus through an abnormal opening in the wall of its natural cavity.

◆ **External hernia** is the protrusion of the bowel through a defect or weakness in the peritoneum.

◆ **Internal hernia** is the term applied for herniation that does not present on the external surface.

Two major factors involved in the formation of a hernia are as under:
i) Local weakness, ii) Increased intra-abdominal pressure.

Inguinal hernias are more common, followed in decreasing frequency, by femoral and umbilical hernias. Inguinal hernias may be of 2 types: Direct and indirect.

When the blood flow in the hernial sac is obstructed, it results in *strangulated hernia*. Obstruction to the venous drainage and arterial supply may result in infarction or gangrene of the affected loop of intestine.

INTUSSUSCEPTION (p. 563)

Intussusception is the telescoping of a segment of intestine into the segment below due to peristalsis. The telescoped segment is called the *intussusceptum* and lower receiving segment is called the *intussusciptens*. The condition occurs more commonly in infants and young children, more often in the ileocaecal region when the portion of ileum invaginates into the ascending colon without affecting the position of the ileocaecal valve (**Web Image 20.21**).

The main *complications* of intussusception are intestinal obstruction, infarction, gangrene, perforation and peritonitis.

VOLVULUS (p. 563)

Volvulus is the twisting of loop of intestine upon itself through 180° or more. This leads to obstruction of the intestine as well as cutting off of the blood supply to the affected loop. The usual causes are bands and adhesions (congenital or acquired) and long mesenteric attachment.

□ **ISCHAEMIC BOWEL DISEASE** **(ISCHAEMIC ENTEROCOLITIS)** (p. 563)

Ischaemic lesions of the gastrointestinal tract may occur in the small intestine and/or colon; the latter is called *ischaemic colitis* or *ischaemic enterocolitis* and is commonly referred to as ischaemic bowel disease.

Depending upon the extent and severity of ischaemia, 3 patterns of pathologic lesions can occur (**Web Image 20.22**):

1. *Transmural infarction*, characterised by full thickness involvement i.e. transmural ischaemic necrosis and gangrene of the bowel.
2. *Mural infarction*, characterised by haemorrhagic gastroenteropathy (haemorrhage and necrosis). The ischaemic effect in mural infarction is limited to mucosa, submucosa and superficial muscularis, while *mucosal infarction* is confined to mucosal layers superficial to muscularis mucosae.
3. *Ischaemic colitis*, due to chronic colonic ischaemia causing fibrotic narrowing of the affected bowel.

TRANSMURAL INFARCTION (p. 563)

Ischaemic necrosis of the full-thickness of the bowel wall is more common in the small intestine than the large intestine.

ETIOPATHOGENESIS. Following causes are implicated:

- i) *Mesenteric arterial thrombosis*
 - ◆ Atherosclerosis (most common)
 - ◆ Aortic aneurysm
 - ◆ Vasospasm
 - ◆ Fibromuscular hyperplasia
 - ◆ Invasion by the tumour
 - ◆ Use of oral contraceptives
 - ◆ Arteritis of various types

476 ii) *Mesenteric arterial embolism*

- ◆ Mural thrombi in the heart
- ◆ Endocarditis (infective and nonbacterial thrombotic)
- ◆ Atherosclerotic plaques
- ◆ Atrial myxoma

iii) *Mesenteric venous occlusion* is less common cause of full-thickness infarction of the bowel.

- ◆ Intestinal sepsis e.g. appendicitis
- ◆ Portal venous thrombosis in cirrhosis of the liver
- ◆ Tumour invasion
- ◆ Use of oral contraceptives

iv) *Miscellaneous causes:*

- ◆ Strangulated hernia
- ◆ Torsion
- ◆ Fibrous bands and adhesions.

G/A Irrespective of the underlying etiology, infarction of the bowel is haemorrhagic (red) type. The affected areas become dark purple and markedly congested and the peritoneal surface is coated with fibrinous exudate. The wall is thickened, oedematous and haemorrhagic. The lumen is dilated and contains blood and mucus. In arterial occlusion, there is sharp line of demarcation between the infarcted bowel and the normal intestine, whereas in venous occlusion the infarcted area merges imperceptibly into the normal bowel (**Web Image 20.23**).

M/E There is coagulative necrosis and ulceration of the mucosa and there are extensive submucosal haemorrhages. The muscularis is less severely affected by ischaemia. Subsequently, inflammatory cell infiltration and secondary infection occur, leading to gangrene of the bowel (**Web Image 20.24**).

MURAL AND MUCOSAL INFARCTION (HAEMORRHAGIC GASTROENTEROPATHY, MEMBRANOUS COLITIS) (p. 564)

Mural and mucosal infarctions are limited to superficial layers of the bowel wall, sparing the deeper layer of the muscularis and the serosa. The condition is also referred to as *haemorrhagic gastroenteropathy*, and in the case of colon as *membranous colitis*.

ETIOPATHOGENESIS. Haemorrhagic gastroenteropathy results from conditions causing non-occlusive hypoperfusion (compared from transmural infarction which occurs from occlusive causes).

- ◆ Shock
- ◆ Cardiac failure
- ◆ Infections
- ◆ Intake of drugs causing vasoconstriction e.g. digitalis, norepinephrine.

G/A The lesions affect variable length of the bowel. The affected segment of the bowel is red or purple but without haemorrhage and exudation on the serosal surface. The mucosa is oedematous at places, sloughed and ulcerated at other places.

M/E There is patchy ischaemic necrosis of mucosa, vascular congestion, haemorrhages and inflammatory cell infiltrate. The changes may extend into superficial muscularis but deeper layer of muscularis and serosa are spared. Secondary bacterial infection may supervene resulting in pseudomembranous enterocolitis.

ISCHAEMIC COLITIS (p. 565)

Although this condition affects primarily colon in the region of splenic flexure, it is described here due to its apparent pathogenetic relationship with ischaemic injury.

G/A Most frequently affected site is the splenic flexure; other site is rectum. Ischaemic colitis passes through 3 stages: infarct, transient ischaemia and ischaemic stricture. However, the surgical submitted specimens generally are of the ischaemic stricture. External surface of the affected area is fusiform or saccular. On cut section, there are patchy, segmental and longitudinal mucosal ulcers.

M/E The ulcerated areas of the mucosa show granulation tissue. The submucosa is characteristically thickened due to inflammation and fibrosis. The muscularis may also show inflammatory changes and patchy replacement by fibrosis.

□ **NECROTISING ENTEROCOLITIS** (p. 565)

Necrotising enterocolitis is an acute inflammation of the terminal ileum and ascending colon, occurring primarily in premature and low-birth-weight infants within the first week of life and less commonly in full-term infants.

ETIOLOGY. The condition has been considered as a variant of the spectrum of ischaemic bowel disease. Important factors in the etiology of this disorder, thus, are:

1. Ischaemia
2. Hypoxia/anoxia of the bowel due to bypassing of blood from the affected area
3. Bacterial infection and endotoxins
4. Establishment of feeding
5. Infants fed on commercial formulae than breast-fed, implying the role of immunoprotective factors.

G/A The affected segment of the bowel is dilated, necrotic, haemorrhagic and friable. Bowel wall may contain bubbles of air (pneumatosis intestinalis).

M/E The changes are variable depending upon the stage. Initial changes are confined to mucosa and show oedema, haemorrhage and coagulative necrosis. A *pseudomembrane* composed of necrotic epithelium, fibrin and inflammatory cells may develop. As the ischaemic process extends to the subjacent layers, muscle layer is also involved and may lead to perforation and peritonitis.

□ **INFLAMMATORY BOWEL DISEASE
(CROHN'S DISEASE AND ULCERATIVE COLITIS)** (p. 565)

DEFINITION. The term 'inflammatory bowel disease (IBD)' is commonly used to include 2 idiopathic bowel diseases having many similarities but the conditions usually have distinctive morphological appearance.

1. **Crohn's disease or Regional enteritis** is an idiopathic chronic ulcerative IBD, characterised by transmural, non-caseating granulomatous inflammation, affecting most commonly the segment of terminal ileum and/or colon, though any part of the gastrointestinal tract may be involved.
2. **Ulcerative colitis** is an idiopathic form of acute and chronic ulceroinflammatory colitis affecting chiefly the mucosa and submucosa of the rectum and descending colon, though sometimes it may involve the entire length of the large bowel.

Both these disorders primarily affect the bowel but may have systemic involvement in the form of polyarthritis, uveitis, ankylosing spondylitis, skin lesions and hepatic involvement. Both diseases can occur at any age but are more frequent in 2nd and 3rd decades of life. Females are affected slightly more often.

ETIOPATHOGENESIS. The exact etiology of IBD remains unknown. However, multiple factors are implicated which can be considered under the following 3 groups:

1. Genetic factors. Genetic factors are implicated in the etiopathogenesis of IBD is supported by the following evidences:

- i) There is about 3 to 20 times higher incidence of occurrence of IBD in first-degree relatives.
- ii) Overall, there is approximately 50% chance of development of IBD in monozygotic twins.
- iii) Genome wide search has revealed that disease-predisposing loci are present in chromosomes 16q, 12p, 6p, 14q and 5q.
- iv) HLA studies show that ulcerative colitis is more common in HLA-DRB1-alleles while Crohn's disease is more common in HLA-DR7 and DQ4 alleles.

2. Immunologic factors. Defective immunologic regulation in IBD has been shown to play significant role in the pathogenesis of IBD:

- i) *Defective regulation of immune suppression.* The mechanism responsible for this is by activation of CD4+ T cells secreting cytokines inhibitory to inflammation (IL-10, TGF- β) which suppress inflammation in the gut wall.
- ii) *Transgenic mouse experimental model studies.* Gene 'knock out' studies on colitis in mice have revealed that multiple immune abnormalities may be responsible for IBD as under:
 - a) Deletion of inflammation inhibitory cytokines (e.g. IL-2, IL-10, TGF- β) or their receptors.
 - b) Deletion of molecules responsible for T cell recognition (e.g. T cell antigen receptors, MHC class II).
 - c) Interference with normal epithelial barrier function in the intestine (e.g. blocking N-cadherin, deletion of multi-drug resistance MDR gene).
- iii) *Type of inflammatory cells.* In both types of IBD, activated CD4+ T cells are present in the lamina propria and in the peripheral blood. There are two main types of CD4+ T cells in IBD:

◆ *TH1 cells* secrete proinflammatory cytokines IFN- γ and TNF which induce transmural granulomatous inflammation seen in Crohn's disease. IL-12 initiates TH1 cytokine pathway.

◆ *TH2 cells* secrete IL-4, IL-5 and IL-13 which induce superficial mucosal inflammation characteristically seen in ulcerative colitis.

3. Exogenous factors. In addition to role of genetic factors and deranged T-cell mediated immunity, a role for several exogenous and environmental factors has been assigned:

- i) Microbial factors, ii) Psychosocial factors, iii) Smoking and iv) Oral contraceptives.

Consensus hypothesis in *pathogenesis* of IBD combines the role of above three major groups of etiologic factors: i.e. in a *genetically predisposed individual*, the effects of exogenous and endogenous host factors result in dysregulation of mucosal immune function, which gets further modified by *certain environmental factors*.

MORPHOLOGIC FEATURES. The morphologic features of Crohn's disease and ulcerative colitis are sufficiently distinctive so as to be classified separately (**Web Table 20.6**).

CROHN'S DISEASE. Crohn's disease may involve any portion of the gastrointestinal tract but affects most commonly 15-25 cm of the terminal ileum which may extend into the caecum and sometimes into the ascending colon:

G/A Characteristic feature is the multiple, well-demarcated segmental bowel involvement with intervening uninvolved 'skip areas'. The wall of the affected bowel segment is thick and hard, resembling a 'hose pipe'. Serosa may be studded with minute granulomas. The lumen of the affected segment is markedly narrowed. The mucosa shows 'serpiginous ulcers', while intervening surviving mucosa is swollen giving 'cobblestone appearance'. There may be deep fissuring into the bowel wall (**Web Image 20.25**).

M/E (Web Image 20.26): The features are as under:

1. *Transmural inflammatory cell infiltrate* consisting of chronic inflammatory cells.
2. *Non-caseating, sarcoid-like granulomas* are present in all the layers of the affected bowel wall in 60% of cases.
3. There is *patchy ulceration* of the mucosa which may take the form of deep fissures.
4. There is *widening of the submucosa* due to oedema and foci of lymphoid aggregates.
5. In more *chronic* cases, fibrosis becomes increasingly prominent in all the layers disrupting muscular layer.

ULCERATIVE COLITIS. Classically, ulcerative colitis begins in the rectum, and in continuity extends upwards into the sigmoid colon, descending colon, transverse colon, and sometimes may involve the entire colon.

G/A The characteristic feature is the continuous involvement of the rectum and colon without any uninvolved skip areas compared to Crohn's disease. The intervening intact mucosa may form inflammatory 'pseudopolyps.' The muscle layer is thickened due to contraction, producing shortening and narrowing of the affected colon with loss of normal haustral folds giving 'garden-hose appearance' (**Web Image 20.27**).

M/E Ulcerative colitis because of remission and exacerbations, is characterised by alternating 'active disease process' and 'resolving colitis.' The changes in the 'active disease process' are as under (**Web Image 20.28**):

1. *Crypt distortion, cryptitis* and focal accumulations of neutrophils forming *crypt abscesses*.
2. *Marked congestion, dilatation and haemorrhages*.
3. *Superficial mucosal ulcerations*.
4. *Goblet cells* are markedly *diminished* in cases of active disease.
5. Areas of *mucosal regeneration and mucodepletion* of lining cells.
6. In long-standing cases, epithelial *cytologic atypia* ranging from mild to marked dysplasia and sometimes developing into carcinoma *in situ* and frank adenocarcinoma.

COMPLICATIONS. These are:

Crohn's disease:

- 1) Malabsorption, 2) Fistula formation, 3) Stricture formation and 4) Development of malignancy.

Ulcerative colitis:

- 1) Toxic megacolon (Fulminant colitis), 2) Perianal fistula formation, 3) Carcinoma and 4) Stricture formation.

□ OTHER INFLAMMATORY LESIONS OF THE BOWEL (p. 569)

INFECTIVE ENTEROCOLITIS (p. 569)

These are a group of acute and chronic inflammatory lesions of small intestine and/or colon caused by microorganisms (bacteria, viruses, fungi, protozoa and helminths). All these are characterised by diarrhoeal syndromes. Pathogenetically speaking, these microorganisms can cause enterocolitis by 2 mechanisms—by *enteroinvasive bacteria* producing ulcerative lesions, and by *enterotoxin-producing bacteria* resulting in non-ulcerative lesions.

A list of common microorganisms producing enterocolitis is presented in **Web Table 20.7**.

INTESTINAL TUBERCULOSIS (p. 569)

Intestinal tuberculosis can occur in 3 forms—primary, secondary and hyperplastic caecal tuberculosis.

1. PRIMARY INTESTINAL TUBERCULOSIS. Though an uncommon disease in the developed countries of the world, primary tuberculosis of the ileocaecal region is quite common in developing countries including India. In the pre-pasteurisation era, it used to occur by ingestion of unpasteurised cow's milk infected with *Mycobacterium bovis*. But now-a-days due to control of tuberculosis in cattle and pasteurisation of milk, virtually all cases of intestinal tuberculosis are caused by *M. tuberculosis*.

G/A The affected lymph nodes are enlarged, matted and caseous (tabes mesenterica). Eventually, there is healing by fibrosis and calcification (**Web Image 20.29,A**).

M/E In the initial stage, there is primary complex or Ghon's focus in the intestinal mucosa as occurs elsewhere in primary tuberculous infection. Subsequently, the mesenteric lymph nodes are affected which show typical tuberculous granulomatous inflammatory reaction with caseation necrosis.

2. SECONDARY INTESTINAL TUBERCULOSIS. Self-swallowing of sputum in patients with active pulmonary tuberculosis may cause secondary intestinal tuberculosis, most commonly in the terminal ileum and rarely in the colon.

G/A The intestinal lesions are prominent than the lesions in regional lymph nodes as in secondary pulmonary tuberculosis (**Web Image 20.29,B**). The lesions begin in the Peyer's patches or the lymphoid follicles with formation of small ulcers that spread through the lymphatics to form large ulcers which are *transverse to the long axis of the bowel*, (c.f. typhoid ulcers of small intestine, described below). In advanced cases, transverse fibrous strictures and intestinal obstruction are seen (**Web Image 20.30,A, B**).

M/E The tuberculous lesions in the intestine are similar to those observed elsewhere i.e. presence of tubercles. Mucosa and submucosa show ulceration and the muscularis may be replaced by variable degree of fibrosis (**Web Image 20.30,C**).

3. HYPERPLASTIC CAECAL TUBERCULOSIS. This is a variant of occurring secondary to pulmonary tuberculosis.

G/A The caecum and/or ascending colon are thick-walled with mucosal ulceration (**Web Image 20.29,C**).

M/E The presence of caseating tubercles distinguishes the condition from Crohn's disease in which granulomas are non-caseating.

ENTERIC FEVER (p. 571)

The term enteric fever is used to describe acute infection caused by *Salmonella typhi* (typhoid fever) or *Salmonella paratyphi* (paratyphoid fever). Besides these 2 salmonellae, *Salmonella typhimurium* causes food poisoning.

PATHOGENESIS. The typhoid bacilli are ingested through contaminated food or water. During the initial asymptomatic incubation period of about 2 weeks, the bacilli invade the lymphoid follicles and Peyer's patches of the small intestine and proliferate. Following this, the bacilli invade the bloodstream causing bacteraemia, and the characteristic clinical features of the disease like continuous rise in temperature and 'rose spots' on the skin are observed. Eventually, the bacilli are localised in the intestinal lymphoid tissue (producing typhoid intestinal lesions), and in the mesenteric lymph nodes (leading to haemorrhagic lymphadenitis).

G/A Terminal ileum is affected most often, but lesions may be seen in the jejunum and colon. Peyer's patches show oval typhoid ulcers with their *long axis along the length of the bowel*, (c.f. tuberculous ulcers of small intestine, described above). The base of the ulcers is black due to sloughed mucosa. The regional lymph nodes are invariably enlarged (**Web Image 20.31,A**).

M/E There is hyperaemia, oedema and cellular proliferation consisting of phagocytic histiocytes (showing characteristic erythrophagocytosis),

lymphocytes and plasma cells. Though enteric fever is an example of acute inflammation, neutrophils are invariably absent from the cellular infiltrate and this is reflected in the leucopenia with neutropenia and relative lymphocytosis in the peripheral blood (**Web Image 20.31,B**).

The main **complications** of the intestinal lesions of typhoid are perforation of the ulcers and haemorrhage.

BACTERIAL FOOD POISONING (p. 572)

This is a form of acute bacterial illness that occurs following ingestion of food or water contaminated with bacteria other than those that cause specific acute intestinal infections like typhoid, paratyphoid, cholera or dysentery bacilli.

The commonest causes of bacterial food poisoning resulting in enteritis or enterocolitis are as under:

1) Staphylococcal food poisoning, 2) Clostridial food poisoning, 3) Botulism and 4) Salmonella food poisoning (Salmonellosis).

DYSENTERIES (p. 572)

The term 'dysentery' is used to mean diarrhoea with abdominal cramps, tenesmus and passage of mucus in the stools, from any cause. There are 2 main forms of dysenteries.

1. BACILLARY DYSENTERY. Bacillary dysentery is the term used for infection by *shigella* species: *S. dysenteriae*, *S. flexneri*, *S. boydii* and *S. sonnei*. Infection occurs by faeco-oral route and is seen with poor personal hygiene, in densely populated areas, and with contaminated food and water. The common housefly plays a role in spread of infection.

G/A The lesions are mainly found in the colon and occasionally in the ileum. Superficial transverse ulcerations of mucosa of the bowel wall occur in the region of lymphoid follicles but perforation is seldom seen.

M/E The mucosa overlying the lymphoid follicles is necrosed. The surrounding mucosa shows congestion, oedema and infiltration by neutrophils and lymphocytes. The mucosa may be covered by greyish-yellow '*pseudomembrane*' composed of fibrinosuppurative exudate.

2. AMOEBIC DYSENTERY. This is due to infection by *Entamoeba histolytica*. It is more prevalent in the tropical countries and primarily affects the large intestine. Infection occurs from ingestion of cyst form of the parasite.

G/A Early intestinal lesions appear as small areas of elevation on the mucosal surface. In advanced cases, typical flask-shaped ulcers having narrow neck and broad base are seen. They are more conspicuous in the caecum, rectum and in the flexures (**Web Image 20.32,A**).

M/E The ulcerated area shows chronic inflammatory reaction consisting of lymphocytes, plasma cells, macrophages and eosinophils. The trophozoites of *Entamoeba* are seen in the inflammatory exudate and are concentrated at the advancing margin of the lesion (**Web Image 20.32,B**). Intestinal amoebae characteristically have ingested red cells in their cytoplasm. Oedema and vascular congestion are present in the area surrounding the ulcers.

□ PSEUDOMEMBRANOUS ENTEROCOLITIS (ANTIBIOTIC-ASSOCIATED DIARRHOEA) (p. 573)

Pseudomembranous enterocolitis is a form of acute inflammation of colon and/or small intestine characterised by formation of '*pseudomembrane*' over the site of mucosal injury.

ETIOLOGY. Numerous studies have established the overgrowth of *Clostridium difficile* with production of its toxin in the etiology of antibiotic-associated diarrhoea culminating in pseudomembranous colitis. Oral anti-

482 biotics such as clindamycin, ampicillin and the cephalosporins are more often (20%) associated with antibiotic-associated diarrhoea, while development of pseudomembranous colitis may occur in 1-10% cases.

G/A The lesions may be confined, to the large intestine or small intestine, or both may be involved. The mucosa of the bowel is covered by patchy, raised yellow-white plaques.

M/E The 'pseudomembrane' is composed of network of fibrin and mucus, in which are entangled inflammatory cells and mucosal epithelial cells. There is focal necrosis of surface epithelial cells.

□ **MALABSORPTION SYNDROME** (p. 573)

DEFINITION AND CLASSIFICATION (p. 573)

The malabsorption syndrome (MAS) is characterised by impaired intestinal absorption of nutrients especially of fat; some other substances are proteins, carbohydrates, vitamins and minerals. MAS is subdivided into 2 broad groups:

◆ **Primary MAS**, which is due to primary deficiency of the absorptive mucosal surface and of the associated enzymes.

◆ **Secondary MAS**, in which mucosal changes result secondary to other factors such as diseases, surgery, trauma and drugs.

Each of the two main groups has a number of causes listed in **Web Table 20.8**.

CLINICAL FEATURES (p. 573)

1. Steatorrhoea (pale, bulky, foul-smelling stools)
2. Chronic diarrhoea
3. Abdominal distension
4. Barborygmi and flatulence
5. Anorexia
6. Weight loss
7. Muscle wasting
8. Dehydration
9. Hypotension
10. Specific malnutrition and vitamin deficiencies depending upon the cause.

INVESTIGATIONS (p. 574)

I. **Laboratory Tests:**

1. **Tests for fat malabsorption:**

- i) Faecal analysis for fat content
- ii) Microscopic analysis for faecal fat
- iii) Blood lipid levels after a fatty meal
- iv) Tests based on absorption of radioactive-labelled fat.

2. **Tests for protein malabsorption:**

- i) Bile acid malabsorption
- ii) Radioactive-labelled glycine breath test.
- iii) Prothrombin time (vitamin K deficiency)
- iv) Secretin and other pancreatic tests.

3. **Tests for carbohydrate malabsorption:**

- i) D-xylose tolerance test
- ii) Lactose tolerance test
- iii) Hydrogen breath test
- iv) Bile acid breath test

4. **Vitamin B₁₂, malabsorption:**

- i) Schilling test.

II. Intestinal Mucosal Biopsy:

Mucosal biopsy of small intestine is essential for making the diagnosis of MAS and also evaluation of a patient on follow-up. The availability of endoscopes has enabled easy viewing of affected mucosa directly and taking mucosal biopsy under vision; this has largely replaced the earlier per-oral Crosby-Kugler capsule biopsy of small intestine.

Normal villous (Web Image 20.33,A). Under the dissecting microscope, the normal jejunal mucosa has tall, slender, finger-shaped or leaf-shaped villi. It is lined by tall columnar absorptive epithelium and has scattered lymphocytes in the lamina propria.

Villous atrophy. Variable degree of flattening of intestinal mucosa in MAS is the commonest pathological change in mucosal pattern and is referred to as villous atrophy. It may be of 2 types—

◆ **Partial villous atrophy** is the mild form of the lesion in which villi fuse with each other and thus become short and broad, commonly called as convolutions and irregular ridges (**Web Image 20.33,B**). The epithelial cells show compensatory hyperplasia suggesting a turnover of these cells (**Web Image 20.34,A**).

◆ **Subtotal/Total villous atrophy** is the severe form of the lesion in which there is flattening of mucosa due to more advanced villous fusion (**Web Image 20.33,C**). The surface epithelium is cuboidal and there is increased plasma cell infiltrate in the lamina propria (**Web Image 20.34,B**).

IMPORTANT TYPES OF MAS (p. 575)

Coeliac Sprue (Non-tropical Sprue, Gluten-Sensitive Enteropathy, Idiopathic Steatorrhoea) (p. 575)

This is the most important cause of primary malabsorption occurring in temperate climates. The condition is characterised by significant loss of villi in the small intestine and thence diminished absorptive surface area. The condition occurs in 2 forms:

Childhood form, seen in infants and children and is commonly referred to as *coeliac disease*.

Adult form, seen in adolescents and early adult life and used to be called *idiopathic steatorrhoea*.

In either case, there is genetic abnormality resulting in sensitivity to gluten (a protein) and its derivative, gliadin, present in diets such as grains of wheat, barley and rye. Serum antibodies—IgA anti-gliadin and IgA anti-endomysial, have been found but is not known whether these antibodies are primary or appear secondary to tissue damage.

The symptoms are usually relieved on elimination of gluten from the diet. The role of heredity is further supported by the observation of familial incidence and HLA association of the disease.

M/E There are no differences in the pathological findings in children and adults. There is variable degree of flattening of the mucosa, particularly of the upper jejunum, and to some extent of the duodenum and ileum. The surface epithelial cells are cuboidal or low columnar type. There may be *partial villous atrophy* which is replacement of normal villous pattern by convolutions, or *subtotal villous atrophy* characterised by flat mucosal surface (**Web Image 20.34**).

Collagenous Sprue (p. 575)

This entity is regarded as the end-result of coeliac sprue in which the villi are totally absent (*total villous atrophy*) and there are unique and diagnostic broad bands of collagen under the basal lamina of surface epithelium.

484 Tropical Sprue (p. 575)

This disease, as the name suggests, occurs in individuals living in or visiting tropical areas such as Caribbean countries, South India, Sri Lanka and Hong Kong. Pathogenesis of the condition is not clear but there is evidence to support enterotoxin production by some strains of *E. coli* which causes the intestinal injury.

M/E There is usually *partial villous atrophy* and sometimes *subtotal atrophy*.

Whipple's Disease (Intestinal Lipodystrophy) (p. 576)

This is an uncommon bacterial disease involving not only the intestines but also various other systems such as central nervous system, heart, blood vessels, skin, joints, lungs, liver, spleen and kidneys. The disease is more common in males in 4th to 5th decades of life.

M/E The affected tissues show presence of characteristic macrophages containing PAS-positive granules and rod-shaped micro-organisms (Whipple's bacilli). These macrophages are predominantly present in the lamina propria of the small intestine and mesenteric lymph nodes.

Protein-Losing Enteropathies (p. 576)

These diseases are listed below:

- i) Whipple's disease
- ii) Crohn's disease
- iii) Ulcerative colitis
- iv) Sprue
- v) Intestinal lymphangiectasia
- vi) Ménétrier's disease (Hypertrophic gastritis).

□ SMALL INTESTINAL TUMOURS (p. 576)

Most common *benign tumours*, in descending order of frequency, are: leiomyomas, adenomas and vascular tumours (haemangioma, lymphangioma). Amongst the *malignant tumours*, the most frequently encountered, in descending frequency, are: carcinoid tumours, lymphomas (**Web Image 20.35**) and adenocarcinoma.

CARCINOID TUMOUR (ARGENTAFFINOMA) (p. 576)

Carcinoid tumour or argentaffinoma is a generic term applied to tumours originating from endocrine cells (*synonyms*: argentaffin cells, Kulchitsky cells, enterochromaffin cells) belonging to APUD cell system and are therefore also called as apudomas. Depending upon the embryologic derivation of the tissues where the tumour is located, these are classified as foregut, midgut, and hindgut carcinoids.

◆ **Midgut carcinoids**, seen in terminal ileum and appendix are the most common (60-80%) and are more often argentaffin positive.

◆ **Hindgut carcinoids**, occurring in rectum and colon are more commonly argyrophil type, and comprise about 10-20% of carcinoids.

◆ **Foregut carcinoids**, located in the stomach, duodenum and oesophagus are also argyrophil type and are encountered as frequently as in the hindgut (10-20%).

Appendix and terminal ileum, the two most common sites for carcinoids, depict variation in their age and sex incidence and biologic behaviour:

◆ **Appendiceal carcinoids**, occur more frequently in 3rd and 4th decades of life without any sex predilection, are often solitary and behave as locally malignant tumours.

◆ **Ileal carcinoids**, on the other hand, are seen more often in later age (7th decade) with female preponderance, are more commonly multiple and behave like metastasising carcinomas.

G/A All carcinoids are small, button-like submucosal elevations with intact or ulcerated overlying mucosa. They are usually small; those larger than 2 cm are more often metastasising. Ileal and gastric carcinoids are commonly multiple, whereas appendiceal carcinoids commonly involve the tip of the organ and are solitary (**Web Image 20.36**). Cut section of all the carcinoids is bright yellow.

M/E The tumour cells may be arranged in a variety of patterns—solid nests, sheets, cords, trabeculae and clusters, all of which show characteristic palisading of the peripheral cells. Acinar arrangement and rosettes are rarely seen. The tumour cells are classically small, monotonous, having uniform nuclei and poorly-defined cell boundaries (**Web Image 20.37**). The argentaffin carcinoids show eosinophilic granules in the cytoplasm which stain positively by the argentaffin reaction.

CARCINOID SYNDROME. Carcinoid tumours that metastasise, especially to the liver, are sometimes associated with the carcinoid syndrome. The syndrome consists of the following features:

1. Intermittent attacks of flushing of the skin of face
2. Episodes of watery diarrhoea
3. Abdominal pain
4. Attacks of dyspnoea due to bronchospasm
5. Right-sided heart failure due to involvement of tricuspid and pulmonary valves and endocardium.

A number of *secretory products* in a functioning carcinoid tumour have been demonstrated:

- i) 5-Hydroxytryptamine (5-HT, serotonin)
- ii) 5-Hydroxytryptophan
- iii) 5-Hydroxy-indole acetic acid (5-HIAA)
- iv) Histamine
- v) Kallikrein
- vi) Bradykinin

APPENDIX (p. 577)

□ NORMAL STRUCTURE (p. 577)

Appendix is a vestigial organ which serves no useful purpose in human beings but instead becomes the site of trouble at times. It is like a diverticulum of the caecum, usually lying behind the caecum and varies in length from 4 to 20 cm (average 7 cm).

M/E Appendix has four layers in its wall—*mucosa*, *submucosa*, *muscularis* and *serosa*. The mucosa has patchy distribution of crypts and the submucosa has abundant lymphoid tissue.

□ APPENDICITIS (p. 578)

The disease is seen more frequently in the West and in affluent societies which may be due to variation in diet—a diet with low bulk or cellulose and high protein intake more often causes appendicitis.

ETIOPATHOGENESIS. The common causes of appendicitis are as under:

A. Obstructive:

1. Faecolith
2. Calculi
3. Foreign body
4. Tumour
5. Worms (especially *Enterobius vermicularis*)
6. Diffuse lymphoid hyperplasia, especially in children.

B. Non-obstructive:

1. Haematogenous spread of generalised infection

- 486 2. Vascular occlusion
3. Inappropriate diet lacking roughage.

G/A The appearance depends upon the stage at which the acutely-inflamed appendix is examined. In *early acute appendicitis*, the organ is swollen and serosa shows hyperaemia. In well-developed acute inflammation called *acute suppurative appendicitis*, the serosa is coated with fibrinopurulent exudate and engorged vessels on the surface. In further advanced cases called *acute gangrenous appendicitis*, there is necrosis and ulcerations of mucosa which extend through the wall so that the appendix becomes soft and friable and the surface is coated with greenish-black gangrenous necrosis (**Web Image 20.38**).

M/E The most important diagnostic histological criterion is the *neutrophilic infiltration of the muscularis*. In early stage, the other changes besides acute inflammatory changes, are congestion and oedema of the appendiceal wall. There may be neutrophilic abscesses in the wall. In either case, an impacted foreign body, faecolith, or concretion may be seen in the lumen (**Web Image 20.39**).

CLINICAL COURSE. The features are:

1. Colicky pain, initially around umbilicus but later localised to right iliac fossa
2. Nausea and vomiting
3. Pyrexia of mild grade
4. Abdominal tenderness
5. Increased pulse rate
6. Neutrophilic leucocytosis.

An attack of acute appendicitis predisposes the appendix to repeated attacks (*recurrent acute appendicitis*) and thus surgery has to be carried out. If appendectomy is done at a later stage following acute attack (*interval appendectomy*), pathological changes of healing by fibrosis of the wall and chronic inflammation are observed.

COMPLICATIONS. These are: 1) Peritonitis, 2) Appendix abscess, 3) Adhesions, 4) Portal pylephlebitis and 5) Mucocele.

TUMOURS OF APPENDIX (p. 579)

CARCINOID TUMOUR. Both argentaffin and argyrophil types are encountered, the former being more common.

G/A Carcinoid tumour of the appendix is mostly situated near the tip of the organ and appears as a circumscribed nodule, usually less than 1 cm in diameter, involving the wall but metastases are rare.

M/E Carcinoid tumour of the appendix resembles other carcinoids of the midgut.

PSEUDOMYXOMA PERITONEI. Pseudomyxoma peritonei is appearance of gelatinous mucinous material around the appendix admixed with epithelial tumour cells. It is generally due to mucinous collection from benign mucinous cystadenoma of the ovary or mucin-secreting carcinoma of the appendix.

ADENOCARCINOMA. It is an uncommon tumour in the appendix and is morphologically similar to adenocarcinoma elsewhere in the alimentary tract.

NORMAL STRUCTURE (p. 579)

The large bowel consists of 6 parts—the caecum, ascending colon, transverse colon, descending colon, sigmoid colon and rectum, and in all measures

about 1.5 meters in length. The serosal surface of the large intestine except the rectum is studded with *appendices epiploicae* which are small, rounded collections of fatty tissue covered by peritoneum.

M/E The wall of large bowel consists of 4 layers as elsewhere in the alimentary tract—

- ◆ The **mucosa** lacks villi and there is preponderance of goblet cells over columnar epithelial cells.

- ◆ The **muscularis propria** of the large intestine is quite peculiar—the inner circular muscle layer ensheaths whole length of the intestine, while the outer longitudinal muscle layer is concentrated into 3 muscle bands called *taenia coli*. The length of outer muscle layer is shorter than the length of the intestine and therefore, it forms the *sacculations or haustra* of the large intestine.

The *blood supply* to the right colon is from the superior mesenteric artery which also supplies blood to the small bowel. The remaining portion of large bowel except the lower part of rectum receives blood supply from inferior mesenteric artery. The lower rectum is supplied by haemorrhoidal branches.

The *innervation* of the large bowel consists of 3 plexuses of ganglion cells—*Auerbach's* or *myenteric plexus* lying between the two layers of muscularis, *Henle's plexus* lying in the deep submucosa inner to circular muscle layer, and *Meissner plexus* that lies in the superficial mucosa just beneath the muscularis mucosae. These are interconnected by non-myelinated nerve fibres.

Anal canal, 3-4 cm long tubular structure, begins at the lower end of the rectum, though is not a part of large bowel, but is included here to cover simultaneously lesions pertaining to this region. It is lined by keratinised or nonkeratinised stratified squamous epithelium.

□ CONGENITAL MALFORMATIONS (p. 580)

HIRSCHSPRUNG'S DISEASE (CONGENITAL MEGACOLON) (p. 580)

The term 'megacolon' is used for any form of marked dilatation of the entire colon or its segment and may occur as a congenital or acquired disorder. *Congenital form* characterised by congenital absence of ganglion cells in the bowel wall (enteric neurons) is called Hirschsprung's disease. As a result, the aganglionic segment remains contracted. Genetically, Hirschsprung's disease is a heterogeneous disorder as under:

1. Autosomal dominant inheritance with mutation in *RET* proto-oncogene in some cases.
2. Autosomal recessive form with mutation in endothelin-B receptor gene in many other cases.

Clinically, the condition manifests shortly after birth with constipation, gaseous distension and sometimes with acute intestinal obstruction. Its frequency is 1 in 5,000 live-births, has familial tendency in about 4% of cases and has predilection for development in Down's syndrome.

G/A Typical case of Hirschsprung's disease shows 2 segments—a *distal narrow segment* that is aganglionic and a *dilated proximal segment* that contains normal number of ganglion cells (**Web Image 20.40**).

M/E The distal narrow segment shows total absence of ganglion cells of all the three plexuses (*Auerbach's* or *myenteric plexus* present between the two layers of muscularis, deep submucosal or *Henle's plexus*, and superficial mucosal or *Meissner's plexus*) and prominence of non-myelinated nerve fibres. Histochemical staining for acetylcholine esterase activity provides confirmation for identifying ganglion cells and nerve trunks.

Depending upon the length of the segment affected by aganglionosis in Hirschsprung's disease, following patterns are recognised:

1. *Classic form*: Aganglionosis from distal colorectal region to proximal dilated colon.
2. *Short segment (rectal and recto-sigmoid) form*: Aganglionosis involving a few centimeters of the rectum and rectosigmoid only.
3. *Ultra-short form*: Aganglionosis is in a very small segment which can be missed in a biopsy.
4. *Long segment (subtotal colonic) form*: Aganglionosis involves most of the colon from rectosigmoid to the ileo-caecal valve, and sometimes may even extend into small bowel.
5. *Zonal colonic aganglionosis*: A short segment is involved in aganglionosis in which the ganglia cells are absent both above and below the aganglionic segment.

In addition to congenital megacolon discussed above, megacolon may occur from certain *acquired causes* as under:

- i) Obstructive, ii) Endocrine, iii) CNS disorders, iv) Psychogenic and v) Chagas' disease.

COLITIS (p. 580)

Web Table 20.9 presents a classification of the various types of colitis/enterocolitis.

□ MISCELLANEOUS LESIONS (p. 581)

DIVERTICULOSIS COLI (p. 581)

Diverticula are the outpouchings or herniations of the mucosa and submucosa of the colon through the muscle wall. *Diverticular disease*, as it is commonly known, is rare under 30 years of age and is seen more commonly as the age advances. Multiple diverticula of the colon are very common in the Western societies, probably due to ingestion of low-fibre diet but is seen much less frequently in tropical countries and in Japan.

1. *Increased intraluminal pressure* such as due to low fibre content of the diet causing hyperactive peristalsis and thereby sequestration, of mucosa and submucosa.
2. *Muscular weakness* of the colonic wall at the junction of the muscularis with submucosa.

G/A Diverticulosis is seen most commonly in the sigmoid colon (95%) but any other part of the entire colon may be involved. They may vary in number from a few to several hundred. They appear as small, spherical or flask-shaped outpouchings, usually less than 1 cm in diameter.

M/E The flask-shaped structures extend from the intestinal lumen through the muscle layer. The colonic wall in the affected area is thin and is composed of atrophic mucosa, compressed submucosa and thin or deficient muscularis.

The *complications* of diverticulosis and diverticulitis are perforation, haemorrhage, intestinal obstruction and fistula formation.

MELANOSIS COLI (p. 581)

Melanosis coli is a peculiar condition in which mucosa of the large intestine acquires brown-black colouration.

G/A The mucosal surface is intact and is pigmented brown-black.

M/E Large number of pigment-laden macrophages are seen in the lamina propria. The nature of this pigment is found to be both melanin and lipofuscin.

HAEMORRHOIDS (PILES) (p. 581)

Haemorrhoids or piles are the varicosities of the haemorrhoidal veins. They are called '*internal piles*' if dilatation is of superior haemorrhoidal plexus

covered over by mucous membrane, and 'external piles' if they involve inferior haemorrhoidal plexus covered over by the skin. They commonly result from increased venous pressure. The possible causes include the following:

1. Portal hypertension
2. Chronic constipation and straining at stool
3. Cardiac failure
4. Venous stasis of pregnancy
5. Hereditary predisposition
6. Tumours of the rectum.

M/E Thin-walled and dilated tortuous veins are seen under the rectal mucosa (*internal piles*) or anal skin (*external piles*). Secondary changes and complications that may occur include: thrombosis, haemorrhage, inflammation, scarring and strangulation (*prolapsed piles*).

ANGIODYSPLASIA (p. 581)

Angiodysplasia is a submucosal telangiectasia affecting caecum and right colon that causes recurrent acute and chronic haemorrhage. The condition is more common in the elderly past 6th decade. The pathogenesis is obscure but is possibly due to mechanical obstruction of the veins.

MISCELLANEOUS INFLAMMATORY CONDITIONS (p. 581)

◆ **'Fistula-in-ano'** is a well known and common condition in which one or more fistulous tracts pass from the internal opening at the pectinate line through the internal sphincter on to the skin surface.

◆ **'Anal fissure'** is an ulcer in the anal canal below the level of the pectinate line, mostly in midline and posteriorly. The common cause is trauma due to passage of hard stools, followed by chronic infection.

◆ **'Solitary rectal ulcer syndrome'** is a condition characterised usually by solitary, at times multiple, rectal ulcers with prolapse of rectal mucosa and development of proctitis. The histological appearance is quite characteristic. Besides ulceration and inflammation of the rectal mucosa, lamina propria is occupied by spindle-shaped fibroblasts and smooth muscle cells.

LARGE INTESTINAL POLYPS AND TUMOURS (p. 581)

Large bowel is the most common site for a variety of benign and malignant tumours, majority of which are of epithelial origin. A classification of polyps, alongwith benign tumours and malignant tumours, is presented in **Web Table 20.10**.

COLORECTAL POLYPS (p. 582)

A polyp is defined as any growth or mass protruding from the mucous membrane into the lumen. Polyps are much more common in the large intestine than in the small intestine and are more common in the recto-sigmoid colon than the proximal colon. Polyps are broadly classified into 2 groups—non-neoplastic and neoplastic (**Web Table 20.10**).

A. NON-NEOPLASTIC POLYPS (p. 582)

Hyperplastic (Metaplastic) Polyps (p. 582)

The hyperplastic or metaplastic polyps are the most common amongst all epithelial polyps, particularly in the rectosigmoid. They are called '*hyperplastic*' because there is epithelial hyperplasia at the base of the crypts, and '*metaplastic*' as there are areas of cystic metaplasia. They may be seen at any age but are more common in the elderly (6th-7th decade).

490 G/A Hyperplastic polyps are generally multiple, sessile, smooth-surfaced and small (less than 0.5 cm).

M/E They are composed of long and cystically dilated glands and crypts lined by normal epithelial cells. Their lining is partly flat and partly papillary.

Hyperplastic polyps are usually symptomless and have no malignant potential unless there is a coexistent adenoma.

Hamartomatous Polyps (p. 582)

These are tumour-like lesions composed of abnormal mixture of tissues indigenous to the part. They are further of 2 types:

PEUTZ-JEGHERS POLYPS AND POLYPOSIS. Peutz-Jeghers syndrome is autosomal dominant defect, characterised by hamartomatous intestinal polyposis and melanotic pigmentation of lips, mouth and genitalia.

G/A These polyps are of variable size but are often large, multiple and pedunculated and more commonly situated in the small intestine.

M/E The most characteristic feature is the tree-like branching of muscularis mucosae. The lining epithelium is by normal-appearing epithelial cells (**Web Image 20.41**).

JUVENILE (RETENTION) POLYPS. Juvenile or retention polyps, another form of hamartomatous polyps, occur more commonly in children below 5 years of age. Solitary juvenile polyps occur more often in the rectum.

G/A Juvenile polyps are spherical, smooth-surfaced, about 2 cm in diameter and are often pedunculated.

M/E The classical appearance is of cystically dilated glands containing mucus and lined by normal mucus-secreting epithelium. The stroma may show inflammatory cell infiltrate if there is chronic ulceration of the surface (**Web Image 20.42**).

Inflammatory Polyps (Pseudopolyps) (p. 583)

Inflammatory polyps or pseudopolyps appear due to re-epithelialisation of the undermined ulcers and overhanging margins in inflammatory bowel disease, most frequently in ulcerative colitis (colitis polyposa) and sometimes in Crohn's disease.

G/A They are usually multiple, cylindrical to rounded overgrowths of mucosa and may vary from minute nodules to several centimeters in size.

M/E The centre of inflammatory polyp consists of connective tissue core that shows some inflammatory cell infiltrate and is covered superficially by regenerating epithelial cells and some cystically-dilated glands.

These lesions have no malignant potential; carcinomas seen in long-standing cases of ulcerative colitis arise in the region of epithelial dysplasia and not from the polyps.

Lymphoid Polyps (p. 583)

Reactive hyperplasia of lymphoid tissue that is normally also more prominent in the rectum and terminal ileum, gives rise to localised or diffuse lymphoid polyps, also called rectal tonsils.

G/A They are solitary or multiple, tiny elevated lesions.

M/E They are composed of prominent lymphoid follicles with germinal centres located in the submucosa and mucosa, and are covered by epithelium that may be inflamed.

They are benign lesions and have to be distinguished from malignant lymphoma.

B. NEOPLASTIC POLYPS (ADENOMAS) (p. 583)

Neoplastic polyps are colorectal adenomas which have potential for malignant change while polypoid carcinoma is the term used for invasive epithelial tumours. Adenomas have 3 main varieties (tubular, villous and tubulovillous).

Tubular Adenoma (Adenomatous Polyp) (p. 584)

Tubular adenomas or adenomatous polyps are the most common neoplastic polyps (75%). They are common beyond 3rd decade of life and have slight male preponderance. They occur most often in the distal colon and rectum.

G/A Adenomatous polyps may be single or multiple, sessile or pedunculated, vary in size from less than 1 cm to large, spherical masses with an irregular surface.

M/E The usual appearance is of benign tumour overlying muscularis mucosa and is composed of branching tubules which are embedded in the lamina propria. The lining epithelial cells are of large intestinal type with diminished mucus secreting capacity, large nuclei and increased mitotic activity (**Web Image 20.43,A**). However, tubular adenomas may show variable degree of cytologic atypia ranging from atypical epithelium restricted within the glandular basement membrane called as 'carcinoma *in situ*' to invasion into the fibrovascular stromal core termed as frank adenocarcinoma.

Malignant transformation is present in about 5% of tubular adenomas; the incidence being higher in larger adenomas.

Villous Adenoma (Villous Papilloma) (p. 584)

Villous adenomas or villous papillomas of the colon are much less common than tubular adenomas. The mean age at which they appear is 6th decade of life with approximate equal sex incidence.

G/A Villous adenomas are round to oval exophytic masses, usually sessile, varying in size from 1 to 10 cm or more in diameter.

M/E The characteristic histologic feature is the presence of many slender, finger-like villi, which appear to arise directly from the area of muscularis mucosae. Each of the papillae has fibrovascular stromal core that is covered by epithelial cells varying from apparently benign to anaplastic cells (**Web Image 20.43,B**).

Villous adenomas are invariably symptomatic; rectal bleeding, diarrhoea and mucus being the common features. The presence of severe atypia, carcinoma *in situ* and invasive carcinoma are seen more frequently. Invasive carcinoma has been reported in 30% of villous adenomas.

Tubulovillous Adenoma (Papillary Adenoma, Villoglandular Adenoma) (p. 584)

Tubulovillous adenoma is an intermediate form of pattern between tubular adenoma and villous adenoma. It is also known by other names like papillary adenoma and villo-glandular adenoma.

G/A Tubulovillous adenomas may be sessile or pedunculated and range in size from 0.5-5 cm.

M/E They show intermediate or mixed pattern, characteristic vertical villi and deeper part showing tubular pattern (**Web Image 20.43,C**).

The behaviour of tubulovillous adenoma is intermediate between tubular and villous adenomas.

The contrasting features of non-neoplastic and neoplastic colorectal polyps are given in **Web Table 20.11**.

492 C. FAMILIAL POLYPOSIS SYNDROMES (p. 585)

Familial polyposis syndromes are a group of disorders with multiple polyposis of the colon with autosomal dominant inheritance pattern.

Familial Polyposis Coli (Adenomatosis) (p. 585)

This hereditary disease is defined as the presence of more than 100 neoplastic polyps (adenomas) on the mucosal surface of the colon; the average number is about 1000 (**Web Image 20.44**). Adenomatosis can be distinguished from multiple adenomas in which the number of adenomas is fewer, not exceeding 100. The condition has autosomal dominant transmission and is due to germline mutations in *APC* gene which results in occurrence of hundreds of adenomas which progress to invasive cancer. The average age at diagnosis is 2nd and 3rd decades of life with equal incidence in both the sexes.

G/A and M/E The commonest pattern is that of adenomatous polyps (tubular adenomas) discussed above.

The malignant potential of familial polyposis coli is very high. Colorectal cancer develops virtually in 100% of cases by age of 50 years if not treated with colectomy. This subject of 'adenoma-carcinoma sequence' has been discussed again on page 493.

Gardner's Syndrome (p. 585)

Gardner's syndrome is combination of familial polyposis coli and certain extra-colonic lesions such as multiple osteomas (particularly of the mandible and maxilla), sebaceous cysts and connective tissue tumours. The number of polyps in Gardner's syndrome is generally fewer than in the familial polyposis coli but their clinical behaviour is identical.

Turcot's Syndrome (p. 586)

Turcot's syndrome is combination of familial polyposis coli and malignant neoplasms of the central nervous system.

Juvenile Polyposis Syndrome (p. 586)

Juvenile polyposis is appearance of multiple juvenile polyps in the colon, stomach and small intestine but their number is not as high as in familial polyposis coli. Family history in some cases may show autosomal dominant inheritance pattern, while it may be negative in others. They resemble the typical juvenile polyps as regards their age (under 5 years), sex distribution and morphology. They lack the malignant potential.

OTHER BENIGN TUMOURS (p. 586)

Some non-epithelial benign tumours that may rarely occur in large intestine are leiomyomas, leiomyoblastoma, neurilemmoma, lipoma and vascular tumours (haemangioma, lymphangioma).

MALIGNANT COLORECTAL TUMOURS (p. 586)

A. Colorectal Carcinoma (p. 586)

Colorectal cancer comprises 98% of all malignant tumours of the large intestine. It is the commonest form of visceral cancer accounting for deaths from cancer in the United States, next only to lung cancer. The incidence of carcinoma of the large intestine rises with age; average age of patients is about 60 years. Cancer in the rectum is more common in males than females in the ratio of 2:1, while at other locations in the large bowel the overall incidence is equal for both sexes.

ETIOLOGY. A few etiological factors have been implicated:

1. Geographic variations. The incidence of large bowel carcinoma shows wide variation throughout the world. It is much more common in North America, Northern Europe than in South America, Africa and Asia.

2. Dietary factors. Diet plays a significant part in the causation of colorectal cancer:

- i) A low intake of vegetable fibre-diet.
- ii) Consumption of large amounts of fatty foods.
- iii) Excessive consumption of refined carbohydrates.

3. Adenoma-carcinoma sequence. There is strong evidence to suggest that colonic adenocarcinoma evolves from pre-existing adenomas, referred to as adenoma-carcinoma sequence (**Web Image 20.45**). The following evidences are cited to support this hypothesis:

- i) In a case with early invasive cancer, the surrounding tissue often shows *preceding changes* of evolution from adenoma → hyperplasia → dysplasia → carcinoma *in situ* → invasive carcinoma.
- ii) *Incidence* of adenomas in a population is directly proportionate to the prevalence of colorectal cancer.
- iii) The risk of adenocarcinoma colon declines with *endoscopic removal* of all identified adenomas.
- iv) Peak incidence of adenomas generally *precedes* by some years to a few decades the peak incidence for colorectal cancer.
- v) The risk of malignancy increases with the following *adenoma-related factors*:
 - a) *Number of adenomas*: familial polyposis coli syndrome almost certainly evolves into malignancy.
 - b) *Size of adenomas*: large size increases the risk.
 - c) *Type of adenomas*: greater villous component associated with higher prevalence.

4. Hereditary non-polyposis colonic cancer (HNPCC or Lynch syndrome). HNPCC is an autosomal dominant condition in which colorectal cancer is seen in at least two generations of first-degree relatives before the age of 50 years, without evidence of familial polyposis coli. There are germline mutations in mismatch repair genes, human mutL homolog abbreviated as *hMLH2* located on chromosome 2 and *hMLH1* on chromosome 3 resulting in DNA instability. In HNPCC, colon cancer appears at a relatively younger age (<50 years), association with multiple primary cancers at different sites (e.g. endometrium, ovary), preferred location in proximal colon and better prognosis than other sporadic colon cancer cases.

5. Other factors. Presence of certain pre-existing diseases such as inflammatory bowel disease (especially ulcerative colitis) and diverticular disease for long duration increase the risk of developing colorectal cancer subsequently.

GENETIC BASIS OF COLORECTAL CARCINOGENESIS. Studies by molecular genetics have revealed that there are sequential multistep mutations in evolution of colorectal cancer from adenomas by one of the following two mechanisms:

1. APC mutation/ β -catenin mechanism. This pathway of multiple mutations is generally associated with morphologically identifiable changes as described above in adenoma-carcinoma sequence. These changes are as under:

- i) *Loss of tumour suppressor APC* (adenomatous polyposis coli) gene located on the long arm of chromosome 5 (5q) is present in 80% cases of sporadic colon cancer. Since the function of *APC* gene is linked to β -catenin, loss of *APC* gene results in translocation of β -catenin to the nucleus where it activates transcription of other genes, mainly *MYC* and cyclin D1, both of which stimulate cell proliferation.

- ii) *Point mutation in K-RAS gene* follows loss of *APC* gene and is seen in 10 to 50% cases of adenoma-carcinoma.
- iii) *Deletion of DCC gene* located on long arm of chromosome 18 i.e. 18q (*DCC* for *deleted in colorectal cancer*) in 60-70% cases of colon cancer.
- iv) *Loss of p53 tumour suppressor gene* seen in 70-80% cases of colon cancer.

2. Microsatellite instability mechanism. In this pathway also, there are multiple mutations but of different genes, and unlike *APC* mutation/ β -catenin mechanism there are no morphologically identifiable changes. This pathway accounts for 10-15% cases of colon cancer. Basic mutation is loss of DNA repair gene. This results in a situation in which repetitive DNA sequences (i.e. microsatellites) become unstable during replication cycle, termed microsatellite instability, which is the hallmark of this pathway. The significant DNA repair genes which are mutated in colon cancer are as under:

- i) *TGF- β receptor gene* and ii) *BAX gene*.

MORPHOLOGIC FEATURES. *Distribution* of the primary colorectal cancer reveals that about 60% of the cases occur in the rectum, followed in descending order, by sigmoid and descending colon (25%), caecum and ileocaecal valve (10%); ascending colon, hepatic and splenic flexures (5%); and quite uncommonly in the transverse colon (**Web Image 20.46**).

G/A There are distinct differences between the growth on the right and left half of the colon (**Web Image 20.47**).

- ◆ **Right-sided colonic growths** tend to be large, cauliflower-like, soft and friable masses projecting into the lumen (*fungating polypoid carcinoma*).

- ◆ **Left-sided colonic growths**, on the other hand, have napkin-ring configuration i.e. they encircle the bowel wall circumferentially with increased fibrous tissue forming annular ring, and have central ulceration on the surface with slightly elevated margins (*carcinomatous ulcers*).

M/E The appearance of right and left-sided growths is similar. About 95% of colorectal carcinomas are adenocarcinomas of varying grades of differentiation, out of which approximately 10% are mucin-secreting colloid carcinomas (**Web Image 20.48**). The remaining 5% tumours include uncommon microscopic patterns like undifferentiated carcinoma, signet-ring cell carcinoma, and adeno-squamous carcinomas seen in more distal colon near the anus. The histologic grades indicating the degree of differentiation are: well-differentiated, moderately-differentiated and poorly-differentiated.

SPREAD. Carcinoma of the large intestine may spread by the following routes:

- 1) Direct spread, 2) Lymphatic spread and 3) Haematogenous spread.

CLINICAL FEATURES. Clinical symptoms in colorectal cancer appear after considerable time. These are as follows:

- i) Occult bleeding (melaena)
- ii) Change in bowel habits, more often in left-sided growth
- iii) Loss of weight (cachexia)
- iv) Loss of appetite (anorexia)
- v) Anaemia, weakness, malaise.

Recently the role of tumour-markers has been emphasised. Of particular importance is the estimation of carcinoembryonic antigen (CEA) level which is elevated in 100% cases of metastatic colorectal cancers, while it is positive in 20-40% of early lesions, and 60-70% of advanced primary lesions. However, the test may have prognostic significance only and is not diagnostic of colorectal cancer because it is positive in other cancers too such as of the lungs, breast, ovary, urinary bladder and prostate. CEA levels are elevated in some non-neoplastic conditions also like in ulcerative colitis, pancreatitis and alcoholic cirrhosis.

STAGING AND PROGNOSIS. The *prognosis* of colorectal cancer depends upon a few variables:

- i) Extent of the bowel involvement
- ii) Presence or absence of metastases
- iii) Histologic grade of the tumour
- iv) Location of the tumour

The most important prognostic factor in colorectal cancer is, however, the *stage* of the disease at the time of diagnosis. Three staging systems are in use:

1. *Dukes' ABC staging* (modified Duke's includes stage D as well).
2. *Astler-Coller staging* which is a further modification of Duke's staging and is most widely used.
3. *TNM staging* described by American Joint Committee is also used.

Web Table 20.12 and **Web Image 20.49** sum up the features of staging classification and the overall 5-year survival rate in disease stage.

□ **TUMOURS OF THE ANAL CANAL** (p. 589)

Epithelial tumours of the anal canal are uncommon and may be combination of several histological types. Amongst the *benign tumours* of the anal canal, multiple viral warts called as condyloma acuminata are the only tumours of note. *Malignant tumours* of the anal canal include the following:

1. Squamous cell carcinoma (**Web Image 20.50**)
2. Basaloid carcinoma
3. Mucoepidermoid carcinoma
4. Adenocarcinoma (rectal, of anal glands, within anorectal fistulas)
5. Undifferentiated carcinoma
6. Malignant melanoma.

These tumours resemble in morphology with similar lesion elsewhere in the body.

CAUSES OF GASTROINTESTINAL BLEEDING (p. 590)

Gastrointestinal bleeding from upper (haematemesis), middle (small intestinal) and lower (melaena) is a major presenting clinical feature of a variety of gastrointestinal diseases. **Web Table 20.13** summarises the main causes of gastrointestinal bleeding.

PERITONEUM (p. 590)

□ **NORMAL STRUCTURE** (p. 590)

The peritoneal cavity is lined by a layer of surface mesothelium derived from mesoderm. The lining rests on vascularised subserosal fibrous tissue. Other structures topographically related to peritoneum are retroperitoneum, omentum, mesentery and umbilicus.

□ **PERITONITIS** (p. 590)

Inflammatory involvement of the peritoneum may result from chemical agents or bacteria.

1. **Chemical peritonitis** can be caused by the following:

- ◆ *Bile*
- ◆ *Pancreatic*
- ◆ *Gastric juice*
- ◆ *Barium sulfate*

Chemical peritonitis is localised or generalised sterile inflammation of the peritoneum.

2. **Bacterial peritonitis** may be primary or secondary; the latter being more common. *Primary* form is caused by streptococcal infection, especially

496 in children. *Secondary* bacterial peritonitis may occur from the following disorders:

- ◆ Appendicitis
- ◆ Cholecystitis
- ◆ Salpingitis
- ◆ Rupture of peptic ulcer
- ◆ Gangrene of bowel
- ◆ Tuberculosis (specific inflammation).

□ **IDIOPATHIC RETROPERITONEAL FIBROSIS** (p. 591)

Also known as Ormond's disease or sclerosing retroperitonitis, this rare entity of unknown etiology is characterised by diffuse fibrous overgrowth and chronic inflammation. The condition is, therefore, more like inflammatory rather than neoplastic in origin. It may be associated with similar process in the mediastinum, sclerosing cholangitis and Riedel's thyroiditis and termed *multifocal fibrosclerosis*.

□ **MESENTERIC CYSTS** (p. 591)

Mesenteric cysts of unknown etiology and varying sizes may be found in the peritoneal cavity. On the basis of their possible origin, they are of various types:

- ◆ *Chylous cyst*
- ◆ *Pseudocysts*
- ◆ *Neoplastic cysts*.

□ **TUMOURS** (p. 591)

Peritoneum may be involved in malignant tumours—primary and metastatic.

- ◆ **Mesothelioma** is an example of primary peritoneal tumour (benign and malignant) and is similar in morphology as in pleural cavity.
- ◆ **Intra-abdominal desmoplastic small cell tumour** is a recently described highly malignant tumour belonging to the group of other round cell or blue cell tumours such as small cell carcinoma lung, Ewing's sarcoma, rhabdomyosarcoma, neuroblastoma and others.
- ◆ **Metastatic peritoneal tumours** are quite common and may occur from dissemination from any intra-abdominal malignancy.

◆ **SELF ASSESSMENT**

1. **The distance from the incisor teeth to the gastro-oesophageal junction is:**
 - A. 25 cm
 - B. 30 cm
 - C. 35 cm
 - D. 40 cm
2. **Oesophageal webs have the following features except:**
 - A. They are located at lower oesophagus
 - B. They are associated with dysphagia
 - C. They are associated with chronic atrophic glossitis
 - D. They are associated with iron deficiency anaemia
3. **Some of the common causes of haematemesis of oesophageal origin are as follows except:**
 - A. Oesophageal varices
 - B. Mallory-Weiss syndrome
 - C. Reflux oesophagitis
 - D. Oesophageal rupture
4. **Some common conditions predisposing to reflux oesophagitis are as follows except:**
 - A. Hiatus hernia
 - B. Mallory-Weiss syndrome
 - C. Peptic ulcers
 - D. Persistent vomiting

5. **The nature of lesion in Barrett's oesophagus is:**
 - A. Congenital anomaly
 - B. Inflammatory disease
 - C. Metaplastic process
 - D. Neoplastic lesion
6. **Barrett's oesophagus predisposes to development of:**
 - A. Reflux oesophagitis
 - B. Oesophageal varices
 - C. Squamous cell carcinoma
 - D. Adenocarcinoma
7. **The most frequent anatomic site for squamous cell carcinoma of the oesophagus is:**
 - A. Upper third
 - B. Middle third
 - C. Lower third
 - D. Gastro-oesophageal junction
8. ***H. pylori* gastritis has the following features except:**
 - A. *H. pylori* is seen on the epithelial layer of the luminal surface
 - B. *H. pylori* is seen on areas with intestinal metaplasia
 - C. *H. pylori* does not invade the mucosa
 - D. *H. pylori* gastritis may lead to malignant transformation
9. **Patients of benign gastric ulcer generally have:**
 - A. High gastric acid
 - B. Normal-to-high gastric acid
 - C. Normal-to-low gastric acid
 - D. Absence of gastric acid
10. **Duodenal ulcers are found most commonly at:**
 - A. First part, anterior surface
 - B. First part, posterior surface
 - C. Second part, anterior surface
 - D. Second part, posterior surface
11. **The most common location for gastric colloid carcinoma is:**
 - A. Cardia
 - B. Fundus
 - C. Body
 - D. Pylorus
12. **The most common gross growth pattern of gastric carcinoma is:**
 - A. Scirrhous
 - B. Fungating
 - C. Ulcerative
 - D. Colloid
13. **Meckel's diverticulum is commonly located at:**
 - A. Mesenteric border of small intestine one meter above ileocaecal valve
 - B. Mesenteric border of small intestine two meter above ileocaecal valve
 - C. Antimesenteric border of small intestine one meter above ileocaecal valve
 - D. Antimesenteric border of small intestine two meter above ileocaecal valve
14. **The remnants of vitellointestinal duct are in the form of following lesions except:**
 - A. Vitelline sinus
 - B. Vitelline cyst
 - C. Omphalocele
 - D. Meckel's diverticulum
15. **Following humoral factors are implicated in the etiology of inflammatory bowel disease except:**
 - A. Anti-colon antibodies to *E. coli*
 - B. Decreased synthesis of IgG
 - C. IgE-mediated hypersensitivity
 - D. Circulating immune complexes
16. **Crohn's disease is characterised by the following histopathologic features except:**
 - A. Non-caseating sarcoid like granulomas
 - B. Superficial mucosal ulceration
 - C. Stricture formation in chronic cases
 - D. Widening of submucosa due to oedema

17. **The following features characterise ulcerative colitis *except*:**
- Formation of crypt abscess and cryptitis
 - Superficial mucosal ulceration
 - Depletion of goblet cells and mucus
 - Stricture formation in chronic cases
18. **Long-standing cases of Crohn's disease may develop the following complications *except*:**
- Malabsorption
 - Toxic megacolon
 - Fistula formation
 - Stricture formation
19. **Tuberculous ulcers in bowel have the following features *except*:**
- They begin in the Peyer's patches
 - They are transverse to the long axis
 - Advanced cases may cause intestinal obstruction
 - Tuberculous ulcers often cause intestinal perforation
20. **The major complication of typhoid ulcer is:**
- Intestinal obstruction
 - Intestinal perforation
 - Malabsorption
 - Fistula formation
21. **Pseudomembranous enterocolitis occurs most often in association with the following:**
- Shigella dysentery
 - Candida enterocolitis
 - Cephalosporin antibiotics
 - Clostridial food poisoning
22. **Common causes of total/subtotal villous atrophy are as follows *except*:**
- Crohn's disease
 - Tropical sprue
 - Nontropical sprue
 - Intestinal lymphoma
23. **The nature of Whipple's disease is:**
- Genetic defect
 - Familial occurrence
 - Bacterial infection
 - Hypersensitivity reaction
24. **The most common location for carcinoid tumour is:**
- Foregut
 - Midgut
 - Hindgut
 - Equal at all these three sites
25. **The histologic hallmark of diagnosis of acute appendicitis is:**
- Mucosal ulceration
 - Impacted foreign body
 - Neutrophilic infiltrate in muscularis
 - Thrombosed blood vessels
26. **Out of various patterns of Hirschsprung's disease, the most common is:**
- Total colonic aganglionosis
 - Long segment disease
 - Short segment disease
 - Ultra short segment disease
27. **The following type of colorectal polyps has highest malignant transformation:**
- Hyperplastic polyp
 - Adenomatous
 - Villous adenoma
 - Tubulovillous adenoma
28. **The most common location for primary colorectal carcinoma is:**
- Rectum
 - Sigmoid and descending colon
 - Caecum and ileocaecal valve
 - Ascending colon
29. **Elevation of carcinoembryonic antigen (CEA) level is particularly significant in:**
- Early lesion of colorectal carcinoma
 - Advanced primary colorectal carcinoma
 - Metastatic colorectal carcinoma
 - Ulcerative colitis

30. Intra-abdominal desmoplastic small cell tumour is a:
 A. Benign tumour
 B. Fibromatosis
 C. Tumour-like lesion
 D. Highly malignant tumour
31. The significant genetic mutations in adenoma-carcinoma sequence are all the following except:
 A. Loss of APC gene
 B. Deletion of DCC gene
 C. Mutated RB gene
 D. Mutation in K-RAS gene
32. *H. pylori* colonisation of gastric mucosa is implicated in the following diseases except:
 A. Gastritis
 B. Gastric carcinoma
 C. MALT lymphoma
 D. Intestinal metaplasia
33. Which of the following is not implicated in oesophageal carcinoma?
 A. HPV infection
 B. Mallory Weiss Syndrome
 C. Plummer Vinson Syndrome
 D. Heavy smoking
34. In gastric ulcer, BAO and MAO are:
 A. Normal
 B. Elevated
 C. Absent
 D. Markedly decreased but not absent
35. Which classification system is used for gastritis?
 A. Bethesda system
 B. Geneva system
 C. Sydney system
 D. WHO system
36. Partial villous atrophy is seen in all except:
 A. Crohn's disease
 B. Parasitic infestation
 C. Drugs
 D. Tropical sprue
37. Most common malignant tumour of the small intestine is:
 A. Carcinoid tumour
 B. Lymphoma
 C. Adenocarcinoma
 D. Malignant GIST
38. All are hamartomatous polyps except:
 A. Juvenile polyps
 B. Peutz-Jeghar's polyps
 C. Retention polyps
 D. Metaplastic polyps
39. Which of the following is not familial polyposis syndrome?
 A. Cronkhite Canada syndrome
 B. Gardner's syndrome
 C. Turcot's syndrome
 D. Juvenile polyposis syndrome
40. Disease predisposing locus implicated in Crohn's disease:
 A. CARD 15
 B. CARD 14
 C. CARD 24
 D. CARD 25

KEY

1 = D	2 = A	3 = C	4 = B
5 = C	6 = D	7 = B	8 = B
9 = C	10 = A	11 = B	12 = C
13 = C	14 = C	15 = B	16 = B
17 = D	18 = B	19 = D	20 = B
21 = C	22 = A	23 = C	24 = B
25 = C	26 = C	27 = C	28 = A
29 = C	30 = D	31 = C	32 = D
33 = B	34 = A	35 = C	36 = D
37 = A	38 = D	39 = A	40 = A



The Liver, Biliary Tract and Exocrine Pancreas

□ NORMAL STRUCTURE (p. 592)

ANATOMY. The liver is the largest organ in the body weighing 1400-1600 gm in the males and 1200-1400 gm in the females. There are 2 main anatomical lobes—right and left, the right being about six times the size of the left lobe. The right and left lobes are separated anteriorly by a fold of peritoneum called the *falciform ligament*, inferiorly by the fissure for the *ligamentum teres*, and posteriorly by the fissure for the *ligamentum venosum* (**Web Image 21.1**).

The *porta hepatis* is the region on the inferior surface of the right lobe where blood vessels, lymphatics and common hepatic duct form the hilum of the liver. A firm smooth layer of connective tissue called *Glisson's capsule* encloses the liver and is continuous with the connective tissue of the porta hepatis forming a sheath around the structures in the porta hepatis. The liver has a double blood supply—the portal vein brings the venous blood from the intestines and spleen, and the hepatic artery coming from the coeliac axis supplies arterial blood to the liver. This dual blood supply provides sufficient protection against infarction in the liver. The right and left hepatic ducts also join in the porta to form the common hepatic duct. The venous drainage from the liver is into the right and left hepatic veins which enter the inferior vena cava.

HISTOLOGY. The hepatic parenchyma is composed of numerous hexagonal or pyramidal *classical lobules*, each with a diameter of 0.5 to 2 mm. Each classical lobule has a central tributary from the hepatic vein and at the periphery are 4 to 5 portal tracts or triads containing branches of bile duct, portal vein and hepatic artery. Cords of hepatocytes and blood-containing sinusoids radiate from the central vein to the peripheral portal triads.

The blood supply to the liver parenchyma flows from the portal triads to the central veins. Accordingly, the hepatic parenchyma of liver lobule is divided into 3 zones (**Web Image 21.2**):

- ◆ **Zone 1** or the *periportal (peripheral) area* is closest to the arterial and portal blood supply and hence bears the brunt of all forms of toxic injury.
- ◆ **Zone 3** or the *centrilobular area* surrounds the central vein and is most remote from the blood supply and thus suffers from the effects of hypoxic injury.
- ◆ **Zone 2** is the intermediate *midzonal area*.

The **hepatocytes** are polygonal cells with a round single nucleus and a prominent nucleolus. A hepatocyte has 3 surfaces: *one* facing the sinusoid and the space of Disse, the *second* facing the canaliculus, and the *third* facing neighbouring hepatocytes.

The blood-containing *sinusoids* between cords of hepatocytes are lined by discontinuous endothelial cells and scattered flat Kupffer cells belonging to the reticuloendothelial system.

The *space of Disse* is the space between hepatocytes and sinusoidal lining endothelial cells. A few scattered fat storing *lto cells* lie within the space of Disse.

FUNCTIONS. The liver performs multifold functions:

1. Manufacture and excretion of bile.

2. Manufacture of several major plasma proteins such as albumin, fibrinogen and prothrombin.
3. Metabolism of proteins, carbohydrates and lipids.
4. Storage of vitamins (A, D and B₁₂) and iron.
5. Detoxification of toxic substances such as alcohol and drugs.

□ **LIVER FUNCTION TESTS** (p. 593)

A summary of various liver function tests is given in **Web Table 21.1**.

I. TESTS FOR MANUFACTURE AND EXCRETION OF BILE (p. 593)

Bile is produced by the liver, stored in the gallbladder and secreted via biliary ducts into the duodenum. Bile consists of biliary phospholipids and primary and secondary bile acids. In brief, jaundice will develop if bilirubin is excessively produced, or there is impaired hepatic uptake and conjugation of bilirubin, or it is insufficiently excreted into the duodenum.

1. BILIRUBIN. Bilirubin pigment can be detected in serum, faeces and urine.

i) Serum bilirubin estimation is based on *van den Bergh diazo reaction* by spectrophotometric method. *Water-soluble conjugated* bilirubin gives *direct* van den Bergh reaction with diazo reagent within one minute, whereas *alcohol-soluble unconjugated* bilirubin is determined by *indirect* van den Bergh reaction. The serum of normal adults contains less than 1 mg/dl of total bilirubin, out of which less than 0.25 mg/dl is conjugated bilirubin. Bilirubin level rises in diseases of hepatocytes, obstruction to biliary excretion into the duodenum, in haemolysis, and defects of hepatic uptake and conjugation of bilirubin pigment such as in Gilbert's disease.

ii) In faeces, excretion of bilirubin is assessed by inspection of stools. Clay-coloured stool due to absence of faecal excretion of the pigment indicates obstructive jaundice.

iii) In urine, conjugated bilirubin can be detected by commercially available 'dipsticks', Fouchet's test, foam test or icotest tablet method. Bilirubinuria does not occur in normal subjects nor is unconjugated bilirubin excreted in the urine.

2. UROBILINOGEN. Urobilinogen is normally excreted in the urine. An increase in urobilinogen in the urine is found in hepatocellular dysfunctions such as in alcoholic liver disease, cirrhosis and malignancy of the liver. It is also raised in haemolytic disease and in pyrexia. In cholestatic jaundice due to complete biliary obstruction, urobilinogen disappears from the urine.

3. BROMSULPHALEIN EXCRETION. Bromsulphalein (BSP) is a dye which is removed from circulation by the same mechanisms of binding, conjugation and excretion as bilirubin. BSP is injected intravenously and a sample of venous blood 45 minutes later is tested for percentage of injected dye remaining in the blood. Presently, the only value of BSP excretion test is in the diagnosis of Dubin-Johnson's syndrome.

4. BILE ACIDS (BILE SALTS). The primary bile acids (cholic acid and cheno-deoxycholic acid) are formed from cholesterol in the hepatocytes.

Hepatobiliary diseases with cholestasis are associated with raised levels of serum bile acids which are responsible for producing itching (pruritus). These acids are excreted in the urine by active transport and passive diffusion and can be detected by simple methods as Hay's test and 'dipsticks'.

II. SERUM ENZYME ASSAYS (p. 595)

1. ALKALINE PHOSPHATASE. Serum alkaline phosphatase is produced by many tissues, especially bone, liver, intestine and placenta and is excreted in the bile. Most of the normal serum alkaline phosphatase (range 33-96 U/L) is derived from bone. Elevation in activity of the enzyme can thus be found in diseases of bone, liver and in pregnancy. In the absence of

502 bone disease and pregnancy, an elevated serum alkaline phosphatase levels generally reflect hepatobiliary disease. The greatest elevation (3 to 10 times normal) occurs in biliary tract obstruction.

2. γ -GLUTAMYL TRANSPEPTIDASE (γ -GT). The primary source of the enzyme, γ -GT, in serum is the liver. Its serum level parallels serum alkaline phosphatase and is used to confirm that the elevated serum alkaline phosphatase is of hepatobiliary origin. Besides its elevation in cholestasis and hepatocellular disease, the levels are high in patients with alcohol abuse even without liver disease.

3. TRANSAMINASES (AMINOTRANSFERASES). Assessment of liver cell necrosis is most frequently done by estimation of the following 2 serum enzymes:

i) Serum aspartate transaminase or AST (formerly glutamic oxaloacetic transaminase or SGOT): AST or SGOT is a *mitochondrial enzyme* released from heart, liver, skeletal muscle and kidney. Its normal serum level is 0.20-0.65 μ kat/L (12-38 U/L).

ii) Serum alanine transaminase or ALT (formerly glutamic pyruvic transaminase or SGPT): ALT or SGPT is a *cytosolic enzyme* primarily present in the liver. Its normal serum level is 0.12-0.70 μ kat/L (7-41 U/L).

Serum levels of SGOT and SGPT are increased on damage to the tissues producing them. Thus serum estimation of SGPT (ALT) which is fairly specific for liver tissue is of greater value in liver cell injury, whereas SGOT (AST) level may rise in acute necrosis or ischaemia of other organs such as the myocardium, besides liver cell injury.

Transaminase estimations are useful in the early diagnosis of viral hepatitis. Very high levels are seen in extensive acute hepatic necrosis such as in severe viral hepatitis and acute cholestasis.

4. OTHER SERUM ENZYMES. These include following:

i) *5'-Nucleotidase* is another phosphatase derived from the liver. Its determination is useful to distinguish alkaline phosphatase of hepatic origin from that of bony tissue.

ii) *Lactic dehydrogenase (LDH)* is found to be elevated in serum of patients with metastatic liver involvement.

iii) *Choline esterase* synthesised by the liver is diminished in hepatocellular disease and malnutrition due to impaired synthesis.

III. TESTS FOR METABOLIC FUNCTIONS (p. 595)

1. AMINO ACID AND PLASMA PROTEIN METABOLISM. Amino acids derived from the diet and from tissue breakdown are metabolised in the liver to ammonia and urea. A number of plasma proteins and immunoglobulins are synthesised on polyribosomes bound to the rough endoplasmic reticulum within the hepatocytes and discharged into plasma.

i) Serum proteins. Liver cells synthesise albumin, fibrinogen, prothrombin, alpha-1-antitrypsin, haptoglobin, ceruloplasmin, transferrin, alpha fetoproteins and acute phase reactant proteins. The blood levels of these plasma proteins are decreased in extensive liver damage. Routinely estimated are total concentration of serum proteins (normal 6.7 to 8.6 gm/dl), serum albumin (normal 3.5 to 5.5 gm/dl), serum globulin (normal 2 to 3.5 gm/dl) and albumin/globulin (A/G) ratio (normal 1.5-3:1).

Hypoalbuminaemia may occur in liver diseases having significant destruction of hepatocytes. Hyperglobulinaemia may be present in chronic inflammatory disorders such as in cirrhosis and chronic hepatitis.

ii) Immunoglobulins. The levels of serum immunoglobulins produced by lymphocytes and plasma cells (IgG, IgM and IgA) show nonspecific abnormalities in liver diseases and represent inflammatory or immune response rather than liver cell dysfunction.

iii) Clotting factors. Hepatic synthetic function of several clotting factors can be assessed by a few simple coagulation tests. Prothrombin time and partial thromboplastin time, both of which reflect the activities of various clotting factors, are prolonged in patients with hepatocellular disease.

iv) Serum ammonia. High blood levels of ammonia are found in acute fulminant hepatitis, cirrhosis and hepatic encephalopathy.

2. LIPID AND LIPOPROTEIN METABOLISM. Lipids synthesised in the liver include cholesterol and cholesterol esters, phospholipids and triglycerides. These are: high density lipoproteins (HDL), low density lipoproteins (LDL) and very low density lipoproteins (VLDL).

- ◆ There is rise in total serum cholesterol in cholestasis, probably due to retention of cholesterol which is normally excreted in the bile (normal < 200 mg/dl). Serum triglyceride is also elevated in cholestasis.

- ◆ Values are lowered in acute and chronic diffuse liver diseases and in malnutrition.

3. CARBOHYDRATE METABOLISM. The liver plays a central role in carbohydrate metabolism. Blood glucose level is lowered in fulminant acute hepatic necrosis. In chronic liver disease, there is impaired glucose tolerance and relative insulin resistance.

IV. IMMUNOLOGIC TESTS (p. 596)

1. NONSPECIFIC IMMUNOLOGIC REACTIONS. These are:

- i) *Smooth muscle antibody* to actin component of muscle is formed in certain hepatic disorders with hepatic necrosis.
- ii) *Mitochondrial antibody* develops in patients with primary biliary cirrhosis.
- iii) *Antinuclear antibody* is present in some patients of chronic hepatitis.

2. ANTIBODIES TO SPECIFIC ETIOLOGIC AGENTS. These are:

- i) *Hepatitis B surface antigen (HBsAg)* can be demonstrated in cases of serum hepatitis.
- ii) *Hepatitis B core antibody (HBc)* can be detected in all patients with hepatitis B.
- iii) *Hepatitis Be antigen (HBeAg)* can be found in chronic varieties of hepatitis B.
- iv) *Amoeba antibodies to Entamoeba histolytica* develop in patients with amoebic liver abscess.

V. ANCILLARY DIAGNOSTIC TESTS (p. 596)

1. ULTRASONOGRAPHY. Ultrasound (US) examination of the liver is indicated in the following situations:

- i) Cholestasis of various etiologies to see the dilated intra- and extrahepatic canalicular tree.
- ii) Space-occupying lesions (SOLs) within the liver to determine whether they are neoplasms or non-neoplastic cysts.
- iii) To provide US-guidance for FNAC or liver biopsy.

2. FNAC AND/OR PERCUTANEOUS LIVER BIOPSY. Lastly, FNAC and percutaneous liver biopsy are employed to examine the microscopic changes of hepatic morphology in various diseases. Their main indications are as follows:

- i) hepatocellular disease of unknown cause;
- ii) suspected cases of chronic hepatitis;
- iii) hepatomegaly of various etiologies;
- iv) splenomegaly of unknown cause;
- v) fever of unknown cause; and
- vi) SOLs visualised in radiologic examination

Jaundice or icterus refers to the yellow pigmentation of the skin or sclerae by bilirubin. Bilirubin pigment has high affinity for elastic tissue and hence jaundice is particularly noticeable in tissues rich in elastin content. Jaundice is the result of elevated levels of bilirubin in the blood termed hyperbilirubinaemia. Normal serum bilirubin concentration ranges from 0.3-1.3 mg/dl, about 80% of which is unconjugated. Jaundice becomes clinically evident when the total serum bilirubin exceeds 2 mg/dl. A rise of serum bilirubin between the normal and 2 mg/dl is generally not accompanied by visible jaundice and is called *latent jaundice*.

NORMAL BILIRUBIN METABOLISM (p. 596)

Normal metabolism of bilirubin can be conveniently described under 4 main headings:

1. SOURCE OF BILIRUBIN. About 80-85% of the bilirubin is derived from the catabolism of haemoglobin present in senescent red blood cells. The destruction of effete erythrocytes at the end of their normal lifespan of 120 days takes place in the reticuloendothelial system in the bone marrow, spleen and liver. The remaining 15-20% of the bilirubin comes partly from non-haemoglobin haem-containing pigments such as myoglobin, catalase and cytochromes, and partly from ineffective erythropoiesis.

2. TRANSPORT OF BILIRUBIN. Bilirubin on release from macrophages circulates as unconjugated bilirubin in plasma tightly bound to albumin.

3. HEPATIC PHASE. On coming in contact with the hepatocyte surface, unconjugated bilirubin is preferentially metabolised which involves 3 steps:

i) Hepatic uptake: Albumin-bound unconjugated bilirubin upon entry into the hepatocyte, is dissociated into bilirubin and albumin. The bilirubin gets bound to cytoplasmic protein *glutathione-S-transferase (GST)* (earlier called ligandin).

ii) Conjugation: Unconjugated bilirubin is not water-soluble but is alcohol-soluble and is converted into water-soluble compound by conjugation. Conjugation occurs in endoplasmic reticulum and involves conversion to bilirubin mono- and diglucuronide by the action of microsomal enzyme, *bilirubin-UDP-glucuronosyl transferase (Web Image 21.3)*.

Conjugated bilirubin is bound to albumin in two forms: reversible and irreversible. Reversible binding is similar to that of unconjugated bilirubin. However, when present in serum for a long time (e.g. in cholestasis, long-standing biliary obstruction, chronic active hepatitis), conjugated bilirubin is bound to albumin irreversibly and is termed *delta bilirubin* or *biliprotein*.

iii) Secretion into bile: Conjugated (water-soluble) bilirubin is rapidly transported directly into bile canaliculi by energy-dependent process and then excreted into the bile.

4. INTESTINAL PHASE. Appearance of conjugated bilirubin in the intestinal lumen is followed by either direct excretion in the stool as stercobilinogen which imparts the normal yellow colour to stool, or may be metabolised to urobilinogen by the action of intestinal bacteria. Some of the absorbed urobilinogen is resecreted by the liver into the bile while the rest is excreted in the urine as urobilinogen.

The major differences between unconjugated and conjugated bilirubin are summarised in **Web Table 21.2**.

CLASSIFICATION AND FEATURES OF JAUNDICE (p. 597)

Based on pathophysiology, jaundice may result from one or more of the following mechanisms:

1. Increased bilirubin production
2. Decreased hepatic uptake

3. Decreased hepatic conjugation
4. Decreased excretion of bilirubin into bile

Accordingly, a simple age-old classification of jaundice was to divide it into 3 predominant types: *pre-hepatic (haemolytic)*, *hepatic*, and *post-hepatic cholestatic*. However, hyperbilirubinaemia due to first three mechanisms is *mainly unconjugated* while the last variety yields *mainly conjugated* hyperbilirubinaemia. The presence of bilirubin in the urine is evidence of conjugated hyperbilirubinaemia.

Based on these mechanisms, the pathogenesis and main features of the two predominant forms of hyperbilirubinaemia are discussed below (**Web Table 21.3**).

I. Predominantly Unconjugated Hyperbilirubinaemia (p. 598)

1. INCREASED BILIRUBIN PRODUCTION (HAEMOLYTIC, ACHOLURIC OR PREHEPATIC JAUNDICE). This results from excessive red cell destruction as occurs in intra- and extravascular haemolysis or due to ineffective erythropoiesis. There is increased release of haemoglobin from excessive breakdown of red cells that leads to overproduction of bilirubin. Hyperbilirubinaemia develops when the capacity of the liver to conjugate large amount of bilirubin is exceeded.

Laboratory data in haemolytic jaundice, in addition to predominant unconjugated hyperbilirubinaemia, reveal normal serum levels of transaminases, alkaline phosphatase and proteins. Bile pigment being unconjugated type is absent from urine (acholuric jaundice).

2. DECREASED HEPATIC UPTAKE. The uptake of bilirubin by the hepatocyte that involves dissociation of the pigment from albumin and its binding to cytoplasmic protein, GST or ligandin, may be deranged in certain conditions e.g. due to drugs, prolonged starvation and sepsis.

3. DECREASED BILIRUBIN CONJUGATION. This mechanism involves deranged hepatic conjugation due to defect or deficiency of the enzyme, glucuronosyl transferase. This can occur in certain inherited disorders of the enzyme (e.g. Gilbert's syndrome and Crigler-Najjar syndrome), or acquired defects in its activity (e.g. due to drugs, hepatitis, cirrhosis).

II. Predominantly Conjugated Hyperbilirubinaemia (Cholestasis) (p. 599)

This form of hyperbilirubinaemia is defined as failure of normal amounts of bile to reach the duodenum. Morphologically, cholestasis means accumulation of bile in liver cells and biliary passages. The defect in excretion may be within the biliary canaliculi of the hepatocyte and in the microscopic bile ducts (*intrahepatic cholestasis or medical jaundice*), or there may be mechanical obstruction to the extrahepatic biliary excretory apparatus (*extrahepatic cholestasis or obstructive jaundice*).

1. INTRAHEPATIC CHOLESTASIS. Intrahepatic cholestasis is due to impaired hepatic excretion of bile and may occur from hereditary or acquired disorders.

i) **Hereditary disorders** producing intrahepatic obstruction to biliary excretion are characterised by '*pure cholestasis*'.

ii) **Acquired disorders** with intrahepatic excretory defect of bilirubin are largely due to hepatocellular diseases and hence are termed '*hepatocellular cholestasis*'.

◆ **Liver biopsy** in cases with intrahepatic cholestasis reveals milder degree of cholestasis than the extrahepatic disorders (**Web Image 21.4,A**). The biliary canaliculi of the hepatocytes are dilated and contain characteristic elongated green-brown *bile plugs*.

506 2. EXTRAHEPATIC CHOLESTASIS. Extrahepatic cholestasis results from mechanical obstruction to large bile ducts outside the liver or within the porta hepatis. The common causes are gallstones, inflammatory strictures, carcinoma head of pancreas, tumours of bile duct, sclerosing cholangitis and congenital atresia of extrahepatic ducts.

◆ **Liver biopsy** in cases with extrahepatic cholestasis shows more marked changes of cholestasis (**Web Image 21.4,B**). Since the obstruction is in the extrahepatic bile ducts, there is progressive retrograde extension of bile stasis into intrahepatic duct system. This results in dilatation of bile ducts and rupture of canaliculi with extravasation of bile producing *bile lakes*.

□ **NEONATAL JAUNDICE** (p. 600)

Jaundice appears in neonates when the total serum bilirubin is more than 3 mg/dl. It may be the result of unconjugated or conjugated hyperbilirubinaemia; the former being more common. Important causes of neonatal jaundice are listed in **Web Table 21.4**.

HEREDITARY NON-HAEMOLYTIC HYPERBILIRUBINAEMIAS (p. 600)

Hereditary non-haemolytic hyperbilirubinaemias are a small group of uncommon familial disorders of bilirubin metabolism when haemolytic causes have been excluded. The commonest is Gilbert's syndrome; others are Crigler-Najjar syndrome, Dubin-Johnson syndrome, Rotor's syndrome and benign familial recurrent cholestasis. Gilbert's syndrome and Crigler-Najjar syndrome are examples of *hereditary non-haemolytic unconjugated hyperbilirubinaemia*, whereas Dubin-Johnson syndrome, Rotor's syndrome and benign familial recurrent cholestasis are conditions with *hereditary conjugated hyperbilirubinaemia*. Their distinguishing features are summarised in **Web Table 21.5**.

Gilbert's Syndrome (p. 600)

This is the commonest of the familial, genetically-determined diseases of the liver affecting 2-5% of the population. Gilbert's syndrome is characterised by mild, benign, unconjugated hyperbilirubinaemia (serum bilirubin 1-5 mg/dl) which is not due to haemolysis. The condition is inherited as an autosomal dominant character. The defect in bilirubin metabolism is complex and appears to be reduced activity of UDP-glucuronosyl transferase with decreased conjugation, or an impaired hepatic uptake of bilirubin.

There are no morphologic abnormalities in the liver except some increased lipofuscin pigment in centrilobular hepatocytes.

Crigler-Najjar Syndrome (p. 601)

Type I Crigler-Najjar syndrome. This is inherited as an autosomal recessive disorder. There is complete absence of conjugating enzyme UDP-glucuronosyl transferase in the hepatocytes and hence no conjugated bilirubin is formed. There is extreme elevation of unconjugated bilirubin (usually more than 20 mg/dl) with high risk of developing permanent CNS damage from kernicterus.

Type II Crigler-Najjar syndrome. This is inherited as an autosomal dominant disease. There is deficiency of enzyme UDP-glucuronosyl transferase but not complete absence. Thus, unconjugated hyperbilirubinaemia is generally mild to moderate (usually less than 20 mg/dl).

There are no morphologic changes in the liver.

Dubin-Johnson Syndrome (p. 601)

Dubin-Johnson syndrome is autosomal recessive disorder characterised by predominant *conjugated hyperbilirubinaemia* (usually less than 5 mg/dl)

with genetic defect in canalicular excretion of conjugated bilirubin. A prolonged BSP dye excretion test is diagnostic of Dubin-Johnson syndrome.

G/A The condition differs from other forms of hereditary hyperbilirubinaemias in producing greenish-black pigmented liver.

M/E The hepatocytes show dark-brown, melanin-like pigment in the cytoplasm, the exact nature of which is obscure but it is neither iron nor bile.

Rotor's Syndrome (p. 601)

This is another form of familial *conjugated hyperbilirubinaemia* with mild chronic jaundice but differs from Dubin-Johnson syndrome in having no brown pigment in the liver cells. The disease is inherited as an autosomal recessive character. The defect probably lies in intrahepatic storage of bilirubin but the exact protein abnormality is not known.

□ **NEONATAL HEPATITIS** (p. 601)

Neonatal hepatitis, also termed giant cell hepatitis or neonatal hepatocellular cholestasis, is a general term used for the constant morphologic change seen in conjugated hyperbilirubinaemia as a result of known infectious and metabolic causes, or may have an idiopathic etiology. 'Idiopathic' neonatal hepatitis is more common and accounts for 75% of cases. The condition usually presents in the first week of birth with jaundice, bilirubinuria, pale stools and high serum alkaline phosphatase.

Morphologic Features

1. Loss of normal lobular architecture of the liver.
2. Presence of prominent multinucleate giant cells derived from hepatocytes.
3. Mononuclear inflammatory cell infiltrate in the portal tracts with some periportal fibrosis.
4. Haemosiderosis.
5. Cholestasis in small proliferated ductules in the portal tract and between necrotic liver cells.

□ **BILIARY ATRESIAS** (p. 601)

Biliary atresias, also called as *infantile cholangiopathies*, are a group of intrauterine developmental abnormalities of the biliary system. The condition may, therefore, have various grades of destruction ranging from complete absence of bile ducts termed *atresia*, to reduction in their number called *paucity of bile ducts*.

Depending upon the portion of biliary system involved, biliary atresias may be extrahepatic or intrahepatic.

EXTRAHEPATIC BILIARY ATRESIA (p. 601)

The extrahepatic bile ducts fail to develop normally so that in some cases the bile ducts are *absent* at birth, while in others the ducts may have been formed but start undergoing sclerosis in the perinatal period. It is common to have multiple defects and other congenital lesions. Extrahepatic biliary atresia is found in 1 per 10,000 livebirths. Cholestatic jaundice appears by the first week after birth.

G/A The liver is enlarged and dark green. The atretic segments of biliary system are reduced to cord-like structures.

M/E The features are as under:

1. Inflammation and fibrous obliteration of the extrahepatic ducts with absence of bile in them.
2. Ductular proliferation and periductular inflammation.
3. Cholestasis and bile thrombi in the portal area.

- 508 4. Periportal fibrosis and later secondary biliary cirrhosis.
5. Transformation of hepatic parenchyma to neonatal (giant cell) hepatitis in 15% of cases.

INTRAHEPATIC BILIARY ATRESIA (p. 602)

Intrahepatic biliary atresia is characterised by biliary hypoplasia so that there is *paucity of bile ducts* rather than their complete absence. The condition probably has its origin in viral infection acquired during intra-uterine period or in the neonatal period. Cholestatic jaundice usually appears within the first few days of birth and is characterised by high serum bile acids with associated pruritus.

M/E The features are:

1. Paucity of intrahepatic bile ducts.
2. Cholestasis.
3. Increased hepatic copper.
4. Inflammation and fibrosis in the portal area, eventually leading to cirrhosis.

REYE'S SYNDROME (p. 602)

Reye's syndrome is defined as an acute postviral syndrome of encephalopathy and fatty change in the viscera. The syndrome may follow almost any known viral disease but is most common after influenza A or B and varicella. Viral infection may act singly, but more often its effect is modified by certain exogenous factors such as by administration of salicylates, aflatoxins and insecticides.

The patients are generally children between 6 months and 15 years of age. Within a week after a viral illness, the child develops intractable vomiting and progressive neurological deterioration due to encephalopathy, eventually leading to stupor, coma and death.

G/A The liver is enlarged and yellowish-orange.

M/E Hepatocytes show small droplets of neutral fat in their cytoplasm (microvesicular fat). Similar fatty change is seen in the renal tubular epithelium and in the cells of skeletal muscles and heart. The brain shows oedema and sometimes focal necrosis of neurons.

HEPATIC FAILURE (p. 602)

Though the liver has a marked regenerative capacity and a large functional reserve, hepatic failure may develop from severe acute and fulminant liver injury with massive necrosis of liver cells (*acute hepatic failure*), or from advanced chronic liver disease (*chronic hepatic failure*).

ETIOLOGY. It includes following:

◆ **Acute (fulminant) hepatic failure** occurs most frequently in *acute viral hepatitis*. Other causes are hepatotoxic drug reactions (e.g. anaesthetic agents, nonsteroidal anti-inflammatory drugs, anti-depressants), carbon tetrachloride poisoning, acute alcoholic hepatitis, mushroom poisoning and pregnancy complicated with eclampsia.

◆ **Chronic hepatic failure** is most often due to *cirrhosis*. Other causes include chronic active hepatitis, chronic cholestasis (cholestatic jaundice) and Wilson's disease.

MANIFESTATIONS. In view of the diverse functions performed by the liver, the syndrome of acute or chronic hepatic failure produces complex manifestations. The major manifestations are diagrammatically illustrated in **Web Image 21.5** and are as follows:

Jaundice, hepatic encephalopathy (hepatic coma), hyperkinetic circulation, hepatorenal syndrome, hepatopulmonary syndrome, coagulation defects, ascites and oedema, endocrine changes, skin changes and foetor hepaticus.

□ CIRCULATORY DISTURBANCES (p. 603)

I. HEPATIC VENOUS OBSTRUCTION (p. 603)

Two uncommon diseases produced by obstruction of the hepatic veins are Budd-Chiari syndrome (hepatic vein thrombosis) and hepatic veno-occlusive disease.

Budd-Chiari Syndrome (Hepatic Vein Thrombosis) (p. 603)

Budd-Chiari syndrome in its pure form consists of slowly developing thrombosis of the hepatic veins and the adjacent inferior vena cava, while some workers include hepatic veno-occlusive disease (described below) in this syndrome.

ETIOLOGY. The etiology of hepatic venous thrombosis in about a third of cases is unknown (idiopathic), while in the remaining cases various causes associated with increased thrombotic tendencies are attributed to polycythaemia vera, paroxysmal nocturnal haemoglobinuria, oral contraceptives, pregnancy, postpartum state, intra-abdominal cancers (e.g. hepatocellular carcinoma), chemotherapy, radiation and myeloproliferative diseases.

G/A The liver is enlarged, swollen, red-purple and has a tense capsule.

M/E The changes in sudden hepatic vein occlusion are those of centrilobular congestion, necrosis and rupture of sinusoids into the space of Disse.

The acute form of illness leads to acute hepatic failure and death, whereas in chronic form the patient may live for months to a few years.

Hepatic Veno-occlusive Disease (p. 604)

Hepatic veno-occlusive disease consists of intimal thickening, stenosis and obliteration of the terminal central veins and medium-sized hepatic veins. The venous occlusion results in pathologic changes similar to those of Budd-Chiari syndrome and can be distinguished from the latter by demonstration of absence of thrombosis in the major hepatic veins.

The cause and stimulus for hepatic veno-occlusive disease are obscure. The condition is more widespread in countries such as Africa, India and certain other tropical countries where 'bush tea' (medicinal tea) is consumed that contains hepatotoxic alkaloids.

II. PORTAL VENOUS OBSTRUCTION (p. 604)

◆ **Intrahepatic cause** of portal venous occlusion is hepatic cirrhosis as the commonest and most important, followed in decreasing frequency by tumour invasion, congenital hepatic fibrosis and schistosomiasis.

◆ **Extrahepatic causes** of portal vein obstruction are intra-abdominal cancers, intra-abdominal sepsis, direct invasion by tumour, myeloproliferative disorders and upper abdominal surgical procedure followed by thrombosis.

Peliosis Hepatis (p. 604)

Although sinusoidal dilatation can occur secondary to many liver diseases, peliosis hepatis is an uncommon condition of primary sinusoidal dilatation that results in blockage of blood outflow and may result in massive intraperitoneal haemorrhage. Although exact etiology is not known, peliosis hepatis and another related condition, bacillary angiomatosis, have been found to occur in HIV-infected patients whose CD4+ T cell counts fall below 100/ μ l. Opportunistic infection with *Bartonella henselae* in poor hygienic conditions in these cases results in blood-filled cysts in liver partly lined by endothelial cells and having mixed inflammatory cells in a fibromyxoid background.

510 III. HEPATIC ARTERIAL OBSTRUCTION (p. 604)

Diseases from obstruction of the hepatic artery are uncommon.

LIVER CELL NECROSIS (p. 604)

All forms of injury to the liver such as microbiologic, toxic, circulatory or traumatic, result in necrosis of liver cells. The extent of involvement of hepatic lobule in necrosis varies. Accordingly, liver cell necrosis is divided into 3 types:

1. DIFFUSE (SUBMASSIVE TO MASSIVE) NECROSIS. When there is extensive and diffuse necrosis of the liver involving all the cells in groups of lobules, it is termed diffuse, or submassive to massive necrosis. It is most commonly caused by viral hepatitis or drug toxicity.

2. ZONAL NECROSIS. Zonal necrosis is necrosis of hepatocytes in 3 different zones of the hepatic lobule. Accordingly, it is of 3 types:

i) **Centrilobular necrosis** is the commonest type involving hepatocytes in zone 3 (i.e. located around the central vein). Centrilobular necrosis is characteristic feature of ischaemic injury such as in shock and CHF since zone 3 is farthest from the blood supply. Besides, it also occurs in poisoning with chloroform, carbon tetrachloride and certain drugs.

ii) **Midzonal necrosis** is uncommon and involves zone 2 of the hepatic lobule. This pattern of necrosis is seen in yellow fever and viral hepatitis. In viral hepatitis, some of the necrosed hepatocytes of the mid-zone are transformed into acidophilic, rounded Councilman bodies.

iii) **Periportal (peripheral) necrosis** is seen in zone 1 involving the parenchyma closest to the arterial and portal blood supply. Since zone 1 is most well perfused, it is most vulnerable to the effects of circulating hepatotoxins e.g. in phosphorus poisoning and eclampsia.

3. FOCAL NECROSIS. This form of necrosis involves small groups of hepatocytes irregularly distributed in the hepatic lobule. Focal necrosis is most often caused by microbiologic infections. These include viral hepatitis, miliary tuberculosis, typhoid fever and various other forms of bacterial, viral and fungal infections. Focal necrosis may also occur in drug-induced hepatitis.

□ VIRAL HEPATITIS (p. 605)

The term viral hepatitis is used to describe infection of the liver caused by hepatotropic viruses. Currently there are 5 main varieties of these viruses and a sixth poorly-characterised virus, causing distinct types of viral hepatitis:

- ◆ **Hepatitis A virus (HAV)**, causing a faecally-spread self-limiting disease.
- ◆ **Hepatitis B virus (HBV)**, causing a parenterally transmitted disease that may become chronic.
- ◆ **Hepatitis C virus (HCV)**, previously termed non-A, non-B (NANB) hepatitis virus involved chiefly in transfusion-related hepatitis.
- ◆ **Hepatitis delta virus (HDV)** which is sometimes associated as superinfection with hepatitis B infection.
- ◆ **Hepatitis E virus (HEV)**, causing water-borne infection.
- ◆ **Hepatitis G virus (HGV)**, is a recently discovered transfusion-transmitted hepatotropic virus but is not known to cause hepatitis.

All these human hepatitis viruses are RNA viruses except HBV which is a DNA virus.

ETIOLOGIC CLASSIFICATION (p. 605)

Based on the etiologic agent, viral hepatitis is currently classified into 6 etiologic types—hepatitis A, hepatitis B, hepatitis C, hepatitis D, hepatitis E and hepatitis G. The contrasting features of major types are presented in **Web Table 21.6**.

Hepatitis A (p. 606)

Infection with HAV causes hepatitis A (infectious hepatitis). Hepatitis A is responsible for 20-25% of clinical hepatitis in the developing countries of the world but the incidence is much lower in the developed countries. Hepatitis A is usually a benign, self-limiting disease and has an incubation period of 15-45 days. The disease occurs in epidemic form as well as sporadically. It is usually spread by faeco-oral route.

HEPATITIS A VIRUS (HAV). The etiologic agent for hepatitis A, HAV, is a small, 27 nm diameter, icosahedral non-enveloped, single-stranded RNA virus.

PATHOGENESIS. An immunologic basis is suspected but the evidence in support is indirect in the form of immunologic markers but not direct demonstration of the etiologic agent in the affected hepatocytes (**Web Image 21.6**):

1. *IgM anti-HAV antibody* appears in the serum at the onset of symptoms of acute hepatitis A.
2. *IgG anti-HAV antibody* is detected in the serum after acute illness and remains detectable indefinitely. It gives life-long protective immunity against reinfection with HAV.

Hepatitis B (p. 606)

Hepatitis B (serum hepatitis) caused by HBV infection has a longer incubation period (30-180 days) and is transmitted parenterally such as in recipients of blood and blood products, intravenous drug addicts, patients treated by renal dialysis and hospital workers exposed to blood, and by intimate physical contact such as from mother to child and by sexual contact.

HEPATITIS B VIRUS (HBV). The etiologic agent for hepatitis B, HBV, is a DNA virus which has been extensively studied. Electron microscopic studies on serum of patients infected with HBV show 3 forms of viral particles of 2 sizes: small (spheres and tubules/filaments) and large (spheres) as under:

- i) *Small particles* are most numerous and exist in two forms— as 22 nm spheres, and as tubules 22 nm in diameter and 100 nm long. These are antigenically identical to envelope protein of HBV and represent excess of viral envelope protein referred as hepatitis B surface antigen (HBsAg).
- ii) *Large particles*, 42 nm in diameter, are double-shelled spherical particles, also called as *Dane particles*. These are about 100 to 1000 times less in number in serum compared to small 22 nm particles and represent intact virion of HBV.

The genomic structure of HBV is quite compact and complex. The HBV DNA consists of 4 overlapping genes which encode for multiple proteins (**Web Image 21.7**):

1. *S gene* codes for the surface envelope protein, hepatitis B surface antigen (HBsAg); this protein product is termed *major protein*.
2. *P gene* is the largest and codes for DNA polymerase.
3. *C gene* codes for two nucleocapsid proteins, HBeAg and a core protein termed HBcAg.
4. *X gene* codes for HBxAg which is a small non-particulate protein. HbxAg has a role in transactivation the transcription of both viral and cellular genes. Expression of HbxAg and its antibodies associated with enhanced HBV DNA replication has been implicated in hepatocellular carcinoma in patients of chronic hepatitis.

PATHOGENESIS. The evidence linking immuno-pathogenetic mechanism with hepatocellular damage is much stronger in HBV infection than with HAV infection. In support of immune pathogenesis is the demonstration of several immunological markers (serologic as well as viral).

512 **Serologic and viral markers.** These are as under (**Web Image 21.8**):

1. **HBsAg.** In 1965, Blumberg and colleagues in Philadelphia found a lipoprotein complex in the serum of a multiple-transfused haemophiliac of Australian aborigine which was subsequently shown by them to be associated with serum hepatitis. This antigen was termed *Australia antigen* by them. HBsAg appears early in the blood after about 6 weeks of infection and its detection is an indicator of active HBV infection. It usually disappears in 3-6 months. Its persistence for more than 6 months implies a carrier state.
2. **Anti-HBs.** Specific antibody to HBsAg in serum called anti-HBs appears late, about 3 months after the onset. Anti-HBs response may be both IgM and IgG type.
3. **HBeAg.** HBeAg derived from core protein is present transiently (3-6 weeks) during an acute attack.
4. **Anti-HBe.** Antibody to HBeAg called anti-HBe appears after disappearance of HBeAg. Seroconversion from HBeAg to anti-HBe during acute stage of illness is a prognostic sign for resolution of infection.
5. **HBcAg.** HBcAg derived from core protein cannot be detected in the blood. But HBcAg can be demonstrated in the nuclei of hepatocytes in carrier state and in chronic hepatitis patients.
6. **Anti-HBc.** Antibody to HBcAg called anti-HBc can, however, be detected in the serum of acute hepatitis B patients during pre-icteric stage. Anti-HBc may be IgM or IgG class antibody.
7. **HBV-DNA.** Detection of HBV-DNA by molecular hybridisation using the Southern blot technique is the most sensitive index of hepatitis B infection.

Hepatitis D (p. 607)

Infection with delta virus (HDV) in the hepatocyte nuclei of HBsAg-positive patients is termed hepatitis D. HDV is a defective virus for which HBV is the helper. Thus, hepatitis D develops when there is concomitant hepatitis B infection. HDV infection and hepatitis B may be simultaneous (*co-infection*), or HDV may infect a chronic HBsAg carrier (*superinfection*) (**Web Image 21.9**):

- ◆ With **coinfection**, acute hepatitis D may range from mild to fulminant hepatitis but fulminant hepatitis is more likely in such simultaneous delta infection.
- ◆ With **superinfection** (incubation period 30-35 days), chronic HBV infection gets worsened indicated by appearance of severe and fulminant acute attacks, progression of carrier stage to chronic delta hepatitis or acceleration towards cirrhosis.

HEPATITIS DELTA VIRUS (HDV). The etiologic agent, HDV, is a small single-stranded RNA particle with a diameter of 36 nm. It is double-shelled—the outer shell consists of HBsAg and the inner shell consists of delta antigen provided by a circular RNA strand. It is highly infectious and can induce hepatitis in any HBsAg-positive host. HDV replication and proliferation takes place within the nuclei of liver cells. Markers for HDV infection include the following:

1. *HDV identification* in the blood and in the liver cell nuclei.
2. *HDAg* detectable in the blood and on fixed liver tissue specimens.
3. *Anti-HD antibody* in acute hepatitis which is initially IgM type and later replaced by IgG type anti-HD antibody.

PATHOGENESIS. HDV, unlike HBV, is thought to cause direct cytopathic effect on hepatocytes.

Hepatitis C (p. 608)

Hepatitis C infection is acquired by blood transfusions, blood products, haemodialysis, parenteral drug abuse and accidental cuts and needle-pricks in health workers. About 90% of post-transfusion hepatitis is of

hepatitis C type. About 1-2% of volunteer blood donors and up to 5% of professional blood donors are carriers of HCV. Hepatitis C has an incubation period of 20-90 days (mean 50 days). Clinically, acute HCV hepatitis is milder than HBV hepatitis but HCV has a higher rate of progression to chronic hepatitis than HBV. Persistence of infection and chronic hepatitis are the key features of HCV.

HEPATITIS C VIRUS (HCV). HCV is a single-stranded, enveloped RNA virus, having a diameter of 30-60 nm. HCV genome has about 3000 amino acids. The genomic organisation of HCV shows a 5' terminal end, C (capsid) region and the envelope regions E1 and E2 in the exons (**Web Image 21.10**).

The viral proteins result in corresponding serologic and virologic markers for HCV infection as under (**Web Image 21.11**):

1. *Anti-HCV antibodies.* Three generations of anti-HCV IgG assays are available:
 - i) First generation antibodies are against C100-3 region proteins and appear 1 to 3 months after infection.
 - ii) Second generation antibodies are against C200 and C33c proteins and appear about one month earlier than the first generation.
 - iii) Third generation antibodies are against C22-3 and NS-5 region proteins and are detected even earlier.
2. *HCV-RNA.* HCV infection is, however, confirmed by HCV-RNA employing PCR technique which can be detected within a few days after exposure to HCV infection.

PATHOGENESIS. Cell-mediated immune mechanism and production of antiviral cytokines by T-lymphocytes certainly play a role in hepatocytic injury due to HCV. HCV virions have not been identified in hepatocytes. Perhaps, HCV infection of lymphoid cells may induce immunologic injury to hepatocytes.

Hepatitis E (p. 609)

Hepatitis E is an enterically-transmitted virus, previously labelled as epidemic or enterically transmitted variant of non-A non-B hepatitis. The infection occurs in young or middle-aged individuals, primarily seen in India, other Asian countries, Africa and central America.

The infection is generally acquired by contamination of water supplies such as after monsoon flooding.

HEPATITIS E VIRUS (HEV). HEV is a single-stranded 32-34 nm, icosahedral non-enveloped virus. Serologic markers for HEV include the following:

1. Anti-HEV antibodies of both IgM and IgG class.
2. HEV-RNA.

CLINICOPATHOLOGIC SPECTRUM (p. 609)

Among the various etiologic types of hepatitis, evidence linking HBV and HCV infection with the spectrum of clinicopathologic changes is stronger than with other hepatotropic viruses. The various clinical patterns and pathologic consequences of different hepatotropic viruses can be considered under the following headings:

- i) Carrier state
- ii) Asymptomatic infection
- iii) Acute hepatitis
- iv) Chronic hepatitis
- v) Fulminant hepatitis (Submassive to massive necrosis)

I. Carrier State (p. 609)

An asymptomatic individual without manifest disease, harbouring infection with hepatotropic virus and capable of transmitting it is called carrier state. There can be 2 types of carriers:

1. An 'asymptomatic healthy carrier' who does not suffer from ill-effects of the virus infection but is capable of transmitting.
2. An 'asymptomatic carrier with chronic disease' capable of transmitting the organisms.

As stated before, hepatitis A and E do not produce the carrier state. Hepatitis B is responsible for the largest number of carriers in the world, while concomitant infection with HDV more often causes progressive disease rather than an asymptomatic carrier state. Data on HBV carrier state reveal role of 2 important factors rendering the individual more vulnerable to harbour the organisms—*early age at infection* and *impaired immunity*.

MORPHOLOGIC FEATURES. These are as follows:

- ◆ *Healthy HBV carriers* may show no changes or minor hepatic change such as presence of finely granular, ground-glass, eosinophilic cytoplasm as evidence of HBsAg.
- ◆ *Asymptomatic carriers with chronic disease* may show changes of chronic hepatitis and even cirrhosis.

II. Asymptomatic Infection (p. 610)

These are cases who are detected incidentally to have infection with one of the hepatitis viruses as revealed by their raised serum transaminases or by detection of the presence of antibodies but are otherwise asymptomatic.

III. Acute Hepatitis (p. 610)

The most common consequence of all hepatotropic viruses is acute inflammatory involvement of the entire liver. In general, type A, B, C, D and E run similar clinical course and show identical pathologic findings.

Clinically, acute hepatitis is categorised into 4 phases:

1. **Incubation period:** It varies among different hepatotropic viruses: for hepatitis A it is about 4 weeks (15-45 days); for hepatitis B the average is 10 weeks (30-180 days); for hepatitis D about 6 weeks (30-50 days); for hepatitis C the mean incubation period is about 7 weeks (20-90 days), and for hepatitis E it is 2-8 weeks (15-60 days).
2. **Pre-icteric phase:** This phase is marked by prodromal constitutional symptoms that include anorexia, nausea, vomiting, fatigue, malaise, distaste for smoking, arthralgia and headache.
3. **Icteric phase:** The prodromal period is heralded by the onset of clinical jaundice and the constitutional symptoms diminish. Other features include dark-coloured urine due to bilirubinuria, clay-coloured stools due to cholestasis, pruritus as a result of elevated serum bile acids, loss of weight and abdominal discomfort due to enlarged, tender liver.
4. **Post-icteric phase:** The icteric phase lasting for about 1 to 4 weeks is usually followed by clinical and biochemical recovery in 2 to 12 weeks. The recovery phase is more prolonged in hepatitis B and hepatitis C. Up to 1% cases of acute hepatitis may develop severe form of the disease (fulminant hepatitis); and 5-10% of cases progress on to chronic hepatitis.

G/A The liver is slightly enlarged, soft and greenish.

M/E (Web Image 21.12): The features are as under:

1. **Hepatocellular injury:** It is most marked in zone 3 (centrilobular zone):
 - i) Mildly injured hepatocytes appear swollen with granular cytoplasm which tends to condense around the nucleus (*ballooning degeneration*).
 - ii) Others show acidophilic degeneration in which the cytoplasm becomes intensely eosinophilic, the nucleus becomes small and pyknotic leaving behind necrotic, acidophilic mass called *Councilman body* or *acidophil body* by the process known as apoptosis.
 - iii) Another type of hepatocellular necrosis is *dropout necrosis*.
 - iv) *Bridging necrosis* is a more severe form of hepatocellular injury in acute viral hepatitis and may progress to fulminant hepatitis or chronic hepatitis.

2. Inflammatory infiltrate: There is infiltration by mononuclear inflammatory cells, usually in the portal tracts, but may permeate into the lobules.

3. Kupffer cell hyperplasia: There is reactive hyperplasia of Kupffer cells many of which contain phagocytosed cellular debris, bile pigment and lipofuscin granules.

4. Cholestasis: Biliary stasis is usually not severe in viral hepatitis and may be present as intracytoplasmic bile pigment granules.

5. Regeneration: As a result of necrosis of hepatocytes, there is lobular disarray. Surviving adjacent hepatocytes undergo regeneration and hyperplasia.

The following morphologic features may help in giving an etiologic clue:

◆ **HAV hepatitis** is a panlobular involvement by heavy inflammatory infiltrate compared to other types.

◆ **HCV hepatitis** causes milder necrosis, with fatty change in hepatocytes, presence of lymphoid aggregates in the portal triads and degeneration of bile duct epithelium.

IV. Chronic Hepatitis (p. 611)

Chronic hepatitis is defined as continuing or relapsing hepatic disease for more than 6 months with symptoms along with biochemical, serologic and histopathologic evidence of inflammation and necrosis. Majority of cases of chronic hepatitis are the result of infection with hepatotropic viruses— hepatitis B, hepatitis C and combined hepatitis B and hepatitis D infection. However, some non-viral causes of chronic hepatitis include: Wilson's disease, α -1-antitrypsin deficiency, chronic alcoholism, drug-induced injury and autoimmune diseases. The last named gives rise to *autoimmune or lupoid hepatitis* which is characterised by positive serum autoantibodies (e.g. antinuclear, anti-smooth muscle and anti-mitochondrial) and a positive LE cell test but negative for serologic markers of viral hepatitis.

Besides, two other factors which determine the vulnerability of a patient of viral hepatitis to develop chronic hepatitis are: *impaired immunity* and *extremes of age* at which the infection is first contracted. Currently, therefore, chronic hepatitis is classified on the basis of etiology and hepatitis activity score. The frequency and severity with which hepatotropic viruses cause chronic hepatitis varies with the organisms as under:

◆ **HCV** infection accounts for 40-60% cases of chronicity in adults. HCV infection is particularly associated with progressive form of chronic hepatitis that may evolve into cirrhosis.

◆ **HBV** causes chronic hepatitis in 90% of infected infants and in about 5% adult cases of hepatitis B.

◆ **HDV** superinfection on HBV carrier state may be responsible for chronic hepatitis in 10-40% cases.

◆ **HAV and HEV** do not produce chronic hepatitis.

MORPHOLOGIC FEATURES. The pathologic features are common to both HBV and HCV infection and include the following lesions (**Web Image 21.13**).

1. Piecemeal necrosis. Piecemeal necrosis is defined as periportal destruction of hepatocytes at the limiting plate (*piecemeal*= piece by piece). Its features in chronic hepatitis are:

- i) Necrosed hepatocytes at the limiting plate in periportal zone.
- ii) Interface hepatitis due to expanded portal tract by infiltration of lymphocytes, plasma cells and macrophages.
- iii) Expanded portal tracts are often associated with proliferating bile ductules as a response to liver cell injury.

2. Portal tract lesions. All forms of chronic hepatitis are characterised by variable degree of changes in the portal tract.

- i) Inflammatory cell infiltration by lymphocytes, plasma cells and macrophages (triaditis).
- ii) Proliferated bile ductules in the expanded portal tracts.
- iii) Additionally, chronic hepatitis C may show lymphoid aggregates or follicles with reactive germinal centre and infiltration of inflammatory cells in the damaged bile duct epithelial cells.

3. Intralobular lesions. Generally, the architecture of lobule is retained in mild to moderate chronic hepatitis.

- i) There are focal areas of necrosis and inflammation within the hepatic parenchyma.
- ii) Scattered acidophilic bodies in the lobule.
- iii) Kupffer cell hyperplasia.
- iv) More severe form of injury shows bridging necrosis.
- v) Regenerative changes in hepatocytes in cases of persistent hepatocellular necrosis.
- vi) Cases of chronic hepatitis C show moderate fatty change.
- vii) Cases of chronic hepatitis B show scattered ground-glass hepatocytes indicative of abundance of HBsAg in the cytoplasm.

4. Bridging fibrosis. The onset of fibrosis in chronic hepatitis from the area of interface hepatitis and bridging necrosis is a feature of irreversible damage.

As prognostic indicator of chronic hepatitis, criteria have been evolved to classify chronic hepatitis by giving **hepatitis activity score** (ranging from none to minimal/mild to moderate and severe) described by Knodell and Ishak based on the following features:

A. Necroinflammatory activity:

- ◆ *Periportal necrosis i.e. piecemeal necrosis and/ or bridging necrosis* (ranging from score 0 as 'no necrosis' to score 4 as 'multilobular necrosis').
- ◆ *Intralobular necrosis, focal or confluent* (ranging from score 0 as 'none' to score 4 for '>10 foci' for focal necrosis, and score 6 as 'panacinar/multiacinar' for confluent necrosis).
- ◆ *Extent and depth of portal inflammation* (ranging from grade 0 as 'no inflammation' to grade 4 having 'marked portal inflammation').

B. Stage of fibrosis:

- ◆ *Extent and density of fibrosis* (ranging from score 0 as 'no fibrosis' to score 6 as 'cirrhosis').

CLINICAL FEATURES. The clinical features of chronic hepatitis are quite variable ranging from mild disease to full-blown picture of cirrhosis.

- i) Mild chronic hepatitis shows only slight but persistent elevation of transaminases ('transaminitis') with fatigue, malaise and loss of appetite.
- ii) Other cases may show mild hepatomegaly, hepatic tenderness and mild splenomegaly.
- iii) Laboratory findings may reveal prolonged prothrombin time, hyperbilirubinaemia, hyperglobulinaemia and markedly elevated alkaline phosphatase.
- iv) Systemic features of circulating immune complexes due to HBV and HCV infection may produce features of immune complex vasculitis, glomerulonephritis and cryoglobulinaemia in a proportion of cases.

V. Fulminant Hepatitis (Submassive to Massive Necrosis) (p. 613)

Fulminant hepatitis is the most severe form of acute hepatitis in which there is rapidly progressive hepatocellular failure. Two patterns are recognised—*submassive necrosis* having a less rapid course extending up to 3 months; and *massive necrosis* in which the liver failure is rapid and fulminant occurring in 2-3 weeks.

Fulminant hepatitis of either of the two varieties can occur from viral and non-viral etiologies:

G/A The liver is small and shrunken, often weighing 500-700 gm. The capsule is loose and wrinkled. The sectioned surface shows diffuse or random involvement of hepatic lobes. There are extensive areas of muddy-red and yellow necrosis (previously called *acute yellow atrophy*) and patches of green bile staining.

M/E Two forms of fulminant necrosis are distinguished—submassive and massive necrosis (**Web Image 21.14**).

- i) In **submassive necrosis**, large groups of hepatocytes in zone 3 (centrilobular area) and zone 2 (mid zone) are wiped out leading to a collapsed reticulin framework. Regeneration in submassive necrosis is more orderly and may result in restoration of normal architecture.
- ii) In **massive necrosis**, the entire liver lobules are necrotic. As a result of loss of hepatic parenchyma, all that is left is the collapsed and condensed reticulin framework and portal tracts with proliferated bile ductules plugged with bile. Inflammatory infiltrate is scanty.

The clinicopathologic course in two major forms of hepatitis, HBV and HCV, is summarised in **Web Image 21.15**.

IMMUNOPROPHYLAXIS AND HEPATITIS VACCINES (p. 614)

Best prophylaxis against the viral hepatitis remains prevention of its spread to the contacts after detection and identification of route by which infection is acquired such as from food or water contamination, sexual spread or parenteral spread. Of late, however, immunoprophylaxis and a few hepatitis vaccines have been developed and some more are under development. The principle underlying either of these two forms of prophylaxis is that the persons who develop good antibody response to the antigen of the hepatotropic virus following active infection are protected against the disease on reinfection.

OTHER INFECTIONS AND INFESTATIONS (p. 614)

CHOLANGITIS (p. 614)

Cholangitis is the term used to describe inflammation of the extrahepatic or intrahepatic bile ducts, or both. There are two main types of cholangitis—pyogenic and primary sclerosing.

Pyogenic Cholangitis (p. 614)

Cholangitis occurring secondary to obstruction of a major extrahepatic duct causes pyogenic cholangitis. Most commonly, the obstruction is from impacted gallstone; other causes are carcinoma arising in the extrahepatic ducts, carcinoma head of pancreas, acute pancreatitis and inflammatory strictures in the bile duct. Bacteria gain entry to the obstructed duct and proliferate in the bile.

MORPHOLOGIC FEATURES. The affected ducts show small beaded abscesses accompanied by bile stasis along their course and larger abscesses within the liver. The abscesses are composed of acute inflammatory cells which in time are replaced by chronic inflammatory cells and enclosed by fibrous capsule.

PYOGENIC LIVER ABSCESS (p. 614)

Most liver abscesses are of bacterial (pyogenic) origin; less often they are amoebic, hydatid and rarely actinomycotic. Pyogenic liver abscesses have become uncommon due to improved diagnostic facilities and the early use of antibiotics. However, their incidence is higher in old age and in immunosuppressed patients such as in AIDS, transplant recipients and those on intensive chemotherapy.

Pyogenic liver abscesses are classified on the basis of the mode of entry as under:

1. *Ascending cholangitis*
2. *Portal pyaemia* by means of spread of pelvic or gastrointestinal infection
3. *Septicaemia* through spread by hepatic artery.
4. *Direct infection* resulting in solitary liver abscess
5. *Iatrogenic causes* include liver biopsy, percutaneous biliary drainage and accidental surgical trauma.
6. *Cryptogenic* from unknown causes, especially in the elderly.

G/A Depending upon the cause for pyogenic liver abscess, they occur as single or multiple yellow abscesses, 1 cm or more in diameter, in an enlarged liver. A single abscess generally has a thick fibrous capsule. The abscesses are particularly common in right lobe of the liver (**Web Image 21.16**).

M/E Typical features of abscess are seen. There are multiple small neutrophilic abscesses with areas of extensive necrosis of the affected liver parenchyma. The adjacent viable area shows pus and blood clots in the portal vein, inflammation, congestion and proliferating fibroblasts.

AMOEBIC LIVER ABSCESS (p. 615)

Amoebic liver abscesses are less common than pyogenic liver abscesses and have many similar features. They are caused by the spread of *Entamoeba histolytica* from intestinal lesions. The trophozoite form of amoebae in the colon invade the colonic mucosa forming flask-shaped ulcers from where they are carried to the liver in the portal venous system.

The patients, generally from tropical and subtropical countries, may give history of amoebic dysentery in the past. Cysts of *E. histolytica* in stools are present in only 15% of patients of hepatic amoebiasis.

G/A Amoebic liver abscesses are usually solitary and more often located in the right lobe in the posterosuperior portion. Amoebic liver abscess may vary greatly in size but is generally of the size of an orange. The centre of the abscess contains large necrotic area having reddish-brown, thick pus resembling anchovy or chocolate sauce. (**Web Image 21.17**).

M/E The necrotic area consists of degenerated liver cells, leucocytes, red blood cells, strands of connective tissue and debris. Amoebae are most easily found in the liver tissue at the margin of abscess. PAS-staining is employed to confirm the trophozoites of *E. histolytica*.

HEPATIC TUBERCULOSIS (p. 615)

Tuberculosis of the liver occurs as a result of miliary dissemination from primary complex or from chronic adult pulmonary tuberculosis. The diagnosis is possible by liver biopsy. The patients may have unexplained fever, jaundice, hepatomegaly or hepatosplenomegaly. There may be elevated serum alkaline phosphatase levels and hyperglobulinaemia.

MORPHOLOGIC FEATURES. The basic lesion is the epithelioid cell granuloma characterised by central caseation necrosis with destruction of the reticulin framework and peripheral cuff of lymphocytes (**Web Image 21.18**).

HYDATID DISEASE (ECHINOCOCCOSIS) (p. 616)

Hydatid disease occurs as a result of infection by the larval cyst stage of the tapeworm, *Echinococcus granulosus*. The dog is the common definite host, while man, sheep and cattle are the intermediate hosts. The dog is infected by eating the viscera of sheep containing hydatid cysts. About 70% of hydatid cysts develop in the liver which acts as the first filter for ova. However, ova which pass through the liver enter the right side of the heart

and are caught in the pulmonary capillary bed and form pulmonary hydatid cysts. Some ova which enter the systemic circulation give rise to hydatid cysts in the brain, spleen, bone and muscles.

Complications of hydatid cyst include its rupture (e.g. into the peritoneal cavity, bile ducts and lungs), secondary infection and hydatid allergy due to sensitisation of the host with cyst fluid. The diagnosis is made by peripheral blood eosinophilia, radiologic examination and serologic tests such as indirect haemagglutination test and Casoni skin test.

MORPHOLOGIC FEATURES. The cyst wall is composed of 3 distinguishable zones—outer *pericyst*, intermediate characteristic *ectocyst* and inner *endocyst* (**Web Image 21.19**):

1. **Pericyst** is the outer host inflammatory reaction consisting of fibroblastic proliferation, mononuclear cells, eosinophils and giant cells, eventually developing into dense fibrous capsule which may even calcify.
2. **Ectocyst** is the intermediate layer composed of characteristic acellular, chitinous, laminated hyaline material (**Web Image 21.20**).
3. **Endocyst** is the inner germinal layer bearing daughter cysts (brood-capsules) and scolices projecting into the lumen.

Hydatid sand is the grain-like material composed of numerous scolices present in the hydatid fluid. Hydatid fluid, in addition, contains antigenic proteins so that its liberation into circulation gives rise to pronounced eosinophilia or may cause anaphylaxis.

□ CHEMICAL AND DRUG INJURY (p. 617)

HEPATIC DRUG METABOLISM. The liver plays a central role in the metabolism of a large number of organic and inorganic chemicals and drugs which gain access to the body by inhalation, injection, or most commonly, via the intestinal tract. The main drug metabolising system resides in the microsomal fraction of the smooth endoplasmic reticulum of the liver cells via P-450 cytochrome and cytochrome reductase enzyme systems.

HEPATOTOXICITY. Toxic liver injury produced by drugs and chemicals may virtually mimic any form of naturally-occurring liver disease. In fact, any patient presenting with liver disease or unexplained jaundice is thoroughly questioned about history of drug intake or exposure to chemicals. Hepatotoxicity from drugs and chemicals is the commonest form of iatrogenic disease.

Among the various *inorganic compounds* producing hepatotoxicity are arsenic, phosphorus, copper and iron. *Organic agents* include certain naturally-occurring plant toxins such as pyrrolizidine alkaloids, mycotoxins and bacterial toxins. The synthetic group of organic compounds are a large number of medicinal agents. In addition, exposure to hepatotoxic compounds may be occupational, environmental or domestic that could be accidental, homicidal or suicidal ingestion.

In general, drug reactions affecting the liver are divided into two main classes:

1. **Direct or predictable**, when the drug or one of its metabolites is either directly toxic to the liver or it lowers the host immune defense mechanism. The adverse effects occur in most individuals who consume them and their hepatotoxicity is dose-dependent e.g. carbon tetrachloride.
2. **Indirect or unpredictable or idiosyncratic**, when the drug or one of its metabolites acts as a hapten and induces hypersensitivity in the host. In many instances, drug hepatotoxicity is associated with appearance of autoantibodies to liver-kidney microsomes (i.e. anti-LKM2) directed against cytochrome P450 enzyme.

A simplified clinicopathologic classification of important hepatic drug reactions and the agents causing them is presented in **Web Table 21.7**.

520 The changes produced by hepatotoxic agents may vary from mild, which are diagnosed only by elevated serum transaminases, to instances of massive necrosis and death. The pathologic changes by hepatotoxins include 2 large categories:

1. *Acute liver disease* characterised by cholestasis, hepatocellular necrosis, fatty change, granulomatous reaction or vascular disease.
2. *Chronic liver disease* characterised by variable degree of fibrosis, cirrhosis or neoplasia.

□ **CIRRHOSIS** (p. 618)

It represents the irreversible end-stage of several diffuse diseases causing hepatocellular injury and is characterised by the following 4 features:

1. It involves the entire liver.
2. The normal lobular architecture of hepatic parenchyma is disorganised.
3. There is formation of nodules separated from one another by irregular bands of fibrosis.
4. It occurs following hepatocellular necrosis of varying etiology so that there are alternate areas of necrosis and regenerative nodules.

PATHOGENESIS (p. 618)

Irrespective of the etiology, cirrhosis in general is initiated by hepatocellular necrosis. Continued destruction of hepatocytes causes collapse of normal lobular hepatic parenchyma followed by *fibrosis* around necrotic liver cells and proliferated ductules and there is formation of compensatory *regenerative nodules*.

FIBROGENESIS. Fibrosis in the liver lobules may be portal-central, portal-portal, or both. The mechanism of fibrosis is by increased synthesis of all types of collagen and increase in the number of collagen-producing cells. In cirrhosis, there is proliferation of fat-storing Ito cells underlying the sinusoidal epithelium which become transformed into myofibroblasts and fibrocytes.

REGENERATIVE NODULE. The cause of compensatory proliferation of hepatocytes to form regenerative nodules is obscure. Possibly, growth factors, chaperones and hormonal imbalance, play a role in regeneration.

CLASSIFICATION (p. 618)

Cirrhosis can be classified on the basis of morphology and etiology (**Web Table 21.8**).

A. MORPHOLOGIC CLASSIFICATION. There are 3 morphologic types of cirrhosis—micronodular, macronodular and mixed. Each of these forms may have an active and inactive form.

1. Micronodular cirrhosis. In micronodular cirrhosis, the nodules are usually regular and small, *less than 3 mm* in diameter.

2. Macronodular cirrhosis. In this type, the nodules are of variable size and are generally *larger than 3 mm* in diameter. The pattern of involvement is more irregular than in micronodular cirrhosis.

3. Mixed cirrhosis. In mixed type, some parts of the liver show micronodular appearance while other parts show macronodular pattern.

B. ETIOLOGIC CLASSIFICATION. Based on the etiologic agent for cirrhosis, various categories of cirrhosis are described as given in **Web Table 21.8**.

SPECIFIC TYPES OF CIRRHOSIS (p. 619)

Alcoholic Liver Disease and Cirrhosis (p. 619)

Alcoholic liver disease is the term used to describe the spectrum of liver injury associated with acute and chronic alcoholism. There are three

sequential stages in alcoholic liver disease: *alcoholic steatosis (fatty liver)*, *alcoholic hepatitis* and *alcoholic cirrhosis*.

ETHANOL METABOLISM. Ethanol after ingestion and absorption from the small bowel circulates through the liver where about 90% of it is oxidised to acetate by a *two-step enzymatic process* involving two enzymes: *alcohol dehydrogenase (ADH)* present in the cytosol, and *acetaldehyde dehydrogenase (ALDH)* in the mitochondria of hepatocytes (**Web Image 21.21**). The remaining 10% of ethanol is oxidised elsewhere in the body.

First step: Ethanol is catabolised to acetaldehyde in the liver by the following three pathways, one major and two minor:

- i) *In the cytosol*, by the major rate-limiting pathway of alcohol dehydrogenase (ADH).
- ii) *In the smooth endoplasmic reticulum*, via microsomal P-450 oxidases (also called microsomal ethanol oxidising system, MEOS), where only part of ethanol is metabolised.
- iii) *In the peroxisomes*, minor pathway via catalase such as H_2O_2 .

Acetaldehyde is toxic and may cause membrane damage and cell necrosis. Simultaneously, the cofactor nicotinamide-adenine dinucleotide (NAD) which is a hydrogen acceptor, is reduced to NADH.

Second step: The second step occurs in the mitochondria where acetaldehyde is converted to acetate with ALDH acting as a co-enzyme. Simultaneously, the same cofactor, NAD, is reduced to NADH resulting in *increased NADH: NAD redox ratio* which is the basic biochemical alteration occurring during ethanol metabolism.

RISK FACTORS FOR ALCOHOLIC LIVER DISEASE. The incidence of cirrhosis among alcoholics at autopsy is about 10-15%. Why some individuals are predisposed to alcoholic cirrhosis is not clearly known, but a few risk factors have been implicated.

1. Drinking patterns. Most epidemiologic studies have attributed alcoholic cirrhosis to chronic alcoholism. Available evidence suggests that chronic and excessive consumption of alcohol invariably leads to fatty liver in >90% of chronic alcoholics, progression to alcoholic hepatitis in 10-20% cases, and eventually to alcoholic cirrhosis in more than 10 years.

2. Gender. Women have increased susceptibility to develop advanced alcoholic liver disease with much lesser alcohol intake (20-40 g/day).

3. Malnutrition. Absolute or relative malnutrition of proteins and vitamins is regarded as a contributory factor in the evolution of cirrhosis. The combination of chronic alcohol ingestion and impaired nutrition leads to alcoholic liver disease and not malnutrition *per se*.

4. Infections. Intercurrent bacterial infections are common in cirrhotic patients and may accelerate the course of the disease.

5. Genetic factors. The rate of ethanol metabolism is under genetic control. It is chiefly related to altered rates of elimination of ethanol due to genetic polymorphism for the two main enzyme systems, MEOS (microsomal P-450 oxidases) and alcohol dehydrogenase (ADH).

6. Hepatitis C infection. Concurrent infection with HCV is an important risk factor for progression of alcoholic liver disease. HCV infection in chronic alcoholic leads to development of alcoholic liver disease with much less alcohol consumption, disease progression at a younger age, having greater severity, and increased risk to develop cirrhosis and hepatocellular carcinoma, and overall poorer survival.

PATHOGENESIS. Exact pathogenesis of alcoholic liver injury is yet unclear. The biomedical and cellular pathogenesis due to chronic alcohol consumption culminating in morphologic lesions of alcoholic steatosis (fatty liver), alcoholic hepatitis and alcoholic cirrhosis can be explained as under and is schematically illustrated in **Web Image 21.22**:

1. Direct hepatotoxicity by ethanol.
2. Hepatotoxicity by ethanol metabolites.
 - i) *Production of protein-aldehyde adducts*
 - ii) *Formation of malon-di-aldehyde-acetaldehyde (MAA) adducts*
3. Oxidative stress.
4. Immunological mechanism.
5. Inflammation.
6. Fibrogenesis.
7. Increased redox ratio.
8. Retention of liver cell water and proteins.
9. Hypoxia.
10. Increased liver fat.

MORPHOLOGIC FEATURES. Three types of morphologic lesions are described in alcoholic liver disease as under:

1. ALCOHOLIC STEATOSIS (FATTY LIVER). **G/A** The liver is enlarged, yellow, greasy and firm with a smooth and glistening capsule.

M/E The features consist of initial *microvesicular* droplets of fat in the hepatocyte cytoplasm followed by more common and pronounced feature of *macrovesicular* large droplets of fat displacing the nucleus to the periphery (**Web Image 21.23**). *Fat cysts* may develop due to coalescence and rupture of fat-containing hepatocytes. Less often, *lipogranulomas* consisting of collection of lymphocytes, macrophages and some multinucleate giant cells may be found.

2. ALCOHOLIC HEPATITIS. Alcoholic hepatitis develops acutely, usually following a bout of heavy drinking.

M/E (Web Image 21.24):

- i) Hepatocellular necrosis
- ii) Mallory bodies or alcoholic hyalin
- iii) Inflammatory response
- iv) Fibrosis

3. ALCOHOLIC CIRRHOSIS. Alcoholic cirrhosis is the most common form of lesion, constituting 60-70% of all cases of cirrhosis.

G/A Alcoholic cirrhosis classically begins as micronodular cirrhosis (nodules less than 3 mm diameter), the liver being large, fatty and weighing usually above 2 kg (**Web Image 21.25**). Eventually over a span of years, the liver shrinks to less than 1 kg in weight, becomes non-fatty, having macronodular cirrhosis (nodules larger than 3 mm in diameter), resembling post-necrotic cirrhosis. On cut section, spheroidal or angular nodules of fibrous septa are seen.

M/E Alcoholic cirrhosis is a progressive alcoholic liver disease. Its features include the following (**Web Image 21.26**):

- i) Nodular pattern
- ii) Fibrous septa
- iii) Hepatic parenchyma
- iv) Necrosis, inflammation and bile duct proliferation

LABORATORY DIAGNOSIS. Progressive form of the disease, however, generally presents the following biochemical and haematological alterations:

1. Elevated transaminases: increase in SGOT (AST) is more than that of SGPT (ALT).
2. Rise in serum γ -glutamyl transpeptidase (γ -GT).
3. Elevation in serum alkaline phosphatase.
4. Hyperbilirubinaemia.
5. Hypoproteinaemia with reversal of albumin-globulin ratio.
6. Prolonged prothrombin time and partial thromboplastin time.

- Anaemia.
- Neutrophilic leucocytosis in alcoholic hepatitis and in secondary infections.

Post-necrotic Cirrhosis (p. 624)

Post-necrotic cirrhosis, also termed *post-hepatic cirrhosis*, *macronodular cirrhosis* and *coarsely nodular cirrhosis*, is characterised by large and irregular nodules with broad bands of connective tissue and occurring most commonly after previous viral hepatitis.

ETIOLOGY. Based on epidemiologic and serologic studies, the following factors have been implicated in the etiology of post-necrotic cirrhosis.

- Viral hepatitis.
- Drugs and chemical hepatotoxins.
- Others.
- Idiopathic.

G/A The liver is usually small, weighing less than 1 kg, having distorted shape with irregular and coarse scars and nodules of varying size (**Web Image 21.27**). Sectioned surface shows scars and nodules varying in diameter from 3 mm to a few centimeters.

M/E (Web Image 21.28): The features are:

- Nodular pattern
- Fibrous septa
- Necrosis, inflammation and bile duct proliferation: Often there is extensive proliferation of bile ductules derived from collapsed liver lobules.
- Hepatic parenchyma: Liver cells vary considerably in size and multiple large nuclei are common in regenerative nodules.

CLINICAL FEATURES. Splenomegaly and hypersplenism are other prominent features. The results of haematologic and liver function test are similar to those of alcoholic cirrhosis. Out of the various types of cirrhosis, post-necrotic cirrhosis, especially when related to hepatitis B and C virus infection in early life, is more frequently associated with hepatocellular carcinoma.

Biliary Cirrhosis (p. 625)

Biliary cirrhosis is defined as a chronic disorder characterised by clinical, biochemical and morphological features of long-continued cholestasis of intrahepatic or extrahepatic origin. Biliary cirrhosis is of following types:

- ◆ *Primary biliary cirrhosis* in which the destructive process of unknown etiology affects intrahepatic bile ducts.
- ◆ *Secondary biliary cirrhosis* resulting from prolonged mechanical obstruction of the extrahepatic biliary passages.
- ◆ *Primary sclerosing cholangitis and autoimmune cholangiopathy* causing biliary cirrhosis.

ETIOLOGY. The etiology of these forms of biliary cirrhosis is distinctive:

A. Primary biliary cirrhosis. The etiology of this type remains unknown. However, a few factors have been implicated:

- Endocrine origin.*
- Familial incidence*
- Elevated cholesterol*
- Autoimmune origin.*

B. Secondary biliary cirrhosis. Most cases of secondary biliary cirrhosis result from prolonged obstruction of extrahepatic biliary passages e.g.:

- Extrahepatic cholelithiasis, most common
- Biliary atresia
- Cancer of biliary tree and of head of pancreas
- Postoperative strictures with superimposed ascending cholangitis.

C. Cirrhosis due to primary sclerosing cholangitis. Primary or idiopathic sclerosing cholangitis is a chronic cholestatic syndrome of unknown etiology. It is characterised by progressive, inflammatory, sclerosing and obliterative process affecting the entire biliary passages, both extra-hepatic and intrahepatic ducts.

G/A In biliary cirrhosis of all types, the liver is initially enlarged and characteristically *greenish* in appearance, but later becomes smaller, firmer and coarsely micronodular.

M/E The salient features of various forms of biliary cirrhosis are as under:

A. Primary biliary cirrhosis: The diagnostic histologic feature is a chronic, non-suppurative, destructive cholangitis involving intrahepatic bile ducts. The disease evolves through the following 4 histologic states:

Stage I: There are *florid bile duct lesions*

Stage II: There is *ductular proliferation*

Stage III: This stage is characterised by *fibrous scarring*

Stage IV: Well-formed *micronodular pattern* (**Web Image 21.29**).

B. Secondary biliary cirrhosis: Prolonged obstruction of extrahepatic bile ducts may produce the following histologic changes:

1) Bile stasis, 2) Formation of bile lakes, 3) Cholangitis, and 4) Progressive expansion of the portal tract.

C. Cirrhosis due to primary sclerosing cholangitis:

1) Fibrosing cholangitis, 2) Periductal fibrosis, 3) Intervening bile ducts are dilated, and 4) Late cases show cholestasis.

CLINICAL FEATURES. Clinical features of the three types of biliary cirrhosis are variable:

◆ **Primary biliary cirrhosis** may remain asymptomatic for months to years. Symptoms develop insidiously. Basically, it is a cholestatic disorder.

◆ The diagnosis of **secondary biliary cirrhosis** is considered in patients with previous history of gallstones, biliary tract surgery or clinical features of ascending cholangitis.

◆ The patients of **primary sclerosing cholangitis** may remain asymptomatic or may show features of cholestatic jaundice (raised alkaline phosphatase, pruritus, fatigue).

The contrasting features of three main types of intrahepatic disorders leading to biliary cirrhosis are summarised in **Web Table 21.9**.

Pigment Cirrhosis in Haemochromatosis (p. 627)

Haemochromatosis is an iron-storage disorder in which there is excessive accumulation of iron in parenchymal cells with eventual tissue damage and functional insufficiency of organs such as the liver, pancreas, heart and pituitary gland. The condition is characterised by a triad of features—*micronodular pigment cirrhosis, diabetes mellitus and skin pigmentation*. On the basis of the last two features, the disease has also come to be termed as '*bronze diabetes*'. Haemochromatosis exists in 2 main forms:

1. *Idiopathic (primary, genetic) haemochromatosis* is an autosomal recessive disorder of excessive accumulation of iron. It is associated with overexpression of HFE gene located on chromosome 6 close to the HLA gene locus, and normally regulates intestinal absorption of iron.
2. *Secondary (acquired) haemochromatosis* is gross iron overload with tissue injury arising secondary to other diseases such as thalassaemia, sideroblastic anaemias, alcoholic cirrhosis or multiple transfusions.

ETIOPATHOGENESIS. It includes following:

◆ In **idiopathic or hereditary haemochromatosis**, the primary mechanism of disease appears to be the genetic basis in which the defect may either lie at the intestinal mucosal level causing excessive iron

absorption, or at the post-absorption excretion level leading to excessive accumulation of iron. The excess iron in primary haemochromatosis is deposited mainly in the cytoplasm of parenchymal cells of organs such as the liver, pancreas, spleen, heart and endocrine glands.

◆ In **secondary or acquired haemochromatosis**, there is excessive accumulation of iron due to acquired causes like ineffective erythropoiesis, defective haemoglobin synthesis, multiple blood transfusions and enhanced absorption of iron due to alcohol consumption.

MORPHOLOGIC FEATURES. Excessive deposition of iron in organs and tissues is ferritin and haemosiderin, both of which appear as golden-yellow pigment granules in the cytoplasm of affected parenchymal cells and haemosiderin stains positively with Prussian blue reaction. The organs most frequently affected are the liver and pancreas, and to a lesser extent, the heart, endocrine glands, skin, synovium and testis.

◆ In the **liver**, excess of pigment accumulates in the hepatocytes, and less often Kupffer cells and in bile duct epithelium.

◆ In the **pancreas**, pigmentation is less intense and is found in the acinar and islet cells. The deposits in pancreas produce diffuse interstitial fibrosis and atrophy of parenchymal cells leading to occurrence of diabetes mellitus.

CLINICAL FEATURES. The major clinical manifestations of haemochromatosis include skin pigmentation, diabetes mellitus, hepatic and cardiac dysfunction, arthropathy and hypogonadism.

Cirrhosis in Wilson's Disease (p. 628)

Wilson's disease, also termed by a more descriptive designation of *hepatolenticular degeneration*, is an autosomal recessive inherited disease of copper metabolism, characterised by toxic accumulation of copper in many tissues, chiefly the liver, brain and eye. These accumulations lead to the *triad* of features:

1. Cirrhosis of the liver.
2. Bilateral degeneration of the basal ganglia of the brain.
3. Greenish-brown pigmented rings in the periphery of the cornea (Kayser-Fleischer rings).

PATHOGENESIS. The pathogenesis of Wilson's disease is best understood when compared with normal copper metabolism.

◆ **Normally**, dietary copper is more than body's requirement. Excess copper so absorbed through the stomach and duodenum is transported to the liver where it is incorporated into α_2 -globulin to form ceruloplasmin, which is excreted by the liver via bile normally.

◆ In **Wilson's disease**, the initial steps of dietary absorption and transport of copper to the liver are normal but copper accumulates in the liver rather than being excreted by the liver. The underlying defect in chromosome 13 is a mutation in ATP7B gene, the normal hepatic copper-excreting gene.

Biochemical abnormalities in Wilson's disease include the following:

1. *Decreased serum ceruloplasmin*
2. *Increased hepatic copper*
3. *Increased urinary excretion of copper.*
4. However, *serum copper levels* are of no diagnostic help and may vary from low-to-normal-to-high depending upon the stage of disease.

MORPHOLOGIC FEATURES. The **liver** shows varying grades of changes that include fatty change, acute and chronic active hepatitis, submassive liver necrosis and macronodular cirrhosis. Mallory bodies are present in some cases. Copper is usually deposited in the periportal hepatocytes in the form of reddish granules in the cytoplasm or as reddish cytoplasmic coloration, stainable by rubeanic acid or rhodamine stains for copper.

Involvement of basal ganglia in the **brain** is seen in the form of toxic injury to neurons, in the **cornea** as greenish-brown deposits of copper in Descemet's membrane, and in the **kidney** as fatty and hydropic change.

Cirrhosis in α -1-Antitrypsin Deficiency (p. 628)

Alpha-1-antitrypsin deficiency is an autosomal codominant condition in which the homozygous state produces liver disease (cirrhosis), pulmonary disease (emphysema), or both. Out of 24 different alleles labelled alphabetically, PiMM is the most common normal phenotype, while the most frequent abnormal phenotype in α -1-antitrypsin deficiency leading to liver and/or lung disease is PiZZ in homozygote form.

The patients may present with respiratory disease due to the development of emphysema, or may develop liver dysfunction, or both.

MORPHOLOGIC FEATURES. The hepatic changes vary according to the age at which the deficiency becomes apparent. At birth or in neonates, the histologic features consist of neonatal hepatitis that may be acute or 'pure' cholestasis. Micronodular or macronodular cirrhosis may appear in childhood or in adolescence in which the diagnostic feature is the presence of intracellular, acidophilic, PAS-positive globules in the periportal hepatocytes.

Cardiac Cirrhosis (p. 628)

Cardiac cirrhosis is an uncommon complication of severe right-sided congestive heart failure of long-standing duration. The common causes culminating in cardiac cirrhosis are cor pulmonale, tricuspid insufficiency or constrictive pericarditis.

G/A The liver is enlarged and firm with stretched Glisson's capsule.

M/E In acute stage, the hepatic sinusoids are dilated and congested with haemorrhagic necrosis of centrilobular hepatocytes (*central haemorrhagic necrosis*). Severe and more prolonged heart failure results in delicate fibrous strands radiating from the central veins. These fibrous strands may form interconnections leading to cardiac cirrhosis and regenerative nodules.

Indian Childhood Cirrhosis (p. 629)

Indian childhood cirrhosis (ICC) is an unusual form of cirrhosis seen in children between the age of 6 months and 3 years in rural, middle class, Hindus in India and in parts of South-East Asia and in the Middle-East.

MORPHOLOGIC FEATURES. Five histologic types of ICC have been distinguished of which type II is the most common. This form is characterised by the following features:

- i) Liver cell injury ranging from ballooning degeneration to significant damage to hepatocytes.
- ii) Prominent Mallory bodies in some hepatocytes without fatty change.
- iii) Neutrophilic and sometimes alongwith lymphocytic infiltrate.
- iv) Creeping pericellular fibrosis which may eventually lead to fine micro-macro-nodular cirrhosis.
- v) There is significant deposition of copper and copper-associated proteins in hepatocytes, often more than what is seen in Wilson's disease.

Cirrhosis in Autoimmune Hepatitis (p. 629)

Autoimmune hepatitis (also called lupoid hepatitis) is a form of chronic hepatitis characterised by continued hepatocellular injury, inflammation and fibrosis which may progress to cirrhosis. The condition may run a variable natural history ranging from indolent to severe rapid course. This form of hepatitis has prominent autoimmune etiology is supported by immunologic abnormalities and a few other characteristic diagnostic criteria as under:

1. Female gender predisposition.
2. Predominant elevation of aminotransferases (AST and ALT).
3. Hyperglobulinaemia (elevated IgG and γ -globulin).
4. High serum titres of nuclear (ANA), smooth muscle (SMA), and liver-kidney microsomal (LKM1) autoantibodies, and absence of antimitochondrial antibodies.
5. Concurrent presence of other autoimmune diseases.
6. Presence of HLA DR3 or HLA DR4 markers.
7. Lack of prominent elevation of alkaline phosphatase.
8. Exclusion of chronic hepatitis of other known etiologies (viral, toxic, genetic etc).

MORPHOLOGIC FEATURES. Autoimmune hepatitis is morphologically indistinguishable from chronic hepatitis of viral etiology. Patients who survive active disease develop cirrhosis. There are features of burnt out chronic autoimmune hepatitis accompanied with cirrhosis.

Cirrhosis in Non-alcoholic Steatohepatitis (p. 629)

Non-alcoholic steatohepatitis (NASH) or non-alcoholic fatty liver disease (NAFLD) is a form of hepatitis resembling alcoholic liver disease but seen in nondrinkers of alcohol. The condition is seen more commonly in affluent western societies, has a strong association with obesity, dyslipidaemia and type 2 diabetes mellitus. It is seen in younger patients with equal gender prevalence.

MORPHOLOGIC FEATURES. The condition is a form of chronic hepatitis after known causes have been excluded. About 10-30% cases of NASH progress to increased fibrosis and develop cirrhosis.

Miscellaneous Forms of Cirrhosis (p. 629)

In addition to the various types of cirrhosis just described, a few other uncommon types associated with different diseases are sometimes distinguished. These include the following:

1. **Metabolic disorders** e.g. in galactosaemia, hereditary fructose intolerance, glycogen storage diseases.
2. **Infectious diseases** e.g. in brucellosis, schistosomiasis, syphilis (hepar lobatum) and toxoplasma infection.
3. **Gastrointestinal disorders** e.g. in inflammatory bowel disease, cystic fibrosis of the pancreas and intestinal bypass surgery for obesity.
4. **Infiltrative diseases** e.g. in sarcoidosis.

Cryptogenic Cirrhosis (p. 629)

Finally, when all the known etiologic types of cirrhosis have been excluded, there remain patients with cirrhosis in whom the cause is unknown.

NON-CIRRHOTIC PORTAL FIBROSIS (p. 629)

Non-cirrhotic portal fibrosis (NCPF) is a group of congenital and acquired diseases in which there is localised or generalised hepatic fibrosis without nodular regenerative activity and there is absence of clinical and functional evidence of cirrhosis. One of the types associated with increased portal fibrosis without definite cirrhosis is seen in *idiopathic (primary) portal hypertension with splenomegaly*, reported from India and Japan. The type common in India, particularly in young males, is related to *chronic arsenic ingestion* in drinking water and intake of orthodox medicines.

G/A The liver is small, fibrous and shows prominent fibrous septa on both external as well as on cut surface forming irregular islands in the liver.

528 **M/E** The features are:

- i) Standing out of portal tracts due to their increased amount of fibrous tissue in triad without significant inflammation.
- ii) Obliterative sclerosis of portal vein branches in the portal tracts (obliterative portovenopathy).

□ **CLINICAL MANIFESTATIONS AND COMPLICATIONS OF CIRRHOSIS** (p. 630)

The range of clinical features in cirrhosis varies widely, from an asymptomatic state to progressive liver failure and death. The onset of disease is insidious. In general, the features of cirrhosis are more marked in the alcoholic form than in other varieties. These include weakness, fatiguability, weight loss, anorexia, muscle wasting, and low-grade fever due to hepatocellular necrosis or some latent infection. Advanced cases develop a number of complications which are as follows:

1. *Portal hypertension and its major effects*
2. *Progressive hepatic failure*
3. *Development of hepatocellular carcinoma*
4. *Chronic relapsing pancreatitis*
5. *Steatorrhoea*
6. *Gallstones*
7. *Infections*
8. *Haematologic derangements*
9. *Cardiovascular complications*
10. *Musculoskeletal abnormalities*
11. *Endocrine disorders*
12. *Hepatorenal syndrome*

The ultimate *causes of death* are hepatic coma, massive gastrointestinal haemorrhage from oesophageal varices (complication of portal hypertension), intercurrent infections, hepatorenal syndrome and development of hepatocellular carcinoma.

□ **PORTAL HYPERTENSION** (p. 630)

Increase in pressure in the portal system usually follows obstruction to the portal blood flow anywhere along its course. Portal veins have no valves and thus obstruction anywhere in the portal system raises pressure in all the veins proximal to the obstruction. However, unless proved otherwise, portal hypertension means obstruction to the portal blood flow by cirrhosis of the liver.

CLASSIFICATION. Based on the site of obstruction to portal venous blood flow, portal hypertension is categorised into 3 main types—*intrahepatic*, *posthepatic* and *prehepatic* (**Web Table 21.10**).

1. Intrahepatic portal hypertension. Cirrhosis is by far the commonest cause of portal hypertension. Other less frequent intrahepatic causes are metastatic tumours, non-cirrhotic nodular regenerative conditions, hepatic venous obstruction (Budd-Chiari syndrome), veno-occlusive disease, schistosomiasis, diffuse granulomatous diseases and extensive fatty change.

2. Posthepatic portal hypertension. This is uncommon and results from obstruction to the blood flow through hepatic vein into inferior vena cava. The causes are neoplastic occlusion and thrombosis of the hepatic vein or of the inferior vena cava (including Budd-Chiari syndrome).

3. Prehepatic portal hypertension. Blockage of portal flow before portal blood reaches the hepatic sinusoids results in prehepatic portal hypertension. Such conditions are thrombosis and neoplastic obstruction of the portal vein before it ramifies in the liver, myelofibrosis, and congenital absence of portal vein.

MAJOR SEQUELAE OF PORTAL HYPERTENSION. Irrespective of the mechanisms involved in the pathogenesis of portal hypertension, there are 4 major clinical consequences (**Web Image 21.30**):

1. Ascites. Ascites is the accumulation of excessive volume of fluid within the peritoneal cavity. It frequently accompanies cirrhosis and other diffuse liver diseases. Ascitic fluid is generally transudate with specific gravity of 1.010, protein content below 3 gm/dl and electrolyte concentrations like those of other extracellular fluids.

Pathogenesis. The ascites becomes clinically detectable when more than 500 ml of fluid has accumulated in the peritoneal cavity. Briefly, the systemic and local factors favouring ascites formation are as under (**Web Image 21.31**):

A. Systemic Factors:

- i) *Decreased plasma colloid oncotic pressure*
- ii) *Hyperaldosteronism*
- iii) *Impaired renal excretion*

B. Local Factors:

- i) *Increased portal pressure*
- ii) *Increased hepatic lymph formation*

2. Varices (Collateral channels or Porto-systemic shunts). As a result of rise in portal venous pressure and obstruction in the portal circulation within or outside the liver, the blood tends to bypass the liver and return to the heart by development of porto-systemic collateral channels (or shunts or varices). These varices develop at sites where the systemic and portal circulations have common capillary beds. The principal sites are as under:

- i) *Oesophageal varices*
- ii) *Haemorrhoids*
- iii) *Caput medusae*
- iv) *Retroperitoneal anastomoses*

3. Splenomegaly. The enlargement of the spleen in prolonged portal hypertension is called congestive splenomegaly. The spleen may weigh 500-1000 gm and is easily palpable. The spleen is larger in young people and in macronodular cirrhosis than in micronodular cirrhosis.

4. Hepatic encephalopathy. Porto-systemic venous shunting may result in a complex metabolic and organic syndrome of the brain characterised by disturbed consciousness, neurologic signs and flapping tremors. Hepatic encephalopathy is particularly associated with advanced hepatocellular disease such as in cirrhosis.

□ **HEPATIC TUMOURS AND TUMOUR-LIKE LESIONS** (p. 632)

The liver is the site for benign tumours, tumour-like lesions, and both primary and metastatic malignant tumours. However, metastatic tumours are much more common than primary tumours and tumour-like lesions. Primary hepatic tumours may arise from *hepatic cells, bile duct epithelium, or mesodermal structures* (**Web Table 21.11**).

TUMOUR-LIKE LESIONS (p. 632)

Hepatic Cysts (p. 632)

1. CONGENITAL CYSTS. These are uncommon. They are usually small (less than 1 cm in diameter) and are lined by biliary epithelium. They may be single, or occur as polycystic liver disease, often associated with polycystic kidney.

2. SIMPLE (NON-PARASITIC) CYSTS. Simple cysts are solitary non-parasitic cysts seen more frequently in middle-aged women. The cyst is usually large (up to 20 cm in diameter), lying underneath the Glisson's capsule and filled with serous fluid. The cyst produces a palpable mass and may be associated with jaundice.

3. HYDATID (ECHINOCOCCUS) CYSTS. Discussed in Chapter 7.

530 Focal Nodular Hyperplasia (p. 633)

The *etiology* of focal nodular hyperplasia is not known but these lesions are more common in women taking oral contraceptives.

G/A Focal nodular hyperplasia is a well-demarcated tumour-like nodule occurring underneath the Glisson's capsule. The nodules may be single or multiple, measuring about 5 cm in diameter. The sectioned surface shows a central fibrous scar.

M/E It is composed of collagenous septa radiating from the central fibrous scar which separate nodules of normal hepatocytes without portal triads or central hepatic veins.

BENIGN HEPATIC TUMOURS (p. 633)

Hepatocellular (Liver Cell) Adenoma (p. 633)

Adenomas arising from hepatocytes are rare and are reported in women in reproductive age group in association with use of oral contraceptives, sex hormone therapy and with pregnancy.

G/A The tumour usually occurs singly but about 10% are multiple. It is partly or completely encapsulated and slightly lighter in colour than adjacent liver or may be bile-stained. The tumours vary from a few centimetres up to 30 cm in diameter. On cut section, many of the tumours have varying degree of infarction and haemorrhage.

M/E Liver cell adenomas are composed of sheets and cords of hepatocytes which may be normal-looking or may show slight variation in size and shape but no mitoses. The hepatocytes in adenomas contain greater amount of glycogen than the surrounding liver cells and may sometimes show fatty change.

Bile Duct Adenoma (Cholangioma) (p. 633)

Intrahepatic or extrahepatic bile duct adenoma is a rare benign tumour. The tumour may be small, composed of acini lined by biliary epithelium and separated by variable amount of connective tissue, or are larger cystadenomas having loculi lined by biliary epithelium.

Haemangioma (p. 633)

Haemangioma is the commonest benign tumour of the liver. Majority of them are asymptomatic and discovered incidentally. Rarely, a haemangioma may rupture into the peritoneal cavity.

G/A Haemangiomas appear as solitary or multiple, circumscribed, red-purple lesions, commonly subcapsular and varying from a few millimetres to a few centimetres in diameter.

M/E Haemangioma of the liver shows characteristic large, cavernous, blood-filled spaces, lined by a single layer of endothelium and separated by connective tissue (**Web Image 21.32**).

MALIGNANT HEPATIC TUMOURS (p. 633)

Among the primary malignant tumours of the liver, hepatocellular (liver cell) carcinoma accounts for approximately 85% of all primary malignant tumours, cholangiocarcinoma for about 5-10%, and infrequently mixed pattern is seen. The remainder are rare tumours that include hepatoblastoma, haemangiosarcoma (angiosarcoma) and embryonal sarcoma.

Hepatocellular Carcinoma (p. 633)

Hepatocellular carcinoma (HCC) or liver cell carcinoma, also termed as hepatoma, is the most common primary malignant tumour of the liver. The

tumour shows marked geographic variations in incidence which is closely related to HBV and HCV infection in the region.

ETIOPATHOGENESIS. A number of etiologic factors are implicated in the etiology of HCC, most important being *HBV and HCV infection, and association with cirrhosis.*

1. Relation to HBV infection. Genesis of HCC is linked to prolonged infection with HBV. The evidence in support is both epidemiologic and direct.

- i) The incidence of HBsAg positivity is higher in HCC patients.
- ii) In African and Asian patients, 95% cases of HCC have anti-HBc.
- iii) There is more direct evidence of integration of HBV-DNA genome in the genome of tumour cells of HCC.

2. Relation to HCV infection. Long-standing HCV infection has emerged as a major factor in the etiology of HCC, generally after more than 30 years of infection.

3. Relation to cirrhosis. Cirrhosis of all etiologic types is more commonly associated with HCC but the most frequent association is with macronodular post-necrotic cirrhosis. The mechanism of progression to HCC appears to be chronic regenerative activity in cirrhosis, or that the damaged liver in cirrhosis is rendered vulnerable to carcinogenic influences.

4. Relation to alcohol. It has been observed that alcoholics have about four-fold increased risk of developing HCC. It is possible that alcohol may act as co-carcinogen with HBV or HCV infection.

5. Mycotoxins. An important mycotoxin, aflatoxin B1, produced by a mould *Aspergillus flavus*, can contaminate poorly stored wheat grains or groundnuts, especially in developing countries.

6. Chemical carcinogens. These include butter-yellow and nitrosamines used as common food additives.

7. Miscellaneous factors.

- i) haemochromatosis;
- ii) α -1-antitrypsin deficiency;
- iii) prolonged immunosuppressive therapy in renal transplant patients;
- iv) other types of viral hepatitis;
- v) tobacco smoking; and
- vi) parasitic infestations such as clonorchiasis and schistosomiasis.

Pathogenesis of hepatocellular carcinoma can be explained on the basis of genetic mutations induced by one of the above major etiologic factors. In many cases, this mutated gene has been identified as inactivation of tumour suppressor oncogene *p53* by HBV that results in disruption of normal growth control. In this regards, the role of X-protein (HBxAg) generated from X-gene of HBV has been found to contribute to carcinogenesis by binding to *p53*.

G/A HCC may form one of the following 3 patterns of growth, in decreasing order of frequency (**Web Image 21.33**):

- i) *Expanding type*: Most frequently, it forms a *single, yellow-brown, large mass*, most often in the right lobe of the liver with central necrosis, haemorrhage and occasional bile-staining (**Web Image 21.34**).
- ii) *Multifocal type*: Less often, *multifocal, multiple masses*, 3-5 cm in diameter, scattered throughout the liver are seen.
- iii) *Infiltrating (Spreading) type*: Rarely, the HCC forms diffusely infiltrating tumour mass.

M/E Most of the HCC have trabecular growth pattern. The tumour cells have a tendency to invade and grow along blood vessels. Thus important diagnostic features are the *patterns of tumour cells* and their *cytologic features*:

1. Histologic patterns: These include the following:

- 532 i) *Trabecular or sinusoidal pattern (Web Image 21.35).*
ii) *Pseudoglandular or acinar pattern*
iii) *Compact pattern*
iv) *Scirrhous pattern*

2 Cytologic features: The typical cytologic features in the HCC consist of cells resembling hepatocytes having vesicular nuclei with prominent nucleoli. Aside from these features, a few other cytologic variants are: pleomorphism, bizarre giant cell formation, spindle-shaped cells, tumour cells with clear cytoplasm, presence of bile within dilated canaliculi, and intracytoplasmic Mallory's hyalin.

FIBROLAMELLAR CARCINOMA. A clinicopathologic variant of the HCC is fibrolamellar carcinoma of the liver found in young people of both sexes. The tumour forms a single large mass which may be encapsulated and occurs in the absence of cirrhosis.

M/E The tumour is composed of eosinophilic polygonal cells (oncocytes) forming cords and nests which are separated by bands of fibrous stroma (**Web Image 21.36**).

The prognosis of fibrolamellar carcinoma is better than other forms of HCC.

CLINICAL FEATURES. The usual features consist of hepatomegaly with palpable mass in the liver, right upper quadrant pain or tenderness, and less often, jaundice, fever and haemorrhage from oesophageal varices. Ascites with RBCs and malignant cells is found in about half the patients.

Laboratory findings yield nonspecific results like anaemia, markedly elevated serum alkaline phosphatase as found in cirrhosis, and high serum alpha-fetoprotein (AFP). Elevated AFP level is quite specific; very high levels of AFP (above 500 ng/ml) are observed in 70-80% cases of HCC but lacks sensitivity since AFP is also found elevated in yolk sac tumour, cirrhosis, chronic hepatitis, massive liver necrosis and normal pregnancy.

SPREAD. The HCC can have both intrahepatic and extrahepatic spread which faithfully reproduces the structure of the primary tumour:

The causes of death from the HCC are cachexia, massive bleeding from oesophageal varices, and liver failure with hepatic coma.

Cholangiocarcinoma (p. 636)

Cholangiocarcinoma is the designation used for carcinoma arising from bile duct epithelium within the liver (*peripheral cholangiocarcinoma*). Carcinomas arising from the large hilar ducts (*hilar cholangiocarcinoma*) and from extrahepatic ducts are termed *bile duct carcinomas*. None of the etiologic factors related to HCC have any role in the genesis of cholangiocarcinoma.

G/A The tumour is firm to hard and whitish.

M/E The tumour has glandular structure. The tumour cells resemble biliary epithelium but without bile secretion. They form various patterns such as tubular, ductular or papillary. The stroma consists of fibrous tissue with little or no capillary formation.

Hepatoblastoma (Embryoma) (p. 637)

Hepatoblastoma is a rare malignant tumour arising from primitive hepatic parenchymal cells. It presents before the age of 2 years as progressive abdominal distension with anorexia, failure to thrive, fever and jaundice. It is more common in boys. The concentration of serum AFP is high.

G/A The tumour is circumscribed and lobulated mass measuring 5-25 cm in size, having areas of cystic degeneration, haemorrhage and necrosis.

M/E Hepatoblastoma consists of 2 components:

- i) **Epithelial component** contains 2 types of cells—‘*embryonal*’ *hepatocytes* are small with dark-staining, hyperchromatic nuclei and scanty cytoplasm, and ‘*foetal*’ *hepatocytes* are larger with more cytoplasm that may be granular or clear.
- ii) **Mesenchymal component** includes fibrous connective tissue, cartilage and osteoid of variable degree of maturation.

Secondary Hepatic Tumours (p. 637)

Metastatic tumours in the liver are more common than the primary hepatic tumours. Most frequently, they are blood-borne metastases, irrespective of whether the primary tumour is drained by portal vein or systemic veins. Most frequent primary tumours metastasising to the liver, in descending order of frequency, are those of stomach, breast, lungs, colon, oesophagus, pancreas, malignant melanoma and haematopoietic malignancies. Sarcomas rarely metastasise to the liver.

G/A Most metastatic carcinomas form multiple, spherical, nodular masses which are of variable size. Liver is enlarged and heavy, weighing 5 kg or more. The tumour deposits are white, well-demarcated, soft or haemorrhagic. The surface of the liver shows characteristic umbilication due to central necrosis of nodular masses (**Web Image 21.37**).

M/E The metastatic tumours generally reproduce the structure of the primary lesions (**Web Image 21.38**).

□ NORMAL STRUCTURE (p. 638)

ANATOMY. The gallbladder is a pear-shaped organ, 9 cm in length and has a capacity of approximately 50 ml. It consists of the *fundus*, *body* and *neck* that tapers into the cystic duct. The two hepatic ducts from right and left lobes of the liver unite at the porta hepatis to form the common hepatic duct which is joined by the cystic duct from the gallbladder to form the common bile duct. In about 70% of cases, it is joined by the main pancreatic duct to form the combined opening in the duodenum (*ampulla of Vater*).

M/E The gallbladder, unlike the rest of gastrointestinal tract, lacks the muscularis mucosae and submucosa. The wall of the gallbladder is composed of the following 4 layers:

1. Mucosal layer
2. Smooth muscle layer
3. Perimuscular layer
4. Perimuscular layer

The *extrahepatic bile ducts* are also lined by tall columnar epithelium that overlies the lamina propria.

FUNCTIONS. The main function of the gallbladder is to store and concentrate the bile secreted by the liver and then deliver it into the intestine for digestion and absorption of fat. The concentrating ability of the gallbladder is due to its absorptive mucosal surface that has numerous folds.

□ CONGENITAL ANOMALIES (p. 638)

Several uncommon congenital anomalies of the biliary system have been described. These include: agenesis, duplication and heterotopic tissue. However, *congenital cystic lesions* of the bile ducts (as also of the liver) are more frequently diagnosed. These conditions include: congenital intrahepatic biliary dilatation (Caroli’s disease), choledochal cysts, polycystic liver disease and congenital hepatic fibrosis.

□ CHOLELITHIASIS (GALLSTONES) (p. 638)

Gallstones are formed from constituents of the bile (viz. cholesterol, bile pigments and calcium salts) along with other organic components.

534 Accordingly, the gallstones commonly contain cholesterol, bile pigment and calcium salts in varying proportions. They are usually formed in the gallbladder, but sometimes may develop within extrahepatic biliary passages, and rarely in the larger intrahepatic bile duct.

RISK FACTORS. The incidence of gallstones varies markedly in different geographic areas, age, gender, diet and various other risk factors. Some of the risk factors in lithogenesis are as under:

1. Geography
2. Genetic factors
3. Age
4. Sex
5. Drugs
6. Obesity
7. Diet
8. Gastrointestinal diseases
9. **Factors in pigment gallstones.** All the above factors apply largely to cholesterol stones. Pigment stones, whether pure or mixed type, are more frequently associated with haemolytic anaemias which lead to increased content of unconjugated bilirubin in the bile. Pigment stones are also more frequent in cirrhosis and hepatocellular disease.

PATHOGENESIS. The mechanism of gallstone formation (i.e. lithogenesis) is explained separately below under 2 headings:

PATHOGENESIS OF CHOLESTEROL, MIXED GALLSTONES AND BILIARY SLUDGE. Cholesterol is essentially insoluble in water and can be solubilised by another lipid. Normally, cholesterol and phospholipids (lecithin) are secreted into bile as 'bilayered vesicles' but are converted into 'mixed micelles' by addition of bile acids, the third constituent. Formation of such lithogenic (stone-forming) bile is explained by the following mechanisms (**Web Image 21.39**):

1. Supersaturation of bile: Several etiologic factors listed above favour increased secretion of cholesterol in the presence of normal bile acids and lecithin in the bile as the major mechanism for initiation of gallstone formation. These factors cause enhanced activity of enzyme, HMG-CoA reductase, that normally regulates cholesterol synthesis and its hepatic uptake. Two other disturbances which may contribute to supersaturation of the bile with cholesterol are as under:

- i) *Reduced bile acid pool*
- ii) *Increased conversion of cholic acid to deoxycholic acid*

2. Cholesterol nucleation. Initiation of cholesterol stones occurs by nucleation of cholesterol monohydrate crystals. Accelerated nucleation of cholesterol monohydrate may occur either from pro-nucleating factors or from deficiency of anti-nucleating factors:

- i) *Pro-nucleating factors* are mucin and non-mucin glycoproteins.
- ii) *Anti-nucleating factors* are apolipoproteins AI and AII, and some glycoproteins.

3. Gallbladder hypomotility. Normally, the gallbladder is capable of emptying and clearing any sludge or debris which might initiate stone formation. This takes place under the influence of *cholecystokinin* secreted from small intestine.

PATHOGENESIS OF PIGMENT GALLSTONES. The mechanism of pigment stone formation is explained on the basis of following factors:

- i) Chronic haemolysis resulting in increased level of unconjugated bilirubin in the bile.
- ii) Alcoholic cirrhosis.
- iii) Chronic biliary tract infection e.g. by parasitic infestations of the biliary tract such as by *Clonorchis sinensis* and *Ascaris lumbricoides*.

iv) Demographic and genetic factors e.g. in rural setting and prevalence in Asian countries.

TYPES OF GALLSTONES. As stated before, gallstones contain cholesterol, bile pigment and calcium carbonate, either in pure form or in various combinations. Accordingly, gallstones are of 3 major types—*pure gallstones*, *mixed gallstones* and *combined gallstones*. Mixed gallstones are the most common (80%) while pure and combined gallstones comprise 10% each. In general, gallstones are formed most frequently in the gallbladder but may occur in extrahepatic as well as intrahepatic biliary passages.

The salient features of various types of gallstones are summarised in **Web Table 21.12** and presented below:

1. Pure gallstones. They are further divided into 3 types according to the component of bile forming them. These are as under (**Web Image 21.40**):

i) *Pure cholesterol gallstones*: They are usually solitary, oval and fairly large (3 cm or more) filling the gallbladder. (**Web Image 21.41**).

ii) *Pure pigment gallstones*: These stones composed primarily of bile pigment, calcium bilirubinate, and contain less than 20% cholesterol. They are generally multiple, jet-black and small (less than 1 cm in diameter). They have mulberry like external surface.

iii) *Pure calcium carbonate gallstones*: They are rare. Calcium carbonate gallstones are usually multiple, grey-white, small (less than 1 cm in diameter).

2. Mixed gallstones. Mixed gallstones are the most common (80%) and contain more than 50% cholesterol monohydrate plus an admixture of calcium salts, bile pigments and fatty acids. They are always multiple, multifaceted so that they fit together and vary in size from as tiny as sand-grain to 1 cm or more in diameter (**Web Image 21.42, A**).

3. Combined gallstones. They comprise about 10% of all gallstones. Combined gallstones are usually solitary, large and smooth-surfaced. It has a *pure gallstone nucleus* (cholesterol, bile pigment or calcium carbonate) and outer shell of mixed gallstone; or a *mixed gallstone nucleus* with pure gallstone shell (**Web Image 21.42, B**).

CLINICAL MANIFESTATIONS AND COMPLICATIONS. In about 50% cases, gallstones cause no symptoms and may be diagnosed by chance during investigations for some other condition (*silent gallstones*). The future course in such asymptomatic silent cases is controversial. Symptomatic cases may manifest as under:

1) Cholecystitis, 2) Choledocholithiasis, 3) Mucocele, 4) Biliary fistula, 5) Gallstone ileus and 6) Gallbladder cancer

□ **CHOLECYSTITIS** (p. 641)

Acute Cholecystitis (p. 641)

In many ways, acute cholecystitis is similar to acute appendicitis. The condition usually begins with obstruction, followed by infection later.

ETIOPATHOGENESIS. Based on the initiating mechanisms, acute cholecystitis occurs in two types of situations—*acute calculous* and *acute acalculous cholecystitis*.

◆ **Acute calculous cholecystitis.** In 90% of cases, acute cholecystitis is caused by obstruction in the neck of the gallbladder or in the cystic duct by a gallstone.

◆ **Acute acalculous cholecystitis.** The remaining 10% cases of acute cholecystitis do not contain gallstones. In such cases, a variety of causes have been assigned such as previous nonbiliary surgery, multiple injuries, burns, recent childbirth, severe sepsis, dehydration, torsion of the gallbladder and diabetes mellitus.

G/A The gallbladder is distended and tense. The serosal surface is coated with fibrinous exudate with congestion and haemorrhages. The mucosa is

536 bright red. The lumen is filled with pus mixed with green bile. In calculous cholecystitis, a stone is generally impacted in the neck or in the cystic duct. When obstruction of the cystic duct is complete, the lumen is filled with purulent exudate and the condition is known as *empyema of the gallbladder*.

M/E Wall of the gallbladder shows marked inflammatory oedema, congestion and neutrophilic exudate.

CLINICAL FEATURES. The patients of acute cholecystitis of either type have similar clinical features. They present with severe pain in the upper abdomen with features of peritoneal irritation such as guarding and hyperaesthesia.

Chronic Cholecystitis (p. 642)

Chronic cholecystitis is the commonest type of clinical gallbladder disease. There is almost constant association of chronic cholecystitis with cholelithiasis.

ETIOPATHOGENESIS. The association of chronic cholecystitis with mixed and combined gallstones is virtually always present. However, it is not known what initiates the inflammatory response in the gallbladder wall.

G/A The gallbladder is generally contracted but may be normal or enlarged (**Web Image 21.43**). The wall of the gallbladder is thickened which on cut section is grey-white due to dense fibrosis or may be even calcified. The lumen commonly contains multiple mixed stones or a combined stone.

M/E The features are as under (**Web Image 21.44**):

1. Thickened and congested mucosa but occasionally mucosa may be totally destroyed.
2. Penetration of the mucosa deep into the wall of the gallbladder up to muscularis layer to form *Rokitansky-Aschoff's sinuses*.
3. Variable degree of chronic inflammatory reaction, consisting of lymphocytes, plasma cells and macrophages, present in the lamina propria and subserosal layer.
4. Variable degree of fibrosis in the subserosal and subepithelial layers.

A few morphologic variants of chronic cholecystitis are considered below:

- ◆ Cholecystitis glandularis
- ◆ Porcelain gallbladder
- ◆ Acute on chronic cholecystitis

CLINICAL FEATURES. Chronic cholecystitis has ill-defined and vague symptoms. Generally, the patient—a *fat, fertile, female of forty or fifty*, presents with abdominal distension or epigastric discomfort, especially after a fatty meal. There is a constant dullache in the right hypochondrium and epigastrium and tenderness over the right upper abdomen. Nausea and flatulence are common.

TUMOURS OF BILIARY SYSTEM (p. 643)

BENIGN TUMOURS (p. 643)

Benign tumours such as papilloma, adenoma, adenomyoma, fibroma, lipoma, myxoma, and haemangioma have been described in the biliary tract but all of them are exceedingly rare. *Adenomyoma* is more common benign tumour than the rest.

MALIGNANT TUMOURS (p. 643)

Carcinoma of the Gallbladder (p. 643)

Primary carcinoma of the gallbladder is more prevalent than other cancers of the extrahepatic biliary tract. Like cholelithiasis and cholecystitis, it is

more frequent in women than in men (ratio 4:1) with a peak incidence in 7th decade of life.

ETIOLOGY. These factors are as under:

1. Cholelithiasis and cholecystitis. The most significant association of cancer of the gallbladder is with cholelithiasis and cholecystitis, though there is no definite evidence of causal relationship. Cholelithiasis and cholecystitis are present in about 75% cases of gallbladder cancer.

2. Chemical carcinogens. A number of chemical carcinogens structurally similar to naturally-occurring bile acids have been considered to induce gallbladder cancer. These include methyl cholanthrene, various nitrosamines and pesticides.

3. Genetic factors. There is higher incidence of cancer of the gallbladder in certain populations living in the same geographic region suggesting a strong genetic component in the disease.

4. Miscellaneous. Patients who have undergone previous surgery on the biliary tract have higher incidence of subsequent gallbladder cancer. Patients with inflammatory bowel disease (ulcerative colitis and Crohn's disease) have high incidence of gallbladder cancer.

MORPHOLOGIC FEATURES. The commonest site is the fundus, followed next in frequency by the neck of the gallbladder (**Web Image 21.45**).

G/A Cancer of the gallbladder is of 2 types (**Web Image 21.46**):

- Infiltrating type* appears as an irregular area of diffuse thickening and induration of the gallbladder wall.
- Fungating type* grows like an irregular, friable, papillary or cauliflower-like growth into the lumen as well as into the wall of the gallbladder and beyond.

M/E The following patterns are observed:

- Most gallbladder cancers are *adenocarcinomas* (90%). They may be papillary or infiltrative, well-differentiated or poorly-differentiated. Most are non-mucin secreting but some are colloid carcinomas forming mucus pools.
- About 5% of gallbladder cancers are *squamous cell carcinomas* arising from squamous metaplastic epithelium.
- A few cases show both squamous and adenocarcinoma pattern of growth called *adenosquamous carcinoma*.

CLINICAL FEATURES. Carcinoma of the gallbladder is slow-growing and causes symptoms late in the course of disease. Quite often, the diagnosis is made when gallbladder is removed for cholelithiasis. The symptomatic cases have pain, jaundice, noticeable mass, anorexia and weight loss.

Carcinoma of Extrahepatic Bile Ducts and Ampulla of Vater (p. 644)

This is an infrequent neoplasm but is more common than the rare benign tumours of the biliary tract. Unlike other diseases of the biliary passages, it is more common in males with peak incidence in 6th decade of life.

ETIOLOGY. There is no association between bile duct carcinoma and gallstones. Bile duct cancers are associated with a number of other conditions such as ulcerative colitis, sclerosing cholangitis, parasitic infestations of the bile ducts with *Fasciola hepatica* (liver fluke), *Ascaris lumbricoides* and *Clonorchis sinensis*.

MORPHOLOGIC FEATURES. Extrahepatic bile duct carcinoma may arise anywhere in the biliary tree but the most frequent sites, in descending order of frequency, are: the ampulla of Vater, lower end of common bile duct, hepatic ducts, and the junction of hepatic ducts to form common bile duct (see **Web Image 21.45**).

G/A Bile duct carcinoma is usually small, extending for 1-2 cm along the duct, producing thickening of the affected duct.

538 M/E The tumour is usually well-differentiated adenocarcinoma which may or may not be mucin-secreting. Perineural invasion is frequently present.

CLINICAL FEATURES. Obstructive jaundice is the usual presenting feature which is characterised by intense pruritus.

□ **NORMAL STRUCTURE** (p. 644)

The human pancreas, though anatomically a single organ, histologically and physiologically has 2 distinct parts—the *exocrine* and *endocrine parts*.

ANATOMY. The pancreas lies obliquely in the concavity of the duodenum as an elongated structure about 15 cm in length and 100 gm in weight (see **Web Image 21.1**). It is subdivided into 3 topographic zones: Head, body and tail .

HISTOLOGY. The exocrine pancreas constitutes 80 to 85% of the total gland, while the endocrine pancreas comprises the remaining part.

The exocrine part is divided into rhomboid lobules separated by thin fibrous tissue septa containing blood vessels, lymphatics, nerves and ducts. Each lobule is composed of numerous acini. The acini are lined by pyramid-shaped columnar epithelial cells.

FUNCTIONS. The main functions of the exocrine pancreas is the alkaline secretion of digestive enzymes prominent among which are trypsin, chymotrypsin, elastase, amylase, lipase and phospholipase.

□ **DEVELOPMENTAL ANOMALIES** (p. 645)

Cystic Fibrosis (p. 645)

Cystic fibrosis of the pancreas or fibrocystic disease is a hereditary disorder characterised by viscid mucous secretions in all the exocrine glands of the body (*mucoviscidosis*) and associated with increased concentrations of electrolytes in the eccrine glands. The terms 'cystic fibrosis' and 'fibrocystic disease' are preferable over 'mucoviscidosis' in view of the main pathologic change of fibrosis produced as a result of obstruction of the passages by viscid mucous secretions.

The disease is transmitted as an *autosomal recessive trait* with apparent clinical features in homozygotes only. It is quite common in the whites (1 per 2000 livebirths). The clinical manifestations may appear at birth or later in adolescence and pertain to multiple organs and systems such as pancreatic insufficiency, intestinal obstruction, steatorrhoea, malnutrition, hepatic cirrhosis and respiratory complications.

MORPHOLOGIC FEATURES. Depending upon the severity of involvement and the organs affected, the pathologic changes are variable. Most of the changes are produced as a result of obstruction by viscid mucous.

1. Pancreas. The pancreas is almost invariably involved in cystic fibrosis.

G/A Pancreatic lobules are ovoid rather than rhomboid. Fatty replacement of the pancreas and grossly visible cysts may be seen.

M/E The lobular architecture of pancreatic parenchyma is maintained. There is increased interlobular fibrosis. The acini are atrophic and many of the acinar ducts contain laminated, eosinophilic concretions.

2. Liver. The bile canaliculi are plugged by viscid mucous which may cause diffuse fatty change, portal fibrosis and ductular proliferation. More severe involvement may cause biliary cirrhosis.

3. Respiratory tract. Changes in the respiratory passages are seen in almost all typical cases of cystic fibrosis. The viscid mucous secretions of the submucosal glands of the respiratory tract cause obstruction, dilatation and infection of the airways.

4. Salivary glands. Pathologic changes in the salivary glands are similar to those in pancreas and include obstruction of the ducts, dilatation, fibrosis and glandular atrophy.

5. Sweat glands. Hypersecretion of sodium and chloride in the sweat observed in these patients may be reflected pathologically by diminished vacuolation of the cells of eccrine glands.

□ PANCREATITIS (p. 646)

Acute Pancreatitis (p. 646)

Acute pancreatitis is an acute inflammation of the pancreas presenting clinically with 'acute abdomen'. The severe form of the disease associated with macroscopic haemorrhages and fat necrosis in and around the pancreas is termed *acute haemorrhagic pancreatitis* or *acute pancreatic necrosis*. The condition occurs in adults between the age of 40 and 70 years and is commoner in females than in males.

The onset of acute pancreatitis is sudden, occurring after a bout of alcohol or a heavy meal. Characteristically, there is elevation of *serum amylase* level within the first 24 hours and elevated *serum lipase* level after 3 to 4 days, the latter being more specific for pancreatic disease. Glucosuria occurs in 10% of cases.

ETIOLOGY. The two leading causes associated with acute pancreatitis are *alcoholism* and *cholelithiasis*, both of which are implicated in more than 80% of cases.

PATHOGENESIS. The destructive changes in the pancreas are attributed to the liberation and activation of pancreatic enzymes. Though more than 20 enzymes are secreted by exocrine pancreas, 3 main groups of enzymes which bring about destructive effects on the pancreas are as under: 1) proteases, 2) lipases and phospholipases, and 3) elastases.

The activation and release of these enzymes is brought about by one of the following mechanisms:

- ◆ *Acinic cell damage*
- ◆ *Duct obstruction*
- ◆ *Block in exocytosis.*

G/A In the early stage, the pancreas is swollen and oedematous. Subsequently, in a day or two, characteristic variegated appearance of grey-white pancreatic necrosis, chalky-white fat necrosis and blue-black haemorrhages are seen.

M/E

1. Necrosis of pancreatic lobules and ducts.
2. Necrosis of the arteries and arterioles with areas of haemorrhages.
3. Fat necrosis.
4. Inflammatory reaction, chiefly by polymorphs, around the areas of necrosis and haemorrhages.

COMPLICATIONS. A patient of acute pancreatitis who survives may develop a variety of systemic and local complications.

Systemic complications:

1. Chemical and bacterial peritonitis.
2. Endotoxic shock.
3. Acute renal failure.

Local sequelae:

1. Pancreatic abscess.
2. Pancreatic pseudocyst.
3. Duodenal obstruction.

Mortality in acute pancreatitis is high (20-30%). Patients succumb to hypotensive shock, infection, acute renal failure, and DIC.

540 Chronic Pancreatitis (p. 646)

Chronic pancreatitis or *chronic relapsing pancreatitis* is the progressive destruction of the pancreas due to repeated mild and subclinical attacks of acute pancreatitis. Weight loss and jaundice are often associated. Later manifestations include associated diabetes mellitus and steatorrhea.

ETIOLOGY. Most cases of chronic pancreatitis are caused by the same factors as for acute pancreatitis. Thus, most commonly, chronic pancreatitis is related to *chronic alcoholism* with protein-rich diet, and less often to *biliary tract disease*. *Familial hereditary pancreatitis*, though uncommon, is more frequently chronic than the acute form.

PATHOGENESIS. Acute haemorrhagic pancreatitis seldom develops into chronic pancreatitis, but instead develops pancreatic pseudocysts following recovery. Pathogenesis of alcoholic and non-alcoholic chronic pancreatitis is explained by different mechanisms:

1. Chronic pancreatitis due to *chronic alcoholism* accompanied by a high-protein diet results in increase in protein concentration in the pancreatic juice which obstructs the ducts and causes damage.
2. *Non-alcoholic cases* of chronic pancreatitis seen in tropical countries (tropical chronic pancreatitis) result from protein-calorie malnutrition. Genetic factors play a role in some cases of chronic pancreatitis.

G/A The pancreas is enlarged, firm and nodular. The cut surface shows a smooth grey appearance with loss of normal lobulation. Foci of calcification and tiny pancreatic concretions to larger visible stones are frequently found.

M/E Depending upon the stage of development, the following changes are seen (**Web Image 21.47**):

1. Obstruction of the ducts by fibrosis in the wall and protein plugs or stones in the lumina.
2. Squamous metaplasia and dilatation of some inter- and intralobular ducts.
3. Chronic inflammatory infiltrate around the lobules as well as the ducts.
4. Atrophy of the acinar tissue with marked increase in interlobular fibrous tissue.
5. Islet tissue is involved in late stage only.

COMPLICATIONS. Late stage of chronic pancreatitis may be complicated by diabetes mellitus, pancreatic insufficiency with steatorrhea and malabsorption and formation of pancreatic pseudocysts (**Web Image 21.48**).

□ TUMOURS AND TUMOUR-LIKE LESIONS (p. 647)

Pancreatic Pseudocyst (p. 647)

Pancreatic pseudocyst is a localised collection of pancreatic juice, necrotic debris and haemorrhages. It develops following either acute pancreatitis or trauma. The patients generally present with abdominal mass producing pain, intraperitoneal haemorrhage and generalised peritonitis.

G/A The pseudocyst may be present within or adjacent to the pancreas. Usually it is solitary, unilocular, measuring up to 10 cm in diameter with thin or thick wall (**Web Image 21.48**).

M/E The cyst wall is composed of dense fibrous tissue with marked inflammatory reaction. There is evidence of preceding haemorrhage and necrosis in the form of deposits of haemosiderin pigment, calcium and cholesterol crystals.

Carcinoma of Pancreas (p. 647)

Pancreatic cancer is the term used for cancer of the exocrine pancreas. It is one of the common cancers, particularly in the Western countries and

Japan. It is commoner in males than in females and the incidence increases progressively after the age of 50 years.

ETIOLOGY. Following factors have been implicated in its etiology:

1. Smoking
2. Diet and obesity
3. Chemical carcinogens
4. Diabetes mellitus
5. Chronic pancreatitis
6. *H. pylori* infection
7. Genetic factors.

However, excessive consumption of alcohol or coffee, and cholelithiasis are not risk factors for pancreatic cancer. A combination of mutations in *K-RAS* gene and *CDKN2A* gene have been found in almost all cases of cancer of the pancreas.

MORPHOLOGIC FEATURES. The most common location of pancreatic cancer is the head of pancreas (70%), followed in decreasing frequency, by the body and the tail of pancreas (**Web Image 21.49**).

G/A Carcinoma of the head of pancreas is generally small, homogeneous, poorly-defined, grey-white mass without any sharp demarcation between the tumour and the surrounding pancreatic parenchyma. The tumour of the head extends into the ampulla of Vater, common bile duct and duodenum, producing obstructive biliary symptoms and jaundice early in the course of illness.

M/E Most pancreatic carcinomas arise from the ductal epithelium which normally comprises less than 4% of total pancreatic cells, whereas carcinoma of the acini constitutes less than 1% of pancreatic cancers. The following histologic patterns of pancreatic carcinoma are seen:

1. *Well-differentiated adenocarcinoma*
2. *Adenoacanthoma*
3. *Tumour giant cell formation*
4. *Acinar cell carcinoma*.

CLINICAL FEATURES. Clinical symptoms depend upon the site of origin of the tumour. Generally, the following features are present:

1. *Obstructive jaundice.* more often and early in the course of disease in cases with carcinoma head of the pancreas (80%), and less often in cancer of the body and tail of the pancreas.
2. *Other features.* These include: abdominal pain, anorexia, weight loss, cachexia, weakness and malaise, nausea and vomiting, and migratory thrombophlebitis (Trousseau's syndrome), GI bleeding and splenomegaly.

The prognosis of pancreatic cancer is dismal: median survival is 6 months from the time of diagnosis. Approximately 10% patients survive 1 year and the 5-year survival is poor 1 to 2%.

◆ SELF ASSESSMENT

1. **All are features of extrahepatic biliary atresia (EHBA) except:**

A. Ductular proliferation	B. Giant cells
C. Cholestasis	D. Increased hepatic copper
2. **Centrilobular necrosis is seen in all except:**

A. Yellow fever	B. Ischaemia
C. Chloroform	D. Carbon tetrachloride
3. **The form of bilirubin which remains detectable in serum for sufficient time after recovery from the disease is:**

A. Biliverdin	B. Unconjugated bilirubin
C. Unbound conjugated bilirubin	D. Delta bilirubin

4. **Acute viral hepatitis by the following hepatotropic virus is characterised by fatty change in liver:**
 - A. HAV
 - B. HBV
 - C. HCV
 - D. HDV
5. **Extrahepatic cholestasis can be distinguished from intrahepatic cholestasis by the following tests in the former:**
 - A. Bilirubinuria
 - B. Hypoprothrombinaemia showing improvement following parental administration of vitamin K
 - C. Elevated serum alkaline phosphatase
 - D. Elevated serum bile acids
6. **The following conditions have unconjugated hyperbilirubinaemia except:**
 - A. Dubin-Johnson syndrome
 - B. Crigler-Najjar syndrome
 - C. Jaundice of prematurity
 - D. Gilbert syndrome
7. **Kernicterus often develops in the following type of hereditary hyperbilirubinaemia:**
 - A. Gilbert syndrome
 - B. Crigler-Najjar syndrome, type I
 - C. Dubin-Johnson syndrome
 - D. Rotor syndrome
8. **Reye's syndrome is characterised by the following features except:**
 - A. It is a form of hereditary hyperbilirubinaemia
 - B. There is microvesicular fatty change in hepatocytes
 - C. Patients have a rapidly downhill course
 - D. There is decreased activity of mitochondrial enzymes in the liver
9. **Hepatic encephalopathy is due to:**
 - A. Hypoxic damage from ischaemia
 - B. Toxic damage from ammonia
 - C. Thromboembolic phenomena
 - D. Hepatopulmonary syndrome
10. **Some etiologic factors implicated in Budd-Chiari syndrome are as under except:**
 - A. Pulmonary embolism
 - B. Hepatocellular carcinoma
 - C. Polycythaemia vera
 - D. Pregnancy
11. **Councilman bodies in viral hepatitis are a form of apoptosis commonly at the following site:**
 - A. Submassive
 - B. Centrilobular
 - C. Midzonal
 - D. Periportal
12. **The following hepatotropic virus is a DNA virus:**
 - A. HAV
 - B. HBV
 - C. HCV
 - D. HEV
13. **Chronic carrier state of the following hepatotropic virus infection is observed in the following except:**
 - A. HAV
 - B. HBV
 - C. HCV
 - D. HDV
14. **In hepatitis A, life-long protective immunity against reinfection is given by the following class of antibody:**
 - A. IgA
 - B. IgE
 - C. IgG
 - D. IgM
15. **Hepatitis B surface antigen (HBsAg) is present as the following structures except:**
 - A. Viral spheres
 - B. Viral tubules
 - C. Surface envelope of Dane particle
 - D. Inner core of Dane particle

16. HBsAg can be demonstrated at the following sites *except*:
- Serum of HBV-infected patient
 - Carrier state of HBV
 - Hepatocyte cell membrane in acute stage of illness
 - Hepatocyte cell membrane in chronic hepatitis B
17. In chronic hepatitis B and carrier state of HBV infection, the following antigen is detected on the nuclei of infected hepatocytes:
- HBsAg
 - HBeAg
 - HBcAg
 - HBV-DNA
18. In an HDV-infected individual, HDV antigen is detected at the following sites *except*:
- Serum in acute illness
 - Serum in carrier state
 - Hepatocyte cell membrane
 - Hepatocyte nuclei
19. Vast majority (more than 90%) of cases of post-transfusion hepatitis are caused by:
- HBV
 - HCV
 - HDV
 - HGV
20. The most progressive form of chronic hepatitis is caused by:
- Hepatitis A
 - Hepatitis B
 - Hepatitis C
 - Hepatitis D
21. The following genetic component of HBV is considered responsible for its carcinogenic influence:
- HBsAg
 - HBeAg
 - HBcAg
 - HBxAg
22. In amoebic liver abscess, trophozoites of *E.histolytica* are best demonstrated at:
- Necrotic centre of abscess
 - Margin of abscess with viable liver tissue
 - Granulation tissue in the abscess wall
 - Fibrous wall of the abscess
23. The most common site for hydatid cyst is:
- Liver
 - Lungs
 - Spleen
 - Brain
24. Micronodular cirrhosis includes the following etiologic types *except*:
- Laennec's cirrhosis
 - Nutritional cirrhosis
 - Post-necrotic cirrhosis
 - Portal cirrhosis
25. The major hepatotoxic effect of ethanol is exerted by:
- Direct hepatotoxicity of ethanol
 - Free radical injury
 - Hepatotoxicity of acetaldehyde
 - Immunologic mechanisms
26. Mallory's hyalin is seen in the following conditions *except*:
- Alcoholic hepatitis
 - Hepatocellular carcinoma
 - Post-necrotic cirrhosis
 - Primary biliary cirrhosis
27. Primary biliary cirrhosis has the following features *except*:
- There is elevated cholesterol level in blood
 - It has familial occurrence
 - The condition is more common in men
 - The disease has autoimmune origin
28. Patients of following type of cirrhosis more often may develop hepatocellular carcinoma as a late complication:
- Biliary cirrhosis
 - Haemochromatosis-induced cirrhosis
 - Cirrhosis in α 1 antitrypsin deficiency
 - Cardiac cirrhosis

- 544 29. Biochemical abnormalities in Wilson's disease include the following *except*:
- Increased serum ceruloplasmin
 - Increased urinary copper excretion
 - Increased hepatic copper
 - Serum copper low-to-normal-to-high
30. Intrahepatic causes of portal hypertension include the following *except*:
- Cirrhosis
 - Budd-Chiari syndrome
 - Portal vein thrombosis
 - Metastatic tumours
31. In developed countries the major risk factor in the pathogenesis of hepatocellular carcinoma is:
- Long-standing HBV infection
 - Long-standing HCV infection
 - Alcoholic cirrhosis
 - Aflatoxin B1
32. Risk factors implicated in the etiology of cholesterol gallstones include the following *except*:
- Family history
 - Obesity
 - Haemolytic anaemia
 - Oral contraceptives
33. The following type of gallstones are generally unassociated with changes in the gallbladder wall:
- Cholesterol
 - Mixed
 - Combined
 - Pigment
34. The most common site for cancer of the gallbladder is:
- Fundus
 - Body
 - Neck
 - Cystic duct
35. Pancreatic carcinoma of the following site more often produces obstructive jaundice:
- Head
 - Body
 - Tail
 - Uncinate process
36. Which of the following hepatotropic viruses is *not* transmitted by transfusion?
- HAV
 - HBV
 - HCV
 - HGV
37. Which of the following hepatotropic viruses does not cause chronic hepatitis?
- HBV
 - HCV
 - HDV
 - HEV
38. All are true for fibrolamellar HCC *except*:
- Found in young
 - Not preceded by cirrhosis
 - Encapsulated
 - Worse prognosis than classic HCC

KEY

- | | | | |
|--------|--------|--------|--------|
| 1 = D | 2 = B | 3 = D | 4 = C |
| 5 = B | 6 = A | 7 = B | 8 = A |
| 9 = B | 10 = A | 11 = C | 12 = B |
| 13 = A | 14 = C | 15 = D | 16 = C |
| 17 = C | 18 = C | 19 = B | 20 = C |
| 21 = D | 22 = B | 23 = A | 24 = C |
| 25 = C | 26 = C | 27 = C | 28 = B |
| 29 = A | 30 = C | 31 = C | 32 = C |
| 33 = D | 34 = A | 35 = A | 36 = C |
| 37 = D | 38 = D | | |



The Kidney and Lower Urinary Tract

□ NORMAL STRUCTURE (p. 649)

ANATOMY. The kidneys are bean-shaped paired organs, each weighing about 150 gm in the adult male and about 135 gm in the adult female. The hilum of the kidney is situated at the midpoint on the medial aspect where the artery, vein, lymphatics and ureter are located.

Cut surface of the kidney shows 3 main structures: well-demarcated *peripheral cortex*, *inner medulla* and the innermost *renal pelvis* (**Web Image 22.1**):

- ◆ The **renal cortex** forms the outer rim of the kidney and is about 1 cm in thickness. It contains all the glomeruli and about 85% of the nephron tubules. Remaining 15% nephrons consisting of collecting tubules, collecting ducts, loops of Henle and vasa recta send their loops into the medulla, and are therefore called juxtamedullary nephrons. This latter part of the cortex forms faint striations called *medullary rays*, a misnomer since these structures are located in the cortex but are destined for medulla.

- ◆ The **renal medulla** is composed of 8-18 cone-shaped renal pyramids. The base of a renal pyramid lies adjacent to the outer cortex and forms the cortico-medullary junction, while the apex of each called the *renal papilla* contains the opening of each renal pyramid for passage of urine collected from collecting ducts and goes down into minor calyces.

- ◆ The **renal pelvis** is the funnel-shaped collection area of the urine for drainage into the ureter. The minor calyces (8-18 in number in a normal kidney) collect urine from renal papillae and drain into major calyces (2-3 in a normal kidney).

HISTOLOGY. The parenchyma of each kidney is composed of approximately one million microstructures called nephrons. A nephron, in turn, consists of 5 major parts, each having a functional role in the formation of urine: the glomerular capsule (glomerulus and Bowman's capsule), the proximal convoluted tubule (PCT), the loop of Henle, the distal convoluted tubule (DCT), and the collecting ducts. From point of view of diseases of the kidneys, 4 components of renal parenchyma require further elaboration:

1. **Renal vasculature.** Each kidney is supplied with blood by a main *renal artery*. It usually divides into *anterior and posterior divisions* at the hilum. The anterior and posterior divisions divide into *segmental branches* from which *interlobar arteries* arise which course between the lobes. Along their course, they give off the *arcuate arteries* which arch between the cortex and medulla. The arcuate arteries, in turn, give off *interlobular arteries* (**Web Image 22.2**). It is from the interlobular arteries that the *afferent arterioles* take their origin. From the glomerulus emerge the *efferent arterioles*. Up to this stage, the arteries and arterioles are end-vessels.

The juxtamedullary glomeruli, however, give off a series of parallel vessels called *vasa recta*. These drain into *arcuate veins* and then into the veins that accompany the corresponding arteries and finally through a single renal vein into the inferior vena cava (**Web Image 22.3**).

2. **Glomerulus.** The glomerulus consists of invagination of the blind end of the proximal tubule and contains a *capillary tuft* fed by the afferent arteriole and drained by efferent arteriole. The capillary tuft is covered by visceral epithelial cells (podocytes) which are continuous with those of the parietal

546 epithelium at the *vascular pole*. The visceral and parietal epithelial cells are separated by the urinary space or *Bowman's space*, into which glomerular filtrate passes (**Web Image 22.4**).

Subdivisions of capillaries derived from the afferent arterioles result in the formation of *lobules* (up to 8 in number) within a glomerulus. Each lobule of a glomerular tuft consists of a centrilobular supporting stalk composed of mesangium containing *mesangial cells* and *mesangial matrix*.

The major *function* of glomerulus is complex filtration from the capillaries to the urinary space. Glomerular filtrate is quite similar in composition to plasma but lacks proteins and cells. Normally, glomerular filtration rate (GFR) is about 120 ml/minute. The barrier to glomerular filtration consists of the following 3 components (**Web Image 22.5**):

- i) Fenestrated endothelial cells lining the capillary loops.
- ii) Glomerular basement membrane (GBM) on which the endothelial cells rest. It further consists of 3 layers—the central lamina densa, bounded by lamina rara interna on endothelial side of the capillary and lamina rara externa on visceral epithelial side of the capillary.
- iii) Filtration slit pores between the foot processes of the visceral epithelial cells (podocytes) external to GBM.

Juxtaglomerular apparatus. The juxtaglomerular apparatus (JGA) is situated at the vascular pole of the glomerulus and is made up of 3 parts (**Web Image 22.4**):

- i) The *juxtaglomerular*
- ii) The *macula densa*
- iii) The *lacis cells* or *non-granular cells*

The JGA is intimately concerned with sodium metabolism and is the principal source of renin production.

3. Tubules. The tubules of the kidney account for the greatest amount of the renal parenchyma. The structure of renal tubular epithelium varies in different parts of the nephron and is correlated with the functional capacity of that part of the tubule (see Web Image 22.3).

i) *Proximal convoluted tubule (PCT)*, ii) *Loop of Henle*, iii) *Distal convoluted tubule (DCT)* and iv) *Collecting ducts*.

4. Interstitium. In health, the renal cortical interstitium is scanty and consists of a small number of fibroblast-like cells. But the medullary interstitium is more plentiful and contains stellate interstitial cells which are considered to produce an anti-hypertensive agent and are involved in the metabolism of prostaglandins.

□ RENAL FUNCTION TESTS (p. 652)

In general, the kidney performs the following vital functions in the body:

- 1) *Excretion of waste products*, 2) *Regulation of acid-base balance*, 3) *Regulation of salt-water balance*, and 4) *Formation of renin and erythropoietin*.

Renal function tests are broadly divided into 4 groups (**Web Table 22.1**):

- 1) Urine analysis, 2) Concentration and dilution tests, 3) Blood chemistry and 4) Renal clearance tests.

In addition, renal biopsy is performed to confirm the diagnosis of renal disease. Renal biopsy is ideally fixed in alcoholic Bouin's solution and examined by routine morphology combined with special stains and further studies as under:

1. *Periodic acid-Schiff* stain for highlighting glomerular basement membrane.
2. *Silver impregnation* to outline the glomerular and tubular basement membrane.
3. *Immunofluorescence* to localise the antigens, complements and immunoglobulins.
4. *Electron microscopy* to see the ultrastructure of glomerular changes.

1. URINE ANALYSIS. The simplest diagnostic tests for renal function is the physical, chemical, bacteriologic and microscopic examination of the urine.

2. CONCENTRATION AND DILUTION TESTS. Concentration and dilution tests are designed to evaluate functional capacity of the renal tubules. The ability of the nephron to concentrate or dilute urine is dependent upon both functional activity of the tubular cells in the renal medulla and the presence of antidiuretic hormone (ADH).

Traditionally, urinary concentration is determined by specific gravity of the urine (normal range 1.003 to 1.030, average 1.018) which in cases of tubular disease remains constant at approximately 1.010. The tubular disease can be diagnosed in its early stage by *water deprivation* (concentration) or *water excess* (dilution) tests.

3. BLOOD CHEMISTRY. Impairment of renal function results in elevation of end-products of protein metabolism. This includes increased accumulation of certain substances in the blood, chiefly urea (normal range 20-40 mg/dl), blood urea nitrogen (BUN) (normal range 10-20 mg/dl) and creatinine (normal range 0.6-1.2 mg/dl). An increase of these end-products in the blood is called *azotaemia*.

High levels of creatinine are associated with high levels of β 2-microglobulin in the serum as well as urine, a low-molecular weight protein filtered excessively in the urine due to glomerular disease or due to increased production by the liver.

4. RENAL CLEARANCE TESTS. A clearance test is employed to assess the rate of glomerular filtration and the renal blood flow. The rate of this filtration can be measured by determining the excretion rate of a substance which is filtered through the glomerulus but subsequently is neither reabsorbed nor secreted by the tubules. The glomerular filtration rate (normal 120 ml/minute in an average adult) is usually equal to clearance of that substance.

The substances which are used for clearance tests include inulin, mannitol, creatinine and urea.

□ PATHOPHYSIOLOGY OF RENAL DISEASE: RENAL FAILURE (p. 653)

Traditionally, diseases of the kidneys are divided into 4 major groups according to the predominant involvement of corresponding morphologic components:

1. *Glomerular diseases:* These are most often immunologically-mediated and may be acute or chronic.
2. *Tubular diseases:* These are more likely to be caused by toxic or infectious agents and are often acute.
3. *Interstitial diseases:* These are likewise commonly due to toxic or infectious agents and quite often involve interstitium as well as tubules (tubulo-interstitial diseases).
4. *Vascular diseases:* These include changes in the nephron as a consequence of increased intra-glomerular pressure such as in hypertension or impaired blood flow.

Regardless of cause, renal disease usually results in the evolution of one of the two major pathological syndromes: *acute renal failure* and *chronic renal failure*. The term '*azotaemia*' is used for biochemical abnormality characterised by elevation of the blood urea nitrogen (BUN) and creatinine levels, while '*uraemia*' is defined as association of these biochemical abnormalities with clinical signs and symptoms.

Acute Renal Failure (ARF) (p. 654)

Acute renal failure (ARF) is a syndrome characterised by rapid onset of renal dysfunction, chiefly oliguria or anuria, and sudden increase in metabolic waste-products (urea and creatinine) in the blood with consequent development of uraemia.

548 ETIOPATHOGENESIS. The causes of ARF may be classified as pre-renal, intra-renal and post-renal in nature.

1. Pre-renal causes. Pre-renal diseases are those which cause sudden decrease in blood flow to the nephron. Renal ischaemia ultimately results in functional disorders or depression of GFR, or both. These causes include inadequate cardiac output and hypovolaemia or vascular disease causing reduced perfusion of the kidneys.

2. Intra-renal causes. Intra-renal disease is characterised by disease of renal tissue itself. These include vascular disease of the arteries and arterioles within the kidney, diseases of glomeruli, acute tubular necrosis due to ischaemia, or the effect of a nephrotoxin, acute tubulointerstitial nephritis and pyelonephritis.

3. Post-renal causes. Post-renal disease is characteristically caused by obstruction to the flow of urine anywhere along the renal tract distal to the opening of the collecting ducts. This may be caused by a mass within the lumen or from wall of the tract, or from external compression anywhere along the lower urinary tract—ureter, bladder neck or urethra.

CLINICAL FEATURES. One of the following three major patterns usually emerge:

1. Syndrome of acute nephritis. This is most frequently associated with acute post-streptococcal glomerulonephritis and rapidly progressive glomerulonephritis. The characteristic features are: mild proteinuria, haematuria, oedema and mild hypertension.

2. Syndrome accompanying tubular pathology. When the ARF is caused by destruction of the tubular cells of the nephron as occurs in acute tubular necrosis, the disease typically progresses through 3 characteristic stages: *i) Oliguric phase, ii) Diuretic phase and iii) Phase of recovery.*

3. Pre-renal syndrome. The ARF occurring secondary to disorders in which neither the glomerulus nor the tubules are damaged, results in pre-renal syndrome. Typically, this pattern is seen in marginal ischaemia caused by renal arterial obstruction, hypovolaemia, hypotension or cardiac insufficiency. Due to depressed renal blood flow, there is decrease in GFR causing oliguria, azotaemia (elevation of BUN and creatinine) and possible fluid retention and oedema.

Chronic Renal Failure (CRF) (p. 654)

Chronic renal failure is a syndrome characterised by progressive and irreversible deterioration of renal function due to slow destruction of renal parenchyma, eventually terminating in death when sufficient number of nephrons have been damaged.

ETIOPATHOGENESIS. All chronic nephropathies can lead to CRF. The diseases leading to CRF can generally be classified into two major groups:

1. Diseases causing glomerular pathology. A number of glomerular diseases associated with CRF have their pathogenesis in immune mechanisms. Glomerular destruction results in changes in filtration process and leads to development of the nephrotic syndrome characterised by proteinuria, hypoalbuminaemia and oedema.

i) Primary glomerular pathology: The major cause of CRF is chronic glomerulonephritis, usually initiated by various types of *glomerulonephritis*.

ii) Systemic glomerular pathology: Certain conditions originate outside the renal system but induce changes in the nephrons secondarily. Major examples of this type are systemic lupus erythematosus, serum sickness nephritis and diabetic nephropathy.

2. Diseases causing tubulointerstitial pathology. Damage to tubulointerstitial tissues results in alterations in reabsorption and secretion of important constituents leading to excretion of large volumes of dilute

urine. Tubulointerstitial diseases can be categorised according to initiating etiology into 4 groups: vascular, infectious, toxic and obstructive.

Regardless of the initiating cause, CRF evolves progressively through 4 stages:

- 1) Decreased renal reserve, 2) Renal insufficiency, 3) Renal failure and 4) End-stage kidney.

CLINICAL FEATURES. Clinical manifestations of full-blown CRF culminating in uraemic syndrome are described under 2 main headings:

A. Primary uraemic (renal) manifestations. Primary symptoms of uraemia develop when there is slow and progressive deterioration of renal function. The resulting imbalances cause the following manifestations:

1. Metabolic acidosis.
2. Hyperkalaemia.
3. Sodium and water imbalance.
4. Hyperuricaemia.
5. Azotaemia.

B. Secondary uraemic (extra-renal) manifestations.

1. Anaemia.
2. Integumentary system.
3. Cardiovascular system.
4. Respiratory system.
5. Digestive system.
6. Skeletal system.
 - i) *Osteomalacia*
 - ii) *Osteitis fibrosa*

□ CONGENITAL MALFORMATIONS (p. 656)

Approximately 10% of all persons are born with potentially significant malformations of the urinary system. These range in severity from minor anomalies which may not produce clinical manifestations to major anomalies which are incompatible with extrauterine life. About half of all patients with malformations of the kidneys have coexistent anomalies either elsewhere in the urinary tract or in other organs.

Malformations of the kidneys are classified into 3 broad groups:

I. Abnormalities in amount of renal tissue. These include: anomalies with deficient renal parenchyma (e.g. unilateral or bilateral renal hypoplasia) or with excess renal tissue (e.g. renomegaly, supernumerary kidneys).

II. Anomalies of position, form and orientation. These are: renal ectopia (pelvic kidney), renal fusion (horseshoe kidney) and persistent foetal lobation.

III. Anomalies of differentiation. This group consists of the more important and common morphologic forms covered under the heading of '*cystic diseases of the kidney*' described in detail below.

□ CYSTIC DISEASES OF KIDNEY (p. 656)

Cystic lesions of the kidney may be *congenital or acquired, non-neoplastic or neoplastic*. Majority of these lesions are congenital non-neoplastic. Cystic lesions in the kidney may occur at any age, extending from foetal life (detected on ultrasonography) to old age.

A simple classification including all cystic lesions of the kidney is given in **Web Table 22.2** and **Web Image 22.6**.

I. Multicystic Renal Dysplasia (p. 657)

The term 'multicystic renal dysplasia' or Potter type II is used for disorganised metanephrogenic differentiation with persistence of structures in the kidney which are not represented in normal nephrogenesis. Renal dysplasia is the most common form of cystic renal disease in the newborn and infants.

MORPHOLOGIC FEATURES. Renal dysplasia may be unilateral or bilateral.

550 G/A The dysplastic kidney is almost always cystic. The kidney or its affected part is replaced by disorderly mass of multiple cysts resembling a bunch of grapes. Normal renal parenchyma is almost totally obscured by the mass while calyces and pelvis may not be recognised. The ureter is invariably abnormal, being either absent or atretic.

M/E The characteristic feature is the presence of undifferentiated mesenchyme that contains smooth muscle, cartilage and immature collecting ducts. The cysts in the mass represent dilated tubules lined by flattened epithelium which are surrounded by concentric layers of connective tissue (**Web Image 22.7**). Glomeruli and tubules are scanty, primitive or absent.

CLINICAL FEATURES. Unilateral renal dysplasia is frequently discovered in newborn or infants as a flank mass. Often, renal dysplasia is associated with other congenital malformations and syndromes such as ventricular septal defect, tracheo-esophageal fistula, lumbosacral meningocele and Down's syndrome.

II. Polycystic Kidney Disease (p. 657)

Polycystic disease of the kidney (PKD) is a disorder in which major portion of the renal parenchyma is converted into cysts of varying size. The disease occurs in two forms:

A. ADULT POLYCYSTIC KIDNEY DISEASE (p. 657)

Adult (autosomal dominant) polycystic kidney disease (ADPKD) is relatively common (incidence 1:400 to 1: 1:1000) and is the cause of end-stage renal failure in approximately 4% of haemodialysis patients. The pattern of inheritance is *autosomal dominant* with mutation in *PKD* gene: mutation in *PKD-1* gene located on chromosome 16 in over 85% cases (ADPKD-1) while remainder 15% cases have mutation in *PKD-2* gene located on chromosome 4 (ADPKD-2). Though the kidneys are abnormal at birth, renal function is retained, and symptoms appear in adult life, mostly between the age of 30 and 50 years.

G/A Kidneys in ADPKD are always bilaterally enlarged, usually symmetrically, heavy (weighing up to 4 kg) and give it a lobulated appearance on external surface due to underlying cysts. The cut surface shows cysts throughout the renal parenchyma varying in size from tiny cysts to 4-5 cm in diameter (**Web Image 22.8,A**). The renal pelvis and calyces are present but are greatly distorted by the cysts and may contain concretions (**Web Image 22.9**). The cysts, however, do not communicate with the pelvis of the kidney—a feature that helps to distinguish polycystic kidney from hydronephrosis of the kidney.

M/E The cysts arise from all parts of nephron. It is possible to find some cysts containing recognisable glomerular tufts reflecting their origin from Bowman's capsule, while others have epithelial lining like that of distal or proximal tubules or collecting ducts. With advancement of age of the patient, acquired lesions such as pyelonephritis, nephrosclerosis, fibrosis and chronic inflammation are seen with increasingly frequency.

CLINICAL FEATURES. The condition may become clinically apparent at any age but most commonly manifests in 3rd to 5th decades of life. The presenting complaints are haematuria or passage of blood clots in urine, renal colic, hypertension, urinary tract infections and progressive CRF with polyuria and proteinuria.

ADPKD is considered a systemic disease. About a third of patients with ADPKD have cysts of the liver.

B. INFANTILE POLYCYSTIC KIDNEY DISEASE (p. 658)

The infantile (autosomal recessive) form of polycystic kidney disease (ARPKD) is distinct from the adult form and is less common (incidence

1:20,000 births). It is transmitted as an *autosomal recessive* trait and the family history of similar disease is usually not present. The condition occurs due to a mutation in chromosome 6. It is invariably bilateral. The age at presentation may be perinatal, neonatal, infantile or juvenile, but frequently serious manifestations are present at birth and result in death from renal failure in early childhood.

G/A The kidneys are bilaterally enlarged with smooth external surface and retained normal reniform shape. Cut surface reveals small, fusiform or cylindrical cysts radiating from the medulla and extend radially to the outer cortex. This gives the sectioned surface of the kidney *sponge-like appearance* (**Web Image 22.8,B**). Pelvis, calyces and ureters are normal.

M/E The total number of nephrons is normal. Since the cysts are formed from dilatation of collecting tubules, all the collecting tubules show cylindrical or saccular dilatations and are lined by cuboidal to low columnar epithelium. Many of the glomeruli are also cystically dilated.

CLINICAL FEATURES. The clinical manifestations depend on age of the child. In severe form, the gross bilateral cystic renal enlargement may interfere with delivery. In infancy, renal failure may manifest early. Almost all cases of infantile polycystic kidney disease have associated multiple epithelium-lined cysts in the liver or proliferation of portal bile ductules.

The contrasting features of the two main forms of the polycystic kidney disease are presented in **Web Table 22.3**.

III. Medullary Cystic Disease (p. 658)

Cystic disease of the renal medulla has two main types:

A. MEDULLARY SPONGE KIDNEY (p. 658)

Medullary sponge kidney consists of multiple cystic dilatations of the papillary ducts in the medulla. It has an autosomal dominant transmission. The condition occurs in adults and may be recognised as an incidental radiographic finding in asymptomatic cases, or the patients may complain of colicky flank pain, dysuria, haematuria and passage of sandy material in the urine.

G/A The kidneys may be enlarged, normal or shrunken in size depending upon the extent of secondary pyelonephritis. On cut surface, the characteristic feature is the presence of several, small (less than 0.5 cm diameter), cystically dilated papillary ducts, which may contain spherical calculi.

M/E The cysts are lined by tall columnar, cuboidal, transitional or squamous epithelium. Renal cortex may show secondary pyelonephritis but cortical cysts are never a component of medullary sponge kidney.

B. NEPHRONOPHTHIASIS-MEDULLARY CYSTIC DISEASE COMPLEX (p. 659)

This form of medullary cystic disease, also called *juvenile nephronophthiasis* or *uraemic sponge kidney*, is a progressive renal disease. It is classified into infantile, juvenile and adolescent type depending upon the age at presentation, juvenile form being the most common. The condition has an autosomal recessive inheritance. Familial occurrence is common.

G/A The kidneys are moderately reduced in size and granular and have narrow cortices. Cut surface reveals minute cysts, majority of which are present at the cortico-medullary junction.

M/E The cysts are lined by flattened or cuboidal epithelium. There is widespread nonspecific chronic inflammatory infiltrate and interstitial fibrosis. Many glomeruli are hyalinised but tubular atrophy is more pronounced.

552 IV. Simple Renal Cysts (p. 659)

Simple renal cysts are a very common postmortem finding. They are seen in about half of all persons above the age of 50 years. Since these cysts are rare in infants and children, they appear to be acquired rather than congenital lesions. The association between simple cysts and hypertension is common.

G/A Simple renal cysts are usually solitary but may be multiple. They are commonly located in the cortex. Their size varies from a few millimeters to 10 cm in diameter.

M/E The lining of the cyst is by flattened epithelium. The cyst wall contains variable amount of collagenised fibrous tissue which may occasionally have deposits of haemosiderin or calcium salts.

V. Acquired Renal Cysts (p. 659)

1. Patients with end-stage renal disease on prolonged dialysis (dialysis-associated cystic disease).
2. Hydatid (echinococcal) cyst.
3. Tuberculosis of the kidney.
4. Cystic degeneration in carcinoma of kidney.
5. Traumatic intrarenal haematoma.
6. Drug-induced cystic disease in experimental animals.

VI. Pararenal Cysts (p. 659)

1. Pyelocalyceal cysts
2. Hilar lymphangiectatic cysts
3. Retroperitoneal cysts
4. Perinephric pseudocysts from trauma.

□ GLOMERULAR DISEASES (p. 660)

DEFINITION AND CLASSIFICATION (p. 660)

It is convenient to classify glomerular diseases into 2 broad groups:

- I. *Primary glomerulonephritis* in which the glomeruli are the predominant site of involvement.
- II. *Secondary glomerular diseases* include certain systemic and hereditary diseases which secondarily affect the glomeruli.

Many classifications of different types of glomerulonephritis have been described, but most widely accepted classification is based on clinical presentation and pathologic changes in the glomeruli given in **Web Table 22.4**.

CLINICAL MANIFESTATIONS (p. 660)

The clinical presentation of glomerular disease is quite variable but in general four features—proteinuria, haematuria, hypertension and disturbed excretory function, are present in varying combinations depending upon the underlying condition. A firm diagnosis, however, can be established by examination of renal biopsy under light, electron and immunofluorescence microscopy.

A number of clinical syndromes are recognised in glomerular diseases. The following are six major glomerular syndromes commonly found in different glomerular diseases:

I. ACUTE NEPHRITIC SYNDROME. This is the acute onset of haematuria, proteinuria, hypertension, oedema and oliguria following an infective illness about 10 to 20 days earlier.

The underlying causes of acute nephritic syndrome may be primary glomerulonephritic diseases (classically acute glomerulonephritis and rapidly progressive glomerulonephritis) or certain systemic diseases (**Web Table 22.5**).

II. NEPHROTIC SYNDROME Nephrotic syndrome is a constellation of features in different diseases having varying pathogenesis; it is characterised by findings of massive proteinuria, hypoalbuminaemia, oedema, hyperlipidaemia, lipiduria, and hypercoagulability.

The causes of nephrotic syndrome are diverse and are listed in **Web Table 22.6**. It must be mentioned here that:

- in *children*, primary glomerulonephritis is the cause in majority of cases of the nephrotic syndrome; most frequent is *lipoid nephrosis* (65%); and
- in *adults*, on the other hand, systemic diseases (diabetes, amyloidosis and SLE) are more frequent causes of nephrotic syndrome. The most common primary glomerular disease in adults is *membranous glomerulonephritis* (40%).

Features of nephritic and nephroic syndromes have been contrasted in **Web Table 22.7**.

III. ACUTE RENAL FAILURE. Acute renal failure (ARF) is characterised by rapid decline in renal function. ARF has many causes including glomerular disease, principally rapidly progressive GN and acute diffuse proliferative GN.

IV. CHRONIC RENAL FAILURE. These cases have advanced renal impairment progressing over years and is detected by significant proteinuria, haematuria, hypertension and azotaemia. Such patients generally have small contracted kidneys due to chronic glomerulonephritis.

V. ASYMPTOMATIC PROTEINURIA. Presence of proteinuria unexpectedly in a patient may be unrelated to renal disease (e.g. exercise-induced, extreme lordosis and orthostatic proteinuria), or may indicate an underlying mild glomerulonephritis. Association of asymptomatic haematuria, hypertension or impaired renal function with asymptomatic proteinuria should raise strong suspicion of underlying glomerulonephritis.

VI. ASYMPTOMATIC HAEMATURIA. Asymptomatic microscopic haematuria is common in children and young adolescents and has many diverse causes such as diseases of the glomerulus, renal interstitium, calyceal system, ureter, bladder, prostate, urethra, and underlying bleeding disorder, congenital abnormalities of the kidneys or neoplasia. Glomerular haematuria is indicated by the presence of red blood cells, red cell casts and haemoglobin in the urine. Glomerular haematuria is frequently associated with asymptomatic proteinuria.

PATHOGENESIS OF GLOMERULAR INJURY (p. 662)

Most forms of primary GN and many of the secondary glomerular diseases in human beings have immunologic pathogenesis. This view is largely based on immunofluorescence studies of GN in humans which have revealed glomerular deposits of immunoglobulins and complement in patterns that closely resemble those of experimental models. The consequences of injury at different sites within the glomerulus in various glomerular diseases can be assessed when compared with the normal physiologic role of the main cells involved i.e. *endothelial, mesangial, visceral epithelial, and parietal epithelial cells* as well as of the *GBM* as summed up in **Web Table 22.8**.

Immunologic mechanisms underlying glomerular injury are primarily *antibody-mediated*. Others are *cell-mediated immune reactions*, a few secondary mechanisms and some non-immunologic mechanisms (**Web Table 22.9**).

I. IMMUNOLOGIC MECHANISMS (p. 662)

A. Antibody-Mediated Glomerular Injury (p. 662)

1. IMMUNE COMPLEX DISEASE. Majority of cases of glomerular disease result from deposits of immune complexes (antigen-antibody complexes).

554 The immune complexes are represented by *irregular or granular glomerular deposits* of immunoglobulins (IgG, IgM and IgA) and complement (mainly C3). Based on the experimental models and studies in human beings, the following 3 patterns of glomerular deposits of immune complexes in various glomerular diseases have been observed as illustrated in **Web Image 22.10**:

- i) *Exclusive mesangial deposits* are characterised by very mild form of glomerular disease.
- ii) *Extensive subendothelial deposits* along the GBM are accompanied by severe hypercellular sclerosing glomerular lesions.
- iii) *Subepithelial deposits* are seen between the outer surface of the GBM and the podocytes.

Glomerular deposits are formed by one of the following two mechanisms:

i) Local immune complex deposits. Formation of glomerular deposits of immune complex *in situ* occurs as a result of combination of antibodies with autologous non-basement membrane antigens or nonglomerular antigens planted on glomeruli. Currently, this mechanism is considered responsible for most cases of immune complex GN.

ii) Circulating immune complex deposits. This mechanism used to be considered very important for glomerular injury but now it is believed that circulating immune complexes cause glomerular damage under certain circumstances only. These situations are: their presence in high concentrations for prolonged periods, or when they possess special properties that cause their binding to glomeruli. The antigens evoking antibody response may be endogenous (e.g. in SLE) or may be exogenous (e.g. Hepatitis B virus, *Treponema pallidum*, *Plasmodium falciparum* and various tumour antigens).

Immune complex GN is observed in the following human diseases:

- i) *Primary GN* e.g. acute diffuse proliferative GN, membranous GN, membranoproliferative GN, IgA nephropathy and some cases of rapidly progressive GN and focal GN.
- ii) *Systemic diseases* e.g. glomerular disease in SLE, malaria, syphilis, hepatitis, Henoch-Schonlein purpura and idiopathic mixed cryoglobulinaemia.

2. ANTI-GBM DISEASE. Less than 5% cases of human GN are associated with anti-GBM antibodies. The constituent of GBM acting as antigen appears to be a component of collagen IV of the basement membrane.

Anti-GBM disease is classically characterised by *interrupted linear deposits* of anti-GBM antibodies (mostly IgG; rarely IgA and IgM) and complement (mainly C3) along the glomerular basement membrane.

Anti-GBM disease is characteristically exemplified by glomerular injury in Goodpasture's syndrome in some cases of rapidly progressive GN.

3. ALTERNATE PATHWAY DISEASE. In alternate pathway activation, there is decreased serum C3 level, decreased serum levels of factor B and properdin, normal serum levels of C1, C2 and C4 but C3 and properdin are found deposited in the glomeruli without immunoglobulin deposits, reflecting activation of alternate pathway of complement. Such patients have circulating anti-complementary nephritic factor (C3NeF) which is an IgG antibody and acts as an autoantibody to the alternate C3 convertase, leading to persistent alternate pathway activation.

The deposits in alternate pathway disease are characteristically electron-dense under electron microscopy; glomerular lesions in such cases are referred to as *dense-deposit disease*.

Alternate pathway disease occurs in most cases of type II membranoproliferative GN, some patients of rapidly progressive GN, acute diffuse proliferative GN, IgA nephropathy and in SLE.

4. OTHER MECHANISMS OF ANTIBODY-MEDIATED INJURY. A few autoantibodies have been implicated in some patients of focal segmental glomerulosclerosis and few other types of GN.

i) Anti-neutrophil cytoplasmic antibodies (ANCA). About 40% cases of rapidly progressive GN are deficient in immunoglobulins in glomeruli (pauciimmune GN) and are positive for ANCA against neutrophil cytoplasmic antigens in their circulation. ANCA-mediated vasculitis is also seen in Wegener's granulomatosis and Churg-Strauss syndrome.

ii) Anti-endothelial cell antibodies (AECA). Autoantibodies against endothelial antigens have been detected in circulation in several inflammatory vasculitis and glomerulonephritis.

B. Cell-mediated Glomerular Injury (Delayed-type Hypersensitivity) (p. 664)

There is evidence to suggest that cell-mediated immune reactions may be involved in causing glomerular injury, particularly in cases with deficient immunoglobulins (e.g. in pauci-immune type glomerulonephritis in RPGN). Cytokines and other mediators released by activated T cells stimulate cytotoxicity, recruitment of more leucocytes and fibrogenesis.

C. Secondary Pathogenetic Mechanisms (Mediators of Immunologic Injury) (p. 664)

1. NEUTROPHILS. Neutrophils are conspicuous in certain forms of glomerular disease such as in acute diffuse proliferative GN, and may also be present in membranoproliferative GN and lupus nephritis. Neutrophils can mediate glomerular injury by activation of complement as well as by release of proteases, arachidonic acid metabolites and oxygen-derived free radicals.

2. MONONUCLEAR PHAGOCYTES. Many forms of human and experimental proliferative GN are associated with glomerular infiltration by monocytes and macrophages. Accumulation of mononuclear phagocytes is considered an important constituent of hypercellularity in these forms of GN aside from proliferation of mesangial and endothelial cells.

3. COMPLEMENT SYSTEM. Besides the components of complement which mediate glomerular injury via neutrophils, C5bC6789 (MAC, acronym for membrane attack complex, also called terminal complex) is capable of inducing damage to GBM directly.

4. PLATELETS. Platelet aggregation and release of mediators play a role in the evolution of some forms of GN.

5. MESANGIAL CELLS. There is evidence to suggest that mesangial cells present in the glomeruli may be stimulated to produce mediators of inflammation and take part in glomerular injury.

6. COAGULATION SYSTEM. Fibrinogen may leak into Bowman's space and act as stimulus for cell proliferation. Crescents usually transform into scar tissue under the influence of fibronectin which is regularly present in crescents in human glomerular disease.

II. NON-IMMUNOLOGIC MECHANISMS (p. 665)

Though most forms of GN are mediated by immunologic mechanisms, a few examples of glomerular injury by non-immunologic mechanisms are found:

- Metabolic glomerular injury* e.g. in diabetic nephropathy (due to hyperglycaemia), Fabry's disease (due to sulfatidosis).
- Haemodynamic glomerular injury* e.g. systemic hypertension, intraglomerular hypertension in FSGS.
- Deposition diseases* e.g. amyloidosis.
- Infectious diseases* e.g. HBV, HCV, HIV, *E. coli*-derived nephrotoxin.
- Drugs* e.g. minimal change disease due to NSAIDs.
- Inherited glomerular diseases* e.g. Alport's syndrome, nail-patella syndrome.

Classification of different forms of glomerular diseases is already presented in Web Table 22.4.

I. PRIMARY GLOMERULONEPHRITIS (p. 665)

Acute Glomerulonephritis (p. 665)

(**Synonyms:** *Acute Diffuse Proliferative GN, Diffuse Endocapillary GN*)

ACUTE POST-STREPTOCOCCAL GN

Acute post-streptococcal GN, though uncommon and sporadic in the Western countries, is a common form of GN in developing countries, mostly affecting children between 2 to 14 years of age but 10% cases are seen in adults above 40 years of age.

ETIOPATHOGENESIS. The relationship between streptococcal infection and this form of GN is now well established. Particularly nephritogenic are types 12,4,1 and Red Lake of group A β -haemolytic streptococci (compare the etiologic agent with that of RHD). The glomerular lesions appear to result from deposition of immune complexes in the glomeruli. The evidences cited in support are as under:

- i) *Epidemiological* evidence
- ii) The *latent period* between streptococcal infection and onset of clinical manifestations
- iii) Streptococcal infection may be identified by *culture* or may be inferred from elevated titres of *antibodies* against streptococcal antigens. These include the following:
 - ◆ anti-streptolysin O (ASO);
 - ◆ anti-deoxyribonuclease B (anti-DNAse B);
 - ◆ anti-streptokinase (ASKase);
 - ◆ anti-nicotinyl adenine dinucleotidase (anti-NADase); and
 - ◆ anti-hyaluronidase (AHase).
- iv) *hypocomplementaemia*.
- v) It has also been possible to identify antigenic component of streptococci which is cytoplasmic antigen, *endostreptosin*.

G/A The kidneys are symmetrically enlarged, weighing one and a half to twice the normal weight. The cortical as well as sectioned surface show petechial haemorrhages giving the characteristic appearance of flea-bitten kidney (**Web Image 22.11**).

M/E (Web Image 22.12): The features are as under:

- i) **Glomeruli**—The glomeruli are affected diffusely. They are enlarged and hypercellular. The diffuse hypercellularity of the tuft is due to proliferation of mesangial, endothelial and occasionally epithelial cells (*acute proliferative lesions*) as well as by infiltration of leucocytes, chiefly polymorphs and sometimes monocytes (*acute exudative lesion*).
- ii) **Tubules**—Tubular changes are not very striking. There may be swelling and hyaline droplets in tubular cells, and tubular lumina may contain red cell casts.
- iii) **Interstitialium**—There may be some degree of interstitial oedema and leucocytic infiltration.
- iv) **Vessels**—Changes in arteries and arterioles are seldom present in acute GN.

E/M Aside from confirming the light microscopic findings, demonstrate the characteristic electron-dense irregular deposits (*'humps'*) on the epithelial side of the GBM. These deposits represent the immune complexes (**Web Image 22.13**).

IF Reveals that the irregular deposits along the GBM consist principally of IgG and complement C3.

CLINICAL FEATURES. Typically, the patient is a young child, presenting with acute nephritic syndrome, having sudden and abrupt onset following an episode of sore throat or skin infection 1-2 weeks prior to the development of symptoms. The features include microscopic or intermittent haematuria, red cell casts, mild non-selective proteinuria (less than 3 gm per 24 hrs), hypertension, periorbital oedema and variably oliguria. In adults, the features are atypical and include sudden hypertension, oedema and azotaemia. Development of hypertension in either case is a poor prognostic sign.

Prognosis varies with the age of the patient. Children almost always (95%) recover completely with reversal of proliferative glomerular changes. Complications arise more often in adults and occasionally in children.

ACUTE NON-STREPTOCOCCAL GN

About one-third cases of acute GN are caused by organisms other than haemolytic streptococci. These include other bacteria (e.g. staphylococci, pneumococci, meningococci, *Salmonella* and *Pseudomonas*), viruses (e.g. hepatitis B virus, mumps, infectious mononucleosis and varicella), parasitic infections (e.g. malaria, toxoplasmosis and schistosomiasis) and syphilis.

Rapidly Progressive Glomerulonephritis

(Synonyms: RPGN, Crescentic GN, Extracapillary GN) (p. 665)

RPGN presents with an acute reduction in renal function resulting in acute renal failure in a few weeks or months. It is characterised by formation of 'crescents' (*crescentic GN*) outside the glomerular capillaries (*extracapillary GN*). 'Crescents' are formed from the proliferation of parietal epithelial cells lining Bowman's capsule with contribution from visceral epithelial cells and the invading mononuclear cells. The stimulus for crescent formation appears to be the presence of fibrin in the capsular space.

ETIOPATHOGENESIS. A number of primary glomerular and systemic diseases are characterised by formation of crescents. Based on the etiologic agents and pathogenetic mechanism, patients with RPGN are divided into 3 groups (**Web Table 22.10**):

Type I RPGN: Anti-GBM disease. A number of systemic diseases such as Goodpasture's syndrome, SLE, vasculitis, Wegener's granulomatosis, Henoch-Schonlein purpura and idiopathic mixed cryoglobulinaemia are associated with crescentic GN.

Goodpasture's syndrome. Goodpasture's syndrome is characterised by acute renal failure due to RPGN and pulmonary haemorrhages. The condition is more common in males in 3rd decade of life. The disease results from damage to the glomeruli by anti-GBM antibodies which cross-react with alveolar basement membrane and hence, produce renal as well as pulmonary lesions. The evidences in support are the characteristic linear deposits of anti-GBM antibodies consisting of IgG and complement along the GBM, detection of circulating anti-GBM antibodies. The Goodpasture's antigen appears to be a component of collagen type IV.

Type II RPGN: Immune complex disease. A small proportion of cases of post-streptococcal GN, particularly in adults and sometimes of non-streptococcal origin, develop RPGN. The evidences in support of post-infectious RPGN having immune complex pathogenesis are granular deposits of immune complexes of IgG and C3 along the glomerular capillary walls.

Type III RPGN: Pauci-immune GN. These include cases of Wegener's granulomatosis and microscopic polyarteritis nodosa. The pathogenesis of pauci-immune GN is yet not fully defined. However, majority of these patients are ANCA-positive, implying a defect in humoral immunity. There is little or no glomerular immune deposit (i.e. pauci-immune).

G/A The kidneys are usually enlarged and pale with smooth outer surface (*large white kidney*). Cut surface shows pale cortex and congested medulla.

558 **M/E (Web Image 22.14):** The features are as under:

- i) **Glomeruli**—Irrespective of the underlying etiology, all forms of RPGN show pathognomonic ‘*crescents*’ on the inside of Bowman’s capsules. These are collections of pale-staining polygonal cells which commonly tend to be elongated. Fibrin thrombi are frequently present in the glomerular tufts.
- ii) **Tubules**—Tubular epithelial cells may show hyaline droplets. Tubular lumina may contain casts, red blood cells and fibrin.
- iii) **Interstitialium**—The interstitium is oedematous and may show early fibrosis. Inflammatory cells, usually lymphocytes and plasma cells, are commonly distributed in the interstitial tissue.
- iv) **Vessels**—Arteries and arterioles may show no change, but cases associated with hypertension usually show severe vascular changes.

EM Findings vary according to the type of RPGN. Post-infectious RPGN cases show electron-dense subepithelial granular deposits similar to those seen in acute GN, while cases of RPGN in Goodpasture’s syndrome show characteristic linear deposits along the GBM (**Web Image 22.15**).

IF shows following patterns in various types of RPGN:

- ◆ linear pattern of RPGN in Goodpasture’s syndrome (type I RPGN), containing IgG accompanied by C3 along the capillaries.
- ◆ Granular pattern of post-infectious RPGN (type II RPGN) consisting of IgG and C3 along the capillary wall.
- ◆ Scanty or no deposits of immunoglobulin and C3 in pauci-immune GN (type III RPGN).

CLINICAL FEATURES. Generally, the features of post-infectious RPGN are similar to those of acute GN, presenting as acute renal failure. The patients of Goodpasture’s syndrome may present as acute renal failure and/or associated intrapulmonary haemorrhage producing recurrent haemoptysis. Prognosis of all forms of RPGN is poor.

Minimal Change Disease

(**Synonyms: MCD, Lipoid Nephrosis, Foot Process Disease, Nil Deposit Disease**) (p. 669)

Minimal change disease (MCD) is a condition in which the nephrotic syndrome is accompanied by no apparent change in glomeruli by light microscopy. Its other synonyms, lipoid nephrosis and foot process disease, are descriptive terms for fatty changes in the tubules and electron microscopic appearance of flattened podocytes respectively. Minimal change disease accounts for 80% cases of nephrotic syndrome in children under 16 years of age with preponderance in boys (ratio of boys to girls 2:1).

ETIOPATHOGENESIS. The etiology of MCD remain elusive. However, following two groups have been identified:

- i) Idiopathic (majority of cases).
- ii) Cases associated with systemic diseases (Hodgkin’s disease, HIV infection) and drug therapy (e.g. NSAIDs, rifampicin, interferon- α).

The following features point to possible immunologic pathogenesis for MCD:

- i) Absence of deposits by immunofluorescence microscopy.
- ii) Normal circulating levels of complement but presence of circulating immune complexes in many cases.
- iii) Universal satisfactory response to steroid therapy.
- iv) Evidence of increased suppressor T cell activity with elaboration of cytokines (IL -8, TNF).
- v) Detection of a mutation in nephrin gene in cases of congenital MCD has focused attention on genetic basis.

Nephrotic syndrome in MCD *in children* is characterised by *selective proteinuria* containing mainly albumin, and minimal amounts of high molecular

weight proteins such as α 2-macroglobulin. The basis for selective proteinuria appears to be as under:

- i) Reduction of normal negative charge on GBM due to loss of heparan sulfate proteoglycan from the GBM.
- ii) Change in the shape of epithelial cells producing foot process flattening due to reduction of sialoglycoprotein cell coat.

Adults having MCD, however, have *non-selective proteinuria*, suggesting more extensive membrane permeability defect.

G/A The kidneys are of normal size and shape.

M/E (Web Image 22.16,A): The features are as under:

- i) **Glomeruli**—The most characteristic feature is no apparent abnormality in the glomeruli except for slight increase in the mesangial matrix at the most (minimal change disease or nil lesion).
- ii) **Tubules**—There is presence of fine lipid vacuolation and hyaline droplets in the cells of proximal convoluted tubules and, hence, the older name of the condition as 'lipoid nephrosis'.
- iii) **Interstitialium**—There may be oedema of the interstitium.
- iv) **Vessels**—Blood vessels do not show any significant change.

EM The most characteristic feature of the disease is identified which is diffuse flattening of foot processes of the visceral epithelial cells (podocytes) and, hence, the name foot process disease or podocytopathy (**Web Image 22.16,B**). Unlike other forms of GN, no deposits are seen and the GBM is normal.

IF No deposits of complement or immunoglobulins are recognised (nil deposit disease).

CLINICAL FEATURES. The classical presentation of MCD is of fully-developed nephrotic syndrome with massive and *highly selective proteinuria*, but hypertension is unusual. Most frequently, the patients are children under 16 years (peak incidence at 6-8 years of age).

The disease characteristically responds to steroid therapy. In spite of remissions and relapses, long-term prognosis is very good and most children become free of albuminuria after several years.

Membranous Glomerulonephritis

(**Synonym: Epimembranous Nephropathy**) (p. 669)

Membranous GN is characterised by widespread thickening of the glomerular capillary wall and is the most common cause of nephrotic syndrome in adults. In majority of cases (85%), membranous GN is truly *idiopathic*, while in about 15% of cases it is *secondary* to an underlying condition (e.g. SLE, malignancies, infections such as chronic hepatitis B and C, syphilis, malaria and drugs).

ETIOPATHOGENESIS. *Idiopathic membranous GN* is an immune complex disease. The deposits of immune complex are formed locally because circulating immune complexes are detected in less than a quarter of cases. While nephritogenic antigen against which autoantibodies are formed in *idiopathic membranous GN* is not known yet, the antigen in cases of *secondary membranous GN* is either an endogenous (e.g. DNA in SLE) or exogenous one (e.g. hepatitis B virus, tumour antigen, treponema antigen, drug therapy with penicillamine). Currently, pathogenesis of membrane alteration in membranous GN is believed to be by MAC (membrane attack complex i.e. C35b-C9) terminal complex on podocytes.

G/A The kidneys are enlarged, pale and smooth.

M/E (Web Image 22.17): The features are as under:

- i) **Glomeruli**—The characteristic finding is diffuse thickening of the glomerular capillary walls with all the glomeruli being affected more or less uniformly. As the disease progresses, the deposits are incorporated into

560 enormously thickened basement membrane, producing 'duplication' of GBM which is actually formation of a new basement membrane.

ii) **Tubules**—The renal tubules remain normal.

iii) **Interstitialium**—The interstitium may show fine fibrosis and scanty chronic inflammatory cells.

iv) **Vessels**—In the early stage, vascular changes are not prominent, while later hypertensive changes of arterioles may occur.

EM Shows characteristic electron-dense deposits in subepithelial location. The basement membrane material protrudes between deposits as '*spikes*' (**Web Image 22.18**).

IF Reveals granular deposits of immune complexes consisting of IgG associated with complement C3. In secondary cases of membranous GN the relevant antigen such as hepatitis B or tumour antigen may be seen.

CLINICAL FEATURES. The presentation in majority of cases is insidious onset of nephrotic syndrome in an adult. The proteinuria is usually of *non-selective* type. In addition, microscopic haematuria and hypertension may be present at the onset or may develop during the course of the disease. Progression to impaired renal function and end-stage renal disease with progressive azotaemia occurs in approximately 50% cases within a span of 2 to 20 years.

Membranoproliferative Glomerulonephritis

(**Synonyms: MPGN, Mesangiocapillary GN**) (p. 671)

Membranoproliferative GN is another important cause of nephrotic syndrome in children and young adults.

ETIOPATHOGENESIS. Etiology of MPGN is unknown though in some cases there is evidence of preceding streptococcal infection. Three types of MPGN are recognised:

◆ **Type I or classic form** is an example of immune complex disease and comprises more than 70% cases. Immune-complex MPGN is seen in association with systemic immune-complex diseases (e.g. SLE, mixed cryoglobulinaemia, Sjögren's syndrome), chronic infections (e.g. bacterial endocarditis, HIV, hepatitis B and C) and malignancies (e.g. lymphomas and leukaemias).

◆ **Type II or dense deposit disease** is the example of alternate pathway disease and constitutes about 30% cases. Type II cases have an association with partial lipodystrophy, an unusual condition of unknown pathogenesis characterised by symmetrical loss of subcutaneous fat from the upper half of the body.

◆ **Type III** is rare and shows features of type I MPGN and membranous nephropathy in association with systemic diseases or drugs.

G/A The kidneys are usually pale in appearance and firm in consistency.

M/E (Web Image 22.19): The features are as under:

i) **Glomeruli**—Glomeruli show highly characteristic changes. They are enlarged with accentuated lobular pattern. The enlargement is due to variable degree of mesangial cellular proliferation and increase in mesangial matrix. The GBM is considerably thickened, which with silver stains shows two basement membranes with a clear zone between them. This is commonly referred to as '*double contour*', '*splitting*', or '*tram track*' appearance.

ii) **Tubules**—Tubular cells may show vacuolation and hyaline droplets.

iii) **Interstitialium**—There may be scattered chronic inflammatory cells and some finely granular foam cells in the interstitium.

iv) **Vessels**—Vascular changes are prominent in cases in which hypertension develops.

EM and IF (Web Image 22.20). The findings are:

Type I: It shows *electron-dense deposits* in subendothelial location conforming to immune-complex character of the disease. These deposits reveal positive fluorescence for C3 and slightly fainter staining for IgG.

Type II: The hallmark of type II MPGN is the presence of *dense amorphous deposits* within the lamina densa of the GBM and in the mesangium. Immunofluorescence studies reveal the universal presence of C3 and properdin in the deposits but the immunoglobulins are usually absent.

Type III: This rare form has *electron-dense deposits* within the GBM as well as in subendothelial and subepithelial regions of the GBM. Immunofluorescence studies show the presence of C3, IgG and IgM.

CLINICAL FEATURES. Clinically, there are many similarities between the main forms of MPGN. The most common age at diagnosis is between 15 and 20 years. Approximately 50% of the patients present with nephrotic syndrome; about 30% have asymptomatic proteinuria; and 20% have nephritic syndrome at presentation. The proteinuria is non-selective. Haematuria and hypertension are frequently present.

Focal Proliferative Glomerulonephritis

(Synonym: Mesangial Proliferative GN) (p. 672)

Focal proliferative GN is characterised by pathologic changes in certain number of glomeruli (*focal*), and often confined to one or two lobules of the affected glomeruli (*segmental*), while other glomeruli are normal.

ETIOPATHOGENESIS. It may occur under following diverse clinical settings:

- ◆ As an early manifestation of a number of *systemic diseases* such as SLE, Henoch-Schonlein purpura, subacute bacterial endocarditis, Wegener's granulomatosis, and polyarteritis nodosa, Goodpasture's syndrome.
- ◆ As a component of a known *renal disease* such as in IgA nephropathy.
- ◆ As a primary *idiopathic* glomerular disease unrelated to systemic or other renal disease.

M/E The single most important feature in focal GN is the abnormality seen in certain number of glomeruli and generally confined to one or two lobules of the affected glomeruli i.e. *focal and segmental glomerular involvement (Web Image 22.21,A)*. The pathologic change most frequently consists of focal and segmental cellular proliferation of mesangial cells and endothelial cells but sometimes necrotising changes can be seen.

IF Widespread mesangial deposits of immunoglobulins (mainly IgA with or without IgG), complement (C3) and fibrin are demonstrated in most cases of focal GN.

CLINICAL FEATURES. The clinical features vary according to the condition causing it. Haematuria is one of the most common clinical manifestation. Proteinuria is frequently mild to moderate but hypertension is uncommon.

Focal Segmental Glomerulosclerosis

(Synonyms: Focal Sclerosis, Focal Hyalinosis) (p. 673)

Focal segmental glomerulosclerosis (FSGS) is a condition in which there is sclerosis and hyalinosis of some glomeruli and portions of their tuft (less than 50% in a tissue section), while the other glomeruli are normal by light microscopy i.e. involvement is focal and segmental.

ETIOPATHOGENESIS. FSGS was previously believed to be a variant of MCD with accentuation of epithelial damage in the form of hyalinosis and sclerosis. Currently, the condition is divided into 3 groups:

- i) Idiopathic type,
- ii) With superimposed primary glomerular disease and
- iii) Secondary type.

The hallmark of pathogenesis of FSGS is injury to visceral epithelial cells that results in disruption of visceral epithelial cells and resultant nephron loss.

M/E Depending upon the severity of the disease, variable number of glomeruli are affected focally and segmentally, while others are normal. The affected glomeruli show solidification or *sclerosis* of one or more lobules of the tuft. *Hyalinosis* refers to collection of eosinophilic, homogeneous, PAS-positive, hyaline material present on the inner aspect of a sclerotic peripheral capillary loop. In addition, to glomerular changes, there is interstitial fibrosis and infiltration by mononuclear leucocytes, and tubular epithelial cell atrophy and degeneration (**Web Image 22.21, B, C**).

Besides the lesions of focal and segmental scarring, a variant of FSGS, *collapsing glomerulopathy*, has been described in HIV patients.

EM Diffuse loss of foot processes as seen in minimal change disease is evident but, in addition, there are electron-dense deposits in the region of hyalinosis and sclerosis which are believed to be immune complexes.

IF The deposits in the lesions are shown to contain IgM and C3.

CLINICAL FEATURES. The condition may affect all ages including children and has male preponderance. The most common presentation is in the form of nephrotic syndrome with heavy proteinuria. Haematuria and hypertension tend to occur more frequently than in minimal change disease.

IgA Nephropathy (Synonyms: Berger's Disease, IgA GN) (p. 674)

IgA nephropathy is emerging as the most common form of glomerulopathy worldwide and its incidence has been rising.

ETIOPATHOGENESIS. The etiology of IgA nephropathy remains unclear:

- i) It is idiopathic in most cases.
- ii) Seen as part of Henoch-Schonlein purpura.
- iii) Association with chronic inflammation in various body systems (e.g. chronic liver disease, inflammatory bowel disease, interstitial pneumonitis, leprosy, dermatitis herpetiformis, uveitis, ankylosing spondylitis, Sjögren's syndrome, monoclonal IgA gammopathy).

Pathogenesis of IgA nephropathy is explained on the basis of following mechanisms:

- i) IgA nephropathy has been considered to arise from *entrapment* of these complexes in the mesangium.
- ii) Activation of *alternate complement pathway*.
- iii) *Increased mucosal secretion of IgA*.
- iv) HLA-B35 association *genetically-determined* abnormality.

M/E The pattern of involvement varies. These include: focal proliferative GN, focal segmental glomerulosclerosis, membranoproliferative GN, and rarely RPGN.

EM Finely granular electron-dense deposits are seen in the mesangium.

IF The diagnosis is firmly established by demonstration of mesangial deposits of IgA, with or without IgG, and usually with C3 and properdin.

CLINICAL FEATURES. The disease is common in children and young adults. The clinical picture is usually characterised by recurrent bouts of haematuria that are often precipitated by mucosal infections.

Chronic Glomerulonephritis (Synonym: End-Stage Kidney) (p. 674)

Chronic GN is the final stage of a variety of glomerular diseases which result in irreversible impairment of renal function. The conditions which may progress to chronic GN, in descending order of frequency, are as under:

- i) Rapidly progressive GN (90%)
- ii) Membranous GN (50%)

- iii) Membranoproliferative GN (50%)
- iv) Focal segmental glomerulosclerosis (50%)
- v) IgA nephropathy (40%)
- vi) Acute post-streptococcal GN (1%).

However, about 20% cases of chronic GN are *idiopathic* without evidence of preceding GN of any type.

G/A The kidneys are usually small and contracted weighing as low as 50 gm each. The capsule is adherent to the cortex. The cortical surface is generally diffusely granular (**Web Image 22.22**).

M/E (**Web Image 22.23**). The findings are as under:

- i) **Glomeruli**—Glomeruli are reduced in number and most of those present show completely hyalinised tufts, giving the appearance of acellular, eosinophilic masses which are PAS-positive. Evidence of underlying glomerular disease may be present.
- ii) **Tubules**—Many tubules completely disappear and there may be atrophy of tubules close to scarred glomeruli.
- iii) **Interstitialium**—There is fine and delicate fibrosis of the interstitial tissue and varying number of chronic inflammatory cells are often seen.
- iv) **Vessels**—Advanced cases which are frequently associated with hypertension show conspicuous arterial and arteriolar sclerosis.

CLINICAL FEATURES. The patients are usually adults. The terminal stage of chronic GN is characterised by hypertension, uraemia and progressive deterioration of renal function. These patients eventually die if they do not receive a renal transplant.

The salient features of various types of primary glomerulonephritis are summarised in **Web Table 22.11**.

II. SECONDARY GLOMERULAR DISEASES (p. 675)

Lupus Nephritis (p. 675)

Renal manifestations of systemic lupus erythematosus (SLE) are termed lupus nephritis. The incidence of renal involvement in SLE ranges from 40 to 75%. The two cardinal clinical manifestations of lupus nephritis are proteinuria and haematuria. In addition, hypertension and casts of different types such as red cell casts, fatty casts and leucocyte casts in the urinary sediment are found.

Pathogenesis of lesions in lupus nephritis is linked to genes related to major histocompatibility complex and B-cell signaling pathways such as TNF superfamily members.

MORPHOLOGIC FEATURES. According to the WHO, six patterns of mutually-merging renal lesions are seen in lupus nephritis (*also refer to Web Table 4.9*):

Class I: Minimal lesions. On light microscopy, these cases do not show any abnormality. But examination by electron microscopy and immunofluorescence microscopy shows deposits within the mesangium which consist of IgG and C3.

Class II: Mesangial lupus nephritis. These cases have mild clinical manifestations. By light microscopy, there is increase in the number of mesangial cells and of mesangial matrix. Ultrastructural and immunofluorescence studies reveal granular mesangial deposits of IgG and C3; sometimes IgA and IgM are also present in the deposits.

Class III: Focal segmental lupus nephritis. This is characterised by focal and segmental proliferation of endothelial and mesangial cells, together with infiltration by macrophages and sometimes neutrophils. Haematoxylin bodies of Gross may be present. Subendothelial and subepithelial deposits of IgG, often with IgM or IgA and C3, are seen.

564 Class IV: Diffuse proliferative lupus nephritis. In this type, all the morphologic manifestations of lupus are present in most advanced form. This is the most severe and the most common form of lupus nephritis. There is diffuse proliferation of endothelial, mesangial, and sometimes epithelial cells, involving most or all glomeruli. Electron microscopy shows large electron-dense deposits in the mesangium and in the subendothelial region which on immunofluorescence are positive for IgG; sometimes also for IgA or IgM, and C3.

Class V: Membranous lupus nephritis. These lesions resemble those of idiopathic membranous GN. These consist of diffuse thickening of glomerular capillary wall on light microscopy and show subendothelial deposits of immune complexes containing IgG, IgM and C3 on ultrastructural studies. Mesangial hypercellularity is present in some cases.

Class VI: Sclerosing lupus nephritis. This is end-stage kidney of SLE, akin to chronic GN. Most glomeruli are sclerosed and hyalinised and there may be remnants of preceding lesions.

Diabetic Nephropathy (p. 677)

Renal involvement is an important complication of diabetes mellitus. End-stage kidney with renal failure accounts for deaths in more than 10% of all diabetics. Renal complications are more severe, develop early and more frequently in type 1 (earlier called insulin-dependent) diabetes mellitus (30-40% cases) than in type 2 (earlier termed non-insulin-dependent) diabetics (about 20% cases). A variety of clinical syndromes are associated with diabetic nephropathy that includes asymptomatic proteinuria, nephrotic syndrome, progressive renal failure and hypertension. Cardiovascular disease is 40 times more common in patients of end-stage renal disease in diabetes mellitus than in non-diabetics and more diabetics die from cardiovascular complications than from uraemia.

MORPHOLOGIC FEATURES. Diabetic nephropathy encompasses 4 types of renal lesions in diabetes mellitus:

1. DIABETIC GLOMERULOSCLEROSIS. Glomerular lesions in diabetes mellitus are particularly common and account for majority of abnormal findings referable to the kidney.

Pathogenesis of these lesions in diabetes mellitus is explained by following sequential changes: hyperglycaemia → glomerular hypertension → renal hyperperfusion → deposition of proteins in the mesangium → glomerulosclerosis → renal failure.

Glomerulosclerosis in diabetes may take one of the 2 forms:

i) Diffuse glomerulosclerosis. Diffuse glomerular lesions are the most common. There is involvement of all parts of glomeruli. The pathologic changes consist of thickening of the GBM and diffuse increase in mesangial matrix with mild proliferation of mesangial cells. Various exudative lesions such as capsular hyaline drops and fibrin caps may also be present (**Web Image 22.24,A**).

ii) Nodular glomerulosclerosis. Nodular lesions of diabetic glomerulosclerosis are also called as *Kimmelstiel-Wilson (KW) lesions* or *intercapillary glomerulosclerosis*. These lesions are specific for type 1 diabetes (juvenile-onset diabetes). The pathologic changes consist of one or more nodules in a few or many glomeruli. *Nodule* is an ovoid or spherical, laminated, hyaline, acellular mass located within a lobule of the glomerulus. The nodules are surrounded peripherally by glomerular capillary loops which may have normal or thickened GBM (**Web Image 22.24,B**). The nodules are PAS-positive and contain lipid and fibrin. As the nodular lesions enlarge, they compress the glomerular capillaries and obliterate the glomerular tuft (**Web Image 22.25**).

2. VASCULAR LESIONS. *Atheroma* of renal arteries is very common and severe in diabetes mellitus. *Hyaline arteriosclerosis* affecting the afferent

and efferent arterioles of the glomeruli is also often severe in diabetes. These vascular lesions are responsible for renal ischaemia that results in tubular atrophy and interstitial fibrosis.

3. DIABETIC PYELONEPHRITIS. Poorly-controlled diabetics are particularly susceptible to bacterial infections. Papillary necrosis (necrotising papillitis) is an important complication of diabetes that may result in acute pyelonephritis. Chronic pyelonephritis is 10 to 20 times more common in diabetics than in others.

4. TUBULAR LESIONS (ARMANNI-EBSTEIN LESIONS). In untreated diabetics who have extremely high blood sugar level, the epithelial cells of the proximal convoluted tubules develop extensive glycogen deposits appearing as vacuoles. These are called Armanni-Ebstein lesions.

Hereditary Nephritis (p. 678)

A group of hereditary diseases principally involving the glomeruli are termed hereditary nephritis. These include the following:

1. Alport's syndrome. Out of various hereditary nephritis, Alport's syndrome is relatively more common and has been extensively studied. This is an X-linked dominant disorder having mutation in α -5 chain of type IV collagen located on X-chromosome. It affects males more severely than females. The syndrome consists of sensori-neural deafness and ophthalmic complications (lens dislocation, posterior cataracts and corneal dystrophy) associated with hereditary nephritis.

M/E The glomeruli have predominant involvement and show segmental proliferation of mesangial cells with increased mesangial matrix and occasional segmental sclerosis. Another prominent feature is the presence of *lipid-laden foam cells* in the interstitium.

EM Reveals characteristic basement membrane splitting or lamination in the affected parts of glomeruli.

IF Fails to show deposits of immunoglobulins or complement components.

2. Fabry's disease, another hereditary nephritis is characterised by accumulation of neutral glycosphingolipids in lysosomes of glomerular, tubular, vascular and interstitial cells.

3. Nail-patella syndrome or osteonychodysplasia is a rare hereditary disease having abnormality in α -1 chain of collagen V on chromosome 9 associated with multiple osseous defects of elbows, knees and nail dysplasia. About half the cases develop nephropathy.

TUBULAR AND TUBULOINTERSTITIAL DISEASES (p. 678)

I. Primary tubular diseases that include tubular injury by ischaemic or toxic agents i.e. acute tubular necrosis.

II. Tubulointerstitial diseases that include inflammatory involvement of the tubules and the interstitium i.e. tubulointerstitial nephritis.

ACUTE TUBULAR NECROSIS (p. 679)

Acute tubular necrosis (ATN) is the term used for acute renal failure (ARF) resulting from destruction of tubular epithelial cells. ATN is the most common and most important cause of ARF characterised by sudden cessation of renal function. Based on etiology and morphology, two forms of ATN are distinguished—*ischaemic* and *toxic*; however both forms have a somewhat common pathogenesis.

Pathogenesis of ATN (p. 679)

The pathogenesis of both types of ATN resulting in ARF is explained on the basis of the following sequential mechanism (**Web Image 22.26**):

- 566 i) Renal tubules are highly *susceptible* to injury by ischaemia and toxic agents.
- ii) *Tubular damage* in ischaemic ATN is initiated by arteriolar vasoconstriction induced by renin-angiotensin system, while in toxic ATN by direct damage to tubules by the agent.
- iii) Debris of the desquamated epithelium due to necrosis causes *tubular obstruction* and may block urinary outflow with consequent reduction of GFR and also produce casts in the urine.
- iv) These events cause *increased intratubular pressure* resulting in damage to tubular basement membrane.
- v) Due to increased intratubular pressure, there is *tubular rupture*.
- vi) Damage to tubules is accompanied with leakage of fluid into the interstitium causing *interstitial oedema*.
- vii) Leakage of tubular fluid into the interstitium increases *interstitial pressure*.
- viii) Leaked fluid incites host *inflammatory response*.
- ix) Increased interstitial pressure causes *compression of tubules and blood vessels* and setting up a vicious cycle of accentuated ischaemia and necrosis.
- x) Ultimately, it leads to reduced GFR and consequently *oliguria*.

Ischaemic ATN (p. 679)

Ischaemic ATN, also called tubulorrhctic ATN, lower (distal) nephron nephrosis, anoxic nephrosis, or shock kidney, occurs due to hypoperfusion of the kidneys resulting in focal damage to the distal parts of the convoluted tubules.

ETIOLOGY. Ischaemic ATN is more common than toxic ATN and accounts for more than 80% cases of tubular injury. Ischaemia may result from a variety of causes as follows:

1. Shock (post-traumatic, surgical, burns, dehydration, obstetrical and septic type).
2. Crush injuries.
3. Non-traumatic rhabdomyolysis induced by alcohol, coma, muscle disease or extreme muscular exertion (myoglobinuric nephrosis).
4. Mismatched blood transfusions, black-water fever (haemoglobinuric nephrosis).

G/A The kidneys are enlarged and swollen. On cut section, the cortex is often widened and pale, while medulla is dark.

M/E Predominant changes are seen in the tubules, while glomeruli remain unaffected. The interstitium shows oedema and mild chronic inflammatory cell infiltrate. Tubular changes are as follows (**Web Image 22.27**):

1. Dilatation of the proximal and distal convoluted tubules.
2. Focal tubular necrosis at different points along the nephron.
3. Flattened epithelium lining the tubules suggesting epithelial regeneration.
4. Eosinophilic hyaline casts or pigmented haemoglobin and myoglobin casts in the tubular lumina (**Web Image 22.28**).
5. Disruption of tubular basement membrane adjacent to the cast may occur (tubulorrhhexis).

Prognosis of ischaemic ATN depends upon the underlying etiology. In general, cases that follow severe trauma, surgical procedures, extensive burns and sepsis have much worse outlook than the others.

Toxic ATN (p. 680)

Toxic ATN, also called nephrotoxic ATN or toxic nephrosis or upper (proximal) nephron nephrosis, occurs as a result of direct damage to tubules, more marked in proximal portions, by ingestion, injection or inhalation of a number of toxic agents.

ETIOLOGY. The factors are as under:

1. General poisons such as mercuric chloride, carbon tetrachloride, ethylene glycol, mushroom poisoning and insecticides.
2. Heavy metals (mercury, lead, arsenic, phosphorus and gold).
3. Drugs such as sulfonamides, certain antibiotics (gentamycin, cephalosporin), anaesthetic agents (methoxyflurane, halothane), barbiturates, salicylates.
4. Radiographic contrast material.

MORPHOLOGIC FEATURES. Poisoning with mercuric chloride provides the classic example that produces widespread and readily discernible tubular necrosis (*acute mercury nephropathy*).

G/A The kidneys are enlarged and swollen. On cut section, the cortex is pale and swollen, while the medulla is slightly darker than normal.

M/E The appearance varies according to the cause of toxic ATN but, in general, involves the segment of tubule diffusely (unlike ischaemic ATN where the involvement of nephron is focal). In mercuric chloride poisoning, the features are as follows (**Web Image 22.28**):

1. Epithelial cells of mainly proximal convoluted tubules are necrotic and desquamated into the tubular lumina.
2. The desquamated cells may undergo dystrophic calcification.
3. Tubular basement membrane is generally intact.
4. The regenerating epithelium, which is flat and thin with few mitoses, may be seen lining the tubular basement membrane.

Prognosis of toxic ATN is good if there is no serious damage to other organs such as heart and liver.

The contrasting features of the two forms of ATN are presented in **Web Table 22.12**.

□ TUBULOINTERSTITIAL DISEASES (p. 680)

The term tubulointerstitial nephritis is used for inflammatory process that predominantly involves the renal interstitial tissue and is usually accompanied by some degree of tubular damage. However, the term *interstitial nephritis* is reserved for those cases where there is no primary involvement of glomeruli, tubules or blood vessels.

A number of bacterial and non-bacterial, acute and chronic conditions may produce tubulointerstitial nephritis and are listed in **Web Table 22.13**.

Acute Pyelonephritis (p. 680)

Acute pyelonephritis is an acute suppurative inflammation of the kidney caused by pyogenic bacteria.

ETIOPATHOGENESIS. Most cases of acute pyelonephritis follow infection of the lower urinary tract. The most common pathogenic organism in urinary tract infection (UTI) is *Escherichia coli* (in 90% of cases), followed in decreasing frequency, by *Enterobacter*, *Klebsiella*, *Pseudomonas* and *Proteus*. The bacteria gain entry into the urinary tract, and thence into the kidney by one of the two routes (**Web Image 22.29**):

1. **Ascending infection.** This is the most common route of infection. The common pathogenic organisms are inhabitants of the colon and may cause faecal contamination of the urethral orifice, especially in females in reproductive age group. Ascending infection may occur in a normal individual but the susceptibility is increased in patients with diabetes mellitus, pregnancy, urinary tract obstruction or instrumentation. Bacteria multiply in the urinary bladder and produce asymptomatic bacteriuria found in many of these cases. The role of vesico-ureteral reflux is not of a great significance in the pathogenesis of acute chronic pyelonephritis as it is in chronic pyelonephritis.
2. **Haematogenous infection.** Less often, acute pyelonephritis may result from blood-borne spread of infection. This occurs more often in patients with

568 obstructive lesions in the urinary tract, and in debilitated or immunosuppressed patients.

G/A Well-developed cases of acute pyelonephritis show enlarged and swollen kidney that bulges on section. The cut surface shows small, yellow-white abscesses with a haemorrhagic rim. These abscesses may be several millimetres across and are situated mainly in the cortex.

M/E Acute pyelonephritis is characterised by extensive acute inflammation involving the interstitium and causing destruction of the tubules. Generally, the glomeruli and renal blood vessels show considerable resistance to infection and are spared. The acute inflammation may be in the form of large number of neutrophils in the interstitial tissue and bursting into tubules, or may form focal neutrophilic abscesses in the renal parenchyma.

CLINICAL FEATURES. Classically, acute pyelonephritis has an acute onset with chills, fever, loin pain, lumbar tenderness, dysuria and frequency of micturition. Urine will show bacteria in excess of 100,000/ml, pus cells and pus cell casts in the urinary sediment.

COMPLICATIONS. Complications of acute pyelonephritis are encountered more often in patients with diabetes mellitus or with urinary tract obstruction.

1. Papillary necrosis. Papillary necrosis or necrotising papillitis develops more commonly in analgesic abuse nephropathy and in sickle cell disease but may occur as a complication of acute pyelonephritis as well.

G/A The necrotic papillae are yellow to grey-white, sharply-defined areas with congested border and resemble infarction.

M/E Necrotic tissue is separated from the viable tissue by a dense zone of polymorphs.

2. Pyonephrosis. Rarely, the abscesses in the kidney in acute pyelonephritis are extensive, particularly in cases with obstruction. This results in inability of the abscesses to drain and this transforms the kidney into a multilocular sac filled with pus called as pyonephrosis or renal carbuncle (**Web Image 22.30**).

3. Perinephric abscess. The abscesses in the kidney may extend through the capsule of the kidney into the perinephric tissue and form perinephric abscess.

Chronic Pyelonephritis (p. 682)

Chronic pyelonephritis is a chronic tubulointerstitial disease resulting from repeated attacks of inflammation and scarring.

ETIOPATHOGENESIS. Depending upon the etiology and pathogenesis, two types of chronic pyelonephritis are described (**Web Image 22.31**):

1. Reflux nephropathy. Reflux of urine from the bladder into one or both the ureters during micturition is the major cause of chronic pyelonephritis. *Vesicoureteric reflux* is particularly common in children, especially in girls, due to congenital absence or shortening of the intravesical portion of the ureter so that ureter is not compressed during the act of micturition (**Web Image 22.29**).

2. Obstructive pyelonephritis. Obstruction to the outflow of urine at different levels predisposes the kidney to infection. Recurrent episodes of such obstruction and infection result in renal damage and scarring.

G/A The kidneys show rather characteristic appearance. The kidneys are usually small and contracted (weighing less than 100 gm) showing unequal reduction, which distinguishes it from other forms of contracted kidney. The surface of the kidney is irregularly scarred; the capsule can be stripped off with difficulty due to adherence to scars (**Web Image 22.32**).

M/E (Web Image 22.33):

i) Interstitium—There is chronic interstitial inflammatory reaction, chiefly composed of lymphocytes, plasma cells and macrophages with pronounced interstitial fibrosis. *Xanthogranulomatous pyelonephritis* is an uncommon variant characterised by collection of foamy macrophages admixed with other inflammatory cells and giant cells.

ii) Tubules—The tubules show varying degree of atrophy and dilatation. Dilated tubules may contain eosinophilic colloid casts producing thyroidisation of tubules.

iii) Pelvicalyceal system—The renal pelvis and calyces are dilated. The walls of pelvis and calyces show marked chronic inflammation and fibrosis. The lining epithelium may undergo squamous metaplastic change.

iv) Blood vessels—Blood vessels entrapped in the scarred areas show obliterative endarteritis. There may be changes of hypertensive hyaline arteriosclerosis.

v) Glomeruli—Though glomerular tuft in the scarred area is usually intact, there is often periglomerular fibrosis. In advanced cases, there may be hyalinisation of glomeruli.

CLINICAL FEATURES. Chronic pyelonephritis often has an insidious onset. The patients present with clinical picture of chronic renal failure or with symptoms of hypertension. Sometimes, the patients may present with features of acute recurrent pyelonephritis with fever, loin pain, lumbar tenderness, dysuria, pyuria, bacteriuria and frequency of micturition.

Tuberculous Pyelonephritis (p. 684)

Tuberculosis of the kidney occurs due to haematogenous spread of infection from another site, most often from the lungs.

G/A The lesions in tuberculous pyelonephritis are often bilateral, usually involving the medulla with replacement of the papillae by caseous tissue.

M/E Typical granulomatous reaction is seen. Acid-fast bacilli can often be demonstrated in the lesions.

CLINICAL FEATURES. Most patients are young to middle-aged adults. The clinical presentation is extremely variable. The diagnosis rests on identification of *M. tuberculosis* by repeated culture of urine on L.J. media.

Myeloma Nephropathy (p. 684)

Renal involvement in multiple myeloma is referred to as myeloma nephropathy or myeloma kidney. Functional renal impairment in multiple myeloma is a common manifestation, developing in about 50% of patients. The pathogenesis of myeloma kidney is related to excess filtration of Bence Jones proteins through the glomerulus, usually *kappa* (κ) light chains. These light chain proteins are precipitated in the distal convoluted tubules in combination with Tamm-Horsfall proteins, the urinary glycoproteins.

G/A The kidneys may be normal or small and shrunken.

M/E There are some areas of tubular atrophy while many other tubular lumina are dilated and contain characteristic bright pink laminated cracked or fractured casts consisting of Bence-Jones proteins called fractured casts. These casts are surrounded by peritubular interstitial inflammatory reaction including the presence of nonspecific inflammatory cells and some multinucleate giant cells induced by tubular casts.

Nephrocalcinosis (p. 684)

Nephrocalcinosis is a diffuse deposition of calcium salts in renal tissue in a number of renal diseases, in hypercalcaemia, hyperphosphataemia and renal tubular acidosis. Most commonly, it develops as a complication of severe hypercalcaemia such as due to hyperparathyroidism, hypervitaminosis D, excessive bone destruction in metastatic malignancy, hyperthyroidism, excessive calcium intake such as in milk-alkali syndrome and sarcoidosis.

570 MORPHOLOGIC FEATURES. Nephrocalcinosis due to hypercalcaemia characteristically shows deposition of calcium in the tubular epithelial cells in the basement membrane, within the mitochondria and in the cytoplasm. These concretions may produce secondary tubular atrophy, interstitial fibrosis and nonspecific chronic inflammation in the interstitium.

□ **RENAL VASCULAR DISEASES** (p. 685)

HYPERTENSIVE VASCULAR DISEASE (p. 685)

An elevated arterial blood pressure is a major health problem, particularly in developed countries. A persistent and sustained high blood pressure has damaging effects on the heart (e.g. hypertensive heart disease, Chapter 16), brain (e.g. cerebrovascular accident or stroke, Chapter 30) and kidneys (benign and malignant nephrosclerosis).

Definition and Classification (p. 685)

Hypertension is a common disease in industrialised countries and accounts for 6% of death worldwide. Epidemiologic studies have revealed that with elevation in systolic and diastolic blood pressure above normal in adults, there is a continuous increased risk of cardiovascular disease, stroke and renal disease—cardiovascular risk doubles with every 20 mmHg increase in systolic and 10 mmHg increase in diastolic blood pressure above normal levels. Recently, criteria for normal blood pressure, prehypertension and hypertension (stage 1 and stage 2) have been laid by the National Institutes of Health (NIH), US (**Web Table 22.14**). According to this criteria, normal cut-off values for systolic and diastolic blood pressure are taken as < 120 and < 80 mmHg respectively. As per this criteria, arterial or systemic hypertension in adults is defined clinically as persistently elevated systolic blood pressure of 140-159 mmHg, or diastolic pressure of 90-99 mmHg as *stage 1 hypertension*, and corresponding values above 160 or above 100 mmHg as *stage 2 hypertension*. Cases falling between upper normal values for systolic and diastolic blood pressure (i.e. above 120/80 mmHg) and those for stage 1 hypertension (120-139/80-89 mmHg) are grouped under *prehypertension* requiring monitoring and follow-up. The diastolic pressure is often considered more significant.

Hypertension is generally classified into 2 types:

1. **Primary or essential hypertension**
2. **Secondary hypertension**

According to the clinical course, both essential and secondary hypertension may be benign or malignant.

◆ **Benign hypertension** is moderate elevation of blood pressure and the rise is slow over the years. About 90-95% patients of hypertension have benign hypertension.

◆ **Malignant hypertension** is marked and sudden increase of blood pressure to 200/140 mmHg or more in a known case of hypertension or in a previously normotensive individual; the patients develop papilloedema, retinal haemorrhages and hypertensive encephalopathy.

Etiology and Pathogenesis (p. 685)

The etiology and pathogenesis of secondary hypertension that comprises less than 10% cases has been better understood, whereas the mechanism of essential hypertension that constitutes about 90% of cases remains largely obscure. In general, normal blood pressure is regulated by 2 haemodynamic forces—*cardiac output* and *total peripheral vascular resistance*. Factors which alter these two factors result in hypertension. The role of kidney in hypertension, particularly in secondary hypertension, by elaboration of renin and subsequent formation of angiotensin II, is well established (renin-angiotensin system).

With this background knowledge, we next turn to the mechanisms involved in the two forms of hypertension (**Web Table 22.15**).

ESSENTIAL (PRIMARY) HYPERTENSION. By definition, the cause of essential hypertension is unknown but a number of factors are related to its development. These are as under:

1. Genetic factors.
2. Racial and environmental factors.
3. Risk factors modifying the course of essential hypertension:
 - i) Age, ii) Sex, iii) Atherosclerosis, iv) Other risk factors.

The *pathogenetic mechanism* in essential hypertension is explained by many theories. These are as under:

1. *High plasma level of catecholamines.*
2. *Increase in blood volume* i.e. arterial overfilling (volume hypertension) and arteriolar constriction (vasoconstrictor hypertension).
3. *Increased cardiac output.*
4. *Low-renin essential hypertension* found in approximately 20% patients due to altered responsiveness to renin release.
5. *High renin essential hypertension* seen in about 15% cases due to decreased adrenal responsiveness to angiotensin II.

SECONDARY HYPERTENSION. Though much less common than essential hypertension, mechanisms underlying secondary hypertension with identifiable cause have been studied more extensively.

1. RENAL HYPERTENSION. Hypertension produced by renal diseases is called renal hypertension. Renal hypertension is subdivided into 2 groups:

- i) *Renal vascular hypertension* e.g. in occlusion of a major renal artery, pre-eclampsia, eclampsia, polyarteritis nodosa and fibromuscular dysplasia of renal artery.
- ii) *Renal parenchymal hypertension* e.g. in various types of glomerulonephritis, pyelonephritis, interstitial nephritis, diabetic nephropathy, amyloidosis, polycystic kidney disease and renin-producing tumours.

In either case, renal hypertension can be produced by one of the following 3 inter-related pathogenetic mechanisms:

a) Activation of renin-angiotensin system. The renin-angiotensin system is concerned mainly with 3 functions:

- i) Control of blood pressure by altering plasma concentration of angiotensin II and aldosterone.
- ii) Regulation of sodium and water content.
- iii) Regulation of potassium balance.

The renin-angiotensin mechanism is summarised in **Web Image 22.34**.

b) Sodium and water retention. Blood volume and cardiac output, both of which have a bearing on blood pressure, are regulated by blood levels of sodium which is significant for maintaining extracellular fluid volume. Blood concentration of sodium is regulated by 3 mechanisms:

- i) *Release of aldosterone.*
- ii) *Reduction in GFR.*
- iii) *Release of atriopeptin hormone.*

c) Release of vasodepressor material. A number of vasodepressor materials and antihypertensives counterbalance the vasopressor effect of angiotensin II. These substances include: prostaglandins (PGE₂, PGF₂, PGA or medullin) released from interstitial cells of the medulla, urinary kallikrein-kinin system and platelet-activating factor.

2. ENDOCRINE HYPERTENSION. A number of hormonal secretions may produce secondary hypertension:

- i) *Adrenal gland*—e.g. in primary aldosteronism, Cushing's syndrome, adrenal virilism and pheochromocytoma.
- ii) *Parathyroid gland*—e.g. hypercalcaemia in hyperparathyroidism.

572 iii) *Oral contraceptives*—Oestrogen component in the oral contraceptives stimulates hepatic synthesis of renin substrate.

3. COARCTATION OF AORTA. Coarctation of the aorta causes systolic hypertension in the upper part of the body due to constriction itself. Diastolic hypertension results from changes in circulation.

4. NEUROGENIC. Psychogenic, polyneuritis, increased intracranial pressure and section of spinal cord are all uncommon causes of secondary hypertension.

EFFECTS OF HYPERTENSION (p. 687)

Systemic hypertension causes major effects in three main organs—heart and its blood vessels, nervous system, and kidneys. An important and early clinical marker for renal injury from hypertension and risk factor for cardiovascular disease is *macroalbuminuria*, or *microalbuminuria* estimated by radioimmunoassay (i.e. microalbumin 30-300 mg/day or random urine microalbumin/creatinine ratio of 30-300 mg/gm creatinine).

Benign Nephrosclerosis (p. 687)

Benign nephrosclerosis is the term used to describe the kidney of benign phase of hypertension. Mild benign nephrosclerosis is the most common form of renal disease in persons over 60 years of age but its severity increases in the presence of hypertension and diabetes mellitus.

G/A Both the kidneys are affected equally and are reduced in size and weight, often weighing about 100 gm or less. The capsule is often adherent to the cortical surface. The surface of the kidney is finely granular and shows V-shaped areas of scarring.* The cut surface shows firm kidney and narrowed cortex (**Web Image 22.35**).

M/E There are primarily diffuse vascular changes which produce parenchymal changes secondarily as a result of ischaemia (**Web Image 22.36,A**):

i) Vascular changes: Changes in blood vessels involve arterioles and arteries up to the size of arcuate arteries. There are 2 types of changes in these blood vessels:

- a) *Hyaline arteriolosclerosis*
- b) *Intimal thickening*

ii) Parenchymal changes: As a consequence of ischaemia, there is variable degree of atrophy of parenchyma. This includes: glomerular shrinkage, deposition of collagen in Bowman's space, periglomerular fibrosis, tubular atrophy and fine interstitial fibrosis.

CLINICAL FEATURES. There is variable elevation of the blood pressure with headache, dizziness, palpitation and nervousness. Eye ground changes may be found but papilloedema is absent.

Malignant Nephrosclerosis (p. 688)

Malignant nephrosclerosis is the form of renal disease that occurs in malignant or accelerated hypertension. Malignant nephrosclerosis is uncommon and usually occurs as a superimposed complication in 5% cases of pre-existing benign essential hypertension.

*The various acquired causes of '*small contracted kidney*' and their characteristic gross macroscopic appearance may be recollected here. These are: 1. Chronic GN (granular appearance); 2. Chronic pyelonephritis (U-shaped scars); and 3. Benign nephrosclerosis (V-shaped scars). Although granular, U- and V-shaped scars correspond to the respective macroscopic patterns, acronym to remember is: '*granular*' for glomerular scars of chronic GN; '*U-scars*' for uneven scars of chronic pyelonephritis; and '*V-scars*' for vascular scars of benign nephrosclerosis. Less common causes are: amyloidosis of the kidney, myeloma kidney and diabetic nephropathy.

G/A The appearance of the kidney varies. In a case of malignant hypertension superimposed on pre-existing benign nephrosclerosis, the kidneys are small in size, shrunken and reduced in weight and have finely granular surface. However, the kidneys of a patient who develops malignant hypertension in pure form are enlarged, oedematous and have petechial haemorrhages on the surface producing so called '*flea-bitten kidney*'* (**Web Image 22.37**).

M/E Most commonly the changes are superimposed on benign nephrosclerosis. These changes are as under (**Web Image 22.36,B**):

i) Vascular changes: These are more severe and involve the arterioles. The two characteristic vascular changes seen are as under:

a) *Necrotising arteriolitis*

b) *Hyperplastic intimal sclerosis or onionskin proliferation.*

ii) Ischaemic changes: The effects of vascular narrowing on the parenchyma include tubular loss, fine interstitial fibrosis and foci of infarction necrosis.

CLINICAL FEATURES. The patients of malignant nephrosclerosis have malignant or accelerated hypertension with blood pressure of 200/140 mmHg or higher. Headache, dizziness and impaired vision are commonly found. The presence of papilloedema distinguishes malignant from benign phase of hypertension. The urine frequently shows haematuria and proteinuria.

THROMBOTIC MICROANGIOPATHY (p. 689)

Thrombotic renal disease encompasses a group of diseases having in common the formation of thrombi composed by platelets and fibrin in arterioles and glomeruli of the kidney and culminating clinically in acute renal failure. Causes of thrombotic microangiopathy of renal microvasculature are listed in **Web Table 22.16**.

PATHOGENESIS In all such cases, endothelial injury appears to be the trigger for vascular changes. The injured endothelial surface causes the following effects:

- ◆ Passage of plasma constituents to the subendothelial zone of microvasculature.
- ◆ Promotes thrombosis.

M/E The features are:

- ◆ Fibrinoid necrosis of arterioles.
- ◆ Thrombi in renal microvasculature.
- ◆ Oedema of intima of arterioles.
- ◆ Consolidation, necrosis and congestion of glomeruli.

RENAL CORTICAL NECROSIS (p. 690)

Renal cortical necrosis is infarction of renal cortex varying from microscopic foci to a situation where most of the renal cortex is destroyed. The medulla, the juxtamedullary cortex and a rim of cortex under the capsule are usually spared. The condition develops most commonly as an obstetrical emergency (e.g. in eclampsia, pre-eclampsia, premature separation of the placenta). Other causes include septic shock, poisoning, severe trauma etc.

The lesions may be present focally, patchily or diffusely. The gross and microscopic characteristics of infarcts of cortex are present.

OBSTRUCTIVE UROPATHY (p. 690)

Obstruction in the urinary tract is common and important because it increases the susceptibility to infection and stone formation. Obstruction can occur at

*Recall the other causes of *flea-bitten kidney*: acute post-streptococcal GN, rapidly progressive GN, haemolytic-uraemic syndrome, thrombotic thrombocytopenic purpura and Henoch-Schonlein purpura.

574 any age and in either sex. The cause of obstruction may lie at any level of the urinary tract—renal pelvis, ureters, urinary bladder and urethra. The obstruction at any of these anatomic locations may be intraluminal, intramural or extramural. Important causes are listed in **Web Table 22.17** and illustrated in **Web Image 22.38**.

NEPHROLITHIASIS (p. 690)

Nephrolithiasis or urolithiasis is formation of urinary calculi at any level of the urinary tract. Urinary calculi are worldwide in distribution. It is estimated that approximately 2% of the population experiences renal stone disease at sometime in their life with male-female ratio of 2:1. Renal calculi are characterised clinically by colicky pain (*renal colic*) as they pass down along the ureter and manifest by haematuria.

Types of Urinary Calculi (p. 691)

There are 4 main types of urinary calculi (**Web Table 22.18**).

1. CALCIUM STONES. Calcium stones are the most common comprising about 75% of all urinary calculi. They may be pure stones of calcium oxalate (50%) or calcium phosphate (5%), or mixture of calcium oxalate and calcium phosphate (45%).

Etiology. Etiology of calcium stones is variable.

- i) About 50% of patients with calcium stones have *idiopathic hypercalciuria without hypercalcaemia*.
- ii) Approximately 10% cases are associated with *hypercalcaemia* and *hypercalciuria*, most commonly due to hyperparathyroidism, or a defect in the bowel (i.e. absorptive hypercalciuria), or in the kidney (i.e. renal hypercalciuria).
- iii) About 15% of patients with calcium stones have *hyperuricosuria with a normal blood uric acid level* and without any abnormality of calcium metabolism.
- iv) In about 25% of patients with calcium stones, the cause is unknown as there is no abnormality in urinary excretion of calcium, uric acid or oxalate and is referred to as '*idiopathic calcium stone disease*'.

Pathogenesis. The mechanism of calcium stone formation is explained on the basis of imbalance between the degree of supersaturation of the ions forming the stone and the concentration of inhibitors in the urine. A number of other predisposing factors contributing to formation of calcium stones are alkaline urinary pH, decreased urinary volume and increased excretion of oxalate and uric acid.

Morphology. Calcium stones are usually small (less than a centimeter), ovoid, hard, with granular rough surface. They are dark brown due to old blood pigment deposited in them as a result of repeated trauma caused to the urinary tract by these sharp-edged stones.

2. MIXED (STRUVITE) STONES. About 15% of urinary calculi are made of magnesium-ammonium-calcium phosphate, often called *struvite*; hence mixed stones are also called as '*struvite stones*' or 'triple phosphate stones'.

Etiology. Struvite stones are formed as a result of infection of the urinary tract with urea-splitting organisms that produce urease such as by species of *Proteus*, and occasionally *Klebsiella*, *Pseudomonas* and *Enterobacter*. These are, therefore, also known as infection-induced stones. However, *E. coli* does not form urease.

Morphology. Struvite stones are yellow-white or grey. They tend to be soft and friable and irregular in shape. 'Staghorn stone' which is a large, solitary stone that takes the shape of the renal pelvis where it is often formed is an example of struvite stone (**Web Image 22.39**).

3. URIC ACID STONES. Approximately 6% of urinary calculi are made of uric acid. Uric acid calculi are *radiolucent* unlike radio-opaque calcium stones.

Etiology. Uric acid stones are frequently formed in cases with hyperuricaemia and hyperuricosuria such as due to primary gout or secondary gout due to myeloproliferative disorders (e.g. in leukaemias), especially those on chemotherapy, and administration of uricosuric drugs (e.g. salicylates, probenacid). Other factors contributing to their formation are acidic urinary pH (below 6) and low urinary volume.

Pathogenesis. As the urine becomes more acidic, the solubility of uric acid in urine decreases and precipitation of uric acid crystals increases favouring the formation of uric acid stones. Hyperuricosuria is the most important factor in the production of uric acid stones, while hyperuricaemia is found in about half the cases.

Morphology. Uric acid stones are smooth, yellowish-brown, hard and often multiple. On cut section, they show laminated structure.

4. CYSTINE STONES. Cystine stones comprise less than 2% of urinary calculi.

Etiology. Cystine stones are associated with cystinuria due to a genetically-determined defect in the transport of cystine and other amino acids across the cell membrane of the renal tubules and the small intestinal mucosa.

Morphology. Cystine stones are small, rounded, smooth and often multiple. They are yellowish and waxy.

5. OTHER CALCULI. Less than 2% of urinary calculi consist of other rare types such as due to inherited abnormality of enzyme metabolism e.g. hereditary xanthinuria developing xanthine stones.

□ **HYDRONEPHROSIS** (p. 692)

Hydronephrosis is the term used for dilatation of renal pelvis and calyces due to partial or intermittent obstruction to the outflow of urine (see Web Image 22.38). Hydroureter nearly always accompanies hydronephrosis. Hydronephrosis may be *unilateral* or *bilateral*.

Unilateral Hydronephrosis (p. 692)

This occurs due to some form of ureteral obstruction at the level of pelviureteric junction (PUJ). The causes are:

- 1. Intraluminal** e.g. a calculus in the ureter or renal pelvis.
- 2. Intramural** e.g. congenital PUJ obstruction, atresia of ureter, inflammatory stricture, trauma, neoplasm of ureter or bladder.
- 3. Extramural** e.g. obstruction of upper part of the ureter by inferior renal artery or vein, pressure on ureter from outside such as carcinoma cervix, prostate, rectum, colon or caecum and retroperitoneal fibrosis.

Bilateral Hydronephrosis (p. 692)

This is generally the result of some form of urethral obstruction but can occur from the various causes listed above if the lesions involve both sides. Based on this, hydronephrosis may be of following types:

- 1. Congenital** e.g. atresia of the urethral meatus, congenital posterior urethral valve.
- 2. Acquired** e.g. bladder tumour involving both ureteric orifices, prostatic enlargement, prostatic carcinoma and prostatitis, bladder neck stenosis, inflammatory or traumatic urethral stricture and phimosis.

G/A The kidneys may have moderate to marked enlargement. Initially, there is *extrarenal hydronephrosis* characterised by dilatation of renal pelvis

576 medially in the form of a sac (**Web Image 22.40,A**). As the obstruction persists, there is progressive dilatation of pelvis and calyces and pressure atrophy of renal parenchyma. Eventually, the dilated pelvi-calyceal system extends deep into the renal cortex so that a thin rim of renal cortex is stretched over the dilated calyces and the external surface assumes lobulated appearance. This advanced stage is called as *intrarenal hydronephrosis* (**Web Image 22.40,B**). An important point of distinction between the sectioned surface of advanced hydronephrosis and polycystic kidney disease (page 657) is the direct continuity of dilated cystic spaces (i.e. dilated calyces) with the renal pelvis in the former (**Web Image 22.41**).

M/E The wall of hydronephrotic sac is thickened due to fibrous scarring and chronic inflammatory cell infiltrate. There is progressive atrophy of tubules and glomeruli along with interstitial fibrosis. Stasis of urine in hydronephrosis causes infection (*pyelitis*) resulting in filling of the sac with pus, a condition called *pyonephrosis*.

□ TUMOURS OF KIDNEY (p. 693)

Both benign and malignant tumours occur in the kidney, the latter being more common. These may arise from *renal tubules* (adenoma, adenocarcinoma), *embryonic tissue* (mesoblastic nephroma, Wilms' tumour), *mesenchymal tissue* (angiomyolipoma, medullary interstitial tumour) and from the *epithelium of the renal pelvis* (urothelial carcinoma). Besides these tumours, the kidney may be the site of the secondary tumours (**Web Table 22.19**).

BENIGN TUMOURS (p. 693)

Cortical Adenoma (p. 693)

Cortical tubular adenomas are more common than other benign renal neoplasms. They are frequently multiple and associated with chronic pyelonephritis or benign nephrosclerosis.

G/A These tumours may form tiny nodules up to 3 cm in diameter. They are encapsulated and white or yellow.

M/E They are composed of tubular cords or papillary structures projecting into cystic space. The cells of the adenoma are usually uniform, cuboidal with no atypicality or mitosis. However, size of the tumour rather than histologic criteria is considered more significant parameter to predict the behaviour of the tumour—those larger than 3 cm in diameter are potentially malignant and metastasising.

Oncocytoma (p. 694)

Oncocytoma is a benign epithelial tumour arising from collecting ducts.

Other Benign Tumours (p. 694)

◆ **Angiomyolipoma** is a hamartoma of the kidney that contains differentiated tissue element derived from blood vessels, smooth muscle and fat.

◆ **Mesoblastic nephroma** is a congenital benign tumour.

◆ **Multicystic nephroma** is another uncommon tumour of early infancy.

◆ **Medullary interstitial cell tumour** is a tiny nodule in the medulla composed of fibroblast-like cells in hyalinised stroma. These tumours used to be called *renal fibromas* but electron microscopy has revealed that the tumour cells are not fibrocytes but are medullary interstitial cells.

◆ **Juxtaglomerular tumour or reninoma** is a rare tumour of renal cortex consisting of sheets of epithelioid cells with many small blood vessels. The tumour secretes excessive quantities of renin and, thus, the patients are likely to have hypertension.

Adenocarcinoma of Kidney (Synonyms: Renal cell carcinoma, Hypernephroma, Grawitz tumour) (p. 694)

Hypernephroma is an old misnomer under the mistaken belief that the tumour arises from adrenal rests because of the resemblance of the tumour cells with clear cells of the adrenal cortex. It is now known that the renal cell carcinoma (RCC) is an adenocarcinoma arising from tubular epithelium. This cancer comprises 70 to 80% of all renal cancers and occurs most commonly in 50 to 70 years of age with male preponderance (2:1).

ETIOLOGY AND PATHOGENESIS. Various etiologic factors implicated in the etiology of RCC are as follows:

1. Tobacco.

2. Genetic factors. Heredity and first-degree relatives of RCC are associated with higher risk. Although majority of cases of RCC are sporadic but about 5% cases are inherited. These cases have following associations: i) *von Hippel-Lindau (VHL) disease*, ii) *Hereditary clear cell RCC*, iii) *Papillary RCC* and iv) *Chromophobe RCC*

3. Cystic diseases of the kidneys.

4. Other risk factors. Besides above, following other factors are associated with higher incidence of RCC:

- i) Exposure to asbestos, heavy metals and petrochemical products.
- ii) In women, obesity and oestrogen therapy.
- iii) Analgesic nephropathy.
- iv) Tuberosus sclerosis.

CLASSIFICATION. Based on cytogenetics of sporadic and familial tumours, RCC has been reclassified into clear cell, papillary, granular cell, chromophobe, sarcomatoid and collecting duct type (**Web Table 22.20**).

G/A RCC commonly arises from the poles of the kidney as a solitary and unilateral tumour, more often in the upper pole. The tumour is generally large, golden yellow and circumscribed. Papillary tumours have grossly visible papillae and may be multifocal. About 1% RCC are bilateral. Cut section of the tumour commonly shows large areas of ischaemic necrosis, cystic change and foci of haemorrhages. Another significant characteristic is the frequent presence of tumour thrombus in the renal vein which may extend into the vena cava (**Web Image 22.42**).

M/E The features are as under:

1. **Clear cell type RCC (70%):** This is the most common pattern. The clear cytoplasm of tumour cells is due to removal of glycogen and lipid from the cytoplasm during processing of tissues. The tumour cells have a variety of patterns: solid, trabecular and tubular, separated by delicate vasculature (**Web Image 22.43**).
2. **Papillary type RCC (15%):** The tumour cells are arranged in papillary pattern over the fibrovascular stalks. The tumour cells are cuboidal with small round nuclei. Psammoma bodies may be seen.
3. **Granular cell type RCC (8%):** The tumour cells have abundant acidophilic cytoplasm. These tumours have more marked nuclear pleomorphism, hyperchromatism and cellular atypia.
4. **Chromophobe type RCC (5%):** This type shows admixture of pale clear cells with perinuclear halo and acidophilic granular cells. The cytoplasm of these tumour cells contains many vesicles.
5. **Sarcomatoid type RCC (1.5%):** This is the most anaplastic and poorly differentiated form. The tumour is characterised by whorls of atypical spindle tumour cells.
6. **Collecting duct type RCC (0.5%):** This is a rare type that occurs in the medulla. It is composed of a single layer of cuboidal tumour cells arranged in tubular and papillary pattern.

578 CLINICAL FEATURES. Renal cell carcinoma is generally a slow-growing tumour and the tumour may have been present for years before it is detected. The classical clinical evidence for diagnosis of renal cell carcinoma is the triad of *gross haematuria*, *flank pain* and *palpable abdominal mass*. By the time the tumour is detected, it has spread to distant sites via haematogenous route to the lungs, brain and bone, and locally to the liver and perirenal lymph nodes.

A number of paraneoplastic syndromes due to ectopic hormone production by the renal cell carcinoma have been described. These include *polycythaemia* (by erythropoietin), *hypercalcaemia* (by parathyroid hormone and prostaglandins), *hypertension* (by renin), effects of *feminisation* or *masculinisation* (by gonadotropins) and *Cushing's syndrome* (by glucocorticoids).

Wilms' Tumour (Synonym: Nephroblastoma) (p. 696)

Nephroblastoma or Wilms' tumour is an embryonic tumour derived from primitive renal epithelial and mesenchymal components. It is the most common abdominal malignant tumour of young children, seen most commonly between 1 to 6 years of age with equal sex incidence.

ETIOLOGY AND PATHOGENESIS. Wilms' tumour has following etiologic associations:

1. A defect in *chromosome 11p13*
2. *Monozygotic twins*
3. Association of Wilms' tumour with some *other congenital anomalies*
4. A few *other malignancies* are known to have higher incidence of Wilms' tumour.

G/A The tumour is usually quite large, spheroidal, replacing most of the kidney. It is generally solitary and unilateral but 5-10% cases may have bilateral tumour. On cut section, the tumour shows characteristic variegated appearance—soft, fishflesh-like grey-white to cream-yellow tumour with foci of necrosis and haemorrhages and grossly identifiable myxomatous or cartilaginous elements (**Web Image 22.44**).

M/C Nephroblastoma shows mixture of primitive epithelial and mesenchymal elements. Most of the tumour consists of small, round to spindle, anaplastic, sarcomatoid tumour cells. In these areas are present abortive tubules and poorly-formed glomerular structures (**Web Image 22.45**). Mesenchymal elements such as smooth and skeletal muscle, cartilage and bone, fat cells and fibrous tissue, may be seen.

CLINICAL FEATURES. The most common presenting feature is a palpable abdominal mass in a child. Other common abnormalities are haematuria, pain, fever and hypertension. The tumour rapidly spreads via blood, especially to lungs.

Secondary Tumours (p. 698)

Leukaemic infiltration of the kidneys is a common finding, particularly in chronic myeloid leukaemia. Kidney is a common site for blood-borne metastases from different primary sites, chiefly from cancers of the lungs, breast and stomach.

LOWER URINARY TRACT (p. 698)

□ **NORMAL STRUCTURE (p. 698)**

The lower urinary tract consists of *ureters*, *urinary bladder* and *urethra*.

URETERS are tubular structures, 30 cm in length and half a centimeter in diameter, and extend from the renal pelvis (pelvi-ureteric junction) to the urinary bladder (vesico-ureteric junction).

M/E Ureter has an outer fibrous investing layer which overlies a thick muscular layer and is lined internally by transitional epithelium or urothelium similar to the lining of the renal pelvis above and bladder below.

URINARY BLADDER lies extraperitoneally and the peritoneum is reflected on its superior surface. Besides *superior* surface (or dome), the bladder has *posterior surface* (or base) and two *lateral surfaces*. The *trigone* is at the base of the bladder and continues as *bladder neck*.

M/E The greater part of the bladder wall is made up of muscular layer (detrusor muscle) having 3 coats—internal, middle and external.

URETHRA runs from the bladder up to the external meatus. The *male urethra* consists of 3 parts—prostatic, membranous and penile. It is lined in the prostatic part by urothelium but elsewhere by stratified columnar epithelium except near its orifice where the epithelium is stratified squamous. The *female urethra* is shorter and runs from the bladder parallel with the anterior wall of the vagina. The mucous membrane in female urethra is lined throughout by columnar epithelium except near the bladder where the epithelium is transitional.

□ CONGENITAL ANOMALIES (p. 698)

DOUBLE URETER. This is a condition in which the entire ureter or only the upper part is duplicated. Double ureter is invariably associated with a double renal pelvis, *one* in the upper part and the *other* in the lower part of the kidney.

URETEROCELE. Ureterocele is cystic dilatation of the terminal part of the ureter which lies within the bladder wall.

ECTOPIA VESICAE (EXSTROPHY). This is a rare condition owing to congenital developmental deficiency of anterior wall of the bladder and is associated with splitting of the overlying anterior abdominal wall. This results in exposed interior of the bladder. If the defect is not properly repaired, the exposed bladder mucosa gets infected repeatedly and may undergo squamous metaplasia with subsequent increased tendency to develop carcinoma of the bladder.

URACHAL ABNORMALITIES. Rarely, there may be persistence of the urachus in which urine passes from the bladder to the umbilicus. More often, part of urachus remains patent which may be the umbilical end, bladder end, or central portion. Persistence of central portion gives rise to *urachal cyst* lined by transitional or squamous epithelium. Adenocarcinoma may develop in urachal cyst.

□ INFLAMMATIONS (p. 698)

Ureteritis (p. 698)

Infection of the ureter is almost always secondary to pyelitis above, or cystitis below. Ureteritis is usually mild but repeated and longstanding infection may give rise to chronic ureteritis.

Cystitis (p. 699)

Inflammation of the urinary bladder is called cystitis. Cystitis may occur by spread of infection from upper urinary tract as seen following renal tuberculosis, or may spread from the urethra such as in instrumentation. Cystitis is caused by a variety of bacterial and fungal infections as discussed in the etiology of pyelonephritis. The most common pathogenic organism in UTI is *E. coli*, followed in decreasing frequency by *Enterobacter*, *Klebsiella*, *Pseudomonas* and *Proteus*. Infection with *Candida albicans* may occur in the bladder in immunosuppressed patients. Besides bacterial and fungal organisms, parasitic infestations such as with *Schistosoma haematobium* is common in the Middle-East countries, particularly in Egypt.

Cystitis, like UTI, is more common in females than in males because of the shortness of urethra which is liable to faecal contamination and due to mechanical trauma during sexual intercourse. In males, prostatic obstruction is a frequent cause of cystitis. All forms of cystitis are clinically characterised by a *triad* of symptoms—*frequency* (repeated urination), *dysuria* (painful or burning micturition) and *low abdominal pain*.

MORPHOLOGIC FEATURES. Cystitis may be acute or chronic.

ACUTE CYSTITIS. G/A The bladder mucosa is red, swollen and haemorrhagic. There may be suppurative exudate or ulcers on the bladder mucosa.

M/E This form of cystitis is characterised by intense neutrophilic exudate admixed with lymphocytes and macrophages.

CHRONIC CYSTITIS. Repeated attacks of acute cystitis lead to chronic cystitis.

G/A The mucosal epithelium is thickened, red and granular with formation of polypoid masses. Long-standing cases result in thickened bladder wall and shrunken cavity.

M/E There is patchy ulceration of the mucosa with formation of granulation tissue in the regions of polypoid masses. Submucosa and muscular coat show fibrosis and infiltration by chronic inflammatory cells. A form of chronic cystitis characterised by formation of lymphoid follicles in the bladder mucosa is termed *cystitis follicularis*.

A few other special forms of cystitis having distinct clinical and morphological appearance are described below.

INTERSTITIAL CYSTITIS (HUNNER'S ULCER). This variant of cystitis occurs in middle-aged women. The patients get repeated attacks of severe and excruciating pain on distension of the bladder, frequency of micturition and great decrease in bladder capacity. The *etiology* of the condition is unknown but it is thought to be neurogenic in origin.

CYSTITIS CYSTICA. As a result of long-standing chronic inflammation, there occurs a downward projection of epithelial nests known as *Brunn's nests* from the deeper layer of bladder mucosa. These epithelial cells may appear as small cystic inclusions in the bladder wall.

MALAKOPLAKIA. This is a rare condition most frequently found in the urinary bladder but can occur in the ureters, kidney, testis and prostate, and occasionally in the gut. The *etiology* of the condition is unknown but probably results from persistence of chronic inflammation with defective phagocytic process by the macrophages.

POLYPOID CYSTITIS. Polypoid cystitis is characterised by papillary projections on the bladder mucosa due to submucosal oedema and can be confused with transitional cell carcinoma. The condition occurs due to indwelling catheters and infection.

Urethritis (p. 699)

Urethritis may be *gonococcal* or *non-gonococcal*.

◆ **Gonococcal (gonorrhoeal) urethritis** is an acute suppurative condition caused by gonococci (*Neisseria gonorrhoeae*).

◆ **Non-gonococcal urethritis** is more common and is most frequently caused by *E. coli*. The infection of urethra often accompanies cystitis in females and prostatitis in males. Urethritis is one of the components in the triad of Reiter's syndrome which comprises arthritis, conjunctivitis and urethritis.

□ TUMOURS OF THE BLADDER (p. 700)

Epithelial (Urothelial) Bladder Tumours (p. 700)

More than 90% of bladder tumours arise from transitional epithelial (urothelium) lining of the bladder in continuity with the epithelial lining of the renal pelvis, ureters, and the major part of the urethra. Though many workers consider all transitional cell tumours as transitional cell carcinoma, others distinguish true transitional cell papilloma from grade I transitional cell carcinoma.

Bladder cancer comprises about 3% of all cancers. Most of the cases appear beyond 5th decade of life with 3-times higher preponderance in males than females.

ETIOPATHOGENESIS. Urothelial tumours in the urinary tract are typically multifocal and the pattern of disease becomes apparent over a period of years. A number of environmental and host factors are associated with increased risk of bladder cancer. These are as under:

1. Industrial occupations.
2. Schistosomiasis.
3. Dietary factors.
4. Local lesions.
5. Smoking.
6. Drugs.

Multicentric nature of urothelial cancer and high rate of recurrence has led to the hypothesis that a *field effect* in the urothelium is responsible for this form of cancer. This is responsible for polychronotropism in bladder cancer i.e. the tumour tends to recur with time and develops at new locations within the urinary tract.

Several cytogenetic abnormalities have been seen in bladder cancer. These include mutations in *p53*, *RB* gene and *p21* gene, all of which are associated with higher rate of recurrences and metastasis.

G/A Urothelial tumours may be single or multiple. About 90% of the tumours are papillary (non-invasive or invasive), whereas the remaining 10% are flat indurated (non-invasive or invasive) (**Web Image 22.46**). The papillary tumours have free floating fern-like arrangement with a broad or narrow pedicle. The non-papillary tumours are bulkier with ulcerated surface (**Web Image 22.47**).

M/E Urothelial tumours are of 3 cell types—transitional cell, squamous cell, and glandular (**Web Table 22.21**).

A. TRANSITIONAL CELL TUMOURS. Approximately 90% of all epithelial tumours of the bladder are transitional cell tumours.

1. Transitional cell papilloma. Papillomas may occur singly or may be multiple. They are generally small, less than 2 cm in diameter, papillary with branching pattern. Each papilla is composed of fibrovascular stromal core covered by normal-looking transitional cells having normal number of layers (upto 6-7) in thickness. The individual cells resemble the normal transitional cells and do not vary in size and shape.

2. Carcinoma *in situ* (CIS). Foci of epithelial hyperplasia, dysplasia and carcinoma *in situ* are seen in other parts of the bladder in non-invasive as well as in invasive carcinomas. Similar foci may be present in the ureters and renal pelvis. The malignant potential of epithelial hyperplasia and dysplasia is uncertain but carcinoma *in situ* is certainly precancerous and is currently included as grade 0 transitional cell carcinoma. Carcinoma *in situ* is characterised by anaplastic malignant cells confined to layers superficial to basement membrane of the bladder mucosa.

3. Transitional cell carcinoma (TCC). This is the commonest cancer of the bladder. The widely accepted classification of Mostofi (1960) adopted by

582 the American Bladder Tumour Registry divides TCC into 3 grades. The basis for this grading depends upon 2 features: the *degree of anaplasia* and the *extent of invasion*.

◆ The *criteria for anaplasia* are: increased cellularity, nuclear crowding, deranged cellular polarity, failure of normal orientation from base to the surface, variation in cell size and shape, variation in nuclear chromatin pattern, mitotic figures and giant cells.

◆ The *criteria for invasion* in papillary as well as non-papillary tumours are: penetration of the basement membrane of bladder mucosa.

Grade I: The tumour cells are clearly transitional type but show increased number of layers of cells (*c.f.* transitional cell papilloma). The individual cells are generally regular but are slightly larger and show mild hyperchromatism.

Grade II: The tumour cells are still recognisable as of transitional cell origin and the number of layers of cells is increased. The individual tumour cells are less regular, larger in size, and show pronounced nuclear hyperchromatism, mitotic activity and loss of polarity. The tumour may or may not be invasive (**Web Image 22.48**).

Grade III: This is the anaplastic or undifferentiated grade of the tumour which is always invasive extending into the bladder wall to variable depth depending upon the clinical stage (described later). The tumour cells are no longer recognisable as of transitional origin. The individual tumour cells show pronounced features of anaplasia such as marked pleomorphism, hyperchromatism, total loss of polarity with loosened surface cells exfoliated in the bladder lumen.

B. SQUAMOUS CELL CARCINOMA. Squamous cell carcinoma comprises about 5% of the bladder carcinomas. Unlike TCC which is mostly papillary and non-ulcerating, most squamous carcinomas of the bladder are sessile, nodular, infiltrating and ulcerating. Association of squamous carcinoma and schistosomiasis has already been highlighted.

C. ADENOCARCINOMA. Adenocarcinoma of the bladder is rare. Adenocarcinoma has association with exostrophy of the bladder with glandular metaplasia, or may arise from urachal rests, periurethral and periprostatic glands, or from cystitis cystica.

STAGING OF BLADDER CANCER. The clinical behaviour and prognosis of bladder cancer can be assessed by the following simple staging system:
Stage 0: Carcinoma confined to the mucosa.

Stage A: Carcinoma invades the lamina propria but not the muscularis.

Stage B1: Carcinoma invades the superficial muscle layer.

Stage B2: Carcinoma invades the deep muscle layer.

Stage C: Carcinoma invades the perivesical tissues.

Stage D1: Carcinoma shows regional metastases.

Stage D2: Carcinoma shows distant metastases.

Non-epithelial Bladder Tumours (p. 702)

These may be benign or malignant.

BENIGN. The most common benign mesenchymal tumour of the bladder is leiomyoma. Other less common examples are neurofibroma, haemangioma and granular cell myoblastoma.

MALIGNANT. Rhabdomyosarcoma is the most frequent malignant mesenchymal tumour. It exists in 2 forms:

Adult form occurring in adults over 40 years of age and resembles the rhabdomyosarcoma of skeletal muscle.

Childhood form occurring in infancy and childhood and appears as large polypoid, soft, fleshy, grapelike mass and is also called *sarcoma botryoides* or *embryonal rhabdomyosarcoma*. It is morphologically

characterised by masses of embryonic mesenchyme consisting of masses of highly pleomorphic stellate cells in myxomatous background. Similar tumours occur in the female genital tract.

TUMOURS OF RENAL PELVIS AND URETERS (p. 702)

Almost all the tumours of the renal pelvis and ureters are of epithelial origin. They are of the same types as are seen in the urinary bladder. However, tumours in the ureters are quite rare.

TUMOURS OF URETHRA (p. 702)

URETHRAL CARUNCLE. Urethral caruncle is not uncommon. It is an inflammatory lesion present on external urethral meatus in elderly females.

G/A The caruncle appears as a solitary, 1 to 2 cm in diameter, pink or red mass, protruding from urethral meatus. It is quite friable and ulcerated.

M/E The mass may be covered by squamous or transitional epithelium or there may be ulcerated surface. The underlying tissues show proliferating blood vessels, fibroblastic connective tissue and intense acute and chronic inflammatory infiltrate. Thus, the histologic appearance closely resembles a *pyogenic granuloma*.

URETHRAL CARCINOMA. Carcinoma of the urethra is uncommon. In most cases it occurs in the distal urethra near the external meatus and thus is commonly squamous cell carcinoma. Less often, there may be transitional cell carcinoma or adenocarcinoma arising from periurethral glands.

◆ SELF ASSESSMENT

1. **Glomerular tuft contains capillaries forming following number of lobules:**

A. Four	B. Six
C. Eight	D. Ten
2. **Azotaemia results from elevation of following waste-products of protein metabolism except:**

A. Blood urea	B. Blood urea nitrogen
C. Serum uric acid	D. Serum creatinine
3. **In end-stage kidney disease, GFR is:**

A. 5% of normal	B. 10% of normal
C. 15% of normal	D. 20% of normal
4. **Infantile polycystic kidney disease has the following features except:**

A. It has autosomal recessive inheritance
B. It is invariably bilateral
C. The condition often manifests in adults
D. The condition is frequently associated with multiple hepatic cysts
5. **The most common features of nephritic syndrome include the following except:**

A. Heavy proteinuria	B. Hypertension
C. Microscopic haematuria	D. Oliguria
6. **The most common form of glomerulonephritis (GN) in adults is:**

A. Minimal change disease	B. Membranous GN
C. Membranoproliferative GN	D. Focal segmental GN
7. **The most frequent form of primary glomerular disease in children is:**

A. Minimal change disease
B. Acute glomerulonephritis
C. Membranous GN
D. Membranoproliferative GN

8. **Examples of immune complex GN include the following except:**
- Acute GN
 - Membranous GN
 - Membranoproliferative GN
 - RPGN in Goodpasture's disease
9. **Classic example of anti-GBM disease is:**
- Minimal change disease
 - Acute GN
 - Membranous GN
 - Goodpasture's disease
10. **Alternate pathway disease occurs in following forms of glomerular disease except:**
- Membranous GN
 - Membranoproliferative GN
 - Rapidly progressive GN
 - IgA nephropathy
11. **Acute post-streptococcal GN is characterised by proteinuria of:**
- Non-selective
 - Selective
 - Albuminuria only
 - Low molecular weight only
12. **The serum markers for RPGN are as follows except:**
- Serum C3 levels
 - Anti-GBM antibody
 - Anti-neutrophil cytoplasmic antibody (ANCA)
 - Anti-endothelial cell antibody (AECA)
13. **In Goodpasture disease, the antigen is:**
- Collagen IV of basement membrane
 - DNA
 - Bacterial products
 - Cationic proteins
14. **Children having minimal change disease have selective proteinuria because of:**
- Reduction of negative charge on GBM
 - Extensive damage to the GBM
 - Deposits of IgG and C3 on GBM
 - Increased mesangial matrix in the glomeruli
15. **Majority of cases of membranous glomerulonephritis have following etiology:**
- SLE
 - Viral infections
 - History of drugs
 - Idiopathic
16. **Basement membrane material in membranous glomerulonephritis appears as:**
- Dense deposits
 - Spikes protruding from GBM
 - Double-contoured
 - Tram-track
17. **Membranoproliferative glomerulonephritis is characterised by lobular proliferation of:**
- Epithelial cells
 - Endothelial cells
 - Mesangial cells
 - Leucocytes
18. **HIV infection commonly produces the following type of glomerular lesions:**
- Membranous GN
 - Membranoproliferative GN
 - Focal GN
 - Focal segmental glomerulosclerosis
19. **The most common and most severe form of lupus nephritis shows the following lesions:**
- Mesangial lupus nephritis
 - Focal segmental lupus nephritis
 - Diffuse proliferative lupus nephritis
 - Membranous lupus nephritis

20. In diabetic nephropathy, the following lesions are specific for juvenile-onset diabetes:
- Diffuse glomerulosclerosis
 - Nodular glomerulosclerosis
 - Diabetic pyelonephritis
 - Armanni-Ebstein lesions
21. In ischaemic ATN, the following holds true *except*:
- There is dilatation of proximal and distal convoluted tubules
 - There is disruption of tubular basement membrane
 - There is diffuse tubular necrosis
 - Tubular lumina contain casts
22. The most common mechanism in pathogenesis of chronic pyelonephritis is:
- Ascending infection
 - Reflux nephropathy
 - Obstructive nephropathy
 - Haematogenous infection
23. Nephrocalcinosis is characterised by deposition of calcium salt at the following locations *except*:
- Basement membrane
 - Within mitochondria
 - Lysosomes
 - Cytoplasm
24. The causes of renal hypertension include the following *except*:
- Fibromuscular dysplasia of renal artery
 - Polyarteritis nodosa
 - Sickle cell nephropathy
 - Polycystic kidney disease
25. Causes of flea-bitten kidney include the following *except*:
- Acute post-streptococcal GN
 - Rapidly progressive GN
 - Haemolytic uraemic syndrome
 - Benign nephrosclerosis
26. The following type of renal calculi are radiolucent:
- Calcium oxalate
 - Struvite
 - Uric acid
 - Calcium phosphate
27. The following type of renal calculi are infection-induced:
- Calcium oxalate
 - Struvite
 - Uric acid
 - Cystine
28. In hereditary renal cell carcinoma (RCC), the following syndrome is implicated in carcinogenesis:
- von Hippel-Lindau disease
 - Polycystic kidney disease
 - Alport's syndrome
 - Fabry's disease
29. Out of various histologic types of renal cell carcinoma, the following type has worst prognosis:
- Clear cell type
 - Granular cell type
 - Sarcomatoid type
 - Papillary type
30. Malakoplakia of the urinary bladder is a form of:
- Dysplasia
 - Metaplasia
 - Papillary hyperplasia
 - Chronic inflammation
31. Schistosomiasis of the urinary bladder is implicated in the following type of bladder tumour:
- Transitional cell carcinoma
 - Squamous cell carcinoma
 - Adenocarcinoma
 - Adenoacanthoma
32. Collapsing sclerosis is a feature of following type of primary glomerular disease:
- Membranoproliferative GN
 - IgA nephropathy
 - Focal segmental glomerulosclerosis
 - Focal glomerulonephritis

- 586 33. Genetic basis of minimal change disease consists of mutation in:
 A. Podocin B. Nephtrin
 C. *Alpha*-3 collagen D. Fibrillin
34. Pseudo-crescent formation is seen in:
 A. Membranous glomerulonephritis
 B. Membranoproliferative glomerulonephritis
 C. Focal segmental glomerulosclerosis
 D. IgA nephropathy
35. All are classes of lupus nephritis except:
 A. Membranoproliferative lupus nephritis
 B. Mesangial lupus nephritis
 C. Focal segmental lupus nephritis
 D. Minimal lesions
36. Prehypertension is defined as blood pressure between:
 A. 110-120/75-80 mm Hg
 B. 120-139/80-89 mm Hg
 C. 130-149/90-95 mm Hg
 D. 140-159/95-99 mm Hg
37. Which of the following is a congenital benign tumour of kidney:
 A. Angiomyolipoma B. Reninoma
 C. Multicystic nephroma D. Mesoblastic nephroma

KEY

- | | | | |
|--------|--------|--------|--------|
| 1 = C | 2 = C | 3 = A | 4 = C |
| 5 = A | 6 = B | 7 = A | 8 = D |
| 9 = D | 10 = A | 11 = A | 12 = D |
| 13 = A | 14 = A | 15 = D | 16 = B |
| 17 = C | 18 = D | 19 = C | 20 = B |
| 21 = C | 22 = B | 23 = C | 24 = C |
| 25 = D | 26 = C | 27 = B | 28 = A |
| 29 = C | 30 = D | 31 = B | 32 = C |
| 33 = B | 34 = C | 35 = A | 36 = B |
| 37 = D | | | |



The Male Reproductive System and Prostate

□ NORMAL STRUCTURE (p. 703)

Contents of the scrotal sac include the testicle and epididymis along with lower end of the spermatic cord and the tunica vaginalis that forms the outer serous investing layer. The epididymis is attached to body of the testis posteriorly. Thus, the testicle and epididymis may be regarded as one organ.

M/E The seminiferous tubules are formed of a lamellar connective tissue membrane and contain several layers of cells (**Web Image 23.1,A**). In the adult, the cells lining the seminiferous tubules are of 2 types:

1. *Spermatogonia* or germ cells which produce spermatocytes (primary and secondary), spermatids and mature spermatozoa.
2. *Sertoli cells* which are larger and act as supportive cells to germ cells, produce mainly androgen (testosterone) and little oestrogen.

The seminiferous tubules drain into collecting ducts which form the rete testis from where the secretions pass into the vasa efferentia. Vasa efferentia opens at the upper end of the epididymis. The lower end of the epididymis is prolonged into a thick muscular tube, the vas deferens, that transports the secretions into the urethra.

The fibrovascular stroma present between the seminiferous tubules contains varying number of *interstitial cells of Leydig*. These cells are the main source of testosterone and other androgenic hormones in males.

□ CONGENITAL ANOMALIES (p. 703)

Cryptorchidism (p. 703)

Cryptorchidism or undescended testis is a condition in which the testicle is arrested at some point along its descent. Its incidence is about 0.2% in adult male population. In 70% of cases, the undescended testis lies in the inguinal ring, in 25% in the abdomen.

ETIOLOGY. The exact etiology is not known in majority of cases. However, a few apparent causes associated with cryptorchidism are as under:

1. **Mechanical factors** e.g. short spermatic cord, narrow inguinal canal, adhesions to the peritoneum.
2. **Genetic factors** e.g. trisomy 13, maldevelopment of the scrotum or cremaster muscles.
3. **Hormonal factors** e.g. deficient androgenic secretions.

MORPHOLOGIC FEATURES. Cryptorchidism is unilateral in 80% cases and bilateral in the rest.

G/A The cryptorchid testis is small in size, firm and fibrotic.

M/E (Web Image 23.1,B): The features are as under:

1. *Seminiferous tubules:* There is progressive loss of germ cell elements so that the tubules may be lined by only spermatogonia and spermatids but foci of spermatogenesis are discernible in 10% of cases.
2. *Interstitial stroma:* There is usually increase in the interstitial fibrovascular stroma and conspicuous presence of Leydig cells.

588 CLINICAL FEATURES. As such, cryptorchidism is completely asymptomatic. However, if surgical correction by orchiopexy is not undertaken by about 2 years of age, or certainly in the prepubertal period, significant adverse clinical outcome may result as under:

1. Sterility-infertility
2. Inguinal hernia
3. Malignancy 30-50 times increased risk

Male Infertility (p. 704)

These causes can be divided into 3 groups: pre-testicular, testicular and post-testicular.

A. Pre-testicular causes:

1. Hypopituitarism
2. Oestrogen excess
3. Glucocorticoid excess
4. Other endocrine disorders

B. Testicular causes:

1. Agonadism
2. Cryptorchidism
3. Maturation arrest
4. Hypospermatogenesis
5. Sertoli cell-only syndrome
6. Klinefelter's syndrome
7. Mumps orchitis
8. Irradiation damage

C. Post-testicular causes:

1. Congenital block
2. Acquired
3. Impaired sperm motility

□ **INFLAMMATIONS (p. 705)**

Non-specific Epididymitis and Orchitis (p. 705)

Non-specific epididymitis and orchitis, or their combination, may be acute or chronic. The common routes of spread of infection are via the vas deferens, or via lymphatic and haematogenous routes. Most frequently, the infection is caused by urethritis, cystitis, prostatitis and seminal vesiculitis. The common infecting organisms in sexually-active men under 35 years of age are *Neisseria gonorrhoeae* and *Chlamydia trachomatis*.

G/A In acute stage the testicle is firm, tense, swollen and congested. There may be multiple abscesses, especially in gonorrhoeal infection.

M/E Acute orchitis and epididymitis are characterised by congestion, oedema and diffuse infiltration by neutrophils, lymphocytes, plasma cells and macrophages or formation of neutrophilic abscesses. Acute inflammation may resolve, or may progress to chronic form. In chronic epididymo-orchitis, there is focal or diffuse chronic inflammation, disappearance of seminiferous tubules, fibrous scarring and destruction of interstitial Leydig cells.

Granulomatous (Autoimmune) Orchitis (p. 705)

Non-tuberculous granulomatous orchitis is a peculiar type of unilateral, painless testicular enlargement in middle-aged men that may resemble a testicular tumour clinically. The exact etiology and pathogenesis of the condition are not known though an autoimmune basis is suspected.

G/A The affected testis is enlarged with thickened tunica.

M/E There are circumscribed non-caseating granulomas lying within the seminiferous tubules. These granulomas are composed of epithelioid cells, lymphocytes, plasma cells, some neutrophils and multinucleate giant cells. The origin of the epithelioid cells is from Sertoli cells lining the tubules.

Tuberculous Epididymo-orchitis (p. 705)

Tuberculosis invariably begins in the epididymis and spreads to involve the testis. Tuberculous epididymo-orchitis is generally secondary tuberculosis from elsewhere in the body. It may occur either by direct spread from genitourinary tuberculosis such as tuberculous seminal vesiculitis, prostatitis and renal tuberculosis, or may reach by haematogenous spread of infection.

G/A Discrete, yellowish, caseous necrotic areas are seen.

M/E Numerous tubercles which may coalesce to form large caseous mass are seen. Characteristics of typical tubercles such as epithelioid cells, peripheral mantle of lymphocytes, occasional multinucleate giant cells and central areas of caseation necrosis are seen (**Web Image 23.2**).

Spermatic Granuloma (p. 705)

Spermatic granuloma is the term used for development of inflammatory lesions due to invasion of spermatozoa into the stroma. Spermatic granuloma may develop due to trauma, inflammation and loss of ligature following vasectomy.

G/A The sperm granuloma is a small nodule, 3 mm to 3 cm in diameter, firm, white to yellowish-brown.

M/E It consists of a granuloma composed of histiocytes, epithelioid cells, lymphocytes and some neutrophils. Characteristically, the centre of spermatic granuloma contains spermatozoa and necrotic debris.

Elephantiasis (p. 706)

Elephantiasis is enormous thickening of the scrotal skin resembling the elephant's hide and results in enlargement of the scrotum. The condition results from filariasis in which the adult worm lives in the lymphatics, while the larvae travel in the blood. The most important variety of filaria is *Wuchereria bancrofti*.

G/A The affected leg and scrotum are enormously thickened with enlargement of regional lymph nodes.

M/E The changes begin with lymphatic obstruction by the adult worms. The worm in alive, dead or calcified form may be found in the dilated lymphatics or in the lymph nodes. Dead or calcified worm in lymphatics is usually followed by lymphangitis with intense infiltration by eosinophils.

MISCELLANEOUS LESIONS (p. 706)

Torsion of Testis (p. 706)

Torsion of the testicle may occur either in a fully-descended testis or in an undescended testis. Torsion is common in boys and young men.

MORPHOLOGIC FEATURES. There may be coagulative necrosis of the testis and epididymis, or there may be haemorrhagic infarction.

Varicocele (p. 706)

Varicocele is the dilatation, elongation and tortuosity of the veins of the pampiniform plexus in the spermatic cord.

- 590 **Primary or idiopathic form** is more frequent and is common in young unmarried men. It is nearly always on the left side as the loaded rectum presses the left vein.
- Secondary form** occurs due to pressure on the spermatic vein by enlarged liver, spleen or kidney.

Hydrocele (p. 706)

A hydrocele is abnormal collection of serous fluid in the tunica vaginalis. It may be acute or chronic, congenital or acquired. The usual causes are trauma, systemic oedema such as in cardiac failure and renal disease, and as a complication of gonorrhoea, syphilis and tuberculosis.

Haematocele (p. 706)

Haematocele is haemorrhage into the sac of the tunica vaginalis. It may result from direct trauma, from injury to a vein by the needle, or from haemorrhagic diseases.

In long-standing cases, the tunica vaginalis is thickened with dense fibrous tissue and occasionally may get partly calcified (**Web Image 23.3**).

TESTICULAR TUMOURS (p. 706)

Testicular tumours are the cause of about 1% of all cancer deaths. They have *trimodal* age distribution—a peak during infancy, another during late adolescence and early adulthood, and a third peak after 60 years of age.

CLASSIFICATION (p. 707)

The most widely accepted classification is the histogenetic classification proposed by the World Health Organisation (**Web Table 23.1**). Based on this, all testicular tumours are divided into 3 groups: *germ cell tumours*, *sex cord-stromal tumours* and *mixed forms*. Vast majority of the testicular tumours (95%) arise from germ cells or their precursors in the seminiferous tubules, while less than 5% originate from sex cord-stromal components of the testis. From clinical point of view, germ cell tumours of the testis are categorised into 2 main groups—seminomatous and non-seminomatous which need to be distinguished (**Web Table 23.2**).

ETIOLOGIC FACTORS (p. 707)

Exact etiology of testicular germ cell tumours is unknown, but the following factors have been implicated:

1. Cryptorchidism. 30-50 times greater
2. Other developmental disorders e.g. dysgenetic gonads
3. Genetic factors: High incidence in first-degree family members, twins.
4. Other factors
 - i) *Orchitis*
 - ii) *Trauma*
 - iii) *Carcinogens*

HISTOGENESIS (p. 707)

Based on current concepts on histogenesis of testicular tumours, following agreements and disagreements have emerged (**Web Image 23.4**):

1. **Developmental disorders.** Disorders such as cryptorchidism, gonadal dysgenesis and androgen insensitivity syndrome are high risk factors for development of testicular germ cell tumours. These observations point to developmental defect in gonadogenesis.
2. **Molecular genetic features.** Testicular germ cell tumours have been found to have several genetic abnormalities suggesting a common molecular pathogenesis of all germ cell tumours:

- i) Hyperdiploidy
- ii) In more than 90% of testicular germ cell tumours, an isochromosome of short arm of chromosome 12 is found.
- iii) Deletion of long arm of chromosome 12
- iv) Telomerase activity
- v) Other mutations include *p53*, *cyclin E* and *FAS* gene.

3. CIS/ITGCN. A preinvasive stage of carcinoma *in situ* (CIS) termed *intratubular germ cell neoplasia (ITGCN)* generally precedes the development of most of the invasive testicular germ cell tumours in adults. Areas of CIS are found in seminiferous tubules adjacent to most seminomas, embryonal carcinomas and other mixed germ cell tumours.

4. 'Three hit' process. Germ cells in seminiferous tubules undergo activation ('*first hit*') before undergoing malignant transformation confined to seminiferous tubules (CIS) ('*second hit*') and eventually into invasive stage by some epigenetic phenomena ('*third hit*').

CLINICAL FEATURES AND DIAGNOSIS (p. 708)

The usual presenting clinical symptoms of testicular tumours are gradual gonadal enlargement and a dragging sensation in the testis.

SPREAD. Testicular tumours may spread by both lymphatic and haematogenous routes:

TUMOUR MARKERS. Two tumour markers widely used in the diagnosis, staging and monitoring the follow-up of patients with testicular tumours are:

- ◆ **hCG** is synthesised by placental syncytio-trophoblast such as in various non-seminomatous germ cell tumours of the testis (e.g. in choriocarcinoma, yolk sac tumour and embryonal carcinoma).

- ◆ **AFP** is normally synthesised by the foetal liver cells, yolk sac and foetal gut. Its levels are elevated in testicular tumours associated with yolk sac components.

PROGNOSIS. For selecting post-orchietomy treatment (radiation, surgery, chemotherapy or all the three) and for monitoring prognosis, 3 clinical stages are defined:

Stage I: tumour confined to the testis.

Stage II: distant spread confined to retroperitoneal lymph nodes below the diaphragm.

Stage III: distant metastases beyond the retroperitoneal lymph nodes.

GERM CELL TUMOURS (p. 709)

Germ cell tumours comprise approximately 95% of all testicular tumours and are more frequent before the age of 45 years. *Testicular germ cell tumours are almost always malignant.* Nearly half of them contain more than one histologic type. Germ cell tumours are also found at the extragonadal sites such as the retroperitoneum and mediastinum, besides their counterparts in the female gonads.

Intratubular Germ Cell Neoplasia (p. 709)

The term intratubular germ cell neoplasia (ITGCN) is used to describe the preinvasive stage of germ cell tumours, notably intratubular seminoma and intratubular embryonal carcinoma. Others have used carcinoma *in situ* (CIS) stage of germ cell tumours as synonymous term.

Classic Seminoma (p. 709)

Seminoma is the commonest malignant tumour of the testis and corresponds to dysgerminoma in the female. It constitutes about 45% of all germ cell tumours, and in another 15% comprises the major component of mixed germ cell tumour. Seminoma is divided into 2 main categories: classic and

592 spermatocytic. Classic seminoma comprises about 93% of all seminomas and has a peak incidence in the 4th decade of life and is rare before puberty. Undescended testis harbours seminoma more frequently as compared to other germ cell tumours.

G/A The involved testis is enlarged up to 10 times its normal size but tends to maintain its normal contour since the tumour rarely invades the tunica. The larger tumour replaces the entire testis, whereas the smaller tumour appears as circumscribed mass in the testis. Cut section of the affected testis shows homogeneous, grey-white lobulated appearance (**Web Image 23.5**).

M/E (Web Image 23.6): The features are as under:

1. Tumour cells. The seminoma cells generally lie in cords, sheets or columns forming lobules. Typically, in a classic seminoma, the tumour cells are fairly uniform in size with clear cytoplasm and well-defined cell borders. The cytoplasm contains variable amount of glycogen that stains positively with PAS reaction. The nuclei are centrally located, large, hyperchromatic and usually contain 1-2 prominent nucleoli.

2. Stroma. The stroma of seminoma is delicate fibrous tissue which divides the tumour into lobules. The stroma shows a characteristic lymphocytic infiltration, indicative of immunologic response of the host to the tumour. About 20% of the tumours show granulomatous reaction in the stroma.

The *prognosis* of classic seminoma is better than other germ cell tumours. The tumour is highly radiosensitive.

Spermatocytic Seminoma (p. 710)

Spermatocytic seminoma is both clinically and morphologically a distinctive tumour from classic seminoma and is, therefore, classified separately in the WHO classification. It is an uncommon tumour having an incidence of about 5% of all germ cell tumours. Spermatocytic seminoma usually occurs in older patients, generally in 6th decade of life.

G/A Spermatocytic seminoma is homogeneous, larger, softer and more yellowish and gelatinous than the classic seminoma.

M/E The features are as under:

1. Tumour cells. The tumour cells vary considerably in size from lymphocyte-like to huge mononucleate or multinucleate giant cells. Majority of the tumour cells are, however, of intermediate size. The cells have eosinophilic cytoplasm devoid of glycogen. The nuclei of intermediate and large cells have filamentous pattern.

2. Stroma. The stroma lacks lymphocytic and granulomatous reaction seen in classic seminoma.

The *prognosis* of spermatocytic seminoma is excellent compared and better than classic seminoma since the tumour is slow-growing and rarely metastasises.

Embryonal Carcinoma (p. 710)

Pure embryonal carcinoma constitutes 30% of germ cell tumours but areas of embryonal carcinoma are present in 40% of germ cell tumours.

G/A Embryonal carcinoma is usually a small tumour in the testis. It distorts the contour of the testis as it frequently invades the tunica and the epididymis. Cut surface of the tumour is grey-white, soft with areas of haemorrhages and necrosis.

M/E The features are as under:

1. The tumour cells are arranged in a variety of *patterns*—glandular, tubular, papillary and solid.

2. The *tumour cells* are highly anaplastic carcinomatous cells having large size, indistinct cell borders, amphophilic cytoplasm and prominent hyperchromatic nuclei showing considerable variation in nuclear size. Mitotic figures and tumour giant cells are frequently present. Haemorrhage and necrosis are common.

3. The *stroma* is not as distinct as in seminoma and may contain variable amount of primitive mesenchyme.

Embryonal carcinoma is more aggressive and less radiosensitive than seminoma.

Yolk Sac Tumour

(Synonyms: Endodermal Sinus Tumour, Orchioblastoma, Infantile Embryonal Carcinoma) (p. 711)

This characteristic tumour is the most common testicular tumour of infants and young children upto the age of 4 years. In adults, however, yolk sac tumour in pure form is rare but may be present as the major component in 40% of germ cell tumours. 100% cases of yolk sac tumours.

G/A The tumour is generally soft, yellow-white, mucoid with areas of necrosis and haemorrhages.

M/E (Web Image 23.7): Following features are seen:

1. The tumour cells form a variety of *patterns*—loose reticular network, papillary, tubular and solid arrangement.
2. The *tumour cells* are flattened to cuboid epithelial cells with clear vacuolated cytoplasm.
3. The tumour cells may form distinctive perivascular structures resembling the yolk sac or endodermal sinuses of the rat placenta called *Schiller-Duval bodies*.
4. There may be presence of both intracellular and extracellular PAS-positive *hyaline globules*, many of which contain AFP.

Polyembryoma (p. 711)

Polyembryoma is defined as a tumour composed predominantly of embryoid bodies.

Choriocarcinoma (p. 711)

Pure choriocarcinoma is a highly malignant tumour composed of elements consisting of syncytiotrophoblast and cytotrophoblast.

However, pure form is extremely rare and occurs more often in combination with other germ cell tumours. The serum and urinary levels of hCG are greatly elevated in 100% cases.

G/A The tumour is usually small and may appear as a soft, haemorrhagic and necrotic mass.

M/E The characteristic feature is the identification of intimately related syncytiotrophoblast and cytotrophoblast without formation of definite placental-type villi.

Teratoma (p. 711)

Teratomas are complex tumours composed of tissues derived from more than one of the three germ cell layers—endoderm, mesoderm and ectoderm. Testicular teratomas are more common in infants and children and constitute about 40% of testicular tumours in infants, whereas in adults they comprise 5% of all germ cell tumours. However, teratomas are found in combination with other germ cell tumours (most commonly with embryonal carcinoma) in about 45% of mixed germ cell tumours.

MORPHOLOGIC FEATURES. G/A Most teratomas are large, grey-white masses enlarging the involved testis. Cut surface shows characteristic

594 variegated appearance—grey-white solid areas, cystic and honey-combed areas, and foci of cartilage and bone (**Web Image 23.8**). Dermoid tumours commonly seen in the ovaries are rare in testicular teratomas.

M/E The three categories of teratomas show different appearances:

1. Mature (differentiated) teratoma. Mature teratoma is composed of disorderly mixture of a variety of well-differentiated structures such as cartilage, smooth muscle, intestinal and respiratory epithelium, mucus glands, cysts lined by squamous and transitional epithelium, neural tissue, fat and bone. This type of mature or differentiated teratoma is the most common, seen more frequently in infants and children and has favourable prognosis. It is believed that *all testicular teratomas in the adults are malignant*.

As mentioned above, dermoid cysts similar to those of the ovary are rare in the testis.

2. Immature teratoma. Immature teratoma is composed of incompletely differentiated and primitive or embryonic tissues along with some mature elements (**Web Image 23.9**). Primitive or embryonic tissue commonly present are poorly-formed cartilage, mesenchyme, neural tissues, abortive eye, intestinal and respiratory tissue elements etc.

3. Teratoma with malignant transformation. This is an extremely rare form of teratoma in which one or more of the tissue elements show malignant transformation.

Mixed Germ Cell Tumours (p. 713)

About 60% of germ cell tumours have more than one of the above histologic types (except spermatocytic seminoma) and are called mixed germ cell tumours. The clinical behaviour of these tumours is worsened by inclusion of more aggressive tumour component in a less malignant tumour.

The most common combinations of mixed germ cell tumours are as under:

1. Teratoma, embryonal carcinoma, yolk sac tumour and syncytiotrophoblast.
2. Embryonal carcinoma and teratoma (teratocarcinoma).
3. Seminoma and embryonal carcinoma.

SEX CORD-STROMAL TUMOURS (p. 713)

Leydig (Interstitial) Cell Tumour (p. 713)

Leydig cell tumours are quite uncommon. They may occur at any age but are more frequent in the age group of 20 to 50 years. Characteristically, these cells secrete androgen, or both androgen and oestrogen, and rarely corticosteroids.

G/A The tumour appears as a small, well-demarcated and lobulated nodule. Cut surface is homogeneously yellowish or brown.

M/E The tumour is composed of sheets and cords of normal-looking Leydig cells. These cells contain abundant eosinophilic cytoplasm and Reinke's crystals and a small central nucleus.

Sertoli Cell Tumours (Androblastoma) (p. 713)

Sertoli cell tumours correspond to arrhenoblastoma of the ovary. They may occur at all ages but are more frequent in infants and children. These tumours may elaborate oestrogen or androgen and may account for gynaecomastia in an adult, or precocious sexual development in a child.

MIXED GERM CELL-SEX CORD STROMAL TUMOURS (p. 713)**Gonadoblastoma** (p. 713)

Dysgenetic gonads and undescended testis are predisposed to develop such combined proliferations of germ cells and sex cord-stromal elements. The patients are commonly intersexuals, particularly phenotypic females.

G/A The tumour is of variable size, yellowish-white and soft.

M/E Gonadoblastoma is composed of 2 principal cell types—large germ cells resembling seminoma cells, and small cells resembling immature Sertoli, Leydig and granulosa cells. Call-Exner bodies of a granulosa cell tumour may be present.

OTHER TUMOURS (p. 713)**Malignant Lymphoma** (p. 713)

Malignant lymphomas comprises 5% of testicular malignancies and is the most common testicular tumour in the elderly.

□ **NORMAL STRUCTURE** (p. 714)

The penis is covered by skin, foreskin (prepuce) and stratified squamous mucosa. The structure of penis consists of 3 masses of erectile tissue—two corpora cavernosa, one on each side dorsally, and the corpus spongiosum ventrally through which the urethra passes. The expanded free end of the corpus spongiosum forms the glans.

The lumen of the urethra in sectioned surface of the penis appears as an irregular cleft in the middle of the corpus spongiosum. In the prostatic part, it is lined by transitional epithelium, but elsewhere it is lined by columnar epithelium except near its orifice where stratified squamous epithelium lines it.

□ **CONGENITAL ANOMALIES** (p. 714)**Phimosis** (p. 714)

Phimosis is a condition in which the prepuce is too small to permit its normal retraction behind the glans. It may be congenital or acquired. *Congenital phimosis* is a developmental anomaly whereas *acquired phimosis* may result from inflammation, trauma or oedema leading to narrowing of preputial opening.

Paraphimosis is a condition in which the phimotic prepuce is forcibly retracted resulting in constriction over the glans penis and subsequent swelling.

Hypospadias and Epispadias (p. 714)

Hypospadias is a developmental defect of the urethra in which the urethral meatus fails to reach the end of the penis, but instead, opens on the ventral surface of the penis. Similar developmental defect with resultant urethral opening on the dorsal surface of the penis is termed *epispadias*.

□ **INFLAMMATIONS** (p. 714)**Balanoposthitis** (p. 714)

Balanoposthitis is the term used for non-specific inflammation of the inner surface of the prepuce (*balanitis*) and adjacent surface of the glans (*posthitis*). It is caused by a variety of microorganisms such as staphylococci, streptococci, coliform bacilli and gonococci. It is a common accompaniment of phimosis.

596 Balanitis Xerotica Obliterans (p. 714)

Balanitis xerotica obliterans is a white atrophic lesion on the glans penis and the prepuce and is a counterpart of the *lichen sclerosus et atrophicus* in the vulva.

□ **BENIGN TUMOURS (p. 714)**

Condyloma Acuminatum (p. 714)

Condyloma acuminatum or anogenital wart is a benign tumour caused by human papilloma virus (HPV) types 6 and 11. The tumour may occur singly, or there may be conglomerated papillomas. A more extensive, solitary, exophytic and cauliflower-like warty mass is termed *giant condyloma* or *Buschke-Löwenstein tumour* or *verrucous carcinoma*.

G/A The tumour consists of solitary or multiple, warty, cauliflower-shaped lesions of variable size with exophytic growth pattern.

M/E The lesions are essentially like common warts (*verruca vulgaris*). The features include formation of papillary villi composed of connective tissue stroma and covered by squamous epithelium which shows hyperkeratosis, parakeratosis, and hyperplasia of prickle cell layer. Many of the prickle cells show clear vacuolisation of the cytoplasm (*koilocytosis*) indicative of HPV infection.

□ **PREMALIGNANT LESIONS (CARCINOMA IN SITU) (p. 714)**

Bowen's Disease (p. 714)

Bowen's disease is located on the shaft of the penis and the scrotum besides the sun-exposed areas of the skin.

G/A It appears as a solitary, circumscribed plaque lesion with ulceration.

M/E The changes are superficial to the dermo-epidermal border. The epithelial cells of the epidermis show hyperplasia, hyperkeratosis, parakeratosis and scattered bizarre dyskeratotic cells.

Erythroplasia of Queyrat (p. 715)

The lesions of erythroplasia of Queyrat appear on the penile mucosa.

G/A The lesions are pink, shiny and velvety soft.

M/E The thickened and acanthotic epidermis shows variable degree of dysplasia.

Bowenoid Papulosis (p. 715)

The lesions of bowenoid papulosis appear on the penile shaft and adjacent genital skin.

□ **MALIGNANT TUMOURS (p. 715)**

Squamous Cell Carcinoma (p. 715)

The incidence of penile carcinoma shows wide variation in different populations. In the United States, the overall incidence of penile cancer is less than 1% of all cancers in males but it is 3-4 times more common in blacks than in whites. Relationship of penile cancer with HPV has been well supported; high-risk HPV types 16 and 18 are strongly implicated and their DNA has been documented in the nuclei of malignant cells. The greatest incidence of penile cancer is between 45 and 60 years.

G/A The tumour is located, in decreasing frequency, on frenum, prepuce, glans and coronal sulcus. The tumour may be cauliflower-like and papillary, or flat and ulcerating (**Web Image 23.10**).

M/E Squamous cell carcinoma of both fungating and ulcerating type is generally well differentiated to moderately-differentiated type which resembles in morphology to similar cancer elsewhere in the body (**Web Image 23.11**).

□ **NORMAL STRUCTURE** (p. 716)

The prostate gland in the normal adult weighs approximately 20 gm. It surrounds the commencement of the male urethra and is composed of 5 lobes during embryonic development—anterior, middle, posterior and two lateral lobes. But at birth, the five lobes fuse to form 3 distinct lobes—two major lateral lobes and a small median lobe (**Web Image 23.12,A**).

M/E The prostate is composed of tubular alveoli (acini) embedded in fibromuscular tissue mass. The glandular epithelium forms infoldings and consists of 2 layers—a basal layer of low cuboidal cells and an inner layer of mucus-secreting tall columnar cells.

Based on hormonal responsiveness, the prostate is divided into 2 separate parts:

- ◆ *the inner periurethral female part* which is sensitive to oestrogen and androgen; and
- ◆ *outer subcapsular true male part* which is sensitive to androgen.

While benign nodular hyperplasia occurs in the periurethral part distorting and compressing the centrally located urethral lumen, the prostatic carcinoma usually arises from the outer subcapsular part in which case it does not compress the urethra (**Web Images 23.12, B, C**).

□ **PROSTATITIS** (p. 716)

Acute Prostatitis (p. 716)

Acute focal or diffuse suppurative inflammation of the prostate is not uncommon. It occurs most commonly due to ascent of bacteria from the urethra, less often by descent from the upper urinary tract or bladder, and occasionally by lymphogenous or haematogenous spread from a distant focus of infection. The infection may occur spontaneously or may be a complication of urethral manipulation such as by catheterisation, cystoscopy, urethral dilatation and surgical procedures on the prostate. The common pathogens are those which cause UTI, most frequently *E. coli*, and others such as *Klebsiella*, *Proteus*, *Pseudomonas*, *Enterobacter*, gonococci, staphylococci and streptococci.

G/A The prostate is enlarged, swollen and tense. Cut section shows multiple abscesses and foci of necrosis.

M/E The prostatic acini are dilated and filled with neutrophilic exudate. There may be diffuse acute inflammatory infiltrate. Oedema, hyperaemia and foci of necrosis frequently accompany acute inflammatory involvement.

Chronic Prostatitis (p. 717)

Chronic prostatitis is more common and foci of chronic inflammation are frequently present in the prostate of men above 40 years of age.

Chronic prostatitis is of 2 types:

- ◆ **Chronic bacterial prostatitis** is caused in much the same way and by the same organisms as the acute prostatitis. It is generally a consequence of recurrent UTI.
- ◆ **Chronic abacterial prostatitis** is more common. There is no history of recurrent UTI and culture of urine and prostatic secretions is always negative, though leucocytosis is demonstrable in prostatic secretions.

598 **G/A** The prostate may be enlarged, fibrosed and shrunken.

M/E The diagnosis of chronic prostatitis is made by foci of lymphocytes, plasma cells, macrophages and neutrophils within the prostatic substance. Corpora amylacea, prostatic calculi and foci of squamous metaplasia in the prostatic acini may accompany inflammatory changes.

Granulomatous Prostatitis (p. 717)

Granulomatous prostatitis is a variety of chronic prostatitis, probably caused by leakage of prostatic secretions into the tissue, or could be of autoimmune origin.

G/A The gland is firm to hard, giving the clinical impression of prostatic carcinoma on rectal examination.

M/E The inflammatory reaction consists of macrophages, lymphocytes, plasma cells and some multinucleate giant cells. The condition may be confused with tuberculous prostatitis.

□ **NODULAR HYPERPLASIA** (p. 717)

Non-neoplastic tumour-like enlargement of the prostate, commonly termed benign nodular hyperplasia (BNH) or benign enlargement of prostate (BEP), is a very common condition in men and considered by some as normal ageing process. It becomes increasingly more frequent above the age of 50 years and its incidence approaches 75-80% in men above 80 years.

ETIOLOGY. The cause of BEP has not been fully established. However, a few etiologic factors such as *endocrinologic, racial, inflammation and arteriosclerosis* have been implicated but endocrine basis for hyperplasia has been more fully investigated and considered a strong possibility in its genesis. A plausible hypothesis suggested is that there is synergistic stimulation of the prostate by both hormones—the *oestrogen* acting to sensitise the prostatic tissue to the growth promoting effect of *dihydroxy-testosterone* derived from plasma testosterone.

G/A The enlarged prostate is nodular, smooth and firm and weighs 2-4 times its normal weight i.e. may weigh up to 40-80 gm. The appearance on cut section varies depending upon whether the hyperplasia is predominantly of the glandular or fibromuscular tissue (**Web Image 23.13**). In *primarily glandular BEP* the tissue is yellow-pink, soft, honey-combed, and milky fluid exudes, whereas in *mainly fibromuscular BEP* the cut surface is firm, homogeneous and does not exude milky fluid.

M/E In every case, there is hyperplasia of all three tissue elements in varying proportions—glandular, fibrous and muscular (**Web Image 23.14**):

◆ *Glandular hyperplasia* predominates in most cases and is identified by exaggerated intra-acinar papillary infoldings with delicate fibrovascular cores.

◆ *Fibromuscular hyperplasia* when present as dominant component appears as aggregates of spindle cells forming an appearance akin to fibromyoma of the uterus.

CLINICAL FEATURES. Clinically, the symptomatic cases develop symptoms due to complications such as urethral obstruction and secondary effects on the bladder (e.g. hypertrophy, cystitis), ureter (e.g. hydronephrosis) and kidneys (e.g. hydronephrosis). The presenting features include frequency, nocturia, difficulty in micturition, pain, haematuria and sometimes, the patients present with acute retention of urine requiring immediate catheterisation.

□ **CARCINOMA OF PROSTATE** (p. 718)

Cancer of the prostate is the second most common form of cancer in males, followed in frequency by lung cancer. It is a disease of men above the age of 50 years and its prevalence increases with increasing age so

that more than 50% of men 80 years old have asymptomatic (latent) carcinoma of the prostate. Thus, it is common to classify carcinoma of the prostate into the following 4 types:

1. Latent carcinoma
2. Incidental carcinoma
3. Occult carcinoma
4. Clinical carcinoma

ETIOLOGY. The cause of prostatic cancer remains obscure. However, a few factors have been suspected. These are as under:

1. **Endocrinologic factors.** Androgens are considered essential for development and maintenance of prostatic epithelium.
2. **Racial and geographic influences.** There are some racial and geographic differences in the incidence of prostatic cancer.
3. **Environmental influences.** Some common environmental factors and carcinogens have been identified with high risk to development of prostatic cancer. These include high dietary fat, and exposure to polycyclic aromatic hydrocarbons. Flavonoids, antioxidants and selenium may reduce the risk.
4. **Nodular hyperplasia.** Though nodular prostatic hyperplasia has been suggested by some as precursor for development of prostatic cancer, it is considered unlikely. Approximately 15-20% of nodular hyperplastic prostates harbour carcinoma.
5. **Heredity.** The possibility of genetic basis of prostatic cancer has been suggested by the observations of familial clustering and 2-fold higher frequency in first-degree relatives.

HISTOGENESIS. Histogenesis of prostatic adenocarcinoma has been documented as a multistep process arising from premalignant stage of *prostatic intraepithelial neoplasia (PIN)*. Based on cytologic atypia, PIN may be low grade to high grade. PIN of high-grade progresses to prostatic adenocarcinoma.

G/A The prostate may be enlarged, normal in size or smaller than normal. In 95% of cases, prostatic carcinoma is located in the peripheral zone, especially in the posterior lobe. The malignant prostate is firm and fibrous. Cut section is homogeneous and contains irregular yellowish areas.

M/E 4 histologic types are described—adenocarcinoma, transitional cell carcinoma, squamous cell carcinoma and undifferentiated carcinoma. However, *adenocarcinoma* is the most common type found in 96% of cases and is the one generally referred to as carcinoma of the prostate.

The histologic characteristics of adenocarcinoma of the prostate are as under (**Web Image 23.15**):

1. **Architectural disturbance.** In contrast to convoluted appearance of the glands seen in normal and hyperplastic prostate, there is loss of intracinar papillary convolutions. The groups of acini are either closely packed in back-to-back arrangement without intervening stroma or are haphazardly distributed.
2. **Stroma.** Normally, fibromuscular sling surrounds the acini, whereas malignant acini have little or no stroma between them.
3. **Gland pattern.** Most frequently, the glands in well-differentiated prostatic adenocarcinoma are small or medium-sized, lined by a single layer of cuboidal or low columnar cells. Moderately-differentiated tumours have cribriform or fenestrated glandular appearance.
4. **Tumour cells.** In many cases, the individual tumour cells in prostatic carcinoma do not show usual morphologic features of malignancy. The tumour cells may be clear, dark and eosinophilic cells.
5. **Invasion.** One of the important diagnostic features of malignancy in prostate is the early and frequent occurrence of invasion of intra-prostatic *perineural spaces*.

600 **SPREAD.** It may spread by following routes:

Direct spread. Direct extension of the tumour occurs into the prostatic capsule and beyond.

Metastases. Distant spread occurs by both lymphatic and haematogenous routes. Haematogenous spread leads most often to characteristic osteoblastic *osseous metastases*, especially to pelvis, and lumbar spine; other sites of metastases are lungs, kidneys, breast and brain. The route of blood-borne metastases may be retrograde spread by prostatic venous plexus or via systemic circulation.

CLINICAL FEATURES. By the time symptoms appear, the carcinoma of prostate is usually palpable on rectal examination as a hard and nodular gland fixed to the surrounding tissues. In such symptomatic cases, clinical features are: urinary obstruction with dysuria, frequency, retention of urine, haematuria, and in 10% of cases pain in the back due to skeletal metastases.

Clinical staging has good correlation with histologic grading and, thus, has a prognostic significance. *Mostofi's (WHO) histologic grading* categorising prostate cancer into grade I (well-differentiated), grade II (moderately differentiated) and grade III (poorly differentiated) has largely been replaced with *Gleason's microscopic grading system* which is based on two features:

- i) Degree of glandular differentiation.
- ii) Growth pattern of the tumour in relation to the stroma.

Two serum *tumour markers* employed commonly for diagnosis and monitoring the prognosis of prostatic carcinoma are as under:

◆ **Prostatic acid phosphatase (PAP)** is secreted by prostatic epithelium. Elevation of serum level of PAP is found in cases of prostatic cancer which have extended beyond the capsule or have metastasised.

◆ **Prostate-specific antigen (PSA)** can be detected by immuno-histochemical method in the malignant prostatic epithelium as well as estimated in the serum. A reading between 4 and 10 (normal 0-4 ng/ml) is highly suspicious (10% risk) but value above 10 is diagnostic of prostatic carcinoma. PSA assay is useful in deciding whether the metastasis originated from the prostate or not. PSA level is generally higher in low-grade tumours than in high-grade tumours.

◆ **SELF ASSESSMENT**

1. In an undescended testis the risk of developing a testicular malignancy is increased to average of:
 - A. 20 fold
 - B. 25 fold
 - C. 30 fold
 - D. 35 fold
2. In an undescended testis, the following tumour develops most often:
 - A. Seminoma
 - B. Teratoma
 - C. Choriocarcinoma
 - D. Yolk sac tumour
3. Granulomatous orchitis is the term used for inflammation of testis due to following etiology:
 - A. Tuberculosis
 - B. Sarcoidosis
 - C. Autoimmune
 - D. Leprosy
4. The origin of epithelioid cells in autoimmune orchitis is from:
 - A. Macrophages
 - B. Sertoli cells
 - C. Leydig cells
 - D. Spermatogenic cells
5. Seminoma is a:
 - A. Benign tumour
 - B. Borderline tumour
 - C. Malignant tumour
 - D. Locally aggressive tumour

6. **Sequential tumorigenesis in seminomatous tumours involves:**
 - A. Single hit
 - B. Double hit
 - C. Triple hit
 - D. Multiple hits
7. **Spermatocytic seminoma differs from classic seminoma in the following respects except:**
 - A. It occurs in older age (past 6th decade)
 - B. Tumour cells are pleomorphic
 - C. The stroma lacks lymphocytic infiltrate
 - D. The tumour has worse prognosis
8. **AFP levels are elevated in 100% cases of following type of germ cell tumour:**
 - A. Seminoma
 - B. Embryonal carcinoma
 - C. Yolk sac tumour
 - D. Choriocarcinoma
9. **All types of testicular teratomas in adults are:**
 - A. Benign tumours
 - B. Borderline tumours
 - C. Locally aggressive tumours
 - D. Malignant tumours
10. **The most common testicular tumour in the elderly is:**
 - A. Seminoma
 - B. Teratoma
 - C. Malignant lymphoma
 - D. Leydig cell tumour
11. **The following penile lesions are considered as *in situ* carcinoma except:**
 - A. Condyloma acuminatum
 - B. Bowen's disease
 - C. Erythroplasia of Queyrat
 - D. Bowenoid papulosis
12. **Prostatic hyperplasia affects most often:**
 - A. Peripheral prostate
 - B. Periurethral prostate
 - C. Capsule of prostate
 - D. Entire prostate
13. **Normally prostatic tissue responds to hormones as under:**
 - A. Periurethral prostate responds to oestrogen as well as androgen
 - B. Outer prostate responds to androgen as well as oestrogen
 - C. Periurethral prostate responds to rising level of oestrogen
 - D. Outer prostate responds to rising level of oestrogen
14. **Prostatic acid phosphatase (PAP) levels given below are diagnostic of prostatic carcinoma:**
 - A. 1-2 KA units
 - B. 2-3 KA units
 - C. 3-5 KA units
 - D. 5-7 KA units
15. **Metastasis to the following tissues occur early in prostatic carcinoma:**
 - A. Vertebrae
 - B. Obturator lymph node
 - C. Lungs
 - D. Brain
16. **Areas of intratubular germ cell neoplasia (ITGCN) are frequently found in seminiferous tubules adjacent to the following tumours except:**
 - A. Seminoma
 - B. Spermatocytic seminoma
 - C. Embryonal carcinoma
 - D. Immature teratoma
17. **Classic seminoma cells show positivity for which special stain?**
 - A. Mucicarmine
 - B. PAS
 - C. Alcian blue
 - D. Masson's trichrome
18. **Classic perivascular structures seen in yolk sac tumours are known as:**
 - A. Schiller -Duval bodies
 - B. Call-Exner bodies
 - C. Michaelis-Guttman bodies
 - D. Russel bodies
19. **Latent prostatic carcinoma is:**
 - A. Incidental carcinoma prostate found in prostatectomies done for BEH
 - B. Small focus of prostate carcinoma found during autopsy
 - C. Asymptomatic carcinoma of prostate presenting with metastasis on investigation
 - D. Prostatic carcinoma in-situ

- 602 20. Granulomatous prostatitis occurs due to:
- A. Tuberculosis
 - B. Sarcoidosis
 - C. Autoimmune
 - D. Syphilis

KEY

1 = D	2 = A	3 = C	4 = B
5 = C	6 = C	7 = D	8 = C
9 = D	10 = C	11 = A	12 = B
13 = A	14 = D	15 = B	16 = B
17 = B	18 = A	19 = B	20 = C



The Female Genital Tract

□ NORMAL STRUCTURE (p. 721)

The vulva consists of structures of ectodermal origin—labia majora, labia minora, mons pubis, clitoris, vestibule, hymen, Bartholin's glands and minor vestibular glands. The mons pubis and labia majora are covered externally by skin with hair follicles, sebaceous glands and sweat glands including apocrine glands. The inner surface of labia majora, labia minora and vestibule are covered by stratified squamous epithelium. The clitoris is made up of vascular erectile tissue. Bartholin's or vulvovaginal glands are located one on each side of the mass of tissue forming labia majora.

□ BARTHOLIN'S CYST AND ABSCESS (p. 721)

Inflammation of Bartholin's vulvovaginal glands (Bartholin's adenitis) may occur due to bacterial infection, notably gonorrhoeal infection.

◆ **Acute Bartholin's adenitis** occurs from obstruction and dilatation of the duct by infection resulting in formation of a Bartholin's abscess. The condition presents with intense pain, swelling and fluctuant mass which can be incised and drained.

◆ **Chronic Bartholin's adenitis** results from a less virulent infection so that the process is slow and prolonged. Alternatively, the chronic process evolves from repeated attacks of less severe acute inflammation which may be short of abscess formation and resolves incompletely. In either case, the chronic inflammatory process terminates into fluid-filled Bartholin's cyst.

M/E Shows variable lining of the cyst varying from the transitional epithelium of the normal duct to a flattened lining because of increased intracystic pressure. The cyst wall may show chronic inflammatory infiltrate and a few mucus-secreting acini.

□ NON-NEOPLASTIC EPITHELIAL DISORDERS (p. 721)

The older nomenclature vulvar dystrophy has been replaced by more descriptive and clinically relevant term, non-neoplastic epithelial disorders of vulvar skin and mucosa of vulva. The term is applied to chronic lesions of the vulva characterised clinically by white, plaque-like, pruritic mucosal thickenings and pathologically by disorders of epithelial growth. Clinicians often use the term '*leukoplakia*' for such white lesions.

Currently, non-neoplastic epithelial disorders of the skin of vulva includes following 2 lesions:

1. Lichen sclerosus (older term: atrophic dystrophy).
2. Squamous hyperplasia (older term: hyperplastic dystrophy).

Lichen Sclerosus (p. 721)

Lichen sclerosus may occur anywhere in the skin but is more common and more extensive in the vulva in post-menopausal women. The lesions appear as multiple, small, coalescent, yellowish-blue macules or papules which produce thin and shiny parchment-like skin. The lesions may extend from vulva onto the perianal and perineal area. Eventually, there is progressive

604 shrinkage and atrophy resulting in narrowing of the introitus, clinically referred to as *kraurosis vulvae*.

M/E (Web Image 24.1,A): The features are:

1. Hyperkeratosis of the surface layer.
 2. Thinning of the epidermis with disappearance of rete ridges.
 3. Amorphous homogeneous degenerative change in the dermal collagen.
 4. Chronic inflammatory infiltrate in the mid-dermis.
- Lichen sclerosus is *not* a premalignant lesion and responds.

Squamous Hyperplasia (p. 722)

Squamous hyperplasia is characterised by white, thickened vulvar lesions which are usually itchy.

M/E (Web Image 24.1,B): The features are:

1. Hyperkeratosis.
2. Hyperplasia of squamous epithelium with elongation of rete ridges.
3. Increased mitotic activity of squamous layers but cytologically no atypia.
4. Chronic inflammatory infiltrate in the underlying dermis.

A small proportion of cases of hyperplastic dystrophy (1-4%) may show cytologic atypia and produce vulvar dysplasia which may progress to vulvar carcinoma *in situ* and invasive carcinoma.

VULVAL TUMOURS (p. 722)

Stromal Polyps (p. 722)

Stromal (fibroepithelial) polyps or acrochordons may form in the vulva or vagina. There may be single or multiple polypoid masses.

M/E They are covered by an orderly stratified squamous epithelium. The stroma consists of loose fibrous and myxomatous connective tissue with some adipose tissue and blood vessels.

Papillary Hidradenoma (Hidradenoma Papilliferum) (p. 722)

This is a benign tumour arising from apocrine sweat glands of the vulva. Most commonly, it is located in the labia or in the perianal region as a small sharply circumscribed nodule.

M/E The tumour lies in the dermis under a normal epidermis. The tumour consists of papillary structures composed of fibrovascular stalk and is covered by double layer of epithelial cells—a layer of flattened myoepithelial cells and an overlying layer of columnar cells.

Condyloma Acuminatum (p. 722)

Condyloma acuminata or anogenital warts are benign papillary lesions of squamous epithelium which can be transmitted venereally to male sex partner. They may be solitary but more frequently are multiple forming soft warty masses. The common locations are the anus, perineum, vaginal wall, vulva and vagina. They are induced by human papilloma virus (HPV), particularly types 6 and 11.

M/E They are identical to their counterparts on male external genitalia. The features consist of a tree-like proliferation of stratified squamous epithelium, showing marked acanthosis, hyperkeratosis, parakeratosis, papillomatosis and perinuclear vacuolisation of epithelium called *koilocytosis*, indicative of HPV infection.

Extra-Mammary Paget's Disease (p. 722)

Paget's disease of the vulva is a rare condition which has skin manifestations like those of Paget's disease of the nipple.

M/E Extra-mammary Paget's disease is identified by the presence of large, pale, carcinoma cells lying singly or in small clusters within the epidermis and adnexal structures. These cells characteristically have halo which stains positively with PAS, alcian blue and mucicarmine and are thus believed to be of apocrine epithelial origin.

Extra-mammary Paget's disease is confined to the epidermis in most cases and only a small proportion of cases have an underlying adenocarcinoma.

Vulval Intraepithelial Neoplasia and Invasive Carcinoma (p. 723)

Vulval intraepithelial neoplasia (VIN) and invasive squamous cell carcinoma are morphologically similar to those in the cervix and vagina. The etiologic role of certain viruses in carcinogenesis, particularly high-risk HPV types 16 and 18, in these sites is well documented. The usual age for development of cancer or VIN is the 4th to 6th decade.

G/A VIN and vulval carcinoma in early stage is a 'white' lesion (leukoplakia) while later the area develops an exophytic or endophytic (ulcerative) growth pattern.

M/E These lesions are squamous cell type with varying anaplasia and depth of invasion depending upon the stage (**Web Image 24.2**). HPV-positive tumours are more often poorly-differentiated squamous cell carcinoma while HPV-negative are well-differentiated keratinising type. *Verrucous carcinoma* is a rare variant which is a fungating tumour but is locally malignant.

Clinical staging for vulval carcinoma based on tumour size (< or > 2 cm) and extent of spread has been described by International Federation of Gynaecology and Obstetrics (FIGO staging, **Web Table 24.1**).

□ **NORMAL STRUCTURE (p. 723)**

The vagina consists of a collapsed cylinder extending between vestibule externally and the cervix internally.

M/E The vaginal wall consists of 3 layers: an *outer* fibrous, a *middle* muscular and an *inner* epithelial. The muscular coat has a double layer of smooth muscle. The epithelial layer consists of stratified squamous epithelium which undergoes cytologic changes under hormonal stimuli.

□ **VAGINITIS AND VULVOVAGINITIS (p. 723)**

Since vulva and vagina are anatomically close to each other, often inflammation of one affects the other location. Certain other infections are quite common in the vulva and vagina as follows:

- ◆ Bacterial e.g. streptococci, staphylococci, *Escherichia coli*, *Haemophilus vaginalis*.
- ◆ Fungal e.g. *Candida albicans*.
- ◆ Protozoal e.g. *Trichomonas vaginalis*.
- ◆ Viral e.g. Herpes simplex.

The most common causes of vaginitis are *Candida* (moniliasis) and *Trichomonas* (trichomoniasis).

□ **TUMOURS AND TUMOUR-LIKE CONDITIONS (p. 723)**

Vaginal cysts such as Gartner's duct (Wolffian) cyst lined by glandular epithelium and vaginal inclusion cyst arising from inclusion of vaginal epithelium are more common benign vaginal tumours and tumour-like conditions. Other uncommon benign tumours are papillomas, fibromas, lipomas, angiomas and leiomyomas and resemble their counterparts elsewhere in the body.

606 Carcinoma of Vagina (p. 724)

Primary carcinoma of the vagina is an uncommon tumour. Squamous cell dysplasia or vaginal intraepithelial neoplasia occur less frequently as compared to the cervix or vulva and can be detected by Pap smears. Invasive carcinoma of the vagina includes two main types:

1. **Squamous cell carcinoma** of vagina constitutes less than 2% of all gynaecologic malignancies. The role of HPV types 16 and 18 in its etiology and the possibility of an extension from cervical carcinoma to the vagina have been emphasised.
2. **Adenocarcinoma of the vagina** is much less than squamous cell carcinoma of the vagina. It may be endometrioid or mucinous type.

Clinical staging of carcinoma of vagina proposed by FIGO is given in **Web Table 24.2**.

Embryonal Rhabdomyosarcoma (Sarcoma Botyroides) (p. 724)

This is an unusual and rare malignant tumour occurring in infants and children under 5 years of age. The common location is anterior vaginal wall. Similar tumours may occur in the urinary bladder, head and neck region (orbit, nasopharynx, middle ear, oral cavity) and biliary tract.

G/A The tumour is characterised by bulky and polypoid grape-like mass (*botyroides* = grape) that fills and projects out of the vagina.

M/E The features are as under:

1. Groups of round to fusiform tumour cells are characteristically lying underneath the vaginal epithelium, called *cambium layer* of tumour cells.
2. The central core of polypoid masses is composed of loose and myxoid stroma with many inflammatory cells.

□ NORMAL STRUCTURE (p. 724)

The cervix consists of an *internal os* communicating with the endometrial cavity above, and an *external os* opening into the vagina below. *Ectocervix* (exocervix) or *portio vaginalis* is the part of the cervix exposed to the vagina and is lined by stratified squamous epithelium, whereas the endocervix is continuous with the endocervical canal and is lined by a single layer of tall columnar mucus-secreting epithelium. The junction of the ectocervix and endocervix—*junctional mucosa*, consists of gradual transition between squamous and columnar epithelia (squamo-columnar junction) and is clinically and pathologically significant landmark.

□ CERVICITIS (p. 724)

Some degree of cervical inflammation is present in virtually all multiparous women and some nulliparous women. The normal intact ectocervical stratified epithelium is usually more resistant to infection whereas the endocervical columnar epithelium bears the brunt of the initial inflammation.

Cervicitis may be specific or nonspecific, acute or chronic. *Specific cervicitis* may be caused by tuberculosis, syphilis, granuloma inguinale, lymphogranuloma venereum, chlamydia and chancroid.

ACUTE CERVICITIS. Acute cervicitis is usually associated with puerperium or gonococcal infection. Other causes are primary chancre and infection with herpes simplex.

G/A The cervix shows everted endocervical mucosa which is red and oedematous.

M/E There is infiltration of the subepithelial and periglandular tissue with neutrophils, and there is oedema and congestion. The mucosa may be ulcerated and haemorrhagic.

CHRONIC CERVICITIS. The most common organisms responsible for chronic cervicitis are the normal mixed vaginal flora that includes streptococci, enterococci (e.g. *E. coli*) and staphylococci. Other infecting organisms include gonococci, *Trichomonas vaginalis*, *Candida albicans* and herpes simplex. Factors predisposing to chronic cervicitis are sexual intercourse, trauma of childbirth, instrumentation and excess or deficiency of oestrogen.

G/A There is eversion of ectocervix with hyperaemia, oedema and granular surface. Nabothian (retention) cysts may be grossly visible from the surface as pearly grey vesicles.

M/E Chronic cervicitis is characterised by extensive subepithelial inflammatory infiltrate of lymphocytes, plasma cells, large mononuclear cells and a few neutrophils. There may be formation of lymphoid follicles termed *follicular cervicitis*. The surface epithelium may be normal, or may show squamous metaplasia. The squamous epithelium of the ectocervix in cases of uterine prolapse may develop surface keratinisation and hyperkeratosis, so called *epidermidisation*.

□ TUMOURS (p. 725)

Cervical Polyps (p. 725)

Cervical polyps are localised benign proliferations of endocervical mucosa though they may protrude through the external os. They are found in 2-5% of adult women and produce irregular vaginal spotting.

G/A Cervical polyp is a small (up to 5 cm in size), bright red, fragile growth which is frequently pedunculated but may be sessile.

M/E Most cervical polyps are endocervical polyps and are covered with endocervical epithelium which may show squamous metaplasia. The stroma of the polyp is composed of loose and oedematous fibrous tissue with variable degree of inflammatory infiltrate and contains dilated mucus-secreting endocervical glands (**Web Image 24.3**).

Microglandular Hyperplasia (p. 725)

Microglandular hyperplasia is a benign condition of the cervix in which there is closely packed proliferation of endocervical glands without intervening stroma. The condition is caused by progestin stimulation such as during pregnancy, postpartum period and in women taking oral contraceptives.

Squamous Intraepithelial Lesion (SIL) (Cervical Intraepithelial Neoplasia, CIN) (p. 725)

TERMINOLOGY. Presently, the terms dysplasia, CIN, carcinoma *in situ*, and SIL are used synonymously as follows:

DYSPLASIA. The term 'dysplasia' (meaning 'bad moulding') has been commonly used for atypical cytologic changes in the layers of squamous epithelium, the changes being progressive. Depending upon the thickness of squamous epithelium involved by atypical cells, dysplasia is conventionally graded as *mild*, *moderate* and *severe*. Carcinoma *in situ* is the full-thickness involvement by atypical cells, or in other words carcinoma confined to layers above the basement membrane. It is well accepted that invasive cervical cancer evolves through progressive stages of dysplasia and carcinoma *in situ*.

CIN. An alternative classification is to group various grades of dysplasia and carcinoma *in situ* together into cervical intraepithelial neoplasia (CIN)

◆ *CIN-1* represents less than one-third involvement of the thickness of epithelium (mild dysplasia).

◆ *CIN-2* is one-third to two-third involvement (moderate dysplasia).

◆ *CIN-3* is full-thickness involvement or equivalent to carcinoma *in situ* (severe dysplasia and carcinoma *in situ*).

SIL. Currently, the National Cancer Institute (NCI) of the US has proposed the *Bethesda System (TBS)* for reporting cervical and vaginal cytopathology. According to the Bethesda system, based on cytomorphologic features and HPV types implicated in their etiology, the three grades of CIN are readjusted into two grades of squamous intraepithelial lesions (SIL)—low-grade SIL (L-SIL) and high-grade SIL (H-SIL) as under:

◆ *L-SIL* corresponds to CIN-1 and is a flat condyloma, having koilocytic atypia, usually related to HPV 6 and 11 infection (i.e. includes mild dysplasia and HPV infection).

◆ *H-SIL* corresponds to CIN-2 and 3 and has abnormal pleomorphic atypical squamous cells. HPV 16 and 18 are implicated in the etiology of H-SIL (i.e. includes moderate dysplasia, severe dysplasia, and carcinoma *in situ*).

A comparison of these classifications is shown in **Web Table 24.3**.

Progressive grades of dysplasia/CIN/SIL is a classical example of progression of malignancy through stepwise epithelial changes and that it can be detected early by simple Papanicolaou cytologic test ('Pap smear'). The use of Pap smear followed by colposcopy and biopsy confirms the diagnosis which has helped greatly in instituting early effective therapy and thus has reduced the incidence of cervical cancer in the West.

ETIOPATHOGENESIS. The biology of CIN/SIL and its relationship to invasive carcinoma of the cervix is well understood by epidemiologic, virologic, molecular, immunologic and ultrastructural studies (**Web Image 24.4**):

1. Epidemiologic studies. Based on epidemiology of large population of women with cervical cancer, several risk factors have been identified which include the following 4 most important factors:

- i) Women having *early age of sexual activity*.
- ii) Women having *multiple sexual partners*.
- iii) Women with *persistent HPV infection* with high-risk types of oncogenic virus.
- iv) *Potential role of high risk male sexual partner* such as promiscuous male having previous multiple sexual partners, having history of penile condyloma, or male who had previous spouse with cervical cancer.

In addition to the above factors, other epidemiologic observations reveal high incidence of cervical cancer in lower socioeconomic strata, in multiparous women, promiscuous women, cigarette smoking women, users of oral contraceptives, HIV infection and immunosuppression, while a low incidence is noted in virgins and nuns.

2. Virologic studies. Human papilloma virus (HPV) infection is strongly implicated in the etiology of cervical cancer. By recombinant DNA hybridisation techniques, following observations have been documented:

◆ *High-risk type HPV*, most commonly of types 16 and 18 (in 70% cases), and less often types 31, 33, 52 and 58, are present in 70-100% cases of cervical cancer.

◆ *Low-risk type HPV* types 6 and 11 are found most frequently in condylomas.

◆ *Mixed high and low risk types* of HPV may be found in dysplasias.

3. Molecular studies. Immunohistochemical, cytogenetic and molecular studies have shown that low-risk HPV types do not integrate in the host cell genome, while high-risk HPV types are integrated into the nucleus of cervical epithelial cells. Upon integration, protein product of HPV-16 and 18, E7 and E6 proteins respectively, inactivate tumour suppressor genes, *p53* and *RB-1 gene*, thus permitting uncontrolled cellular proliferation. Women who have persistence of this infection or those who have another cofactor such as cigarette smoking or immunodeficiency, are at greater risk to develop progression of lesions.

4. Immunologic studies. Circulating tumour specific antigens and antibodies are detected in patients of cervical cancer.

5. Ultrastructural studies. The changes observed on ultrastructural studies of cells in CIN/SIL reveal increased mitochondria and free ribosomes, and depletion of normally accumulated glycogen in the surface cells. The latter change forms the basis of *Schiller's test* in which the suspected cervix is painted with solution of iodine and potassium iodide. The cancerous focus, if present, fails to stain because of lack of glycogen in the surface cells.

G/A No specific picture is associated with cellular atypia found in dysplasias or carcinoma *in situ* except that the changes begin at the squamocolumnar junction or transitional zone. The diagnosis can be suspected clinically on the basis of Schiller's test done on bedside.

M/E Distinction between various grades of CIN is quite subjective, but, in general dysplastic cells are distributed in the layers of squamous epithelium for varying thickness, and accordingly graded as mild, moderate and severe dysplasia, and carcinoma *in situ* (**Web Image 24.5,A**).

The atypical cells migrate to the surface layers from where they are shed off (exfoliated) into vaginal secretions in Pap smear. The individual dysplastic or abnormal cells in these grades of atypia show various cytologic changes such as: crowding of cells, pleomorphism, high nucleocytoplasmic ratio, coarse and irregular nuclear chromatin, numerous mitoses and scattered dyskaryotic cells.

The diagnosis of dysplasia and carcinoma *in situ* or CIN/SIL is best made by *exfoliative cytologic studies*. The degree of atypicality in the exfoliated surface epithelial cells can be objectively graded on the basis of 3 principal features (**Web Image 24.5,B**):

The lesions of SIL in cytology have histologic correlation with colposcopy-directed cervical biopsy in 70-90% cases (**Web Image 24.6**).

CERVICAL SCREENING AND THE BETHESDA SYSTEM. With introduction of effective Pap screening programme in the Western countries, incidence of invasive cervical cancer has declined greatly. However, still worldwide cervical cancer remains third most common cancer in women, next to breast and lung cancer. Although accurate statistics are not available from India, but it is perhaps the leading cause of death in women.

The broad principles of the **Bethesda system** of cytologic evaluation are as under:

- ◆ Pap smears are evaluated as regards *adequacy of specimen* i.e. satisfactory for evaluation, satisfactory but limited, or unsatisfactory for evaluation giving reason.
- ◆ General diagnosis is given in the form of *normal or abnormal smear*.
- ◆ *Descriptive diagnosis* is given in abnormal smears that includes: benign cellular changes, reactive cellular changes, and abnormalities of epithelial cells.
- ◆ Cellular abnormalities include: ASCUS (atypical squamous cells of undetermined significance), L-SIL (mentioning HPV infection and CIN-1 present or not), H-SIL (stating CIN-2 or CIN-3) and *squamous cell carcinoma*.

Invasive Cervical Cancer (p. 728)

Invasive cervical cancer in about 80% of cases is epidermoid (squamous cell) carcinoma. The incidence of invasive carcinoma of the cervix has shown a declining trend in developed countries in the last half of the century due to increased use of Pap smear technique for early detection and diagnosis but the incidence remains high in developing countries with low living standards. The risk factors and etiologic factors are the same as for CIN discussed above. The peak incidence of invasive cervical cancer is in 4th to 6th decades of life.

610 G/A Invasive cervical carcinoma may present 3 types of patterns: fungating, ulcerating and infiltrating. The fungating or exophytic pattern appearing as cauliflower-like growth infiltrating the adjacent vaginal wall is the most common type (**Web Image 24.7**). Characteristically, cervical carcinoma arises from the squamocolumnar junction.

M/E The features are as under:

1. Epidermoid (Squamous cell) carcinoma. This type comprises vast majority of invasive cervical carcinomas (about 70%).

◆ The most common pattern (70%) is moderately-differentiated non-keratinising large cell type and has better prognosis (**Web Image 24.8**).

◆ Next in frequency (25%) is well-differentiated keratinising epidermoid carcinoma.

◆ Small cell undifferentiated carcinoma (neuroendocrine or oat cell carcinoma) is less common (5%) and has a poor prognosis.

2. Adenocarcinoma. Adenocarcinomas comprise about 20-25% of cases.

3. Others. The remaining 5% cases are a variety of other patterns such as adenosquamous carcinoma, verrucous carcinoma and undifferentiated carcinoma.

CLINICAL STAGING. Classification of cervical cancer described by the Cancer Committee of the International Federation of Gynaecology and Obstetrics (FIGO classification) is widely adopted by the clinicians and pathologists and is given in **Web Table 24.4**.

□ **NORMAL STRUCTURE** (p. 730)

The *myometrium* is the thick muscular wall of the uterus which is covered internally by uterine mucosa called the *endometrium*. The endometrium extends above the level of the internal os where it joins the endocervical epithelium. The endometrium responds in a cyclic fashion to the ovarian hormones with resultant monthly menstruation and has remarkable regenerative capacity.

□ **NORMAL CYCLIC CHANGES** (p. 730)

The normal endometrial cycle begins with proliferative phase lasting for about 14 days under the influence of oestrogen, followed by ovulation on or around 14th day, and consequent secretory phase under the influence of progesterone. The cycle ends with endometrial shedding and the next cycle begins anew.

M/E The endometrium has different appearance in different phases of the menstrual cycle. Essentially, the endometrium consists of 3 structures: the endometrial lining epithelium, endometrial glands and stroma (**Web Image 24.9**).

□ **EFFECTS OF HORMONES** (p. 730)

In addition to the changes that take place during the normal menstrual cycle, the endometrium undergoes morphologic changes when hormonal preparations are administered, or during pregnancy and menopause.

Oestrogen and Progesterone (p. 731)

Oestrogen produces the characteristic changes of proliferative phase at the time of menopause and in young women with anovulatory cycles as occurs in Stein-Leventhal syndrome. The therapeutic addition of progesterone produces secretory pattern in an oestrogen-primed endometrium. Oestrogen-progesterone combination hormonal therapy is employed for control of conception. Repeated cyclic administration with

combination therapy such as after long-term use of oral contraceptives produces inactive-looking, small and atrophic endometrial glands, and compact decidua-like stroma.

Pregnancy (p. 731)

The endometrial glands are enlarged with abundant glandular secretions and the stromal cells become more plump, polygonal with increased cytoplasm termed *decidual reaction*. About 25% cases of uterine or extrauterine pregnancy show hyperactive secretory state called *Arias-Stella reaction*. It is characterised by hyperchromatic, atypical, tall cells lining the glands and the glandular epithelium may show multilayering and budding which may be mistaken for an adenocarcinoma.

Menopause (p. 731)

The onset of menopause is heralded with hormonal transition and consequent varying morphologic changes in the endometrium. Most commonly, the *senile endometrium*, as it is generally called, is thin and atrophic with inactive glands and fibrous stroma. However, some of the glands may show cystic dilatation.

□ **DYSFUNCTIONAL UTERINE BLEEDING (DUB)** (p. 731)

Dysfunctional uterine bleeding (DUB) may be defined as excessive bleeding occurring during or between menstrual periods without a causative uterine lesion such as tumour, polyp, infection, hyperplasia, trauma, blood dyscrasia or pregnancy. Anovulation is the result of prolonged and excessive oestrogenic stimulation without the development of progesterational phase. The causes for *anovulation* at different ages are as follows:

1. In *pre-puberty*: precocious puberty of hypothalamic, pituitary or ovarian origin.
2. In *adolescence*: anovulatory cycles at the onset of menstruation.
3. In *reproductive age*: complications of pregnancy, endometrial hyperplasia, carcinoma, polyps, leiomyomas and adenomyosis.
4. At *premenopause*: anovulatory cycles, irregular shedding, endometrial hyperplasia, carcinoma and polyps.
5. At *perimenopause*: endometrial hyperplasia, carcinoma, polyps and senile atrophy.

□ **ENDOMETRITIS AND MYOMETRITIS** (p. 732)

Myometritis is seen less frequently than endometritis and occurs in continuation with endometrial infections. Endometritis and myometritis may be acute or chronic.

◆ **Acute form** generally results from 3 types of causes—puerperal (following full-term delivery, abortion and retained products of conception), intrauterine contraceptive device (IUCD), and extension of gonorrhoeal infection from the cervix and vagina.

◆ **Chronic form** is more common and occurs by the same causes which result in acute phase. In addition, *tuberculous endometritis* is an example of specific chronic inflammation, uncommon in the Western countries but not so uncommon in developing countries. Its incidence in India is reported to be approximately in 5% of women.

M/E In *acute endometritis and myometritis*, there is progressive infiltration of the endometrium, myometrium and parametrium by polymorphs and marked oedema. *Chronic nonspecific endometritis and myometritis* are characterised by infiltration of plasma cells alongwith lymphocytes and macrophages. *Tuberculous endometritis* is almost always associated with tuberculous salpingitis and shows small non-caseating granulomas (**Web Image 24.10**).

612 □ **ADENOMYOSIS** (p. 732)

Adenomyosis is defined as abnormal distribution of histologically benign endometrial tissue within the myometrium along with myometrial hypertrophy. The term *adenomyoma* is used for actually circumscribed mass made up of endometrium and smooth muscle tissue. Adenomyosis is found in 15-20% of all hysterectomies. Clinically, the patients of adenomyosis generally complain of menorrhagia, colicky dysmenorrhoea and menstrual pain in the sacral or sacrococcygeal regions.

G/A The uterus may be slightly or markedly enlarged. On cut section, there is diffuse thickness of the uterine wall with presence of coarsely trabecular, ill-defined areas of haemorrhages.

M/E The diagnosis is based on the finding of normal, benign endometrial islands composed of glands as well as stroma deep within the muscular layer. The minimum distance between the endometrial islands within the myometrium and the basal endometrium should be one low-power microscopic field (2-3 mm) for making the diagnosis (**Web Image 24.11**).

□ **ENDOMETRIOSIS** (p. 732)

Endometriosis refers to the presence of endometrial glands and stroma in abnormal locations outside the uterus. Endometriosis and adenomyosis are closely interlinked, so much so that some gynaecologists have termed adenomyosis as *endometriosis interna* and the other category termed as *endometriosis externa* for similar appearance at the extrauterine sites.

The chief locations where the abnormal endometrial development may occur are as follows (in descending order of frequency): ovaries, uterine ligaments, rectovaginal septum, pelvic peritoneum, laparotomy scars, and infrequently in the umbilicus, vagina, vulva, appendix and hernial sacs.

The **histogenesis** of endometriosis has been a debatable matter for years. Currently, however, the following 3 theories of its histogenesis are described:

1. *Transplantation or regurgitation theory*
2. *Metaplastic theory*
3. *Vascular or lymphatic dissemination*

G/A The appearance of endometriosis varies widely depending upon the location and extent of the disease. Often, these foci are surrounded by fibrous tissue resulting in adherence to adjacent structures. The ovary is the most common site of endometriosis and shows numerous cysts varying in diameter from 0.1 to 2.5 cm. Ovarian involvement is often bilateral. Larger cysts, 3-5 cm in diameter, filled with old dark brown blood form '*chocolate cysts*' of the ovary.

M/E The diagnosis is simple and rests on identification of foci of endometrial glands and stroma, old or new haemorrhages, haemosiderin-laden macrophages and surrounding zone of inflammation and fibrosis (**Web Image 24.12**).

□ **ENDOMETRIAL HYPERPLASIAS** (p. 733)

Endometrial hyperplasia is a condition characterised by proliferative patterns of glandular and stromal tissues and commonly associated with prolonged, profuse and irregular uterine bleeding in a menopausal or postmenopausal woman. It may be emphasised here that the syndrome of DUB with which endometrial hyperplasia is commonly associated is a clinical entity, while hyperplasia is a pathologic term. Hyperplasia results from prolonged oestrogenic stimulation unopposed with any progestational activity. Such conditions include Stein-Leventhal syndrome, functioning granulosa-theca cell tumours, adrenocortical hyperfunction and prolonged administration of oestrogen.

The following classification of endometrial hyperplasias is widely employed by most gynaecological pathologists:

SIMPLE HYPERPLASIA WITHOUT ATYPIA (CYSTIC GLANDULAR HYPERPLASIA). Commonly termed cystic glandular hyperplasia (CGH), this form of endometrial hyperplasia is characterised by the presence of varying-sized glands, many of which are large and cystically dilated and are lined by atrophic epithelium. Mitoses are scanty and there is no atypia. (*Web Image 24.13,A*).

There is minimal risk (1%) of adenocarcinoma developing in cystic hyperplasia.

COMPLEX HYPERPLASIA WITHOUT ATYPIA (COMPLEX NON-ATYPICAL HYPERPLASIA). This type of hyperplasia shows distinct proliferative pattern. The glands are increased in number, exhibit variation in size and are irregular in shape. The glands are lined by multiple layers of tall columnar epithelial cells with large nuclei which have not lost basal polarity and there is no significant atypia. The glandular epithelium at places is thrown into papillary infolds or out-pouchings into adjacent stroma i.e. there is crowding and complexity of glands without cytologic atypia. The stroma is generally dense, cellular and compact (*Web Image 24.13,B*).

The malignant potential of complex hyperplasia in the absence of cytologic atypia is 3%.

COMPLEX HYPERPLASIA WITH ATYPIA (COMPLEX ATYPICAL HYPERPLASIA). Some authors have suggested the terms such as endometrial intraepithelial neoplasia (EIN) or carcinoma *in situ* for this form of endometrial hyperplasia. Complex hyperplasia with atypia is distinguished from complex non-atypical hyperplasia by the presence of 'atypical cells' in the hyperplastic epithelium. The extent of cytologic atypia may be mild, moderate or severe. The cytologic features present in these cells include loss of polarity, large size, irregular and hyperchromatic nuclei, prominent nucleoli, and altered nucleocytoplasmic ratio (*Web Image 24.13,C*).

Complex atypical hyperplasia is a precancerous condition and its malignant transformation is related to the degree of cytologic atypia. About 20-25% cases of untreated atypical hyperplasia progress to carcinoma.

□ TUMOURS OF ENDOMETRIUM AND MYOMETRIUM (p. 735)

Endometrial Polyps (p. 735)

'Uterine polyp' is clinical term used for a polypoid growth projecting into the uterine lumen and may be composed of benign lesions (e.g. endometrial or mucous polyp, leiomyomatous polyp and placental polyp), or malignant polypoid tumours (e.g. endometrial carcinoma, choriocarcinoma and sarcoma). The most common variety, however, is the one having the structure like that of endometrium and is termed *endometrial or mucus polyp*.

G/A Endometrial polyps may be single or multiple, usually sessile and small (0.5 to 3 cm in diameter) but occasionally they are large and pedunculated.

M/E They are essentially made up of mixture of endometrial glands and stroma. The histologic pattern of the endometrial tissue in the polyp may resemble either functioning endometrium or hyperplastic endometrium of cystic hyperplasia type.

Endometrial Carcinoma (p. 735)

Carcinoma of the endometrium, commonly called uterine cancer, is the most common pelvic malignancy in females in the United States and Eastern Europe but is uncommon in Asia where cervical cancer continues to be the leading cancer in women. It is primarily a disease of postmenopausal

614 women, the peak incidence at onset being 6th to 7th decades of life and is uncommon below the age of 40 years. The most important presenting complaint is abnormal bleeding in postmenopausal woman or excessive flow in the premenopausal years.

ETIOPATHOGENESIS. The exact etiology of endometrial cancer remains unknown. However, a few factors associated with increased frequency of its development are chronic unopposed oestrogen excess, obesity, diabetes, hypertension and nulliparous state. There is irrefutable evidence of *relationship of endometrial carcinoma with prolonged oestrogenic stimulation.*

Pathogenetically, papillary serous variant of endometrial carcinoma is associated with mutation in *p53* tumour suppressor gene while endometrioid carcinoma has mutation in *PTEN* gene located on chromosome 10. The role of heredity in pathogenesis of endometrial cancer is supported by higher incidence in hereditary non-polyposis colon cancer (HNPCC) syndrome (having simultaneous cancers of the colon and endometrioid adenocarcinoma) and in Cowden syndrome (having simultaneous cancers of the breast, thyroid, and endometrium).

G/A Endometrial carcinoma may have 2 patterns—localised *polypoid tumour*, or a *diffuse tumour*; the latter being more common (**Web Image 24.14**). The tumour protrudes into the endometrial cavity as irregular, friable and grey-tan mass. Extension of the growth into the myometrium may be identified by the presence of soft, friable and granular tissue in cut section.

M/E Most endometrial carcinomas are adenocarcinomas, commonly termed *endometrioid adenocarcinomas* due to their resemblance with normal endometrium. Depending upon the pattern of glands and individual cell changes, these may be well-differentiated, moderately-differentiated or poorly-differentiated (**Web Image 24.15**).

Cases can also be categorised as regards histologic grade as follows:

G1: Well-differentiated (predominantly glandular).

G2: Moderately-differentiated (glandular and partly solid areas).

G3: Poorly-differentiated (predominantly solid).

Carcinoma of the endometrium is categorised into four stages as per FIGO classification given in **Web Table 24.5**.

Leiomyoma (p. 737)

Leiomyomas or fibromyomas, commonly called *fibroids* by the gynaecologists, are the most common uterine tumours of smooth muscle origin, often admixed with variable amount of fibrous tissue component. About 20% of women above the age of 30 years harbour uterine myomas of varying size. Vast majority of them are benign and cause no symptoms. Malignant transformation occurs in less than 0.5% of leiomyomas. Symptomatic cases may produce abnormal uterine bleeding, pain, symptoms due to compression of surrounding structures and infertility.

The cause of leiomyomas is unknown but the possible stimulus to their proliferation is oestrogen. This is evidenced by increase in their size in pregnancy (**Web Image 24.16,C**) and high dose oestrogen-therapy and their regression following menopause and castration. Other possible factors implicated in its etiology are human growth hormone and sterility.

MORPHOLOGIC FEATURES. Leiomyomas are most frequently located in the uterus where they may occur within the myometrium (*intramural* or *interstitial*), the serosa (*subserosal*), or just underneath the endometrium (*submucosal*).

G/A Irrespective of their location, leiomyomas are often multiple, circumscribed, firm, nodular, grey-white masses of variable size. On cut section, they exhibit characteristic whorled pattern (**Web Images 24.16, A,B**).

M/E They are essentially composed of 2 tissue elements—whorled bundles of smooth muscle cells admixed with variable amount of connective tissue. The smooth muscle cells are uniform in size and shape with abundant cytoplasm and central oval nuclei (**Web Image 24.17**).

The pathologic appearance may be altered by secondary changes in the leiomyomas; these include: hyaline degeneration, cystic degeneration, infarction, calcification, infection and suppuration, necrosis, fatty change, and rarely, sarcomatous change.

Leiomyosarcoma (p. 737)

Leiomyosarcoma is an uncommon malignant tumour as compared to its rather common benign counterpart. The incidence of malignancy in pre-existing leiomyoma is less than 0.5% but primary uterine sarcoma is less common than that which arises in the leiomyoma.

G/A The tumour may form a diffuse, bulky, soft and fleshy mass, or a polypoid mass projecting into lumen.

M/E Though there are usually some areas showing whorled arrangement of spindle-shaped smooth muscle cells having large and hyperchromatic nuclei, the hallmark of diagnosis and prognosis is the number of mitoses per high power field (HPF). The essential diagnostic criteria are: more than 10 mitoses per 10 HPF with or without cellular atypia, or 5-10 mitoses per 10 HPF with cellular atypia. More the number of mitoses per 10 HPF, worse is the prognosis.

NORMAL STRUCTURE (p. 738)

The fallopian tube or oviducts are paired structures, each extending from superior angle of the uterus laterally to the region of the ovaries and running in the superior border of the broad ligaments forming mesosalpinx. Each tube is 7-14 cm long and is divided into 4 parts—*interstitial portion* in the uterine cornual wall; narrow *isthmic portion*; wider *ampullary region*; and funnel-like distal *infundibulum*.

M/E The wall of tube has 4 coats—*serous* forming the peritoneal covering, *subserous* consisting of fibrovascular tissue, *muscular* composed of longitudinal and circular smooth muscle layers, and *tubal mucosa* having 3 types of cells namely: ciliated, columnar and dark intercalated cells.

INFLAMMATIONS (p. 738)

Salpingitis and Pelvic Inflammatory Disease (p. 738)

Pelvic inflammatory disease (PID) by definition is a clinical syndrome characterised by signs and symptoms of ascending infection beginning in the vulva or vagina and spreading through the entire genital tract. Although ascending route of infection is the most common mode of spread, PID may occur following abortion and puerperium, with use of intrauterine contraceptive devices, or from local intra-abdominal infections such as appendicitis with peritonitis. In addition, haematogenous spread may occur, though this route is more important in the pathogenesis of tuberculosis.

G/A The fallopian tubes are invariably involved bilaterally. The distal end is blocked by inflammatory exudate and the lumina are dilated. There may be formation of loculated tubo-ovarian abscess involving the tube, ovary, broad ligament and adjacent part of uterus.

M/E The appearance varies with the duration of inflammatory process. Accordingly, it may have following forms:

- ◆ *Acute salpingitis*
- ◆ *Pelvic peritonitis and pelvic abscess.*

- ◆ *Pyosalpinx*
- ◆ *hydrosalpinx*
- ◆ *chronic salpingitis*
- ◆ *Salpingitis isthmica nodosa*

Tuberculous Salpingitis (p. 739)

Tuberculous salpingitis is almost always secondary to focus elsewhere in the body. The tubercle bacilli reach the tube, most commonly by haematogenous route, generally from the lungs, but occasionally from the urinary tract or abdominal cavity. Tubal tuberculosis is always present when there is tuberculosis of other female genital organs such as of endometrium, cervix and lower genital tract. Though infrequent in developed countries of the world, the incidence of tubal tuberculosis in developing countries like India is estimated to be about 5%; concomitant involvement of endometrium is present in about 80% cases. It affects more commonly young women in their active reproductive life and the most common complaint is infertility.

G/A The tube is dilated and contains purulent exudate though the fimbrial end is generally patent. The tubal peritoneum as well as the peritoneum in general is studded with yellowish tubercles.

M/E Typical caseating granulomas and chronic inflammation are identified in the tubal serosa, muscularis and mucosa.

□ **ECTOPIC TUBAL PREGNANCY** (p. 739)

The term ectopic tubal pregnancy is used for implantation of a fertilised ovum in the tube. Though ectopic pregnancy may rarely occur in the uterine horn, cornu, ovary and abdominal cavity, tubal pregnancy is by far the most common form of ectopic gestation (**Web Image 24.18**). Ectopic tubal pregnancy is a potentially hazardous problem because of rupture which is followed by intraperitoneal haemorrhage.

□ **NORMAL STRUCTURE** (p. 739)

The ovaries are paired bean-shaped organs hanging from either tube by a mesentery called the mesovarium, the lateral suspensory ligament and the ovarian ligament. The lateral suspensory ligament of the ovary contains blood vessels, lymphatics and plexuses of nerves. Each ovary measures 2.5-5 cm in length, 1.5-3 cm in breadth and 0.7-1.5 cm in width and weighs 4-8 gm.

M/E The ovarian structure consists of covering by coelomic epithelium, outer cortex and inner medulla (**Web Image 24.19**).

Coelomic epithelium. The surface of the ovary is covered by a single layer of cuboidal epithelial cells.

Cortex. The cortex contains numerous ovarian follicles and their derivative structures. Each follicle consists of a central *germ cell ovum* surrounded by specialised gonadal stroma. This stroma consists of *granulosa cells* encircling the ovum, and concentrically-arranged plump spindle-shaped *theca cells*. The granulosa component is avascular and draws its nutrition from the highly vascular theca component. The theca component has 2 parts—luteinised theca layer called *theca interna*, and outer condensed ovarian stroma called *theca externa*. Granulosa cells and follicle-associated (luteinised) theca cells produce oestrogen.

Medulla. The ovarian medulla is primarily made up of connective tissue fibres, smooth muscle cells and numerous blood vessels, lymphatics and nerves. In addition, the medulla may also contain clusters of hilus cell (or

hilar-Leydig cells) which may have androgenic role in contrast to oestrogenic role of the ovarian cortex.

□ **NON-NEOPLASTIC CYSTS** (p. 740)

Follicular and Luteal Cysts (p. 740)

Normally follicles and corpus luteum do not exceed a diameter of 2 cm. When their diameter is greater than 3 cm, they are termed as cysts.

◆ **Follicular cysts** are frequently multiple, filled with clear serous fluid and may attain a diameter upto 8 cm. When large, they produce clinical symptoms.

M/E They are lined by granulosa cells. Occasionally, however, there may be difficulty in distinguishing between a large cyst of coelomic epithelial origin (*serous cyst*) lined by flattened epithelial cells and a cyst of follicular origin. Such cases are appropriately designated as '*simple cysts*'.

◆ **Luteal cysts** are formed by rupture and sealing of corpus haemorrhagicum. The wall of these cysts is composed of yellowish luteal tissue (*lutein* = yellow pigment).

M/E Luteal cysts are commonly lined by luteinised granulosa cells. Lining by predominantly luteinised theca cells may also be seen in cystic ovaries in association with hydatidiform mole and choriocarcinoma, and rarely, in normal pregnancy.

Polycystic Ovary Disease (Stein-Leventhal Syndrome) (p. 740)

Polycystic ovary syndrome (PCOS) is a syndrome characterised by oligomenorrhoea, anovulation, infertility, hirsutism and obesity in young women having bilaterally enlarged and cystic ovaries. Current concept of pathogenesis of PCOS is the unbalanced release of FSH and LH by the pituitary. A hereditary basis for the syndrome has been suggested in some cases.

G/A The ovaries are usually involved bilaterally and are at least twice the size of the normal ovary. They are grey-white in colour and studded with multiple small (0.5-1.5 cm in diameter) bluish cysts just beneath the cortex.

M/E The outer cortex is thick and fibrous. The subcortical cysts are lined by prominent luteinised theca cells and represent follicles in various stages of maturation but there is no evidence of corpus luteum.

□ **OVARIAN TUMOURS** (p. 740)

The ovary is third most common site of primary malignancy in the female genital tract, preceded only by endometrial and cervical cancer.

ETIOPATHOGENESIS (p. 740)

Unlike the two other female genital cancers (cervix and endometrium), not much is known about the etiology of ovarian tumours. However, a few risk factors have been identified as under:

1. **Nulliparity.**
2. **Heredity.** About 10% cases of ovarian cancer occur in women with family history of ovarian or breast cancer.
3. **Complex genetic syndromes, e.g.**
 - i) *Lynch syndrome*, ii) *Peutz-Jeghers syndrome*, iii) *Gonadal dysgenesis*, and iv) *Nevoid basal cell carcinoma*.

CLINICAL FEATURES AND CLASSIFICATION (p. 741)

In general, benign ovarian tumours are more common, particularly in young women between the age of 20 and 40 years, and account for 80% of all ovarian neoplasms. Malignant tumours may be primary or metastatic, ovary being a common site for receiving metastases from various other cancers.

618 Primary malignant ovarian tumours are more common in older women between the age of 40 and 60 years.

A simplified classification proposed by the WHO with minor modifications has been widely adopted (**Web Table 24.6**). According to this classification, ovarian tumours arise from normally-occurring cellular components of the ovary (**Web Image 24.19**). Five major groups have been described:

- I. Tumours of surface epithelium (common epithelial tumours)
- II. Germ cell tumours
- III. Sex cord-stromal tumours
- IV. Miscellaneous tumours
- V. Metastatic tumours

I. TUMOURS OF SURFACE EPITHELIUM (COMMON EPITHELIAL TUMOURS) (p. 741)

Tumours derived from the surface (coelomic) epithelium called common epithelial tumours form the largest group of ovarian tumours. This group constitutes about 60-70% of all ovarian neoplasms and 90% of malignant ovarian tumours. The common epithelial tumours are of 3 major types—*serous*, *mucinous* and *endometrioid*, though mixtures of these epithelia may occur in the same tumour. These tumours frequently have prominent cystic component which may have a single or multiple loculations and hence the descriptive prefix *cystadeno-* in these tumours. In addition, surface epithelial tumours may differentiate along urothelium to form *Brenner tumour*, and along mesonephroid pattern forming *clear cell (mesonephroid) adenocarcinoma*.

Depending upon the aggressiveness, the surface epithelial tumours are divided into 3 groups: *clearly benign*, *clearly malignant*, and *borderline* (or *atypical proliferating* or *low-grade*) *malignant tumours*. In general, the criteria for diagnosis of these 3 grades of aggressiveness are as follows (**Web Image 24.20**):

- ◆ **Clearly benign tumours** are lined by a single layer of well-oriented columnar epithelium. Papillary projections, if present, are covered by the same type of epithelium without any invasion into fibrovascular stromal stalk.
- ◆ **Clearly malignant tumours** have anaplastic epithelial component, multilayering, loss of basal polarity and unquestionable stromal invasion. The prognosis of these tumours is very poor.
- ◆ **Borderline (atypical proliferating) tumours** or tumours with low malignant potential have some morphological features of malignancy, apparent detachment of cellular clusters from their site of origin and essential absence of stromal invasion. Morphological features of malignancy which may be present in varying combinations include: stratification (2-3 layers) of the epithelial cells but generally maintained basal polarity of nuclei, moderate nuclear abnormalities, and some mitotic activity. This group has a much better prognosis than frankly malignant tumours of the ovary.

Serous Tumours (p. 742)

Serous tumours comprise the largest group constituting about 20% of all ovarian tumours and 40% of malignant ovarian tumours. They are called serous tumours because of the presence of clear, watery, serous fluid in these predominantly cystic tumours. About 60% of serous tumours are benign, 15% borderline and 25% malignant. Only 20% of benign tumours occur bilaterally, whereas 65% of both borderline and malignant serous tumours have bilateral ovarian involvement.

Histogenesis of the serous tumours is by metaplasia from the surface (coelomic) epithelium or mesothelium which differentiates along tubal-type of epithelium.

G/A Benign, borderline and malignant serous tumours are large (above 5 cm in diameter) and spherical masses. Small masses are generally unilocular while the larger serous cysts are multiloculated similar to the mucinous variety, but differ from the latter in containing serous fluid rather than the viscid fluid of mucinous tumours. *Malignant serous tumours* may have solid areas in the cystic mass. Exophytic as well as intracystic papillary projections may be present in all grades of serous tumours but are more frequent in malignant tumours termed papillary serous cystadenocarcinomas (**Web Image 24.21**).

M/E The features are as under:

- 1. Serous cystadenoma** is characteristically lined by properly-oriented low columnar epithelium which is sometimes ciliated and resembles tubal epithelium.
- 2. Borderline (atypical proliferating) serous tumour** usually has stratification (2-3 layers) of benign serous type of epithelium. There is detachment of cell clusters from their site of origin and moderate features of malignancy but there is absence of stromal invasion.
- 3. Serous cystadenocarcinoma** has multilayered malignant cells which show loss of polarity, presence of solid sheets of anaplastic epithelial cells and definite evidence of stromal invasion. Papillae formations are more frequent in malignant variety and may be associated with psammoma bodies (**Web Image 24.22**).

Mucinous Tumours (p. 743)

Mucinous tumours are somewhat less common than serous tumours and constitute about 20% of all ovarian tumours and 10% of all ovarian cancers. Over 80% are benign, 10-15% are borderline (atypical proliferating) and 5-10% are malignant. These predominantly cystic tumours contain mucin which was previously described as pseudomucin. Well-differentiated borderline mucinous tumours are associated with mucinous ascites termed *pseudomyxoma peritonei*. As compared with serous tumours, mucinous tumours are more commonly unilateral. Benign mucinous tumours occur bilaterally in 5% of cases while borderline and malignant are bilateral in 20%. As per current concept, the diagnosis of primary ovarian mucinous adenocarcinoma is made after excluding metastatic tumours to the ovary, while bilateral mucinous adenocarcinoma of the ovary is invariably metastatic deposits to the ovary. Mucinous tumours occur principally between 2nd and 5th decades of life. Mucinous cystadenocarcinoma usually develops in women above the age of 40 years.

Histogenesis of mucinous tumours, in line with that of serous tumours, is by metaplasia from the coelomic epithelium that differentiates along endocervical type or intestinal type of mucosa.

G/A Mucinous tumours are much larger than serous tumours. They are smooth-surfaced cysts with characteristic multiloculations containing thick and viscid gelatinous fluid (**Web Image 24.23**). Benign tumours generally have thin wall and septa dividing the loculi are also thin and often translucent, but malignant varieties usually have thickened areas.

M/E The most distinctive feature is the characteristic tall columnar nonciliated epithelium lining the loculi (**Web Image 24.24**). Other features are as under:

- 1. Mucinous cystadenoma** is lined by a single layer of these cells having basal nuclei and apical mucinous vacuoles.
- 2. Borderline (atypical proliferating) mucinous tumour** is identified by the same histologic criteria as for borderline serous tumour i.e. stratification (usually 2-3 cell thick) of typical epithelium without stromal invasion.
- 3. Mucinous cystadenocarcinoma** likewise is characterised by piling up of malignant epithelium, at places forming solid sheets, papillary formation, adenomatous pattern and infiltration into stroma with or without pools of mucin.

620 Endometrioid Tumours (p. 744)

Endometrioid tumours comprise about 5% of all ovarian tumours. Most of them are malignant accounting for about 20% of all ovarian cancers.

Histogenesis of these tumours in majority of cases is believed to be from ovarian coelomic epithelium differentiating towards endometrial type of epithelium.

G/A These tumours are partly solid and partly cystic and may have foci of haemorrhages, especially in benign variety.

M/E The endometrioid adenocarcinoma is distinguished from serous and mucinous carcinomas by typical glandular pattern that closely resembles that of uterine endometrioid adenocarcinoma.

Clear Cell (Mesonephroid) Tumours (p. 745)

Clear cell (mesonephroid) tumours are almost always malignant and comprise about 5% of all ovarian cancers; rare benign variety is called *clear cell adenofibroma*. They are termed clear cell or mesonephroid carcinomas because of the close histologic resemblance to renal adenocarcinoma.

G/A These tumours are large, usually unilateral, partly solid and partly cystic. Less than 10% are bilateral.

M/E Clear cell or mesonephroid carcinoma is characterised by tubules, glands, papillae, cysts and solid sheets of tumour cells resembling cells of renal adenocarcinoma i.e. clear cells having abundant eosinophilic cytoplasm rich in glycogen.

Brenner Tumour (p. 745)

Brenner tumours are uncommon and comprise about 2% of all ovarian tumours. They are characteristically solid ovarian tumours. Less than 10% of Brenner tumours are bilateral. Most Brenner tumours are benign. Rarely, borderline form is encountered called 'proliferating Brenner tumour' while the one with carcinomatous change is termed 'malignant Brenner tumour'.

Histogenesis of the tumour is from coelomic epithelium by metaplastic transformation into transitional epithelium (urothelium).

G/A Brenner tumour is typically solid, yellow-grey, firm mass of variable size. Occasionally, a few scattered tiny cysts may be present on cut section.

M/E Brenner tumour consists of nests, masses and columns of epithelial cells, scattered in fibrous stroma of the ovary. These epithelial cells resemble urothelial cells which are ovoid in shape, having clear cytoplasm, vesicular nuclei with characteristic nuclear groove called 'coffee-bean' nuclei.

II. GERM CELL TUMOURS (p. 745)

Ovarian germ cell tumours arising from germ cells which produce the female gametes (i.e. ova) account for about 15-20% of all ovarian neoplasms. The neoplastic germ cells may follow one of the several lines of differentiation as shown in **Web Image 24.25**. Nearly 95% of them are benign and occur chiefly in young females, vast majority of them being benign cystic teratomas (dermoid cysts). Most germ cell tumours of the ovaries have their counterparts in the testis and sometimes in the mediastinum but their frequency differs from one site to the other.

Teratomas (p. 746)

Teratomas are tumours composed of different types of tissues derived from the three germ cell layers—ectoderm, mesoderm and endoderm, in different combinations. In view of wide spectrum of tissue elements found in these teratomas, their *histogenesis* has been a matter of speculation for a long

time. Cytogenetic studies have revealed that these tumours arise from a single germ cell (ovum) after its first meiotic division.

Teratomas are divided into 3 types: mature (benign), immature (malignant), and monodermal or highly specialised teratomas.

MATURE (BENIGN) TERATOMA. Vast majority of ovarian teratomas are benign and cystic and have the predominant ectodermal elements, often termed clinically as *dermoid cyst*. Infrequently, mature teratoma may be solid and benign and has to be distinguished from immature or malignant teratoma.

G/A Benign cystic teratoma or dermoid cyst is characteristically a unilocular cyst, 10-15 cm in diameter, usually lined by the skin and hence its name. On sectioning, the cyst is filled with paste-like sebaceous secretions and desquamated keratin admixed with masses of hair. The cyst wall is thin and opaque grey-white. Generally, in one area of the cyst wall, a solid prominence is seen (Rokitansky's protuberance) where tissue elements such as tooth, bone, cartilage and various other odd tissues are present (**Web Image 24.26**).

M/E The most prominent feature is the lining of the cyst wall by stratified squamous epithelium and its adnexal structures such as sebaceous glands, sweat glands and hair follicles (**Web Image 24.27**). Though ectodermal derivatives are most prominent features, tissues of mesodermal and endodermal origin are also commonly present. *kaleidoscopic patterns*.

Less than 1% of patients with a dermoid cyst develop malignant transformation of one of the tissue components, most commonly squamous cell carcinoma.

IMMATURE (MALIGNANT) TERATOMA. Immature or malignant teratomas of the ovary are rare and account for approximately 0.2% of all ovarian tumours. They are predominantly solid tumours that contain immature or embryonal structures in contrast to the mature or adult structures of the benign teratomas.

G/A Malignant teratoma is a unilateral solid mass which on cut section shows characteristic variegated appearance revealing areas of haemorrhages, necrosis, tiny cysts and heterogeneous admixture of various tissue elements.

M/E Parts of the tumour may show mature tissues, while most of it is composed of immature tissues having an embryonic appearance. Immature tissue elements may differentiate towards cartilage, bone, glandular structures, neural tissue etc, and are distributed in spindle-shaped myxoid or undifferentiated sarcoma cells. An important factor in grading and determining the prognosis of immature teratoma is the relative amount of immature neural tissue.

MONODERMAL (SPECIALISED) TERATOMA. Monodermal or highly specialised teratomas are rare and include following types:

- ◆ **Struma ovarii.** It is a teratoma composed exclusively of thyroid tissue, recognisable grossly as well as microscopically.
- ◆ **Carcinoid tumour.** This is an ovarian teratoma arising from argentaffin cells of intestinal epithelium in the teratoma.
- ◆ **Struma-carcinoid** is a rare combination of struma ovarii and ovarian carcinoid.

Dysgerminoma (p. 747)

Dysgerminoma is an ovarian counterpart of seminoma of the testes. Dysgerminomas comprise about 2% of all ovarian cancers. They occur most commonly in 2nd to 3rd decades. About 10% of them are bilateral. About 10% of patients with dysgerminoma have elevated hCG level in the plasma.

622 G/A Dysgerminoma is a solid mass of variable size. Cut section of the tumour is grey-white to pink, lobulated, soft and fleshy with foci of haemorrhages and necrosis.

M/E Their structure is similar to that of seminoma of the testis (**Web Image 24.28**). The tumour cells are arranged in diffuse sheets, islands and cords separated by scanty fibrous stroma. The tumour cells are uniform in appearance and large, with vesicular nuclei and clear cytoplasm rich in glycogen. The fibrous stroma generally contains lymphocytic infiltrate and sometimes may have sarcoid granulomas.

Endodermal Sinus (Yolk Sac) Tumour (p. 748)

Endodermal sinus tumour or yolk sac tumour is the second most common germ cell tumour occurring most frequently in children and young women. More often, endodermal sinus tumour is found in combination with other germ cell tumours rather than in pure form. The tumour is rich in alphafetoprotein (AFP) and α -1-antitrypsin.

G/A The tumour is generally solid with areas of cystic degeneration.

M/E Like its testicular counterpart, the endodermal sinus tumour is characterised by the presence of papillary projections having a central blood vessel with perivascular layer of anaplastic embryonal germ cells. Such structures resemble the endodermal sinuses of the rat placenta (Schiller-Duval body) from which the tumour derives its name. It is common to find intracellular and extracellular PAS-positive hyaline globules which are composed of AFP (**Web Image 24.29**).

Choriocarcinoma (p. 748)

Choriocarcinoma in females is of 2 types—*gestational and non-gestational*. Gestational choriocarcinoma of placental origin is more common and considered separately later. Pure primary non-gestational choriocarcinoma of ovarian origin is rare while its combination with other germ cell tumours is seen more often. The patients are usually young girls under the age of 20 years.

M/E Ovarian choriocarcinoma is identical to gestational choriocarcinoma.

III. SEX CORD-STROMAL TUMOURS (p. 748)

Granulosa-Theca Cell Tumours (p. 748)

Granulosa-theca cell tumours comprise about 5% of all ovarian tumours.

GRANULOSA CELL TUMOUR. Pure granulosa cell tumours may occur at all ages. These tumours invade locally but occasionally may have more aggressive and malignant behaviour. Most granulosa cell tumours secrete oestrogen which may be responsible for precocious puberty in young girls, or in older patients may produce endometrial hyperplasia, endometrial adenocarcinoma and cystic disease of the breast.

G/A Granulosa cell tumour is a small, solid, partly cystic and usually unilateral tumour. Cut section of solid areas is yellowish-brown (**Web Image 24.30**).

M/E The granulosa cells are arranged in a variety of patterns including micro- and macrofollicular, trabecular, bands and diffuse sheets. The microfollicular pattern is characterised by the presence of characteristic rosette-like structures, Call-Exner bodies, having central rounded pink mass surrounded by a circular row of granulosa cells (**Web Image 24.31**).

THECOMA. Pure thecomas are almost always benign. They occur more frequently in postmenopausal women. Thecomas are typically oestrogenic. Endometrial hyperplasia, endometrial carcinoma and cystic disease of the breast are some of its adverse effects.

G/A Thecoma is a solid and firm mass, 5-10 cm in diameter. Cut section is yellowish.

M/E Thecoma consists of spindle-shaped theca cells of the ovary admixed with variable amount of hyalinised collagen. The cytoplasm of theca cells is lipid-rich and vacuolated which reacts with lipid stains.

GRANULOSA-THECA CELL TUMOUR. Mixture of both granulosa and theca cell elements in the same ovarian tumour is seen in some cases with elaboration of oestrogen.

FIBROMA. Fibromas of the ovary are more common and account for about 5% of all ovarian tumours. These tumours are hormonally inert but some of them are associated with pleural effusion and benign ascites termed Meig's syndrome.

G/A These tumours are large, firm and fibrous, usually unilateral masses.

M/E They are composed of spindle-shaped well-differentiated fibroblasts and collagen. Sometimes, combination of fibroma and thecoma is present called fibrothecoma.

Sertoli-Leydig Cell Tumours

(Androblastoma, Arrhenoblastoma) (p. 749)

Tumours containing Sertoli and Leydig cells in varying degree of maturation comprise Sertoli-Leydig cell tumours, also called androblastomas or arrhenoblastomas. Characteristically, they produce androgens and masculinise the patient.

G/A Sertoli-Leydig cell tumour resembles a granulosa-theca cell tumour.

M/E These tumours recapitulate to some extent the structure of the testis. Three histologic types are distinguished:

1. *Well-differentiated androblastoma*
2. *Tumours with intermediate differentiation*
3. *Poorly-differentiated or sarcomatoid variety*

Gynandroblastoma (p. 749)

Gynandroblastoma is an extremely rare tumour in which there is combination of patterns of both granulosa-theca cell tumour and Sertoli-Leydig cell tumour.

IV. MISCELLANEOUS TUMOURS (p. 749)

LIPID CELL TUMOURS. There is a small group of ovarian tumours that appears as soft yellow or yellow-brown nodules which on histologic examination are composed of large lipid-laden cells.

GONADOBLASTOMA. This is a rare tumour occurring exclusively in dysgenetic gonads, more often in phenotypic females and in hermaphrodites.

V. METASTATIC TUMOURS (p. 750)

About 10% of ovarian cancers are secondary carcinomas. Metastasis may occur by lymphatic or haematogenous route but direct extension from adjacent organs (e.g. uterus, fallopian tube and sigmoid colon) too occurs frequently. Bilaterality of the tumour is the most helpful clue to diagnosis of metastatic tumour. Most common primary sites from where metastases to the ovaries are encountered are: carcinomas of the breast, genital tract, gastrointestinal tract (e.g. stomach, colon appendix, pancreas, biliary tract) and haematopoietic malignancies.

Krukenberg Tumour (p. 750)

Krukenberg tumour is a distinctive bilateral tumour metastatic to the ovaries by transcoelomic spread. The tumour is generally secondary to a gastric

624 carcinoma but other primary sites where mucinous carcinomas occur (e.g. colon, appendix and breast) may also produce Krukenberg tumour in the ovary.

G/A Krukenberg tumour forms rounded or kidney-shaped firm large masses in both ovaries. Cut section shows grey-white to yellow firm fleshy tumour and may have areas of haemorrhage and necrosis (**Web Image 24.32**).

M/E It is characterised by the presence of mucus-filled signet ring cells which may lie singly or in clusters. It is accompanied by sarcoma-like cellular proliferation of ovarian stroma (**Web Image 24.33**).

FIGO staging of ovarian cancer is given in **Web Table 24.7**.

□ **NORMAL STRUCTURE** (p. 751)

At term, the normal placenta is blue red, rounded, flattened and discoid organ 15-20 cm in diameter and 2-4 cm thick. It weighs 400-600 gm or about one-sixth the weight of the newborn. The umbilical cord is about 50 cm long and contains two umbilical arteries and one umbilical vein attached at the foetal surface. The placenta is derived from both maternal and foetal tissues. The *maternal portion* of the placenta has irregular grooves dividing it into cotyledons which are composed of sheets of decidua basalis and remnants of blood vessels. The *foetal portion* of the placenta is composed of numerous functional units called chorionic villi and comprise the major part of placenta at term. The villi consist of a loose fibrovascular stromal core and a few phagocytic (Höffbauer's) cells. The villous core is covered by an inner layer of cytotrophoblast and outer layer of syncytiotrophoblast.

□ **HYDATIDIFORM MOLE** (p. 751)

The word 'hydatidiform' means *drop of water* and 'mole' for a *shapeless mass*. Hydatidiform mole is defined as an abnormal placenta characterised by 2 features:

- i) Enlarged, oedematous and hydropic change of the chorionic villi which become vesicular.
- ii) Variable amount of trophoblastic proliferation.

Most workers consider hydatidiform mole as a benign tumour of placental tissue with potential for developing into choriocarcinoma, while some authors have described mole as a degenerative lesion though capable of neoplastic change.

Hydatidiform mole may be non-invasive or invasive. Two types of non-invasive moles are distinguished—*Pathogenesis* of these 2 forms is different:

● **Complete (classic) mole** by cytogenetic studies has been shown to be derived from the father (androgenesis) and has 46, XX or rarely 46, XY chromosomal pattern.

● **Partial mole** is mostly triploid (i.e. 69,XXY or 69,XXX) and rarely tetraploid. Partial mole rarely develops into choriocarcinoma.

Clinically, the condition appears in 4th-5th month of gestation and is characterised by increase in uterine size, vaginal bleeding and often with symptoms of toxæmia. Frequently, there is history of passage of grape-like masses per vaginum. About 1% of women with molar pregnancy develop it again in a subsequent pregnancy.

The single most significant *investigation* forming the mainstay of management is the serial determination of β -hCG which is elevated more in both blood and urine as compared with the levels in normal pregnancy.

Complete mole. G/A The uterus is enlarged and characteristically filled with grape-like vesicles up to 3 cm in diameter (**Web Image 24.34**). The vesicles contain clear watery fluid. Rarely, a macerated foetus may be found.

M/E (Web Image 24.35): The features are:

- ◆ Large, round, oedematous and acellular villi due to hydropic degeneration forming central cysterns.
- ◆ Decreased vascularity of villous stroma.
- ◆ Trophoblastic proliferation in the form of masses and sheets of both cytotrophoblast and syncytiotrophoblast, generally circumferential around the villi.

PARTIAL MOLE. G/A The uterus is generally smaller than expected and contains some cystic villi, while part of the placenta appears normal. A foetus with multiple malformations is often present.

M/E Some of the villi show oedematous change while others are normal or even fibrotic. Trophoblastic proliferation is usually slight and focal.

INVASIVE (DESTRUCTIVE) MOLE (CHORIOADENOMA DESTRUENS). G/A Invasive mole shows invasion of the molar tissue into the uterine wall which may be a source of haemorrhage. Rarely, molar tissue may invade the blood vessels and reach the lungs.

M/E The lesion is benign and identical to classic mole but has potential for haemorrhage. It is always associated with persistent elevation of β -hCG levels.

□ CHORIOCARCINOMA (p. 753)

Gestational choriocarcinoma is a highly malignant and widely metastasising tumour of trophoblast. Approximately 50% of cases occur following hydatidiform mole, 25% following spontaneous abortion, 20% after an otherwise normal pregnancy, and 5% develop in an ectopic pregnancy.

Clinically, the most common complaint is vaginal bleeding following a normal or abnormal pregnancy. Occasionally, the patients present with metastases in the brain or lungs. The diagnosis is confirmed by demonstration of persistently high levels of β -hCG in the plasma and urine. Widespread haematogenous metastases are early and frequent in choriocarcinoma if not treated; these are found chiefly in the lungs, vagina, brain, liver and kidneys.

G/A The tumour appears as haemorrhagic, soft and fleshy mass. Sometimes, the tumour may be small, often like a blood clot, in the uterus.

M/E The characteristic features are as under:

- ◆ Absence of identifiable villi.
- ◆ Masses and columns of highly anaplastic and bizarre cytotrophoblast and syncytiotrophoblast cells which are intermixed.
- ◆ Invariable presence of haemorrhages and necrosis.
- ◆ Invasion of the underlying myometrium and other structures, blood vessels and lymphatics.

Gestational choriocarcinoma and its metastases respond very well to chemotherapy while non-gestational choriocarcinoma is quite resistant to therapy and has worse prognosis. The effectiveness of treatment is also monitored by serial β -hCG determinations. Death from choriocarcinoma is generally due to fatal haemorrhage in the CNS or lungs or from pulmonary insufficiency.

The contrasting features of complete (classic) and partial mole and choriocarcinoma are summed up in **Web Table 24.8**.

◆ SELF ASSESSMENT

1. The following vulval lesion can progress to vulval carcinoma:

A. Stromal polyp	B. Papillary hidradenoma
C. Squamous hyperplasia	D. Lichen sclerosus

2. **High risk HPV types implicated in cervical intraepithelial lesions are:**
 - A. 6 and 11
 - B. 5 and 8
 - C. 16 and 18
 - D. 19 and 22
3. **The most common histologic type of cervical cancer is:**
 - A. Well-differentiated keratinising squamous cell carcinoma
 - B. Moderately-differentiated non-keratinising squamous cell carcinoma
 - C. Small cell undifferentiated carcinoma
 - D. Adenocarcinoma
4. **Arias-Stella reaction occurs in:**
 - A. Ectopic tubal gestation only
 - B. All ectopic gestations
 - C. Uterine gestation
 - D. Uterine as well as ectopic gestations
5. **Chocolate cyst of the ovary is:**
 - A. Haemorrhagic corpus luteum
 - B. Ruptured luteal cyst
 - C. Endometriotic cyst
 - D. Ruptured follicular cyst
6. **The malignant potential of atypical hyperplasia is:**
 - A. About 5%
 - B. About 25%
 - C. About 50%
 - D. About 75%
7. **Peak incidence of endometrial adenocarcinoma is in:**
 - A. Reproductive years
 - B. Premenopausal years
 - C. Perimenopausal years
 - D. Postmenopausal years
8. **The commonest site for endometriosis is:**
 - A. Hernial sacs
 - B. Vulva
 - C. Ovaries
 - D. Vagina
9. **Bilaterality of following ovarian tumours is most common:**
 - A. Benign serous tumours
 - B. Malignant serous tumours
 - C. Benign mucinous tumours
 - D. Brenner tumour
10. **The most common germ cell tumour of the ovary is:**
 - A. Dysgerminoma
 - B. Benign teratoma
 - C. Immature teratoma
 - D. Endodermal sinus tumour
11. **The most aggressive ovarian germ cell tumour is:**
 - A. Malignant teratoma
 - B. Embryonal carcinoma
 - C. Endodermal sinus tumour
 - D. Dysgerminoma
12. **Granulosa cell tumour is associated with following except:**
 - A. Endometrial hyperplasia
 - B. Endometrial adenocarcinoma
 - C. Endometrioid tumour
 - D. Fibrocystic change in breast
13. **Krukenberg tumour is bilateral metastatic tumour from the following primary sites except:**
 - A. Stomach
 - B. Colon
 - C. Breast
 - D. Endometrium
14. **The following trophoblastic tumour does not respond to chemotherapy:**
 - A. Complete mole
 - B. Invasive mole
 - C. Gestational choriocarcinoma
 - D. Ovarian choriocarcinoma
15. **Identifiable chorionic villi are present in the following tumours except:**
 - A. Complete mole
 - B. Partial mole
 - C. Invasive mole
 - D. Gestational choriocarcinoma

16. According to the Bethesda system, the squamous intraepithelial lesions for the grades of cervical cytology are:
 A. Two
 B. Three
 C. Four
 D. Five
17. In the etiology of condyloma acuminatum, the most commonly implicated HPV types are:
 A. Types 1,2
 B. Types 6, 11
 C. Types 2,3,9
 D. Types 16,18
18. Protein product of HPV 16 is:
 A. E2
 B. E5
 C. E6
 D. E7
19. Upper age limit for cervical screening is:
 A. 50 years
 B. 55 years
 C. 60 years
 D. None
20. Characteristic mutation seen in endometrioid carcinoma is:
 A. PTEN
 B. p53
 C. Rb
 D. K-ras
21. Genetic syndrome associated with increased risk of ovarian cancer includes all *except*:
 A. Lynch syndrome
 B. Peutz-Jegher's syndrome
 C. Nevoid basal cell carcinoma
 D. Turcot's syndrome
22. Pick the odd one out:
 A. Sertoli's leydig cell tumour
 B. Androblastoma
 C. Arrhenblastoma
 D. Gonadoblastoma

KEY

1 = C	2 = C	3 = B	4 = D
5 = C	6 = B	7 = D	8 = C
9 = B	10 = B	11 = B	12 = C
13 = D	14 = D	15 = D	16 = A
17 = B	18 = D	19 = D	20 = A
21 = D	22 = D		



The Breast

The breast is a modified skin appendage which is functional in the females during lactation but is rudimentary in the males. Microanatomy of the breast reveals 2 types of tissue components: *epithelial* and *stromal* (**Web Image 25.1**). In a fully-developed non-lactating female breast, the epithelial component comprises less than 10% of the total volume but is more significant pathologically since majority of lesions pertain to this portion of the breast.

EPITHELIAL COMPONENT. The epithelial component of the breast consists of 2 major parts: terminal duct-lobular unit (TDLU) which performs the main secretory function during lactation, and large duct system which performs the function of collection and drainage of secretions; both are interconnected to each other.

The breast is divided into about 20 *lobes*. Each lobe consists of *breast lobules* which drain their secretions through its *collecting duct system* and opens into the nipple through its own main excretory duct, *lactiferous duct*. The segment of lactiferous duct subjacent to the nipple shows a small dilatation called *lactiferous sinus*. Each lactiferous duct has its own collecting duct system which has branches of smaller diameter, ultimately terminating peripherally as *terminal ducts* (or TDLU) in the breast lobules.

The entire ductal-lobular epithelial system has bilayered lining: the inner epithelium with secretory and absorptive function, and an outer supporting myoepithelial lining. The inner epithelium stains positive for epithelial membrane antigen (EMA) and lactalbumin while the myoepithelium is positive for smooth muscle actin (SMA) and S-100.

STROMAL COMPONENT. The supportive stroma of the breast consists of variable amount of loose connective tissue and adipose tissue during different stages of reproductive life. The stromal tissue of the breast is present at 2 locations: intralobular and interlobular stroma.

Section III

Systemic Pathology

□ INFLAMMATIONS

Acute Mastitis and Breast Abscess (p. 755)

Acute pyogenic infection of the breast occurs chiefly during the first few weeks of lactation and sometimes by eczema of the nipples. Bacteria such as staphylococci and streptococci gain entry into the breast by development of cracks and fissures in the nipple. Initially a localised area of acute inflammation is produced which, if not effectively treated, may cause single or multiple breast abscesses.

Granulomatous Mastitis (p. 755)

Although chronic non-specific mastitis is uncommon, chronic granulomatous inflammation in the breast may occur as a result of the following:

1. *Systemic non-infectious granulomatous disease* e.g. as part of systemic sarcoidosis, Wegener's granulomatosis.
2. *Infections* e.g. tuberculosis which is not so uncommon in developing countries like India and may be misdiagnosed clinically as breast cancer

owing to axillary nodal involvement. Tubercle bacilli reach the breast by haematogenous, lymphatic or direct spread, usually from the lungs or pleura. Pathologically, typical caseating tubercles with discharging sinuses through the surface of the breast are found. ZN staining may demonstrate acid-fast bacilli.

3. *Silicone breast implants* implanted on breast cancer patients after mastectomy or as breast augmentation cosmetic surgery may rupture or silicone may slowly leak into surrounding breast tissue.

4. *Idiopathic granulomatous mastitis* is an uncommon form of reaction around lobules and ducts in the absence of any known etiology. Exact pathogenesis is not known but probably it is a form of hypersensitivity reaction to luminal secretion of the breast epithelium during lactation.

Mammary Duct Ectasia (Plasma Cell Mastitis) (p. 755)

Mammary duct ectasia is a condition in which one or more of the larger ducts of the breast are dilated and filled with inspissated secretions. These are associated with periductal and interstitial chronic inflammatory changes. Duct ectasia affects women in their 4th to 7th decades of life. The etiology of the condition remains unknown but it appears to begin with periductal inflammation followed by destruction of the elastic tissue to cause ectasia and periductal fibrosis.

G/A The condition appears as a single, poorly-defined indurated area in the breast with ropiness on the surface. Cut section shows dilated ducts containing cheesy inspissated secretions.

M/E The features are as under:

1. Dilated ducts with either necrotic or atrophic lining by flattened epithelium and lumen containing granular, amorphous, pink debris and foam cells.
2. Periductal and interstitial chronic inflammation, chiefly lymphocytes, histiocytes with multinucleate histiocytic giant cells. Sometimes, plasma cells are present in impressive numbers and the condition is then termed *plasma cell mastitis*.
3. Occasionally, there may be obliteration of the ducts by fibrous tissue and varying amount of inflammation and is termed *obliterative mastitis*.

Fat Necrosis (p. 755)

Focal fat necrosis of an obese and pendulous breast followed by an inflammatory reaction is generally initiated by trauma. The condition presents as a well-defined mass with indurated appearance.

G/A The excised lump has central pale cystic area of necrosis.

M/E There is disruption of the regular pattern of lipocytes with formation of lipid-filled spaces surrounded by neutrophils, lymphocytes, plasma cells and histiocytes having foamy cytoplasm and frequent foreign body giant cell formation. In late stage, there is replacement fibrosis and even calcification.

Galactocele (p. 755)

A galactocele is cystic dilatation of one or more ducts occurring during lactation. The mammary duct is obstructed and dilated to form a thin-walled cyst filled with milky fluid.

FIBROCYSTIC CHANGE (p. 755)

Fibrocystic change is the most common benign breast condition producing vague 'lumpy' breast rather than palpable lump in the breast. Its incidence has been reported to range from 10-20% in adult women, most often between 3rd and 5th decades of life, with dramatic decline in its incidence

630 after menopause suggesting the role of oestrogen in its pathogenesis. It was previously termed *fibrocystic disease* but is currently considered as an exaggerated physiologic phenomena and not a disease.

As such, fibrocystic change of the female breast is a histologic entity characterised by following features:

- i) Cystic dilatation of terminal ducts.
- ii) Relative increase in inter- and intralobular fibrous tissue.
- iii) Variable degree of epithelial proliferation in the terminal ducts.

It is important to identify the spectrum of histologic features by core needle biopsy or cytologic findings by FNAC in fibrocystic changes since only some subset of changes has an increased risk of development of breast cancer. Presently, the spectrum of histologic changes are divided into two clinicopathologically relevant groups:

A. Nonproliferative Fibrocystic Changes: Simple Fibrocystic Change (p. 756)

Simple fibrocystic change most commonly includes 2 features—formation of cysts of varying size, and increase in fibrous stroma.

G/A The cysts are rarely solitary but are usually multifocal and bilateral. They vary from microcysts to 5-6 cm in diameter. The usual large cyst is rounded, translucent with bluish colour prior to opening (blue-dome cyst).

M/E (Web Image 25.2): The features are as under:

- 1. Cyst formation:** The cyst lining shows a variety of appearances. Often, the epithelium is flattened or atrophic. Frequently, there is apocrine change or apocrine metaplasia in the lining of the cyst resembling the cells of apocrine sweat glands. Occasionally, there is simultaneous epithelial hyperplasia (discussed below) forming tiny intracystic papillary projections of piled up epithelium.
- 2. Fibrosis:** There is increased fibrous stroma surrounding the cysts and variable degree of stromal lymphocytic infiltrate.

B. Proliferative Fibrocystic Changes; Epithelial Hyperplasia and Sclerosing Adenosis (p. 756)

Proliferative fibrocystic change in the breasts includes 2 entities: epithelial hyperplasia and sclerosing adenosis.

EPITHELIAL HYPERPLASIA. Epithelial hyperplasia is defined as increase in the layers of epithelial cells over the basement membrane to three or more layers in the ducts (*ductal hyperplasia*) or lobules (*lobular hyperplasia*). The latter condition, lobular hyperplasia, must be distinguished from adenosis in which there is increase in the number of ductules or acini without any change in the number or type of cells lining them. Epithelial hyperplasia may be totally benign or may have atypical features. It is the latter type of hyperplasia which is precancerous and is associated with increased risk of developing breast cancer.

M/E Epithelial hyperplasia is characterised by epithelial proliferation to more than its normal double layer. In general, ductal hyperplasia is termed as *epithelial hyperplasia of usual type* and may show various grades of epithelial proliferations (mild, moderate and atypical) as under, while *lobular hyperplasia* involving the ductules or acini is always atypical:

- 1. Mild hyperplasia** of ductal epithelium consists of at least three layers of cells above the basement membrane, present focally or evenly throughout the duct.
- 2. Moderate and florid hyperplasia** of ductal type is associated with tendency to fill the ductal lumen with proliferated epithelium. Such epithelial proliferations into the lumina of ducts may be focal, forming papillary epithelial projections called *ductal papillomatosis*, or may be more extensive, termed

florid papillomatosis, or may fill the ductal lumen leaving only small fenestrations in it.

3. Of all the ductal hyperplasias, **atypical ductal hyperplasia** is more ominous and has to be distinguished from intraductal carcinoma. The proliferated epithelial cells in the atypical ductal hyperplasia partially fill the duct lumen and produce irregular microglandular spaces or *cribriform pattern*.

4. **Atypical lobular hyperplasia** is closely related to lobular carcinoma *in situ* but differs from the latter in having cytologically atypical cells only in half of the ductules or acini.

SCLEROSING ADENOSIS. Sclerosing adenosis is benign proliferation of small ductules or acini and intralobular fibrosis. The lesion may be present as diffusely scattered microscopic foci in the breast parenchyma, or may form an isolated palpable mass which may simulate an infiltrating carcinoma, both clinically and pathologically.

G/A The lesion may be coexistent with other components of fibrocystic disease, or may form an isolated mass which has hard cartilage-like consistency, resembling an infiltrating carcinoma.

M/E There is proliferation of ductules or acini and fibrous stromal overgrowth. The histologic appearance may superficially resemble infiltrating carcinoma but differs from the latter in having maintained lobular pattern and lack of infiltration into the surrounding fat.

Prognostic Significance (p. 757)

Since there is a variable degree of involvement of epithelial and mesenchymal elements in fibrocystic change, following prognostic implications may occur:

1. *Simple fibrocystic change* or *nonproliferative fibrocystic changes* of fibrosis and cyst formation do not carry any increased risk of developing invasive breast cancer.
2. Identification of *general proliferative fibrocystic changes* are associated with 1.5 to 2 times increased risk for development of invasive breast cancer.
3. *Multifocal and bilateral proliferative changes* in the breast pose increased risk to both the breasts equally.
4. Within the group of proliferative fibrocystic changes, *atypical hyperplasia* in particular, carries 4 to 5 times increased risk to develop invasive breast cancer later. This risk is further more if there is a history of breast cancer in the family.

□ GYNAECOMASTIA (HYPERTROPHY OF MALE BREAST) (p. 757)

Unilateral or bilateral enlargement of the male breast is known as gynaecomastia. The enlargement is mainly due to proliferation of ducts and increased periductal stroma. Gynaecomastia occurs in response to hormonal stimulation, mainly oestrogen. Such excessive oestrogenic activity in males is seen in young boys between 13 and 17 years of age (*pubertal gynaecomastia*), in men over 50 years (*senescent gynaecomastia*), in endocrine diseases associated with increased oestrogenic or decreased androgenic activity e.g. in hepatic cirrhosis, testicular tumours, pituitary tumours, carcinoma of the lung, exogenous oestrogen therapy as in carcinoma of the prostate and testicular atrophy.

G/A One or both the male breasts are enlarged having smooth glistening white tissue.

M/E The features are:

1. Proliferation of branching ducts which display epithelial hyperplasia with formation of papillary projections at places.
2. Increased fibrous stroma with, myxoid appearance.

Tumours of the female breast are common and clinically significant but are rare in men. Among the important benign breast tumours are fibroadenoma, phyllodes tumour (cystosarcoma phyllodes) and intraductal papilloma. Carcinoma of the breast is an important malignant tumour which occurs as non-invasive (carcinoma *in situ*) and invasive cancer with its various morphologic varieties.

□ **FIBROADENOMA** (p. 757)

Fibroadenoma or adenofibroma is a benign tumour of fibrous and epithelial elements. It is the most common benign tumour of the female breast. Though it can occur at any age during reproductive life, most patients are between 15 to 30 years of age. Clinically, fibroadenoma generally appears as a solitary, discrete, freely mobile nodule within the breast.

G/A Typical fibroadenoma is a small (2-4 cm diameter), solitary, well-encapsulated, spherical or discoid mass. The cut surface is firm, grey-white, slightly myxoid and may show slit-like spaces formed by compressed ducts. A fibroadenoma may be fairly large in size, up to 15 cm in diameter, and is called *giant fibroadenoma* but lacks the histologic features of cystosarcoma phyllodes.

M/E Fibrous tissue comprises most of a fibroadenoma. The arrangements between fibrous overgrowth and ducts may produce two types of patterns which may coexist in the same tumour. These are intracanalicular and pericanalicular patterns (**Web Image 25.3**):

- ◆ **Intracanalicular pattern** is one in which the stroma compresses the ducts so that they are reduced to slit-like clefts lined by ductal epithelium or may appear as cords of epithelial elements surrounding masses of fibrous stroma.
- ◆ **Pericanalicular pattern** is characterised by encircling masses of fibrous stroma around the patent or dilated ducts.

Occasionally, the fibrous tissue element in the tumour is scanty, and the tumour is instead predominantly composed of closely-packed ductular or acinar proliferation and is termed *tubular adenoma*. If an adenoma is composed of acini with secretory activity, it is called *lactating adenoma* seen during pregnancy or lactation. *Juvenile fibroadenoma* is an uncommon variant of fibroadenoma which is larger and rapidly growing mass seen in adolescent girls but fortunately does not recur after excision.

□ **PHYLLODES TUMOUR (CYSTOSARCOMA PHYLLODES)** (p. 758)

Cystosarcoma phyllodes was the nomenclature given by Müller in 1838 to an uncommon bulky breast tumour with leaf-like gross appearance (*phyllodes*=leaf-like) having an aggressive clinical behaviour. Most patients are between 30 to 70 years of age.

G/A The tumour is generally large, 10-15 cm in diameter, round to oval, bosselated, and less fully encapsulated than a fibroadenoma. The cut surface is grey-white with cystic cavities, areas of haemorrhages, necrosis and degenerative changes (**Web Image 25.4**).

M/E The phyllodes tumour is composed of an extremely hypercellular stroma, accompanied by proliferation of benign ductal structures. Thus, phyllodes tumour resembles fibroadenoma except for enhanced stromal cellularity. The histologic criteria used to distinguish benign, borderline and malignant categories of phyllodes tumour are as under:

- ◆ frequency of mitoses;
- ◆ cellular atypia;
- ◆ cellularity; and
- ◆ infiltrative margins.

About 20% of phyllodes tumours are histologically malignant and less than half of them may metastasise.

□ INTRADUCTAL PAPILLOMA (p. 759)

Intraductal papilloma is a benign papillary tumour occurring most commonly in a lactiferous duct or lactiferous sinus near the nipple. Clinically, it produces serous or serosanguineous nipple discharge. It is most common in 3rd and 4th decades of life.

G/A Intraductal papilloma is usually solitary, small, less than 1 cm in diameter, commonly located in the major mammary ducts close to the nipple. Less commonly, there are multiple papillomatosis which are more frequently related to a papillary carcinoma.

M/E An intraductal papilloma is characterised by multiple papillae having well-developed fibrovascular stalks attached to the ductal wall and covered by benign cuboidal epithelial cells supported by myoepithelial cells. An intraductal papillary carcinoma is distinguished from intraductal papilloma in having severe cytologic atypia, pleomorphism, absence of myoepithelial cells, multilayering and presence of mitotic figures.

□ CARCINOMA OF THE BREAST (p. 759)

Cancer of the breast is among the commonest of human cancers throughout the world. Its incidence varies in different countries but is particularly high in developed countries. Cancer of the male breast, on the other hand, is quite rare and comprises 0.2% of malignant tumours (ratio between male-female breast cancer is 1:100). The incidence of breast cancer is highest in the perimenopausal age group and is uncommon before the age of 25 years.

Currently, emphasis is on early diagnosis by mammography, xeroradiography and thermography. Techniques like fine needle aspiration cytology (FNAC), stereotactic biopsy and frozen section are immensely valuable to the surgeon for immediate pathological diagnosis.

Etiology (p. 759)

Based on current status of our knowledge, the following risk factors are considered significant in its etiology:

1. Geography. The incidence of breast cancer is about six times higher in developed countries than the developing countries, with the notable exception of Japan.

2. Genetic factors. Recently, much work has been done on the influence of family history and inherited mutations in breast cancer:

i) *Family history:* First-degree relatives (mother, sister, daughter) of women with breast cancer have 2 to 6-fold higher risk of development of breast cancer.

ii) *Genetic mutations:* About 10% breast cancers have been found to have inherited mutations. These mutations include the following, most important of which is breast cancer (*BRCA*) susceptibility gene in inherited breast cancer:

- ◆ *BRCA 1 gene* located on chromosome 17
- ◆ *BRCA 2 gene* located on chromosome 13
- ◆ Mutation in *p53* tumour suppressor gene
- ◆ Other mutations
- ◆ Ataxia telangiectasia gene
- ◆ PTEN

3. Oestrogen excess. There is sufficient evidence to suggest that excess endogenous oestrogen or exogenously administered oestrogen for prolonged duration is an important factor in the development of breast cancer. Normal breast epithelium possesses oestrogen and progesterone receptors. The

634 breast cancer cells secrete many growth factors which are oestrogen-dependent. In this way, the interplay of high circulating levels of oestrogen, oestrogen receptors and growth factors brings about progression of breast cancer.

4. Miscellaneous factors. These include a host of following environmental influences and dietary factors associated with increased risk of breast cancer:

- i) Consumption of large amounts of animal fats, high calorie foods.
- ii) Cigarette smoking.
- iii) Alcohol consumption.
- iv) Breast augmentation surgery.
- v) Exposure to ionising radiation during breast development.
- vi) Identification of a transmissible retrovirus in early 20th century, mouse mammary tumour virus (MMTV), also called *Bittner milk factor* transmitted from the infected mother-mice to the breast-fed daughter-mice prompted researchers to look for similar agent in human breast cancer. Though no such agent has yet been identified, there are reports of presence of reverse transcriptase in breast cancer cells.

5. Fibrocystic change. Fibrocystic change, particularly when associated with atypical epithelial hyperplasia, has about 5-fold higher risk of developing breast cancer subsequently.

General Features and Classification (p. 760)

Cancer of the breast occurs more often in left breast than the right and is bilateral in about 4% cases. Anatomically, upper outer quadrant is the site of tumour in half the breast cancers; followed in frequency by central portion, and equally in the remaining both lower and the upper inner quadrant as shown in **Web Image 25.5**.

Carcinoma of the breast arises from the ductal epithelium in 90% cases while the remaining 10% originate from the lobular epithelium. For variable period of time, the tumour cells remain confined within the ducts or lobules (non-invasive carcinoma) before they invade the breast stroma (invasive carcinoma). While only 2 types of *non-invasive carcinoma* have been described—intraductal carcinoma and lobular carcinoma *in situ*, there is a great variety of histological patterns of *invasive carcinoma breast* which have clinical correlations and prognostic implications (**Web Table 25.1**).

A. NON-INVASIVE (IN SITU) BREAST CARCINOMA (p. 760)

Intraductal Carcinoma (p. 760)

Carcinoma *in situ* confined within the larger mammary ducts is called intraductal carcinoma. The tumour initially begins with atypical hyperplasia of ductal epithelium followed by filling of the duct with tumour cells. Clinically, it produces a palpable mass in 30-75% of cases and presence of nipple discharge in about 30% patients. Approximately a quarter of patients of intraductal carcinoma treated with excisional biopsy alone develop ipsilateral invasive carcinoma during a follow-up period of 10 years while the chance of a contralateral breast cancer developing in patients with intraductal carcinoma is far less than that associated with *in situ* lobular carcinoma.

G/A The tumour may vary from a small poorly-defined focus to 3-5 cm diameter mass. On cut section, the involved area shows cystically dilated ducts containing cheesy necrotic material (in *comedo pattern*), or the intraductal tumour may be polypoid and friable resembling intraductal papilloma (in *papillary pattern*).

M/E The proliferating tumour cells within the ductal lumina may have 4 types of patterns in different combinations: solid, comedo, papillary and cribriform (**Web Image 25.6,A**):

- i) *Solid pattern* is characterised by filling and plugging of the ductal lumina with tumour cells.
- ii) *Comedo pattern* is centrally placed necrotic debris surrounded by neoplastic cells in the duct.
- iii) *Papillary pattern* has formation of intraductal papillary projections of tumour cells which lack a fibrovascular stalk so as to distinguish it from intraductal papilloma.
- iv) *Cribriform pattern* is recognised by neat punched out fenestrations in the intraductal tumour.

Lobular Carcinoma *in Situ* (p. 761)

Lobular carcinoma *in situ* is not a palpable or grossly visible tumour. Patients of *in situ* lobular carcinoma treated with excisional biopsy alone develop invasive cancer of the ipsilateral breast in about 25% cases in 10 years as in intraductal carcinoma but, in addition, have a much higher incidence of developing a contralateral breast cancer (30%).

G/A No visible tumour is identified.

M/E *In situ* lobular carcinoma is characterised by filling up of terminal ducts and ductules or acini by rather uniform cells which are loosely cohesive and have small, rounded nuclei with indistinct cytoplasmic margins (**Web Image 25.6,B**).

B. INVASIVE BREAST CARCINOMA (p. 761)

Infiltrating (Invasive) Duct Carcinoma-NOS (p. 761)

Infiltrating duct carcinoma-NOS (*not otherwise specified*) is the classic breast cancer and is the most common histologic pattern accounting for 70% cases of breast cancer. In fact, this is the pattern of cancer for which the terms 'cancer'. In fact, this is the pattern of cancer for which the terms 'cancer' and 'carcinoma' were first coined by Hippocrates. Clinically, majority of infiltrating duct carcinomas have a hard consistency due to dense collagenous stroma (scirrhous carcinoma).

G/A The tumour is irregular, 1-5 cm in diameter, hard cartilage-like mass that cuts with a grating sound. The sectioned surface of the tumour is grey-white to yellowish with chalky streaks and often extends irregularly into the surrounding fat (**Web Image 25.7**).

M/E As the name NOS suggests, the tumour is different from other special types in lacking a regular and uniform pattern throughout the lesion. A variety of histologic features commonly present are as under (**Web Image 25.8**):

- i) Anaplastic tumour cells forming solid nests, cords, poorly-formed glandular structures and some intraductal foci.
- ii) Infiltration by these patterns of tumour cells into diffuse fibrous stroma and fat.
- iii) Invasion into perivascular and perineural spaces as well as lymphatic and vascular invasion.

Infiltrating (Invasive) Lobular Carcinoma (p. 762)

Invasive lobular carcinoma comprises about 5% of all breast cancers. This peculiar morphologic form differs from other invasive cancers in being more frequently bilateral; and within the same breast, it may have multicentric origin.

G/A The appearance varies from a well-defined scirrhous mass to a poorly-defined area of induration that may remain undetected by inspection as well as palpation.

M/E (Web Image 25.9): The features are as under:

- i) **Pattern**—A characteristic single file (Indian file) linear arrangement of stromal infiltration by the tumour cells with very little tendency to gland

636 formation is seen. Infiltrating cells may be arranged concentrically around ducts in a target-like pattern.

ii) Tumour cytology—Individual tumour cells resemble cells of *in situ* lobular carcinoma. They are round and regular with very little pleomorphism and infrequent mitoses.

Medullary Carcinoma (p. 763)

Medullary carcinoma is a variant of ductal carcinoma and comprises about 1% of all breast cancers. The tumour has a significantly better prognosis than the usual infiltrating duct carcinoma, probably due to good host immune response in the form of lymphoid infiltrate in the tumour stroma.

G/A The tumour is characterised by a large, well-circumscribed, rounded mass that is typically soft and fleshy or brain-like and hence the alternative name of 'encephaloid carcinoma'. Cut section shows areas of haemorrhages and necrosis (**Web Image 25.10**).

M/E (**Web Image 25.11**): The features are as under:

i) Tumour cells—Sheets of large, pleomorphic tumour cells with abundant cytoplasm, large vesicular nuclei and many bizarre and atypical mitoses are diffusely spread in the scanty stroma.

ii) Stroma—The loose connective tissue stroma is scanty and usually has a prominent lymphoid infiltrate.

Colloid (Mucinous) Carcinoma (p. 763)

This is an uncommon pattern of breast cancer occurring more frequently in older women and is slow-growing. Colloid carcinoma has better prognosis than the usual infiltrating duct carcinoma.

G/A The tumour is usually a soft and gelatinous mass with well-demarcated borders.

M/E Colloid carcinoma contains large amount of extracellular epithelial mucin and acini filled with mucin. Cuboidal to tall columnar tumour cells, some showing mucus vacuolation, are seen floating in large lakes of mucin (**Web Image 25.12**).

Other Morphologic Forms (p. 763)

A few other morphologic forms of invasive breast carcinoma having clinical significance have been recognised:

PAPILLARY CARCINOMA. It is a rare variety of infiltrating duct carcinoma in which the stromal invasion is in the form of papillary structures.

1. TUBULAR CARCINOMA. Tubular carcinoma is an uncommon variant of invasive ductal carcinoma which has more favourable prognosis.

M/E The tumour is highly well-differentiated and has an orderly pattern. The tubules are quite even and distributed in dense fibrous stroma.

2. ADENOID CYSTIC CARCINOMA. Adenoid cystic or invasive cribriform carcinoma is a unique histologic pattern of breast cancer with excellent prognosis.

3. SECRETORY (JUVENILE) CARCINOMA. This pattern is found more frequently in children and has a better prognosis.

4. INFLAMMATORY CARCINOMA. Inflammatory carcinoma of the breast is a clinical entity and does not constitute a histological type. The term has been used for breast cancers in which there is redness, oedema, tenderness and rapid enlargement. Inflammatory carcinoma is associated with extensive invasion of dermal lymphatics and has a dismal prognosis.

5. METAPLASTIC CARCINOMA. Rarely, invasive ductal carcinomas may have various types of metaplastic alterations such as squamous metaplasia, cartilaginous and osseous metaplasia, or their combinations.

C. PAGET'S DISEASE OF THE NIPPLE (p. 764)

Paget's disease of the nipple is an eczematoid lesion of the nipple, often associated with an invasive or non-invasive ductal carcinoma of the underlying breast. The nipple bears a crusted, scaly and eczematoid lesion with a palpable subareolar mass in about half the cases. Most of the patients with palpable mass are found to have infiltrating duct carcinoma, while those with no palpable breast lump are usually subsequently found to have intraductal carcinoma.

The *pathogenesis* of Paget's disease of the breast is explained by the following 2 hypotheses:

1. The tumour cells from the underlying ductal carcinoma have migrated up into the lactiferous ducts and invaded the epidermis producing skin lesions.
2. An alternate theory, though less reliable than the former, is that Paget's disease represents a form of carcinoma *in situ* of the epidermis itself.

G/A The skin of the nipple and areola is crusted, fissured and ulcerated with oozing of serosanguineous fluid from the erosions (**Web Image 25.13, A**).

M/E The skin lesion is characterised by the presence of Paget's cells singly or in small clusters in the epidermis (**Web Image 25.13, B**). These cells are larger than the epidermal cells, spherical, having hyperchromatic nuclei with cytoplasmic halo that stains positively with mucicarmine. In these respects, Paget's cells are adenocarcinoma-type cells. In addition, the underlying breast contains invasive or non-invasive duct carcinoma which shows no obvious direct invasion of the skin of nipple.

GRADING, STAGING AND PROGNOSIS (P. 765)

A. HISTOLOGIC GRADING. The breast cancers are subdivided into various histologic grades depending upon the following parameters:

1. Histologic type of tumour. Based on classification described in **Web Table 25.1**, various microscopic types of breast cancer can be subdivided into 3 histologic grades:

- i) *Non-metastasising*—Intraductal and lobular carcinoma *in situ*.
- ii) *Less commonly metastasising*—Medullary, colloid, papillary, tubular, adenoid cystic (invasive cribriform), and secretory (juvenile) carcinomas.
- iii) *Commonly metastasising*—Infiltrating duct, invasive lobular, and inflammatory carcinomas.

2. Microscopic grade. Widely used system for microscopic grading of breast carcinoma is that of Nottingham modification of the Bloom-Richardson system. It is based on 3 features:

- i) Tubule formation
- ii) Nuclear pleomorphism
- iii) Mitotic count.

3. Tumour size. There is generally an inverse relationship between diameter of primary breast cancer at the time of mastectomy and long-term survival.

4. Axillary lymph node metastasis. Survival rate is based on the number and level of lymph nodes involved by metastasis. More the number of regional lymph nodes involved, worse is the survival rate. Involvement of the lymph nodes from proximal to distal axilla (i.e. *level I*—superficial axilla, to *level III*—deep axilla) is directly correlated with the survival rate. In this regards, identification and dissection of sentinel lymph node followed by its histopathologic examination has attained immense prognostic value (*Sentinel lymph node* is the first node in the vicinity to receive drainage from primary cancer i.e. it stands 'sentinel' over the tumour).

5. Oestrogen and progesterone receptors (ER/PR). Oestrogen is known to promote the breast cancer. Presence or absence of hormone receptors

638 on the tumour cells can help in predicting the response of breast cancer to endocrine therapy (**Web Image 25.14**). Accordingly, patients with high levels of ER and PR on breast tumour cells have a slightly better prognosis.

6. HER2/neu overexpression. *HER2/neu* (also called *erbB2*), a member of the family of epidermal growth factors, is a transmembrane protein having tyrosine kinase activity. It can be detected by immunohistochemistry or by fluorescence in situ hybridisation (FISH) and is considered as a good predictive marker. An individual having overexpression of *HER2/neu* by tumour cells is likely to respond higher dose of herceptin therapy but is not related to other forms of chemotherapy.

7. DNA content. Tumour cell subpopulations with aneuploid DNA content as evaluated by mitotic markers (e.g. Ki-67) or by flow cytometry have a worse prognosis than purely diploid tumours.

B. CLINICAL STAGING. The American Joint Committee (AJC) on cancer staging has modified the TNM (primary Tumour, Nodal, and distant Metastasis) staging proposed by UICC (Union International for Control of Cancer) and is shown in **Web Table 25.2**.

Spread of breast cancer to axillary lymph nodes occurs early. Common sites for haematogenous metastatic spread from breast cancer are the lungs, liver, bones, adrenals, brain and ovaries.

C. PROGNOSTIC FACTORS IN BREAST CANCER. These prognostic factors are divided into following 3 groups:

1. Potentially pre-malignant lesions. These include following:

- i) *Atypical ductal hyperplasia* is associated with 4-5 times increased risk than women of the same age.
- ii) *Clinging carcinoma* is a related lesion in the duct but different from carcinoma *in situ* and has lower risk of progression to invasive cancer than *in situ* carcinoma.
- iii) *Fibroadenoma* is a long-term risk factor (after over 20 years) for invasive breast cancer, the risk being about twice compared to controls.

2. Breast carcinoma *in situ*. Following factors act as determinants:

- i) *Ductal carcinoma in situ* (comedo and non-comedo subtypes) is diagnosed on the basis of three histologic features—nuclear grade, nuclear morphology and necrosis, while *lobular neoplasia* includes full spectrum of changes of lobular carcinoma *in situ* and atypical lobular hyperplasia. Ductal carcinoma *in situ* is more important and demands most attention.
- ii) *Breast conservative therapy* is used more frequently nowadays in carcinoma *in situ* which requires consideration of three factors for management: *margins*, *extent of disease*, and *biological markers*. The biological markers such as *p53* and *BCL-2* have low positivity in high-grade *in situ* ductal carcinoma and likelihood of recurrences after conservative surgery.

3. Invasive breast cancer. Prognostic and predictive factors for invasive breast cancer have been extensively studied and can be broadly divided into 3 groups:

1. routine histopathology criteria;
2. hormone receptor status; and
3. biological indicators.

A summary combining all these factors is given in **Web Table 25.3**.

Overall, taking the most important parameter of node-positive or node-negative breast cancer, the prognosis varies—localised form of breast cancer without axillary lymph node involvement has a survival rate of 84% while survival rate falls to 56% with nodal metastases.

1. **Mammary duct ectasia is characterised by the following features except:**
 - A. It affects women in 2nd to 3rd decade of life
 - B. There are dilated ducts containing inspissated secretions
 - C. There is periductal chronic inflammation
 - D. There may be presence of multinucleate giant cells
2. **Out of the various epithelial hyperplasias in breast the most ominous is:**
 - A. Papillary ductal hyperplasia
 - B. Florid ductal papillomatosis
 - C. Lobular hyperplasia
 - D. Epithelial hyperplasia of usual type
3. **Tubular adenoma of breast is mainly composed of:**
 - A. Closely-packed ductules
 - B. Ductal epithelial hyperplasia
 - C. Lobular hyperplasia
 - D. Lactational hyperplasia
4. **Phyllodes tumour is distinguished from fibroadenoma by having:**
 - A. More ductal hyperplasia
 - B. Compressed ducts
 - C. More cellular stroma
 - D. More lobular hyperplasia
5. **Intraductal papilloma occurs most often in the following region:**
 - A. Collecting ducts
 - B. Lactiferous ducts
 - C. Terminal ducts
 - D. Acini
6. **Lobular carcinoma *in situ* has the following features except:**
 - A. A palpable lump is generally present
 - B. After excision, about 25% cases develop ipsilateral invasive cancer in 10 years
 - C. There is a higher incidence of bilaterality
 - D. The tumour cells are rather uniform and cohesive
7. **The following type of carcinoma of the breast is characterised by 'Indian file' pattern of tumour cells:**
 - A. Infiltrating duct carcinoma
 - B. Invasive lobular carcinoma
 - C. Medullary carcinoma
 - D. Tubular carcinoma
8. **The following type of breast carcinoma is seen in children:**
 - A. Papillary carcinoma
 - B. Adenoid cystic carcinoma
 - C. Secretory carcinoma
 - D. Metaplastic carcinoma
9. **Paget's cells in Paget's disease of the breast are malignant cells of following type:**
 - A. Squamous cell carcinoma
 - B. Basal cell carcinoma
 - C. Melanoma
 - D. Adenocarcinoma
10. **Patients of breast cancer having high levels of oestrogen receptors imply:**
 - A. Patient has an anaplastic breast cancer
 - B. Anti-oestrogen therapy will be helpful
 - C. Patient has an oestrogen-secreting ovarian tumour
 - D. Patient is likely to have poor prognosis
11. **Men who have mutated *BRCA 1* have increased risk of following cancer:**
 - A. Male breast
 - B. Germ cell tumours of testis
 - C. Sex-cord-stromal tumour of testis
 - D. Carcinoma of prostate

- 640 12. What percentage of phyllodes tumours are malignant:
A. 10% B. 20%
C. 30% D. 40%
13. All are genetic mutations seen in breast cancer *except*:
A. BRCA-1 B. p53
C. PTEN D. Rb
14. All are true about medullary carcinoma breast *except*:
A. Worse prognosis than IDC
B. Prominent lymphoid infiltrate
C. Bizarre & atypical mitosis
D. Soft & fleshy consistency
15. Which of the following feature is *not* used in modified Bloom Richardson grading system for breast cancer:
A. Tubule formation B. Nuclear pleomorphosis
C. Mitotic count D. Tumour necrosis
16. HER2/neu overexpression in breast cancer:
A. Is a bad prognostic marker
B. Responds to herceptin therapy
C. Responds to tamoxifen
D. Is a serum marker for breast cancer

KEY

1 = A	2 = C	3 = A	4 = C
5 = B	6 = A	7 = B	8 = C
9 = D	10 = B	11 = D	12 = B
13 = D	14 = A	15 = D	16 = B



The Skin

NORMAL STRUCTURE (p. 768)

The histology of normal skin shows some variation in different parts of the body. In general, it is composed of 2 layers, the epidermis and the dermis, which are separated by an irregular border. Cone-shaped dermal papillae extend upward into the epidermis forming peg-like *rete ridges* of the epidermis.

Web Image 26.1 presents a diagrammatic representation of the main structures identifiable in a section of the normal skin while **Web Image 26.2** shows the various layers of the epidermis.

□ EPIDERMIS (p. 768)

The epidermis is composed of the following 5 layers from base to the surface:

1. Basal cell layer (stratum germinatum)
2. Prickle cell layer (Stratum spinosum, Stratum malpighii)
3. Granular cell layer (stratum granulosum)
4. Stratum lucidum
5. Horny layer (Stratum corneum)

□ DERMIS (p. 769)

The dermis consists of 2 parts—the superficial *pars papillaris* or *papillary dermis*, and the deeper *pars reticularis* or *reticular dermis*. The dermis is composed of fibrocollagenic tissue containing blood vessels, lymphatics and nerves. In the skin of fingers, arteriovenous shunts or *glomera* are normally present. The specialised nerve endings present at some sites perform specific functions. These are as under:

◆ *Pacinian corpuscles* concerned with pressure are present in the deep layer of skin.

◆ *Meissner corpuscles* are touch receptors, located in the papillae of skin of palms, soles, tips of fingers and toes.

◆ *Ruffini corpuscles* are cold receptors found in the external genitalia.

◆ *End-bulbs of Krause* are cold receptors found in the external genitalia. Besides these structures, the dermis contains cutaneous appendages or adnexal structures:

1. *Sweat glands*. These are of 2 types—eccrine and apocrine.
2. *Sebaceous (holocrine) glands*
3. *Hair*
4. *Arrectores pilori*
5. *Nails*.

□ HISTOPATHOLOGIC TERMS (p. 769)

Acanthosis: Thickening of the epidermis due to hyperplasia of stratum malpighii.

Acantholysis: Loss of cohesion between epidermal cells with formation of intraepidermal space containing oedema fluid and detached epithelial cells.

Dyskeratosis: Abnormal development of epidermal cells resulting in rounded cells devoid of their prickles and having pyknotic nuclei. Dyskeratosis is a feature of premalignant and malignant lesions and is rarely seen in benign conditions.

642 **Hyperkeratosis:** Thickening of the horny layer.

Parakeratosis: Abnormal keratinisation of the cells so that the horny layer contains nucleated keratinocytes rather than the normal non-nucleate keratin layer.

Spongiosis: Intercellular oedema of the epidermis which may progress to vesicle formation in the epidermis.

Pigment incontinence: Loss of melanin pigment from damaged basal cell layer so that the pigment accumulates in the melanophages in the dermis.

DERMATOSES (p. 769)

□ I. GENETIC DERMATOSES (p. 769)

1. **ICHTHYOSIS.** Two important forms of ichthyosis are— *ichthyosis vulgaris* and *sex-linked ichthyosis*.

◆ **Ichthyosis vulgaris** is an autosomal dominant disorder. It is more common and appears a few months after birth as scaly lesions on the extensor surfaces of the extremities.

◆ **Sex-linked ichthyosis** is a sex-(X) linked recessive disorder. It begins shortly after birth and affects extensor as well as flexor surfaces but palms and hands are spared.

2. **KERATOSIS PALMARIS ET PLANTARIS.** The condition occurs as both autosomal dominant and autosomal recessive forms. It mainly affects the palms and soles as localised or diffuse lesions.

3. **XERODERMA PIGMENTOSUM.** This is an autosomal recessive disorder in which sun-exposed skin is more vulnerable to damage. The condition results from decreased ability to repair the sunlight-induced damage to DNA. Patients of xeroderma pigmentosum are more prone to develop various skin cancers like squamous cell carcinoma, basal cell carcinoma and melanocarcinoma.

M/E The changes include hyperkeratosis, thinning and atrophy of stratum malpighii, chronic inflammatory cell infiltrate in the dermis and irregular accumulation of melanin in the basal cell layer.

4. **DARIER'S DISEASE (KERATOSIS FOLLICULARIS).** The condition is either transmitted as autosomal dominant disorder or as a mutation. In typical cases, there is extensive papular eruption.

M/E The characteristic changes are hyperkeratosis, papillomatosis and dyskeratosis. Dyskeratosis results in the formation of '*corps ronds*' (present in the granular layer as a central homogeneous basophilic dyskeratotic mass surrounded by a clear halo) and '*grains*' (having grain-shaped elongated nuclei surrounded by homogeneous dyskeratotic material) and there is appearance of suprabasal clefts containing acantholytic cells.

5. **URTICARIA PIGMENTOSA.** Urticaria pigmentosa may occur as congenital form or may appear without any family history in the adolescents. Clinically, the condition presents as extensive pigmented macules.

M/E The epidermis is normal except for an increase in melanin pigmentation in the basal cell layer. The characteristic feature is the presence of numerous mast cells in the dermis.

6. **ATAXIA TELANGIECTASIA.** An autosomal recessive disorder, ataxia appears in infancy, while telangiectasia appears in childhood. The lesions are located on the conjunctivae, cheeks, ears and neck.

M/E The papillary dermis shows numerous dilated blood vessels.

□ II. NON-INFECTIOUS INFLAMMATORY DERMATOSES (p. 770)

1. **DERMATITIS (ECZEMA).** The pathologic term dermatitis is synonymous with the clinical term eczema. Both refer to inflammatory response to a

variety of agents acting on the skin from outside or from within the body such as chemicals and drugs, hypersensitivity to various antigens and haptens etc. Accordingly, clinical types such as contact dermatitis, atopic dermatitis, drug-induced dermatitis, photo-eczematous dermatitis and primary irritant dermatitis are described.

M/E Dermatitis reaction may be acute, subacute or chronic:

- ◆ **Acute dermatitis** is characterised by considerable spongiosis (intercellular oedema) that may lead to formation of intraepidermal vesicles or bullae. The vesicles and bullae as well as the oedematous epidermis are permeated by acute inflammatory cells. The upper dermis shows congested blood vessels and mononuclear inflammatory cell infiltrate, especially around the small blood vessels.

- ◆ **Subacute dermatitis** may follow acute dermatitis. Spongiosis and vesicles are smaller than in acute dermatitis. The epidermis shows moderate acanthosis and varying degree of parakeratosis in the horny layer with formation of surface crusts containing degenerated leucocytes, bacteria and fibrin. The dermis contains perivascular mononuclear infiltrate. The classical example of subacute dermatitis is *nummular dermatitis*.

- ◆ **Chronic dermatitis** shows hyperkeratosis, parakeratosis and acanthosis with elongation of the rete ridges and broadened dermal papillae. Vesicles are absent but slight spongiosis may be present. The upper dermis shows perivascular chronic inflammatory infiltrate and fibrosis (**Web Image 26.3**).

2. URTICARIA. Urticaria or hives is the presence of transient, recurrent, pruritic wheals (i.e. raised erythematous areas of oedema). Hereditary angioneurotic oedema is an uncommon variant of urticaria in which there is recurrent oedema not only on the skin but also on the oral, laryngeal and gastrointestinal mucosa.

3. MILIARIA. Miliaria is a condition in which there is cutaneous retention of sweat due to obstruction of sweat ducts. There are 2 types of miliaria:

- ◆ **Miliaria crystallina** occurs when there is obstruction of sweat duct within the stratum corneum. It occurs in areas of the skin exposed to sun or may occur during a febrile illness.

- ◆ **Miliaria rubra** occurs when there is obstruction of sweat ducts within the deeper layers of the epidermis. It is seen more often in areas of skin covered by clothes following profuse sweating and the lesions are itchy.

4. PANNICULITIS (ERYTHEMA NODOSUM AND ERYTHEMA INDURATUM). Panniculitis is inflammation of the subcutaneous fat. Panniculitis may be acute or chronic. Generally, panniculitis appears as nodular lesions, predominantly on the lower legs. The following types of panniculitis are described:

- ◆ **Erythema nodosum**, acute or chronic, is the most common form. The lesions consist of tender red nodules, 1-5 cm in diameter, seen more often on the anterior surface of the lower legs.

- ◆ **Erythema induratum** is a less common variety. The lesions are chronic, painless, slightly tender, recurrent and found on the calves of lower legs.

M/E The early lesions show necrotising vasculitis involving the blood vessels in the deep dermis and subcutis. In chronic stage, there is inflammatory infiltrate consisting of lymphocytes, histiocytes and multinucleate giant cells. The infiltrate is located in the septa separating the lobules of fat.

5. ACNE VULGARIS. Acne vulgaris is a very common chronic inflammatory dermatosis found predominantly in adolescents in both sexes. The lesions are seen more commonly on the face, upper chest and upper back. The appearance of lesions around puberty is related to physiologic hormonal variations. The condition affects the hair follicle, the opening of which is blocked by keratin material resulting in formation of *comedones*.

644 **M/E** A comedone consists of keratinised cells, sebum and bacteria. The hair follicle containing a comedone is surrounded by lymphocytic infiltrate in papular acne, and neutrophilic infiltrate in pustular acne.

□ **III. INFECTIOUS DERMATOSES (p. 771)**

1. IMPETIGO. Impetigo is a common superficial bacterial infection caused by staphylococci and streptococci. The condition may occur in children or in adults and more commonly involves hands and face. The lesions appear as vesico-pustules which may rupture and are followed by characteristic yellowish crusts.

M/E The characteristic feature is the subcorneal pustule which is a collection of neutrophils under the stratum corneum. Often, a few acantholytic cells and gram-positive bacteria are found within the pustule. The upper dermis contains severe inflammatory reaction composed of neutrophils and lymphoid cells.

2. VERRUCAE (WARTS). Verrucae or warts are common viral lesions of the skin. They are caused by human papillomaviruses (HPV) that belong to papovavirus group, a type of DNA oncogenic virus. Various types of HPVs have variable oncogenic potential as summed up in **Web Table 26.1**. Infection with HPV is acquired by direct contact or by autoinoculation. They are classified into different types described below.

i) **Verruca vulgaris** is the most common human wart, commonly caused by HPV-1 and 2. The lesions are often multiple, less than 1 cm in size, circumscribed, firm, elevated papules occurring more commonly on the dorsal surfaces of hands and fingers.

ii) **Verruca plana** on the other hand, is flat or slightly elevated wart, common on the face and dorsal surface of hands and is usually associated with HPV-10.

iii) **Verruca planatairs or plantar warts** occur on the sole of the foot and is caused by HPV-1. They are covered with a thick callus.

iv) **Epidermodysplasia verruciformis** resembles verruca plana but differs by having familial occurrence with autosomal recessive inheritance. Epidermodysplasia verruciformis is of special clinical significance as it may undergo malignant change, usually into Bowen's disease, and occasionally into squamous cell carcinoma.

v) **Condyloma acuminatum or venereal wart or anogenital wart** occurs on the penis, on the vulva and around the anus. They are commonly caused by HPV-6. The lesions appear as soft, papillary, cauliflower-like mass that may grow fairly large in size (giant condyloma acuminata).

M/E Prototype of verruca is common viral wart having following features (**Web Image 26.4**):

- i) Papillomatosis (papillary folds).
- ii) Acanthosis (hyperplasia of stratum malpighii containing foci of vacuolated cells in the upper stratum malpighii).
- iii) Hyperkeratosis with parakeratosis.
- iv) Clumped keratohyaline granules in the granular cells in the valleys between adjacent papillae.
- v) Elongation of rete ridges with their lower tips bent inwards.
- vi) Virus-infected epidermal cells contain prominent vacuolation (koilocytosis) and keratohyaline granules of intracytoplasmic keratin aggregates due to viral cytopathic effects.

3. MOLLUSCUM CONTAGIOSUM. Molluscum contagiosum is a common self-limiting contagious lesion caused by a poxvirus which is a DNA virus. It is more common in children and young adults. Infection is acquired by direct contact.

M/E Typical lesion consists of sharply circumscribed cup-like epidermal lesion growing down into the dermis. The proliferating epidermal cells contain the pathognomonic intracytoplasmic eosinophilic inclusion bodies called *molluscum bodies* (**Web Image 26.5**).

4. VIRAL EXANTHEMATA. Viral exanthemata are a group of contagious conditions in which the epidermal cells are destroyed by replicating viruses causing eruption or rash. There are predominantly two groups of viruses which may cause exanthem. These are: the *poxvirus group* (e.g. smallpox or variola, cowpox or vaccinia), and the *herpesvirus group* (e.g. chickenpox or varicella, herpes zoster or shingles, herpes simplex).

M/E The characteristic feature of viral exanthemata is the formation of intra-epidermal vesicles or bullae due to cytopathic effects of viruses. In the early stage, there is proliferation of epidermal cells and formation of multinucleate giant cells.

5. SUPERFICIAL MYCOSES. Superficial fungal infections of the skin are localised to stratum corneum. These include some of the common dermatophytes such as *Trichophyton rubrum* and *Pityrosporum*. Clinically, these fungal infections are labelled according to the region involved. These are as follows:

- i) **Tinea capitis** occurring on the scalp, especially in children.
- ii) **Tinea barbae** affecting the region of beard in adult males.
- iii) **Tinea corporis** involving the body surface at all ages.
- iv) **Tinea cruris** occurs most frequently in the region of groin in obese men, especially in hot weather.
- v) **Tinea pedis** or 'athlete foot' is located in the web spaces between the toes.
- vi) **Onychomycosis** shows disintegration of the nail substance.
- vii) **Tinea versicolor** caused by *Malassezia furfur* generally affects the upper trunk.

M/E Fungal hyphae (or mycelia) and arthrospores of dermatophytes are present in the stratum corneum of skin, nails or hair. Spores are round to oval bodies which grow by budding. Special stains can be used to demonstrate the fungi. These are: *periodic acid-Schiff (PAS) reaction* which stains the fungi deep pink to red (**Web Image 26.6**), and *methenamine silver nitrate method* that stains fungi black.

□ IV. GRANULOMATOUS DISEASES (p. 774)

1. LUPUS VULGARIS. The lesions of lupus vulgaris, the prototype of skin tuberculosis, are found most commonly on the head and neck, especially skin of the nose. They are yellowish-brown to reddish-brown tiny nodules (apple-jelly nodules).

M/E The nodules consist of well-defined tubercles lying in the upper dermis. They consist of accumulation of epithelioid cells surrounded by lymphoid cells. Caseation necrosis may be slight or absent. Langhans' and foreign body type of giant cells are often present (**Web Image 26.7**).

2. CUTANEOUS SARCOIDOSIS. Sarcoidosis is a systemic granulomatous disease of unknown etiology. The lesions appear in the lungs, skin, eyes, nose and lymph nodes. Cutaneous manifestations appear as presenting feature in about a quarter of patients.

M/E Characteristic feature is the presence of non-caseating epithelioid cell granulomas having Langhans' giant cells but having paucity of lymphocytes, also called 'naked granulomas' (**Web Image 26.8**). Fibrinoid necrosis and presence of intracellular inclusions such as asteroid bodies are some other features which may be seen.

3. GRANULOMA ANNULARE. The lesions of granuloma annulare are often numerous. Dermal nodules are arranged in a ring-like fashion,

646 commonly on the hands and feet. The condition appears to have correlation with diabetes mellitus.

M/E The centre of the lesion shows a well demarcated focus of complete collagen degeneration. These foci are surrounded by an infiltrate composed largely of histiocytes and some mononuclear inflammatory cells forming a palisade arrangement.

□ **V. CONNECTIVE TISSUE DISEASES** (p. 774)

1. LUPUS ERYTHEMATOSUS. Two types of lupus erythematosus are recognised—a chronic form, *discoid lupus erythematosus (DLE)* which is confined to the skin; and a systemic form, *systemic lupus erythematosus (SLE)* that has widespread visceral vascular lesions. The discoid variety is more common which is generally benign, while systemic form may be fatal, usually from renal involvement. The diagnosis is made on the basis of clinical, serologic and pathologic changes.

M/E Cutaneous lesion in DLE and SLE may not be distinguishable in all cases (**Web Image 26.9**):

- i) Hyperkeratosis with keratotic plugging.
- ii) Thinning and flattening of rete malpighii.
- iii) Hydropic degeneration of basal layer.
- iv) Patchy lymphoid infiltrate around cutaneous adnexal structures.
- v) Upper dermis showing oedema, vasodilatation and extravasation of red cells.

Direct immunofluorescence reveals granular deposits of immunoglobulins, most commonly IgG and IgM, and components of complement on the basement membrane of the affected skin in both DLE and SLE.

2. SYSTEMIC SCLEROSIS (SCLERODERMA). Two types of systemic sclerosis or scleroderma are identified: a localised form called *morphea*, and a generalised form called *progressive systemic sclerosis*. A variant of progressive systemic sclerosis is *CREST syndrome*. (C = calcinosis, R = Raynaud's phenomenon, E = esophageal dysmotility, S = sclerodactyly and T = telangiectasia). *Morphea* consists of lesions limited to the skin and subcutaneous tissue, while *progressive systemic sclerosis* consists of extensive involvement of the skin and the subcutaneous tissue and has visceral lesions too.

M/E There is thickening of the dermal collagen extending into the subcutaneous tissue. There is pronounced chronic inflammatory infiltrate in the affected area. The epidermis is often thin, devoid of rete ridges and adnexal structures, and there is hyalinised thickening of the walls of dermal arterioles and capillaries.

3. LICHEN SCLEROSUS ET ATROPHICUS. This condition involves genital skin most frequently and is often the only site of involvement. It occurs in both sexes, more commonly in women than in men. It is termed *kraurosis vulvae* in women while the counterpart in men is referred to as *balanitis xerotica obliterans*.

M/E The characteristic features are as under:

- i) Hyperkeratosis with follicular plugging.
- ii) Thinning and atrophy of the epidermis.
- iii) Hydropic degeneration of the basal layer.
- iv) Upper dermis showing oedema and hyaline appearance of collagen.
- v) Inflammatory infiltrate in mid-dermis.

□ **VI. NON-INFECTIOUS BULLOUS DERMATOSES** (p. 775)

A few common examples of noninfectious dermatoses are pemphigus, pemphigoid, dermatitis herpetiformis and erythema multiforme and are illustrated in **Web Image 26.10**.

1. PEMPHIGUS. Pemphigus is an autoimmune bullous disease of the skin and mucosa which has 4 clinical and pathologic variants:

i) **Pemphigus vulgaris** is the most common type characterised by the development of flaccid bullae on the skin and oral mucosa. These bullae break easily leaving behind denuded surface.

M/E The bullae are suprabasal in location so that the basal layer remains attached to dermis like a row of tombstones. The bullous cavity contains serum and acantholytic epidermal cells (**Web Image 26.11**).

ii) **Pemphigus vegetans** is an uncommon variant consisting of early lesions resembling pemphigus vulgaris. But later, verrucous vegetations are found on the skin and oral mucosa instead of bullous lesions.

M/E There is considerable acanthosis and papillomatosis. Intraepidermal abscesses composed almost entirely of eosinophils are diagnostic of pemphigus vegetans (**Web Image 24.4,B**).

iii) **Pemphigus foliaceus** is characterised by quite superficial bullae which leave shallow zones of erythema and crust.

M/E Superficial subcorneal bullae are found which contain acantholytic epidermal cells.

iv) **Pemphigus erythematosus** is an early form of pemphigus foliaceus. The distribution of clinical lesions is similar to lupus erythematosus involving face.

M/E The picture is identical to that of pemphigus foliaceus.

2. PEMPHIGOID. This is a form of bullous disease affecting skin or the mucous membranes. Three variants have been described—*localised form* occurring on the lower extremities; *vesicular form* consisting of small tense blisters; and *vegetating form* having verrucous vegetations found mainly in the axillae and groins.

M/E The characteristic distinguishing feature from pemphigus is the subepidermal location of the non-acantholytic bullae. With passage of time, there is some epidermal regeneration from the periphery at the floor of the bulla. The bullous cavity contains fibrin network and many mononuclear inflammatory cells and many eosinophils (**Web Image 26.12**).

3. DERMATITIS HERPETIFORMIS. Dermatitis herpetiformis is a form of chronic, pruritic, vesicular dermatosis. The lesions are found more commonly in males in 3rd to 4th decades of life. The disease has an association with gluten-sensitive enteropathy (coeliac disease).

M/E The early lesions of dermatitis herpetiformis consist of neutrophilic micro-abscesses at the tips of papillae, producing separation or blister between the papillary dermis and the epidermis (**Web Image 26.13**). The older blisters contain fair number of eosinophils causing confusion with bullous pemphigoid. Direct immunofluorescence shows granular deposits of IgA at the papillary tips in dermatitis herpetiformis.

4. ERYTHEMA MULTIFORME. This is an acute, self-limiting but recurrent dermatosis. The condition occurs due to hypersensitivity to certain infections and drugs, and in many cases, it is idiopathic. As the name suggests, the lesions are *multiform* such as macular, papular, vesicular and bullous. Quite often, the lesions have symmetric involvement of the extremities. *Stevens-Johnson syndrome* is a severe, at times fatal, form of involvement of skin and mucous membranes of the mouth, conjunctivae, genital and perianal area.

M/E The changes vary according to the clinical multiform stage.

i) *Early lesions* show oedema and lymphocytic infiltrate at the dermo-epidermal junction. The superficial dermis shows perivascular lymphocytic infiltrate.

- 648 ii) *Later stage* is associated with migration of lymphocytes upwards into the epidermis resulting in epidermal necrosis and blister formation (**Web Image 26.14**).

□ **VII. SCALING DERMATOSES** (p. 778)

1. PSORIASIS. Psoriasis is a chronic inflammatory dermatosis that affects about 2% of the population. It usually appears first between the age of 15 and 30 years. The lesions are characterised by brownish-red papules and plaques which are sharply demarcated and are covered with fine, silvery white scales. As the scales are removed by gentle scrapping, fine bleeding points appear termed *Auspitz sign*.

M/E (Web Image 26.15): The features are as under:

- i) Acanthosis with regular downgrowth of rete ridges to almost the same dermal level with thickening of their lower portion.
- ii) Elongation and oedema of the dermal papillae with broadening of their tips.
- iii) Suprapapillary thinning of stratum malpighii.
- iv) Absence of granular cell layer.
- v) Prominent parakeratosis.
- vi) Presence of Munro microabscesses in the parakeratotic horny layer is diagnostic of psoriasis.

2. LICHEN PLANUS. Lichen planus is a chronic dermatosis characterised clinically by irregular, violaceous, shining, flat-topped, pruritic papules. The lesions are distributed symmetrically with sites of predilection being flexor surfaces of the wrists, forearms, legs and external genitalia. Buccal mucosa is also involved in many cases of lichen planus.

M/E (Web Image 26.16): The features are:

- i) Marked hyperkeratosis.
- ii) Focal hypergranulosis.
- iii) Irregular acanthosis with elongated saw-toothed rete ridges.
- iv) Liquefactive degeneration of the basal layer.
- v) A band-like dermal infiltrate of mononuclear cells, sharply demarcated at its lower border and closely hugging the basal layer.

□ **VIII. METABOLIC DISEASES OF SKIN** (p. 778)

1. Amyloidosis (primary as well as secondary).
2. Lipoid proteinosis is rare.
3. Porphyria of various types.
4. Calcinosis cutis
5. Gout due to urate deposits or tophi.
6. Ochronosis due to alkaptonuria.
7. Mucinosis seen in myxoedema.
8. Idiopathic haemochromatosis with skin pigmentation.

CALCINOSIS CUTIS. There are four types of calcification in the skin:

- i) Metastatic calcinosis cutis
 - ii) Dystrophic calcinosis cutis
 - iii) Idiopathic calcinosis cutis
 - iv) Subepidermal calcified nodule
- i) **Metastatic calcinosis cutis** develops due to hypercalcaemia or hyperphosphataemia.
 - ii) **Dystrophic calcinosis cutis** results when there is deposition of calcium salts at damaged tissue.
 - iii) **Idiopathic calcinosis cutis** resembles dystrophic type but is not associated with any underlying disease. A special manifestation of idiopathic calcinosis cutis is *tumoral calcinosis* in which there are large subcutaneous

calcified masses, often accompanied by foreign body giant cell reaction. Calcium may discharge from the surface of the lesion. *Idiopathic calcinosis of the scrotum* consists of multiple asymptomatic nodules of the scrotal skin (**Web Image 26.17**).

iv) **Subepidermal calcified nodule** or *cutaneous calculus* is a single raised hard calcified nodule in the upper dermis.

TUMOURS AND TUMOUR-LIKE LESIONS (p. 779)

Tumours and tumour-like lesions may arise from different components of the skin such as surface epidermis, epidermal appendages and dermal tissues. Each of these tissues may give rise to benign and malignant tumours as well as tumour-like lesions. Besides these, there is a group of conditions and lesions which are precancerous. Another group of tumours have their origin from elsewhere in the body but are cellular migrants to the skin. A comprehensive list of tumours and tumour-like lesions of the skin is presented in **Web Table 26.2**.

□ I. TUMOURS AND CYSTS OF THE EPIDERMIS (p. 780)

A. Benign Tumours (p. 780)

1. **SQUAMOUS PAPILLOMA.** Squamous papilloma is a benign epithelial tumour of the skin. Though considered by many authors to include common viral warts (*verrucae*) and *condyloma acuminata*, true squamous papillomas differ from these viral lesions.

M/E squamous papillomas are characterised by hyperkeratosis, acanthosis with elongation of rete ridges and papillomatosis (**Web Image 26.18**). The *verrucae*, in addition to these features, have foci of vacuolated cells in the acanthotic stratum malpighii, vertical tiers of parakeratosis between the adjacent papillae and irregular clumps of keratohyaline granules.

2. **SEBORRHEIC KERATOSIS.** Seborrheic keratosis is a very common lesion in middle-aged adults. There may be only one lesion, but more often these are many. The common locations are trunk and face. They are sharply-demarcated, brownish, smooth-surfaced, measuring a few millimeters in diameter.

M/E The pathognomonic feature is a sharply-demarcated exophytic tumour overlying a straight line from the normal epidermis at one end of the tumour to the normal epidermis at the other end. The other features are papillomatosis, hyperkeratosis and acanthosis as seen in squamous cell papillomas (**Web Image 26.19**).

3. **FIBROEPITHELIAL POLYPS.** Also known by other names such as 'skin tags', 'acrochordons' and 'soft fibromas', these are the most common cutaneous lesions. They are often multiple, soft, small (a few mm in size), bag-like tumours commonly seen on the neck, trunk and axillae.

M/E The tumours are composed of loosely-arranged fibrovascular cores with overlying hyperplastic epidermis (**Web Image 26.20**).

B. Epithelial Cysts (p. 780)

1. **EPIDERMAL CYST.** These intradermal or subcutaneous cysts, commonly called sebaceous cysts, are common and may occur spontaneously or due to implantation of the epidermis into the dermis or subcutis (implantation cysts). Most frequent sites are the skin of face, scalp, neck and trunk.

M/E Epidermal cysts have a cyst wall composed of true epidermis with laminated layers of keratin (**Web Image 26.21**). Rupture of the cyst may incite foreign body giant cell inflammatory reaction in the wall.

650 2. PILAR (TRICHILEMMAL, SEBACEOUS) CYST. These cysts clinically resemble epidermal cysts but occur more frequently on the scalp and are less common than the epidermal cysts.

M/E The cyst wall is composed of palisading squamous epithelial cells. These cells undergo degeneration towards the cyst cavity. Rupture of the cyst wall is common and leads to foreign body giant cell inflammatory reaction. Calcification in the cyst wall is often present.

3. DERMOID CYST. These are subcutaneous cysts often present since birth. Dermoid cysts are more common on the face, along the lines of embryonic closure.

M/E The cyst wall contains epidermis as well as appendages such as hair follicles, sebaceous glands and sweat glands (**Web Image 26.22**).

4. STEATOCYSTOMA MULTIPLEX. This is an inherited autosomal dominant disorder having multiple cystic nodules, 1-3 cm in size. They are more common in the axillae, sternum and arms.

M/E The cyst walls are composed of several layers of epithelial cells and contain lobules of sebaceous glands in the cyst wall.

C. Pre-malignant Lesions (p. 782)

1. SOLAR KERATOSIS (ACTINIC KERATOSIS, SENILE KERATOSIS). Solar (sun-induced) or actinic (induced by a variety of rays) keratoses are the multiple lesions occurring in sun-exposed areas of the skin in fair-skinned elderly people. Similar lesions may be induced by exposure to ionising radiation, hydrocarbons and arsenicals. The condition is considered to be a forerunner of invasive squamous cell and/or basal cell carcinoma.

M/E Solar keratoses are squamous cell carcinoma *in situ* with the following characteristic features:

- i) Considerable hyperkeratosis.
- ii) Marked acanthosis.
- iii) Dyskeratosis and dysplasia of the epidermal cells showing features such as hyperchromatism, loss of polarity, pleomorphism and increased number of mitotic figures.
- iv) Non-specific chronic inflammatory cell infiltrate in the upper dermis encroaching upon the basement membrane of the epidermis.

2. BOWEN'S DISEASE. Bowen's disease is also a carcinoma *in situ* of the entire epidermis but differs from solar keratosis in having solitary lesion often that may occur on sun-exposed as well as sun-unexposed skin.

M/E (Web Image 26.23): The features are:

- i) Marked hyperkeratosis.
- ii) Pronounced parakeratosis.
- iii) Marked epidermal hyperplasia with disappearance of dermal papillae.
- iv) Scattered bizarre dyskeratotic cells distributed throughout the epidermis.

3. XERODERMA PIGMENTOSUM. This condition is a hypersensitivity of the skin to sunlight that is determined by a recessive gene. The disorder may lead to multiple malignancies of the skin such as basal cell carcinoma, squamous cell carcinoma and malignant melanoma.

D. Malignant Tumours (p. 783)

1. SQUAMOUS CELL CARCINOMA. Squamous cell carcinoma may arise on any part of the skin and mucous membranes lined by squamous epithelium but is more likely to occur on sun-exposed parts in older people. Various predisposing conditions include the following:

- i) Xeroderma pigmentosum
- ii) Solar keratosis
- iii) Chronic inflammatory conditions such as chronic ulcers and draining osteomyelitis

- iv) Old burn scars (Marjolin's ulcers)
- v) Chemical burns
- vi) Psoriasis
- vii) HIV infection
- viii) Ionising radiation
- ix) Industrial carcinogens (coal tars, oils etc)
- x) In the case of cancer of oral cavity, chewing betel nuts and tobacco.

Cancer of scrotal skin in chimney-sweepers was the first cancer in which an occupational carcinogen (soot) was implicated. '*Kangari cancer*' of the skin of inner side of thigh and lower abdomen common in natives of Kashmir is another example of skin cancer due to chronic irritation.

Although squamous carcinomas can occur anywhere on the skin, most common locations are the face, pinna of the ears, back of hands and mucocutaneous junctions such as on the lips, anal canal and glans penis. Cutaneous squamous carcinoma arising in a pre-existing inflammatory and degenerative lesion has a higher incidence of developing metastases.

G/A Squamous carcinoma of the skin and squamous-lined mucosa can have one of the following two patterns (**Web Image 26.24**):

- i) More commonly, an *ulcerated growth* with elevated and indurated margin is seen.
- ii) Less often, a raised *fungating or polypoid verrucous* lesion without ulceration is found.

M/E Squamous cell carcinoma is an invasive carcinoma of the surface epidermis characterised by the following features (**Web Image 26.25**):

- i) There is irregular downward proliferation of epidermal cells into the dermis.
- ii) Depending upon the grade of malignancy, the masses of epidermal cells show atypical features such as variation in cell size and shape, nuclear hyperchromatism, absence of intercellular bridges, individual cell keratinisation and occurrence of atypical mitotic figures.
- iii) Better-differentiated squamous carcinomas have whorled arrangement of malignant squamous cells forming horn pearls. The centres of these horn pearls may contain laminated, keratin material.
- iv) Higher grades of squamous carcinomas, however, have fewer or no horn pearls and may instead have highly atypical cells.
- v) An uncommon variant of squamous carcinoma may have spindle-shaped tumour cells (*spindle cell carcinoma*).
- vi) Adenoid changes may be seen in a portion of squamous cell carcinoma (*adenoid squamous cell carcinoma*).
- vii) *Verrucous carcinoma* is a low-grade squamous cell carcinoma in which the superficial portion of the tumour resembles verruca (hyperkeratosis, parakeratosis, acanthosis and papillomatosis) but differs from it in having downward proliferation into deeper portion of the tumour.
- viii) All variants of squamous cell carcinoma show inflammatory reaction between the collections of tumour cells, while in *pseudocarcinomatous hyperplasia* there is permeation of the epithelial proliferations by inflammatory cells.

2. BASAL CELL CARCINOMA (RODENT ULCER). Typically, the basal cell carcinoma is a locally invasive, slow-growing tumour of middle-aged that rarely metastasises. It occurs exclusively on hairy skin, the most common location (90%) being the face, usually above a line from the lobe of the ear to the corner of the mouth (**Web Image 26.26**). Basal cell carcinoma is seen more frequently in white-skinned people and in those who have prolonged exposure to strong sunlight like in those living in Australia and New Zealand.

G/A The most common pattern is a nodulo-ulcerative basal cell carcinoma in which a slow-growing small nodule undergoes central ulceration with

652 pearly, rolled margins. The tumour enlarges in size by burrowing and by destroying the tissues locally like a rodent and hence the name 'rodent ulcer'. However, less frequently non-ulcerated nodular pattern, pigmented basal cell carcinoma and fibrosing variants are also encountered.

M/E The most characteristic feature is the proliferation of basaloid cells (resembling basal layer of epidermis). A variety of patterns of these cells may be seen: solid masses, masses of pigmented cells, strands and nests of tumour cells in morphea pattern, keratotic masses, cystic change with sebaceous differentiation, and adenoid pattern with apocrine or eccrine differentiation. The most common pattern is *solid basal cell carcinoma* in which the dermis contains irregular masses of basaloid cells having characteristic peripheral palisaded appearance of the nuclei (**Web Image 26.27**).

3. METATYPICAL CARCINOMA (BASOSQUAMOUS CELL CARCINOMA). Metatypical or basosquamous cell carcinoma is the term used for a tumour in which the cell type and arrangement of cells cause difficulty in deciding between basal cell carcinoma and squamous cell carcinoma.

□ II. ADNEXAL (APPENDAGEAL) TUMOURS (p. 785)

Tumours arising from epidermal adnexa or appendages can differentiate towards hair follicles, sebaceous glands and sweat glands (apocrine and eccrine glands). Most of the adnexal tumours are benign but a few malignant variants also exist.

A. Tumours of Hair Follicle (p. 785)

1. TRICHOEPITHELIOMA (BROOKE'S TUMOUR). This tumour may occur as a solitary lesion or as multiple inherited lesions, predominantly on the face, scalp and neck.

M/E The tumour is often circumscribed. The most characteristic histologic feature is the presence of multiple horn cysts having keratinised centre and surrounded by basophilic cells resembling basal cells.

2. PILOMATRICOA (CALCIFYING EPITHELIOMA OF MALHERBE). Pilomatricoma usually occurs as a solitary lesion, more often on the face and upper extremities. It may be seen at any age. The lesions vary in size from 0.5-5 cm and appear as well-demarcated dark red nodules.

M/E The circumscribed tumour is located in deeper dermis and subcutis. The masses of tumour cells embedded in cellular stroma characteristically consist of 2 types of cells: the *peripheral basophilic cells* resembling hair matrix cells, and the *inner shadow cells* having central unstained shadow in place of the lost nucleus. Areas of calcification are present within lobules of shadow cells in three-fourth of the tumours (**Web Image 26.28**).

B. Tumours of Sebaceous Glands (p. 785)

1. NAEVUS SEBACEUS. Naevus sebaceus of Jadassohn occurs mainly on the scalp or face as a solitary lesion that may be present at birth. Initially, the lesion appears as a hairless plaque, but later it becomes verrucous and nodular.

M/E Naevus sebaceus is characterised by hyperplasia of immature sebaceous glands and pilar structures. The overlying epidermis shows papillary acanthosis.

2. SEBACEOUS ADENOMA. Sebaceous adenoma occurs in middle-aged persons, most commonly on the face.

M/E It is sharply demarcated from the surrounding tissue. The tumour is composed of irregular lobules of incompletely differentiated sebaceous glands.

3. SEBACEOUS CARCINOMA. Sebaceous carcinoma is a rare tumour that may occur anywhere in the body except the palms and soles. Variants of sebaceous carcinoma are carcinoma of the Meibomian glands of the eyelids and carcinoma of the ceruminous glands in the external meatus.

M/E The tumour is composed of variable-sized lobules of poorly-differentiated cells containing some sebaceous cells. The tumour cells show marked cytologic atypia such as pleomorphism and hyperchromasia.

C. Tumours of Sweat Glands (p. 786)

1. ECCRINE TUMOURS. Depending upon the portion of eccrine sweat gland from which the tumour takes origin, the eccrine tumours are of 3 types:

- i) arising from *intraepidermal portion of the duct* e.g. eccrine poroma;
- ii) arising from *intraepidermal portion of the duct* e.g. hidradenoma; and
- iii) arising from *secretory coils* e.g. eccrine spiradenoma.

◆ **Eccrine poroma.** This tumour arises from intraepidermal portion of the sweat gland duct. The tumour is found more commonly on the sole and hands.

M/E It consists of tumour cells arising from the lower portion of the epidermis and extending downward into dermis as broad anastomosing bands.

◆ **Eccrine hidradenoma.** Hidradenoma originates from the intradermal portion of the eccrine sweat duct. The tumour may occur anywhere in the body.

M/E Hidradenoma consists of solid masses and cords of tumour cells which may have an occasional duct-like structure containing mucin. The tumour cells are round to polygonal and may have clear or eosinophilic cytoplasm.

◆ **Eccrine spiradenoma.** This is found as a solitary, painful, circumscribed nodule in the dermis.

M/E The tumour consists of lobules which are surrounded by a thin capsule. The tumour lobules contain 2 types of epithelial cells like in the secretory coils of the eccrine sweat gland. Peripheral cells are small with dark nuclei, while the centre of lobules contains large cells with pale nuclei.

2. APOCRINE TUMOURS. Apocrine sweat glands may give rise to tumours; the two common examples being papillary hidradenoma and cylindroma.

◆ **Papillary hidradenoma.** Papillary hidradenoma or hidradenoma papilliferum is usually located as a small lesion commonly in women in the skin of the anogenital area.

M/E It is a circumscribed tumour in the dermis under a normal epidermis. Papillary hidradenoma represents an adenoma with apocrine differentiation and containing papillary, tubular and cystic structures.

◆ **Cylindroma.** Also called as 'turban tumour' due to its common location on the scalp, cylindroma may occur as both solitary and multiple lesions.

M/E The tumour is composed of irregular islands of tumour cells creating a pattern resembling jigsaw puzzle. The islands are surrounded by a hyaline sheath. The tumour cells comprising the islands consist of 2 types of epithelial cells: *peripheral small cells* with dark nuclei, and *inner large cells* with light staining nuclei.

3. SWEAT GLAND CARCINOMA. Rarely, the eccrine and apocrine gland tumours described above may turn malignant. All these carcinomas are adenocarcinomas and must be distinguished from metastatic adenocarcinoma in the skin.

□ III. MELANOCYTIC TUMOURS (p. 787)

1. NAEVOCELLULAR NAEVI. Pigmented naevi or moles are extremely common lesions on the skin of most individuals. They are often flat or slightly

654 elevated lesions; rarely they may be papillomatous or pedunculated. Most naevi appear in adolescence and in early adulthood due to hormonal influence but rarely may be present at birth. They are mostly tan to brown and less than 1 cm in size.

M/E Irrespective of the histologic types, all naevocellular naevi are composed of 'naevus cells' which are actually identical to melanocytes but differ from melanocytes in being arranged in clusters or nests. Naevus cells are cuboidal or oval in shape with homogeneous cytoplasm and contain large round or oval nucleus. Melanin pigment is abundant in the naevus cells present in the lower epidermis and upper dermis, but the cells in the mid-dermis and lower dermis hardly contain any melanin (**Web Image 26.29**).

The important *histological variants* of naevi are as under:

- i) **Lentigo** is the replacement of the basal layer of the epidermis by melanocytes.
- ii) **Junctional naevus** is the one in which the naevus cells lie at the epidermal-dermal junction. The naevus cells form well-circumscribed nests.
- iii) **Compound naevus** is the commonest type of pigmented naevus. These lesions, in addition to the junctional activity as in junctional naevi, show nests of naevus cells in the dermis to a variable depth.
- iv) **Intradermal naevus** shows slight or no junctional activity. The lesion is mainly located in the upper dermis as nests and cords of naevus cells. Multinucleate naevus cells are common.
- v) **Spindle cell (epithelioid) naevus or juvenile melanoma** is a compound naevus with junctional activity. The naevus cells are, however, elongated and epithelioid in appearance which may or may not contain melanin. Juvenile melanoma is important since it is frequently confused with malignant melanoma histologically.
- vi) **Blue naevus** is characterised by dendritic spindle naevus cells rather than the usual rounded or cuboidal naevus cells. These cells are often quite rich in melanin pigment.
- vii) **Dysplastic naevi** are certain atypical naevi which have increased risk of progression to malignant melanoma.

2. MALIGNANT MELANOMA. Malignant melanoma or melanocarcinoma arising from melanocytes is one of the most rapidly spreading malignant tumour of the skin that can occur at all ages but is rare before puberty. The tumour spreads locally as well as to distant sites by lymphatics and by blood. The etiology is unknown but there is role of excessive exposure of white skin to sunlight e.g. higher incidence in New Zealand and Australia where sun exposure is high. Besides the skin, melanomas may occur at various other sites such as oral and anogenital mucosa, oesophagus, conjunctiva, orbit and leptomeninges.

Some high risk factors associated with increased incidence of malignant melanoma are as under:

- i) Persistent change in appearance of a mole.
- ii) Presence of pre-existing naevus (especially dysplastic naevus).
- iii) Family history of melanoma in a patient of atypical mole.
- iii) Higher age of the patient.
- iv) More than 50 moles 2 mm or more in diameter.

Clinically, melanoma often appears as a flat or slightly elevated naevus which has variegated pigmentation, irregular borders and, of late, has undergone secondary changes of ulceration, bleeding and increase in size. Many of the malignant melanomas, however, arise *de novo* rather than from a pre-existing naevus. Malignant melanoma can be differentiated from benign pigmented lesions by subtle features as summed up in **Web Table 26.3**; the dermatologists term this as ABCD of melanoma (acronym for Asymmetry, Border irregularity, Colour change and Diameter >6 mm).

G/A Depending upon the clinical course and prognosis, cutaneous malignant melanomas are of the following 4 types:

i) Lentigo maligna melanoma. This often develops from a pre-existing lentigo (a flat naevus characterised by replacement of basal layer of epidermis by naevus cells). It is essentially a malignant melanoma *in situ*. It is slow-growing and has good prognosis.

ii) Superficial spreading melanoma. This is a slightly elevated lesion with variegated colour and ulcerated surface. It often develops from a superficial spreading melanoma *in situ* (pagetoid melanoma) in 5 to 7 years. The prognosis is worse than for lentigo maligna melanoma.

iii) Acral lentiginous melanoma. This occurs more commonly on the soles, palms and mucosal surfaces (**Web Image 26.30**). The tumour often undergoes ulceration and early metastases. The prognosis is worse than that of superficial spreading melanoma.

iv) Nodular melanoma. This often appears as an elevated and deeply pigmented nodule that grows rapidly and undergoes ulceration. This variant carries the worst prognosis.

M/E (Web Image 26.31): The features are as under:

i) Origin. The malignant melanoma, whether arising from a pre-existing naevus or starting *de novo*, has marked junctional activity at the epidermo-dermal junction and grows downward into the dermis.

ii) Tumour cells. The malignant melanoma cells are usually larger than the naevus cells. They may be epithelioid or spindle-shaped, the former being more common. The tumour cells have amphophilic cytoplasm and large, pleomorphic nuclei with conspicuous nucleoli. Mitotic figures are often present and multinucleate giant cells may occur.

iii) Melanin. Melanin pigment may be present (melanotic) or absent (amelanotic melanoma) without any prognostic influence. The pigment, if present, tends to be in the form of uniform fine granules (unlike the benign naevi in which coarse irregular clumps of melanin are present). Immunohistochemically, melanoma cells are positive for HMB-45 (most specific), S-100 and Melan-A.

iv) Inflammatory infiltrate. Some amount of inflammatory infiltrate is present in the invasive melanomas.

Depending upon the depth of invasion below the granular cell layer in millimeters, *Clark* has described 5 levels:

Level I: Malignant melanoma cells confined to the epidermis and its appendages.

Level II: Extension into the papillary dermis.

Level III: Extension of tumour cells upto the interface between papillary and reticular dermis.

Level IV: Invasion of reticular dermis.

Level V: Invasion of the subcutaneous fat.

Metastatic spread of malignant melanoma is very common and takes place via lymphatics to the regional lymph nodes and through blood to distant sites like lungs, liver, brain, spinal cord, and adrenals. Rarely, the primary lesion regresses spontaneously but metastases are present widely distributed.

□ IV. TUMOURS OF THE DERMIS (p. 789)

1. DERMATOFIBROMA AND MALIGNANT FIBROUS HISTIOCYTOMA.

These soft tissue tumours are composed of cells having mixed features of fibroblasts, myofibroblasts, histiocytes and primitive mesenchymal cells. The commonest sites are the lower and upper extremities, followed in decreasing frequency, by abdominal cavity and retroperitoneum. The benign

656 variant is also known by various synonyms like dermatofibroma, histiocytoma, sclerosing haemangioma, fibroxanthoma and xanthogranuloma.

M/E The tumours are composed of spindle-shaped fibrohistiocytoid cells which are characteristically arranged in cartwheel or storiform pattern. The benign variety contains uniform spindle-shaped cells with admixture of numerous foamy histiocytes. The malignant fibrous histiocytoma shows pleomorphic tumour cells and some multinucleate giant cells in a stroma that may show myxoid change and inflammatory infiltrate.

2. DERMATOFIBROSARCOMA PROTUBERANS. This is a low-grade fibrosarcoma that rarely metastasises but is locally recurrent. The tumour usually forms a solid nodule, within the dermis and subcutaneous fat, protruding the epidermis outwards.

M/E The tumour is very cellular and is composed of uniform fibroblasts arranged in a cartwheel or storiform pattern. A few mitoses are often present. The overlying epidermis is generally thinned and may be ulcerated (**Web Image 26.32**).

3. XANTHOMAS. These are solitary or multiple tumour-like lesions, often associated with high levels of serum cholesterol and phospholipids. Many of the cases result from familial hyperlipidaemia.

M/E Xanthomas are composed of dermal collections of benign-appearing foamy histiocytes. Multinucleate tumour giant cells surrounded by lipid-laden cytoplasm are often present.

□ **V. CELLULAR MIGRANT TUMOURS (p. 790)**

MYCOSIS FUNGOIDES (CUTANEOUS T-CELL LYMPHOMA) AND SEZARY SYNDROME. Mycosis fungoides or cutaneous T-cell lymphoma (CTCL) is the commonest form of lymphoma in the skin but in advanced stage, mycosis fungoides may disseminate to the lymph nodes and other organs. Clinically, mycosis fungoides may manifest in 3 stages:

- i) **Premycotic stage** in which the lesions are erythematous, red-brown, scaly and pruritic, resembling eczema or psoriasis.
- ii) **Infiltrative stage** has slightly elevated, bluish-red, firm plaques.
- iii) **Fungoid (Tumour) stage** is characterised by red-brown nodules of tumour which often undergo ulceration.

The etiology of mycosis fungoides or CTCL has been found to be the same as for adult T cell lymphoma-leukaemia syndrome which is human T cell-leukaemia virus-I (HTLV-I).

Sézary syndrome is a variant of CTCL, often due to dissemination of underlying CTCL to the blood and infiltration into the skin causing generalised erythroderma, lymphadenopathy and hepatosplenomegaly.

The condition is found more frequently beyond 4th decade of life. Lesions may affect different body surfaces but often involve the trunk, extremities, face and scalp.

M/E The features are as under:

- i) Initially, lower portion of the epidermis contains hyperchromatic enlarged lymphocytes. In about half the cases, there is formation of intraepidermal clusters of atypical lymphoid cells forming *Darier-Pautrier's microabscesses* which is a misnomer as it does not contain pus cells.
- ii) Later, there are band-like sharply demarcated aggregates of polymorphous cellular infiltrate in the dermis including atypical lymphoid cells (Sézary-Lutzner cells) and multinucleated cells.
- iii) The individual mycosis cells are malignant T lymphocytes which have hyperchromatic and cerebriform nuclei and express CD4 and HLA-DR antigen.

1. **Molluscum contagiosum is caused by:**
 - A. Papilloma virus
 - B. Herpes virus
 - C. Pox virus
 - D. EB virus
2. **Xeroderma pigmentosum is characterised by the following features except:**
 - A. Autosomal recessive inheritance
 - B. Inability to repair sunlight-induced damage to DNA
 - C. Proneness to develop various skin cancers
 - D. Irregular accumulation of melanin in the basal layer
3. **The etiologic agent implicated in epidermodysplasia verruciformis is:**
 - A. Herpes virus (HSV)
 - B. Pox virus
 - C. EB virus
 - D. Papilloma virus (HPV)
4. **Herpesviruses cause the following exanthemata except:**
 - A. Herpes simplex
 - B. Herpes zoster
 - C. Vaccinia
 - D. Varicella
5. **The following bullous dermatosis is associated with coeliac disease:**
 - A. Pemphigus vulgaris
 - B. Pemphigoid
 - C. Erythema multiforme
 - D. Dermatitis herpetiformis
6. **Psoriasis has the following features except:**
 - A. Acanthosis with thickened lower portion
 - B. Suprapapillary thinning of epidermis
 - C. Prominent granular cell layer
 - D. Munro abscesses in parakeratotic layer
7. **Lichen planus is characterised by the following features except:**
 - A. Marked hyperkeratosis
 - B. Acanthosis with elongated saw-toothed lower border
 - C. Band-like dermal infiltrate of inflammatory cells
 - D. Intact basal cell layer
8. **The following conditions are premalignant except:**
 - A. Solar keratosis
 - B. Seborrheic keratosis
 - C. Bowen's disease
 - D. Xeroderma pigmentosum
9. **The following tumour is commonly non-metastasising:**
 - A. Squamous cells carcinoma
 - B. Basal cell carcinoma
 - C. Melanoma
 - D. Sweat gland carcinoma
10. **Papillary hidradenoma occurs most commonly in the following region:**
 - A. Scalp
 - B. Back
 - C. Anogenital region
 - D. Extremities
11. **The following type of naevi most often progress to malignant melanoma:**
 - A. Compound naevus
 - B. Blue naevus
 - C. Dysplastic naevus
 - D. Epithelioid naevus
12. **The following type of malignant melanoma has worse prognosis:**
 - A. Nodular melanoma
 - B. Superficial spreading melanoma
 - C. Acral lentigenous melanoma
 - D. Lentigo maligna melanoma
13. **Darier-Pautrier's abscess is composed of the following cells:**
 - A. Neutrophils
 - B. Macrophages
 - C. Plasma cells
 - D. Atypical lymphoid cells
14. **The following HPV types are implicated in the etiology of verruca vulgaris:**
 - A. Types 1, 2
 - B. Types 6, 11
 - C. Types 2, 3
 - D. Types 16, 18

- 658 15. High risk factor for malignant melanoma include the following **except**:
- Change in appearance
 - Higher age of the patient
 - More than 50 or more moles 2 mm or more in diameter
 - Uniform pigmentation
16. All are types of calcification in the skin **except**:
- Metastatic calcinosis cutis
 - Dystrophic calcinosis cutis
 - Secondary calcinosis cutis
 - Subepidermal calcified nodule
17. Metatypical carcinoma is:
- Basosquamous carcinoma
 - Rodent ulcer
 - Sebaceous carcinoma
 - Sweat gland carcinoma
18. Familial cases of malignant melanoma show germ line mutations in:
- p53
 - Rb
 - CDKN2A
 - C-myc
19. All are immunohistochemical stains for melanoma **except**:
- HMB-45
 - S-100
 - Melan-A
 - SMA
20. Which of the following is true about the behaviour of dermatofibrosarcoma protuberans:
- Rare metastasis, rare recurrence
 - Rare metastasis, locally recurrent
 - Frequent metastasis and recurrence
 - No metastasis or recurrence

KEY

1 = C	2 = D	3 = D	4 = C
5 = D	6 = C	7 = D	8 = B
9 = B	10 = C	11 = C	12 = A
13 = D	14 = A	15 = D	16 = C
17 = A	18 = C	19 = D	20 = B



The Endocrine System

The development, structure and functions of human body are governed and maintained by 2 mutually interlinked systems—the *endocrine system* and the *nervous system*; a third system combining features of both these systems is appropriately called *neuroendocrine system*.

□ NEUROENDOCRINE SYSTEM (p. 791)

This system forms a link between the endocrine and nervous systems. The cells of this system elaborate polypeptide hormones; owing to these biochemical properties, it has also been called as *APUD cell system*. However, though having common biochemical properties, the cells of this system are widely distributed in the body in different anatomic areas and hence is currently called *dispersed neuroendocrine system*. Cells comprising this system are as under:

1. *Neuroendocrine cells* are present in the gastric and intestinal mucosa and elaborate peptide hormones.
2. *Neuroganglia cells* lie in the ganglia cells in the sympathetic chain and elaborate amines.
3. *Adrenal medulla* elaborates epinephrine and norepinephrine.
4. *Parafollicular C cells* of the thyroid secrete calcitonin.
5. *Islets of Langerhans* in the pancreas (included in both endocrine and neuroendocrine systems) secrete insulin.
6. *Isolated cells in the left atrium* of the heart secrete atrial natriuretic (salt-losing) peptide hormone.

□ THE ENDOCRINE SYSTEM (p. 791)

Anatomically, the endocrine system consists of 6 distinct organs: pituitary, adrenals, thyroid, parathyroids, gonads, and pancreatic islets; the last one is included in neuroendocrine system also. Understanding the pathology of these endocrine organs requires the knowledge of overall framework of hormone secretions, their actions and broad principles of feedback mechanisms.

Broadly speaking, human hormones are divided into 5 major classes which are further grouped under two headings depending upon their site of interactions on the target cell receptors (whether cell membrane or nuclear receptor):

Group I: Those interacting with cell-surface membrane receptors:

1. *Amino acid derivatives*: thyroid hormone, catecholamines.
2. *Small neuropeptides*: gonadotropin-releasing hormone (GnRH), thyrotropin-releasing hormone (TRH), somatostatin, vasopressin.

Group II: Those interacting with intracellular nuclear receptors:

3. *Large proteins*: insulin, luteinising hormone (LH), parathormone hormone.
4. *Steroid hormones*: cortisol, estrogen.
5. *Vitamin derivatives*: retinol (vitamin A) and vitamin D.

Major functions of hormones are as under:

- i) *Growth and differentiation of cells*, ii) *Maintenance of homeostasis*, iii) *Reproduction*.

A basic feature of all endocrine glands is the existence of both negative and positive **feedback control system** that *stimulates* or *regulates* hormone production in a way that levels remain within the normal range (abbreviated as S or R respectively). This system is commonly termed *hypothalamic-pituitary hormone axis* for different hormones schematically illustrated in **Web Image 27.1**. The stimulatory or regulatory action by endocrine hormonal secretions may follow paracrine or autocrine pathways:

- ◆ *Paracrine regulation* means that the stimulatory/regulatory factors are released by one type of cells but act on another adjacent cell of the system.
- ◆ *Autocrine regulation* refers to action of the factor on the same cell that produced it.

In general, pathologic processes affecting endocrine glands with resultant hormonal abnormalities may occur from following processes:

Hyperfunction: This results from excess of hormone secreting tissues e.g. hyperplasia, tumours (adenoma, carcinoma), ectopic hormone production, excessive stimulation from inflammation (often autoimmune), infections, iatrogenic (drugs-induced, hormonal administration).

Hypofunction: Deficiency of hormones occurs from destruction of hormone-forming tissues from inflammations (often autoimmune), infections, iatrogenic (e.g. surgical removal, radiation damage), developmental defects (e.g. Turner's syndrome, hypoplasia), enzyme deficiency, haemorrhage and infarction (e.g. Sheehan's syndrome), nutritional deficiency (e.g. iodine deficiency).

Hormone resistance: There may be adequate or excessive production of a hormone but there is peripheral resistance, often from inherited mutations in receptors (e.g. defect in membrane receptors, nuclear receptors or receptor for signal transduction).

□ **NORMAL STRUCTURE** (p. 792)

ANATOMY. The pituitary gland or hypophysis in an adult weighs about 500 mg and is slightly heavier in females. It is situated at the base of the brain in a hollow called *sella turcica* formed out of the sphenoid bone. The gland is composed of 2 major anatomic divisions:

HISTOLOGY AND FUNCTIONS. The histology and functions of the anterior and posterior lobes of the pituitary gland are quite distinct.

A. ANTERIOR LOBE (ADENOHYPHYSIS). It is composed of round to polygonal epithelial cells arranged in cords and islands having fibrovascular stroma. These epithelial cells, depending upon their staining characteristics and functions, are divided into 3 types, each of which performs separate functions:

1. **Chromophil cells with acidophilic granules**

- i) *Somatotrophs (GH cells)*
- ii) *Lactotrophs (PRL cells)*

2. **Chromophil cells with basophilic granules**

- i) *Gonadotrophs (FSH-LH cells)*
- ii) *Thyrotrophs (TSH cells)*
- iii) *Corticotrophs (ACTH-MSH cells).*

3. **Chromophobe cells without visible granules.**

B. POSTERIOR LOBE (NEUROHYPHYSIS). The neurohypophysis is composed mainly of interlacing nerve fibres in which are scattered specialised glial cells called *pituitocytes*. These nerve fibres on electron microscopy contain granules of neurosecretory material made up of 2 octapeptides—*vasopressin* or *antidiuretic hormone* (ADH), and *oxytocin*, both of which are

produced by neurosecretory cells of the hypothalamus but are stored in the cells of posterior pituitary.

□ **HYPERPITUITARISM** (p. 793)

A. Hyperfunction of Anterior Pituitary (p. 793)

Three common syndromes of adenohypophyseal hyperfunction are: gigantism and acromegaly, hyperprolactinaemia and Cushing's syndrome.

GIGANTISM AND ACROMEGALY. Both these clinical syndromes result from sustained excess of growth hormone (GH), most commonly by somatotroph (GH-secreting) adenoma.

HYPERPROLACTINAEMIA. Hyperprolactinaemia is the excessive production of prolactin (PRL), most commonly by lactotroph (PRL-secreting) adenoma, also called prolactinoma.

CUSHING'S SYNDROME. Pituitary-dependent Cushing's syndrome results from ACTH excess. Most frequently, it is caused by corticotroph (ACTH-secreting) adenoma.

B. Hyperfunction of Posterior Pituitary and Hypothalamus (p. 794)

Lesions of posterior pituitary and hypothalamus are uncommon. Two of the syndromes associated with hyperfunction of the posterior pituitary and hypothalamus are: inappropriate release of ADH and precocious puberty.

INAPPROPRIATE RELEASE OF ADH. Inappropriate release of ADH results in its excessive secretion which manifests clinically by passage of concentrated urine due to increased reabsorption of water and loss of sodium in the urine, consequent hyponatraemia, haemodilution and expansion of intra- and extracellular fluid volume.

PRECOCIOUS PUBERTY. A tumour in the region of hypothalamus or the pineal gland may result in premature release of gonadotropins causing the onset of pubertal changes prior to the age of 9 years.

□ **HYPOPITUITARISM**

In hypopituitarism, there is usually deficiency of one or more of the pituitary hormones affecting either anterior pituitary, or posterior pituitary and hypothalamus.

A. Hypofunction of Anterior Pituitary

Adenohypophyseal hypofunction is invariably due to destruction of the anterior lobe of more than 75% because the anterior pituitary possesses a large functional reserve. This may result from anterior pituitary lesions or pressure and destruction from adjacent lesions. Lesions of the anterior pituitary include nonsecretory (chromophobe) adenoma, metastatic carcinoma, craniopharyngioma, trauma, postpartum ischaemic necrosis (Sheehan's syndrome), empty-sella syndrome, and rarely, tuberculosis.

PANHYPOPITUITARISM. The classical clinical condition of major anterior pituitary insufficiency is called panhypopituitarism. Three most common causes of panhypopituitarism are: non-secretory (chromophobe) adenoma (discussed later), Sheehan's syndrome and Simmond's disease, and empty-sella syndrome.

Sheehan's syndrome and Simmond's disease. Pituitary insufficiency occurring due to postpartum pituitary (Sheehan's) necrosis is called Sheehan's syndrome, whereas occurrence of similar process without preceding pregnancy as well as its occurrence in males is termed Simmond's disease.

The first *clinical manifestation* of Sheehan's syndrome is failure of lactation following delivery which is due to deficiency of prolactin. Subsequently, other symptoms develop which include loss of axillary and pubic hair, amenorrhoea, sterility and loss of libido. Concomitant deficiency of TSH and ACTH may result in hypothyroidism and adrenocortical insufficiency.

Empty-sella syndrome. Empty-sella syndrome is characterised by the appearance of an empty sella and features of panhypopituitarism. Most commonly, it results from herniation of subarachnoid space into the sella turcica due to an incomplete diaphragma sella creating an empty sella.

PITUITARY DWARFISM. Severe deficiency of GH in children before growth is completed results in retarded growth and pituitary dwarfism. Most commonly, isolated GH deficiency is the result of an inherited autosomal recessive disorder. Less often it may be due to a pituitary adenoma or craniopharyngioma, infarction and trauma to the pituitary. The clinical features of inherited cases of pituitary dwarfism appear after one year of age. These include proportionate retardation in growth of bones, normal mental state for age, poorly-developed genitalia, delayed puberty and episodes of hypoglycaemia.

B. Hypofunction of Posterior Pituitary and Hypothalamus (p. 795)

Insufficiency of the posterior pituitary and hypothalamus is uncommon. The only significant clinical syndrome due to hypofunction of the neurohypophysis and hypothalamus is diabetes insipidus.

DIABETES INSIPIDUS. Deficient secretion of ADH causes diabetes insipidus. The causes of ADH deficiency are: inflammatory and neoplastic lesions of the hypothalamo-hypophyseal axis, destruction of neurohypophysis due to surgery, radiation, head injury, and lastly, are those cases where no definite cause is known and are labelled as idiopathic. The main features of diabetes insipidus are excretion of a very large volume of dilute urine of low specific gravity (below 1.010), polyuria and polydipsia.

□ PITUITARY TUMOURS (p. 795)

Tumours of the anterior pituitary are more common than those of the posterior pituitary and hypothalamus. The most common of the anterior pituitary tumours are adenomas; primary and metastatic carcinomas being rare. Craniopharyngioma and granular cell tumour (choristoma) are the other benign pituitary tumours found occasionally.

All pituitary tumours, whether benign or malignant, cause symptoms by following 2 ways:

1. Pressure effects
2. Hormonal effects.

Pituitary Adenomas (p. 795)

Adenomas are the most common pituitary tumours. They are conventionally classified according to their H & E staining characteristics of granules into acidophil, basophil and chromophobe adenomas. **Web Table 27.1** presents a classification of pituitary adenomas based on functional features as correlated with morphologic features of older classification.

G/A Pituitary adenomas range in size from small foci of less than 10 mm in size (termed microadenoma) to large adenomas several centimeters in diameter. They are spherical, soft and encapsulated.

M/E By light microscopy of H & E stained sections, an adenoma is composed predominantly of one of the normal cell types of the anterior pituitary i.e. acidophil, basophil or chromophobe cells. These cells may have following 3 types of patterns:

1. *Diffuse pattern* is composed of polygonal cells arranged in sheets with scanty stroma.
2. *Sinusoidal pattern* consists of columnar or fusiform cells with fibrovascular stroma around which the tumour cells are arranged (**Web Image 27.2**).
3. *Papillary pattern* is composed of columnar or fusiform cells arranged about fibrovascular papillae.

Functionally, most common pituitary adenomas, in decreasing order of frequency, are: lactotroph (PRL-secreting) adenoma, somatotroph (GH-secreting) adenoma and corticotroph (ACTH-secreting) adenoma.

Craniopharyngioma (p. 796)

Craniopharyngioma is a benign tumour arising from remnants of Rathke's pouch. It is more common in children and young adults.

G/A The tumour is encapsulated, adherent to surrounding structures and is typically cystic, reddish-grey mass.

M/E Craniopharyngioma closely resembles ameloblastoma of the jaw. There are 2 distinct histologic features:

1. Stratified squamous epithelium frequently lining, a cyst and containing loose stellate cells in the centre.
2. Solid ameloblastous areas.

Granular Cell Tumour (Choristoma) (p. 796)

Though tumours of the posterior pituitary are rare, granular cell tumour or choristoma is the most common tumour of the neurohypophysis. It is composed of a mass of cells having granular eosinophilic cytoplasm similar to the cells of the posterior pituitary.

ADRENAL GLAND (p. 796)

□ NORMAL STRUCTURE (p. 796)

ANATOMY. The adrenal glands lie at the upper pole of each kidney. Each gland weighs approximately 4 gm in the adult but in children the adrenals are proportionately larger. On sectioning, the adrenal is composed of 2 distinct parts: an outer yellow-brown *cortex* and an inner grey *medulla*.

ADRENAL CORTEX. It is composed of 3 layers:

1. **Zona glomerulosa** is the outer layer and comprises about 10% of the cortex. It consists of cords or columns of polyhedral cells just under the capsule. This layer is responsible for the synthesis of *mineralocorticoids*, the most important of which is aldosterone, the salt and water regulating hormone.
2. **Zona fasciculata** is the middle layer and constitutes approximately 70% of the cortex. It is composed of columns of lipid-rich cells which are precursors of various *steroid hormones* manufactured in the adrenal cortex such as glucocorticoids (e.g. cortisol) and sex steroids (e.g. testosterone).
3. **Zona reticularis** is the inner layer which makes up the remainder of the adrenal cortex. It consists of cords of more compact cells than those of zona fasciculata but has similar functional characteristics of synthesis and secretion of *glucocorticoids* and *androgens*.

The synthesis of glucocorticoids and adrenal androgens is under the control of ACTH from hypothalamus-anterior pituitary.

ADRENAL MEDULLA. The adrenal medulla is a component of the dispersed neuroendocrine system derived from primitive neuroectoderm; the other components of this system being *paraganglia* distributed in the vagi, paravertebral and visceral autonomic ganglia. The cells comprising this system are neuroendocrine cells, the major function of which is synthesis and secretion of catecholamines (epinephrine and norepinephrine).

664 □ **ADRENOCORTICAL HYPERFUNCTION (HYPERADRENALISM)** (p. 797)

Hypersecretion of each of the three types of corticosteroids elaborated by the adrenal cortex causes distinct corresponding hyperadrenal clinical syndromes:

1. *Cushing's syndrome* caused by excess of glucocorticoids (i.e. cortisol); also called *chronic hypercortisolism*.
2. *Conn's syndrome* caused by oversecretion of mineralocorticoids (i.e. aldosterone); also called *primary hyperaldosteronism*.
3. *Adrenogenital syndrome* characterised by excessive production of adrenal sex steroids (i.e. androgens); also called *adrenal virilism*.

Cushing's Syndrome (Chronic Hypercortisolism) (p. 797)

Cushing's syndrome is caused by excessive production of cortisol of whatever cause.

ETIOPATHOGENESIS. There are 4 major etiologic types of Cushing's syndrome.

1. **Pituitary Cushing's syndrome.** About 60-70% cases of Cushing's syndrome are caused by excessive secretion of ACTH due to a lesion in the pituitary gland, most commonly a corticotroph adenoma or multiple corticotroph microadenomas.
2. **Adrenal Cushing's syndrome.** Approximately 20-25% cases of Cushing's syndrome are caused by disease in one or both the adrenal glands. These include adrenal cortical adenoma, carcinoma, and less often, cortical hyperplasia.
3. **Ectopic Cushing's syndrome.** About 10-15% cases of Cushing's syndrome have an origin in ectopic ACTH elaboration by non-endocrine tumours. Most often, the tumour is an oat cell carcinoma of the lung but other lung cancers, malignant thymoma and pancreatic tumours have also been implicated.
4. **Iatrogenic Cushing's syndrome.** Prolonged therapeutic administration of high doses of glucocorticoids or ACTH may result in Cushing's syndrome e.g. in organ transplant recipients and in autoimmune diseases.

CLINICAL FEATURES. These are as under:

1. Central or truncal *obesity*.
2. Increased *protein breakdown* resulting in wasting and thinning of the skeletal muscles, atrophy of the skin and subcutaneous tissue.
3. *Systemic hypertension* is present in 80% of cases because of associated retention of sodium and water.
4. *Impaired glucose tolerance* and diabetes mellitus are found in about 20% cases.
5. Amenorrhoea, hirsutism and infertility in many women.
6. Insomnia, depression, confusion and psychosis.

Conn's Syndrome (Primary Hyperaldosteronism) (p. 797)

This is an uncommon syndrome occurring due to overproduction of aldosterone, the potent salt-retaining hormone.

ETIOPATHOGENESIS. The condition results primarily due to adrenocortical diseases as follows:

1. Adrenocortical adenoma, producing aldosterone.
2. Bilateral adrenal hyperplasia, especially in children (congenital hyperaldosteronism).
3. Rarely, adrenal carcinoma.

CLINICAL FEATURES. Conn's syndrome is more frequent in adult females. Its principal features are as under:

Hypertension, hypokalaemia, retention of sodium and water and polyuria and polydipsia.

Adrenogenital Syndrome (Adrenal Virilism) (p. 798)

Adrenal cortex secretes a smaller amount of sex steroids than the gonads. However, adrenocortical hyperfunction may occasionally cause sexual disturbances.

ETIOPATHOGENESIS. Hypersecretion of sex steroids, mainly androgens, may occur in children or in adults:

1. *In children*, it is due to congenital adrenal hyperplasia in which there is congenital deficiency of a specific enzyme.
2. *In adults*, it is caused by an adrenocortical adenoma or a carcinoma. Cushing's syndrome is often present as well.

CLINICAL FEATURES. The clinical features depend upon the age and sex of the patient.

1. *In children*, there is distortion of the external genitalia in girls, and precocious puberty in boys.
2. *In adults*, the features in females show virilisation (e.g. hirsutism, oligomenorrhoea, deepening of voice, hypertrophy of the clitoris); and in males may rarely cause feminisation.

ADRENOCORTICAL INSUFFICIENCY (HYPOADRENALISM) (p. 798)

Adrenocortical insufficiency may result from deficient synthesis of cortical steroids from the adrenal cortex or may be secondary to ACTH deficiency. Three types of adrenocortical hypofunction are distinguished:

1. *Primary adrenocortical insufficiency* caused primarily by the disease of the adrenal glands. Two forms are described: acute or 'adrenal crisis', and chronic or 'Addison's disease'.
2. *Secondary adrenocortical insufficiency* resulting from diminished secretion of ACTH.
3. *Hypoadosteronism* characterised by deficient secretion of aldosterone.

PRIMARY ADRENOCORTICAL INSUFFICIENCY (p. 798)

Primary adrenal hypofunction occurs due to defect in the adrenal glands and normal pituitary function. It may develop in 2 ways:

A. Primary Acute Adrenocortical Insufficiency (Adrenal Crisis) (p. 798)

Sudden loss of adrenocortical function may result in an acute condition called *adrenal crisis*.

ETIOPATHOGENESIS. It includes following:

1. Bilateral adrenalectomy
2. Septicaemia
3. Rapid withdrawal of steroids.
4. Any form of acute stress in a case of chronic insufficiency i.e. in Addison's disease.

CLINICAL FEATURES. These are as under:

1. Deficiency of mineralocorticoids (i.e. aldosterone deficiency) result in salt deficiency, hyperkalaemia and dehydration.
2. Deficiency of glucocorticoids (i.e. cortisol deficiency) leads to hypoglycaemia, increased insulin sensitivity and vomitings.

B. Primary Chronic Adrenocortical Insufficiency (Addison's Disease) (p. 798)

Progressive chronic destruction of more than 90% of adrenal cortex on both sides results in an uncommon clinical condition called Addison's disease.

666 ETIOPATHOGENESIS. Any condition which causes marked chronic adrenal destruction may produce Addison's disease. These include: tuberculosis, autoimmune or idiopathic adrenalitis, histoplasmosis, amyloidosis, metastatic cancer, sarcoidosis and haemochromatosis. However, currently the first two causes—tuberculosis and autoimmune chronic destruction of adrenal glands, are implicated in majority of cases of Addison's disease.

CLINICAL FEATURES. These are:

1. Asthenia i.e. progressive weakness, weight loss and lethargy as the cardinal symptoms.
2. Hyperpigmentation, initially most marked on exposed areas, but later involves unexposed parts and mucous membranes as well.
3. Arterial hypotension.
4. Vague upper gastrointestinal symptoms such as mild loss of appetite, nausea, vomiting and upper abdominal pain.
5. Lack of androgen causing loss of hair in women.
6. Episodes of hypoglycaemia.
7. Biochemical changes include reduced GFR, acidosis, hyperkalaemia and low levels of serum sodium, chloride and bicarbonate.

SECONDARY ADRENOCORTICAL INSUFFICIENCY (p. 799)

Adrenocortical insufficiency resulting from deficiency of ACTH is called secondary adrenocortical insufficiency.

ETIOPATHOGENESIS. ACTH deficiency may appear in 2 settings :

1. *Selective ACTH deficiency* due to prolonged administration of high doses of glucocorticoids. This leads to suppression of ACTH release from the pituitary gland and selective deficiency.
2. *Panhypopituitarism* due to hypothalamus-pituitary diseases is associated with deficiency of multiple trophic hormones.

CLINICAL FEATURES. These are:

1. These cases lack hyperpigmentation because of suppressed production of melanocyte-stimulating hormone (MSH) from the pituitary.
2. Plasma ACTH levels are low-to-absent in secondary insufficiency but are elevated in Addison's disease.
3. Aldosterone levels are normal due to stimulation by renin.

HYPOALDOSTERONISM (p. 799)

Isolated deficiency of aldosterone with normal cortisol level may occur in association with reduced renin secretion.

ETIOPATHOGENESIS. It includes following:

1. Congenital defect due to deficiency of an enzyme required for its synthesis.
2. Prolonged administration of heparin.
3. Certain diseases of the brain.
4. Excision of an aldosterone-secreting tumour.

CLINICAL FEATURES. The patients of isolated hypoaldosteronism are adults with mild renal failure and diabetes mellitus.

ADRENOCORTICAL TUMOURS (p. 799)

Cortical Adenoma (p. 799)

The commonest cortical tumour is adenoma. They are indistinguishable from hyperplastic nodules except that lesions smaller than 2 cm diameter are labelled *hyperplastic nodules*. A cortical adenoma is a benign and slow-growing tumour. It is usually small and nonfunctional. A few large adenomas may, however, produce excess of cortisol, aldosterone or androgen.

G/A An adenoma is usually a small, solitary, spherical and encapsulated tumour which is well-delineated from the surrounding normal adrenal gland. Cut section is typically bright yellow.

M/E The tumour cells are arranged in trabeculae and generally resemble the cells of zona fasciculata.

Cortical Carcinoma (p. 799)

Carcinoma of the adrenal cortex is an uncommon tumour occurring mostly in adults. It invades locally as well as spreads to distant sites.

G/A An adrenal carcinoma is generally large, spherical and well-demarcated tumour. On cut section, it is predominantly yellow with intermixed areas of haemorrhages, necrosis and calcification.

M/E The cortical carcinoma may vary from well-differentiated to anaplastic growth.

□ **MEDULLARY TUMOURS** (p. 799)

Pheochromocytoma (Chromaffin Tumour) (p. 799)

Pheochromocytoma (meaning *dusky brown tumour*) is generally a benign tumour arising from the pheochromocytes (i.e. chromaffin cells) of the adrenal medulla. The extra-adrenal pheochromocytomas arising from other paraganglia are preferably called *paragangliomas*, named along with the anatomic site of origin, as described later.

Pheochromocytoma may occur at any age but most patients are 20-60 years old. Most pheochromocytomas are slow-growing and benign but about 5% of the tumours are malignant, invasive and metastasising.

The *clinical features* of pheochromocytoma are predominantly due to secretion of catecholamines, both epinephrine and norepinephrine. The most common feature is hypertension.

G/A The tumour is soft, spherical, may be quite variable in size and weight, and well-demarcated from the adjacent adrenal gland. On cut section, the tumour is grey to dusky brown with areas of haemorrhages, necrosis, calcification and cystic change (**Web Image 27.3**).

M/E (**Web Image 27.4**): It shows following features:

1. The tumour cells are arranged characteristically as well-defined nests (also termed as zellballen pattern) separated by abundant fibrovascular stroma.
2. Other arrangements are as solid columns, sheets, trabeculae or clumps.
3. The tumour cells are large, polyhedral and pleomorphic with abundant granular amphophilic or basophilic cytoplasm and vesicular nuclei.
4. The tumour cells of pheochromocytoma stain positively with neuroendocrine substances such as neuron-specific enolase (NSE) and chromogranin.

Myelolipoma (p. 800)

Myelolipoma is an uncommon benign adrenal medullary tumour found incidentally at autopsy.

G/A A myelolipoma is usually a small tumour, measuring 0.2-2 cm in diameter.

M/E It consists of well-differentiated adipose tissue in which is scattered clumps of haematopoietic cells are seen.

Neuroblastoma (p. 800)

Neuroblastoma, also called as sympatheticoblastoma, is a common malignant tumour of embryonic nerve cells, occurring most commonly in children under 5 years of age. Vast majority of cases occur within the abdomen (in

668 the adrenal medulla and paravertebral autonomic ganglia) and rarely in the cerebral hemisphere.

The *clinical manifestations* of neuroblastoma are related to its rapid local growth, metastatic spread or development of hormonal syndrome. Local symptoms include abdominal distension, fever, weight loss and malaise. Foci of calcification may be observed on radiologic examination of the abdomen. Neuroblastoma produces variable amounts of catecholamines and its metabolites such as vanillyl mandelic acid (VMA) and homovanillic acid (HVA), which can be detected in the 24-hour urine.

G/A The tumour is generally large, soft and lobulated mass with extensive areas of necrosis and haemorrhages. The tumour is usually diffusely infiltrating into the adjacent tissues. Cut surface of the tumour is grey white and may reveal minute foci of calcification.

M/E (Web Image 27.5): Following features are seen:

1. The tumour cells are small, round and oval, slightly larger than lymphocytes, and have scanty and poorly-defined cytoplasm and hyperchromatic nuclei.
2. They are generally arranged in irregular sheets separated by fibrovascular stroma.
3. Classical neuroblastomas show Homer-Wright's rosettes (pseudo-rosettes) which have a central fibrillar eosinophilic material surrounded by radially arranged tumour cells. The central fibrillar material stains positively by silver impregnation methods indicating their nature as young nerve fibrils.
4. The tumour cells stain positively with immunohistochemical markers such as neuron-specific enolase (NSE), neurofilaments (NF) and chromogranin.

Ganglioneuroma (p. 801)

A ganglioneuroma is a mature, benign and uncommon tumour occurring in adults. It is derived from ganglion cells, most often in the posterior mediastinum, and uncommonly in other peripheral ganglia and brain. Catecholamines and their metabolites can be detected in large amounts in the 24-hour urine specimen of patients with ganglioneuroma.

G/A The tumour is spherical, firm and encapsulated.

M/E It contains large number of well-formed ganglionic nerve cells scattered in fibrillar stroma and myelinated and non-myelinated nerve fibres.

Extra-adrenal Paraganglioma (Chemodectoma) (p. 801)

Parasympathetic paraganglia located in extra-adrenal sites such as the carotid bodies, vagus, jugulotympanic and aortic sympathetic (pre-aortic) paraganglia may produce neoplasms, collectively termed *paragangliomas* with the anatomic site of origin e.g. carotid body paraganglioma, intravagal paraganglioma, jugulotympanic paraganglioma etc. These tumours are also called chemodectomas because of their responsiveness to chemoreceptors.

THYROID GLAND (p. 801)

□ NORMAL STRUCTURE (p. 801)

ANATOMY. Embryologically, the thyroid gland arises from a midline invagination at the root of the tongue and grows downwards in front of trachea and thyroid cartilage to reach its normal position. Failure to descent may produce *anomalous lingual thyroid*. The C-cells of the thyroid originate from the neuroectoderm.

The thyroid gland in an adult weighs 15-40 gm and is composed of two lateral lobes connected in the midline by a broad isthmus which may have a pyramidal lobe extending upwards. Cut section of normal thyroid is yellowish and translucent.

HISTOLOGY. The thyroid is composed of lobules of colloid-filled spherical follicles or acini. The lobules are enclosed by fibrovascular septa. The follicles are the main functional units of the thyroid. They are lined by cuboidal epithelium with numerous fine microvilli extending into the follicular colloid that contains the glycoprotein, *thyroglobulin*. Calcitonin-secreting C-cells or parafollicular cells are dispersed within the follicles and can only be identified by silver stains and immunohistochemical methods.

FUNCTIONS. The major function of the thyroid gland is to maintain a high rate of metabolism which is done by means of iodine-containing thyroid hormones, thyroxine (T_4) and tri-iodothyronine (T_3).

The *synthesis and release* of the two main circulating thyroid hormones, T_3 and T_4 are regulated by hypophyseal thyroid-stimulating hormone (TSH).

A number of *thyroid function tests* are currently available. These include the following:

- ◆ Determination of serum levels of T_3 , T_4 by radioimmunoassay (RIA).
- ◆ TSH and TRH determination.
- ◆ Determination of calcitonin secreted by parafollicular C cells.
- ◆ Estimation of thyroglobulin secreted by thyroid follicular cells.
- ◆ Assessment of thyroid activity by its ability to uptake radioactive iodine (RAIU).
- ◆ Assessment whether thyroid lesion is a nonfunctioning ('cold nodule') or hyperactive mass ('hot nodule').

□ HYPERTHYROIDISM (THYROTOXICOSIS) (p. 802)

Hyperthyroidism, also called thyrotoxicosis, is a hypermetabolic clinical and biochemical state caused by excess production of thyroid hormones. The condition is more frequent in females and is associated with rise in both T_3 and T_4 levels in blood, though the increase in T_3 is generally greater than that of T_4 .

ETIOPATHOGENESIS. Hyperthyroidism may be caused by many diseases but three most common causes are: Graves' disease (diffuse toxic goitre), toxic multinodular goitre and a toxic adenoma.

CLINICAL FEATURES. Patients with hyperthyroidism have a slow and insidious onset, varying in severity from case to case. The usual symptoms are emotional instability, nervousness, palpitation, fatigue, weight loss in spite of good appetite, heat intolerance, perspiration, menstrual disturbances and fine tremors of the outstretched hands. Cardiac manifestations in the form of tachycardia, palpitations and cardiomegaly are invariably present in hyperthyroidism. Serum levels of T_3 and T_4 are elevated but TSH secretion is usually inhibited.

□ HYPOTHYROIDISM (p. 803)

Cretinism (p. 803)

A cretin is a child with severe hypothyroidism present at birth or developing within first two years of postnatal life. This is the period when brain development is taking place; in the absence of treatment the child is both physically and mentally retarded.

ETIOPATHOGENESIS. It includes following:

1. *Developmental anomalies* e.g. thyroid agenesis and ectopic thyroid.
2. *Genetic defect* in thyroid hormone synthesis e.g. defect in iodine trapping, oxidation, iodination, coupling and thyroglobulin synthesis.
3. *Foetal exposure* to iodides and antithyroid drugs.
4. *Endemic cretinism* in regions with endemic goitre due to dietary lack of iodine.

670 CLINICAL FEATURES. The clinical manifestations usually become evident within a few weeks to months of birth. The presenting features of a cretin are: slow to thrive, poor feeding, constipation, dry scaly skin, hoarse cry and bradycardia.

Characteristic laboratory findings include a rise in TSH level and fall in T_3 and T_4 levels.

Myxoedema (p. 803)

The adult-onset severe hypothyroidism causes myxoedema. The term myxoedema connotes non-pitting oedema due to accumulation of hydrophilic mucopolysaccharides in the ground substance of dermis and other tissues.

ETIOPATHOGENESIS. It includes following:

1. Ablation of the thyroid by surgery or radiation.
2. Autoimmune (lymphocytic) thyroiditis (termed primary idiopathic myxoedema).
3. Endemic or sporadic goitre.
4. Hypothalamic-pituitary lesions.
5. Thyroid cancer.
6. Prolonged administration of antithyroid drugs.
7. Mild developmental anomalies and dyshormonogenesis.

CLINICAL FEATURES. The onset of myxoedema is slow and a fully-developed clinical syndrome may appear after several years of hypothyroidism. The striking features are cold intolerance, mental and physical lethargy, constipation, slowing of speech and intellectual function, puffiness of face, loss of hair and altered texture of the skin.

The laboratory diagnosis in myxoedema is made by low serum T_3 and T_4 levels and markedly elevated TSH levels as in the case of cretinism but cases with suprathyroid lesions (hypothalamic-pituitary disease) have low TSH levels.

The clinical appearance of three major forms of functional disorders of the thyroid gland is shown in **Web Image 27.6**.

□ **THYROIDITIS** (p. 804)

Inflammation of the thyroid, thyroiditis, is more often due to non-infectious causes and is classified on the basis of onset and duration of disease into acute, subacute and chronic as under:

I. Acute thyroiditis:

1. Bacterial infection e.g. *Staphylococcus*, *Streptococcus*.
2. Fungal infection e.g. *Aspergillus*, *Histoplasma*, *Pneumocystis*.
3. Radiation injury

II. Subacute thyroiditis:

1. Subacute granulomatous thyroiditis (de Quervain's thyroiditis, giant cell thyroiditis, viral thyroiditis)
2. Subacute lymphocytic (postpartum, silent) thyroiditis
3. Tuberculous thyroiditis

III. Chronic thyroiditis:

1. Autoimmune thyroiditis (Hashimoto's thyroiditis or chronic lymphocytic thyroiditis)
2. Riedel's thyroiditis (or invasive fibrous thyroiditis).

HASHIMOTO'S (AUTOIMMUNE, CHRONIC LYMPHOCYTIC) THYROIDITIS (p. 804)

Hashimoto's thyroiditis, also called diffuse lymphocytic thyroiditis, struma lymphomatosa or goitrous autoimmune thyroiditis, is characterised by 3 principal features:

1. Diffuse goitrous enlargement of the thyroid.
2. Lymphocytic infiltration of the thyroid gland.
3. Occurrence of thyroid autoantibodies.

Hashimoto's thyroiditis occurs more frequently between the age of 30 and 50 years and shows an approximately ten-fold preponderance among females. Though rare in children, about half the cases of adolescent goitre are owing to autoimmune thyroiditis. Hashimoto's thyroiditis is the most common cause of *goitrous hypothyroidism* in regions where iodine supplies are *adequate*. Regions where iodine intake is highest have higher incidence of Hashimoto's thyroiditis.

ETIOPATHOGENESIS. Hashimoto's thyroiditis is an autoimmune disease is well established. Autoimmune pathogenesis of Hashimoto's thyroiditis is explained by the following observations:

1. Other autoimmune disease association: Like in other autoimmune diseases, Hashimoto's disease has been found in association with other autoimmune diseases such as Graves' disease, SLE, Sjögren's syndrome, rheumatoid arthritis, pernicious anaemia and Type 1 diabetes mellitus.

2. Immune destruction of thyroid cells: The sequence of immune phenomena is initial activation of CD4+ T helper cells. These cells then induce infiltration of CD8+ T cytotoxic cells in the thyroid parenchyma as well as activate B cells to form autoantibodies, which bring about immune destruction of thyroid parenchyma.

3. Detection of autoantibodies: The following autoantibodies against different thyroid cell antigens are detectable in the sera of most patients with Hashimoto's thyroiditis:

- i) Thyroid microsomal autoantibodies (against the microsomes of the follicular cells).
- ii) Thyroglobulin autoantibodies.
- iii) TSH receptor autoantibodies.
- iv) Less constantly found are thyroid autoantibodies against follicular cell membranes, thyroid hormones themselves, and colloid component other than thyroglobulin.

4. Inhibitory TSH-receptor antibodies: TSH-receptor antibody seen on the surface of thyroid cells in Hashimoto's thyroiditis is inhibitory to TSH, producing hypothyroidism.

5. Genetic basis: The disease has higher incidence in first-degree relatives of affected patients. Hashimoto's thyroiditis is seen more often with HLA-DR3 and HLA-DR5 subtypes.

G/A The *classic form* is characterised by diffuse, symmetric, firm and rubbery enlargement of the thyroid which may weigh 100-300 gm. Sectioned surface of the thyroid is fleshy with accentuation of normal lobulations but with retained normal shape of the gland. The *fibrosing variant* has a firm, enlarged thyroid with compression of the surrounding tissues.

M/E The *classic form* shows the following features (**Web Image 27.7**):

1. There is extensive infiltration of the gland by lymphocytes, plasma cells, immunoblasts and macrophages, with formation of lymphoid follicles having germinal centres.
2. There is decreased number of thyroid follicles which are generally atrophic and are often devoid of colloid.
3. The follicular epithelial cells are transformed into their degenerated state termed Hurthle cells (also called Askanazy cells, or oxyphil cells, or oncocytes). These cells have abundant oxyphilic and eosinophilic and granular cytoplasm due to large number of mitochondria and contain large bizarre nuclei.
4. There is slight fibrous thickening of the septa separating the thyroid lobules.

The less common *fibrosing variant* of Hashimoto's thyroiditis shows considerable fibrous replacement of thyroid parenchyma and a less prominent lymphoid infiltrate.

SUBACUTE LYMPHOCYTIC THYROIDITIS (p. 805)

Subacute lymphocytic (or painless or silent or postpartum) thyroiditis is another variety of autoimmune thyroiditis. Clinically, it differs from subacute granulomatous thyroiditis in being non-tender thyroid enlargement. It is seen more often 3-6 months after delivery.

SUBACUTE GRANULOMATOUS (DE QUERVAIN'S) THYROIDITIS (p. 805)

Granulomatous thyroiditis, also called de Quervain's or subacute, or giant cell thyroiditis, is a distinctive form of self-limited inflammation of the thyroid gland. Etiology of the condition is not known but clinical features of a prodromal phase and preceding respiratory infection suggest a possible viral etiology.

G/A There is moderate enlargement of the gland which is often asymmetric or focal. The cut surface of the involved area is firm and yellowish-white.

M/E Following features are seen:

- ◆ *Initially*, there is acute inflammatory destruction of the thyroid parenchyma and formation of microabscesses.
- ◆ *Later*, the more characteristic feature of granulomatous appearance is produced. These granulomas consist of central colloid material surrounded by histiocytes and scattered multinucleate giant cells.
- ◆ More *advanced* cases may show fibroblastic proliferation.

RIEDEL'S THYROIDITIS (p. 805)

Riedel's thyroiditis, also called Riedel's struma or invasive fibrous thyroiditis, is a rare chronic disease characterised by stony-hard thyroid that is densely adherent to the adjacent structures in the neck. The condition is clinically significant due to compressive clinical features (e.g. dysphagia, dyspnoea, recurrent laryngeal nerve paralysis and stridor) and resemblance with thyroid cancer. Riedel's struma is seen more commonly in females in 4th to 7th decades of life. The etiology is unknown but possibly Riedel's thyroiditis is a part of *multifocal idiopathic fibrosclerosis*. This group of disorders includes: idiopathic retroperitoneal, mediastinal and retro-orbital fibrosis, and sclerosing cholangitis, all of which may occur simultaneously with Riedel's thyroiditis.

G/A The thyroid gland is usually contracted, stony-hard, asymmetric and firmly adherent to the adjacent structures. Cut section is hard and devoid of lobulations.

M/E There is extensive fibrocollagenous replacement, marked atrophy of the thyroid parenchyma, focally scattered lymphocytic infiltration and invasion of the adjacent muscle tissue by the process.

□ GRAVES' DISEASE (DIFFUSE TOXIC GOITRE) (p. 806)

Graves' disease, also known as Basedow's disease, primary hyperplasia, exophthalmic goitre, and diffuse toxic goitre, is characterised by a triad of features:

- ◆ Hyperthyroidism (thyrotoxicosis)
- ◆ Diffuse thyroid enlargement
- ◆ Ophthalmopathy.

The disease is more frequent between the age of 30 and 40 years and has five-fold increased prevalence among females.

ETIOPATHOGENESIS. There are many immunologic similarities between this condition and Hashimoto's thyroiditis:

1. Genetic factor association. Like in Hashimoto's thyroiditis. Graves' disease too has genetic predisposition. A familial occurrence has been observed. Susceptibility to develop Graves' disease has been found associated with HLA-DR3, *CTLA-4* and *PTPN22* (a T-cell regulatory gene).

2. Autoimmune disease association. Graves' disease may be found in association with other organ-specific autoimmune diseases. Hashimoto's thyroiditis and Graves' disease are frequently present in the same families and the two diseases may coexist in the same patient.

3. Other factors. Besides these two factors, Graves' disease has higher prevalence in women (7 to 10 times), and association with emotional stress and smoking.

4. Autoantibodies. Autoantibodies against thyroid antigens are detectable in the serum of these patients too but their sites of action are different from that of Hashimoto's thyroiditis. In Graves' disease, TSH-receptor autoantigen is the main antigen against which *autoantibodies* are directed. These are as under:

- i) *Thyroid-stimulating immunoglobulin (TSI)*
- ii) *Thyroid growth-stimulating immunoglobulins (TGI)*
- iii) *TSH-binding inhibitor immunoglobulins (TBII)*

G/A The thyroid is moderately, diffusely and symmetrically enlarged and may weigh up to 70-90 gm. On cut section, the thyroid parenchyma is typically homogeneous, red-brown and meaty and lacks the normal translucency.

M/E (Web Image 27.8): Following features are seen:

1. There is considerable epithelial hyperplasia and hypertrophy as seen by increased height of the follicular lining cells and formation of papillary infoldings of piled up epithelium into the lumina of follicles which are small.
2. The colloid is markedly diminished and is lightly staining, watery and finely vacuolated.
3. The stroma shows increased vascularity and accumulation of lymphoid cells.

CLINICAL FEATURES. Graves' disease generally develops slowly and insidiously. Patients are usually young women who present with symmetric, moderate enlargement of the thyroid gland with features of thyrotoxicosis, ophthalmopathy and dermatopathy.

□ **GOITRE** (p. 807)

The term goitre is defined as thyroid enlargement caused by compensatory hyperplasia and hypertrophy of the follicular epithelium in response to thyroid hormone deficiency. Two morphologic forms of goitre are distinguished:

- A. Diffuse goitre (simple nontoxic goitre or colloid goitre).
- B. Nodular goitre (multinodular goitre or adenomatous goitre).

Pathogenesis of Goitre (p. 807)

The pathogenetic mechanisms of both forms of goitre can be considered together since nodular goitre is generally regarded as the end-stage of long-standing simple goitre (**Web Image 27.9**). The fundamental defect is deficient production of thyroid hormones due to various etiologic factors described below, but most common is *dietary lack of iodine*. Deficient thyroid hormone production causes excessive TSH stimulation which leads to hyperplasia of follicular epithelium as well as formation of new thyroid follicles. Cyclical hyperplastic stage followed by involution stage completes the picture of *simple goitre*. Repeated and prolonged changes of hyperplasia result in continued growth of thyroid tissue while involuted areas undergo fibrosis, thus completing the picture of *nodular goitre*.

674 Diffuse Goitre (Simple Non-toxic Goitre, Colloid Goitre) (p. 807)

Diffuse, nontoxic simple or colloid goitre is the name given to diffuse enlargement of the thyroid gland, unaccompanied by hyperthyroidism. Most cases are in a state of euthyroid though they may have passed through preceding stage of hypothyroidism due to inadequate supply of iodine. TSH levels are invariably elevated. In general, goitre is more common in females.

ETIOLOGY. Epidemiologically, goitre occurs in 2 forms:

Endemic goitre. Prevalence of goitre in a geographic area in more than 10% of the population is termed endemic goitre. Such endemic areas are several high mountainous regions far from the sea where iodine content of drinking water and food is low such as in the regions of the Himalayas, the Alps and the Ande.

Though most endemic goitres are caused by dietary lack of iodine, some cases occur due to goitrogens and genetic factors.

Sporadic (non-endemic) goitre. Non-endemic or sporadic simple goitre is less common than the endemic variety. In most cases, the etiology of sporadic goitre is unknown. A number of causal influences have been attributed.

- ◆ Suboptimal iodine intake in conditions of increased demand as in puberty and pregnancy.
- ◆ Genetic factors.
- ◆ Dietary goitrogens.
- ◆ Hereditary defect in thyroid hormone synthesis and transport.
- ◆ Inborn errors of iodine metabolism.

G/A The enlargement of the thyroid gland in simple goitre is moderate (weighing up to 100-150 gm), symmetric and diffuse. Cut surface is gelatinous and translucent brown (**Web Image 27.10**).

M/E Two stages are distinguished:

1. *Hyperplastic stage* is the early stage and is characterised by tall columnar follicular epithelium showing papillary infoldings and formation of small new follicles.
2. *Involution stage* generally follows hyperplastic stage after variable period of time. This stage is characterised by large follicles distended by colloid and lined by flattened follicular epithelium (**Web Image 27.11**).

Nodular Goitre (Multinodular Goitre, Adenomatous Goitre) (p. 808)

As already stated, nodular goitre is regarded as the end-stage of long-standing simple goitre. It is characterised by most extreme degree of tumour-like enlargement of the thyroid gland and characteristic nodularity. The enlargement of the gland may be sufficient to not only cause cosmetic disfigurement, but in many cases may cause dysphagia and choking due to compression of oesophagus and trachea. About 10% cases may develop thyrotoxicosis resulting in toxic nodular goitre or Plummer's disease.

ETIOLOGY. Etiologic factors implicated in endemic and non-endemic or sporadic variety of simple goitre are involved in the etiology of nodular goitre too. Epithelial hyperplasia, generation of new follicles, and irregular accumulation of colloid in the follicles—all contribute to produce increased tension and stress in the thyroid gland causing rupture of follicles and vessels. This is followed by haemorrhages, scarring and sometimes calcification, resulting in development of nodular pattern.

G/A The thyroid in nodular goitre shows asymmetric and extreme enlargement, weighing 100-500 gm or even more. The *five* cardinal macroscopic features are as under (**Web Image 27.12**):

1. Nodularity with poor encapsulation
2. Fibrous scarring

3. Haemorrhages
4. Focal calcification
5. Cystic degeneration.

Cut surface generally shows multinodularity but occasionally there may be only one or two nodules which are poorly-circumscribed.

M/E Corresponding microscopic features are as follows (**Web Image 27.13**):

1. Partial or incomplete encapsulation of nodules.
2. The follicles varying from small to large and lined by flat to high epithelium. A few may show macropapillary formation.
3. Areas of haemorrhages, haemosiderin-laden macrophages and cholesterol crystals.
4. Fibrous scarring with foci of calcification.
5. Micro-macrocytic change.

The contrasting features of diffuse and nodular goitre are summarised in **Web Table 27.2**.

□ **THYROID TUMOURS** (p. 810)

FOLLICULAR ADENOMA (p. 810)

Follicular adenoma is the most common benign thyroid tumour occurring more frequently in adult women. Clinically, it appears as a solitary nodule which can be found in approximately 1% of the population. Though most adenomas cause no clinical problem and behave as a 'cold nodule', rarely they may produce mild hyperthyroidism and appear as 'hot nodule' on RAIU studies.

G/A The follicular adenoma is characterised by *four* features so as to distinguish it from a nodule of nodular goitre (**Web Image 27.14**):

1. solitary nodule;
2. complete encapsulation;
3. clearly distinct architecture inside and outside the capsule; and
4. compression of the thyroid parenchyma outside the capsule

Usually, an adenoma is small (up to 3 cm in diameter) and spherical. On cut section, the adenoma is grey-white to red-brown, less colloidal than the surrounding thyroid parenchyma and may have degenerative changes such as fibrous scarring, focal calcification, haemorrhages and cyst formation.

M/E The tumour shows complete fibrous encapsulation. The tumour cells are benign follicular epithelial cells forming follicles of various sizes or may show trabecular, solid and cord patterns with little follicle formation:

1. *Microfollicular (foetal) adenoma* consists of small follicles containing little or no colloid and separated by abundant loose stroma (**Web Image 27.15**).
2. *Normofollicular (simple) adenoma*.
3. *Macrofollicular (colloid) adenoma*.
4. *Trabecular (embryonal) adenoma*.
5. *Hurthle cell (oxyphilic) adenoma*.
6. *Atypical adenoma*.

THYROID CANCER (p. 811)

Approximately 95% of all primary thyroid cancers are carcinomas. Primary lymphomas of the thyroid comprise less than 5% of thyroid cancers and majority of them possibly evolve from autoimmune (lymphocytic) thyroiditis.

In line with most other thyroid lesions, most carcinomas of the thyroid too have female preponderance and are twice more common in women.

Carcinoma of the thyroid gland has 4 major morphologic types with distinctly different clinical behaviour and variable prevalence. These are: papillary, follicular, medullary and undifferentiated (anaplastic) carcinoma; their contrasting features are summed up in **Web Table 27.3**.

676 ETIOPATHOGENESIS. Most important risk factor implicated in the etiology of thyroid cancer is external radiation, and to a some extent there is role of TSH receptors and iodine excess, while pathogenesis of thyroid cancer is explained on genetic alterations.

1. External radiation. The single most important environmental factor associated with increased risk of developing thyroid carcinoma after many years of exposure to external radiation of high dose.

2. Iodine excess and TSH. In regions where endemic goitre is widespread, addition of iodine to diet has resulted in increase in incidence of papillary cancer.

3. Genetic basis. Familial clustering of thyroid cancer has been observed, especially in medullary carcinoma. Molecular studies reveal that thyroid carcinoma is a multistep process involving genetic alterations but distinct mutations are seen in different histologic types:

i) *Papillary thyroid carcinoma:* Mutation in *RET* gene (gene overexpression) located on chromosome 10q is seen in about 20% cases of papillary thyroid carcinoma.

ii) *Follicular thyroid carcinoma:* About 50% cases of follicular thyroid carcinoma have mutation in *RAS* family of oncogenes that includes *HRAS*, *NRAS* and *KRAS*.

iii) *Medullary thyroid carcinoma:* Medullary thyroid carcinoma arises from parafollicular C-cells in the thyroid. Point mutation in *RET*-protooncogene is seen in both familial as well as sporadic cases of medullary thyroid carcinoma.

iv) *Anaplastic thyroid carcinoma:* This tumour either arises from further dedifferentiation of differentiated papillary or follicular thyroid carcinoma, or by inactivating point mutation in *p53* tumour suppressor gene or by mutation in gene coding for β -catenin pathway.

Papillary Thyroid Carcinoma (p. 812)

Papillary carcinoma is the most common type of thyroid carcinoma, comprising 75-85% of cases. It can occur at all ages including children and young adults but the incidence is higher with advancing age. The tumour is found about three times more frequently in females than in males.

Papillary carcinoma is typically a slow-growing malignant tumour, most often presenting as an asymptomatic solitary nodule. Involvement of the regional lymph nodes is common but distant metastases to organs are rare. Some cases first come to attention by spread to regional lymph nodes and cause cervical lymphadenopathy. '*Lateral aberrant thyroid*' is the term used for occurrence of thyroid tissue in the lateral cervical lymph node, which in most patients represents a well-differentiated metastasis of an occult papillary carcinoma of the thyroid.

G/A Papillary carcinoma may range from microscopic foci to nodules upto 10 cm in diameter and is generally poorly delineated. Cut surface of the tumour is greyish-white, hard and scar-like (**Web Image 27.16**).

M/E (Web Image 27.17): Following features are seen:

1. Papillary pattern. Papillae composed of fibrovascular stalk and covered by single layer of tumour cells is the predominant feature. Papillae are often accompanied by follicles.

2. Tumour cells. The tumour cells have characteristic nuclear features due to dispersed nuclear chromatin imparting it *ground glass or optically clear appearance* and clear or oxyphilic cytoplasm. These tumour cells, besides covering the papillae, may form follicles and solid sheets.

3. Invasion. The tumour cells invade the capsule and intrathyroid lymphatics but invasion of blood vessels is rare.

4. Psammoma bodies. Half of papillary carcinomas show typical small, concentric, calcified spherules called psammoma bodies in the stroma.

The prognosis of papillary carcinoma is good: 10-year survival rate is 80-95%, irrespective of whether the tumour is pure papillary or mixed papillary-follicular carcinoma.

Follicular Thyroid Carcinoma (p. 813)

Follicular carcinoma is the other common type of thyroid cancer, next only to papillary carcinoma and comprises about 10-20% of all thyroid carcinomas. It is more common in middle and old age and has preponderance in females (female-male ratio 2.5:1). In contrast to papillary carcinoma, follicular carcinoma has a positive correlation with endemic goitre but the role of external radiation in its etiology is unclear.

Distant metastases by haematogenous route are common, especially to the lungs and bones.

G/A Follicular carcinoma may be either in the form of a solitary adenoma-like circumscribed nodule or as an obvious cancerous irregular thyroid enlargement. The cut surface of the tumour is grey-white with areas of haemorrhages, necrosis and cyst formation and may extend to involve adjacent structures.

M/E (Web Image 27.18): Following features are seen:

1. Follicular pattern: Follicular carcinoma, like follicular adenoma, is composed of follicles of various sizes and may show trabecular or solid pattern. The tumour cells have hyperchromatic nuclei and the cytoplasm resembles that of normal follicular cells. However, variants like *clear cell type* and *Hurthle cell (oxyphilic) type* of follicular carcinoma may occur.

2. Vascular invasion and direct extension: Vascular invasion and direct extension to involve the adjacent structures (e.g. into the capsule) are significant features but lymphatic invasion is rare.

The prognosis of follicular carcinoma is between that of papillary and undifferentiated carcinoma: 10-year survival rate is 50-70%.

Medullary Thyroid Carcinoma

Medullary carcinoma is a less frequent type derived from parafollicular or C-cells present in the thyroid and comprises about 5% of thyroid carcinomas. It is equally common in men and women. There are 3 distinctive features which distinguish medullary carcinoma from the other thyroid carcinomas.

1. Familial occurrence. Most cases of medullary carcinoma occur sporadically, but about 10% have a genetic background with point mutation in *RET*-protooncogene located on chromosome 10q. The sporadic cases occur in the middle and old age (5th-6th decades) and are generally unilateral, while the familial cases are found at younger age (2nd-3rd decades) and are usually bilateral and multicentric.

2. Secretion of calcitonin and other peptides. Like normal C-cells, tumour cells of medullary carcinoma secrete calcitonin, the hypocalcaemic hormone.

3. Amyloid stroma. Most medullary carcinomas have amyloid deposits in the stroma which stains positively with usual amyloid stains such as Congo red. The amyloid deposits are believed to represent stored calcitonin derived from neoplastic C-cells in the form of prohormone.

G/A The tumour may either appear as a unilateral solitary nodule (*sporadic form*), or have bilateral and multicentric involvement (*familial form*). However, sporadic neoplasms also eventually spread to the contralateral lobe. Cut surface of tumour in both forms shows well-defined tumour areas which are firm to hard, grey-white to yellow-brown with areas of haemorrhages and necrosis.

678 **M/E (Web Image 27.19):** Following features are seen:

1. Tumour cells: Like other neuroendocrine tumours (e.g. carcinoid, islet cell tumour, paraganglioma etc), medullary carcinoma of the thyroid too has a well-defined organoid pattern, forming nests of tumour cells separated by fibrovascular septa. Sometimes, the tumour cells may be arranged in sheets, ribbons pseudopapillae or small follicles. The tumour cells are uniform and have the structural and functional characteristics of C-cells.

2. Amyloid stroma: The tumour cells are separated by amyloid stroma derived from altered calcitonin which can be demonstrated by immunostain for calcitonin. The staining properties of amyloid are similar to that seen in systemic amyloidosis and may have areas of irregular calcification.

3. C-cell hyperplasia: Familial cases generally have C-cell hyperplasia as a precursor lesion but not in sporadic cases.

Most medullary carcinomas are slow-growing. Regional lymph node metastases may occur but distant organ metastases are infrequent. The prognosis is better in familial form than in the sporadic form: overall 10-year survival rate is 60-70%.

Anaplastic Carcinoma (p. 814)

Undifferentiated or anaplastic carcinoma of the thyroid comprises less than 5% of all thyroid cancers and is one of the most malignant tumour in humans. The tumour is predominantly found in old age (7th-8th decades) and is slightly more common in females than in males (female-male ratio 1.5:1). The tumour is widely aggressive and rapidly growing. The features at presentation are usually those of extensive invasion of adjacent soft tissue, trachea and oesophagus. The tumour metastasises both to regional lymph nodes and to distant organs such as lungs.

G/A The tumour is generally large and irregular, often invading the adjacent strap muscles of the neck and other structures in the vicinity of the thyroid. Cut surface of the tumour is white and firm with areas of necrosis and haemorrhages.

M/E The tumour is too poorly-differentiated to be placed in any other histologic type of thyroid cancer, but usually shows a component of either papillary or follicular carcinoma in better differentiated areas. The tumour is generally composed of 3 types of cells occurring in varying proportions: small cells, spindle cells and giant cells. When one of these cell types is predominant, the histologic variant of undifferentiated carcinoma is named accordingly.

The prognosis is poor: 5-year survival rate is less than 10% and median survival after the diagnosis is about 2 months.

NORMAL STRUCTURE (p. 815)

ANATOMY. The parathyroid glands are usually 4 in number: the *superior pair* derived from the 3rd branchial pouch and *inferior pair* from the 4th branchial pouch of primitive foregut. Both pairs are usually embedded in the posterior aspect of the thyroid substance but separated from it by a connective tissue capsule. In the adults, each gland is an oval, yellowish-brown, flattened body, weighing 35-45 mg.

M/E Parathyroid glands are composed of solid sheets and cords of parenchymal cells and variable amount of stromal fat. The parenchymal cells are of 3 types: *chief cells*, *oxyphil cells* and *water-clear cells*.

The major *function* of the parathyroid hormone, in conjunction with calcitonin and vitamin D, is to regulate serum calcium levels and metabolism of bone. Parathyroid hormone tends to elevate serum calcium level and

reduce serum phosphate level. The role of parathyroid hormone in regulating calcium metabolism in the body is at the following 3 levels (**Web Image 27.20**):

1. Parathyroid hormone *stimulates osteoclastic activity* and results in resorption of bone and release of calcium.
2. Parathyroid hormone acts *directly on renal tubular epithelial cells* and increases renal reabsorption of calcium and inhibits reabsorption of phosphate.
3. Parathyroid hormone increases renal production of the *most active metabolite of vitamin D*.

□ **HYPERPARATHYROIDISM** (p. 816)

Primary Hyperparathyroidism (p. 816)

Primary hyperparathyroidism is not uncommon and occurs more commonly with increasing age. It is especially likely to occur in women near the time of menopause.

ETIOLOGY. Common causes of primary hyperparathyroidism are as follows:

1. Most commonly, parathyroid adenomas in approximately 80% cases.
2. Carcinoma of the parathyroid glands in 2-3% patients.
3. Primary hyperplasia in about 15% cases (usually chief cell hyperplasia).

CLINICAL FEATURES. These are:

1. Elevated levels of parathyroid hormone
2. Hypercalcaemia
3. Hypophosphataemia
4. Hypercalciuria

Clinical presentation of individuals with primary hyperparathyroidism may be in a variety of ways:

1. Most commonly, *nephrolithiasis* and/or *nephrocalcinosis*.
2. *Metastatic calcification*.
3. *Generalised osteitis fibrosa cystica*.
4. *Neuropsychiatric disturbances*.
5. *Hypertension*.

Secondary Hyperparathyroidism (p. 816)

Secondary hyperparathyroidism occurs due to increased parathyroid hormone elaboration secondary to a disease elsewhere in the body. Hypocalcaemia stimulates compensatory hyperplasia of the parathyroid glands and causes secondary hyperparathyroidism.

ETIOLOGY. It includes

1. *Chronic renal insufficiency*.
2. *Vitamin D deficiency*.
3. *Intestinal malabsorption syndromes*.

CLINICAL FEATURES. The main biochemical abnormality in secondary hyperparathyroidism is mild hypocalcaemia, in striking contrast to hypercalcaemia in primary hyperparathyroidism. Usually, secondary hyperparathyroidism is a beneficial compensatory mechanism, but more severe cases may be associated with renal osteodystrophy (i.e. features of varying degree of osteitis fibrosa, osteomalacia, osteoporosis and osteosclerosis in cases of chronic renal insufficiency) and soft tissue calcification (**Web Image 27.21**).

Tertiary Hyperparathyroidism (p. 817)

Tertiary hyperparathyroidism is a complication of secondary hyperparathyroidism in which the hyperfunction persists in spite of removal of the cause of secondary hyperplasia.

Primary Hypoparathyroidism (p. 817)

Most common causes of primary hypoparathyroidism are: surgical procedures involving thyroid, parathyroid, or radical neck dissection for cancer. Other causes are uncommon and include idiopathic hypoparathyroidism of autoimmune origin in children and may occur as sporadic or familial cases.

CLINICAL FEATURES. These are:

1. Increased neuromuscular irritability and tetany
2. Calcification of the lens and cataract formation
3. Abnormalities in cardiac conduction
4. Disorders of the CNS due to intracranial calcification
5. Abnormalities of the teeth.

Pseudo-hypoparathyroidism (p. 817)

In pseudo-hypoparathyroidism, the tissues fail to respond to parathyroid hormone though parathyroid glands are usually normal. It is a rare inherited condition with an autosomal dominant character. The patients are generally females and are characterised by signs and symptoms of hypoparathyroidism and other clinical features like short stature, short metacarpals and metatarsals, flat nose, round face and multiple exostoses.

Pseudopseudo-hypoparathyroidism (p. 817)

Pseudopseudo-hypoparathyroidism is another rare familial disorder in which all the clinical features of pseudo-hypoparathyroidism are present except that these patients have no hypocalcaemia or hyperphosphataemia and the tissues respond normally to parathyroid hormone.

□ **PARATHYROID TUMOURS** (p. 817)**Parathyroid Adenoma** (p. 817)

The commonest tumour of the parathyroid glands is an adenoma. It may occur at any age and in either sex but is found more frequently in adult life.

G/A A parathyroid adenoma is small (less than 5 cm diameter) encapsulated, yellowish-brown, ovoid nodule and weighing up to 5 gm or more.

M/E Majority of adenomas are predominantly composed of chief cells arranged in sheets or cords. Oxyphil cells and water-clear cells may be found intermingled in varying proportions.

Parathyroid Carcinoma (p. 818)

Carcinoma of the parathyroid is rare and produces manifestations of hyperparathyroidism which is often more pronounced. Carcinoma tends to be irregular in shape and is adherent to the adjacent tissues. Most parathyroid carcinomas are well-differentiated.

The human pancreas, though anatomically a single organ, histologically and functionally, has 2 distinct parts—the exocrine and endocrine. The discussion here is focused on the endocrine pancreas and its two main disorders: *diabetes mellitus* and *islet cell tumours*.

□ **NORMAL STRUCTURE** (p. 818)

The endocrine pancreas consists of microscopic collections of cells called islets of Langerhans found scattered within the pancreatic lobules, as well as individual endocrine cells found in duct epithelium and among the acini.

The total weight of endocrine pancreas in the adult, however, does not exceed 1-1.5 gm (total weight of pancreas 60-100 gm). The islet cell tissue is greatly concentrated in the tail than in the head or body of the pancreas. Islets possess no ductal system and they drain their secretory products directly into the circulation. Ultrastructurally and immunohistochemically, 4 *major* and 2 *minor* types of islet cells:

A. Major cell types:

1. *Beta* (β) or *B cells* comprise about 70% of islet cells and secrete insulin, the defective response or deficient synthesis of which causes diabetes mellitus.
2. *Alpha* (α) or *A cells* comprise 20% of islet cells and secrete glucagon which induces hyperglycaemia.
3. *Delta* (δ) or *D cells* comprise 5-10% of islet cells and secrete somatostatin which suppresses both insulin and glucagon release.
4. *Pancreatic polypeptide (PP) cells* or *F cells* comprise 1-2% of islet cells and secrete pancreatic polypeptide having some gastrointestinal effects.

B. Minor cell types:

1. *D1 cells* elaborate vasoactive intestinal peptide (VIP) which induces glycogenolysis and hyperglycaemia and causes secretory diarrhoea by stimulation of gastrointestinal fluid secretion.
2. *Enterochromaffin cells* synthesise serotonin which in pancreatic tumours may induce carcinoid syndrome.

□ **DIABETES MELLITUS** (p. 818)

Definition and Epidemiology (p. 818)

As per the WHO, diabetes mellitus (DM) is defined as a heterogeneous metabolic disorder characterised by common feature of chronic hyperglycaemia with disturbance of carbohydrate, fat and protein metabolism.

DM is a leading cause of morbidity and mortality world over. It is estimated that approximately 1% of population suffers from DM. The incidence is rising in the developed countries of the world at the rate of about 10% per year, especially of type 2 DM, due to rising incidence of obesity and reduced activity levels.

Classification and Etiology (p. 818)

The older classification systems dividing DM into primary (idiopathic) and secondary types, juvenile-onset and maturity onset types, and insulin-dependent (IDDM) and non-insulin dependent (NIDDM) types, have become obsolete and undergone major revision due to extensive understanding of etiology and pathogenesis of DM in recent times.

As outlined in **Web Table 27.4**, current classification of DM based on etiology divides it into two broad categories—type 1 and type 2; besides there are a few uncommon specific etiologic types, and gestational DM. American Diabetes Association (2007) has identified risk factors for type 2 DM listed in **Web Table 27.5**.

Brief comments on etiologic terminologies as contrasted with former nomenclatures of DM are as under:

TYPE 1 DM. It constitutes about 10% cases of DM. It was previously termed as juvenile-onset diabetes (JOD) due to its occurrence in younger age, and was called insulin-dependent DM (IDDM). Based on underlying etiology, type 1 DM is further divided into 2 subtypes:

Subtype 1A (immune-mediated) DM characterised by autoimmune destruction of β -cells which usually leads to insulin deficiency.

Subtype 1B (idiopathic) DM characterised by insulin deficiency with tendency to develop ketosis but these patients are negative for autoimmune markers.

Though type 1 DM occurs commonly in patients under 30 years of age, autoimmune destruction of β -cells can occur at any age. In fact, 5-10% patients who develop DM above 30 years of age are of type 1A DM and hence the term JOD has become obsolete.

TYPE 2 DM. This type comprises about 80% cases of DM. It was previously called maturity-onset diabetes, or non-insulin dependent diabetes mellitus (NIDDM) of obese and non-obese type.

OTHER SPECIFIC ETIOLOGIC TYPES OF DM. Besides the two main types, about 10% cases of DM have a known specific etiologic defect. One important subtype in this group is *maturity-onset diabetes of the young (MODY)* which has autosomal dominant inheritance, early onset of hyperglycaemia and impaired insulin secretion.

GESTATIONAL DM. About 4% pregnant women develop DM due to metabolic changes during pregnancy. Although they revert back to normal glycaemia after delivery, these women are prone to develop DM later in their life.

Pathogenesis (p. 819)

Depending upon etiology of DM, hyperglycaemia may result from the following:

- Reduced insulin secretion
- Decreased glucose use by the body
- Increased glucose production.

Pathogenesis of two main types of DM and its complications is distinct.

NORMAL INSULIN METABOLISM. *The major stimulus for both synthesis and release of insulin is glucose.* The steps involved in biosynthesis, release and actions of insulin are as follows (**Web Image 27.22**):

Synthesis. Insulin is synthesised in the β -cells of pancreatic islets of Langerhans:

- i) It is initially formed as *pre-proinsulin*.
- ii) Subsequent proteolysis removes the amino terminal signal peptide, forming *proinsulin*.
- iii) Further cleavage of proinsulin gives rise to *A (21 amino acids) and B (30 amino acids) chains* of insulin, linked together by connecting segment called *C-peptide*.

Release. Glucose is the key regulator of insulin secretion from β -cells by a series of steps:

- i) Hypoglycaemia (glucose level below 70 mg/dl or below 3.9 mmol/L) stimulates transport into β -cells of a *glucose transporter, GLUT2*.
- ii) An islet transcription factor, *glucokinase*, causes glucose phosphorylation.
- iii) Metabolism of glucose to glucose-6-phosphate by glycolysis generates *ATP*.
- iv) Generation of ATP *alters the ion channel activity* on the membrane which stimulates insulin release.

Action. Half of insulin secreted from β -cells into portal vein is degraded in the liver while the remaining half enters the systemic circulation for action on the target cells:

PATHOGENESIS OF TYPE 1 DM. *The basic phenomenon in type 1 DM is destruction of β -cell mass, usually leading to absolute insulin deficiency.* While type 1B DM remains idiopathic, pathogenesis of type 1A DM is immune-mediated and has been extensively studied. Currently, pathogenesis of type 1A DM is explained on the basis of 3 mutually-interlinked mechanisms: genetic susceptibility, autoimmune factors, and certain environmental factors (**Web Image 27.23,A**).

KEY POINTS: Pathogenesis for type 1A DM can be summed up by inter-linking the above factors as under:

1. At birth, individuals with *genetic susceptibility* to this disorder have normal β -cell mass.
2. β -cells act as autoantigens and activate CD4+ T lymphocytes, bringing about immune destruction of pancreatic β -cells by *autoimmune phenomena* and takes months to years. Clinical features of diabetes manifest after more than 80% of β -cell mass has been destroyed.
3. The trigger for autoimmune process appears to be some *infectious or environmental factor* which specifically targets β -cells.

PATHOGENESIS OF TYPE 2 DM. The basic metabolic defect in type 2 DM is either a delayed insulin secretion relative to glucose load (*impaired insulin secretion*), or the peripheral tissues are unable to respond to insulin (*insulin resistance*).

Type 2 DM is a heterogeneous disorder with a more complex etiology and is far more common than type 1, but much less is known about its pathogenesis. A number of factors have been implicated though, but HLA association and autoimmune phenomena are not implicated. These factors are as under (**Web Image 27.23,B**):

1. Genetic factors
2. Constitutional factors
3. Insulin resistance
4. Impaired insulin secretion
5. Increased hepatic glucose synthesis.

KEY POINTS: In essence, hyperglycaemia in type 2 DM is not due to destruction of β -cells but is instead a failure of β -cells to meet the requirement of insulin in the body. Its pathogenesis can be summed up by interlinking the above factors as under:

1. Type 2 DM is a more *complex multifactorial disease*.
2. There is greater role of *genetic defect and heredity*.
3. Two main mechanisms for hyperglycaemia in type 2 DM—*insulin resistance and impaired insulin secretion*, are interlinked.
4. While *obesity* plays a role in pathogenesis of insulin resistance, impaired insulin secretion may be from many constitutional factors.
5. *Increased hepatic synthesis of glucose* in initial period of disease contributes to hyperglycaemia.

Morphologic Features in Pancreatic Islets (p. 822)

1. Insulinitis:

In type 1 DM, characteristically, in early stage there is lymphocytic infiltrate, mainly by T cells, in the islets which may be accompanied by a few macrophages and polymorphs.

In type 2 DM, there is no significant leucocytic infiltrate in the islets but there is variable degree of fibrous tissue in the islets.

2. Islet cell mass:

In type 1 DM, as the disease becomes chronic there is progressive depletion of β -cell mass, eventually resulting in total loss of pancreatic β -cells and its hyalinisation.

In type 2 DM, β -cell mass is either normal or mildly reduced.

3. Amyloidosis:

In type 1 DM, deposits of amyloid around islets are absent.

In type 2 DM, characteristically chronic long-standing cases show deposition of amyloid material, amylin, around the capillaries of the islets causing compression and atrophy of islet tissue (**Web Image 27.24**).

4. β -cell degranulation: *In type 1 DM*, EM shows degranulation of remaining β -cells of islets.

In type 2 DM, no such change is observed.

684 Clinical Features (p. 823)

It can be appreciated that hyperglycaemia in DM does not cause a single disease but is associated with numerous diseases and symptoms, especially due to complications. Two main types of DM can be distinguished clinically to the extent shown in **Web Table 27.6**. Pathophysiology in evolution of clinical features is schematically shown in **Web Image 27.25**.

Type 1 DM:

- i) Patients of type 1 DM usually manifest at early age, generally below the age of 35.
- ii) The onset of symptoms is often abrupt.
- iii) At presentation, these patients have polyuria, polydipsia and polyphagia.
- iv) The patients are not obese but have generally progressive loss of weight.
- v) These patients are prone to develop metabolic complications such as ketoacidosis and hypoglycaemic episodes.

Type 2 DM:

- i) This form of diabetes generally manifests in middle life or beyond, usually above the age of 40.
- ii) The onset of symptoms in type 2 DM is slow and insidious.
- iii) Generally, the patient is asymptomatic when the diagnosis is made on the basis of glucosuria or hyperglycaemia during physical examination, or may present with polyuria and polydipsia.
- iv) The patients are frequently obese and have unexplained weakness and loss of weight.
- v) Metabolic complications such as ketoacidosis are infrequent.

Pathogenesis of Complications (p. 824)

It is now known that in both type 1 and 2 DM, *severity and chronicity of hyperglycaemia* forms the main pathogenetic mechanism for 'microvascular complications' (e.g. retinopathy, nephropathy, neuropathy); therefore control of blood glucose level constitutes the mainstay of treatment for minimising development of these complications. Longstanding cases of type 2 DM, however, in addition, frequently develop 'macrovascular complications' (e.g. atherosclerosis, coronary artery disease, peripheral vascular disease, cerebrovascular disease) which are more difficult to explain on the basis of hyperglycaemia alone.

The following biochemical mechanisms have been proposed to explain the development of complications of diabetes mellitus (**Web Image 27.26, A**):

1. Non-enzymatic protein glycosylation
2. Polyol pathway mechanism
3. Excessive oxygen free radicals.

Complications of Diabetes (p. 825)

As a consequence of hyperglycaemia of diabetes, every tissue and organ of the body undergoes biochemical and structural alterations which account for the major complications in diabetics which may be *acute metabolic* or *chronic systemic*.

Both types of diabetes mellitus may develop complications which are broadly divided into 2 major groups:

I. ACUTE METABOLIC COMPLICATIONS. Metabolic complications develop acutely. While ketoacidosis and hypoglycaemic episodes are primarily complications of type 1 DM, hyperosmolar nonketotic coma is chiefly a complication of type 2 DM (also see Web Image 27.25).

1. Diabetic ketoacidosis (DKA). Ketoacidosis is almost exclusively a complication of type 1 DM. It can develop in patients with severe insulin

deficiency combined with glucagon excess. Failure to take insulin and exposure to stress are the usual precipitating causes.

2. Hyperosmolar hyperglycaemic nonketotic coma (HHS). Hyperosmolar hyperglycaemic nonketotic coma is usually a complication of type 2 DM. It is caused by severe dehydration resulting from sustained hyperglycaemic diuresis.

The contrasting features of diabetic ketoacidosis and hyperosmolar non-ketotic coma are summarised in **Web Table 27.7**.

3. Hypoglycaemia. Hypoglycaemic episode may develop in patients of type 1 DM. It may result from excessive administration of insulin, missing a meal, or due to stress.

II. LATE SYSTEMIC COMPLICATIONS. A number of systemic complications may develop after a period of 15-20 years in either type of diabetes. Late complications are largely responsible for morbidity and premature mortality in diabetes mellitus (**Web Image 27.26,B**).

1. Atherosclerosis. Diabetes mellitus of both type 1 and type 2 accelerates the development of atherosclerosis. Consequently, atherosclerotic lesions appear earlier than in the general population, are more extensive, and are more often associated with complicated plaques such as ulceration, calcification and thrombosis.

2. Diabetic microangiopathy. Microangiopathy of diabetes is characterised by basement membrane thickening of small blood vessels and capillaries of different organs and tissues such as the skin, skeletal muscle, eye and kidney.

3. Diabetic nephropathy. Renal involvement is a common complication and a leading cause of death in diabetes. Four types of lesions are described in diabetic nephropathy:

- i) *Diabetic glomerulosclerosis*
- ii) *Vascular lesions*
- iii) *Diabetic pyelonephritis and necrotising renal papillitis*
- iv) *Tubular lesions or Armani-Ebstein lesion.*

4. Diabetic neuropathy. Diabetic neuropathy may affect all parts of the nervous system but symmetric peripheral neuropathy is most characteristic. The basic pathologic changes are segmental demyelination.

5. Diabetic retinopathy. Diabetic retinopathy is a leading cause of blindness. There are 2 types of lesions involving retinal vessels: *background* and *proliferative*.

6. Infections. Diabetics have enhanced susceptibility to various infections such as tuberculosis, pneumonias, pyelonephritis, otitis, carbuncles and diabetic ulcers.

Diagnosis of Diabetes (p. 826)

Hyperglycaemia remains the fundamental basis for the diagnosis of diabetes mellitus. In *symptomatic cases*, the diagnosis is not a problem and can be confirmed by finding glucosuria and a random plasma glucose concentration above 200 mg/dl.

◆ The severity of clinical symptoms of polyuria and polydipsia is directly related to the degree of hyperglycaemia.

◆ In *asymptomatic cases*, when there is persistently elevated fasting plasma glucose level, diagnosis again poses no difficulty.

◆ The problem arises in asymptomatic patients who have normal fasting glucose level in the plasma but are suspected to have diabetes on other grounds and are thus subjected to oral glucose tolerance test (GTT). If abnormal GTT values are found, these subjects are said to have '*chemical diabetes*' (**Web Image 27.27**). The American Diabetes Association (2007)

686 has recommended definite diagnostic criteria for early diagnosis of diabetes mellitus (**Web Table 27.8**).

The following investigations are helpful in establishing the diagnosis of diabetes mellitus:

I. URINE TESTING. Urine tests are cheap and convenient but the diagnosis of diabetes cannot be based on urine testing alone since there may be false-positives and false-negatives. They can be used in population screening surveys. Urine is tested for the presence of glucose and ketones.

1. Glucosuria. *Benedict's qualitative test* detects any reducing substance in the urine and is not specific for glucose.

Besides diabetes mellitus, *glucosuria* may also occur in certain other conditions such as: renal glucosuria, alimentary (lag storage) glucosuria, many metabolic disorders, starvation and intracranial lesions (e.g. cerebral tumour, haemorrhage and head injury).

◆ **Renal glucosuria (Web Image 27.27,B):** After diabetes, the next most common cause of glucosuria is the reduced renal threshold for glucose. In such cases although the blood glucose level is below 180 mg/dl (i.e. below normal renal threshold for glucose) but glucose still appears regularly and consistently in the urine due to lowered renal threshold.

Renal glucosuria is a benign condition unrelated to diabetes and runs in families and may occur temporarily in pregnancy without symptoms of diabetes.

◆ **Alimentary (lag storage) glucosuria (Web Image 27.27,C):** A rapid and transitory rise in blood glucose level above the normal renal threshold may occur in some individuals after a meal. During this period, glucosuria is present. This type of response to meal is called 'lag storage curve' or more appropriately 'alimentary glucosuria'. A characteristic feature is that unusually high blood glucose level returns to normal 2 hours after meal.

2. Ketonuria. Tests for ketone bodies in the urine are required for assessing the severity of diabetes and not for diagnosis of diabetes.

Besides uncontrolled diabetes, ketonuria may appear in individuals with prolonged vomitings, fasting state or exercising for long periods.

II. SINGLE BLOOD SUGAR ESTIMATION. For diagnosis of diabetes, blood sugar determinations are absolutely necessary. Whole blood or plasma may be used but *whole blood values are 15% lower than plasma values*.

A grossly elevated single determination of plasma glucose may be sufficient to make the diagnosis of diabetes. *A fasting plasma glucose value above 126 mg/dl (≥ 7 mmol/L) is certainly indicative of diabetes.* In other cases, oral GTT is performed.

III. SCREENING BY FASTING GLUCOSE TEST. Fasting plasma glucose determination is a screening test for DM type 2.

- i) Many of the cases meeting the current criteria of DM are asymptomatic and don't know that they have the disorder.
- ii) Studies have shown that type 2 DM may be present for about 10 years before symptomatic disease appears.
- iii) About half the cases of type 2 DM have some diabetes-related complication at the time of diagnosis.
- iv) The course of disease is favourably altered with treatment.

IV. ORAL GLUCOSE TOLERANCE TEST. Oral GTT is performed principally for patients with borderline fasting plasma glucose value (i.e. between 100-140 mg/dl). The patient who is scheduled for oral GTT is instructed to eat a high carbohydrate diet for at least 3 days prior to the test and come after an overnight fast on the day of the test (for at least 8 hours). A fasting blood sugar sample is first drawn. Then 75 gm of glucose dissolved in 300 ml of water is given. Blood and urine specimen are collected at half-hourly

intervals for at least 2 hours. Blood or plasma glucose content is measured and urine is tested for glucosuria to determine the approximate renal threshold for glucose.

- ◆ Normal cut off value for fasting blood glucose level is considered as 100 mg/dl.
- ◆ Cases with fasting blood glucose value in range of 100-125 mg/dl are considered as *impaired fasting glucose tolerance (IGT)*; these cases are at increased risk of developing diabetes later and therefore kept under observation for repeating the test. During pregnancy, however, a case of IGT is treated as a diabetic.
- ◆ Individuals with fasting value of plasma glucose higher than 126 mg/dl and 2-hour value after 75 gm oral glucose higher than 200 mg/dl are labelled as *diabetics (Web Image 27.27,D)*.
- ◆ In symptomatic case, the random blood glucose value above 200 mg/dl is diagnosed as diabetes mellitus.

V. OTHER TESTS. These include following:

1. *Glycosylated haemoglobin (HbA_{1C})*. Measurement of blood glucose level in diabetics suffers from variation due to dietary intake of the previous day. Long-term objective assessment of degree of glycaemic control is better monitored by measurement of glycosylated haemoglobin (HbA_{1C}).
2. Glycated albumin
3. Extended GTT
4. Intravenous GTT
5. Cortisone-primed GTT
6. Insulin assay
7. Proinsulin assay
8. C-peptide assay
9. Islet autoantibodies
10. Screening for diabetes-associated complications.

□ ISLET CELL TUMOURS (p. 828)

Islet cell tumours are rare as compared with tumours of the exocrine pancreas. Islet cell tumours are generally small and may be hormonally inactive or may produce hyperfunction. They may be benign or malignant, single or multiple. They are named according to their histogenesis such as: β -cell tumour (insulinoma), G-cell tumour (gastrinoma), A-cell tumour (glucagonoma) D-cell tumour (somatostatinoma), vipoma (diarrhoeogenic tumour from D₁ cells which elaborate VIP), pancreatic polypeptide (PP)-secreting tumour, and carcinoid tumour.

Insulinoma (β -Cell Tumour) (p. 828)

Insulinomas or beta (β)-cell tumours are the most common islet cell tumours. The neoplastic β -cells secrete insulin into the blood stream which remains unaffected by normal regulatory mechanisms. This results in characteristic attacks of hypoglycaemia with blood glucose level falling to 50 mg/dl or below, high plasma insulin level (hyperinsulinism) and high insulin-glucose ratio.

G/A Insulinoma is usually solitary and well-encapsulated tumour which may vary in size from 0.5 to 10 cm. Rarely, they are multiple.

M/E The tumour is composed of cords and sheets of well-differentiated β -cells which do not differ from normal cells.

Gastrinoma (G-Cell Tumour, Zollinger-Ellison Syndrome) (p. 829)

Zollinger and Ellison described diagnostic triad consisting of the following:

- ◆ Fulminant peptic ulcer disease
- ◆ Gastric acid hypersecretion
- ◆ Presence of non- β pancreatic islet cell tumour.

Such non- β pancreatic islet cell tumour is the source of gastrin, producing hypergastrinaemia and hence named gastrinoma.

MORPHOLOGIC FEATURES. Majority of gastrinomas occur in the wall of the duodenum. They may be benign or malignant.

MISCELLANEOUS ENDOCRINE TUMOURS (p. 829)

MULTIPLE ENDOCRINE NEOPLASIA (MEN) SYNDROMES (p. 829)

Multiple adenomas and hyperplasias of different endocrine organs are a group of genetic disorders which produce heterogeneous clinical features called multiple endocrine neoplasia (MEN) syndromes. Presently, 4 distinct types of MEN syndromes are distinguished. These are briefly outlined below along with major disease associations:

1. MEN type 1 syndrome (Wermer's syndrome) includes adenomas of the parathyroid glands, pancreatic islets and pituitary. The syndrome is inherited as an autosomal dominant trait. There is 50% chance of transmitting the predisposing gene, *MEN 1* (or *menin*) gene, to the child of an affected person.

2. MEN type 2 syndrome (Sipple's syndrome) is characterised by medullary carcinoma thyroid and pheochromocytoma. Genetic abnormality in these cases is mutation in *RET* gene in almost all cases. MEN 2 has two major syndromes:

◆ *MEN type 2A* is the combination of medullary carcinoma thyroid, pheochromocytoma and hyperparathyroidism.

◆ *MEN type 2B* the combination of medullary carcinoma thyroid, pheochromocytoma, mucosal neuromas, intestinal ganglioneuromatosis, and marfanoid features.

3. Mixed syndromes include a variety of endocrine neoplastic combinations which are distinct from those in MEN type 1 and type 2. A few examples are as under:

◆ von Hippel-Lindau syndrome from mutation in *VHL* gene is association of CNS tumours, renal cell carcinoma, pheochromocytoma and islet cell tumours.

◆ Type 1 neurofibromatosis from inactivation of neurofibromin protein and activation of *RAS* gene, is associated with MEN type 1 or type 2 features.

POLYGLANDULAR AUTOIMMUNE (PGA) SYNDROMES (p. 829)

Immunologic syndromes affecting two or more endocrine glands and some non-endocrine immune disturbances produce syndromic presentation termed polyglandular autoimmune (PGA) syndromes. PGA syndromes are of two types:

◆ PGA type I occurring in children is characterised by mucocutaneous candidiasis, hypoparathyroidism, and adrenal insufficiency.

◆ PGA type II (Schmidt syndrome) presents in adults and commonly comprises of adrenal insufficiency, autoimmune thyroiditis, and type 1 diabetes mellitus.

◆ SELF ASSESSMENT

1. Hyperfunction of anterior pituitary in pre-pubertal children generally results in:

- | | |
|------------------------|-----------------------|
| A. Acromegaly | B. Gigantism |
| C. Hyperprolactinaemia | D. Cushing's syndrome |

2. Excessive secretion of ADH from posterior pituitary results from the following conditions except:

- | | |
|-----------------------|-----------------------|
| A. Oat cell carcinoma | B. Carcinoma pancreas |
| C. Pituitary adenoma | D. Thymoma |

3. **Hypofunction of anterior pituitary results in the following except:**
- | | |
|-----------------------|-------------------------|
| A. Sheehan's syndrome | B. Diabetes insipidus |
| C. Pituitary dwarfism | D. Empty-sella syndrome |
4. **The most common form of pituitary adenoma is:**
- | | |
|----------------|-----------------|
| A. Somatotroph | B. Lactotroph |
| C. Gonadotroph | D. Corticotroph |
5. **Craniopharyngioma arises from:**
- Arachnoid cap cells
 - Lining epithelium of pharynx
 - Chromophil cells
 - Remnants of Rathke's pouch
6. **Cushing's syndrome due to ectopic elaboration of cortisol occurs in the following conditions except:**
- Oat cell carcinoma lung
 - Adrenal cortical adenoma
 - Malignant thymoma
 - Pancreatic carcinoma
7. **Main causes of Addison's disease include the following except:**
- | | |
|-----------------------------|------------------------|
| A. Tuberculosis | B. Amyloidosis |
| C. Adrenal cortical adenoma | D. Autoimmune diseases |
8. **Pheochromocytoma has the following features except:**
- It is generally a benign tumour of adrenal medulla
 - Hypertension is generally presenting feature
 - It arises from embryonal nerve cells
 - 24 hour urinary measurement of catecholamines is diagnostic
9. **Neuroblastoma has the following features except:**
- It arises from primitive nerve cells
 - It is a common malignant tumour in children under 5 years of age
 - The tumour spreads by haematogenous route early
 - The tumour cells are highly pleomorphic and large
10. **Common causes of myxoedema are as under except:**
- Follicular adenoma
 - Ablation of thyroid by surgery
 - Thyroid cancer
 - Autoimmune thyroiditis
11. **There is higher incidence of lymphoma of the thyroid in the following condition:**
- | | |
|--------------------|----------------------------|
| A. Graves' disease | B. Hashimoto's thyroiditis |
| C. Nodular goitre | D. Riedel's thyroiditis |
12. **There is considerable depletion of colloid in the follicles in the following thyroid disease:**
- | | |
|--------------------|----------------------------|
| A. Graves' disease | B. Hashimoto's thyroiditis |
| C. Nodular goitre | D. Follicular adenoma |
13. **Nodular goitre is characterised by the following features except:**
- Iodine deficiency plays role in etiology
 - There is repeated hyperplasia and involution
 - There is deficient thyroid hormone production
 - There is decreased TSH stimulation
14. **Role of external radiation in etiology of thyroid cancer is maximum in:**
- | | |
|------------------------|-------------------------|
| A. Papillary carcinoma | B. Follicular carcinoma |
| C. Medullary carcinoma | D. Anaplastic carcinoma |
15. **Haematogenous spread is rare and exceptional in following thyroid cancer:**
- | | |
|-------------------------|-------------------------|
| A. Follicular carcinoma | B. Medullary carcinoma |
| C. Papillary carcinoma | D. Anaplastic carcinoma |
16. **Male: female ratio is equal in the following thyroid cancer:**
- | | |
|------------------------|-------------------------|
| A. Papillary carcinoma | B. Follicular carcinoma |
| C. Medullary carcinoma | D. Anaplastic carcinoma |

- 17. The following thyroid cancer is a neuroendocrine tumour:**
- A. Papillary carcinoma B. Follicular carcinoma
 C. Medullary carcinoma D. Anaplastic carcinoma
- 18. Following thyroid cancer has the best prognosis:**
- A. Anaplastic carcinoma B. Medullary carcinoma
 C. Papillary carcinoma D. Follicular carcinoma
- 19. Secondary hyperparathyroidism secondary to disease elsewhere in the body causes:**
- A. Hypercalcaemia
 B. Hypocalcaemia
 C. Normocalcaemia
 D. Normal parathormone levels
- 20. Islets of Langerhans are concentrated in the pancreas in the following zone:**
- A. Head B. Body
 C. Tail D. Uncinate process
- 21. The following holds true for type 1 diabetes except:**
- A. There is association with HLA-DR 3 and HLA-DR 4
 B. There is autoimmune disease association
 C. There is more than 90% concordance for monozygotic twins to develop diabetes
 D. Viral infection may precede type I diabetes
- 22. The following are correct statements for type 2 diabetes (NIDDM) except:**
- A. It is more common than IDDM
 B. These patients are generally obese
 C. There is role of insulin resistance
 D. There is presence of 'insulinitis'
- 23. The following complication is almost exclusive for type 1 diabetes mellitus (IDDM):**
- A. Hyperosmolar nonketotic coma B. Diabetic ketoacidosis
 C. Atherosclerosis D. Diabetic nephropathy
- 24. Renal glucosuria is characterised by:**
- A. Elevation of fasting blood glucose level
 B. Elevation of blood glucose at 1 hour after meal
 C. Elevation of blood glucose at 2 hours after meal
 D. Normal blood glucose level during entire GTT
- 25. Long-term assessment of diabetes is provided by the following investigation:**
- A. Whole blood glucose estimation
 B. Plasma glucose estimation
 C. Capillary method of glucose estimation
 D. Glycosylated haemoglobin
- 26. Hypoglycaemia (blood glucose 50 mg/dl or lower) is a characteristic finding in:**
- A. Gastrinoma B. Insulinoma
 C. Glucagonoma D. VIPoma
- 27. Lateral aberrant thyroid is the term used for the following:**
- A. Ectopic normal thyroid tissue in lateral cervical region
 B. Abnormal thyroid tissue at unusual site
 C. Metastatic deposits in cervical lymph node from papillary carcinoma thyroid
 D. Metastatic deposits in cervical lymph node from gastric carcinoma
- 28. Following pathologic finding is invariably present in pancreas in type 2 diabetes mellitus:**
- A. Insulinitis B. Depleted islet cell mass
 C. B-cell degranulation D. Amyloidosis of islets

29. Which of the following chromophil cells of the anterior pituitary have acidophilic granules: 691
- A. GH cells
 B. FSH-LH cells
 C. TSH cells
 D. ACTH-MSH cells
30. Sheehan's syndrome is:
- A. Irradiation damage of pituitary gland
 B. Scarred pituitary adenoma
 C. Post partum pituitary necrosis
 D. Surgical removal of pituitary gland
31. Conn's syndrome is:
- A. Chronic hypercortisolism
 B. Adrenogenital syndrome
 C. Secondary hyperaldosteronism
 D. Primary hyperaldosteronism
32. Pick the odd one out:
- A. Papillary thyroid carcinoma – RET gene
 B. Follicular thyroid carcinoma – PAX-8-PPAR γ 1 gene
 C. Medullary thyroid carcinoma – k-ras gene
 D. Anaplastic thyroid carcinoma – p53 gene
33. Amyloidosis is seen in which type of diabetes:
- A. Type I DM
 B. Type II DM
 C. Gestational diabetes
 D. MODY

KEY

- | | | | |
|--------|--------|--------|--------|
| 1 = B | 2 = C | 3 = B | 4 = B |
| 5 = D | 6 = B | 7 = C | 8 = C |
| 9 = D | 10 = A | 11 = B | 12 = A |
| 13 = D | 14 = A | 15 = C | 16 = C |
| 17 = C | 18 = C | 19 = B | 20 = C |
| 21 = C | 22 = D | 23 = B | 24 = D |
| 25 = D | 26 = B | 27 = C | 28 = D |
| 29 = A | 30 = C | 31 = D | 32 = C |
| 33 = B | | | |



The Musculoskeletal System

□ NORMAL STRUCTURE OF BONE (p. 830)

Bone is divided into 2 components (**Web Image 28.1**):

◆ **Cortical or compact bone** comprises 80% of the skeleton and is the dense outer shell responsible for structural rigidity. It consists of haversian canals with blood vessels surrounded by concentric layers of mineralised collagen forming osteons which are joined together by cement lines.

◆ **Trabecular or cancellous bone** composes 20% of the skeleton and has trabeculae traversing the marrow space. Its main role is in mineral homeostasis.

HISTOLOGY. Bone consists of large quantities of extracellular matrix which is loaded with calcium hydroxyapatite and relatively small number of bone cells which are of 3 main types besides the ground substance, the osteoid matrix.

1. Osteoblasts. Osteoblasts are uninucleate cells found abundantly along the new bone-forming surfaces. They synthesise bone matrix. The serum levels of bone-related *alkaline phosphatase* is a marker for osteoblastic activity. Its levels are raised in puberty during period of active bone growth and in pathologic conditions associated with high osteoblastic activity such as in fracture repair and Paget's disease of the bone.

2. Osteocytes. Osteocytes are those osteoblasts which get incorporated into the bone matrix during its synthesis. Osteocytes are found within small spaces called lacunae lying in the bone matrix. The distribution of the osteocytic lacunae is a reliable parameter for distinguishing between woven and lamellar bone.

◆ *Woven bone* is immature and is rapidly deposited. It contains large number of closely-packed osteocytes and consists of irregular interlacing pattern of collagen fibre bundles in bone matrix.

◆ *Lamellar bone* differs from woven bone in having smaller and less numerous osteocytes and fine and parallel or lamellar sheets of collagen fibres. Lamellar bone usually replaces woven bone or pre-existing cartilage.

3. Osteoclasts. Osteoclasts are large multinucleate cells of mononuclear-macrophage origin and are responsible for bone resorption. The osteoclastic activity is determined by bone-related serum *acid phosphatase* levels.

4. Osteoid matrix. The osteoid matrix of bone consists of 90-95% of collagen type I and comprises nearly half of total body's collagen. Virtually whole of body's hydroxyproline and hydroxylysine reside in the bone.

BONE FORMATION AND RESORPTION. Bone is not a static tissue but its formation and resorption are taking place during period of growth as well as in adult life. Bone deposition is the result of osteoblasts while bone resorption is the function of osteoclasts. Bone formation may take place directly from collagen called *membranous ossification* seen in certain flat bones, or may occur through an intermediate stage of cartilage termed *endochondral ossification* found in metaphysis of long bones. In either case, firstly an uncalcified osteoid matrix is formed by osteoblasts which is then mineralised in 12-15 days.

□ NORMAL STRUCTURE OF CARTILAGE (p. 831)

Unlike bone, the cartilage lacks blood vessels, lymphatics and nerves. It may have focal areas of calcification. Cartilage consists of 2 components:

Cartilage matrix. Like bone, cartilage too consists of organic and inorganic material. Inorganic material of cartilage is calcium hydroxyapatite similar to that in bone matrix but the organic material of the cartilage is distinct from the bone. It consists of very high content of water (80%) and remaining 20% consists of type II collagen and proteoglycans.

Chondrocytes. Primitive mesenchymal cells which form bone cells form chondroblasts which give rise to chondrocytes. However, calcified cartilage is removed by the osteoclasts.

Depending upon location and structural composition, cartilage is of 3 types:

1. *Hyaline cartilage* is the basic cartilaginous tissue comprising articular cartilage of joints, cartilage in the growth plates of developing bones, costochondral cartilage, cartilage in the trachea, bronchi and larynx and the nasal cartilage. Hyaline cartilage is the type found in most cartilage-forming tumours and in the fracture callus.
2. *Fibrocartilage* is a hyaline cartilage that contains more abundant type II collagen fibres. It is found in annulus fibrosus of intervertebral disc, menisci, insertions of joint capsules, ligament and tendons. Fibrocartilage may also be found in some cartilage-forming tumours and in the fracture callus.
3. *Elastic cartilage* is hyaline cartilage that contains abundant elastin. Elastic cartilage is found in the pinna of ears, epiglottis and arytenoid cartilage of the larynx.

□ OSTEOMYELITIS (p. 831)

An infection of the bone is termed osteomyelitis (myelo = marrow). A number of systemic infectious diseases may spread to the bone such as enteric fever, actinomycosis, mycetoma (madura foot), syphilis, tuberculosis and brucellosis. However, two of the conditions which produce significant pathologic lesions in the bone, are pyogenic osteomyelitis and tuberculous osteomyelitis.

Pyogenic Osteomyelitis (p. 831)

Suppurative osteomyelitis is usually caused by bacterial infection and rarely by fungi. Pyogenic osteomyelitis by haematogenous route occurs most commonly in the long bones of infants and young children (5-15 years of age), particularly in the developing countries of the world. In the developed world, however, where institution of antibiotics is early and prompt, haematogenous spread of infection to the bone is uncommon. In such cases, instead, direct extension of infection from the adjacent area, frequently involving the jaws and skull, is more common mode of spread. Bacterial osteomyelitis may be a complication at all ages in patients with compound fractures, surgical procedures involving prosthesis or implants, gangrene of a limb in diabetics, debilitation and immunosuppression. Though any etiologic agent may cause osteomyelitis, *Staphylococcus aureus* is implicated in a vast majority of cases.

Clinically, the child with acute haematogenous osteomyelitis has painful and tender limb. Fever, malaise and leucocytosis generally accompany the bony lesion. Radiologic examination confirms the bony destruction.

MORPHOLOGIC FEATURES. Depending upon the duration, osteomyelitis may be *acute*, *subacute* or *chronic*. The basic pathologic changes in any stage of osteomyelitis are: suppuration, ischaemic necrosis, healing by fibrosis and bony repair. The **sequence of pathologic changes** is as under (**Web Image 28.2**):

1. The infection begins in the metaphyseal end of the *marrow cavity* which is largely occupied by *pus*. At this stage, microscopy reveals congestion, oedema and an exudate of neutrophils.
2. The tension in the marrow cavity is increased due to pus and results in spread of infection along the marrow cavity, into the endosteum, and into the haversian and Volkmann's canal, causing *periosteitis*.
3. The infection may reach the subperiosteal space forming *subperiosteal abscesses*. It may penetrate through the cortex creating draining skin sinus tracts (**Web Image 28.3**).
4. Combination of suppuration and impaired blood supply to the cortical bone results in erosion, thinning and infarction necrosis of the cortex called *sequestrum*.
5. With passage of time, there is formation of new bone beneath the periosteum present over the infected bone. This forms an encasing sheath around the necrosed bone and is known as *involucrum*.
6. Long continued neo-osteogenesis gives rise to dense sclerotic pattern of osteomyelitis called *chronic sclerosing non-suppurative osteomyelitis of Garré*.
7. Occasionally, acute osteomyelitis may be contained to a localised area and walled off by fibrous tissue and granulation tissue. This is termed *Brodie's abscess*.
8. In *vertebral pyogenic osteomyelitis*, infection begins from the disc (discitis) and spreads to involve the vertebral bodies (**Web Image 28.4,A**).

COMPLICATIONS. These are:

1. Septicaemia.
2. Acute bacterial arthritis.
3. Pathologic fractures.
4. Development of squamous cell carcinoma in long-standing cases.
5. Secondary amyloidosis in long-standing cases.
6. Vertebral osteomyelitis may cause vertebral collapse with paravertebral abscess, epidural abscess, cord compression and neurologic deficits.

Tuberculous Osteomyelitis (p. 833)

Tuberculous osteomyelitis, though rare in developed countries, continues to be a common condition in under-developed and developing countries of the world. The tubercle bacilli, *M. tuberculosis*, reach the bone marrow and synovium most commonly by haematogenous dissemination from infection elsewhere, usually from the lungs, and infrequently by direct extension from the pulmonary or gastrointestinal tuberculosis. Most frequently involved are the spine and bones of extremities.

MORPHOLOGIC FEATURES. The bone lesions in tuberculosis have the same general histological appearance as in tuberculosis elsewhere and consist of central caseation necrosis surrounded by tuberculous granulation tissue and fragments of necrotic bone (**Web Image 28.5**). Tuberculosis of the spine, *Pott's disease*, often commences in the vertebral body and may be associated with compression fractures and destruction of intervertebral discs, producing permanent damage and paraplegia. Extension of caseous material along with pus from the lumbar vertebrae to the sheaths of psoas muscle produces *psoas abscess* or *lumbar cold abscess* (**Web Image 28.4,B**).

□ **AVASCULAR NECROSIS (OSTEONECROSIS)** (p. 833)

Avascular necrosis of the bones or osteonecrosis results from ischaemia. It is a relatively common condition.

ETIOPATHOGENESIS. It includes following:

1. Fracture or dislocation
2. Sickle cell disease

3. Corticosteroid administration
4. Radiation therapy
5. Chronic alcoholism
6. Idiopathic

The pathogenetic mechanism of osteonecrosis in many cases remains obscure, while in others it is by interruption in the blood supply to the bones induced by direct trauma, compression, or thromboembolic obstruction.

MORPHOLOGIC FEATURES. There are pathological fractures of the involved bone due to infarcts. Most common sites are the ones where the disruption in blood supply is at end-arterial circulation.

G/A The lesional area shows a wedge-shaped area of infarction in the subchondral bone under the convex surface of the joint.

M/E The infarcted medulla shows saponified marrow fat. The overlying cartilage and the cortex of the long bones are relatively unaffected.

□ **DISORDERS OF BONE GROWTH AND DEVELOPMENT (SKELETAL DYSPLASIAS)** (p. 834)

A number of abnormalities of the skeleton are due to disordered bone growth and development and are collectively termed *skeletal dysplasias*. These include both local and systemic disorders.

◆ **Local defects** involve a single bone or a group of bones such as: absence or presence in diminished form, fused with neighbouring bones (e.g. syndactyly), and formation of extra bones (e.g. supernumerary ribs).

◆ However, more importantly, skeletal dysplasias include *systemic disorders* involving particular epiphyseal growth plate. These include: achondroplasia (disorder of chondroblasts), osteogenesis imperfecta (disorder of osteoblasts), osteopetrosis (disorder of osteoclasts) and foetal rickets (disorder of mineralisation).

Achondroplasia (p. 834)

Achondroplasia is an autosomal dominant genetic abnormality. There is selective interference with normal endochondral ossification at the level of epiphyseal cartilaginous growth plates of long bones. Thus, the long bones are abnormally short but the skull grows normally leading to relatively large skull. Achondroplasia is the commonest cause of dwarfism.

Osteogenesis Imperfecta (p. 834)

Osteogenesis imperfecta is an autosomal dominant or recessive disorder of synthesis of type I collagen that constitutes 90-95% of bone matrix. The disorder, thus, involves not only the skeleton but other extra-skeletal tissues as well containing type I collagen such as sclera, eyes, joints, ligaments, teeth and skin. The skeletal manifestations of osteogenesis imperfecta are due to defective osteoblasts which normally synthesise type I collagen. This results in thin or non-existent cortices and irregular trabeculae (*too little bone*) so that the bones are very fragile and liable to multiple fractures. Extraskelatal lesions of osteogenesis imperfecta include blue and translucent sclerae, hearing loss due to bony abnormalities of the middle and inner ear, and imperfect teeth.

Osteopetrosis (p. 834)

Osteopetrosis, also called *marble bone disease*, is an autosomal dominant or recessive disorder of increased skeletal mass or osteosclerosis caused by a hereditary defect in osteoclast function. The condition may appear in 2 forms: autosomal recessive (malignant infantile form) and autosomal dominant (benign adult form). Failure of normal osteoclast function of bone resorption coupled with continued bone formation and endochondral ossification results in net overgrowth of calcified dense bone (*too much bone*)

696 which occupies most of the available marrow space. Despite increased density of the bone, there is poor structural support so that the skeleton is susceptible to fractures.

□ **METABOLIC AND ENDOCRINE BONE DISEASES** (p. 834)

A large number of metabolic and endocrine disorders produce generalised skeletal disorders. These include the following:

1. **Osteoporosis**—Resulting from quantitative reduction in otherwise normal bone.
2. **Osteomalacia and rickets**—Characterised by qualitative abnormality in the form of impaired bone mineralisation due to deficiency of vitamin D in adults and children respectively.
3. **Scurvy**—Caused by deficiency of vitamin C resulting in subperiosteal haemorrhages.
4. **Hyperparathyroidism**—Leading to osteitis fibrosa cystica .
5. **Pituitary dysfunctions**—Hyperpituitarism causing gigantism and acromegaly and hypopituitarism resulting in dwarfism.
6. **Thyroid dysfunctions**—Hyperthyroidism causing osteoporosis and hypothyroidism leading to cretinism.
7. **Renal osteodystrophy**—Occurring in chronic renal failure and resulting in features of osteitis fibrosa cystica, osteomalacia and areas of osteosclerosis.
8. **Skeletal fluorosis**—Occurring due to excess of sodium fluoride content in the soil and water in an area.

Osteoporosis (p. 835)

Osteoporosis or osteopenia is a common clinical syndrome involving multiple bones in which there is quantitative reduction of bone tissue mass but the bone tissue mass is otherwise normal. This reduction in bone mass results in fragile skeleton which is associated with increased risk of fractures and consequent pain and deformity. The conditions is particularly common in elderly people and more frequent in postmenopausal women. Radiologic evidence becomes apparent only after more than 30% of bone mass has been lost. Levels of serum calcium, inorganic phosphorus and alkaline phosphatase are usually within normal limits.

PATHOGENESIS. Osteoporosis is conventionally classified into 2 major groups:

◆ **Primary osteoporosis** results primarily from osteopenia without an underlying disease or medication. Primary osteoporosis is further subdivided into 2 types: *idiopathic type* found in the young and juveniles and is less frequent, and *involutional type* seen in postmenopausal women and aging individuals and is more common. A number of risk factors have been attributed to cause this imbalance between bone resorption and bone formation.

1. *Genetic factors*—more marked in whites and Asians than blacks.
2. *Sex*—more frequent in females than in males.
3. *Reduced physical activity*—as in old age.
4. *Deficiency of sex hormones*—oestrogen deficiency in women as in postmenopausal osteoporosis and androgen deficiency in men.
5. *Combined deficiency of calcitonin and oestrogen.*
6. *Hyperparathyroidism.*
7. *Deficiency of vitamin D.*
8. *Local factors*—which may stimulate osteoclastic resorption or slow osteoblastic bone formation.

◆ **Secondary osteoporosis** is attributed to a number of factors and conditions (e.g. immobilisation, chronic anaemia, acromegaly, hepatic disease, hyperparathyroidism, hypogonadism, thyrotoxicosis and starvation), or as an effect of medication (e.g. hypercortisonism, administration of anticonvulsant drugs and large dose of heparin).

MORPHOLOGIC FEATURES. Except disuse or immobilisation osteoporosis which is localised to the affected limb, other forms of osteoporosis have systemic skeletal distribution. Most commonly encountered osteoporotic fractures are: vertebral crush fracture, femoral neck fracture and wrist fracture. There is enlargement of the medullary cavity and thinning of the cortex.

M/E The features are as under:

◆ **Active osteoporosis** is characterised by increased bone resorption and formation i.e. *accelerated turnover*.

◆ **Inactive osteoporosis** has the features of minimal bone formation and reduced resorptive activity i.e. *reduced turnover*.

Osteitis Fibrosa Cystica (p. 835)

Hyperparathyroidism of primary or secondary type results in oversecretion of parathyroid hormone which causes increased osteoclastic resorption of the bone. Severe and prolonged hyperparathyroidism results in osteitis fibrosa cystica. The lesion is generally induced as a manifestation of primary hyperparathyroidism, and less frequently, as a result of secondary hyperparathyroidism such as in chronic renal failure (renal osteodystrophy).

The clinical manifestations of bone disease in hyperparathyroidism are its susceptibility to fracture, skeletal deformities, joint pains and dysfunctions as a result of deranged weight bearing. The bony changes may disappear after cure of primary hyperparathyroidism such as removal of functioning adenoma. The chief biochemical abnormality of excessive parathyroid hormone is hypercalcaemia, hypophosphataemia and hypercalciuria.

G/A There are focal areas of erosion of cortical bone and loss of lamina dura at the roots of teeth.

M/E The features are as under:

◆ Earliest change is *demineralisation* and *increased bone resorption* beginning at the subperiosteal and endosteal surface of the cortex.

◆ There is replacement of bone and bone marrow by fibrosis coupled with increased number of bizarre osteoclasts at the surfaces of moth-eaten trabeculae and cortex (*osteitis fibrosa*).

◆ As a result of increased resorption, microfractures and microhaemorrhages occur in the marrow cavity leading to development of cysts (*osteitis fibrosa cystica*).

◆ Haemosiderin-laden macrophages and multinucleate giant cells appear at the areas of haemorrhages producing an appearance termed as '*brown tumour*' or '*reparative giant cell granuloma of hyperparathyroidism*'.

Renal Osteodystrophy (Metabolic Bone Disease) (p. 836)

Renal osteodystrophy is a loosely used term that encompasses a number of skeletal abnormalities appearing in cases of chronic renal failure and in patients treated by dialysis for several years. Renal osteodystrophy is more common in children than in adults.

The mechanisms underlying renal osteodystrophy are schematically illustrated in **Web Image 28.6** and briefly outlined below:

1. **Hyperphosphataemia:** In CRF, there is impaired renal excretion of phosphate, causing phosphate retention and hyperphosphataemia. Hyperphosphataemia, in turn, causes hypocalcaemia which is responsible for secondary hyperparathyroidism.

2. **Hypocalcaemia:** Hypocalcaemia may also result from the following:

- ◆ Due to renal dysfunction, there is decreased conversion of vitamin D metabolite 25(OH) cholecalciferol to its active form 1,25 (OH)₂ cholecalciferol.
- ◆ Reduced intestinal absorption of calcium.

3. Parathormone secretion: Hypocalcaemia stimulates secretion of parathormone, eventually leading to secondary hyperparathyroidism.

4. Metabolic acidosis: As a result of decreased renal function, acidosis sets in which may cause osteoporosis and bone decalcification.

5. Calcium phosphorus product > 70: When the product of biochemical value of calcium and phosphate is higher than 70, metastatic calcification may occur at extraosseous sites.

6. Dialysis-related metabolic bone disease: Long-term dialysis employing use of aluminium-containing dialysate is currently considered to be a major cause of metabolic bone lesions.

M/E The features are as under:

1. *Mixed osteomalacia-osteitis fibrosa* is the most common manifestation of renal osteodystrophy resulting from disordered vitamin D metabolism and secondary hyperparathyroidism.
2. *Pure osteitis fibrosa* results from metabolic complications of secondary hyperparathyroidism.
3. *Pure osteomalacia* of renal osteodystrophy is attributed to aluminium toxicity.
4. *Renal rickets* resembling the changes seen in children with nutritional rickets with widened osteoid seams may occur.
5. *Osteosclerosis* is characterised by enhanced bone density in the upper and lower margins of vertebrae.
6. *Metastatic calcification* is seen at extraosseous sites such as in medium-sized blood vessels, periarticular tissues, myocardium, eyes, lungs and gastric mucosa.

Skeletal Fluorosis (p. 837)

Fluorosis of bones occurs due to high sodium fluoride content in soil and water consumed by people in some geographic areas and is termed endemic fluorosis. Such endemic regions exist in some tropical and subtropical areas; in India it exists in parts of Punjab and Andhra Pradesh. The condition affects farmers who consume drinking water from wells. Non-endemic fluorosis results from occupational exposure in manufacturing industries of aluminium, magnesium, and superphosphate.

PATHOGENESIS. In fluorosis, fluoride replaces calcium as the mineral in the bone and gets deposited without any regulatory control. This results in heavily mineralised bones which are thicker and denser but are otherwise weak and deformed (just as in osteopetrosis). In addition, there are also deposits of fluoride in soft tissues, particularly as nodules in the interosseous membrane.

G/A The long bones and vertebrae develop nodular swellings which are present both inside the bones and on the surface.

M/E These nodules are composed of heavily mineralised irregular osteoid admixed with fluoride which requires confirmation chemically.

□ PAGET'S DISEASE OF BONE (OSTEITIS DEFORMANS) (p. 834)

Paget's disease of bone* or osteitis deformans was first described by Sir James Paget in 1877. Paget's disease of bone is an osteolytic and osteosclerotic bone disease of uncertain etiology involving one (monostotic)

*It is pertinent to recall here that James Paget described Paget's disease at three different anatomic sites which are not mutually interlinked in any way: Paget's disease of nipple (page 764), Paget's disease of vulva (page 722) and Paget's disease of bone.

or more bones (polyostotic). The condition affects predominantly males over the age of 50 years. Though the etiology remains obscure, following factors have been implicated:

1. There has been some evidence that osteitis deformans is a form of *slow-virus infection* by paramyxovirus (e.g. respiratory syncytial virus, measles) in osteoclasts.
2. Autosomal dominant inheritance and *genetic susceptibility* have been proposed on the basis of observation of 7-10 fold higher prevalence of disease in first-degree relatives. The susceptibility gene located on chromosome 18q encodes for a member of tumour necrosis factor called RANK (receptor activator of nuclear factor: κ B).

Clinically, the *monostotic form* of the disease may remain asymptomatic and the lesion is discovered incidentally or on radiologic examination. *Polyostotic form*, however, is more widespread and may produce pain, fractures, skeletal deformities, and occasionally, sarcomatous transformation.

M/E Three sequential stages are identified in Paget's disease:

1. **Initial osteolytic stage:** This stage is characterised by areas of osteoclastic resorption produced by increased number of large osteoclasts.
2. **Mixed osteolytic-osteoblastic stage:** In this stage, there is imbalance between osteoblastic laying down of new bone and osteoclastic resorption so that mineralisation of the newly-laid matrix lags behind, resulting in development of characteristic *mosaic pattern* or *jigsaw puzzle appearance* of osteoid seams or cement lines.
3. **Quiescent osteosclerotic stage:** After many years, excessive bone formation results so that the bone becomes more compact and dense producing osteosclerosis.

□ TUMOUR-LIKE LESIONS OF BONE (p. 837)

Web Table 28.1 gives a list of such tumour-like lesions.

Fibrous Dysplasia (p. 837)

Fibrous dysplasia is not an uncommon tumour-like lesion of the bone. It is a benign condition, possibly of developmental origin, characterised by the presence of localised area of replacement of bone by fibrous connective tissue with a characteristic whorled pattern and containing trabeculae of woven bone. Radiologically, the typical focus of fibrous dysplasia has well-demarcated ground-glass appearance.

Three types of fibrous dysplasia are distinguished—

◆ **Monostotic fibrous dysplasia.** Monostotic fibrous dysplasia affects a solitary bone and is the most common type, comprising about 70% of all cases. The condition affects either sex and most patients are between 20 and 30 years of age. The bones most often affected, in descending order of frequency, are: ribs, craniofacial bones (especially maxilla), femur, tibia and humerus.

◆ **Polyostotic fibrous dysplasia.** Polyostotic form of fibrous dysplasia affecting several bones constitutes about 25% of all cases. Both sexes are affected equally but the lesions appear at a relatively earlier age than the monostotic form. Most frequently affected bones are: craniofacial, ribs, vertebrae and long bones of the limbs.

◆ **Albright syndrome.** Also called McCune-Albright syndrome, this is a form of polyostotic fibrous dysplasia associated with endocrine dysfunctions and accounts for less than 5% of all cases. The syndrome is characterised by polyostotic bone lesions, skin pigmentation (*cafe-au-lait* macular spots) and sexual precocity, and infrequently other endocrinopathies.

G/A The lesions appear as sharply-demarcated, localised defects measuring 2-5 cm in diameter, present within the cancellous bone, having thin and

700 smooth overlying cortex. The epiphyseal cartilages are generally spared in the monostotic form but involved in the polyostotic form of disease.

M/E The lesions of fibrous dysplasia have characteristic benign-looking fibroblastic tissue arranged in a loose, whorled pattern in which there are irregular and curved trabeculae of woven (non-lamellar) bone in the form fish-hook appearance or Chinese letter shapes. Characteristically, there are no osteoblasts rimming then trabeculae of the bone, suggesting a maturation defect in the bone (**Web Image 28.7**).

Fibrous Cortical Defect (Metaphyseal Fibrous Defect, Non-ossifying Fibroma) (p. 838)

Fibrous cortical defect or metaphyseal fibrous defect is a rather common benign tumour-like lesion occurring in the metaphyseal cortex of long bones in children. Most commonly involved bones are upper or lower end of tibia or lower end of femur. The lesion is generally solitary but rarely there may be multiple and bilaterally symmetrical defects. Radiologically, the lesion is eccentrically located in the metaphysis and has a sharply-delimited border. The pathogenesis of fibrous cortical defect is unknown.

G/A The lesion is generally small, less than 4 cm in diameter, granular and brown. Larger lesion (5-10 cm) occurring usually in response to trauma is referred to as *non-ossifying fibroma*.

M/E Fibrous cortical defect consists of cellular masses of fibrous tissue showing storiform pattern. There are numerous multinucleate osteoclast-like giant cells, haemosiderin-laden macrophages and foamy cells; hence the lesion is also termed histiocytic xanthogranuloma or fibrous xanthoma of bone.

Solitary (Simple, Unicameral) Bone Cyst (p. 839)

Solitary, simple or unicameral bone cyst is a benign condition occurring in children and adolescents, most frequently located in the metaphyses at the upper end of humerus and femur. The cyst expands the bone causing thinning of the overlying cortex.

G/A Simple cyst of the bone is generally unilocular with smooth inner surface. The cavity is filled with clear fluid.

M/E The cyst wall consists of thin collagenous tissue having scattered osteoclast giant cells and newly formed reactive bony trabeculae. Fracture alters the appearance and produces sanguineous fluid in the cavity, and haemorrhages, haemosiderin deposits and macrophages in the cyst wall.

Aneurysmal Bone Cyst (p. 840)

Aneurysmal bone cyst, true to its name, is an expanding osteolytic lesion filled with blood (*aneurysm* = dilatation, distension). The condition is seen more commonly in young patients under 30 years of age. Most frequently involved bones are shafts of metaphyses of long bones or the vertebral column. The radiographic appearance shows characteristic ballooned-out expansile lesion underneath the periosteum.

G/A the lesion consists of a large haemorrhagic mass covered over by thinned out reactive bone (**Web Image 28.8**).

M/E The cyst consists of blood-filled aneurysmal spaces of variable size, some of which are endothelium-lined. The spaces are separated by connective tissue septa containing osteoid tissue, numerous osteoclast-like multinucleate giant cells and trabeculae of bone (**Web Image 28.9**).

□ BONE TUMOURS (p. 840)

Bone tumours may be primary or metastatic. Since histogenesis of some bone tumours is obscure, the WHO has recommended a widely accepted classification of primary bone tumours based on both histogenesis and histologic criteria. **Web Table 28.2** lists the various types of bone tumours arising from different tissue components—osseous and non-osseous, indigenous to the bone. The anatomic origin of common primary bone tumours is illustrated in **Web Image 28.10**.

It may be mentioned here that the diagnosis of any bone lesion is established by a combination of clinical, radiological and pathological examination, supplemented by biochemical and haematological investigations wherever necessary. These include: serum levels of calcium, phosphorus, alkaline phosphatase and acid phosphatase. Specific investigations like plasma and urinary proteins and the bone marrow examination in case of myeloma, urinary catecholamines in metastatic neuroblastoma and haematologic profile in lymphoma and leukaemic involvement of the bone, are of considerable help.

BONE-FORMING (OSTEOBLASTIC) TUMOURS (p. 840)

Bone-forming or osteoblastic group of bone tumours are characterised by the common property of synthesis of osteoid or bone, or both, directly by the tumour cells (osteogenesis).

Osteoma (p. 841)

An osteoma is a rare benign, slow-growing lesion, regarded by some as a hamartoma rather than a true neoplasm. Osteoma is almost exclusively restricted to flat bones of the skull and face. It may grow into paranasal sinuses or protrude into the orbit.

M/E The lesion is composed of well-differentiated mature lamellar bony trabeculae separated by fibrovascular tissue.

Osteoid Osteoma and Osteoblastoma (p. 841)

Osteoid osteoma and osteoblastoma (or giant osteoid osteoma) are closely related benign tumours occurring in children and young adults. Osteoid osteoma is more common than osteoblastoma. There are no clear-cut histologic criteria to distinguish the two. The distinction between them is based on clinical features, size and radiographic appearance.

◆ **Osteoid osteoma** is small (usually less than 1 cm) and painful tumour, located in the cortex of a long bone. The tumour is clearly demarcated having surrounding zone of reactive bone formation which radiographically appears as a small radiolucent central focus or nidus surrounded by dense sclerotic bone.

◆ **Osteoblastoma**, on the other hand, is larger in size (usually more than 1 cm), painless, located in the medulla, commonly in the vertebrae, ribs, ilium and long bones, and there is absence of reactive bone formation.

M/E The distinction between osteoid osteoma and osteoblastoma is not obvious. In either case, the lesion consists of trabeculae of osteoid, rimmed by osteoblasts and separated by highly vascularised connective tissue stroma.

Osteosarcoma (p. 841)

Osteosarcoma or osteogenic sarcoma is the most common primary malignant tumour of the bone. The tumour is characterised by *formation of osteoid or bone, or both, directly by sarcoma cells*. The tumour is thought to arise from primitive osteoblast-forming mesenchyme. Depending upon their locations within the bone, osteosarcomas are classified into 2 main categories: central (medullary) and surface (parosteal and periosteal).

702 CENTRAL (MEDULLARY) OSTEOSARCOMA (p. 841)

This is the more common and classic type and is generally referred to as 'osteosarcoma' if not specified. The tumour occurs in young patients between the age of 10 and 20 years. Males are affected more frequently than females. The tumour arises in the metaphysis of long bones. Most common sites, in descending order of frequency, are: the lower end of femur and upper end of tibia (i.e. around knee joint about 60%); the upper end of humerus (10%); pelvis and the upper end of femur (i.e. around hip joint about 15%); and less often in jaw bones, vertebrae and skull.

Based upon the pathogenesis, osteosarcoma is divided into 2 types:

◆ **Primary osteosarcoma** is more common and occurs in the absence of any known underlying disease. Its etiology is unknown but there is evidence linking this form of osteosarcoma with genetic factors (e.g. hereditary mutation of chromosome 13 in common with retinoblastoma locus), period of active bone growth (occurrence of the tumour in younger age), and with certain environmental influences (e.g. radiation, oncogenic virus). Cases of hereditary retinoblastoma have a very high prevalence risk of development of osteosarcoma implicating *RB* gene in their pathogenesis.

◆ **Secondary osteosarcoma**, on the other hand, develops following pre-existing bone disease e.g. Paget's disease of bone, fibrous dysplasia, multiple osteochondromas, chronic osteomyelitis, infarcts and fractures of bone.

Medullary osteosarcoma is a highly malignant tumour. The tumour arises centrally in the metaphysis, extends longitudinally for variable distance into the medullary cavity, expands laterally on either side breaking through the cortex and lifting the periosteum. If the periosteum is breached, the tumour grows relentlessly into the surrounding soft tissues. The only tissue which is able to stop its spread, *albeit* temporarily, is the cartilage of epiphyseal plate. The radiographic appearance is quite distinctive: characteristic '*sunburst pattern*' due to osteogenesis within the tumour and presence of *Codman's triangle* formed at the angle between the elevated periosteum and underlying surface of the cortex.

G/A The tumour appears as a grey-white, bulky mass at the metaphyseal end of a long bone of the extremity. The articular end of the bone is generally uninvolved in initial stage. Codman's triangle, though identified radiologically, may be obvious on macroscopic examination (**Web Image 28.11**). Cut surface of the tumour is grey-white with areas of haemorrhages and necrotic bone.

M/E Osteosarcoma shows considerable variation in pattern from case-to-case and even within a tumour from one area to the other. However, the following two features characterise all classic forms of osteosarcomas (**Web Image 28.12**):

1. Sarcoma cells. The tumour cells of osteosarcomas are undifferentiated mesenchymal stromal cells which show marked pleomorphism and polymorphism i.e. variation in size as well as shape. The tumour cells may have various shapes such as spindle, round, oval and polygonal and bizarre tumour giant cells. The tumour cells have variable size and show hyperchromatism and atypical mitoses.

2. Osteogenesis. The anaplastic sarcoma cells form osteoid matrix and bone directly; this is found interspersed in the areas of tumour cells. In addition to osteoid and bone, the tumour cells may produce cartilage, fibrous tissue or myxoid tissue.

A few histologic variants of the usual osteosarcoma have been described as under:

◆ **Telangiectatic osteosarcoma.** The tumour in this variant presents with pathological fractures. The tumour has large, cavernous, dilated vascular channels. This variant has a more aggressive course.

- ◆ **Small cell osteosarcoma.** This variant has small, uniform tumour cells just like the tumour cells of Ewing's sarcoma or lymphoma but osteogenesis by these tumour cells is the distinguishing feature.
- ◆ **Fibrohistiocytic osteosarcoma.** This variant resembles malignant fibrous histiocytoma but having osteogenesis by the tumour cells.
- ◆ **Anaplastic osteosarcoma.** In this variant, the tumour has so marked anaplasia that it may resemble any other type of pleomorphic sarcoma and is identified by the presence of osteoid formed directly by the tumour cells.
- ◆ **Well-differentiated osteosarcoma.** Rarely a well-differentiated variant having minimal cytologic atypia resembling parosteal osteosarcoma may be seen.

SURFACE OSTEOSARCOMA

About 5% of osteosarcomas occur on the surface of bone and are slow-growing tumours compared to medullary osteosarcomas. Surface osteosarcoma includes 2 variants:

Parosteal or juxtacortical osteosarcoma is an uncommon form of osteosarcoma having its origin from the metaphysis on the external surface of the bone (*parosteal* or *juxtacortical* means outer to cortex). The tumour should be distinguished from the more common medullary osteosarcoma because of its better prognosis and different presentation. The tumour occurs in older age group, has no sex predilection and is slow growing.

G/A The tumour is lobulated and circumscribed, calcified mass in the subperiosteal location.

M/E The features which characterise the usual osteosarcoma (sarcomatous stroma and production of neoplastic osteoid and bone) are present, but the tumour shows a high degree of structural differentiation, and there are generally well-formed bony trabeculae.

Periosteal osteosarcoma is a rare form of osteosarcoma that arises between the cortex and the overlying periosteum. Its common location is the diaphysis of the tibia or the femur.

M/E Periosteal osteosarcoma has cartilaginous differentiation and higher degree of anaplasia than that seen in parosteal osteosarcoma.

Web Table 28.3 sums up the contrasting features of central (medullary) and surface (parosteal and periosteal) osteosarcomas.

CARTILAGE-FORMING (CHONDROBLASTIC) TUMOURS (p. 843)

The tumours which are composed of frank cartilage or derived from cartilage-forming cells are included in this group.

Osteocartilaginous Exostoses (Osteochondromas) (p. 843)

Osteocartilaginous exostoses or osteochondromas are the commonest of benign cartilage-forming lesions. It may occur as a '*solitary sporadic exostosis*' or there may be '*multiple hereditary exostoses*'.

Exostoses arise from metaphyses of long bones as exophytic lesions, most commonly lower femur and upper tibia (i.e. around knee) and upper humerus but may also be found in other bones such as the scapula or ilium.

G/A Osteochondromas have a broad or narrow base (i.e. may be either sessile or pedunculated) which is continuous with the cortical bone. They protrude exophytically as mushroom-shaped, cartilage-capped lesions enclosing well-formed cortical bone and marrow (**Web Image 28.13**).

M/E They are composed of outer cap composed of mature cartilage resembling epiphyseal cartilage and the inner mature lamellar bone and bone marrow (**Web Image 28.14**).

704 Enchondroma (p. 844)

Enchondroma is the term used for the benign cartilage-forming tumour that develops centrally within the interior of the affected bone, while chondroma refers to the peripheral development of lesion similar to osteochondromas.

Most common locations for enchondromas are short tubular bones of the hands and feet, and less commonly, they involve the ribs or the long bones. Malignant transformation of solitary enchondroma is rare but multiple enchondromas may develop into chondrosarcoma.

G/A The enchondroma is lobulated, bluish-grey, translucent, cartilaginous mass lying within the medullary cavity.

M/E The tumour has characteristic lobulated appearance. The lobules are composed of normal adult hyaline cartilage separated by vascularised fibrous stroma. Foci of calcification may be evident within the tumour. Enchondroma is distinguished from chondrosarcoma by the absence of invasion into surrounding tissues and lack of cytologic features of malignancy.

Chondroblastoma (p. 845)

Chondroblastoma is a relatively rare benign tumour arising from the epiphysis of long bones adjacent to the epiphyseal cartilage plate. Most commonly affected bones are upper tibia and lower femur (i.e. about knee) and upper humerus. The tumour usually occurs in patients under 20 years of age with male preponderance (male-female ratio 2:1). The behaviour of the tumour is benign though it may recur locally after curettage.

G/A Chondroblastoma is a well-defined mass, up to 5 cm in diameter, lying in the epiphysis. The tumour is surrounded by thin capsule of dense sclerotic bone. Cut surface reveals a soft chondroid tumour with foci of haemorrhages, necrosis and calcification.

M/E The tumour is highly cellular and is composed of small, round to polygonal mononuclear cells resembling chondroblasts and has multinucleate osteoclast-like giant cells. There are small areas of cartilaginous intercellular matrix and focal calcification.

Chondromyxoid Fibroma (p. 845)

Chondromyxoid fibroma is an uncommon benign tumour of cartilaginous origin arising in the metaphysis of long bones. Most common locations are upper end of tibia and lower end of femur i.e. around the knee joint. Majority of tumours appear in 2nd to 3rd decades of life with male preponderance. Radiologically, the tumour appears as a sharply-outlined radiolucent area with foci of calcification and expansion of affected end of the bone.

G/A Chondromyxoid fibroma is sharply-demarcated, grey-white lobulated mass, not exceeding 5 cm in diameter, lying in the metaphysis. The tumour is often surrounded by a layer of dense sclerotic bone. Cut surface of the tumour is soft to firm and lobulated.

M/E The tumour has essentially lobulated pattern. The lobules are separated by fibrous tissue and variable number of osteoclast-like giant cells. The lobules themselves are composed of immature cartilage consisting of spindle-shaped or stellate cells with abundant myxoid or chondroid intercellular matrix.

Chondrosarcoma (p. 845)

Chondrosarcoma is a malignant tumour of chondroblasts. In frequency, it is next in frequency to osteosarcoma but is relatively slow-growing and thus has a much better prognosis than that of osteosarcoma. Two types of chondrosarcoma are distinguished:

◆ **Central chondrosarcoma** is more common and arises within the medullary cavity of diaphysis or metaphysis. This type of chondrosarcoma is generally primary i.e. occurs *de novo*.

◆ **Peripheral chondrosarcoma** arises in the cortex or periosteum of metaphysis. It may be primary or secondary occurring on a pre-existing benign cartilaginous tumour such as osteochondromatous exostoses (osteochondromas), multiple enchondromatosis, and rarely, chondroblastoma.

Both forms of chondrosarcoma usually occur in patients between 3rd and 6th decades of life with slight male preponderance. In contrast to benign cartilaginous tumours, majority of chondrosarcomas are found more often in the central skeleton (i.e. in the pelvis, ribs and shoulders). Radiologic appearance is of hugely expansile and osteolytic growth with foci of calcification. Clinically, the tumour is slow-growing and comes to attention because of pain and gradual enlargement over the years.

G/A Chondrosarcoma may vary in size from a few centimeters to extremely large and lobulated masses of firm consistency. Cut section of the tumour shows translucent, bluish-white, gelatinous or myxoid appearance with foci of ossification (**Web Image 28.15**).

M/E The two hallmarks of chondrosarcoma are: invasive character and formation of lobules of anaplastic cartilage cells. These tumour cells show cytologic features of malignancy such as hyperchromatism, pleomorphism, two or more cells in the lacunae and tumour giant cells (**Web Image 28.16**).

GIANT CELL TUMOUR (OSTEOCLASTOMA) (p. 846)

Giant cell tumour or osteoclastoma is a distinctive neoplasm with uncertain histogenesis and hence classified separately. The tumour arises in the epiphysis of long bones close to the articular cartilage. Most common sites of involvement are lower end of femur and upper end of tibia (i.e. about the knee), lower end of radius and upper end of fibula. Giant cell tumour occurs in patients between 20 and 40 years of age with no sex predilection. Radiologically, giant cell tumour appears as a large, lobulated and osteolytic lesion at the end of an expanded long bone with characteristic 'soap bubble' appearance.

G/A Giant cell tumour is eccentrically located in the epiphyseal end of a long bone which is expanded. The tumour is well-circumscribed, dark-tan and covered by a thin shell of subperiosteal bone. Cut surface of the tumour is characteristically haemorrhagic, necrotic, and honey-combed due to focal areas of cystic degeneration (**Web Image 28.17**).

M/E The hallmark features of giant cell tumour are the presence of large number of multinucleate osteoclast-like giant cells regularly scattered throughout the stromal mononuclear cells (**Web Image 28.18**):

◆ **Giant cells** often contain as many as 100 benign nuclei and have many similarities to normal osteoclasts. These cells have very high acid phosphatase activity.

◆ **Stromal cells** are mononuclear cells and are the real tumour cells and their histologic appearance determines the biologic behaviour of the tumour. Typically, they are uniform, plump, spindle-shaped or round to oval cells with numerous mitotic figures.

◆ **Other features** of the stroma include its scanty collagen content, rich vascularity, areas of haemorrhages and presence of macrophages.

Giant cell tumour of bone has certain peculiarities which deserve further elaboration.

CELL OF ORIGIN. Though designated as giant cell tumour or osteoclastoma, the true tumour cells are round to spindle-shaped mononuclear cells and not osteoclast-like giant cells. Histogenesis of tumour cells is uncertain but possibly they are of mesenchymal origin.

706 OTHER GIANT CELL LESIONS. This peculiar tumour with above description is named 'giant cell tumour' but giant cells are present in several other benign tumours and tumour-like lesions from which the giant cell tumour is to be distinguished. These *benign giant cell lesions* are: chondroblastoma, brown tumour of hyperparathyroidism, reparative giant cell granuloma, aneurysmal bone cyst, simple bone cyst and metaphyseal fibrous defect (non-ossifying fibroma).

BIOLOGIC BEHAVIOUR. Giant cell tumours are best described as aggressive lesions or low grade malignant tumour. About 40 to 60% of them recur after curettage, sometimes after a few decades of initial resection. Approximately 4% cases result in distant metastases, mainly to lungs. Metastases are histologically benign and there is usually history of repeated curettages and recurrences.

EWING'S SARCOMA AND PRIMITIVE NEUROECTODERMAL TUMOUR (ES/PNET) (p. 848)

Ewing's sarcoma (ES) is a highly malignant small round cell tumour occurring in patients between the age of 5 and 20 years with predilection for occurrence in females. At different times, the possibilities suggested for the cell of origin have been endothelial, pericytic, bone marrow, osteoblastic, and mesenchymal; currently it is settled for origin from primitive neuroectodermal cells. Now, Ewing's sarcoma includes 3 variants:

- i) classic (skeletal) Ewing's sarcoma;
- ii) soft tissue Ewing's sarcoma; and
- iii) primitive neuroectodermal tumour (PNET).

The three are linked together by a common neuroectodermal origin and by a common cytogenetic translocation abnormality t(11; 22) (q24; q12). This suggests a phenotypic spectrum in these conditions varying from undifferentiated Ewing's sarcoma to PNET positive for rosettes and neural markers (neuron-specific enolase, S-100). However, PNET ultimately has a worse prognosis.

The skeletal Ewing's sarcoma arises in the medullary canal of diaphysis or metaphysis. The common sites are shafts and metaphysis of long bones, particularly femur, tibia, humerus and fibula, although some flat bones such as pelvis and scapula may also be involved.

Clinical features include pain, tenderness and swelling of the affected area accompanied by fever, leucocytosis and elevated ESR. These signs and symptoms may lead to an erroneous clinical diagnosis of osteomyelitis. However, X-ray examination reveals a predominantly osteolytic lesion with patchy subperiosteal reactive bone formation producing characteristic '*onion-skin*' radiographic appearance.

G/A Ewing's sarcoma is typically located in the medullary cavity and produces expansion of the affected diaphysis (shaft) or metaphysis, often extending into the adjacent soft tissues (**Web Image 28.19**).

M/E Ewing's tumour is a member of *small round cell tumours* which includes other tumours such as: PNET, neuroblastoma, embryonal rhabdomyosarcoma, lymphoma-leukaemias, and metastatic small cell carcinoma. Ewing's tumour shows the following histologic characteristics (**Web Image 28.20**):

1. Pattern. The tumour is divided by fibrous septa into irregular lobules of closely-packed tumour cells. These tumour cells are characteristically arranged around capillaries forming *pseudorosettes*.

2. Tumour cells. The individual tumour cells comprising the lobules are small and uniform resembling lymphocytes and have ill-defined cytoplasmic outlines, scanty cytoplasm and round nuclei having 'salt and pepper' chromatin and frequent mitoses. Based on these cytological features the tumour is also called *round cell tumour* or *small blue cell tumour*. The

cytoplasm contains glycogen that stains with periodic acid-Schiff (PAS) reaction. The consistently expressed cell surface marker by tumour cells of ES/PNET group is CD99 which is a product of *MIC-2* gene located on X and Y chromosome.

3. Other features. The tumour is richly vascularised and lacks the intercellular network of reticulin fibres. There may be areas of necrosis and acute inflammatory cell infiltration.

Ewing's sarcoma metastasises early by haematogenous route to the lungs, liver, other bones and brain. But currently, use of combined regimen consisting of radiotherapy and systemic chemotherapy has improved the outcome greatly (5-year survival rate 40-80%).

CHORDOMA (p. 849)

Chordoma is a slow-growing malignant tumour arising from remnants of notochord. Notochord is the primitive axial skeleton which subsequently develops into the spine. Normally, remnants of notochord are represented by notochordal or physaliphorous (*physalis* = bubble, *phorous* = bearing) cells present in the nucleus pulposus and a few clumps within the vertebral bodies. Chordomas thus occur in the axial skeleton, particularly sacral and spheno-occipital region, and infrequently in the vertebrae. Chordoma is usually found in patients over the age of 40 years with no sex predilection. Radiographically, the tumour usually appears as an osteolytic lesion.

G/A The tumour is soft, lobulated, translucent and gelatinous with areas of haemorrhages.

M/E Chordoma is composed of highly vacuolated physaliphorous cells surrounded by a sea of intercellular mucoid material (**Web Image 28.21**).

METASTATIC BONE TUMOURS (p. 850)

Metastases to the skeleton are more frequent than the primary bone tumours. Metastatic bone tumours are exceeded in frequency by only 2 other organs—lungs and liver. Most skeletal metastases are derived from haematogenous spread.

Bony metastases of carcinomas predominate over the sarcomas. Some of the common *carcinomas* metastasising to the bones are from: breast, prostate, lung, kidney, stomach, thyroid, cervix, body of uterus, urinary bladder, testis, melanoma and neuroblastoma of adrenal gland. Examples of *sarcomas* which may metastasise to the bone are: embryonal and alveolar rhabdomyosarcoma, Ewing's sarcoma and osteosarcoma.

Skeletal metastases may be single or multiple. Most commonly involved bones are: the spine, pelvis, femur, skull, ribs and humerus. Usual radiographic appearance is of an *osteolytic* lesion. *Osteoblastic* bone metastases occur in cancer of the prostate, carcinoid tumour and small cell carcinoma of lung.

Metastatic bone tumours generally reproduce the microscopic picture of primary tumour (**Web Image 28.22**).

JOINTS (p. 850)

□ **NORMAL STRUCTURE** (p. 850)

The joints are of 2 types—*diarthrodial* or *synovial joints* with a joint cavity, and *synarthrodial* or *nonsynovial joints* without a joint cavity. The synovial membrane is composed of inner layer of 1-4 cell thick synoviocytes and outer layer of loose vascular connective tissue. On electron microscopy, two types of synoviocytes are distinguished: type A and type B. *Type A* synoviocytes are more numerous and are related to macrophages and produce degradative enzymes, while *type B* synthesise hyaluronic acid.

Osteoarthritis (OA), also called osteoarthrosis or degenerative joint disease (DJD), is the most common form of chronic disorder of synovial joints. It is characterised by progressive degenerative changes in the articular cartilages over the years, particularly in weight-bearing joints.

TYPES AND PATHOGENESIS. OA occurs in 2 clinical forms—

◆ **Primary OA** occurs in the elderly, more commonly in women than in men. The process begins by the end of 4th decade and then progressively and steadily increases producing clinical symptoms. Probably, wear and tear with repeated minor trauma, heredity, obesity, aging *per se*, all contribute to focal degenerative changes in the articular cartilage of the joints. Genetic factors favouring susceptibility to develop OA have been observed.

◆ **Secondary OA** may appear at any age and is the result of any previous wear and tear phenomena involving the joint such as previous injury, fracture, inflammation, loose bodies and congenital dislocation of the hip.

MORPHOLOGIC FEATURES. The pathologic changes occur in the articular cartilages, adjacent bones and synovium (**Web Image 28.23**):

1. **Articular cartilages.** The regressive changes are most marked in the weight-bearing regions of articular cartilages. Initially, there is loss of cartilaginous matrix (proteoglycans) resulting in progressive loss of normal metachromasia. This is followed by focal loss of chondrocytes, and at other places, proliferation of chondrocytes forming clusters.

2. **Bone.** The denuded subchondral bone appears like polished ivory. There is death of superficial osteocytes and increased osteoclastic activity causing rarefaction, microcyst formation and occasionally microfractures of the subjacent bone. The margins of the joints respond to cartilage damage by *osteophyte* or *spur formation*. These are cartilaginous outgrowths at the joint margins which later get ossified. Loosened and fragmented osteophytes may form free 'joint mice' or loose bodies.

3. **Synovium.** Initially, there are no pathologic changes in the synovium but in advanced cases there is low-grade chronic synovitis and villous hypertrophy. There may be some amount of synovial effusion associated with chronic synovitis.

The manifestations of OA are most conspicuous in large joints such as hips, knee and back. In symptomatic cases, clinical manifestations are joint stiffness, diminished mobility, discomfort and pain. In the spine, osteophytes of OA may cause compression of cervical and lumbar nerve root with pain, muscle spasms and neurologic abnormalities.

□ RHEUMATOID ARTHRITIS (p. 851)

Rheumatoid arthritis (RA) is a chronic multisystem disease of unknown cause. Though the most prominent manifestation of RA is inflammatory arthritis of the peripheral joints, usually with a symmetrical distribution, its systemic manifestations include haematologic, pulmonary, neurological and cardiovascular abnormalities.

RA is a common disease having peak incidence in 3rd to 4th decades of life, with 3-5 times higher preponderance in females. The condition has high association with HLA-DR4 and HLA-DR1 and familial aggregation. The onset of disease is insidious, beginning with prodrome of fatigue, weakness, joint stiffness, vague arthralgias and myalgias. This is followed by pain and swelling of joints usually in symmetrical fashion, especially involving joints of hands, wrists and feet.

About 80% of cases are seropositive for *rheumatoid factor* (RF). However, RF titres are elevated in certain unrelated diseases too such as in: viral hepatitis, cirrhosis, sarcoidosis and leprosy. Other laboratory findings include mild normocytic and normochromic anaemia, elevated ESR, mild leucocytosis and hypergammaglobulinaemia.

ETIOPATHOGENESIS. Present concept on etiology and pathogenesis proposes that RA occurs in an *immunogenetically predisposed individual to*

the effect of microbial agents acting as trigger antigen. The role of superantigens which are produced by several microorganisms with capacity to bind to HLA-DR molecules (MHC-II region) has also emerged.

I. Immunologic derangements. A number of observations in patients and experimental animals indicate the role of immune processes, particularly autoimmune phenomenon, in the development of RA.

1. Detection of circulating autoantibody called rheumatoid factor (RF) against Fc portion of autologous IgG in about 80% cases of RA.
2. The presence of antigen-antibody complexes (IgG-RF complexes) in the circulation as well as in the synovial fluid.
3. The presence of other autoantibodies such as antinuclear factor (ANF), antibodies to collagen type II, and antibodies to cytoskeleton.
4. Antigenicity of proteoglycans of human articular cartilage.
5. The presence of γ -globulin, particularly IgG and IgM, in the synovial fluid.
6. Association of RA with amyloidosis.
7. Activation of cell-mediated immunity as observed by presence of numerous inflammatory cells in the synovium, chiefly CD4+ T lymphocytes and some macrophages.

II. Trigger events. Various possibilities which have been suggested are as follows:

1. The existence of an infectious agent such as mycoplasma, Epstein-Barr virus (EBV), cytomegalovirus (CMV) or rubella virus, either locally in the synovial fluid or systemic infection some time prior to the attack of RA.
2. The possible role of HLA-DR4 and HLA-DR1 in initiation of immunologic damage.

The proposed events in immunopathogenesis of RA are as under (**Web Image 28.24**):

- ◆ In response to antigenic exposure (e.g. infectious agent) in a genetically predisposed individual (HLA-DR), CD4+ T-cells are activated.
- ◆ These cells elaborate cytokines, the important ones being tumour necrosis factor (TNF)- α , interferon (IF)- γ , interleukin (IL)-1 and IL-6.
- ◆ These cytokines activate endothelial cells, B lymphocytes and macrophages.
- ◆ Activation of B-cells releases IgM antibody against IgG (i.e. anti-IgG); this molecule is termed *rheumatoid factor (RF)*.
- ◆ IgG and IgM immune complexes trigger inflammatory damage to the synovium, small blood vessels and collagen.
- ◆ Activated endothelial cells express adhesion molecules which stimulate collection of inflammatory cells.
- ◆ Activation of macrophages releases more cytokines which cause damage to joint tissues and vascularisation of cartilage termed *pannus formation*.
- ◆ Eventually damage and destruction of bone and cartilage are followed by fibrosis and ankylosis producing joint deformities.

MORPHOLOGIC FEATURES. These are as follows:

ARTICULAR LESIONS. RA involves first the small joints of hands and feet and then symmetrically affects the joints of wrists, elbows, ankles and knees. The proximal interphalangeal and metacarpophalangeal joints are affected most severely. Frequently cervical spine is involved but lumbar spine is spared.

M/E The characteristic feature is diffuse proliferative synovitis with formation of pannus (**Web Image 28.25**):

1. Numerous folds of large villi of synovium.
2. Marked thickening of the synovial membrane due to oedema, congestion and multilayering of synoviocytes.
3. Intense inflammatory cell infiltrate in the synovial membrane with predominance of lymphocytes, plasma cells and some macrophages, at places forming lymphoid follicles.
4. Foci of fibrinoid necrosis and fibrin deposition.

710 EXTRA-ARTICULAR LESIONS. Nonspecific inflammatory changes are seen in the blood vessels (acute vasculitis), lungs, pleura, pericardium, myocardium, lymph nodes, peripheral nerves and eyes. But one of the characteristic extra-articular manifestation of RA is occurrence of rheumatoid nodules in the skin. *Rheumatoid nodules* are particularly found in the subcutaneous tissue over pressure points such as the elbows, occiput and sacrum.

There are a few *variant forms* of RA:

1. **Juvenile RA** found in adolescent patients under 16 years of age is characterised by acute onset of fever and predominant involvement of knees and ankles.
2. **Felty's syndrome** consists of polyarticular RA associated with splenomegaly and hypersplenism and consequent haematologic derangements.
3. **Ankylosing spondylitis or rheumatoid spondylitis** is rheumatoid involvement of the spine, particularly sacroiliac joints, in young male patients. The condition has a strong HLA-B27 association.

□ **SUPPURATIVE ARTHRITIS** (p. 853)

Infectious or suppurative arthritis is invariably an acute inflammatory involvement of the joint. Bacteria usually reach the joint space from the bloodstream but other routes of infection by direct contamination of an open wound or lymphatic spread may also occur. Immunocompromised and debilitated patients are increasingly susceptible to suppurative arthritis. The common causative organisms are gonococci, meningococci, pneumococci, staphylococci, streptococci, *H. influenzae* and gram-negative bacilli.

MORPHOLOGIC FEATURES. The haematogenous infectious joint involvement is more often monoarticular rather than polyarticular. The process begins with hyperaemia, synovial swelling and infiltration by polymorphonuclear and mononuclear leucocytes along with development of effusion in the joint space.

□ **TUBERCULOUS ARTHRITIS** (p. 853)

Tuberculous infection of the joints results most commonly from haematogenous dissemination of the organisms from pulmonary or other focus of infection. Another route of infection is direct spread from tuberculous osteomyelitis close to the joint.

MORPHOLOGIC FEATURES. Tuberculous involvement of the joints is usually monoarticular type but tends to be more destructive than the suppurative arthritis. Most commonly involved sites are the spine, hip joint and knees, and less often other joints are affected. Tuberculosis of the spine is termed *Pott's disease* or *tuberculous spondylitis*.

G/A The affected articular surface shows deposition of grey-yellow exudate and occasionally tubercles are present. The joint space may contain tiny grey-white loose bodies and excessive amount of fluid.

M/E The synovium is studded with solitary or confluent caseating tubercles. The underlying articular cartilage and bone may be involved by extension of tuberculous granulation tissue and cause necrosis (*caries*).

□ **GOUT AND GOUTY ARTHRITIS** (p. 853)

Gout is a disorder of purine metabolism manifested by the following features, occurring singly or in combination:

1. Increased serum uric acid concentration (*hyperuricaemia*).
2. Recurrent attacks of characteristic type of acute arthritis in which crystals of *monosodium urate monohydrate* may be demonstrable in the leucocytes present in the synovial fluid.
3. Aggregated deposits of monosodium urate monohydrate (*tophi*) in and around the joints of the extremities.

4. *Renal disease* involving interstitial tissue and blood vessels.
5. Uric acid *nephrolithiasis*.

The disease usually begins in 3rd decade of life and affects men more often than women. A family history of gout is present in a fairly large proportion of cases indicating role of inheritance in hyperuricaemia.

TYPES AND PATHOGENESIS. The fundamental biochemical hallmark of gout is *hyperuricaemia*. A serum uric acid level in excess of 7 mg/dl, which represents the upper limit of solubility of monosodium urate in serum at 37°C at blood pH, is associated with increased risk of development of gout. Thus, *pathogenesis of gout is pathogenesis of hyperuricaemia*.

Hyperuricaemia and gout may be classified into 2 types: *metabolic* and *renal*, each of which may be *primary* or *secondary*. Primary refers to cases in which the underlying biochemical defect causing hyperuricaemia is not known, while secondary denotes cases with known causes of hyperuricaemia.

1. Hyperuricaemia of metabolic origin. This group comprises about 10% cases of gout which are characterised by overproduction of uric acid.

2. Hyperuricaemia of renal origin. About 90% cases of gout are the result of reduced renal excretion of uric acid. Altered renal excretion could be due to reduced glomerular filtration of uric acid, enhanced tubular reabsorption or decreased secretion.

MORPHOLOGIC FEATURES. The pathologic manifestations of gout include:

1. Acute gouty arthritis. This stage is characterised by acute synovitis triggered by precipitation of sufficient amount of needle-shaped crystals of monosodium urate from serum or synovial fluid. There is joint effusion containing numerous polymorphs, macrophages and microcrystals of urates. Acute gouty arthritis is predominantly a disease of lower extremities, affecting most commonly *great toe*. Other joints affected, in order of decreasing frequency, are: the instep, ankles, heels, knees, wrists, fingers and elbows.

2. Chronic tophaceous arthritis. Recurrent attacks of acute gouty arthritis lead to progressive evolution into chronic arthritis. The deposits of urate encrust the articular cartilage. There is synovial proliferation, pannus formation and progressive destruction of articular cartilage and subchondral bone.

3. Tophi in soft tissue. A *tophus* (meaning 'a porous stone') is a mass of urates measuring a few millimeters to a few centimeters in diameter. Tophi may be located in the periarticular tissues as well as subcutaneously such as on the hands and feet. Tophi are surrounded by inflammatory reaction consisting of macrophages, lymphocytes, fibroblasts and foreign body giant cells (*Web Image 28.26*).

4. Renal lesions. Chronic gouty arthritis frequently involves the kidneys. Three types of renal lesions are described in the kidneys: acute urate nephropathy, chronic urate nephropathy and uric acid nephrolithiasis.

□ **PSEUDOGOUT (PYROPHOSPHATE ARTHROPATHY)** (*p. 855*)

Pseudogout refers to an inflammatory joint involvement due to deposition of calcium pyrophosphate in the joint space. The condition is seen in middle-aged and elderly individuals of either sex. The pain is usually less severe and involvement of big toe is rare. The pathogenesis is unclear but several factors have been implicated. These include: associated metabolic disease (e.g. hyperparathyroidism, hypothyroidism, gout, ochronosis, Wilson's disease and haemochromatosis), heredity, familial occurrence, rheumatoid arthritis and osteoarthritis.

□ **PIGMENTED VILLODULAR SYNOVITIS AND TENOSYNOVIAL GIANT CELL TUMOUR (NODULAR TENOSYNOVITIS)** (*p. 855*)

The terms 'pigmented villonodular synovitis' and 'nodular tenosynovitis' represent diffuse and localised form respectively of the same underlying process. The localised form of lesion is also termed *xanthofibroma* or *benign*

712 *synovioma*. When the giant cells are numerous in localised tenosynovitis, the condition is called *giant cell tumour of tendon sheath*.

MORPHOLOGIC FEATURES. Though the two conditions have many morphologic similarities, they are best described separately.

◆ **Giant cell tumour of tendon sheath (Nodular tenosynovitis).** The localised nodular tenosynovitis is seen most commonly in the tendons of fingers.

G/A It takes the form of a solitary, circumscribed, pedunculated, small and lobulated nodule, measuring less than 2 cm in diameter. It is closely attached to and sometimes grooved by the underlying tendon.

M/E It is well encapsulated and is composed of sheets of small oval to spindle-shaped cells, foamy xanthoma cells, scattered multinucleate giant cells and irregular bundles of collagen. Many of the spindle-shaped cells are haemosiderin-laden (**Web Image 28.27**).

◆ **Pigmented villonodular tenosynovitis.** This is a diffuse form of synovial overgrowth seen most commonly in the knee and hip.

G/A The synovium has characteristic sponge-like reddish-brown or tan appearance with intermingled elongated villous projections and solid nodules.

M/E The changes are modified by recurrent injury. The enlarged villi are covered by hyperplastic synovium and abundant subsynovial infiltrate of lymphocytes, plasma cells and macrophages, many of which are lipid-laden and haemosiderin-laden. Multinucleate giant cells are scattered in these areas.

□ **CYST OF GANGLION** (p. 855)

A ganglion is a small, round or ovoid, movable, subcutaneous cystic swelling. The most common location is dorsum of wrist but may be found on the dorsal surface of foot near the ankle.

G/A A ganglion is a small cyst filled with clear mucinous fluid. It may or may not communicate with the joint cavity or tendon where it is located.

M/E The cyst has a wall composed of dense or oedematous connective tissue which is sometimes lined by synovial cells but more often has indistinct lining (**Web Image 28.28**).

□ **BURSITIS** (p. 856)

Inflammation of bursa is termed bursitis. Bursae are synovial-lined sacs found over bony prominences. Bursitis occurs following mechanical trauma or inflammation. It may result following a single injury but is more often due to repeated injuries from excessive pressure.

G/A The bursal sac is thick-walled and may contain watery, mucoid or granular brown material.

M/E The bursal wall is composed of dense fibrous tissue lined by inflammatory granulation tissue. The wall is infiltrated by lymphocytes, plasma cells and macrophages and may show focal calcium deposits.

SKELETAL MUSCLES (p. 856)

□ **NORMAL STRUCTURE** (p. 856)

Striated skeletal muscles consist of bundles of fibres called *fascicles*, each of which is surrounded by connective tissue sheath termed *perimysium*. Perimysium contains blood vessels and nerve supply of the muscle fascicles. Each muscle fibre is enveloped by delicate fibrous stroma called *endomysium*.

Individual muscle fibre is an elongated multinucleated syncytium-like cell about 100 µm in diameter and several centimeters in length. The muscle nuclei are spindle-shaped and lie at the periphery of fibre under the

sarcolemma, the plasma membrane of muscle fibre. The cytoplasm of the muscle fibre contains myofilaments which are contractile elements. Myofilaments are of 2 types—*myosin* comprising thick filaments and *actin* constituting thin filaments. These together produce cross-striations in muscle fibres seen in longitudinal sections on light microscopy.

A classification of neuromuscular disorders based on the part of the motor unit involved is presented in **Web Table 28.4**.

□ **NEUROGENIC DISEASES** (p. 857)

The group of neurogenic diseases affecting skeletal muscles is characterised by a combination of muscular weakness and fatiguability. The most common of these is myasthenia gravis; others are congenital myasthenia, an acquired Eaton-Lambert syndrome associated with carcinoma of the lung, and denervation atrophy.

MYASTHENIA GRAVIS (p. 857)

Myasthenia gravis (MG) is a neuromuscular disorder of autoimmune origin in which the acetylcholine receptors (AChR) in the motor end-plates of the muscles are damaged. The term '*myasthenia*' means 'muscular weakness' and '*gravis*' implies 'serious'; thus both together denote the clinical characteristics of the disease. MG may be found at any age but adult women are affected more often than adult men in the ratio of 3:2. The condition presents clinically with muscular weakness and fatiguability, initially in the ocular musculature but later spreads to involve the trunk and limbs. There is about 10% mortality in MG which is due to severe generalised disease and involvement of respiratory muscles. Several other autoimmune diseases have been found associated with MG such as autoimmune thyroiditis, rheumatoid arthritis, SLE, pernicious anaemia and collagen-vascular diseases.

PATHOGENESIS. The pathogenesis of MG is best understood in the context of normal muscle metabolism (**Web Image 28.29**):

◆ **Normally**, acetylcholine is synthesised in the motor nerve terminal and stored in vesicles that are released spontaneously when an action potential reaches the nerve terminal. Acetylcholine from released vesicles combines with AChRs.

◆ **In MG**, the basic defect is reduction in the number of available AChRs at the postsynaptic muscle membrane. In addition, the postsynaptic folds are flattened. These changes result in decreased neuromuscular transmission leading to failure to trigger muscle action potentials and consequent weakened muscle contraction.

G/A The muscles appear normal until late in the course of disease when they become wasted.

M/E A few clumps of lymphocytes may be found around small blood vessels. Degenerating muscle fibres are present in half the cases.

E/M Reveals reduction in synaptic area of the motor axons due to flattening or simplification of postsynaptic folds. The number of AChRs is greatly reduced. By immunocytochemistry combined with electron microscopy, it is possible to demonstrate the complex of IgG and complement at the neuromuscular junctions.

DENERVATION ATROPHY (p. 857)

If the muscle or a part of muscle is deprived of its motor nerve supply, the affected muscle undergoes atrophy. In demyelination, on the other hand, there is conduction block in the nerve impulse but no denervation and hence muscle atrophy does not occur.

714 Denervating diseases are characterised by axonal degeneration and consequent muscle atrophy. These include *amyotrophic lateral sclerosis* as an example of anterior horn cell disease, and *peripheral neuropathy* causing injury to myelinated axon.

MORPHOLOGIC FEATURES. Denervation atrophy is pathologically characterised by groups of small angulated muscle fibres alternating with groups of plump, normal or even hypertrophic fibres with intact innervation.

MYOPATHIC DISEASES (MYOPATHIES) (p. 858)

Myopathies are primary skeletal muscle diseases resulting in chronic muscle weakness. These are divided into 5 broad groups: hereditary (muscular dystrophies), inflammatory, endocrine, metabolic and toxic myopathies.

MUSCULAR DYSTROPHIES (p. 858)

Muscular dystrophies are a group of genetically-inherited primary muscle diseases, having in common, progressive and unremitting muscular weakness. Six major forms of muscular dystrophies are described: *Duchenne's*, *Becker's*, *myotonic*, *facio-scapulothoracic*, *limb-girdle* and *oculopharyngeal type*. Each type of muscular dystrophy is a distinct entity having differences in inheritance pattern, age at onset, clinical features, other organ system involvements and clinical course. These differences are summarised in **Web Table 28.5**. However, in general, muscular dystrophies manifest in childhood or in early adulthood. Family history of neuromuscular disease is elicited in many cases.

MORPHOLOGIC FEATURES. Common to all forms of muscular dystrophies are muscle fibre necrosis, regenerative activity, replacement by interstitial fibrosis and adipose tissue (**Web Image 28.30**).

SELF ASSESSMENT

- 1. The serum marker for increased osteoclastic activity is:**
 - A. Total acid phosphatase level
 - B. Bony acid phosphatase level
 - C. Total alkaline phosphatase level
 - D. Bony alkaline phosphatase level
- 2. The serum marker for increased osteoblastic activity is:**
 - A. Total acid phosphatase level
 - B. Bony acid phosphatase level
 - C. Total alkaline phosphatase level
 - D. Bony alkaline phosphatase level
- 3. Mineralisation of uncalcified osteoid matrix takes about:**

A. 3-5 days	B. 5-8 days
C. 8-12 days	D. 12-15 days
- 4. Cartilage matrix largely consists of:**

A. Chondroitin sulfate	B. Keratan sulfate
C. Heparan sulfate	D. Dermatan sulfate
- 5. Long-term complications of chronic osteomyelitis are as follows except:**
 - A. Secondary amyloidosis
 - B. Draining sinus tracts
 - C. Development of Ewing's sarcoma
 - D. Squamous carcinoma in sinus tract
- 6. Osteopetrosis is characterised by the following features except:**
 - A. Overgrowth of calcified dense bone
 - B. Hereditary defect in osteoclast function
 - C. There is hypercalcaemia
 - D. Skeleton is susceptible to fractures

7. **Osteoporosis is characterised by the following laboratory investigations except:**
- Normal inorganic phosphate
 - Raised serum calcium
 - Normal alkaline phosphatase
 - Normal acid phosphatase
8. **Renal osteodystrophy has the following biochemical parameters except:**
- Raised parathormone level
 - Hyperphosphataemia
 - Hypercalcaemia
 - Calcium phosphorus product >70
9. **Paget's disease of the bone has following features except:**
- Affects older age past 50 years
 - Elevation of serum alkaline phosphatase
 - There is generally hypocalcaemia
 - Role of virus in its etiology
10. **Albright's syndrome has the following features except:**
- There is monostotic bony lesion
 - Skin pigmentation
 - Sexual precocity
 - More common in females
11. **Osteoblastoma differs from osteoid osteoma by the following features except:**
- It is larger than osteoid osteoma
 - It is generally painful
 - It is commonly located in the medulla of vertebrae, ribs, etc.
 - There is absence of reactive bone formation
12. **Classic osteosarcoma has the following features except:**
- It occurs in age range of 10-20 years
 - There is role of mutation in Rb gene in its etiology
 - It is a highly malignant tumour
 - Serum alkaline phosphatase levels are generally lowered
13. **Parosteal osteosarcoma has the following features except:**
- It occurs at extracortical location
 - It occurs in older age group
 - Worse prognosis than classic osteosarcoma
 - It has no sex predilection
14. **There is a higher possibility of development of chondrosarcoma in the following benign cartilage-forming tumour:**
- Solitary enchondroma
 - Multiple enchondroma
 - Chondroblastoma
 - Chondromyxoid fibroma
15. **In giant cell tumour of bone, the tumour cells are:**
- Osteoclastic giant cells
 - Mononuclear stromal cells
 - Fibroblastic cells
 - Sinusoidal lining cells
16. **The cell of origin of Ewing's sarcoma is:**
- Endothelial cell
 - Marrow cell
 - Osteoblast
 - Primitive neuroectodermal cell
17. **Chordoma is a:**
- Benign tumour
 - Locally recurrent tumour
 - Intermediate grade tumour
 - Malignant tumour
18. **Osteoblastic skeletal metastasis are characteristically seen in:**
- Thyroid cancer
 - Breast cancer
 - Prostatic cancer
 - Malignant melanoma

19. Osteoarthritis has the following pathologic changes *except*:
- Progressive loss of cartilaginous matrix
 - Increased osteoclastic activity
 - Osteophyte formation at the joint margin
 - Atrophy of synovium
20. Most frequently and severely involved joints in rheumatoid arthritis are:
- Knees
 - Elbows
 - Interphalangeal
 - Sacroiliac
21. Most frequently affected joint in acute gouty arthritis in the beginning is:
- Knee
 - Elbow
 - Shoulder
 - Great toe
22. The origin of villonodular tenosynovitis and giant cell tumour of tendon sheath is:
- Inflammatory
 - Neoplastic
 - Traumatic
 - Autoimmune
23. Patients of myasthenia gravis have the following features *except*:
- There is reduction in AChRs
 - Majority of patients have anti-AChR antibodies in their serum
 - Thymic hypoplasia has a risk in its etiology
 - The disease has other autoimmune associations
24. All the following tumours are benign *except*:
- Osteoma
 - Chondroma
 - Chordoma
 - Osteoblastoma
25. Most common etiologic agent implicated in chronic osteomyelitis is:
- Staphylococcus aureus*
 - Escherichia coli*
 - Pseudomonas*
 - Klebsiella*
26. All are causes of avascular necrosis *except*:
- Long-term steroid therapy
 - Chronic alcoholism
 - Radiation therapy
 - Fungal infection
27. All are types of skeletal dysplasia *except*:
- Achondroplasia
 - Osteogenesis imperfecta
 - Osteoporosis
 - Osteopetrosis
28. All are benign bone forming tumours *except*:
- Osteoma
 - Osteochondroma
 - Osteoid osteoma
 - Osteoblastoma
29. All of the following infectious agents are implicated in rheumatoid arthritis *except*:
- CMV
 - Rubella
 - Mycoplasma
 - Mycobacterium*

KEY

1 = B	2 = D	3 = D	4 = A
5 = C	6 = C	7 = B	8 = C
9 = C	10 = A	11 = B	12 = D
13 = C	14 = B	15 = B	16 = D
17 = D	18 = C	19 = D	20 = C
21 = D	22 = B	23 = C	24 = C
25 = A	26 = D	27 = C	28 = B
29 = D			



Soft Tissue Tumours

INTRODUCTION. Soft tissues included for the purpose of categorisation of their tumours are: fibrous tissue, adipose tissue, muscle tissue, synovial tissue, blood vessels and neuroectodermal tissues of the peripheral and autonomic nervous system. The lesions of these tissues are embryologically derived from mesoderm, except those of peripheral nerve which are derived from ectoderm.

Benign soft tissue tumours are about 100 times more common than sarcomas. Sarcomas rarely arise from malignant transformation of a pre-existing benign tumour. Instead, sarcomas originate from the primitive mesenchymal cells having the capacity to differentiate along different cell pathways.

Majority of soft tissue tumours have following important general features:

- ◆ Superficially-located tumours tend to be benign while *deep-seated lesions* are more likely to be malignant.
- ◆ *Large-sized tumours* are generally more malignant than small ones.
- ◆ *Rapidly-growing tumours* often behave as malignant tumours than those that develop slowly.
- ◆ Malignant tumours have frequently *increased vascularity* while benign tumours are selectively avascular.
- ◆ Although soft tissue tumours may arise anywhere in the body but in general *more common locations* are: lower extremity (40%), upper extremity (20%), trunk and retroperitoneum (30%) and head and neck (10%).
- ◆ Generally, *males* are affected more commonly than females.
- ◆ Approximately 15% of soft tissue tumours occur in *children* and include some specific examples of soft tissue sarcomas e.g. rhabdomyosarcoma, synovial sarcoma.

ETIOLOGY AND PATHOGENESIS. Etiology of soft tissue tumours remains largely unknown; however, a few common features in etiology and pathogenesis apply to many soft tissue tumours:

1. Frequently there is history of antecedent *trauma* which may bring the tumour to attention of the patient.
2. Molecular and cytogenetic studies in many soft tissue tumours reveal *chromosomal abnormalities and mutations* in genes which can be used as a marker for diagnosis and histogenesis e.g. translocations, various fusion genes etc.
3. Most of the soft tissue tumours occur *sporadically*; however there are a few examples which are components of *genetic syndromes* e.g. neurofibromatosis type 1, Li-Fraumeni syndrome, Osler-Weber-Rendu syndrome etc.

CLASSIFICATION. Currently, the WHO classification divides all soft tissue tumours into following 4 categories:

Benign: These soft tissue tumours generally do not recur and are cured by complete excision. Common example is lipoma.

Intermediate, locally aggressive: These tumours are locally destructive, infiltrative and often recur but do not metastasise. Such tumours are generally treated by wide excision; for example desmoid tumour.

Intermediate, rarely metastasising: This category of tumours are also locally destructive, infiltrative and recurrent but in addition about 2% cases may have clinical metastasis which may not be predicted by morphology. Common example in this category is dermatofibrosarcoma protuberans.

718 Malignant: Tumours in this category are clearly malignant—they are locally destructive, infiltrative and metastasise in a high percent of cases. The metastatic rate in low-grade sarcomas is about 2-10% and in high-grade sarcomas is 20-100%.

DIAGNOSTIC CRITERIA. Accurate pathological diagnosis of soft tissue tumours is based on histogenesis which is important for determining the prognosis and can be made by the following plan:

1. Cell patterns: Several morphological patterns in which tumour cells are arranged are peculiar in different tumours e.g.

i) *Smooth muscle tumours:* interlacing fascicles of pink staining tumour cells.

ii) *Fibrohistiocytic tumours:* characteristically have storiform pattern in which spindle tumour cells radiate from the centre in a spoke-wheel manner.

iii) *Herringbone pattern:* is seen in fibrosarcoma in which the tumour cells are arranged like the vertebral column of seafish.

iv) *Pallisaded arrangement:* is characteristically seen in schwannomas in which the nuclei of tumour cells are piled upon each other.

v) *Biphasic pattern:* is the term used for a combination arrangement of two types—fascicles and epithelial-like e.g. in synovial sarcoma.

2. Cell types: After looking at the pattern of cells described above, preliminary categorisation of soft tissue tumours is done on the basis of cell types comprising the soft tissue tumour:

i) **Spindle cells:** These are the most common cell types in most sarcomas. However, there are subtle differences in different types of spindle cells e.g.

a) *Fibrogenic tumours* have spindle cells with light pink cytoplasm and tapering-ended nuclei.

b) *Neurogenic (Schwann cell) tumours* have tumour cells similar to fibrogenic cells but have curved nuclei.

c) *Leiomyomatous tumours* have spindle cells with blunt-ended (cigar-shaped) nuclei and more intense eosinophilic cytoplasm.

d) *Skeletal muscle tumours* have spindle cells similar to leiomyomatous cells but in addition have cytoplasmic striations.

ii) **Small round cells:** Some soft tissue sarcomas are characterised by dominant presence of small round cells or blue cells and are termed by various names such as malignant small round cell tumours, round cell sarcomas, or blue cell tumours (due to presence of lymphocyte-like round nuclear size and dense blue chromatin). Examples of this group of tumours are as under:

a) Rhabdomyosarcoma (embryonal and alveolar types)

b) Primitive neuroectodermal tumour (PNET)

c) Ewing's sarcoma

d) Neuroblastoma

e) Malignant lymphomas.

A few examples of epithelial tumours such as small cell carcinoma and malignant carcinoid tumours enter in the differential diagnosis of small round cell tumours.

iii) **Epithelioid cells:** Some soft tissue tumours have either epithelioid cells as the main cells (e.g. epithelioid sarcoma) or have epithelial-like cells as a part of biphasic pattern of the tumour (e.g. synovial sarcoma).

3. Immunohistochemistry: Soft tissue tumours are distinguished by application of immunohistochemical stains. Based on differential diagnosis made on routine morphology, the panel of antibody stains is chosen for applying on paraffin sections for staining. Some common examples are as under:

i) Smooth muscle actin (SMA): for smooth muscle tumours.

ii) Vimentin: as common marker to distinguish mesenchymal cells from epithelium.

- iii) Desmin: for skeletal muscle cells.
- iv) S-100: for nerve fibres.
- v) Factor VIII: antigen for vascular endothelium.
- vi) LCA (leucocyte common antigen): common marker for lymphoid cells.

4. Electron microscopy: EM as such is mainly a research tool and does not have much diagnostic value in soft tissue tumours but can be applied sometimes to look for tonofilaments or cell organelles.

5. Cytogenetics: Many soft tissue tumours have specific genetic and chromosomal changes which can be done for determining histogenesis, or for diagnosis and prognosis.

GRADING. The number of pathological grades of soft tissue tumours may vary according to different grading systems: 2 grade system (grade I-II as low and high grade), 3-grade system (grade I, II, III as low, intermediate and high grade) and 4 grade system (grade I-IV). Pathological grading is based on following 3 features:

- i) Tumour differentiation or degree of cytologic atypia
- ii) Mitotic count
- iii) Tumour necrosis

STAGING. Different staging systems for soft tissue sarcomas have been described but two of the most accepted staging systems are *Enneking's staging* and American Joint Committee (AJC) staging system:

Enneking's staging: This staging system is accepted by most oncologists and is based on grade and location of tumour as under:

- ◆ According to tumour location: T1 (intracompartmental) and T2 (extracompartmental) tumours.
- ◆ According to tumour grade : G1 (low grade) and G2 (high grade) tumours.

Accordingly, the stages of soft tissue tumours vary from stage I to stage III as under:

Stage I: G1 and T1-T2 tumours, but no metastases.

Stage II: G2 and T1 -T2 tumours, but without metastases.

Stage III: G1 or G2 , T1 or T2 tumours, but with metastases.

AJC staging: This AJC system of staging is similar to staging for other tumours. It is based on TNM system in which the primary tumor (T), the status of lymph nodes (N) and presence or absence of metastases (M) are taken into consideration for staging, besides the histologic grade of the tumour.

TUMOURS AND TUMOUR-LIKE LESIONS OF FIBROUS TISSUE (p. 861)

□ FIBROMAS (p. 861)

True fibromas are uncommon tumours in soft tissues. Many fibromas are actually examples of hyperplastic fibrous tissue rather than true neoplasms. On the other hand, combinations of fibrous growth with other mesenchymal tissue elements are more frequent e.g. neurofibroma, fibromyoma etc.

Three types of fibromas are distinguished:

1. Fibroma durum is a benign, often pedunculated and well-circumscribed tumour occurring on the body surfaces and mucous membranes. It is composed of fully matured and richly collagenous fibrous connective tissue (**Web Image 29.1**).

2. Fibroma molle or fibrolipoma, also termed **soft fibroma**, is similar type of benign growth composed of mixture of mature fibrous connective tissue and adult-type fat.

720 3. Elastofibroma is a rare benign fibrous tumour located in the subscapular region. It is characterised by association of collagen bundles and branching elastic fibres.

FIBROMATOSIS (p. 862)

'Fibromatosis' is the term used for tumour-like lesions of fibrous tissue which continue to proliferate actively and may be difficult to differentiate from sarcomas. These lesions may, therefore, be regarded as non-metastasising fibroblastic tumours which tend to invade locally and recur after surgical excision. In addition, electron microscopy has shown that the cells comprising these lesions have features not only of fibroblasts but of both fibroblasts and smooth muscle cells, so called *myofibroblasts*. Depending upon the anatomic locations and the age group affected, fibromatoses are broadly grouped as under:

A. Infantile or juvenile fibromatoses include: fibrous hamartoma of infancy, fibromatosis colli, diffuse infantile fibromatosis, juvenile aponeurotic fibroma, juvenile nasopharyngeal angiofibroma and congenital (generalised and solitary) fibromatosis.

B. Adult type of fibromatoses are: palmar and plantar fibromatosis, nodular fasciitis, cicatricial fibromatosis, keloid, irradiation fibromatosis, penile fibromatosis (Peyronie's disease), abdominal and extra-abdominal desmoid fibromatosis, and retroperitoneal fibromatosis.

KELOID. A keloid is a progressive fibrous overgrowth in response to cutaneous injury such as burns, incisions, insect bites, vaccinations and others. Keloids are found more often in blacks.

There are some differences between a *keloid* and a *hypertrophic scar*. A hypertrophic scar of the skin is more cellular and has numerous fibroblasts than a keloid and is composed of thinner collagenous fibres. A keloid is a progressive lesion and liable to recurrences after surgical excision.

NODULAR FASCITIS. Nodular fasciitis, also called pseudosarcomatous fibromatosis, is a form of benign and reactive fibroblastic growth extending from superficial fascia into the subcutaneous fat, and sometimes into the subjacent muscle. The most common locations are the upper extremity, trunk and neck region of young adults.

PALMAR AND PLANTAR FIBROMATOSES. These fibromatoses, also called Dupuytren-like contractures are the most common form of fibromatoses occurring superficially.

◆ **Palmar fibromatosis** is more common in the elderly males occurring in the palmar fascia and leading to flexion contractures of the fingers (Dupuytren's contracture). It appears as a painless, nodular or irregular, infiltrating, benign fibrous subcutaneous lesion. In almost half the cases, the lesions are bilateral.

◆ **Plantar fibromatosis** is a similar lesion occurring on the medial aspect of plantar arch. However, plantar lesions are less common than palmar type and do not cause contractures as frequently as palmar lesions. They are seen more often in adults and are infrequently multiple and bilateral. Essentially similar lesions occur in the shaft of the penis (*penile fibromatosis* or *Peyronie's disease*) and in the soft tissues of the knuckles (*knuckle pads*).

DESMOID FIBROMATOSES. Desmoid fibromatoses or musculo-aponeurotic fibromatoses, commonly referred to as desmoid tumours, are of 2 types: abdominal and extra-abdominal. Both types are, however, histologically similar. Clinically, both types behave in an aggressive manner and have to be distinguished from sarcomas. Recurrences are frequent and multiple.

G/A Desmoids are solitary, large, grey-white, firm and unencapsulated tumours infiltrating the muscle locally. Cut surface is whorled and trabeculated.

M/E Their appearance is rather misleadingly bland in contrast with aggressive local behaviour. They are composed of uniform-looking fibroblasts arranged in bands and fascicles. Pleomorphism and mitoses are infrequent.

FIBROSARCOMA (p. 863)

Fibrosarcoma is a slow-growing tumour, affecting adults between 4th and 7th decades of life. Most common locations are the lower extremity (especially thigh and around the knee), upper extremity, trunk, head and neck, and retroperitoneum (**Web Image 29.2**). The tumour is capable of metastasis, chiefly via the blood stream.

G/A Fibrosarcoma is a grey-white, firm, lobulated and characteristically circumscribed mass. Cut surface of the tumour is soft, fishflesh-like, with foci of necrosis and haemorrhages.

M/E The tumour is composed of uniform, spindle-shaped fibroblasts arranged in intersecting fascicles. In well-differentiated tumours, such areas produce 'herring-bone pattern' (herring-bone is a sea fish) (**Web Image 29.3**).

The group of fibrohistiocytic tumours is characterised by distinctive light microscopic features that include presence of cells with fibroblastic and histiocytic features in varying proportion and identification of characteristic *cart-wheel or storiform pattern* in which the spindle cells radiate outward from the central focus. The histogenesis of these cells is uncertain but possibly they arise from primitive mesenchymal cells or facultative fibroblasts which are capable of differentiating along different cell lines.

BENIGN FIBROUS HISTIOCYTOMA (p. 864)

Depending upon the location and predominant pattern, benign fibrous histiocytomas include a number of diverse entities such as dermatofibroma, sclerosing haemangioma, fibroxanthoma, xanthogranuloma, giant cell tumour of tendon sheath and pigmented villonodular synovitis.

DERMATOFIBROSARCOMA PROTUBERANS (p. 864)

Dermatofibrosarcoma protuberans is a low-grade malignant cutaneous tumour of fibrohistiocytic origin. The tumour recurs locally, and in rare instances gives rise to distant metastases. Most frequent location is the trunk.

G/A The tumour forms a firm, solitary or multiple, satellite nodules extending into the subcutaneous fat and having thin and ulcerated skin surface.

M/E The tumour is highly cellular and is composed of fibroblasts arranged in a cart-wheel or storiform pattern.

MALIGNANT FIBROUS HISTIOCYTOMA (p. 864)

Malignant fibrous histiocytomas (MFH) represent approximately 20-30% of all soft tissue sarcomas. It is the most common soft tissue sarcoma and is the most frequent sarcoma associated with radiotherapy. The tumour occurs more commonly in males and more frequently in the age group of 5th to 7th decades. Most common locations are the lower and upper extremities and retroperitoneum. It begins as a painless, enlarging mass, generally in relation to skeletal muscle, deep fascia or subcutaneous tissue.

G/A MFH is a multilobulated, well-circumscribed, firm or fleshy mass, 5-10 cm in diameter. Cut surface is grey-white, soft and myxoid (**Web Image 29.4**).

M/E There is marked variation in appearance from area to area within the same tumour. In general, there is admixture of spindle-shaped *fibroblast-*

722 *like cells* and mononuclear round to oval *histiocyte-like cells* which may show phagocytic function. There is tendency for the spindle shaped cells to be arranged in characteristic cart-wheel or storiform pattern. The tumour cells show varying degree of pleomorphism, hyperchromatism, mitotic activity and presence of multinucleate bizarre tumour giant cells. Usually there are numerous blood vessels and some scattered lymphocytes and plasma cells (**Web Image 29.5**). Important immunohistochemical markers for MFH include vimentin, α -chymotrypsin, CD68 and factor VIII-a.

LIPOMA (p. 865)

Lipoma is the commonest soft tissue tumour. It appears as a solitary, soft, movable and painless mass which may remain stationary or grow slowly. Lipomas occur most often in 4th to 5th decades of life and are frequent in females. They may be found at different locations in the body but most common sites are the subcutaneous tissues in the neck, back and shoulder (**Web Image 29.6, A**).

G/A A subcutaneous lipoma is usually small, round to oval and encapsulated mass. The cut surface is soft, lobulated, yellowish-orange and greasy (**Web Image 29.6, B**).

M/E The tumour is composed of lobules of mature adipose cells separated by delicate fibrous septa. A thin fibrous capsule surrounds the tumour (**Web Image 29.7**).

LIPOSARCOMA (p. 866)

Liposarcoma is one of the most common soft tissue sarcomas in adults, perhaps next in frequency only to malignant fibrous histiocytoma. Unlike lipoma which originates from mature adipose cells, liposarcoma arises from primitive mesenchymal cells, the *lipoblasts*. The peak incidence is in 5th to 7th decades of life. In contrast to lipomas which are more frequently subcutaneous in location, liposarcomas often occur in the deep tissues. Most frequent sites are intermuscular regions in the thigh, buttocks and retroperitoneum.

G/A Liposarcoma appears as a nodular mass, 5 cm or more in diameter. The tumour is generally circumscribed but infiltrative. Cut surface is grey-white to yellow, myxoid and gelatinous. Retroperitoneal masses are generally much larger.

M/E The hallmark of diagnosis of liposarcoma is the identification of variable number of *lipoblasts* which may be univacuolated or multivacuolated (**Web Image 29.4**). The vacuoles represent fat in the cytoplasm. Four major histologic varieties of liposarcomas are distinguished: (**Web Image 29.8**):

1. *Well-differentiated liposarcoma* resembles lipoma but contains uni- or multi-vacuolated lipoblasts.
2. *Myxoid liposarcoma* is the most common histologic type. It is composed of monomorphic, fusiform or stellate cells representing primitive mesenchymal cells, lying dispersed in mucopolysaccharide-rich ground substance. Occasional tumour giant cells may be present. Prominent meshwork of capillaries forming chicken-wire pattern is a conspicuous feature.
3. *Round cell liposarcoma* is composed of uniform, round to oval cells having fine multivacuolated cytoplasm with central hyperchromatic nuclei.
4. *Pleomorphic liposarcoma* is highly undifferentiated and the most anaplastic type. There are numerous large tumour giant cells and bizarre lipoblasts.

RHABDOMYOMA (p. 867)

Rhabdomyoma is a rare benign soft tissue tumour. Soft tissue rhabdomyomas are predominantly located in the head and neck, most often in the upper neck, tongue, larynx and pharynx.

M/E the tumour is composed of large, round to oval cells, having abundant, granular, eosinophilic cytoplasm which is frequently vacuolated and contains glycogen. Cross-striations are generally demonstrable in some cells with phosphotungstic acid-haematoxylin (PTAH) stain.

RHABDOMYOSARCOMA (p. 867)

Rhabdomyosarcoma is a much more common soft tissue tumour than rhabdomyoma, and is the commonest soft tissue sarcoma in children and young adults. It is a highly malignant tumour arising from rhabdomyoblasts in varying stages of differentiation with or without demonstrable cross-striations. Depending upon the growth pattern and histology, 4 types are distinguished:

1. EMBRYONAL RHABDOMYOSARCOMA. The embryonal form is the most common of the rhabdomyosarcomas. It occurs predominantly in children under 12 years of age. The common locations are in the head and neck region, most frequently in the orbit, urogenital tract and the retroperitoneum.

G/A The tumour forms a gelatinous mass growing between muscles or in the deep subcutaneous tissues but generally has no direct relationship to the skeletal muscle.

M/E The tumour cells have resemblance to embryonal stage of development of muscle fibres. There is considerable variation in cell types. Generally, the tumour consists of a mixture of small, round to oval cells and spindle-shaped strap cells having tapering bipolar cytoplasmic processes in which cross-striations may be evident.

2. BOTRYOID RHABDOMYOSARCOMA. Botryoid variety is regarded as a variant of embryonal rhabdomyosarcoma occurring in children under 10 years of age. It is seen most frequently in the vagina, urinary bladder and nose.

G/A The tumour forms a distinctive grape-like gelatinous mass protruding into the hollow cavity.

M/E the tumour grows underneath the mucosal layer, forming the characteristic *cambium layer* of tumour cells. The tumour is hypocellular and myxoid with predominance of small, round to oval tumour cells (**Web Image 29.9**).

3. ALVEOLAR RHABDOMYOSARCOMA. Alveolar type of rhabdomyosarcoma is more common in older children and young adults under the age of 20 years. The most common locations, unlike the embryonal variety, are the extremities.

G/A The tumour differs from embryonal type in arising directly from skeletal muscle and grows rapidly as soft and gelatinous mass.

M/E the tumour shows characteristic alveolar pattern resembling pulmonary alveolar spaces. These spaces are formed by fine fibrocollagenous septa. The tumour cells lying in these spaces and lining the fibrous trabeculae are generally small, lymphocyte-like with frequent mitoses and some multinucleate tumour giant cells (**Web Image 29.10**).

4. PLEOMORPHIC RHABDOMYOSARCOMA. This less frequent variety of rhabdomyosarcoma occurs predominantly in older adults above the age of 40 years. They are most common in the extremities, most frequently in the lower limbs.

724 G/A The tumour forms a well-circumscribed, soft, whitish mass with areas of haemorrhages and necrosis.

M/E The tumour cells show considerable variation in size and shape. The tumour is generally composed of highly anaplastic cells having bizarre appearance and numerous multinucleate giant cells. Various shapes include racquet shape, tadpole appearance, large strap cells, and ribbon shapes containing several nuclei in a row.

Conventionally, the cross-striations can be demonstrated with PTAH stain in a few rhabdomyosarcomas. Immunohistochemical stains include: myogenin, Myo-D1, desmin, actin, myosin, myoglobin, and vimentin.

SYNOVIAL SARCOMA (MALIGNANT SYNOVIOMA) (p. 868)

Synovial sarcoma or malignant synovioma, on the other hand, is a distinctive soft tissue sarcoma arising from synovial tissues close to the large joints, tendon sheaths, bursae and joint capsule but almost never arising within joint cavities. Most common locations are the extremities, frequently the lower extremity. However, synovial sarcoma is also found in regions where synovial tissue is not present such as in the anterior abdominal wall, parapharyngeal region and the pelvis. The tumour principally occurs in young adults, usually under 40 years of age. The tumour grows slowly as a painful mass but may metastasise via blood stream, chiefly to the lungs.

The *histogenesis* of tumour is, believed to be from multipotent mesenchymal cells which may differentiate along different cell lines.

G/A The tumour is of variable size and is grey-white, round to multilobulated and encapsulated. Cut surface shows fishflesh-like sarcomatous appearance with foci of calcification, cystic spaces and areas of haemorrhages and necrosis.

M/E *Classic synovial sarcoma* shows a characteristic *biphasic cellular pattern* composed of clefts or gland-like structures lined by cuboidal to columnar epithelial-like cells and plump to oval spindle cells (**Web Image 29.11**). Reticulin fibres are present around spindle cells but absent within the epithelial foci. The spindle cell areas form interlacing bands similar to those seen in fibrosarcoma. Myxoid matrix, calcification and hyalinisation are frequently present in the stroma. Mitoses and multinucleate giant cells are infrequent. Immunohistochemically, both types of tumour cells are positive for cytokeratin.

ALVEOLAR SOFT PART SARCOMA (p. 869)

Alveolar soft part sarcoma is a histologically distinct, slow-growing malignant tumour of uncertain histogenesis. The tumour may occur at any age but affects children and young adults more often.

G/A The tumour is well-demarcated, yellowish and firm.

M/E The tumour shows characteristic alveolar pattern. Organoid masses of tumour cells are separated by fibrovascular septa. The tumour cells are large and regular and contain abundant, eosinophilic, granular cytoplasm which contains diastase-resistant PAS-positive material.

GRANULAR CELL MYOBLASTOMA (p. 869)

Granular cell tumour is a benign tumour of unknown histogenesis. It may occur at any age but most often affected are young to middle-aged adults. The most frequent locations are the tongue and subcutaneous tissue of the trunk and extremities.

G/A The tumour is generally small, firm, grey-white to yellow-tan nodular mass.

M/E The tumour consists of nests or ribbons of large, round or polygonal, uniform cells having finely granular, acidophilic cytoplasm and small dense nuclei.

EPITHELIOID SARCOMA (p. 869)

This soft tissue sarcoma occurring in young adults is peculiar in that it presents as an ulcer with sinuses, often located on the skin and subcutaneous tissues as a small swelling. The tumour is slow growing but metastasising.

G/A The tumour is somewhat circumscribed and has nodular appearance with central necrosis.

M/E The tumour cells comprising the nodules have epithelioid appearance by having abundant pink cytoplasm and the centres of nodules show necrosis and thus can be mistaken for a granuloma.

CLEAR CELL SARCOMA (p. 869)

Clear cell sarcoma, first described by Enginzer, is seen in skin and subcutaneous tissues, especially of hands and feet.

M/E It closely resembles malignant melanoma, and is therefore also called melanoma of the soft tissues.

MYOSITIS OSSIFICANS (p. 869)

Myositis ossificans is a benign, tumour-like lesion characterised by osteoid and heterotopic bone formation in the soft tissues. It is a misnomer since the lesion neither occurs exclusively in the skeletal muscle as the name leads one to believe, nor are the inflammation or ossification always essential.

Myositis ossificans is generally preceded by history of antecedent trauma to a skeletal muscle or its tendon. The trauma may be minor and repetitive e.g. to the adductor muscles of the thigh of a horseman, or may be single injury followed by haemorrhage into the muscle.

G/A The lesion appears as unencapsulated, gritty mass replacing the muscle.

M/E The central region of the mass shows loosely-arranged fibroblasts having high mitotic activity. Towards the periphery, there is presence of osteoid matrix and formation of woven mineralised bone with trapped skeletal muscle fibres and regenerating muscle (myogenic) giant cells. The appearance is sufficiently atypical to suggest osteosarcoma but osteosarcoma lacks maturation phenomena seen in myositis ossificans. This is why the condition is also called *pseudomalignant osseous tumour* of the soft tissues.

SELF ASSESSMENT

1. **The term soft tissue tumours includes:**

A. Mesodermal tissue	B. Epithelial tissues
C. Reticuloendothelial tissues	D. Glial tissue
2. **Nodular fasciitis has the following features except:**
 - A. It is an inflammatory condition
 - B. Local excision is curative
 - C. There are whorls of fibroblasts
 - D. There is mild nuclear atypia and mitosis
3. **Desmoid tumour has the following characteristics except:**
 - A. It has an aggressive behaviour
 - B. The lesion is generally solitary and unencapsulated
 - C. It has pleomorphic fibroblasts having moderate mitotic activity
 - D. It may be abdominal or extra-abdominal
4. **The following lesions generally do not metastasise except:**

A. Dermatofibrosarcoma protuberans	B. Fibrosarcoma
C. Granular cell myoblastoma	D. Fibromatosis

5. The most common soft tissue sarcoma is:
- Fibrosarcoma
 - Rhabdomyosarcoma
 - Liposarcoma
 - Malignant fibrous histiocytoma
6. The commonest soft tissue sarcoma in children is:
- Liposarcoma
 - Rhabdomyosarcoma
 - Malignant fibrous histiocytoma
 - Synovial sarcoma
7. Synovial sarcoma has the following characteristics *except*:
- It generally arises from synovial tissues
 - It has a biphasic growth pattern
 - It always grows within joint cavities
 - Most common locations are extremities
8. Granular cell myoblastoma is seen most frequently in:
- Extremities
 - Trunk
 - Tongue
 - Visceral organs
9. The term pseudomalignant osseous tumour is used for the following condition:
- Myositis ossificans
 - Osteochondroma
 - Osteoid osteoma
 - Osteoblastoma
10. The following tumour is characterised by biphasic pattern of growth:
- Osteosarcoma
 - Osteochondroma
 - Synovial sarcoma
 - Malignant fibrous histiocytoma
11. All of the following sarcomas are composed of small round cells *except*:
- PNET
 - Neuroblastoma
 - Embryonal rhabdomyosarcoma
 - Synovial sarcoma
12. Pick the odd one out:
- SMA – Smooth muscle tumours
 - S-100 – Skeletal muscle tumours
 - Factor VIII – Vascular tumours
 - LCA – lymphoid cells
13. Which of the following is associated with Gardner's Syndrome:
- Abdominal desmoids
 - Extra-abdominal desmoids
 - Intra-abdominal desmoids
 - Plantar fibromatosis
14. All are histologic variants of liposarcoma *except*:
- Myxoid liposarcoma
 - Round cell liposarcoma
 - Pleomorphic liposarcoma
 - Dedifferentiated liposarcoma
15. Which of the following variants of rhabdomyosarcoma is seen in adulthood:
- Embryonal
 - Botryoid
 - Alveolar
 - Pleomorphic

KEY

1 = A	2 = A	3 = C	4 = B
5 = D	6 = B	7 = C	8 = C
9 = A	10 = C	11 = D	12 = B
13 = C	14 = D	15 = D	



The Nervous System

□ NORMAL STRUCTURE (p. 871)

The average weight of the brain is about 1400 gm in men and 1250 gm in women.

There are 2 types of tissues in the nervous system:

1. *Neuroectodermal tissues* which include neurons (nerve cells) and neuroglia, and together form the predominant constituent of the CNS.
2. *Mesodermal tissues* are microglia, dura mater, the leptomeninges (pia-arachnoid), blood vessels and their accompanying mesenchymal cells.

The predominant tissues comprising the nervous system and their general response to injury are briefly considered below:

1. NEURONS. The neurons are highly specialised cells of the body which are incapable of dividing after the first few weeks of birth. A neuron consists of 3 main parts: the cell body, an axon and numerous dendrites (**Web Image 30.1,A**). The cytoplasm contains polygonal, basophilic structures called Nissl substance. It consists of aggregates of RNA, sheaves of rough endoplasmic reticulum and intervening groups of free ribosomes. Besides Nissl substance, other special features of the cytoplasm of neuronal cell body are the presence of microtubules, synaptic vesicles and neurofilaments which are a form of intermediate filaments specific to neurons. Lipofuscin may be present due to ageing.

Neuropil is the term used for the fibrillar network formed by processes of all the neuronal cells.

2. NEUROGLIA. The neuroglia provides supportive matrix and maintenance to the neurons. It includes 3 types of cells: astrocytes, oligodendrocytes and ependymal cells (**Web Image 30.1,B**). Neuroglia is generally referred to as *glia*; the tumours originating from it are termed *gliomas*, and reactive proliferation of the astrocytes being called *gliosis*.

i) Astrocytes. The astrocytes are stellate cells with numerous fine branching processes. In routine haematoxylin and eosin stains, an astrocyte has round or oval vesicular nucleus, but unlike neuron, lacks a prominent nucleolus. The cytoplasm is generally scanty. The processes radiate from the cell body. Depending upon the type of processes, two types of astrocytes are distinguished:

- ◆ *Protoplasmic astrocytes*
- ◆ *Fibrous astrocytes.*

The astrocytic processes may not be visible by routine stains but can be demonstrated by phosphotungstic acid haematoxylin (PTAH) stain.

The astrocytes in respond to injury undergo hyperplasia and hypertrophy termed 'gliosis' which is an equivalent of scar elsewhere in the body.

◆ *Gemistocytic astrocytes* are early reactive astrocytes having prominent pink cytoplasm. Long-standing progressive gliosis results in the development of *Rosenthal fibres* which are eosinophilic, elongated or globular bodies present on the astrocytic processes.

◆ *Corpora amylacea* are basophilic, rounded, sometimes laminated bodies, present in elderly people in the white matter and result from accumulation of starch-like material in the degenerating astrocytes.

ii) Oligodendrocytes. Oligodendrocytes are so named because of their short and fewer processes when examined by light microscopy with special stains (*oligo*=short). In haematoxylin-eosin stained sections, these cells

728 appear as small cells with a darkly-staining nucleus resembling that of small lymphocyte. The cytoplasm appears as a clear halo around the nucleus.

iii) Ependymal cells. The ependymal cells are epithelium-like and form a single layer of cells lining the ventricular system, aqueduct, central canal of the spinal cord and cover the choroid plexus.

The ependymal cells influence the formation and composition of the cerebrospinal fluid (CSF) by processes of active secretion, diffusion, absorption and exchange.

3. MICROGLIA. Microglia is the nervous system counterpart of the monocyte-macrophage system. Although the term 'microglia' is commonly used but it is inappropriate since these cells, unlike neuroglia, are not of neuroectodermal origin. Normally, microglial cells appear as small inconspicuous cells with bean-shaped vesicular nuclei, scanty cytoplasm and long cytoplasmic processes (**Web Image 30.1,C**). Microglial cells may actually assume the shape and phagocytic function of macrophages and form *gitter cells*.

4. DURA MATER. The dura mater is a tough fibrous covering of the brain which is closely attached to the skull on its inner layer of endocranial periosteum. In the region of spinal canal, it encloses a potential space, the *epidural space*, between the bone and the dura. The dura is composed of dense collagen, fused with periosteum of the skull.

5. PIA-ARACHNOID (LEPTOMENINGES). The leptomeninges (*lepto*=thin, slender) consisting of the pia and arachnoid mater form the delicate vascular membranous covering of the central nervous system. The pia mater is closely applied to the brain and its convolutions, while the arachnoid mater lies between the pia mater and the dura mater without dipping into sulci. Thus, a space is left between the two layers of leptomeninges, known as *subarachnoid space*, which contains the CSF.

□ DEVELOPMENTAL ANOMALIES (p. 872)

Spinal Cord Defects (p. 873)

Spina bifida is the term applied to the malformations of the vertebral column involving incomplete embryologic closure of one or more of the vertebral arches (rachischisis), most frequently in the lumbosacral region. The vertebral defect is frequently associated with defect in the neural tube structures and their coverings. The least serious form is **spina bifida occulta** in which there is only vertebral defect but no abnormality of the spinal cord and its meninges. The larger bony defect, however, appears as a distinct cystic swelling over the affected site called **spina bifida cystica**. This is associated with herniation of the meninges or the spinal cord, or both.

◆ Herniation of the meninges alone through the bony defect, **meningocele**, is a less common variety.

◆ The commonest and more serious form is, however, **meningomyelocele** in which the spinal cord or its roots also herniate through the defect and are attached to the posterior wall of the sac.

◆ A rare form of the defect is **myelocele** or **syringomyelocele** in which there is defective closure of the spinal canal so that the sac consists of an open flat neural tissue plate without skin covering and the CSF leaking through it.

The existence of defect in bony closure in the region of occipital bone or fronto-ethmoid junction may result in **cranial meningocele** and **encephalocele**.

Syringomyelia and Syringobulbia (p. 873)

These are congenital malformations which manifest clinically later in life and often develop in association with certain acquired lesions involving the CNS.

Syringomyelia and syringobulbia are characterised by development of a *syrinx* or a tubular cavity in the spinal cord and medulla respectively.

Arnold-Chiari Malformations (p. 873)

Arnold-Chiari malformation is the term used for a group of malformations of the brain involving the brainstem and cerebellum. The primary defect is elongation of the medulla and part of the vermis of the cerebellum resulting from failure of the pontine flexure to form. Approximately 50% of children with hydrocephalus have the Arnold-Chiari malformation. The major components of type II Arnold-Chiari malformation are as follows:

1. Elongation of the medulla with part of fourth ventricle in the cervical canal.
2. Distortion of the medulla forming a characteristic S-shaped bend at the junction with the cervical spinal cord.
3. Lengthening and herniation of the cerebellar vermis and cerebellar tonsils through the foramen magnum resulting in formation of a mass over the upper cervical cord.

□ **HYDROCEPHALUS** (p. 873)

Hydrocephalus is the term used for increased volume of CSF within the skull, accompanied by dilatation of the ventricles. In majority of cases of hydrocephalus, there is increased intracranial pressure. This type of hydrocephalus involving ventricular dilatation is termed *internal hydrocephalus*. A localised collection of CSF in the subarachnoid space is called *external hydrocephalus*.

Source and Circulation of CSF (p. 873)

CSF is mainly produced by choroid plexus in the lateral, third and fourth ventricle, and a small part is formed on the surface of the brain and spinal cord. The total volume of CSF is about 120-150 ml. It is absorbed into the blood by the arachnoid villi present along the dural venous sinuses (**Web Image 30.2**).

Types and Etiopathogenesis (p. 873)

PRIMARY HYDROCEPHALUS. Primary hydrocephalus is defined as actual increase in the volume of CSF within the skull along with elevated intracranial pressure. There are 3 possible mechanisms of primary hydrocephalus:

1. Obstruction to the flow of CSF.
2. Overproduction of CSF.
3. Deficient reabsorption of CSF.

Non-communicating hydrocephalus. When the site of obstruction of CSF pathway is in the third ventricle or at the exit foramina in the fourth ventricle, the ventricular system enlarges and CSF cannot pass into the subarachnoid space. This is termed as non-communicating hydrocephalus. Among the common causes are the following:

- i) *Congenital non-communicating hydrocephalus* e.g. stenosis of the aqueduct, Arnold-Chiari malformation, progressive gliosis of the aqueduct and intra-uterine meningitis.
- ii) *Acquired non-communicating hydrocephalus* may occur from expanding lesion within the skull. These conditions are as under:
 - ◆ Tumours adjacent to the ventricular system e.g. ependymoma, choroid plexus papilloma, medulloblastoma and others.
 - ◆ Inflammatory lesions e.g. cerebral abscess, meningitis.
 - ◆ Haemorrhage e.g. parenchymal haemorrhage, intraventricular haemorrhage, and epidural and subdural haematoma.

Communicating hydrocephalus. When obstruction to the flow of CSF is in the subarachnoid space at the base of the brain, it results in enlargement of

- 730** the ventricular system but CSF flows freely between dilated ventricles and the spinal canal. This is called communicating hydrocephalus. The causes of communicating hydrocephalus are non-obstructive which are as follows:
- i) *Overproduction of CSF* e.g. choroid plexus papilloma.
 - ii) *Deficient reabsorption of CSF* e.g. following meningitis, subarachnoid haemorrhage and dural sinus thrombosis.

SECONDARY HYDROCEPHALUS. Secondary hydrocephalus is much less common and is defined as compensatory increase of CSF due to loss of neural tissue without associated rise in intracranial pressure (normal pressure hydrocephalus) e.g. from cerebral atrophy and infarction.

□ **INFECTIONS** (p. 874)

A large number of pathogens comprising various kinds of bacteria, fungi, viruses, rickettsiae and parasites can cause infections of the nervous system. The micro-organisms may gain entry into the nervous system by one of the following routes:

1. Via blood stream
2. Direct implantation
3. Local extension
4. Along nerve.

In general, resultant lesions are in the form of either diffuse inflammation of the meninges (meningitis) and of brain parenchyma (encephalitis), or combination of both (meningoencephalitis). In addition, other inflammatory lesions of CNS include: brain abscess, epidural abscess, subdural empyema, septic thromboembolism of dural sinuses and encephalomyelitis.

MENINGITIS (p. 874)

Meningitis is inflammatory involvement of the meninges. Meningitis may involve the dura called *pachymeningitis*, or the leptomeninges (pia-arachnoid) termed *leptomeningitis*. The latter is far more common, and unless otherwise specified, meningitis would mean leptomeningitis.

Pachymeningitis is invariably an extension of the inflammation from chronic suppurative otitis media or from fracture of the skull. An *extradural abscess* may form by suppuration between the bone and dura. Further spread of infection may penetrate the dura and form a *subdural abscess*. Other effects of pachymeningitis are localised or generalised leptomeningitis and *cerebral abscess*.

Infectious meningitis is broadly classified into 3 types: acute pyogenic, acute lymphocytic (viral, aseptic) and chronic (bacterial or fungal).

Acute Pyogenic Meningitis (p. 875)

Acute pyogenic or acute purulent meningitis is acute infection of the pia-arachnoid and of the CSF enclosed in the subarachnoid space. Since the subarachnoid space is continuous around the brain, spinal cord and the optic nerves, infection spreads immediately to whole of the cerebrospinal meninges as well as to the ventricles.

ETIOPATHOGENESIS. The causative organisms vary with age of the patient:

1. *Escherichia coli*
2. *Haemophilus influenzae*
3. *Neisseria meningitidis*
4. *Streptococcus pneumoniae*.

The **routes** of infection in acute pyogenic meningitis are as follows:

1. Most commonly by the blood stream.
2. From an adjacent focus of infection.
3. By iatrogenic infection such as introduction of micro-organisms at operation or during lumbar puncture.

G/A Pus accumulates in the subarachnoid space so that normally clear CSF becomes turbid or frankly purulent. Purulent material may interfere with CSF flow and result in obstructive hydrocephalus.

M/E There is presence of numerous polymorphonuclear neutrophils in the subarachnoid space as well as in the meninges, particularly around the blood vessels (**Web Image 30.3**). Gram-staining reveals varying number of causative bacteria.

CLINICAL FEATURES AND DIAGNOSIS. Acute bacterial meningitis is a medical emergency. The immediate clinical manifestations are fever, severe headache, vomiting, drowsiness, stupor, coma, and occasionally, convulsions.

The *diagnosis* is confirmed by examining CSF as soon as possible.

1. Naked eye appearance of cloudy or frankly purulent CSF.
2. Elevated CSF pressure (above 180 mm water).
3. Polymorphonuclear neutrophilic leucocytosis in CSF (between 10-10,000/ μ l).
4. Raised CSF protein level (higher than 50 mg/dl).
5. Decreased CSF sugar concentration (lower than 40 mg/dl).
6. Bacteriologic examination by Gram's stain or by CSF culture reveals causative organism.

Acute Lymphocytic (Viral, Aseptic) Meningitis (p. 875)

Acute lymphocytic meningitis is a viral or aseptic meningitis, especially common in children and young adults. Among the etiologic agents are numerous viruses such as enteroviruses, mumps, ECHO viruses, coxsackie virus, Epstein-Barr virus, herpes simplex virus-2, arthropode-borne viruses and HIV.

G/A Some cases show swelling of the brain while others show no distinctive change.

M/E There is mild lymphocytic infiltrate in the leptomeninges.

CLINICAL FEATURES AND DIAGNOSIS. The clinical manifestations of viral meningitis are much the same as in bacterial meningitis with features of acute onset meningeal symptoms and fever.

The *CSF findings* in viral meningitis are as under:

1. Naked eye appearance of clear or slightly turbid CSF.
2. CSF pressure increased (above 250 mm water).
3. Lymphocytosis in CSF (10-100 cells/ μ l).
4. CSF protein usually normal or mildly raised.
5. CSF sugar concentration usually normal.
6. CSF bacteriologically sterile.

Chronic (Tuberculous and Cryptococcal) Meningitis (p. 876)

There are two principal types of chronic meningitis—

◆ **Tuberculous meningitis** occurs in children and adults through haematogenous spread of infection from tuberculosis elsewhere in the body, or it may simply be a manifestation of miliary tuberculosis.

◆ **Cryptococcal meningitis** develops particularly in debilitated or immunocompromised persons, usually as a result of haematogenous dissemination from a pulmonary lesion. Cryptococcal meningitis is especially an important cause of meningitis in patients with AIDS.

G/A In tuberculous meningitis, the subarachnoid space contains thick exudate, particularly abundant in the sulci and the base of the brain. Tubercles, 1-2 mm in diameter, may be visible, especially adjacent to the blood vessels.

M/E Tuberculous meningitis shows exudate of acute and chronic inflammatory cells, and granulomas with or without caseation necrosis and giant

732 cells. Acid-fast bacilli may be demonstrated. Cryptococcal meningitis is characterised by infiltration by lymphocytes, plasma cells, an occasional granuloma and abundant characteristic capsulated cryptococci.

CLINICAL FEATURES AND DIAGNOSIS. Tuberculous meningitis manifests clinically as headache, confusion, malaise and vomiting.

The *CSF findings* in chronic meningitis are as under:

1. Naked eye appearance of a clear or slightly turbid CSF which may form fibrin web on standing.
2. Raised CSF pressure (above 300 mm water).
3. Mononuclear leucocytosis consisting mostly of lymphocytes and some macrophages (100-1000 cells/ μ l).
4. Raised protein content.
5. Lowered glucose concentration.
6. Tubercle bacilli may be found on microscopy of centrifuged deposits by ZN staining in tuberculous meningitis. Pathognomonic capsulated cryptococci with a halo are appreciated in India ink preparation of CSF in cases of cryptococcal meningitis, while the capsule is better demonstrated by mucicarmine stain (**Web Image 30.4**).

Web Table 30.1 summarises the CSF findings in the three important types of meningitis in comparison with those in health.

ENCEPHALITIS (p. 877)

Parenchymal infection of brain is termed encephalitis. Encephalitis may be the result of bacterial, viral, fungal and protozoal infections.

Bacterial Encephalitis (p. 877)

Bacterial infection of the brain substance is usually secondary to involvement of the meninges rather than a primary bacterial parenchymal infection. This results in bacterial cerebritis that progresses to form *brain abscess*. However, *tuberculosis* and *neurosyphilis* are the two primary bacterial involvements of the brain parenchyma.

BRAIN ABSCESS. Brain abscesses may arise by one of the following routes:

1. By direct implantation of organisms.
2. By local extension of infection.
3. By haematogenous spread.

G/A It appears as a localised area of inflammatory necrosis and oedema surrounded by fibrous capsule.

M/E The changes consist of liquefactive necrosis in the centre of the abscess containing pus. It is surrounded by acute and chronic inflammatory cells, neovascularisation, oedema, septic thrombosis of vessels, fibrous encapsulation and zone of gliosis.

TUBERCULOMA. Tuberculoma is an intracranial mass occurring secondary to dissemination of tuberculosis elsewhere in the body. Tuberculomas may be solitary or multiple.

G/A It has a central area of caseation necrosis surrounded by fibrous capsule.

M/E There is typical tuberculous granulomatous reaction around the central caseation necrosis (**Web Image 30.5**). A zone of gliosis generally surrounds the tuberculoma.

NEUROSYPHILIS. The lesions in syphilis may be in the form of *syphilitic meningitis* found in secondary syphilis, and *neurosyphilis* consisting of tabes dorsalis and generalised paralysis of the insane occurring in tertiary stage.

Syphilitic meningitis. This is a form of chronic meningitis characterised by distinctive perivascular inflammatory reaction of plasma cells and endarteritis obliterans.

Tabes dorsalis (Locomotor ataxia). There is slowly progressive degeneration of the posterior roots of the spinal nerves and the posterior columns of the spinal cord by the spirochaetes.

General paralysis of the insane. This is the result of diffuse parenchymal involvement by the spirochaetes with widespread lesions in the nervous system.

Viral Encephalitis (p. 877)

A number of viruses can infect the CNS and produce either aseptic meningitis (described already) or viral encephalitis, but sometimes combination of both termed meningoencephalitis, is present. Most viral infections of the CNS are the end-result of preceding infection in other tissues and organs.

Most of the viruses reach the nervous system via blood stream before which they enter the body by various routes e.g. infection of the skin and mucous membrane (in herpes simplex and herpes zoster-varicella), by the alimentary tract (in enteroviruses including polio virus), by arthropod bite (in arbovirus), by transplacental infection (in cytomegalovirus), and through body fluids in AIDS (in HIV infection). Rabies virus travels along the peripheral nerves to reach the CNS. Herpes zoster-varicella is a distinct primary disease (chickenpox) but the virus remains latent for a long time before it gets reactivated to cause severe hyperalgesia and pain along the distribution of nerve related to acutely inflamed posterior root ganglia (herpes zoster).

M/E These features are:

1. Parenchymal infiltrate, chiefly in perivascular location, of mononuclear cells consisting of lymphocytes, plasma cells and macrophages.
2. Microscopic clusters of microglial cells and presence of neuronophagia.
3. Intranuclear inclusion bodies in most viral diseases and specific cytoplasmic inclusions of Negri bodies in rabies.

HIV Encephalopathy (AIDS-Dementia Complex) (p. 878)

Next to knocking off of the immune system, HIV has profound neurovirulence but unlike tropism for CD4+ T cells of the immune system, HIV does not have neurotropism. HIV has not been identified to infect the neuronal cells but instead infects the cells of monocyte-macrophage cell line including microglial cells. HIV infection then sets in a cascade of toxic mediators and cytokines—TNF- α , IL-1, IL-6, TGF- β , IFN- γ , platelet activating factor (PAF) and endothelin, all of which cause damage to the neuroglial tissues.

Important forms of CNS diseases in patients with AIDS are listed in **Web Table 30.2**. Late in the course of AIDS, a group of signs and symptoms of CNS disease appear termed HIV encephalopathy or AIDS-dementia complex. One major clinical feature of this entity is the occurrence of *dementia* i.e. fall in the cognitive ability of the individual compared to previous level. Clinically, the disease develops in about 25% cases of AIDS while autopsy studies reveal presence of HIV-encephalopathy in 80-90% cases of AIDS.

Progressive Multifocal Leucoencephalopathy (p. 878)

Progressive multifocal leucoencephalopathy (PML) is a slow viral infection of the CNS caused by a papovavirus called *JC virus* (not to be confused with CJ disease or mad-cow disease; JC virus here stands for the initials of the patient first infected). PML develops in immunocompromised individual like CMV and *Toxoplasma* encephalitis does, and is, therefore, an important form of encephalitis due to increasing number of cases of AIDS.

734 **M/E** The features are as under:

- ◆ Focal areas of demyelination.
- ◆ Many lipid-laden macrophages in the centre of foci.
- ◆ Enlarged oligodendroglial nuclei containing purple viral inclusions at the periphery of the lesion.

Spongiform Encephalopathy (Creutzfeldt-Jakob Disease) (p. 878)

Spongiform encephalopathy, also called Creutzfeldt-Jakob disease (CJD) or mad-cow disease, though included under the group of viral encephalitis but is caused by accumulation of prion proteins. *Prion proteins* are a modified form of normal structural proteins present in the mammalian CNS and are peculiar in two respects: they lack nucleic acid (DNA or RNA), and they can be transmitted as an infectious proteinaceous particles.

Majority of cases occur sporadically though familial predisposition with autosomal dominant inheritance has also been reported in 5-15% cases.

Clinically, CJD is characterised by rapidly progressive dementia with prominent association of myoclonus. CJD is invariably fatal with mean survival of about 7 months after diagnosis.

M/E The hallmark is spongiform change i.e. there are small round vacuoles in the neuronal cells. These changes are predominantly seen in the cortex and other grey matter areas.

Fungal and Protozoal Encephalitis (p. 879)

Mycotic diseases of the CNS usually develop by blood stream from systemic deep mycoses elsewhere in the body. They are particularly more common in immunosuppressed individuals such as in AIDS, patients of lymphomas and other cancers. Some of the fungi which may disseminate to the CNS are *Candida albicans*, *Mucor*, *Aspergillus fumigatus*, *Cryptococcus neoformans*, *Histoplasma capsulatum* and *Blastomyces dermatitidis*. These fungal infections may produce one of the three patterns: fungal chronic meningitis, vasculitis and encephalitis.

Besides fungal infections, CNS may be involved in protozoal diseases such as in malaria, toxoplasmosis, amoebiasis, trypanosomiasis and cysticercosis (**Web Image 30.6**).

CEREBROVASCULAR DISEASES (p. 879)

Cerebrovascular diseases are all those diseases in which one or more of the blood vessels of the brain are involved in the pathologic processes. Various pathologic processes commonly implicated in cerebrovascular diseases are: thrombosis, embolism, rupture of a vessel, hypoxia, hypertensive arteriolosclerosis, atherosclerosis, arteritis, trauma, aneurysm and developmental malformations. These processes can result in 2 main types of parenchymal diseases of the brain:

A. Ischaemic brain damage:

- Generalised reduction in blood flow resulting in *global hypoxic-ischaemic encephalopathy*
- Local vascular obstruction causing *infarcts*.

B. Intracranial haemorrhage:

- Haemorrhage in the brain parenchyma (*intracerebral haemorrhage*)
- Haemorrhage in the subarachnoid space (*subarachnoid haemorrhage*).

The *stroke syndrome* is the cardinal feature of cerebrovascular disease. The term stroke is used for sudden and dramatic development of focal neurologic deficit, varying from trivial neurologic disorder to hemiplegia and coma. Other less common effects of vascular disease include: transient ischaemic attacks (TIA), vascular headache (e.g. in migraine, hypertension

and arteritis), local pressure of an aneurysm and increased intracranial pressure (e.g. in hypertensive encephalopathy and venous thrombosis).

A. ISCHAEMIC BRAIN DAMAGE (p. 879)

Ischaemic necrosis in the brain results from ischaemia caused by considerable reduction or complete interruption of blood supply to neural tissue which is insufficient to meet its metabolic needs.

Deprivation of oxygen (anoxia) to the brain may occur in 4 different ways:

1. *Anoxic anoxia*, in which there is low inspired pO_2 .
2. *Anaemic anoxia*, in which the oxygen-carrying haemoglobin is reduced.
3. *Histotoxic anoxia*, in which there is direct toxic injury as occurs in cyanide poisoning.
4. *Stagnant (ischaemia) anoxia*, in which the damage is caused by cessation of blood with resultant local accumulation of metabolites and changes in pH.

In all these different forms of anoxia, the end-result is ischaemic brain damage which may have one of the following two patterns:

Global Hypoxic-Ischaemic Encephalopathy (p. 879)

The brain receives 20% of cardiac output for maintaining its vital aerobic metabolism. A number of factors determine the maximum length of time the CNS can survive irreversible ischaemic damage.

- i) Severity of the hypoxic episode.
- ii) Presence of pre-existing cerebrovascular disease.
- iii) Age of the patient.
- iv) Body temperature.

Depending upon the proneness of different cells of the brain to the effects of ischaemia-hypoxia, three types of lesion may occur:

1. Selective neuronal damage: Neurons are most vulnerable to damaging effect of ischaemia-hypoxia and irreversible injury. In particular, oligodendroglial cells are most susceptible, followed by astrocytes while microglial cells and vascular endothelium survive the longest.

2. Laminar necrosis: Global ischaemia of cerebral cortex results in uneven damage because of different cerebral vasculature which is termed laminar or pseudolaminar necrosis. In this, superficial areas of cortical layers escape damage while deeper layers are necrosed.

3. Watershed infarcts: Circulatory flow in the brain by anterior, middle and posterior cerebral arteries has overlapping circulations. In ischaemia-hypoxia, perfusion of overlapping zones, being farthest from the blood supply, suffers maximum damage. This results in wedge-shaped areas of coagulative necrosis called watershed or borderzone infarcts. Particularly vulnerable is the border zone of the cerebral cortex between the anterior and middle cerebral arteries, producing para-sagittal infarction.

MORPHOLOGIC FEATURES. The pathologic appearance of the brain in hypoxic encephalopathy varies depending upon the duration and severity of hypoxic episode and the length of survival.

• **Survival for a few hours:** No pathologic changes are visible.

• **Survival 12-24 hours:** No macroscopic change is discernible but microscopic examination reveals early neuronal damage in the form of eosinophilic cytoplasm and pyknotic nuclei, so called red neurons.

• **After 2-7 days: G/A** there is focal softening. The area supplied by distal branches of the cerebral arteries suffers from the most severe ischaemic damage and may develop *border zone* or *watershed infarcts* in the junctional zones between the territories supplied by major arteries.

M/E the nerve cells die and disappear and are replaced by reactive fibrillary gliosis. There are minor variations in the distribution of neuronal damage to the cortex; the loss of pyramidal cell layer is more severe than that of granular cell layer producing laminar necrosis.

◆ **Longer duration:** Use of modern ventilators has led to maintenance of cardiorespiratory function in the presence of total brain necrosis unassociated with vital reaction.

Cerebral Infarction (p. 880)

Cerebral infarction is a localised area of tissue necrosis caused by local vascular occlusion—arterial or venous. Occasionally, it may be the result of non-occlusive causes such as compression on the cerebral arteries from outside and from hypoxic encephalopathy. However, significant atherosclerotic cerebrovascular disease may produce transient ischaemic attacks (TIA).

1. Arterial occlusion. Occlusion of the cerebral arteries by either thrombi or emboli is the most common cause of cerebral infarction. Thrombotic occlusion of the cerebral arteries is most frequently the result of atherosclerosis, and rarely, from arteritis of the cranial arteries. Embolic arterial occlusion is commonly derived from the heart, most often from mural thrombosis complicating myocardial infarction, from atrial fibrillation and endocarditis.

◆ Circle of Willis provides a complete collateral flow for internal carotid and vertebral arteries.

◆ Middle and anterior cerebral arteries have partial anastomosis of their distal branches. Their complete occlusion may cause infarcts.

◆ Small terminal cerebral arteries, on the contrary, are end-arteries and have no anastomosis. Hence, occlusion of these branches will invariably lead to an infarct.

2. Venous occlusion. Venous infarction in the brain is an infrequent phenomenon due to good communications of the cerebral venous drainage. However in cancer, due to increased predisposition to thrombosis, superior sagittal thrombosis may occur leading to bilateral, parasagittal, multiple haemorrhagic infarcts.

3. Non-occlusive causes. Compression of the cerebral arteries from outside such as occurs during herniation may cause cerebral infarction.

In any case, the extent of damage produced by any of the above causes depends upon:

- i) rate of reduction of blood flow;
- ii) type of blood vessel involved; and
- iii) extent of collateral circulation.

G/A Cerebral infarcts may be anaemic or haemorrhagic. An *anaemic infarct* becomes evident 6-12 hours after its occurrence. The affected area is soft and swollen and there is blurring of junction between grey and white matter. Within 2-3 days, the infarct undergoes softening and disintegration. Eventually, there is central liquefaction with peripheral firm glial reaction and thickened leptomeninges, forming a cystic infarct (**Web Image 30.7**).

M/E The features are as under:

1. Initially, there is eosinophilic neuronal necrosis and lipid vacuolisation produced by breakdown of myelin. Simultaneously, the infarcted area is infiltrated by neutrophils.
2. After the first 2-3 days, there is progressive invasion by macrophages and there is astrocytic and vascular proliferation.
3. In the following weeks to months, the macrophages clear away the necrotic debris by phagocytosis followed by reactive astrocytosis, often with little fine fibrosis (**Web Image 30.8**).
4. Ultimately, after 3-4 months an old cystic infarct is formed which shows a cyst traversed by small blood vessels and has peripheral fibrillary gliosis. Small cavitory infarcts are called *lacunar infarcts* and are commonly found as a complication of systemic hypertension.

B. INTRACRANIAL HAEMORRHAGE (p. 881)

Haemorrhage into the brain may be traumatic, non-traumatic, or spontaneous. There are two main types of spontaneous intracranial haemorrhage:

1. Intracerebral haemorrhage, which is usually of hypertensive origin.
2. Subarachnoid haemorrhage, which is commonly aneurysmal in origin.

In addition to hypertension and rupture of an aneurysm, other causes of spontaneous intracranial haemorrhage include vascular malformations which produce mixed intracerebral and subarachnoid haemorrhage, haemorrhagic diathesis and haemorrhage into tumours.

Intracerebral Haemorrhage (p. 881)

Spontaneous intracerebral haemorrhage occurs mostly in patients of hypertension. Most hypertensives over middle age have microaneurysms in very small cerebral arteries in the brain tissue. Rupture of one of the numerous microaneurysms is believed to be the cause of intracerebral haemorrhage. Unlike subarachnoid haemorrhage, it is not common to have recurrent intracerebral haemorrhages.

About 40% of patients die during the first 3-4 days of haemorrhage, mostly from haemorrhage into the ventricles. The survivors tend to have haematoma that separates the tissue planes which is followed by resolution and development of an *apoplectic cyst* accompanied by loss of function.

G/A & M/E The haemorrhage consists of dark mass of clotted blood replacing brain parenchyma. The borders of the lesion are sharply-defined and have a narrow rim of partially necrotic parenchyma. Small ring haemorrhages in the Virchow-Robin space in the border zone are commonly present. Ipsilateral ventricles are distorted and compressed and may contain blood in their lumina.

Subarachnoid Haemorrhage (p. 882)

Haemorrhage into the subarachnoid space is most commonly caused by rupture of an aneurysm, and rarely, rupture of a vascular malformation.

Of the three types of aneurysms affecting the larger intracranial arteries—berry, mycotic and fusiform, berry aneurysms are most important and most common.

BERRY ANEURYSMS are sacular in appearance with rounded or lobulated bulge arising at the bifurcation of intracranial arteries and varying in size from 2 mm to 2 cm or more. They account for 95% of aneurysms which are liable to rupture.

In more than 85% cases of subarachnoid haemorrhage, the cause is massive and sudden bleeding from a berry aneurysm on or near the circle of Willis. The four most common sites are as under (**Web Image 30.9**):

1. In relation to anterior communicating artery.
2. At the origin of the posterior communicating artery from the stem of the internal carotid artery.
3. At the first major bifurcation of the middle cerebral artery.
4. At the bifurcation of the internal carotid into the middle and anterior cerebral arteries.

The remaining 15% cases of subarachnoid haemorrhage are the result of rupture in the posterior circulation, vascular malformations and rupture of mycotic aneurysms that occurs in the setting of bacterial endocarditis.

Initial mortality from first rupture is about 20-25%. Survivors recover completely but frequently suffer from recurrent episodes of fresh bleeding.

MORPHOLOGIC FEATURES. Rupture of a berry aneurysm frequently spreads haemorrhage throughout the subarachnoid space with rise in intracranial pressure and characteristic blood-stained CSF. An intracerebral haematoma may develop if the blood tracks into the brain parenchyma.

738 □ TRAUMA TO THE CNS (p. 882)

Trauma to the CNS constitutes an important cause of death and permanent disability in the modern world. Important causes of head injuries are: motor vehicle accidents, accidental falls and violence. Traumatic injuries to the CNS may result in three consequences which may occur in isolation or in combination:

A. Epidural Haematoma (p. 882)

Epidural haematoma is accumulation of blood between the dura and the skull following fracture of the skull, most commonly from rupture of middle meningeal artery. The haematoma expands rapidly since accumulating blood is arterial in origin and causes compression of the dura and flattening of underlying gyri (**Web Image 30.10**). The patient develops progressive loss of consciousness if haematoma is not drained early.

B. Subdural Haematoma (p. 882)

Subdural haematoma is accumulation of blood between the dura and subarachnoid and develops most often from rupture of veins which cross the surface convexities of the cerebral hemispheres. Subdural haematoma may be acute or chronic.

◆ **Acute subdural haematoma.** Acute subdural haematoma develops following trauma and consists of clotted blood, often in the frontoparietal region. There is no significant compression of gyri (**Web Image 30.11**).

◆ **Chronic subdural haematoma.** Chronic subdural haematoma occurs often with brain atrophy and less commonly following trauma. Chronic subdural haematoma is composed of liquid blood.

C. Parenchymal Brain Damage (p. 883)

Trauma to the CNS may result in damage to brain parenchyma and includes the following forms:

1. **Concussion.** Concussion is caused by closed head injury and is characterised by transient neurologic dysfunction and loss of consciousness. Invariably, there is complete neurologic recovery after some hours to days.
2. **Diffuse axonal injury.** Diffuse axonal injury is the most common cause of persistent coma or vegetative state following head injury. The underlying cause is sudden angular acceleration or deceleration resulting in widespread axonal shearing in the deep white matter of both the hemispheres.
3. **Contusions and lacerations.** Contusions and lacerations are the result of direct damage to the brain parenchyma, particularly cerebral hemispheres, as occurs in the soft tissues. Most often, they are the result of blunt trauma.
4. **Traumatic intracerebral haemorrhage.** On trauma to the CNS, the parenchymal vessels of the hemispheres may get torn and cause multiple intracerebral haemorrhages.
5. **Brain swelling.** Head injury may be accompanied by localised or diffuse brain swelling.

□ DEMYELINATING DISEASES (p. 883)

Demyelinating diseases are an important group of neurological disorders which have, in common, the pathologic features of focal or patchy destruction of myelin sheaths in the CNS accompanied by an inflammatory response. Demyelination may affect peripheral nervous system as well.

Pathologically and clinically, two demyelinating diseases are distinguished:

Multiple (Disseminated) Sclerosis (p. 883)

Multiple or disseminated sclerosis is the most common of the CNS demyelinating diseases. The usual age at onset is 20 to 40 years. The disease presents as recurrent attacks of focal neurologic disorder with predilection for involvement of the spinal cord, optic nerve and brain.

MORPHOLOGIC FEATURES. The pathologic hallmark is the presence of many scattered discrete areas of demyelination termed *plaques*.

G/A Plaques appear as grey-pink, swollen, sharply defined, usually bilaterally symmetric areas in the white matter.

M/E The features are as under:

1. In *active enlarging plaques*, the histologic features are accumulation of lymphocytes and macrophages around venules and at the plaque margin where demyelination is occurring.
2. In *old inactive plaques*, there is no perivascular inflammatory cell infiltrate and nearly total absence of oligodendrocytes.

Perivenous Encephalomyelitis (p. 884)

Perivenous encephalomyelitis includes two uncommon diseases:

◆ **Acute disseminated encephalomyelitis** occurs usually following viral infection (measles, mumps, rubella, chickenpox), whooping cough or vaccination.

◆ **Acute necrotising haemorrhagic leucoencephalitis** is a rare disease occurring more often after a respiratory infection.

□ MISCELLANEOUS DISEASES (p. 884)**Degenerative Diseases (p. 884)**

Degenerative diseases are disorders of unknown etiology and pathogenesis, characterised pathologically by progressive loss of CNS neurons and their processes accompanied by fibrillary astrocytosis. The identification of these diseases depends upon exclusion of diseases with known etiologies such as metabolic disturbances, vascular diseases, nutritional deficiencies or infection. A considerable proportion of degenerative disorders are genetic in origin, with either dominant or recessive inheritance; others occur sporadically. Family history is, of course, of great importance.

Some of the more common degenerative diseases are listed in **Web Table 30.3**. Two of the important examples are considered below.

ALZHEIMER'S DISEASE. Alzheimer's disease is the most common cause of dementia in the elderly. The condition occurs after 5th decade of life and its incidence progressively increases with advancing age. The exact cause is not known but a few factors are implicated in its etiology which include positive family history and deposition of A β amyloid derived from amyloid precursor protein (APP) forming *neuritic 'senile' plaques* and *neurofibrillary tangles*.

G/A The brain is often reduced in weight and bilaterally atrophic.

M/E The features are as follows:

- i) *Senile neuritic plaque* is the most conspicuous lesion and consists of focal area which has a central core containing A β amyloid.
- ii) *Neurofibrillary tangle* is a filamentous collection of neurofilaments and neurotubules within the cytoplasm of neurons.
- iii) *Amyloid angiopathy* is deposition of the same amyloid in the vessel wall which is deposited in the amyloid core of the plaque.
- iv) *Granulovacuolar degeneration* is presence of multiple, small intraneuronal cytoplasmic vacuoles, some of which contain one or more dark granules called *Hirano bodies*.

740 PARKINSONISM. Parkinsonism is a syndrome of chronic progressive disorder of motor function and is clinically characterised by tremors which are most conspicuous at rest and worsen with emotional stress; other features are rigidity and disordered gait and posture. Parkinsonism is caused by several degenerative diseases, the most important being Parkinson's disease; other causes of parkinsonism are trauma, toxic agents, and drugs (dopamine antagonists).

G/A The brain is atrophic or may be normal externally.

M/E The hallmark is depigmentation of substantia nigra and locus ceruleus due to loss of neuromelanin pigment from neurons and accumulation of neuromelanin pigment in the glial cells. Some of the residual neurons in these areas contain intracytoplasmic, eosinophilic, elongated inclusions called *Lewy bodies*.

Metabolic Diseases (p. 885)

Metabolic diseases of the CNS result from neurochemical disturbances which are either inherited or acquired.

A. HEREDITARY METABOLIC DISEASES:

1. Neuronal storage diseases—characterised by storage of a metabolic product in the neurons due to specific enzyme deficiency. Common examples are: gangliosidoses (e.g. Tay-Sachs disease or GM2 gangliosidosis), mucopolysaccharidoses, Gaucher's disease and Niemann-Pick disease).

2. Leucodystrophies—are diseases of white matter characterised by diffuse demyelination and gliosis. They are caused by deficiency of one of the enzymes required for formation and maintenance of myelin. That is why these conditions are also called *dysmyelinating diseases*.

3. Other inborn errors of metabolism—e.g. Wilson's disease (hepatolenticular degeneration), glycogen-storage diseases, phenylketonuria and galactosaemia.

B. ACQUIRED METABOLIC DISEASES:

1. Anoxic-ischaemic encephalopathy
2. Hypoglycaemic encephalopathy
3. Hyperglycaemic coma
4. Acute hepatic encephalopathy (Reye's syndrome)
5. Chronic hepatic encephalopathy
6. Kernicterus
7. Uraemic encephalopathy
8. Encephalopathy due to electrolyte and endocrine disturbances.

Nutritional Diseases (p. 886)

Neurologic disorders may be caused by malnutrition from lack of adequate diet in many developing countries and many poor socio-economic groups. In the United States and Europe, however, nutritionally-induced disease is chiefly found in association with chronic alcoholism or due to defect in absorption, transport or metabolism of dietary nutrients.

Some of the common neurologic diseases included in the category of deficiency diseases are as under:

1. Wernicke's encephalopathy and Korsakoff's psychosis (vitamin B₁ or thiamine deficiency).
2. Subacute combined degeneration of the spinal cord (vitamin B₁₂ deficiency).
3. Folic acid deficiency.
4. Spinocerebellar syndrome (vitamin E deficiency).
5. Pellagra (niacin deficiency).
6. Alcoholic cerebellar degeneration.

□ TUMOURS OF THE CNS (p. 886)

Tumours of the CNS may originate in the brain or spinal cord (primary tumours), or may spread to the brain from another primary site of cancer (metastatic tumours). More than one-quarter of the CNS tumours are secondary metastases arising in patients undergoing treatment for systemic cancer. Primary CNS tumours are the second commonest form of cancer in infants and children under the age of 15 years, exceeded in frequency only by leukaemia. Both benign and malignant CNS tumours are capable of producing neurologic impairment depending upon their site.

Primary CNS tumours or intracranial tumours include: tumours arising from *constituent cells of the brain* (with the sole exception of microglial cells) and from *the supporting tissues*. Childhood brain tumours arise from more primitive cells (e.g. neuroblastoma, medulloblastoma).

A classification of intracranial tumours abbreviated from the WHO classification is given in **Web Table 30.4**. The anatomic distribution of common intracranial tumours is illustrated in **Web Image 30.12**.

GLIOMAS (p. 886)

The term glioma is used for all tumours arising from neuroglia, or more precisely, from neuroectodermal epithelial tissue. Gliomas are the most common of the primary CNS tumours and collectively account for 40% of all intracranial tumours. They include tumours arising:

- ◆ from astrocytes (astrocytomas and glioblastoma multiforme);
- ◆ from oligodendrocytes (oligodendroglioma);
- ◆ from ependyma (ependymoma); and
- ◆ from choroid plexus (choroid plexus papilloma).

Gliomas are disseminated to other parts of the CNS by CSF but they rarely ever metastasise beyond the CNS.

Astrocytomas (p. 887)

Astrocytomas are the most common type of gliomas. In general, they are found in the late middle life with a peak in 6th decade of life. They occur predominantly in the cerebral hemispheres, and occasionally in the spinal cord.

The diagnosis of various types of astrocytomas can be generally made by routine H & E morphology but in difficult situations and poorly differentiated cases, immunohistochemical staining with glial fibrillary protein (GFAP) or by electron microscopic demonstration of glial filaments can be done.

MORPHOLOGIC FEATURES. Pathologically, astrocytomas have been conventionally divided into 3 progressive histologic grades: fibrillary (most common), gemistocytic and protoplasmic. However, currently WHO classification of astrocytomas is widely used which divides them into 4 grades from grade I (low grade) to grade IV (glioblastoma multiforme) as under.

WHO GRADE I ASTROCYTOMA. Also called as diffuse astrocytoma, it is a low-grade tumour having good prognosis and includes special histologic entities which mainly occur in children as under:

- i) **Juvenile pilocytic astrocytoma.** It occur in children and young adults in the cerebellum, third ventricle and optic nerve pathway.
- ii) **Pleomorphic xanthoastrocytoma.** It looks histologically pleomorphic and alarming but has favourable prognosis.

WHO GRADE II (WELL-DIFFERENTIATED) ASTROCYTOMA. It is also called as fibrillary astrocytoma and is the most common form of glioma occurring in 3rd to 4th decades of life.

G/A It is a poorly defined, grey-white tumour of variable size. The tumour distorts the underlying brain tissue and merges with the surrounding tissue.

742 M/E It is composed of well-differentiated astrocytes separated by variable amount of fibrillary background of astrocytic processes. Based on the type of astrocytes, three subtypes are distinguished: *fibrillary*, *protoplasmic* and *gemistocytic astrocytoma*.

WHO GRADE III (ANAPLASTIC) ASTROCYTOMA. It generally evolves from lower grade of astrocytoma.

G/A It may not be distinguishable from the low-grade astrocytoma.

M/E It contains features of anaplasia such as hypercellularity, pleomorphism, nuclear hyperchromatism and mitoses. Another characteristic feature of anaplastic variety of astrocytoma is the proliferation of vascular endothelium (**Web Image 30.13**).

WHO GRADE IV ASTROCYTOMA (GLIOBLASTOMA MULTIFORME).

Although its nomenclature means its origin from embryonal cells but now it is known that this tumour arises by neoplastic transformation of mature astrocytes. It is the most aggressive of astrocytomas.

G/A It shows variegated appearance, with some areas showing grey-white appearance while others are yellow and soft with foci of haemorrhages and necrosis.

M/E (Web Image 30.14): The features are as follows:

- i) It has highly anaplastic and cellular appearance. The cell types show marked variation consisting of fusiform cells, small poorly-differentiated round cells, pleomorphic cells and giant cells. Mitoses are quite frequent and glial fibrils are scanty.
- ii) It shows areas of tumour necrosis around which tumour cells may form pseudopalisading.
- iii) Microvascular endothelial proliferation is marked.

Oligodendroglioma (p. 888)

Oligodendroglioma is an uncommon glioma of oligodendroglial origin and may develop in isolation or may be mixed with other glial cells. The tumour commonly presents in 3rd to 4th decades of life. It occurs in the cerebral hemispheres, most commonly in the frontal lobes or within the ventricles. X-ray examination and CT scan reveal a well-defined mass with numerous small foci of calcification.

G/A Oligodendroglioma is well-circumscribed, grey-white and gelatinous mass having cystic areas, foci of haemorrhages and calcification.

M/E The tumour is characterised by uniform cells with round to oval nuclei surrounded by a clear halo of cytoplasm and well-defined cell membranes. Tumour cells tend to cluster around the native neurons forming *satellitosis*. Typically, there are varying degree of endothelial cell hyperplasia and foci of calcification.

Ependymoma (p. 888)

Ependymoma is not an uncommon tumour, derived from the layer of epithelium that lines the ventricles and the central canal of the spinal cord. It occurs chiefly in children and young adults (below 20 years of age). Typically, it is encountered in the fourth ventricle (posterior fossa tumour). The usual biologic behaviour is of a slow-growing tumour over a period of years.

G/A Ependymoma is a well-demarcated tumour but complete surgical removal may not be possible due to close proximity to vital structures in the medulla and pons.

M/E The tumour is composed of uniform epithelial (ependymal) cells forming rosettes, canals and perivascular pseudorosettes. By light microscopy under high magnification, PTAH-positive structures, blepharoplasts,

representing basal bodies of cilia may be demonstrated in the cytoplasm of tumour cells (**Web Image 30.15**).

Two variants of ependymoma deserve special mention:

Myxopapillary ependymoma. It is a special variant of ependymoma which is common and occurs in adults. Characteristically, it occurs in the region of cauda equina and originates from the filum terminale. True to its name, it contains myxoid and papillary structures interspersed in the typical ependymal cells.

Subependymoma. It occurs as a small, asymptomatic, incidental solid nodule in the fourth and lateral ventricle of middle-aged or elderly patients. Areas of microcysts and calcification may be encountered.

Choroid Plexus Papilloma (*p. 889*)

Tumours derived from choroid plexus epithelium are uncommon intracranial tumours. They are found in the distribution of the choroid plexus. In children, they occur most frequently in the lateral ventricles, whereas in adults fourth ventricle is the most common site. They are invariably benign tumours and rarely ever undergo malignant transformation.

POORLY-DIFFERENTIATED AND EMBRYONAL TUMOURS (*p. 889*)

Medulloblastoma (*p. 889*)

Medulloblastoma is the most common variety of primitive neuroectodermal tumour. It comprises 25% of all childhood brain tumours but a quarter of cases occur in patients over the age of 20 years. The most common location is the cerebellum in the region of roof of fourth ventricle, in the midline of cerebellum, in the vermis, and in the cerebellar hemispheres. Medulloblastoma is a highly malignant tumour and spreads to local as well as to distant sites.

G/A The tumour typically protrudes into the fourth ventricle as a soft, grey-white mass or invades the surface of the cerebellum.

M/E Medulloblastoma is composed of small, poorly-differentiated cells with ill-defined cytoplasmic processes and a tendency to be arranged around blood vessels and occasionally forms pseudorosettes (Homer-Wright rosettes). Another characteristic of the tumour is differentiation into glial or neuronal elements.

OTHER PRIMARY INTRAPARENCHYMAL TUMOURS (*p. 889*)

Haemangioblastoma (*p. 889*)

Haemangioblastoma is a tumour of uncertain origin and constitutes about 2% of all intracranial tumours. It is seen more commonly in young adults and is commoner in males. It may occur sporadically or be a part of von Hippel-Lindau syndrome.

G/A The tumour is usually a circumscribed cystic mass with a mural nodule. The cyst contains haemorrhagic fluid.

M/E The features are as under:

- i) Large number of thin-walled blood vessels lined by plump endothelium.
- ii) Vascular spaces are separated by groups of polygonal lipid-laden foamy stromal cells.

Primary CNS Lymphoma (*p. 889*)

Lymphomas in the brain may occur as a part of disseminated non-Hodgkin's lymphoma or may be a primary CNS lymphoma. The incidence of the primary CNS lymphoma has shown a rising trend in patients of AIDS and

744 other immunosuppressed conditions. They occur in men above 5th decade of life. Primary CNS lymphoma has a poor prognosis.

Germ Cell Tumours (p. 890)

Rarely, germ cell tumours may occur in the brain, especially in children. Common locations are suprasellar region and pineal area. Some common examples of such tumours are germinoma (seminoma/dysgerminoma), teratoma and embryonal carcinoma. Morphologically, they are similar to their counterparts elsewhere.

TUMOURS OF MENINGES (p. 890)

The most common tumour arising from the pia-arachnoid is meningioma accounting for 20% of intracranial tumours.

Meningioma (p. 890)

Meningiomas arise from the cap cell layer of the arachnoid. Their most common sites are in the front half of the head and include: lateral cerebral convexities, midline along the falx cerebri adjacent to the major venous sinuses parasagittally, and olfactory groove. They are usually found in 2nd to 6th decades of life. Most meningiomas are benign and can be removed successfully.

G/A Meningioma is well-circumscribed, solid, spherical or hemispherical mass of varying size (1-10 cm in diameter). The tumour is generally firmly attached to the dura and indents the surface of the brain but rarely ever invades it (**Web Image 30.16**). The overlying bone usually shows hyperostosis. Cut surface of the tumour is firm and fibrous, sometimes with foci of calcification.

M/E Meningiomas are divided into 5 subtypes:

- 1. Meningotheliomatous (syncytial) meningioma.** This pattern of meningioma resembles the normal arachnoid cap cells. The tumour consists of solid masses of polygonal cells with poorly-defined cell membranes (i.e. syncytial appearance). The cells have round to oval, central nuclei with abundant, finely granular cytoplasm.
- 2. Fibrous (fibroblastic) meningioma.** A less frequent pattern is of a spindle-shaped fibroblastic tumour in which the tumour cells form parallel or interlacing bundles. Whorled pattern and psammoma bodies are less common features of this type.
- 3. Transitional (mixed) meningioma.** This pattern is characterised by a combination of cells with syncytial and fibroblastic features with conspicuous whorled pattern of tumour cells, often around central capillary-sized blood vessels. Some of the whorls contain psammoma bodies due to calcification of the central core of whorls (**Web Image 30.17**).
- 4. Angioblastic meningioma.** An angioblastic meningioma includes 2 patterns: *haemangioblastic pattern* resembling haemangioblastoma of the cerebellum, and *haemangiopericytic pattern* which is indistinguishable from haemangiopericytoma elsewhere in the body. Both types of angioblastic meningiomas have high rate of recurrences.
- 5. Anaplastic (malignant) meningioma.** Rarely, a meningioma may display features of anaplasia and invade the underlying brain or spinal cord. This pattern of meningioma is associated with extraneural metastases, mainly to the lungs.

METASTATIC TUMOURS (p. 891)

Approximately a quarter of intracranial tumours are metastatic tumours. The clinical features are like those of a primary brain tumour. Most common

primary tumours metastasising to the brain are: carcinomas of the lung, breast, skin (malignant melanoma), kidney and the gastrointestinal tract and choriocarcinoma. Infiltration from lymphoma and leukaemias may also occur.

G/A The metastatic deposits in the brain are usually multiple, sharply-defined masses at the junction of grey and white matter (**Web Image 30.18**). A less frequent pattern is carcinomatous meningitis or meningeal carcinomatosis in which there is presence of carcinomatous nodules on the surface of the brain and spinal cord, particularly encountered in carcinomas of the lung and breast.

M/E Metastatic tumours in the brain recapitulate the appearance of the primary tumour of origin with sharp line of demarcation from adjoining brain tissue. It is usually surrounded by a zone of oedema.

□ **NORMAL STRUCTURE** (p. 891)

The peripheral nervous system (PNS) consists of cranial and spinal nerves, sympathetic and parasympathetic autonomic nervous system and the peripheral ganglia. A peripheral nerve is surrounded by an outer layer of fibrous tissue, the *epineurium*. Each nerve is made of several fascicles enclosed in multilayered membrane of flattened cells, the *perineurium*. Each fascicle is composed of bundles of connective tissue, the *endoneurium*. There are 2 main types of nerve fibres or axons comprising a peripheral nerve—myelinated and non-myelinated.

□ **PATHOLOGIC REACTIONS TO INJURY** (p. 891)

The pathologic reactions of the PNS in response to injury may be in the form of one of the types of degenerations causing *peripheral neuropathy* or formation of a *traumatic neuroma*. There are 3 main types of degenerative processes in the PNS—(**Web Image 30.19**):

WALLERIAN DEGENERATION. Wallerian degeneration occurs after transection of the axon which may be as a result of knife wounds, compression, traction and ischaemia. Following transection, initially there is accumulation of organelles in the proximal and distal ends of the transection sites. Subsequently, the axon and myelin sheath distal to the transection site undergo disintegration upto the next node of Ranvier, followed by phagocytosis.

AXONAL DEGENERATION. In axonal degeneration, degeneration of the axon begins at the peripheral terminal and proceeds backward towards the nerve cell body. The cell body often undergoes chromatolysis. There is Schwann cell proliferation in the region of axonal degeneration. The loss of axonal integrity occurs, probably as a result of some primary metabolic disturbance within the axon itself.

SEGMENTAL DEMYELINATION. Segmental demyelination is similar to demyelination within the brain. Segmental demyelination is loss of myelin of the segment between two consecutive nodes of Ranvier, leaving a denuded axon segment. The axon, however, remains intact. Schwann cell proliferation generally accompanies demyelination. This results in remyelination of the affected axon.

TRAUMATIC NEUROMA. Normally, the injured axon of a peripheral nerve regenerates at the rate of approximately 1 mm per day. However, if the process of regeneration is hampered due to an interposed haematoma or fibrous scar, the axonal sprouts together with Schwann cells and fibroblasts form a peripheral mass called as traumatic or stump neuroma.

746 PERIPHERAL NEUROPATHY (p. 892)

Peripheral neuropathy is the term used for disorders of the peripheral nerves of any cause. It may be polyneuropathy, mononeuropathy multiplex, and mononeuropathy.

◆ **Polyneuropathy** is characteristically symmetrical with noticeable sensory features such as tingling, pricking, burning sensation or dysaesthesia in feet and toes. Motor features in the form of muscle weakness and loss of tendon reflexes may be present.

M/E Polyneuropathy may be the result of axonal degeneration (axonopathy) or segmental demyelination (demyelinating polyneuropathy). In each type, acute, subacute and chronic forms are distinguished. *Guillain-Barré syndrome* is the classical example of acute demyelinating polyneuropathy which has probably an autoimmune etiology.

◆ **Mononeuropathy multiplex or multifocal neuropathy** is defined as simultaneous or sequential multifocal involvement of nerve trunks which are not in continuity. The involvement may be partial or complete and may evolve over days or years. Multifocal neuropathy represents part of spectrum of chronic acquired demyelinating neuropathy.

◆ **Mononeuropathy**, on the other hand, is focal involvement of a single nerve. It is generally the result of local causes such as direct trauma, compression and entrapment.

□ NERVE SHEATH TUMOURS (p. 893)

Tumours of the peripheral nerves are commonly benign and include schwannoma (neurilemmoma) and neurofibroma. Both of them arise from Schwann cells but neurofibroma contains large amount of collagen. Rarely, their malignant counterpart, malignant peripheral nerve sheath tumour, develops particularly in patients with von Recklinghausen's neurofibromatosis.

Schwannomas (Neurilemmomas) (p. 893)

Schwannomas or neurilemmomas arise from cranial and spinal nerve roots. An *acoustic schwannoma* or *acoustic neuroma* is an intracranial schwannoma located within the internal auditory canal originating from vestibular portion of the acoustic nerve. *Intraspinal schwannomas* are found as intradural tumours in the thoracic region. In the peripheral nerves, they occur as solitary nodule on any sheathed sensory, motor, or autonomic nerve.

G/A A schwannoma is an encapsulated, solid, sometimes cystic, tumour that produces eccentric enlargement of the nerve root from where it arises.

M/E The tumour is composed of fibrocellular bundles forming whorled pattern. There are areas of dense and compact cellularity (*Antoni A pattern*) alternating with loose acellular areas (*Antoni B pattern*). Areas of Antoni A pattern show palisaded nuclei called *Verocay bodies* (**Web Image 30.20**). Nerve fibres are usually found stretched over the capsule but not within the tumour. Areas of degeneration contain haemosiderin and lipid-laden macrophages. Schwann cells characteristically express S-100 protein.

Neurofibromas and von Recklinghausen's Disease (p. 893)

Neurofibromas may occur as solitary, fusiform cutaneous tumour of a single nerve, but more often are multiple associated with von Recklinghausen's disease. Solitary neurofibroma is a tumour of adults but multiple neurofibromas or neurofibromatosis is a hereditary disorder with autosomal dominant inheritance. Solitary neurofibroma is generally asymptomatic but patients with von Recklinghausen's disease have a triad of features:

◆ Multiple cutaneous neurofibromas.

- ◆ Numerous pigmented skin lesions ('cafe au lait' spots).
- ◆ Pigmented iris hamartomas.

Neurofibromatosis type 1 is a genetic disorder having mutation in chromosome 17 while type 2 has mutation in chromosome 22.

G/A Neurofibroma is an unencapsulated tumour producing fusiform enlargement of the affected nerve. Neurofibromatosis in von Recklinghausen's disease is characterised by numerous nodules of varying size, seen along the small cutaneous nerves but may also be found in visceral branches of sympathetic nerves. Neurofibromatosis may involve a group of nerves or may occur as multiple, oval and irregular swellings along the length of a nerve (plexiform neurofibroma) (**Web Image 30.21**).

M/E A neurofibroma is composed of bundles and interlacing fascicles of delicate and elongated spindle-shaped cells having wavy nuclei. The cellular area is separated by loose collagen and mucoid material. Residual nerve fibres (neurites) may be demonstrable (**Web Image 30.22**). Histologic appearance of Antoni B pattern of schwannoma may be seen in neurofibroma and cause diagnostic difficulty.

Neurofibromas have tendency for local recurrences after excision. Neurilemmoma virtually never turns malignant, while sarcomatous transformation in neurofibroma, particularly in neurofibromatosis, is not unusual. It is estimated that about 3% of patients with von Recklinghausen's neurofibromatosis develop malignant transformation of one of the nodules.

The contrasting features to distinguish neurofibroma from schwannoma are listed in **Web Table 30.5**.

Malignant Peripheral Nerve Sheath Tumour (p. 894)

Malignant peripheral nerve sheath tumour (MPNST) is a poorly differentiated spindle cell sarcoma of the peripheral nerves occurring most often in adults. The tumour may arise *de novo* or from malignant transformation of a pre-existing neurofibroma than a schwannoma, generally at an early age (20-40 years). About 50% of the tumours are seen in patients with neurofibromatosis type 1 with chromosomal deletion 17p and *p53* gene mutations, while some develop at sites of previous irradiation.

G/A The tumour appears as an unencapsulated fusiform enlargement of a nerve.

M/E The tumour has the general appearance of tumour cells resembling a fibrosarcoma. The tumour has frequent mitosis and areas of necrosis. *Triton tumour* is the name used for MPNST which has areas of poorly-differentiated rhabdomyosarcoma, cartilage and bone.

Epithelioid MPNST has plump cells resembling epithelioid cells and is positive for HMB-45 immunostain.

◆ SELF ASSESSMENT

1. **Astrocytic processes can be demonstrated by:**
 - A. Reticulin stain
 - B. Phosphotungstic acid haematoxylin (PTAH)
 - C. Periodic acid Schiff (PAS)
 - D. van Gieson
2. **Normally, the most numerous of the cells in the central nervous system are:**

A. Astrocytes	B. Neurons
C. Oligodendrocytes	D. Microglia

3. **Arnold-Chiari malformation consists of the following except:**
 - A. Elongation of the medulla with part of 4th ventricle
 - B. S-shaped bend in the medulla
 - C. Encephalocele
 - D. Lengthening and herniation of cerebellar vermix
4. **Secondary hydrocephalus has the following features except:**
 - A. There is compensatory increase of CSF
 - B. It occurs due to loss of neural tissue
 - C. There is increased intracranial pressure
 - D. Common causes are cerebral atrophy and infarction
5. **The most common route of spread of infection to the brain is:**
 - A. Via venous route
 - B. Via arterial route
 - C. Via lymphatics
 - D. Along nerves
6. **Glucose content of CSF is unaltered in the following type of meningitis:**
 - A. Acute pyogenic meningitis
 - B. Acute viral meningitis
 - C. Cryptococcal meningitis
 - D. Tuberculous meningitis
7. **The following viral infection of the brain produces intracytoplasmic inclusions:**
 - A. Herpes simplex virus
 - B. Cytomegalovirus
 - C. Rabies virus
 - D. Enteroviruses
8. **The etiologic agent for Creutzfeldt-Jakob disease (CJD) is as under:**
 - A. HIV
 - B. JC virus
 - C. Prions
 - D. Zoster-varicella virus
9. **The lowest limit of critical level of systolic pressure upto which the brain continues to be perfused is:**
 - A. 70 mmHg
 - B. 60 mmHg
 - C. 50 mmHg
 - D. 40 mmHg
10. **Subarachnoid haemorrhage results most often from the following:**
 - A. Hypertension
 - B. Aneurysm
 - C. Vascular malformation
 - D. Bleeding diathesis
11. **Acute subdural haematoma has the following features except:**
 - A. Blood is of venous origin
 - B. Accumulated blood is in liquid form
 - C. No significant compression of gyri
 - D. Symptoms develop slowly
12. **Neuritic plaques are seen in the brain in:**
 - A. Multiple sclerosis
 - B. Alzheimer's disease
 - C. Parkinsonism
 - D. Perivenous encephalomyelitis
13. **Primary CNS tumours may arise from the following constituent cells except:**
 - A. Neuroglia
 - B. Microglia
 - C. Neurons
 - D. Meninges
14. **Out of the following, the most common tumour in children is:**
 - A. Ewing's sarcoma
 - B. Neuroblastoma
 - C. Glioma
 - D. Embryonal rhabdomyosarcoma
15. **Astrocytoma occurring in children is commonly:**
 - A. Fibrillary
 - B. Pilocytic
 - C. Anaplastic
 - D. Glioblastoma multiforme
16. **Small foci of calcification are frequently seen on X-ray of the following glioma:**
 - A. Ependymoma
 - B. Oligodendroglioma
 - C. Astrocytoma
 - D. Choroid plexus papilloma

17. Myxopapillary ependymoma characteristically occurs at the following location:
 A. Lateral ventricles
 B. Fourth ventricle
 C. Third ventricle
 D. Filum terminale
18. The following brain tumour has a tendency to metastasise by haematogenous route:
 A. Anaplastic astrocytoma
 B. Glioblastoma multiforme
 C. Medulloblastoma
 D. Ependymoma
19. The cell of origin of meningioma is:
 A. Dura mater
 B. Arachnoid cap cell layer
 C. Pia mater
 D. Choroid plexus
20. Transection of axon is followed by:
 A. Wallerian degeneration
 B. Axonal degeneration
 C. Segmental degeneration
 D. Hypertrophy of Schwann cells
21. Angiocentric growth pattern is typical of following CNS tumour:
 A. Glioblastoma multiforme
 B. Haemangioblastoma
 C. Primary CNS lymphoma
 D. Medulloblastoma
22. The most common cause of dementia is:
 A. Parkinsonism
 B. Alzheimer's disease
 C. Multiple sclerosis
 D. Perivenous encephalomyelitis
23. Common cause of meningitis in neonates with neural tube defects is:
 A. *Escherichia coli*
 B. *Neisseria meningitidis*
 C. *Streptococcus pneumoniae*
 D. *Staphylococcus aureus*
24. Progressive multifocal leucoencephalopathy is caused by:
 A. HIV
 B. CMV
 C. JC virus
 D. Prions
25. Characteristic inclusions seen in parkinsonism are:
 A. Hirano bodies
 B. Neurofibrillary tangle
 C. Negri bodies
 D. Lewy bodies
26. Type of meningioma associated with extraneural metastasis:
 A. Syncytial meningioma
 B. Fibrous meningioma
 C. Anaplastic meningioma
 D. Angioblastic meningioma
27. Which of the following is *not true* about a schwannoma:
 A. Unencapsulated
 B. Antoni A pattern
 C. Antoni B pattern
 D. Verocay bodies

KEY

- | | | | |
|--------|--------|--------|--------|
| 1 = B | 2 = C | 3 = C | 4 = C |
| 5 = B | 6 = B | 7 = C | 8 = C |
| 9 = C | 10 = B | 11 = B | 12 = B |
| 13 = B | 14 = B | 15 = B | 16 = B |
| 17 = D | 18 = C | 19 = B | 20 = A |
| 21 = C | 22 = B | 23 = A | 24 = C |
| 25 = D | 26 = C | 27 = A | |



Normal Values

WEIGHTS AND MEASUREMENTS OF NORMAL ORGANS (p. 896)

A comprehensive list of generally accepted normal weights and measurements of most of the normal organs in fully-developed, medium-sized individual and a normal healthy newborn are compiled in Table A-1.

Single value and value within brackets are indicative of the average figure for that organ. An alphabetic order has been followed.

TABLE A-1: Weights and Measurements of Normal Organs.

Organ	In Adults
Adrenal gland:	
Weight	4–5 gm
Brain:	
Weight (in males)	1400 gm
Weight (in females)	1250 gm
Volume of cerebrospinal fluid	120–150 ml
Heart:	
Weight (in males)	300–350 gm
Weight (in females)	250–300 gm
Thickness of right ventricular wall	0.3–0.5 cm
Thickness of left ventricular wall	1.3–1.5 cm
Circumference of mitral valve	10 cm
Circumference of aortic valve	7.5 cm
Circumference of pulmonary valve	8.5 cm
Circumference of tricuspid valve	12 cm
Volume of pericardial fluid	10–30 ml
Intestines:	
Length of duodenum	30 cm
Total length of small intestine	550–650 cm
Length of large intestine	150–170 cm
Kidneys:	
Weight each (in males)	150 gm
Weight each (in females)	135 gm
Liver:	
Weight (in males)	1400–1600 (1500) gm
Weight (in females)	1200–1400 (1300) gm
Lungs:	
Weight (right lung)	375–500 (450) gm
Weight (left lung)	325–450 (400) gm
Volume of pleural fluid	< 15 ml

Contd...

TABLE A-1: Weights and Measurements of Normal Organs.
(Contd...)

Organ	In Adults
Oesophagus:	
Length (cricoid cartilage to cardia)	25 cm
Distance from incisors to gastro-oesophageal junction	40 cm
Ovaries:	
Weight (each)	4–8 (6) gm
Pancreas:	
Total weight	60–100 (80) gm
Weight of endocrine pancreas	1–1.5 gm
Parotid glands:	
Weight (each)	30 gm
Pituitary gland (Hypophysis):	
Weight	500 mg
Placenta:	
Weight at term	400–600 gm
Prostate:	
Weight	20 gm
Spleen:	
Weight	125–175 (150) gm
Testis and epididymis:	
Weight each (in adults)	20–27 gm
Thymus:	
Weight	5–10 gm
Thyroid:	
Weight	15–40 gm
Uterus:	
Weight (in nonpregnant woman)	35–40 gm
Weight (in parous woman)	75–125 gm

LABORATORY VALUES OF CLINICAL SIGNIFICANCE (p. 897)

Currently, the concept of 'normal values' and 'normal ranges' is replaced by 'reference values' and 'reference limits' in which the variables for establishing the values for the reference population in a particular test are well defined. Reference ranges are valuable guidelines for the clinician.

The WHO as well as International Committee for Standardisation in Haematology (ICSH) have recommended adoption of SI system by the scientific community throughout world. However, conventional values continue to followed in many countries.

According to the SI system, the prefixes and conversion factors for metric units of length, weight and volume are given in Table A-2.

The laboratory values given here are divided into three sections: clinical chemistry of blood (Table A-3), other body fluids (Table A-4), and haematologic values (Table A-5). An alphabetic order has been followed.

TABLE A-2: Prefixes and Conversion Factors in SI System.

Prefix	Prefix Symbol	Factor
kilo-	k	10^3
—	l/g	1
deci-	d	10^{-1}
centi-	c	10^{-2}
milli-	m	10^{-3}
micro-	μ	10^{-6}
nano-	n	10^{-9}
pico-	p	10^{-12}
femto-	f	10^{-15}
atto-	a	10^{-18}

TABLE A-3: Clinical Chemistry of Blood.

Component	Fluid	Reference Value
Aminotransferases (transaminases)		
aspartate (AST, SGOT)	Serum	12-38 U/L
alanine (ALT, SGPT)	Serum	7-41 U/L
Bilirubin		
total	Serum	0.3-1.3 mg/dl
direct (conjugated)	Serum	0.1-0.4 mg/dl
indirect (unconjugated)	Serum	0.2-0.9 mg/dl
Calcium, total	Serum	8.7-10.2 mg/dl
Chloride (Cl^-)	Serum	102-109 mEq/L
Cholesterol		
total desirable for adults		<200 mg/dl
borderline high		200-239 mg/dl
high undesirable		≥ 240 mg/dl
LDL-cholesterol, desirable range		<130 mg/dl
borderline high		130-159 mg/dl
high undesirable		≥ 160 mg/dl
HDL-cholesterol, protective range		>60 mg/dl
low		<40 mg/dl
triglycerides		<160 mg/dl
CO ₂ content	Plasma	22-30 mEq/L (arterial)
Creatine kinase (CK), total		
males	Serum	51-294 U/L
females	Serum	39-238 IU/L
Creatine kinase-MB (CK-MB)	Serum	0-5.5 ng/ml
Creatinine	Serum	0.6-1.2 mg/dl
Electrophoresis, protein	Serum	See under proteins
Gamma-glutamyl transpeptidase (transferase) (γ -GT)	Serum	9-58 IU/L
Gases, arterial		
bicarbonate (HCO_3^-)	Whole blood	22-30 mEq/L
pH	Whole blood	7.35-7.45
P _{CO₂}	Whole blood	22-45 mmHg
P _{O₂}	Whole blood	72-104 mmHg

Contd...

TABLE A-3: Clinical Chemistry of Blood.
(Contd...)

Component	Fluid	Reference Value
Glucose (fasting)	Plasma	
normal		70-100 mg/dl
impaired fasting glucose (IFG)		101-125 mg/dl
diabetes mellitus		≥126 mg/dl
Glucose (2-hr post-prandial)	Plasma	
normal		<140 mg/dl
impaired glucose tolerance (IGT)		140-200 mg/dl
diabetes mellitus		>200 mg/dl
Haemoglobin A _{1c}	Whole blood	4-6%
Lactate dehydrogenase (LDH)	Serum	115-221 U/L
Lactate/pyruvate ratio		10/1
Lipase	Serum	3-43 U/L
Lipids	<i>See under cholesterol</i>	
Lipoproteins	Serum	0-30 mg/dl
Oxygen (% saturation)		
arterial blood	Whole blood	94-100%
venous blood	Whole blood	60-85%
pH	Blood	7.35-7.45
Phosphatases		
acid phosphatase	Serum	0-5.5 U/L
alkaline phosphatase	Serum	33-96 U/L
Phosphorus, inorganic	Serum	2.5-4.3 mg/dl
Potassium	Serum	3.5-5.0 mEq/L
Prostate specific antigen (PSA)	Serum	0-4.0 ng/ml
Proteins	Serum	
total		6.7-8.6 g/dl
albumin		3.5-5.5 g/dl (50-60%)
globulins		2.0-3.5 g/dl (40-50%)
A/G ratio		1.5-3 : 1
Renal blood flow		1200 ml/min
Rheumatoid factor	Serum	< 30 IU/ml
Sodium	Serum	136-146 mEq/L
Urea	Blood	20-40 mg/dl
Urea nitrogen (BUN)	Blood	7-20 mg/dl
Uric acid	Serum	
males		3.1-7.0 mg/dl
females		2.5-5.6 mg/dl

TABLE A-4: Other Body Fluids.

Component	Fluid	Reference Value
Cerebrospinal fluid (CSF)	CSF	
CSF volume		120-150 ml
CSF pressure		60-150 mm water
leucocytes		0-5 lymphocytes/μl
pH		7.31-7.34
glucose		40-70 mg/dl
proteins		20-50 mg/dl
FIGLU	24-hr urine	<3 mg/day
Glomerular filtration rate (GFR)	Urine	180 L/day (about 125 ml/min)

Contd...

TABLE A-4: Other Body Fluids.
(Contd...)

Component	Fluid	Reference Value
Seminal fluid	Semen	
liquefaction		Within 20 min
sperm morphology		>70% normal, mature spermatozoa
sperm motility		>60%
pH		>7.0 (average 7.7)
sperm count		60-150 million/ml
volume		1.5-5.0 ml
Stool examination	Stool	
coproporphyrin		400-1000 mg/day
faecal fat excretion		<6.0 g/day
occult blood		Negative (<2 ml blood /day)
urobilinogen		40-280 mg/day
Schilling's test (Intrinsic factor test)	24-hr urinary excretion	>10% of ingested dose of 'hot' vitamin B ₁₂
Urine examination	24-hr volume urine	600-1800 ml (variable)
pH		5.0-9.0
specific gravity, quantitative		Urine (random)
protein excretion	24-hr urine	<150 mg/day
protein, qualitative	Urine (random)	Negative
glucose excretion, quantitative	24-hr urine	50-300 mg/day
glucose, qualitative	Urine (random)	Negative
porphobilinogen	Urine (random)	Negative
urobilinogen	24-hr urine	1.0-3.5 mg/day
microalbuminuria (24 hour)		0-30 mg/24 hr (0-30 µg/mg creatinine)
Urobilinogen	Urine (random)	Present in 1: 20 dilution

TABLE A-5: Normal Haematologic Values.

Component	Fluid	Reference Value
Erythrocytes and Haemoglobin		
Erythrocyte count	Blood	
males		4.5-6.5 million/µl (mean 5.5 million/µl)
females		3.8-5.8 million/µl (mean 4.8 million/µl)
Erythrocyte diameter		6.7-7.7 µm (mean 7.2 µm)
Erythrocyte thickness		
peripheral		2.4 µm
central		1.0 µm
Erythrocyte indices	Blood	
(Absolute values)		
mean corpuscular haemoglobin (MCH)		27-32 pg

Contd...

TABLE A-5: Normal Haematologic Values.
(Contd...)

Component	Fluid	Reference Value
mean corpuscular volume (MCV)		77-93 fl
mean corpuscular haemoglobin concentration (MCHC)		30-35 g/dl
Erythrocyte life-span	Blood	120±30 days
Erythrocyte sedimentation rate (ESR)	Blood	
Westergren 1st hr, males		0-15 mm
females	0-20 mm	
Wintrobe, 1st hr, males		0-9 mm
females	0-20 mm	
Ferritin	Serum	
males		30-250 ng/ml
females		10-150 ng/ml
Haematocrit (PCV)	Blood	
males		40-54%
females		37-47%
Haptoglobin	Serum	60-270 mg/dl
Haemoglobin (Hb)		
adult haemoglobin (HbA)	Whole blood	
males		13.0-18.0 g/dl
females		11.5-16.5 g/dl
plasma Hb (quantitative)		0.5-5 mg/dl
haemoglobin A ₂ (HbA ₂)		1.5-3.5%
haemoglobin, foetal (HbF) in adults		<1%
HbF, children under 6 months		<5%
Iron, total	Serum	40-140 µg/dl
total iron binding capacity (TIBC)	Serum	250-406 µg/dl
iron saturation	Serum	20-45% (mean 33%)
Iron intake		10-15 mg/day
Iron loss		
males		0.5-1.0 mg/day
females		1-2 mg/day
Iron, total body content		
males		50 mg/kg body weight
females		35 mg/kg body weight
Iron, storage form (ferritin and haemosiderin)		30% of body iron
Osmotic fragility	Blood	
slight haemolysis		at 0.45 to 0.39 g/dl NaCl
complete haemolysis		at 0.33 to 0.36 g/dl NaCl
mean corpuscular fragility		0.4-0.45 g/dl NaCl
Reticulocytes	Blood	
adults		0.5-2.5%
infants		2-6%
Transferrin	Serum	200-400 mg/dl
Leucocytes		
Differential leucocyte count (DLC)	Blood film/ CBC counter	
P (polymorphs or neutrophils)		40-75% (2,000-7,500/µl)
L (lymphocytes)		20-50% (1,500-4,000/µl)

Contd...

TABLE A-5: Normal Haematologic Values.
(Contd...)

Component	Fluid	Reference Value
M (monocytes)		2-10% (200-800/ μ l)
E (eosinophils)		1-6% (40-400/ μ l)
B (basophils)		< 1% (10-100/ μ l)
Total leucocyte count (TLC)	Blood	
adults		4,000-11,000/ μ l
infants (full term, at birth)		10,000-25,000/ μ l
infants (1 year)		6,000-16,000/ μ l
Myelogram	Blood	
Fat/cell ratio		50:50
Myeloid/erythroid (M/E) ratio		2-4:1 (mean 3:1)
Myeloid series		30-45% (37.5%)
• Myeloblasts		0.1-3.5%
• Promyelocytes		0.5-5%
Erythroid series		10-15%
		(mean 12.5%)
Megakaryocytes		0.5%
Lymphocytes		5-20%
Plasma cells		\leq 3%
Reticulum cells		0.1-2%
Platelets and Coagulation		
Bleeding time (BT)	Prick blood	
Ivy's method		2-7 min
template method		2.5-9.5 min
Clot retraction time	Clotted blood	
qualitative		Visible in 60 min (complete in <24-hr)
quantitative		48-64% (55%)
Clotting time (CT)	Whole blood	
Lee and White method		4-9 min at 37°C
Euglobin lysis time		72 hr
Fibrinogen	Plasma	200-400 mg/dl
Fibrin split (or degradation) products (FSP or FDP)	Plasma	<10 μ g/ml
Partial thromboplastin time with kaolin (PTTK) or activated partial thromboplastin time (APTT)	Plasma	30-40 sec
Platelet count	Blood	150,000-400,000/ μ l
Prothrombin time (PT) (Quick's one-stage method)	Plasma	10-14 sec
Thrombin time (TT)	Plasma	<20 sec (control \pm 2 sec)



A

- AA protein, 55, 56, 57
- Abscess, 105
- Bartholin's, 603
 - brain, 29, 732
 - Brodie's, 694
 - cold, 434, 694
 - crypt, 659
 - liver, 517
 - lung, 396
 - pyaemic, 105
 - tubo-ovarian, 615
- Absolute values, 754
- Accumulations, intracellular, 24-26
- glycogen, 26
 - proteins, 26
- Acetyl choline receptors (AChRs), 488, 713
- Achalasia, 455
- Achondroplasia, 695
- Acid-base balance, 63
- Acinus, lung, 385
- Acoustic neuroma, 432, 746
- Acquired immunodeficiency syndrome (AIDS), 46-50
- Acrochordons, 604, 649
- Acromegaly, 661
- ACTH, 663
- Actinic keratosis, 650
- Actinomycosis, 121
- Activated partial thromboplastin time (APTT), 270
- Acute transforming viruses, 174
- Adaptations, cellular, 34-37
- Addison's disease, 665-66
- Addisonian anaemia, 246
- Adenocarcinoma, colon, 492-95
- Adenocarcinoma, kidney, 577-78
- Adenocarcinoma, oesophagus, 459
- Adenocarcinoma, stomach, 470-72
- Adenocarcinoma, prostate, 598-600
- Adenocarcinoma salivary gland, 452
- Adenolymphoma, 451
- Adenoma,
- adrenocortical, 666-67
 - bronchial, 418
 - cortical, kidney, 578
 - hepatocellular, 530
 - monomorphic, 451
 - parathyroid, 680
 - pituitary, 662-63
 - pleomorphic, 450-51
 - rectum, 491
 - thyroid, 675
 - tubular, 491
 - tubulovillous, 491
 - villoglandular, 491
 - villous, 491
- Adenoma-carcinoma sequence, colon, 493-94
- Adenomyosis, 612
- Adenosis, sclerosing, 631
- ADH, 660, 662
- Adhesion molecules, 16-17
- Adipose tissue, tumours of, 722
- Adnexal (appendageal) tumours, 652-53
- Adrenal gland, 663-68
- tumours of, 666-68
- Adrenocortical hyperfunction (hyperadrenalism), 664-65
- Adrenocortical insufficiency, 665-66
- Adrenogenital syndrome, 665
- Adult T cell leukaemia-lymphoma (ATLL), 174-75, 312
- Aeroembolism, 85
- Aging, cellular, 37-38
- Air-dried smears *versus* wet-dried smears, 220, 221
- Air pollution, 185
- AL protein, 55, 56, 57
- Albinism, 26
- Albright syndrome, 699
- Alcoholic hyalin, 23, 522
- Alcoholic liver disease and cirrhosis, 520-23
- Alcoholism, 187-88, 521
- Alpha 1-antitrypsin deficiency, cirrhosis in, 528
- emphysema, 398-99
- Alpha-foetoprotein (AFP), 181, 591
- Alpha-protease inhibitor, 398, 526
- Alport's syndrome, 565
- Alternate pathway disease, 554
- Alveolar soft part sarcoma, 724
- Alzheimer's disease, 739
- Ameloblastoma, 447-48
- Ames' test, 167-68
- Amniotic fluid embolism, 86
- Amyloidosis, 55-60
- primary, 57
 - secondary, 57-58
- Anaemia, aplastic, 261-62
- Anaemia, blood loss, 234
- Anaemia, chronic disorders, 240-41
- Anaemia, classification of, 233-34

- Anaemia, Cooley's, 259
 Anaemia, Fanconi's, 261
 Anaemia, general considerations, 230-34
 Anaemia, haemolytic, 247-61
 acquired (extracorporeal), 248-51
 autoimmune (AIHA), 248-50
 classification of, 247
 cold antibody, 249-50
 drug-induced AIHA, 250
 general features of, 247-48
 hereditary (intracorporeal), 251-61
 isoimmune, 250, 278
 microangiopathic, 250
 red cell morphology in, 232
 warm antibody, 248-49
 Anaemia, hypochromic, 234-38
 Anaemia, iron deficiency, 234-38
 Anaemia, Mediterranean, 259
 Anaemia, megaloblastic, 241-47
 Anaemia, microcytic hypochromic, 233, 234
 Anaemia, myelophthisic, 262
 Anaemia, normocytic and normochromic, 233
 Anaemia, pernicious, 245-46
 Anaemia, sideroblastic, 238-39
 Anal canal, tumours of, 495
 Anaplasia, 148
 Anasarca, 55
 Aneuploidy, 149, 205
 Aneurysmal bone cyst, 700
 Aneurysms, 335-37
 Berry, 335, 737
 Angiitis, 330-35
 Angina pectoris, 354-55
 Angiofibroma, nasopharyngeal, 434-35
 Angiogenesis, bacillary, 342
 Angiomyolipoma, 576
 Angioplasty, 381
 Angiosarcoma, 342
 Anitschkow cells, 363
 Ann Arbor staging, 307
 Annexin V, 31
 Anthracosis, 28, 405
 Anthrax, 133-34
 Anti-endothelial cell antibody, 332, 555
 Anti-GBM disease, 554
 Anti-neutrophilic cytoplasmic antibodies (ANCA), 555
 Anti-oncogenes, 161-62
 Antioxidants, 22
 Antoni A and B, 746
 Aortic atheroma *versus* syphilitic aortitis, 331
 Aortic valve, insufficiency, 372
 stenosis, 352, 371-72
 Apoptosis, 30-32
 Appendicitis, 485-86
 Appendix, 485-86
 Arachidonic acid metabolites, 98
 Argentaffin cells, 473
 Arias-Stella reaction, 611
 Armani-Ebstein lesions, 565
 Arnold-Chiari malformation, 729
 Arteriosclerosis, 323
 Arteriosclerosis, Mönckeberg's, 323
 Arteritis, 330-35
 Arthritis, gouty, 710-11
 osteoarthritis, 708
 rheumatoid, 708-10
 suppurative, 710
 tuberculous, 710
 Asbestos disease, 407-09
 Aschoff cells, 363
 Ascites, 59, 529
 Aspiration, bone marrow, 227
 Asthma, 401-02
 Astrocytoma, 741-42
 Atelectasis, 389
 Atheroma, 324, 329-30
 Atheromatous plaques, 329-30
 Atherosclerosis, 324-30
 Atmospheric pollutants, 185
 Atrial septal defect (ASD), 351
 Atrophy, 34-35
 brown, 28
 testicular, 587
 Atypical lymphocytes, 290
 Australia antigen, 511
 Autoimmune diseases, 52-55
 Autopsy pathology, 6
 Azotaemia, 547
- B**
- Bacterial diseases, 132-36
 Bacterial endocarditis, 367-70
 Bactericidal mechanisms, 96-97
 Balanitis xerotica obliterans, 596
 Balanoposthitis, 595
 Ballooning degeneration, 514
 Banding techniques, 204-05
 Banti's spleen (fibrocongestive splenomegaly), 72, 318
 Bantu's siderosis, 27
 Barr body, 204, 218
 Barrett's oesophagus, 457-58
 Bartholin's cyst and abscess, 603
 Basal cell carcinoma, 651-52
 BCG vaccination, 111

- BCL2, 163
 Bence Jones' proteins, 315
 Berger's disease, 562
 Beriberi, 198
 Berylliosis, 409
 Beta fibrillosis, 55
 Beta-amyloid protein, 56, 58
 Beta-catenin mechanism, 493
 Beta-2 microglobulin, 56, 58
 Bethesda system, 215, 609
 Biliary atresia, 507-08
 Biliary system, 533-38
 Bilirubin, 27, 504-05
 conjugated *versus* unconjugated, 504-06
 Bilirubin metabolism, 504
 Biotin, 200
 Birefringence, 59
 Bittner milk factor, 174, 634
 Blackwater fever, 142, 251
 Blast crisis in CML, 295
 Blastomas, 156, 209
 Bleeding disorders, 266-76
 Bleeding, GI, 495
 Blood group antigens and antibodies, 276
 Blood transfusion, 276-77
 complications of, 277
 Blood vessels, 322-43
 Bones, 692-707
 tumour-like lesions of, 699-701
 tumours of, 701-07
 Bone marrow, 226-28
 aspiration *versus* trephine, 227-28
 Botryoid rhabdomyosarcoma, 606, 723
 Botulism, 136
 Bowen's disease, 596, 650
 Bowenoid papulosis, 596
 Brain, metastatic tumours, 744-45
 Branchial cyst, 437
 BRCA gene, 162, 633
 Breast, 628-40
 cancer, 633-38
 fibrocystic change in, 629-31
 tumours of, 632-38
 Brenner's tumour, ovary, 620
 Broders' grading, 651
 Bronchiectasis, 402-03
 Bronchitis, chronic, 398-99
 Broncho-(lobular) pneumonia, 393-94
 versus lobar pneumonia, 394
 Bronchogenic carcinoma, 413-18
 Brown atrophy, heart, 28
 Brown induration, lung, 72
 Brown tumour of hyperparathyroidism, 679, 697
 Bubos, 133
 Buccal smear, 204, 218
 Budd-Chiari syndrome (hepatic vein thrombosis), 509
 Buerger's disease, 334
 Burkitt's lymphoma, 172, 311
 Bypass, coronary, 381
- C**
 Cadherins, 16, 153
 Caisson's disease, 85
 Calcific aortic stenosis, 352, 371
 Calcification, pathologic, 33-34
 Calcifying epithelioma of Malherbe, 652
 Calcinosis cutis, 648
 Calcitonin, 669, 677
 Calculi, gallbladder, 533-35
 Calculi, urinary, 574-75
 Call-Exner bodies, 622
 Callender classification, 429-30
 Callus formation, 126-27
 CAMs, 16-17
 Cancer, definition of, 145
 Cancer cervix, invasive, 25, 609-10
 Candidiasis, 136, 605
 Caplan's syndrome, 406
 Carcinoembryonic antigen (CEA), 181
 Carcinogenesis, 158-75
 biologic, 169-75
 chemical, 164-68
 molecular basis, 158-64
 physical, 168-69
 viral, 169-75
 Carcinoid heart disease, 372
 Carcinoid syndrome, 485
 Carcinoid tumour, 418, 484-85
 Carcinoma, acinic cell, 452
 Carcinoma, adenoid cystic, 452
 Carcinoma, adrenal cortex, 667
 Carcinoma, breast, 633-38
 Carcinoma, cervix, 609-10
 cytology of, 215-16, 607-09
 Carcinoma, colorectal, 492-95
 Carcinoma, embryonal, testis, 592-93
 Carcinoma, endometrium, 613-14
 Carcinoma, fibrolamellar, 532
 Carcinoma, gallbladder, 536-37
 Carcinoma, hepatocellular, 530-32
 Carcinoma *in situ*, 157
 breast, 634-35
 bronchus, 414
 cervix, 215, 607
 oral cavity, 443-44
 urinary bladder, 581
 Carcinoma, kidney, 577-78
 Carcinoma, liver, 530-32

- Carcinoma, lung, 413-18
- Carcinoma, mucoepidermoid, 451-52
- Carcinoma, nasopharyngeal, 435
- Carcinoma, oesophagus, 172, 458-59
- Carcinoma, oral cavity, 444
- Carcinoma, pancreas, 540-41
- Carcinoma, parathyroid, 680
- Carcinoma, penis, 596-97
- Carcinoma, prostate, 598-600
- Carcinoma, sinonasal, 434
- Carcinoma, skin, 650-52, 654-55
- Carcinoma, stomach, 470-72
- Carcinoma, thyroid, 675-78
- Carcinoma, transitional cell, 581-82
- Carcinoma, urinary bladder, 581-82
- Carcinoma, vagina, 606
- Carcinoma, vulva, 605
- Cardiac oedema, 67-68
- Cardiac transplantation, 382
- Cardiomyopathy, 375-78
- Caries, dental, 445-46
- Caries, spine, 694
- Carotid body tumour, 437
- Cartilage-forming tumours, 703-05
- Caruncle, urethral, 583
- Caseous necrosis, 30, 112
- Castleman's disease, 283
- Cat-scratch disease, 141
- Cavitary lesions of lung, 415
- CD markers, 42, 43, 287
- Cell aging, 37-38
- Cell cycle, 17-18
- Cell death, 20, 29
- Cell injury, 18-38
- Cellular adaptations, 34-37
- Cellular swelling, 22-23
- Cementum, 445
- Central nervous system (CNS), 727-45
- Cerebral infarction, 736
- Cerebral oedema, 69
- Cerebrospinal fluid (CSF), 729, 753
 - cytology of, 217
- Cerebrovascular disease, 734-37
- Cervical intraepithelial neoplasia (CIN), 215, 607
- Cervicitis, 606-07
- Cervix, 606-10
 - carcinoma of, 609-10
- Chalazion, 426
- Chancre, 119-20
- Charcot-Leyden crystals, 402
- Chemical carcinogenesis, 164-68
- Chemical mediators of inflammation, 97-100
- Chemodectoma, 437
- Chemotaxis, 95
- Chickenpox, 645
- Childhood tumours, 156, 209-10
- Chloasma, 26
- Cholangiocarcinoma, 532
- Cholangitis, 517
 - primary sclerosing, 524
- Cholecystitis, 535-36
- Cholelithiasis (gallstones), 533-35
- Cholestasis, 505-06
- Cholesterosis, 536
- Choline, 200
- Chondroma, 704
- Chondroblastoma, 704
- Chondromyxoid fibroma, 704
- Chondrosarcoma, 704-05
- Chordoma, 707
- Choriocarcinoma,
 - gestational, 625
 - nongestational, 622
 - testis, 593
 - versus mole, 625
- Choristoma, 146, 210
- Choroid plexus papilloma, 743
- Christmas disease, 273
- Chromaffin tumour, 667
- Chronic inflammation, 106-22
- Chronic ischaemic heart disease, 359-60
- Chronic lymphocytic leukaemia, 309-10
- Chronic myeloid leukaemia (CML), 294-96
- Chronic obstructive pulmonary disease (COPD), 397-403
- Chronic restrictive pulmonary disease, 403-13
- Chronic venous congestion (CVC), 71-72
- CIN, 215, 607
- Circle of Willis, 737
- Cirrhosis, liver, 520-27
- Clear cell sarcoma, 725
- Clear cell tumours, ovary, 620
- Clostridial disease, 135-36
- Clotting system, 79, 100, 268-69
- CNS tumours, 741-45
- Coagulation disorders, 272-75
- Coagulation system, 79, 100, 268-69
- Coagulation tests, 268
- Coagulative necrosis, 29
- Coal-workers' pneumoconiosis, 405-06
- Coarctation of aorta, 352
- Codman's triangle, 702
- Coeliac disease, 483
- Coeliac sprue, 483
- Coelomic epithelium,
 - ovarian tumours of, 618-20
- Cold agglutinin disease, 249
- Colitis, ulcerative, 477-79

- Collagen diseases, 52-55
 Collagen vascular disease, lung, 411-12
 Collapse lung, 389
 Colloid carcinoma, breast, 636
 Colorectal, polyps, 489-92
 Components, blood, 277-78
 Computers in pathology lab, 12
 Concentration and dilution tests, kidney, 547
 Conchoid bodies, 122
 Condyloma acuminatum, 596, 604
 Congenital heart diseases, 350-53
 Congestive heart failure (CHF), 347
 Congo red, 59
 Conjugated *versus* unconjugated bilirubin, 505-06
 Coronary artery disease (CAD), 324, 355-59
 Coronary syndromes, acute, 354
 Councilman (acidophil) body, 514
 Craniopharyngioma, 663
 Crescents, 558
 CREST syndrome, 54
 Creutzfeldt-Jakob disease (CJD), 734
 Crigler-Najjar syndrome, 506
 Crohn's disease, 477-79
 Crypt abscess, 479
 Cryptorchidism, 587-88
 CSF, source and circulation of, 729
 Curling's ulcers, 465
 Curschmann's spiral, 402
 Cushing's syndrome, 664
 Cyanmethaemoglobin method, 231
 Cystic diseases of kidney, 549-52
 Cystic fibrosis, pancreas, 538
 Cystic hygroma, 341, 437
 Cystic hyperplasia, endometrium, 613
 Cysticercosis, 142-43, 734
 Cystitis, 579-80
 Cystosarcoma phyllodes, 632-33
 Cysts,
 Bartholin's, 603
 bone, 700
 branchial (lymphoepithelial), 437
 dentigerous, 447
 dermoid, 437, 621
 echinococcal, 518-19
 epidermal, 125, 649
 follicular, 617
 ganglion, 712
 jaw, 446-47
 kidney, 549-52
 lateral cervical, 437
 luteal, 617
 lymphoepithelial, 437
 midline cervical, 436-37
 neck, 436-38
 odontogenic, 447
 pillar (trichilemmal and sebaceous), 650
 radicular, 446
 sebaceous, 650
 simple renal, 552
 thyroglossal, 436-37
 trichilemmal, 650
 Cytogenetics, 10, 204
 Cytohormonal evaluation, 213
 Cytokines, 17, 99
 Cytology, diagnostic, 212-25
 exfoliative, 213-20
 fine needle aspiration (FNAC), 220-23
 fluids, 216-18
 Pap smear, applications of, 213-14
- D**
- Dane particle, 511
 Darier-Pautrier abscess, 656
 Dawney cells, 290
 Decompression sickness, 85-86
 Degenerations, 22-24
 Degenerations, peripheral nervous system, 745-46
 Degenerative joint disease, 708-10
 Delayed hypersensitivity, 52, 110
 Demyelinating diseases, 738-39
 Dengue fever, 138
 Denver classification, 14
 DeQuervain's thyroiditis, 672
 Dermatitis (eczema), 642-43
 Dermatitis herpetiformis, 647
 Dermatofibrosarcoma protuberans, 656, 721
 Dermatomyositis-polymyositis, 54
 Dermatoses, 642-49
 Dermoid cyst ovary, 621
 Desmoid tumours, 720-21
 Desmoplasia, 150, 635
 Desmoplastic small cell tumour, 496
 Developmental defects, 217-18
 Diabetes mellitus, 681-87
 Diabetic ketoacidosis, 684-85
 Diabetic microangiopathy, 685
 Diabetic nephropathy, 564-65, 685
 Diabetic neuropathy, 685
 Diabetic retinopathy, 426-27, 685
 Diagnosis of cancer, 179-82
 Diet and cancer, 201
 Differentiation of neoplastic cells, 148
 Diphtheria, 434
 Disseminated intravascular coagulation (DIC), 275-76
 Disseminated sclerosis, 739
 Diverticulosis coli, 488
 DNA oncogenic viruses, 171-74

- DNA, structure of, 4, 14-15
- Donovan bodies, 134
- Down's syndrome, 205
- Downey cells, 290
- Dubin-Johnson syndrome, 506-07
- Dukes' staging, 495
- Duodenal ulcer, 465-69
- Dupuytren's contracture, 720
- Dwarfism,
 - achondroplasia, 695
 - hypothyroid, 669
 - pituitary, 662
- Dysfunctional uterine bleeding (DUB), 611
- Dysgerminoma ovary, 621-22
- Dyslipidaemia, 324-25
- Dysplasia, 37
 - bronchopulmonary, 388-89
 - cervical, 607
 - fibromuscular, artery, 337
- Dystrophic calcification, 33
- Dystrophy, muscular, 714

- E**
- Ear, 430-32
 - tumours and tumour-like lesions of, 431-32
- Eccrine tumours, 653
- Echinococcosis, 518-19
- Ectopia vesicae (exstrophy), 579
- Ectopic hormone production, 179
- Ectopic tubal pregnancy, 616
- Eczema, 642-43
- Effusions, pleural, 216-17, 419
- Electron microscope, 9
- Elephantiasis, 66
- Elliptocytosis, 252
- Emden-Meyerhof pathway, 230, 253
- Embolism, 81-86
- Embryoma, 532-33
- Embryonal carcinoma testis, 592-93
- Embryonal rhabdomyosarcoma, 606, 723
- Embryonal tumours, brain, 743-44
- Empyema, 398-401
- Empyema,
 - gallbladder, 536
 - thoracis, 419
- Encephalitis,
 - bacterial, 732
 - fungal, 734
 - HIV, 733
 - protozoal, 734
 - viral, 733
- Encephalocele, 728
- Encephalomyelitis, acute
 - disseminated, 739
- Encephalomyelitis, perivenous, 739
- Encephalopathy, hepatic, 508, 529
- Encephalopathy,
 - global ischaemic-hypoxic, 735-36
 - spongiform, 734
- Enchondroma, 704
- End-stage kidney, 562-63
- Endocarditis,
 - non-rheumatic, 366-70
 - rheumatic, 364-65
 - vegetations in, 364
- Endodermal sinus tumour,
 - ovary, 622
 - testis, 593
- Endometrioid tumours, 620
- Endometriosis, 612
- Endometritis, 611
- Endomyocardial biopsy, 381
- Enteric fever, 480-81
- Environmental chemicals, 190
- Ependymoma, 742-43
- Epididymo-orchitis, 588
- Epithelioid cells, 111-12
- Epithelioid sarcoma, 725
- Epstein-Barr virus, 172-73
- Epulis, 442
- Erdheim's disease, 336
- Erythema nodosum
 - leprosum (ENL), 117
- Erythropoiesis, 228-30
- Erythropoietin, 228-29
- Eumycetoma, 136
- Ewing's sarcoma, 706-07
- Extracellular matrix, 125
- Exudate *versus* transudate, 55
- Eye, 425-30

- F**
- FAB classification,
 - acute leukaemia, 300
 - myelodysplastic syndrome, 298-99
- Fabry's disease, 565
- Fallopian tube, 615-16
- Fallot's tetralogy, 352
- Familial polyposis coli syndrome, 492
- Fatty liver, 24-25, 522
- Fibrocystic change, breast, 629-31
- Fibrohistiocytic tumours, 721-22
- Fibroma, 719-20
- Fibromatosis, 720
- Fine needle aspiration cytology (FNAC), 220-23
- Flavonoids, 200-01
- Floppy valve syndrome, 372-73
- Flu, 139-40
 - bird, 139-40
 - swine, 140
- Fluorescent microscope, 8-9

- Fluorosis, skeletal, 698
 Fordyce's granules, 440
 Fracture healing, 126-27
 Free radicals, 21-22, 99
 Fungal diseases, 136-37
 Fungal infections, lungs, 397
 skin, 645
- G**
- Gallstones, 533-35
 Gamna-Gandy bodies, 72
 Ganglion cyst, 712
 Ganglioneuroma, 668
 Gangrene, 32-33
 Gastric analysis, 460-61
 Gastric canal, 460
 Gastric carcinoma, 470-72
 Gastric ulcer, 465-69
 benign *versus* malignant, 468
 versus duodenal ulcer, 465-69
 Gastrinoma, 687-88
 Gastritis, 462-65
 Gastrointestinal tract, 455-99
 Gaucher's disease, 208
 Genetic diseases, 203-09
 Germ cell tumours,
 ovary, 620-22
 testis, 591-95
 Ghon's complex, 112-13
 Giant cell tumour of bone, 705-06
 Giant cell tumour of tendon sheath,
 711-12
 Giant cells, 103-04
 Gigantism, 661
 Gilbert's syndrome, 506
 Gleason's staging, prostate, 600
 Glioblastoma multiforme, 742
 Gliomas, 741-43
 Glomerular basement membrane
 (GBM), 546
 Glomerular diseases, 552-65
 Glomerular injury, pathogenesis of,
 553-55
 Glomerulonephritis (GN), 552-63
 Glomerulosclerosis, 561
 diabetic, 564
 Glomus tumour (glomangioma), 341
 Glucose-6-phosphatedehydrogenase
 (G6PD) deficiency, 253-54
 Glucose tolerance test (GTT),
 686-87
 Glucosuria, 686
 alimentary (lag storage), 686
 renal, 686
 Gluten-sensitive enteropathy, 483
 Glycogen storage diseases, 207-08
 Glycosaminoglycans, 126
 Glycosylated Hb (Hb A1c), 687
- Goitre, 673-75
 Goodpasture's syndrome, 557
 Gout and pseudogout, 710-11
 G-proteins, 17
 Grading of tumours, 154, 719
 Granulomatous inflammation, 109
 actinomycosis, 121
 leprosy, 115-18
 sarcoidosis, 121-22
 syphilis, 119-20
 tuberculosis, 109-15
 Granulopoiesis, 284-85
 Granulosa cell tumour,
 ovary, 622-23
 Graves' disease, 669
 Growth factors, 160
 receptors for, 160-61
 Gynaecomastia, 631
- H**
- 5-Hydroxy tryptamine (HT), 98
 Haemangioblastoma, 743
 Haemangioendothelioma, 342
 Haemangioma, 340-41, 530
 Haemangiopericytoma, 342
 Haematemesis,
 of gastric origin, 469
 of oesophageal origin, 457, 529
 Haematin, 27
 Haematogenous spread of tumours,
 151-52
 Haematological values, 754-56
 Haematoma, 73
 dissecting, 336
 epidural, 738
 subdural, 738
 Haematopoiesis, 226
 Haematoxylin bodies of Gross, 367
 Haemochromatosis, 27, 524-25
 Haemodynamic derangements,
 71-90
 Haemoglobin, 231
 Haemoglobinopathies, 254-61
 Haemoglobinuria, 247
 cold, 249
 march, 250
 paroxysmal nocturnal (PNH), 251
 Haemolysis, general features of,
 247-48
 Haemolytic uraemic syndrome, 269,
 271
 Haemophilia, 272-73
 Haemoptysis, causes of, 417
 Haemorrhage, 73
 intracerebral, 737
 intracranial, 737
 subarachnoid, 737

- Haemorrhagic diatheses, 266-72
 - coagulation disorders, 272-76
 - Haemorrhagic disease of newborn (HDN), 278-79
 - Haemorrhoids, 489
 - Haemosiderosis, 27, 524-25
 - Haemostatic function, tests for, 266-65
 - Hair follicle, tumours of, 662
 - Hairy cell leukaemia, 311-12
 - Ham's test, 248, 251
 - Hamartoma, 146, 210
 - Hand-Schuller-Christian disease, 317
 - Hashimoto's thyroiditis, 670-72
 - HbsAg, 512
 - hCG, 591, 625
 - HDL, 325
 - Head injury, 738
 - Healing, 122-28
 - Heart, 346-84
 - blood supply of, 347
 - brown atrophy of, 28
 - congenital diseases of, 350-53
 - Heart failure cells, 72
 - Heat shock proteins, 17
 - Helicobacter pylori*, 169, 464, 466
 - Henoch-Schonlein's purpura, 269
 - Hepatic failure, 508
 - Hepatisation, lung, 392
 - Hepatitis, viral, 510-17
 - Hepatoblastoma, 532-33
 - Hepatocellular carcinoma, 530-32
 - Hepatorenal syndrome, 508
 - Hepatotoxicity, 519
 - Hereditary haemorrhagic telangiectasia, 269
 - Hereditary hyperbilirubinaemia, 506-07
 - Herpes virus, 140, 173, 645
 - Hirschsprung's disease, 487-88
 - Histiocytoma, malignant fibrous, 721-22
 - Histochemistry, 7-8
 - HIV, structure of, 46-47
 - HLA system, 44
 - Hodgkin's disease, 304-08
 - versus non-Hodgkin's lymphoma, 308
 - Howell-Jolly bodies, 232
 - Human herpes virus (HHV), 140, 173, 645
 - Human immunodeficiency virus (HIV), 46-47
 - Human papilloma virus (HPV), 171, 596, 608
 - Human T cell lymphotropic virus (HTLV), 174, 293
 - Hyaline membrane disease, 386-88
 - Hybridisation, *in situ*, 11
 - Hydatid disease liver, 518-19
 - Hydatidiform mole, 624
 - versus choriocarcinoma, 625
 - Hydrocephalus, 729-30
 - Hydronephrosis, 575-76
 - Hydroptic change, 22-23
 - Hydrostatic pressure, 64
 - Hyperaemia, 71
 - Hyperbilirubinaemia, 505-07
 - Hypercalcaemia, 33, 699
 - Hypercholesterolaemia, 324-25
 - Hyperglycaemia, 681-87
 - Hyperlipidaemia, 324-25
 - Hypernephroma, 577-78
 - Hyperparathyroidism, 679
 - Hyperpigmentation, 26
 - Hyperpituitarism, 661
 - Hyperplasia, 35-36
 - breast, epithelial, 630-31
 - endometrial, 612-13
 - prostate, 598
 - thyroid, primary, 669
 - Hyperprolactinaemia, 661
 - Hypersensitivity reactions, 50-52
 - Hypersplenism, 318
 - Hypertension, portal, 528-29
 - Hypertension, pulmonary, 389-91
 - Hypertension, systemic, 570-73
 - Hypertensive heart disease, 360-61
 - Hypertensive retinopathy, 427
 - Hypertensive vascular disease, 323
 - Hyperthyroidism, 669
 - Hypertrophy, 35
 - cardiac, 349-50
 - Hyperuricaemia, 575, 710-11
 - Hypoaldosteronism, 664-65
 - Hypoparathyroidism, 680
 - Hypopigmentation, 26
 - Hypopituitarism, 661-62
 - Hypothyroidism, 669-70
 - Hypoxic cell injury, 19-22
 - Hypoxic-ischaemic encephalopathy, 735-36
- I**
- Idiopathic pulmonary fibrosis, 412
 - Idiopathic thrombocytopenic purpura (ITP), 270-71
 - IgA nephropathy, 562
 - Immotile cilia syndrome, 402, 588
 - Immune complex disease, kidney, 553-54
 - Immunofluorescence, 8-9
 - Immunohistochemistry, 9-10
 - Immunologic lung disease, 409-10
 - Immunology of cancer, 176-78
 - Immunosurveillance of cancer, 176-78

- Immunopathology, 41-62
 Infarction, 88-90
 Infections, 131-44
 Infectious mononucleosis, 289-91
 Infestations, 141-43
 Inflammation, acute, 92-106
 Inflammation, chronic, 106-22
 granulomatous, 109-22
 Inflammatory bowel disease, 477-79
 Inflammatory cells, 101-04, 285-89
In situ hybridisation, 11
 Insulinoma, 687
 Integrins, 16
 Interferon, 17, 99
 Interleukin, 17, 99
 Intermediate filaments, 15
 Interstitial lung disease (ILD), 403-13
 Intestinal biopsy, 483-84
 Intestine, large, 487-95
 Intestine, small, 473-85
 Intracellular accumulations, 24-26
 Intratubular germ cell neoplasia, 591
 Intrinsic factor (IF), 241, 461
 Intussusception, 475
 Involucrum, 694
 Ionising radiation, 22, 182-83,
 204-05
 Iron metabolism, 234-35
 Irreversible cell injury, 20-21
 Ischaemia, 86-88
 Ischaemic bowel disease, 475-77
 Ischaemic brain damage, 735-36
 Ischaemic heart disease (IHD),
 353-59
 chronic, 359-60
 Islet cell tumours, 687-88
- J**
- Jamshidi needle, 227
 Janeway's spots, 370
 Jaundice, 27, 504-07
 Jaw, lumpy, 121
 cysts of, 446-47
 Joints, disease of, 707-12
 Jones' criteria, modified, 366
 Juvenile (retention) polyps, 480
- K**
- Kaposi's sarcoma, 173, 343
 Karyorrhexis, 20
 Kawasaki's disease, 334
 Keloid, 125
 Ketoacidosis, diabetic, 684-85
 Kidney, diseases of, 545-78
 short contracted, 572
 Kimmelstiel-Wilson lesions, 564
 Klinefelter syndrome, 205
 Koch's phenomenon, 111
- Krukenberg tumour, 152, 623-24
 Kulchitsky cells, 473
 Kviem test, 122
- L**
- Lactic dehydrogenase (LDH), 21, 359
 Langerhans' cell,
 histiocytosis, 317
 Langhans' giant cells, 102, 108
 Larynx, 435-36
 Laser microdissection, 12
 LE cell phenomenon, 53
 Lead poisoning, 188-89
 Legionnaire's disease, 395
 Leiomyoma, 614-15
 Leiomyosarcoma, 615
 Lepra reaction, 117
 Lepromin test, 117
 Leprosy, 115-18
 Lethal midline granuloma, 312, 433
 Letterer Siwe disease, 317
 Leucocytes in health and disease,
 283-89
 Leucocytosis, 286-89
 Leucoerythroblastic reaction, 262
 Leucopenia, 286-89
 Leucoplakia, oral cavity, 443-44
 Leukaemias,
 acute lymphoid (ALL), 308-09
 acute myeloid (AML), 299-302
 chronic myeloid (CML), 294-96
 chronic lymphoid (CLL), 309-10
 hairy cell (HCL), 311-12
 Leukaemoid reaction, 291
 Lewis experiment, 93
 Leydig cell tumour, 594, 613
 Lichen planus, 440, 648
 Lines of Zahn, 80
 Linitis plastica, 471
 Lipofuscin, 28
 Lipogranuloma, 25, 522
 Lipoma, 722
 Lipoxygenase pathway, 98
 Liposarcoma, 722
 Liver, 500-33
 Liver cell necrosis, types of, 510
 Liver function tests, 501-03
 Löffler's endocarditis, 377
 Löffler's syndrome, 274, 377, 410
 Lukes-Collins classification, 303
 Lung, 385-419
 Lupus nephritis, 53, 563-64
 Lupus, nose, 433, 645
 Lupus vulgaris, 645
 Lymph nodes, normal and reactive,
 281-83
 Lymphadenitis, reactive, 281-83
 Lymphadenopathy, 282

- Lymphangioma, 341
 - Lymphatic obstruction, 66, 339-40
 - Lymphoblast, 285
 - Lymphocytes, 42-43, 287
 - Lymphocytosis, 287
 - Lymphoedema, 66, 339-40
 - Lymphomas, 292-317
 - CNS, 310
 - Hodgkin's, 304-08
 - non-Hodgkin's (NHL), 308-17
 - Lymphopenia, 287
 - Lymphopoiesis, 285
 - Lysosomal components, 98-99
 - Lysosomal storage diseases, 207-09
- M**
- M-band, 315
 - MacCallum's patch, 364
 - Macrophage, 43, 287
 - Madura foot, 136
 - Maffucci's syndrome, 704
 - Malabsorption syndrome, 482-84
 - Malakoplakia, 580
 - Malaria, 142
 - Malignant melanoma, 429-30, 654-55
 - Malignant peripheral nerve sheath tumour (MPNST), 747
 - Mallory hyaline, 23, 522
 - Maltoma, 297, 572-73
 - Mammary duct ectasia, 629
 - Mammary dysplasia, 629-31
 - Mantoux test, 111
 - Marasmus, 193
 - Marble bone disease, 695-96
 - Marfan syndrome, 336, 372
 - Marjolin's ulcer, 651
 - Mastitis, 628-29
 - Meckel's diverticulum, 473-74
 - Medial calcific sclerosis, 323-24
 - Medial necrosis, cystic, Erdheim's, 336
 - Medullary sponge kidney, 551
 - Megacolon, 487
 - Meigs' syndrome, 623
 - Melanoma, 429-30, 654-55
 - Melanosis coli, 488
 - MEN syndrome, 688
 - Mendelian disorders, 206-07
 - Ménétrier's disease, 465
 - Meningioma, 744-45
 - Meningitis, 730-32
 - CSF in, 753
 - Meningocele, 728
 - Mercury chloride nephropathy, 566-67
 - Mesonephroid tumour, ovary, 620
 - Mesothelioma, 420-21
 - Metaplasia, 36-37
 - Metastasis, 150-52
 - mechanisms of, 152-53
 - Metastatic calcification, 33-34
 - Michaelis-Gutmann bodies, 580
 - Microalbuminuria, 572
 - Microarrays, 12
 - Microangiopathy, thrombotic, kidney, 573
 - MicroRNAs, 164
 - Microsatellite instability, 494
 - Microscopy, 8-9
 - Mikulicz syndrome, 450
 - Milroy's disease, 66, 338
 - Minimal change disease, 558-59
 - Mitral stenosis and insufficiency, 370-71
 - Mitsuda reaction, 117
 - Mixed salivary tumour, 450-51
 - malignant, 452
 - MMTV, 174, 634
 - Molecular pathogenesis of cancer, 158-64
 - Molecular pathology, 10-11
 - Mönckeberg's arteriosclerosis, 323-24
 - Monocyte-macrophage series, 43, 102-03
 - Morphometry, 12
 - Mostofi classification, 581
 - Mucinous tumours of ovary, 619
 - Mucocele,
 - appendix, 486
 - gallbladder, 535
 - oral cavity, 432
 - Mucoepidermoid carcinoma, 451
 - Mucopolysaccharidoses, 208
 - Mucormycosis, 397
 - Multiple myeloma, 313-15
 - Mumps, 449
 - Munro abscess, 648
 - Muscular dystrophies, 714
 - Mutations, 206
 - Mutator genes, 163-64
 - Myasthenia gravis, 320, 713
 - Mycetoma, 136
 - Mycosis fungoides, 312, 656
 - Mycosis, superficial, skin, 645
 - Myeloblast, 270
 - Myelodysplastic syndrome (MDS), 298-99
 - Myelogram, 756
 - Myeloid metaplasia, 297-98
 - Myeloid series, 284
 - Myelolipoma, 677
 - Myeloma, 313-16
 - kidney, 569
 - multiple, 313-15
 - Myeloproliferative disorders, 294-302

- Myoblastoma, granular cell, 443, 724-25
- Myocardial infarction, 355-59
- Myocarditis, 373-75
- Myositis ossificans, 725
- Myxoedema, 69, 670
- N**
- Naevi, naevocellular, 653-54
- Nasopharyngeal carcinoma, 435
- Neck, 436-38
- Necrosis, 29-30
bridging, 514
zonal, liver, 510
- Necrotising enterocolitis, 136, 477
- Necrotising papillitis, 568
- Neonatal hepatitis, 507
- Neoplasia (*also see under* Tumours), 145-84
- Nephritic syndrome, 552
- Nephritis, hereditary, 565
- Nephritis, tubulointerstitial, 565, 567
- Nephroblastoma, 578
- Nephrocalcinosis, 569
- Nephrolithiasis, 574-75
- Nephroma, 576
- Nephropathy,
diabetic, 564-65
IgA, 562
lupus, 563-64
- Nephrosclerosis, 572-73
- Nephrotic syndrome, 553
- Nerve sheath tumours, 746-47
- Nervous system, 727-49
central, 727-45
peripheral, 745-47
- Neurilemmoma, 746
- Neuroblastoma, 667-68
- Neurofibroma, 746-47
- Neuropathy, peripheral, 746
- Neutrophil alkaline phosphatase (NAP), 291
- Neutrophilia, 286
- Neutrophils, 43, 101, 285-86
- Nexus, 16
- Niacin, 199
- Niemann-Pick disease, 208-09
- Nitric oxide mechanism, 99
- Nodular fasciitis, 720
- Nodule, vocal, 436
- Non-Hodgkin's lymphoma (NHL), 308-17
- Noncirrhotic portal fibrosis, 527-28
- Nonossifying fibroma, 700
- Normal values, 750-56
- Normoblasts, 237
- Nose and paranasal sinuses, 422-24
- Notochord, 707
- Nutmeg liver, 72
- Nutritional diseases, 191-201
- O**
- Oat cell carcinoma, lung, 416
- Obesity, 192-93
- Ochronosis, 26
- Odontogenic tumours, 447-49
- Oedema, 64-70
- Oesophagitis, 457-58
Barrett's, 457-58
- Oesophagus, 455-59
- Oligodendroglioma, 742
- Oncocytoma, 451
- Oncogenes, 160-61
- Oncogenic viruses, 169-75
DNA, 171-74
RNA, 174-75
- Oncomirs, 164
- Oncotic pressure, 64
- Opportunistic infections, 47, 49, 131
- Opsonisation, 96
- Oral soft tissues, 440-44
- Orchitis, 588-89
- Osler's nodes, 369
- Osmotic pressure, 64
- Osteitis deformans, 698-99
- Osteitis fibrosa cystica, 679, 697
- Osteoarthritis, 708-10
- Osteoblastic tumours, 701-03
- Osteoblastoma, 701
- Osteochondroma, 703
- Osteoclastoma, 705-06
- Osteodystrophy, renal, 697-98
- Osteoid osteoma, 701
- Osteomalacia, 196, 696
- Osteomyelitis, 693-94
- Osteonecrosis, avascular, 694
- Osteopetrosis, 695-96
- Osteophytes, 708
- Osteoporosis, 696-97
- Osteosarcoma, 701-03
- Otitis media, 431
- Ovalocytosis, 252
- Ovarian tumours, 617-24
- Ovaries, 616-24
- P**
- p53* gene, 161
- P-component, 56
- Paediatric diseases, 209-10
- Paediatric tumours, 156, 209-10
- Paget's disease,
of bone, 698-99
of nipple, 637
of vulva, 604-05
- Pancarditis, rheumatic, 364-65
- Pancreatitis, 539-40

- Pancytopenia, 247
 - Pannus formation, 709
 - Papanicolaou's (Pap) smear, 219-21
 - stain, 220
 - Papilloma,
 - breast, intraductal, 633
 - choroid plexus, 743
 - larynx, 436
 - mouth, 442
 - nose and paranasal sinuses, 433
 - skin, 649
 - urinary bladder, 581
 - Papilloma viruses, 171-72, 596, 608
 - Papovaviruses, 171-72
 - Pappenheimer bodies, 24
 - Paraneoplastic syndrome (PNS), 178-79
 - Parasitic diseases, 141-43
 - Parathyroid gland, 678-80
 - Paroxysmal nocturnal
 - haemoglobinuria (PNH), 251
 - Parvoviruses, 262
 - Patent ductus arteriosus (PDA), 351
 - Peliosis hepatis, 342, 509
 - Pellagra, 199
 - Pelvic inflammatory disease (PID), 615-16
 - Pemphigoid, 441, 647
 - Pemphigus, 440, 647
 - Penis, 595-97
 - Peptic ulcer, 465-69
 - Pericarditis, 378-70
 - Periodontal disease, 446
 - Peritoneum, 495-96
 - Peritonitis, 495-96
 - Permeability, vascular, 93-94
 - Pertussis, 134
 - Peutz-Jeghers syndrome, 490
 - Phagocytosis, 96-97
 - Pharynx, 434-35
 - Pheochromocytoma, 667
 - Philadelphia chromosome, 149, 294
 - Phyllodes tumour, 632-33
 - Physaliphorous cells, 707
 - Pigments, 26-29
 - Pilomatricoma, 652
 - Pituitary gland, 660-63
 - Placenta, 624-25
 - Plague, 132-33
 - Platelets, 78-79, 266
 - Pleomorphic adenoma,
 - salivary gland, 450-51
 - Pleura, 419-21
 - Pleuritis, (pleurisy), 419
 - Pneumoconiosis, 404-09
 - Pneumonias, 391-96
 - Pneumothorax, 420
 - Podocytes, 559
 - Poisoning,
 - aluminium phosphide, 190
 - carbon monoxide, 189
 - cyanide, 190
 - lead, 18-89
 - mercuric chloride, 566-67
 - Pollutants, 185
 - Polyarteritis nodosa (PAN), 332
 - Polycystic kidney disease, 550-51
 - adult, 550
 - infantile, 550-51
 - Polycystic ovary disease, 617
 - Polycythaemia vera, 296
 - Polyglandular autoimmune
 - syndrome, 688
 - Polymyositis-dermatomyositis, 54
 - Polyploidy, 205
 - Polyps,
 - antrochoanal, 433
 - aural, 431
 - cervical, 607
 - colorectal, 489-92
 - endometrial, 604
 - fibroepithelial, 604, 649
 - hamartomatous, 490
 - hyperplastic, 489-90
 - inflammatory, 490
 - juvenile, 490
 - lymphoid, 490
 - nasal, 433
 - metaplastic, 490
 - otic, 431
 - Peutz Jeghers, 490
 - rectal, 489-90
 - stomach, 469
 - Porphyryns, 28
 - Portal hypertension, 528-29
 - Pott's disease, 694
 - Primitive neuroectodermal tumour (PNET), 706-07
 - Prion proteins, 734
 - Prostate, 597-600
 - Pulmonary embolism, 82-83
 - Pyelonephritis, 53-55
 - Pyloric stenosis, 462
 - Pyruvate kinase (PK) deficiency, 254
- Q**
- Quick's one stage method, 268
 - Quinacrine banding, 204
- R**
- Radicals, free, 21-22, 99
 - Radiolysis, 22, 168-69
 - Rappaport classification, 288, 302
 - Raynaud's disease and
 - phenomenon, 334-35
 - RB* gene, 161, 430
 - REAL classification, 303

- Red blood cell, 228-30
 Red cell membrane, 229
 Reed-Sternberg (RS) cell, 305
 Reidel's struma, 672
 Reiter's syndrome, 55
 Renal failure, 533-35
 Renal function tests, 546-47
 Renal osteodystrophy, 697-98
 Reperfusion injury, 21-22
 Respiratory distress syndrome (RDS), 386-88
 Response-to-injury hypothesis, 327-28
 Reticulocyte, 228
 Retinoblastoma, 430
 Retinopathy,
 diabetic, 426, 685
 hypertensive, 427
 Reversible cell injury, 19-20
 Reye's syndrome, 508
 Rhabdomyosarcoma,
 embryonal, 606, 723
 Rhesus system, 276
 Rheumatic fever and RHD, 361-66
 Rheumatoid arthritis, 708-10
 Rheumatoid factor, 708
 Rhinosporidiosis, 433
 Ridley-Jopling classification, 117
 Rye classification, 304
- S**
- Salivary glands, 449-52
 Sarcoidosis, 121-22
 Sarcoma, definition, 145
 Sarcoma, botryoides, 606, 723
 SARS, 139-40
 Schaumann bodies, 122
 Schiller Duval body, 622
 Schilling test, 245
 Schwannoma, 746
 Selectins, 17
 Seminoma, testis, 591-92
 classic, 591-92
 spermatocytic, 592
 Sequestrum, 694
 Serous tumours of ovary, 618-19
 Sex chromatin, 218, 232
 Sex chromosomes, 14, 218
 Sex cord-stromal tumours,
 ovary, 622-23
 testis, 594
 Sezary syndrome, 312, 656
 Shock, 73-77
 Shock kidney, 77, 566
 Shock lung, 77,
 Shunts, heart, 351-52
 Sialadenitis, 449-50
 Sickle syndrome, 254-56
 Sideroblasts, 238
 Siderocytes, 238
 Signal transduction proteins, 160
 Silicosis, 406-07
 Sinus histiocytosis, 283
 Sjögren's syndrome, 54
 Skeletal muscles, structure of,
 712-14
 Skeletal system, 692-716
 Skin, 641-58
 dermatoses, 642-56
 tumours of, 649-56
 Small cell carcinoma lung, 416
 Small contracted kidney, 572
 Smoking, 185-86, 398, 412-13, 414
 Soft tissue tumours, 717-26
 Southern blot, 11
 Special stains, 7
 Spermatic granuloma, 589
 Spherocytosis, hereditary, 252
 Spina bifida, 204, 728
 Spleen, 317-19
 CVC of, 72, 318
 Splenectomy, effects of, 319
 Splenic rupture, 319
 Splenic tumour, 319
 Splenomegaly, 318
 congestive, 72, 318
 Squamous cell carcinoma,
 cervix, 609-10
 lung, 416
 oesophagus, 459
 oral cavity, 444
 penis, 596-97
 skin, 650-51
 vulva, 605
 Squamous metaplasia, 36, 414, 607
 Staging of tumours, 154, 719
 Enneking, 719
 AJC, 154
 TNM, 154
 Staphylococcal infections, 134-35
 Stein-Leventhal syndrome, 617
 Stevens-Johnson syndrome, 441
 Stomach, 459-73
 cancer of, 470-72
 tumours and tumour-like
 lesions of, 469-73
 Stomatocytosis, 252
 Stones, gallbladder, 533-35
 Stones, kidney, 574-75
 Storage diseases, 207-09
 Storiform pattern, 718, 721
 Streptococcal infections, 135
 Stroke syndrome, 734
 Struma ovarii, 621
 Struvite (staghorn) stone, 574
 Surgical pathology, protocol, 6-7
 Synovial sarcoma, 724

- Synovitis, villonodular, 711-12
 Syphilis, 119-20
 Systemic lupus erythematosus (SLE), 53-54
 kidneys in, 563-64
 heart in, 366
 lung in, 411
 Systemic sclerosis, 54
- T**
- Tabes dorsalis, 733
 Tabes mesenterica, 480
 Takayasu's arteritis, 333-34
 Tamm Horsfall protein, 315
 Telepathology, 12
 Telomerase, 37, 163
 Teratoma,
 ovary, 620-21
 sacrococcygeal, 210
 testis, 579-80
 Testicular tumours, 590-95
 Testis, 587-95
 Tetralogy of Fallot, 352
 Thalassaemias, 256-61
 Thrombocythaemia, essential, 297
 Thrombocytopenias, 269-71
 immune, 270-71
 thrombotic, 271
 Thrombocytosis, 271-72, 297
 Thrombophlebitis, 336-37
 Thrombophlebitis migrans, 339
 Thrombopoiesis, 266
 Thrombopoietin, 266
 Thrombosis, 77-81
 Thrombospondin, 79, 266
 Thrombotic microangiopathy,
 kidney, 573
 Thrombotic thrombocytopenic
 purpura (TTP), 271
 Thymoma, 320
 Thymus, 319-20
 Thyroid cancer, 675-78
 Thyroid gland, 668-78
 Thyroiditis, 670-72
 Thyrotoxicosis, 669
 Tobacco smoking, 185-86, 398,
 412-13, 414
 Trace elements, 201
 Transfusion of blood, 276-78
 complications of, 277-78
 Transitional cell carcinoma,
 nasopharynx, 435
 urinary bladder, 581-82
 Transplant rejection, 45
 Transthyretin, 55
 Transudate *versus* exudate, 65
 Trauma to brain, 738
 Trephine biopsy, 227
 Triphenyl tetrazolium chloride
 (TTC), 357
 Tropical pulmonary eosinophilia,
 288, 377, 410
 Troponins, cardiac, 359
 Trousseau's syndrome, 339
 Tubercle, 111-12
 Tuberculoma, brain, 732-33
 Tuberculosis, pulmonary, 109-15
 Tuberculous meningitis, 731-32
 Tubular necrosis, acute (ATN),
 565-67
 Tubulointerstitial disease, 567-70
 Tumoral calcinosis, 648
 Tumour lysis syndrome, 178
 Tumour markers, 181
 Tumours, soft tissue, 717-26
 Turner's syndrome, 205
 Typhoid fever, 480-81
 Typhoid ulcers, 480
- U**
- Ubiquitin, 17
 UICC staging, 154
 Ulcer,
 amoebic, 141
 Curling's, 465
 Cushing's, 465
 peptic, 465-66
 rodent, 651-52
 stress, 465-66
 Ulcerative colitis, 477-79
 Ultraviolet light, 168
 Urachal abnormalities, 579
 Uraemia, 547-49
 Urate nephrolithiasis, 575
 Urethral caruncle, 583
 Uric acid stones, 575
 Urinary bladder, 578-83
 tumours of, 581-83
 Urinary cytology, 216, 219
 Urinary tract infection (UTI), 567,
 579-82
 Urine analysis, 547
 Urolithiasis, 574-75
 Uropathy, obstructive, 573-75
 Urothelial tumours, 581-83
 Uveal melanoma, 429-30
- V**
- Vagina, 605-16
 tumours of, 605-06
 Vaginal smear, 213-16
 Vaginitis, 605
 Valvulitis, rheumatic, 364
 Varices, 457, 529
 Varicocele, 589-90
 Varicosities, 338

- Vascular disorders, haemostasis, 269
 - Vasculitis, 330-35
 - Vegetations, heart, 364, 367, 369
 - Veins, 337-39
 - Ventricular septal defect (VSD), 351
 - Verocay bodies, 746
 - Verrucae, heart, 364, 367, 369
 - Verrucous carcinoma, 444
 - Villous atrophy, 483
 - Viral hepatitis, 510-17
 - Virchow cells, 118
 - Virchow's sign, 472
 - Virtual microscopy, 12
 - Viruses and human cancer, 175
 - Viruses, diseases caused by, 137-41
 - Viruses, oncogenic,
 - DNA, 171-74
 - RNA, 174-75
 - Vitamins, 193-200
 - Vitellointestinal duct, 473-74
 - Vitiligo, 26
 - Vocal nodules, 436
 - Volvulus, 475
 - von Gierke's disease, 207
 - von Hippel-Lindau syndrome, 577
 - von Recklinghausen's disease, 746-47
 - von Willebrand's disease, 273-74
 - Vulva, 603-05
- W**
- Waldenstrom's
 - macroglobulinaemia, 315-16
 - Warthin's tumour, 451
 - Warts, 644
 - Wegener's granulomatosis, 332-33, 412
 - Weights and measurements,
 - normal organs, 750-51
 - Wilms' tumour, 578
 - Wilson's disease, 525
 - Working formulation for clinical usage, 303
 - Wound healing, 124-25
- X**
- X-linked disorders, 207
 - Xanthogranuloma, 721
 - Xanthomas, 656
 - Xeroderma pigmentosum, 164, 642
- Y**
- Y-chromatin, 218
 - Yellow atrophy, acute, 516-17
 - Yellow fever, 137-38
 - Yolk sac tumour,
 - ovary, 622
 - testis, 593
- Z**
- Zenker's degeneration, 23
 - Ziehl-Neelsen staining, 109, 15
 - Zollinger-Ellison syndrome, 687-88
 - Zonal necrosis, liver, 510
 - Zoster virus infection, 140, 173, 645