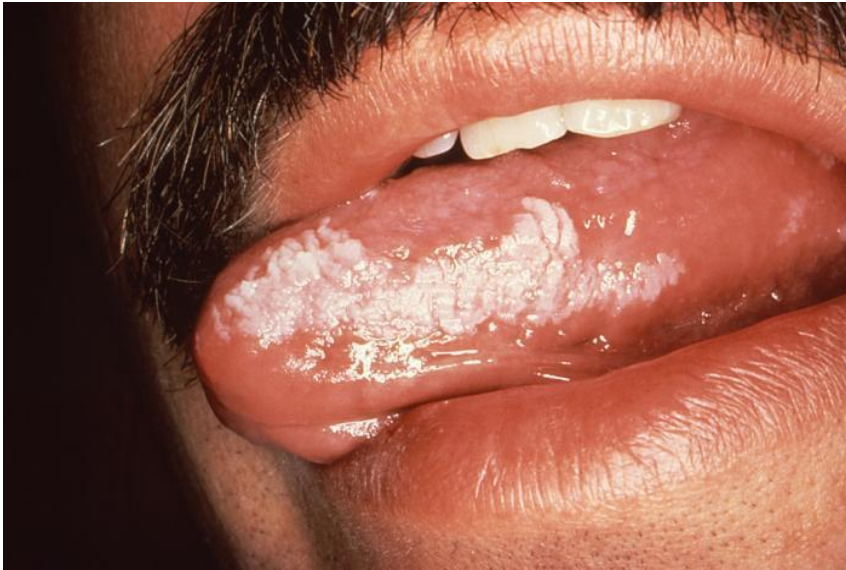

Revision spots

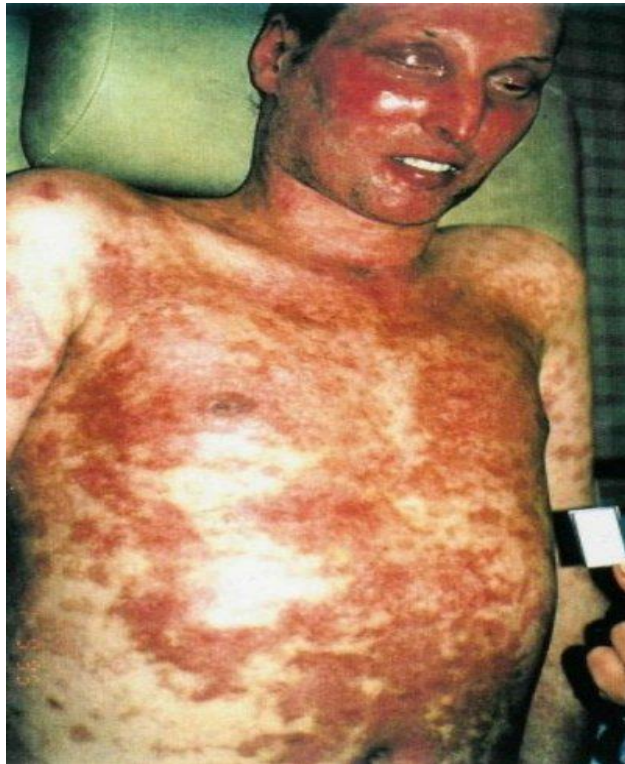Dr .Ndede.

A patient presents with the lesion shown. The lesions could not be scrapped off the tongue by a wooden spatula. Choose the false statement



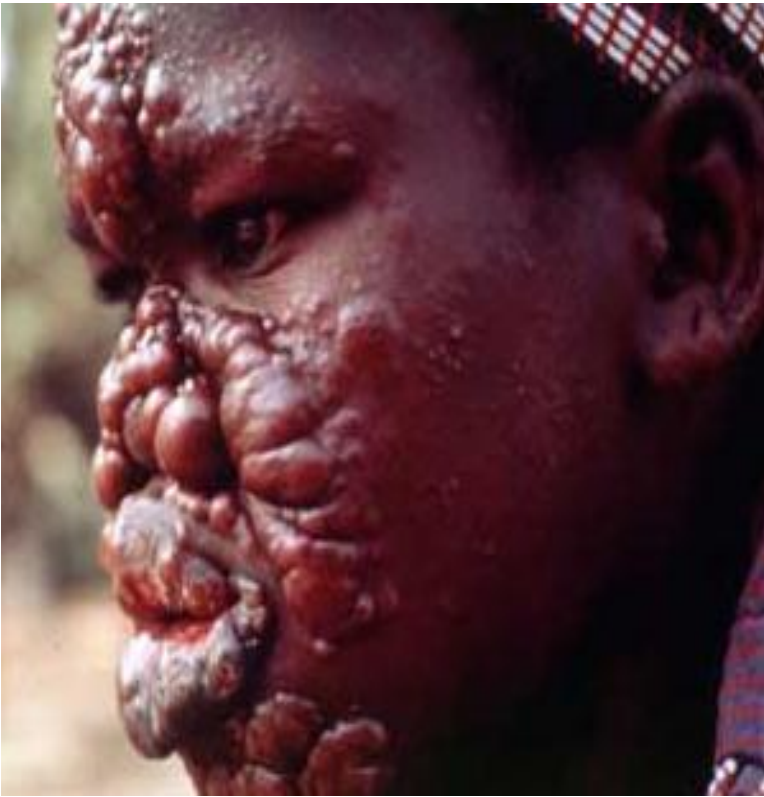- A) HIV status of patient is important contributor
- B) Aetiological virus is epstein barr virus
- C) Specific treatment is usually not indicated
- D) It represents a premalignant lesion for SCC of the tongue

A known HIV patient presents with above skin lesions a few weeks after initiation of 2nd line HAART. He has had a HB of 6g/dl and is known to have CKD. Which of the following is the most likely culprit drug



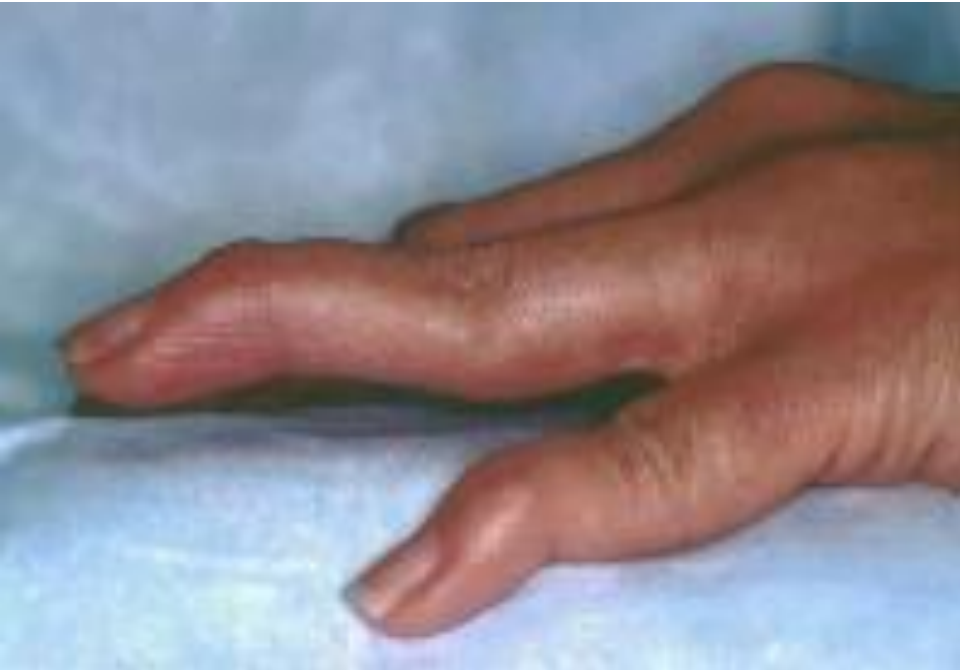- A) nevirapine
- B) Ritonavir
- C) AZT
- D) Efavirenz
- E) Abacavir

Choose the correct statement(s)



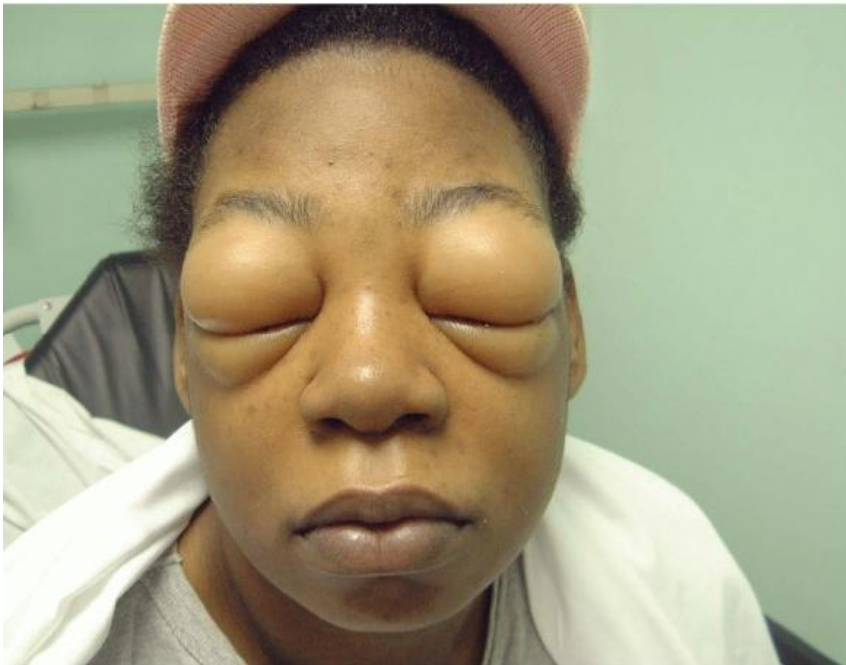- a) This is tuberculoid leprosy
- b) Lesions are multibacillary
- c) Lepromin skin test would be negative
- d) Treatment of choice includes rifampin
- e) Dapsone is contraindicated in this subset of patients

The deformity shown is described as



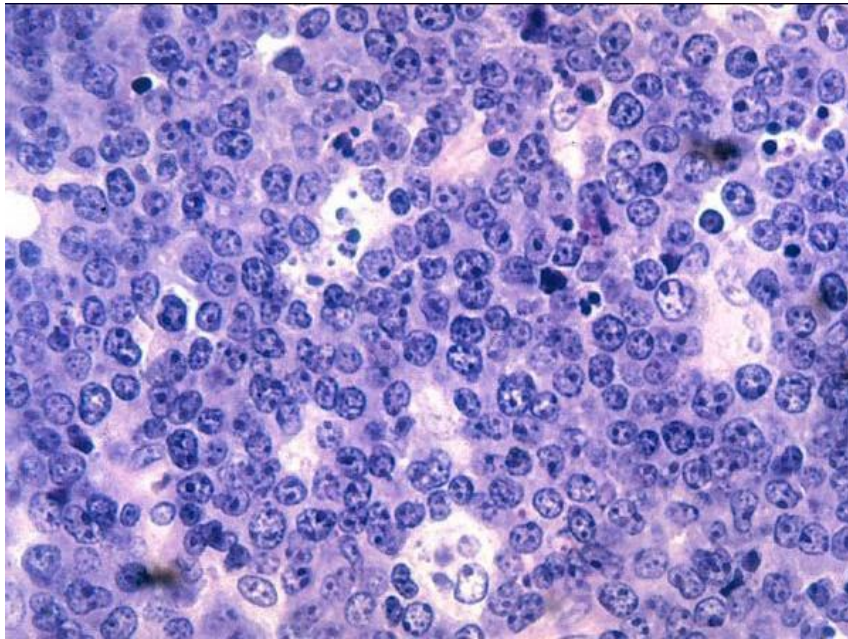
- a) Boutonnaire
- b) Swan neck
- c) Bouchard nodes
- d) Herbedeen nodes

The next single most important test in this patient would be



- A) 24 hour urine protein
- B) Renal ultrasound
- C) Complement C3 levels
- D) Urine red cell casts
- E) UECs

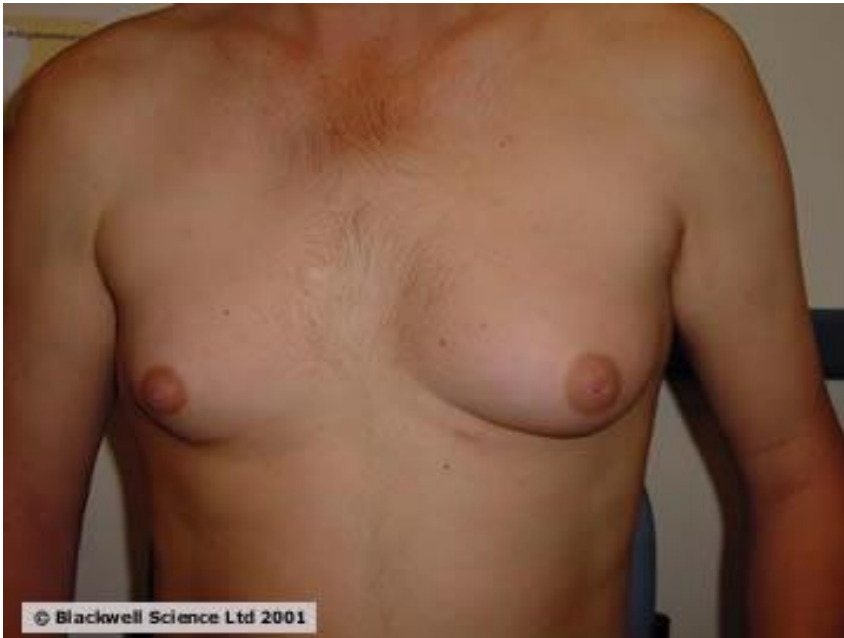The BMA film was described as starry sky appearance. The diagnosis is



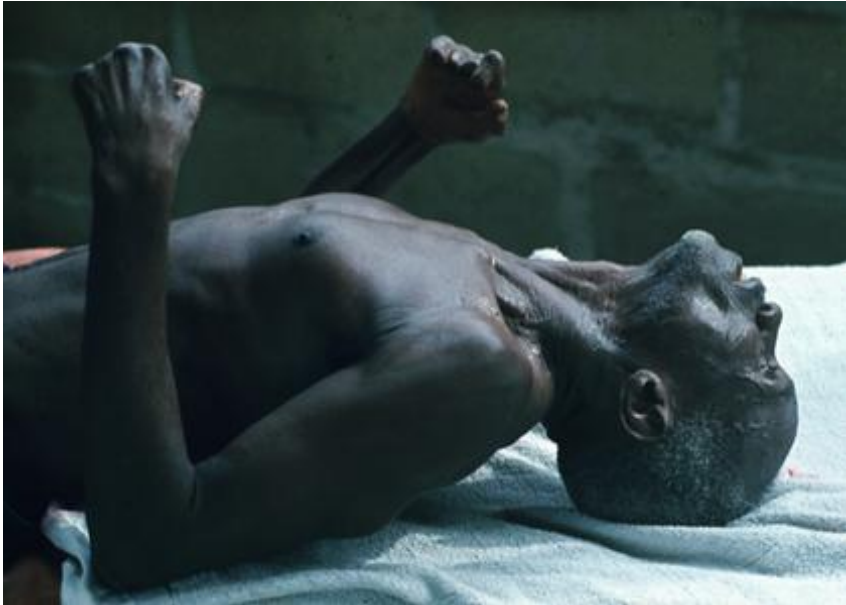- A) Burkitts lymphoma
- B) Hodgkins lymphoma
- C) Non hodgkins lymphoma
- D) MDS

The most likely chronic disease in this patient is

- a) COPD
- b) CKD
- c) LIVER CIRRHOSIS
- d) CCF



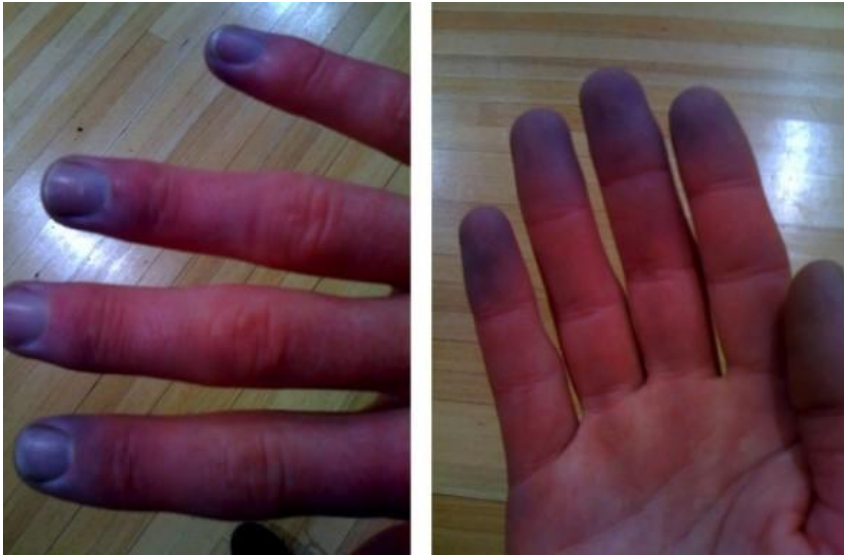A patient who has a recent cut wound on the foot presented as shown



- a) A vaccine is curative at this stage
- b) Patients requires aggressive antibiotic treatment
- c) Disease is mediated by a toxin called tetanolysin
- d) The toxin largely affects GABAergic neurons
- e) Areas close to the wound are least affected

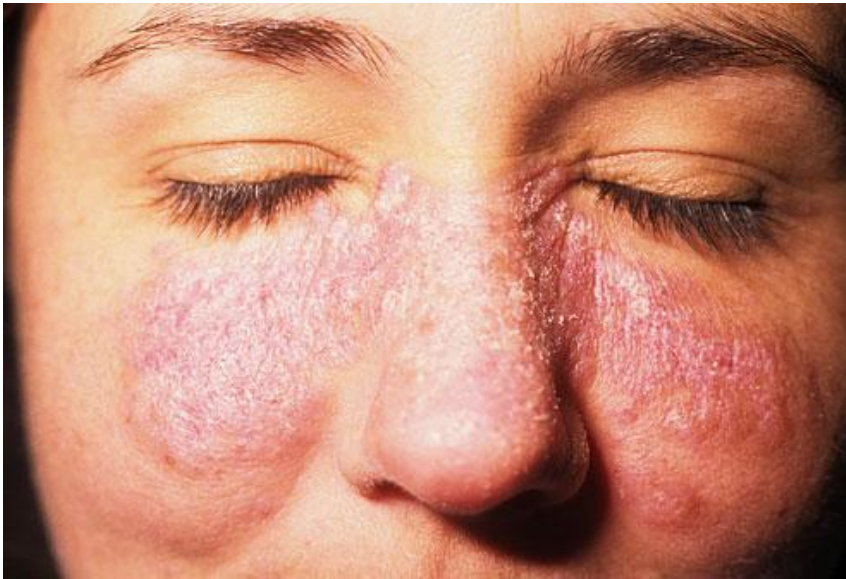Condition(s) likely to present with the feature shown

- A) SLE
- B) Scleroderma
- C) Buerger's disease
- D) Diabetes mellitus
- E) All the above

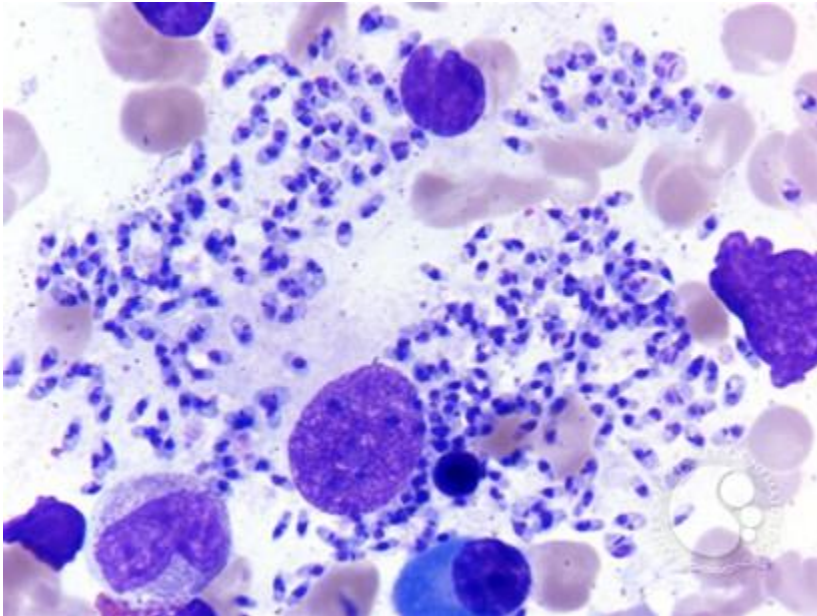


The most sensitive test for the condition shown would be

- a) Anti ds DNA
- b) ANA
- c) Anti sm antibodies
- d) ANCA

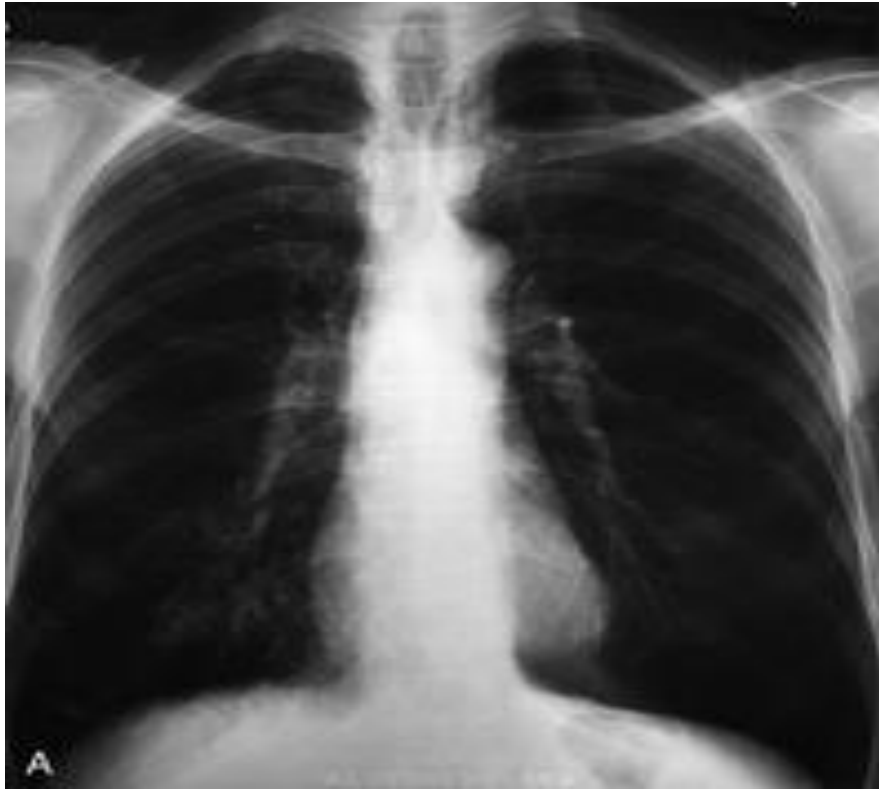

Choose the most sensitive diagnostic test in this protozoal disease



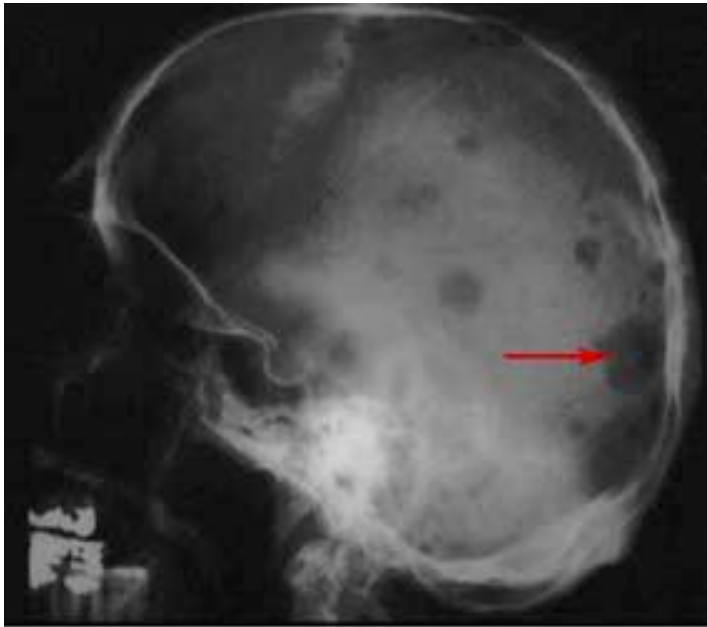
- A) PBF
- B) BMA
- C) Liver biopsy
- D) Splenic aspirate

Concerning the radiograph shown all are true except



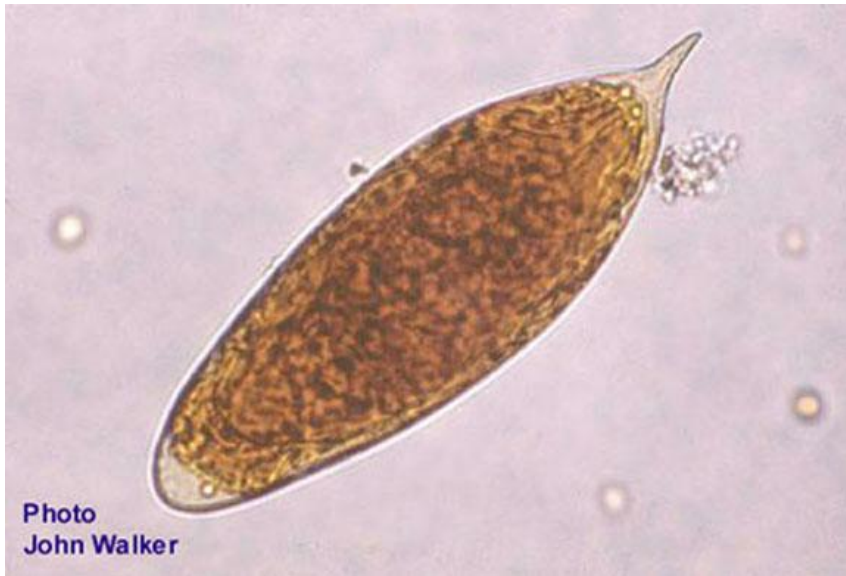- a) Smoking is a major risk factor
- b) Asthma is a differential diagnosis
- c) Spirometry shows reduced total lung capacity
- d) FEV₁/FVC ratio less than 80%

The next most important test to make a diagnosis would be



- a) Pelvic Xray
- b) Serum protein electrophoresis
- c) Bone marrow aspiration cytology
- d) Urine protein electrophoresis

Infection by the parasite whose ova is shown



- a) Associated with SCC of the bladder
- b) Adult lives in the mesenteric plexus
- c) Biomphalaria snail is the intermediate host
- d) Drug of choice is sodium stibogluconate

Snail shown is intermediate host for

- a) *S. japonicum*
- b) *S. hematobium*
- c) *S. mekongi*
- d) *S. Mansoni*

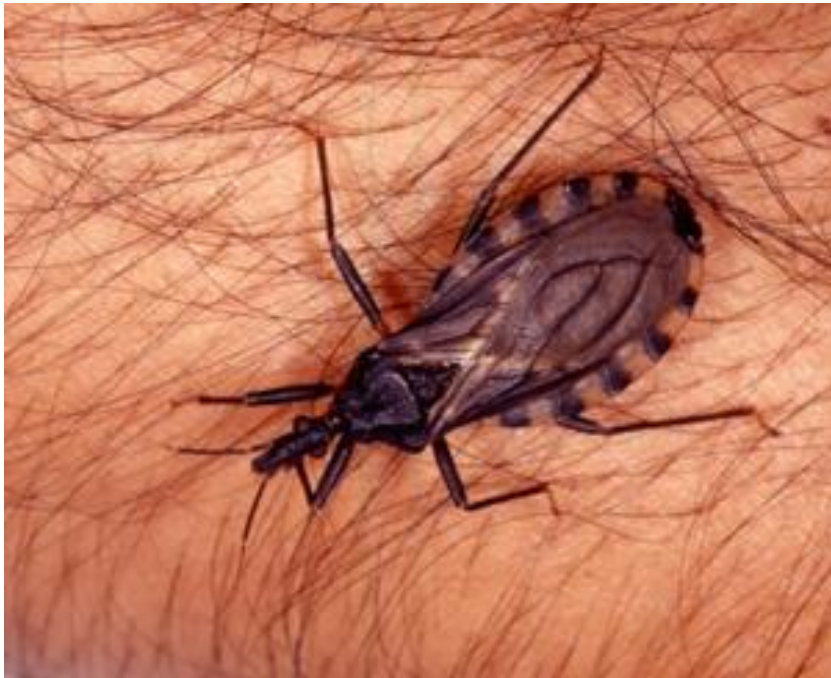

Vector for

- a) *Trypanosoma cruzi*
- b) *Trypanosoma brucei*
- c) *Leshmania donovani*
- d) Malaria




Disease caused by the parasite transmitted by this vector causes complications in which of the following three sets of organs



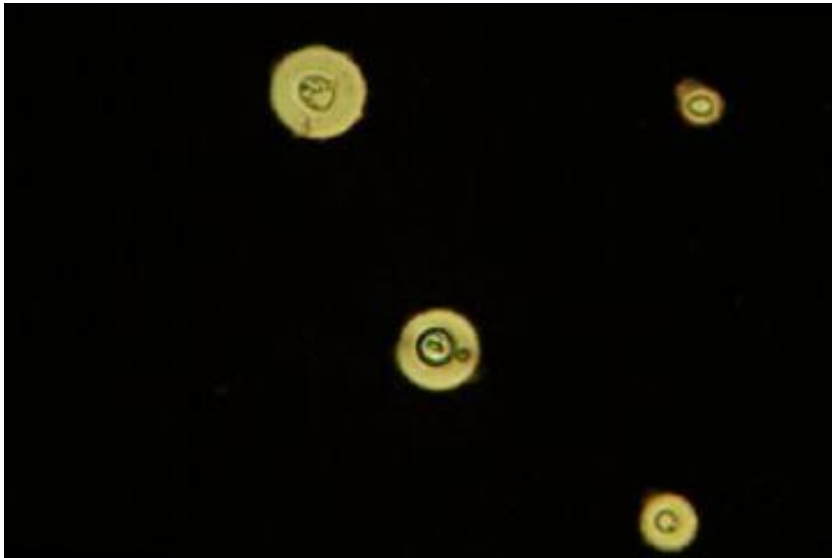
- a) brain, colon, heart
- b) Heart, stomach, liver
- c) Liver, spleen, bone marrow
- d) Colon, esophagus, heart

Which is not a drug used to treat the disease caused by this vector

- a) Melasorprol
- b) DEC
- c) Suramin
- d) Eflornithine



Concerning the organism shown which was isolated from csf of a HIV patient



- a) CD 4 count is above 500
- b) Living with a cat is a risk factor
- c) Visual loss is common if left untreated
- d) Organism infects the brain
- e) Septrin is the prophylactic drug of choice

The cranial nerve involved is

- a) Oculomotor
- b) facial
- c) Optic
- d) Abducens

