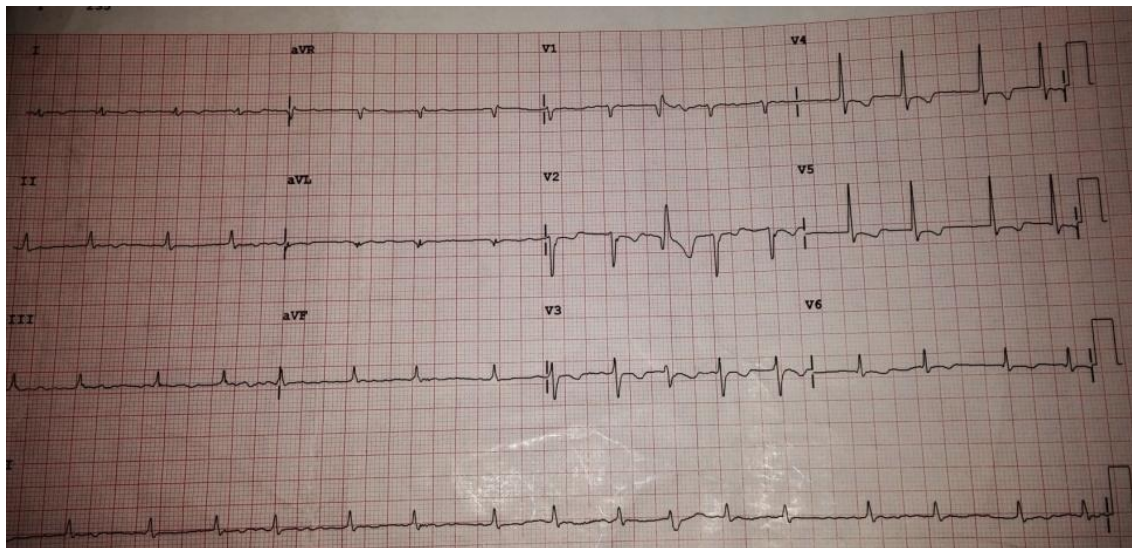


ECG REVISION

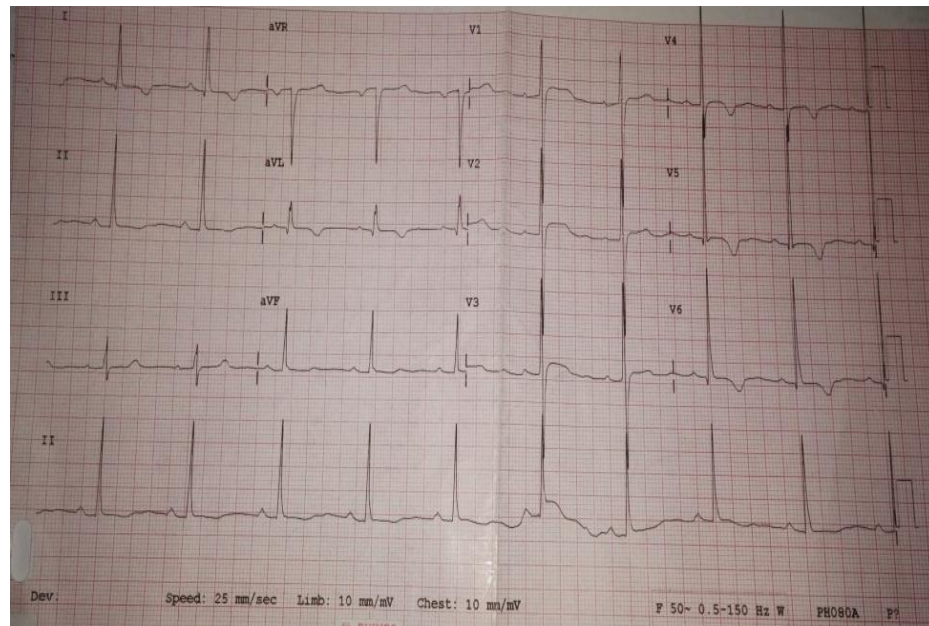
Dr. Kevin Ndede

The following drugs are indicated in treatment of the condition shown on the ecg EXCEPT

- A) warfarin
- B) amiodorone
- C) carvedilol
- D) enalapril

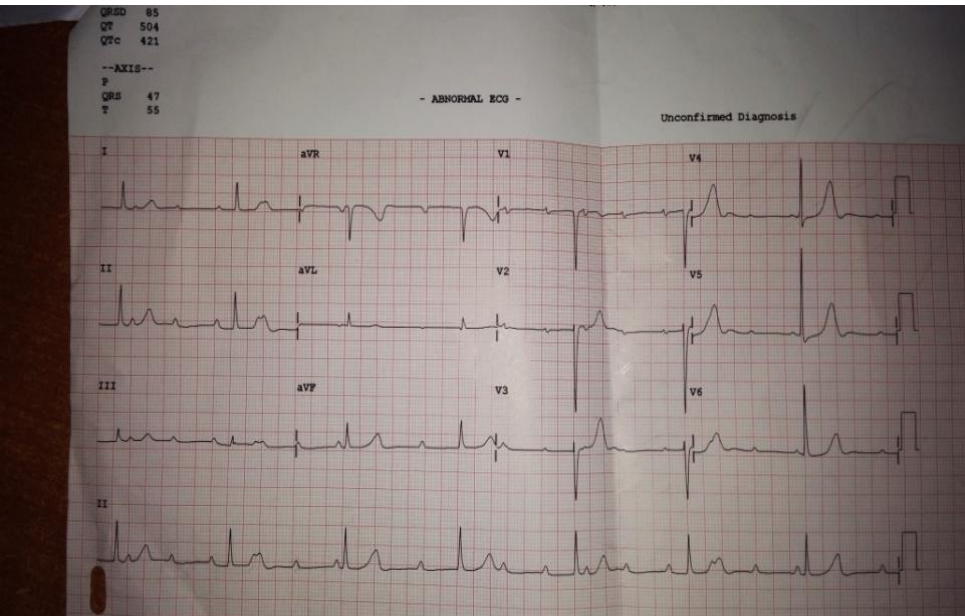


Which is the least likely condition to cause the features shown on the ecg

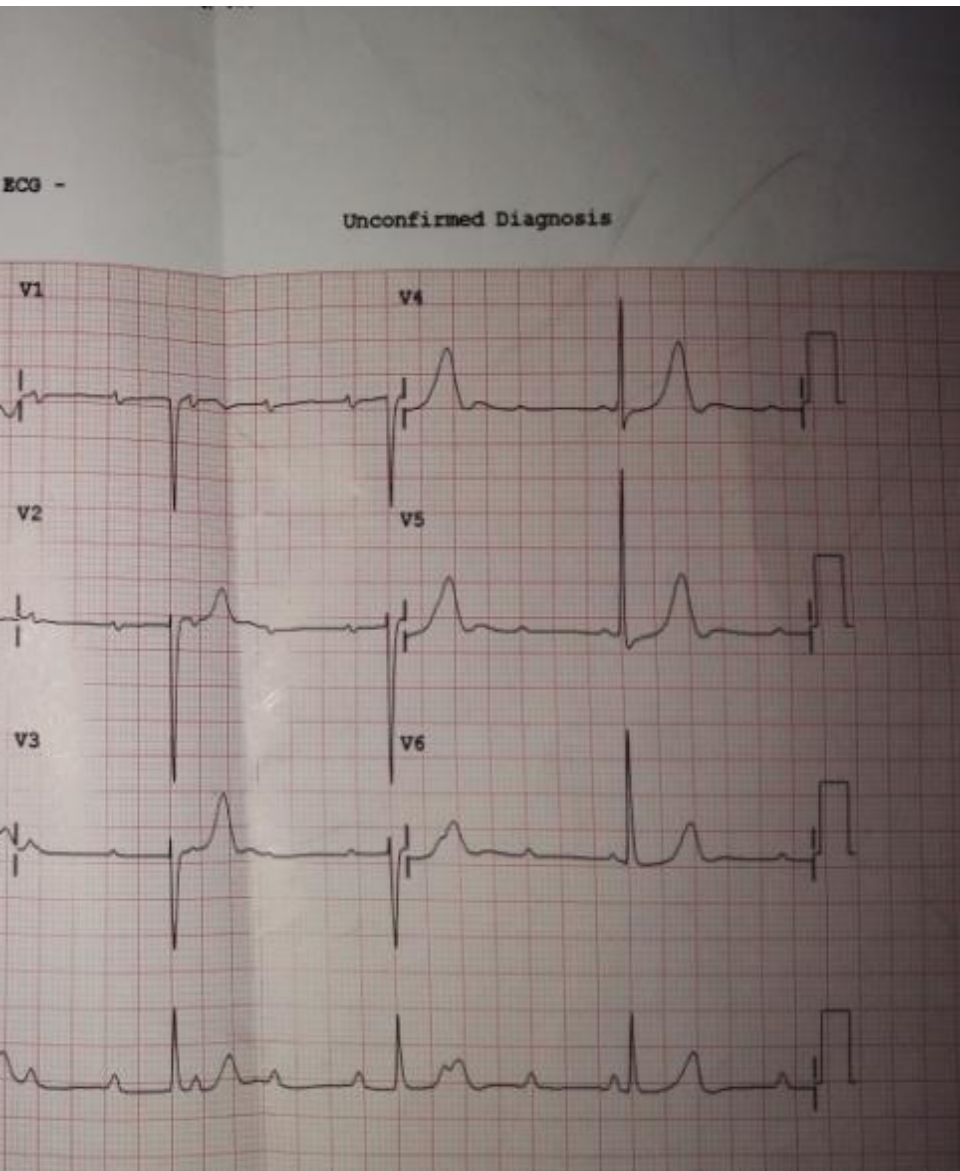


- A) aortic stenosis
- B) aortic regurgitation
- C) mitral regurgitation
- D) tricuspid stenosis
- E) tetralogy of fallot

The characteristic clinical presentation in patients with condition shown on the ecg is



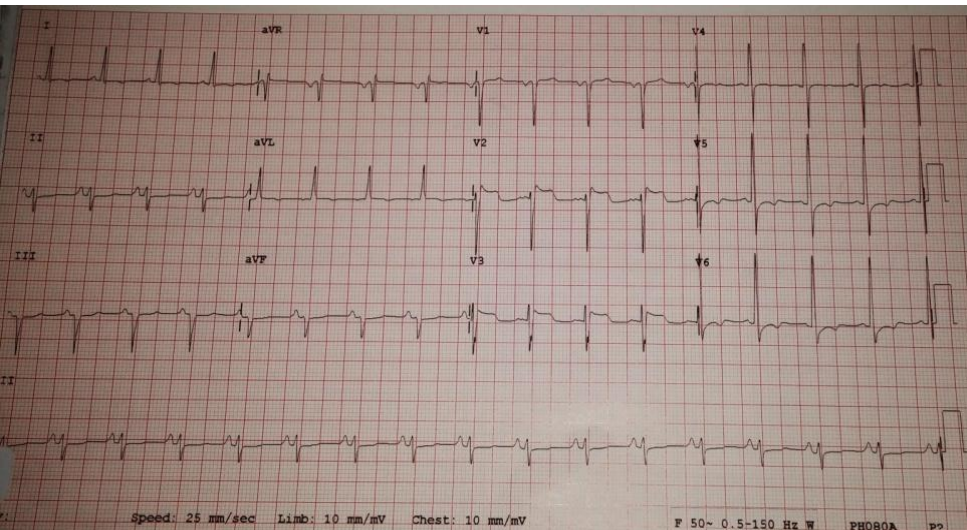
- A) Bilateral pedal oedema
- B) palpitations
- C) shortness of breath on exertion
- D) Angina pectoris
- E) orthopnoea



Management of the
shown is

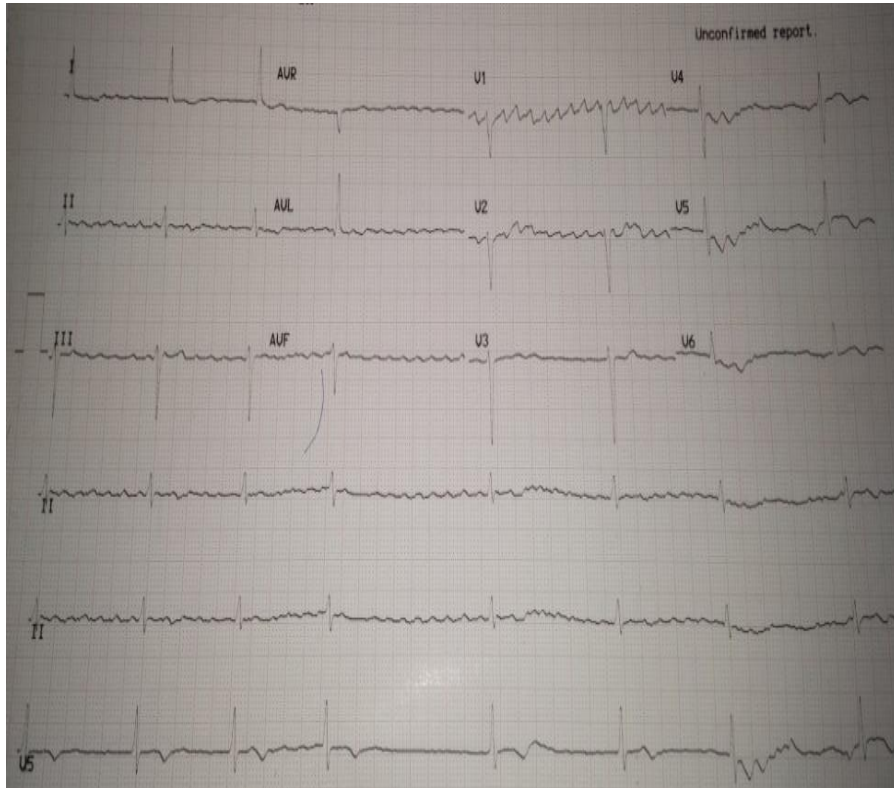
- A) Defibrillation
- B) pacemaker
- C) Mitral valve replacement
- D) Nebivolol

Choose the incorrect statement concerning the ecg provided



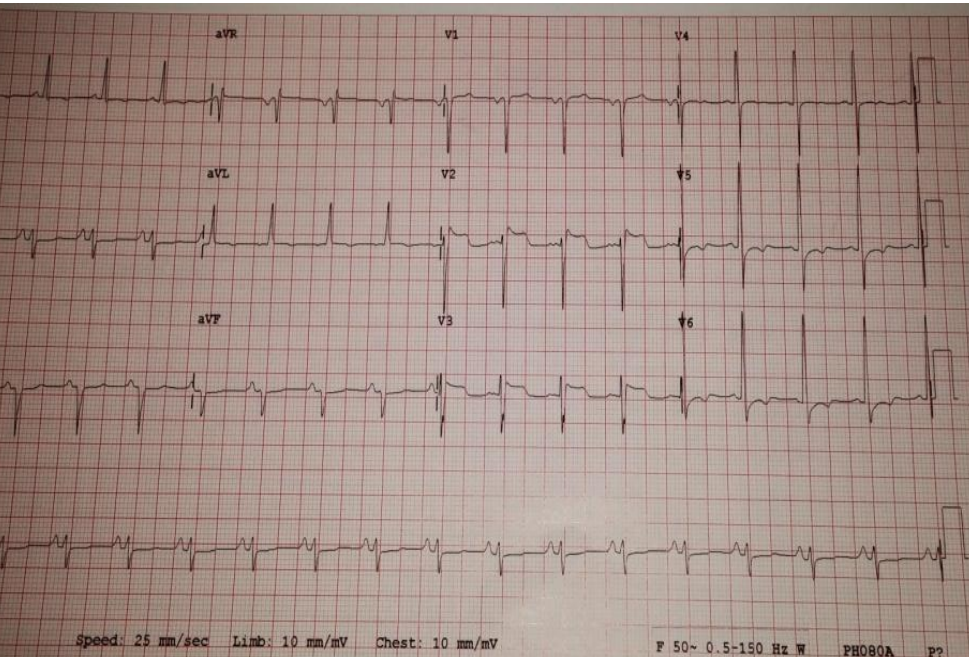
- A) Dual platelet blockade is indicated
- B) UFH is indicated
- C) LMWH may be used
- D) Warfarin is indicated
- E) Atorvastatin is recommended at high doses

Concerning the ecg provided



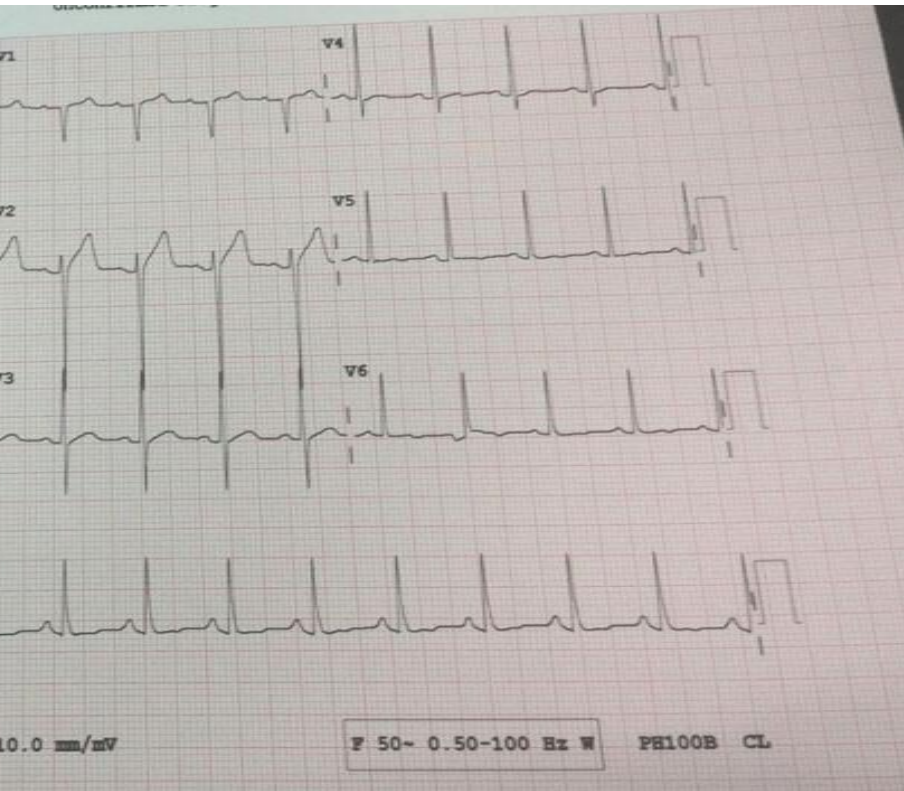
- A) This is atrial flutter
- B) this is atrial fibrillation
- C) This is ventricular fibrillation
- D) the atrial rate is often between 300 -600bpm

The next most useful test in a patient presenting at A & E with this ecg is



- A) troponin T
- B) echocardiogram
- C) Coronary angiogram
- D) CT pulmonary angiogram
- E) Sensitive D – dimer test

The patient whose ECG is shown presented with chest pain that worsened on exertion. The most likely diagnosis is



- A) STEMI
- B) NSTEMI
- C) Pulmonary embolism
- D) Heart failure