

Clinical features

- Exertional dyspnoea
- Chronic cough with regular sputum production
- Wheeze

Investigations

- Spirometry
 - Obstructive pattern: \downarrow FEV₁ (<80%), normal FVC (>80%), \downarrow FEV₁/FVC ratio (<0.7)
 - FEV₁ grades severity
- Chest X-ray
 - Hyperinflation (>8 anterior ribs visible)
 - Flat hemi-diaphragms
 - Decreased lung markings
 - Black lesions (bullae)
 - Prominent hila

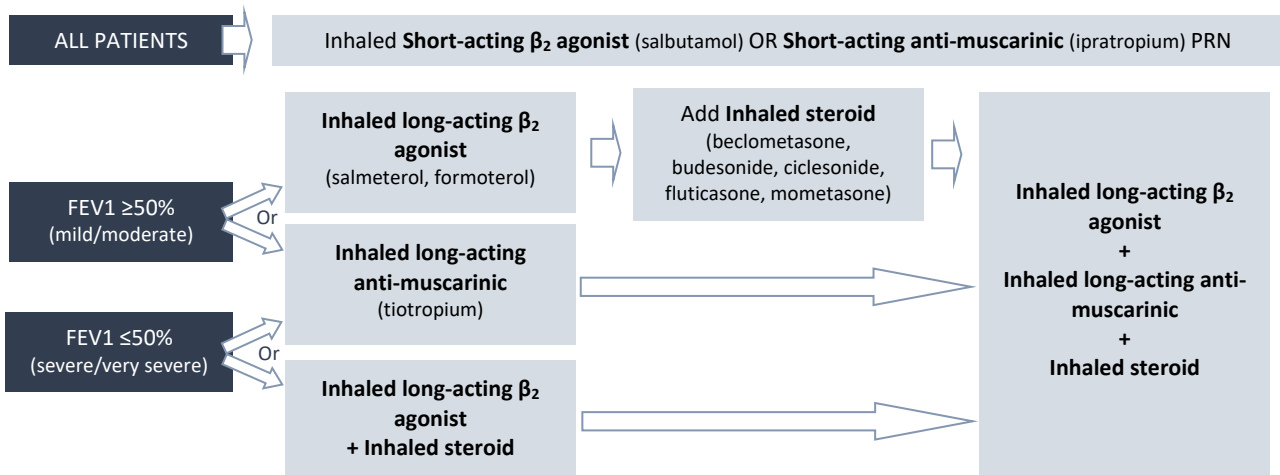
Severity

- Mild FEV₁ >80%
- Moderate FEV₁ 50-80%
- Severe FEV₁ 30-50%
- Very severe FEV₁ <30%

Management

Pharmacological

- Inhalers



- Combination inhalers
 - **Seretide** = salmeterol + fluticasone
 - **Symbicort** = formoterol + budesonide
 - **Fostair** = formoterol + beclomethasone
- Tablets
 - Mucolytics
 - Theophylline

Non-pharmacological

- Smoking cessation
- Pulmonary rehabilitation
- Oxygen therapy
- Lung transplant