

Sue

unplished



UNIVERSITY OF NAIROBI

UNIVERSITY EXAMINATIONS 2015/2016

LEVEL V EXAMINATIONS FOR THE DEGREE OF BACHELOR OF MEDICINE AND
BACHELOR OF SURGERY

HSU 500: SURGERY
MULTIPLE CHOICE QUESTIONS

DATE: NOVEMBER 3, 2016

TIME: 9.00 A.M. - 12.00 NOON

INSTRUCTIONS

1. This Multiple Choice Examination has 100 Questions.
2. There is only ONE answer for each question. Pick the most suitable answer.
3. There is NO negative marking.
4. Shade the correct answer on the answer sheet provided with a pen. NO use of pencil is allowed on the answer sheet.

1. Which of the following is least likely to be due to a UTI?

- a) Nocturia
- b) Loin pain
- c) Frequency
- d) Vaginal discharge
- e) Haematuria

2. A 60-year-old male presents with a right inguinal hernia of recent onset. Which of the following statements is TRUE?

- a) The hernia is more likely to be direct than indirect.
- b) Presents through the posterior wall of the inguinal canal, lateral to the deep inguinal ring.
- c) Is most likely to be lateral to the inferior epigastric vessels.
- d) Is more likely than a femoral hernia to strangulate.
- e) The sac is congenital.

3. A 40-year-old man presents to the emergency room complaining of severe abdominal pain that radiates to his back accompanied by several episodes of vomiting. He drinks alcohol daily. On physical examination, the patient is found on the stretcher lying in the fetal position. He is febrile and appears ill. The skin of his abdomen has an area of bluish periumbilical discoloration. Which of the following is the most likely diagnosis?

- a) Acute Cholecystitis
- b) Intestinal Obstruction
- c) Acute pancreatitis
- d) Chronic pancreatitis
- e) Appendicitis

4. A 4-year-old girl has the sudden onset of colicky abdominal pain and vomiting. She has a mass in the right lower quadrant and hyperactive bowel sounds and her mother reports passage of red currant stools. Which of the following is the most likely diagnosis?

- a) Appendicitis
- b) Intussusception
- c) Merkel diverticulum
- d) Necrotizing enterocolitis
- e) Strangulated hernia

5. An 18-year-old man is admitted to the emergency room following a motorcycle accident. He is alert and fully oriented, but witnesses to the accident report loss of consciousness following the injury. While you are attending to the patient he suddenly loses consciousness and is noted to have dilatation of the left pupil. What is the most likely diagnosis?

- a) Ruptured berry aneurysm
- b) Acute subdural hematoma
- c) Acute Epidural hematoma *& lucid intervals*
- d) Intra-abdominal haemorrhage
- e) Ruptured arteriovenous malformation

6. All of the following are contraindications to passing a nasogastric tube EXCEPT

- a) Suspected perforation of the oesophagus
- b) Confirmed perforation of the oesophagus
- c) History of oesophageal varices ✓
- d) Nearly complete obstruction of the oesophagus due to benign or malignant strictures ✓
- e) Presence of an oesophageal foreign body ✓

7. What is the most common initial manifestation of increasing intracranial pressure in the patient with head trauma?

- a) Change in level of consciousness
- b) Ipsilateral pupillary dilation
- c) Contralateral pupillary dilation
- d) Hemiparesis
- e) Hypertension

8. You are the intern covering the surgical floor for the night and the nurses ask you to review a patient who has had thyroidectomy earlier in the day. You notice that she has an anterior neck swelling and difficulty breathing. The next step of management will be

- a) Open the wound immediately
- b) Intubate oro-tracheally
- c) Wait and watch
- d) Oxygen by mask
- e) Call the surgeon urgently

open wound & evacuate haematoma

9. Assessment of a breast lump includes all of the following EXCEPT?

- a) Lumpectomy
- b) Clinical examination ✓
- c) Core biopsy ✓
- d) Breast imaging ✓
- e) Fine needle aspiration ✓

10. Which of the following is the most common type of hernia in women?

- a) Inguinal
- b) Femoral
- c) Epigastric
- d) Hiatal
- e) Incisional

11. Which one of the following statements is INCORRECT in regards to sepsis?

- a) Tachycardia and tachypnoea are early signs ✓
- b) Sepsis is defined as Systemic Inflammatory Response Syndrome in the setting of documented infection ✓
- c) Leucocytosis or leucopenia may be a sign ✓
- d) Septic shock is defined as hypotension and sepsis ✓
- e) Temperature of more than 38 degrees or less than 36 degrees is a sepsis defining criteria ✓

12. Which one of the following is NOT associated with compartment syndrome?

- a) Disproportionate pain ✓
- b) Pallor ✓
- c) Paraesthesia ✓
- d) Absent distal pulses ✓
- e) Erythema ✓

13. Which one of the following statements is INCORRECT regarding osteomyelitis?

- a) X-ray features include ^{collings} Codman's triangle and sunrise calcification ✓ (osteosarcoma)
- b) Staphylococcus aureus is a common pathogenic isolate in acute and chronic osteomyelitis ✓
- c) Brodie's abscess is a sub-acute complication ✓
- d) Long course antibiotics, surgical debridement and washouts are methods used in management ✓
- e) Marjolin's ulcer can be a complication of chronic osteomyelitis ✓ ^{chronic}

14. Which one of the following best describes a Colle's fracture?

- a) Extra-articular palmarly displaced distal radius fracture
- b) Intra-articular distal radial fracture with dislocation of the radio-carpal joint
- c) Fracture of the radial styloid
- d) Extra-articular distal radial fracture with dorsal angulation and impaction
- e) Intra-articular distal radial fracture with dorsal angulation and impaction

15. Management of clinically diagnosed compartment syndrome?

- a) Surgical release of all compartments.
- b) Elevation and ice packing for few hours.
- c) Compression dressing and re-evaluate the next day.
- d) Extremity elevation is the cornerstone of treatment.
- e) Need an MRI to confirm diagnosis

16. Codman's triangle is:

- a) Triangle of metaphysis from which the tumour arises.
- b) Triangle of bone erosion by the tumour.
- c) Triangle of new bone formation at the elevated edge of the tumour due to irritation of subperiosteal blood vessels.
- d) Diagnostic of Ewing sarcoma of bone.
- e) Characteristic of osteoclastoma.

PPP
ppm
pmm

17. A 49 year old man is found to have a solitary neck nodule on physical examination. Laboratory studies reveal an elevated calcitonin level and fine needle aspiration confirms a diagnosis of medullary carcinoma of the thyroid. Which of the following disease processes might the physician be concerned to look for in this patient?

(A)

- ~~a) Hyperparathyroidism~~
- b) Papillary thyroid carcinoma
- ~~c) Pituitary adenoma~~
- ~~d) Subacute thyroiditis~~
- e) Zollinger-Ellison syndrome

18. The emergent management of tension pneumothorax entails:

(B)

- ~~a) Immediate needle thoracostomy~~
- b) Oxygen via mask
- ~~c) Chest X-ray~~
- d) Emergency thoracotomy
- e) Tube thoracostomy

19. The shortest acting muscle relaxant is

- a) Curare
- b) Pancuronium
- ~~c) Suxamethonium~~
- d) Succinylcholine
- e) Rocuronium

20. Which of the following statements regarding unusual hernias is INCORRECT?

(C)

- a) An obturator hernia may produce nerve compression diagnosed by a positive Howship-Romberg sign ✓
- b) Littre's hernia is defined by a Merkel's diverticulum presenting as the sole component of the hernia sac ✓
- ~~c) Sciatic hernias usually present with a painful groin mass below the inguinal ligament~~
- d) Grynfeltt's hernia appears through the superior lumbar triangle, whereas Petit's hernia occurs through the inferior lumbar triangle ✓
- e) Richter's hernia involves the antimesenteric surface of the intestine within the hernia sac and may present with partial intestinal obstruction ✓

21. Which ONE of the following anaesthetic agents can cause malignant hyperpyrexia?

- a) Isoflurane ✓
- ~~b) Halothane~~
- ~~c) Propofol~~
- ~~d) Enflurane~~
- ~~e) Ketamine~~

22. Jose is a 62-year-old man who just had a needle biopsy of the pancreas showing adenocarcinoma. You run into his brother in the hall, and he begs you not to tell Jose because the knowledge would kill him even faster. A family conference to discuss the prognosis is already scheduled for later that afternoon. What is the best way for you as the doctor to handle the situation?

- a) The doctor should honor the request of the family member who is protecting his beloved brother from the bad news.
- b) The doctor should tell Jose's brother that withholding information is not permitted under any circumstance.
- c) Jose should withhold informing the patient about the pancreatic cancer because of the grave diagnosis.
- d) The doctor should ask Jose how he wants to handle the information in front of the rest of the family, and allow for family discussion time for this matter.
- e) All of the above

23. A 28-year-old man presents to the emergency room with testicular torsion, in extreme pain. Emergency surgery is scheduled, but the urologist will be unable to see the patient for at least one hour. He asks that the patient not be given any pain medication, so that "consent can be obtained" when he sees the patient. Are the surgeon's concerns about informed consent valid?

- a) Yes, because the surgeon has to obtain informed consent from the patient before surgery and the pain medication will invalidate the consent.
- b) Yes, because the hospital policy requires the presence of informed consent from a lucid person before surgery.
- c) The informed consent is not required in this case because it is an emergency.
- d) The surgeon's concerns are not valid because severe pain, by impairing a patient's ability to listen and understand, is an encumbrance to the informed consent process
- e) All of the above

24. A 67 year old lady who is on ibuprofen and steroids for rheumatoid arthritis presents to the casualty with a history of sudden onset epigastric pain with vomiting. On examination she is noted to have epigastric tenderness with guarding and rigidity. Which is the single most important investigation that should be ordered to aid in diagnosis?

- a) CT scan abdomen
- b) Endoscopy
- c) Erect Chest X-ray
- d) Complete blood count
- e) Abdominal ultrasound

free gas under diaphragm

25. Which one of the following statements is INCORRECT regarding a Merkel's diverticulum?

- a) It is two inches long
- b) It is two meters from the ileocecal junction in the terminal ileum
- c) It contains heterotopic gastric and pancreatic tissue ✓
- d) It is a remnant of the embryonic vitelline duct ✓
- e) It occurs in 2% of the population ✓

26. Which of the following is the correct statement in regard to colorectal cancer?

- a) Is the most common cause of large bowel obstruction
- b) Is the most common cause of vesico-intestinal fistula ✓
- c) Most commonly occurs in recto-sigmoid region $\Rightarrow 70\%$
- d) Rarely develops from colonic polyps \neq adenomatous polyps
- e) Neoadjuvant therapy has no role in its management ✓

arises from adenomatous polyp after a sequence of genetic mutations

Amsterdam criteria for colorectal CA

- 3 or more family members with an HNPCC related CA \Rightarrow colorectal, endometrial, small bowel, vtrict, renal (one of which is a 1st degree relative)

- 2 successive affected generations

- at least one colorectal cancer diagnosed by the age of 50y

- FAP excluded

- Tumours will be verified by pathological exams

27. In Infantile hypertrophic pyloric stenosis:

- a) Presents with vomiting from birth - 2-3 wks
- b) Frequently results in acidosis
- c) Is readily diagnosed clinically
- d) Is usually cured by surgery X
- e) Is associated with subsequent duodenal ulceration X

- non bilious vomiting
- olive epigastric mass
- peristaltic waves 4/11 L → R.

28. A 24 year old female presents with palpitations, diarrhea and weight loss. On examination she is noted to have exophthalmos, sweating, slight tremor and a large goiter. Which of the following is the most likely diagnosis?

- a) Toxic Multinodular goiter
- b) Graves disease
- c) De Quervains thyroiditis
- d) Hashimoto thyroiditis
- e) Solitary thyroid nodule

29. Which is the most common site for the appendix found at appendicectomy?

- a) Retro-ileal
- b) Retro-caecal - 70%
- c) Pelvic - 21%
- d) Anterior to terminal ileum
- e) Below terminal ileum overlying psoas

30. Which of the following is not an established risk factor for SSI (surgical site infection)?

- a) Smoking ✓
- b) Diabetes ✓
- c) Male gender
- d) Shaving the surgical site ✓
- e) Malnutrition

31. Which of the following wound classifications is correctly matched with its description?

- a) Clean- controlled opening with minor break in technique
- b) Clean-contaminated: emergency laparotomy for peritonitis
- c) Contaminated: obvious infection present
- d) Dirty: major spillage or technique break
- e) None of the above

32. Which of the following statements about scrotal and testicular problems is TRUE?

- a) Torsion of the testis is seen most commonly between the ages of 20 and 30 years - 10-25 yrs
- b) Hydrocele is diagnosed by transillumination and, if any portion transilluminates, malignancy is excluded by us
- c) A right-sided Varicocele is slightly less common than a left-sided Varicocele - 90% left sided
- d) A painless testicular mass in a man aged 20 to 35 years, found incidentally, is the most common presentation of a testicular tumour
- e) Epididymal cysts always occur in the tail of the epididymis

33. Traumatic rupture of the membranous urethra:

- a) May be associated with a "floating prostate" on rectal examination
- b) Is best treated by immediate urethral catheterisation X
- c) Rarely leads to long-term sequelae X
- d) Is usually diagnosed by radionuclide cystogram X
- e) Is most often due to endoscopic surgery

34. If testicular torsion is suspected, surgical exploration:
- a) Can be delayed but include the asymptomatic side
 - b) Can be delayed but only explore the affected side
 - c) Should be immediate and limited to the affected side
 - d) Should be immediate and include the asymptomatic side
 - e) All of the above

35. In the management of patients with head injury all of the following statements are true EXCEPT?

- a) The lowest possible GCS is 3T ✓
- b) Skull fracture is a risk factor for epidural haematoma ✓
- c) Patients with acute subdural hematoma present with a lucid interval ✓
- d) With decreased level of consciousness a skull x-ray is the investigation of choice
- e) Normal intracranial pressure ranges from 0-15mmhg

36. The diagnosis of carcinoma of the oesophagus should initially include:

- a) Upper gastrointestinal ^{endoscopy} and biopsy
- b) Carcinoembryonic antigen (CEA) level
- c) Oesophageal manometry
- d) Laparoscopy
- e) Transoesophageal ultrasound and lymph node biopsy

37. A male neonate who was delivered vaginally at term one hour ago has a deformity of the right foot. On physical examination, plantar flexion of the ankle, inversion of the subtalar joint medial subluxation of the talocalcaneal and calcaneocuboid joints are noted. The position of the foot cannot be passively corrected. Which of the following disorders is the most likely diagnosis?

- a) Calcaneovalgus
- b) Congenital talipes equinovarus
- c) Metatarsus adductus
- d) Pes planus
- e) Tarsal coalition

38. Which of the following statements is not a component in the principles of compound fracture management?

- a) No tendon repair
- b) Aggressive antibiotic cover
- c) Wound debridement
- d) Immediate wound cover
- e) Use of external fixator

39. Which of the following statements about Hirschsprung's disease are true EXCEPT?

- a) There are no ganglion cells seen in Auerbach's plexus. ✓
- b) There is an increased incidence of Down syndrome. ✓
- c) It is more common in girls. ✓
- d) It may be associated with enterocolitis. ✓
- e) The dilated portion of bowel is aganglionic ✗

M: F 4: 1

40. Regarding oesophageal atresia and tracheo-oesophageal fistula (TOF), all of the following statements are true except?

- a) Most cases of oesophageal atresia are associated with a proximal TOF to the lower oesophagus ✓
- b) Often present prenatally with polyhydramnios ✓
- c) Post-natally present with difficulty swallowing and aspiration ✓
- d) The diagnosis may be confirmed by the inability to pass a nasogastric catheter ✓
- e) Radiological evidence of gas in the stomach indicates the presence of distal TOF ✓

41. When progressive enlargement of a Multinodular goitre causes symptomatic tracheal compression the preferred modality of treatment is?

- a) Iodine treatment
- b) Anti-thyroid medication
- c) Surgical resection of abnormal thyroid tissue
- d) Radio-iodine ablation
- e) Cricothyrotomy

42. Which of the following statements on hypovolemic shock is true?

- a) Class I shock is equal to voluntary blood donation of one unit ✓
- b) Class II shock is evidenced by change in vital signs and a significant decrease in systolic blood pressure ✓
- c) Class III shock can be managed by simple administration of crystalloids only ✓
- d) Class IV shock is evidenced by blood loss of less than 40% and is not life threatening. ✓
- e) In class II shock, capillary return is more than two seconds. ✓

43. A large pituitary tumour will usually cause which of the following kinds of visual field defects?

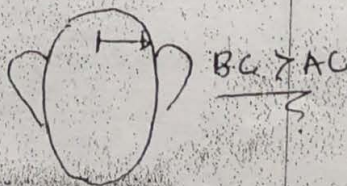
- a) Bitemporal hemianopsia
- b) Left homonymous hemianopsia
- c) Right homonymous hemianopsia
- d) Right homonymous inferior quadrantanopsia
- e) Left homonymous inferior quadrantanopsia

44. What is the most common cause of significant Upper Gastrointestinal bleeding?

- a) Oesophageal varices
- b) Mallory-Weiss tear
- c) Peptic ulcer disease
- d) Esophagitis
- e) Gastric cancer

45. A 38 year old man comes in to see you as his family doctor with complaints of reduced hearing. He reports that his family and work mates are complaining that they have to shout for him to hear. You carry out a battery of tests including those for hearing loss. What kind of hearing loss is characterised by a Weber test that lateralizes to the deaf ear and a Rinne test that is negative?

- a) Conductive
- b) Sensorineural
- c) Electrical
- d) Hysterical
- e) Semantic



46. A 37 year old intravenous drug user is referred by his Family Doctor for a suspected Bells Palsy. On examining his inner ear there are a number of vesicles visible on his ear drum. His cranial nerve examination reveals a weakness of the whole of the left side of his face. The most likely diagnosis is:

- a) Steven Johnson Syndrome
- b) HIV
- c) Stroke
- d) Ramsay Hunt Syndrome
- e) Bells Palsy

47. The most precise diagnostic screening procedure for differentiating benign thyroid nodules from malignant ones is:

- a) Ultrasound guided fine-needle-aspiration biopsy (FNAB)
- b) Thyroid ultrasonography
- c) Thyroid scintiscan
- d) Thyroid hormone suppression
- e) Core needle biopsy

48. What is the most common cause of hearing loss in a previously healthy patient?

- a) Barotrauma
- b) Cerumen impaction
- c) Neuritis
- d) Otitis media
- e) Tympanic membrane perforation

49. Which is the single best enzyme for diagnosing acute pancreatitis?

- a) Lipase
- b) Serum amylase
- c) Amylase isoenzymes
- d) Renal clearance of amylase
- e) All of the above

50. A 56 year old woman presents with a two weeks history of increasing jaundice and pruritus. Further questioning reveals that she has vague epigastric pain radiating to the back for the last few months. On examination, the gall bladder is palpable with no obvious hepatomegaly. The most likely diagnosis is

- a) Cholangiocarcinoma
- b) Head of pancreas carcinoma
- c) Carcinoma of gall bladder
- d) Hepatocellular carcinoma
- e) Gallstone disease

51. A 75 year old male patient presents in the emergency room with a 1 day history of severe abdominal pain. He is a known case of chronic bilateral knee osteoarthritis and takes NSAIDs. Chest X ray shows gas under both domes of diaphragm and on exploration he is found to have a small duodenal ulcer perforation. What would be the best surgery for him?

- a) Truncal Vagotomy Pyloroplasty
- b) Gastrectomy
- c) Truncal Vagotomy with gastrectomy
- d) Omental patch closure of the perforation
- e) Tube duodenostomy

52. Using the Goodsall's rule as a guide for identifying the internal opening of a fistula-in-ano, an external opening located 3cm at left posterolateral area would:

- a) Have a short radical tract anteriorly
- b) Have a short radical tract posteriorly
- c) Have a curvilinear tract to the anterior midline
- d) Have a curvilinear tract to the posterior midline
- e) None of the above



53. The most common site of volvulus is the

- a) Caecum
- b) Sigmoid
- c) Transverse
- d) Splenic flexure
- e) Hepatic flexure

54. The hallmark of Fournier's gangrene is:

- a) Foul smelling wound discharge
- b) Intense pain and tenderness
- c) Occurrence in an immunocompromised patient
- d) Decreased WBC count in the blood
- e) Fever accompanied by scrotal pain

55. A 48-year-old woman has prolonged ileus after surgery for a perforated duodenal ulcer. The problem is probably due to:

- a) Hypocalcaemia
- b) Hypochloremia
- c) Hypomagnesaemia
- d) Hypokalemia
- e) Hypophosphatemia

56. A 60-year-old man has a 3 cm nodular lesion with central ulceration in his left cheek. Section biopsy proves this to be a basal cell carcinoma. This condition is best managed by:

- a) External beam radiation
- b) Topical 5-fluouracil
- c) Electrodesiccation
- d) Excision with 2-4 mm margin
- e) Laser therapy

57. A 20-year-old woman consults you for a 2-cm mass in her left breast. The mass is movable, non-tender and has a rubbery consistency and smooth surface. The probable diagnosis is:

- a) Fibroadenoma
- b) Fibrocystic disease
- c) Carcinoma
- d) Cystosarcoma phyllodes
- e) Fibroadenosis

58. The presence of tenesmus, decrease in calibre of stools and occasional bloody-mucoid diarrhoea in a 67-year-old man is suggestive of:

- a) Rectal carcinoma
- b) Amoebic colitis
- c) Intussusception
- d) Ileocecal tuberculosis
- e) Inflammatory bowel disease

59. Which of the following factors present in an Enterocutaneous fistula increases the possibility of closure of the tract?

- a) Non-epithelialization of the tract
- b) High output fistula
- c) Malnutrition
- d) Sepsis
- e) Distal obstruction

60. Skin lesions that extend beyond the boundaries of the original wound, do not regress with time and recur after excision are known as:

- a) Hypertrophic scars
- b) Keloids
- c) Diabetic ulcers
- d) Decubitus ulcers
- e) Squamous cell carcinoma

61. A 50 year old male comes to see you because of loss of weight about 30% of his previous bodyweight associated with on and off colicky abdominal pain. He also noticed that his stools have diminished in calibre. The single most important examination would be:

- a) Stool microscopy
- b) Barium enema
- c) Colonoscopy with biopsy
- d) CT scan
- e) Endorectal coil MRI

62. Which is the most common site of metastasis from Prostatic carcinoma?

- a) Liver
- b) Kidneys
- c) Bladder
- d) Bone
- e) Brain

63. A 25-year-old man is unconscious, withdraws from painful stimuli, he opens his eyes in response to pain and makes unintelligible sounds. His Glasgow coma scale score is:

- a) 5
- b) 7
- c) 8
- d) 10
- e) 12

4 + 2 + 2

E 4
3
2
C 5
M 4

2
4
5
4
3
2

64. In patients with colorectal cancer the serum CEA level is a clinically useful measure for all of the following reasons except:

- a) Prognosis
- b) Detection of recurrence. ✓ ↑↑
- c) Guiding second-look operations ??
- d) Following treatment response ✓
- e) Early diagnosis ✓

65. The most important factor in fracture healing is:
- a) Good alignment
 - b) Absorption of blood clot
 - c) Accurate reduction and apposition of fractured fragments
 - d) Immobilization
 - e) Adequate calcium intake

66. The commonest type of lesion causing recurrent shoulder dislocation is:

- a) Shallow glenoid labrum
- b) Bankarts lesion
- c) Stiffness of subscapularis muscle
- d) Injury to humeral head
- e) Subluxation of acromioclavicular joint

67. Delayed wound healing is seen in all except?

- a) Post radiotherapy ✓
- b) Hypertension
- c) Diabetes ✓ (microvascular dx)
- d) Infection ✓
- e) Malnutrition ✓

68. A patient with a grossly contaminated lower limb wound presents 12 hours after an accident. How would you as the surgical intern manage this wound?

- a) Thorough cleaning with debridement of all dead and devitalized tissue with primary closure
- b) Thorough cleaning with debridement of all dead and devitalized tissue without primary closure
- c) Primary closure over a drain ✓
- d) Covering the defect with split skin graft after cleaning ✓
- e) Negative pressure wound therapy

69. The remodelling phase of wound healing is most likely to be identified by:

- a) Erythema.
- b) Haemostasis.
- c) Scar formation
- d) Collagen formation
- e) Granulation tissue

70. Features of Charcot triad and Reynolds Pentads in acute Cholecystitis/Cholangitis include all of the following EXCEPT:

- a) Jaundice ✓
- b) Fever ✓
- c) Right upper quadrant pain ✓
- d) Shock
- e) Palpable gall bladder

71. In obstructive jaundice due to gallstones:

- a) Serum alkaline phosphatase is raised
- b) Oral cholecystogram is of value
- c) The gall bladder is palpable ✓
- d) There is sometimes an associated splenomegaly ✓
- e) Vitamin K absorption is always impaired ✓

72. Your best friend calls you from campus that his irate girlfriend splashed some Jik into his eyes and they are now burning. He tells you that this happened about fifteen minutes ago. What is the first line of treatment for the injury he has sustained?

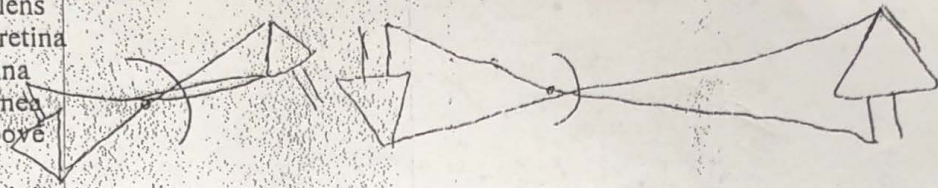
- a) Admission if severe
- b) Topical antibiotics
- c) Topical cycloplegia
- ~~d) Irrigation with water~~
- e) Oral analgesia

73. Exophthalmos associated with thyroid ophthalmopathy has the following clinical signs except:

- a) Proptosis
- ~~b) Ptosis~~
- c) Lid retraction ✓
- d) Conjunctival chemosis
- e) Extra ocular muscle thickening ✓

74. In the absence of lens accommodation, a myopic eye focuses images:

- a) In front of the lens
- b) In front of the retina
- ~~c) Behind the retina~~
- ~~d) Behind the cornea~~
- e) None of the above



75. The commonest painless lid swelling is:

- ~~a) Stye~~
- b) Cyst of moll
- c) Cyst of zeis
- d) Internal hordeolum
- e) Chalazion

76. Symptoms of cataract include all of the following except:

- a) Halos
- ~~b) Decreased vision in low illumination~~
- ~~c) Decreased vision in bright light~~
- d) Glare
- e) Sudden loss of vision

77. Which of the following is specific for the diagnosis of allergic conjunctivitis?

- a) Eye redness
- ~~b) Itching~~
- c) Foreign body sensation
- d) Excessive lacrimation
- e) None of the above

78. The Pathognomic clinical sign of proliferative diabetic retinopathy is:

- a) Micro aneurysms
- b) Hard exudates
- c) Deep retinal haemorrhages
- ~~d) Neovascularization of retina~~
- e) Vitreous haemorrhage

79. What is the most common type of malignant melanoma?

- a) Superficial spreading melanoma
- b) Acral lentiginous melanoma
- c) Lentigo maligna
- d) Nodular melanoma
- e) Mucosal melanoma

80. A 20-year-old man is healthy but has a family history of colon cancer at a young age. There are no abnormal physical examination findings. He undergoes colonoscopy and there are over 200 tubular adenomas ranging in size from 0.2 to 1 cm on gross inspection. Which of the following genetic diseases is he most likely to have?

- a) Hereditary non-polyposis colon carcinoma syndrome
- b) Von Hippel Lindau syndrome
- c) Peutz-Jeghers syndrome
- d) Adenomatous polyposis coli
- e) Multiple endocrine neoplasia

81. All of the following are indications for initiating total parenteral nutrition EXCEPT

- a) Hemodynamic instability
- b) Hyperglycemia (blood glucose > 300 mg/dL)
- c) Hyperosmolality (serum Osm > 350 mOsm/kg)
- d) Severe prolonged ileus
- e) Re-feeding syndrome

82. Wound healing:

- a) Occurs by secondary intention in surgical wounds
- b) Is accelerated by glucocorticoids
- c) Achieves maximal wound strength at two weeks
- d) Does not depend on site or size of wound
- e) In healing by secondary intention involves abundant granulation tissue

83. Which of the following are characteristics of absorbable sutures?

- a) They may be made of catgut and do not normally require removal after the wound has healed
- b) They are commonly used in skin closure of wounds requiring strength after 90 days
- c) They must be removed after wound healing is well under way
- d) They are made of silk, nylon, or Dacron
- e) They are made of monofilament only

84. Pain around the hip with flexion, adduction & internal rotation of lower limb in a young adult after a road traffic accident is suggestive of:

- a) Intra-capsular fracture of the femoral neck
- b) Extra-capsular fracture of the femoral neck
- c) Posterior dislocation of hip
- d) Anterior dislocation of hip
- e) Acetabulum fracture

85. All of the following are indications for admission of a burn wound patient EXCEPT:

- a) 10% superficial burn in child ✓
- b) Scald on the face ✓
- c) 25% first degree burn in an adult
- d) 25% second degree burn in an adult
- e) Burn of the palms ✓

86. Skin graft survival in the first 48 hours is dependent on:

- a) Random connection between host & donor capillaries
- b) Plasmatic imbibition
- c) Saline in dressing
- d) Development of new blood vessels
- e) Inosculation

87. The preferred incision in an adult for abdominal exploration in Blunt abdominal trauma with haemodynamic instability is:

- a) Midline incision
- b) Depending upon the organ
- c) Transverse incision
- d) Paramedian
- e) Pfannenstiel

88. Regarding clavicular fractures, which of the following statements is INCORRECT?

- a) Fracture is commonest in medial third ✓
 - b) Non union is rare
 - c) Most cases can be treated conservatively ✓
 - d) Fracture usually occurs due to indirect injury
 - e) Fracture is common in middle third ✓
- ulnar x*

89. Which of the following is true about Monteggia fractures:

- a) It is usually associated with posterior interosseous nerve paralysis
- b) It can be usually treated conservatively in adults
- c) It is not an injury of children
- d) It is a combination of fracture of radius with distal radio-ulnar joint dislocation ✗
- e) It is a combination of fractures of proximal ulna with dislocation

90. Which of the following statements about extracellular fluid are true?

- a) The total extracellular fluid volume represents 40% of the body weight.
- b) The plasma volume constitutes one fourth of the total extracellular fluid volume. ✓
- c) Potassium is the principal cation in extracellular fluid: ✗ Na^+
- d) The protein content of the plasma produces a lower concentration of cations than in the interstitial fluid.
- e) The interstitial fluid equilibrates slowly with the other body compartments.

91. The intravenous fluid that a 60 kg, 30-year-old woman with an 80% burn should be given in the first 24 hours following burn injury is:

- a) 19.2 litres of 5% glucose in lactated Ringer's.
 - b) 14.4 litres of lactated Ringer's.
 - c) 9.6 litres of hypertonic salt solution (sodium concentration 200 mEq. per litre).
 - d) 7.2 litres of 5% albumin solution.
 - e) 5.5 litres of the pentafraction component of hydroxyethyl starch.
- 60 x 80% x 40 = 1920*
1920 / 120 = 16

92. Which of the following statements about head injuries is/are false?
- a) The majority of deaths from auto accidents are due to head injuries. ✓
 - b) Head injury alone often produces shock. ✓
 - c) A rapid and complete neurologic examination is part of the initial evaluation of the trauma patient. ✓
 - d) Optimizing arterial oxygenation is part of initial therapy. ✓
 - e) Patients with GCS less than 8 should be intubated to protect the airway. ✓
93. In the imaging of a trauma patient, all of the following statements are true EXCEPT?
- a) In a multiply injured patient, CT of head and spine should be the first line of imaging. ✓
 - b) Focused assessment with sonography for trauma (FAST) helps in detecting intraperitoneal fluid and cardiac tamponade. ✓
 - c) CT should not be used when a patient is unstable. ✓
 - d) US is useful for diagnosing occult pneumothorax. ✓
 - e) CT is the main imaging method for intracranial, intra abdominal and vertebral injuries. ✓
94. In scrubbing, which of the following statements is false?
- a) If the surgeon has a suspected infected lesion, it is sprayed with iodine and covered with a sterile dressing before gloving. ✓
 - b) The first scrub of the day should take about 5 min from start to drying. ✓
 - c) A sterile scrubbing brush and nail cleaner are used for 1-2 min at the first scrub provided the surgeon stays within the theatre suite in between cases. ✓
 - d) After applying disinfectant, the arms are washed from distal to proximal with hands up and elbows flexed. ✓
 - e) Drying, using a towel for each side, should start with the fingers and work across the hand and up the arm. ✓
95. Which of the following statements is true in regards to claudication?
- a) Intermittent claudication may be present at rest. ✓
 - b) Intermittent claudication is commonly relieved by getting out of bed. ✓
 - c) Intermittent claudication is most commonly felt in the calf. ✓
 - d) Intermittent claudication distance is usually inconsistent on a day-to-day basis for a given patient. ✓
 - e) Intermittent claudication is thought to be due to nerve compression in the leg muscle compartments. ✓

Choose and match the correct intervention with each of the diagnoses below:

- 96. Sigmoid volvulus C ✓
 - 97. Irreducible inguinal hernia D ✓
 - 98. Adhesive small-bowel obstruction A ✓
 - 99. Faecal impaction EB ✓ SB ✓
 - 100. Signs of peritonitis J ✓
- a) Emergency laparotomy
 - b) Trial with conservative management
 - c) Flatus tube insertion
 - d) Manual disimpaction
 - e) Urgent exploration