

Salter Harris Classification
of Growth Plate Fractures

November 15th, 2011

Abstract

Salter-Harris Classifications are a straightforward and reliable way to diagnose and treat growth plate fractures. There are five types of classifications that are listed by the location of the fracture. This is the most widely used method for classification today since its conception in the 1960s. The importance of this classification system is to accurately diagnose a fracture so the correct method of treatment can be performed swiftly to decrease the chances of growth disturbances and angular growth deformities. The epiphyseal plate is the weakest area in children's anatomy, weaker than their associated ligaments and tendons, causing fractures to occur in the growth plate when trauma occurs.

Salter Harris Classification of Growth Plate Fractures

Identifying fractures of children's growth plates is of monumental importance due to possible growth disturbances. Pediatric patient's bones are still growing allowing the bones to heal faster; this increases the risk for misalignment and callus formations to occur. Radiographic images are used to diagnosis if there is a fracture and what type. If a fracture is hard to find or verify the use of follow-up images, Magnetic Resonance Imaging (MRI), Computed Tomography (CT), and Ultrasound (US) are used (Laer, 2004, p.81). Ever since the Salter and Harris published their article "Injuries Involving the Epiphyseal Plate" in 1963, it has become the most widely used classification system for growth plate fractures. The Salter-Harris system divides fractures into five categories based on the type of damage to the growth plate. With each type of diagnosis a method of treatment regarding the patient can be made. It is important to accurately find the type of fracture in order for the young patient to recover fast and normal (Rockwood, Wilkins, Beaty, & Kasser, 2001, p. 93).

General Overview

Children's bones heal faster than adults due to their stronger periosteum, meaning they are more at risk for misalignment and permanent trauma to the site of injury. Salter-Harris Fractures are categorized by the location of the fracture in one or more of the physis (epiphyseal plate), epiphysis, and metaphysis. The physis is the weakest area in children's anatomy, even weaker than their associated ligaments and tendons. Therefore, when injuries occur that would usually result in only a torn ligament or dislocation for an adult, growth plate fractures occur in children. Growth plate fractures are suspected when the child presents with localized tenderness

and swelling around or near the end of a long bone. Precise diagnosis can only be certain with radiographic images (Salter, 1999, pp. 499-504).

mnemonic: SALTR

S lip of physis	=	type 1
A bove physis	=	type 2 (distal)
L ower than physis	=	type 3 (proximal)
T hrough physis	=	type 4
R ammed physis	=	type 5

A mnemonic used to help remember the five different types of Salter-Harris fractures are given in a manual that is used as a tool that combines multiple radiographic findings to help radiologists locate diagnostic information faster (Dahnert, 2007, p. 87). (See Fig.1)

Fig. 1 mnemonic to help distinguish between Salter-Harris types

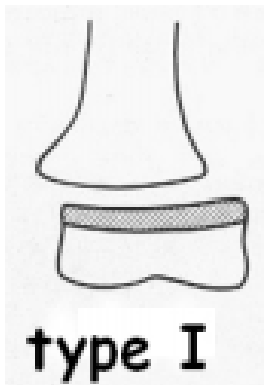
Note: From Dahnert, W. (2007). Philadelphia: Lippincott Williams Wilkins

If the radiograph still appears normal and there is a strong suspicion of a fracture, a comparison radiograph can be made or an alternate modality can be used such as MRI, CT, or US. Dr. Marc Cardinal a licensed radiologist for twenty five years said, “I would choose an MRI follow-up over the other modalities, the reason being the increased diagnostic quality it gives such as the ability to see microfractures, bone contusions, and soft tissue injury around the joint” (personal communication, November 7, 2011).

Growth plate fractures generally occur around the ages 7 through 15, during the peak of growing. “The wide open growth plate largely protects the joint, and the vulnerability of the joint increases significantly as physiological closure of the growth plate progresses” (Laer, 2004, p. 3). Typically males are two times more likely than females to receive a growth plate fracture. Research suggests that upper extremity fractures are more commonly found than lower extremity fractures, typically to the distal radius (Burnei et al., 2010).

Dr. Cardinal lists some common indicators he uses when diagnosing Salter-Harris fractures. They are a) epiphyseal widening shown most clearly in the lateral view b) fracture lines that could be present, specifically the region of pain, and c) the presence of fat pads to indicate swelling (personal communication, November 7, 2011). Treatment for Salter-Harris fractures can be either closed or open reduction, depending on the type, followed by immobilization. Immobilization of the fracture prevents misalignment and protects the adjacent structures around the fracture (Eiff, Hatch, & Calmbach, 1998, p. 20).

Common Salter-Harris Fractures



Type I Salter-Harris fractures occur when there is a complete separation of the entire physis and the surrounding bone is not involved. (See Fig. 2) This fracture is commonly seen when considering growth plate injuries and tends to occur more frequently in younger children. Any radiographic images obtained will more likely than not appear normal due to the physis being radiolucent. Simple closed reduction and

immobilization is needed because healing is rapid in children and the risks after immobilization of complications is extremely low (Salter, 1999, pp. 505-506). Burnei, et al. (2010) explain why it is necessary to immobilize re-aligned fractures. They explain, “It is necessary to use immobilization even if the detachment is not accompanied by displacement, because of the chance of improper growth” (p. 73). Once misalignment has occurred, causing deformity, it would require more invasive measures to try and correct.

Fig. 2 Salter-Harris type I fracture

Note: From “The therapeutic attitude in distal radial Salter and Harris type I and II fractures in children” by G. Burnei et.al 2010, *Journal of Medicine* 3(1), p. 71. Copyright Carol Davila University Foundation. Retrieved October 31, 2011, from <http://www.ncbi.nlm.nih.gov/pmc/articles/PMC3019033/pdf/JMedLife-03-70.pdf>. Copyright Journal of Medicine and Life. Reprinted with permission.

Type II fractures are the most commonly diagnosed and “are usually easily identified on routine radiographs” (Eiff, Hatch, & Calmbach, 1998, p. 257). The fracture exists along the physis and continues up through a small section of the metaphysis. (See Fig. 3) This fracture is triangle-like and the periosteum is torn on the opposite side to where the metaphysis is fractured, but it is still intact on the adjacent side. The intact periosteum makes it easier for physicians to perform a closed reduction without on over-reduction. Since this type of fracture requires more adjustment a local anesthesia is usually required. After

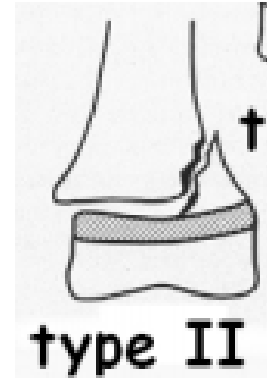


Fig. 3 Salter-Harris type II fracture

Note: From “The therapeutic attitude in distal radial Salter and Harris type I and II fractures in children” by G. Burnei et.al 2010, *Journal of Medicine* 3(1), p. 71. Copyright Carol Davila University Foundation. Retrieved October 31, 2011, from <http://www.ncbi.nlm.nih.gov/pmc/articles/PMC3019033/pdf/JMedLife-03-70.pdf>. Copyright Journal of Medicine and Life. Reprinted with permission.

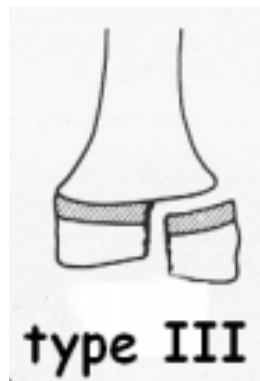


Fig. 4 Salter-Harris type III fracture

Note: From “The therapeutic attitude in distal radial Salter and Harris type I and II fractures in children” by G. Burnei et.al 2010, *Journal of Medicine* 3(1), p. 71. Copyright Carol Davila University Foundation. Retrieved October 31, 2011, from <http://www.ncbi.nlm.nih.gov/pmc/articles/PMC3019033/pdf/JMedLife-03-70.pdf>. Copyright Journal of Medicine and Life. Reprinted with permission.

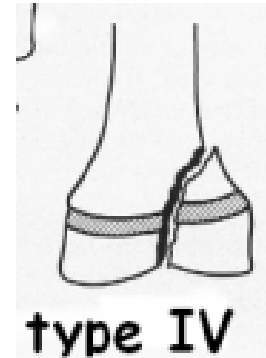
immobilization healing is usually quick and complications are uncommon. This type of fracture generally occurs in older children whose growth plates are relatively thin (Salter, 1999, p. 506). The Thurston-Holland fracture fragment pattern is where there is a visible, small separated fragment of

bone seemingly a bit torn from the growth plate; this sign is also an indication of a type II fracture. (Burnei et al., 2010, p. 71)

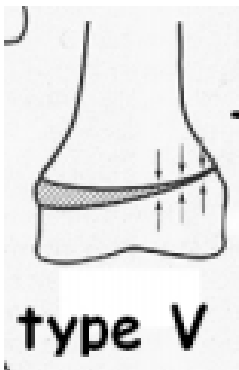
Uncommon Salter-Harris Fractures

Type III fractures run along the joint surface and persist deep into the epiphyseal plate. (See Fig 4) While this fracture is uncommon when they are

diagnosed, it is usually found in the distal tibia of an adolescent whose growth plate is nearly finished. Surgery is usually required to ensure the bones are properly aligned and then the injury is kept immobilized for optimal recovery (Burnei et al., 2010, p. 74). The prospect of recovery is positive as long as the vascular supply to the bones remains intact (Salter, 1999, pp. 506-507).



Type IV fractures start above the growth plate (in the metaphysis) and cut all the way through the epiphysis. (See Fig. 5) “These fractures are usually caused by axial loading or shear stress, comminution is common” (Eiff, Hatch, &



Calmbach, 1998, p. 257). Since this fracture damages the joint cartilage normal growth of the individual may be impaired. Surgery is required in order to properly re-align the joint surface, if not

Fig. 5 Salter-Harris type IV fracture

Note: From “The therapeutic attitude in distal radial Salter and Harris type I and II fractures in children” by G. Burnei et.al 2010, *Journal of Medicine* 3(1), p. 71. Copyright Carol Davila University Foundation. Retrieved October 31, 2011, from <http://www.ncbi.nlm.nih.gov/pmc/articles/PMC3019033/pdf/JMedLife-03-70.pdf>. Copyright Journal of Medicine and Life. Reprinted with permission.

Fig. 6 Salter-Harris type V fracture

Note: From “The therapeutic attitude in distal radial Salter and Harris type I and II fractures in children” by G. Burnei et.al 2010, *Journal of Medicine* 3(1), p. 71. Copyright Carol Davila University Foundation. Retrieved October 31, 2011, from <http://www.ncbi.nlm.nih.gov/pmc/articles/PMC3019033/pdf/JMedLife-03-70.pdf>. Copyright Journal of Medicine and Life. Reprinted with permission.

aligned correctly growth problems will occur. “Close follow-up to monitor for bone-length discrepancies and angular deformities is essential” (Eiff, Hatch, & Calmbach, 1998, p.527).

Type V fractures are diagnosed as a crushing of the epiphysis. (See Fig. 6) This is the hardest fracture type to diagnosis and the most difficult to heal. This injury is most likely to occur in the weight-bearing joints of the knee and ankle. “Crush injuries where complete disruption of the

epiphyseal vascular system has resulted in death of the growth plate cartilage” (Laer, 2004, p.6). This is why type V fractures always have an increased risk of pre-mature fusion. “In the arm this may produce only a cosmetic deformity, but in the leg any consequent inequality of length may cause considerable disability” (Sutton, 1980, p.196). It is very difficult to diagnosis this fracture

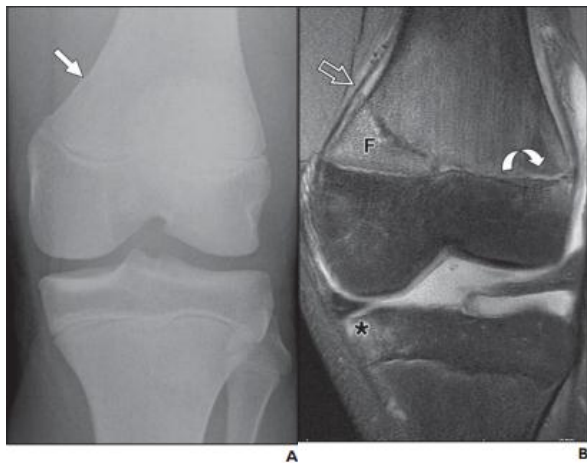


Fig. 7 A 14yr. old boy who presented with hyperextension injury to left knee
 A. AP radiograph reveals only a subtle oblique metaphyseal fracture extending to medial cortex. (arrow)
 B. Coronal image confirms Salter-Harris II fracture with adjacent periosteal elevation (open arrow). Lateral physis is widened with increased fluid (curved arrow). Bone bruise in medial tibial epiphysis and joint effusion (asterisk)

Note: From “Posterior Periosteal Disruption in Salter-Harris Type II Fractures of the Distal Femur: Evidence for a Hyperextension Mechanism” by P. Kleinman, R. Shah, S. Kritsaneepaiboon, M. Murray 2003, *American Roentgen Ray Society*, 193, p. W543. Copyright American Roentgen Ray Society. Retrieved October 31, 2011, from <http://www.ajronline.org/content/193/6/W540.full.pdf+html>

and usually is only caught after months or years have passed and growth arrest has already happened (Eiff, Hatch, & Calmbach, 1998, pp. 257-258). Bar excisions can be a method to help with symmetrical growth if the crushed injury causes the growth plate to stop growing (Lalonde & Letts, 2005, p.144). “Weight bearing must be avoided for at least three weeks in the hope of preventing further compression of the epiphyseal plate” (Salter, 1999, p 507) this is the only preemptive treatment found that does not immediately suggest surgery.

Advantages of MRI

Dr. Cardinal suggests using MRI over other modalities for a follow up exam. MRI beats other modalities in diagnostic quality (especially diagnosing microfractures) and he estimates that when reading an MRI versus a plain film, hard to

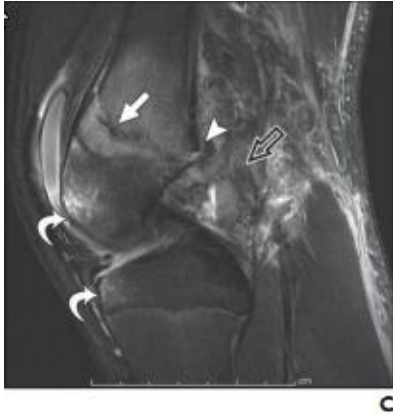

Fig. 7 Sagittal image showing type II fracture line (solid arrow). Posterior physical widening and periosteal (arrowhead) and capsular (open arrow) disruption are evident. Findings pointing to hyperextension injury.

Note: See Fig 7. A & B text box p.8

read Salter-Harris fractures could be diagnosed approximately eighty percent more (Cardinal, personal communication, November 7, 2011).

Kleinman. Shah, Kritsaneepaiboon, and Murray (2009) used MRI images of several patients’ knees to demonstrate the value of MRI exams. (See Fig. 7) The plain film barely shows

a fracture line present whereas in the MRI images it is blatantly evident. They reasoned this choice with, “MRI is a useful supplement to radiography in cases of occult or subtle injuries” (p. W540). The MRI’s on these patients were done because the clinical findings still persisted despite normal plain films. Due to the higher level of diagnostic quality “in

some cases, the findings may be noted only on MRI” (p. W543).

Not only did the MRI show the Salter-Harris type II fracture, but provides a great deal more diagnostic information (See Fig. 7). Having the ability to view in three different planes (coronal, sagittal, and axial) allows physicians the ability to see the fractures from a variety of views, thus analyzing the severity of damage and how it is affecting the joint. This information can be used by the physician and therapists in order to better treat the injury and grant a faster recovery. Furthermore, MRIs provide numerous advantages for follow up studies. The images are clearer and more precise,

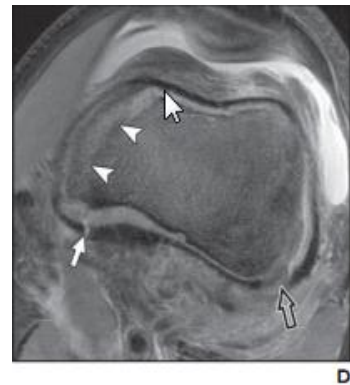


Fig. 7 Axial image shows torn periosteum (solid arrow), Metaphysical fracture (arrowheads), and Posterolateral periosteal disruption (open arrow)

Note: See Fig 7. A & B text box p.8

no radiation is given to the patient, and sedation is not necessary (Rockwood et al., 2001, p. 121).

As radiology increases in the future, the use of MRIs as follow ups for this acute trauma will probably increase. The disadvantage to using MRI is mostly the cost of the procedure and if insurance will cover (Cardinal, personal communication, November 7, 2011).

Commonly Missed Salter-Harris Fractures

The most commonly missed fractures are usually cases of stubbed toes (Cardinal, personal communication, November 7, 2011). “Fractures of the phalanges of the foot in children are uncommon” (Rockwook et al., 2001, p. 1208), these fractures should be treated carefully and not dismissed as a simple stubbed toe. According to Hatch and Hacking (2003) “Most toe fractures are caused by an axial force (e.g., a stubbed toe)” (p. 2413), they are usually non-displaced or minimally angled as well. (See Fig. 8) When trying to clinically assess whether or not a child might present with a fracture instead of a stubbed toe, Hatch and Hacking (2003) suggest:

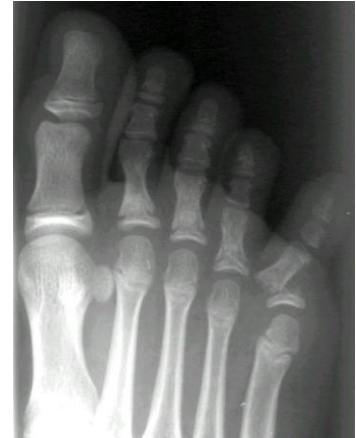

Fig. 8 Displaced Salter Harris type II fracture

Note: From Robert L. Hatch, M.D., M.P.H., University of Florida college of Medicine Reprinted with permission.

Nondisplaced fractures usually are less apparent; however, most patients with toe fractures have point tenderness over the fracture site. The localized tenderness of a contusion may mimic the point of tenderness of a fracture. Application of a gentle axial loading force distal to the injury (i.e. compressing the distal phalanx toward the foot) may distinguish contusions from fractures. If this maneuver produces sharp pain in a more proximal phalanx, it suggests a fracture in that phalanx. (p. 2414)

Hatch and Hacking (2003) advises treatment to include splinting with a simple Buddy taping technique or in more active children; a rigid-sole shoe can be used to keep fracture stable. Aligning the nail-bed is important to ensure that there is not a chance of rotation; it is useful to use the opposite toe for comparison. Treatment should continue until point tenderness is resolved, usually at least 3 weeks. Radiographic images should be taken approximately three to five days after treatment to confirm proper alignment (pp. 2417-2418).

Conclusion

Since children's bones heal faster than adults, prompt and accurate identification of growth plate fractures is critical. While Salter-Harris type II fractures are the most commonly seen and diagnosed, types III, IV, and V involve growth plate disturbances. These three types often require surgery and follow-up imaging in order to guarantee no growth disturbances. Other modalities allow for more diagnostic information on whether or not a fracture is present, MRI being the best diagnostically. Treatment includes closed or open reduction to re-align the epiphyseal plate and immobilization to protect the fracture while it is healing. One of the most difficult growth plate fracture(s) to identify occurs in the distal phalanges of the foot. Without an immediate diagnosis a child's bones could heal wrong causing permanent misalignment, or the growth plate could be so damaged that growth will stop.

References

- Burnei, G., Gavriiliu, S., Georgescu, I., Vlad, C., Drăghici, I., Hurmuz, L., et al. (2010). The therapeutic attitude in distal radial Salter and Harris type I and II fractures in children. *Journal of Medicine and Life*, 3(1), 70-75. Retrieved October 31, 2011, from <http://www.ncbi.nlm.nih.gov/pmc/articles/PMC301033/pdf/JMedLife-03-70.pdf>
- Dahnert, W. (2007). *Radiology review manual* (6th ed.). Philadelphia: Lippincott Williams Wilkins.
- Eiff, M.P., Hatch, R., & Calmbach, W.L. (1998). *Fracture management for primary care*. Philadelphia: W.B. Saunders Company.
- Hatch, R., & Hacking, S. (2003). Evaluation and Management of Toe Fractures. *American Family Physician*, 68(12), 2413-2418. Retrieved November 7, 2011, from <http://www.aafp.org/afp/2003/1215/p2413.pdf>
- Kleinman, P., Shah, R., Kritsaneepaiboon, S., & Murray, M. (2009). Posterior Periosteal Disruption in Salter-Harris Type II Fractures of the Distal Femur: Evidence for a Hyperextension Mechanism. *American Journal of Roentgenology*, 13, W540-W54. Retrieved October 31, 2011, from doi:10.2214/AJR.09.2353
- Laer, L. V. (2004). *Pediatric fractures and dislocations*. Stuttgart: Thieme.
- Lalonde, K., & Letts, M. (2005). Traumatic growth arrest of the distal tibia: a clinical and radiographic review. *Canadian Journal of Surgery*, 48(2), 143-147.
- Rockwood, C.A., Wilkins, K.E., Beaty, J.H., & Kasser, J.R. (2001). *Rockwood and Wilkins' fractures in children* (5th ed.). Philadelphia, Pa.: Lippincott Williams & Wilkins.
- Salter, R.B. (1999). *Textbook of disorders and injuries of the musculoskeletal system* (rd ed.). Baltimore, Md.: Williams & Wilkins.

Sutton, D. (1980). *A Textbook of radiology and imaging* (3rd ed.). Edinburgh; New York: Churchill Livingstone.